





THE AMERICAN JOURNAL

OF

ANATOMY

EDITORIAL BOARD

CHARLES R. BARDEEN
University of Wisconsin

HENRY H. DONALDSON
The Wistar Institute

SIMON H. GAGE
Cornell University

G. CARL HUBER
University of Michigan

GEORGE S. HUNTINGTON
Columbia University

J. PLAYFAIR McMURRICH
University of Toronto

GEORGE A. PIERSOL
University of Pennsylvania

HENRY MCE. KNOWER, SECRETARY
University of Cincinnati

VOLUME 25
JANUARY—JULY
1919

THE WISTAR INSTITUTE OF ANATOMY AND BIOLOGY
PHILADELPHIA, PA.

CONTENTS

No. 1. JANUARY

GEORGE L. STREETER. Factors involved in the formation of the filum terminale. Three text figures.....	1
J. A. BADERTSCHER. The ultimobranchial bodies in postnatal pigs (<i>Sus scrofa</i>). Four figures.....	13
FRANK ADAM MCJUNKIN. The origin of the phagocytic mononuclear cells of the peripheral blood. Eleven figures.....	27
H. D. SENIOR. The development of the arteries of the human lower extremity. Eleven figures.....	55

No. 2. MARCH

C. H. DANFORTH. The developmental relations of brachydaactly in the domestic fowl. Five figures.....	97
DELLA DRIPS. Studies on the ovary of the spermophile (<i>Spermophilus citellus tridecemlineatus</i>) with special reference to the corpus luteum. Twenty-nine figures.....	117
ROYAL NORTON CHAPMAN. A study of the correlation of the pelvic structure and the habits of certain burrowing mammals. Five plates (twenty-six figures).....	185

No. 3. MAY

C. M. JACKSON. The postnatal development of the suprarenal gland and the effects of inanition upon its growth and structure in the albino rat. Ten figures.....	221
JOHN C. DONALDSON. The relative volumes of the cortex and medulla of the adrenal gland in the albino rat. Four charts.....	291
FRANKLIN PARADISE JOHNSON. The development of the lobule of the pig's liver. Twenty-eight figures.....	299
LUCILE WITTE. Histogenesis of the heart muscle of the pig in relation to the appearance and development of the intercalated discs. Two plates (eighteen figures).....	333

No. 4. JULY

EDWARD PHELPS ALLIS, JR. The homologies of the maxillary and vomer bones of <i>Polypertus</i> . Three plates (eighteen figures).....	349
J. A. MYERS. Studies on the mammary gland. IV. The histology of the mammary gland in male and female albino rats from birth to ten weeks of age. Nineteen figures (eleven text figures and two plates).....	395
H. E. JORDAN. The histology of the blood and the red bone-marrow of the leopard frog, <i>Rana pipiens</i> . Two plates (seventy-three figures).....	437

FACTORS INVOLVED IN THE FORMATION OF THE FILUM TERMINALE

GEORGE L. STREETER

*From the Department of Embryology, Carnegie Institution of Washington,
Baltimore, Maryland*

THREE TEXT FIGURES

In a study recently published by the writer¹ on the development of the cartilaginous capsule of the ear in human embryos it was pointed out that the changes in size and form which the capsule undergoes during its development are accomplished not only by a progressive differentiation, but also in part by a retrogressive differentiation of its constituent tissues. The margins of the cartilaginous cavities are in a continual state of change; they exhibit an unstable equilibrium between two opposing tendencies: on one hand, toward the deposit of new cartilage, and on the other, toward the excavation of the old. The margins thereby are always advancing or receding, and as a result of this there is provided a suitable suite of chambers for the contained membranous labyrinth in all stages of its development.

It is the feature of retrogressive differentiation or dedifferentiation that I wish particularly to recall here. The fact that certain areas of cartilaginous tissue revert to an earlier embryonic type and are subsequently redifferentiated into a tissue of a widely different histological character, is very clearly shown in the case of the otic capsule, and is a factor of great embryological significance. Such a process of retrogressive change, combined with redifferentiation of the same tissue, greatly increases the facilities for and the range of certain structural

¹ Streeter, G. L., 1917. The factors involved in the excavation of the cavities in the cartilaginous capsule of the ear in the human embryo. *Amer. Jour. Anat.*, vol. 22.

adjustments that occur in many regions in the development of the human embryo.

Another instance of dedifferentiation has recently been pointed out by Kunitomo.² This writer has published the results of a careful study of the tail region in a large number of human embryos, representing the period of greatest development of the caudal appendage, and also the later period of its gradual reduction. He shows that in very young specimens the spinal cord reaches the extreme tip of the tail and throughout its length is quite uniform in structure. Somewhat later (11 to 15-mm. stage) it can be divided at about the level of the thirty-second vertebra into two parts—a cranial or main part, having a wide central canal and thick walls in which can be recognized well-developed mantle and marginal zones, and a caudal slender part, having a narrow canal with walls consisting only of an ependymal zone. Kunitomo shows that it is this caudal atrophic portion that eventually forms the filum terminale. The main part lying cranial to the thirty-second vertebra undergoes uninterrupted and progressive differentiation, whereas the portion caudal to this undergoes regressive changes and, with the exception of the extreme tip, finally becomes converted into a fibrous strand, the tip forming the coccygeal medullary vestige. This, therefore, is another instance in which an absorptive adjustment is brought about by the reversion of the tissue to an earlier embryonic type with a certain amount of subsequent redifferentiation.

Kunitomo further calls attention to the fact that in the formation of the filum terminale, in addition to the dedifferentiation of the caudal end of the medullary tube, there is also the mechanical disproportion between the growth of the medullary tube and that of the vertebral column. How much of one and how much of the other of these two factors is responsible for the further development of the filum terminale was not determined by him. It has occurred to the writer that this question could be answered by the determination of the elongation of the nerve

² Kunitomo, K., 1918. The development and reduction of the tail and of the caudal end of the spinal cord in the human embryo. Contributions to Embryology, vol. 8, Publication No. 271, Carnegie Inst. of Wash.

roots. In the younger stages the spinal cord and the vertebral column lie alongside of each other in a metameric manner, corresponding in position segment for segment. Owing to their disproportion in growth, there occurs a relative displacement of their segment levels, so that, for instance, the thirtieth segment of the cord comes to lie opposite the twentieth segment of the vertebral column. The segment levels of the vertebral column are, of course, evident; in the spinal cord they are just as plainly marked by the attachment of the nerve roots, for these become attached to the cord before the displacement begins, and thus permanently mark the various segmental levels. In the case of each segment of the spinal cord there are two fixed topographical points: the spinal ganglion, which is held in the intervertebral foramen and registers the original position of the segment relative to the vertebral column, and the place at which the dorsal root is attached to the cord and which moves as the cord moves. By locating those points for the different stages one can determine the exact elongation of the nerve roots, and this in turn is the index of the relative displacement of the spinal cord as regards the vertebral column. Conversely, it will be seen that the alteration not explained by mechanical displacement must be attributed to the retrogressive changes referred to above. The determination of the amount of displacement was made by comparison of selected stages by means of profile reconstructions of the smaller specimens and actual dissection of the older ones. I was assisted in this by Mr. James F. Didusch, of the Carnegie Embryological Laboratory, who made careful dissections of these structures in several older fetuses, two of which will be used for illustration. The results of this determination are given in the following note as a matter of interest to those who have read the paper by Kunitomo, and also because it offers an opportunity to emphasize the significance of dedifferentiation of tissues in the processes of development in the human embryo.

The part played by dedifferentiation in the caudal region of the spinal cord is more apparent in the younger stages of development, as pointed out by Kunitomo. The so-called 'absorption' of the tail is completed before the embryo reaches a length of

30 mm. It is also well known that the remodeling which takes place in the gill region completes the obliteration of the gill bars before the embryo is 20 mm. long. One well might expect these processes of dedifferentiation and redifferentiation to be more active in the earlier stages. They are not confined, however, to this period, for in the case of the ear capsule they were found to be very active throughout fetal life. In the case of the spinal cord dedifferentiation is well demonstrated in the period represented by embryos between 11 and 30 mm. long. A comparison of these two stages can be made in figure 1. It will be noted in the first place that the spinal ganglia show a regression varying from arrest in development to complete disappearance. All but two of the coccygeal ganglia have disappeared in the 30-mm. specimen, and the remaining two are of about the same size as the same two ganglia in the 11.5-mm. specimen.³

As for the cord itself, the changes are equally marked. In the younger stage (embryo 11.5 mm. long) the extreme caudal end of the spinal cord, the part belonging to the non-vertebrated tail, shows little differentiation, consisting only of indifferent cells resembling embryonic ependyma. In the coccygeal region, however, the development is more advanced. Opposite the five coccygeal ganglia the wall of the cord is differentiated into distinct ependymal, mantle, and marginal zones, with well-developed rootlets entering into it from the first two ganglia. Sections through it show nothing to indicate that this region is not going on to complete its differentiation into the adult condition. When, for comparison, one examines the very same region in the older specimens (fig. 1, embryo 30 mm. long) it is found that its condition, relative to the remainder of the cord, has undergone a marked change. While the precoccygeal cord has continued to increase in the thickness of its walls and in the elaboration of the mantle and marginal zones, the coccygeal region is less advanced

³ Throughout this paper the twenty-fifth to the twenty-ninth segments have been uniformly regarded as sacral. The slight variation which is known to exist in this respect is too small to be taken into account in our general conclusions, and for convenience the regional terms, lumbar, sacral, and coccygeal, will be used, upon the assumption that the specimen concerned has the usual regional distribution of its segments.

in its development than it was in the younger stage. Whereas in the 11-mm. embryo there existed a distinct elaboration into ependymal, mantle and marginal zones, the mantle zone is completely missing in the 30-mm. embryo, and we find thin walls consisting only of ependymal cells covered by a thin marginal zone. The coccygeal spinal cord in the 30-mm. embryo is in an earlier embryonic state than that of the 11.5-mm. embryo; that

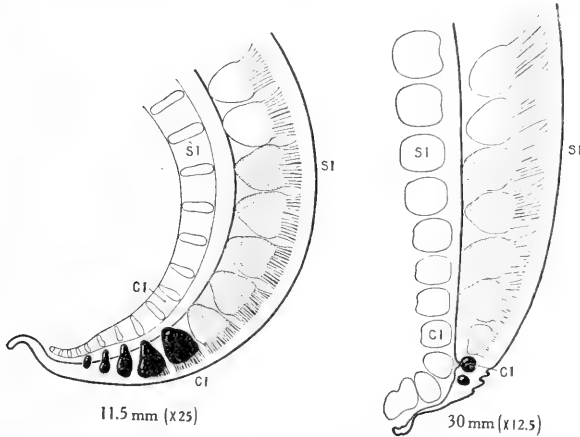


Fig. 1 Profile reconstructions showing the spinal ganglia and their dorsal roots in the tail region of the human embryo. The last two lumbar ganglia are shown in white, the sacral ganglia are stippled, and the coccygeal ganglia are solid black. It will be noted that in the period included between these two stages marked regressive changes have affected the entire coccygeal region of the spinal cord, with complete disappearance of the last three coccygeal ganglia, in sharp contrast to the sacral region of the cord, which undergoes uninterrupted development. The reconstructions are taken from embryos No. 544, 11.5 mm. long, and No. 75, 30 mm. long, belonging to the Carnegie Collection.

is, it has undergone dedifferentiation. In later stages the process goes still farther and, as has been pointed out by Kunitomo, this ependymal tube eventually becomes converted or redifferentiated into a fibrous strand.

How much of the spinal cord is involved in this retrograde process can be seen by comparing the two stages shown in figure 1. In the region of the attachment of the fifth sacral nerve the wall of the cord remains thick and develops a well-

differentiated mantle zone. About opposite the first coccygeal nerve in the 30-mm. embryo the mantle zone abruptly disappears, and there is a corresponding enlargement of the lumen of the cord, thereby producing the thin-walled *ventriculus terminalis*. There is some variation in different embryos as to the segmental level caudal to which the mantle zone has dedifferentiated and also in the manner of transition from the well-developed sacral cord into the atrophic coccygeal cord, including sometimes the doubling or partial obliteration of the central canal. The transition is quite abrupt, involving only one segment. In the 30-mm. embryo in figure 1 the cord at the level of the first coccygeal nerve shows some decrease in the size of its mantle-zone area. Opposite the second coccygeal nerve the mantle zone is entirely gone. The second coccygeal ganglion present in this case would probably soon have disappeared.

The *ventriculus terminalis* at this stage tapers caudally and may be said to extend to the third coccygeal segment. Caudal to this the differentiation of the cord is more complete and results in the gradual obliteration of the lumen and the replacement of the *ependymal substance* by a fibrous strand, embedded in which can be found isolated groups of persistent *ependymal cells*. At its extreme tip there is often found a more or less detached group of such cells which undergoes cystic enlargement and constitutes the coccygeal medullary vestige. The interval of cord lying between this and the *ventriculus terminalis* constitutes what is later known as the *filum terminale*. Thus far its formation is based upon the process of dedifferentiation; its subsequent growth and elongation is accomplished by an interstitial increase of its constituent fibres, and not by the further invasion of the process of dedifferentiation into the sacral region of the cord. This will become evident on examination of figure 2.

It has been pointed out that in embryos 30 mm. long a *ventriculus terminalis* is formed opposite the second and third coccygeal vertebrae, owing to a retrogressive thinning out of the walls of the spinal cord, with a consequent irregular enlargement of the central canal. In fetuses with a crown-rump

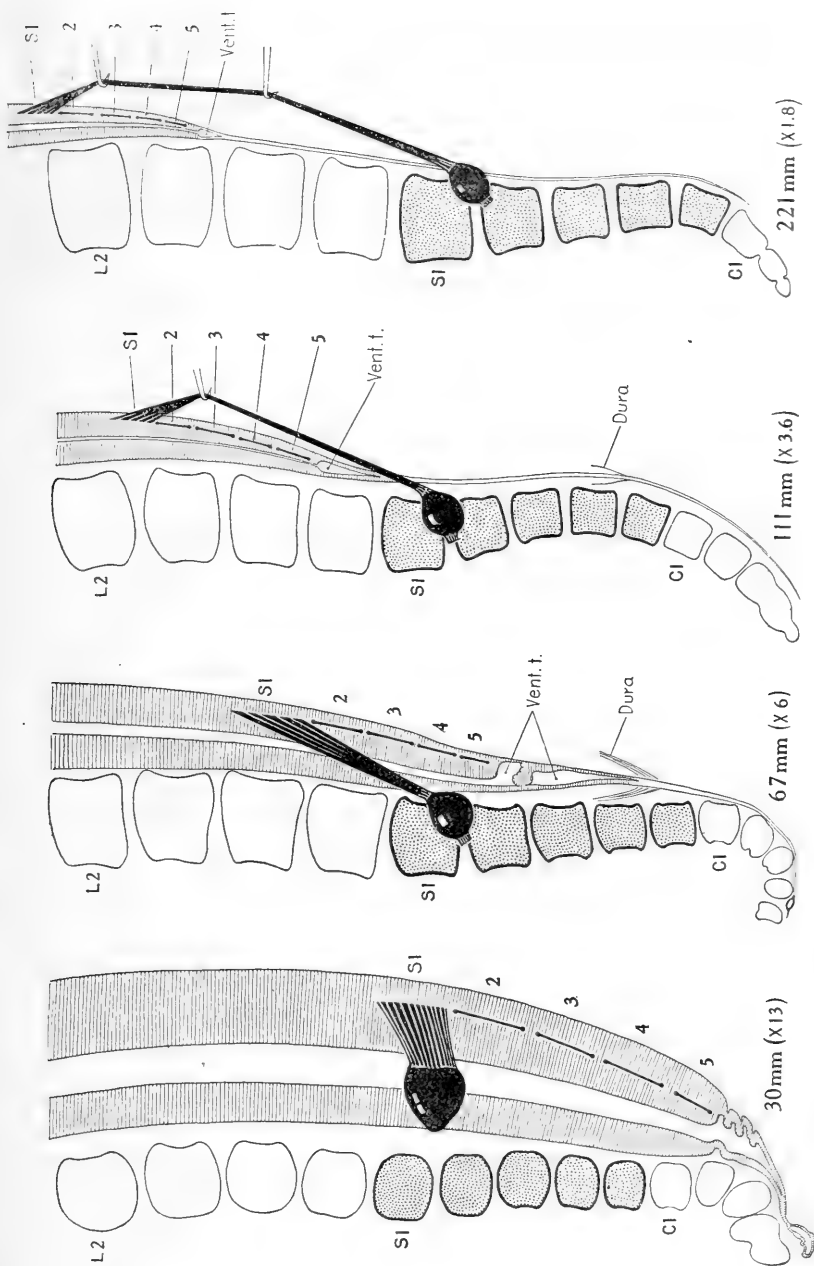


Fig. 2 Topographical relations of the caudal end of the spinal cord in the human fetus from the eighth to the twenty-fifth week. Comparison of these stages shows the rate and extent of caudal displacement of the vertebral column, in relation to the terminal ventricle and the attachment of the sacral nerve roots, which constitute definite and fixed points on the spinal cord. In each case the dorsal root of the first sacral nerve is drawn in, and the attachment of the dorsal roots of the other sacral nerves is shown by heavy lines. The twenty-fifth to twenty-ninth vertebræ were regarded as sacral vertebrae, irrespective of form, as shown in stipple. The fetuses are listed in the Carnegie Collection as follows: No. 75, 30 mm.; No. 1656, 67 mm.; No. 1073, 111 mm.; No. 1345, 221 mm. The first two are from profile reconstructions, the last two from dissections.

length of 100 to 200 mm. the *ventriculus terminalis* can be recognized in gross dissection with the naked eye, as a piriform, translucent area at the tip of the *conus medullaris*. Apparently in the natural condition it presents smooth outlines, but in prepared sections its thin walls are thrown into what are evidently shrinkage folds. This ventricle bears a permanent relation to the rootlets of the fifth sacral nerve at their entrance into the cord, as is shown in figure 2. In the four stages there represented it lies just caudal to the entrance of the fifth sacral nerve. The rootlets of the first coccygeal nerve in these specimens were so delicate that they could not be traced with certainty and were therefore omitted. The roots of the five sacral nerves, however, could be very accurately followed, and are all indicated in the figures. Their entrance into the substance of the cord constitutes in each case a firm attachment and remains a fixed topographical point. By comparing the four stages from 30 mm. to 221 mm. it will be seen that the *ventriculus terminalis* and the points of attachment of the sacral roots maintain the same relative positions, there being no further encroachment of the former into the territory of the more cephalic lying spinal cord. In other words, there is no further dedifferentiation of the sacral region of the cord after the embryo has attained a length of 30 mm. The cephalic migration that is subsequently experienced by the *ventriculus terminalis* and points of attachment of the sacral nerve roots, relative to the bodies of the vertebrae, is clearly a result of the fact that the vertebral column gradually extends farther caudalward than the spinal cord, and since the nerve roots and the *filum terminale* are attached at both ends they are correspondingly elongated. The latter process is not a simple stretching, for, as these structures lengthen they actually become thicker. In other words, there is a compensatory interstitial growth. This increase in thickness is not apparent in figure 2, as the older stages are shown at a progressively decreasing scale of enlargement.

The rapidity and extent of the caudal thrust of the vertebral column—that is, its caudal displacement in relation to the terminal ventricle—can be seen in figure 2. This covers a little

over the first half of fetal life (twenty-five weeks). In the adult the corresponding points fall at the interval between the bodies of the first and second lumbar vertebrae. Thus in the first twenty-five weeks there is an ascent of the ventriculus terminalis from the level of the second coccygeal to the third lumbar vertebra, or a distance of nine segments, and there remain but two segments before the adult position is reached. One may say that the principal part of the migration is accomplished during the first half of fetal life.

The dura mater and its relations can be plainly recognized in the 67-mm. fetus, where it can be seen to reach and adhere to the filum terminale at the lower border of the fourth sacral vertebra, thereby sealing off the lower end of the subdural space. It is of interest to note that it undergoes very little change from its position here and that which it occupies in the adult. In the 111-mm. fetus it extends to about the same level and ends in the same manner. In the adult it terminates about two segments higher up. Thus the dural sac conforms more to its bony environment than does the spinal cord and shows very little of the migratory adjustment of position that is noted in the latter. We therefore find the ventriculus terminalis gradually receding cranialward from the caudal end of the sac.

In figure 2 the specimens are enlarged upon a decreasing scale of magnification according to age, so that the segments of the different stages are brought to about the same size. This has been done in order to facilitate the comparison of segment levels. The actual elongation of the spinal root of a given nerve is greater, therefore, than would appear from the figure. Measurements of the dorsal root of the first sacral nerve from the margin of the ganglion to the point of entrance into the cord yield the following figures: 30-mm. fetus, 0.65 mm. long; 67-mm. fetus, 4.75 mm. long; 111-mm. fetus, 12.25 mm. long; 221-mm. fetus, 32 mm. long.

The actual elongation of the first sacral root is indicated for the first three of these stages in figure 3, in which the topography of the spinal cord and the vertebral column is drawn on the same scale of enlargement. The dorsal root of the first sacral nerve

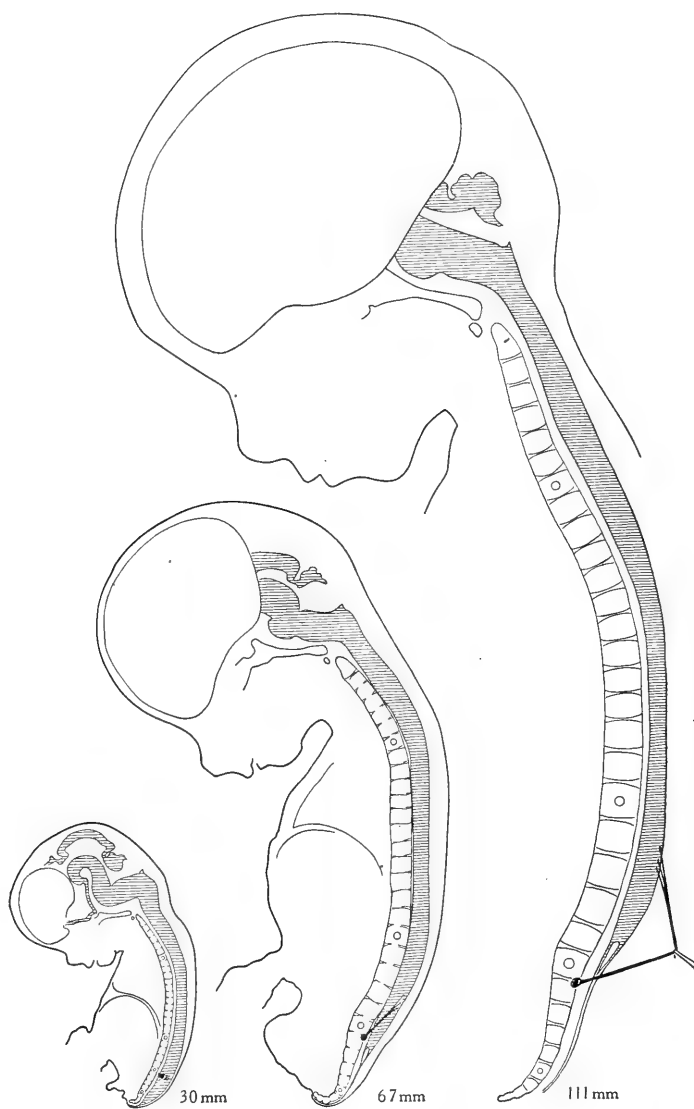


Fig. 3 Topography of the spinal cord and the dorsal root of the first sacral nerve in three fetal stages. These are taken from three of the same specimens shown in figure 2, but here they are shown on one scale of enlargement in order to indicate the actual changes in size. The 30-mm. specimen is shown both in figure 2 and figure 1.

is indicated by a heavy black line; the first thoracic, first lumbar, first sacral, and first coccygeal vertebrae are marked by small circles. Comparison of the stages, as shown in this figure, gives perhaps a better representation of the actual topographical changes that occur in this apparent ascent than does figure 2.

From these results we may conclude that in the human embryo the greater part of the coccygeal and post-coccygeal cord—that is, the part caudal to the thirtieth segment—undergoes dedifferentiation, the more cephalic part of it persisting as the *ventriculus terminalis* and the more caudal part redifferentiating into a fibrous strand—the *filum terminale*, with the coccygeal medullary vestige at the tip. The first twenty-nine segments of the spinal cord are not affected by this process of dedifferentiation, but continue in a progressive development. When the embryo reaches 30 mm. in length there begins a disproportion in the rate of growth as between the vertebral column and the spinal cord, the former elongating more rapidly than the latter. This results in a relative displacement of the two, the *ventriculus terminalis* in the 221-mm. fetus (twenty-five weeks) lying nine segments higher than it did originally, and by the time the adult form is attained two more segments have been added to this disproportion. We may say, therefore, that the *filum terminale* represents that portion of the spinal cord caudal to the second coccygeal segment (thirty-first segment), which has undergone dedifferentiation and has finally become converted into a fibrous strand. This strand, like the sacral nerve roots, elongates by interstitial growth in adaptation to the ascending displacement of the spinal cord. The caudal tip of the dural sac maintains its relation to the vertebrae rather than to the spinal cord and remains attached to the *filum terminale* in the sacral region at a more or less fixed point.

Resumido por el autor, J. A. Badertscher.

Los cuerpos últimobranquiales después del nacimiento en el cerdo (*Sus scrofa*).

Una porción de los cuerpos últimobranquiales puede persistir durante largo tiempo en la glándula tiroídes del cerdo, después del nacimiento. En cerdos hasta de 56 días de edad, están formados por áreas de cordones sincitiales nucleados y masas en las cuales está comenzando a formarse materia coloide, o por áreas en las cuales los folículos son pequeños pero con la estructura típica de la glándula tiroídes. La porción central de algunas de las áreas sincitiales está desprovista de coloide. Un área alargada de pequeños folículos que contienen coloide, la cual representa probablemente un cuerpo últimobranquial, fué encontrada por el autor en dos entre tres glándulas tiroídes de cerdos subadultos. Los cuerpos últimobranquiales están colocados generalmente en la mitad posterior de la glándula tiroídes, cerca de su borde dorsal o dorso-lateral. Es imposible determinar exactamente la proporción relativa en que los cuerpos últimobranquiales y el esbozo tiroideo medio contribuyen a la formación de la glándula tiroídes. A causa del comportamiento variable durante el desarrollo, por parte de los cuerpos últimobranquiales, la proporción relativa en que dichos cuerpos contribuyen a la constitución de la glándula tiroidea es indudablemente variable en diferentes cerdos. Es sin embargo evidente que solo una pequeña porción de la glándula deriva de los cuerpos últimobranquiales. Folículos excepcionalmente grandes (cistoideos) abundan en algunas de las tiroídes examinadas. De un modo general puede decirse que la situación de estos folículos está limitada a la porción de la tiroídes en la cual se encuentran generalmente los cuerpos ultimobranquiales, es decir, en la mitad posterior de la glándula.

Translation by Dr. José F. Nonidez,
Columbia University

THE ULTIMOBRANCHIAL BODIES IN POSTNATAL PIGS (*SUS SCROFA*)

J. A. BADERTSCHER

From the Department of Anatomy, Indiana University, Bloomington, Indiana

FOUR FIGURES

In a recent study ('18) of the ultimobranchial bodies in a wide range of successively older developmental stages of pig embryos (before their fusion with the median thyroid anlage to full term), the writer was convinced that these bodies contribute to the structural elements of the thyroid gland. The time at which they are completely transformed into typical thyroid structures, that is, when they can no longer be recognized structurally from the median thyroid anlage, varies greatly. Even in a full-term embryo a portion of the ultimobranchial bodies may be free from colloid. It thus became evident that in order to follow out a more complete developmental history of these structures, the thyroid gland of postnatal pigs must be examined.

The material used for this investigation was obtained from a litter of pigs and from three young adult hogs (age unknown). The pigs were killed at the following ages: one a few hours after birth, one 7.5 days old, one 15 days old, one 28 days old, one 42 days old, and one 56 days old. The thyroid and a portion of the trachea were removed from the pigs, while only the thyroid was removed from the adults. All the material was fixed in Zenker's fluid and imbedded in paraffin. The thyroid glands of the pigs were cut transversely into sections 15μ in thickness, all the sections were mounted in serial order, and stained with eosin and Unna's alkaline methylene-blue solution. The thyroid gland of the adults were cut transversely into sections 20μ thick, only every fifth section was mounted, and stained with hematoxylin and eosin.

In the description of the following stages special attention will be given: 1) to the structure of the ultimobranchial bodies and to their location in the thyroid gland, and 2) to the location and extent of areas of unusually large (cystoid) follicles. Since in the embryonic material it was found that cystoid follicles may develop in the ultimobranchial bodies, the latter consideration is of importance.¹

Pig at birth. The thyroid gland is 9.3 mm. long and its greatest width is 4.8 mm. Caudally it terminates in a rather blunt point, while the anterior portion is drawn out into a slender streamer. The greater portion of the bulk of the gland is thus located in its posterior half. The more bulky part of the gland is crescent in shape in transverse sections. In the middle third of the left lateral half of the thyroid gland the ultimobranchial body is represented by three small areas which are composed of tortuous syncytial cords and masses quite closely packed together. These areas are embedded beneath the dorsal surface of the gland lateral to its medial plane, a position usually occupied by the ultimobranchial bodies in the later embryonic stages. Anterocaudally, they extend through eight, six, and twelve consecutive sections, respectively. The most anteriorly located of these areas is free from colloid and lies in a field of follicles that are on an average smaller than the average size of the majority of follicles present in the thyroid gland. In the central and caudal areas the colloid is just beginning to form. On account of the absence of colloid in one and its scanty amount in the other two of these areas, they stand out sharply from the thyroid follicles immediately surrounding them. No difference could be observed between the structure of the nuclei in these areas and the nuclei in the cells composing the follicles. In the right lateral half of the thyroid gland the ultimobranchial body is absent.

¹ As this work is practically a continuation of a previous investigation ('18) by the author of the ultimobranchial bodies in pig embryos, it was deemed unnecessary to repeat an historical sketch of this subject in this article. Also the bibliography includes only those references to articles in which may be found more or less definite statements concerning the fate of the ultimobranchial bodies. If an extensive bibliography on this subject is desired, reference should be made to the works of Verdun ('98) and Grosser ('12).

Unusually large follicles are present in both lateral halves of the caudal fourth of the thyroid gland. These are located mainly near the dorsal and dorsolateral surface of the gland. A few very large follicles are located near the most caudally located area of the ultimobranchial body. Also an area of very large follicles (extending through a series of thirty-four sections) is present in the caudal portion of the middle third of the right lateral half of the thyroid gland just below its dorsal surface.

Fig 7.5 days old (fig. 1). The thyroid gland is 15 mm. long and its greatest width is 6.8 mm. The greater portion of the anterior half of the thyroid gland is in form a slender band, so that by far the greater portion of its bulk lies in the posterior half of the gland. The more bulky portion of the gland is crescent in shape in transverse section. Traces of both ultimobranchial bodies are present in the caudal fourth of the thyroid gland. The left one is represented by three oblong areas composed of closely packed syncytial cords and masses which are almost free from colloid. The nuclei in the syncytium have a structure identical to the structure of the nuclei in the cells composing the follicles. Anterocaudally, these areas extend through nineteen, seven, and thirty consecutive sections, respectively. The most anteriorly (fig. 1, *U.*) and caudally located of these areas are partially exposed to the free surface on the dorsal border of the thyroid gland, while the centrally located one is embedded only a short distance below the dorsal surface of the gland. The ultimobranchial body on the right side has a structure similar to the left one. It extends through a series of ten sections and is entirely embedded below the dorsal surface of the thyroid gland.

In the left lateral half of the thyroid gland and just anterior to the ultimobranchial body represented in figure 1 is the caudal termination of an elongated area containing many large (cystoid) follicles. This area of large follicles is located just below the dorsal border of the thyroid gland and extends through seventy consecutive sections. Very large follicles are also found in the immediate neighborhood of the centrally located area of the ultimobranchial body. Two rather large follicles lie near

the right ultimobranchial body. A few large follicles are found near the caudal end of the thyroid gland.

Pig 15 days old (fig. 2). The thyroid gland is 10.5 mm. long and its greatest width is 6.3 mm. It tapers to a blunt point at each end. Only the right ultimobranchial body is present. It is embedded deeply below the dorsal surface in the posterior half of the thyroid gland. It is represented by two areas which are composed of syncytial cords and masses in which follicles containing colloid are quite numerous, but on an average much smaller than the majority of follicles in the immediate neighborhood of these areas. The more anteriorly located and larger of these areas (fig. 2, *U.*) extends through a series of eighty-five sections, while the more caudally located one extends through sixteen consecutive sections. Thirty-six sections intervene between the two areas. The structure of the nuclei in these areas is identical to that of the nuclei in the cells composing the follicles. In the caudal fourth of the thyroid gland there are many very large follicles which are located chiefly in the dorso-lateral margin of the gland.

Pig 28 days old. The thyroid gland is 11.1 mm. long and its greatest width is 7.7 mm. It tapers to a blunt point at each end and its more bulky portion is crescent in shape in cross-section. Both ultimobranchial bodies are present. They are located just below the dorsal surface in the caudal portion of the middle third of the thyroid gland, lateral to its medial plane. The right one is similar in structure to the ultimobranchial body in the thyroid gland of the 15-day-old pig. It extends through a series of sixteen sections. The left ultimobranchial body is composed largely of an attenuated syncytial mass in which are found a few small follicles. It extends through a series of thirty-eight sections.

In the immediate neighborhood of the left ultimobranchial body are found a few very large follicles. Many very large follicles are present in the caudal fourth of the thyroid gland. These are located chiefly near the dorsal and dorsolateral border of the gland, excepting near its caudal end where they are scattered throughout the entire thickness of the gland.

Pig 42 days old (fig. 3). The thyroid gland is 14.6 mm. long and its greatest width is 7.3 mm. It tapers to a point at each end and, excepting near its ends, is crescent in shape in transverse section. The ultimobranchial body on the right side is located midway between the two ends of the thyroid gland and is embedded just below the dorsal surface of the gland lateral to its medial plane. It extends through a series of twenty-six sections and is composed of syncytial cords and masses. In both ends and in the peripheral portion of this structure the follicles are quite numerous but comparatively small, while in places its center is free from colloid. The ultimobranchial body on the left side is located in the anterior portion of the caudal fourth of the thyroid gland and is embedded just below the dorsal surface of the gland lateral to its medial plane. It extends through fifty-four consecutive sections and has a structure (fig. 3, *U.*) similar to the right one. In place it is almost separated from the rest of the thyroid gland by connective tissue.

An area of large follicles in the right lateral half of the thyroid gland extends anteriorly from the ultimobranchial body. This area of large follicles is located chiefly just below the dorsal border of the gland, but in places it extends to its dorsolateral margin. In the dorsolateral portion of the middle third of the left lateral half of the thyroid gland is an area, variable in width, of very large (cystoid) follicles. Near the caudal portion of the anterior third of the thyroid gland these areas of large follicles become continuous just below its dorsal surface and gradually extend more deeply into the gland so that large follicles are found throughout its extreme anterior portion. No follicles of an unusually large size are found in the extreme caudal portion of the thyroid gland.

Pig 56 days old. The thyroid gland is 13.5 mm. long and its greatest width is 10.2 mm. It tapers to a blunt point at both ends. The left lateral half of the gland is considerably more bulky than the right lateral half. The only traces of an ultimobranchial body is an area of very small follicles near the dorsolateral margin in the right lateral half of the thyroid gland.

This area extends through a series of ten consecutive sections and is located nearly midway between the two ends of the gland. A feature very noticeable in the thyroid of this pig is the presence of only a small number of large follicles. These are located chiefly near the dorsal border in the caudal fourth of the gland.

Young adult hog no. 1 (fig. 4). The thyroid gland is 26 mm. long and its greatest width is 18.5 mm. Its anterior end terminates in a single blunt point, while its posterior end terminates in two blunt processes each about 3.5 mm. long. The only structural feature representing a possible derivative of an ultimobranchial body is an elongated area of small follicles (fig. 4, *U.*) which extends through 125 consecutive sections. This area is located along the dorsal border in the posterior fourth of the right lateral half of the thyroid gland and extends for a short distance into its right terminal process. More interfollicular connective tissue is present in this area than in other parts of the gland. The anterior two-thirds of the thyroid is free from unusually large follicles. Many are found in the posterior third of the gland. Two large follicles (*C.F.*) are represented in figure 4.

Young adult hog no. 2. The thyroid gland is 29 mm. long and its greatest width is 20 mm. The anterior end terminates in two blunt processes each 6.5 mm. long, while the posterior end terminates in a single blunt point. The only structural feature representing a possible remnant of an ultimobranchial body is an area of small follicles in the posterior fourth of the left lateral half of the thyroid gland. This area extends through a series of forty sections and has a structure similar to that of the ultimobranchial body represented in figure 4.

Two areas of large follicles are present. In the interior and middle thirds of the thyroid gland these areas extend from the tip end of the two anterior processes along the dorsolateral margin of the thyroid. In the caudal third of the gland these areas gradually become larger, so that at the extreme caudal end they are found throughout the entire thickness of the gland.

Young adult hog no. 3. The thyroid gland is 26.5 mm. long and its greatest width is 20 mm. At each end it tapers to a blunt

point. No remnants of the ultimobranchial bodies are present. Only a few follicles of an unusually large size are present in the extreme anterior and posterior ends of the gland.

SUMMARY

In pig embryos² it was found that the peripheral portion of the ultimobranchial bodies generally develops into typical thyroid structures before its more central portion. It thus becomes evident that the ultimobranchial bodies which can be recognized structurally as such in the thyroid gland of postnatal pigs are mere remnants of these structures that have not fully developed into typical thyroid structures. Also, the structure of the ultimobranchial bodies in the late developmental stages of pig embryos and in the postnatal pigs are similar, namely, areas composed of nucleated syncytial cords and masses the central portion of which may be free from colloids. Areas of small follicles (developmentally young) are not so marked in the immediate neighborhood of the ultimobranchial bodies in postnatal pigs as in the immediate vicinity of these structures in most of the late embryonic developmental stages.

One of the ultimobranchial bodies in the thyroid gland of three pigs is not a continuous structure, but is broken up into segments. For example, the one on the left side in the 7.5-day-old pig is composed of three oblong areas which vary in length. It seems that a satisfactory explanation for this condition is a more rapid transformation into typical thyroid structures of some parts of the more central portion or core than of other parts, thus dividing it into segments which are separated from each other by follicles. The length of the portion of an ultimobranchial body broken up into segments is obtained by measuring the distance between the anterior and posterior parts of the most anteriorly and most posteriorly located segments, respectively. Thus the left ultimobranchial body in the 7.5-day-old pig extends through a series of seventy-five sections. The

² In the summary it will be necessary to refer quite frequently to the writer's previous work on the ultimobranchial bodies in pig embryos. This will be done without calling attention to the bibliographic reference of that article.

right ultimobranchial body in the same pig is represented by a single area which extends through a series of ten sections. Judging from the so variable developmental behavior of these structures in pig embryos, this single area (and similar single areas in the thyroid gland of other pigs) undoubtedly does not represent the greatest length of the central core of this ultimobranchial body, but only what is left of it at the time the pig was killed. It underwent a more rapid transformation than the left one.

A considerable lapse of time intervenes between the age of the pigs and the young adult hogs, thus producing an undesirable break in the continuity of the postnatal developmental history of the ultimobranchial bodies. Although the conclusion in regard to these structures in the young adult hogs is thus rendered somewhat uncertain, I have a strong feeling that the areas of small follicles in the thyroid of the young adult hogs nos. 1 and 2 represent the ultimobranchial bodies in an advanced stage of development. Their structure, location in the thyroid gland, and their proximity to unusually large follicles strengthen this interpretation.

In some of the later developmental stages of pig embryos it was found that unusually large (cystoid) follicles develop in connection with the ultimobranchial bodies. The extent and location of areas of this type of follicles in the thyroid gland of postnatal pigs need therefore to be considered.

The existence of a possible interrelationship between the large follicles and the ultimobranchial bodies is exemplified in a single thyroid gland in some of the postnatal pigs. Thus, in the pig at birth the ultimobranchial body that is present is located in the middle third of the left lateral half of the thyroid gland, while an area of large follicles occupies an almost corresponding position in the right lateral half of the gland. Also a few very large follicles are found near the most caudally located segment of the ultimobranchial body. In the thyroid gland in pig 7.5 days old large follicles are found in the immediate neighborhood of the right ultimobranchial body and near the central segment of the left one. Also cephalad to the most anteriorly located

area of the left ultimobranchial body is an elongated area of large follicles that extends into the middle third of the thyroid gland. A few very large follicles are found in the immediate neighborhood of the left ultimobranchial body in the thyroid gland in pig 28 days old. Large follicles are present in the immediate neighborhood of the ultimobranchial bodies (?) in the young adult hogs nos. 1 and 2.

In a general way, it can be stated that the unusually large follicles are most numerous in the majority of postnatal stages in the portion of the thyroid gland in which the ultimobranchial bodies are generally found, that is, in the posterior half of the gland. This feature is in accord with the fact that in embryos from about 50 mm. in length to full term the ultimobranchial bodies are also usually located in the posterior half of the thyroid gland, although in some they are located in the middle third or in the middle two-fourths of the gland. Exceptions to the usual location of the majority of large follicles in a single gland are not wanting. The most striking example of this exception is found in pig 42 days old, in which the great majority of large follicles are found in the anterior half of the thyroid gland. In consideration of the variable developmental behavior of the ultimobranchial bodies³ in pig embryos, it is therefore, not surprising (granting an interrelationship between the large follicles and the ultimobranchial bodies) to occasionally find large follicles out of their usual place (pig 42 days old) or the almost entire absence of large follicles, as is the case in the thyroid gland in pig 56 days old and in the young adult hog no. 3.

Another significant feature of the location of the very large follicles is the depth at which they are embedded in the thyroid gland. In the more bulky portion of the gland they are located near the dorsal or dorsolateral border of the gland, that is, in the region in which the ultimobranchial bodies may be found, and not in the ventral or ventrolateral region which is derived

³ Variations as to their size, the time of their complete transformation into typical thyroid structures, their location in the thyroid gland, and the presence or absence of large (cystoid) follicles in connection with them.

from the median thyroid anlage. The caudal end of the thyroid gland in some of the postnatal pigs (pig at birth, pig 15 days old, and young adult hogs no. 1 and 2) contains many large follicles. This feature apparently bears with it a significance when it is correlated with the fact that in some of the comparatively early embryonic stages the caudal portion of the tripartite complex is largely composed of ultimobranchial bodeis.

Although the evidence of an interrelationship between the large follicles and the ultimobranchial bodies in postnatal pigs is circumstantial, yet when this evidence is correlated with their development in connection with the ultimobranchial bodies in some of the later embryonic developmental stages, it appears that the ultimobranchial bodies are largely responsible for the large (cystoid) follicles.

In conclusion, it can be said that since the ultimobranchial bodies fuse with the thyroid gland and also form colloid the boundary between these structures and the gland becomes obliterated, so that it is impossible to determine the exact relative proportion that is contributed to the thyroid gland by the ultimobranchial bodies and the median thyroid anlage. Owing to the variable developmental behavior of the ultimobranchial bodies, the relative proportion they contribute to the thyroid gland undoubtedly varies in different pigs. It is, however, quite evident that only a relatively small portion of the gland is derived from the ultimobranchial bodies.

BIBLIOGRAPHY

- BADERTSCHER, J. A. 1918 The fate of the ultimobranchial bodies in the pig (*Sus scrofa*). *Amer. Journ. Anat.* vol. 23.
- BORN, G. 1883 Über die Derivate der embryonalen Schlundbogen und Schlundspalten bei Säugetieren. *Arch. f. mikr. Anat.*, Bd. 22.
- GROSSER, O. 1910 Zur Kenntnis des ultimobranchialen Körpers beim Menschen, *Anat. Anz.*, Bd. 37.
1912 The development of the pharynx and of the organs of respiration. *Manual of Human Embryology*, edited by F. Keibel and F. P. Mall, vol. 2.
- HERRMANN, G., AND VERDUN. 1899 Persistence des corps post-branchiaux chez l'homme. Remarques sur l'anatomie comparée des corps post-branchiaux. *Comptes Rend. Soc. Biol. Paris.*
1900 Note sur les corps post-branchiaux des Caméliens.—Les corps post-branchiaux et la thyroïde; vestiges kystiques. *Comptes Rend. Soc. Biol. Paris.*
- KINGSBURY, B. F. 1914 On the so-called ultimobranchial body of the mammalian embryo. *Man. Anat. Anz.*, Bd. 47.
- MAURER, F. 1899 Die Schilddrüse, Thymus und andere Schlundspaltenderivate bei der Eidechse. *Morph. Jahrb.*, Bd. 27.
1899 Die Schlundspalten—Derivate von Echinodermata. *Anat. Anz. Ergänzungsheft.* Bd. 16.
- MOODY, R. M. 1912 Some features of the histogenesis of the thyroid gland in the pig. Reprints of papers from the Dept. of Anat. of the Univ. of Cal., vol. 4.
- PRENANT, A. 1894 Contribution à l'étude organique et histologique du thymus, de la glande thyroïde et de la glande carotidienne. *La Cellule.* T. 10.
- RABL, H. 1913 Die Entwicklung der Derivate des Kiemendarms beim Meer-schweinchen. *Arch. f. mikr. Anat.*, Bd. 82.
- SIMON, CH. 1896 Thyroïde latérale et glandule thyroïdienne chez les mammifères. Thèse de Nancy.
- VERDUN, P. 1898. Contribution à l'étude des dérivés Branchiaux chez les vertébrés supérieurs. Thèse, Toulouse.

PLATE 1

EXPLANATION OF FIGURES

1 From a photograph of a portion of a transverse section of the caudal fourth of the thyroid gland showing the left ultimobranchial body (*U.*). The colloid in the thyroid gland is represented by black dots. From a pig 7.5 days old. $\times 60$.

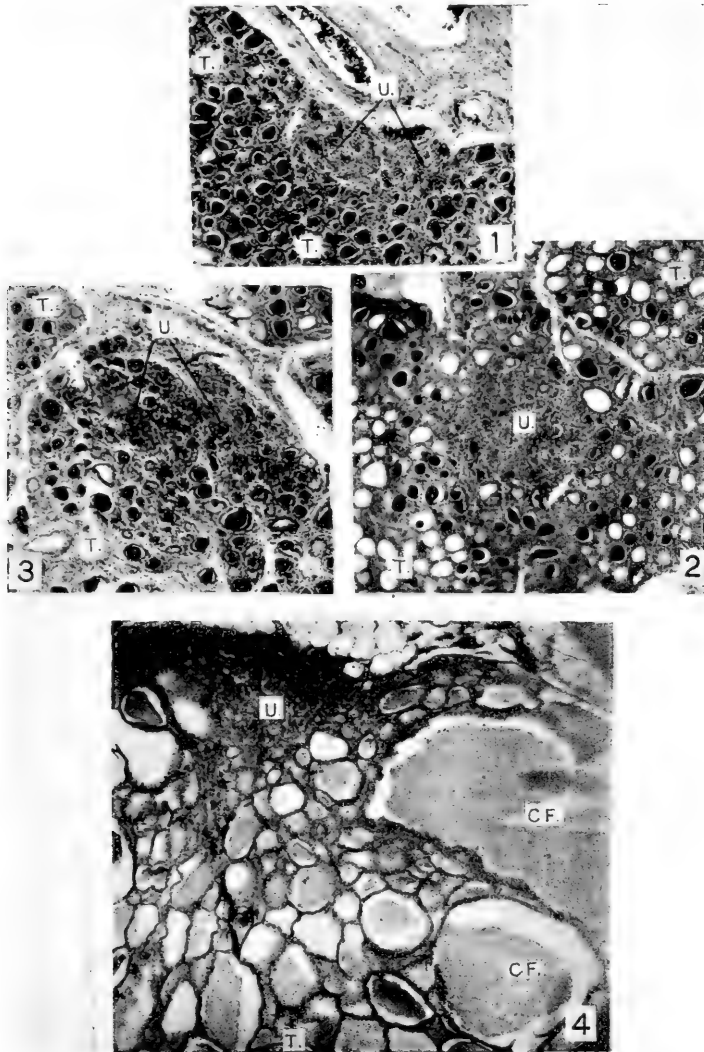
2 From a photograph of a portion of a transverse section of the caudal half of the thyroid gland showing the more anteriorly located segment of the right ultimobranchial body (*U.*). The white spots in the thyroid gland represent follicles out of which the colloid has dropped. From a pig 15 days old. $\times 60$.

3 From a photograph of a portion of a transverse section through the caudal fourth of the thyroid gland showing the left ultimobranchial body (*U.*). From pig 42 days old. $\times 60$.

4 From a photograph of a portion of a transverse section of the posterior fourth of the thyroid gland showing the right ultimobranchial body (*U.?*) and two very large (cystoid) follicles (*C.F.*) which are filled with colloid. From young adult hog no. 1. $\times 45$.

ABBREVIATIONS

C.F., cystoid follicle; *T.*, thyroid; *U.*, ultimobranchial body



Resumido por el autor, Frank Adam McJunkin.

El origen de las células mononucleares fagocitarias de la sangre periférica.

Introducción: La fagocitosis como una función especializada de ciertas células; naturaleza del carbón ingerido por fagocitosis bajo condiciones experimentales; condiciones bajo las cuales tiene lugar la fagocitosis del carbón in vivo. Experimentos que demuestran el origen de las células mononucleares fagocitarias de la sangre, a expensas del endotelio de los vasos sanguíneos. Localización del carbón ingerido en los leucocitos mononucleares fagocitarios de la sangre y células endoteliales de los vasos sanguíneos de pequeño tamaño; mitosis de células que contienen carbón, en las paredes de los vasos sanguíneos que no están alargándose; actividad fagocítica de las células mieloblásticas jóvenes; probable origen de cierto número de células mononucleares fagocitarias de la sangre a expensas de la túnica endotelial de los vasos linfáticos. Conclusiones. Mediante una inyección intravenosa simultánea de negro de humo y citrato sódico en perros y conejos, el carbón es solamente ingerido por ciertas células mononucleares de la sangre y por las células endoteliales de los vasos sanguíneos pequeños. En la mitosis de las células endoteliales con carbón ingerido, de los capilares de los órganos sólidos (sinusoides del hígado), se encuentra una nueva prueba del origen de dichas células sanguíneas a expensas del endotelio y de su penetración en el torrente circulatorio. Aunque el 3 por ciento de las células mononucleares que han ingerido carbón se encuentran en la sangre periférica unas pocas horas después de la inyección, tales células no se encuentran pasadas 24 horas. Este hecho explica perfectamente el fracaso de los que han trabajado con coloraciones intravitalas para demostrar la existencia de células teñidas por este método, en la sangre periférica.

Translation by Dr. José F. Nonidez,
Columbia University

THE ORIGIN OF THE PHAGOCYTTIC MONONUCLEAR CELLS OF THE PERIPHERAL BLOOD¹

FRANK A. McJUNKIN

*Department of Pathology, Marquette University School of Medicine, Milwaukee,
Wisconsin*

ELEVEN FIGURES (THREE PLATES)

CONTENTS

A. Introduction.....	27
a. Phagocytosis as a specialized function of certain cells.....	27
b. The nature of carbon ingested under experimental conditions by phagocytosis.....	31
c. Conditions under which phagocytosis of carbon takes place in vivo	34
B. Experiments that show the origin of the phagocytic mononuclear cells of the blood from the endothelium of blood-vessels.....	36
a. Limitation of ingested carbon to the phagocytic mononuclear leucocytes of the blood and the endothelial cells of small blood- vessels.....	36
b. Mitosis of carbon-containing endothelial cells in the walls of blood-vessels that are not lengthening.....	40
c. The phagocytic activity of immature myeloblastic cells.....	41
d. The possible origin of a certain number of the phagocytic mono- nuclear cells of the blood from the endothelial lining of lymph- vessels.....	42
C. Conclusions.....	45

A. INTRODUCTION

a. Phagocytosis as a specialized function of certain cells

In an earlier report by the writer ('18) about five per cent of phagocytic mononuclear cells are shown to be present in normal human blood. The purpose of the present paper is to trace the origin of the phagocytic mononuclear cells found in the blood from fixed tissue cells. Since the technic of the experiments employed for this purpose as well as that of the earlier

¹ A second report of Studies on the Mononuclear Cells of the Blood.

method used to demonstrate a non-lymphocytic group of mononuclear blood-cells is based on the ingestion by the cells of microscopic particles, a consideration of the phenomenon of phagocytosis so far as the ingestion of carbon is concerned becomes desirable.

Although Langhans ('70) called attention to the ingestion of red-blood-corpuscles by the leucocytes in the tissues about hemorrhages, it was not until about 1883 that general attention was focused on the phagocytic activity of the cells of metazoa, at which time Metschnikoff ('83) began his publications on the subject. This activity of cells is often discussed in connection with such questions as immunity, the physiological atrophy of certain organs, removal from the tissues of mechanical irritants such as coal-dust, and the solution of dead cells and cellular debris. The ingestion of extraneous material is intimately related to the phenomena of chemotaxis and intracellular digestion.

Among the protozoa as among the differentiated cells of metazoa the ability to incorporate microscopic particles is present in some (amebae) and absent in others (trypanosomes). The determination of the phagocytic property of the cells present in higher animals is less simple than it is of protozoön cells, but experimentally microscopic particles may be brought into contact with many different living tissue cells. In distinction to true phagocytosis substances, such as bile pigment, hemoglobin, melanin, lead, and many other products, present normally or pathologically in the tissue may pass into the cells in solution and there be deposited as microscopic matter. The entrance in this manner of molecular and larger ultramicroscopic particles (colloids) into cells does not come under the term of phagocytosis which is a microscopic phenomenon of the cells. During phagocytosis the cytoplasm flows about the foreign body probably as the result of an alteration of surface tension (Wells, '14) at the point of contact, while molecules and small colloids pass through the cell membrane by diffusion without any change in the cell contour, and it is likely that the two processes have a different explanation. The demonstration of microscopic foreign

particles inside cells is not, therefore, certain evidence of phagocytosis. It appears further that foreign bodies may come to lie within the cytoplasm of cells other than by the diffusion of substances in molecular or colloidal solution and by phagocytosis. The introduction of a foreign body into cells without the activity of the latter appears to take place when leprosy bacilli proliferate in epithelial structures such as the coil glands of the skin (Mallory, '14). The writer has found rather large particles of carbon in living cells twenty-four hours after the injection of lampblack suspensions directly into the liver parenchyma. Here as in the growth of leprosy bacilli in epithelial cells it appears that the microscopic particles are mechanically forced into the cell protoplasm.

In considering phagocytosis in human tissue or in the tissue of any metazoa the question of the differentiation and the specificity of cells arises, because specific activities cannot be assigned to cells that are not themselves specific and that may change into entirely different cells under a varying environment. Proof of any such transition of one type of cell to another, however, is lacking except in the case of a limited number of closely related cells, and the very function of organs and tissues is dependent upon the specificity of the cells which compose them and which frequently undergo mitosis to replace dead cells. Such unfailing reproduction of the same variety of cells can result only from the existence of a living protoplasm specific for that kind of cell, and once a definite physical and chemical unit characterizing a cell has arisen in embryologic development it certainly rarely changes. In the adult body many examples of cell differentiation may be observed. The neutrophile differentiates from a younger cell through well-defined changes, but once differential characters have been acquired the neutrophile does not change to an eosinophile or a basophile.

A point of equal importance with the specificity of differentiated cells is the identification of such cells by morphologic or other characters. It is idle talk to speak of phagocytosis by a fibroblast when the preparation on which the statement is based reveals none of the 'earmarks' which are known to characterize

this cell. In this particular case it has been stated by some that only the younger cells manifest such activities, yet here the characteristic fibrils must be present, for they appear in this cell within twenty-four to forty-eight hours after mitosis, in which time ingested particles could scarcely be disposed of. Ingested foreign particles, such as carbon, or other cells, such as red blood corpuscles, neutrophiles, or lymphocytes, have not been demonstrated in fibroblasts stained in such a way as to bring out the characteristic fibrils either in human or experimental tissue.

In the blood the identification of cells for obvious reasons is carried out under greater difficulties than elsewhere and tentative non-histological terms, such as transitional leucocyte, large mononuclear leucocyte, etc., have been introduced. Had morphological characters been more closely defined these terms would have served a more useful purpose until such time as the origin of the cells could be established, but no uniformity exists in regard to the cells which are to be included under these terms. The number of observations on normal and pathological bone-marrow appears to warrant the statement as a fact that the neutrophiles, eosinophiles, and basophiles (polymorphonuclear leucocytes) differentiate from younger myeloblastic cells normally present only in the bone-marrow. A parallel statement holds for the lymphocytes, and that the smallest cells of the blood come from the lymphoid tissue is not seriously questioned. There are present, however, non-lymphocytic mononuclear cells of a different type and these are larger than the lymphocytes and frequently have irregularities in the nuclear contour. It is about these that the greatest doubt exists. The significance of the experiments tabulated below calculated to show the origin of phagocytic non-lymphocytic mononuclear cells does not rest on the acceptance of any prescribed origin of lymphocytes or polymorphonuclear leucocytes (neutrophiles, eosinophiles, and basophiles), but is based rather on the specificity of the function of phagocytosis by a given cell under given conditions. The only point urged here is that lymphocytes, eosinophiles, basophiles, fibroblasts, most epithelial cells, etc., do

not commonly ingest microscopic particles, and it does not seem necessary to review the great mass of literature to prove that phagocytosis is not a facultative function of most differentiated cells of adult human tissue because such cells may readily be brought into contact with foreign substances in vitro and in vivo.

b. The nature of carbon ingested under experimental conditions by phagocytosis

Although a considerable number of microscopic substances in suspension, such as neutral oils, India ink, staphylococcus, bacillus subtilis, and bacillus tuberculosis, were employed to determine the phagocytic properties of cells in vivo, lampblack was chosen as the most suitable for this purpose. All the suspensions of this substance used show on examination with the high-dry lens great numbers of microscopic particles which correspond in size and shape to those in the cytoplasm of phagocytic cells placed in the suspensions. Since the particles of carbon are small, the question of colloid solution and intravital staining is raised.

Bouchard ('06) was the first to demonstrate the possibility of staining living tissue *intra vitam* by the administration of certain benzidine dyes in colloid solution. Recently many dyes, pyrrhol blue, trypan blue, Janus green, and carmine solutions, some in molecular solution and others in colloid solution, have been injected into animals in normal and pathologic conditions to determine the behavior of living cells toward them. Many conflicting opinions in regard to the results obtained by *intra vitam* staining have been advanced. It was found by H. M. Evans ('15) that the endothelial cells lining small blood-vessels were uniformly stained by the *intra vitam* method. His observations on the peripheral blood failed to show appreciable numbers of cells containing the dye granules, and he says, "Macrophages do not occur in the peripheral blood stream except when produced in numbers so great that the condition may be called pathological." He defines a macrophage as a vitally staining mononuclear cell and applied the term phagocytosis to

the ingestion of microscopic particles as well as to the 'drinking in' of colloids (ultramicroscopic). In a small series of rabbits injected with trypan blue and with a carmine solution used by Kiyono ('13) practically the same results have been obtained by the writer. The probable explanation of the absence of vitally stained cells in the peripheral blood is given below. Conflicting opinions have arisen about the specificity of the cells stained by this method rather than in regard to the presence of the dye in the endothelial lining of blood-vessels. Evans ('15) speaks of macrophages other than the vascular ones which are more or less fixed and probably of endothelial origin. This view of tissue spaces lined with endothelium is scarcely in accord with most work which shows that not only the blood-vessels, but the lymph-vessels as well are closed endothelial lined tubes (MacCallum, '03).

In the first experiments with lampblack it was found that this substance is removed from lampblack-citrate suspensions by filtration through muslin, but that it passes through if blood is added to the suspension before filtration. This corresponds in general to what is known as protective colloid action, and later it was found that gelatin has the same effect on the lampblack as the protein of the blood and that lampblack-gelatin-citrate suspensions not only pass through muslin, but even through filter-paper. Microscopic examination with the oil-immersion lens of the muslin filtrate reveals innumerable rather coarse particles together with many minute particles at the limit of vision. In the filter-paper filtrate there are no coarse particles, but on examination with dark-field illumination innumerable ultramicroscopic particles are visible. The lampblack-gelatin-citrate suspensions after filtration through the finer filter-papers do not separate even after standing a number of days and they correspond in all respects to the typical colloid sols. The exact way in which gelatin, albumin, and other protective substances increase the permanency of colloid solutions is not agreed upon by physical chemists. If such a colloid carbon suspension made up largely of ultramicroscopic but partly of microscopic particles is incubated in vitro with phagocytic cells instead of a suspension

of much coarser carbon particles, the carbon taken up by the phagocytes is invisible or only a few particles (those visible microscopically in the sol) are seen in the cells. There is no absolute limit on the maximum size of colloid particles, but masses or lumps which settle out in a few minutes would hardly be called colloid particles. Many at least of the dyes used for staining *intra vitam* appear to fall in the class of colloid sols, but the term colloid in this connection has been rather loosely applied because, although there is no definite minimum size for colloids and no clear separation between colloid and molecular sol, no one should call a readily diffusible substance such as an alkaline carmine solution a colloid. The point of greatest interest is an explanation for the failure of those working with *intra vitam* stains to demonstrate the presence in the blood of numerous cells containing the dye granules, since cells which have ingested microscopic particles of lampblack are readily demonstrated here *in vivo* and *in vitro*. In the animals receiving intravenous injection of lampblack-citrate suspensions carbon-containing cells appear in the peripheral blood within thirty minutes, but at the end of five hours few remain in the blood obtained in the usual way and after twenty-four hours no carbon-containing cells are demonstrable. Examination of all the tissues shows that owing to some change brought about in the leucocytes by the presence of carbon particles in them they are held in the capillaries of the liver, spleen, lungs, and other organs, and that after twenty-four hours many are migrating through the walls of the capillaries into the extravascular tissue. There is every reason to think that vitally stained cells may behave in the same way, and since the process of *intra vitam* staining requires twenty-four hours or more granule-containing cells do not appear in the peripheral blood. In the capillaries even in the thinnest and most perfectly stained paraffin sections it is not easy to differentiate between the cells present in the capillaries and the tissue about them, and it would seem that little accurate information could be obtained by the study of frozen sections of such tissue.

Further, it was found that large quantities of lampblack must be injected else most of it is removed from the plasma by endothelial cells rather than by free cells in the blood. Again as many as 90 per cent of the neutrophiles of the peripheral blood contain lampblack after its injection, and in rabbits especially the number of mononuclear carbon-containing cells is very small after the intravenous injection of non-citrated carbon suspensions. By injecting sodium citrate at the same time that the lampblack is injected the percentage of neutrophiles with carbon is reduced to below one per cent and as many as 3.03 per cent of phagocytic mononuclear cells have been counted. It appears, therefore, to be necessary for the satisfactory *intra vitam* demonstration of so-called macrophages in blood not only to inject large amounts of microscopic particles, but also to inhibit the active phagocytosis of the neutrophiles by the use of sodium citrate.

*c. Conditions under which phagocytosis of carbon takes place
in vivo*

In a previous report (McJunkin, '18) it is shown that the ingest on of carbon by certain cells *in vitro* may be controlled by the concentration of sodium citrate, and since both polymorphonuclear leucocytes and the mononuclear ones ingest the carbon it became a matter of importance to employ certain concentrations of sodium citrate in order to inhibit the activity of the neutrophiles and to obtain a clear picture. It was found that *in vitro* 15 mg. of this salt (Merck highest purity) per cubic centimeter of blood almost completely inhibits the ingestion by all cells under the conditions prescribed, while with 5 mg. per cubic centimeter of blood not only the phagocytic mononuclear cells, but more than half of the neutrophiles ingest the carbon. By using 7.7 mg. sodium citrate per cubic centimeter of blood the best differentiation of cells is obtained, since a small percentage of neutrophiles ingested the carbon and practically all of the phagocytic mononuclear leucocytes ingest it.

Since publication of the first report it has been found that even 40 mg. sodium citrate per cubic centimeter of blood does not prevent the ingestion of large numbers of staphylococcus pyogenes aureus when this organism in suspension is substituted for the lampblack. By using strengths of citrate varying between 5 and 15 mg. and substituting tubercle bacilli for the lampblack, 2.2 per cent is the maximum number of macrophages containing the bacilli, while as many as 20 per cent of neutrophils have ingested the organisms. In a small number of experiments with bacteria the limitation of phagocytosis to the mononuclear cells has not been successful. Leucocytes (polymorphonuclears and mononuclears) ingest the carbon in a plasma-free medium, provided the carbon has previously been brought into contact with fresh plasma or serum, although it has subsequently been washed (four times) with saline. Washed leucocytes, however, do not ingest untreated carbon.

In preliminary experiments heavy suspensions of lampblack in 1 per cent gelatin were injected intravenously into rabbits and dogs with discouraging results so far as the blood is concerned, for although polymorphonuclear leucocytes contained the carbon in abundance, very rarely could a mononuclear leucocyte be found which had ingested it. Only after repeated injections of large amounts did any mononuclear carbon-containing leucocytes appear in the peripheral blood of dogs.

The next step was to inhibit by the simultaneous injection of citrate the phagocytic activity of the polymorphonuclear leucocytes just as it had been successfully done in the test-tube. The amount of citrate to be injected was determined by estimating the weight of blood at one-twentieth of the body weight and injecting 7.7 mg. citrate per cubic centimeter of calculated blood.

The exact way in which the citrate acts in the blood stream to prevent phagocytosis is problematical, but there are indications that it acts by diminishing the protective colloid action of the albumin of the plasma and in this way allows flocculation of the carbon so that it may be ingested by the leucocytes.

B. EXPERIMENTS THAT SHOW THE ORIGIN OF THE PHAGOCYTTIC
MONONUCLEAR CELLS OF THE BLOOD FROM THE
ENDOTHELIUM OF BLOOD VESSELS

The points to be established by experiment are, first, the limitation of the phagocytosis of carbon to certain mononuclear cells of the blood and the endothelial cells lining the small blood-vessels and, second, absolute proof of the latter's becoming free in the blood stream. There are other points discussed, such as a diminished power of immature neutrophiles (metamyelocytes) to ingest carbon, since they have a direct bearing on the question.

*a. Limitation of ingested carbon to the phagocytic mononuclear
leucocytes of the blood and the endothelial cells
of small blood-vessels*

The carbon (commercial lampblack ground for thirty minutes in a mortar) was given intravenously to the animals (table 1) as a 5 per cent unfiltered suspension in 1 per cent gelatin. In both rabbits and dogs the suspension was injected into a vein of the left ear at the same time that the citrate was injected as a 10 per cent solution into a vein of the right ear. The lampblack must not be thrown into the circulation too rapidly and the rate of the citrate injection must be controlled by the dyspnea that develops. Cover-glass films of blood were taken at varying intervals from the ear employed for the citrate injection and stained with polychrome blood stain. The films are made from drops of fresh blood of the exact size required. In the peripheral blood of the rabbits (121, 138, 139, and 213) that received lampblack alone very few carbon-containing mononuclear cells are present, although numerous polymorphonuclear leucocytes contain it. Thus in rabbit 139 one hour after the sixth injection less than 0.5 per cent carbon-containing mononuclear cells are present and on previous days none are found. In the blood of dog 151 four hours after the seventh injection of lampblack alone 2.15 per cent mononuclear carbon-containing cells along with 9.1 per cent carbon-containing polymorphonuclear leucocytes are present. Thirty minutes after the fifth injection there

are present 2.66 per cent mononuclear cells with carbon and 8.85 per cent of polymorphonuclears containing it. Twenty-two and one-half hours after the fifth injection no carbon containing cells are present. One hour after the third injection no carbon-containing mononuclear cells are found.

Rabbit 164 was the first to receive both citrate and lampblack, and for the first time a distinct number of carbon-containing cells are present in the peripheral blood of a rabbit after a single injection. After application of the method used for determining the number of phagocytic mononuclear cells in human blood

TABLE 1

NO.	ANIMAL	DURATION OF EXPERIMENT	DOSE OF CARBON	DOSE OF CITRATE	TIME KILLED AFTER LAST INJECTION
121	Rabbit	1 da.	2.25 cc. once	0	24 hr.
138	Rabbit	3 da.	1.5 cc. three times	0	10 min.
139	Rabbit	7 da.	1.5 cc. six times	0	1 hr.
151	Dog	9 da.	10.0 cc. seven times	0	5 hr.
164	Rabbit	30 min.	5.5 cc. once	5.5 cc.	Not killed
176	Dog	1 da.	9.0 cc. once	9.0 cc.	24 hr.
200	Rabbit	1 hr.	2.0 cc. once	4.25 cc.	1 hr.
201	Rabbit	30 min.	3.0 cc. once	7.75 cc. ¹	30 min.
205	Rabbit	2 hr.	2.5 cc. once	5.0 cc.	2 hr.
208	Rabbit	24 hrs.	1.0 cc. once	3.5 cc. ¹	Dead 24 hr.
209	Dog	1 da.	3.0 cc. once	8.0 cc. ¹	24 hr.
212	Rabbit	1 da.	1.75 cc. once	4.5 cc. ¹	24 hr.
213	Rabbit	1 da.	1.5 cc. once.	0	24 hr.

¹ Citrate contains opalescent suspension typhoid bacilli.

(McJunkin, '18) variations between 1.09 and 4.7 per cent of these cells are found in the peripheral blood of rabbits. The next animal to receive the lampblack and citrate was a dog (176). The smears made at the end of one hour are not satisfactory and an accurate count cannot be made.

A count of 595 cells in the peripheral blood of rabbit 200 taken one hour after injection shows 3.03 per cent mononuclear cells with carbon together with 2.02 per cent carbon-containing polymorphonuclear leucocytes. Of 1026 cells in the blood of rabbit 201 thirty minutes after injection 2.63 per cent are mononuclear cells containing carbon with only 0.97 per cent polymorphonuclear carbon-containing ones. In rabbit 205 two hours after

injection there are 0.49 per cent carbon-containing mononuclear leucocytes and 3.21 per cent polymorphonuclear ones. In rabbit 208 there are present five hours after injection 6.9 per cent polymorphonuclear leucocytes with carbon, but no carbon-containing mononuclear cells. In the blood of dog 209 no carbon-containing cells are present twenty-four hours after injection. Again in rabbit 212 no cells with carbon are present after twenty-four hours.

The intravascular phagocytosis of carbon is readily produced. After large injection of non-citrated carbon suspensions repeated a number of times, as many as 2.15 per cent of the mononuclear cells (dog) may contain carbon, and after single injections of smaller amounts of carbon together with large doses of citrate 3.03 per cent mononuclear leucocytes may contain carbon two hours after injection with the reduction of carbon-containing polymorphonuclear ones to a minimum (less than 1 per cent). The number of phagocytic cells in the peripheral blood varies in different animals, reaching a maximum in one-half to two hours with a very noticeable diminution in five hours and a total disappearance of cells with carbon within twenty-four hours.

The disappearance within twenty-four hours from the peripheral circulation of all cells that have incorporated foreign particles appears to explain perfectly the failure of Evans ('15) and others to find vitally stained cells in the peripheral blood, since the cells stained by the *intra vitam* methods contain microscopic particles and considerable time (more than twenty-four hours) and frequently multiple injections of the dye are required.

The limitation of the ingested carbon to the mononuclear cells of the blood (3 per cent in some animals) and to endothelial cells lining the capillaries of various organs is of the nature of a highly specific stain. In dog 209 (fig. 6) two or three and less commonly more perfectly round carbon-containing mononuclear cells may be found in the sinusoids of the liver which are lined with elongated carbon-containing endothelial cells. The round contour of the former and an elongation due to ameboid motion (fig. 5) is a differential point between the two. There

are very few polymorphonuclear leucocytes (fig. 6) with ingested carbon. At this time only an occasional carbon-containing cell has migrated into the extravascular tissue, but the accumulation of these cells in the sinusoids explains their disappearance from the peripheral blood. After several days, as in dog 151, numerous carbon-containing cells are present in the periportal tissue and tubercle-like foci made up of carbon-containing mononuclear cells about which there is a small amount of fibrin (fig. 7) have formed in the sinusoids. In the liver of dog 209 and of other one-day animals an occasional small focus of carbon-containing mononuclear cells resembling the large foci of animal 151 may be seen in the sinusoids. Wide areas of surrounding liver parenchyma reveal no extravascular leucocytes, and the only possible source of these cells is the blood. In the capillaries of the spleen, bone-marrow, and lymph nodes and to a less extent in the capillaries of other organs there is a similar accumulation of leucocytes. In the one-day animals the reaction to the carbon is entirely intravascular and is limited to free and attached cells similar morphologically.

That most normal tissue contains practically no extravascular phagocytic cells may readily be proved by injecting lampblack into organs and fixing the tissue after the cells of the tissue have had ample opportunity to ingest carbon, but before leucocytes have had time to pass from the blood stream into the tissue spaces. A tissue or organ, such as the bone-marrow or spleen, is not suitable for such an experiment, for it is difficult to determine what cells are intravascular and what ones extravascular. In the intestinal wall, the subcutaneous tissue beneath the nipples and the kidney of animals 211 and 212 practically no extravascular carbon-containing cells are present thirty minutes and two hours after injection. There is a tendency to recognize a close relationship or identity of cells to which such terms as adventitial cells, gland connective tissue cells, areolar connective tissue cells, reticulum cells, etc., and the fibroblast. Certainly proof that is positive and easily obtained shows that such extravascular cells do not ingest by phagocytosis and do not give rise to phagocytes.

b. Mitosis of carbon-containing cells in the walls of blood vessels that are not lengthening

The identical behavior to carbon of the phagocytic mononuclear leucocytes of the blood and the phagocytic endothelial cells of the capillaries is evident and observations to show that most normal extravascular tissue contains practically no phagocytic cells may be readily made. That mononuclear phagocytes of the blood arise from the endothelial cells lining the capillaries may be demonstrated by a careful histologic technic. A desquamation into the lumen of a vessel is frequently spoken of, but there seems to be little evidence of such a process aside from the formation of a new cell by mitosis. In routine autopsy examinations an occasional mitotic figure may be found after prolonged search in the endothelial cells of capillaries in the liver, pancreas, and other organs. In the animals that received no typhoid bacilli, such as rabbit 138 (fig. 3), prolonged search is required to find a karyokinetic figure, and even the accumulation of enormous amounts of carbon in the cells (dog 151) does not increase the proliferation of the endothelial cells to any appreciable extent. In animals receiving typhoid bacilli (dog 209) mitoses (figs. 1, 2, and 4) may be demonstrated with much greater ease. A careful histologic technic is required and demonstration of the achromatic spindle is necessary for certain identification, since the dense polymorphous nuclei of neutrophils, pyknotic nuclei of endothelial cells and even masses of carbon may be confused with imperfect division figures, and judging from the comparatively small number of the mitoses in many of the animals receiving intravenous injections, such mistakes have not been uncommon. The tissues were removed from the body immediately after the animal was killed and pieces 2 mm. thick placed in Zenker's fluid. After embedding in paraffin, sections not more than $7\ \mu$ thick were cut and stained by the eosin-methylene blue method of Mallory.

The endothelial cells of the liver contain more carbon than those of other organs and is well adapted for a search for mitoses. In the liver, heart, kidney, and other solid organs in which the

parenchymal cells are normal, cells resulting from mitoses necessarily enter the blood stream since the capillaries cannot lengthen.

It is true that the dividing endothelial cells in the lengthening of vessels in granulation tissue often remain more or less elongated during division, but the demonstration of mitoses in vessels that are not lengthening is more certain proof of the entrance of these cells into the blood stream. A careful search in the liver of animals one to three days after a lampblack-citrate-typhoid injection shows the presence of mitoses in endothelial cells with particles of lampblack in them (figs. 1 and 2). In an organ such as the heart (fig. 3) in which the capillary wall is somewhat thicker than that of the sinusoids of the liver the relationship of the dividing cell is better defined.

c. The phagocytic activity of immature myeloblastic cells

The identification of cells in sections of bone-marrow stained with eosin-methylene blue is less certain than in smears, although the position of the cells in the tissue is helpful. The relationship of bone-marrow structures is difficult to determine and the exact location of the myeloblastic cells as regards the endothelial lining of vessels is not easy to make out even in the best paraffin sections. In the animals receiving single doses of both lampblack and citrate examination of sections of bone-marrow shows little if any carbon in any cells except the endothelial cells lining the blood-vessels and an occasional mononuclear phagocyte in the lumen of the vessels. The only other cells in which carbon may be found are small numbers of mature polymorphonuclear leucocytes. The younger myeloblastic cells (myelocytes and metamyelocytes) contain little carbon. On the other hand in animals that have received lampblack alone the carbon is present not only in the endothelial cells of the vessels, but also in many of the polymorphonuclear leucocytes. In these animals myelocytes are almost free of carbon. In the cells that have become older and smaller with shrinkage of the nucleus (so-called metamyelocyte) there is an occasional one that has ingested the carbon.

In smears properly prepared the cells have the appearance

seen in cover-glass films of the peripheral blood. To make the smears about 5 gm. red bone-marrow crushed with forceps is placed in a 15 cc. graduated centrifuge tube with 15 cc. saline and shaken vigorously for five minutes, when the suspension is filtered through thin muslin moistened with saline and the filtrate centrifuged. The supernatant fluid and as much fat as possible is siphoned off. A small drop of the sediment is placed on a cover-glass by means of a capillary pipette with rubber nipple attached and cover-glass smears made in the usual way. The mature polymorphonuclear leucocytes in smears made in this way from dog 151 contain much carbon, but the immature ones (metamyelocytes) and myelocytes contain little. The comparison of the metamyelocytes with the phagocytic mononuclear leucocytes present in smears of blood shows that the cytoplasm of the former is more acidophilic with a marked granulation, while its nucleus is more pyknotic and has the shape of a three-quarter segment of a doughnut rather than a slight to moderate indentation (kidney nucleus).

An attempt to prove diminished power of immature polymorphonuclear leucocytes to ingest carbon by phagocytosis was attempted by substituting the suspension of bone-marrow cells for blood and performing the test in vitro in the usual way (McJunkin, '18) except 0.2 mg. lampblack is used per cubic centimeter of the suspension and the citrate omitted. The technic does not give entirely satisfactory results, but serves to demonstrate that the phagocytic property of many polymorphonuclear leucocytes is greater than that of the myelocytes and metamyelocytes.

d. The possible origin of a certain number of the phagocytic mononuclear cells of the blood from the endothelial lining of the lymph-vessels.

Two methods of determining whether mononuclear phagocytes enter the blood from the lymph-vessels were utilized. The first was to induce in the lymphatics changes that supposedly accentuate the activities of the endothelial cells lining the

lymphatic vessels and the second was to determine whether or not phagocytic mononuclear cells are present in the lymph entering the great veins of the neck. The first technic was carried out by injecting a 5 per cent suspension of lampblack in 1 per cent gelatin subcutaneously over large areas on the lower portion of the abdomen, in the groins, and in the flexor surfaces of the thighs. In guinea-pigs 211 and 212 (table 2) the lampblack was introduced into the subcutaneous tissue, the substance of the kidney, and the intestinal wall.

After repeated injections (dog 152) a large anthracotic iliac node is present on either side of the vertebral column. Examination of these shows carbon in the endothelial cells lining the lymph sinuses, but most of it is within large mononuclear cells in the sinuses and in the extravascular spaces near them (fig. 10). In an animal killed twenty-four hours after a single injection (dogs 177 and 210) an occasional cell with carbon is found in the sinuses, but none elsewhere (fig. 9). In the regional nodes in the one-day animals there is no macroscopic blackening, but with the lapse of a few days a sufficient number of carbon-containing cells have arrived from the site of injection to cause a blackening. Dilated lymphatic vessels in the subcutaneous tissue into which carbon has been forced are lined with carbon-containing cells (fig. 8), and there is little question but what these divide to form free phagocytic cells. That mobilization of phagocytic mononuclear cells at the point of injection requires about twenty-four hours (dogs 177 and 210) indicates that these cells at first at least come from free cells in the blood stream, since cells do not arise by mitosis in less than this time. The attraction of leucocytes from the blood stream requires a number of hours for very few have appeared after two hours.

Although the impossibility of phagocytosis by the lymphocytes has not been seriously questioned, the resemblance of some phagocytic cells to lymphocytes morphologically and the many conflicting statements on the subject have led to a close study of this phase of the subject. The distinct separation of lymph-vessels and lymphoblastic tissue has been referred to in foregoing paragraphs. The lymph-vessels like the blood-vessels are

closed channels lined with endothelial cells which have nothing in common with the lymphoblastic cells. In the lymph nodes, therefore, there are present two varieties of endothelial cells (those lining blood-vessels and those lining lymph-sinuses) and the lymphoblastic cells. Twenty-four hours after a single intravenous injection (dog 176) the endothelial cells lining the capillaries are the only cells that contain carbon. Even in the germinal centers made up of large proliferating lymphoblasts carbon is present in the endothelial cells of the capillaries (fig. 11). Later (dog 151) carbon-containing cells migrate into the lymphoblastic tissue, and then there is an admixture of carbon-containing cells and lymphoblasts. This origin of phagocytic cells from blood-vessels in the germinal centers has been lost sight of by some.

TABLE 2

NO.	ANIMAL	DURATION OF EXPERIMENT	DOSE OF CARBON	HOURS KILLED AFTER LAST INJECTION
130	Rabbit	6 da.	5 cc. four times	24 hours
152	Dog	10 da.	10 cc. five times	24 hours
177	Dog	1 da.	40 cc. once	24 hours
210	Dog	1 da.	30 cc. once	24 hours
211	Guinea-pig	30 min.	5 cc. once	30 min.
212	Guinea-pig	2 hrs.	5 cc. once	2 hours

In (dog 151) a deeply pigmented node was found in the retro-peritoneal tissue below the liver. The structure of this gland strongly suggests a hemolymph gland. With this exception, no markedly blackened nodes have been found in animals receiving intravenous injections.

In one etherized animal (dog 152) lymph was obtained from the thoracic duct and no cells (count of 500) containing carbon are present. Owing to irregularities in the course of the lymph-vessels, some difficulty has been encountered in freeing the vessels near their entrance into the jugular or subclavian, but once dissected free collection of the lymph is easy. Coagulation is prevented by 5 mg. citrate per cubic centimeter and the fluid centrifuged. Smears from the sediment are fixed in alcohol-ether to free them from fat and stained in the usual way.

This observation scarcely proves that phagocytic cells do not enter the venous circulation by way of thoracic duct, but certainly large numbers do not travel this route for the reaction in the lymph glands of this animal is marked. It seems more likely that a certain number of phagocytic cells arising from the endothelial lining of lymph-vessels pass directly into the blood stream by migration.

C. CONCLUSIONS

For studying the phagocytic activity of cells lampblack has an advantage over intra vitam stains, since the reaction is almost immediate. By showing that cells which have ingested carbon (3 per cent mononuclear ones) completely disappear from the peripheral circulation within twenty-four hours, the failure of those employing intra vitam stains to demonstrate any considerable number of phagocytic cells in the blood is explained. Another advantage of lampblack over intra vitam stains is that thin paraffin sections may be made of the tissue fixed in a way best calculated to bring out the histologic structure. In such sections the limitation of the ingested carbon to the endothelial cells and mononuclear leucocytes assumes the character of a specific reaction for cells of endothelial origin. The demonstration of mitoses in endothelial carbon-containing cells lining capillaries which are not lengthening is proof of the origin of phagocytic mononuclear blood-cells from the endothelial cells of vessels.

That the five per cent of phagocytic mononuclear cells present in human blood consists entirely of endothelial leucocytes seems likely in view of the fact that there is positive proof of this origin and negative evidence showing that they are not of myeloblastic or lymphoblastic origin and that few phagocytic cells of any variety are present in normal extravascular tissue.

For the incentive to undertake these experiments, it affords me great pleasure to acknowledge my indebtedness to Prof. F. B. Mallory, who has for a great many years taught his students the important rôle of the endothelial leucocytes. I am indebted to Miss Alice Charlton for valuable technical assistance and to Mr. L. Massopust for the illustrations.

BIBLIOGRAPHY

- BOUCHARD 1906 Ann. de l'Inst. Pasteur, vol. 20.
EVANS, H. M. 1915 Am. Jour. Physiol., vol. 37.
KIYONO, K. 1914 Folia Hemtalog., vol. 18.
LANGHANS, TH. 1870 Virchow's Archiv, vol. 49.
MACCALLUM, W. G. 1903 Johns Hopkins Hosp. Bull., vol. 14.
MALLORY, F. B. 1914 Principles of pathologic histology. W. B. Saunders Co., Phila.
McJUNKIN, F. A. 1918 Archives of Internal Medicine, vols. 21 and 22.
METSCHNIKOFF, E. 1883 Arb. a. d. Zool. Inst. Wien, Bd. 5.
WELLS, H. G. 1914 Chemical pathology. W. B. Saunders Co., Phila.

PLATES

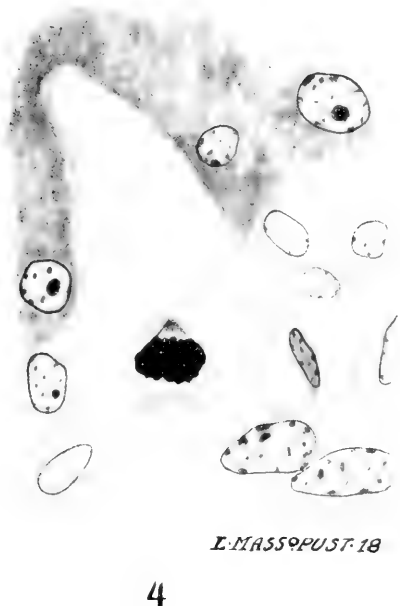
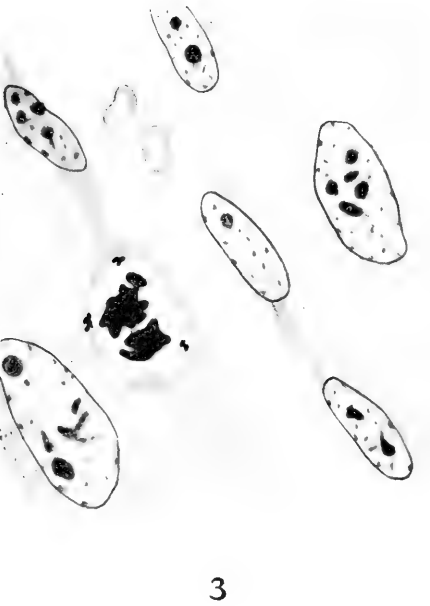
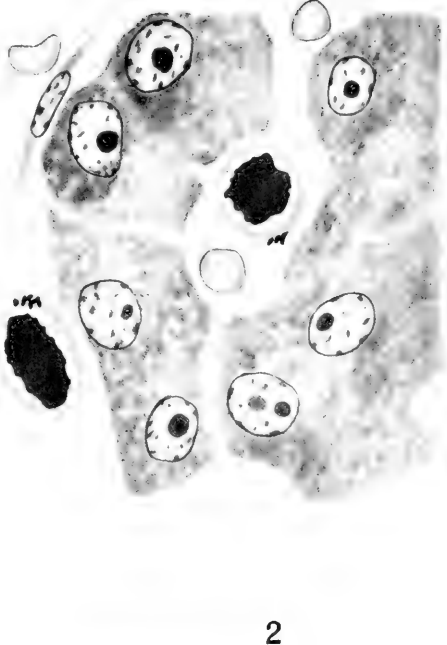
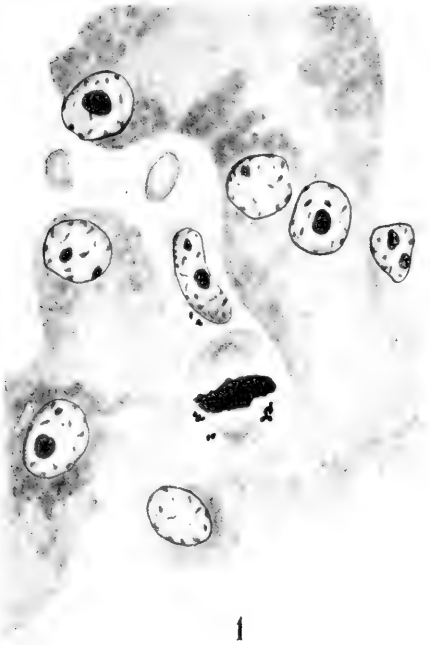
The sections from which the drawings were made are paraffin sections of Zenker-fixed tissue stained by the eosin-methylene-blue method of Mallory. The drawings were made with the aid of a camera lucida.

PLATE 1

EXPLANATION OF FIGURES

Oil-immersion objective and no. 4 ocular (Leitz).

- 1 Monaster showing achromatic spindle in an endothelial cell containing carbon in a sinusoid of the liver (dog 209, table 1).
- 2 Two monasters (liver dog 209, table 1).
- 3 Diaster in capillary of heart muscle (rabbit 138, table 1). Note carbon particles in cytoplasm.
- 4 Monaster in an endothelial cell of a vessel (portal vein?) in a portal tract at a point where the vessel narrows and enters the liver parenchyma (dog 209, table 1).



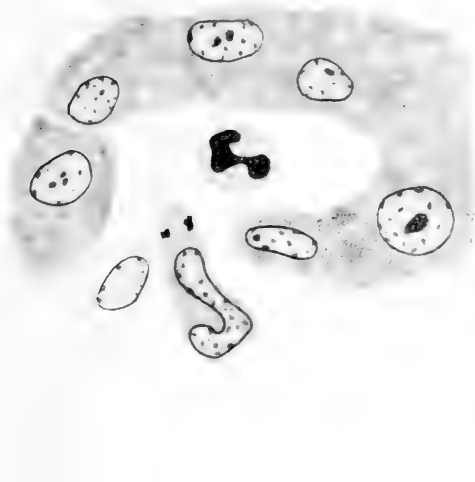E. MASSOPUST 18

PLATE 2

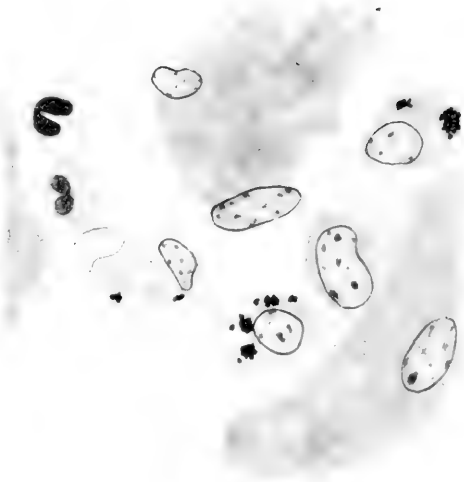
EXPLANATION OF FIGURES

Oil-immersion objective and no. 4 ocular (Leitz).

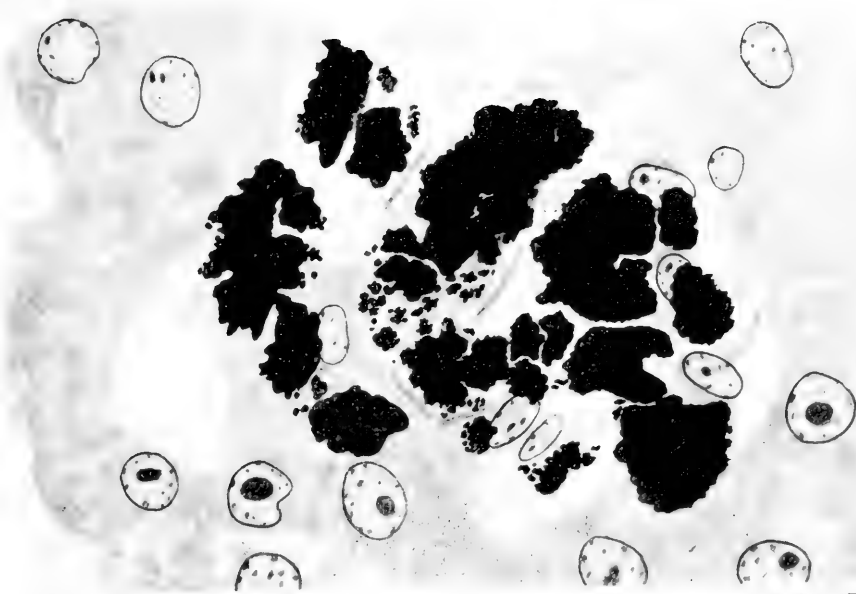
- 5 Migrating phagocytic mononuclear leucocyte containing carbon in a sinusoid of the liver (dog 209, table 1).
- 6 Four phagocytic mononuclear leucocytes (three with carbon) and two polymorphonuclear leucocytes (no carbon) in a sinusoid of the liver (dog 209, table 1).
- 7 Tubercle-like focus consisting of carbon-containing mononuclear leucocytes in sinusoid of liver (dog 151, table 1). A distinct fibrin network between the leucocytes.



5



6



L. MASSOPUST '18.

PLATE 3

EXPLANATION OF FIGURES

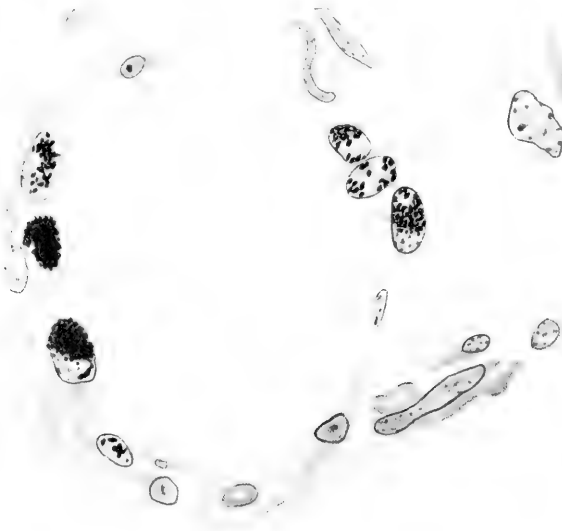
Oil-immersion objective and no. 4 ocular (Leitz) except fig. 8 which was made with the high-dry lens (no. 7, Leitz) and fig. 10 which was made with the low-power objective and no. 2 ocular (Leitz).

8 Carbon-containing endothelial cells lining a dilated lymph-vessel in the subcutaneous tissue ten days after first subcutaneous injection (dog 152, table 2).

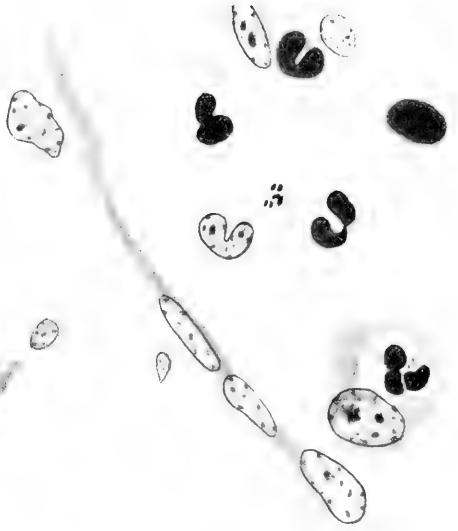9 Carbon-containing phagocytic mononuclear leucocyte and one containing a polymorphonuclear leucocyte in the peripheral sinus of a retroperitoneal lymph node one day after subcutaneous injection (dog 177, table 2).

10 Lymph nodule from a retroperitoneal lymph node ten days after subcutaneous injection (dog 152, table 2). Most of the carbon is in phagocytic mononuclear leucocytes in and near the sinuses.

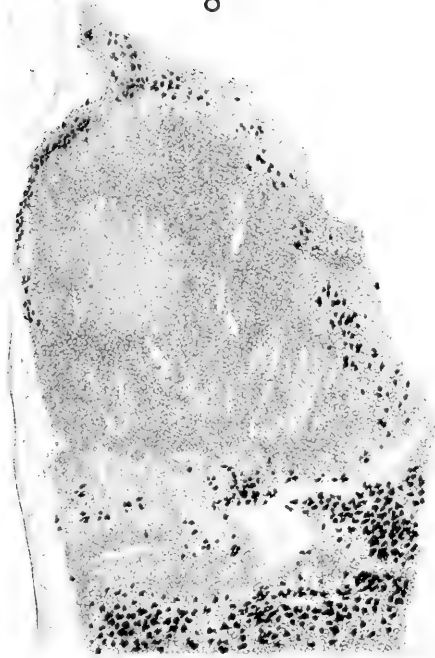
11 Blood-vessel at the periphery of a germinal center (retroperitoneal lymph node, dog 151, table 1). The endothelial lining shows carbon. A mitotic figure and two large lymphoblasts at the right of the vessel.



8



9



L. MASSOPUST. 18.

10



11

Resumido por el autor, Harold Dickinson Senior.

Sobre el desarrollo de las arterias de la extremidad inferior
del hombre.

La arteria axial primitiva nace de la raíz dorsal (secundaria) de la arteria umbilical; perfora el plexo lumbosacro y sigue el trayecto del nervio tibial a lo largo del muslo. Por debajo de la rodilla pasa primero entre el músculo poplíteo y la tibia y después entre el músculo tibial posterior y la membrana interósea. Entra la planta del pié pasando por detrás del maleolo medio y se ramifica para constituir la red plantar y ramas que atraviesan el seno tarsal para formar la red dorsal. Algunas partes de la arteria axial persisten para formar en el adulto la arteria glútea inferior, anastomosis postfemorales, porción proximal de la arteria poplíteas, raíz de la arteria articular infero-media, una pequeña parte del trayecto de la arteria tibial anterior, toda la tibial recurrente posterior y una pequeña porción de la arteria peronea. En el miembro se desarrollan muchas arterias secundarias. La arteria iliaca externa nace de la umbilical y se divide en la epigástrica inferior y la femoral. Dos de las arterias secundarias de la pierna se combinan con una porción de la axial para formar la arteria peronea y otras tres arterias se combinan para formar la arteria tibial anterior. Porciones de dos arterias se mezclan para formar la parte distal de la arteria poplíteas y partes de estas mismas arterias entran en la planta del pié para transformarse en las arterias plantares. Las otras arterias del pié se derivan de las redes embrionarias.

Translation by Dr. José F. Nonidez,
Columbia University

THE DEVELOPMENT OF THE ARTERIES OF THE HUMAN LOWER EXTREMITY

H. D. SENIOR

Department of Anatomy, New York University

ELEVEN FIGURES

I. INTRODUCTION

a. General considerations

It is well known that considerable differences exist between the various types of arterial distribution which are normally encountered in the pelvic limb of the different representatives of the mammalian series. In all mammals in which the developmental history of the arteries of the limb has been investigated, however, it has been found that the adult arterial system of the part results from the elaboration of two embryonic vessels.

Both of the embryonic arteries in question take origin from the dorsal (secondary) root of the a. umbilicalis. One of them, the primitive artery of the limb, traverses the axis of the thigh and leg and divides into a number of branches for the supply of the foot. This vessel is present before the limb forms a distinct prominence upon the surface of the body and is known as the axial or ischiadic artery.

The other is an artery of later development which traverses the pelvis and the ventral region of the thigh. It joins the axial artery a short distance above the knee and gives rise to the a. iliaca externa, the a. femoralis, and the a. epigastrica inferior and to the branches which arise from these vessels. All other arteries of the limb arise from the axial artery itself or from the branches to which it gives origin.

Whether the relations of the embryonic axial artery to the other constituents of the limb are identical in the embryos of

all mammalian forms is a question to which direct observation of the vessel has not yet furnished an answer. Much indirect evidence bearing upon this subject is furnished by Zuckerkandl's comparative study of the arteries of the leg which appeared in 1895.

The study in question, although it is mainly concerned with the relations of the adult arteries, is influenced throughout by embryological considerations. It includes, in fact, a study of the arteries in a series of vertebrate embryos in which the mammalia are represented by the rabbit and cat. Zuckerkandl's work is obviously based upon the conception of the identity of the course of the axial artery throughout the mammalian series. It may be said that the general results of the investigation are greatly in favor of the correctness of the author's conception.

The principal relations of the axial artery of the human embryo have been established by the present study. An adequate account of the relations of this and other arteries of the developing limb of one of the quadruped mammals would be of great value for purposes of comparison.

The only consecutive account which has been given of the development of the arteries of the pelvic limb in any mammalian form is that of DeVriese, which appeared in 1902. It deals with the human embryo. The other papers contained in the literature of the subject are concerned with isolated stages in the development of one or more forms rather than with a complete history of the arteries of any particular mammal.

Hochstetter showed for the first time, in 1890, that the primitive artery of the mammalian thigh, which he termed the *a. ischiadica*, follows the course of the *n. ischiadicus* in the embryos of both the cat and the rabbit. He also described the development of the *a. femoralis*, which, appearing at a later stage, supersedes the proximal part of the *a. ischiadica* as the chief artery of the thigh. The secondary assumption of the original function of the *a. ischiadica* by the *a. femoralis* was shown to occur in man by DeVriese in 1902.

Hochstetter did not succeed in following the continuation of the *a. ischiadica* through the leg. Leboucq, however, described it in 1893, as pursuing, in the human embryo, an axial course between the tibia and fibula and finally perforating the tarsus to reach the dorsum of the foot.

In 1894, Zuckerkandl described the continuation of the *a. ischiadica* of the rabbit as traversing the flexor region of the leg and dividing into a number of branches for the supply of the sole. He also described two branches of the artery which supply the extensor aspects of the leg and foot, respectively. In 1895 the same author described the perforating artery of the tarsus in cat and rabbit embryos and made considerable progress in the nomenclature to the primitive artery of the limb.

In Zuckerkandl's second paper a distinction was made between the terms axial and ischiadic which formerly had been used more or less interchangeably to denote the primitive artery of the limb. For the entire artery Zuckerkandl employed the name axial. He restricted the use of the term ischiadic to the part of it which traverses the thigh and used the term *a. interossea* for the remainder of the vessel. The same paper contained the first accurate description which had been given of the distal part of the axial artery of any mammal. The *a. interossea* was described in the rabbit as lying between the interosseous membrane and *m. tibialis posterior*.

Grosser, in 1901, and DeVriese, in 1902, described the *a. interossea* (the *a. nervi interossei cruris* of the latter author) in bat and human embryos, respectively, as pursuing the course it had been described by Zuckerkandl as following in the rabbit. Both of these observers also recorded the presence, in the subjects of their respective studies, of the *r. perforans tarsi*.

During the course of the present investigation it has become apparent that the existing literature contains no definite statement regarding the course taken by the part of the axial artery which traverses the popliteal fossa. It is questionable whether the popliteal section of the axial artery has been tacitly included as a part of the *a. ischiadica* or not, since the distal limit of the latter artery does not appear to have been definitely fixed. In

the following description the term *a. ischiadica* has been restricted to the part of the axial artery proximal to the site at which it is subsequently joined by the *a. femoralis*. This restriction has necessitated the use of a new term for the part of the axial artery which extends from the hiatus tendineus (the approximate site of the femoro-ischiadic junction) to the point (in the neighborhood of the distal border of the *m. popliteus*) at which the *a. interossea* begins.

An examination of the popliteal portion of the human axial artery shows that its distal part does not lie upon the posterior surface of the *m. popliteus* as does the distal part of the adult *a. poplitea*, but upon the anterior surface of that muscle. It seems clear, therefore, that the distal part of the *a. poplitea* of the majority of adult mammals, which lies upon the anterior surface of the *m. popliteus* represents a persisting portion of the embryonic axial artery. On this account the name *a. poplitea profunda* has been used in the following pages to designate entire popliteal section of the human axial artery.

The solution of Zuckerkandl's difficulty regarding the difference of the mutual relations between the *a. poplitea* and the *m. popliteus* in man on the one hand and in the majority of other mammals upon the other has thus been furnished by determining the course of the popliteal portion of the axial artery of the human embryo.¹

The part of the adult human *a. poplitea* which extends from the hiatus tendineus to the origin of the *a. genu inferior medialis* is a direct survival of the embryonic *a. poplitea profunda*. The part of that artery which lies upon the posterior surface of the *m. popliteus* is derived from an embryonic vessel of later formation referred to in the following pages as the *a. poplitea superficialis*.

¹ *Arteria poplitea*. Ein Stück dieser Arterie lagert bei den Halbaffen und den Primaten auf der freien (dorsalen) Fläche des Musculus popliteus, bei den übrigen Säugetieren auf der Gelenkkapsel, bedeckt von dem oben erwähnten Muskel. Diese Verschiedenheit im Verlaufe der Poplitea kann nur auf die weise erklärt werden, dass entweder die den Muskel querenden Stücke der Poplitea nicht homolog oder die beiden Muskeln nicht dieselben sind. Nach meinen bisherigen Erfahrungen scheint ersteres wahrscheinlicher zu sein. (Zuckerkandl ('95), p. 255.)

The literature dealing with the arteries of the mammalian pelvic limb shows a tendency towards the perpetuation of a conception regarding the relation of the adult human *a. peronaea* to the embryonic *a. interossea* which Zuckerkandl has already shown to be erroneous. Stieda stated, in 1893, that the study of the variations of the arteries of the human leg had led him to the conclusion that the *a. peronaea* represents a persisting portion of the embryonic axial artery. A similar opinion regarding the relationship between these two arteries was expressed by Zuckerkandl in 1894. In 1895 the recognition of the course of the *a. interossea* led Zuckerkandl to a modification of the views he had previously expressed upon the subject. He drew attention to the fact that it would be impossible for the part of the *a. peronaea* which is separated from the interosseous membrane by the *m. tibialis posterior* to be a derivative of the part of the *a. interossea* which lies between the membrane and the muscle. In 1902 DeVriese revived the conception of the identity of the *aa. interossea* and *peronaea*, notwithstanding the obvious justice of Zuckerkandl's contention.

A careful examination of the embryos which form the basis of the present study and of a large number of others belonging to the collection of the Carnegie Institution has been made in the search for a *r. saphenus* of the *a. femoralis* comparable in extent to that of the *a. saphena* which occurs very rarely in adult man and invariably in most of the other mammals. The result has been entirely negative.

That the *a. saphena* occurs occasionally in the human embryo is indicated by the fact that its presence has been noted at least five times in the adult. In the embryos examined in connection with the present study, however, the *r. saphenus* has not been found to extend in a single instance beyond the middle of the leg.

I take this opportunity of expressing my gratitude to Professor Thyng for the trouble he has taken in the revision of this manuscript.

b. Material

In the present investigation the lower extremities of embryos have been studied in seven stages of development, one extremity or both having been reconstructed in wax. The selection of stages depended upon the accessibility of well-preserved material rather than upon a preconceived plan regarding the most instructive stages to use.²

The following embryos have been studied, the right limb having been reconstructed in all cases. The embryos of which both lower limbs have been reconstructed are marked with an asterisk:

6.0 mm.* Carnegie Institution, Embryological Collection (C.I.E.C.) No. 1075.

8.5 mm.* Cornell University, Embryological Collection (C.E.C.) No. 9.

12.0 mm.* Cornell University, Embryological Collection (C.E.C.) No. 3.

12.0 mm.* Minnesota, Embryological Collection (M.E.C.) No. H. 16.

14.0 mm. Cornell University, Embryological Collection (C.E.C.) No. 5.

17.8 (?) Harvard University, Embryological Collection (H.E.C.) No. 839.

18.0 mm. Carnegie Institution, Embryological Collection (C.I.E.C.) No. 409.

22.0 mm. Cornell University, Embryological Collection (C.E.C.) No. 1.

For their generosity in placing their material at my disposal, I wish to express my great obligation to Profs. C. M. Jackson, F. T. Lewis, F. P. Mall, C. R. Stockard, and G. L. Streeter.

Toward the end of the investigation, there were a number of difficulties, for the solution of which the examination of rather close intermediate stages was required. Such stages were found in the collection of the Carnegie Institution at Baltimore.

In the formation of this valuable collection, so ably cared for and sympathetically administered, Professor Mall has made available to his fellow-workers a wealth of material adequate for the solution of any ordinary problem in human embryology.

The reconstruction of vascular plexuses in wax, using every second or fourth section as the case may be, is somewhat difficult. The practice followed has been to unite the parts of the adjacent

² In the case of the embryos from the Carnegie Institution and Minnesota University the measurement is crown-rump. The Harvard and Cornell measurements represent the greatest total length.

plates which fit after careful adjustment and to remove those which do not join. In this way the plexus represented in the reconstruction is probably less dense than that occurring in the embryo. The reconstruction, in fact, reproduces the spirit rather than the letter of the original.

In reconstructing the stage of 6 mm. consecutive sections were used, and these were comparatively thick (20μ). In this case the parts usually fitted so accurately that the plexuses, as reproduced, must represent, as nearly as possible, the actual conditions in the original.

c. Nomenclature

As already noted, the term *a. poplitea profunda* is used in the following account to denote the popliteal section of the embryonic axial artery. The term *a. ischiadica* and *a. interossea* have been retained for the proximal distal parts of that artery, respectively.

To the artery which normally perforates the tarsus of adult ungulates, and which has been recognized in all mammalian embryos hitherto observed, numerous terms have been applied.³ The name *ramus perforans tarsi* is used here.

For two of the embryonic arteries the names used by Hyrtl in 1864 have been retained. They are the *r. coronarius* (of the medial malleolus) and the *a. peronaea posterior superficialis*.

The description of a number of embryonic vessels, the existence of which has not been noted heretofore, has necessitated the use of several new terms. These conform, as nearly as may be, with current usage.

In referring to the relative positions of the structures of the limb, the adult terms of orientation have been used throughout. This course has been adopted in order to avoid the confusion which might arise from the alternative use of two sets of terms in making comparisons between the relative positions of structures in the adult and embryonic limb, respectively.

³ *Ramus and sinum tarsi*, Hyrtl ('64); *Arteria tarsea perforans*, Süssdorf ('89); *perforans tarsi*, DeVriese ('92) *Arteria anastomotica tarsi*, Salvi ('99).

The limb preserves its primitive position which, with the exception of progressively increasing flexion of the knee, remains unchanged throughout the period of development under consideration. The flexor aspect of the embryonic thigh and leg and the plantar aspect of the sole are directed medially; the great toe is preaxial or cephalic. The term posterior for the adult has, therefore, the same significance as the term medial for the embryo; so have, respectively, the terms anterior and lateral, medial and pre-axial, lateral, and post-axial. For the parts above the hip-joint there can be no possibility of confusion, since like terms of orientation serve equally well for the postnatal and embryonic periods.

II. THE ARTERIAL SYSTEM OF THE LOWER LIMB IN PROGRESSIVE STAGES OF DEVELOPMENT

a. Stage of 6 mm. C. I. E. C., no. 1075, figs, 1 and 9 A.

In the lumbar region the nerve roots are not recognizable. The ganglia of the lumbar and sacral regions appear as segmentally disposed swellings upon the continuous neural crest. Distal to the second lumbar segment the postcardinal vein becomes plexiform. The medial part of the plexus receives the segmental veins, the lateral part represents the still indefinite marginal vein.

The dorsal segmental arteries, with the exception of the fifth lumbar and second sacral, pass directly to the spinal cord without branching. The umbilical arteries, the ventral roots of which are still very large, arise opposite the intervals between the third and fourth lumbar segmentals.

The secondary, or dorsal, roots of the umbilical arteries are present, but are smaller than the original or ventral roots of that vessel. Each dorsal root, in the embryo under consideration, arises from the union of two arteries.

The chief share in the formation of the dorsal root of the a. umbilicalis is taken by a vessel which arises from the fifth lumbar segmental artery a short distance beyond its root. The vessel in question is joined almost perpendicularly near its origin by a smaller one which springs from the aorta in the interval between the fourth and fifth lumbar segmental arteries.

The dorsal root of the a. umbilicalis, which may be said to begin at the junction of the two vessels mentioned above, continues the transverse direction of the larger of the two, until it reaches the dorsal aspect of the Wolffian duct of its own side. In this situation it turns ventrally, passing upon the lateral side of the duct, which is now enclosed between the two roots of the umbilical artery, to join the ventral root.

As the dorsal root of the a. umbilicalis curves around the lateral side of the Wolffian duct it gives origin to the axial artery of the lower extremity and to the a. pudenda interna.

The axial artery, takes an almost transverse, slightly recurrent, course towards the surface. It ends by dividing into two

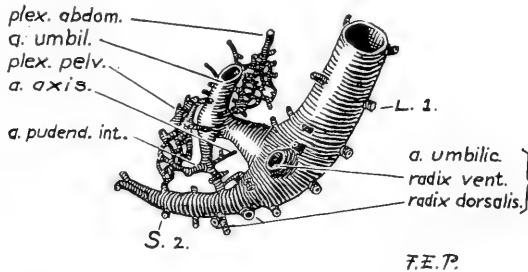


Fig. 1 Reconstruction showing the distal end of the aorta; also the arteries of the right lower extremity and neighboring parts in a human embryo of 6 mm. C.I.E.C., 1075). Medial aspect. $\times 40$ diams.

branches, each of which breaks up into a plexus which passes over into the postcardinal venous plexus. The a. pudenda interna follows the dorsolateral surface of the Wolffian duct towards the urogenital sinus and enters the pelvic arterial plexus.

In addition to the arteries already described, there are two extensive arterial plexuses, which may be called the abdominal and pelvic plexuses, respectively. Of these the abdominal arises by seven or eight stems from the concavity of the umbilical artery somewhat distal to the junction of its two roots. It invades the flexor region of the thigh, although it is uncertain to what extent, for the lower limb bud is not distinctly circumscribed at this period.

The abdominal plexus has no connection whatever with the segmental arterial series. It is drained partly by postcardinal plexus, but mainly by the umbilical vein. The pelvic plexus arises by two roots from the convexity of the umbilical artery opposite the roots of the abdominal plexus. It covers the cloaca and receives the pudendal artery and a large branch from the second sacral segmental. It is drained by the postcardinal plexus. The abdominal and pelvic plexuses appear to be connected by a few vessels passing lateral to the umbilical artery. It is probable that all the visceral branches of the adult *a. hypogastrica* (excepting the superior vesical) arise out of the primitive pelvic plexus of the original umbilical artery. The parietal branches (as far as they are present before the stage of 22 mm.) arise from, or very near to, the axial artery. They are therefore connected with the dorsal root.⁴

This stage agrees in most essentials with the 5-mm. embryo (II) described by Tandler ('03). The inferior mesenteric artery arises opposite the first lumbar segmental.

b. Stage of 8.5 mm., C. U. C., no. 9, figs. 2 and 9 B

The femoral, obturator, genitofemoral, and peroneal nerves are readily recognized as short relatively unbranched trunks. The extremity of the tibial is divided into what appear to be the medial and lateral plantar nerves.

The *aa. umbilicales* have lost their original (ventral) roots and now spring from the aorta in the intervals between the fourth and fifth dorsal pairs of lumbar segmental arteries.⁵ The

⁴ The distinction between the respective origins of the visceral and parietal branches of the *a. hypogastrica* has already been pointed out by McMurrich ('04).

⁵ It is questionable whether the common iliac artery should be regarded as belonging to the fifth lumbar dorsal segmental or not. At the stage of 8.5 mm. of this series the fifth lumbar segmental has regained its independence, and springs from the aorta (on both sides) between the fourth and fifth. The work of Levy ('02) shows, however, that absence of the *a. lumbalis ima* is the rule rather than the exception. Whether this vessel is frequently retained by the root of the *a. iliaca communis* or merely overshadowed (as it were) by it is doubtful.

fifth lumbar segmental arteries have thus regained their independence, and, like the other segmental arteries in this region, pass to the spinal cord without branching.

The axial artery passes distally into the lower limb, crossing the *n. tibialis* posteriorly from the medial to the lateral side. It then follows the posterior aspect of the skeletal mesenchyme throughout the leg into the sole. In the latter situation it breaks up into a flattened plexus which extends somewhat beyond

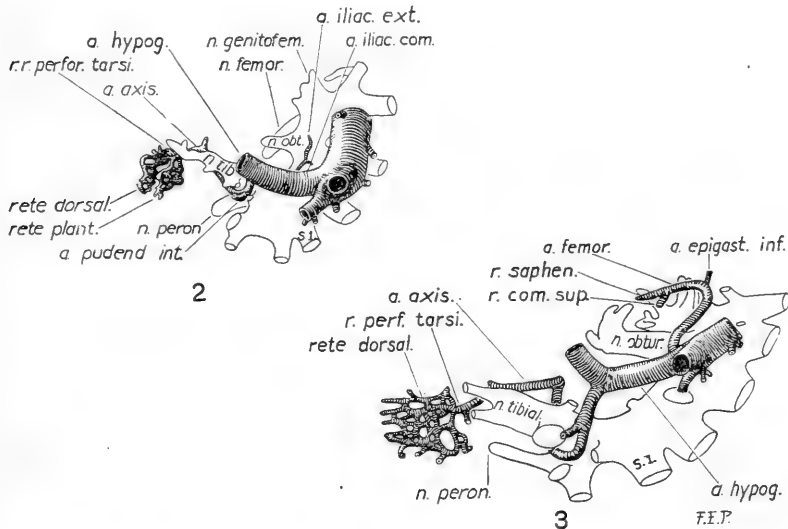


Fig. 2 Reconstruction showing the arteries of the right lower extremity in a human embryo of 8.5 mm. (C.E.C., 9). Medial aspect. $\times 20$ diams.

Fig. 3 Reconstruction showing the arteries of the right side of the pelvis, right thigh, leg, and dorsum of the foot in a human embryo of 12 mm. (M.E. C., H. 14). Medial aspect. $\times 20$ diams.

the extremities of the plantar nerves. Just as it is breaking up into the plantar plexus the axial artery gives origin to two or three branches which pierce the mesenchymal skeleton of the foot to reach the dorsum. Upon the dorsum of the foot the perforating branches produce another flattened plexus. The two plexuses (or retia) of the foot are separated from one another by the mesenchymal skeleton of the foot, the plantar rete lying between the latter and the plantar nerves.

In passing from the medial to the lateral side of the sacropudendal plexus, the axial artery runs between the main plexus and a branch from its lower part. The branch referred to has been removed from the reconstructions illustrated in figures 1 to 6, since it partially covers the artery when viewed from the medial side.

From the lateral aspect of the concavity of the umbilical artery, some distance proximal to the origin of the axial artery, there now arises a new vessel, the a. iliaca externa. This vessel takes a cephalic direction, nearly parallel to the aorta, coursing medially to the origin of the obturator nerve. At this stage the wall of the external iliac artery is thin and its course slightly tortuous. The artery is not connected with the dorsal segmental arterial series or with any other artery. The further history of the external iliac is rather remarkable. It soon becomes quite straight and acquires a wall of great thickness, but remains unbranched until a stage of (approximately) 12 mm. The a. iliaca externa appears as a thick-walled straight artery in the well-known pig embryo of 12 mm.

The place of origin of the a. iliaca externa marks the permanent subdivision of the dorsal root of the umbilical artery into two parts. The proximal part becomes the adult a. iliaca communis while the distal part represents the a. hypogastrica and a short proximal section of its umbilical branch.

At this stage the marginal vein is fully formed; its caudal root, represented by the v. ischiadica, runs in close contact with the proximal part of the corresponding artery.

c. Stage of 12 mm. M. E. C., no. H. 16, figs. 3 and 9 C

Condensation of the mesenchymal skeleton is now well advanced. It is not sufficiently definite in the tarsal region, however, for the determination of the course taken by the connection between the axial artery and the dorsal rete of the foot. The surfaces of the growing nerves are considerably roughened by the beginning outgrowth of numerous branches, many of which can be identified.

The course of the axial artery is somewhat less straight than in the preceding stage. This is due chiefly to a sharp convexity directed toward the growing extremity of the a. femoralis. The convexity is surmounted by a short sprout indicating the point at which the femoral is later to unite with the axial artery. Although the axial artery is straighter in the preceding stage than at the stage of 12 mm., an irregularity is noticeable at the stage of 8.5 mm. in a similar situation. It seems to represent an earlier indication of the convexity which is so pronounced at the present stage of development.

Distal to the knee the axial artery lies in the narrow interval between the tibia and fibula. The interosseous membrane and individual muscles are still unrecognizable, but, although the artery bulges toward the extensor region, its distal course clearly indicates that it does not leave the flexor aspect of the leg.

At what appears to be the proximal end of the very short tibiofibular interspace a second bend occurs in the axial artery. This bend is so pronounced as to practically amount to the bud of the vessel which is shortly to grow into the extensor aspect of the leg from this point.

The dorsal and plantar retia of the foot are richer than in the preceding stage. The connection between the axial artery and the dorsal rete is now reduced to a single vessel of large size, the r. perforans tarsi.

The a. iliaca externa has bifurcated into the a. epigastrica inferior and the a. femoralis.⁶ The latter is contrasted sharply from the a. iliac externa by the thinness of its walls, which consist of endothelium only. Its structure resembles very closely that of the femoral vein which accompanies it. The femoral artery runs parallel with and upon the medial side of the n. saphenus. Its extremity, now about half way along the femur, is bifurcated into a lateral and a medial branch. The former is short and will later join the axial artery; it may be called the

⁶ That the a. epigastrica inferior is an independent branch of the a. iliaca externa, which considerably antedates it and the a. femoralis in development, has already been pointed out by the writer (Senior, '17).

ramus communicans superius. The latter is longer and is recognizable as the ramus saphenus of the a. genu suprema.

The difficulty in finding developmental stages in which the a. femoralis is present, but not yet united with the axial artery, coupled with the thinness of the wall of the femoral artery at this stage, indicates that the artery is one of extremely rapid growth. In a 12-mm. embryo slightly younger than the specimen described (C. E. C., No. 3), reconstruction was begun under the impression that the femoral was absent. After more thorough study the artery was identified, bifurcated as in M. E. C., No. H 16, but much shorter. At this stage the a. femoralis has no branches, other than the terminal bifurcation already referred to.

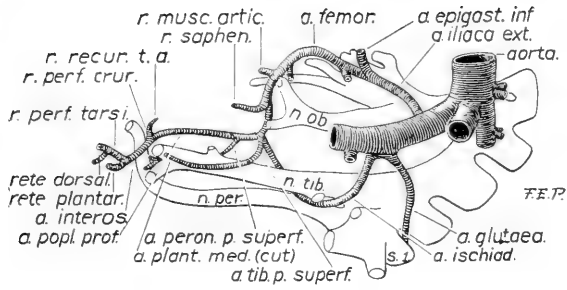
d. Stage of 14 mm. C. E. C., no. 5, figs. 4 and 9 D

This stage is principally characterized by the participation of the a. femoralis in the blood supply of the leg and by the appearance of three branches of the axial artery.

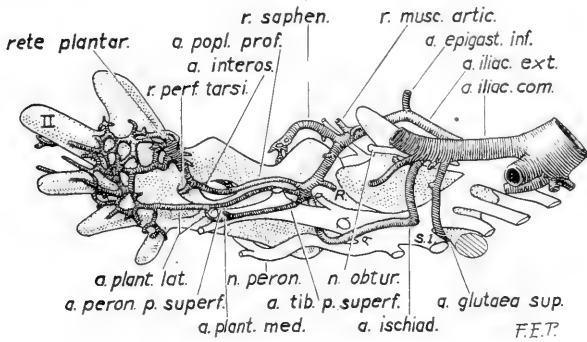
The r. communicans superius of the a. femoralis has joined the axial artery at the more proximal of the two angular bends noticed in the preceding stage. The r. saphenus remains free and can be traced to the level of the knee joint.

At the more distal bend of the axial artery there is now a branch, which passes to the extensor surface of the leg. This artery passes through the proximal end of the tibiofibular interspace and takes a recurrent course toward the knee. The proximal part of the artery takes part in the formation of the adult a. tibialis anterior. It may be referred to as the ramus perforans cruris. The recurrent vessel continuing from the r. perforans cruris is the arteria recurrens tibialis anterior of the adult.

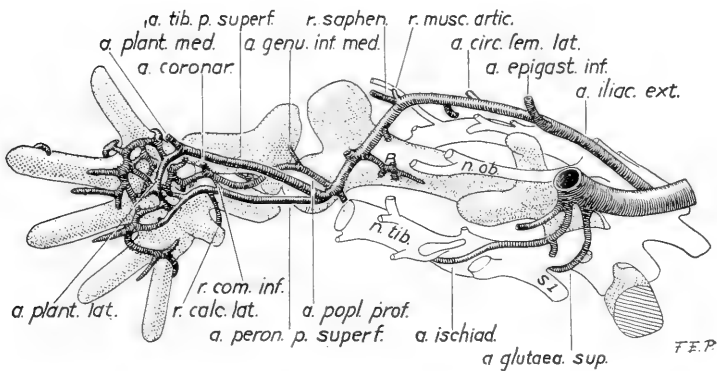
The points marked upon the axial artery by means of the r. communicans superius and by the origin of the r. perforans cruris, respectively, may be used for the convenient subdivision of the vessel into three parts. The part upon the proximal side of the r. communicans superius will be referred to as the a. ischiadica and that upon the distal side of the r. perforans cruris



4



5



6

Fig. 4 Reconstruction showing the arteries of the right side of the pelvis and right thigh and leg in a human embryo, of 14 mm. (C.E.C., 5). Medial aspect. $\times 20$ diams.

Fig. 5 Reconstruction showing the arteries of the right side of the pelvis and right lower extremity in a human embryo of 17.6 mm. (H.E.C., 839). Medial aspect. $\times 20$ diams.

Fig. 6 Reconstruction showing the arteries of the right side of the pelvis and right lower extremity in a human embryo of 18 mm. (C.E.I.C., 409) $\times 20$ diams.

as the *a. interossea*. The intervening part will be called the *a. poplitea profunda*.

At this stage the *a. poplitea profunda* has two branches which course longitudinally through the posterior crural region. One of these arteries resembles, in a general way, the *a. tibialis posterior* of the adult, it may be called the *a. tibialis posterior superficialis*. The other slightly more distal in its place of origin is the *a. peronaea posterior superficialis* (of Hyrtl).⁷ The relations borne by these arteries to the *n. tibialis* remain constant throughout a prolonged period of development.

The *a. tibialis posterior superficialis* passes at first backward upon the medial side of the *n. tibialis* to reach its posterior aspect. Running upon the posterior aspect of the *n. tibialis* in the leg, it passes into the sole upon the inferior aspect of the *n. plantaris medialis*. The part of the artery which enters the sole becomes the *a. plantaris medialis* of the adult.

The *a. peronaea posterior superficialis* passes from the medial to the lateral aspect of the *n. tibialis* by skirting around the proximal and lateral sides of a large muscular ramus of the nerve.⁸ It follows the anterior and lateral aspect of the *n. tibialis* as far as the place of origin of the *nn. plantares*. In this situation the artery bifurcates into a lateral and a medial branch. The branches are both short and end blindly.

Two branches now spring from the lateral side of the *a. femoralis*. One of these is situated upon the proximal side of the *r. saphenus* and represents the *r. musculo-articularis* of the adult *a. genu suprema*. The other is the *a. circumflexa femoris lateralis* of the adult *a. profunda femoris*.

The branches arising from the medial side of the *a. femoralis* which will be discussed under stages E and F.

The *a. glutaea superior* is present and takes origin from the root of the *a. ischiadica*.

⁷ According to the system of nomenclature in use at the present time, the adjective 'posterior' as used by Hyrtl is redundant. In view of the essentially fugitive nature of anatomical terminology it has seemed unnecessary to modify Hyrtl's original term, which adequately meets the requirements of the case.

⁸ This is resolved later into the *rami musculares* for the *mm. popliteus*, *tibialis posterior*, *flexor digitorum longus*, and *flexor longus hallucis*.

e. Stage of 17.8 mm. H. E. C., no. 839,⁹ figs. 5 and 9 E

During the preceding stages of development the arterial retia of the foot have received their blood supply exclusively through the a. interossea; the reta plantare directly, and the rete dorsale by means of the r. perforans tarsi. The mesenchymal skeleton of the foot is now definitely circumscribed, and it is plain that the latter vessel reaches the dorsum by way of the tarsal sinus. The arterial retia of the foot lie in close contact with the tarsus and metatarsus and represent the following vessels of the adult circulation—the arcus plantaris and its articular branches, the aa. tarseae mediales and laterales, the a. arcuata, the aa. metatarsae and digitales (both dorsal and plantar), and the rami perforantes (including the ramus plantaris profundus).

The present stage is characterized by the presence of four arteries which traverse the leg for the supply of the sole. The a. interossea is still present, the aa. tibialis posterior superficialis and peronaea posterior superficialis have formed their definitive connections, and a new vessel, the a. tibialis anterior, pars distalis, has arisen.

The a. tibialis posterior superficialis and the a. peronaea posterior superficialis preserve in the leg the same relations to the n. tibialis as obtained in the preceding stage. At the ankle the medial terminal branch of the a. peronaea posterior superficialis has traversed the fork formed by the diverging plantar nerves to join the a. tibialis posterior superficialis. The lateral terminal branch of the same artery has reached the lateral side of the sole to join the plantar arterial rete. The connection thus formed between the a. tibialis posterior superficialis and the rete plantare becomes the a. plantaris lateralis of the adult foot. At the present stage of development it receives blood from two sources.

⁹ The greatest total length of this embryo, measured in formalin, was 17.8 mm. In 80 per cent alcohol it measured 13.6 mm. It has been described by Thyng as a 17.8 mm. embryo (Am. Jour. Anat., vol. 17, p. 31), and referred to by Thyng (Am. Jour. Anat., vol. 7, p. 489) and by Thyng and Lewis (Am. Jour. Anat., vol. 7, p. 505) as an embryo of 13.6 mm. The distribution of the arteries of the lower extremity resembles that of other embryos of about 15 or 16 mm.

The part of the a. tibialis posterior superficialis distal to the newly formed origin of the a. plantaris lateralis now becomes the a. plantaris medialis. The portion of the remainder of that vessel which is not concerned in the formation of the a. poplitea becomes the a. tibialis posterior.

The branches of the medial plantar artery anastomose, upon the lateral side of the foot, with the plantar rete, thus constituting a (transitory) superficial plantar arch.

The a. tibialis anterior, pars distalis, extends from the part of r. perforans cruris which lies in the extensor region of the leg to the rete dorsale. The portion of the r. perforans which now lies beyond the proximal end of the pars distalis corresponds to the adult a. recurrens tibialis anterior. The portion which extends from the a. poplitea profunda to the pars distalis enters into the composition of the adult a. tibialis anterior. The a. recurrens tibialis anterior is connected by means of a plexiform anastomosis, with the r. saphenus of the a. femoralis.

Upon the medial side of the a. femoralis there are at this stage three branches exclusive of the r. saphenus. Of these the most distal, which has a longer individual course than the others, takes a recurrent direction. The three branches break up to form an extensive plexus (not indicated in the figures) which ramifies throughout the thigh and is particularly rich around the perichondrium. It is probable that this plexus is eventually taken over by the adult a. profunda femoris and its branches. Two branches arise from the lateral side of the a. femoralis as in the preceding stage.

The a. glutea superior now takes direct origin from the a. hypogastrica upon the proximal side of the origin of the a. ischiadica.

f. Stage of 18 mm. C. I. E. C., no. 409, figs. 6 and 9 F

From the time of the junction between the r. communicans superius and the axial artery the caliber of the a. femoralis has gradually exceeded that of the a. ischiadica, which has now become exceedingly slender. After having traversed the lower portion of the sacropudendal plexus, the a. ischiadica passes

to the region of the hiatus tendineus upon the lateral side of the n. tibialis. The n. peronaeus lies immediately upon its lateral side.

In a general way the aa. poplitea profunda and interossea and their branches have the same arrangement as in the preceding stage. The exact course taken by these vessels can now be clearly recognized, since it is possible to identify the individual muscles of the limb.

The a. poplitea profunda runs between the m. popliteus and the tibia. At the proximal border of the muscle the artery gives off the a. genu media and a short trunk which is being formed by the progressive union of the proximal ends of the aa. tibialis posterior superficialis and the a. peronaea posterior superficialis. This short trunk, which lies upon the posterior surface of the m. popliteus, may now be called the a. poplitea superficialis. It forms the distal part of the a. poplitea of the adult. A short distance below the origin of the a. poplitea superficialis there arises the a. genu inferior medialis.

The a. interossea passes down the leg between the m. tibialis posterior and the interosseous membrane. Just above the medial malleolus it gives off a branch which passes around the posterior to the medial side of the tibia, the ramus coronarius of the medial malleolus (Hyrtl).¹⁰ At the malleolus the a.

¹⁰ In this vessel lies, according to Hyrtl, the key to the deep supramalleolar anastomosis (i.e., the r. communicans) between the a. peronaea and the a. tibialis posterior. The r. coronarius is regarded by Hyrtl as primarily passing from the a. peronaea around the medial side of the tibia to unite with the a. tibialis anterior. By means of a secondary connection occurring between the r. coronarius and the a. tibialis posterior, the former vessel eventually becomes converted into an anastomosing chain in which the aa. malleolaris anterior medialis, malleolaris posterior medialis and r. communicans are the named components. At the stage of 18 mm. of this series the r. coronarius arises from the part of the a. interossea which persists to take part in the formation of the adult a. peronaea. It runs, at this stage, as at the stage of 22 mm., toward the a. tibialis anterior as described by Hyrtl, and would, no doubt, eventually join it. Since in both these stages the a. tibialis posterior is situated upon a plane superficial to that occupied by the r. coronarius, no junction of the vessels in question has occurred. There can be little doubt, however, that Hyrtl has interpreted the nature of the r. coronarius correctly. His views upon this subject, which were derived from an extensive study of the normal and abnormal conditions found in adult legs, have been of the greatest assistance in the interpretation of the conditions obtaining during development.

interossea lies upon the lateral side of the tendon of the m. tibialis posterior (i.e., between tendon and malleolus) and then passes across the plantar end of the sinus tarsi to join the plantar rete.

The a. peronaea posterior superficialis is placed anteriorly and laterally to the n. tibialis and lies upon the posterior surface of the m. flexor hallucis longus. At the distal border of the muscle the artery lies near the a. interossea and interosseous membrane. In this situation it gives off a very large r. calcaneus lateralis which runs upon the lateral side of the tuber calcanei. This branch eventually forms the termination of the a. peronaea.

The a. tibialis posterior superficialis follows the posterior surface of the n. tibialis until the latter bifurcates in the neighborhood of the medial malleolus. Here the artery is placed between the n. tibialis and the tendon of the flexor hallucis longus. The a. tibialis anterior, pars distalis, has relations identical with those of the adult.

The relations existing between the various structures of the leg were ascertained by making a reconstruction which, from the fact that it yields but little information when entirely built up, is unsuitable for reproduction. The data gained from an examination of its separate parts are embodied in two diagrams (fig 7, A and B) which may serve as a rough guide to the interpretation of anomalies. These diagrams show, approximately, the course taken by the embryonic aa. poplitea profunda, interossea, and peronaea posterior superficialis.

The order in which the various structures passing from the leg to foot are arranged in the hollow between the medial malleolus and tuber calcanei is as follows: m. tibialis anterior and a. interosseus together; m. flexor digitorum longus; a. peronaea posterior superficialis; n. tibialis, a. tibialis posterior superficialis, and m. flexor hallucis longus.

Embryos of about this age are instructive mainly by reason of the fortunate circumstance that the individual muscles are differentiated before the continuity of the axial artery has been broken. Only one important change has occurred at this stage of development; this consists in the appearance of a com-

municating branch which foreshadows the development of the future a. peronaea.

. The communicating branch in question leaves the a. peronaea posterior superficialis at the proximal border of the m. flexor hallucis longus. It passes distally between the mm. flexor hallucis longus and tibialis posterior to join the a. interossea,

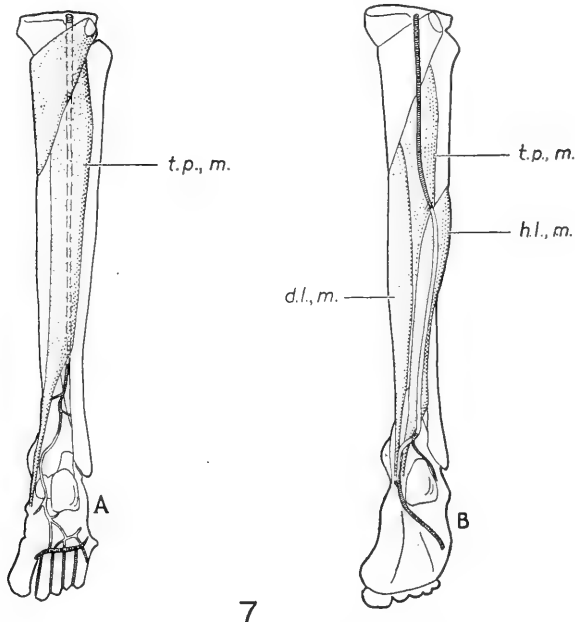


Fig. 7 Indicates the course of three arteries of the embryonic lower extremity, represented diagrammatically as they would appear if persisting in the adult. The vessels which normally persist are indicated by shading. A, A. poplitea profunda and a. interossea. B, A. peronaea posterior superficialis. *d. l. m.* flexor digitorum longus; *h. l., m.* flexor hallucis longus; *t. p., m.* tibialis posterior.

as that artery lies upon the interosseous membrane. It may be called the r. communicans inferius.

The entire r. communicans inferius persists in the adult as the portion of the a. peronaea which lies between the mm. flexor hallucis longus and tibialis posterior. The portions of the aa. peronaea posterior superficialis and interossea with which the

proximal and distal ends of the r. communicans inferior are respectively connected also take part in the formation of the a. peronaea.

Of the branches of the a. femoralis, those arising from the lateral side are identical with the branches of the preceding stage. There are three branches upon the medial side. The recurrent branch (*R* in figures) seems to be identical with the similar branch of the preceding stage. It is doubtful whether the two other medial branches correspond to those observed in the preceding stage or not.

g. Stage of 22 mm C. I. C no. 1, figs. 8 and 9 G

At this stage of development the continuity of the a. ischiadica has been interrupted and the a. femoralis alone conveys blood to the region beyond the knee.

The femoral artery pursues a more direct course than before and gives origin to most of its important branches. In addition to the a. circumflexa lateralis which appeared at the stage of 14 mm., it gives origin to the a. pudenda externa and the a. profunda. The r. musculo-articularis has migrated to the embryonic r. saphenus. The root of the latter branch, therefore, now appears as the a. genu suprema and gives origin to the r. saphenus and the rr. muscularis and articulares of the adult.

The a. profunda arises from the a. femoralis quite close to the origin of the a. circumflexa lateralis. It seems probable that the embryonic a. profunda sometimes arises from the root of the latter artery and sometimes directly from the femoral. In the former case the adult a. circumflexa lateralis would appear to arise from the a. profunda and in the latter from the femoral. The great variation in the site of the origin of the vessel is well known.

The a. profunda femoris gives origin to one perforating artery which, since it pierces the adductores brevis and magus, represents the first or second of the adult series. The single a. perforans is connected, by means of an extensive plexus, with the more distal section of the now interrupted a. ischiadica.

The *a. ischiadica* passes through the sacropudendal plexus as before and reaches the lateral side of the *a. tibialis*, which is now contained in the same sheath as the *n. peroneus*. After its exit from the pelvis the artery gives origin to a few gluteal branches and leaves the *n. tibialis* with the *n. cutaneus femoris posterior*. In company with the latter nerve and the *v. ischiadica*, it passes to the posterior surface of the thigh and ends by dividing into several cutaneous branches. This part of the *a. ischiadica* persists as the *a. glutea inferior*.

The more distal portion of the *a. ischiadica* is traceable as a definite path through a plexus upon the posterior surface of the *m. adductor magnus*, but has lost its continuity with the *a. poplitea*. The other vessel participating in the formation of the plexus is the perforating branch of the *a. profunda femoris*. This plexus evidently represents the terminal anastomosis between the perforating arteries of the adult. It probably takes a large share in the formation of the perforating arteries themselves.

The distal part of the anterior tibial artery has received blood since the time of its first appearance by way of the *a. poplitea profunda* and *r. perforans cruris*. An alternative path has now been provided by the appearance of a vessel which, passing around the distal border of the *m. popliteus*, connects the developing *a. peronea* with a more distal part of the *a. poplitea profunda*. It is the *r. communicans medius* which will later become the definitive proximal end of the *a. tibialis anterior*. The significance of this vessel in relation to the formation of the adult *aa. profunda* and *tibialis anterior* will be dealt with in the succeeding section.

The principal changes which have occurred in the embryonic arteries of the posterior crural region since the preceding stage of development involve the vessels which participate in the formation of the adult *a. peronea*. These changes consist in the disappearance of considerable parts of the *aa. interossea* and *peronea posterior superficialis*.

The portion of the *a. interossea* which formerly extended from the *r. perforans cruris* to the distal end of the *r. communicans*

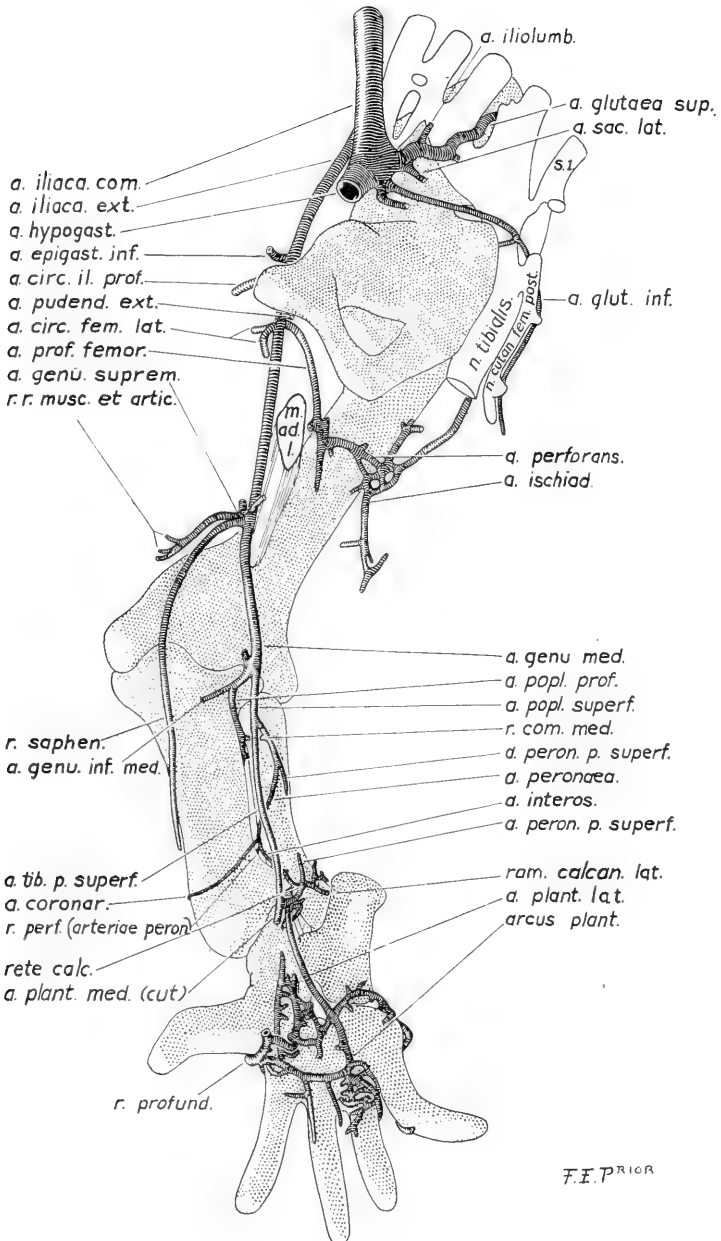


Fig. 8 Reconstruction showing the arteries of the right side of the pelvis and right lower extremity in a human embryo of 22 mm. (C.E.I.C., 1.). Medial aspect. $\times 20$ diams.

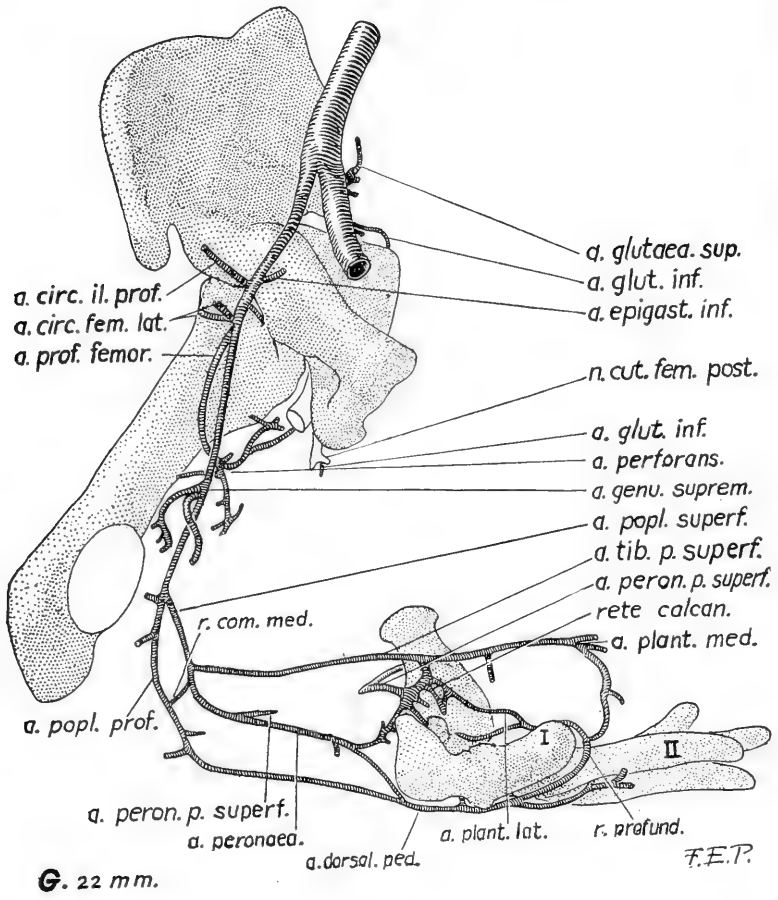
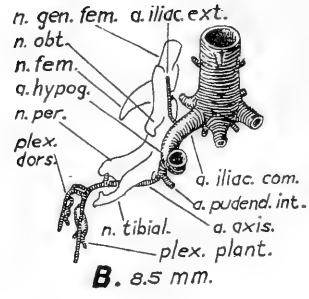
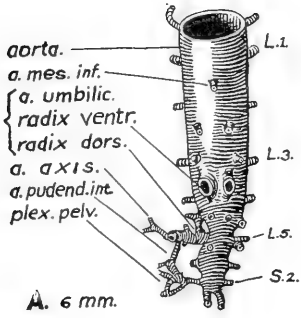
inferius has practically disappeared. The portion immediately beyond the distal end of the latter vessel lies upon the posterior surface of the interosseus membrane and gives origin to two branches. The remainder of the vessel is involved in the meshes of the rete calcaneum.

The portion of the *a. peronaea posterior superficialis* which extends from the present termination of the *a. poplitea superficialis* to the proximal end of the *r. communicans inferius* persists to become a part of the adult *a. peronaea*. A large part of the remainder of the artery has been lost, but the distal portion of the vessel can still be recognized as forming a projection upon the proximal aspect of the rete calcaneum. This portion of the artery can be traced through the meshes of the rete as far as the *a. plantaris lateralis*.

The rete calcaneum is very extensive at this stage of development and occupies the concavity upon the medial side of the calcaneum and surrounds the deep flexor tendons in the malleolar region of the leg.

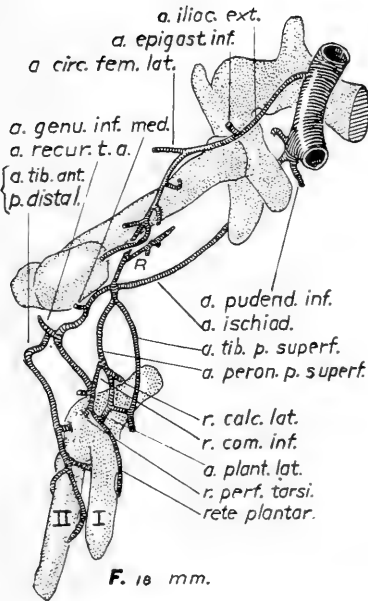
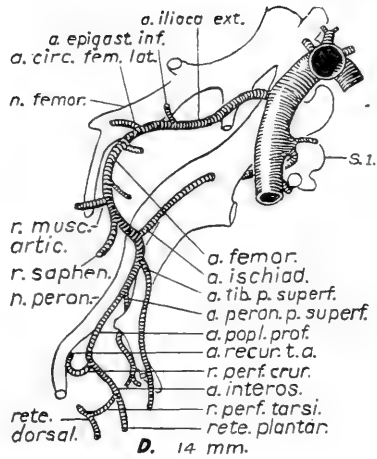
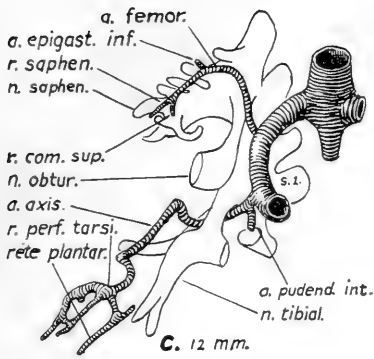
The component parts of the *a. peronaea* are now recognizable. The proximal part is derived from the *a. peronaea posterior superficialis*. The part between the *aa. flexor hallucis longus* and *tibialis posterior* represents the entire *r. communicans inferius*. The immediately succeeding part, which rests upon the *membrana interossea*, is derived from the *a. interossea*. The terminal part of the artery consists mainly of the *r. calcaneus lateralis* of the *a. peronaea posterior superficialis*. The connection between the *a. interossea* and the part of the latter artery which gives origin to the calcanean branch is effected through the agency of the plexus calcaneum.

The part of the *a. interossea* which takes part in the formation of the *a. peronaea* has been noted as giving rise to a branch, the *r. coronarius*, at the stage of 18 mm. At the present stage another branch arises from it, namely, the *r. perforans*. Both of them become branches of the adult artery. At the stage of 22 mm. the *r. coronarius* can be traced around the posterior and medial aspects of the tibia almost as far as the *a. tibialis anterior*. The views expressed by Hyrtl upon the conversion

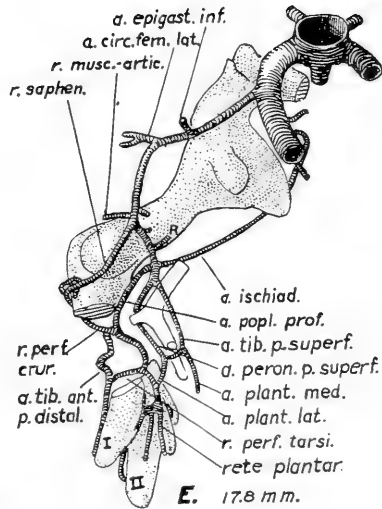


9

Fig. 9 Reconstructions showing the arteries of the right lower extremity in the seven human embryos shown in the preceding figures. The cephalic (embryonic pre-axial, adult medial) aspect is shown in all cases. A, $\times 40$, the others $\times 20$ diams. The skeleton is shown, in part, in E, F and G. Parts of the tibia



9



and tarsus are omitted in E, the tibia in F and the tibia and medial femoral condyle in G. The fibula is omitted in all. The medial plantar artery has been almost entirely removed from E and F. In C, *a. femor.* should read *a. iliaca ext.*

of the r. coronarius into the communicating branch and medial malleolar arteries of the adult have been noted above (footnote 10, p. 73).

A small portion of the a. peronaea posterior superficialis appears at the present stage as a branch of the a. peronaea. It runs upon the posterior surface of the m. flexor hallucis longus. The disintegrating a. interossea has left a similar vestige of its proximal end upon the posterior surface of its interosseous membrane. This vestigial branch occasionally persists as a branch of the adult a. tibialis anterior.¹¹ The terminal part of the main trunk of the a. peronaea posterior superficialis is now involved in the rete calcaneum. It usually leaves its mark in the adult as a recurrent element among the leash of branches known as the r. calcaneus medialis of the a. plantaris lateralis.

The aa. iliolumbalis and sacralis lateralis now arise from the a. glutea superior. The root of the latter artery has consequently become the posterior division of the adult a. hypogastrica. All the visceral arteries of the pelvis, with the exception of the a. vesicalis superior, have assumed their adult relations.

h. Changes occurring in the principal arteries subsequent to the stage of 22 mm.

A. Formation of the adult a. poplitea and a. tibialis anterior. Fig. 10, A, C. I. E. C., 22; B, C. E. C., 1; C, C. I. E. C., 840.

The r. communicans medius, the presence of which was noted at the stage of 22 mm., seems to arise at about that stage of development. In C. E. C., no 1, it is larger upon the right side than upon the left and in C. E. C., no. 6, which also measures 22 mm., it is absent altogether.

¹¹ Mr. Kimbrig has kindly dissected six adult legs for evidence of persistence of this vessel. In two instances he found a branch accompanying the n. interosseus cruris for a short distance. In both cases the branch arose from the root of the ramus fibularis.

It is very questionable whether the B. N. A. is correct in classifying the r. fibularis as belonging to the a. tibialis posterior. It has usually been regarded, in English-speaking countries at all events, as a branch of the a. tibialis anterior.

At the stage of 20 mm. (fig. 10, A) blood traverses the popliteal region to reach the r. perforans cruris through the original channel, namely the a. poplitea profunda. The a. poplitea superficialis is longer than at the stage of 18 mm., having increased in length at the expense of the aa. tibialis posterior superficialis and peronaea posterior superficialis.

At the stage of 22 mm. (fig. 10, B), a junction between the developing a. peronaea and the distal part of the a. poplitea

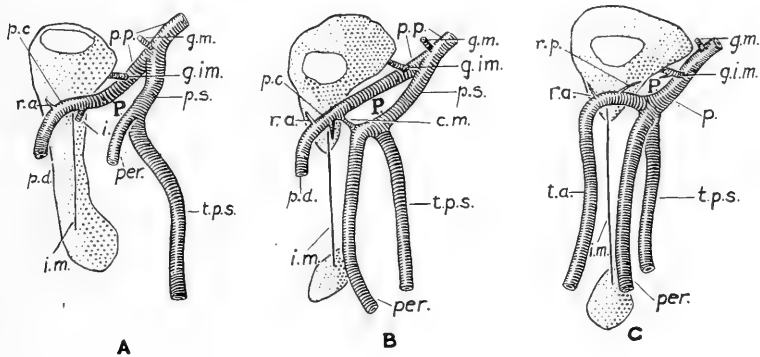


Fig. 10 Three reconstructions, each showing a sagittal segment (0.25 mm. thick) from the left leg of an embryo of the length indicated. Lateral aspect. $\times 19$. A, 20 mm.; B, 22 mm.; C, 24.8 mm. The tibia appears in all cases. P. indicates the position of the m. popliteus. c. m., a. communicans media; g. i. m., a. genu inferior medialis; g. m., a. genu media; i., a. interossea; i. m., interosseous membrane; p., a. poplitea; p. c., a. perforans cruris; p. d., a. tibialis anterior, pars distalis; p. p., a. poplitea profunda; p. s., a. poplitea superficialis; per., a. peronaea; r. a., a. recurrens tibialis anterior; r. p., a. recurrens tibialis posterior; t. a., a. tibialis anterior; t. p. s., a. tibialis posterior superficialis.

profunda has been effected by the development of the r. communicans medius. Blood may now pass from the proximal part of the a. poplitea profunda to the a. tibialis anterior, pars distalis by two routes: 1) anterior to the m. popliteus, by way of the distal part of the a. poplitea profunda and r. perforans cruris, or 2) posterior to the m. popliteus, by way of the a. poplitea superficialis, developing a. peronaea, r. communicans medius, a. poplitea profunda, and r. perforans cruris.

At the stage of 24.5 mm. (fig. 10, C) the direct arterial route upon the anterior surface of the m. popliteus has ceased to exist. The part of the a. poplitea profunda not incorporated in the definitive a. poplitea or tibialis anterior is represented: 1) by the root and a small branch of the a. genu inferior medialis of the former and 2) by the a. recurrens tibialis posterior of the latter. The main arterial channel through the popliteal region has thus been transferred from the anterior to the posterior surface of the popliteus muscle. Both the a. poplitea and the a. tibialis anterior have assumed their adult arrangement.

The formation of the adult a. poplitea results from the combination of two embryonic elements. The part of the vessel which extends from the hiatus tendineus to the origin of the a. genu inferior medialis is derived from the embryonic a. poplitea profunda. The remainder of the artery corresponds to the embryonic a. poplitea superficialis.

The embryonic components of the a. tibialis anterior consist of the r. communicans medius, a short section of the distal end of the a. poplitea profunda, the proximal part of the r. perforans cruris, and the entire tibialis anterior, pars distalis.

The a. poplitea superficialis reaches completion at the stage of 24.5 mm. by extending as far as the r. communicans medius which then becomes one of its terminal branches. By this means the a. peronaea relinquishes its temporary participation in the formation of the a. tibialis anterior.

B. The conversion of the embryonic a. tibialis posterior superficialis into the adult a. tibialis posterior.

The a. tibialis posterior superficialis is originally a branch of the a. poplitea profunda and extends into the sole. The distal portion of the artery, marked off from the remainder of the vessel upon the development of the a. plantaris lateralis, becomes the a. plantaris medialis. The proximal portion of the a. tibialis posterior superficialis has blended with the corresponding section of the a. peronaea posterior superficialis at the stage of 24.5 mm. as far as the termination of the popliteal artery. The further blending between these two arteries which is to occur during the later stages of development will cause the migration of the

origin of the a. peronaea from the termination of the a. poplitea to a point upon the a. tibialis posterior.

After the formation of the a. tibialis posterior has been completed by the occurrence of these changes the vessel still retains its original relation to the n. tibialis. The relations between the a. poplitea and the n. tibialis also differ from those of the adult.

The entire a. poplitea lies upon the medial side of the n. tibialis. The a. tibialis posterior crosses the medial side of the nerve to gain its posterior aspect upon which it runs until it ends behind the medial malleolus. The relations of the aa. poplitea and tibialis posterior to the n. tibialis have been thoroughly studied up to the stage of 22 mm. They seem to remain unaltered in the oldest serially cut embryo which has been examined in this regard. It is C. I. E. C., no. 1134, which measures 33.5 mm.

It is not difficult to see how an agency capable of moving the termination of the a. poplitea across the anterior aspect of the n. tibialis from the medial to the lateral side would produce a condition differing little from that normally encountered in the adult. Since the knee is flexed throughout intrauterine life it would seem that the modification of the relative positions of the arteries and nerve might depend upon the straightening of the n. tibialis which occurs at birth. In order to put the matter to the test, a foetus of 7.9 cm. was dissected.¹² The relations, however, were found to be identical with those of the adult.

Apart from the study of a few special points, this investigation has not extended beyond the stage of 22 mm. At that period all the vessels of the adult limb are present with the exception of two of the three aa. perforantes, which usually arise from the adult a. profunda femoris, the a. circumflexa femoris medialis, and the a. obturatoria. At the stage of 22 mm. two obturator veins are present in C. E. C., no. 1, one of these is tributary to the v. hypogastrica, the other to the v. femoralis.

The leading features in the process of the arterial development of the limb are indicated in figure 11.

¹² For this dissection and for many others made upon various mammals, I wish to express my indebtedness to Mr. B. Spector.

III. BRIEF DEVELOPMENTAL HISTORY OF THE INDIVIDUAL ARTERIES

A. Axis. This artery is a branch of the dorsal root of the a. umbilicalis, its presence has been noted by Tandler as early as the stage of 5 mm. '03). At the stage of 6 mm. it terminates by giving origin to the r. perforans tarsi and to the rete plantare.

The axial artery has three rami communicantes, and gives origin to three rami perforantes as follows:

The r. communicans superius, from the a. femoralis, joins it near the hiatus tendineus shortly before the stage of 14 mm.

The r. communicans medius, from its own branch the a. peronaea posterior superficialis, has joined it near the distal border of the m. popliteus at the stage of 22 mm.

The r. communicans inferius, from the a. peronaea posterior superficialis, joins it, near the distal border of the m. tibialis posterior, between the stages of 17 and 18 mm.

The r. perforans cruris arises between the stages of 13 and 14 mm.

The r. perforans arteriae peronaea arises between the stages of 18 and 22 mm.

The r. perforans tarsio is present at the earliest stages of development at which the axial artery has been observed.

Two points have been marked upon the axial artery at the stage of 14 mm. which may be used for the convenient subdivision of the axial artery into three parts. These points correspond to the termination of the r. communicans superius and to the origin of the r. perforans cruris, respectively.

The respective parts of the artery are defined and named as follows: The part upon the proximal side of the termination of the r. communicans superius is the a. ischiadica, while that upon the distal side of the origin of the r. perforans cruris is the a. interossea. That part intervening between the other two is the a. poplitea profunda. Further information regarding the axial artery may be found under the headings devoted to the description of its respective parts.

A. dorsalis pedis. This artery is a channel through the embryonic rete dorsale. Its importance dates from the appearance

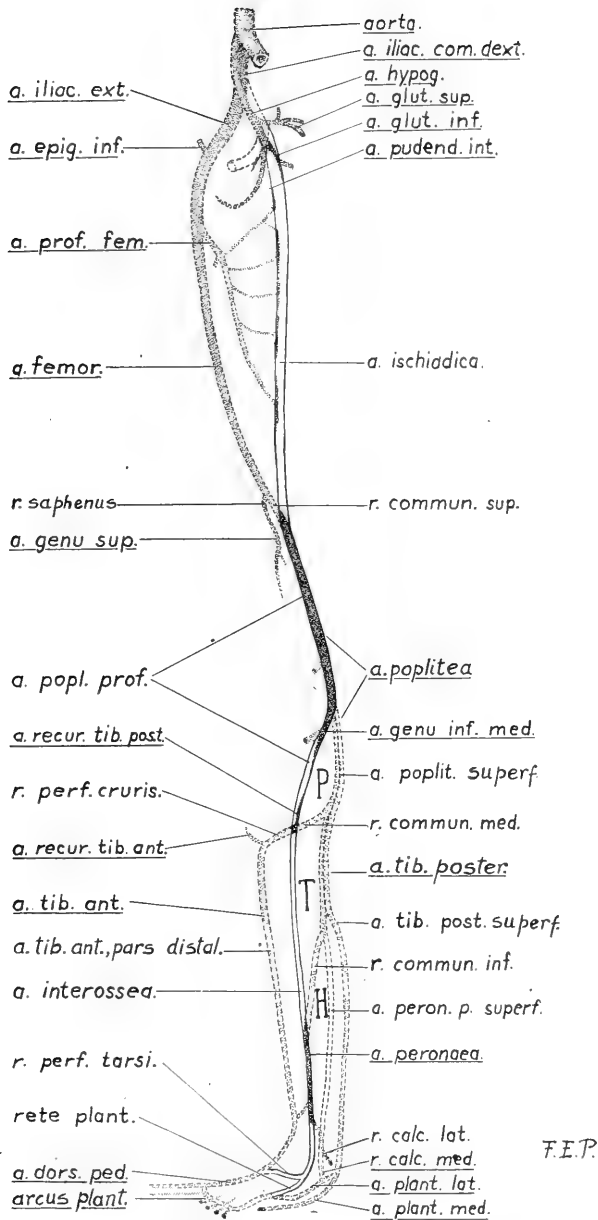


Fig. 11 Diagram to illustrate the general development of the arteries of the human lower extremity. Adult arteries are stippled and their names underlined. The chief embryonic channels are outlined in black. The black line is continuous only in the case of the axial artery, otherwise it is broken. The letter P indicates the position of the m. popliteus; T, that of the m. tibialis posterior, and H that of the m. flexor hallucis longus.

of the distal part of the a. tibialis anterior which is developed between the stages of 15 and 16 mm.

Branches. One of the adult rr. tarseae laterales represents the dorsal end of the r. perforans tarsi, all other branches are derived from the rete dorsale.

A. femoralis. This artery arises from the a. iliaca externa between the stages of 11 and 12 mm. From the time of the first appearance of the femoral artery its growing end is bifurcated into the r. communicans superius and the r. saphenus. The r. communicans superius traverses the hiatus tendineus and joins the a. axis between the stages of 12 and 14 mm., while the r. saphenus terminates below the region of the knee-joint.

Branches. The A. profunda femoris seems to be derived from an arterial plexus which envelops the femur as early as the stage of 14 mm. The proximal end of the artery is distinguishable at the stage of 22 mm. The a. circumflexa lateralis arises from the femoral trunk shortly before the stage of 14 mm. Although this artery is commonly regarded as a branch of the a. profunda, its original connection with the a. femoralis is frequently retained in the adult. The a. circumflexa medialis is not present at the stage of 22 mm. One of the a. perforantes, the first or second, is present at the stage of 22 mm., and is involved at that period of development in an extensive arterial plexus connected with the remainder of the distal part of the a. ischiadica. The other perforating arteries are not present at the stage of 22 mm. The a. pudenda externa is the only superficial inguinal branch present at the stage of 22 mm. The a. genu suprema corresponds to the part of the r. saphenus upon the proximal side of the origin of the rr. musculares and articulares. These branches arise directly from the a. femoralis, but have migrated to the embryonic r. saphenus by the stage of 22 mm. The distal portion of the latter vessel corresponds to the r. saphenus of the adult.

A. hypogastrica. The main stem of this artery represents the part of the dorsal root of the a. umbilicalis which lies beyond the place of origin of the a. iliaca externa.

Branches. The anterior division of the a. hypogastrica is derived from the proximal part of the a. axis, which becomes the

a. glutaea inferior, from the root of the a. pudenda interna, and from the part of the a. umbilicalis beyond the distal end of its dorsal root. The portion of the original a. umbilicalis which contributes to the formation of the a. hypogastrica is the source, in all probability, of all the visceral branches of the artery. The a. obturatoria is not present at the stage of 22 mm. In consequence of the transference of the origins of the aa. iliolumbalis and sacralis lateralis to the a. glutaea superior, the proximal part of that artery becomes the posterior division of the a. hypogastrica.

A. iliaca communis. This artery is derived from the portion of the dorsal root of the a. umbilicalis which lies upon the proximal side of the origin of the a. iliaca externa.

A. iliaca externa. This artery already springs from the convexity of the a. iliaca communis at the stage of 8.5 mm. Its termination is unbranched until a period shortly before the stage of 12 mm., when it divides into the a. epigastrica inferior and the a. femoralis. The a. circumflexa ileum profunda arise from the a. iliaca externa between the stages of 18 and 22 mm.

A. interossea. The course of this part of the axial artery is described on page 73.

The a. interossea is joined before the stage of 18 mm. by the distal end of the r. communicans inferius. The junction occurs at a point immediately beyond the inferior margin of the m. tibialis posterior. This artery has given origin to the r. coronarius at the stage of 18 mm. and to the r. perforans and to the branch of communication with the a. peronea posterior superficialis at the stage of 22 mm.

The part of the a. interossea extending from the termination of the a. poplitea profunda to the distal end of the r. communicans inferius disappears between the stages of 18 and 22 mm. A vestige of the proximal end of this part of the artery sometimes persists in the form of a small branch of the a. tibialis anterior or of the r. fibularis.

The small portion of the a. interossea which extends from the distal end of the r. communicans inferius to that of the membrana interossea persists as the third part of the a. peronea (p. 79).

The branches which arise from this portion of the a. interossea are transferred to the a. peronaea. They are the r. coronarius malleolaris, part of which becomes the adult r. communicans, and the r. perforans. The remainder of the a. interossea has lost its identity at the stage of 22 mm. The r. perforans tarsi disappears at about the same period.

A. ischiadica. The course taken by this part of the axial artery is described on page 73.

The continuity of the a. ischiadica has been broken in the region of the gluteal fold, at the stage of 22 mm. The proximal part of the vessel, which has now become the a. glutea inferior, follows the v. ischiadica and the n. cutaneus femoris to the surface of the limb where it ends by dividing into cutaneous branches. The more distal portion of the artery is involved, with the single perforating artery present at the stage of 22 mm., in the formation of an extensive plexus upon the posterior surface of the m. adductor magnus.

A. peronaea. This artery is clearly recognizable at the stage of 22 mm. (p. 79). It may be divided into four parts:

The first part of the a. peronaea, which extends from the origin of the artery to the proximal margin of the m. flexor hallucis longus, is a persisting portion of the a. peronaea posterior superficialis (p. 74).

The second part, which lies between the m. tibialis posterior and the m. flexor hallucis longus, represents the entire embryonic r. communicans inferius (p. 76).

The third part, which is short and rests upon the interosseus membrane near the distal border of the m. tibialis posterior, is a persisting portion of the a. interossea (p. 73).

The fourth part, which ramifies upon the fibula and calcaneum in the neighborhood of the lateral malleolus, represents a survival of the short portion of the a. peronaea posterior superficialis and of the entire r. calcaneus lateralis of that vessel (p. 74).

Branches. The r. perforans and r. communicans, belong originally to the a. interossea. The rr. calcanei laterales are branches of the r. calcaneus lateralis of the a. peronaea posterior superficialis.

A. peronaea posterior superficialis. The course of this embryonic artery is described on pages 70 and 74. The main stem of the vessel is present at the stage of 14 mm., its terminal branches form their definitive connections at a stage of 15 or 16 mm.

The proximal part of the *a. peronaea posterior superficialis* unites with the *a. tibialis posterior superficialis* to form the *a. poplitea superficialis* and the part of the *a. tibialis posterior* above the root of the *a. peronaea*. A more distal portion persists as the first part of the *a. peronaea*, and a still more distal portion enters slightly into the formation of the fourth part of that vessel.

The terminal branches of the *a. peronaea posterior superficialis* form the adult *a. plantaris lateralis*. The *r. calcaneus medialis* of the latter artery represents the end of the stem of the parent vessel. The *r. calcaneus lateralis*, which arises from the *a. peronaea posterior superficialis* shortly before the stage of 18 mm., persists to form the major portion of the fourth part of the *a. peronaea* (p. 79).

A. plantaris lateralis. The proximal part of this artery represents the medial terminal branch of the *a. peronaea posterior superficialis* (p. 71), which unites with the *a. tibialis posterior superficialis*. The distal part represents the lateral terminal part of the same vessel.

Branches. The *r. calcaneus medialis* represents the terminal portion of the main trunk of the embryonic *a. peronaea posterior superficialis*. The *arcus plantaris* and all its branches are derived from the embryonic *rete plantare*.

A. plantaris medialis. This artery is the distal portion of the embryonic *a. tibialis posterior superficialis*. It is marked off from the remainder of that vessel by the medial terminal branch of the embryonic *a. peronaea posterior superficialis*.

A. poplitea. The part of this artery above the origin of the *a. genu inferior medialis* represents a surviving portion of the embryonic *a. poplitea profunda* (p. 73). The part lying upon the posterior surface of that muscle represents the embryonic *a. poplitea superficialis*. The proximal portion of the *a. genu inferior medialis* is derived from the *a. poplitea profunda*.

Branches. The a. genu media is present at the stage of 18 mm. The other branches appear at a later stage of the development.

A. poplitea profunda. The course of this vessel is described on page 73. The part of the a. poplitea profunda which extends from the hiatus tendineus to the origin of the a. genu inferior medialis becomes the proximal part of the adult a. poplitea. The remainder of the artery is represented in part by the root of the a. genu inferior medialis. It is represented also by the a. recurrens tibialis posterior and by the second part of the a. tibialis anterior (p. 84).

A. poplitea superficialis. The formation of this artery results from the gradual union which takes place between the proximal part of the embryonic a. tibialis posterior superficialis and that of the a. peronaea posterior superficialis. The vessel lies upon the posterior surface of the m. popliteus and has nearly reached completion at the stage of 22 mm. The a. poplitea superficialis persists as the distal portion of the adult a. poplitea (p. 84).

A. tibialis anterior. This vessel may be divided into four parts which correspond to the four embryonic components of the adult artery.

The first part extends from the origin of the vessel to the root of the a. recurrens tibialis posterior. It corresponds to the whole of the r. communicans medius (p. 84).

The second part occupies the immediate neighborhood of the origin of the a. recurrens tibialis posterior. It represents, like that artery, a persisting portion of the embryonic a. poplitea profunda (p. 84).

The third part extends from the a. recurrens tibialis posterior to a point immediately beyond the root of the a. recurrens tibialis anterior. It is derived from the proximal portion of embryonic r. perforans cruris (p. 68).

The fourth part of the artery extends from the termination of the third part to the proximal end of the a. dorsalis pedis. It represents the entire a. tibialis anterior, pars distalis, of the embryo (p. 72).

Branches. The a. recurrens tibialis anterior represents the terminal portion of the a. perforans cruris (p. 68).

The a. malleolaris anterior medialis is derived from the r. coronarius of the a. interossea which arises shortly before the stage of 18 mm.

A. tibialis anterior, pars distalis. This embryonic artery arises at about the stage of 15 or 16 mm. Its course is identical with that of the fourth part of the a. tibialis anterior of the adult.

A. tibialis posterior. The part of this artery proximal to the origin of the a. peronaea is the product of the union between the a. tibialis posterior superficialis and the a. peronaea posterior superficialis. The remainder of the vessel is a survival of the part of the stem of the a. tibialis posterior superficialis proximal to the point at which it is joined by the medial terminal branch of the a. peronaea posterior superficialis.

Branches. The a. peronaea is described on page 90. The a. malleolaris posterior medialis and the r. communicans are derived from the embryonic r. coronarius malleolaris medialis of the a. interossea (p. 73).

A. tibialis posterior superficialis. The course of this artery, which arises shortly before the stage of 14 mm., is described on page 70.

The whole of the a. tibialis posterior superficialis persists in the adult life. In combination with the a. peronaea posterior superficialis, the more proximal part of the artery forms the part of the a. poplitea in contact with the m. popliteus and the part of the a. tibialis posterior proximal to the origin of the a. peronaea. The more distal part of the artery persists as the portion of the a. tibialis posterior beyond the origin of the a. peronaea and as the a. plantaria medialis.

The relation of the part of the a. tibialis posterior superficialis which forms the a. tibialis posterior of the adult to the n. tibialis is discussed on page 84.

Rete dorsale. The dorsal rete of the embryonic arises from the r. perforans tarsi. It forms all the arteries which are distributed upon the dorsum of the adult foot.

Rete plantare. This embryonic plexus arises from the terminal branches of the a. interossea. It furnishes the arcus plantaris and all the other arteries of the adult sole excepting the aa. plantares.

BIBLIOGRAPHY

- CAILLARD 1832 Proportions de Méd. et de la Chir. Thèse inaug., Paris.
- CRUVEILHIER, J. 1843 Traité d'Anatomie descriptive. Paris.
- DEVRIESE, BERTHA 1902 Recherches sur l'évolution des vaisseaux sanguins chez l'homme. Archiv. de Biologie, T. 18, p. 665.
- DUBRUEIL, J. M. 1847 Des anomalies artérielles, Paris.
- ELLIS, G. V. 1853 An account of an instance of remarkable deformity of the lower limbs. Medico-Chir. Trans., vol. 36, p. 439.
- FAGGE, C. H. 1864 Case of aneurism seated on an abnormal main artery of the lower limb. Guy's Hosp. Rep., vol. 10, p. 15.
- FRORIEP, L. FR. V. 1832. Notizen aus dem Gebiete der Natur u. Heilkunde, B. 34, S. 45.
- GREEN, P. H. 1832 On a new variety of the femoral artery, with observations. Lancet for 1831, vol. 1, p. 731.
- GROSSER, O. 1901 Zur Anat. u. Entwicklungsges. des Gefäss-systems der Chiropteren. Anat. Hefte, B. 17, H. 2, S. 203.
- HOCHSTETTER, F. 1890 Über die ursprüngliche hauptschlagader der hinteren Gliedmasse des Menschen, u.s.w. Morph. Jahrb., B. 16, S. 300.
- HYRTL, J. 1864 Über normal u. abnorme Verhältnisse der Schlagadern des Unterschenkels. Wien.
- LEBOUCQ 1893 Verhandl. d. Anatom. Gesellsch., auf d. siebenten Versamml. Anat. Anz., Ergänzungsh. zum B. 8.
- LEVY, G. 1902 Morphologia delle arteriae iliache, Parte 2. Archiv. Ital. di Anat. e di Embriol., V. 295.
- McMURRICH, J. P. 1904 The development of the human body, 2nd ed., Philadelphia.
- POPOWSKI, J. 1893 Überbleibsel der Arteria saphena beim Menschen. Anat. Anz., B. 8, S. 580.
1894 Das Arteriensystem der unteren Extremitäten bei den Primaten. Anat. Anz., B. 10, S. 55 u. 99.
- QUAIN, R. 1844 The anatomy of the arteries of the human body. London.
- RUG, C. 1863 Anomalie der Arteria cruralis. Würzb. mediz. Zeits., B. 4, S. 344.
- RUGE, G. 1894 Varietäten im Gebiete der Arteria femoralis des Menschen. Morph. Jahrb., B. 22, S. 161.
- SALVI 1898 Arteria dorsalis pedis. Pisa.
- SENIOR, H. D. 1917 The development of the external iliac artery in man. Ann. N. Y. Acad. Sci., vol. 27.
- STIEDA, H. 1893 Verhandl. d. Anatom. Gesellsch., auf d. siebenten Versamml. Anat., Anz., Ergänzungsh. zum B. 8.

- SUESSDORF, M. 1895 Lehrbuch der vergleichenden Anatomie der Haustiere. Stuttgart.
- TANDLER, J. 1903 Zur Entwicklungsges. der menschlichen Darmarterien. Anat. Hefte, B. 23, H. 1, S. 187.
- VELPEAU 1839 Éléments de Médecine Opératoire.
- ZAGORSKI 1809 Mém. de l'Académ. des Sci. de Petersb.
- ZUCKERKANDL 1894 Zur Anat. u. Entwicklungsges. der Arterien des Vorderarms (1. theil). Anat. Hefte, B. 4, H. 1, S. 1.
1895 Zur Anat. u. Entwicklungsges. der Arterien des Unterschenkels u. des Fusses. Anat. Hefte, B. 5, H. 2, S. 207.

THE DEVELOPMENTAL RELATIONS OF BRACHY- DACTYLY IN THE DOMESTIC FOWL

C. H. DANFORTH

Department of Anatomy, Washington University School of Medicine

FIVE FIGURES

The factors which exercise determining influences in the ontogeny of animals have proved difficult of recognition and evaluation. To what extent any given structure is the direct expression of some more or less specific 'determiner' in the germ cell and to what extent it represents the product of reactions to the influence of other parts of the developing organism cannot often be estimated in any reliable manner. Nevertheless, some knowledge of the relative weight of the two kinds of factors involved is essential to a satisfactory conception of the processes of embryology and morphology. The observations recorded in the present paper are reported because they seem to throw some light on this problem with reference to a rather special case; namely, the correlation between skeletal peculiarities of the fourth toe and the presence of feathers on the tarsi in the common fowl.

The data to be presented were collected as the result of the following observations: In July, 1915, an egg incubated in the laboratory hatched out a chick (no. 12) which showed an almost complete absence of the fourth toe on each foot. This particular chick was helped from the shell and the condition of its toes noted at that time, so there is no possibility of the malformation having been due to injury received after hatching. Subsequent dissection showed that the three terminal phalanges and the nail were lacking on both sides (fig. 1, B). During growth the lateral rudimentary toes turned under the balls of the feet causing the bird some inconvenience, especially in perching.

The specimen, a male, had moderately booted tarsi and was also strongly polydactyl. It met an accidental death at about nine months of age before any offspring had been obtained.

The parents of this chick were full brother and sister (no. 8, ♂, and no. 7, ♀). Both were polydactyl and both had booted tarsi. On closer inspection it was found that their fourth toes were somewhat shorter than normal. It was at first thought possible that the brachydaetyly and polydactyly might be cor-



Fig. 1. Bones of the left foot from (A) normal and (B) brachydaetyl cockerel.

related, that the excessive toe development on the medial side of the foot might be more or less at the expense of the tissues on the lateral side. The following data show that such was not the case.

From the mating of nos. 7 and 8 only a few chicks were obtained. These included specimens with four and five digits, bare and feathered tarsi, brachydaetyl and normal fourth toes. Some additional specimens secured by crossing no. 8 with a barred Plymouth Rock hen gave essentially the same distri-

bution of characteristics. The association of characters in these chicks was such as to suggest that the brachydactyly might be correlated with booting but the numbers were not adequate to warrant definite conclusions.

Through the courtesy of the officials in charge, it was possible to make a superficial examination of the feet in a considerable series of booted fowls exhibited at poultry shows in St. Louis. Such examinations sufficed to show that brachydactyly occurs in several races with booted tarsi. One highly valued buff Cochin fowl was found to present the characteristic in as pronounced a form as did the specimen which first attracted our attention to the peculiarity. Owners and judges are inclined to attribute such cases to accident, but the fact that the standard of requirements for some of these breeds specifically calls for well formed toes suggests that the tendency to brachydactyly has been vaguely recognized by breeders. No instance was found in which a short lateral toe occurred on a smooth-shanked bird.

These observations were sufficient to indicate that brachydactyly is of rather common occurrence in the domestic fowl and seemed to justify a more careful investigation of the peculiarity. Consequently a further breeding experiment was undertaken in order to furnish material for study of the heredity and embryology of the condition.

MATERIAL AND METHODS

To obtain this material male no. 8 was mated to a flock of 13 white Leghorn hens. All eggs laid between February 15 and April 18, 1917, were incubated, except when, as occasionally happened, the number of eggs remained for several days in excess of the capacity of the incubator. At such times the oldest eggs were discarded. It is not probable that this method could have resulted in any differential selection. A total of 300 eggs were used. Of these, 108 yielded living embryos and 86 were allowed to hatch. Two of the remaining eggs were infected with bacteria, 34 were non-fertile or developed only slightly, and 70 contained embryos that died before hatching.

The living embryos were fixed in Zenker's fluid or in 10 per cent formalin. They were subsequently examined under a binocular microscope and parts of many of them were either sectioned or stained by the van Wijhe method and studied in toto.

The contents of eggs found to contain dead chicks were put in formalin and after a short period of hardening the embryos were examined, their age estimated and characteristics recorded.

All the toes on both feet of each of the 86 living chicks were measured, the grade of polydactyly, the grade of booting and also the form of the comb were noted. These data likewise were recorded so far as possible for the older embryos. For each of the living chicks an index of brachydactyly was obtained by dividing the sum of the lengths of the two lateral toes (digits IV) by the sum of the lengths of the two medial toes (digits II). This gives a value varying above and below 1. The value obtained is multiplied by 100 in each case to eliminate fractions. The index is thought to be fairly reliable, since careful measurements have shown that the fourth toe is the one chiefly affected while the third is only slightly so and the second possibly not at all. The toe measurements represent the distance, obtained by the use of dividers, from the base of the nail to the metatarsophalangeal articulation.

DESCRIPTION OF STOCK USED FOR BREEDING

The females employed in the breeding experiment were all pure bred white Leghorns of a well established strain. Their shanks were free from feathers and there was no indication of polydactyly or brachydactyly. The fourth toe index ranged from 106 to 121 with an average of 112. All were pure white with large single combs. Eight of these and a male were obtained in 1916 from a poultryman who devotes himself exclusively to this breed. The other five were raised at the laboratory from this original flock. There can be little doubt as to the purity of the stock especially in regard to the characteristics under investigation. At the time of the experiment five of the hens were less than ten months old, the rest were two years or more.

The male (no. 8) differed from these hens in a considerable number of characteristics, for most of which he seems to have been heterozygous. His color was partly that of a barred Plymouth Rock, although hackle, saddle feathers, and tail contained much white and the breast was somewhat spotted. The comb was broad and long with irregular elevations and a flattened, truncated and slightly trifid posterior prolongation. It did not seem to be either typically 'rose' or 'walnut' although perhaps more closely approaching the latter. The tarsi were moderately booted (grade 2 in an arbitrary scheme adopted for purposes of this paper). Digit I on the left foot was partially doubled (grade 2) while on the right foot it was normal. Digits IV were short, giving an index of 89. At the time of the experiment this bird was in the last half of his third year of life.

HEREDITY OF CHARACTERISTICS

The heredity of the five outstanding characteristics, color, comb form, polydactyly, booting and brachydactyly may be briefly summarized. The first four of these have been subjected to careful study by Davenport ('06, '09) and others.

A. Color. All chicks that hatched and all embryos that reached the stage for developing down were white, or white with occasional small dark spots. White was to have been expected in the offspring since the white of the Leghorn is a well known dominant character.

B. Comb. According to the prevailing view as to the unit factors involved (Bateson, '09) four types of comb should have occurred in equal numbers: walnut, rose, pea and single. These four types did occur, but since in the embryo and chick it is often difficult to differentiate with certainty between rose and walnut (of the type met in this experiment), pea and single, the four categories were grouped into two; broad combs and narrow combs. Of 172 chicks and late embryos, 88 had broad combs and 84 narrow, the expectation being 86 of each. This is very close to the Mendelian ratio.

C. Polydactyly. For the sake of convenience three grades of polydactyly, corresponding essentially to those designated by Anthony ('99), were employed. Grade 1 includes cases in which only the distal phalanx is involved; grade 2 includes cases where two phalanges are involved but with the toes usually more or less united and equal; grade 3 includes all cases of a more pronounced form. In grade 3 the metatarsal is also affected and the accessory toe generally has three phalanges. Only one instance of six toes occurred. Occasional specimens in which there were really only four toes but in which the first digit showed three phalanges instead of two were classed as polydactyl, grade 1. Such individuals were included because the evidence seems to the writer to indicate that polydactyly in the fowl is not so much a matter of added elements as of readjustments following early hypertrophy of a single anlage. In possibly a third of the cases the two sides were not strictly symmetrical. Of the 28 polydactyly chicks that hatched, 8 were of grade 1 and 10 each of grades 2 and 3. The father was of grade 2 (on the left side only).

As shown by Kufmann-Wolf ('08), some cases of polydactyly can be recognized as early as the fifth day of incubation. Probably all individuals which would develop into grade-3 specimens can be recognized as polydactyl at this age. But for purposes of the present record no individual under seven days is included. Of 220 chicks and embryos of 7 days and over, 147 were normal, 73, or 33 per cent, were polydactyl. If polydactyly behaved as a strictly dominant character the expectation in this case would be 50 per cent. The failure of polydactyly in poultry to give typical Mendelian ratios has been discussed by several authors, especially Davenport ('09).

D. Booting. In chicks that are to be booted, feather (down) rudiments generally become apparent on the tarsi during the eleventh day of incubation (fig. 2) or considerably later than on other parts of the body. After the twelfth day, booting is easily recognized. Thirty-six living chicks which were booted were classified into three grades, based upon the amount of down on the tarsi. Grade 1 represents individuals with from one

to several feathers on the shank. Grade 3 stands for specimens with about twelve feathers on the shank, three or four on the lateral toe, and occasionally one or two on the middle toe. Grade 2 includes specimens intermediate between 1 and 3. The distribution among the three grades was as follows: grade 1, 14; grade 2, 10; grade 3, 12. The father was grade 2.

Out of a total of 129 chicks and embryos of thirteen days and over, 80 were normal and 49 booted,—38 per cent. Booting,

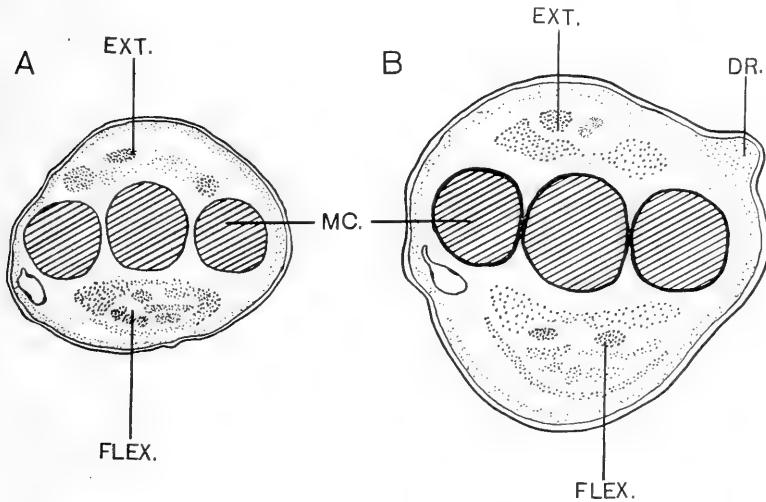


Fig. 2 Sketches of cross-sections of comparable regions of the right shank from (A) nine-day and (B) eleven-day embryos, both of which were strongly brachydactyl. *Dr.*, down rudiment; *Ext.*, extensor group of tendons; *Flex.*, flexor group of tendons; *Mc.*, metatarsal cartilages.

like polydactyly, does not give strictly Mendelian proportions (Hurst, '05, Davenport, '09).

E. Brachydactyly. In chicks with normal feet the lateral toe is about 10 per cent longer than the medial; in brachydactyly chicks it is of equal length or shorter. While the differences are only slight and in embryos difficult to measure a certain number of obvious cases can be recognized in nine-day specimens. From the tenth day on they are clearly distinguishable, probably in nearly all cases. It is possible, however, that a small number

of brachydactyl specimens, having a relatively high index, may be overlooked even among late embryos. Among 90 embryos of ten days and over, 57 had long fourth toes; 33, short. Of 86 young chicks, 55 had an index of more than 100 while 31 showed an index of 100 or less (brachydactyl). The totals for embryos and chicks are: out of 186 individuals, 112 normal, 64 brachydactyl. This is 36.4 per cent, which is intermediate between the percentages for booting and polydactyly. These characteristics behave in heredity quite differently from color and comb form which give results corresponding closely to the Mendelian expectation.

EMBRYOLOGY OF BRACHYDACTYLY

Since brachydactyly in poultry has not seemed to attract much attention (Anthony, '99, states that he has seen specimens which showed four and six phalanges in their fourth toes), a fuller account of the condition may be entered upon at this point. Inasmuch as the shortening of the other toes is relatively slight and difficult to measure the fourth only will be considered. The skeleton of a normal foot is shown in figure 1, B. Digit IV has five phalanges, the terminal one bearing a nail. Among brachydactyl specimens, the fourth toe varies from a condition in which nail and all five phalanges are present with a total length equalling that of the second toe (but not exceeding it as in normal feet) to a condition showing complete absence of the nail bearing phalanx and only two remaining phalanges. Intermediate conditions are represented by toes with three or four well formed phalanges and by toes with the full number of joints but of considerably reduced length. The brachydactyl toes also varied from the normal in other characteristics such for example as the number of rows of scales. The two sides of the same individual were found to be very closely correlated. Among the 31 brachydactyl chicks that hatched, the index varies from 70 to 100, with an average of 89, which is identical with the index of the father. All of the specimens had the nail reduced and seven of them had only four bones in the toe as shown either by dissection or surface configuration (fig. 3).

Tracing the condition back in the development of the chick, we find, as already stated, that brachydactyl can be recognized, at least in many cases, as early as the ninth day, when the fourth toe in certain individuals can be seen to be conspicuously shortened. It has not been possible to determine whether or not the shortening is actually present at an earlier date. The cartilage of the third phalanx of the fourth toe is laid down during the 8th day. The fourth and sometimes the fifth cartilage are formed on the 9th day. By the end of the 10th day all of the phalanges to develop are present in cartilages. Definite reduction in the number of cartilages cannot be recognized with certainty earlier than the tenth day.

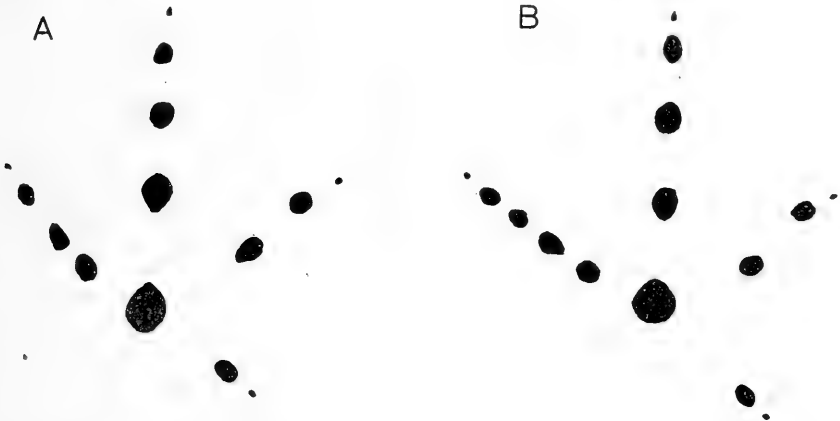


Fig. 3 Foot-prints of (A) brachydactyl and (B) normal left feet. In A the absence of one phalanx in the fourth toe is revealed.

The fact that brachydactyly is apparent at the time when cartilages are formed, if not actually before then, would seem to indicate that the reduction of the skeleton takes place in response to conditions already manifest in the toe, and not as a result of any factor acting specifically on cartilage or bone formation. In other words the cartilage anlagen form while subjected to a kind of compression resulting from the shortening of the toe. The consequent reduction in the cartilages, and the correlated changes in ligaments, tendons, etc., would therefore seem to be

due not to any inherent peculiarity of the structures themselves, but rather to the conditions under which they develop. The shortening of the soft parts, seemingly secondary is more probably the primary factor in causing brachydactyly. In the adult foot, however, the bony framework provides an accurate index of toe length.

As already indicated, the reduction in the skeletal elements is both qualitative and quantitative. It may be that this reduction does not take place in the same way in all short-toed specimens, but a series of grades may be described which seem to represent successive steps in the process.

The first degree of shortening represented by the least pronounced type is characteristic of the majority of brachydactyl specimens. Here all of the phalanges are present, but the fourth, or sometimes the third, is more or less shortened. The amount of shortening in these phalanges varies greatly and can often be estimated in the living chick. It has not been possible to determine accurately whether or not the other phalanges are also shortened, although it is probable that they are, especially the fifth since the nail is almost always abnormally small. The fact that the fourth, or occasionally the third, phalanx is the one first affected suggest that the reducing factor is most effective at the time these phalanges are being laid down, viz: on the ninth, or occasionally the eighth day.

The second degree, found in slightly over a fifth of the cases studied, shows the first numerical reduction in the phalanges. Here the third and fourth segments are replaced by a single element. The resulting cartilage is commonly a slender rod slightly longer than a normal fourth which it otherwise resembles. This cartilage also varies in length so that there is some fluctuation within this grade. It has not been possible to determine with certainty whether the coalescence of the two elements is due to one cartilage forming from the substance that normally gives rise to two, or whether both elements form separately and then fuse. The specimen shown in figure 4 seems to favor the latter alternative, but where the adult organ presents an unlimited series of gradations it is impossible to say in the

case of any individual embryo whether the observed condition is transient or definitive.

The third degree is represented by one twenty day embryo and possibly one or two younger embryos. In this case there seems to be a general reduction in which the terminal phalanx suffers most. The third and fourth phalanges are fused. The claw is represented only by a small flat scale and the fifth bone

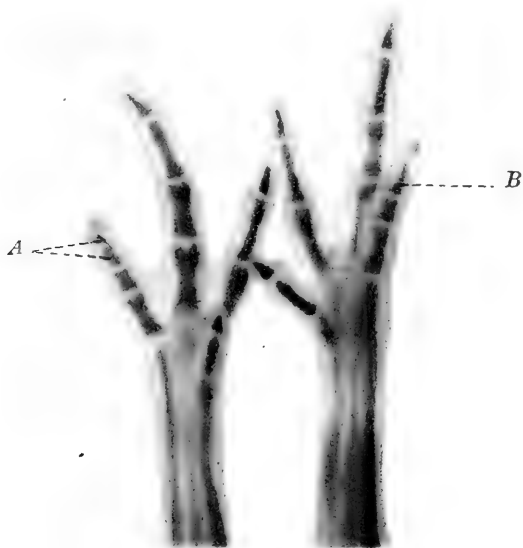

Fig. 4 Feet of a brachydaetyl embryo on the tenth day of incubation. In the fourth toe of the right foot, at B, is shown the completely fused third and fourth phalanges. In the left foot, at A, these two phalanges are seen to be only partially fused.

by a little nodule into which the terminal slip of the flexor profundus tendon is inserted. Since the flexor profundus is also inserted into the plantar surface of the normal fourth phalanx or the fused third and fourth phalanges, a stage showing a complete absence of the fifth segment would differ very slightly from the case here described. It is interesting to note in this connection, however, that the basal and terminal phalanges are

the most stable, the intermediate elements being the ones first affected.

The fourth degree was found in no. 12 (half brother of these chicks), referred to at the beginning of the paper, and in several chicks obtained later. Here there are only two bones present in the fourth toe (fig. 1, B). There is no nail. The tendon of the flexor profundus is inserted on the plantar surface of the terminal bone and the superficial flexor into the lateral aspects of both segments. In view of this arrangement, the conformation of the two bones, and the condition observed in other specimens it would seem probable that the proximal element represent the normal basal phalanx while the distal one represents a fusion (in effect, if not in reality) of phalanges II, III and IV; phalanx V being entirely absent.

Owing to the brief period between the first indication of clearly demonstrable brachydactyly and the appearance of phalangeal cartilages, the possibility that the precartilagel cells are the ones first affected by the shortening factor can not be entirely excluded. If such be the case, it is the skeletal elements that from the earliest period determine the form and proportions of the toe; but as already indicated, the evidence seems to point quite as strongly to the alternative possibility, namely, that the form of the skeletal elements as first laid down is the result of a more or less passive response of cartilage forming cells to the influence of surrounding conditions. The relation of brachydactyly to booting (to be discussed in a later paragraph) adds considerable support to the latter interpretation. If this interpretation is correct, it follows that the early shortening of the toe as a whole results in a reduction of the skeletal elements, the degree of reduction being directly correlated with the degree of shortening, and not improbably passing successively through the above described stage till the definitive condition is reached on the tenth day or shortly thereafter.

INTERRELATION OF CHARACTERISTICS

The relations of brachydactyly and the other hereditary characteristics observed in this experiment are indicated in the

TABLE 1

A summary of the data arranged to show the relation between brachydactyly polydactyly, booting and comb form in the eighty-six living chicks

	A. BRACHYDACTYLY AND COMB FORM				D. BRACHYDACTYLY AND POLYDACTYLY			
	Broad comb		Narrow comb		Five toes		Four toes	
	Obs.	Exp.	Obs.	Exp.	Obs.	Exp.	Obs.	Exp.
Short fourth toe.....	15	15.5	16	15.5	10	10	21	21
Long fourth toe.....	28	27.5	27	27.5	18	17.9	37	37.1
	B. POLYDACTYLY AND COMB FORM				E. POLYDACTYLY AND BOOTING			
	Broad comb		Narrow comb		Booted shank		Smooth shank	
	Obs.	Exp.	Obs.	Exp.	Obs.	Exp.	Obs.	Exp.
Five toes.....	16	14	12	14	13	11.8	15	16.2
Four toes.....	27	29	31	29	23	24.2	35	33.8
	C. BOOTING AND COMB FORM				F. BOOTING AND BRACHY-DACTYLISM			
	Broad comb		Narrow comb		Short fourth toe		Long fourth toe	
	Obs.	Exp.	Obs.	Exp.	Obs.	Exp.	Obs.	Exp.
Booted shank.....	17	18	19	18	31	12.9	5	23.1
Smooth shank.....	26	25	24	25	0	18	50	32

accompanying table (table 1, A-F), which is based on the 86 chicks hatched. Since the male used was, in Mendelian terms, heterozygous for all four of the peculiarities studied, the determiners for each (with the partial exception of comb form) having been supplied by his paternal gamete alone, and since the females were homozygous for the absence of all these characters, an especially favorable opportunity was afforded for testing linkage relations. If each character behaved in a strictly Mendelian fashion and segregated independently, the expected value for each combination would be 21.5, and the sum of each pair added either vertically or horizontally would be 43. While, as already indicated comb form agrees exactly with the Mendelian expectation (43 : 43 for those that hatched)

the other three characters do not, so that linking can only be tested by comparing the proportional distribution of one pair of contrasted characters with reference to other pairs. The table shows the observed values for all possible combinations and the expected values for each of these based on the behavior of the several characters considered separately.

It will at once be apparent that the observed and expected values agree very closely in the first five sets of combinations. The slight apparent deviations in favor of a correlation between polydactyly and broad comb and between polydactyly and booting are too small to be of significance. So far as this part of the data goes it is in full accord with Davenport's ('06) conclusion that correlation of characteristics in poultry is very rare.

But, on the other hand, between brachydactyly and booting there is found to be a close correlation. Here the values are clearly significant. Of thirty-one brachydaetyl chicks, all had booted tarsi; and of thirty-six chicks with booted tarsi, thirty-one were brachydaetyl. The distribution is shown graphically in figure 5 where it also appears that the length of the fourth toe is rather more variable in specimens with booted shanks than in those with smooth shanks.

There is, then, a distinct relation, which becomes apparent in embryonic stages, between brachydactyly and booting, but there is no evidence of a significant connection between either of these characters and comb form, color or polydactyly.

SIGNIFICANCE OF THE CORRELATION BETWEEN BRACHY- DACTYLY AND BOOTING

The explanation for the relation between short toes and feathered tarsi is not obvious. Several possibilities suggest themselves.

In the first place, it might be that we have here a case of true linkage, such, for example, as Morgan ('15) and others have successfully demonstrated in fruit flies. Morgan believes that in such cases the determiners for both of the linked characters are located in the same chromosome. If this were the true explanation, 'crossing over' might possibly be expected to occur

in a certain percentage of cases, the frequency depending on the distances of the two determiners from each other. There is some evidence that could be regarded as favoring this interpretation. Five chicks with more or less booted tarsi (grades 1, 1, 1, 1, 2) were not brachydaetyl. If these represented true cases of 'crossing over' there should have been an equal number of brachydaetyl chicks which were not booted. One specimen was obtained. To fully substantiate this hypothesis it would

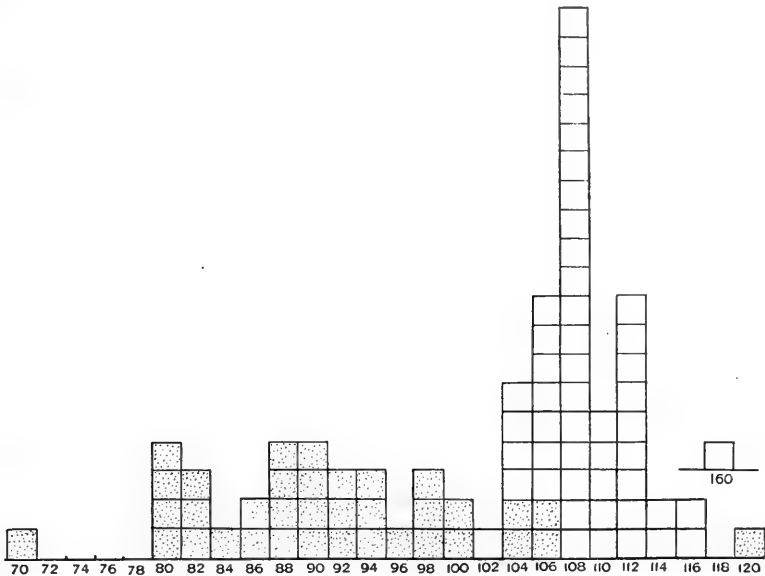


Fig. 5 Curve showing the relation between brachydaetyly and booting in 86 living chicks. Each square represents an individual, the shaded ones being booted. The indices of brachydaetyly are indicated below.

be necessary by further breeding experiments to derive from the same hybrid stock one strain with feathered feet and long toes and another strain with unfeathered feet and short toes.

In this connection it was thought desirable to investigate the relation of these characters in other species. The writer is greatly indebted to Mr. Louis Agassiz Fuertes for carefully examining for him a large number of booted grouse, ptarmigans,

and owls. Mr. Fuertes was unable to find any indication whatever of brachydactyly in any of these birds.

In the case of the domestic pigeons on the other hand, the writer has found somewhat the same condition that occurs in hens. 'Swallow' and 'pouters' both of which are booted, often show short lateral toes. Among 'muffed tumblers' also heavily booted, several specimens were found to have the third and fourth toes fully webbed, and I have been informed that the same condition sometimes obtains in 'pouters.' Davenport ('09, pp. 29 to 36) describes a similar condition in a strain of fowl. It is not clear whether all of his syndactylous specimens were also booted but the fact that the first cases arose in breeds that are normally booted, is probably significant. In another flock of fowl, related to those here described and having so far as known no syndactyly in the ancestry, a pair of brachydactyl birds produced two syndactylous chicks of the type described by Davenport. These cases suggest that syndactyly like brachydactyly may represent an arrest of development, occurring in the former case a little earlier than in the latter, and that the two conditions may be dependent upon a single factor.

While the suggestion of linked determiners cannot be entirely ignored as a possible explanation of the results obtained, there is still further evidence against such an interpretation. This rests chiefly on the fact that there is a correlation between the degree of booting and the index of brachydactyly. Despite wide fluctuations, this fact is brought out by averaging the indices for the different grades. After excluding the two extreme cases with indices of 70 and 120 the average index for each group is as follows, grade 1, 93; grade 2, 91; grade 3, 89. If the two extremes are included, they tend to raise the value of grade 1 and lower the value of grade 3, thus accentuating the differences. Such a result is not easily explained on the assumption of two independent determiners but, on the contrary, strongly suggest that the association is due to something more than a chance proximity of the determiners in a chromosome.

If this is the case the question presents itself as to whether the relation is causal, one condition producing the other or whether the two conditions are both dependent on some one determining factor. It was at first thought probable that the abnormal development of feathers or down on the feet overtaxes the nutritional supply of the limb with the result that the fourth toe becomes somewhat stunted in its development. The embryology of the condition, however, does not support this view. On the contrary, in light of the sequence in which the characteristics make their appearance in ontogeny, brachydactyly would seem to be the cause of feathered tarsi, an interpretation which, *a priori*, does not seem plausible.

Since, on the whole, the evidence does not favor the idea that either condition is really the cause of the other the only alternative that would seem to be left is that they are both caused by the same factor. The close association of the two characteristics and the fact that they tend to fluctuate together, points strongly toward this conclusion. What the factor may be or precisely how it acts cannot at present be answered. Nor can the number of characteristics which it affects be stated since it is quite possible that some of them have been overlooked in the present study.

If the connection between brachydactyly and booting had been a little less obvious the former might have been described as an independent unit character and a separate determiner in the germ plasm postulated for it, as has already been done for booting by the several authors who have studied that character. In general the relations here described would seem to be such as tend to support the contention of Morgan (*loc. cit.*) that the determiners in the germ plasm are not strictly specific, but tend to influence the character of the organism as a whole.

In the particular case under consideration it is quite possible that the determining factor may actually be effective for only a short time, possibly a few days. After two cartilages have once fused it is doubtful if the removal of the exciting cause would in itself induce them to separate. It is also possible that a feather germ once formed would need no further stimulus than

proper nutritional conditions to continue its development to the end. If these suppositions are correct it is quite conceivable that the whole complex is due to a slight irregularity (delay or acceleration) in the beginning functioning of some one or other of the endocrine glands. The character of the gland would of course be determined by other factors which would have an ultimate basis in the nature of the germ plasm itself. An explanation of this sort, both for these characters and for polydactyly would much more readily account for the aberrant nature of the ratios obtained in breeding experiments.

SUMMARY

The observation reported in this paper establish the fact that, at least in certain strains of poultry (and probably in pigeons) there is a close correlation between brachydactyly involving the size and number of bones in the feet, and the presence of feathers on the tarsi. The embryology of both conditions has been studied, the evidence from this source indicating that while the size and number of skeletal elements are determined by the length of the embryonic toe, there is no causal relation between toe length and feathering. The data cited seem to indicate, on the contrary, that brachydactyly, feathering of the tarsi, and probably syndactyly are all dependent on one and the same factor. No attempt is made to postulate the nature of this factor but it is suggested that a study of the early functioning of the endocrine glands in normal and abnormal embryos might throw some light on the question.

No correlation could be detected between either of these characters and polydactyly or comb form.

LITERATURE CITED

- ANTHONY, R. 1899 Étude sur la Polydactylie chez les Gallinacés. Jour. de l'Ant. et de la Physiol., T. 35, pp. 711-750.
- BATESON, W. 1909 Mendel's principles of heredity. Cambridge University Press.
- BATESON, W., AND PUNNETT, R. C. 1905 Poultry. *In* Report to the Evolution Committee of the Royal Society. Report II, pp. 99-131.
- BEDDARD, FRANK E. 1898 The structure and classification of birds. Longmans, Green & Co., London, New York, and Bombay.
- DAVENPORT, C. B. 1906. Inheritance in poultry. Publications of the Carnegie Institution of Washington, no. 52.
1909 Inheritance of characteristics in domestic fowl. Carnegie Institution of Washington, Publication no. 121.
- HURST, C. C. 1905 Experiments with poultry. *In* Report to the Evolution Committee of the Royal Society. Report II, pp. 131-154.
- KAUFMANN-WOLF, MARIE 1908 Embryologische und anatomische Beiträge zur Hyperdactylie (Houdanhuhn). Morph. Jahrb., Bd. 38, S. 471-531.
- LILLIE, FRANK R. 1908 The development of the chick. Henry Holt & Co., New York.
- MORGAN, T. H., STURTEVANT, A. H., ET AL 1915 The mechanism of Mendelian heredity. Henry Holt & Co., New York.

Resumido por la autora, Della Drips.

Estudios sobre el ovario del espermófilo, con especial mención del cuerpo amarillo.

En el presente trabajo se considera el ciclo de cambios que ocurren anualmente en los ovarios del espermófilo, dando detalladas descripciones histológicas del cuerpo amarillo en cada uno de los estados de su desarrollo. Se han empleado coloraciones específicas para poner de manifiesto los caracteres nucleares y protoplásmicos de las células amarillas. En el ciclo vital del cuerpo amarillo se reconocen tres fases: Primera, una fase que se caracteriza por la presencia de un gran número de gránulos rojos, indudablemente gránulos de secreción, en el protoplasma de las células amarillas. Esta fase comprende, prácticamente, todo el periodo de la preñez. Segunda, la fase lipóide, así, llamada por la abundancia de gotitas de substancia lipóide en el protoplasma de dichas células. Esta fase comienza algún tiempo antes del parto y dura próximamente unas seis semanas después de este, que es también próximamente el tiempo que requiere para completarse la involución normal del útero. Tercera, la fase de regresión. Se dan a conocer también ciertos estudios experimentales, tales como los efectos de la ovariectomía sencilla y doble, practicada sobre animales preñados y no preñados. La ovariectomía sencilla produce resultados negativos. La ovariectomía doble en animales no preñados causa una atrofia funcional del útero, que se manifiesta muy gradualmente. En las hembras preñadas esta operación da lugar a abortos, excepto cuando se practica cuando la preñez está muy avanzada. Como resultado de los estudios histológicos y experimentales, la autora llega a la conclusión de que los cuerpos amarillos producen dos secreciones internas que presiden sobre los cambios que tienen lugar en el útero a consecuencia de la preñez. La primera secreción produce la implantación normal y desarrollo del embrión, y la secreción lipóide ulterior ayuda a la involución normal del útero.

STUDIES ON THE OVARY OF THE SPERMOPHILE (SPERMOPHILUS CITELLUS TRIDECIMLINEATUS) WITH SPECIAL REFERENCE TO THE CORPUS LUTEUM¹

DELLA DRIPS

Mayo Foundation, Rochester, Minnesota
Division of Experimental Surgery

TWENTY-NINE FIGURES

CONTENTS

Literature.....	117
The ovarian cycle. A. Material and methods. B. Histologic descriptions of ovaries at consecutive intervals of the annual cycle. 1. The ovary of the early fall. 2. The ovary of the late fall. 3. The ovary of the early spring. 4. The ovary of early pregnancy with corpora lutea of the red granule stage. 5. The ovary of the middle of pregnancy with its characteristic corpora lutea. 6. The ovary at parturition with its characteristic corpora lutea. 7. The ovary of July with corpora lutea of the lipid stage. 8. The ovary of the late summer with corpora lutea in regression.....	126
Experimental studies. A. Effects of the removal of the uterus on the ovaries. 1. In non-pregnant spermophiles. 2. In pregnant spermophiles. B. Effects of the removal of both ovaries on the uterus. 1. In non-pregnant spermophiles. 2. In pregnant spermophiles. C. Effects of the removal of one ovary. 1. In non-pregnant spermophiles. 2. In pregnant spermophiles. D. Effects on the remaining ovary of the removal of one ovary and the uterus in pregnant spermophiles. E. Studies on the normal bursting of follicles and the formation of corpora lutea. F. Studies on ovulation, fertilization and corpora lutea formation.....	142
Summary and Discussion. A. Summary of the results obtained from the histological and experimental studies. B. Conclusions as to the functions of the corpora lutea in the ovaries of spermophiles.....	160

LITERATURE

The first papers written on the corpus luteum of the ovary had to do largely with its formation, particularly with the origin of the luteal cells. Were these cells connective-tissue elements

¹ Thesis for degree of Master of Science, University of Minnesota (Mayo Foundation, 1917).

from the internal theca of the follicle according to the hypothesis of von Baer, or were they epithelial in nature and derived from the membrana granulosa of the follicle as advocated by Bischoff? Marshall, in his book, "The Physiology of Reproduction" ('10), carefully reviews this early literature.

It was not until Sobotta ('96) published the first of his series of papers on the corpus luteum that the discussion over the origin of the luteal cells began to come to an end. Sobotta's study on the corpus luteum of the mouse was the first systematic record of the transformation of the follicle into a corpus luteum and the latter's subsequent development. He describes, first, the follicle about to burst; then, one just after bursting; one, one-half hour afterward, and others at succeeding short intervals up to seventy-two hours after bursting. All the descriptions are very detailed, every change in the structure as it proceeds in its development being noted. Sobotta traces the origin of the luteal cells to the epithelial cells of the granulosa of the follicle. The internal theca cells, he says, expend themselves utterly in the formation of connective tissue and blood-vessels. The external theca remains as it was.

Sobotta believed the function of the corpora lutea was to maintain a constant equal tension in the ovaries, which shows how little thought he gave to this phase of the problem. He was all absorbed in the formation of the luteal structure. This paper of Sobotta's was followed shortly by a very similar one on the rabbit, in which he confirmed all of his findings in the mouse. These papers started a real investigation of the corpus luteum, and for the following ten or fifteen years there were any number of papers written regarding it. A few writers continued the discussion as to the origin of the luteal cells. Some criticised Sobotta, trying to disprove his statements. Among these was Clarke ('98), who contributed an account of the formation of the corpus luteum in the sow. His studies were made on serial sections of pig's corpora lutea and follicles in different but not subsequent stages of development. The sections in each set were treated alternately to a process of tryptic digestion and a micro-fuchsin stain. From a study of these sections he concludes that the

luteal cells are of a connective-tissue origin and that the function of the corpus luteum is to preserve the ovarian circulation.

Sobotta ('99) published his third paper on the corpus luteum of mammals. Honore ('00) was one of the first to confirm Sobotta's findings. He wrote concerning the corpus luteum in the rabbit. Marshall ('01) published a paper on the corpus luteum in the sheep, coming to practically the same conclusions as Sobotta. Cohn ('03) further confirmed Sobotta's work on the rabbit. Jankowski ('04) published a paper in which he came to entirely different conclusions. They are as follows: "He (Sobotta) simply lets the internal theca vanish. If one layer must vanish, it would be the one for whom the conditions after the follicle bursting are very unfavorable and that is the case with the epithelium of the follicle. The corpus luteum is not an epithelial but a connective tissue structure." Sobotta ('06) published a fourth paper on the formation of the corpus luteum in the guinea-pig, again confirming his former work.

Such an amount of histologic investigation over the formation of the corpus luteum could not very well go on without arousing much interest in regard to the physiologic function of the structure. The men who upheld the connective-tissue origin held many curious ideas as to its function, all of which tended toward making its action more or less mechanical. Several thought the only function of the luteal structures was to prevent ovulation. Clarke thought its function was to preserve the ovarian circulation.

On the the other hand, those who accepted Sobotta's conclusions began looking for a much more important function for the corpus luteum. If the luteal cells were epithelial and each was so intimately in contact with the blood stream, and the whole organ had so much the appearance of a gland, why couldn't it be a gland of internal secretion? Several histologists began studying the cells for evidences of a secretory product. Regaud and Policard in 1901 were the first to publish any results. They stained sections of ovaries of the dog, that had been fixed in acetic potassium bichromate, with a copper-hematoxylin method of Weigert. They described some black secretion droplets in

the luteal cells. In Cohn's paper previously mentioned, he describes some granules which he thinks may be the same as those described by Regaud and Policard. He also gives his reasons for believing that the fatty osmic-stained droplets, seen in the luteal cells in greatest abundance when the cells reach their maximum hypertrophy, are real secretion droplets and not evidences of fatty degeneration as had been previously contended.

Along with the attempt to discover by a special histologic technic, evidences of secretory products in the luteal cells, a number of men sought to discover, by animal experimentation, proofs of the glandular action of the corpus luteum. The uterus and the mammary glands, in the minds of all, were the most closely associated of all the organs of the body, with the ovaries. Ovulation had been observed to be closely related to menstruation in the human and to the heat periods in animals. Complete double ovariectomy was known to stop menstruation, cause an atrophy of the uterus, and, in young women, to bring on menopause symptoms. In the very young castration had prevented the development of the uterus and mammary glands. Double ovariectomy in pregnant women, especially in the first months, was known to be followed by abortion.

Various attempts had been made to overcome the bad effects of ovariectomy by the transplantation of ovaries and by ovarian medication. These were reported to have given good results, at least partially.

All these facts seemed to speak for the production of an internal secretion in the ovaries which affected the uterus and mammary glands.

Fraenkel ('06) was the first to attempt to prove by a series of experimental studies on rabbits and cats that the corpora lutea in the ovaries were responsible for the various effects produced on these organs.

He begins his papers as follows: "The corpus luteum must, from its structure and development, be a gland of internal secretion, made to insure the implanting and development of the fertilized egg in the uterus. The corpus luteum maintains

the state of nutrition of the uterus during the years of sexual activity." He thought it ruled over the phenomena of rut as well as pregnancy.

About this same time Marshall and Jolly published a series of experiments very similar to Fraenkel's. They used dogs and rabbits, and their conclusions were much like those of Fraenkel.

Daels ('08) published a paper in which he gives his several objections to Fraenkel's theories and records a series of experiments on guinea-pigs. In his first series of experiments he tried to determine the influence of bilateral ovariectomy on the pregnant animal, concluding that this operation in the pregnant animal always interrupts pregnancy during more than the first half of its duration. He also tried giving Fraenkel's lutein tablets, with no results. He had better results from a product of the whole ovary.

Ancel and Bouin ('08-'09) contributed several papers to the literature on the corpus luteum. They believed with Fraenkel that the corpus luteum produced rut and the other changes incident to pregnancy. They performed a series of experiments on rabbits in which they produced an unfertile coitus either between a normal female and a male in which a part of the vas deferens had been resected, and a female in which a part of the uterus had been resected and a normal male. They wished by these experiments to eliminate any action of the egg and the placenta on any changes taking place in the uterus incident to ovulation. They describe structural changes in the uterus and mammary glands for a period equal to the period of activity of the yellow body.

In this same year ('09) two other Frenchmen, Regaud and Dubreuil, published several articles. They were particularly interested in the cause of rut and ovulation. They made a systematic study of a large number of uteri and ovaries in different phases of the genital cycle and concluded that rut is independent of the corpora lutea, and that it is improbable that the corpora lutea plays a rôle in originating the pregestative changes in the uterus, for the graphic curve of their development is much later chronologically than the curve of its changes. They claim that

coitus only will bring about ovulation. The congestive phenomena which they notice in the ovaries during rut will not produce the rupture of a single follicle without coitus.

Niskoubina, the same year ('09), published a series of studies which confirmed the observations of Ancel and Bouin. He first made a histologic study of a series of ovaries removed at varying intervals after coitus and then did some experiments similar to Fraenkel's to determine the period during which the ovaries seem to exert an influence on the pregnant uterus. From his experimental studies, he concludes: "The corpus luteum exercises an obvious action on the physiology of pregnancy. It puts the uterus in a condition necessary to assume the development of the fertilized egg. This action lasts during the first half of pregnancy, after which it ceases to act."

Loeb ('08) published a paper in which he states that deciduomata can be produced experimentally in the uterine mucosa of guinea-pigs by making a number of transverse and longitudinal cuts so as to break the continuity of the tissue. He states that this can happen only during a certain definite period after copulation, between the fourth and the eighth days. This is the time when freshly formed corpora lutea are present in the ovaries. These changes were not excited by the presence of ova, since they took place when the uterus was ligated and the passage of ova prevented. If the ovaries were removed, deciduomata could not be produced. He concluded, then, that the ovaries at certain periods after ovulation elaborate a predisposing substance, in the presence of which indifferent stimuli may produce deciduomata.

Parhon, Dumitresco and Nissipesco ('09) published a paper on the lipoids of the ovary. From various staining reactions on sections of ovaries and from chemical reactions of a powder made from ovaries, they conclude that in the interstitial cells of the ovary and in those of the yellow body fats are found which differ in many characteristics from the fat of the adipose tissue.

Mulon ('10) reported that the fat in the corpus luteum, which stains only faintly with osmic acid, was similar to other fats found in the adrenal and other organs of the body which form a

class of fats different from the ordinary body fat. He thought these so-called glandular fats had to do with the neutralization of the glandular excretions or the ordinary poisons formed in the cellular activity. The specific action of the fat of the corpus luteum was to neutralize the poisonous products formed by the developing embryo.

Miller ('10, '14) published some studies on human corpora lutea. He tried out many fat stains on fresh corpora lutea and claimed they contain no fat. He says the negative result of the fat reaction on fresh corpora lutea makes it possible to tell the difference easily between these and other ovarian structures. When the involution of the yellow body begins, the neutral fat reaction begins. The peripheral parts show the fat reaction first. In the corpus luteum of pregnancy the reaction to neutral fat remains negative to the end of pregnancy. He says that in a corpus luteum of five days the fat reaction was negative, in one of six to eight days there was a little, in one of eleven days more, and in one of twelve to sixteen days the cells were rich in fat (not neutral fat).

Meyer ('11, '13) wrote on the human corpus luteum. In his first paper he described the development and regression of the human corpus luteum of pregnancy, which confirms Sobotta's and Cohn's work.

Van der Stricht ('12) published the results of his studies on the corpora lutea and the interstitial cells of the ovary of the bat. This is one of the most valuable studies ever published on the corpus luteum, because the ovary of the bat, with its contained structures, is one of the simplest ever studied. No confusion arises from old corpora lutea; these are gone before the new ones are formed, as the periods of ovulation are so far apart, occurring each spring only. The author describes two secretions in the luteal cells. The first is a serous secretion which is very like the liquor of the follicle. This is secreted by the cells from the time of bursting until about the time the egg enters the uterine horns. The second is a lipid secretion. Beginning some time after the bursting, there is a slow elaboration of fatty granules from the depth of the cytoplasm of the luteal cells, the amount of which increases as the cells increase in size.

He says: "Far be it from our idea of admitting two absolutely distinct phases for serous secretion and lipid secretion. On the contrary, at a moment in the development of the corpus luteum these two processes coexist, but the first is especially marked at the beginning of gestation and the second exists alone during the following period." He concludes that: "the serous secretion exercises its influence on the transformations of the uterine mucosa of the first phase of gestation during the displacement of the egg and that the lipid secretion intervenes principally to provoke the arrest and fixation of the blastocyst and the formation of the placenta." Van der Stricht has not been able to demonstrate this serous secretion in the luteal cells, but because it is present in the central cavity of the young corpus luteum and in the lymphatics when they are first formed, he thinks the cells must be secreting it. Both the serous secretion and the lipid secretion are carried away, he says, by the lymphatics.

Corner ('16) published a paper on the corpus luteum of pregnancy in swine. He claims to have found in the corpora lutea of pregnancy, beside the cells which are descendants of the granulosa cells and the cells which are descendants of the theca cells, two more types of cells which can be found at all stages of pregnancy.

Livon ('09) published the results of the effect of injecting luteal extract into guinea-pigs. He writes as follows: "We have employed an extract of the corpora lutea of the sow and the cow, a product that I have today called the Product A. Injected into the peritoneal cavity of guinea-pigs, we find a toxic action varying with the rapidity of the absorption and with the individual. The toxic dose obtained generally is 20 to 30 centigrams per kilogram of animal. The animals die presenting general tremors, dyspnea, convulsions and uttering weak cries."

Champy and Gley ('11) are said to have been the first to show that the corpus luteum from pregnant cows was exceedingly active, whereas that from non-pregnant animals possessed little physiologic action.

Hare ('12) reported very favorably on the clinical use of corpus luteum extract.

Frank and Rosenbloom ('15) published the results of some experimental work done on rabbits with extracts of the placenta and the corpus luteum. They claim to have gotten better results than former investigators because they used a more concentrated and an alcoholic (fat solvent) solution of the active substance of the luteal extract. This active substance, they say, "is not a lipid but is carried along the lipoids." They state that the only corpus luteum substance extracted, which was found to be active, was derived from pregnant animals.

Dannreuther ('14) reported his results obtained clinically from the use of corpus luteum extract. He calls attention to the necessity of using the extract of pregnant animals only.

Up to date, the most noteworthy publication concerning the clinical value of the extract of the corpus luteum is that of Culbertson ('16), entitled, "A study of the menopause." He regards the climacteric as a "functional disarrangement on the part of the endocrine glands, the ovarian secretion having ceased." His theory concerning the value of luteal extract in the treatment of menopause disorders is as follows:

"Thus the chief characteristic stamping the vasomotor disturbances of the climacteric seems to be a disarrangement of the systolic-diastolic relation producing elevation in the pulse pressure. In blood-pressure estimations, then, we find a fairly reliable measure of the vasomotor disturbances of the menopause, as will be shown, a satisfactory method of treatment.

"If we accept the propositions thus far laid down, that the cessation of ovarian activity leads to a functional over-efficiency on the part of the pituitary and adrenal glands and that this, in turn, produces an arterial hypertension, the corollary is that by the administration of corpus luteum extract, the pressor substances will be neutralized and the tension will decrease."

In summing up, it may be stated that up to 1906 practically all the literature on corpus luteum had to do with the histologic origin and consequent structure at various succeeding periods in its life cycle. The writings of Sobotta and Cohn practically established the epithelial nature of the luteal cells and the glandular character of the structure as a whole. From 1906 to

1912 most of the papers written were reports of experimental studies undertaken to prove that the corpus luteum is the gland of internal secretion in the ovaries, and that, through this secretion, the luteal structure produces specific effects on other organs, particularly the uterus. In spite of the many criticisms directed against his work, Fraenkel still stands preëminent among the experimental workers who established beyond a doubt the foregoing hypothesis.

Since 1910, efforts have been put forth by investigators actually to demonstrate this secretion in the corpus luteum. Van der Stricht comes nearer the goal than any others. The greater part of recent literature, however, concerns the extract of the corpus luteum, its chemical constituency, its physiologic action, and its clinical value.

THE OVARIAN CYCLE

In the summer of 1914, while studying microscopic sections of the various tissues and organs of the spermophile, the relatively immense size of the ovaries, compared with those observed the previous spring, strikingly presented itself. On further comparison, it was very evident that this great increase in size had been brought about by a growth in the corpora lutea only. One ovary contained eleven of these bodies; there remained only a framework of ovarian stroma with a few atretic follicles.

With the particular stain the luteal cells bore a marked resemblance to the cells of the cortex of the adrenal. The former were much larger, but the shape of both, their arrangement in columns, the position and appearance of the nuclei, and the presence of lipid droplets in the protoplasm accounted for the likenesses. In fact, the luteal cells resemble secreting cells.

From observations that had been going on, it was known that these spermophiles had given birth to young about a month before. According to most writers, degeneration of the luteal cells begins not later than birth. Here were what looked like actively secreting cells a month after birth. Thereupon it was decided to try out some differential stains on these luteal cells at every stage in their life history, and to study the complete

ovarian cycle in the spermophile with a view to gaining some accurate information of the origin, development, life history, and function of the corpora lutea of the ovary.

In the spring of 1915, numbers of spermophiles were captured. But not having realized how very soon the animals become impregnated after coming out of hibernation, no strenuous efforts were made to obtain them until they were quite numerous in the fields, and consequently they were found to be either in advanced stages of pregnancy or lactating. However, all the animals that could be gotten were used for a study of the ovarian cycle through the summer and fall, until hibernation began.

Several animals were sacrificed each week. They were killed quickly with ether and bleeding. The ovaries were immediately placed in one of several fixatives, 10 per cent formalin, Zenker's fluid with acetic acid, Bensley's formalin Zenker, and Bensley's acetic acid bichromate. Many stains were experimented with. After considerable study of the fixed and stained sections, it was decided that for the problem in hand, two fixatives seemed best, Bensley's formalin Zenker and Bensley's acetic osmic bichromate—the former particularly for the nuclear structures and the latter for the elements in the protoplasm. In all the work of the past spring ('16), one ovary of each animal sacrificed was routinely placed in formalin Zenker and the other in acetic osmic bichromate.

Of the sections fixed in zenker, the best results were obtained with a modified Weigert stain (copper-chrome-hematoxylin), Ehrlich's hematoxylin and eosin, Mallory's connective-tissue stain, and Bensley's acid fuchsin and methyl green. A few sections of each series were prepared with these stains.

Of the sections fixed in acetic osmic bichromate, one of each series was stained with the Weigert stain and several with the acid fuchsin and methyl green of Bensley. Complete paraffin serial sections were made of all the ovaries studied.

The spermophiles went into hibernation about the middle of October although many of them became partially torpid earlier than this. The next spring it was determined to get them early enough. The frost was not out of the ground until about

April 15. As a result of strenuous efforts, the females were obtained while in rut and every day through the period of pregnancy, which was found to be twenty-eight days. Two or more were sacrificed each day.

The ovarian cycle was now completed. Ovaries were at hand for every week of the year except during the hibernation period when only a sufficient number of animals was sacrificed to make sure there were no changes taking place in these organs. For the period of pregnancy, a time which is especially related to ovarian activity, there were ovaries for even fractions of a day.

The period of rut evidently follows immediately on the awakening of the spermophiles in the spring. Ovulation follows on coitus. Most of the females are impregnated in a very short time. The period of pregnancy follows. From the time of ovulation until about September 1 the ovaries contain corpora lutea. These approach their greatest size about July 1. From September 1 to 15 the large corpora lutea have disappeared. With a disappearance of the corpora lutea, there is a very noticeable rapid growth of the follicles together with a noticeable decrease in size. The ovaries which in July consisted almost entirely of large corpora lutea with a small amount of ovarian stroma containing a few atretic follicles, by September 15 contained no corpora lutea, but instead, many medium and good-sized growing follicles containing very little liquor folliculi, but filled with mitotic figures.

In this paper descriptions will be presented, gross and microscopic, of the ovaries which, as the year goes around, show the characteristic changes of their cycle.

A typical ovary of the early fall will be presented first; second, one of the late fall just before hibernation, with its inactivity, and, third, one of the early spring, showing the characteristics of the rutting season. For the fourth period, the period of pregnancy, several ovaries will be described, marking the successive changes occurring in the corpora lutea principally. Finally, will be presented descriptions of a number of ovaries of the summer months, which show the final stages in the life history of the corpora lutea and the corresponding notable differences in the rest of the ovary.

Experiment 379-15 (spermophile 200). Captured during the spring of 1915. The ovaries were removed surgically September 14, 1915. Weight, 150 grams.

Microscopic observations of an ovary. Fixative, formalin zenker. Stain, hematoxylin and eosin (fig. 10). There are nine good-sized follicles, the larger of which measure about 0.4 x 0.4 mm. There are twice as many follicles half as large. There is a goodly number of small hyalinized follicles. Around the periphery of the ovary are numbers of primordial ova. The larger follicles are approaching maturity, but are still growing. They contain many mitotic figures and very little liquor folliculi. They are located through the cortex of the ovary, only three being near the surface. None of these larger follicles appear to be atretic. Through the medullary portion of the ovary are conspicuous clumps of interstitial cells.

The spermophiles begin to become torpid about September 15, but they are active by spells for some time after this, depending on weather conditions. In the laboratory, some are active until November 15.

Experiment 503-15 (spermophile 254). Captured during the spring of 1915. Sacrificed November 15, 1915. The animal had been hibernating six days.

Microscopic observations of an ovary. Fixative, formalin zenker. Stain, hematoxylin and eosin. This ovary appears very similar to that of spermophile 200. The larger follicles are about the same in number, size, and location. There are about the same number of smaller and hyalinized follicles as well as primordial ova. The size of the ovaries as a whole, however, has decreased. This is probably due to a marked decrease in the size of the blood-vessels and sinuses. The clumps of interstitial cells are much less conspicuous. The ovaries appear to have prepared themselves for their long period of functional inactivity.

Experiment 246-16 (spermophile 291). Captured April 25, 1916. Was injured in being caught, so was sacrificed immediately. Weight, 170 grams.

Gross observations of the uterus. The animal is in rut. The rutting season evidently lasts about two weeks. During this time practically all the females become impregnated. It may be stated here that the laboratory animals come out of hibernation much earlier. Those killed from the 1st to the 15th of March appeared to be in rut and one killed April 11 was found to be pregnant, showing that weather conditions set the time of the commencement of their sexual activities. The large size of the uterus is immediately noted (fig. 7). There has been an increase in length and breadth. It is twice as large as the inactive uterus. The cervix shows the greatest increase in size and it is filled with a thick mucoid substance. The walls of the vagina are swollen. It is very evident that the great increase in the size of the whole organ is due to a marked increase in the fluid content, which gives it a pale appearance. (For measurements see table.)

Gross observations of the ovaries. The ovaries of rut show several changes from those of the fall. They are larger and seem to be slightly congested. On the surface of each ovary may be seen several slightly raised, tiny, colorless, cyst-like bodies which are the mature follicles.

Microscopic observations of the ovaries. Fixative, formalin zenker. Stain, hematoxylin and eosin. Serial sections show ten larger follicles, all of which lie at the surface of the ovary and several of which are projecting slightly from the surface. One of these follicles measures 0.5 mm. x 0.4 mm., and another 0.5 mm. x 0.6 mm. None of them shows atretic changes and all are apparently mature. There is considerable liquor folliculi, and few mitotic figures among the granulosa cells (fig. 12).

The internal and external theca of these large follicles are distinct and comparatively thick layers. There is a well-marked membrane between the stratum granulosum and the internal theca. Acetic osmic bichromate sections stained with acid fuchsin and methyl green show a red secretion along this membrane and between the cells of the granulosa near it. The cells of the granulosa seem to have an increased amount of protoplasm which makes them larger.

Of the smaller follicles, a few are in good condition, but the greater number have become hyalinized. The hyalinization of so many of the smaller follicles gives a characteristic appearance to the ovaries of the spring (fig. 11). Indeed, it would seem that a few mature follicles have been produced at the expense of many. The primordial ova are few in number. The interstitial cells are not at all conspicuous.

Toward the end of the rutting season many uteri present a different picture. They are smaller and instead of appearing edematous appear congested.

Experiment 256-16 (spermophile 298). Date of capture April 27, 1916. Sacrificed April 28, 1916. Weight, 105 grams. (For measurements of uterus see table.)

Gross observations of the uterus. The blood-vessels to the uterus are all much congested and the organ itself shows some congestion throughout. There is one especially congested area in each horn about 1 cm. from their point of union. There is another specially congested area in the body near the point of union of the horns.

As there are no corpora lutea in the ovaries of this spermophile, the uterus is still one of rut, not pregnancy. What brings about this change in the uterus is not evident. The congested condition is, however, without doubt preparatory to the reception of the fertilized ova.

This brings us in the life cycle to the ovaries of pregnancy. It has been shown that the ovaries of the fall, winter, and early spring contain no corpora lutea. Occasionally some remains of these bodies of the previous year may be found, but this is very unusual. Thus when coitus takes place during rut and the

follicles burst and become transformed into corpora lutea, these new bodies are the only corpora lutea in the ovary. They are all produced simultaneously and they also develop simultaneously if they are not abnormal in some way.

The picture of the ovary changes, then, when fertilization brings on pregnancy. From this time on until the period of the growing follicles is reached in the late summer, the ovaries contain corpora lutea. These are the predominating structures in the ovaries of the spring and summer. The changes which take place in these organs during the period have to do with the corpora lutea principally. The following descriptions of ovaries will be attempts at picturing them with corpora lutea of various ages. As this study is very largely concerned with these luteal structures, they will be described in considerable detail. Probably the ovaries which contained the very youngest corpora lutea seen were those in which ovulation took place in the laboratory, the animals being sacrificed very shortly afterward.

Experiment 268-13 (spermophile 303). Captured May 3, 1916. Sacrificed the same day. Weight, 112 grams.

Gross observations. There are no visible signs of pregnancy in the uterus except congestion. The ovaries contain several slightly raised, small spherical bodies which resemble mature follicles except that they are red or pink instead of colorless.

Microscopic observations of the left ovary. Fixative, acetic osmic bichromate. Stain, acid fuchsin and methyl green. This ovary contains five luteal bodies, three of which are normal and two of which are not. Beside these, there are several growing medium-sized follicles, no large ones, quite a number of small atretic follicles and a few primordial ova. The interstitial cells are not as conspicuous in this ovary as they were in some of the ovaries of early pregnancy. All the blood-vessels and sinuses in the medullary portion of the ovary are very much dilated. Most of the ovary is made up of the five corpora lutea. Serial sections of the three normal ones show them to be of different sizes from 0.7 mm. x 0.8 mm. in diameter to 1.3 mm. x 0.1 mm., depending on the amount of blood which they contain, for practically all the young corpora lutea contain blood in their centers (figs. 13 and 17). A hemorrhage from a blood-vessel in the wall of the follicle must occur as the follicle bursts. The exact point of this bursting cannot be made sure of in any of these structures. Each luteal body is surrounded by a very thin connective-tissue capsule, no doubt the same theca externa which surrounded the follicle. From this thin capsule to the central core of blood are massed the luteal cells. They

seem to have no definite arrangement. Among them may be seen numerous fibroblasts and endothelial cells. These are most numerous about the periphery of the central mass of blood. Some are already making their way into it. The cells all seem to have their axes directed radially as if they were approaching the central mass of blood from the periphery of the luteal body. The luteal cells are of various sizes and shapes. Some are spindle-form and some polygonal, but the majority are spherical or oval. There is one specific characteristic of all young luteal cells and that is the existence of spherical granules in their protoplasm. In the sections fixed in Bensley's acetic osmic bichromate and stained with acid fuchsin and methyl green, these granules are strikingly brought out (fig. 26). They are colored a brilliant red. Their sizes vary somewhat, but they are all spherical. The protoplasm of some cells is so full of these granules that it resembles a homogeneous red secretion, but on examination with very high power, the separate granules may be seen. In many cells where the granules do not fill the protoplasm, they are grouped about the nucleus, leaving a narrow clear zone about the periphery of the cell. The nuclei take the green stain and are strikingly brought out against the red granules. Each nucleus contains one or two good-sized bright, red staining nucleoli. The chromatin threads stain green and do not show very well with this stain. For the nuclear characteristics, another ovary stained differently will be described.

The two abnormal luteal structures of this ovary are very interesting. One of them is a luteal cyst (fig. 23). There is only a single layer of luteal cells next to the thin capsule. No fibroblasts or endothelial cells are present. The whole body is filled with a transparent greenish-colored fluid which has every appearance of being of the same composition as the liquor folliculi.

The other structure (fig. 21) is much more normal. The center contains what resembles the above green-tinged fluid containing numerous red blood corpuscles. Masses of normal luteal cells are found most of the way around the body. But on one side is a mass of follicle or granulosa cells persisting untransformed. In several places, as in figure 22, some granulosa cells are found among the luteal cells. This peculiar luteal structure appears to give striking evidence to the theory that luteal cells are simply transformed granulosa cells. The differences between them are well brought out in the picture.

It may be well to state here that other fixatives and stains bring out these same specific luteal-cell characteristics, particularly the granules in the protoplasm. With a formalin zenker fixative and the acid fuchsin and methyl green stain, the granules appear the same in every way except in color. They are pink instead of red. With this same fixative and a copper-chrome hematoxylin stain, the granules appear brownish-black. With an acetic osmic bichromate fixative and the copper-chrome hematoxylin stain, the granules appear bluish-black. The nuclear characteristics of the early luteal cells are best brought out with a formalin zenker fixative and a hematoxylin and eosin stain.

Experiment 275-16 (spermophile 310). Captured May 1, 1916. One ovary was removed and the uterus ligated May 4, 1916.

Gross observations. There are no recognizable signs of pregnancy in the uterus, but the ovaries contain what resemble young corpora lutea.

Microscopic observations of the ovary removed. Fixative, formalin zenker. Stain, hematoxylin and eosin (fig. 13).

The nuclei of these early luteal cells are strikingly like those of the follicle cells. The nuclei of the latter have several small nucleoli with quite conspicuous chromatin strands. The nuclei of most of these early luteal cells also have several small nucleoli with numerous chromatin strands. But in some cells, the nucleus is much larger and contains only one or two larger and darker nucleoli, while the chromatin strands are finer and fewer.

A very few of the luteal cells in the early luteal structures show mitotic figures. There were none at all in those of spermophile 303. Of all the early corpora lutea studied, mitotic figures were found in these structures in the ovaries of only three spermophiles. These were apparently the earliest luteal bodies found. If mitosis occurs, as a rule it occurs just after the bursting of the follicle. It may be that the luteal cells which show mitotic figures are the transformed follicle cells undergoing mitosis as the bursting occurred.

There is one abnormal early luteal structure in the ovary (spermophile 310) which deserves mention, as it seems quite common and furnishes further proof that the luteal cells are simply transformed granulosa cells (fig. 24). The structure with this staining appears at first glance like a mature follicle. The liquor folliculi is present and the ovum lies over at one side of the central cavity against the surrounding cells, which resemble the granulosa cells of the follicle. On closer observation, however, it will be seen that the cells which were thought to be the epithelial cells of the follicle are larger, richer in protoplasm, and more irregular in shape and size. Scattered through them are numerous fibroblasts and endothelial cells. These fibroblasts are quite numerous about the ovum, as if they were attempting to wall it off. The ovum has been stripped of its own rim of granulosa cells and appears to be undergoing degeneration. The internal theca is missing. In fact, what we have here is a corpus luteum formed in a follicle which, if it burst, did not throw out enough of its contents to get rid of the ovum. Practically all of the epithelial cells must then have been retained. Where are they if they are not the luteal cells? The only missing cells are those of the internal theca and the only new cells are the fibroblasts and endothelial cells. Does it not appear reasonable that the internal theca cells which are of the same origin as the connective-tissue cells expend themselves in the formation of the new fibroblasts and endothelial cells? It is hard to account for these abnormal structures. Several of them showed blood in the central cavity, as if the normal hemorrhage had occurred into them. Possibly they are formed in the mature follicles that are ready to burst

and undergo the same changes incident to this phenomenon as the others except that, on account of not occupying a position close enough to the surface of the ovary, they are not able to discharge their contents.

Experiment 293-16 (spermophile 328). Captured May 4, 1916. Both ovaries were removed May 6, 1916. Weight, 119 grams.

Gross observations. The fetuses in the uterus measure about 2 mm. in length, which makes the luteal bodies in the ovaries older than those previously described.

Microscopic observations of the right ovary. Fixative, formalin zenker. Stain, acid fuchsin and methyl green. This ovary contained six corpora lutea. These luteal bodies appear differently, due principally to the rapid growth which has been going on among the fibroblasts and endothelial cells. These ovaries suffered some congestion through the manipulation of removal, and this helps to show the great numbers of capillaries and blood-vessels that have been formed in a short time. The central mass of blood is undergoing rapid organization. No doubt the presence of this blood with its serum and fibrin is the great attractive force which aids in the complete formation of the luteal body. Fibroblasts and endothelial cells are always attracted by serum and fibrin. As soon as the hemorrhage occurs in the follicle, they start in to organize it. This is evident from the radial direction which the axis of the fibroblasts all take very early. As they go into the center, the transformed epithelial cells of the follicle are carried in by them. Endothelial cells grow in, and so very early there is formed in the corpus luteum a complex system of blood-vessels and capillaries, as is seen in sections of this ovary.

In one of the corpora lutea in this ovary, the hemorrhage was so extensive that instead of trying to organize it, the fibroblasts have formed a wall around it. Since the fibroblasts have not penetrated very far, there is only a narrow rim of luteal cells. This structure is what is ordinarily called a hemorrhagic luteal cyst (fig. 25). Beside the corpora lutea in a section of this ovary, one notices readily the large clumps of interstitial cells through the medullary portion. These are, as a rule, conspicuous in the ovary of early pregnancy.

Microscopic observations of the left ovary. Fixative, formalin zenker. Stain, hematoxylin and eosin. This ovary contains only two corpora lutea. There are present in it several large, apparently mature follicles. The number of such follicles in an ovary evidently depends on the number of corpora lutea. Where there are a good many of the latter, the follicles evidently cannot grow. When there are only a few corpora lutea in an ovary, one or two follicles may reach the size of 0.5 mm. x 0.5 mm., or 0.5 mm. x 0.7 mm. These will, of course, degenerate as ovulation takes place only once a year, during the rutting season which has just gone by. And as there are practically no large follicles ever seen in the ovaries of July which contain the largest luteal bodies, they must degenerate before this time. Perhaps the pressure of even one large, growing corpus luteum is enough to bring this about.

Experiment 264-16 (spermophile 302). Captured May 1, 1916, and sacrificed the same day.

Gross observations. This animal is definitely pregnant, the fetuses measuring 7 mm. in length. The blood-vessels going to the uterus and the ovary are very much congested. They stand out sharply, showing plainly the blood supply to the two organs. The blood supply to the ovary is practically separate from that to the uterus, there being only one small anastomosing branch close to the ovary. There are what look like corpora lutea in the ovaries, but they cannot be counted with any certainty. They resemble little reddish-pink cysts sticking out from the surface of the ovary. Naturally, from the size of the fetuses, the corpora lutea in these ovaries are older than those of spermophile 328.

Microscopic observations of the left ovary. Fixative, acetic osmic bichromate. Stain, acid fuchsin and methyl green. There are four luteal structures in this ovary. They show some changes over the younger ones previously described. They are slightly larger, measuring about 0.7 mm. x 0.8 mm. The luteal cells have become larger and more regular in shape. Many more have assumed an oval form and all seem to be approaching this. They seem to be tending toward a radial arrangement also. This is being effected evidently by the arrangement of the connective-tissue strands. The latter are running from the capsule to the central core of blood, which is almost organized. The system of capillaries and blood-vessels is even more complex than that of the luteal body of spermophile 328. In the luteal cells themselves the red granules have increased in number and vary slightly in size. They occupy the same position in the cell. The nuclei of all the cells are larger and contain one or two large bright nucleoli with numbers of very fine chromatin strands.

Experiment 296-16 (spermophile 331). Captured and sacrificed May 6, 1916. Weight, 146 grams.

Gross observations. The fetuses in the uterus are 1 cm. in length, which lead us to expect to find changes in the corpora lutea of the ovaries.

Microscopic observations of the left ovary. Fixative, acetic osmic bichromate. Stain, acid fuchsin and methyl green. The size of the luteal structures has increased. There are two in this ovary, one measuring 0.9 mm. x 0.9 mm., and the other, 1 cm. x 0.8 mm. The most noticeable feature of this later luteal body is the absence of any blood in the center. Instead, there is a core of connective tissue. The size of this connective-tissue core depends evidently on the amount of hemorrhagic material there is to organize. In some bodies the core is much larger than in others. Very perceptible strands of connective tissue run from this central mass to the capsule, enclosing columns of luteal cells. Gross strands have developed also so that connective-tissue strands seem to be enveloping each cell. There is a complete capillary network following the arrangement of the strands of connective tissue. Good-sized blood-vessels are located about the periphery

of the structure. Several smaller ones are present in the central connective-tissue core. There are several sinuses about the periphery lined with endothelium which appear to contain lymph. The lutea cells themselves have increased in size. Many more have taken on an oval shape and are lying with their long axes perpendicular to the capsule. The same red granules are still present in the protoplasm. These do not seem to be quite as numerous in the cells, which fact is in part due, no doubt, to the increased size of the latter. The granules are now found scattered throughout the protoplasm, the clear zone about the periphery of the cell having disappeared. The granules show more difference in size than formerly, but they are still all spherical. The nuclei have not changed. In a few cells there is a clear space in the protoplasm on one side of the nucleus.

Microscopic observations of the right ovary. Fixative, formalin zenker. Stain, hematoxylin and eosin. There are seven corpora lutea which make this ovary larger than the other one. Beside these bodies, this ovary contains approximately five good-sized, growing follicles about 0.4 mm. x 0.4 mm. Four follicles nearly the same size are undergoing atretic changes and there are about twenty small follicles, some of which are degenerating. Around the edge of the ovary are a few primordial ova. Through the medullary portion are some small groups of interstitial cells. They are not nearly as conspicuous as they were earlier in pregnancy (fig. 14).

Experiment 355-16 (spermophile 375). Captured May 20, 1916. Both ovaries were removed May 22, 1916. Weight, 128 grams.

Gross observations. The fetuses in the uterus are 1.5 cm. in length.

Microscopic observations of the right ovary. Fixative, acetic osmic bichromate. Stain, acid fuchsin and methyl green. There are six corpora lutea in the right ovary, measuring about 0.8 mm. x 0.9 mm. in diameter. Something is noted in the luteal structures in this ovary which has not been seen before, namely, that there are present in the cells close to the periphery some osmic-stained droplets. The size of the corpus luteum and the size of the individual cells are about the same as that of spermophile 331. There is a slight increase in the number of red granules in the cells. The clear space next to the nucleus is present in many more cells. The osmic-stained droplets are located at the periphery of the cell. They are very large compared with the red granules. They vary somewhat in size, but not in shape; all are spherical. Of course, in sections fixed with formalin zenker and stained with the various stains which were used, these lipid droplets appeared as vacuoles. But they could be easily recognized by their corresponding size and location in the cells. For convenience, these droplets will be called lipid droplets, because they certainly are a lipid product. They do not appear in the luteal cells before the fetus is about 1.5 cm. in length or about fourteen days old, that is, until the period of pregnancy is half over. These droplets make up the 'lutein' of the corpus luteum which has been described for many years and which has given the corpus luteum its name.

When the lipoid droplets appear in the cells, the period of the red granules is waning. The latter seem to reach their crisis of abundance when the fetus measures about 8 mm. in length. But the granules are still very abundant in the cells until the lipoid droplets begin to appear. From this time on, the former grow fewer and fewer and the latter increase in number, as will be shown, until they, too, reach a crisis of abundance and then decline.

Experiment 363-16 (spermophile 383). Captured and sacrificed May 24, 1916. Weight 140 grams.

Gross observations. The animal was in labor when killed. The uterus still contains two live fetuses, four having already been born. The crown-rump measurement of a fetus is from 4 to 5 cm.

Microscopic observations of the left ovary. Fixative, acetic osmic bichromate. Stain, acid fuchsin and methyl green. The luteal structures in the ovaries of this animal show some changes over those previously described (fig. 18). There are four of them. They have increased slightly in size, measuring 0.9 mm. x 0.9 mm. and the individual cells have increased correspondingly. Still more noticeable than their increase in size is the regularity of their oval form and the uniformity with which all their axes point in a radial direction. This seems to be due to an increased amount of connective-tissue framework, which, from the first, has seemed to govern the position and shape of the cells. The increase of connective-tissue framework has been accompanied by an increase in the size of the blood-vessels and capillaries. In the luteal cells (fig. 27) the red granules have decreased still more than in the cells last described, and this is very general throughout the structure. The lipoid droplets are much more numerous in all the cells. In fact, it seems hard to tell which is the predominant product of the cells, the red granules or the black droplets. The nuclei of these cells are slightly larger than the ones of the preceding description. Otherwise, they are the same. Most writers have agreed that degeneration of the corpus luteum begins about the time of birth. None is in evidence here. Several writers have stated that the principal reason for their belief was the entrance into the cells of osmic staining droplets which they considered to be evidences of fatty degeneration in the cells. It would not seem from the nuclear characteristics of the cell nor from the color, shape, and the regular size of the droplets, that they could be fatty degeneration products, especially when compared with the true fatty degeneration which occurs much later in the life history of the corpus luteum and which will be described accordingly.

Microscopic observations of the right ovary. Fixative, formalin zenker. Stain, hematoxylin and eosin. There are two corpora lutea in this ovary. A striking feature is the number of good-sized atretic follicles. There are at least twelve. This seems to be a noticeable feature of other ovaries about this same time. In fact, the follicles which were growing when ovulation took place, evidently go on and develop if there are not too many corpora lutea in the ovary, but as

the latter structures begin to increase in size quite rapidly about the time of parturition, there seems to be a degeneration of all the mature follicles even where there are only one or two luteal structures present. There are five medium-sized and about twenty small growing normal follicles, only a few of which show atretic changes. The primordial ova are very few in number, and the interstitial cells can scarcely be distinguished from the connective-tissue cells of the stroma.

Experiment 368-16 (spermophile 387). Captured May 24, 1916. Sacrificed May 25, 1916, twelve hours after having given birth to young. Weight, 115 grams.

Microscopic observations of the left ovary. Fixative, acetic osmic bichromate. Stain, acid fuchsin and methyl green. The three luteal structures in the left ovary of the animal measure either 0.9 mm. x 1.1 cm. or 0.9 mm. x 1 cm. The appearance of the luteal structure as a whole and of the individual cells is very similar to that of spermophile 383.

Experiment 369-16 (spermophile 388). Captured May 24, 1916, and sacrificed May 26, 1916, twenty-four hours after having given birth to young. Weight, 115 grams.

Microscopic observations of the left ovary. Fixative, acetic osmic bichromate. Stain, acid fuchsin and methyl green. The corpora lutea of the ovaries of this animal measure 0.8 mm. x 0.9 mm. There is scarcely any new noticeable difference unless it is a slight increase in the number of lipid droplets.

Experiment 370-16 (spermophile 389). Captured May 24, 1916. It gave birth to young on May 25, 1916. It was with the young until May 26, 1916, when it killed them. The next day, May 27, 1916, the animal was sacrificed. Weight, 135 grams.

Microscopic observations of the left ovary. Fixative, acetic osmic bichromate. Stain, acid fuchsin and methyl green. The corpora lutea in this ovary show a marked increase in the amount of lipid in the luteal cells. The red granules have correspondingly decreased in number. There are no other differences except a slight increase in size of the luteal structure and the cells.

Experiment 372-16 (spermophile 391). Captured May 18, 1916, and gave birth to normal young May 22, 1916. The young were destroyed May 26, and the animal was sacrificed May 31, 1916.

Microscopic observations of the left ovary. Fixative, acetic osmic bichromate. Stain, acid fuchsin and methyl green. The corpora lutea in the ovaries show the lipid content to be still more increased in amount and the red granules to be very scarce. There are no other differences. It might be stated here that there is some variation in the time when this lipid change comes on. For instance, the corpora lutea of the ovaries of spermophile 390, ten days after parturition, do not contain as much lipid as those of spermophile 391, nine days after parturition. But the majority of luteal bodies for any given time before or after parturition appear very similar.

Experiment 351-16 (spermophile 371). Captured May 20, 1916. The left ovary was removed on May 22, 1916. Weight, 135.5 grams.

Gross observations. The fetuses in the uterus are 2 cm. in length. This animal gave birth to young May 31, 1916, and was sacrificed June 17, 1916.

Microscopic observations of the right ovary. Fixative, acetic osmic bichromate. Stain, acid fuchsin and methyl green. The individual luteal cells are of about the same size and shape. The red granules are still quite abundant, but there seems to be a marked difference in the cells as to their individual content of red granules. This appears to vary with the number of lipoid droplets in the cell. In a few cells where the latter are very abundant, the red granules are found only in a rim about the periphery. Where the lipoid droplets are still few the cell protoplasm still contains many red granules with these few droplets scattered among them or occupying a peripheral position. Many cells have not changed at all; they have no lipoid droplets. Some cells have a peculiar appearance. Their protoplasm appears honeycombed. Since none of the cells had this appearance in the unstained sections, it was concluded that the cells must have been filled with lipoid which was dissolved out in the staining process and the result was this honey-combed appearance to the protoplasm. This was later proved to be the case. The lipoid droplets, when they are numerous, show much less variance in size than when they are few in number in the cell. The nuclei of these cells appear very similar to those of earlier cells. In some cells there is a slight change in their position. Instead of being directly in the center, in the cells filled with lipoid, the nucleus lies a little to one side of the center. The 1st of July, about thirty-five days after parturition, the corpora lutea in the ovaries were larger than at any other time.

Experiment 412-16 (spermophile 415). Captured and sacrificed July 1, 1916. Weight, 125 grams.

Gross observations. The ovaries are the largest yet seen, owing to the comparatively immense size of the corpora lutea. These are now of a yellowish-cream color and stand out prominently so that the ovary looks as if it were made up of several spherical bodies 1.5 mm. in diameter. Any other ovarian tissue except that holding the spherical bodies together can scarcely be distinguished. There are three corpora lutea in the right ovary and four in the left, which numbers correspond to the tiny white spots marking the former placental sites in the uterus.

Experiment 413-16 (spermophile 416). Captured and sacrificed on July 3, 1916. Weight, 157.3 grams.

Gross observations. The right ovary appeared grossly just like that of spermophile 415 (fig. 15).

Microscopic observations of the left ovary. Fixative, acetic osmic bichromate. Stain, acid fuchsin and methyl green. The corpora lutea are much larger than those previously described (fig. 19). They measure 1.1 mm. x 1.5 mm. in diameter (1.7 mm. x 1.3 mm., grossly some shrinkage). The luteal cells are correspondingly larger, and their

protoplasm is absolutely full of a mass of lipid droplets. This is seen to advantage in the unstained sections. In the stained sections the cells appear more or less honeycombed, according to the amount of lipid which has been dissolved out. These lipid droplets are very uniform in size and are dark brown, quite a different color from the black fat droplets of fatty degeneration. The red granules are gone. Where there is any protoplasm visible, it appears granular and pinkish-gray in color (fig. 28). The nuclei of the cells appear slightly smaller than formerly, but this apparent decrease in size is evidently due to the increase in the size of the cells, for the nuclei are no smaller by measurement. The location of the nucleus in the cell is the same as described under spermophile 371, either in the center or to one side of the center. The nucleolus stands out large and bright and the chromatin strands appear as they did. There are no apparent degenerative changes. Beside the three corpora lutea in this ovary, there are six or seven medium-sized normal growing and three atretic follicles. There are no large follicles or even any of good size. A few primordial ova are present, fewer than in any of the ovaries described thus far, and no interstitial cells can be distinguished as such (fig. 15).

Experiment 439-16 (spermophile 436). Captured June 23, 1916. Sacrificed July 15, 1916. Weight, 194.2 grams.

Gross observations. The uterus still shows several tiny white spots marking the placental sites. It is otherwise normal. The ovaries appear to contain corpora lutea, but these latter are certainly much reduced in size over those of spermophile 416. They appear congested or of a reddish-yellow color.

Microscopic observations of the left ovary. Fixative, acetic osmic bichromate. Stain, acid fuchsin and methyl green. The corpora lutea are much smaller (fig. 20). They measure 0.7 mm. x 0.8 mm. and 0.9 mm. x 0.9 mm. The cells are smaller. The protoplasm of the cells contains no red granules and very few lipid droplets or any honeycombing suggestive of these. It has a grayish, granular appearance. Something is present, however, which has not been seen before, and that is fat. Scattered here and there throughout the luteal structure, fat globules, characteristic of fatty degeneration, are present in the protoplasm of the cells. They are of various sizes and take on a characteristic black color with the osmic acid in the acetic osmic bichromate fixative. The nuclei of the cells show degenerating changes. The nucleolus has disappeared in some cells and in others appears pale and fringed. The chromatin strands are fewer and appear clumped in some cells. One striking new feature in the luteal structure is the great increase in the size of the blood-vessels and capillaries. The congestion of blood is not common to the whole ovary, but is only in the corpus luteum. The vascular change is apparently one factor in the disappearance of the luteal body.

Experiment 515-16 (spermophile 458). Captured August 18, 1916. Sacrificed August 21, 1916. Weight, 190 grams.

Gross observations. There are no evidences of placental sites in the uterus. There are no signs of corpora lutea in the ovaries.

Microscopic observations of the left ovary. Fixative, acetic osmic bichromate. Stain, acid fuchsin and methyl green. The left ovary shows three luteal structures (fig. 16). The largest measures 0.8 mm. x 0.8 mm. No red granules or lipid droplets are discernible. The greenish-gray granular protoplasm is everywhere filled with various sized fat droplets. In some cells these fat droplets are so large that they occupy nearly the whole cell, squeezing the degenerated nucleus out to one side of the cell (fig. 29). The nuclei are so degenerated, no chromatin strands or nucleolus are recognizable as such. What is left of the nucleus takes the acid fuchsin rather than the methyl green stain—so it is red. All the blood-vessels and capillaries are markedly dilated. There is a marked increase of connective tissue throughout the body. The thin capsule of connective tissue which before surrounded the luteal structure seems to have disappeared in places, making it appear as if the connective tissue of the body were continuous with that of the ovary around it. This connective-tissue invasion is evidently another factor in the disappearance of the corpus luteum. Three factors, then, are associated with the disappearance of the corpora lutea in the ovaries, cellular degeneration, vascular dilatation, and connective-tissue invasion.

A word may be added concerning the changes in the ovary outside the luteal bodies. There were in this organ six or seven good-sized, normal, growing follicles and four and five atretic ones. The most noticeable feature is the number of small hyalinized follicles. This is a noticeable feature of all the ovaries of this date which contain old corpora lutea. It would appear that as long as there are still luteal bodies in the ovary, there is very little growth in the follicles. There are a few primordial ova. The interstitial cells are not recognizable as such. By September 1 the corpora have disappeared from the ovaries and the organs again have assumed the appearance described for September 15.

There are occasional exceptions to the normal cycle. An ovary of spermophile 462, sacrificed October 30, 1916, was found with a little structure in it which appeared in every way to be a young corpus luteum. The cells contained red granules. Perhaps impregnation had occurred in the fall. This instance is mentioned because one function of the corpus luteum in spermophiles has been suggested by it. What keeps the follicles from becoming mature and ovulation from taking place at other times in the year from the spring? Evidently, the corpora

lutea help in regulating the periods between oestrus. No new follicles become mature in the fall as long as there are luteal bodies in the ovary and by the time the latter have disappeared it is too late for the follicles to become mature before the period of hibernation comes on.

A word concerning the interstitial cells may be added. These appear very prominent at two periods of the cycle, during the period of early pregnancy when the corpora lutea are young and apparently very active, and in the early fall when the follicles are developing and growing rapidly. Their significance is not evident. Several writers have claimed that the cells of the corpus luteum become the interstitial cells of the ovary. There is absolutely no basis for such a supposition as far as the spermophiles are concerned.

EXPERIMENTAL STUDIES

These experiments were made with a view to determining whether or not the results of certain experimental studies on the spermophile would substantiate the same work done on other animals.

The spermophile stand experimental surgery well. They are very satisfactory to work on as they are not nearly as susceptible to infectious diseases and are more resistant to local infections than most small laboratory animals. They are easily anesthetized. The surgical technic must be aseptic, and the animals must be placed in separate cages after the operation or they will chew one another's wounds open. They recover from the effects of the operation quickly, as a rule, and the wounds usually heal by first intention.

To all workers who have been interested in the functional relationship of the ovaries and the uterus and especially to those trying to isolate a particular function or functions for the corpora lutea, two problems have seemed of vital importance: First, what are the effects on the uterus of the removal of one or both of the ovaries? And, second, what are the effects on the ovaries of the extirpation of the uterus? These two problems

have a special bearing on the function of the corpora lutea when they deal with pregnant animals.

Another much studied problem closely related to the function of the luteal bodies attempts to explain the means by which ovulations are brought about and the results on the development of the corpora lutea if fertilization is prevented.

Following are protocols and results of experiments performed in connection with these various problems. Only those experiments which proved operative successes and in which reliable data were obtained will be included.

Series 1. Effects of the removal of the uterus on the ovaries of non-pregnant spermophiles

Experiment 230-15 (spermophile 146). Captured in the spring of 1915. Weight, 128 grams. Operated on June 11, 1915. Complete removal of the uterus.

Gross observations. There are good-sized corpora lutea in the ovaries.

Sacrificed July 20, 1915.

Gross observations. The ovaries appeared very much smaller.

Microscopic observations of the ovaries. Fixative, formalin zenker. Stain, hematoxylin and eosin. The ovaries show no degenerative changes except in the corpora lutea. These are undergoing regression. Connective tissue has heavily invaded every part of the luteal structure. The blood-vessels are numerous and good sized. There are many fat vacuoles present. The decrease in size of these ovaries is no doubt due to the decrease in the size of the corpora lutea.

Experiment 443-15 (spermophile 247). Captured in the spring of 1915. Weight, 207 grams. Operated on October 1, 1915. Complete removal of the uterus.

Died October 8, 1915.

Gross observations. Death was due to peritonitis.

Microscopic observations of the ovaries. Fixative, formalin zenker. Stain, hematoxylin and eosin. There is a marked congestion throughout the ovary. Many of the larger follicles are undergoing degeneration. Practically all the smaller follicles are markedly degenerated. This, no doubt, is a pathologic condition.

Experiment 444-15 (spermophile 248). Captured in the spring of 1915. Weight, 196 grams. Operated on October 1, 1915.

Died January 13, 1916.

Microscopic observations of the ovaries. Fixative, formalin zenker. Stain, hematoxylin and eosin. The great number of small hyalinized follicles are immediately apparent. They are so numerous that the

ovary has a lacy appearance. There are a few good-sized, apparently normal follicles and on the periphery are numbers of primordial ova.

Experiment 445-15 (spermophile 249). Captured in the spring of 1915. Weight, 110 grams. Operated on October 4, 1915. Complete removal of the uterus.

Sacrificed April 22, 1916.

Gross observations. The blood supply to the ovaries is intact. The ovaries are very small; the left so small as to leave doubt as to its identity. The right ovary appears to contain several tiny cysts.

Microscopic observations of the ovaries. Fixative, formalin zenker. Stain, hematoxylin and eosin. Tissue removed for left ovary proves to be a bit of granulation tissue. The right ovary appears to be normal. The several cysts noted grossly are large mature follicles which normally occur on the surfaces of the ovaries at this time of the year. No effects from the removal of the uterus are noted.

Discussion and summary of results. There seems to be no marked effect on the ovaries from the removal of the uterus. They seem able to repeat their life cycle as far as the follicles are concerned. It was thought that the great number of hyalinized follicles noted in the ovaries of spermophile 248 was a sign of degeneration due to removal of the uterus. However, on studying the ovaries of normal spermophiles killed about the same time for controls, there were found in the ovaries of two a great number of these hyalinized follicles (fig. 11). Evidently the hyalin degeneration occurs normally at this time of the year. It is, no doubt, part of the attempt to produce a few large mature follicles at the expense of many smaller ones.

Series 2. Effects of removal of the uterus on ovaries in pregnant animals

Experiment 270-16 (spermophile 305). Captured May 1, 1916. Weight, 98 grams. Operated on May 4, 1916. The uterus was removed to the cervix.

Gross observations. There are no signs of pregnancy in the uterus, but the right ovary contains what appears to be a hemorrhagic cyst.

Died May 9, 1916.

Gross observations. There was no apparent cause for death.

Microscopic observations of one ovary. Fixative, formalin zenker. Stain, hematoxylin and eosin. The ovary contains several corpora lutea of an early stage. One is markedly hemorrhagic. There is some degeneration apparent in the luteal bodies. Some cells are undergoing chromatolysis. There is an increased amount of connective tissue. The rest of the ovary appears to be in a very normal condition.

Experiment 294-16 (spermophile 329). Captured May 4, 1916. Weight, 117 grams. Operated on May 6, 1916. The uterus was removed to the cervix.

Gross observations. The animal appears to be in early pregnancy. Sacrificed May 20, 1916. Weight, 130 grams.

Gross observations. There are no adhesions about the ovaries; they appear to contain several white, transparent corpora lutea.

Microscopic observations of the right ovary. Fixative, formalin zenker. Stains, hematoxylin and eosin, and acid fuchsin and methyl green. There is no apparent pathologic condition of this ovary. Even the corpora lutea appear normal. They have proceeded in their development without the uterus and now have the same appearance as others of the same age. The only detectable difference might be a smaller number of red granules in the luteal cells.

Experiment 251-16 (spermophile 348). Captured May 6, 1916. Weight, 108 grams. Operated on May 9, 1916. The uterus was removed to the cervix.

Gross observations. The animal is pregnant. There are five placental swellings in each horn, measuring 6.5 mm. in length.

Sacrificed May 19, 1916. Weight, 102 grams.

Gross observations. Everything in the abdominal cavity is in excellent condition.

Microscopic observations of the ovaries. Right ovary: fixative acetic osmic bichromate; stain, acid fuchsin and methyl green. Left ovary: fixative, formalin zenker; stain, Weigert's copper-chrome hematoxylin. The ovaries are apparently normal. The corpora lutea appear like those of the controls except that the luteal cells contain a larger number of lipid droplets and fewer red granules. There are no signs of degeneration in the nuclei of the cells.

Experiment 314-16 (spermophile 349). Captured May 6, 1916. Weight, 122 grams. Operated on May 9, 1916. The uterus was removed to within 3 mm. of the cervix.

Gross observations. The animal is pregnant. There are four placental swellings in the right horn and five in the left about 4 mm. in length.

Sacrificed June 5, 1916. Weight, 135 grams.

Gross observations. Everything in the abdominal cavity is in excellent condition. Both ovaries were readily found and appear to contain large corpora lutea.

Microscopic observations of the ovaries. Right ovary: Fixative, formalin zenker; stain, Weigert's copper-chrome hematoxylin. Left ovary: fixative, acetic osmic bichromate; stain, acid fuchsin and methyl green and Weigert's copper-chrome hematoxylin. There is no apparent abnormality in the ovaries. The corpora lutea have developed normally. They are still in the red-granule stage. The cells contain some lipid droplets, but are full of red granules. The lipid droplets in these ovaries are not as numerous as would be expected, but normal ovaries vary somewhat as to the time when the lipid droplets begin to appear in the cells.

Experiment 317-16 (spermophile 353). Captured April 25, 1916. Weight, 116 grams. Operated on May 9, 1916. The uterus was removed to the cervix.

Gross observations. The animal is pregnant and, having been kept by itself since capture, the period of pregnancy must be at least fourteen days. The placental swellings measure 13 mm. in length and 10 mm. in width.

Sacrificed May 20, 1916. Weight, 130 grams.

Microscopic observations of the ovaries. Right ovary: fixative, formalin zenker; stains, hematoxylin and eosin, and Weigert's copper-chrome hematoxylin. Left ovary: fixative, acetic osmic bichromate; stain, acid fuchsin and methyl green. There is no pathologic condition apparent in the ovaries. The corpora lutea have gone on in their normal development. They appear very similar to those of spermophiles whose fetuses are nearing parturition.

Experiment 318-16 (spermophile 353). Captured April 28, 1916. Weight, 127 grams. Operated on May 9, 1916. The uterus was removed to the cervix.

Gross observations. The animal is pregnant and, since it has been kept by itself since capture, it must have been pregnant at least eleven days. The placental swellings measure 7 mm. in length.

Sacrificed May 31, 1916. Weight, 120 grams.

Gross observations. The ovaries appear very small. The blood supply is intact and there are no adhesions. There is a mass of fat around each ovary.

Microscopic observations of the ovaries. The right ovary was carefully studied. The other was lost. Fixative, formalin zenker. Stains, hematoxylin and eosin, and acid fuchsin and methyl green. Many degeneration changes are present all through the ovary. Practically all the follicles are degenerating. The corpora lutea show many degeneration changes also. There are practically no red granules in the cells and many fatty degeneration vacuoles are present. The nuclei of the cells show degenerative changes. Their margins are indented and their nucleoli are faded and fringed. The strands of chromatin are clumped. The capillary sinuses seem dilated and filled with blood. Evidently the ovaries have been injured by the operation.

Experiment 331-16 (spermophile 361). Captured May 4, 1916. Weight, 141 grams. Operated on May 12, 1916. The uterus was removed to the cervix.

Gross observations. The animal is pregnant, the placental swellings being 9 mm. in length.

Sacrificed May 20, 1916. Weight, 120 grams.

Microscopic observations of the ovaries. Right ovary: fixative, formalin zenker; stains, acid fuchsin and methyl green, and hematoxylin and eosin. The left ovary was lost. The right ovary shows no abnormality. The corpora lutea have gone on in their development. They are just entering the lipid stage.

Experiment 61-16 (spermophile 381) Captured May 20, 1916. Weight, 145.5 grams. Operated on May 22, 1916. The uterus was removed to the cervix.

Gross observations. The animal has given birth to young, probably a few days previously, as the uterus appears to be in an early stage of involution. There are good-sized corpora lutea in the ovaries.

Sacrificed October 20, 1916. Weight, 170 grams.

Gross observations. The ovaries are so small they are hard to find.

Microscopic observations of the ovaries. Right ovary: fixative, formalin zenker; stain, hematoxylin and eosin. Left ovary; fixative, acetic osmic bichromate; stain, acid fuchsin and methyl green. There is nothing abnormal about the ovaries. They are very similar to other ovaries removed at this time. The corpora lutea have disappeared normally.

Discussion and summary of results. Removal of the uterus has no apparent pathologic effect on the ovaries containing the corpora lutea of pregnancy. The latter pass through their normal cycle of development and regression. There seems to be a slight irregularity about the time at which the various changes in the life cycle come on; for instance, the corpora lutea in the ovaries of spermophile 348 seem to lose the red granules and take on the lipid droplets sooner than normally. Then, in the ovaries of spermophile 349, the corpora lutea have retained their red granules longer than usual. However, this may not be significant since there is some irregularity about the cycle normally.

Series 3. Effects of the removal of both ovaries on the uterus of non-pregnant animals

Experiment 200-15 (spermophile 139). Captured in the spring of 1915. Weight, 130 grams. Operated on May 28, 1915. Both ovaries were removed.

Gross observations. The uterus is in a stage of early involution. Sacrificed April 22, 1916.

Gross and microscopic observations of the uterus. Fixative, formalin zenker. Stain, hematoxylin and eosin. The uterus is very small. It shows no signs of rut or having been in rut, either grossly or microscopically. This is very abnormal for this time of the year. A comparison of this uterus with a normal uterus in rut at this time of the year brings out the differences. (Compare figs. 1 and 3; also 2 and 4.) A comparison of the dimensions of the two uteri brings out the marked differences in size (table).

Microscopic observations of the uterus. Fixative, formalin zenker. Stain, hematoxylin and eosin. Cross-sections through the horns and body of the uterus show much fibrosis of all the layers. There is much less muscular and glandular tissue than in a normal inactive uterus (compare figs. 3 and 5, 4 and 6). One striking feature is the number of obliterated blood-vessels with hyalinized walls. The lumen of the uterus is closed and no mucous secretion is present. The cervix shows these same changes to an even greater degree than the rest of the organ.

Experiment 201-15 (spermophile 140). Captured in the spring of 1915. Weight, 101 grams. Operated on May 28, 1915. The ovaries were completely removed.

Gross observations. The uterus is in the condition of early involution.

Postoperative notes. This animal became very fat and went into a torpid condition at times. On July 24 it was changed to a cage with two other animals who killed it. The body was badly traumatized and specimens were not saved.

Experiment 202-15 (spermophile 141). Captured in the spring of 1915. Weight, 108 grams. Operated on May 28, 1915. Both ovaries were removed.

Gross observations. The uterus is undergoing involution. Died September 21, 1915.

Gross and microscopic observations of the uterus. Fixative, formalin zenker. Stain, hematoxylin and eosin. This uterus appears very similar to the uterus of a normal animal killed the same day.

Experiment 218-15 (spermophile 142). Captured in the spring of 1915. Weight, 135 grams. Operated on June 3, 1915. Both ovaries were removed.

Gross observations. The uterus is undergoing involution. Sacrificed November 10, 1915.

Gross and microscopic observations. Fixative, formalin zenker. Stain, hematoxylin and eosin. The uterus is very similar to the uteri of the controls.

Experiment 220-15 (spermophile 151). Captured in the spring of 1915. Operated on June 28, 1915. Both ovaries were removed.

Gross observations. The uterus has become completely involuted. The uterus was removed September 28, 1915.

Gross and microscopic observations. Fixative, formalin zenker. Stain, hematoxylin and eosin. Compared with a normal control, this uterus shows no abnormalities.

Experiment 423-15 (spermophile 231). Captured in the spring of 1915. Weight, 200 grams. Operated on September 22, 1915. Both ovaries were removed.

Sacrificed March 18, 1916. Weight, 100 grams.

Gross and microscopic observations of the uterus. Fixative, formalin zenker. Stain, hematoxylin and eosin. This uterus shows the same changes as that of spermophile 139.

Experiment 424-15 (spermophile 232). Captured in the spring of 1915. Weight, 205 grams. Operated on September 22, 1915. Both ovaries were removed.

Gross observations. The uterus is normal.

Sacrificed May 8, 1916. Weight, 117 grams.

Gross and microscopic observations. Fixative, formalin zenker. Stain, hematoxylin and eosin. This uterus shows the same changes as that of spermophile 139. (Photograph of this uterus with a normal uterus of rut removed the same day (fig. 7). Table for measurements of these uteri).

Experiment 435-15 (spermophile 242.) Captured in the spring of 1915. Weight, 210 grams. Operated on September 28, 1916. Both ovaries were removed.

Sacrificed May 9, 1916. Weight, 155 grams. The same day a control animal, spermophile 233, which was captured the same time as spermophile 242, and had lived in the laboratory under the same conditions, was sacrificed also and the uteri of these two animals were photographed together (fig. 8).

Gross and microscopic observations. Fixative, formalin zenker. Stain, hematoxylin and eosin. The uterus of spermophile 242 shows all the changes noted in that of spermophile 139. (For dimensions of uterus see table.) The control uterus (table) does not show as marked enlargement as the uteri of animals brought in from the fields in the condition of rut, but aside from this variation in size, the uterus appears in every way like a typical one of rut.

Experiment 436-15 (spermophile 246). Captured in the spring of 1914. Weight, 95 grams. Operated on July 10, 1914. Both ovaries were completely removed.

Sacrificed September 29, 1915.

Gross and microscopic observations. Fixative, formalin zenker. Stain, hematoxylin and eosin. Compared with the uteri of the controls, this uterus shows atrophic changes of a similar nature to those of the uterus of spermophile 139, except that the atrophy must be even more marked to be noticed in a comparison with the controls of this time of the year.

Experiment 354-16 (spermophile 374). Captured May 20, 1916. Weight 128 grams. Operated on May 22, 1916. Both ovaries were removed.

Gross observations. The uterus is undergoing involution.

Sacrificed October 30, 1916. Weight, 120 grams. This uterus was photographed with that of a control animal and that of an animal ovariectomized and sacrificed on the same date—spermophile 378 (fig. 9).

Experiment 358-16 (spermophile 378). Captured May 18, 1916. Weight, 115 grams. Operated on May 22, 1916. Both ovaries were removed.

Sacrificed October 30, 1916. Weight, 135 grams. This uterus was photographed with that of spermophile 374 and a control.

Gross and microscopic observations. Some slight differences can be noted between the uteri of spermophiles 374 and 378 and their control. The uteri of the doubly ovariectomized spermophiles are both smaller than their control. This decrease in size is more noticeable in the cervix than in the rest of the uterus. The cervixes of these two uteri are much firmer also and contain very little mucus. It is true, the differences are only slight and are scarcely recognizable microscopically, especially after fixation. The main microscopic difference is a decrease in size of the blood-vessels in the uteri of the ovariectomized spermophiles. Perhaps this accounts for the fact that the uterus of the control has a healthier appearance grossly.

Discussion and summary of results. The uteri of animals doubly ovariectomized in the spring of the year show some changes over their controls by the fall of the same year. These are slight and are all of the nature of a functional atrophy. The cervix is affected the most. This atrophy increases so as to be quite noticeable by the fall of the next year. The very striking effect of double ovariectomy is the discontinuation of the changes in the uterus incident to the phenomena of rut.

Series 4. Effects of removal of both ovaries on the pregnant uterus

Experiment 293-16 (spermophile 328). Captured May 4, 1916. Weight, 119 grams. Operated on May 6, 1916. Both ovaries were removed.

Gross observations. The animal is in an early stage of pregnancy, the placental swellings being just visible grossly in the uterus.

Sacrificed May 20, 1916. Weight, 115 grams.

Gross observations. There are no signs of placental sites in the uterus. To be sure the animal had been pregnant, the ovaries were studied carefully. They contained early corpora lutea. Evidently the regression changes began in the uterus immediately after the removal of the ovaries.

Experiment 300-16 (spermophile 335). Captured in the spring of 1916. Weight, 101 grams. Operated on May 8, 1916. Both ovaries were removed.

Gross observations. The animal was in an early stage of pregnancy, the placental swellings being just large enough to be recognizable.

Died May 12, 1916.

Gross observations. The external wound is in bad condition, perhaps the fault of too much iodine. The inside of the abdominal cavity appears normal. The uterus is in good condition save on the ends where the blood supply has been injured. The congestion is much reduced. There are placental swellings, hard and dark red; five in the right horn and three in the left, very hard to see. The placentas and fetuses are apparently undergoing degeneration.

Experiment 302-16 (spermophile 337). Captured in the spring of 1916. Weight, 120 grams. Operated on May 8, 1916. Both ovaries were removed.

Gross observations. The animal is pregnant, the placental swellings being 6 mm. in diameter.

Sacrificed May 18, 1916. Weight, 142 grams.

Gross observations. The uterus is in a very unnatural condition. It appears dark red in color all over. (The color is not due to congestion as can be seen on microscopic section. Instead, it must be due to the presence of old clotted blood in the lumen.) There is one hard swelling still palpable. The pregnancy was interrupted and the placentas with the fetuses have been undergoing degenerative changes.

Experiment 303-16 (spermophile 338). Captured April 23, 1916. Weight, 221.5 grams. Operated on May 8, 1916. Both ovaries were removed.

Gross observations. The animal is pregnant, the placental swellings being of good size.

Sacrificed May 19, 1916. Weight, 140 grams.

Gross observations. The uterus is very dark-red colored, dead-looking and contains several dark-colored swellings. The blood supply to the uterus is intact as tested by Dr. Mann. It appears as though degeneration of the placentas with the fetuses has been going on.

Experiments 305-16 (spermophile 340). Captured May 6, 1916. Weight, 124 grams. Operated on May 8, 1916. Both ovaries were removed.

Gross observations. The animal is in an advanced condition of pregnancy, the placental swellings measuring 2.2 cm. in length and 1.3 cm. in breadth.

Died May 11, 1916.

Gross observations. The cause of death could not be determined. The uterus is very unhealthy appearing, dark red in color. The remaining placental swellings are of various sizes. They are very dark red and are hard. Apparently degeneration changes have been going on.

Experiment 307-16 (spermophile 342). Captured May 6, 1916. Weight, 142 grams. Operated on May 8, 1916. Both ovaries were removed.

Gross observations. The animal is pregnant, the placental swellings being 6.5 mm. in length. There are nine swellings in the left horn and three in the right.

Sacrificed May 20, 1916. Weight, 152 grams.

Gross observations. The uterus is very dark in color. There are some adhesions on the left end. In the left horn are four swellings, the first and fourth measuring 4 mm. in length and breadth, the second 4 mm. by 5 mm., and the third, 2 mm. x 2 mm. In the right horn are three swellings—the first measuring 4 mm. x 4 mm., the second

5 mm. x 5 mm., and the third, 3 mm. x 2 mm. Each swelling consists of a light-colored band surrounding a hard dark red mass. The same condition was found in all the other cases. Some of the placental swellings with the fetuses have disappeared entirely, the others are degenerating.

Experiment 333-16 (spermophile 362). Captured April 28, 1916. Weight, 168 grams. Operated on May 12, 1916. Both ovaries were removed.

Gross observations. The animal is in advanced pregnancy. The operation was difficult as there were so many large fetuses. No attempt was made to count the number for fear of disturbing them.

Sacrificed May 20, 1916. Weight, 125 grams.

Gross observations. The uterus appears about normal in color. There are three swellings in the left horn, 4 mm. by 5 mm., and ten in the right horn, same size, dark red and hard.

Experiment 355-16 (spermophile 375). Captured May 20, 1916. Weight, 143 grams. Operated on May 22, 1916. Both ovaries were removed.

Gross observations. The animal is in advanced pregnancy. The operation was performed with very little trauma, the fetuses not being removed from the abdominal cavity. The placental swellings were 1.5 cm. or more in length.

Sacrificed May 26, 1916. Weight, 130 grams.

Gross observations. The animal had aborted some time previously, perhaps twenty-four hours. There are seven placental sites in the right horn and two in the left, all 5 mm. x 6 mm. The uterus is normal in color. The placental swellings appear congested but not hard. They look very different from those previously described.

Experiment 357-16 (spermophile 377) Captured May 18, 1916. Weight, 116 grams. Operated on May 22, 1916. Both ovaries were removed.

Gross observations. The animal is in advanced pregnancy, the placental swellings measuring 2 cm. in length. The operation was performed with very little trauma, the fetuses not being removed from the abdominal cavity.

Sacrificed May 25, 1916. Weight, 110 grams.

Gross observations. The animal must have aborted shortly after the operation. There are three placental sites in the right horn and four in the left, 5 mm. by 4 mm.

Experiment 309-16 (spermophile 344). Captured May 6, 1916. Weight, 120 grams. Operated on May 8, 1916. Instead of removing both ovaries, the left ovary was removed and the right tube ligated on the opposite side.

Gross observations. The animal is pregnant, the placental swellings measuring 1.4 cm. in length. There are many of the latter in the left horn and only one in the right.

Sacrificed May 20, 1916. Weight, 120 grams.

Gross observations. The uterus appears healthy, a normal pale pink color, but it is very much swollen (table). There are three small palpable swellings in the left horn recognizable only from the increased size of the uterus at these points. Placental sites in the right horn not definitely established. Evidently the animal had aborted. The cause of the swollen condition of the uterus is not evident.

Microscopic observations of the ovaries. Left ovary: fixative, formalin zenker; stain, hematoxylin and eosin. Right ovary: fixative, formalin zenker; stain, hematoxylin and eosin. The left ovary removed at operation May 8, 1916, is normal. It contains eight corpora lutea, 0.8 mm. x 0.9 mm. in size. The right ovary obtained at autopsy May 20, 1916, is very interesting. It contains only one corpus luteum, 0.4 mm. x 0.5 mm. in size. This is in the final stage of its life cycle, the degenerative stage described in the first part of this work. The rest of the ovary is normal. Through its cortex are eight large follicles, apparently mature, not showing any atretic changes. One of these measures 0.8 mm. x 0.5 mm. There are many smaller growing follicles also, and quite a number of primordial ova. Almost in the middle of the ovary, just inside the cortex, is the one degenerated corpus luteum. It is full of large fatty degenerative vacuoles and enlarged blood-vessels and capillaries. The connective tissue has made great inroads. What made this corpus luteum degenerate is not evident. It will be shown later that after the removal of one ovary the other shows no pathologic effects. And even after removal of one ovary and a uterus containing fetuses, the other ovary with its corpora lutea shows no pathology. Evidently the ligation of the tube caused the corpus luteum in the right ovary to degenerate and abortion occurred, the same as on removal of both ovaries. This would make it appear as if the corpus luteum was the part of the ovary necessary to the development of the fetuses.

Discussion and summary of results. Ten animals were operated on to get results from the removal of both ovaries containing corpora lutea on the uterus containing fetuses. One of the animals died from too much ether. The others lived, but none of them came to term. Those operated on early in pregnancy did not abort. The placentas and fetuses degenerated. Those operated on when the pregnancy was well advanced, aborted. That this was not the effect of operative trauma will be shown by another series of experiments on the removal of one ovary in pregnant spermophiles.

Series 5. Effects of the removal of one ovary on the one remaining in non-pregnant spermophiles

Experiment 219-15 (spermophile 143). Captured in the spring of 1915. Operated on June 3, 1915. The left ovary was removed.

Gross observations. There are spots marking placental sites in the uterus.

Right ovary removed September 20, 1915.

Microscopic observations of the ovaries. Both ovaries: fixative, formalin zenker; stain, hematoxylin and eosin. The left ovary contains several large corpora lutea of the late lipoid stage. The right ovary contains no corpora lutea. It is a typical ovary of the fall of the year. There are many medium-sized growing follicles and many primordial ova. There is no demonstrable pathology. The corpora lutea must have disappeared normally.

Experiment 221-15 (spermophile 159). Captured in the spring of 1915. Operated on June 29, 1915. The left ovary was removed.

Gross observations. The uterus is normal and inactive.

The right ovary was removed August 5, 1915.

Microscopic observations of the ovaries. Both ovaries; fixative, formalin zenker; stain, hematoxylin and eosin. The left ovary contains six very large corpora lutea of the lipoid stage. The right ovary contains two small corpora lutea in the final stage of their life cycle, evidenced by their size, the large amount of fatty degeneration, the numerous large blood-vessels, and the great invasion of connective tissue. This ovary contains many medium-sized, ripening follicles, also many small follicles and primordial ova. No pathology is evident. It is a typical ovary of August 5. The results of these two successful experiments were so evidently negative that it seemed unnecessary to repeat them the next year.

Series 6. Effects of the removal of one ovary on the other ovary and the uterus in pregnant spermophiles

These experiments were controls for the experiments under series 4.

Experiment 352-16 (spermophile 372). Captured May 20, 1916. Weight, 148 grams. Operated on May 22, 1916. The left ovary was removed.

Gross observations. The animal is pregnant, the fetuses measuring 1.5 cm. in length. There are not many fetuses.

Sacrificed May 25, 1916. Weight, 135 grams.

Gross observations. All the fetuses are alive and no abnormalities are apparent. There are five fetuses in the right horn and two in the left. They measure 2.7 cm. by 1.5 cm.

Microscopic observations of the ovaries. Right ovary: fixative, formalin zenker; stains, hematoxylin and eosin, and Weigert's copper-chrome-hematoxylin. The left ovary was lost. The right ovary shows no abnormality. It contains five corpora lutea. They measure 0.8 mm. x 0.9 mm. in diameter and are in the early lipid stage, the condition which exists about the time of the birth of the fetuses. They still contain numbers of red granules, but the lipid droplets are very conspicuous in the cells. In fact, some cells are so full of the lipid that the red granules are in evidence only at the periphery of the cell.

Experiment 351-16 (spermophile 371). Captured May 20, 1916. Weight, 135.5 grams. Operated on May 22, 1916. The left ovary was removed.

Gross observations. The animal is pregnant, the fetuses measuring 2 cm. in length. The animal gave birth to young, May 31, 1916.

Sacrificed June 17, 1916. Weight, 130.2 grams.

Gross observations. The remaining ovary and uterus appear normal. There are three spots marking the placental site in the right horn and three in the left.

Microscopic observations of ovaries. Left ovary: fixative, formalin zenker, stains hematoxylin and eosin, and Weigert's copper-chrome-hematoxylin. Right ovary: fixative, acetic osmic bichromate; stain, acid fuchsin and methyl green. The left ovary contains three corpora lutea. These are in the late red-granule stage. The red granules are still quite numerous, but some cells contain lipid droplets about their periphery. The right ovary contains three corpora lutea of the lipid stage. It appears very similar to other ovaries containing luteal bodies of this stage. There is no demonstrable pathology in the ovary.

Experiment 359-16 (spermophile 379). Captured May 20, 1916. Weight, 154 grams. Operated on May 22, 1916. The left ovary was removed.

Gross observations. The animal is in advanced pregnancy. There was more trauma experienced in this operation than in the one performed on spermophile 377, in which both ovaries were removed. The animal gave birth to young on May 28, 1916, and kept them until June 8, 1916.

Sacrificed June 24, 1916. Weight, 136.5 grams.

Gross observations. The placental sites in the uterus are scarcely visible.

Microscopic observations of the ovaries. Both ovaries: fixative, formalin zenker; stain, hematoxylin and eosin. The left ovary contains six corpora lutea of the same stage as the left ovary of spermophile 371, the late red granule stage. There are a few lipid droplets located through the cells. The right ovary contains four corpora lutea of the lipid stage. There is nothing abnormal about it.

Discussion and summary of results. Three spermophiles were operated on in this series. The results were positive. The removal of one ovary during the second half of pregnancy does not affect in any way the normal development of the fetuses. They go on to term. There is no effect produced on the remaining ovary and the development of its corpora lutea.

Series 7. Effects on the remaining ovary of the removal of one ovary and the uterus in pregnant animals

Experiment 273-16 (spermophile 308). Captured May 1, 1916. Operated on May 4, 1916. The right ovary and the uterus were removed.

Gross observations. Three or four placental swellings in the right horn of the uterus and three in the left about 4.5 mm. in length. Both ovaries show hemorrhagic areas which look like tiny hemorrhagic cysts. They are more noticeable in the right ovary.

Died May 11, 1916.

Gross observations. Absolutely no cause for death is apparent in the abdomen. The blood-vessels to the remaining ovary are very much congested.

Microscopic observations of the ovaries. Both ovaries: fixative, formalin zenker; stains, hematoxylin and eosin, acid fuchsin and methyl green, and Weigert's copper-chrome-hematoxylin. The right ovary contains five corpora lutea of a very early stage, measuring 0.7 mm. x 0.9 mm. The left ovary contains four corpora lutea, measuring 0.8 mm. x 0.5 mm. This organ shows no pathology except in the corpora lutea. These bodies show many degenerative changes. The cells have lost their red granules and their nuclei are undergoing chromatolysis. The connective tissue has increased greatly.

Experiment 290-16 (spermophile 325). Captured May 4, 1916. Weight, 111 grams. Operated on May 6, 1916. The right ovary and uterus were removed.

Gross observations. The animal is pregnant, the fetuses being just recognizable.

Sacrificed June 8, 1916.

Microscopic observations of the ovaries. Fixative, formalin zenker. Stain, acid fuchsin and methyl green. The right ovary contains five corpora lutea of a very early stage, about 0.5 mm. x 0.6 mm. in diameter. The luteal cells are filled with the red granules. There is a mass of blood in the center and practically no organization of connective tissue or blood-vessels. The left ovary contains six corpora lutea of the late red-granule stage. They have increased in size to 0.9 mm. x 1 mm. The normal development of the corpora lutea has apparently gone on in this ovary, as it compares very favorably with other ovaries of this date. There is no demonstrable pathology.

Experiment 279-16 (spermophile 314). Captured May 1, 1916. Weight, 100 grams. Operated on May 5, 1916. The left ovary and the uterus were removed.

Gross observations. It is impossible to recognize any fetuses in the uterus.

Sacrificed May 18, 1916. Weight, 112 grams.

Gross observations. The right ovary appears to contain corpora lutea. Everything in the abdomen is in excellent condition. There are no adhesions.

Microscopic observations of the ovaries. Right ovary: fixative, formalin zenker; stains, acid fuchsin and methyl green, Weigert's copper-chrome-hematoxylin, and hematoxylin and eosin. The left ovary was lost. The right ovary shows no pathology. It contains two corpora lutea which measure about 0.8 mm. x 0.8 mm. They seem to have reached their normal development for eighteen days. The number of red granules might have been slightly less than normal, but they are much more abundant still than the lipid droplets. There is a well-developed connective-tissue framework and network of blood-vessels throughout the luteal body. As there are only two corpora lutea in this ovary, several follicles have had room to mature. Two of these show atretic changes.

Experiment 292-16 (spermophile 327). Captured May 4, 1916. Weight, 130 grams. Operated on May 6, 1916. The right ovary and uterus were removed.

Gross observations. There are six swellings in the right horn of the uterus and four in the left, 8.5 mm. in length.

Sacrificed May 31, 1916. Weight, 170 grams.

Gross observations. The left ovary is found embedded in a mass of fat, but the blood supply to the ovary seems intact.

Microscopic observations of the ovaries. Right ovary; fixative, formalin zenker; stains, hematoxylin and eosin, Weigert's copper-chrome-hematoxylin. Left ovary: fixative, acetic osmic bichromate; stain, acid fuchsin and methyl green. The right ovary contains six corpora lutea, measuring 0.6 mm. x 0.7 mm. They are of the red-granule stage. There is no lipid. The mass of blood in the center is fairly well organized. The connective-tissue framework and network of capillaries are fairly well developed. The left ovary contains six corpora lutea which measure 0.7 mm. x 1.1 mm. in diameter. They have developed very normally, although not quite as rapidly as their controls. The red granules are still very numerous and there is scarcely any lipid present. The connective-tissue framework and the blood-vessel network are very well developed.

Experiment 295-16 (spermophile 330). Captured May 4, 1916. Weight, 116.5 grams. Operated on May 6, 1916. The right ovary and uterus were removed.

Gross observations. There are five swellings in each horn, all about 5.5 mm. in length.

Sacrificed May 26, 1916. Weight, 130 grams.

Microscopic observations of the ovaries. Left ovary: fixative, acetic osmic bichromate; stain, acid fuchsin and methyl green. The right ovary was lost. The left ovary contains five corpora lutea, measuring 0.7 mm. x 0.8 mm., and showing many degeneration changes. These are most apparent in the corpora lutea and the clumps of interstitial cells of the stroma. The latter cells appear swollen and their nuclei are undergoing chromatolysis. The cells of the corpora lutea are most degenerated in the center of the structure. Some cells seem to have disappeared entirely here, leaving holes. Many are undergoing fatty changes. Toward the outside of the structure there are cells which are still in fairly good condition, still containing red granules, though their nuclei have not taken the stains well, have indented margins and clumped chromatin strands.

Experiment 308-16 (spermophile 343). Captured May 6, 1916. Weight, 110 grams. Operated on May 8, 1916. The ovary and the uterus were removed.

Gross observations. The animal is pregnant. There are eight placental swellings in the left horn and one in the right, all 6.5 mm. in length.

Sacrificed May 31, 1916. Weight, 153 grams.

Microscopic observations of the ovaries. Right ovary: fixative, formalin zenker; stains, hematoxylin and eosin, Weigert's copper-chrome-hematoxylin, Mallory's connective-tissue stain. Left ovary: fixative, formalin zenker; stains, hematoxylin and eosin, Weigert's copper-chrome-hematoxylin. The right ovary contains one corpus luteum, measuring 0.8 mm. x 0.8 mm., and is of the red-granule stage. The left ovary shows no apparent pathology. The corpora lutea measure 1 cm. x 0.9 mm. and are of the early lipoid stage. They have developed normally.

Discussion and summary of results. In four of these animals the remaining ovary with its corpora lutea was not at all affected by the operation. In two of the spermophiles operated on, the second ovary showed changes. In spermophile 330 the whole ovary was affected, and in spermophile 308, only the corpora lutea. There was evidently some injury to the blood supply.

Series 8. Studies on the production of the normal bursting of follicles and the formation of corpora lutea

Experiment 311-16 (spermophile 346). Captured in the spring of 1916. Weight 88 grams. This animal appeared to be in rut on May 7, 1916. She was placed with a male at 10:10 A.M. on this date and removed at 3 P.M. on May 8, 1916.

Sacrificed May 8, 1916.

Gross observations. The uterus shows no signs of pregnancy. The ovaries show very small hemorrhagic areas, the smallest noted so far. In all probability, the animal has ovulated during the time it was with the male.

Microscopic observations of the ovaries. Fixative, formalin zenker. Stain, hematoxylin and eosin. There are three corpora lutea in the right ovary and five in the left. They are in a very early stage of development, appearing just like other very early ones. There were a few mitotic figures, one very sure proof of their very recent development.

Experiment 323-16 (spermophile 357). Captured April 27, 1916. Weight, 125 grams. This animal was kept separate from the time of her capture until May 8, 1916. At 3 p.m. on May 8 a male was placed with her and kept there until 10:45 a.m. on May 10, 1916.

Sacrificed May 10, 1916, 10:45 a.m.

Gross observations. Gross evidences did not show that the animal had ovulated.

Microscopic observations of the ovaries. Fixative, formalin zenker. Stain, hematoxylin and eosin. Both ovaries showed beautiful early corpora lutea, three in the right ovary and four in the left. These could not have been more than twenty hours old.

Discussion and summary of results. The results obtained in these two experiments prove that ovulation follows on coitus during rut.

*Series 9. To determine if ovulation is followed by the formation of corpora lutea when fertilization is prevented by the resection of 1 cm. of the uterus. One ovary was removed, also, to determine absolutely whether the animal was pregnant or not.*²

Experiment 280-16 (spermophile 315). Captured May 3, 1916. Weight, 100 grams. Operated on May 5, 1916. The right ovary was removed and 1 cm. of the uterus just above the body was ligated and resected.

Gross observations. The animal is not pregnant. She was placed with a male on May 20, 1916, and remained with him until sacrificed.

Sacrificed June 5, 1916. Weight, 120 grams.

Gross observations. The remaining ovary appears to contain corpora lutea. There is a good deal of pus about the ligature on the uterus, with adhesions to the intestines.

Microscopic observations of the ovaries. Fixative, formalin zenker. Stains, hematoxylin and eosin and Weigert's copper-chrome-hematoxylin. There are no corpora lutea in the right ovary. Several

² This series of experiments is at present being continued. No conclusions can be drawn from the results obtained so far.

large mature follicles are present. There are six corpora lutea present in the left ovary. They are of a very early stage, and measure 0.6 mm. x 0.7 mm. or 0.7 mm. x 0.7 mm. The cells are full of granules. There is a core of blood in the center which is undergoing organization. It certainly appears as if ovulation had taken place shortly before the animal was sacrificed.

Comparative sizes of uteri

EXPERIMENT	SPERMOPHILE	DATE	LENGTH OF RIGHT HORN	LENGTH OF LEFT HORN	SIZE OF BODY OF UTERUS	SIZE OF CERVIX	WIDTH OF RIGHT HORN	WIDTH OF LEFT HORN
			<i>cm.</i>	<i>cm.</i>	<i>mm.</i>	<i>mm.</i>	<i>mm.</i>	<i>mm.</i>
20C-15	139	April 22, 1916	4.5	4.5	2.5	2.0	1.0	1.0
42'-15	232	May 8, 1916	5.6	5.6	4.0	1.8	0.75	0.75
42"-15	233	May 9, 1916	7.0	6.5	5.0	4.0	1.0	1.0
437-15	242	May 9, 1916	6.3	6.3	3.0	2.0	0.7	0.7
246-16	291	April 25, 1916	11.4	10.3	8.5	8.0	4.0	5.0
276-16	298	April 29, 1916	7.2	7.0	9.0	8.0	3.0	3.0
374-16	374	October 30, 1916	6.8	6.0	3.5	2.0	1.0	1.0
378-16	378	October 30, 1916	6.3	6.3	4.5	2.5	1.0	1.0
657-16	462	October 30, 1916	6.7	6.5	5.5	2.0	1.5	1.5
30"-16	344	May 20, 1916	6.8	7.2	8.0	8.0	5.0	5.0

SUMMARY AND DISCUSSION

The results obtained from the histologic and experimental investigations carried on may be summarized as follows:

1. In the spermophiles, ovulation occurs only once a year, during the rutting season in the early spring. Ovulation is dependent on the stimulus of coitus, for no corpora lutea were found in the ovaries of animals which were kept from the males.

2. The corpora lutea cannot be responsible for the phenomena of rut for they are not present in the ovaries at this time.

3. The corpora lutea develop and pass through their normal cycle after ovulation whether fertilization follows or not (foot-note 2, p. 159).

4. While the corpora lutea are present in the ovaries, especially during the two months following parturition, the process of developing and ripening the follicles is at a standstill.

5. If the uterus is removed after conception, the corpora lutea do not begin to degenerate, but pass through their normal cycle. No effects are noted in the ovaries.

6. Removal of the uterus at any time does not produce noticeable effects on the ovaries even after a year's time.

7. Double ovariectomy performed at any time during the period of pregnancy interrupts gestation. If the operation is performed after a little more than the first half of pregnancy, the placentas with the fetuses simply degenerate. The involution of the uterus in these cases is very abnormal. If both ovaries are removed late in pregnancy, the animal aborts and the uterus undergoes a much more normal involution. The removal of only one ovary does not interrupt the pregnancy.

8. Double ovariectomy at any time prevents the recurrence of the cyclic changes in the uterus and produces an atrophy of the organ scarcely noticeable within a year.

9. The corpora lutea apparently do not influence the development of the mammary gland. When the uterus was removed very soon after conception, before any signs of pregnancy could be noted grossly in the uterus, and before any development of the mammary glands could be noted grossly, the developing corpora lutea in the ovaries produced no development in the mammary glands. This would seem to substantiate the work of Lane-Clayton and Starling who attribute to the fertilized egg the stimulus for the development of the mammary glands.

10. The corpus luteum of the spermophile derives its elements from the follicle just as Sobotta states occurs in the mouse. The luteal cells are the transformed granulosa cells of the follicle. The connective tissue and vascular network are derived from the cells of the internal theca which spends itself entirely in their formation. The capsule of connective tissue surrounding the luteal structure is the same external theca which surrounded the follicle. The microscopic pictures of the corpora lutea in the succeeding stages of their development correspond also to Sobotta's descriptions. It may be well to emphasize the complexity of the vascular network throughout the luteal structure which, when it is completed, brings every luteal cell in intimate contact with the blood stream.

11. The life cycle of the corpus luteum is made up of three distinct phases. First, the phase characterized by the presence

of great numbers of red granules in the protoplasm of the luteal cells. This phase embraces a period dating from the bursting of the follicle and covering the entire period of pregnancy. From a point of time very shortly after the bursting, the protoplasm of the luteal cells shows these red granules which become more and more abundant until they seem to reach a crisis of abundance when the organization of the luteal structure is about perfected, which is not until the placental swellings have reached a length of about 8.5 cm. From this time on the granules seem very gradually to decrease in number in the cells until parturition, when there is a sudden considerable reduction in their number. Some are found in the cells, however, even as late as the fourth week after parturition. Second, the phase characterized by the presence of many lipoid droplets in the protoplasm of the luteal cells. This phase begins sometime before parturition and lasts for about six weeks afterward. About the fourteenth day of pregnancy when the placental swellings in the uterus measure 1.5 cm. to 2 cm. in length, the lipoid droplets usually begin to make their appearance at the periphery of the luteal cells next to the capsule of the corpus luteum. They increase in number until at the time of parturition, they are quite noticeable in the cells, being found scattered all through the protoplasm among the red granules. After parturition, there seems to be a more rapid increase in the number of lipoid droplets, which coincides with the sudden decrease in the number of red granules previously noted. With this increase in lipoid content the cells which, from the beginning, have been growing constantly larger, seem to begin to hypertrophy more rapidly. The luteal cells are largest and contain the greatest amount of lipoid about six weeks after parturition. In two more weeks practically all the lipoid has disappeared from the cells and they are beginning to show evidences of degeneration. Third, the phase of regression. This period begins about eight weeks after parturition and lasts for four weeks. By the last of August the corpora lutea have disappeared from the ovaries. This phase is characterized by a fatty degeneration of the luteal cells by an increased vascularization and a connective-tissue invasion.

From these results, the following conclusions were drawn as to the functions of the corpora lutea in the ovaries of spermophiles:

The corpora lutea fix the period of estrus by preventing the development and the ripening of follicles until the time for the next rutting season is at hand.

The corpus luteum is a gland with two internal secretions, both of which have specific effects on the uterus, one bringing about the changes incident to pregnancy and the other effecting the normal involution of the organ. The first internal secretion is represented in the luteal cells during the period of pregnancy by granules which are very similar in their location and staining reactions to the granules in the A cells of the islands of Langerhans, the glands of internal secretion of the pancreas, described by Bensley. The granules of the luteal cells, however, are much larger than those of the A cells, being very easily seen with high powers of the microscope. No mitochondrial granules or filaments could be observed, perhaps because of the abundance of the granulations in the protoplasm. These luteal cell granules are very much like other secretion granules described by various writers as occurring in the secreting serous cells of several glands of the body.

The majority of writers have agreed that there is no fatty product demonstrable in the corpus luteum of several species of animals and man in the very early stages. They all seem to have been of the same opinion that the activity of the ovarian gland of internal secretion begins with the appearance of the lipid droplets in the cells. These lipid droplets were considered by them to be the evidence of the secretory activity of the corpus luteum. Its period of activity would then begin when these droplets begin to appear in the cells, which time varies with different species, but in all seems to be about the time of the fixation of the blastocyst. This activity lasts, they consider, for varying periods in different species. In the rabbit, Cohn, Fraenkel, and Niskoubina consider that it lasts for nine or ten days, when regression sets in about the fifteenth day. Van der Stricht says that in the bat the lipid droplets are in much greater abundance during the second half of the period

of pregnancy and that regressive changes do not begin until the period of pregnancy is over. Miller says there is no neutral fat in the human corpus luteum until regression sets in at birth. Because the first-mentioned group of men found that double ovariectomy did not cause abortion in rabbits after the fifteenth day, and did so earlier than this, they considered this lipid secretion related to changes in the uterus occurring between the fourth and fifteenth days after coitus, or between the time of the fixation of the blastocyst and the middle of the period of pregnancy.

Van der Stricht seems to have been the first to conceive of the presence of a secretion in the luteal cells prior to the appearance of the lipid droplets which coexists with them for some time after their appearance. He judges of the presence of this secretion in the cells from its presence in the near-by intercellular spaces and lymphatics. The latter, according to van der Stricht, are the avenues of excretion of both the serous and the lipid secretions.

In spermophiles, the lipid product does not begin to appear in the luteal cells until the period of pregnancy is half over and is not very abundant until after birth. As far as these animals are concerned, then, the lipid product is not the active substance of the corpus luteum which has specific effects on the uterus during pregnancy. This active substance is rather a secretion represented in the cells by the secretory granules previously noted, which are of a very different nature from the lipid droplets.

The second internal secretion which is represented in the luteal cells by lipid droplets and which formerly has been considered the secretion which is responsible for the changes occurring in the uterus incident to pregnancy, must be considered, as far as the spermophiles are concerned at least, as having another function. There seems to be some relationship in these animals between the period of greatest abundance of the lipid product in the cells and the period of regression and atrophy in the uterus. The uterus of the spermophile atrophies very slowly, much more so than in animals that bear several

litters of young every year. The atrophy is not completed until six or seven weeks after parturition, about the time when the lipid product reaches its crisis of abundance in the cells and begins to disappear. Another result which substantiates the theory that the lipid secretion brings about the normal involution of the uterus in the very abnormal, even pathologic process which goes on in the uterus following the removal of both ovaries during all but the more advanced stages of pregnancy. During the first half of the period of pregnancy there is no lipid in the corpora lutea, which, according to this theory, would account for the pathology in the uterus following double ovariectomy. If the ovariectomy is performed late in pregnancy after the lipid droplets have become quite abundant in the luteal cells, the animal aborts and the uterus undergoes an involution more nearly like the normal, due to the specific effect of the lipid secretion which is already present in the circulation. Mulon thought the lipid of the corpus luteum had an antitoxic action toward the poisons elaborated in the development of the fetuses. It would seem more reasonable to suppose that it neutralizes the toxic products produced in normal involution, which would be only a part of its function as a specific agent in effecting this normal involution of the uterus.

It may be added, in closing, that the two luteal secretions are undoubtedly emptied into the blood stream in these animals. An observation of the elaborate capillary network of these structures could lead to no other conclusion. Lymphatic sinuses are demonstrable in the corpora lutea, but they are found only near the capsule in the proximity of the larger blood-vessels. There is no anatomical evidence for concluding that the secretions are carried away by the lymphatics.

The writer wishes to express her appreciation for the valuable aid given her by Dr. Frank C. Mann, head of the Division of Experimental Surgery and Pathology of the Mayo Clinic, under whose direction this work was done.

LITERATURE CITED

- ALQUIER, L., AND THEUVENY, L. 1909 Etat de l'ovaire de chiennes ayant subi l'extirpation partielle ou totale de l'appareil thyro-parathyroïdien. *Compt. rend. Soc. de biol.*, T. 66, pp. 217-219.
- ANCEL, P., AND BOUIN, P. 1909 Sur la fonction du corps jaune; action du corps jaune vrai sur l'uterus. *Compt. rend. Soc. de biol.*, T. 66, pp. 505-507.
- 1908 Sur le follicule de De Graaf mur et la formation du corps jaune chez la chienne. *Compt. rend. Soc. de biol.*, T. 65, pp. 314-316.
- 1909 Sur les homologues et la signification des glandes a secretion interne de l'ovaire. *Compt. rend. Soc. de biol.*, T. 67, pp. 497, 464-466.
- BEACH, R. 1916 The management of ovarian tumors complicating pregnancy, labor and the puerperium. *Am. Jour. Obst.*, vol. 73, pp. 1029-1041.
- BELL, W. B. 1916 *The sex-complex*. New York, Wood, 1916.
- BENSLEY, R. R. 1911-12 Studies on the pancreas of the guinea-pig. *Am. Jour. Anat.*, vol. 12, pp. 297-388.
- 1916 The normal mode of secretion in the thyroid gland. *Am. Jour. Anat.*, vol. 19, pp. 37-57.
- BOND, C. J. 1906 An inquiry into some points in uterine and ovarian physiology and pathology. *Brit. Med. Jour.*, vol. 2, pp. 121-128.
- BURNAM, C. F. 1912 Corpus luteum extract, with suggestions as to its use in gynecologic practice. *Jour. Am. Med. Assn.*, vol. 59, pp. 698-703.
- CARMICHEL, E. S., AND MARSHALL, F. H. 1907 The correlation of the ovarian and uterine functions. *Proc. Roy. Soc., Lond., Series B*, vol. 79, pp. 387-395.
- CHALFANT, S. A. 1915 Subcutaneous transplantation of ovarian tissue, report of thirty-two cases with special reference to its effects on the menopause. *Surg., Gynec., and Obst.*, vol. 21, pp. 579-590.
- CHAPPELLIER, A. 1909 Follicles pluriovulaires et degenerescence ovulaire chez la souris blanche. *Compt. rend. Soc. de biol.*, T. 66, pp. 543-545.
- CHAUFFARD, A., LAROCHE, G., AND GRIGAUT, A. 1912 Fonction cholesterinigenique du corps jaune. *Compt. rend. Soc. de biol.*, T. 72, pp. 223-225, 265-267.
- CLARK, J. G. 1898-99 The origin, growth and fate of the corpus luteum. *John Hopkins Hospital Reports*, vol. 7, pp. 181-221.
- COHN, F. 1903 Zur Histologie und Histogenese des Corpus luteum und des interstitiellen Ovarialgewebes. *Arch. f. mikr. Anat.*, Bd. 62, S. 745-772.
- CORNER, G. W. 1915 The corpus luteum of pregnancy in swine. *Carnegie Institution, Washington, Publication no. 222*, pp. 69-94.
- CULBRETSON, C. 1916 A study of the menopause. *Surg., Gynec., and Obst.*, vol. 23, pp. 667-685.
- DAELS, F. 1908 On the relations between the ovaries and the uterus. *Surg., Gynec. and Obst.*, vol. 6, pp. 153-160.
- DANNREUTHER, W. T. 1914 Corpus luteum organotherapy in clinical practice. *Jour. Am. Med. Assn.*, vol. 62, pp. 359-362.

- DE LEE, J. B. 1916 Auto-transplantation of the corpus luteum. *Surg., Gynec. and Obst.*, vol. 22, pp. 228-231.
- FRAENKEL, L. 1903 Die Function des Corpus luteum. *Arch. f. Gynäk.*, Bd. 68, S. 438-545.
- FRANK, R. T., AND ROSENBLOOM, J. 1915 Physiologically active substances contained in the placenta and in the corpus luteum. *Surg., Gynec. and Obst.*, vol. 21, pp. 646-649.
- GRAVES, W. P. 1913 Influence of the ovary as an organ of internal secretion. *Am. Jour. Obst.*, vol. 67, pp. 649-665, 779-785.
- HARE, H. A. 1912 Therapeutic application of ductless glands. *Am. Jour. Obst.*, vol. 64, pp. 514-518.
- HARROWER, H. R. 1916 Relation of the internal secretions to neurasthenia in women. *Am. Jour. Obst.*, vol. 73, pp. 630-637.
- HEAPE, W. 1906 The source of the stimulus which causes the development of the mammary gland and the secretion of milk. *Am. Jour. Physiol.*, vol. 34, pp. 499-500.
- HIRST, J. C. 1916 The control of disagreeable symptoms of the surgical menopause by the hypodermic intramuscular administration of corpus luteum extract. *Am. Jour. Obst.*, vol. 73, pp. 648-650.
- ISCOVESCO, H. 1912 Les lipoides de l'ovaire. *Compt. rend. de la Soc. biol.*, T. 73, pp. 16-18, 189-191.
- JANKOWSKI, J. 1904 Beitrag zur Entstehung des Corpus luteum der Säugtiere. *Arch. f. mikr. Anat.*, Bd. 64, S. 361-389.
- LANE-CLAYPON, J. E., AND STARLING, E. H. 1906 An experimental inquiry into the factors which determine the growth and activity of the mammary glands. *Proc. Roy. Soc. Lond.*, Series B, vol. 77, pp. 505-523.
- LANE-CLAYPON, J. E. 1906 On the origin and life history of the interstitial cells of the ovary in the rabbit. *Proc. Roy. Soc. Lond.*, Series B, vol. 77, pp. 32-58.
- LEIGHTON, A. P. 1915 The use of corpus luteum extract in the treatment of menopause disorders. *Am. Jour. Obst.*, vol. 72, pp. 878-888.
- LEWIS, M. R., AND WARREN, H. 1914-15 Mitochondria in tissue cultures. *Am. Jour. Anat.*, vol. 17, pp. 339-402.
- LIVON, J., JR. 1909 Sur l'action des extraits du corps jaune de l'ovaire. *Compt. rend. de la Soc. biol.*, T. 66, p. 549.
- LOEB, L. 1906 The formation of the corpus luteum in the guinea-pig. *Jour. Am. Med. Assn.*, vol. 46, pp. 416-423.
- MARSHALL, F. H. A. 1910 The physiology of reproduction. *Lond.*, Longmans.
- MARSHALL, F. H., AND RUNCIMAN, J. G. 1915 On the ovarian factor concerned in the recurrence of the oestrous cycle. *Jour. Physiol.*, vol. 49, pp. 17-22.
- MARTIN, F. H. 1915 Ovarian transplantation. *Surg., Gynec. and Obst.*, vol. 20, pp. 568-579.
- MEYER, R. 1911 Über Corpus-luteum-Bildung beim Menschen. *Arch. f. Gynäk.*, Bd. 93, S. 354-404.
1913 Über die Beziehung der Eizelle und des befruchteten Eies zum Follikelapparat, sowie des Corpus luteum zur Menstruation. *Arch. f. Gynäk.*, Bd. 100, S. 1-19.

- MILLER, J. W. 1900 Die Rückbildung des Corpus luteum. Arch. f. Gynäk., Bd. 61, S. 263-286.
 1914 Corpus luteum, Menstruation und Gravidität. Arch. f. Gynäk., Bd. 101, S. 568-619.
- MULON, P. 1910 Sur l'existence de graisses antitoxiques. Compt. rend. Soc. biol., T. 69, pp. 389-391.
- NISKOUBINA, N. 1908 Sur la structure du corps jaune pendant et apres la gestation. Compt. rend. Soc. biol., T. 65, pp. 767-769.
- PARHON, C., DUMITRESCO, G., AND NISEIPESCO, C. 1909 Note sur les lipoides des ovaires. Compt. rend. Soc. biol., T. 66, pp. 650-652.
- PEARL, R., AND SURFACE, F. 1914 On the effect of corpus luteum substance upon ovulation in the fowl. Jour. Biol. Chem., vol. 19, pp. 263-274.
- REGAUD, C., AND DUBREUIL, C. Sur les relations fonctionnels des corps jaunes avec l'uterus non gravide:
 1909 1. Etat de la question et methodes de recherches. Compt. rend. Soc. de biol., T. 66, pp. 257-259.
 1909 2. Statistiques de variations de volume de l'uterus par rapport a l'etat des ovaires. Compt. rend. Soc. de biol., T. 66, pp. 299-301.
 1909 3. Etats successifs de l'uterus chez le meme sujet aux diverses phases de la periode pregravidique. Compt. rend. Soc. de biol., T. 66, pp. 413-415.
 1909 Sur les follicules ovariens hemorrhagiques et sur le mecanisme de la dehiscence des follicles. Compt. rend. Soc. de biol., T. 66, pp. 828-830.
 1908 Action du male sur le rut et l'ovulation chez la lapine. 1. Le voisinage prolonge, sans accouplement, est insuffisant pour provoquer l'ovulation. Compt. rend. Soc. de biol., T. 65, pp. 501-503.
- REGAUD, C., AND POLICARD, A. 1901 Fonction glandulaire de l'epithelium ovarique et de ses diverticules tubuliformes chez la chienne. Compt. rend. Soc. de biol., T. 53, pp. 615-616.
- SOBOTTA, J. 1896 Über die Bildung des Corpus luteum dei der Maus. Arch. f. mikr. Anat., Bd. 47, S. 261-309.
 1897 Über die Bildung des Corpus luteum beim Kaninchen nebst einigen Bemerkungen über den sprungreifen Follikel und die Richtungsspindeln des Kaninchens. Anat. Hefte, Bd. 8, S. 469-521.
- SUNDWALL, J. 1916 The lachrymal gland. Am. Jour. Anat., vol. 20, pp. 137-247.
- TUFFIER, T. 1915 Transplantation of ovaries. Surg., Gynee. and Obst., vol. 20, pp. 30-34.
- VAN DER STRICHT, O. 1912 Sur le processus de l'excretion des glandes endocrines; le corps jaune et la glande interstitielle de l'ovaire. Archiv. Biol., T. 27, pp. 585-722.
- VINCENT, S. 1912 Internal secretion and the ductless glands. Lond., Arnold.
- VINEBERG, H. 1915 Fate of ovaries after hysterectomy. Am. Jour. Obst. vol. 22, pp. 144-147.

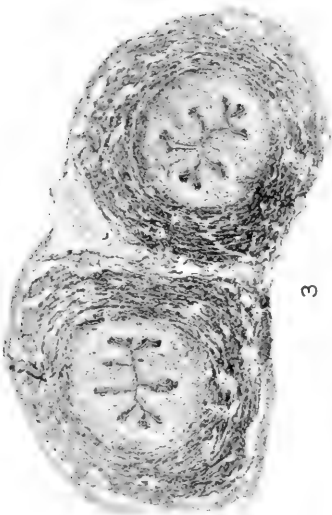FIGURES

Fig. 1 (experiment 248-16). Fixative, formalin zenker; stain, hematoxylin and eosin. Cross-section through the body of a normal uterus of rut. $\times 12$.

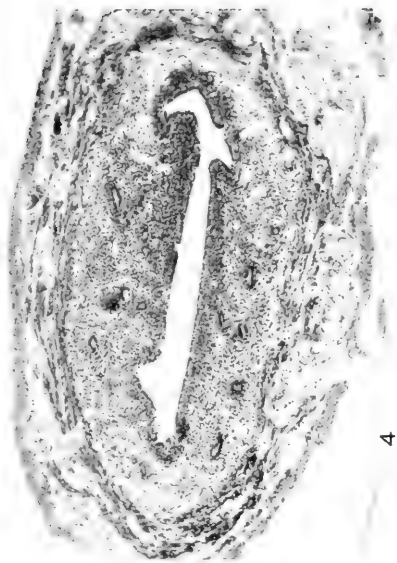Fig. 2 (experiment 248-16). Fixative, formalin zenker; stain, hematoxylin and eosin. Cross-section through the horn of a normal uterus of rut. $\times 12$

Fig. 3 (experiment 200-15) Fixative, formalin zenker; stain, hematoxylin and eosin. Cross-section through the body of a uterus after the removal of both ovaries. $\times 40$.

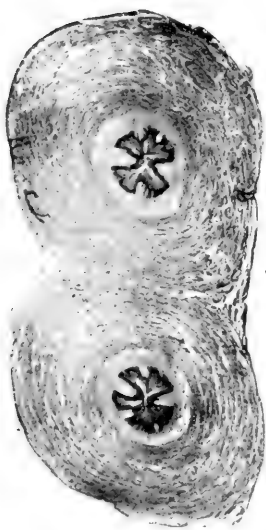
Fig. 4 (experiment 200-15). Fixative, formalin zenker; stain, hematoxylin and eosin. Cross-section through the horn of a uterus after the removal of both ovaries. $\times 40$.



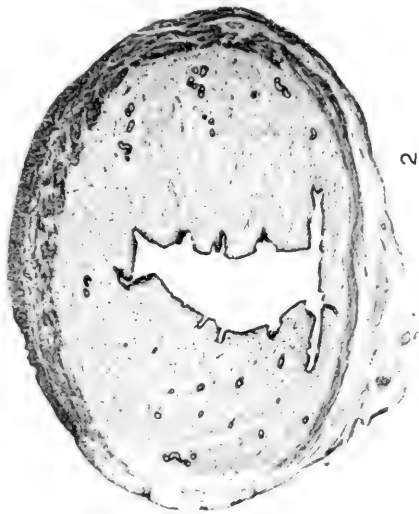
3



4



1



2

Fig. 5 (experiment 446-15). Fixative, formalin zenker; stain, hematoxylin and eosin. Cross-section through the body of a normal inactive uterus of September 22, 1915. $\times 40$.

Fig. 6 (experiment 446-15). Fixative, formalin zenker; stain, hematoxylin and eosin. Cross-section through the horn of a normal inactive uterus of September 22, 1915. $\times 40$.

Fig. 10 (experiment 346-15). Fixative, formalin zenker; stain, brasilin and wasserblau. Cross-section of an ovary of the late summer. $\times 24$.

Fig. 11 (experiment 219-16). Fixative, formalin zenker; stain, hematoxylin and eosin. Cross-section of a normal ovary of early spring. $\times 20$.

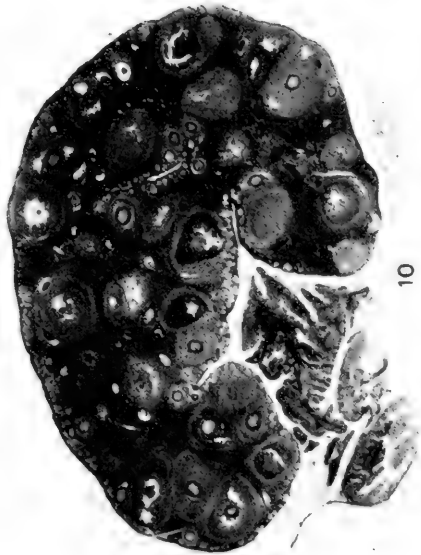
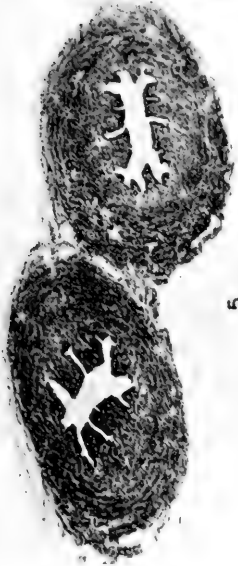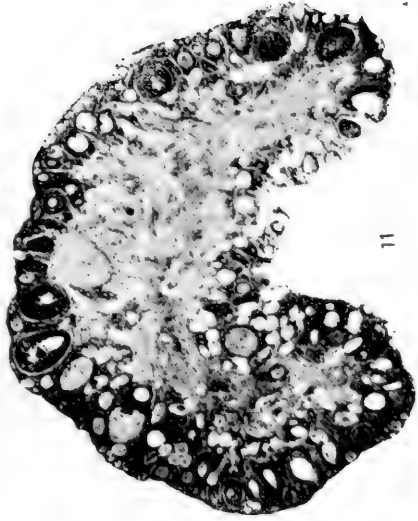

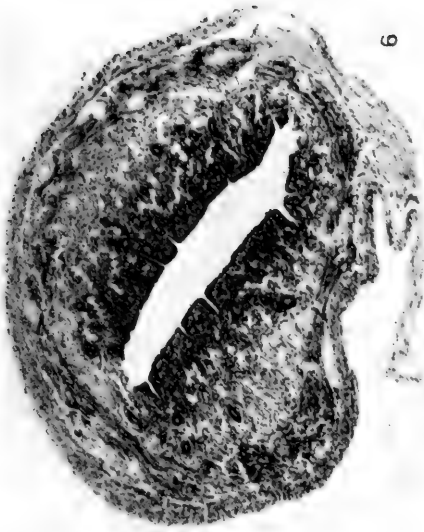
Fig. 7 (experiment 446-15). A uterus after the removal of both ovaries with a normal uterus of rut.

Fig. 8 (experiment 435-15). A uterus after the removal of both ovaries with a normal uterus of rut. Both were laboratory animals.

Fig. 9 (experiment 354-16). A is the uterus of a normal control. B and C are uteri of animals after double ovariectomy.

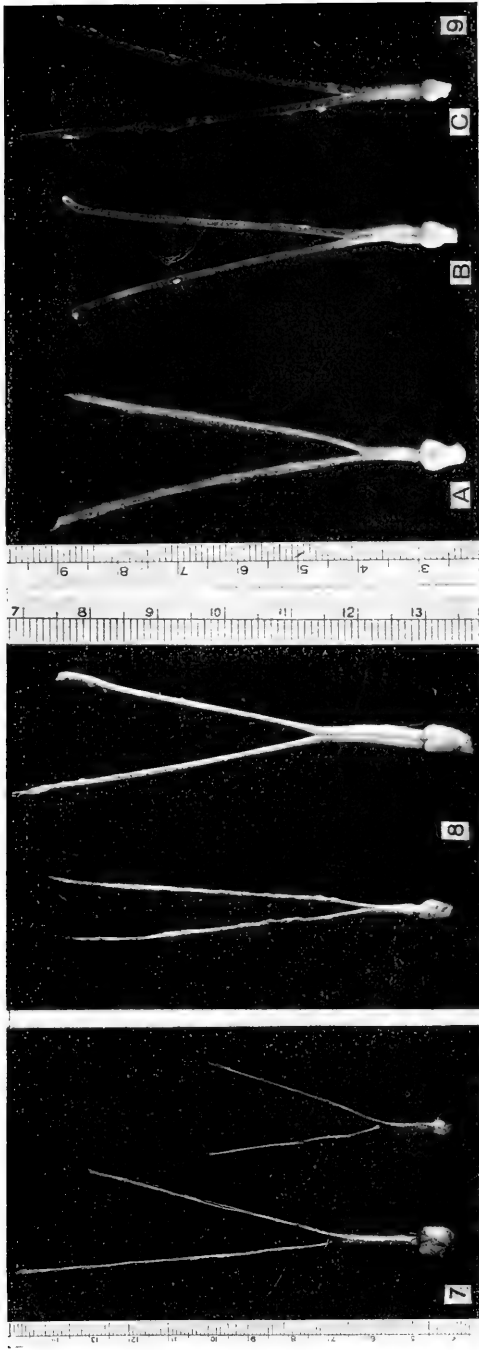
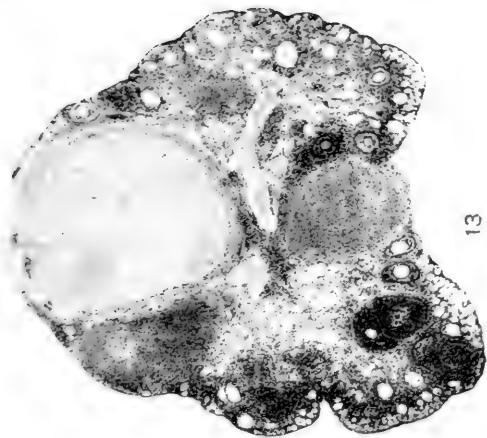


Fig. 12 (experiment 246-16). Fixative, formalin zenker; stain, acid fuchsin and methyl green. Cross-section of an ovary of rut. $\times 20$.

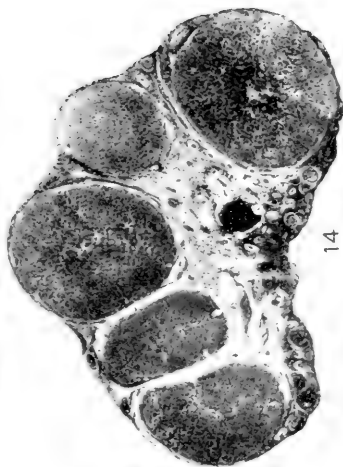
Fig. 13 (experiment 275-16). Fixative, formalin zenker; stain, hematoxylin and eosin. Cross-section of an ovary very early in pregnancy. $\times 20$.

Fig. 14 (experiment 277-16). Fixative, formalin zenker; stain, hematoxylin and eosin. Cross-section of an ovary early in pregnancy after the corpora lutea have become completely organized. $\times 20$.

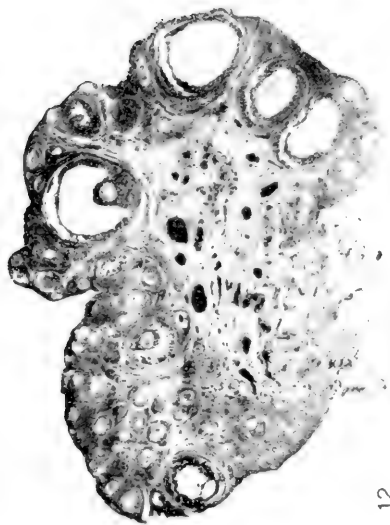
Fig. 15 (experiment 444-16). Fixative, acetic osmic bichromate; stain, acid fuchsin and methyl green. Cross-section of an ovary about eight weeks after parturition. $\times 16$.



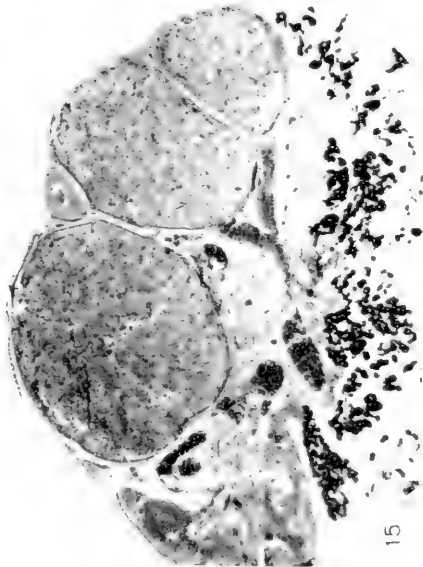13



14



12



15

Fig. 16 (experiment 515-16). Fixative, formalin zenker; stain, hematoxylin and eosin. Cross-section of an ovary about twelve weeks after parturition. $\times 20$.

Fig. 17 (experiment 268-16). Fixative, acetic osmic bichromate; stain, acid fuchsin and methyl green. Cross-section of a very early corpus luteum. $\times 64$.

Fig. 18 (experiment 363-16). Fixative, acetic osmic bichromate; stain, acid fuchsin and methyl green. Cross-section of a corpus luteum at parturition $\times 64$.

Fig. 19 (experiment 413-16). Fixative, acetic osmic bichromate; stain, acid fuchsin and methyl green. Cross-section of a corpus luteum six weeks after parturition. $\times 64$.

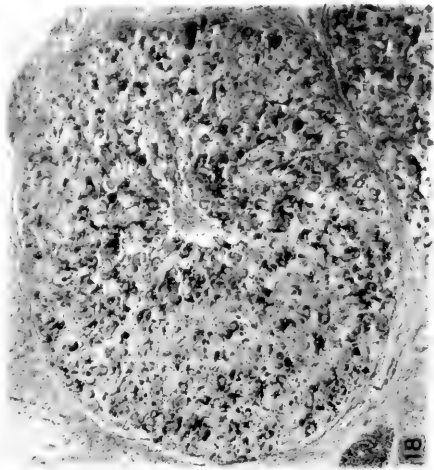
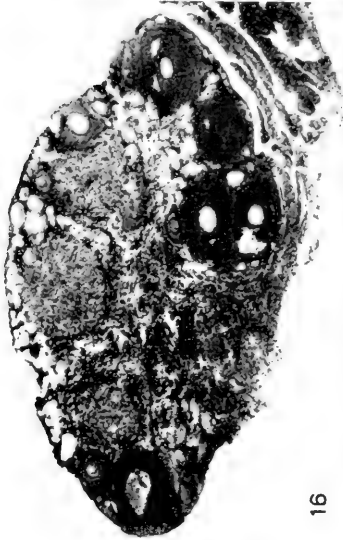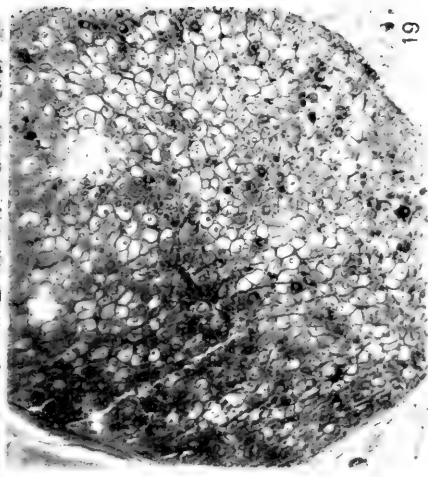

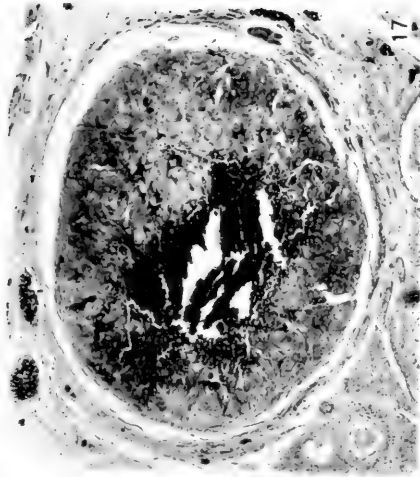
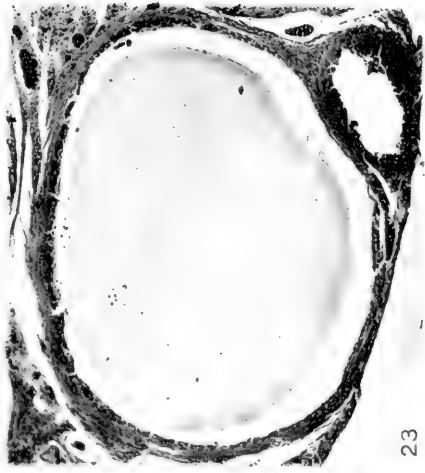Fig. 20 (experiment 439-16). Fixative, acetic osmic bichromate; stain, acid fuchsin and methyl green. Cross-section of a corpus luteum about eight weeks after parturition. $\times 64$.

Fig. 21 (experiment 268-16). Fixative, acetic osmic bichromate; stain, acid fuchsin and methyl green. Cross-section of an abnormal corpus luteum. $\times 64$.

Fig. 22 (experiment 268-16). Fixative, acetic osmic bichromate; stain, acid fuchsin and methyl green. Section through the wall of an abnormal corpus luteum showing untransformed cells of the stratum granulosum of the follicle persisting among the early luteal cells. $\times 480$.

Fig. 23 (experiment 268-16). Fixative, acetic osmic bichromate; stain, acid fuchsin and methyl green. Cross-section of a corpus luteum cyst. $\times 64$.

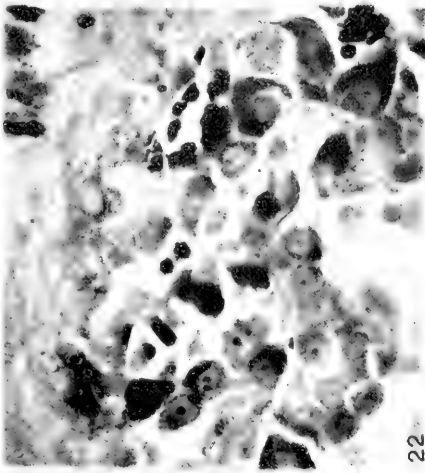
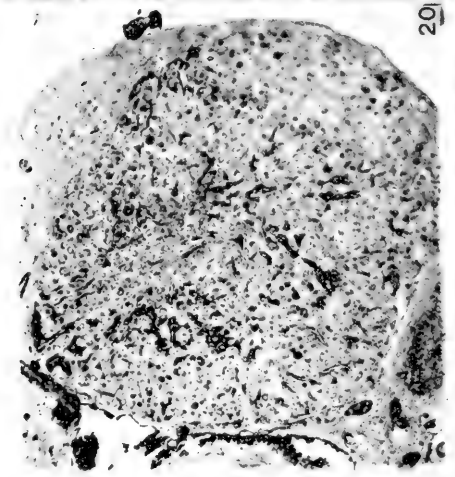
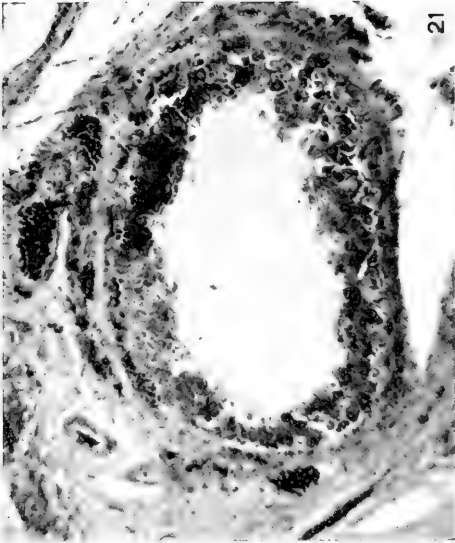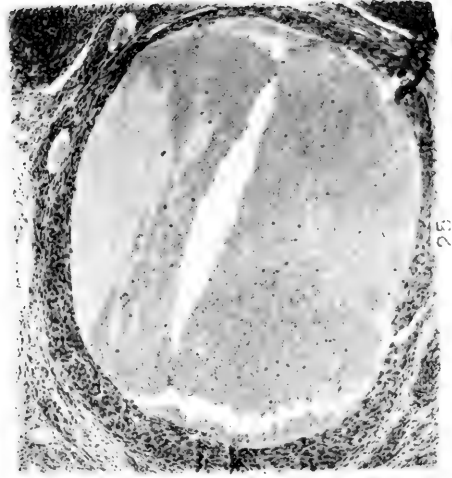
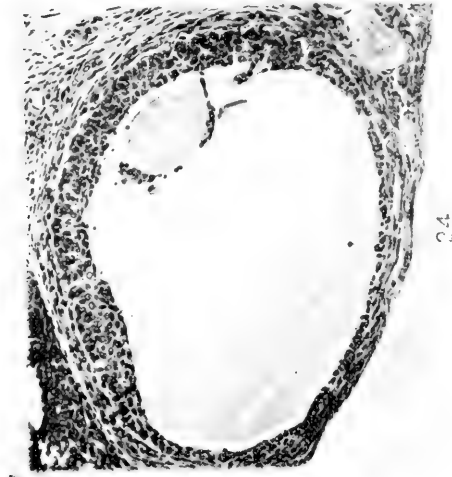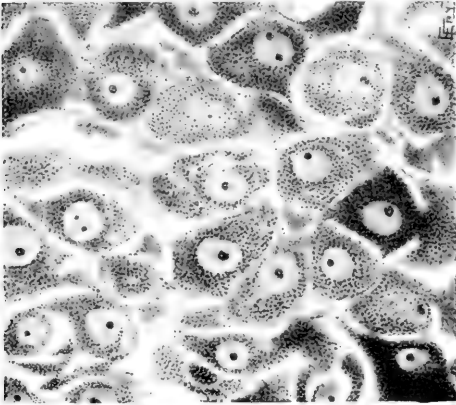




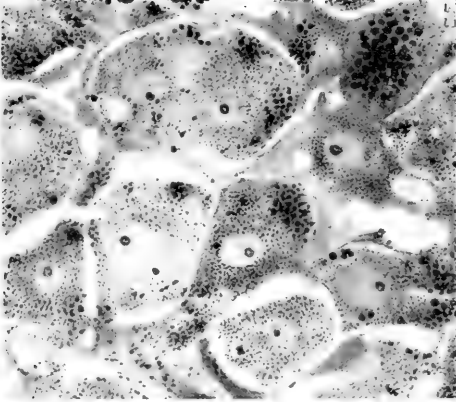
Fig. 24 (experiment 275-16). Fixative, formalin zenker; stain, hematoxylin and eosin. Cross-section of a corpus luteum with a retained ovum. $\times 64$.

Fig. 25 (experiment 293-16). Fixative, formalin zenker; stain, hematoxylin and eosin. Cross-section of a corpus luteum hemorrhagic cyst. $\times 64$.



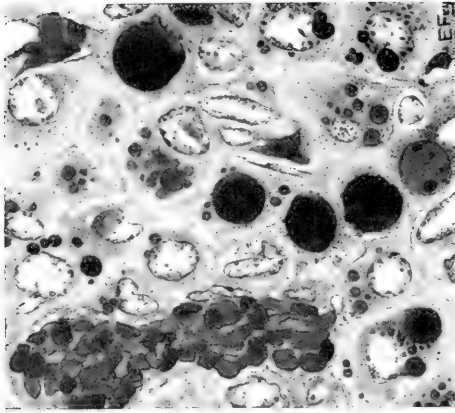
26

Fig. 26 (experiment 268-16). Fixative, acetic osmic bichromate; stain, acid fuchsin and methyl green. Portion of very early corpus luteum. (Red-granule stage.) Note luteal cells with so many granules that their protoplasm appears a homogeneous red. Fibro-blasts are forming the connective-tissue framework. \times 960.

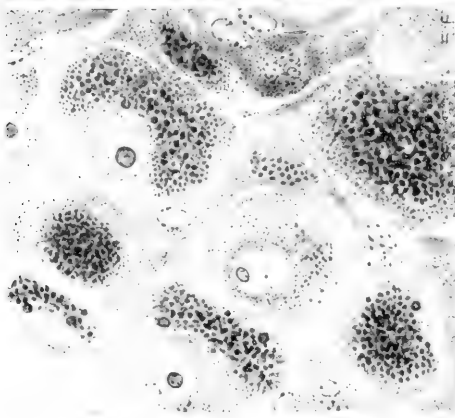


27

Fig. 27 (experiment 363-46) Fixative, acetic osmic bichromate; stain, acid fuchsin and methyl green. Portion of a corpus luteum at parturition. Note the black lipid droplets at the periphery of the luteal cells. Compare their size with that of the red granules. There is a well-formed connective-tissue framework. \times 960.



29



28

Fig. 28 (experiment 421-16). Fixative, acetic osmic bichromate; stain, acid fuchsin and methyl green. Portion of a corpus luteum six weeks after parturition (lipoid stage). Note the size of the cells, the active-looking nuclei, and the abundance of lipid droplets. $\times 960$.

Fig. 29 (experiment 515-16). Fixative, acetic osmic bichromate; stain, acid fuchsin and methyl green. Portion of a corpus luteum about twelve weeks after parturition (regression stage). Note vascularization and fatty degeneration. The nuclei have taken the acid fuchsin stain which is an evidence of degeneration. $\times 960$.

Resumido por el autor, Royal Norton Chapman.

Estudio sobre la correlación entre la estructura de la pelvis y las costumbres de algunos mamíferos cavadores.

En el presente trabajo se describen y estudian las pelvis de los mamíferos cavadores y según la estructura de dichos huesos se clasifican en 'cavadoras típicas' (topos, musarañas, *Geomys*, y algunas especies de *Microtus*) en las cuales los bordes ventrales de los huesos pubianos son horizontales y divergen posteriormente y la sínfisis falta en absoluto o, si existe, está formada por una barra ósea transversal; las 'semi-cavadoras' (muchas especies de ratones, algunos insectívoros), en las cuales los huesos pubianos están inclinados caudo-ventralmente y convergen para formar una sínfisis en sus puntos de contacto. Las pelvis 'cavadoras típicas' se han dividido en las de 'tipo estrecho' (topos y musarañas) y las de 'tipo ancho' (*Geomys*, topos marsupiales y otros). La sínfisis pubiana puede existir o faltar en las hembras de *Geomys* pertenecientes a la misma especie. Todas estas pelvis son horizontales y coosificadas con la columna vertebral, y de este modo dirigen la fuerza producida por los miembros posteriores al cavar, a lo largo de una línea recta paralela a la columna vertebral. La capacidad de la pelvis es, por consiguiente, tan limitada que es necesaria la desaparición de la sínfisis pubiana para permitir el paso del feto durante el parto. La falta de sínfisis pubiana está compensada en el soporte de las vísceras por el cruzamiento de los músculos rectos del abdomen—el músculo derecho se inserta en el hueso pubiano izquierdo y el músculo de este lado en el mismo hueso del lado derecho. Estas estructuras paralelas que se presentan en los diferentes grupos de animales de costumbres semejantes, indican la importancia de fuerzas similares, que actúan de un modo semejante, como factores de la modificación de la estructura.

Translation by Dr. José F. Nonidez
Columbia University

A STUDY OF THE CORRELATION OF THE PELVIC STRUCTURE AND THE HABITS OF CERTAIN BURROWING MAMMALS

ROYAL NORTON CHAPMAN

From the Zoological Laboratory, Cornell University

FIVE PLATES (TWENTY-SIX FIGURES)

CONTENTS

Introduction.....	185
The structure of the pelvis.....	187
1. The pelvic bones of the Rodentia.....	187
2. The pelvic bones of the Insectivora.....	192
3. The pelvic bones of the marsupial mole (Notoryctes).....	194
4. A classification of the pelvis of burrowing mammals.....	194
The status of the rectus abdominis muscles.....	195
1. The relations of the rectus abdominis muscles of the Rodentia.....	196
2. The relations of the rectus abdominis muscles of the Insectivora.....	197
The relation of the pelvic girdle and the habits.....	198
1. The attainment of the horizontal pelvis.....	198
2. The loss of the symphysis pubis.....	199
3. The persistence of the symphysis in certain cases.....	203
4. The function of crossed rectus abdominis muscles.....	205
Summary.....	206

INTRODUCTION

The results embodied in this paper are from data accumulated during several years of observation. This line of work first suggested itself during the examination of specimens in the field. It was noticed that the pocket gophers (*Geomys bur-sarius*) have two types of pelvis, one with a symphysis and the other without. This led to a more extended investigation of the pelvis of burrowing mammals, resulting in the revelation that they possess certain structural characteristics in common.

Huxley ('75), in a consideration of the mammalian pelvis, employed certain angles to show the progress of its phylogenetic development. A longitudinal line drawn through the centra of

the sacral vertebrae he termed the sacral axis (fig. 3, *Sa*). A line passing through the junctions of the ischium and the pubis on both sides of the obturator foramen designates the obturator axis (*Os*). Another line, drawn along the ilium through the middle of the sacral articulation and the center of the acetabulum bears the designation of the iliac axis (*Ia*). The iliopectineal axis (*Ilp*) is determined by a line traversing the union of the ilium with the pubis in front and with the ischium behind. This author concludes that in the phylogeny of the Mammalia the iliac axis (*Ia*) has tended to form a more acute angle with the sacral axis (*Sa*), that the angle formed between the iliopectineal axis (*Ilp*) and the sacral axis (*Sa*) has approached a right angle, and that the angle between the obturator axis (*Oa*) and the sacral axis has become more and more acute. That is, the pelvis, which in the Reptilia (fig. 1) was nearly perpendicular to the vertebral column, has approached a horizontal position. The symphysis is said to move posteriorly, until it is formed largely by the ischial bones rather than the pubic bones.

G. E. Dobson ('82) incidentally included descriptions of the estate of the pelvis in his study of the Insectivora. The nature of the symphysis pubis in the families treated is mentioned, but no generalizations are given.

W. Lecke ('84, '92) considered the pelvis and the rectus abdominis muscles of the Insectivora from both the phylogenetic and ontogenetic points of view. His conclusions will be referred to later in this paper.

H. L. Osborn ('94) concluded that the symphysis proper of the pocket gophers (*Geomys bursarius*) was absent and stated his belief that the bone present in the male, forming a 'pseudo-symphysis,' was an ossification of a tendon and not a part of the pubic (or ischial) bone.

Broek ('14) and others have made studies of the pelvis of man and the apes in which correlations with the habits of locomotion have been found and described. There is a vast amount of literature dealing with the human pelvis but, since it does not bear directly upon the subject at hand, it has not been included in this discussion.

Thanks are due Dr. H. D. Reed, under whose direction this work was done, for many suggestions and for assistance while the work was in progress. Acknowledgments are also due the authorities of the Smithsonian Institution for placing at the disposal of the author the material in the National Museum, especially Drs. Leonhard Stejneger and Gerrit S. Miller and Mr. Ned Holister for kindnesses and assistance while examining material in the Smithsonian collection.

THE STRUCTURE OF THE PELVIS

1. *The pelvic bones of the Rodentia*

The two types of pelvis which occur among the pocket gophers (family Geomyidae) are well illustrated by *Geomys bursarius* (figs. 4, 5, 6, and 7). It will be noticed that these two pelves differ not only in the presence or absence of the symphysis, but in that a triangular portion of bone lying at the sides of the symphysis in the pelvis of the closed type is absent in that of the open type. These two types of pelvis occur not only in the same species, but also in the same sex, as shown by the females where both types occur. All the males examined possess the symphysis.

No intermediate conditions have been found; the bones either meet to form a symphysis or are widely separated. Very young females have been found possessing a symphysis, while old females without a symphysis are not uncommon. It seems, therefore, that the presence or absence of the symphysis cannot be a matter of the ossification of the bones due to age.

The following table shows the proportion of the open and closed pelves found in the species of the pocket gophers which have been examined. Since the symphysis was present in all of the males examined, only the females have been included in the table.

SPECIES	NUMBER EXAMINED	OPEN TYPE	CLOSED TYPE
<i>Geomys bursarius</i>	23	9	14
<i>Geomys tuza</i>	6	2	4
<i>Geomys hispidus</i>	1	0	1
<i>Geomys</i> (species not known).....	5	1	4
<i>Thomomys talpoides rufescens</i>	3	3	0
<i>Thomomys bottae bottae</i>	3	1	2
<i>Thomomys bottae nigricans</i>	1	0	1
<i>Thomomys bottae pascalis</i>	3	0	3
<i>Thomomys bottae anitae</i>	3	1	2
<i>Thomomys columbianus</i>	1	1	0
<i>Thomomys fulvus intermedius</i>	1	0	1
<i>Thomomys monticola mazama</i>	5	0	5
<i>Thomomys quadratus quadratus</i>	1	0	1

These data are based upon specimens in the flesh which were dissected to determine the condition of the pelvis and the sex of the specimens.

It is obvious that no conclusions as to the percentage of the open and closed types of pelvis in the various species can be drawn without the examination of a much more extended series of material. This table shows, however, that the closed type of pelvis predominates in the females. But the point to be emphasized by a study of the table is, that both the open and the closed types of pelvis occur among the females of nearly all the species. In every species where only one type of pelvis was found, so few specimens were examined that the occurrence of the other type is not precluded.

Aside from these variations with regard to the presence or absence of the symphysis, the pelvis of the pocket gophers present certain characteristics which are constant. The pelvis of *Geomys bursarius* has again been used, in comparison with figures from Huxley ('75). The first two caudal vertebrae are coössified with the sacral vertebrae and with each other forming an extension of the sacrum which arches dorsad in such a way that the second caudal vertebra is on a level with the dorsal margin of the ischium with which it is coössified. For this reason the line designated as the sacral axis (*Sa*) has been drawn through the articulation of the sacrum with the ilium and the

fusion of the second caudal vertebra and the ischium rather than through the centra of the sacral vertebrae which are arched dorsad.

The iliac and sacral axes (fig. 6, *Ia* and *Sa*) are very nearly parallel. This is an advanced step in the attainment of a horizontal pelvis, in which direction Huxley ('75) believed mammals to be tending. In the case of the pocket gophers, the symphysis has moved caudad and is evidently formed by the ischial bones, as shown by the study of immature specimens. The pubic bones are nearly parallel and their ventral margins diverge posteriorly (fig. 6).

This condition is undoubtedly a high specialization. By referring to the figure of the Monotreme pelvis (fig. 2), it will be noticed that this structure in the primitive mammals possesses a symphysis which is very long and is formed by both the ischium and the pubis. In still more primitive vertebrates, amphibians and reptiles, morphologically the symphysis is even longer.

A study of the pelvis of the rodents, in general, contributes instructively to the understanding of specializations such as are found in the pocket gophers. Apodontia of the family Apodontiidae has a relatively short symphysis. Among the 'mole-rats' (Bathyergidae), *Bathyergus miratimus* and *Heterocephalus glaber* were examined in the flesh. The symphysis was found to be very short in both cases, being a rod-like structure very much like that found among the pocket gophers. Since only one specimen of *Bathyergus* and four specimens of *Heterocephalus* were examined, it is not known whether there is any variation of the symphysis in this family. The position of the pelvic axes are also unknown.

The beavers (family Castoridae) possess a long symphysis, and the caudal vertebrae are not coössified as they are in the pocket gophers. The condition in the guinea-pigs (Cavidae) is very similar to that of the beavers and must be considered as a generalized state, where the caudal vertebrae are free and a well-developed symphysis is present. In a morphologic way, the chinchillas (*Chinchillidae*) might also be included with

these families, since the condition of the pelvis is a very generalized one.

Of the Jerboas (*Dipodidae*), the pelvis of *Allactaga longior* was examined. The symphysis is very long, one-sixth the length of the entire pelvis, and the pelvis is so inclined that the iliac axis forms a large angle with the sacral axis. The caudal vertebrae are free, save for a slight coössification of the transverse processes of the first caudal vertebra with the sacrum.

The 'pocket rats' (*Heteromyidae*), although in their systematic relations placed very close to the pocket gophers (*Geomyidae*), have a very well-developed symphysis. In the pocket mouse (*Perognathus flavus*) the symphysis is over one-sixth the total length of the pelvis, and in *Dipodomys deserti* it is about one-fourth the length of the pelvis. No other representatives of this family have been studied.

The porcupines (*Hystricidae*), as found from the study of *Hystrix*, have the symphysis one-fifth the length of the pelvis, and the iliac axis forms a large angle with the sacral axis of the pelvis. The transverse processes of the first caudal vertebra are fused to the sacrum, but it is important to note that the caudal vertebrae are free from the ischium and, because of the pelvic inclination, dorsal to it.

The mice (*Muridae*), with numerous genera with varying habits, present some very interesting conditions. The deer mouse (*Peromyscus*) and mice belonging to several other closely related genera (*Phyllotis*, *Akodon hirtus*) have been examined, and in all cases the symphysis is short and the pelvis is slightly less inclined than it is in some of the other rodents; that is, the pelvis approaches the horizontal position. The sacral and first two caudal vertebrae are coössified along their transverse processes, but the caudal vertebrae are free from the ischium and the pubic bones converge posteriorly.

The meadow mice (voles, subfamily *Microtinae*) illustrate another step in the attainment of a horizontal pelvis and the loss of the symphysis. However, it is only a part of this subfamily which is so greatly modified. The musk rat (*Ondatra*) possesses a symphysis and, although the pelvis is nearly hor-

izontal, the sacrum, along with the caudal vertebrae, is arched dorsally so that the pelvis is far from being a closed box. The red-backed mouse (*Evotomys grapperi*) and the meadow mouse (*Microtus pennsylvanicus*) have no symphysis and the ventral margins of the pubic bones are nearly parallel in the adult meadow mouse (figs. 8 and 9). The pelvis is very nearly horizontal, but the direction of the pubic bones is quite oblique ventrocaudad. In the young meadow mouse the pubic bones converge posteriorly and form the symphysis at their points of contact.

The house mouse (subfamily Murinae) has a short symphysis formed by the point of contact of the two converging pubic bones as in the young meadow mouse. The pelvis is also less horizontal than it is in the meadow mouse (figs. 10 and 11).

Throughout the mouse family (Muridae), with the exception of some of the meadow mice, the estate of the pelvis is quite different from that of the pocket gophers (*Geomyidae*). In the former, the pubic bones converge posteriorly, forming a symphysis at their point of contact (fig. 10), while in the latter the pubic bones diverge posteriorly and the symphysis, when it is present, is formed by the union of bony processes from each side (fig. 4).

The pelvis of the 'Quette vole' (*Myospalax*), the only member of the family Spalacidae which has been studied, was examined in the flesh. The symphysis is very short (one-twenty-fourth of the length of the pelvis) and appears to be formed by the fusion of two long bony processes, such as that prevailing among the pocket gophers. The ventral margins of the pubic bones also suggest the condition among the pocket gophers in that they are quite parallel.

The squirrels (*Sciuridae*), in so far as they have been examined, seem to be quite uniform in the possession of a well-developed symphysis and having the pelvis inclined to form a large angle with the sacrum. They have, therefore, been considered to be a group in which the pelvis is quite generalized and not of special interest in the present consideration.

2. The pelvic bones of the Insectivora

The pelvis of the Insectivora, as described by Lecke ('84), is found to exhibit a series of changes similar to those described above for the rodents. The material which has been examined in the course of this investigation agrees with the descriptions given by him.

The pelvis of the tree shrew (*Tupaia*) is very generalized, the symphysis is long and the angle of inclination formed with the sacral axis is large. *Elephantulus* also has a similar pelvis.

The hedgehogs (family *Erinaceidae*) possess a short symphysis which Lecke ('84) describes as cartilaginous. However this may be, the pubic bones converge posteriorly in all the specimens which have been examined and the pelvis is more like that of the mice than like that of the pocket gophers in that the symphysis is formed at the point of contact between the two converging pubic bones.

The shrews (family *Soricidae*) represent a high specialization with regard to the pelvis, and Lecke ('84) speaks of them, together with the moles (*Talpidae*), as differing from all other mammals in the possession of diverging pubic bones. The 'mole shrew' (*Blarina talpoides*), the 'short-tailed shrew' (*Blarina brevicauda*), *Cryptotis parva*, 'musk shrew' (*Crocidura halconus*), *Pachyura luzoniensis*, and the 'wood shrew' (*Sylvisorex gemmeus*) have been examined and in every case, regardless of sex, the symphysis has been found to be absent. The pubic bones not only diverge posteriorly, but at the anterior end tend to converge until, in the 'mole shrew' (*Blarina talpoides*), they are less than a millimeter apart at the iliopectineal prominence (fig. 12 and 13). There is thus formed a virtual secondary symphysis, but, unlike the original symphysis, it is at the anterior end of the pubic bones and dorsal to the digestive tract and the urino-genital ducts. In all the specimens examined the pelvis is horizontal and very much narrowed, except in the 'musk shrew' (*Crocidura*).

Of the moles (family *Talpidae*) the 'star-nosed mole' (*Condylura cristata*), *Scapanus townsendii*, *Scalopus aquaticus* aquat-

icus, the European mole (*Talpa europea*), *Scaptochirus* sp., *Urotichus* sp., and *Galemys* sp., were examined. In all but *Galemys* the symphysis is absent, and even in this case the pubic bones diverge posteriorly and the symphysis appears as a rod of bone uniting the two sides. It was found that in *Scaptochirus* the pubic bones converge anteriorly and form a complete secondary symphysis dorsal to the viscera. Dobson ('82) found the same condition in *Mogera wogura* (fig. 14). In all cases the pelvis is horizontal (fig. 15) and the transverse processes of the sacral and caudal vertebrae are coössified and the second caudal vertebra is fused to the ischium in all but the star-nosed mole (*Condylura*) in which the transverse processes of the caudal vertebrae are greatly reduced. The pelvis is very long and narrow in all cases.

Solenodon, the only member of the family *Solenodontidae* examined, possesses the symphysis well developed. Among the *Tenrecidae*, *Ericulus setosis*, *Tenrec ecaudatus*, *Hemicentetes semispinosus*, *Ericulus setosus*, and *Oryzorictes hova* have been studied. Here the pubic bones converge posteriorly and the symphysis is formed by the line of contact between the two bones rather than by a rod of bone from the two sides as in the two preceding families. The bones are slightly separated in *Tenrec* and *Ericulus* with a heavy ligament uniting them, but in others the symphysis is present. The inclination of the pelvis is greater than among the moles and the shrews.

The South African golden mole (*Chrysochloris leucorhina* of the family *Chrysochloridae*) was examined in the flesh. It was found to resemble other moles (*Talpidae*) in that the pubic bones diverge posteriorly and are widely separated. The angle of the pelvis was not determined.

Lecke ('84) reports that the ontogeny of the insectivores agrees with the phylogeny, that the pelvis represents a high degree of specialization and that the symphysis appears in the embryo of all the members of the group and is lost later.

3. *The pelvic bones of the marsupial mole*

Attention must be called to the marsupial mole (*Notoryctes*) in this connection (fig. 16). Huxley ('75) considered the marsupial pelvis to be inclined to form a large angle with the sacrum, as is the case among marsupials in general, but, in the case of the marsupial mole, the pelvis is horizontal and is firmly coössified with the sacrum. Furthermore, the symphysis is greatly reduced (fig. 17), which is another departure from the usual condition among the marsupials and an approach to the condition found among other burrowing mammals.

From the above consideration of the pelvis of burrowing mammals it is clear that the pelvis of such a form, regardless of the taxonomic group to which it may belong, may be distinguished from the pelvis of mammals in general by its more horizontal position, its more complete ossification with the vertebral column, and by the great reduction or the entire absence of the symphysis. In the absence of the symphysis, a pubic ligament extends between the two innominate bones.

Among both the rodents and the insectivores there are forms which possess the generalized pelvis with the marked inclination and the long symphysis, while, on the other hand, there are burrowing forms in both groups which possess the typical 'burrowing pelvis.'

4. *A classification of the pelves of burrowing mammals*

The pelves of the burrowing forms may be classified as: the typical burrowing (moles, shrews, pocket gophers, and certain meadow mice), in which the ventral margins of the pubic bones are horizontal and diverging posteriorly, and the symphysis is absent or, when present, formed of a transverse rod of bone (figs. 4 to 9 and 12 to 15); the semi-burrowing (mice in general and certain insectivores), in which the pubic bones are inclined caudoventrad and converge posteriorly to form a symphysis at their points of contact (figs. 10 and 11). The typical burrowing pelvis may be further divided into the narrow type (moles,

shrews, and meadow mice), in which the symphysis is always absent and the pelvis is very narrow, and the broad type (pocket gophers and a few others), in which the symphysis may or may not be present. This classification becomes clearer when placed in synoptic form as follows:

Pelvis of bur- rowing mam- mals	{	<i>Typical burrowing forms</i>	{	<i>Narrow type of pelvis</i>
		1. Ventral margins of pubic bones horizontal and diverging caudad.		1. Symphysis always absent.
		2. Symphysis absent or, if present, formed of a transverse rod of bone.		2. Pelvis narrow.
		3. Includes: moles, shrews, pocket gophers and certain meadow mice.		3. Includes: moles, shrews, and meadow mice.
		<i>Semi-burrowing forms</i>		<i>Broad type of pelvis</i>
		1. Pubic bones inclined caudoventrad, converging posteriorly to form a symphysis at points of contact.		1. Symphysis may or may not be present.
		2. Includes: mice in general and certain Insectivora.		2. If present, in form of a transverse rod.
		3. Figures 10 and 11.		3. Includes: pocket gophers and a few others.

THE STATUS OF THE RECTUS ABDOMINIS MUSCLES

Having considered the variations of the symphysis pubis and having found that in many cases it is absent, a consideration of the muscles which are typically attached to the bones forming the symphysis, the *M. rectus abdominis*, is very instructive. Typically, the *rectus abdominis* muscle is paired, the right and left muscles lying on either side of the midventral line, with the origin on the pubic bones at the symphysis and the insertion on the first two or three ribs near their costal cartilages. The rabbit (fig. 18) illustrates very well the usual condition of these muscles near their points of origin.

When the pelvis is modified by the loss of the symphysis, it is obvious that these muscles must also become modified, for the bone to which they normally attach is absent. It has been

found that the rectus abdominis muscles show modification to be directly correlated with the variations of the symphysis.

In the absence of the symphysis, the usual condition of the rectus abdominis muscles is a crossed one; the rectus muscle of the right side originating on the left pubic bone and the left muscle originating on the right. The two muscles cross a short distance anterior to their origin and proceed to their insertion in the usual manner (fig. 22).

1. *The relations of the rectus abdominis muscles of Rodentia*

Among the pocket gophers (Geomyidae), the rectus abdominis muscles show variations to be correlated directly with those of the pelvis. In the common pocket gopher of the Middle West (*Geomys bursarius*), the muscles spread out into a tough aponeurosis just anterior to the pelvis when the symphysis is absent (fig. 19), while, in case the symphysis is present, the muscle fibers may be traced to their origin on the bones forming the symphysis (fig. 20).

In the one specimen of *Geomys hispidus* which has been examined, the muscles attached to the bones forming the symphysis and are, in the main, uncrossed, although some of the fibres do appear to cross over to the opposite side.

In *Thomomys bottae bottae* the muscles are crossed and attached to the bones forming the symphysis when the symphysis is present (fig. 21) or to the pubic ligament when it is absent. *Thomomys bottae amitae* possesses the same relation of the muscles as the preceding subspecies. In *Thomomys monticola mazama* the muscles are crossed and attached to the pubic ligament. *Thomomys bottae pascalis* and *Thomomys fulvus intermedius* possess crossed muscles which are attached to the bones at the sides of the pelvis in the absence of the symphysis.

The pocket gophers, therefore, possess rectus abdominis muscles which, like the pelvis, are varying in their relations. In some cases the muscles exhibit only the rudiments of a crossed condition, the majority of the fibers composing the right and left muscles originating on the right and left sides, respectively,

and only a few of the fibers of the ventral layers of the muscles crossing over to the opposite side. In other cases the crossed condition is completely developed and the muscles originate on the bones at the sides of the pubic opening. Even the various subspecies of *Thomomys bottae* which have been examined differ as to whether the muscles originate on the bones forming the symphysis—in the absence of the symphysis on the pubic ligament—or on the bones at the sides of the pubic opening (fig. 22).

Throughout the rodent group the tendency of the muscles to become crossed seems to accompany the loss of the symphysis. In the 'mole rats' (*Bathyergidae*) the muscles are only slightly crossed in the few specimens which have been examined. Among the mice (*Muridae*) the muscles are crossed in all the specimens examined which have no symphysis (fig. 23). Even the mice with the short symphysis formed by the converging pubic bones possess crossed rectus abdominis muscles which originate on the posterior border of the ischium (fig. 24).

2. *The relations of the rectus abdominis muscles of Insectivora*

The insectivora present a series of muscle variations as complete as the symphyseal variations themselves. The crossing of the rectus abdominis muscles accompanies the loss of the symphysis in all the cases which have been examined (figs. 25 and 26) except the South African golden mole (*Chrysochloris*), in which case there is a specialized condition of the gracilis muscles, whereby they meet on the midventral line and form a firm union with the rectus abdominis muscles.

Lecke ('92) has studied the modification of the rectus abdominis muscles in the Insectivora, both as to their phylogeny and their ontogeny, and has concluded that their crossing is to be correlated with the loss of the pubic symphysis. He states that the beginning of the crossed condition is found in the 'hedgehogs' (*Erinaceidae*) and the *Gymnura* and that it is mostly highly developed in the moles (*Talpidae*) and the shrews (*Soricidae*). Thus, the burrowing insectivora agree with the

other burrowing mammals in the possession of a pelvis which lacks a symphysis and in the peculiar crossed condition of the rectus abdominis muscles.

THE RELATION OF THE PELVIC ESTATES AND THE HABITS

1. The attainment of a horizontal pelvis

If the evidence offered by the probable ancestors of mammals is accepted, it must be considered that the pelvis was originally confined to the ventral side of the body and served to articulate the hind limbs which pushed the body along over a parallel surface. Upon the attainment of a strictly terrestrial habit, the body was elevated above the substratum and the limbs necessarily functioned for support as well as for propulsion. This necessitated a firm union between the limbs and the framework of the body. This was accomplished by the union of the pelvis and the vertebral column.

Huxley ('75) has followed the series of changes from a condition in which the pelvis was nearly perpendicular to the vertebral column (fig. 1) to a condition in which it is nearly parallel (fig. 3). In the first instance the locomotive force exerted by the limbs must pass along a line extending dorsally through the pelvis (the iliac axis, *Ia*) and then anteriorly, almost at a right angle, along the vertebral column (the sacral axis, *Sa*). In the case of the mammal with the nearly horizontal pelvis, the force exerted passes along a nearly straight line, for the pelvis and the vertebral column are in nearly the same plane (the iliac and sacral axis nearly coincide). The mechanical advantage of such a structure is at once evident in the more direct application of the locomotive force to the framework of the body.

The series of pelvises of burrowing mammals presented in this paper agree in exhibiting the pelvis in every case more nearly parallel to the vertebral column than in any case described by Huxley ('75). A further modification is seen in the coössi-fication of the sacral and caudal vertebrae and, in many cases, the coössi-fication of these posteriorly with the ischium (fig. 6). This provides a still more firm union between the pelvis and the

vertebral column, and the line of locomotive force exerted by the hind limbs passes directly along the vertebral column.

The pocket gophers, moles, and shrews burrow continually in search of their food, and in so doing depend upon their fore limbs for propulsion. A pocket gopher, for example, digs the dirt loose and uses the hind limbs as a brace while so doing. The pelvis, parallel to the vertebral column and firmly co-ossified with it, offers the greatest advantage in directing the locomotive force along a straight line to the anterior part of the body.

The firm union of the pelvis and the vertebral column is well illustrated by the marsupial mole (fig. 16) in which the co-ossification is complete and the structure is widely different from that of other marsupials. Among the moles, *Scaptochirus* and *Mogura* (fig. 14) are also good examples of a rigid pelvis and sacrum. In these forms the iliopectineal prominences of the two sides have united to form a secondary symphysis dorsal to the viscera and just anterior to the articulation of the hind limbs.

Having seen that the pelvis of the mammalian ancestors was perpendicular to the vertebral column and that it became more nearly horizontal when the terrestrial habit was attained and finally that, in the mammals which had the habit of continual burrowing, the pelvis became horizontal, it seems most logical to conclude that these modifications are to be correlated with the increased locomotive force exerted along the line of the pelvis and the vertebral column. The attainment of the horizontal position by the pelvis must be further considered in connection with the loss of the symphysis pubis.

2. *The loss of the symphysis pubis*

As the pelvis attains the horizontal position, the sacrum and the caudal vertebrae become more completely co-ossified and the symphysis moves posteriorly, probably due to the enlarged flexor muscles of the hind limbs which attach to the posterior portion of the pelvis, until it is formed entirely by the ischial

bones. In the ordinary terrestrial habitat where the animals are free-ranging, an optimum condition is evidently reached, in which the force exerted by the hind limbs in propelling the body will be directed along the spinal column through the ilium which is placed at an efficient angle. But there are certain limitations in the attainment of a horizontal position of the pelvis. The symphysis may be brought so near the vertebrae that there will not be sufficient room to allow the passage of the fetus at the time of birth. When the caudal and sacral vertebrae are not coössified, the caudal vertebrae may be elevated in providing room, but in the event of their coössification the bones dorsal to the pelvic opening are rigid and the pubis, obviously, must provide the extra space needed for the passage of the fetus. The horizontal pelvis and the absence of the symphysis are therefore conditions which are interlinked, the latter dependent upon the former.

There are two types of pelvis among the burrowing mammals with regard to width, as has already been stated, and, in the broad pelvis of the pocket gopher, the symphysis sometimes persists, while in the narrow pelvis of the moles and shrews it is always absent. These two types of pelvis are to be correlated with two methods of burrowing.

The pocket gophers have the habit of standing with the hind feet wide apart while digging, so that the dirt may be thrown out between them. The moles, on the other hand, press the dirt to the sides and push it upward with the back—literally crawling between the earth particles.

Seton ('09), in describing the habits of the western pocket gopher, wrote:

“Its method of burrowing, as observed in a captive specimen, is to loosen the earth with the powerful front claws, as it stands with the hind feet advanced and wide spread, then throw it backward between the hind legs, to be further passed on by the hind feet; and when a sufficient pile is ready, the gopher turns round and pushes with its broad head and powerful front feet, forcing the pile ahead of it to the first gallery, up that and out, usually without exposing itself.”

Such action undoubtedly calls for strenuous exertion on the part of the hind legs while loosening the earth and again while the earth is being pushed out of the tunnel. It also requires a broad pelvis in order that the hind legs may be placed well apart. This broad pelvis possesses a large pelvic aperture, allows more room for the passage of the fetus, and hence the loss of the symphysis is less imperative than it would be if the pelvis were narrower.

Seton ('09) describes the star-nosed mole (*Condylura cristata*) as piling up the earth as the pocket gopher does, while working in moist soil, and as tunneling without throwing up the earth in the dryer soil. Anyone who has seen the ridges of earth raised up by moles in a garden will realize that they force their way through the soil in a manner quite different from that of the pocket gopher. And from the length of the tunnels which they are capable of making, even in a single night, one can well believe that a great deal of force is being continually exerted. This crawling between the earth and pushing it aside has a continual tendency to compress the pelvis laterally rather than to broaden it, as the action of the pocket gopher tends to do. Such a narrow pelvis so restricts the pelvic aperture that the loss of the symphysis is imperative to allow the passage of the fetus.

Concerning the shrews, it may be said that their pelvis, so similar to that of the moles, though less highly specialized, is a result of similar habits. The shrews burrow, though they are less strenuous in their operations, confining themselves to the surface of the ground and the litter which covers it. Seton refers to the habits of the short-tailed shrew (*Blarina brevicauda*) as follows:

“The furrowed—sometimes tunneled—track that this animal leaves in the snow is the exact expression of its methods and of its summer life beneath the leaves and rubbish in the woods.”

From this author's notes the following quotation is taken describing an observation:

“Free as a mole in the soil, he drove his sub-leaf gangway where he would, and doubtless lived on the country as he went.

This then was his way of life—this little inter world between the floor and carpet was for him; and thus I learned why he had bartered his eyesight for keener powers of smell and touch.”

Shull ('07) concluded from his observations in the field and laboratory that shrews, like moles, push the earth aside as they burrow. We may therefore class the moles and shrews together with respect to the forces which have developed their narrow horizontal pelves lacking the symphysis.

Brief attention should be given to those forms in which the conditions are less specialized. Some of the meadow mice (*Microtinae*) possess habits similar to those of the shrews which live in the litter over the surface of the ground. Seton ('09) may again be quoted with regard to the habits of some of the mice:

“If we make of our six common mice a ladder to show their chosen elevations, we shall put *Peromyscus arcticus* (the deer mouse) at the top, far above the ground, next *Evotomys* (the red-backed wood-mouse) very near the ground, next *Microtus minor* (the small meadow mouse or vole) a little below, and lowest of all, much of the time below the surface, we find the present subterranean group (the common meadow mouse, *Microtus pennsylvanicus*).”

The modification of the pelves in these mice conforms in a remarkable way to the elevations as given in this account of their habits. The deer mouse (*Peromyscus*) possesses a symphysis and the pubic bones converge posteriorly, while the meadow mouse (*Microtus pennsylvanicus*) is without the symphysis and the ventral margins of the pubic bones are parallel. Other forms with less specialized pelves have not been studied sufficiently to determine all the correlations between their habits and structure. Mice in general live more under cover, where they crowd under and between obstacles, than in the open where their action is free and unimpeded, and their progress, between and under the litter and under the vegetation which covers the ground, may have to do with the approach of the pelvis to the position parallel to the sacrum and the shortening of the symphysis pubis, as in the typical burrowers.

What has been said of the rodents which have a tendency to a reduction of the symphysis may also apply to the insectivores, such as the hedgehogs (Erinaceidae), which have a similar pelvis. Here again there is a correlation between the habits and structure which is parallel to the condition among the rodents, but a more extended study is necessary before making final statements.

3. The persistence of the symphysis in certain cases

There are certain cases which seem, upon superficial examination, to present exceptions to the explanations offered in this paper. Among the squirrel family (Sciuridae), the so-called ground squirrels, woodchucks, and a few others are considered fossorial mammals, and in all of these the symphysis is well developed. However, all of these animals burrow only to make a shelter for themselves. Burrowing is a secondary matter with them and but a very small portion of their time is devoted to it. On the other hand, they are adapted to rapid running, for sitting erect, and for other activities which call for a pelvis very different from that found in pocket gophers and moles which are so restricted to continual burrowing.

The mole rats (Bathyergidae) have many characteristics of well-adapted burrowers. Thomas ('85) considers them to have been specialized for a purely subterranean life. They are said to burrow in the sand and throw up the loose earth in piles without exposing themselves. Two of these forms were examined in the flesh (*Bathyergus* and *Heterocephalus glaber*) and the symphysis was found to be present, but, as explained above, it is very short and appears like a rod reaching between the two sides of the pelvis, a condition very similar to that found in the pocket gophers.

Since the habits and structure are so similar to those of the pocket gophers, the presence of the symphysis may be explained in the same way as that which is sometimes present in the pocket gopher is explained. The pelvis is broad and has allowed

sufficient room for the passage of the fetus at the time of birth, and there has, therefore, been no necessity for its loss.

The pocket gophers evidently represent a stage in which the room within the pelvis is greatly restricted, and the symphysis is in the process of being lost. The pelvis has attained a position nearly parallel to the sacrum and the caudal vertebrae, the sacrum and the ischium are coössified, forming a closed box. At the same time, the pubic bones have diverged caudally, and the symphysis, when it is present, is maintained by a rod of bone which seems to be unnecessary otherwise, for when the symphysis is absent, a portion of the bone on either side is also absent (compare figs. 4 and 6).

Having arrived at this condition, it would seem to be a distinct advantage for the female to lose the symphysis and thus provide for the easier passage of the fetus at the time of birth. No advantage can be seen in the retention of the symphysis for the attachment of the rectus abdominis muscles, since they have been found to accomodate themselves to all of the modifications of the pelvis. There seems to be no reason, therefore, why the female should retain the symphysis.

The males, as far as can be seen, have no call for the loss of the symphysis. On the other hand, they have well-developed levator muscles of the penis attaching to the bones forming the symphysis which, in a mechanical way, would seem to justify its retention.

From this consideration of the pocket gophers, it is concluded that, when the mechanical necessities of propulsion have brought the pelvis to a horizontal position, caused it to fuse with the sacrum, and the pubic bones to diverge posteriorly in such a way that a portion of bone, otherwise unnecessary, must be present in order to maintain a symphysis, other forces appear which are different in the two sexes. Thus, when the symphysis has been greatly reduced and is on the verge of being lost, the step seems to be hastened in the female associated with the necessity of more room in the pelvis and retarded in the male, an association with the necessity of a support for the levator muscles of the penis.

The occurrence of both types of pelvis in the females of the same species cannot be explained unless it is the case of a structure in the course of reduction, the pocket gophers representing a stage in which the first step is being taken, while the mole-rats (*Bathyergidae*) have not yet reached this stage, the moles and shrews having passed on to the completed stage as shown by the absence of the symphysis in both sexes.

4. *The function of the crossed rectus abdominis muscles*

The relations of the rectus abdominis muscles show a general conformity to the condition of the pelvis. Lecke ('92) believed that the crossed conditions of these muscles was for the purpose of compensating the loss of the symphysis, giving support to the viscera. As stated above, he found the beginning of the crossing of the muscles where there was the first tendency toward the loss of the symphysis in the hedgehogs (*Erinaceidae*) and found the crossing of the muscles most complicated in the moles (*Talpidae*) where the symphysis is entirely absent. The South African golden mole (*Chrysochloris*), constituting an exception to this, but in this form the gracilis muscles meet in the midline and, together with the rectus muscles, form an efficient support to the viscera.

The rectus abdominis muscles of the pocket gophers have been shown to vary in their attachments, but the crossing of the muscles has accompanied the loss of the symphysis. In the pocket gopher (*Geomys bursarius*), a strong aponeurosis is formed which affords an efficient support to the viscera. Even though there is a variation in the muscles throughout the family, the provisions for the support of the viscera, by the crossing of the muscles or some other device, is constant. The fact that the muscles are crossed in some of the mice (*Muridae*) in which the symphysis is present would substantiate Lecke's findings, that the muscles have a tendency to cross over in forms in which the symphysis shows the beginnings of reduction.

Here, then, is another parallelism between the Rodentia and the Insectivora which may be referred to the similar necessity

for the support of the viscera in the absence of the symphysis. In both groups there are cases, certain pocket gophers and the South African golden mole, where the symphysis is absent and the rectus abdominis muscles are not crossed, but in both groups provisions for the support of the viscera are constant.

SUMMARY

This paper is based upon a study of structures in animals belonging to different systematic groups but which have similar habits. All of the forms are found to agree in the general structure of the pelvis which is correlated with the habits, and the minor differences in the structure are correlated with specific differences in the habits.

The moles (Talpidae), so well adapted to the burrowing habit, possess horizontal pelvises which are firmly coössified to the vertebral column, the ventral margins of the pubic bones are horizontal and diverge from each other posteriorly, and the symphysis pubis is absent. In some cases (*Scaptochirus* and *Mogura*) a second symphysis is formed dorsal to the viscera, contributing to the greater strength of the pelvis.

The pocket gophers (Geomyidae), also well adapted to the burrowing habit, possess a horizontal pelvis firmly coössified to the vertebral column, and have the ventral margins of the pubic bones horizontal and diverging from each other posteriorly. The symphysis, however, is present in the males and in some of the females, while it is absent in others even of the same species.

There are other rodents (meadow mice, Microtinae) and insectivores (shrews, Soricidae) which possess similar pelvises with various degrees of specialization. These forms live in runways in the debris which covers the ground, and the degree of their specialization is correlated with the depth to which they drive their tunnels.

The marsupial mole (*Notoryctes*) has a habit similar to that of other moles and has departed from the marsupial type of pelvis, as is shown by the firm coössification of the pelvic bones with the vertebral column, the greatly reduced symphysis, and the horizontal pelvis.

The parallelism exhibited by these forms in the attainment of a horizontal pelvis which is firmly fused with the vertebral column and in which the symphysis is greatly reduced or absent is correlated with the mechanical force exerted by the hind limbs in propelling the body during continuous burrowing. This position of the pelvis transmits the locomotive force exerted by the hind limbs along a straight line from the articulation of the limbs to the anterior part of the body. The action of the flexor muscles is much greater than that of the extensor muscles, and consequently their attachments, posterior to the articulation of the hind limbs, have been developed at the expense of the anterior portion of the pelvis. When this condition is attained, it is believed that the symphysis is a hindrance to the passage of the fetus at the time of birth, for the pelvis has become a closed box. The bones are so firmly coössified dorsally and so necessary for the attachment of the large flexor muscles of the hind limb that it follows that the symphysis is lost in order to provide the necessary room for the passage of the fetus.

The retention of the symphysis in the pocket gophers and a few others is attributed to the fact that in these forms the pelvis is very broad, while in the moles, shrews, and the meadow mice the pelvis is so narrow that the elimination of the symphysis has been more imperative.

The broad and narrow pelves are correlated with two methods of digging. The pocket gophers stand with the hind legs wide apart and throw the earth back between them, while the moles, shrews, and the others with the narrow pelves push the earth to the sides and crowd their way through the soil. In the former case the pelvis is constantly drawn out laterally by the action of the muscles, while in the latter case the pelvis is compressed by the action of the hind limbs.

A parallelism is also found in the crossing of the rectus abdominis muscles in the forms in which the symphysis is reduced or absent. This is believed to function as a support for the viscera in the absence of the symphysis. Exception to this crossing of the rectus abdominis muscles have been found among both the rodents and the insectivores which have lost their symphysis,

but in such cases some other means of support for the viscera have been supplied.

This series of structural modifications so well correlated with the habits of the animals may justify one or more of the following conclusions: (1) that the correlation is a coincidence due to chance and that by the same chance other types of pelvis do not exist among the forms studied; (2) that from a number of chance variations in each group of burrowing mammals, the most efficient burrowing structure has been preserved by natural selection; (3) that similar forces acting in a similar way have been factors in causing similar modifications of structure in animals belonging to widely different systematic groups, just as tuberosities develop on bones at the points of attachment of muscles of strenuous action. A combination of the second and third conclusions seems to be in entire harmony with the findings in this study and ascribes a dominant influence to the environment in the production of the parallelisms in the forms studied.

LITERATURE CITED

- BROEK, A. J. P. v. d. 1914 Studien zur Morphologie des Primatenbeckers Morphologisches Jahrbuch. 1914-15; Bd. 49; ppl-118.
- DOBSON, C. E. 1882 A monograph of the Insectivora, systematic and anatomical. Part I. London, 1892.
- HUXLEY, THOMAS HENRY 1875 On the characters of the pelvis in the Mammalia, and the conclusions respecting the origin of the Mammalia which may be based on them. Proceedings of the Royal Society of London, 1878-79, pp. 395-405.
- LECKE, W. 1884 Mammalia, pelvis. Bronn, Klassen und Ordnung des Tierreichs. 1892, Bd. 6, s. 571.
1892 Mammalia, Myology. Bronn, Klassen und Ordnung des Tierreichs, Bd. 6, s. 784.
- OSBORN, HENRY L. 1894 Notes on *Geomys bursarius*. Science, vol. 23, p. 102.
- SETON, ERNEST THOMPSON 1909 Life; Histories of northern animals. New York, 2 vols.
- SHINNER, H. W. 1903 Adaptations to aquatic, arboreal, fossorial, and cursorial habits in mammals. III. Fossorial adaptations. American Naturalist, vol. 37, pp. 819-825.
- SHULL, A. FRANKLIN 1907 Habits of the short-tailed shrew, (*Blarina brevicauda*). American Naturalist, vol. 41, pp. 495-522.
- THOMAS, P. 1885 Proceedings of the Zoological Society of London, 1885, p. 611.
Drawings by Helen Sanborn Chapman, Department of Animal Biology, The University of Minnesota.

PLATES

ABBREVIATIONS

Il., ilium
Pb., pubis
Is., ischium
M.b., marsupial bone
Pbl., pubic ligament

Il.a., iliac axis
Ip.a., iliopectineal axis
Ob.a., obturator axis
S.a., sacral axis

PLATE 1

EXPLANATION OF FIGURES

- 1 Pelvis of crocodile (*Crocodylus*). Lateral view. After Huxley.
- 2 Pelvis of duck bill (*Ornithorhynchus*). Lateral view. After Huxley.
- 3 Pelvis of rabbit (*Lepus*). Lateral view. After Huxley.
- 4 Pelvis of pocket gopher (*Geomys bursarius*), closed type. Ventral view.
- 5 Pelvis of pocket gopher (*Geomys bursarius*), closed type. Lateral view.
- × $1\frac{3}{4}$.
- 6 Pelvis of pocket gopher (*Geomys bursarius*), open type. Ventral view.

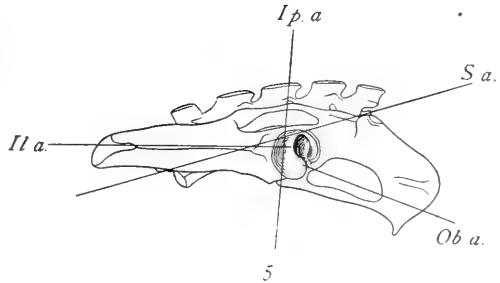
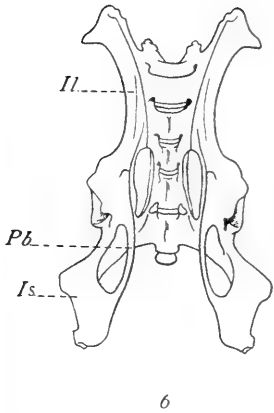
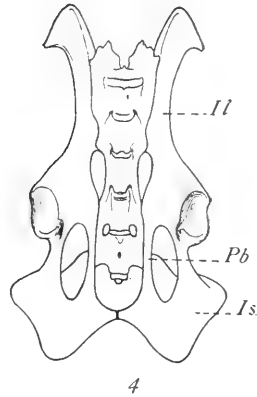
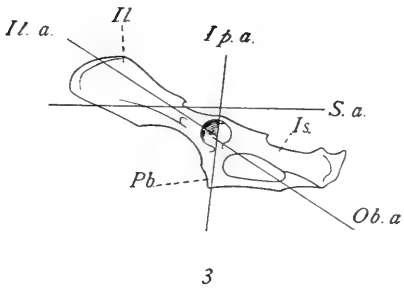
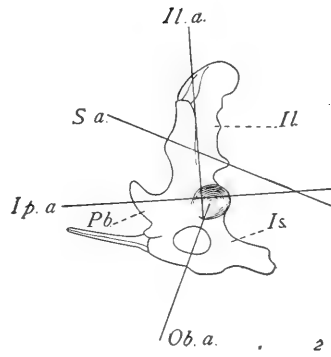
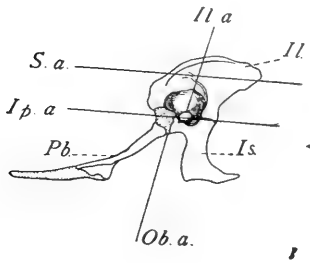
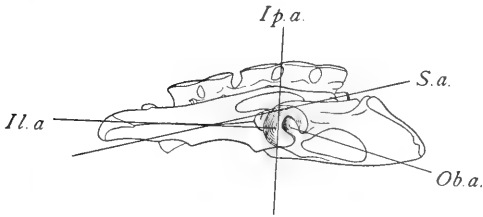


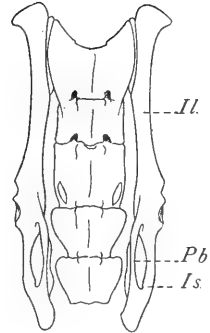
PLATE 2

EXPLANATION OF FIGURES

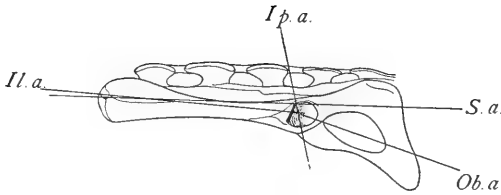
- 7 Pelvis of pocket gopher (*Geomys bursarius*), open type. Lateral view
 $\times 1\frac{3}{4}$.
- 8 Pelvis of meadow mouse (*Microtus pennsylvanicus*). Ventral view. $\times 3$.
- 9 Pelvis of meadow mouse (*Microtus pennsylvanicus*). Lateral view. $\times 3$.
- 10 Pelvis of house mouse (*Mus musculus*). Ventral view. $\times 4$.
- 11 Pelvis of house mouse (*Mus musculus*). Lateral view. $\times 4$.
- 12 Pelvis of shrew (*Sorex* sp.). Ventral view. $\times 5\frac{1}{2}$.



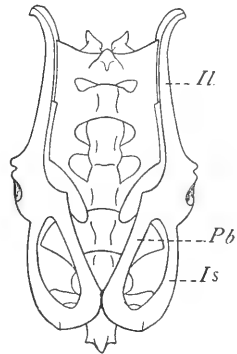
7



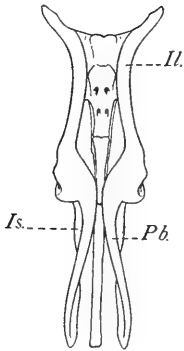
8



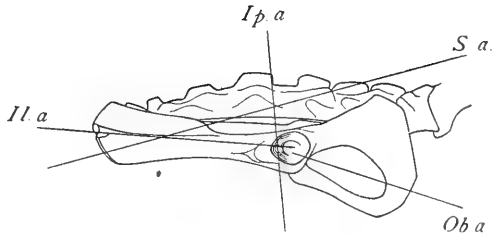
9



10



12

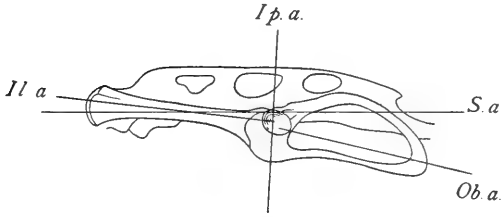


11

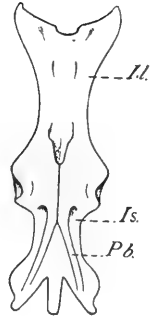
PLATE 3

EXPLANATION OF FIGURES

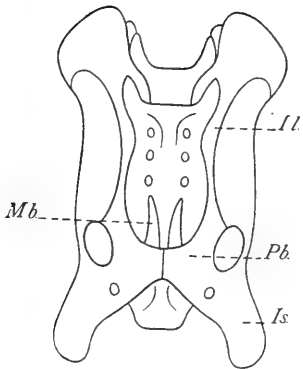
- 13 Pelvis of shrew (*Sorex* sp.). Lateral view. $\times 5\frac{1}{2}$.
- 14 Pelvis of *Mogera wogura*. Ventral view. After Dobson. $\times 2\frac{1}{2}$.
- 15 Pelvis of star-nosed mole (*Condylura cristata*). Lateral view. $\times 2$.
- 16 Pelvis of Marsupial mole (*Notoryctes* sp.). Ventral view. $\times 3$.
- 17 Pelvis of Marsupial mole (*Notoryctes* sp.). Lateral view. $\times 3$.



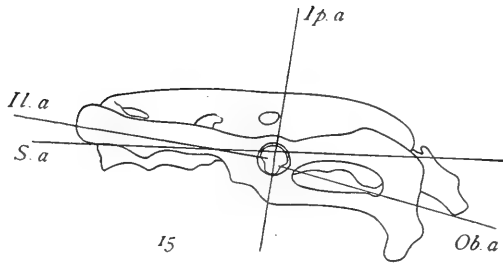
13



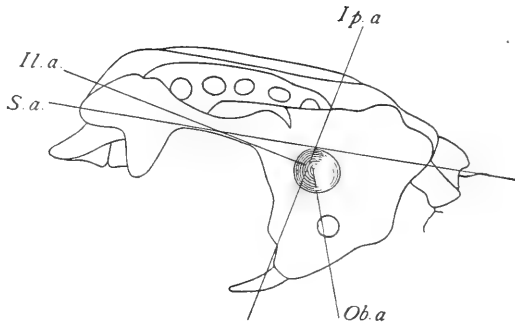
14



16



15



17

PLATE 4

EXPLANATION OF FIGURES

- 18 Rectus abdominis muscles of rabbit (*Lepus*). After Huxley.
- 19 Rectus abdominis muscles of pocket gopher (*Geomys bursarius*), open type of pelvis.
- 20 Rectus abdominis muscles of pocket gopher (*Geomys bursarius*), closed type of pelvis.
- 21 Rectus abdominis muscles of Western pocket gopher (*Thomomys bottae*), closed type of pelvis.

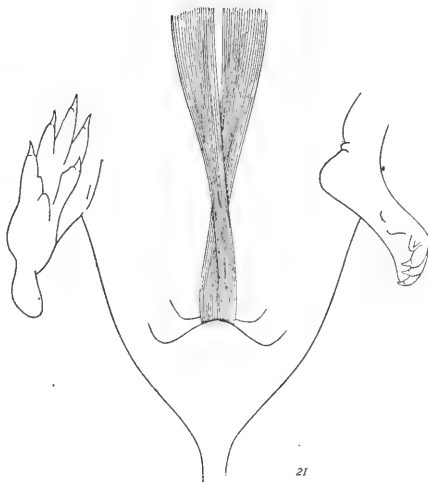
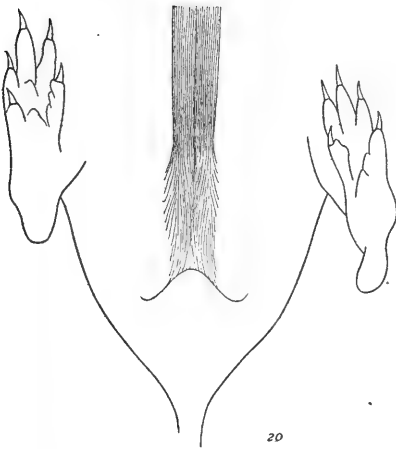
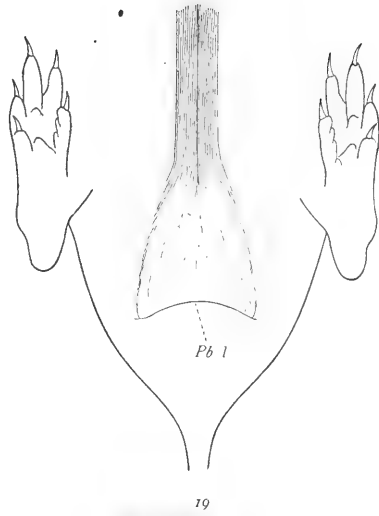
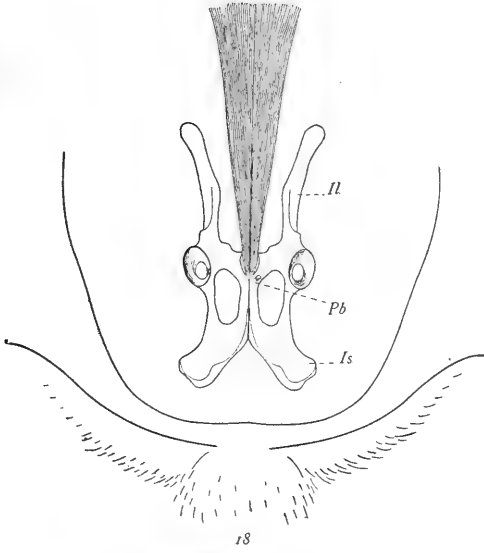
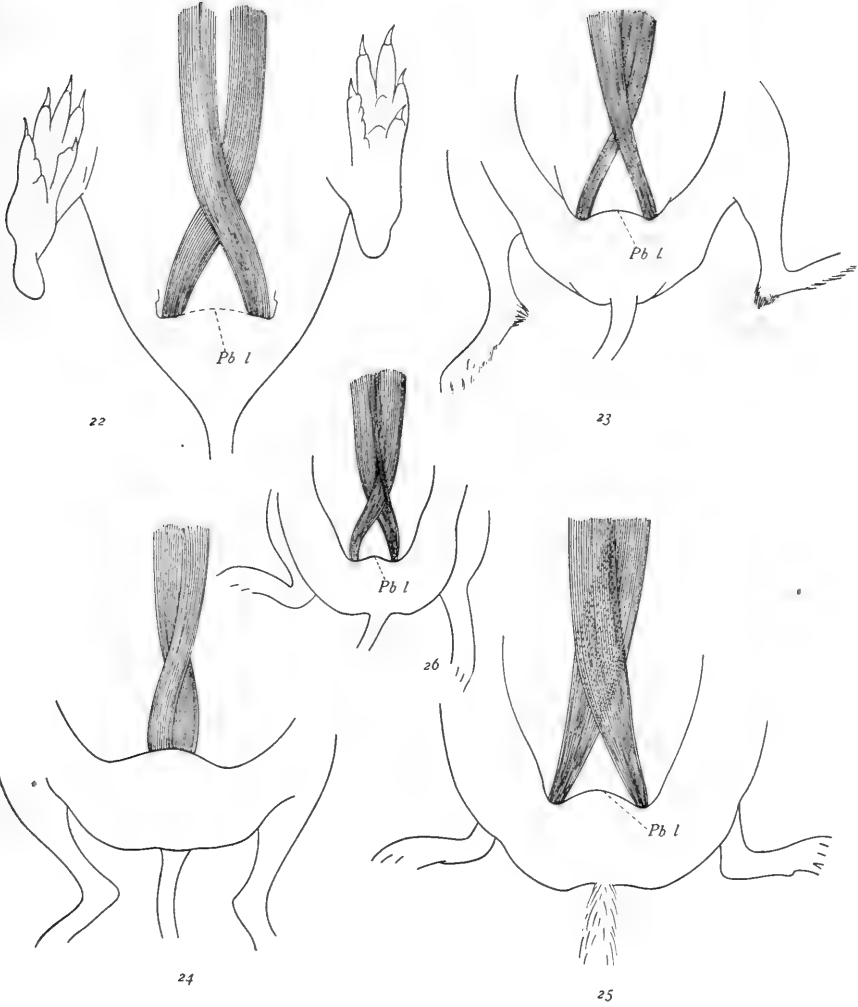


PLATE 5

EXPLANATION OF FIGURES

- 22 Rectus abdominis muscles of Western pocket gopher (*Thomomys bottae pascalis*), open type of pelvis.
- 23 Rectus abdominis muscles of meadow mouse (*Microtus pennsylvanicus*).
- 24 Rectus abdominis muscles of house mouse (*Mus musculus*).
- 25 Rectus abdominis muscles of star-nosed mole (*Condylura cristata*).
- 26 Rectus abdominis muscles of shrew (*Sorex* sp.).





THE POSTNATAL DEVELOPMENT OF THE SUPRA- RENAL GLAND—AND THE EFFECTS OF INANITION UPON ITS GROWTH AND STRUCTURE IN THE AL- BINO RAT

C. M. JACKSON

Institute of Anatomy, University of Minnesota, Minneapolis

TEN FIGURES

CONTENTS

Material and methods.....	222
Volumes of suprarenal cortex and medulla.....	228
Volumes of suprarenal parenchyma and stroma.....	232
Size of parenchyma cells and nuclei.....	233
Cell division—frequency of mitosis.....	239
Histological changes in the suprarenal gland.....	244
1. Normal postnatal histogenesis.....	244
2. Changes in young rats stunted by underfeeding.....	261
3. Changes in rats refed after stunting by underfeeding.....	263
4. Changes in adult rats after acute or chronic inanition.....	264
Morphogenesis of the suprarenal gland.....	269
Summary.....	270
Literature cited.....	277

In a previous paper (Jackson, '13) the relative growth curve of the suprarenal gland in the albino rat was described, including the characteristic difference in weight according to sex. In later papers (Jackson, '15 a, '15 b) the changes in the weights of the suprarenal in underfed young rats, and in adult rats during acute and chronic inanition were considered. The object of the present study is to extend these observations so as to include the volumetric analysis and histological structure of the suprarenal cortex and medulla during normal postnatal development and as affected by inanition and by refeeding.

This paper forms the fifth of a series of studies upon the effects of inanition in the albino rat, the investigation being supported by a special grant from the research funds of the Graduate School of the University of Minnesota.

MATERIAL AND METHODS

The material used included the suprarenals from 108 albino rats (*Mus norvegicus albinus*), obtained partly in connection with my previous studies ('15 a and '15 b), partly, from material collected by Hoskins ('16) and Stewart ('16), and partly from new material. The 108 rats include 52 normal (control) rats of both sexes, varying from new-born to about one year of age; 16 young rats held nearly at maintenance (constant body weight) or severely stunted by underfeeding for various periods; 10 rats refed after such underfeeding and 1 refed after acute inanition (adult); 13 adult rats subjected to acute inanition; and 6 subjected to chronic inanition (table 1).

The diet in all cases was whole-wheat (graham) bread soaked in whole milk, the amount being reduced during the maintenance and chronic inanition experiments and cut off entirely in acute inanition. Water ad libitum was supplied in all cases. In the chronic-inanition experiments the amount of food was gradually reduced through a period of about five weeks. The percentage losses and final body weights are given in tables 1 D and 1 E.

In order to keep the animals alive during the longer experimental periods, especially in the case of the young rats underfed for long periods, it was found necessary to keep them in a warm room. The cages were provided with wire-net bottoms to prevent the rats from eating their feces.

The general data for the individual rats used are shown in table 1. In the first column the letters indicate the series to which the rats belong. The number preceding the decimal point is the litter number and the number following designates the individual rat. In several of the rats used for adult acute- and chronic-inanition tests, however, the litter records were not available. The sex, age (where known), nose-anus length, gross body weight (in some cases also net, without intestinal contents), and the fresh weight of both suprarenals are recorded in the table.

In the subsequent tables 2, 3, and 5, the data are usually grouped for economy of space. The individual data will be filed in The Wistar Institute of Anatomy, Philadelphia, where they may be consulted by those interested.

The suprarenals were removed immediately after the animals had been killed. The rats were killed by chloroform, excepting those used for the chromaffin tests (series F), which were killed by cutting their throats. One rat (F 6.2) died from acute inanition.

In most cases the glands were fixed in Zenker's fluid, embedded in paraffin, cut in serial sections ($3\ \mu$ to $5\ \mu$), and stained with haematoxylin and eosin. In a few cases other fixatives (formalin, Zenker-formol, Flemming's) and other stains (iron-haematoxylin, Mallory's anilin-blue connective-tissue stain, etc.) were employed. In the series F and a few others one gland was immediately placed in Müller's fluid for one week, then sectioned with the freezing microtome. The sections were mounted in glycerin for the study of the chromaffin reaction. The other gland was first fixed one or two hours in 10 per cent aqueous formalin solution (neutralized with lithium carbonate). In a few cases the glands were left in 5 per cent formalin from eighteen to twenty-four hours, without apparent effect upon the liposomes. Bell ('10), however, found in some cases a partial disappearance of the liposomes in muscle and epithelium after even a brief exposure to formalin. The formalin-hardened gland was cut with the freezing microtome into sections (at $10\ \mu$).

Some of these sections were placed for about twenty hours in 1 per cent aqueous osmic acid solution, and the others stained with scarlet red and mounted in glycerin for special study of the lipoids and fat. Herxheimer's formula (saturated solution of scarlet red in 70 per cent alcohol containing 2 per cent of sodium hydroxide) was used. The sections were first placed in 60 per cent alcohol (one minute), then in Herxheimer's fluid (three minutes), then rinsed in 60 per cent alcohol (one-half minute), washed in distilled water a few minutes, and mounted in glycerin.

Frozen sections were also studied fresh, mounted in normal salt solution, and also treated with 1 per cent potassium hydroxide, 1 per cent acetic acid, alcohol, etc. The frozen sections were cut by means of a Spencer automatic freezing microtome, using liquid carbon dioxide for refrigeration.

The method used for the volumetric determinations is a modification of Hammar's paper method, as described in my work on the hypophysis (Jackson, '17). The outlines of the magnified sections are projected and drawn upon 'American linen record' paper (sheets 18 x 23 inches, 36 lbs. per ream) by means of an Edinger projection apparatus. Four samples, each 5 cm. square, are weighed from each sheet, and the area corresponding to each gram of paper determined. The structures whose volume is to be determined are then cut out and weighed, and the corresponding area calculated. This magnified area is then reduced to actual area (dividing by the square of the magnification). Multiplying by the actual thickness of the sections now gives the actual volume of the parts concerned. For determining the volumes of cortex and medulla (table 2) it was not considered necessary to draw every section. Enough were taken to make a total of at least fifty drawings for each suprarenal. This required every fourth section for some of the smaller glands, but fewer for the larger glands, some of the largest requiring only every sixteenth section. A magnification of 75 diameters was used for the cortex and medulla.

As was found in the hypophysis, the volumes obtained (in cubic centimeters) are usually considerably less than half the corresponding fresh weight of the gland (in grams). The difference is due: 1) to the density of the gland; 2) to the fibrous capsule and attached extracapsular tissue, weighed but not measured (forming about 11 per cent of the gland in the dog, according to Flint's data), and 3) to the great shrinkage due to the process of fixation, dehydration, and embedding in paraffin.

For determining the relative volumes of parenchyma and stroma (including blood-vessels), a higher magnification was required. A Leitz ocular no. 4 and objective no. 7a were used, with large Spencer camera lucida, giving at table level a magnification of about 500 diameters. As it is impracticable to measure the entire gland in this way, typical areas are selected and drawn from the various regions of the cortex and medulla, outlining merely the areas of parenchyma and vascular stroma in a given plane. These areas are then cut out of the paper and weighed. Since

it is desired merely to determine the relative proportions of parenchyma versus stroma, it is necessary merely to compare the weights of the paper representing the corresponding areas. In this way the results summarized in table 3 were obtained. These results are of course merely approximate, based upon the assumption that the areas selected represent the typical or average condition for the entire gland.

For the volumetric determinations on parenchyma cells and nuclei (table 4) a similar plan was used. In this case a Zeiss 2-mm. apochromatic objective with ocular no. 4 was used, giving at table level a magnification of about 1600 diameters. Typical fields were selected and drawn with the camera lucida, outlining parenchyma cells and nuclei (stroma and vessels omitted) in the various zones of the cortex and medulla. No change of focus is permissible while the drawing is being made, since the volumetric calculations are based upon the assumption that it represents a true optical plane.

The further procedure is as follows: The paper representing the areas drawn from the various zones is weighed (to the milligram). Then the nuclei are cut out with a sharp-pointed scalpel, the paper resting upon a wax plate. The paper representing the nuclear areas and the remainder (cytoplasm) are then weighed separately. From the weight of the nuclear areas, the magnified area in square centimeters is calculated. This divided by the square of the magnification and by the number of nuclei involved gives the average actual area per nucleus. If we assume that the nuclei are spherical and not greatly different in size, the average area per nucleus in a given optical plane should, according to the rules of solid geometry, represent two-thirds the area of the corresponding great circle.

This result is derived as follows: The volume of any sphere equals two-thirds the volume of the circumscribed cylinder. The diameter of the sphere equals the height of this circumscribed cylinder, and the area of the great circle of the sphere equals the cross-sectional area of the cylinder. The volume of the cylinder is obtained by the product of its cross-sectional area \times height of cylinder. The volume of the sphere may be obtained by the

product of the average cross-sectional area (i.e., the average of a series of parallel planes, perpendicular to any diameter) of the sphere \times the diameter of the sphere. Since the height of the cylinder equals the diameter of the sphere, the average cross-sectional area of the sphere must equal two-thirds of the cross-sectional area of the cylinder (or of the great circle area of the sphere), since the corresponding products (the volumes of the sphere and the circumscribed cylinder) bear that ratio.

Hence in an optical plane, as seen in a histological section, assuming the nuclei to be approximately spherical and similar in size, the observed average nuclear area should correspond approximately to two-thirds the corresponding great circle area of the nucleus. From the great circle area ($= \pi r^2$), the average nuclear diameter ($= 2 r$) and volume ($= 4/3 \pi r^3$) are readily calculated.

The average nuclear dimensions being known, the average total cell dimensions may also be calculated, assuming that the cytoplasm surrounds the nucleus in a uniform layer, making the whole cell approximately spherical.

Another relation, which may not appear evident at first glance, is that in the optical plane of any section the sum total of the nuclear area bears the same ratio to the sum total of the cell areas as does the volume of the average nucleus to the volume of the corresponding average cell. This relation is proved as follows, assuming the cells to be fairly uniform: The volume of any given region is made up of its parenchyma cells (stroma being excluded). The ratio of this volume, the total cell volume, to the total nuclear volume is the same as that of the average cell volume to the average nuclear volume (since the average volume is derived from the total by dividing by the total number of cells (or nuclei) in the region). But the total cell volume and total nuclear volume for a region may be derived in another way. The region may be considered as made up of parallel sections of minimal thickness, as found in histological preparations. In each section, the total cell volume is equal to the total area of the region measured (stroma excluded) \times the thickness of the section; and the total nuclear volume likewise corresponds to the

sum total of the nuclear areas \times the thickness of the section. The total cell and nuclear volumes for the region would be obtained by multiplying by the total number of sections. Thus it is evident that the ratio of total cell volume to total nuclear volume of a region (or of average cell volume to average nuclear volume) is the same as the ratio of the total area to the total nuclear area in a typical optical plane. The total area of a section is represented by the total paper weight for that section and the total nuclear area by the paper weight of the nuclear areas. Moreover, the ratio of the average cell diameter to the corresponding nuclear diameter is the same as the ratio of the cube roots of the average cell volume and nuclear volume. Therefore, for a given region, assuming that the cells are fairly uniform spheres, the average

$$\text{Cell diameter} = \text{Nuclear diameter} \times \sqrt[3]{\frac{\text{Total paper weight}}{\text{weight of nuclear areas}}}$$

From the cell diameter, the cell volume is readily obtained, and the volume of cytoplasm in this average cell will be the difference between the cell volume and the nuclear volume. The results are given in table 4. Errors in computation¹ may be checked by comparing the ratio of nuclear volume and cell volume with the corresponding ratio of the cube of the nuclear diameter and the cube of the cell diameter. Crelle's Rechentafeln were found helpful in the calculations.

The mitoses were counted in each case in an entire section through the middle of the gland. A 2-mm. Zeiss apochromatic objective and a mechanical stage were used. The results are summarized in table 5.

¹ In my previous paper on the hypophysis (Jackson, '17) an unfortunate error was made in the calculation of the parenchyma cell diameters listed in the last column of table 3, p. 333. Instead of 10.1, 11.9, 13.6, 9.7, 10.2, 10.0, 10.8, and 11.0, this column should read: 8.4, 9.3, 10.4, 7.8, 8.0, 8.1, 8.6, and 8.7. A corresponding correction is necessary for cell diameters on the lower part of page 335, and in the Summary, paragraph 7, page 355, of the same paper. A similar correction for the diameter of the parenchyma cells should be made in the abstract of that paper, published in the *Anatomical Record*, vol. 11, p. 370, lines 5 to 8.

VOLUMES OF SUPRARENAL CORTEX AND MEDULLA

Volumetric data for the relative volumes of the suprarenal cortex and medulla are given in table 2. These will be considered successively, 1) during normal postnatal development; 2) in young rats stunted by underfeeding; 3) in such rats refed after stunting, and 4) in adult rats subjected to acute or chronic inanition.

1. During normal postnatal development

The data summarized in table 2 A include the relative volumes of cortex and medulla in groups at various ages, beginning at seven days. (In the new-born the cortex and medulla are still intermingled and were not measured.) If the data for the absolute volumes (not given in the table) are considered, it appears that both cortex and medulla continue to grow from birth to one year of age. Although there are marked individual variations, it is on the whole clearly evident that the cortex and medulla grow at different rates, so that their relative sizes change. During the second and third weeks, the cortex grows more rapidly, increasing from 75 or 80 per cent to about 90 per cent of the entire gland, by volume. It apparently continues to increase relatively, averaging about 93 per cent at ten weeks of age. In older rats, there are marked individual variations, but the cortex appears to decrease slightly to 90 or 91 per cent in average relative volume.

The medulla increases more slowly in absolute size, so that its relative volume decreases (inversely with the cortex). The medulla is relatively small in the new-born, though difficult to measure on account of the intermingled cortex. In connection with the process of confluence, the medulla expands rapidly, being relatively largest at one week, forming 20 to 25 per cent of the total volume. It decreases to about 15 per cent at two weeks, 10 per cent at three weeks, and to about 7 per cent at ten weeks, increasing again slightly to an average of 9 or 10 per cent of the entire suprarenal in the older rats. In a few cases in which the whole suprarenal gland is relatively small, the medulla was found

relatively large (as in the female St 5.1 at 56 days). In very large glands, on the contrary, the medulla is usually relatively small. This suggests that the variability in the size of the suprarenal may be due mostly to variability in the volume of the cortex.

On account of the known sexual difference in the weight of the suprarenals (which become relatively heavier in the female from the age of about six weeks),² the question naturally arises concerning the relative sizes of cortex and medulla in the two sexes. As shown by table 2 A, however, the present data grouped by sexes reveal no constant or important differences in this respect. A study of the individual data likewise reveals no constant sexual differences in the absolute or relative sizes of the suprarenal cortex and medulla. It is possible that a larger number of observations would reveal differences obscured by large individual variations (or experimental error) in the present small series of data. Provisionally, however, on the basis of the present data, I would conclude that the relatively larger suprarenal gland in the female is due to an increase in both cortex and medulla, with no important change in their relative sizes as compared with those of the smaller gland in the male. Thus the conditions in the suprarenal would appear to be different from those in the hypophysis, where the relatively larger gland in the female is apparently due to a larger pars anterior (Jackson, '17).

In one female (J 1.7) which had just given birth to a litter the suprarenal glands were not hypertrophied (table 1), being on the contrary below the normal weight for corresponding body weight or length. The volumetric relations of cortex and medulla appear normal, the latter forming 7.2 per cent of the total vol-

² Elliott and Tuckett ('06) noted in several cases that in the rat, cat, guinea-pig, and rabbit of reproductive age the suprarenal glands were larger in the female. They considered this a temporary hypertrophy, however, concluding that "Gestation accelerates the growth of the gland, so that for a time that of the female outstrips the male. In such increase the cortex is concerned, but there is undoubtedly growth of the medulla also. Our analyses are too few to trace the changes satisfactorily." That the larger suprarenal in the female rat is a regular sexual characteristic, independent of gestation, was first established by Hatai ('13) and Jackson ('13).

ume. Hypertrophy of the suprarenal gland (especially of the cortex) during pregnancy has been described by various authors.

Elliott and Tuckett ('06) found great variation in the relative volumes of cortex and medulla in the suprarenal gland of adult animals. Thus the medulla varies from 1.6 per cent of the gland in the guinea-pig to 50 per cent in the fowl. In the adult rat the medulla forms about 5 per cent of the gland. In very young mammals the medulla is relatively larger, the growth of the suprarenal after early youth being apparently in the cortex alone. They also noted a relatively larger suprarenal in the female, ascribing this to pregnancy.³

Bager ('17) found the suprarenal glands of the rabbit relatively heavier in the female after the age of puberty.

A relative increase in the amount of cortex, with corresponding decrease in the relative size of the medulla in the suprarenal gland according to age, was previously noted by Canalis ('87) in the rabbit, and by Hultgren and Anderson ('99) in various mammals, especially cat and rabbit. Soulié ('03), however, describes the suprarenal medulla as relatively small in the human fetus, forming hardly 10 per cent in the new-born, the proportion being a little higher in the adult and relatively greater in other mammals. Scheel ('08), Starkel and Wegrzynowski ('10), Thomas ('11), and others describe a relative increase in the post-natal human medulla (which will be considered later under 'Morphogenesis of the suprarenal gland'). Gottschau ('83), by comparison of the relative widths of cortex and medulla in sections of the suprarenal, concluded that there is great variability in different mammals. Pfaundler ('92) found the ratio of cortex to medulla in the suprarenal of the horse to be variable, the average being about 4:1, which is nearly in agreement with the data of Flint ('00) for the dog. In the rabbit, Bager ('17) found the medulla to decrease in relative size from 20.8 per cent of the gland in the new-born to 1.84 per cent at one year. No difference was noted according to sex in the ratio of cortex and medulla.

On the whole, therefore, the evidence would appear to support the conclusion that in general the suprarenal medulla in mammals

³ See footnote on page 229.

forms but a small part of the gland. It usually appears relatively large in the new-born, however, decreasing later in relative size on account of more rapid growth in the cortex. In the rat, although the suprarenal becomes relatively larger in the female, there is apparently no constant sexual difference in the relative size of cortex and medulla. The whole question of the changes in relative size of cortex and medulla according to age and sex in various species deserves a more careful and extensive study.

2. In young rats stunted by underfeeding

As previously shown (Jackson, '15 b), in young rats held at maintenance (nearly constant body weight) by underfeeding for various periods there is a definite tendency to increase in the weight of the suprarenal gland, especially in the female. The observations in table 2 B indicate no marked change in the relative volumes of the cortex and medulla as a result of such experiments, however. While during normal growth up to ten weeks the suprarenal medulla tends to lag behind (cortex becoming relatively larger), in the maintenance experiments it apparently remains nearly constant in relative size. Lewis and Pappenheimer ('16) likewise found no constant change in the relative size of cortex and medulla in the suprarenal glands of children emaciated through malnutrition.

3. In rats refed after stunting

As shown by table 2 B, in rats refed one or two weeks (after being held at maintenance from three to twelve weeks of age), the relative sizes of the suprarenal cortex and medulla appear nearly normal. In a permanently stunted female (St 33.120, refed to one year after maintenance from three to twenty-one weeks of age), the medulla appears relatively large, while in a male (S 33.118) similarly refed the ratio appears nearly normal. Stewart ('16) found that in rats refed four weeks or less, after maintenance from three to twelve weeks of age, the suprarenals seem to lag behind somewhat in weight, although they appeared normal in such rats refed to the age of one year.

4. In adult rats during acute or chronic inanition

In adult rats subjected to acute inanition seven to nine days, with loss of about one-third in body weight, the relative volumes of cortex and medulla remain nearly normal (table 2 B), indicating that the loss (if any) has been nearly proportionately distributed. In rats after chronic inanition due to gradual decrease of food for five weeks, with loss of about 36 per cent in body weight, the medulla averages a little higher. This may indicate a relatively greater loss of the cortex, but the difference is small and of doubtful significance.

VOLUMES OF SUPRARENAL PARENCHYMA AND STROMA

The averages (and ranges) of the percentages by volume formed by the stroma, including the vessels, are summarized by groups in table 3. The variations are due chiefly to the differences in blood content. On account of the great variability shown, no conclusions can be drawn with certainty. Neither the groups nor the individual data reveal any marked change in the normal vascularity of the gland from new-born to adult. There is in general, however, an increased vascularity evident upon passing from the outer zone of the cortex toward the medulla, with the exception of a decrease in the outer part of the middle zone. More than one-fourth of the medulla by volume is composed of stroma and included vessels.

In the young rats held at maintenance the vascular stroma appears moderately decreased in relative volume in the outer and middle zones and greatly increased in the inner zone, with but little change in the medulla. The hyperemia of the inner zone is usually strikingly apparent in the sections under the microscope (low power).

In the rats refed one or two weeks after maintenance experiments, there appears in general a reduction in the relative volume of the vascular stroma in the most hyperemic regions—medulla and inner cortical zones—and an increase in the vascular stroma of the middle zone. The outer cortical zone, however, appears even more anemic than before.

In adult rats subjected to either acute or chronic inanition, there appears to be an increased vascularity of the middle and inner cortical zones, with a decreased vascularity in the medulla. Marked hyperemia of the suprarenal cortex has also been noted as a result of inanition in the guinea-pig (Martinotti, '92; Rondoni and Montagnani, '15).

The most constant effect of inanition upon the suprarenal stroma is therefore an increased hyperemia of the inner cortical zone. The changes in the vascularity of the remainder of the gland appear variable in different individuals and according to the type of inanition. The variations are due chiefly to the amount of blood remaining in the vessels, which of course may vary greatly under different circumstances. Moreover, the amount retained in the vessels after death may be quite different from that during life. In pathological histology, however, it is customary to judge as to relative anemia or hyperemia by the distention of the vessels in prepared sections of organs. So an attempt to measure the amount appears justified, even though the results are only roughly approximate.

SIZE OF PARENCHYMA CELLS AND NUCLEI

The average sizes of the parenchyma cells and nuclei were not determined by direct measurement, but were calculated by the method previously explained. The data are given in table 4. The cell and nuclear dimensions will be considered, 1) in normal postnatal development; 2) in young rats stunted by underfeeding; 3) in such rats refed after stunting, and 4) in adult rats with acute or chronic inanition.

1. During normal postnatal development

As noted by Canalis ('87) in the rabbit, there is in the rat a general increase in the size of the cells from birth to maturity (table 4). In average diameter, the cells of the outer cortical zone (zona glomerulosa) increase gradually from about 7μ at birth to about 8μ at three weeks and to about 9μ from ten weeks on.

The middle zone (*zona fasciculata*) cells during the first week average about 9μ in diameter, being of approximately the same size throughout the zone. In the outer portion of this zone they increase to about 9.6μ at two and three weeks, increasing to 14 or 15μ from ten weeks on. The cells in the inner portion of the middle zone appear slightly larger (10.3 – 10.7μ) at two and three weeks, but lag behind thereafter, reaching about 12μ in diameter from ten weeks on.

The inner zone (*zona reticularis*) cells during the first three weeks are similar in size to those in the adjacent outer part of the middle zone. Later, however, they lag behind, and at ten weeks are about equal in average diameter to those of the outer zone (8 – 10μ). In the adult rat, they are in average size the smallest cells of the suprarenal cortex. They do not vary greatly from 9μ in average diameter throughout postnatal life. The small size of the cells is associated with the atrophic condition of the inner zone, which undergoes continual absorption (as will be discussed later).

The cells of the suprarenal medulla increase steadily from an average diameter of about 8μ at birth to 10μ or 11μ during the second and third weeks. At ten weeks, they average about 13μ , and in the adult reach an average diameter of nearly 16μ .

The nuclear growth of the suprarenal parenchyma cells is in general less rapid than that of the cytoplasm, so that with the increasing volume of the cell the nucleus decreases in relative size, forming a steadily decreasing percentage of the average cell volume (table 4). The outer zone nuclei apparently decrease in average diameter from 5.4μ at birth to 4.6μ at one week. They increase to about 5.5μ at three weeks, thereafter remaining nearly constant in absolute size. In relative volume, however, they decrease from 44 per cent of the average cell volume in the new-born to about 23 per cent in the adult rat.

The middle-zone nuclei likewise appear to decrease slightly during the first two weeks (from average diameter of 6.2μ to 5.6μ), but increase to 6.2μ at three weeks. Thereafter the nuclei of the inner part of the zone (like the corresponding cells) increase but little in average diameter, while those of the outer part of

the middle zone increase to an average diameter of about 7μ . In relative volume, the nuclei of the outer part of the zone decrease from about 33 per cent of the average cell volume at birth to about 10 per cent in the adult, while the nuclei of the inner part of the zone decrease from about 28 per cent to about 15 per cent in the adult.

The nuclei of the inner cortical zone apparently decrease in average diameter from 6.1μ in the new-born to from 5 to 5.8μ thereafter. In relative volume, they decrease from about 28 per cent of the average cell volume at birth to about 20 per cent thereafter.

The nuclei of the medulla parenchyma cells increase in average diameter from about 6μ at birth to about 6.7μ at three weeks, 7.2μ at ten weeks, and 7.3μ in the adult. In relative volume, they decrease from about 46 per cent of the average cell volume in the new-born to less than 10 per cent in the adult.

Da Costa ('13), in the suprarenal gland of the rat (*Mus decumanus*), gives the following measurements for the nuclei: outer cortical zone, $4 \times 6\mu$; middle zone, spherical, 6μ ; inner zone, spherical, smaller. My data (previously cited) indicate a somewhat larger average size for the nuclei of the middle zone.

Canalis ('87) noted that, in general, the suprarenal parenchyma cells of both cortex and medulla are larger in the adult than in the young (rabbit, dog, guinea-pig). In the mouse Inaba ('91) found the nuclei of medulla cells increasing in diameter from 5.2μ in the new-born to 6μ at twenty-nine days and later. The cortical nuclei (near the corticomedullary boundary) showed a decrease in diameter from an average of 6.5μ in the new-born to 5μ at twenty-nine days and later. This would indicate that there is an atrophic process of the inner cortical zone in the mouse corresponding to that found in the rat and other forms (to be discussed later).

Mann ('16) noted a seasonal change in the suprarenal cells (both cortex and medulla) of the gopher, which increase in size in the spring, with decrease later and during hibernation.

2. In young rats stunted by underfeeding

Table 4 includes the individual results in four young rats held at maintenance from three weeks to ten or twelve weeks, and one in which the experiment continued to 139 days. Since in the latter case the cells and nuclei are similar in size to those of the other cases, the average is also given for the entire group. In the following discussion the data are compared with those of normal rats at the same body weight (that is, at three weeks, when the experiment began).

The cells of the outer zone have in some cases apparently increased in average diameter, but the average for the group is but slightly increased, if at all. The cells of the outer part of the middle zone show an increased average diameter in all cases, the average for the group being 11.1μ . This is greater than the normal at three weeks (9.7μ), though less than the normal at ten weeks (14.5μ). The cells of the inner part of the middle zone, on the contrary, shows a definite decrease to 8.9μ (from normal 10.5μ). The inner-zone cells likewise decrease in average diameter to 8.1μ (from 9.5μ), but the cells of the medulla show but little if any change in size.

In nuclear size the outer zone in the suprarenal cortex of the maintenance rats is but slightly changed. The average nuclear diameter is slightly lowered, with a corresponding decrease in the relative volume of the nucleus to 25.7 per cent (from normal 34.5 per cent). The nuclei in the outer part of the middle zone remain nearly unchanged in average diameter, but on account of the increase in cytoplasm and cell volume the relative size of the nucleus decreases to about 17 per cent (from normal 27 per cent) of the cell volume. The nuclei in the inner part of the middle zone show a definite decrease in diameter to 5.5μ (from normal 6.2μ), but as the reduction in cell diameter (cytoplasm) is still greater, the relative volume of the nucleus averages slightly higher at 23 per cent of the cell volume (normal 21 per cent). The inner cortical zone nuclei decrease in average diameter to 4.9μ (from 5.7μ), but since the cytoplasm decreases similarly, the relative volume of the nucleus is unchanged. The nuclei

of the medulla parenchyma cells show a slight decrease in average diameter to 6.4μ (normal 6.7μ) and their relative volume decreases to 17.2 per cent (normal 23.5 per cent).

3. In young rats refed after stunting

Table 4 shows the results in four individuals, two refed one week and two refed two weeks after being held at maintenance (nearly constant body weight). In general, the dimensions are slightly greater in those refed two weeks, but as the differences are usually slight, the average is given for the whole group. Comparison is made with the data for the maintenance group and for the normal.

In cell diameter the cells of the outer cortical zone have increased to about normal size (from 8.1μ at maintenance to 8.7μ). The cells of the outer part of the middle zone have increased materially (from 11.1μ maintenance to 11.8μ after one week of refeeding and to 13.1μ after two weeks), but are still below the normal. The inner-zone cells have increased to about normal size (9.2μ). The medulla cells have increased in diameter (from 11.4 at maintenance to 12.2μ), though still below normal average (13.2μ).

In nuclear size the outer-zone nuclei remain unchanged in diameter, though decreasing slightly in relative volume (percentage of cell volume). The middle-zone nuclei have not changed much in diameter, but on account of the increase in cell volume their relative volume has decreased to nearly normal ratio. The inner-zone nuclei have increased somewhat in diameter, so the nucleus-plasma ratio is now nearly normal. In the medulla the nuclei have apparently decreased in average diameter (to 6.1μ as compared with 6.4μ at maintenance), and this reduces the nuclear percentage of the cell volume from 17.2 per cent to 12.9 per cent, which is considerably below the normal (about 16 per cent). This nuclear change is difficult to understand.

4. In adult acute inanition

As shown by table 4, a comparison of the average data from the four adults with those of the normal adult indicates that the cells of the outer cortical zone have decreased little or none in diameter. The middle-zone cells, however, have decreased in diameter very markedly—from 14.8μ (normal) to 12μ in the outer part of the zone, and from about 11.5μ to 9.2μ in the inner part of the zone. The inner zone cells have decreased but slightly—from 8.7μ to 8.5μ . The medulla parenchyma cells have decreased markedly—from 15.9μ to 12.7μ in average diameter.

The nuclei of the outer zone indicate no shrinkage, but rather an insignificant increase in average diameter from 5.5μ to 5.8μ , with a corresponding slight increase in relative volume (from 23.2 per cent to 27.1 per cent of the average cell volume). The middle-zone nuclei have decreased slightly in diameter (6.9μ to 6.5μ in the outer part and 6.4μ to 5.5μ in the inner part of the zone). But since the loss in cytoplasm is greater, the relative nuclear volume has increased—from 10.1 per cent to 16.2 per cent in the outer part and from 15.5 per cent to 21.7 per cent in the inner part of the zone. The inner-zone nuclei remain nearly constant in size and relative volume. The medulla nuclei appear slightly decreased in average diameter (7.3μ to 7.0μ). But on account of greater loss in the cytoplasm, the relative size of the nuclei has increased from 9.6 per cent to 16.8 per cent of the cell volume.

Barbèra and Bisci ('00), in rabbits starved seven days with loss of 34 per cent in body weight, found the nuclei in the suprarenal cortex to decrease from an average diameter of 7.238μ to 4.817μ , and in the suprarenal medulla from 7.773μ to 5.587μ . The loss in cytoplasm appeared relatively greater than in the nucleus. Similar results were obtained in dogs. These decreases in cell dimensions would appear to be much greater than those observed by me in the rat. Traina ('04) noted a decrease in the size of cortical cells in the suprarenal of the rabbit during starvation, but gives no exact data.

5. *In adult chronic inanition*

The data from the two individuals (table 4) indicate that the suprarenal cells of the outer and middle cortical zones have lost in diameter somewhat more than during acute inanition; the inner zone and medulla cells about the same as during acute inanition (or slightly less).

The nuclei in all the regions during chronic inanition have apparently lost in average diameter somewhat more than during acute inanition. The relative (percentage) volume of the nucleus is therefore usually lower than during acute inanition. In the outer zone and the medulla, the nucleus-plasma ratio is not greatly different from that of the normal animal.

CELL DIVISION—FREQUENCY OF MITOSIS

No conclusive evidence of amitosis was found in any of the suprarenal glands studied, although irregular or bilobed nuclei, which might easily be so interpreted, were occasionally observed in the various zones of the cortex and medulla. If amitosis occurs at all (in the rat), it is probably a degenerative phenomenon of no especial significance or importance in the normal development of the gland.

The frequency of mitosis in the suprarenal, under normal and abnormal conditions at various ages, is given in table 5. The average number of mitoses counted in entire sections through the center of the gland is shown for the various zones in the rats grouped according to age or condition.

1. *Mitosis during normal development*

As shown in table 5 A, the average number of mitoses in an entire section of the suprarenal is somewhat variable in individual cases, but the general trend according to age is evident. The average number per section at birth is 20, decreasing to an average of 10 at one week, and increasing again during the second and third weeks. At twelve days (one case only) there were 40 mitoses per section, which was the maximum number

observed, excepting one of the nine cases at three weeks. The average number of mitoses again decreases somewhat slowly from 27 at 14 days to 24 at 21 days, 11 at 56 days, 4 at 67 to 94 days, 2 at 112 to 138 days, and 1 at 340 days. In other adults no mitoses were observed in the suprarenal.

The relative rate of mitosis ('mitotic index' of Minot) decreases more rapidly than is indicated by the figures for the absolute frequency per section shown in table 5 A. This is because the size of the gland, and consequently the total number of cells in a section, is progressively increasing. Thus between birth and three weeks of age the suprarenal gland of the albino rat has increased about four times in weight (and volume). This corresponds to an increase in diameter of about 1.6, or of about 2.6 times in the area of a cross-section. Since the size of the cells has not greatly increased during this time (table 4), the number of cells in a corresponding section of the gland is probably twice as great at three weeks as in the new-born. Thus the relative rate of mitosis would be obtained by comparing the number of mitoses in a section at birth (20) with half the number in a section at three weeks (half of 24 = 12). Therefore, although the absolute number of mitoses per section increases in the second and third weeks, it is doubtful whether the relative rate of mitosis exceeds that of the new-born.

The distribution of the mitoses in the various zones of the cortex and the medulla is also shown in table 5 A. The rate in the medulla is in general nearly parallel with that for the whole gland, decreasing from an average of 6 per section in the new-born to 3 at one week, and gradually increasing again to 6 at fourteen days. Thereafter the number of mitoses decreases, and none are found in the medulla after eight weeks, though continuing to occur in the cortex. The later growth of the medulla must therefore be due entirely to the growth in the preëxisting cells, which continue to increase in average size (table 4).

As to localization in the various regions of the cortex, the number of mitoses in the outer zone (glomerulosa) is strikingly large, although this zone is the narrowest of the three. When

it is further considered that the majority of the middle-zone mitoses occur in the outer part of the zone, it is evident that in general the outer portion of the cortex is the chief cortical germinative region. Some mitoses are found scattered throughout the cortex, however, an occasional one being found even in the inner zone (reticularis). In general, mitoses disappear first in the medulla, and the inner cortical zone, and later in the middle zone, persisting longest in the outer cortical zone.

The occurrence of amitosis in the suprarenal has been claimed by various investigators. Mulon ('03 b, '05 a) in particular even maintains that in the guinea-pig amitosis is the predominant type of cell division in the suprarenal, mitosis being much less frequent. Kolmer ('12 b), on the contrary, found mitoses more frequent (occasional amitosis) in the suprarenal cortex of the younger guinea-pigs, though in older, non-pregnant females amitosis was observed with no mitosis. Most authors have considered amitosis in the suprarenal (as elsewhere) to be atypical and degenerative in character. Thus Poll ('99) observed amitosis (more rarely mitosis) in the degenerating cortical cells in transplanted suprarenal glands of the rat. Delamare ('03) observed occasional amitosis in the senile human suprarenal cortex, producing multinucleated masses. Bonnamour ('05 a) believes that the figures which have been interpreted as amitosis (direct division), especially in the outer cortical zone and in the medulla, are merely deformed nuclei, without significance for cell division.

In relation to age, cell division (especially mitosis) in the suprarenal has generally been found more frequent in young animals, as might be expected, and especially in fetal stages (Canalis). It has also been observed in adults, especially in the outer cortical region, by Canalis ('87) in the dog, guinea-pig, rabbit, and mule, Mulon ('03 b) (guinea-pig), Kolmer ('12 b) (guinea-pig), and others. Da Costa ('13) has observed mitoses in the cortex of both young and adult dog and guinea-pig.

It is interesting to note that the rate of mitosis in the young rat corresponds rather closely to the growth of the gland in absolute and relative weight. As previously shown (Jackson,

'13), the suprarenal gland in the albino rat increases but slightly in average absolute weight (from 0.0019 gram to 0.0023 gram) during the first week after birth, thereby decreasing in relative weight (percentage of the entire body). This is in agreement with the smaller size of the cortical cells (already mentioned) and the corresponding marked decrease in the rate of mitosis observed in the present study (table 5). The weight of the gland increases rapidly during the second and third weeks, reaching its maximum relative size corresponding to the period when an increase in the number of mitoses appears. The formula for the growth of the suprarenal in the albino rat as derived by Hatai ('13) similarly indicates a maximum relative weight for suprarenal at about 10 to 15 grams body weight. His data, however, do not show the arrested growth during the first week. The suprarenal weights in Donaldson's ('15) tables (which are based upon Hatai's formulas) are therefore apparently too high for this early period. According to these tables, at a body weight of 10 grams, the suprarenals should weigh about 0.0045 gram, whereas in fifty-seven cases (30 m., 27 f.) I found an average of only about 0.0023 gram.

As to regional distribution, cell division has in general been found to occur throughout the gland in the earlier stages, especially prenatal (Canalis, '87, in dog, guinea-pig, and rabbit), with a progressive tendency to be restricted later to the outer cortical region (Canalis, '87; Mulon, '03 b, and others). The occurrence of mitosis in the deeper layers of the suprarenal cortex (occasionally even in the zona reticularis) in growing or adult animals has also been observed by Bonnamour ('05 a), Kolmer ('12 b), and Da Costa ('13) (dog, rat, rabbit, guinea-pig). An extraordinary increase in mitosis in the outer part of the zona fasciculata was noted by Kolmer ('12 a) at the end of pregnancy in the guinea-pig. That the outer cortical region of the suprarenal is the chief 'germinative zone' from which by cell division the remainder of the cortex is derived (especially in postnatal development), is indicated by the observations of Canalis ('87), Roud ('02), Cristiani ('02), Soulié ('03), Mulon ('03 b, '05 a), Kern ('11), Kolmer ('12 b), Cottentot, Mulon

and Zimmerman ('12), and others. Gottschau ('83) considered the germinative zone to lie between the zona glomerulosa and the zona fasciculata, while Wiesel ('01) (in the fetal pig) and Da Costa ('13) placed it in the middle zone (fasciculata), and Dershinsay (cited by Da Costa, '13) even in the inner zone. Graham ('16) found that after toxic lesions regeneration of the suprarenal cortex proceeds from the zona glomerulosa and outer part of the fasciculata. In the child, mitoses may occur throughout the cortex.

2. *Mitosis during inanition and refeeding*

From the data given in table 5 B it is evident that the effect of underfeeding in young rats held at maintenance (nearly constant body weight) is in general to diminish very greatly the number of mitoses, and ultimately to prevent them entirely. In rat St 80.9 underfed from birth to twelve days (body weight increased from about 5 grams to 8.9 grams), the total number of mitoses found in a section of the suprarenal was 4, whereas normally (at corresponding age or body weight) it would be between 10 and 20. In ten rats held at maintenance from three to ten weeks of age, the average number of mitoses was reduced to 1, the maximum being 3, and none present in six of the ten cases. In three cases in which the maintenance was continued to the age of twelve to twenty weeks, no mitoses were found in the suprarenal.

The distribution of the mitoses in the various cortical zones of the suprarenal in the stunted rats appears similar to that in the normal glands. That is, the larger number occurs in the outer zone and the outer part of the middle zone. None was noted in the inner zone and (excepting the youngest rat) none in the medulla.

In the rats refed fully for one week (after maintenance from three to twelve weeks) mitosis in the suprarenal has recommenced. The rate is still below normal, however, the average number being only 2 per section. In rats refed two weeks, the number of mitoses has increased to 10 per section, which

is nearly the same as that found in the normal rat at fifty-six days. Since the body weight (77 to 79 grams) and suprarenal weight are also nearly the same as in the normal at fifty-six days, we may conclude that the normal rate of mitosis has been reestablished in the suprarenal glands of stunted rats after two weeks of refeeding. As might be expected, no mitoses were found in the rat refed one year, which had reached maturity.

Martinotti ('92) briefly states that in guinea-pigs starved three or four days an abnormal increase in the number of mitoses (20 to 25) in the suprarenal cortex was always noted. An increase in mitosis was also noted upon refeeding after several days of inanition. Unfortunately, further details are omitted, including the age and number of animals used. Bonnamour ('05 b), on the contrary, found no mitoses in the suprarenal glands of the rat, guinea-pig, rabbit, and cat starved to death. Rondoni and Montagnani ('15) likewise observed no mitosis in the suprarenals in starved guinea-pigs. This would agree with my results on the albino rat.

HISTOLOGICAL CHANGES IN THE SUPRARENAL GLAND

In addition to the volumetric data previously given, the general changes in histological structure were observed. These include: 1) normal postnatal histogenesis in the albino rat; 2) changes in young rats stunted by underfeeding; 3) changes in rats refed after stunting by underfeeding, and 4) changes in adult rats after acute or chronic inanition.

1. Normal postnatal histogenesis

A brief account of the histology and histogenesis of the suprarenal will be given, with special emphasis upon the structural features of importance in connection with the changes produced by inanition.

New-born and first week. In sections fixed in Zenker's fluid and stained with hematoxylin-eosin, the three cortical zones of the suprarenal in the new-born rat are fairly distinct. Under low magnification they appear as, 1) an outer zone

(glomerulosa), narrow and deeply stained; 2) a middle zone (zona fasciculata), broader, with irregular, radial columns, and 3) an inner zone (zona reticularis), less distinct and more irregular, and (in the new-born) intermingled with the medulla. The medulla, which at birth is not clearly differentiated and separated from the cortex, is more vascular. It is composed of irregular cell groups or cell cords and contains a few scattered, deeply stained cell masses. Similar masses also appear occasionally in the cortex, especially in the region of the hilus.

Under higher magnification, the outer cortical zone appears narrow, but variable in width, about six to ten cells deep. The cells are somewhat variable in size and structure. The cytoplasm is scanty, more or less granular, and presents a few fine vacuoles (lipoids.) The nuclei are spherical or ellipsoidal in form, somewhat deeply chromatic and (as previously shown) present frequent mitoses.

The middle-zone cells are larger. The cytoplasm is more abundant, with distinct eosinophile granules and a few (variable number) of lipoidal vacuoles, somewhat more prominent in cells toward the middle of the zone. The nuclei are spherical and larger than those of the outer zone. They are less deeply chromatic, through occasionally pycnotic.

The inner-zone cells resemble those of the adjacent part of the middle zone, with distinctly granular cytoplasm and a few fine vacuoles. Many of the cells are degenerative in appearance, with indistinct cytoplasm and karyolytic or pycnotic nuclei, sometimes fragmented (karyorrhexis). The inner zone cells of the cortex extend into the medulla, and are intermingled closely with groups of the medulla cells, from which they are frequently difficult to distinguish (in the usual preparations). Inaba ('91) likewise found an intermingling of cortex and medulla in the new-born mouse.

The medulla cells of the suprarenal in the rat are polymorphic, in irregular cords and clumps, separated by relatively large blood sinuses. The cytoplasm is very scanty and the cell boundaries are usually indistinguishable (as also in the cortex). The cytoplasmic (chromaffin?) granules usually appear baso-

philic, with a bluish-violet stain, in contrast with the typical reddish (eosinophile) color in the cytoplasm of the cortical cells. The nuclei appear similar to those of the adjacent cortex. The stroma is not clearly differentiated. The deeply staining cell clusters above referred to are apparently in most cases remnants of the embryonic sympatho-chromaffin cells, consisting of deeply staining nuclei with scanty cytoplasm. They are distinct from the intermingled cortical cell strands, which are especially evident in preparations stained for lipoids or chromaffin reaction.

The chromaffin reaction is present, but faint, in the new-born rat and increases but slightly in intensity during the first week. The medulla cells assume a pale brownish color, by which they may be clearly distinguished from the cortex and from the intermingled cortical cord present in the medulla. In mammals generally the chromaffin reaction of the medullary cells appears during the fetal period (compare Poll, '05) and was noted by Soulié ('03) well marked in the new-born rat and guinea-pig.

Lipoids. In unstained frozen sections of the suprarenal (formalin-fixed a few hours) in the new-born rat, the cortex appears opaque, due to the emulsion formed by the lipoidal granules. Following the terminology of Albrecht and Bell, these lipoidal granules and droplets will be designated as 'liposomes.' They are soluble in absolute alcohol and xylol, but insoluble in 1 per cent aqueous potassium hydroxide and in 1 per cent acetic acid. With the exception of an indistinct clear streak between the outer and middle zones, they appear somewhat uniformly distributed throughout the cortex and in the cortical cell strands extending throughout the medulla.

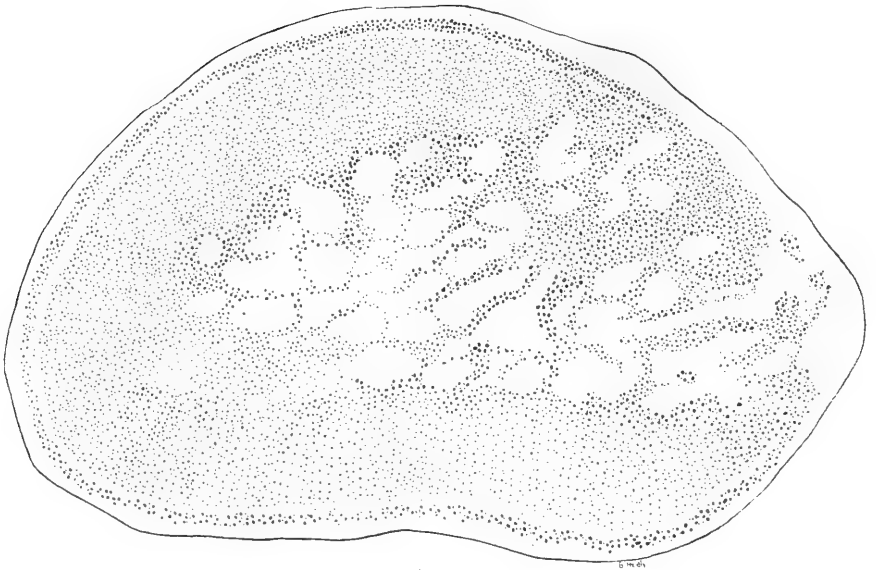
These sections, when stained with Herxheimer's scarlet red or with 1 per cent osmic acid and mounted in glycerin, reveal still more clearly the liposomes (fig. 1). Although not so abundant as later, the lipoids appear in much larger amount than would be expected from the corresponding lipoidal vacuoles as seen in the usual stained paraffin sections. Their staining reactions already appear distinct from those of the ordinary fat droplets outside of the fibrous capsule, even when these

droplets are as small as some of the liposomes. With Herxheimer's scarlet red, the liposomes stain a deep scarlet-reddish color, while the extracapsular ordinary fat droplets assume a characteristic lighter reddish color. With osmic acid, the ordinary extracapsular fat stains jet-black, the suprarenal liposomes stain in varying shades of brown (mostly light brown).

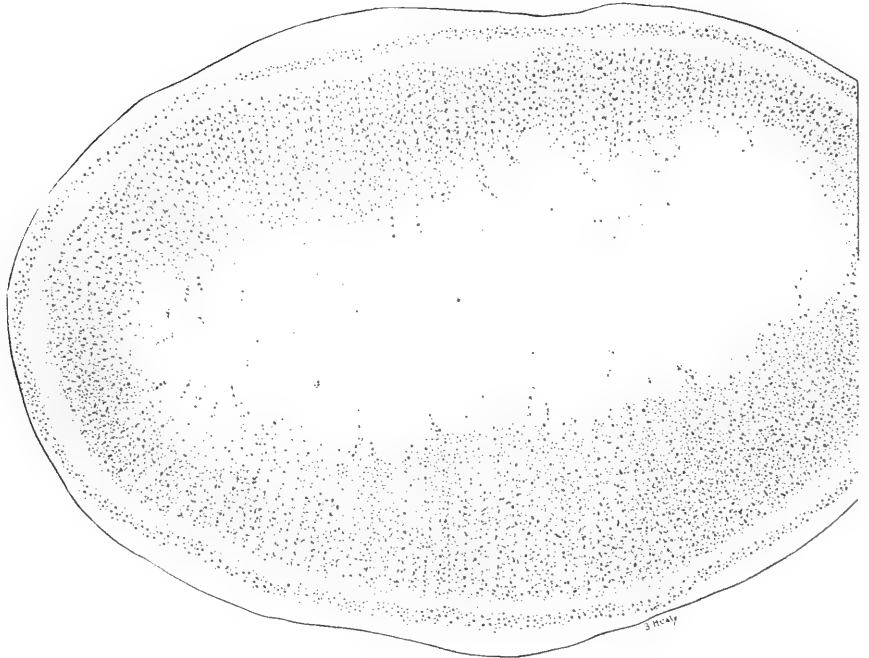
In distribution the liposomes, as noted in the fresh sections, are nearly uniformly present throughout the cortex, although relatively few occur in the narrow clear band between the outer and middle zones. In size they vary from extremely fine to coarse. The largest, however, are much smaller than later, now rarely reaching half the nuclear diameter. They form in each cell a circumnuclear zone which appears very distinct in the scarlet red or osmic-stained sections. The liposomes in the cortical cell strands through the medulla of the newborn rat usually appear similar in size and number to those in the cortical cells elsewhere. No liposomes are present in the cells of the medulla proper, which appear as clear and unstained masses, intermingled with the cortical strands.

In a rat of the second day (F. 10.2), the cortical liposomes in frozen sections stained with scarlet red appear in general as in the new-born, possibly slightly more abundant in the middle zone. The cortical cell strands in the medulla, however, are apparently undergoing absorption, and their liposomes appear fewer and finer than elsewhere in the cortical cells. At three days (fig. 2), the cortical cell strands throughout the medulla are very inconspicuous, though still distinguishable under high power in many places by their content of very fine (rarely coarser) liposomes. In some places the corticomedullary border is now clearly defined, though in other places still irregular. The exact date at which the cortical cell strands in the medulla are absorbed, leaving a clean-cut corticomedullary boundary, is subject to individual variation.

Second week. In rats one week of age, in sections of the suprarenal stained with hematoxylin-eosin, under low magnification, the cortical zones appear as in the new-born, but the medulla is much lighter in appearance and now appears separated from the cortex by a sharply defined border.



1



2

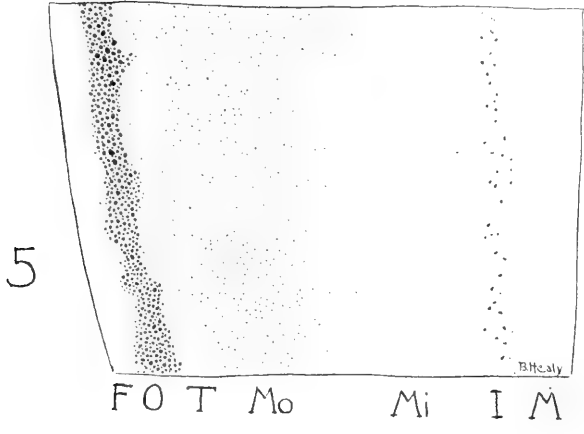
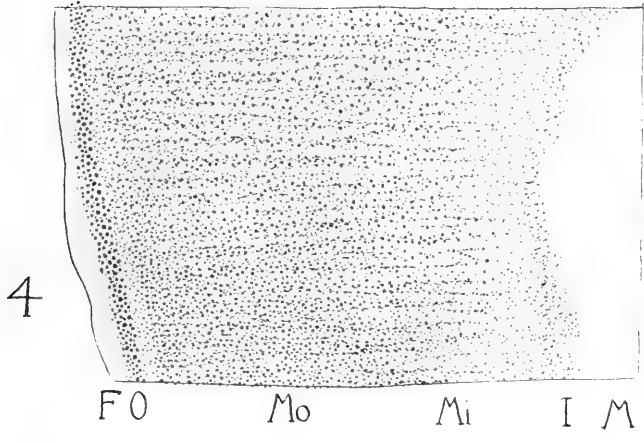

Under higher magnification the cortical zone cells appear in general similar to those of the new-born. The inner-zone cells, however, no longer intermingle with those of the medulla, but (aside from a few scattered islands of cortical cells) present a fairly even and very distinct line of demarcation. Next to this border, the cortical cells frequently appear flattened and more or less atrophic, probably due chiefly to absorption by the expanding medulla.

The medulla has become confluent as a central mass, which may also reach the surface at the hilus (compare fig. 10). It has undergone a marked change in structure and appearance. The stroma is well differentiated, forming an irregular syncytial net work containing elongated nuclei and fine fibrillae. The parenchyma cells are likewise syncytial. The cytoplasm is more abundant and presents small vacuolated (non-lipoidal) spaces, variable in size and number. The fine violet cytoplasmic granules are present, but variable and usually scanty. The nuclei are somewhat variable in form, but usually spheroidal and vesicular, very slightly chromatic. Some are smaller and more deeply staining, occasionally even pycnotic. Bilobed dumb-bell-shaped nuclei are occasionally seen in the medulla (as also in the cortex), but these are comparatively rare. It is doubtful whether they are to be considered as evidence of amitotic cell division. The deeply staining masses (sympathochromaffin cells) mentioned in the new-born occur rarely in the suprarenal medulla at one week.

In a rat at eight days (F 11.3) frozen sections unstained or stained with scarlet red or osmic acid show the liposomes some-

Fig. 1 Longitudinal section of the suprarenal gland of a new-born albino rat (F 8.1). Formalin fixation; frozen section stained with Herxheimer's scarlet red. Liposomes visible in the cortex and in the cortical strands throughout the medulla. The light band, relatively lipoid-free, which separates the outer and middle cortical zones is already evident. $\times 80$.

Fig. 2 Longitudinal section of the suprarenal gland in an albino rat three days old (F 11.1). Formalin fixation; frozen section stained with Herxheimer's scarlet red. The medulla is confluent, and the intermixed cortical strands are undergoing absorption, with the establishment of a definite corticomedullary boundary. $\times 80$.



what similar to those of the first week. Those of the outer zone are relatively most abundant, varying from fine to coarse, the largest approaching nuclear size. The subjacent narrow light band is relatively free from lipoids, with only a few fine granules. In the middle zone the liposomes are less uniformly distributed than heretofore, becoming more abundant in the outer half of the zone. They are less abundant in the inner zone. Here occur a few coarsely granular cells, which also appear as individual cells or small groups sparsely scattered through the medulla. These islands represent unabsorbed remnants of the earlier cortical strands.

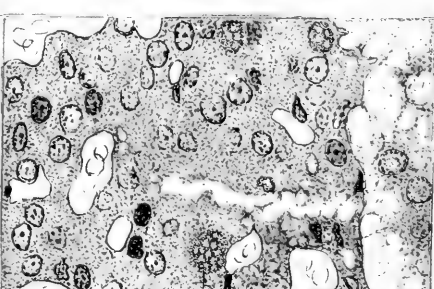
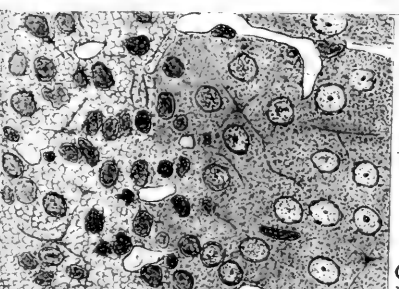
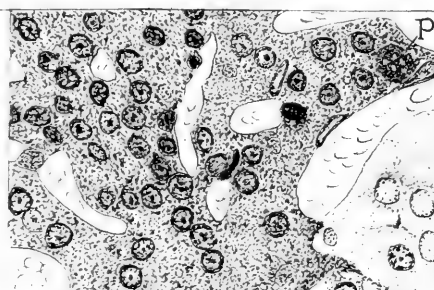
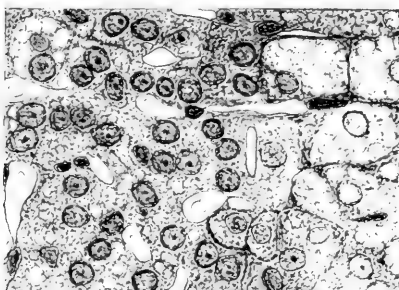
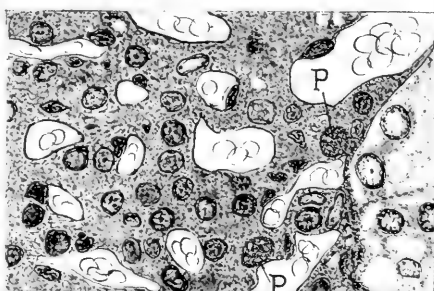
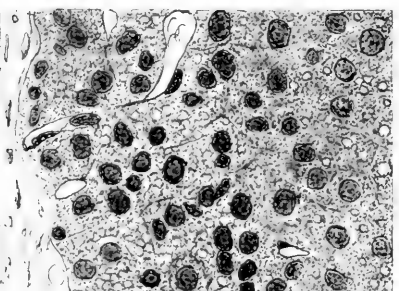
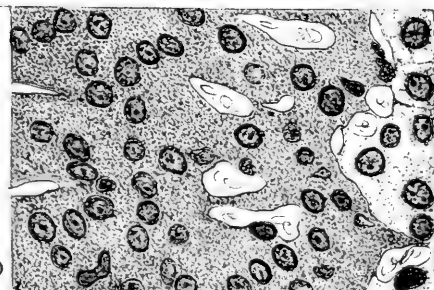
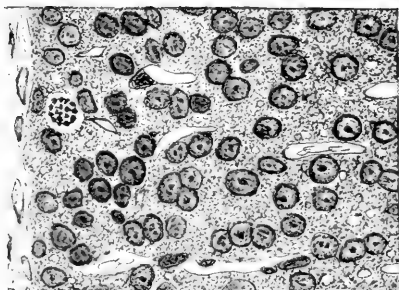
The chromaffin reaction of the medulla, though distinct, is still comparatively weak, as during the first week.

At ten to fourteen days, the suprarenal in general structure and appearance, in sections stained with hematoxylin-eosin, is similar to that at one week. Lipoidal vacuoles are becoming more abundant in the outer and especially the middle cortical zone. The reddish (eosinophile) cytoplasmic granules of the cortical cells are in contrast with the pale violet (faintly basophile) granules of the medulla cells. The cortical cells of the inner zone are usually normal in appearance, but frequently atrophic and degenerated, especially in certain areas. Large sympathetic ganglion cells appear in the medulla.

Fig. 3 Portion of a section of the suprarenal gland in a normal adult albino rat (F 3.1). Formalin fixation; frozen section stained with Herxheimer's scarlet red. Liposomes most abundant in the outer cortical zone and the outer half of the middle zone. *F*, fibrous capsule, with ordinary fat droplets in the tissue outside; *O*, outer zone (glomerulosa); *T*, transition band, relatively lipoid-free; *Mo*, outer part of middle zone (fasciculata); *Mi*, inner part of middle zone; *I*, inner zone (reticularis); *M*, medulla. $\times 90$.

Fig. 4 Portion of a section of the suprarenal gland of an adult albino rat (F 3.2), after nine days of acute inanition. Formalin fixation; frozen section stained with Herxheimer's scarlet red. For explanations, see figure 3. No apparent decrease in the liposomes, which appear more uniformly distributed throughout the cortex. The light band at the transition between outer and middle zones is obscured. $\times 90$.

Fig. 5 Portion of a section of the suprarenal gland of an adult albino rat (F 4.2) after twelve days of acute inanition. Formalin fixation; frozen section stained with Herxheimer's scarlet red. The liposomes persist in the outer zone (*O*), but have nearly all disappeared elsewhere. A few are barely visible in the outer half of the middle zone (*Mo*), and in the inner zone (*I*). $\times 90$.

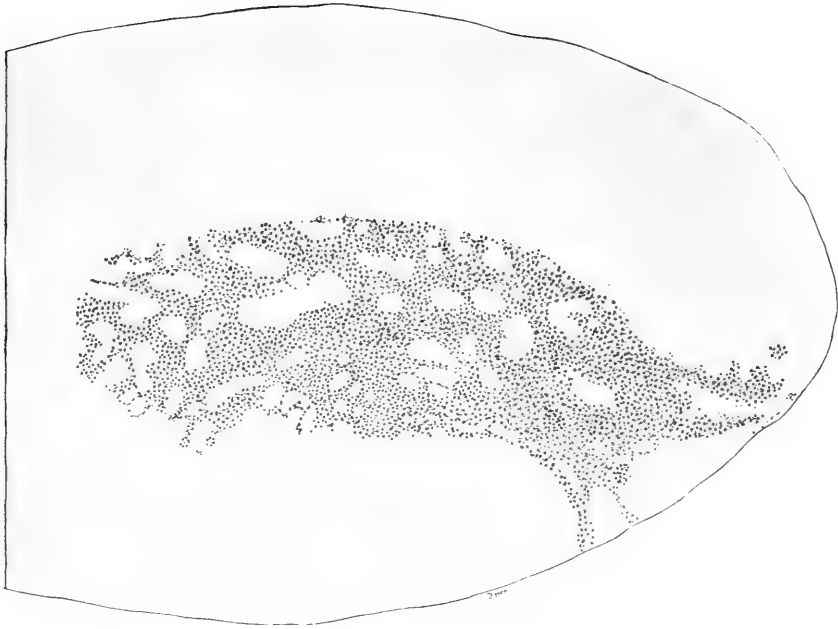


6

7

8

9



10

Fig. 6 Portion of a section of the suprarenal gland of a normal albino rat (J 1.1) three weeks old. Zenker fixation, paraffin section stained with hematoxylin-eosin. Most of the middle cortical zone is omitted. *F*, fibrous capsule; *O*, outer zone (glomerulosa), one cell in mitosis; *T*, transition band, nearly lipid-free; *Mo*, outer part, and *Mi*, inner part of middle zone (fasciculata); *I*, inner zone (reticularis); *M*, medulla. $\times 300$.

Fig. 7 Portion of a section of the suprarenal gland of an albino rat (S 7.31) held at constant body weight by underfeeding from three to ten weeks of age. For explanations, see figure 6. Progressive differentiation of lipoidal vacuoles in the outer zone (*O*) and of pigment (*P*) in the inner zone (*I*). Some cell atrophy, with hyperemia and increased degeneration in the inner zone. $\times 300$.

Fig. 8 Portion of a section of the suprarenal gland of a normal albino rat (St 7.45) ten weeks of age. For explanations, see figure 6. This represents the normal adult structure. Lipoidal vacuoles well marked in the outer zone (*O*) and outer part of the middle zone (*Mo*), but rare in the transition band (*T*). One pigment mass (*P*) visible. $\times 300$.

Fig. 9 Portion of a section of the suprarenal gland of an adult albino rat (J 1.5) subjected to chronic inanition for five weeks. For explanations, see figure 6. The lipoidal vacuoles have disappeared, except in the outer zone (*O*). Marked atrophy with nuclear and cytoplasmic degeneration in the inner cortical zone (*I*). Three pigment masses (*P*) visible. $\times 300$.

Fig. 10 Longitudinal section of the suprarenal gland in an adult albino rat (F 9.3) after ten days of acute inanition. Fixation in Müller's fluid; frozen section (unstained). Normal chromaffin reaction in the medulla, which in this case extends to the surface at the hilus. $\times 80$.

In a rat at seventeen days (F 7.1) the fresh frozen sections of the formalin-hardened gland show the characteristic cortical opacity due to the liposomes. The clear line between the outer and middle zones is distinct. The opacity decreases greatly in the inner half of the middle zone and in the inner zone, the medulla being perfectly clear.

This irregular distribution of the liposomes is still more apparent when the sections are stained with scarlet red or osmic acid. The liposomes are most abundant in the outer zone and the outer half of the middle zone, where the largest droplets now approach nuclear size. Toward the inner cortical zone they become fewer and finer. Some of the inner zone cells are entirely free from liposomes, others occasionally appear well filled. Aside from a few scattered cortical cell islands, no liposomes appear in the medulla.

The other supararenal gland from this rat was hardened in Müller's fluid. The chromaffin reaction of the medulla is more definite than in the earlier stages, though not so intense as later. All of the medulla parenchyma cells are stained light brown, the nucleus darker than the cytoplasm. The vacuoles of various size in the medulla cells are unstained, not giving the chromaffin reaction. The blood in the vascular spaces of the medulla occasionally presents a reddish-brown color to a variable extent (probably from absorbed epinephrin).

At three weeks. The paraffin sections were stained as usual. The outer cortical zone (fig. 6, *O*) is narrow, usually 6 to 8 (rarely 12) cells deep. The cells are in irregular masses or columns, separated by blood capillaries. Cell boundaries are ill defined. The cytoplasm is scanty, contains fine eosinophile granules and more numerous lipoidal vacuoles. The nuclei are hyperchromatic, some almost pyenotic. The deepest cells (fig. 6, *T*) are transitional to the middle zone, and form a narrow zone nearly free from lipoidal vacuoles.

The middle cortical zone is broadest. The cells (fig. 6, *Mo*, *Mi*) are arranged in very distinct cell columns, radially arranged, and usually but one cell wide. The radial cell columns are separated by blood capillaries, which become wider toward the

center of the gland. Cell boundaries are more distinct than heretofore. The relatively abundant cytoplasm is filled with characteristic eosinophile granules and a variable number of lipoidal vacuoles. In some cases these vacuoles appear no more numerous than in the second week. In others they are more abundant especially in the outer half of the middle zone, whereby these cells become much larger than the cells of the inner half of the middle zone. The nuclei are typical in structure, spherical, and moderately rich in chromatin. Atrophic cells occasionally occur in various stages of degeneration.

The inner zone (*zona reticularis*, fig. 6, *I*) is rather narrow, but of variable width, representing the area of irregular cell columns next to the medulla. The irregularity of structure is probably associated with the process of absorption accompanying the expansion of the medulla, although only occasionally are the border cells flattened as though atrophic from pressure. Most of the cells in the inner zone are similar to those of the adjacent middle zone, the cytoplasm containing eosinophile granules and a few small lipoidal vacuoles. Some scattered cells show various stages of degeneration and disintegration. Occasional islets of such cortical cells occur also in the adjacent medulla, but rarely deeper, toward the center of the medulla, as in the earlier stages.

The medulla in stained sections (fig. 6, *M*) appears very light, in strong contrast with the darker cortex. (The converse is true if the suprarenal gland has been fixed in Zenker-formol instead of Zenker's fluid, the sections being stained with hematoxylin.) The parenchyma forms irregular cell masses, separated by delicate fibrous stroma (with elongated nuclei) enclosing wide, sinusoidal blood-vessels. The cytoplasm of the parenchyma cells is abundant, containing pale violet (chromaffin?) granules and numerous non-lipoidal vacuoles, variable in size and number. The nuclei are typically vesicular in form and only moderately chromatic. A few are smaller and more deeply staining, sometimes pyknotic. Degenerative cells with karyolytic nuclei are rarely seen. Occasional large spherical sympathetic ganglion cells and bundles of non-medullated fibers appear.

At eight weeks. The appearance of hematoxylin-stained sections under low power is similar to that at three weeks. The cell structure in the outer and middle zones is also similar, with some increase in the size and number of lipoidal vacuoles, especially in the outer half of the middle zone. The inner zone shows in general a more atrophic appearance, and occasional pigment cells occur for the first time. These are parenchyma cells containing one (sometimes two) irregularly spheroidal, light yellowish-brown, coarsely granular masses. As will be shown later, this pigment is probably a lipochrome. The nuclei of these pigment cells are irregular, sometimes central, sometimes crowded to the side of the cell and flattened. The inner zone cells bordering on the medulla are usually more or less flattened and atrophic in appearance. The medulla appears similar to that at three weeks.

At ten weeks to adult. At ten weeks, the histological structure of the suprarenal (fig. 8) has reached practically the adult condition. In fact, although the gland increases in size, but few changes in structure are noticeable after the eight weeks' stage previously described. In the usual hematoxylin-stained sections the structure appears as follows (fig. 8):

The outer cortical zone (fig. 8, *O*) remains narrow, 6 to 12 cells deep. It is somewhat variable in structure, with irregular cell cords separated by blood capillaries. The cells remain relatively small, with nuclei of variable form and structure. The cytoplasm is relatively scanty and somewhat granular. It contains a variable amount of lipoidal vacuoles, usually giving the cytoplasm a honey-comb appearance. The deepest cells, on the border between the outer and middle zones (fig. 8, *T*), are relatively free from lipoidal vacuoles as found in the earlier stages.

In the middle zone the only noteworthy change is in the amount of lipoids, as shown by the vacuoles. These increase, but to a variable extent. They are larger and more numerous in the outer half of the zone (fig. 8, *Mo*), but smaller and fewer in the inner half. In the larger cells of the outer part, the cytoplasm presents a reticulated (honey-comb) appearance, like

that of sebaceous gland cells. In cells with fewer lipoidal vacuoles, the eosinophile granules are more conspicuous. Occasionally basophilic granules also occur. These are especially evident in preparations stained with iron-hematoxylin, and probably in part correspond to the 'corps sidérophiles' or the mitochondria described by various French investigators. The nuclei are usually central in position, spherical, and typical in structure. A few degenerative cells occur as heretofore.

The inner zone (fig. 8, *I*) appears in general similar to that at eight weeks, the outer cells of the zone being transitional to the middle zone and the inner cells (next to the medulla) being typically more or less atrophic in structure. Atrophic or degenerative changes have likewise been described in the inner cortical zone of various animals (including the rat) by Gottschau ('83), Pfaundler ('92) Soulié ('03) and others. According to Kolmer ('12 a, '12 b) these degenerative changes are increased by pregnancy (guinea-pig).

Pigment cells in the inner cortical zone of the rat at ten weeks occur more frequently than at eight weeks, but in variable degree. They are somewhat variable in number, often numerous, especially in the older rats, and may even extend somewhat into the middle zone. The nuclei of the pigment cells may be central in position, surrounded by the light yellowish-brown or greenish yellow granular masses. In this case the nucleus is irregular in form, but it is often pushed aside and flattened. The pigment is still visible, though inconspicuous, in stained paraffin sections. In thin sections the pigmented substance frequently appears vacuolated (fig. 8, *P*). In fresh frozen sections the pigment cells are clearly visible, and they are deeply stained by osmic acid or scarlet red. This would indicate that the pigment is a lipochrome, probably derived by a transformation of lipoids or other fatty substances. The vacuoles probably represent untransformed lipoids, observed by Ewald ('02) and Da Costa ('13).

The cortical fats (lipoids) in general are best studied in frozen sections of suprarenals, either fresh or hardened a few hours in formalin. In the unstained sections the distribution of the liposomes is clearly evident on account of the varying degrees of

opacity caused by them. The extracapsular fat droplets, on the other hand, appear clear and light. The liposomes present the same reactions mentioned for the new-born.

The amount and distribution of the liposomes are most clearly shown in the frozen sections stained with scarlet red (fig. 4). In the narrow outer zone, they are usually very abundant and closely packed, the largest droplets somewhat exceeding the average nuclear size. The subjacent clear line or narrow band is relatively (but not absolutely) free from liposomes. They are most abundant and closely packed in the outer half of the middle zone, where the largest may reach double the average nuclear diameter. In the inner half of the middle zone they become more or less reduced in amount, and are usually scanty in the inner cortical zone (aside from those associated with the pigment cells). No liposomes are present in the medulla, aside from occasional groups which appear in the cortical islands near the boundary.

The distribution of liposomes in sections stained with osmic acid corresponds closely with that in sections stained with scarlet red. The striking contrast in the staining reactions of the cortical lipoids and the extracapsular ordinary fat was mentioned in the new-born suprarenal, and is constant. The pigment cells (lipochrome) of the inner cortical zone frequently react more like the ordinary fat, however, staining a lighter reddish than the liposomes with the scarlet red and darker than the liposomes in preparations stained with osmic acid.

The amount and distribution of lipoids, as is well known, vary much according to age and species. In general, the formation of lipoids begins during the prenatal period (Poll, '05; Starkel and Wegrzynowski, '10), and increases during postnatal life, though a decrease in the human suprarenal fat after childhood is noted by Napp ('05). As to species the lipoidal content appears greatest in man, carnivora, and rodents, less in ruminants and pachyderms (Ciaccio, '10, and others). The lipoids are usually, as in the rat, most abundant in the middle zone, with less in the outer and inner zones. In some cases, however, a greater abundance of lipoids of the outer zone has been observed (Hultgren and Anderson, '99; Ewald '02; Napp, '05; Bonnamour, '05 b; Starkel and

Wegrzynowski, '10); and in the sheep, according to Mayer, André, Mulon and Schaeffer ('12), the sparse lipoidal granules are located exclusively in the outer zone. The characteristic fat-free band between the zona glomerulosa and the fasciculata was noted in the rat by Bonnamour ('05 b). Babes and Jonesco ('08) likewise noted a scarcity in fat between these zones in the dog, but Mulon ('12), on the contrary, finds larger droplets at this level. The composition of the suprarenal liposomes is generally considered to be chiefly lecithin or cholesterin with a variable admixture of ordinary fats (compare Ciaccio, '10, and Kawamura, '11).

Pigment has often been described in the inner cortical zone of the guinea-pig (even in the albino, according to Mulon) and man, but less frequently in other forms. It was noted by Gottschau ('83) and Pfaundler ('92) in most mammals, Baroncini and Beretta ('01) in bats, and by Elliott and Tuckett ('06) sparsely in the duckbill and pigeon. Bonnamour ('05 a) found it variable in the dog and horse, and absent in the cat, rabbit, and marmot. He found it rarely in the rat, with no difference in pigment between white and black rats. DaCosta ('13) also noted a few pigment cells in the zona reticularis of *Mus decumanus*. Dewitzky ('12) likewise noted brownish pigment in the cortex of the rat at seven weeks. Delamere ('03) and others have noted that the amount of pigment usually increases with age, being rare or absent in the young. Mulon ('02, '03 a), Ciaccio ('05), Kolmer ('12 b), and others believe that the pigment formation may represent a secretion with physiological significance, and an increase during pregnancy (guinea-pig) is claimed by Kolmer ('12 a). As to its composition, this pigment has usually been considered as related to fat (lipochrome), although Starkel and Wegrzynowski ('10) and Thomas ('11) consider that the pigment appearing in the degenerating inner cortical zone of the suprarenal in the human new-born is of hemal origin and different from the pigment in the adult gland.

The suprarenal medulla in the rat at ten weeks and older may extend to the surface at the hilus (fig. 10), as found by Poll ('99). It is similar in structure to that described in earlier stages.

The stroma (also that in the inner cortical zone) stains indistinctly bluish with Mallory's anilin-blue connective-tissue stain. The parenchyma cells (fig. 8, *M*) are large. With Zenker's fixation and hematoxylin-eosin stain, the cytoplasm contains the usual faintly basophilic (chromaffin?) granules and occasionally a few spherical eosinophile bodies of variable size. The cell periphery frequently contains irregular vacuoles, non-lipoidal and of unknown significance. They are variable in size and are somewhat more prominent than in earlier stages. According to Ciaccio ('05), they are acidophile in reaction, like true nucleoli, and are comparable to 'plasmosomes.' The structures described by Ciaccio probably correspond to the eosinophile bodies referred to above, and not to the characteristic vacuoles. The nuclei, as heretofore, are typically vesicular, though a few of them are small and hyperchromatic (sometimes pycnotic). The blood sinuses, sympathetic ganglion cells, and occasional atrophic cortical islands occur as heretofore.

In preparations fixed in Müller's fluid, the chromaffin reaction of the medulla is always well marked (as in fig. 10). The parenchyma cells appear as brownish masses separated by the unstained vascular areas. There is some variation in the intensity of the reaction in different individuals, although the variation is not great in sections of the same thickness. It also usually appears fairly uniform throughout the medulla, all of the parenchyma cells being somewhat similar in their reaction. Some masses or clumps of cells may stain more deeply, however. The brownish color appears in the cytoplasm, which may appear homogeneous or granular (the granules being most distinct in very thin sections). The cytoplasmic vacuoles of various size remain perfectly clear and unstained. Whatever their nature, they evidently do not contain epinephrin. The nucleus gives the chromaffin reaction, being stained slightly darker than the cytoplasm. This was noted by Dostoiewsky ('86) confirming Henle (versus v. Brunn). According to Ciaccio ('05), Diamare claims that the chromaffin substance fills the whole cell, while Grynfeld, localizes it in the cytoplasmic granules. The reaction is weakened or lost a few hours post mortem (Dostoiewsky, '86; Ciaccio.

'05, and others), and is also affected by anesthetics (Schur and Wiesel, '08; Hornowski, '09). The chromaffin reaction sometimes appears also to a variable extent within the blood-vessels of the medulla of the rat, as has often been noted in other animals by various observers.

2. *Changes in young rats stunted by underfeeding*

Underfed from birth. In a rat (St 80.9) underfed from birth to twelve days and reaching a body weight of 8.9 grams, the suprarenal gland has increased in weight to 0.0026 gram, which is about normal for seven days of age. The normal differentiation of the suprarenal cortex and medulla has occurred, and the structure (in sections stained with hematoxylin) is essentially similar to that of the normal rat at seven days. Thus the histological differentiation has continued, as in a normal gland of corresponding weight, although (as previously shown) the rate of mitosis has been greatly diminished.

In a rat (St 247.5) underfed from birth to seven days, there is apparently no increase in the weight of the suprarenal. Frozen sections stained with scarlet red and osmic acid show the cortical liposomes somewhat similar in appearance to those in the newborn, but progressive absorption in the cortical cell strands of the medulla is evident. The chromaffin reaction is normal.

In another rat (St 228.4) underfed from birth to fifty-eight days, the suprarenal gland has increased markedly in weight and shows a progressive differentiation of liposomes similar to those in a normal gland of similar weight (F 7.1). The chromaffin reaction in the medulla is variable. Some cell masses show a very definite reaction. In others it is entirely absent, giving the medulla a spotted appearance. This irregularity of the chromaffin reaction is probably due to the inanition, as it is not observed in the normal animals.

Rats at maintenance from three weeks to eight, ten, or twelve weeks of age. In these underfed young rats the body weight and suprarenal weight (table 1) are but little above the initial weight at three weeks. In general, the stained sections (Zenker's fixation,

hematoxylin-eosin stain) of the suprarenal appear similar to those normal at three weeks, though certain changes are clearly evident (fig. 7).

The vacuoles in the outer-zone cells usually indicate a progressive lipoidal differentiation (fig. 7, *O*). While in a few cases the lipoidal vacuoles appear scanty (as normally at three weeks), in others the outer lipoid zone was as distinct and clearly differentiated as normally at ten weeks. In most cases the lipoidal content appears somewhere between these two extremes. The eosinophile cytoplasmic granules are somewhat indistinct.

The lipoidal vacuoles of the middle zone were also found increased in size and number in most cases, though more variably and not so definitely as in the outer zone. As in normal differentiation, the lipoids usually accumulate to a greater extent in the outer half of the middle zone. Otherwise there is no constant change to be noted, excepting apparently a somewhat greater number of degenerating cells than occurs normally.

The inner zone (fig. 7, *I*), however, when compared with the normal shows the most conspicuous changes. This zone is constantly hyperemic and very markedly atrophic. The cells in general appear greatly decreased in size, and many show various stages of nuclear and cytoplasmic degeneration. More cells are flattened at the medullary border than occurs normally. The nuclei are frequently pycnotic or karyolytic. Pigment masses (not present at three weeks) appear (fig. 7, *P*) and are even more abundant than in the normal gland at ten weeks.

The medulla (fig. 7, *M*) shows relatively less change than any other part of the suprarenal. In most cases it resembles closely the normal at three weeks, though in some cases there is an evident increase in the proportion of smaller, hyperchromatic (occasionally pycnotic or karyolytic) nuclei. The cytoplasmic granules are usually indistinct. No chromaffin tests were made in these cases.

Maintenance from three to fifteen or twenty weeks of age. In these two young rats (St 33.1 and St 38.8) held at maintenance for unusually long periods, the changes in the suprarenal are more pronounced. The glands were fixed in Zenker's fluid, sec-

tioned and stained as usual. In general, the nuclei appear more hyperchromatic, though not much more than in the normal gland at three weeks. Although the fat in the fibrous capsule around the gland has apparently almost entirely disappeared, the lipoidal vacuoles of the outer zone of the cortex are abundant. In the middle zone, however, they are apparently not more numerous than in the normal at three weeks. In the inner part of the middle zone many cells are degenerating some in various stages of disintegration. The atrophic degeneration and pigment formation in the inner cortical zone is very marked. The greenish-yellow, vacuolated pigment masses in many cases have entirely filled the cells and are quite numerous. The medulla cells show increased vacuolization, sparser granulation, and hyperchromatic (frequently pycnotic, some karyolytic) nuclei. In general, however, the structure is less changed than in the cortex.

3. Changes in young rats refed after stunting by underfeeding

In the rats refed fully after maintenance from three to twelve weeks of age, the suprarenal gland rapidly returns to approximately normal structure. Even after one week of refeeding the cortex appears distinctly lighter in stained sections, due to a decrease in the chromatin content of the nuclei. The lipoids accumulate more abundantly (especially in the outer half of the middle zone) and the inner cortical zone becomes somewhat less atrophic in appearance. By the end of two weeks of refeeding, the gland has reached nearly normal structure, although some areas of degeneration may persist for longer periods. Even those held at maintenance up to twenty weeks of age (S 33.118 and S 33.120), with permanently stunted body weight, show practically normal structure in the suprarenals after being refed fully up to about one year of age.

4. Changes in adult rats after acute or chronic inanition

Adult acute inanition. Adult rats were given water only for seven to twelve days, with loss in body weight of 29 to 45 per cent (table 1 D). The suprarenal glands, as previously shown

(Jackson, '15 a), lose but little in absolute weight during adult inanition. The cells (especially those of the middle cortical zone and the medulla) during acute inanition apparently diminish in size, however, as shown in table 4. The decrease in cell size is counterbalanced by hyperemia of the cortex, though apparently the reverse (decrease in proportion of vascular stroma) occurs in the medulla.

Sections of the suprarenal, stained with hematoxylin-eosin, show changes in histological structure. The cytoplasm is reduced in amount and the eosinophile granules usually indistinct. The nuclei are variable, frequently hypochromatic. More frequently, however, they appear hyperchromatic, though less so in the outer half of the middle zone. Pycnosis and deformity of the nuclei are frequent, as described by Bonnamour ('05 b) in the outer cortical zone of the starved rat. The lipoidal vacuoles are variable. Usually, however, they are absent or considerably reduced in number and size in the middle zone, though persisting nearly unchanged in the outer zone. The eosinophile granules of the cortical cells, though sometimes indistinct, are often well preserved and become more evident with the reduction in the amount of lipoids present.

The inner cortical zone shows the hyperemia and atrophic condition usually more pronounced than in the normal animal. Pigment masses are frequent, but it is somewhat doubtful whether they are increased in number. Degenerating cells with pycnotic or karyolytic nuclei in various stages of disintegration are numerous.

Scarlet red or osmic staining of fresh frozen sections reveals the cortical liposomes much more abundant than would be suspected from the ordinary stained paraffin sections. In some cases the usual fat-free boundary line between the outer and middle zones is nearly obliterated by an increased development of liposomes, and they may appear more uniformly scattered through the middle zone, and even the inner zone (fig. 4).

This tendency toward a more uniform distribution of the liposomes throughout the cortex was noted in three of the eight cases of adult acute inanition stained especially for lipoids, though the

total amount of the lipoids appears somewhat reduced in one of them (F 1.2). A similar 'Verbreitung der lipoidhaltigen Schichten' was observed by Landau ('13 b) in fasting guinea-pigs.

In five of the eight rats in my series, however, the change consists in a very marked reduction in the liposomes of the middle and inner zones. Under the low power of the microscope only a few liposomes may remain visible in the outer half of the middle zone, the remainder of the middle and inner zones being apparently free from them (fig. 5). Under higher power, however, numerous extremely fine granules are often still visible in all these cortical cells. The effect in such cases is therefore apparently merely to reduce the liposomes very much in size. In other cases, the liposomes have entirely disappeared. The pigment cells near the corticomedullary zone apparently persist nearly unchanged, contrary to Rondoni and Montagnani ('15), who found a decrease in fasting guinea-pigs.

In striking contrast with the remainder of the cortex is the narrow outer zone, in which the liposomes persist with great tenacity (fig. 5). With the scarlet stain, this zone therefore appears nearly unchanged as a deep reddish band, while the remainder of the cortex appears pale, nearly colorless, or with a pale, diffuse reddish color suggesting some fat-like substance in solution. Osmic preparations give corresponding pictures. In only one case (F 9.3) the outer zone in places appears somewhat broken and irregular. The tenacity of the outer lipoidal zone is not due to any visible difference in the structure or composition of the liposomes in this zone. Landau ('13 b), however, finds that in the fasting guinea-pig, although there is no decrease in the total lipid content, the cholesterin decreases in all but the outer cortical zone. It may be dependent upon the vascular arrangement, as all of the blood to the cortex passes first through the capillaries of this zone (Flint, '00).

The amount of decrease in the liposomes of the suprarenal cortex is usually, but not always, somewhat proportional to the length of the fasting period or to the loss in body weight. In general, the lipoids appear much more resistant to inanition than does the ordinary fat just outside the suprarenal capsule.

The suprarenal medulla is often considerably affected during acute inanition, though usually less so than is the cortex. The cytoplasm frequently becomes more vacuolated, although the characteristic (chromaffin?) granules persist in the parenchyma cells. The nuclei may become more hyperchromatic, and a larger proportion are pycnotic. In many cases the nuclei are hypochromatic, undergoing chromatolysis. Some areas of marked cellular degeneration occur.

The chromaffin reaction is apparently but slightly (if at all) affected by the inanition experiments. The slight variations in the intensity of the brown color are apparently no greater than appear in the normal controls. Even in the rat starved twelve days with loss of 45 per cent in body weight (F 5.2) the chromaffin reaction of the medulla appears fully as intense as in any of the controls. This rat was still active when killed, but the reaction persists in another (F 9.3) which was killed while very weak and near death with a loss of 33 per cent in body weight after ten days of acute inanition (fig. 10).

In only one case (F 6.2) is there a marked decrease, only traces of the chromaffin reaction being present. This was probably a postmortem change, as the rat was found dead. It had lost only 34 per cent in body weight after seven days of inanition. It therefore appears that in adult rats acute inanition produces no appreciable decrease in the chromaffin reaction of the suprarenal medulla, even (aside from postmortem changes) in those starved to death.

Adult chronic inanition. In six adult rats underfed thirty to thirty-five days with gradual loss in body weight amounting to 33 to 38 per cent, the histological changes (in the ordinary preparations) were found in general very similar to those after acute inanition (fig. 9). These include a general atrophy of cells and nuclei with a variable reduction in the amount of lipoids in the middle (but not in the outer) zone (fig. 9, O). There is similarly a pronounced cellular atrophy in the inner zone, and in one case (J 1.5, fig. 9, I) the vacuolated cytoplasm in a few places had apparently disintegrated to form extensive intercellular spaces, similar to the condition described in the human suprarenal by Meyer ('17).

The cells usually undergo simple atrophy, however. Many of the nuclei appear chromatolytic, some pycnotic. There is apparently no change in the number and appearance of the pigment cells, as a rule, although sometimes they appear increased in number (fig. 9, *P*). The changes in the medulla are similar to those noted under acute inanition. The special lipid and chromaffin stains were not employed in the chronic-inanition series.

From the foregoing it appears that during inanition in the albino rat the behavior of the suprarenal lipoids is somewhat variable according to circumstances. In young rats severely stunted by underfeeding there is no apparent loss, the liposomes continuing to differentiate as in the normal gland of corresponding weight. Likewise in older rats there is sometimes no evident decrease, but instead a tendency to more uniform distribution of the liposomes throughout the cortex. This appears characteristic where the inanition has not been carried to extremes. No decrease in suprarenal fat (lipoids) during inanition has also been observed by Frederici ('03) in the guinea-pig, Traina ('04) in man and rabbit, Napp ('05) in man, Kawamura ('11) in man, Landau ('13 b) in man, cat and guinea-pig. Bonnamour ('05 b) even finds an increase in the starved rat, cat, rabbit, and guinea-pig. Ciaccio (according to Landau, '13 b) during inanition found first an increase, with subsequent decrease, in the suprarenal fat content.

In most cases of acute and chronic inanition in the rat, especially in those carried to extremes, there is a well-marked decrease in the suprarenal lipoids, although they are retained in the outer cortical zone with remarkable tenacity in all cases. A decrease in the fat (lipoids) of the suprarenal during inanition has been observed by Orth ('93) in man, Beneke in man and animals, Ewald ('02) in the rabbit, Herman ('05) in man, Ponomarew ('14) in the mouse, and Rondoni and Montagnani ('15) in the guinea-pig. In the latter two investigations, more or less retention of fat in the zona glomerulosa (of mice and guinea-pigs) is mentioned, which would be in agreement with my observations on the rat. A variable decrease in suprarenal fat (lipoids) as a

result of various toxic conditions has been noted by various investigators in man and lower animals. The apparently contradictory results of different observers as to the effect of inanition upon the suprarenal fat (lipoids) is doubtless due to variations in the age, species, and individual animals, as well as to variations in the extent and character of the inanition.

In hibernating gophers, Mann ('16) found no change in the lipid content of the suprarenal. Frederici ('03) found no decrease in hibernating bats, but a progressive decrease is noted by Baroncini and Beretta ('01) and Ciaccio ('10). Bonnamour ('05 b) and Ciaccio ('10) found a decrease in hibernating hedgehogs.

As to the effect of inanition upon the chromaffin reaction of the suprarenal medulla, my results for the rat are more uniform. They indicate that (with rare exceptions in extreme cases, especially in the younger stunted rats) there is no appreciable decrease in the reaction, except as a result of postmortem changes. This is in agreement with the results of Luksch ('05, '11) and Kuriyama ('18), who found no decrease in the epinephrin content of starved rabbits, but contrary to Venulet and Dmitrowsky ('10) in the rabbit, Borberg ('12) in the cat and guinea-pig, Rondoni and Montagnani ('15) in the guinea-pig, and Pellegrini ('16) in the later stages of fasting. In most cases, these positive results were obtained on animals starved to death, and are therefore probably explainable as due to postmortem changes. Effect of anesthetics and acid in the fixative (for example, in the formalin used for Wiesel's mixture) are also possible sources of error, as I have learned by experience.

MORPHOGENESIS OF THE SUPRARENAL GLAND

Some general features in the process of morphogenesis of the suprarenal gland may now be discussed. As is well known (for details in various species compare Poll, ('05), the medulla arises in the embryo in connection with the sympathetic system, and later migrates, usually in the form of multiple, small sympathochromaffin cords or masses, which (in mammals) pass through

the cortical anlage and finally collect in the center of the gland. Here they later become confluent, a few cells ('sympathoblasts') forming the sympathetic ganglion cells, the majority 'phäochromoblasts' or 'chromaffinoblasts') ripening into the characteristic parenchyma of the medulla.

The time at which this confluence of the medulla is finally completed varies in different mammals, but is usually during the late fetal period. In *Echidna*, however, the immigration of the sympatho-chromaffin anlage is greatly delayed, and the suprarenal medulla is not formed until long after birth (Keibel, '04). Also in the new-born mouse (Inaba, '91), cat, dog, and guinea-pig (Soulié, '03) and occasionally even in the human new-born (Starkel and Wegrzynowski, '10; Zuckerlandl, '12), the process is still incomplete and admixture of cortex and medulla persists to a variable extent after birth. In the mouse, Inaba ('91) found the corticomedullary boundary line still indefinite at ten days, but distinct at thirty days.

Soulié ('03) described the confluence of the medulla in the suprarenal of the rat (*Mus decumanus*) as appearing in the 25-mm. fetus. Dewitzky ('12), however, found the suprarenal medulla in the rat very ill defined at birth, becoming distinct at three days and thereafter. This is in general agreement with my observations, although I find the confluence of the medulla in the albino rat to be a gradual process and subject to some individual variation. It is usually completed by the end of the first week. Even in the adult, however, short cords of cortical tissue may occasionally extend into the medulla, as observed by Bonnamour ('05 a) in the rat and rabbit, and small cortical islands occur near the margin of the medulla.

As to the exact manner in which the confluence occurs, but few definite statements appear in the literature. Flint ('00) mentions appearances of pressure atrophy in the cortical strands in the medulla of the suprarenal in the fetal pig, and Soulié ('03) states that the cells of the medulla anlage "etouffent peu à peu les cordons corticaux emprisonnés au stade de pénétration." It seems to be generally assumed, however, as is stated definitely by Inaba ('91) for the mouse, that these cortical cell strands and

masses intermingled with the medulla are finally displaced and squeezed out of the medullary mass. In the rat, at least, there is no evidence that such a displacement occurs. It appears rather that the medulla becomes confluent through degeneration and absorption of the intermingled cortical remnants. This process is difficult to observe in preparations fixed and stained in the usual manner, on which account it is easily overlooked, but it is clearly evident in frozen sections stained with Herxheimer's scarlet red. In such preparations, the stained liposomes reveal the atrophic cortical cells undergoing gradual atrophy and absorption. A careful study of similar preparations would probably show that in other forms the primitive cortical strands in the medulla likewise undergo degeneration and absorption.

The process of absorption of the cortical tissue continues during the postnatal growth and development of the suprarenal gland, associated with the expansion of the medulla. The continued postnatal growth of the medulla has been noted in the rat, cat, rabbit, and guinea-pig by Elliott and Tuckett ('06) and in man by Scheel ('08), Starkel and Wegrzynowski ('10), Thomas ('11), Kern ('11), and others. The continued postnatal increase in the absolute volume of the medulla in the rat is confirmed by the extensive data in the present study.

This expansion of the medulla necessarily involves an encroachment upon the space formerly occupied by cortex. A priori, this might happen in three ways: 1. There might be a corresponding interstitial growth and expansion of the adjacent cortex. This, however, would require continued multiplication and growth of the cells in the inner cortical zone, and numerous observers (as previously shown) agree that postnatal cell division in the inner cortical zone during postnatal growth rarely or never occurs.

2. In the absence of cell division with interstitial growth, the inner cortical zone might remain passive and be mechanically displaced by the expansion of the medulla. Such a displacement, however, would inevitably result in a very marked flattening of the cortical cells on the adjacent surface of the expanding medulla. It cannot be denied that occasionally such a flattening does appear, but it is irregular and inconstant. Indeed the characteristic

irregularity of arrangement of the cell cords in the zona reticularis is perhaps in part due to the pressure of the expanding medulla. In the rat, however, and apparently in other forms, the histological structure of the inner (reticular) zone at the corticomedullary border does not, in general, support the idea of a mechanical displacement by pressure.

3. The remaining possibility is that there is an actual absorption and removal of the cortex at the corticomedullary border. This theory is strongly supported by the available evidence. Hyperemia of the inner cortical zone, absence of cell division and a more or less well-marked cell atrophy with degeneration and pigment formation are (as has been shown) characteristic not only for the rat, but for mammals in general. In most cases, this process of absorption is comparatively slow and inconspicuous, as in the rat, but in the human infant it is more prominent. The extensive degenerative atrophy of the inner cortical zone of the suprarenal in the human new-born, as described by Starkel and Wegrzynowski ('10), Thomas ('11), Kern ('11), Elliott and Armour ('11), Landau ('13 a) and Lewis and Pappenheimer ('16), is therefore not a unique phenomenon, as heretofore supposed. It appears to be merely an exaggeration of the same fundamental process found in the development of the suprarenal in other mammals. It is thus incorrect to claim that nothing similar occurs in the lower animals (Kern, '11; Dewitzky, '12; Landau, '13 a). The erosion of the inner cortical zone is evidently a continuation of the same process of degeneration and absorption of the cortex which removes the cortical strands at the time of the original confluence of the medulla. Minot ('97), on the other hand, believed that the cells of the primitive medulla anlage disappear in the fetus, and agreed with the view of Gottschau ('83) that the permanent medulla is derived by transformation of the suprarenal cortex.

The process of cortical erosion by the medulla may be compared with that of the absorption of the cartilage by the osteogenic tissue in the zone of enchondral ossification. In both cases, small islands of the invaded tissue may persist for variable periods. It is significant that such cortical islands in the medulla

of the suprarenal in animals after the earlier postnatal stages usually occur only in the immediate neighborhood of the corticomedullary border. Those originally in the central portion of the medulla have usually undergone complete absorption. Flint ('00), Pellegrino ('04), and others have described cortical islands in the medulla of the adult suprarenal, and they occur also in the rat; but these probably represent the results of later cortical erosion, rather than persistent embryonic remnants.

The exact nature of this absorptive process is uncertain. It does not appear to be a mere pressure atrophy, due to the expansion of the cortex, although this may be a factor of subordinate importance in the process. It would appear to be rather a chemical process of obscure nature, possibly a result of the contact between the essentially alien cortical and medullary tissues, not yet fully adapted to each other in their comparatively recent phylogenetic association. The observation by Lewis and Pappenheimer ('10) of similar involutinal changes in accessory suprarenals composed of cortical tissue only would seem to invalidate this theory, but this point needs further investigation. It does not appear probable that the absorption of the cortex at the corticomedullary border is of functional significance, as claimed by Gottschau ('93) and Mulon ('02, '03 a, '03 b, '05 a, '05 b, '12).

If the inner zone of the cortex is subject to continued erosion and absorption during the morphogenesis of the suprarenal, it is evident that the zone must be constantly regenerated. As has been previously shown, the abundant evidence in various animals clearly establishes the fact that although during embryonic and fetal periods cell division occurs throughout the cortex, during postnatal development it becomes progressively restricted to the outer region of the cortex in general, and to the zona glomerulosa in particular. There is therefore during the postnatal growth period a continued renewal of the suprarenal cortex, the cytomorphosis of the cells including an origin in or near the outer zone (glomerulosa), a descent through the middle zone (fasciculata), and a final atrophy, absorption and removal in the inner zone (reticularis) at the corticomedullary border. The process

may be compared with the cytomorphosis of the cells of the epidermis, where, however, the process is centrop peripheral instead of peripherocentral in direction.

The weight or volume of the suprarenal gland as a whole, together with the relative volumes of the cortical and medullary constituents, will therefore vary according to the rate of expansion of the medulla, the rate of erosion of the cortex at the inner zone, and the rate of regeneration from the outer zone. Thus the postnatal involution of the inner zone in the human suprarenal is so rapid that it is not fully compensated by regeneration from the outer zone, or by expansion of the medulla; so the gland during the first year actually decreases in weight, as shown by the data of Scheel ('08) Starkel and Wegrzynowski ('10), and others. In the rat the retardation in the growth of the gland during the first week is perhaps explainable upon the same basis. Subsequent changes in the absolute and relative volume of the cortex in the rat and other forms are evidently subject to much variation in different individuals and species. As a rule, however, as in the rat, the medulla appears relatively small in volume in the earlier prenatal stages (during immigration), expands rapidly to a maximum relative size following its confluence (early postnatal stages), and thereafter decreases relatively corresponding to the later more vigorous growth of the cortex (Canalis, '87; Hultgren and Anderson, '99; Soulié, '03; Elliott and Tuckett, '06; Scheel, '08; Starkel and Wegrzynowski, '10; Thomas, '11, and others).

SUMMARY

1. In the new-born rat, the suprarenal cortex and medulla are not yet distinctly separated, the cortical cell strands in the medulla being absorbed during the confluence of the medulla in the first week. During the second and third weeks after birth, the cortex increases from 75 or 80 per cent to about 90 per cent of the entire gland, by volume. It apparently continues to increase relatively to about 93 per cent at ten weeks of age, decreasing slightly in the adult. The medulla increases more slowly in absolute volume, thereby decreasing in relative volume

from 20 or 25 per cent of the gland at one week to 15 per cent at two weeks, 10 per cent at three weeks, and 7 per cent at ten weeks, increasing again slightly in the adult.

2. The relative volumes of cortex and medulla are subject to considerable individual variation. Their ratio shows no distinct difference according to sex and is not materially changed in young rats stunted by underfeeding or in adults subjected to acute or chronic inanition.

3. The vascular stroma (in comparison with parenchyma) normally shows considerable individual variability in relative volume, due chiefly to the varying distention of the blood-vessels. In general, however, there is evidently an increased vascularity upon passing from the outer zone of the cortex (average 13 per cent) toward the medulla (average 28 per cent), with no constant change according to age.

4. The changes in the volume of the vascular stroma during inanition are variable. In general, the stunted young rats show a marked hyperemia in the inner cortical zone, with relative anemia in the middle and outer ones; medulla unchanged. In stunted rats refed one to two weeks, the relative volume of the stroma in general returns toward normal, though the outer zone remains anemic. In adult rats with acute or chronic inanition the inner and middle cortical zones appear hyperemic, the medulla relatively anemic.

5. With the exception of the first week, there is in general an increase in the size of the suprarenal parenchyma cells from birth to ten weeks of age, with little or no increase thereafter. The average change in cell diameter for the various zones between birth and maturity is as follows: outer zone, 7 μ to 9 μ ; middle zone (outer portion), 9 μ to 15 μ ; middle zone (inner portion), 9 μ to 12 μ ; inner zone remains about 9 μ ; medulla, 8 μ to 16 μ .

6. The nuclei increase slightly in diameter during postnatal life, excepting those of the inner cortical zone. The cytoplasmic increase is much greater, however, so the nuclei in general lag behind in relative size (nucleus-plasma ratio). Thus the relative nuclear volume decreases, in the outer cortical zone, from about 44 per cent of the cell volume in the new-born to 23 per cent in

the adult; in the middle zone (outer part) from 33 per cent to 10 per cent; in the middle zone (inner part) from 28 per cent to 16 per cent; in the inner cortical zone from 28 per cent to 21 per cent; in the medulla from 46 per cent to 10 per cent.

7. In the underfed young rats stunted three to ten weeks or more, the suprarenal cells may increase in size (outer part of middle zone), or decrease (inner cortical zone and inner part of middle zone), or remain nearly unchanged. The nuclei are similarly variable, with slight changes in the relative volume. In the stunted rats refed one or two weeks, the cells and nuclei in general approach, but have not yet reached, their normal size.

8. In adult acute inanition there is but little change in the size of the cells and nuclei in the outer and inner cortical zones. In the middle zone and medulla, however, there is a marked loss in size of the cells, though but slight loss in the nuclei (with corresponding increase in relative nuclear volume). In chronic adult inanition there is a greater decrease in the size of the outer- and middle-zone cells, but about the same as during acute inanition in the inner zone and medulla. The nuclear loss is somewhat greater than during acute inanition, with relative nuclear volume not very different from normal, except in the middle zone (where it is high).

9. Amitosis in the suprarenal of the rat is infrequent and of doubtful significance. Mitoses are frequent in the new-born (average about 20 per section), but fewer at the end of the first week (10 per section). They increase to a maximum rate during the second and third weeks, slowly decreasing in number thereafter, although occasionally found even in the adult. Mitoses are most frequent in the outer zone and outermost part of the middle zone (these forming the 'germinative zone,') less frequent in the medulla, and rare in the inner cortical zone.

10. In young rats stunted by underfeeding, mitosis is more or less completely suppressed in the suprarenal. On refeeding one week, mitosis begins again, and in two weeks the normal rate is reestablished. Cell division in the suprarenal is therefore controlled by the amount of nutrition.

11. The three cortical zones of the suprarenal are distinguishable from birth and well differentiated at three weeks. Liposomes (lipoidal granules or droplets) are present in considerable amount at birth, being rather uniformly distributed through the cortex and the cortical strands through the medulla. They increase slowly rather and the distribution changes. They become more abundant in the outer zone and outer half of the middle zone, decreasing in amount toward the inner zone, with none in the medulla. The inner cortical zone is atrophic in character, with cells in various stages of degeneration and absorption. Pigment (lipochrome) appears in these cells after eight weeks of age. The degeneration and absorption of this zone is associated with the expansion of the medulla in the morphogenesis of the suprarenal gland. The absorption of the inner cortical zone during the growth of the suprarenal is characteristic for mammals, though greatly exaggerated in the human infant. The chromaffin reaction of the medulla is weak at birth, becoming well marked in the rat after the age of three weeks.

12. In the young rats stunted by underfeeding certain cell changes occur in the suprarenal. The cortex tends to undergo the normal differentiation of liposomes, but their amount is variable. In some cases many of the cells appear atrophic and degenerative, especially toward the inner cortical zone, where the process is extreme. Pigment appears in unusual abundance. The medulla is usually less affected, although pycnotic nuclei frequently occur. Only in extreme cases is there any appreciable decrease in the chromaffin reaction. In stunted rats refed two weeks the structure is already gaining a normal appearance, though some areas of degeneration persist.

13. In adult rats subjected to acute or chronic inanition the suprarenal cells present a simple atrophy, together with a variable amount of degeneration. The nuclei may be either hypochromatic or hyperchromatic, with frequent pycnosis or karyolysis. The liposomes are retained tenaciously in the outer zone, though usually decreased to a considerable extent in the rest of the cortex, especially in extreme inanition. The pigment remains unchanged. The medulla cells show degenerative changes,

though usually less marked than those of the cortex. The chromaffin reaction is apparently retained undiminished up to the point of death, though occurring as a postmortem change.

LITERATURE CITED

- BABES, V., ET JONESCO, V. 1908 Distribution de la graisse dans les capsules surrénales. C. R. Soc. Biol. Paris, T. 65, Ann. (1908, T. 2).
- BAGER, BERTEL 1917 Bidrag till binjurarnas aldersanatomi hos kaninen. (Zur Altersanatomie der Nebennieren des Kaninchens.) Uppsala Läkareförenings Förhandlingar. Ny. följd., Bd. 23, H. 1-2, S. 48-116.
- BARBÈRA, A. G., E BICCI, D. 1900 Contributo istologico alla conoscenza delle modificazioni che il digiuno apporta negli elementi anatomici dei vari organi e tessuti del l'economia animal. Prima nota: Capsule soprarrenali. Bollettino delle scienze mediche. Società Medico-Chirurgica e della Scuola Medica di Bologna. Anno 71, Serie 7, vol. 11, pp. 679-682.
- BARONCINI, L., E BERETTA, A. 1901 Ricerche istologiche sulle modificazioni degli organi mammiferi ibernanti. IV. Capsule surrenali (Nota preventiva). Lo Riforma Medica, Anno 16, pp. 162-163; Anno 17, pp. 76-78.
- BELL, E. T. 1910 The staining of fats in epithelium and muscle fibers. Anat. Rec., vol. 4, no. 5, pp. 199-212.
- BENEKE ——— Pathologische Anatomie der Nebennieren, in Zülzer's Handbuch der Harn- und Geschlechtsorgane. (Cited by Ewald, '02.)
- BIEDL, A. 1913 Innere Sekretion. 2 Aufl., 2 Abth. (S. 16).
- BONNAMOUR, S. 1905 a Étude histologique des phénomènes de sécrétion de la capsule surrénale chez les mammifères. Thèse, Lyon.
1905 b Modifications histologiques de la capsule surrénale dans certains états physiologiques (hibernation, inanition) et pathologiques expérimentaux (diphthérie, rage). C. R. de l'Assoc. des Anatomistes (Int. Congr. Anat. Geneva, 1905), vol. 7, pp. 87-93.
- BORBERG 1912 Das chromaffine Gewebe. Nebennierenuntersuchungen. II. Skand. Archiv f. Physiol., Bd. 28, S. 91. (Cited by Biedl, '13.)
- CANALIS, P. 1887 Contribution à l'étude du développement et de la pathologie des capsules surrénales. Jour. internat. mens. d'anatomie et de physiol. (Int. Monatschr.), T. 4, pp. 312-333.
- CIACCIO, C. 1903 Ricerche sui processi di secrezione cellulare nelle capsule surrenali dei vertebrati. Anat. Anz., Bd. 23, S. 401-424.
1905 Sur la fine structure et sur les fonctions des capsules surrénales des vertébrés. Arch. ital. de biol. T., 43.
1910 Contributo alla distribuzione ed alla fisio-patologia cellulare dei lipoidi. Arch. f. Zellforschung, Bd. 5, S. 235-363.

- COTTENTOT, MULON, ET ZIMMERN 1912 Action des rayons X sur la corticale surrénale. C. R. Soc. Biol. Paris, T. 73, pp. 717-720.
- CRISTIANI, M. ET MME. 1902 Histologie pathologique des greffes de capsules surrénales. C. R. Soc. Biol. Paris, T. 54, pp. 811-814.
- DA COSTA, A. C. 1913 Recherches sur l'histo-physiologie des glandes surrénales. Archives de Biol., T. 28, p. 111-196.
- DELAMARE, G. 1903 Recherches sur la sénescence de la glande surrénale. C. R. Soc. Biol. Paris, T. 55, pp. 1152-1154.
- DEWITZKY, W. 1912 Beiträge zur Histologie der Nebennieren. Ziegler's Beiträge, Bd. 52, S. 431-443.
- DONALDSON, H. H. 1915 The rat. Reference tables and data. Memoirs of The Wistar Institute, no. 6, Philadelphia.
- DOSTOIEWSKY, A. 1886 Ein Beitrag zur mikroskopischen Anatomie der Nebennieren bei Säugethieren. Archiv f. mikr. Anat., Bd. 27, S. 272-296.
- ELLIOTT, T. R., AND ARMOUR, R. G. 1911 The development of the cortex in the human suprarenal gland and its condition in hemicephaly. Jour. of Path. and Bact., vol. 15, pp. 481-488.
- ELLIOTT, T. R., AND TUCKETT, I. 1906 Cortex and medulla in the suprarenal glands. Jour. Physiol., vol. 34, no. 4-5.
- EWALD, PAUL 1902 Über Fettgehalt und multiple Adenombildung in der Nebenniere. Inaug.-Dissert. München.
- FLINT, J. M. 1900 The blood-vessels, angiogenesis, organogenesis, reticulum and histology of the adrenal. Johns Hopkins Hosp. Rep., vol. 9, pp. 153-230.
- FREDERICI 1903 Lo sperimentale (cited, without title, by Ciaccio, '10).
- GOTTSCHAU, M. 1883 Structur und embryonale Entwicklung der Nebennieren bei Säugethieren. Archiv f. Anat. u. Physiol., Anat. Abth., S. 412-458.
- GRAHAM, G. S. 1916 Toxic lesions of the adrenal gland and their repair. Jour. Med. Research, vol. 34, pp. 241-261.
- HATAI, S. 1913 On the weights of the abdominal and the thoracic viscera, the sex glands, ductless glands and the eyeballs of the albino rat (*Mus norvegicus albinus*) according to body weight. Am. Jour. Anat., vol. 15, no. 1.
- HERMAN 1905 Über Vorkommen und Veränderungen von Myelinsubstanz in der Nebenniere. Inaug.-Dissert. Tübingen. (Cited by Kawamura, '11.)
- HORNOWSKI, J. 1909 Veränderungen im Chromaffinsystem bei unaufgeklärten postoperativen Todesfällen. Virchow's Archiv, Bd. 198.
- HOSKINS, E. R. 1916 The growth of the body and organs of the albino rat as affected by feeding various ductless glands (thyroid, thymus, hypophysis and pineal). Jour. Exper. Zool., vol. 21, no. 3.
- HULTGREN UND ANDERSON 1899 Studien über die Physiologie und Anatomie der Nebennieren. Skand. Arch. f. Physiol., Bd. 9, S. 73-311.
- INABA, M. 1891 Notes on the development of the suprarenal bodies in the mouse. Jour. College of Science, Imp. Univ. Japan, vol. 4, part 1, pp. 215-235.

- JACKSON, C. M. 1913 Postnatal growth and variability of the body and of the various organs in the albino rat. *Am. Jour. Anat.*, vol. 15, pp. 1-68.
- 1915 a Effects of acute and chronic inanition upon the relative weights of the various organs and systems of adult albino rats. *Am. Jour. Anat.*, vol. 18, pp. 75-116.
- 1915 b Changes in the relative weights of the various parts, systems and organs of young albino rats held at constant body weight by underfeeding for various periods. *Jour. Exper. Zool.*, vol. 19, pp. 99-156.
- 1917 Effects of inanition and refeeding upon the growth and structure of the hypophysis in the albino rat. *Am. Jour. Anat.*, vol. 21, pp. 321-358.
- KAWAMURA, R. 1911 Die Cholesterinester-Verfettung (Cholesterinsteatose). Ein differentialdiagnostische morphologische Studie über die in den menschlichen und tierischen Geweben vorkommenden Lipoide. Verlag G. Fischer, Jena.
- KEIBEL, F. 1904 Zoologische Forschungsreisen in Australien und dem Malayischen Archipel von Richard Semon, Bd. 3. Monotremen und Marsupialer, II. 2. Teil, S. 151-206. (Cited by Poll, '05.)
- KERN, H. 1911 Über den Umbau der Nebenniere im extrauterinen Leben. *Deutsche med. Wochenschr.*, Bd. 37, S. 971-974; 1180; 1318-1319.
- KOLMER, W. 1912 a Über gewisse physiologisch-histologische Vorgänge in der Nebenniere und deren Beziehung zum Genitalapparat. *Zentralbl. f. Physiol.*, Bd. 25, S. 1009.
- 1912 b Beziehung von Nebenniere und Geschlechtsfunktion. *Pflüger's Archiv*, Bd. 144, S. 361-395.
- KURIYAMA, S. 1918 The adrenals in relation to carbohydrate metabolism. III. The epinephrin content of the adrenals in various experimental conditions. *Jour. Biol. Chem.*, vol. 34, pp. 299-319.
- LANDAU, M. 1913 a Zur Entwicklung der Nebennierenrinde. *Deutsche med. Wochenschr.*, Bd. 39, no. 7, Feb. 13.
- 1913 b Nebenniere und Fettstoffwechsel. *Deutsche med. Wochenschr.*, Bd. 39, no. 12, May 20.
- LEWIS, R. W., AND PAPPENHEIMER, A. M. 1916 A study of the involutinal changes which occur in the adrenal cortex during infancy. *Jour. Med. Research*, vol. 34, pp. 81-93.
- LUKSCH, F. 1911 Über das histologische und funktionelle Verhalten der Nebennieren beim hungernden Kaninchen. *Arch. f. exper. Path. u. Pharm.*, Bd. 65, S. 161-163.
- MANN, F. C. 1916 The ductless glands and hibernation. *Amer. Jour. Physiol.* vol. 41, no. 2.
- MARTINOTTI, C. 1892 Contributo allo studio delle capsule surrenale. *Giornale della R. Accad. di Med. di Torino. Serie III.*, vol. 40, pp. 299-301.
- MAYER, MULON, ET SCHAEFFER 1912 Contribution à la microchimie des surrénales. I. Recherches sur les surrénales du cheval. *C. R. Soc. Biol. Paris*, T. 73, pp. 313-315. II. Recherches sur les surrénales de mouton. *Ibid.*, pp. 315-318.

- MEYER, A. W. 1917 Some morphological effects of prolonged inanition. *Jour. Med. Research*, vol. 36, pp. 51-78.
- MINOT, C. S. 1897 *Human embryology*. New York.
- MULON, P. 1902 Excretion des capsules surrénales du cobaye dans les vaisseaux sanguins. *C. R. Soc. Biol. Paris*, T. 54, pp. 1540-1542.
- 1903 a Sur le pigment des capsules surrénales chez le cobaye. *C. R. de l'Assoc. des Anat.*, T. 5, pp. 143-151.
- 1903 b Divisions nucléaires et rôle germinatif de la couche glomérulaire des capsules surrénales du cobaye. *C. R. Soc. Biol.*, Paris, T. 55, pp. 592-595.
- 1905 a Évolution de la corticale surrénale du cobaye avec l'âge de l'animal. *C. R. Soc. Biol. Paris*, T. 59 (1905, T. 2), pp. 337-339. (Cf. also pp. 592-593.)
- 1905 b Sur le pigment des capsules surrénales (Cobaye). *Bibl. Anat.* T. 14, pp. 177-182.
- 1912 La corticale surrénale du chien. *C. R. Soc. Biol. Paris*, T. 73, pp. 714-716.
- NAPP, O. 1905 Über den Fettgehalt der Nebenniere. *Virchow's Archiv*, Bd. 182, S. 314-326.
- ORTH, J. 1893 *Lehrbuch der path. Anat.*, Bd. 2.
- PELLEGRINI, R. 1916 (Effect of fasting on the suprarenals.) *Atti r. Inst. Veneto*, vol. 72, p. 781. (Cited from 'Chemical Abstracts' in *Endocrinology*, vol. 1, no. 3, 1917, p. 354.)
- PELLEGRINO, M. 1904 Sopra una particolare disposizione della sostanze midollare nelle capsule surrenali (mammiferi). *Bollet. d. Soc. di Nat. in Napoli*, Anno 18, Série I, pp. 139-142. (Cited by Poll, '05, and Da Costa, '13.)
- PFAUNDLER, M. 1892 Zur Anatomie der Nebenniere. *Sitzungsber. d. k. Akad. d. Wiss. in Wien. Math.-Naturw. Classe*, Bd. 101, Abth. 3, S. 515-533.
- POLL, H. 1899 Veränderungen der Nebenniere bei Transplantation. *Archiv f. mikr. Anat.*, Bd. 54, p. 440-481.
- 1905 Die Entwicklung der Nebennierensysteme, in Hertwig's *Handbuch der Entwicklungslehre der Wirbeltiere*. Bd. 3, Teil 1.
- PONOMAREW, A. 1914 Über den Ursprung der Fettsubstanzen in der Nebennierenrinde. *Ziegler's Beiträge*, Bd. 59, H. 2. (Reviewed in *Zentralblatt f. norm. Anat. u. Mikrotechnik*, Bd. 11, H. 12, 1914.)
- RONDONI, P. E MONTAGNANI, M. 1915 Lesioni istologiche nel maidsimo, nel digiuno e nello scorbuto sperimentale. *Lo sperimentale*, Anno 69, pp. 659-696.
- ROUD, AUG. 1902 Contribution à l'étude du développement de la capsule surrénale de la souris. *Bull. de la soc. vaudoise des sc. nat.*, T. 38, pp. 187-258. (Cited from *Jahresbericht f. Anat.*, volume for 1903, and Poll, '05.)
- SCHEEL, O. 1908 Über Nebennieren. Sekretkörnchen-Oedem-Gewicht. *Virchow's Archiv*, Bd. 192, S. 494-513.
- SCHUR, H., UND WIESEL, J. 1908 Über das Verhalten des chromaffinen Gewebes bei der Narcose. *Wiener klin. Wochenschr.*, Jahrg. 21, No. 8.

- SOULIÉ, A. H. 1903 Recherches sur le développement des capsules surrénales chez les vertébrés supérieurs. *Jour. de l'anat. et de la physiol.*, T. 39, pp. 197-293; 492-533; 634-662.
- STARKEL, S., UND WĘGRZYŃSKI, L. 1910 Beitrag zur Histologie der Nebenniere bei Feten und Kindern. *Arch. f. Anat. u. Physiol., Anat. Abth.*, S. 214-326. (Also (Polish) *Medycyna* Warschau, reviewed by Hoyer in *Jahresbericht f. Anat.* for 1910, III, p. 461-462.)
- STEWART, C. A. 1916 Growth of the body and of the various organs of young albino rats after inanition for various periods. *Biol. Bull.*, vol. 31, pp. 16-51.
- THOMAS, E. 1911 Über die Nebenniere des Kindes und ihre Veränderungen bei Infektionskrankheiten. *Ziegler's Beiträge*, Bd. 50, S. 283-316.
- TRAINA, R. 1904 Über das Verhalten des Fettes und der Zellgranula bei chronischem Marasmus und akuten Hungerszuständen. *Ziegler's Beiträge*, Bd. 35, S. 1-92.
- VENULET, F., UND DMITROWSKY, G. 1910 Über das Verhalten der chromaffinen Substanz der Nebennieren beim Hungern und unter dem Einfluss von Iodkali. *Archiv. f. exper. Path. u. Pharm.*, Bd. 63, S. 460-464.
- WIESEL, J. 1901 Über die Entwicklung der Nebenniere des Schweines, besonders der Marksubstanz. *Anat. Hefte*, Bd. 16, S. 117-150.
1902 Zur Entwicklung der menschlichen Nebenniere. *Centralbl. f. Phys.*, Bd. 15, *Verh. d. Morphol.-Physiol. Gesellsch. zu Wien* (1901), S. 614-615.
- ZUCKERKANDL, E. 1912 The development of the chromaffin organs and of the suprarenal glands. In Kiebel and Mall's *Human Embryology*, vol. 2.

TABLE 1

Individual number, age and condition, sex, body length, body weight and weight of the suprarenal glands in the albino rats used for histological study

RAT NO.	AGE, ETC.	SEX	NOSE-ANUS LENGTH	BODY WEIGHT GROSS (OR NET)	WEIGHT OF SUPRA-RENALS	SEE NOTE
<i>A. Normal rats</i>						
			<i>mm.</i>	<i>grams</i>	<i>grams</i>	
F 10.1	New-born	m.	46	4.2	0.0014	*
F 10.2	1 day	m.	50	4.8	0.0014	*
J 1.7a	New-born	m.		4.9		
J 1.7b	New-born	m.		4.9		
F 8.1	New-born	m.	50	5.1	0.0018	*
F 11.1	3 days	m.	57	6.5	0.0020	*
F 11.2	5 days	f.	60	8.3	0.0020	*
F 11.3	8 days	m.	64	9.6	0.0018	*
St 72.5	7 days	f.	66	10.8 (10.1)	0.0024	
St 72.2	7 days	m.	66	10.8 (10.0)	0.0024	
V 13.1	10 days	m.		12.0	0.0030	
St 80.5	12 days	f.	75	15.5	0.0040	
V 1.3	14 days	m.	75	15.4		
F 7.1	17 days	f.	86	26.3	0.0054	*
V 1.4	21 days	m.	87	20.4		
S 5.2	21 days	f.	95	22.9 (21.1)	0.0100	
J 1.2	21 days	f.	100	28.2	0.0078	
J 1.1	21 days	m.	100	29.0	0.0078	
St 47.2	21 days	m.	102	34.3	0.0134	
St 5.1	56 days	f.		63.0	0.0116	
St 5.2	56 days	m.		77.0	0.0182	
St 228.2	58 days	m.	156	96.0	0.0183	*
St 47.6	67 days	f.	169	124.0	0.0364	
St 47.5	67 days	m.	191	196.0	0.0326	
H 70.3	70 days	m.	194	208.0	0.0357	
H 68.11	72 days	m.	192	171.0 (164)	0.0228	
H 68.8	74 days	f.	184	142.0 (137)	0.0339	
S 5.4	74 days	f.	168	126.0 (118)	0.0319	
S 5.3	74 days	m.	180	172.0 (167)	0.0289	
M 1.2	74 days	m.	190	181.0 (173)	0.0264	
J 1.3	94 days	m.	183	177.0	0.0249	
H 64.3	101 days	m.	191	185.0 (179)	0.0264	
H 60.7	103 days	f.	203	(182)	0.0302	
F 5.1	105 days	m.	188	192.0	0.0234	*
H 58.3	106 days	m.	225	(258)	0.0404	
J 1.7	112 days	f.	185	161.0	0.0365	(1)
F 2.1	116 days	m.	176	149.0	0.0268	*
Mo. 9	120 days	f.	180	157.0		
H 36.3	138 days	m.	202	(202)	0.0406	
H 50.3	141 days	m.	211	(222)	0.0406	

TABLE 1—Continued

RAT NO.	AGE, ETC.	SEX	NOSE- ANUS / LENGTH	BODY WEIGHT GROSS (OR NET)	WEIGHT OF SUPRA- RENALS	SEE NOTE
			<i>mm.</i>	<i>grams</i>	<i>grams</i>	
F 1.1	141 days	m.	195	200.0	0.0234	*
F 9.1	170 days	m.	185	173.0	0.0246	*
F 6.1	150 days	m.	188	178.0	0.0290	*
S 14	(adult)	m.	205	252.0 (247)	0.0414	
H 21.3	202 days	m.	216	(232)	0.0304	
H 34.3	224 days	f.	194	(173)	0.0453	
H 34.6	225 days	f.	205	(188)	0.0604	
L 3.7	234 days	m.	190	241.0 (238)	0.0310	
H 27.3	253 days	f.	195	(166)	0.0475	
H 27.6	254 days	m.	214	(222)	0.0298	
S 33.116	340 days	f.	195	194.0 (188)	0.0414	
S 33.117	346 days	m.	228	302.0 (294)	0.0330	

B. Stunted young rats

St 247.5	Maint. 1-7 days	f.	53	4.5	0.0016	*(2)
St 80.9	Underfed 1-12 days	f.	64	8.9	0.0026	(2)
St 228.4	Underfed 1-58 days	m.	74	10.9	0.0054	*(2)
St 9.36	Maint. 21-51 days	m.	113	30.5	0.0124	(2)
S 12.69	Maint. 21-66 days	f.	100	24.5 (22.7)	0.0090	(2)
St 47.4	Maint. 21-66 days	m.	113	32.3	0.0140	(2)
St 47.3	Maint. 21-66 days	m.	120	34.0	0.0136	(2)
S 12.71	Maint. 21-67 days	m.	95	23.3 (21.2)	0.0086	(2)
S 7.34	Maint. 21-70 days	m.	115	30.5 (29.0)	0.0116	(2)
S 7.31	Maint. 21-70 days	m.	120	34.8 (31.4)	0.0126	(2)
S 7.32	Maint. 21-71 days	m.	120	30.0 (28.8)	0.0100	(2)
S 7.35	Maint. 21-71 days	f.	117	35.3 (31.0)	0.0120	(2)
S 11.65	Maint. 21-73 days	m.	100	23.8 (22.5)	0.0118	(2)
St 12.50	Maint. 21-82 days	m.	123	45.0 (41.2)		(2)
St 33.1	Maint. 22-104 days	f.	89	19.1 (18.2)	0.0086	(2)
St 38.8	Maint. 21-139 days	m.	118	30.0	0.0161	(2)

C. Refed after inanition

St 12.48	88 days Refed 7 days	f.	125	50.2 (46.5)	0.0105	(3)
St 11.42	88 days Refed 7 days	f.	125	55.0 (50.3)	0.0160	(3)
St 11.45	88 days Refed 7 days	f.	130	67.6 (57.7)	0.0156	(3)
St 10.27	89 days Refed 7 days	f.	127	55.0 (51.4)	0.0115	(3)
St 12.51	95 days Refed 14 days	f.	137	77.2 (70.7)	0.0150	(3)
St 11.43	95 days Refed 14 days	f.	143	79.0 (74.7)	0.0196	(3)
St 11.40	95 days Refed 14 days	f.	142	84.5 (76.5)	0.0158	(3)
St 10.26	96 days Refed 14 days	m.	150	91.0 (86.3)	0.0180	(3)
F 2.3	122 days Refed 6 days	m.	176	144.0	0.0350	*(3)
S 33.120	339 days Refed 189 days	f.	181	162.0 (156)	0.0396	(3)
S 33.118	346 days Refed 206 days	m.	204	229.0 (219)	0.0348	(3)

TABLE 1—*Concluded*

RAT NO.	AGE, ETC.	SEX	NOSE-ANUS LENGTH	BODY WEIGHT GROSS (OR NET)	WEIGHT OF SUPRA-RENALS	SEE NOTE
<i>D. Adult acute inanition</i>						
			<i>mm.</i>	<i>grams</i>	<i>grams</i>	
F 2.2	116 days (loss 29%)	m.	173	104.0	0.0316	*(4)
F 1.2	147 days (loss 30%)	m.	188	162.0	0.0374	*(4)
S 27	(loss 30%)	m.	215	223.0 (219)	0.0424	(4)
M 2	(loss 33%)	m.	185 (?)	170.0 (167)	0.0338	(4)
F 9.3	170 days (loss 33%)	m.	179	129.0	0.0334	*(4)
F 6.2	151 days (loss 34%)	m.	183	114.0	0.0422	*(4)
F 3.2	130 days (loss 34%)	m.	171	115.0	0.0280	*(4)
J 1.4	94 days (loss 35%)	m.	180	107.0	0.0302	(4)
S 25	(loss 35%)	m.	205	202.0 (198)	0.0458	(4)
F 9.2	170 days (loss 36%)	m.	191	127.0	0.0374	*(4)
S 26	(loss 39%)	m.	205	174.0 (171)	0.0233	(4)
F 4.2	153 days (loss 43%)	m.	172	103.0	0.0332	*(4)
F 5.2	105 days (loss 45%)	m.	185	110.0	0.0318	*(4)
<i>E. Adult chronic inanition</i>						
J 1.5	117 days (loss 34%)	m.	175	97.0	0.0240	(5)
M 3	(loss 34%)	m.	175	125.0 (122)	0.0252	(5)
M 12	(loss 36%)	m.	173	128.0 (125)	0.0306	(5)
M 5	(loss 37%)	m.	190	129.0 (127)	0.0320	(5)
M 6	(loss 37%)	m.	175	138.0 (134)	0.0270	(5)
M 11	(loss 38%)	m.	190	163.0 (159)	0.0322	(5)

* The 'F' series, and a few others as indicated, were cut by frozen sections for study in the fresh condition, or for lipoids, chromaffin reaction, etc. All of the remaining glands were embedded and cut in paraffin sections.

¹ Rat J 1.7 had just given birth to a (first) litter. The remaining females were virgins.

² Of the stunted rats (table 1 B), St 80.9 and St 228.4 had practically doubled their initial weight during the period of underfeeding. The others were held nearly at maintenance (constant body weight) during the period indicated.

³ Of the rats refed after inanition (table 1 C), all excepting the last three were refed after having been held nearly at maintenance from three to about twelve weeks of age. S 33.118 and S 33.120 had been held with but slight increase in body weight from 21 to 140 and 150 days of age, respectively, and were apparently permanently stunted. Rat F 2.3 decreased from 151 grams to 104 grams (loss of 31 per cent) during seven days of acute inanition, and was then refed as indicated.

⁴ The rats subjected to acute inanition (table 1 D) had been given water only for periods varying from seven to twelve days, with loss in body weight as indicated. In four cases the age was unknown. The final body weights are given in the table.

⁵ The rats with chronic inanition (table 1 E) had been fed gradually decreasing amounts of food during a period of about five weeks, with losses in body weight as indicated. The final body weights are given. The age was unknown in all but the first rat.

TABLE 2

Postnatal growth of volume in suprarenal cortex and medulla in the albino rat

AGE AND CONDITION	NUMBER ¹ AND SEX	GROSS BODY WEIGHT AVER- AGE	SUPRA- RENALS WEIGHT AVERAGE	SUPRA- RENALS PER CENT OF BODY WEIGHT AVERAGE	PERCENTAGE FORMED BY THE	
					Cortex aver- age	Medulla, average (and range)
<i>A. Normal</i>						
		<i>grams</i>	<i>grams</i>	<i>per cent</i>	<i>per cent</i>	<i>per cent</i>
7 days.....	1 m	10.8	0.0024	0.025	74.5	25.5
7 days.....	2 f	10.8	0.0024	0.023	79.8	20.4 (18.6-21.7)
10-14 days.....	3 m	13.7	(0.0031)	(0.019)	80.9	19.1 (16.8-22.3)
10-14 days.....	2 f	15.5	0.0040	0.026	84.3	15.7 (15.3-16.4)
21 days.....	5 m	27.9	0.0106	0.033	90.6	9.4 (8.5-10.8)
21 days.....	2 f	28.2	0.0078	0.028	89.5	10.5 (10.0-11.0)
56 days.....	2 m	77.0	0.0182	0.024	92.3	7.7 (7.4-8.1)
56 days.....	1 f	63.0	0.0116	0.018	82.7	17.3
67-74 days.....	3 m	180.3	0.0218	0.012	92.8	7.2 (5.8-8.0)
67-74 days.....	3 f	132.6	0.0414	0.032	93.5	6.5 (5.3-7.2)
94-346 days.....	8 m	220.1	0.0322	0.015	89.9	10.1 (6-16)
112-253 days.....	4 f	161.1	0.0426	0.027	90.9	9.1 (7.0-11.9)
<i>B. Effect of experiments</i>						
Underfed 1-12 days.....	2 f	8.9	0.0026	0.029	79.3	20.6 (18.6-22.7)
Maintenance 21-51 days.	1 m	30.5	0.0124	0.040	90.2	9.8
Maintenance 3-10 weeks.	7 m	34.1	0.0131	0.041	89.8	10.2 (8.7-12.5)
	1 f					
Maintenance 21-82 days.	2 m	45.0			88.2	11.8 (11.4-12.2)
Maintenance 21-139 days	1 m	30.0	0.0161	0.054	89.3	10.7
Refed 1 week.....	6 f	57.6	0.0125	0.024	89.4	10.6 (9.6-11.6)
Refed 2 weeks.....	1 m	82.9	0.0171	0.022	90.4	9.6 (8.8-11.1)
	5 f					
Refed 189 days.....	2 f	162.0	0.0396	0.024	85.7	14.3 (13.4-15.3)
Refed 206 days.....	2 m	229.0	0.0348	0.016	90.8	9.2 (9.0-9.4)
Adult acute inanition...	6 m	177.3	0.0393	0.024	90.1	9.9 (5.8-12.8)
Adult chronic inanition.	9 m	123.4	0.0278	0.023	88.7	11.3 (8.1-13.1)

¹ The 'No.' in the second column refers to number of glands, not animals. The suprarenal weights were missing in one of the three normal males at ten to fourteen days.

TABLE 3
Average relative volumes of the stroma and vessels in the various zones of the cortex and medulla in the suprarenal gland of the albino rat

AGE AND CONDITION	NUM- BER OF GLANDS	AVERAGE PERCENTAGE OF VASCULAR STROMA IN ZONES OF SUPRARENAL CORTEX				
		Outer zone <i>per cent</i>	Middle (outer half) <i>per cent</i>	Middle (inner half) <i>per cent</i>	Inner zone <i>per cent</i>	Medulla <i>per cent</i>
Normal 1-14 days.....	3	14.4 (12.1-18.5)	8.4 (6-9.4)	8.4 (6-9.4) ¹	18.1 (13.4-18.7)	32.8 (27.-37.6)
Normal 3 weeks to adult.....	5	13.2 (11.1-15.0)	8.6 (5.8-13.5)	12.5 (10-16.7)	19.1 (10.4-23.3)	27.7 (19.8-33.5)
Maintenance from 3 weeks.....	5	10.6 (8.9-12.8)	6.4 (4.4-8.6)	9.0 (7.5-10.4)	28.0 (16.7-39.9)	29.7 (16.2-44.1)
Refed 1 week after maintenance.....	2	6.2 (5.1-7.4)	9.2 (8.6-9.8)	10.4 (7.2-13.6)	15.6 (12.5-18.6)	19.9 (12.4-27.4)
Refed two weeks after maintenance.....	2	9.3 (7.8-10.8)	14.3 (8.4-20.3)	9.6 (8.4-10.8)	21.1 (18-24.3)	23.4 (22.5-24.2)
Adult acute inanition...	4	12.4 (6.4-15.2)	12.6 (8.4-18.1)	16.9 (13.1-26.4)	22.2 (14.0-30.8)	23.5 (16.5-36)
Adult chronic inanition...	2	12.4 (12.3-12.6)	13.5 (10-17.1)	24.6 (23-26.2)	23.7 (21.8-25.6)	16.2 (12.4-20)

¹ In normal group of one to fourteen days the outer and inner portions of the middle zone were not measured separately.

TABLE 5

Mitoses in the suprarenal gland of the albino rat

AGE AND CONDITION	NUM- BER OF GLANDS	AVERAGE NUMBER OF MITOSES PER SECTION IN				
		Outer zone	Middle zone	Inner zone	Me- dulla	Total average (and range)
<i>A. In normal rats</i>						
New-born.....	3	11	2	1	6	20 (12-29)
7 days.....	3	5	2	$\frac{1}{3}$	3	10 (7-13)
10 days.....	2	6	5	$\frac{1}{2}$	4	16 (14-18)
12 days.....	1	18	17	0	5	40
14 days.....	2	10	10	$\frac{1}{2}$	6	27 (22-31)
21 days.....	9	9	12	$\frac{1}{3}$	2	24 (10-41)
56 days.....	1	3	5	0	3	11
67-94 days.....	4	2	2	$\frac{1}{4}$	0	4 (2-5)
112-138 days.....	2	1	1	0	0	2 (1-3)
340 days.....	1	1	0	0	0	1
<i>B. In test rats</i>						
Maintenance birth to 12 days.....	1	1	1	0	2	4
Maintenance 3-10 weeks.....	10 ¹	$\frac{3}{5}$	$\frac{1}{2}$	0	0	1 (0-3)
Maintenance 3-12 to 20 weeks.....	3	0	0	0	0	0
Refed 1 week.....	3	$\frac{1}{3}$	1	0	$\frac{1}{3}$	2 (1-3)
Refed 2 weeks.....	2	3	5	0	2	10 (7-12)
Refed to 1 year.....	1	0	0	0	0	0

¹ Six of the ten held at maintenance from three to ten weeks of age showed no mitoses in the sections examined.

S 27	Adult acute inanition.....	9.9	11.8	9.0	8.3	13.7	6.1	6.4	5.6	5.2	6.7	23.1	16.0	23.5	24.5	11.9
J 1.4	Adult acute inanition.....	8.7	11.3	8.7	8.0	11.7	6.2	6.7	5.3	5.0	7.2	35.6	20.9	23.1	24.4	22.8
M 2	Adult acute inanition.....	8.7	13.2	9.3	9.1	13.8	5.5	6.6	5.5	5.4	7.2	25.8	12.2	20.9	20.8	14.0
S 26	Adult acute inanition.....	8.4	11.7	9.9	8.7	11.7	5.2	6.3	5.7	5.1	6.7	23.9	15.7	19.3	20.2	18.3
	Average for group.....	8.9	12.0	9.2	8.5	12.7	5.8	6.5	5.5	5.2	7.0	27.1	16.2	21.7	22.5	16.8
J 1.5	Adult chronic inanition.....	7.9	11.4	8.5	8.4	13.8	5.1	6.7	5.4	4.9	6.5	26.5	21.7	25.0	20.0	10.4
M 3	Adult chronic inanition.....	9.8	11.5	9.1	8.7	13.6	5.6	5.8	4.7	4.8	6.4	18.6	13.0	13.7	16.3	10.1
	Average for group.....	8.6	11.5	8.8	8.6	13.7	5.4	6.3	5.1	4.9	6.5	22.6	17.4	19.4	18.2	10.3

Resumido por el autor, John C. Donaldson.

El volumen relativo de la corteza y médula en la glándula adrenal
de la rata albina.

Las medidas que han servido de base al presente estudio han sido tomadas en las glándulas adrenales de diez y siete ratas albinas, fijadas en solución de Bouin y después reconstruidas por medio de cortes seriados. La adrenal izquierda es, en general, más grande que la del lado derecho. El volumen relativo que ocupa el tejido medular decrece desde próximamente el 12 por ciento en los machos y el 10 por ciento en las hembras, ambos recién nacidos, hasta llegar a ser el 7.5 por ciento y 6.5 por ciento, respectivamente, hacia el periodo de la pubertad. Desde este momento en adelante hay, relativamente, un cambio muy pequeño. Cuando se comparan las glándulas de la hembra con las del macho, en ejemplares del mismo peso, las de la primera contienen relativamente menos médula.

Translation by José F. Nonidez
Columbia University

THE RELATIVE VOLUMES OF THE CORTEX AND MEDULLA OF THE ADRENAL GLAND IN THE ALBINO RAT

JOHN C. DONALDSON

Department of Anatomy, School of Medicine, University of Cincinnati

FOUR CHARTS

This study was undertaken at the suggestion of Dr. H. H. Donaldson to determine the relations of the cortical and medullary portions of the adrenal gland in the albino rat, *M. norvegicus albinus*, and to demonstrate the changes in their volume which take place with age.

In the albino rat at birth there is a fairly well-marked cortex and medulla in the adrenals, though there are numerous groups of medullary cells still scattered through the cortex. Within a few days most of these have disappeared and the cortex and medulla are sharply marked off from one another. There are present in the albino rat, in addition to the tissues in the adrenal, microscopic masses of chromaffin cells in the retroperitoneal tissue, Fulk and Macleod ('16), and a small but constant mass of cortical cells in the epididymis of the testis, Swale Vincent ('12). No attempt was made to include these extra-adrenal masses in this study.

The materials used were the adrenal glands from seventeen rats, nine males and eight females, of Wistar Institute stock. The glands were fixed in Bouin's solution. After having been stored in cedar oil, they were passed through xylol, embedded in paraffin, and cut into serial sections $10\ \mu$ thick. The sections were stained with haematoxylin and eosin. This gives a very sharp contrast between the cortex and the medulla, the latter showing as a blue mass in the surrounding pink-stained cortex. Every tenth section was projected with an enlargement of fifty

diameters, and the outlines of the entire section and of the medulla were traced. The area of each of these figures was measured with a planimeter. From these areas and the known thickness of the section the actual volume of each section traced and of its medulla was calculated. The nine sections between each of those traced were considered as each having the same volume as the nearest traced section. By adding the volumes determined together the total volumes of the gland and of the medulla were found. Blood sinuses and blood-vessels were considered as a part of the tissues in which they were found. In other words, no attempt was made to subtract their volume from that of the gland. The thin capsule was included in the area of most of the sections. In those toward the end of the gland, where the capsule appeared thick owing to the plane of section passing tangentially to the surface of the gland, the capsule was omitted from the areas.

Somewhat similar methods were used by Elliot and Tuckett ('06) in their study of the adrenals of a number of mammals. They examined the cat, the guinea-pig, and the rabbit, and found in these animals that the relative volume of the medulla, compared with the volume of the whole gland, decreased with age. There were marked differences in the relative amount of medullary tissue in the gland, the maximum being 14 per cent of the entire gland, in a young guinea-pig, and the minimum 1 per cent in an old one. The values for the cat and the rabbit fell between these extremes. These authors give the value of 9 per cent for the amount of medullary tissue in the gland of a male rat of 120 grams, and 6 per cent for that in one of 190 grams. They do not state the variety of rat. They admit that the method they used would not give accurate results with so small a gland as that of the rat. In his study of the adrenal of the rabbit, Bertel Bager ('17) finds that the medulla forms 20 per cent of the total volume of the gland at birth. At twelve months it makes up a little less than 2 per cent. The ratio rises to 3 per cent as the animal gets older. The medulla is relatively smaller in the females.

TABLE 1

NUMBER	SEX	BODY WEIGHT	AGE ESTIMATED FROM BODY LENGTH	VOLUME OF BOTH GLANDS			THE RATIO OF THE VOLUME OF THE MEDULLA TO THAT OF THE WHOLE GLAND	DIFFERENCE IN VOLUME BETWEEN THE RIGHT AND LEFT ADRENAL. LEFT EXCEEDS RIGHT BY
				Total	Medulla	Cortex		
		<i>grams</i>	<i>days</i>	<i>mm.</i>	<i>mm.</i>	<i>mm.</i>	<i>per cent</i>	<i>per cent</i>
1	M	4.6	1	0.825	0.095	0.730	11.3	4.0
2	F	5.9	2	1.042	0.114	0.928	10.2	20.0
3	M	17.0	14	2.010	0.260	1.750	13.0	4.0
4	F	17.0	16	2.130	0.200	1.930	9.1	11.0
5	M	26.0	29	5.370	0.530	4.840	9.8	12.0
6	F	28.0	29	5.49	0.39	5.10	7.2	20.0
7	F	37.0	35	7.35	0.53	6.82	7.2	15.0
8	F	39.0	35	7.55	0.61	6.94	8.0	8.0
9	M	39.0	38	7.46	0.60	6.86	8.0	-0.2
10	M	50.0	45	7.06	0.50	6.56	7.0	2.0
11	M	73.0	55	10.68	0.87	9.81	8.2	14.0
12	F	79.0	64	16.70	1.20	15.50	6.9	11.0
13	M	103.0	69	11.51	0.81	10.70	7.0	-17.0
14	F	104.0	71	17.60	1.00	16.60	6.0	11.0
15	M	192.0	112	17.90	1.50	16.40	8.2	17.0
16	Damaged in preparation							
17	F	205.0	202	33.0	2.2	30.8	6.6	1.2
18	Tumor of the adrenal							
19	M	300.0	280	21.2	2.2	19.0	10.2	18.0

The values for the volume of the cortex were obtained by subtracting the volume of the medulla from that of the total gland.

The results of my observations are shown in the accompanying table 1 and the four charts. All figures are for the sum of the two adrenals of each rat. In this connection it is worth noting that in fifteen out of the seventeen rats the left adrenal was larger than the right; exceeding it in volume by an average of about 10 per cent and in one case by as much as 20 per cent.

Chart 1 shows the change in the volume of the cortical and medullary material in the gland of the rat from birth to nine months—5 to 300 grams. The values were gotten by finding out what fraction of the whole gland was composed of medulla and reducing that fraction to its percentage value. The values

for the males and females have been plotted separately. It will be seen that the curves for the two sexes are essentially parallel, but that the one for the females, marked by crosses, indicates a smaller relative value for the medulla, and at the end of the female curve the relative volume becomes stationary. Both curves show a rapid decrease in the relative volume of the medulla until about the age of puberty, then in the males an in-

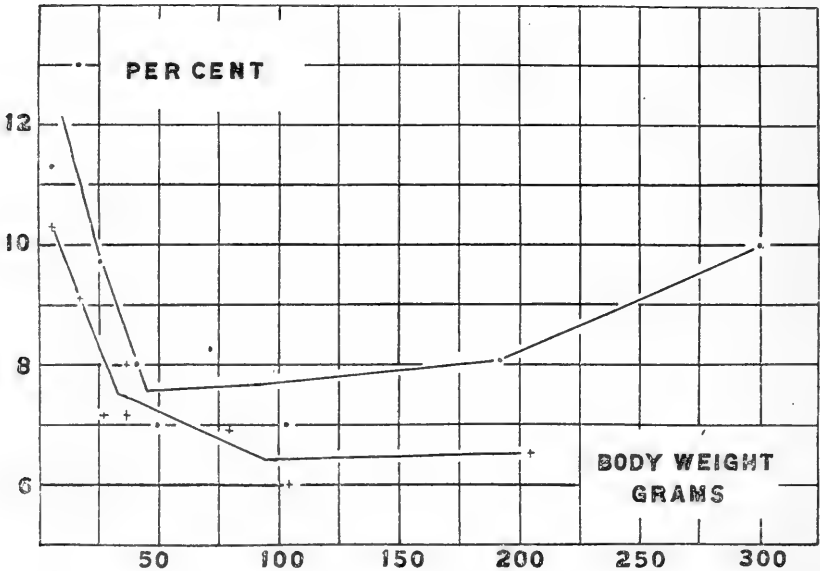


Chart 1 The change in volume of the medulla expressed as a percentage of the whole adrenal gland. Dots, •, males, individual values. Crosses, +, females individual values.

crease and in the females no further loss. Dr. Jackson, in some recently completed work (Jackson, '18), has found essentially the same relative decrease in the chromaffin tissue in the rat. In his rats, however, he did not find any differences between the sexes. His results, as he has kindly told me, were not arranged to bring out any such differences which might exist.

The recent work of Elliot and Armour ('11), and Lewis and Pappenheimer ('16) shows that in the human adrenal just after birth there is a rapid degeneration and absorption of the inner

portion of the cortex. The resulting rapid reduction in the relative size of the enormous cortex is much greater than anything shown in chart 1, and is in the direction of a relative increase of medullary tissue. This degeneration has never been noted except in man. There is nothing resembling it in my specimens.

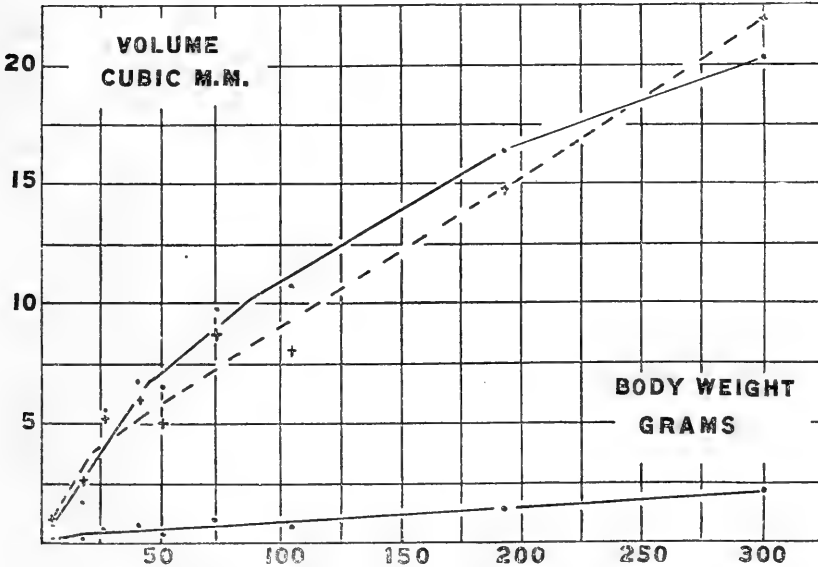


Chart 2 The growth in volume of the male adrenal cortex and medulla. The lowest solid line represents the medulla. The broken line marked by crosses represents the values for the medulla multiplied by ten, so that its growth can more conveniently be compared with that of the cortex.

Charts 2 and 3 show, in solid lines, the growth curve, in volume, for the cortex and for the medulla, chart 2 for the males and chart 3 for the females. The broken line represents the values for the medulla multiplied by ten; so that the relative growths of the two parts can be more conveniently compared. The values for both the cortex and medulla are expressed in cubic millimeters.

Chart 4 shows the values for the whole of the adrenal in cubic millimeters. When compared with the values for the weight of

the adrenal found in table 71 of the rat (Donaldson,'15) and shown in chart 20 of the same, it will be seen that the curves are similar in form and relation, but that the values in chart 4 are about one-half what they should be to satisfy the weights given for the respective ages in table 71. Jackson ('17) found a similar

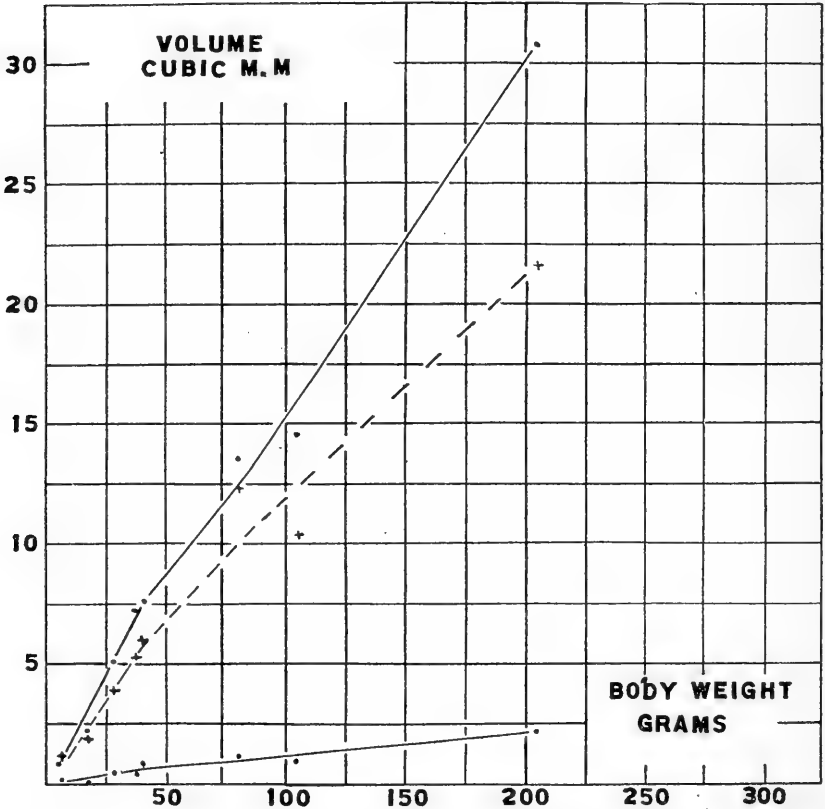


Chart 3 The growth of the female adrenal cortex and medulla. The lines have the same significance as those in chart 2.

discrepancy between the volumes and the weights, when reconstructing the hypophysis from serial sections. He suggests that shrinkage by reagents and the weighing of a certain amount of tissue which is not included when reconstructing the organ explain this. Recent work at The Wistar Institute indicates

that when specimens are embedded in paraffin directly from cedar oil they may show a loss of as much as 41 per cent of their fresh volume.

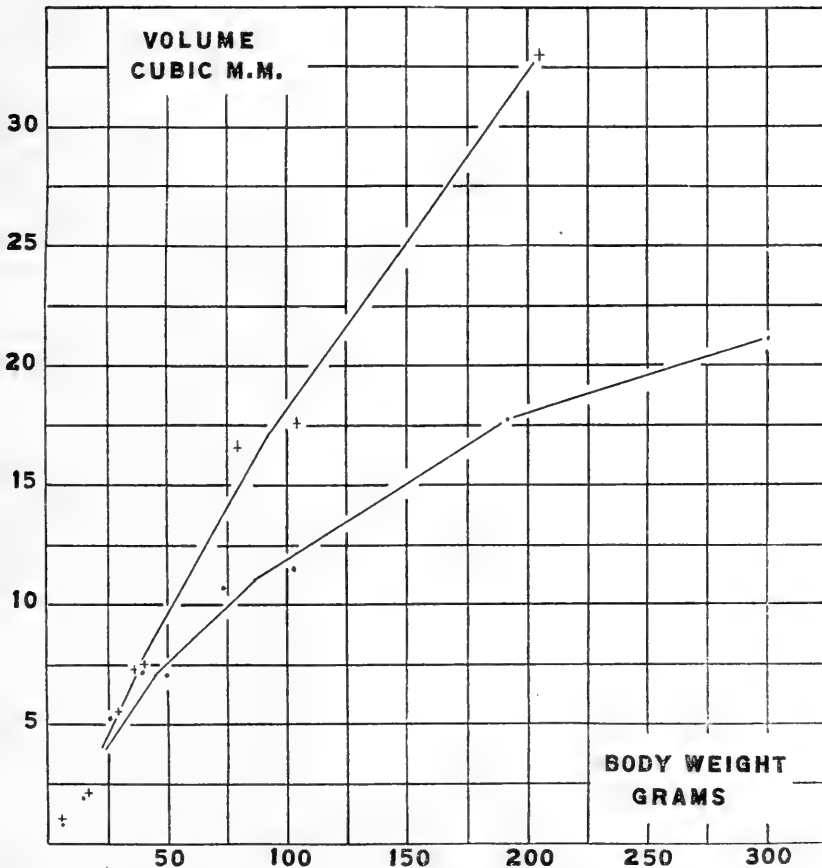


Chart 4 The growth of the whole gland expressed in cubic millimeters. The upper line gives the values for the females, the lower line that for the males. Dots, •, males, individual values. Crosses, +, females, individual values.


To sum up: The left adrenal in the albino rat is usually distinctly heavier than the right. The relative volume occupied by the medullary tissue decreases rapidly from birth to puberty, 50 to 100 grams, and then remains stationary or increases a little

with age. When compared with those of the male, the glands of the female, body weight for body weight, contain relatively less medulla. The difference, however, is slight, less than 2 per cent (chart 1).

Results found by the reconstruction method are comparable with results of growth expressed by weight (chart 4).

LITERATURE CITED

- BAGER, BERTEL. 1917 Bidrag till binjurarnas åldersanatomi hos kaninen (The anatomy of the adrenal in the rabbit as modified by age). Upsala Läkareförenings Förhandlingar. Ny följd. Bd. 23. H. I-2.
- CROWE AND WISLOCKI 1914 Experimental observations on the suprarenal gland with special reference to the functions of their interrenal portions. The Johns Hopkins Bull., no. 284, pp. 287-304
- DONALDSON H. H. 1915. The rat. Reference tables and data. Memoirs of The Wistar Institute, no. 6, Philadelphia.
- ELLIOT, T. R., AND ARMOUR, R. G. 1911 The development of the cortex in the human suprarenal gland and its condition in hemiccephaly. J. Pathology and Bacteriology, vol 15, pp. 481-488.
- ELLIOT, T. R. AND TUCKETT, I. 1906 The cortex and medulla of the adrenal. J. Physiology, vol. 34, pp. 333-369.
- FULK, M. E., AND MACLEOD, J. J. 1916 Evidence that the active principle of the retroperitoneal chromaphil tissue has the same physiological action as the active principle of the suprarenal gland. Amer. J. of Physiology, vol. 40, no. 1, pp. 21-29.
- JACKSON, C. M. 1917 Effects of inanition and refeeding upon the growth and structure of the hypophysis in the albino rat. Amer. J. Anatomy, vol. 21, no. 2.
1918 The postnatal development of the suprarenal gland and the effects of inanition upon its growth and structure in the albino rat. (In the course of publication.)
- LEWIS, R. W., AND PAPPENHEIMER, A. M. 1916 A study of the involutinal changes which occur in the adrenal cortex during infancy. J. of Med. Research, vol. 34, pp. 81-93.
- VINCENT, SWALE 1912 Internal secretion and the ductless glands. Edward Arnold. London.
1917 Experimental and clinical evidence as to the influence exerted by the adrenal bodies upon the genital system. J. Surgery, Gynaecology, and Obstetrics, vol. 25, pp. 294-299.



Resumido por el autor, Franklin P. Johnson.

El desarrollo de los lóbulos del hígado en el cerdo.

En el presente trabajo el autor se ocupa principalmente del desarrollo tardío del hígado del cerdo, considerando especialmente la formación de los tabiques interlobulares formados por tejido conectivo, el modo de formación de nuevos lóbulos, el crecimiento de las venas hepática y porta y el desarrollo del hígado en conjunto. Los resultados obtenidos pueden resumirse del siguiente modo: los tabiques de tejido conectivo se distinguen ya en el animal recién nacido, pero no se hacen bien patentes hasta que el animal tiene dos meses de edad. Se originan como extensiones del tejido conectivo que rodea a la vena porta. La excisión de los lóbulos origina otros nuevos. Durante este proceso la vena central del lóbulo o bien se bifurca o produce una nueva rama en uno de sus lados, y siguiendo su trayecto aparece un nuevo tabique intralobular de tejido conectivo que se extiende formando ángulo recto con la superficie del lóbulo, entre las dos nuevas venas centrales. Cuando se completa la excisión resultan dos nuevos lóbulos provisto cada uno de ellos de una vena central, mientras que el tabique de tejido conectivo y la antigua vena central adoptan posición interlobular. Los tabiques de tejido conectivo desempeñan tan solo un papel pasivo en la formación de nuevos lóbulos. El crecimiento del hígado durante todos los estados de su desarrollo tiene lugar: 1) por el aumento del número de lóbulos; 2) por el aumento de tamaño de estos últimos. En general todas las partes del hígado crecen simultáneamente y de una manera semejante. Hay un cambio constante en la posición de los lóbulos en la periferia, pero este cambio se lleva a cabo de tal modo que las relaciones de un lóbulo con otro sufren una alteración mínima.

THE DEVELOPMENT OF THE LOBULE OF THE PIG'S LIVER

FRANKLIN PARADISE JOHNSON

Department of Anatomy, University of Missouri

TWENTY-EIGHT FIGURES

CONTENTS

Introduction.....	299
Development of the connective tissue septa.....	301
Capsula fibrosa.....	308
Formation of new lobules.....	308
Rôle of the connective tissue septa.....	318
Growth of the liver.....	319
Conclusions.....	325

INTRODUCTION

The development of the liver lobules offers a difficult problem owing to the fact that in most animals the lobules have no definite boundaries, one running directly into the other without demarcation. In section, therefore, the livers appear to consist of solid masses of parenchyma, pierced at more or less regular and alternating intervals by various-sized branches of the portal and hepatic veins. This lack of lobule definition is so great that one readily appreciates why Weber, in 1842, denied the presence of true lobules in the human liver, and one may himself doubt the appropriateness of the term 'lobule' for either the portal or hepatic units.

Early recognizing this difficulty, I chose for material the liver of the pig, for I hoped that by using an animal in which the liver lobules are definitely marked out, this difficulty would be greatly overcome. I soon found that the pig's liver does not show indications of dividing septa until about birth, and that the connective tissue septa are not definite until about the second month of postnatal life. Contrary to the state-

ment of Mall ('06), lobule formation is not complete at this time, for I find with Lewis ('12) that "the multiplication of lobules continues long after birth." The few late stages of the pig which I have been able to procure, consequently, have been of great value in furnishing evidence concerning the development of the hepatic lobules.

Because of the importance of the connective tissue septa, I have found it advantageous to divide the development of the pig's liver into two definite periods—one before and one after the septa are indicated. I shall speak of the former simply as the 'early stages,' of the latter as the 'late stages.' The early stages include those up to but exclusive of an embryo of 254-mm. in length; the later stages include the 254-mm. embryo and extend to the adult.

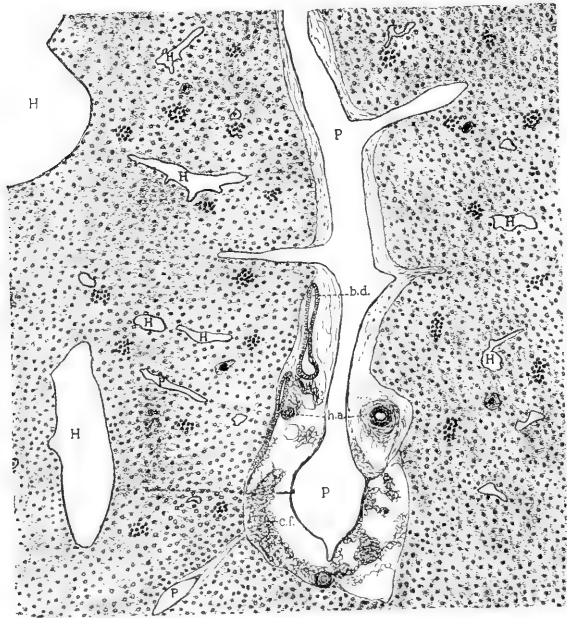
In attempting to determine the manner in which the units of the liver multiply, I first gathered together a series of selected stages of developing livers. But so far as lobule formation is concerned, this was unnecessary. I agree with Mall, ('06) when he says, "the great difficulty is to recognize the same thing from step to step," but I find the greatest difficulty is to recognize the limits of a lobule in its three dimensions in any single early stage. In the later stages, however, because of the presence of the connective tissue septa, the lobules are definitely bounded. Since in any developing liver the lobules present numerous instances of every stage of development, it is possible by a little study to arrange the various stages in their proper sequences. In this manner the development of the liver lobules may be easily and most satisfactorily determined from any single late stage.

Inasmuch as I have worked out the development of the liver lobules from stages in which the connective tissue septa are present and continually growing and delimiting new lobules, I found it necessary to study first the origin of the septa. This was the more essential, for an understanding of the different developmental stages of the septa makes it possible not only to recognize dividing lobules, but to distinguish between the newly formed and the old lobules.

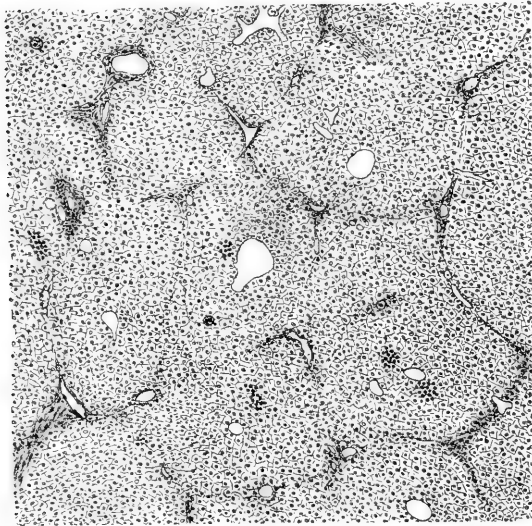
DEVELOPMENT OF THE CONNECTIVE TISSUE SEPTA

In stages until nearly birth the liver of the pig shows no indications of connective tissue septa. The parenchyma is made up of cells not greatly different from those of the adult. The sinusoids, which appear proportionately large, are lined with endothelial cells. The 'Gitterfasern' or 'reticulum of Mall' ('96) is demonstratable following Bielschowsky's silver-impregnation method, and is also slightly discernible after staining with Mallory's triple connective tissue stain. The branches of the hepatic and portal veins interdigitate with one another and furnish a means by which hepatic and portal lobules may in certain areas be roughly outlined. The large branches of the portal veins are readily distinguished from the hepatic, for they are accompanied, as in the adult, by branches of the hepatic artery and of the bile duct; some of the smaller veins are determinable only with the aid of serial sections.

In figure 1 is shown a longitudinal section through a branch of the portal vein, taken from the liver of a pig 229-mm. in length. The interdigitation of its branches with those of the hepatic vein is clearly shown. Surrounding the larger branches of the portal veins, bile ducts, and hepatic arteries is connective tissue. Staining with Mallory's triple connective tissue stain clearly demonstrates in it the presence of collagen fibrils. Where the collagen fibrils are in contact with the parenchyma they often send short fibrils into its reticulum. Surrounding the hepatic veins there is but a thin layer of connective tissue, which, moreover, does not extend out to as small branches as does that surrounding the portal veins. The hepatic cells are polyhedral in shape, with slightly granular protoplasm and distinct chromatic nuclei. They are grouped in strands, but, as stated by Theopold, a radial arrangement about the central vein is not yet to be found. Here and there are to be seen small clusters of nucleated round cells. These cells, which we know to be developing blood-cells, were first described by Kölliker ('79), but were thought by Toldt and Zuckerkandl ('75) to be young hepatic cells. That Kölliker's interpretation is correct,



1



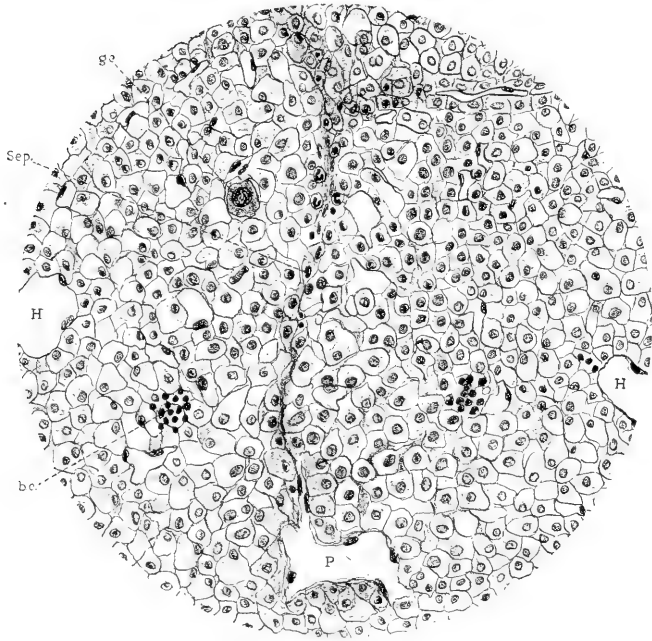
2

Fig. 1 Section of liver of pig 229 mm. in length. Mallory's triple connective-tissue stain. *H*, hepatic veins; *P*, portal veins; *c. f.*, collagen fibrils; *b. d.*, bile duct; *h. a.*, hepatic artery; *b. c.*, group of blood cells; *g. c.*, giant-cells. $\times 50$.

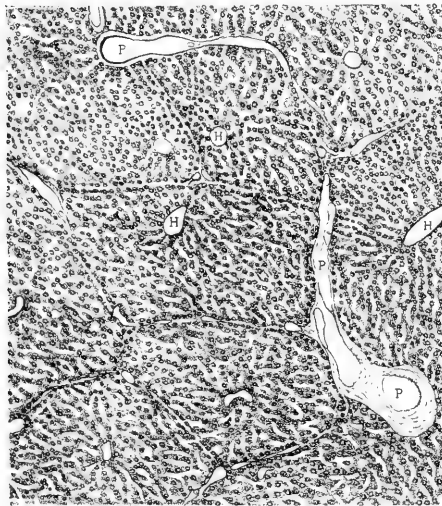
Fig. 2 Section of liver of pig 254 mm. in length, showing first indications of interlobular septa. $\times 50$.

however, has been abundantly proved by the researches of Van der Stricht ('91); Kostanecki ('92), Engel ('99), Lobenhoffer ('08), and others. Large mononuclear giant-cells, also described by Kölliker, are to be found sparsely scattered through sections of the liver. In the later fetal stages both the group of embryonic blood-cells and the giant-cells become fewer and fewer, as is agreed by all investigators. I find with Theopold, however, that they have not all disappeared at birth and that a few may be found for several weeks after birth.

The first indication of a segmentation of the liver parenchyma into hepatic lobules which I have found has been in an embryo of 254-mm. in length. According to Engel ('99), this pig would be one at about full term, since he states that a pig at birth measures 25 cm. Theopold ('10), however, shows that pigs at full term vary considerably in length; that they even attain a length of 35 cm. before birth. In the 254-mm. specimen, the liver cells appear more vesicular, their protoplasm stains but faintly. The boundaries of the hepatic lobules as seen in figure 2 are in many places definitely marked. A close analysis of the dividing medium, however, shows that it contains no collagen fibrils, but rather its appearance is due to a change in the parenchyma. A higher-power drawing of this stage is shown in figure 3. To the right and left of the drawing are shown terminal hepatic on central veins; above and below are terminal portal veins. Extending from portal vein to portal vein is shown the first evidence of an interlobular septum. It consists of hepatic cells which are more coarsely granular and stain more deeply than the remaining cells; similar cells are found surrounding the portal veins. However, the thing which makes the septum most apparent is the arrangement of the cells. As seen in sections, they form two more or less regular parallel rows, an arrangement which becomes greatly accentuated in slightly older stages. Another factor which in places intensifies the distinctness of the septa is the presence of small branches of the portal veins. Nucleated blood-cells found in the sinusoids along the septa also aid in making it more distinct. I have studied carefully the retic-



3



4

Fig. 3 Higher magnifications of portion of figure 2, showing interlobular septum. *H*, hepatic vein; *P*, portal vein. $\times 260$.

Fig. 4 Section of liver of a pig four days old, showing arrangement of lobule border cells in parallel layers. *H*, hepatic veins; *P*, portal veins. $\times 50$.

ulum of the septum stained by the Bielschowsky method and believe that a thickening of it at this stage is very doubtful.

In a slightly longer pig measuring 265-mm. (also unborn) a somewhat similar condition is found, although it is not quite so far advanced as the 254-mm. specimen. This variation in the degree of development I have found to be especially marked in stages around birth. Thus, in specimens of two hours and twenty-four hours after birth, the septa appear no more distinct than those of the 265-mm. stage, while a specimen of three days is no further advanced than a 254-mm. embryo. A similar variation in the degree of development is noted by Theopold ('10). Again a radial arrangement of the hepatic cells is absent.

In a pig of four days the liver shows a more advanced condition (fig. 4). The cells are coarsely granular and stain deeply. The lobules are in most places definitely marked out by the arrangement of their border cells. This consists in their forming continuous sheets of cells about each lobule; thus, when seen in cross-section, they form two parallel rows. Between these rows of cells is found reticulum which is slightly thickened, but contains no collagen fibrils. A Berlin-blue-gelatin injection of the liver of a second pig of four days also shows definite evidence of the lobular nature of the liver. As shown in figure 5, the injection mass has passed through the sinusoids into the central veins. The sinusoids between the lobules, although present and forming free anastomoses between one lobule and another, are smaller and somewhat less numerous than those within the middle of the lobules. This condition results in the appearance shown in the figure, the lobules being separated from one another by a clear translucent zone—an appearance which is more strikingly brought out in the thick sections.

For the first time can a radial arrangement of the liver cells be seen. This point is shown in the injected specimen, since the direction of the trabeculae of liver cells corresponds with the direction of the sinusoids. Although the radial arrangement is not well marked at this stage, it becomes increasingly

more definite in livers of pigs of one, two, and three weeks. At two months it is as strongly marked as in the adult. These observations are in accord with those of Theopold ('10), who states that the radial arrangement of the liver cells is first seen in pigs in the second half of the first week of postnatal life, and that the arrangement gradually increases in definition, although at the sixth week it is not strongly marked in all lobules.

In pigs of three and four weeks old the hepatic lobules are still more strongly marked. The parallel rows of cells with the intervening layer of reticulum are still in evidence. In addition, however, the reticulum in many places shows the addi-




Fig. 5 Portal injection of liver of a pig four days old, showing fewer and smaller sinusoids along interlobular septa. $\times 40$.

tion of delicate strands of collagen fibers (fig. 6), as demonstrated by staining by both Mallory's and Bielschowsky's methods. In certain places these fibers extend from portal vein to portal vein; in other places they extend from one portal vein toward another, leaving, however, the nodal-point region devoid of them. From various degrees of this condition it is safe to conclude that the connective tissue of the interlobular septa has its origin in the connective tissue of the portal canals and grows outward from them, pushing its way into the reticulum already separating the lobules. According to Theopold ('10), complete septa arising from connective tissue already present are in evidence, in certain places in the liver of a pig eight days

old. He does not state, however, whether or not this connective tissue contains true collagen fibrils.

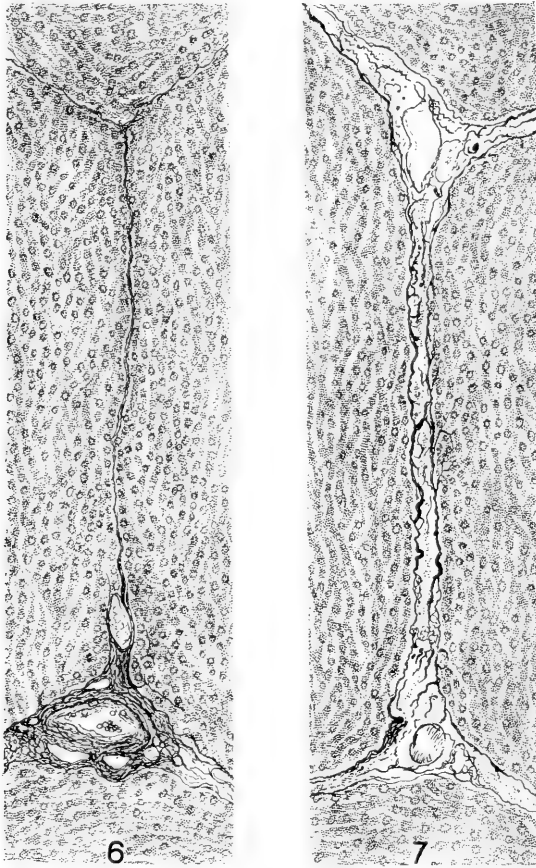


Fig. 6 Interlobular septa of liver of a pig three weeks old. Mallory's triple connective-tissue stain. $\times 250$.

Fig. 7 Same, two months old pig.

The exact manner in which the connective tissue of the septa is laid down, that is, whether the collagen fibrils have their origin from fibroblasts situated in the portal canals and push their way out into the interlobular reticulum or whether the fibroblasts first migrate and give rise to the collagen fibrils

in situ, I have not determined. This point, it seems to me, is of little moment, inasmuch as in either case the origin is from the connective tissue of the portal canals. It is interesting to note that the connective tissue surrounding the sublobular veins does not take part in the formation of the septa to nearly so great an extent as does that of the portal canals. Around some of the larger sublobular veins a few out-pushing collagen fibrils may be found, but it is evident that the bulk of the connective tissue forming the septa springs from the portal canals.

Capsula fibrosa (Glissoni). Collagen fibrils are differentiated in the pig's liver as early as the 80-mm. stage. They are found principally in the portal canals, and to a less extent around the larger sublobular veins, being especially abundant in the region of the porta hepatis. Extending out in either direction from this region, as seen in the cross-section, there are thin strands of collagen fibrils which spread around, but do not entirely encircle the liver. These strands represent the forming external capsule of Glisson. A similar section of the liver of a pig 111 mm. in length, shows a complete capsule. It consists, however, of a very delicate layer of collagen fibrils which lies close to the liver parenchyma. In all stages up to birth the capsule has this appearance, the collagen fibrils showing no appreciable thickening; on the other hand, in certain stages it appears to be less distinct than in the younger ones; in some its presence as a distinct layer is extremely doubtful. After birth it rapidly becomes thicker and continues to augment in strength and density until the adult condition is reached.

FORMATION OF NEW LOBULES

Mall ('06), in his study of the structural unit of the liver, concluded that Thoma's laws concerning the formation of new blood-vessels explain the formation of new lobules. He states:

As the vessels grow the liver tissue increases in quantity, but the liver lobules do not increase in size indefinitely, because Thoma's first law is constantly at work and will soon break up the larger lobules into a number of smaller ones. In all cases the length of the capillaries remains constant, and when they appear to be too long and too

numerous, it is always found that some of them have already turned into small veins and thus mark the beginning of new lobules or of new portal units.

While in general the idea expressed in the above statement may be correct, nevertheless it should be emphasized that the sinusoids of the liver are not all of equal length. Mall, himself, shows that within a single lobule they are of various lengths, that there are short paths and longer ones between the portal and hepatic veins. Yet he believes that all the capillaries of the lobule and of the liver as a whole are equally favored by the circulation. In a former paper ('18 a) I have shown that in the adult pig the lobules vary greatly in diameter; the lengths and numbers of their capillaries, consequently, must also vary. Again, in my study of the development of the lobules, I find that the lobules do not reach a certain constant size before they begin to divide into new ones; a large lobule and a smaller one placed side by side may be in a similar stage of division.

In his recent studies on the growth of the blood-vessels in the tail of the frog larva, Clark ('18) has shown that as certain areas of tissue increase in size, the surrounding capillaries send into the area endothelial sprouts which develop into additional capillaries. When these new capillaries become functional, that is, when a flow of blood through them is inaugurated, there results an increased flow through and an increase in the size of certain ones of them which are favorably located. According to Clark, it is the increased amount of blood flowing through these vessels which causes them to enlarge. Conversely, Clark has shown that when the flow through capillaries is diminished, the capillaries become smaller, when the flow stops altogether, they close, break in two, and are gradually retracted into the vessels with which they were originally connected.

The application of these observations to the growing liver may be made as follows: As the hepatic cells increase in number, new capillaries are formed, bringing about an increased flow of blood in, and a subsequent increase in size of, certain capillaries leading to and from the new ones. These enlarged capillaries become new branches of the portal and hepatic veins.

As the portal and hepatic veins increase in length, the blood flow through certain capillaries along their sides is diminished and finally stopped, with the result that these capillaries disappear through retraction. Thus it is that capillaries arise from only the terminal branches of the hepatic and portal veins.

It was Mall's idea ('06) that new lobules form by the splitting up of old ones, yet he does not make clear the exact manner in which the splitting takes place. Apparently, he believed that the lobules split and become fragmented into a number of parts, each of which is capable of giving rise to a new lobule. Furthermore, he believed that the fragmented parts of several different lobules are capable of uniting into a single lobule, for on page 278 he describes a lobule as arising from three adjoining ones. Yet his diagrams illustrating the formation of new lobules (figs. 41 to 43) are not suggestive of any such 'shattering' and reuniting of parts of lobules, but rather of an accumulation of orderly binary fissions; if we should add other figures to his diagrams to fill in the wide gaps which he has left, we should have similar pictures to those which I have shown in figures 11 to 15.

As stated above, the manner in which the hepatic lobules of the pig develop may be understood from the study of any single stage of development. However, it is only in the later stages where lobule boundaries are made definite through the ingrowth of connective tissue that the process can be determined with any degree of accuracy. I have accordingly used for the following description a liver from a pig two months old. The observations recorded have been checked with other stages, both before and after the connective tissue septa have made their appearance; so far as I can determine, the formation of lobules is the same in all.

The development of new hepatic lobules can be best understood by watching the changes which take place in the growing hepatic veins. Each of their new branches marks the beginning of a new hepatic lobule. The portal veins spread over the surfaces of or between the lobules, dividing repeatedly, their terminal branches being more numerous than those of the

hepatic vein, as pointed out by Mall. In their growth they bear a certain constant relation to the growing hepatic veins, through which relation a constant flow of blood is maintained.

In figures 8 to 10 are shown hepatic lobules in successive stages of development. Figure 8 is a section of a slightly elongated lobule with a bifurcating vein. Although in all other respects this lobule is similar to other single lobules, it can be definitely stated, because of the branching of its hepatic vein, that it has begun to divide. In figure 9 the new branches of the central vein are longer, having kept pace with the lengthening lobule. The new veins grow, as described by Mall, by the enlargement of certain sinusoids. In addition to the new veins is to be seen the beginning of a cleavage of the lobule. This is represented by the arrangement of certain hepatic cells into parallel rows, between which collagen fibrils later appear. It is to be noted that the septum occupies the plane of the original central vein and bisects approximately the angle formed by its two new branches. The free edges of the septum lie just above the fork of the central vein, which position (fig. 9) it maintains for some time.

That the new central veins lengthen in many instances at the expense of the old one, that is, by cleavage of the latter, there is little doubt. In those lobules in which the central vein is just beginning to bifurcate it is relatively long; in those in which the branches are long the old central vein is usually shorter. This apparent splitting of the old central vein seems to be caused by the growth of the septum into the fork of the central vein. In many instances where the cleavage of a lobule is nearly complete the old central vein is split down almost to the point where it enters the lobule.

The further separation of the lobule into two new ones takes place slowly by the continued growth of the new septum from the sides of the lobule toward the old central vein. When the septum is complete, the remaining portion of the old central vein is found to lie between the two new lobules; it may then be spoken of as a small sublobular vein.

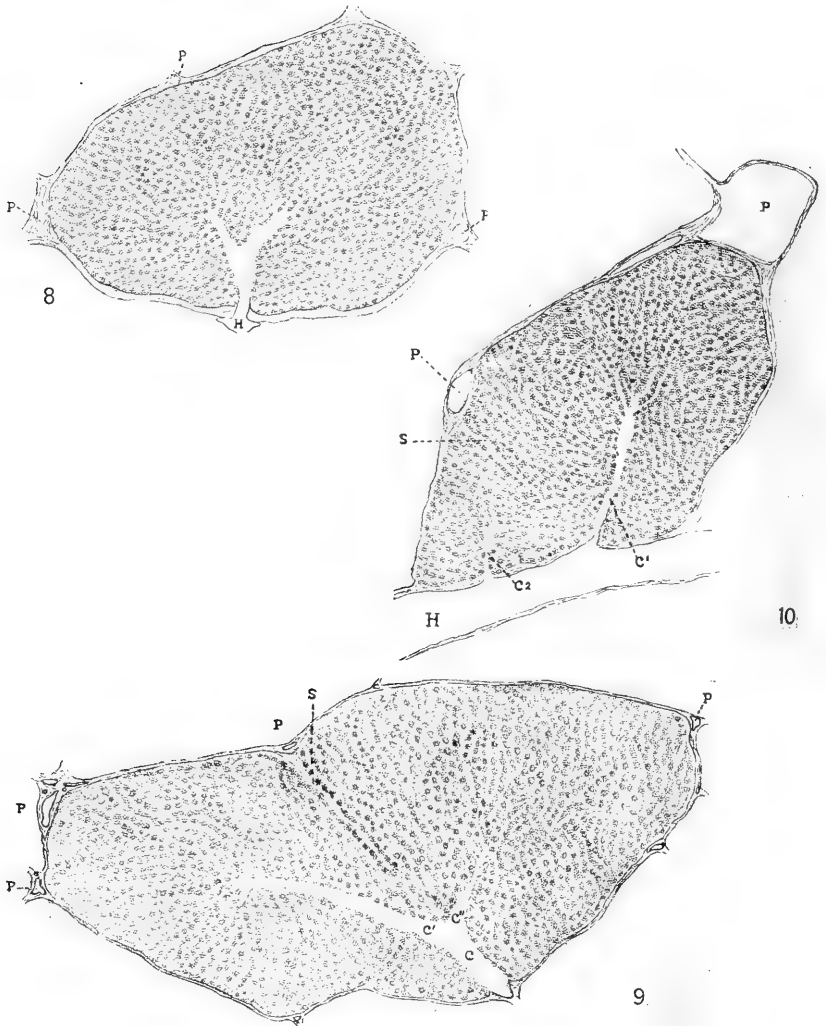


Fig. 8 Dividing lobule from liver of pig two months old. *H*, hepatic vein; *P*, portal vein. $\times 50$.

Fig. 9 Dividing lobule from liver of pig two months old. *C*₁ and *C*₂, branches of central vein; *S*, new interlobular septum. $\times 50$.

Fig. 10 Dividing lobule from liver of pig two months old. *C*₁, old central vein; *C*₂, new central vein; *S*, new interlobular septum. $\times 50$.

Usually, however, before the time the connective tissue septum is complete, the new lobules themselves have begun to divide, thus giving rise to what Kiernan ('33) has described as compound lobules. That the compound lobules of the adult are, as I have stated before ('18 a), incompletely divided lobules due to incompletely developed connective tissue septa is quite apparent; they are similar in every detail to those found in the developmental stages.

Compound lobules have also been described and modeled by Debeyre ('10) who states that in the pig as well as in other mammals they are more numerous than the single lobules.

"Le petit lobule classique, isolable, existe, mais il est presque exceptionnel."

While I am able to confirm Debeyre in that the compound lobules of the pig's liver are numerous, I have not found the single lobule to be exceptional. If blocks of pig's liver are treated with 50 per cent to 75 per cent hydrochloric acid (Johnson, '18), the connective-tissue septa are destroyed and the lobules fall apart. The compound lobules, joined together by liver parenchyma, are preserved intact. Examination of the lobules under the binocular microscope shows that many of the lobules are single. It is true that the compound lobules may be torn into their component parts, but this does not happen if they are handled carefully. If the maceration is allowed to proceed to the proper degree, the lobules separate from one another on a very slight amount of shaking. The compound lobules can be divided only upon rough handling. From a number of such preparations I have observed that the compound lobules vary greatly in number, size, and number of component parts in the livers of different adult pigs.

In addition to the above-described process of division, there is another which frequently takes place. Instead of the distal end of the hepatic vein bifurcating, a new branch is given off from its side. The new branch, as shown in figure 10, enters a portion of the lobule. As it gradually becomes larger and longer a cleavage takes place in the lobule in a similar manner to that described above. The cleavage divides the original

lobule into two new ones, one of which is supplied by the old central vein, the other by the new one. That new branches of both the hepatic and portal veins arise as outgrowths from the main trunks is stated by Mall.

Surface lobules often divide by the combination of the two processes just described. The long axes of such lobules are placed at right angles to the surface of the liver. When a surface lobule divides its central vein bifurcates, the new branches spread apart and then bend to become perpendicular to the surface (fig. 23). A septum then starts from the surface, midway between the two new branches, and grows down to the fork of the central vein. Thus two elongated lobules are marked off. These then become cut up transversely, new branches from either the new or old central veins extending in to the lower ends of the lobules. In some instances, however, the new hepatic veins which supply the lower ends of the lobules are formed earlier by a bifurcation of the new central vein.

Slight variations in development are often met with in certain groups of new lobules. Figure 24 is from a wax reconstruction of three almost completely formed lobules which have developed from a single one. The original central vein *H* has bifurcated into the two branches *h* and *h*. The original septum is shown between *A* and *H*; it is almost complete. A new cleavage, *B*, however, has grown in from the side and has joined the original septum, thus completely cutting off the lobule *N*. A new vein, *h'*, has grown out from the original central vein into the new lobule *O*, which is not yet entirely separated from the lobule *M*. In the process of splitting, the original central vein *H* has become interlobular in position.

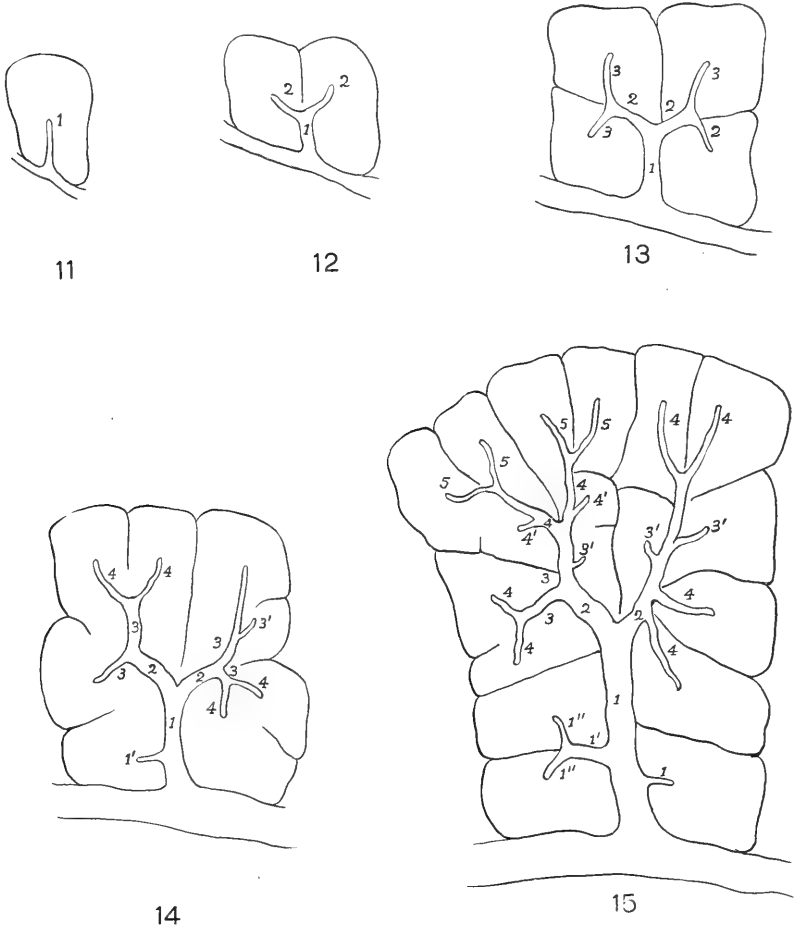
Very seldom in the pig's liver is found a lobule through which the central vein extends to become the central vein of another lobule. One of the few which I have found in looking over a large number of lobules is shown in figure 25. Judging by the stage of development of its connective tissue septa, I have explained its existence in the following manner: The three lobules, *A*, *B*, and *C*, were originally one: its central vein *H* bifurcated into *h* and *h*, and the longitudinal septum grew

down from the surface, bisecting the angle formed by the new branches of the central vein. This septum instead of following the central vein, either turned off to one side or was met by another septum from the side, thus leaving the old central vein completely surrounded by liver cells. That such central veins do not long remain within the lobules is evident, since none of the larger sublobular veins are found passing through single lobules. The manner in which such a vein leaves its lobule, however, I have not fully determined. It may be that they later become interlobular in position by the ingrowth of additional septa. It seems more probable, however, that they gradually become shifted to one side, since in several other similar lobules, I have found them eccentrically placed. In these lobules new central veins were found arising at right angles from the eccentrically placed ones, seemingly marking the path along which the old veins must have shifted.

From the above description, it is evident that lobule formation takes place by the binary fission of an elongated lobule. This is preceded by either a bifurcation of the central vein or by the sprouting out of a new vein from it. In either case, the two veins extend into the halves of the old lobule. By the time the cleavage is complete, each half of the old lobule represents a fully formed new lobule. The self-explanatory figures 11 to 15 show diagrammatically the manner in which a single lobule may give rise to a larger group.

In figure 28 is shown a wax reconstruction of a group of lobules, all of which are supplied by a single sublobular vein. This vein and its accompanying branches are shown in figure 27. From the above description, it follows that all the lobules of this group must have arisen from a single lobule, and, conversely, all the lobules which have arisen from this original lobule belong to this group. Each branch of the hepatic tree goes to an individual lobule and represents an independent cleavage of the hepatic parenchyma. With the exception of a few of the terminal branches, it is impossible to tell which have arisen through a dichotomous bifurcation of terminal central veins and which as new outgrowths from existing stalks.

It is interesting to note, however, that all the branchings of the hepatic vein shown, with possibly one exception, are dichotomous. This condition which has been mentioned by Roux ('95) obtains in the adult and is easily verified by the examination of celloidin corrosions of either the hepatic or portal trees.



Figs. 11 to 15 Diagrams representing manner of formation of hepatic lobules. The numbers represent the number of times the hepatic vein has bifurcated. Vessels marked 1', 2', etc., indicate new growths, not terminal bifurcations.

Thus far I have shown that the terminal hepatic veins always keep within the lobules; that each of its new branches is indicative of the formation of a new lobule. The portal veins in growing spread between the lobules, tending always to keep within a certain distance of the central veins. It should not be inferred, however, that the growth of the portal veins follows in point of time that of the hepatic veins. Both undoubtedly grow hand in hand, increasing in length and diameter, and branching as the increasing parenchyma demands. With the increase in the size of lobules, there is ever the tendency to spread the two sets of veins further apart and this tendency is at all times being counteracted by the formation of new veins.

The manner in which the new veins develop, that is by a widening out of certain sinusoids, has already been described. These new veins, according to Mall, grow into those regions on the surface of the lobules which are most distally situated from the branches of the portal veins, areas which Mall has termed 'nodal points.' The whole matter of nodal points can only be clearly understood from a study of the lobule in its three dimensions; they are uncircumscribed areas on the surfaces of the lobules which lie between the terminal branches of the portal veins and between the central vein of one lobule and that of an adjacent lobule. In the dividing lobule shown in figure 26 as many as ten nodal points may be counted, one of which is just forming coincidentally with the formation of the new dividing septum. The statement of Mall's ('06) that the portal and hepatic veins alternately grow toward the nodal points and break them into fragments to form new nodal points holds good, according to my observations on the pig's liver, for only the portal veins. In figure 26 the whole upper surface of the lobule was originally represented by a single nodal point; the new branch of the portal vein has broken it up into two new ones. But the terminal hepatic veins always lie within the lobules, they grow toward the nodal points only as the parenchyma of the lobule increases, but they never reach them. In the lobule represented in figure 26 the single central vein *H* was originally directed toward the single nodal point of the top surface, but

with the splitting of the lobule two new nodal points are formed, and the two new central veins are again found to be directed toward these new nodal points. That the hepatic veins do not grow into the nodal points and break them into fragments is still more evident when it is considered that the terminal central veins are always found within the lobules, while the nodal points are always interlobular in position.

The rôle of the connective tissue septa in lobule formation. In order to understand clearly the rôle played by the connective-tissue septum in the splitting of one hepatic lobule into two, it will be necessary to review in their proper sequence the events which take place in the formation of new lobules. The first unmistakable evidence of splitting in a lobule is the formation of an additional branch of the hepatic vein, either by the bifurcation of a terminal vein or by its outward growth from the side of an existing vein. At the same time, however, new branches of the portal vein are similarly forming, although these latter branches are not indicative of the formation of new lobules. Next follows the beginning of the cleavage, which consists at first of the parallel arrangement of liver cells and is afterward followed by an ingrowth of connective tissue. The growth of the new branches of the portal vein takes place along the fissures of the new septum, if they have not preceded it (fig. 26). The new septum comes to possess in this way a new nodal point. Branches of the portal vein, however, do not actually enter the new septum to break up its nodal point until both new lobules are fully formed, and not until the new lobules have increased sufficiently in size to warrant this addition to the vascular system.

It is evident, therefore, that the real and essential phase of lobule formation is that concerned with the vascular system. New lobules are actually in existence when certain relations between the new branches of the portal veins and those of the hepatic veins become established. The new branches of the veins determine the position of the new septa, just as they do shortly before birth when the first evidences of dividing septa appear. In the early stages, before traces of the septa are at all apparent, similar branches of both systems of veins are formed, establish-

ing similar relations to one another. Thus they form undefined lobules, which are only different from those which are separated from one another by connective tissue septa, in that their vascular systems are in more open communication with each other.

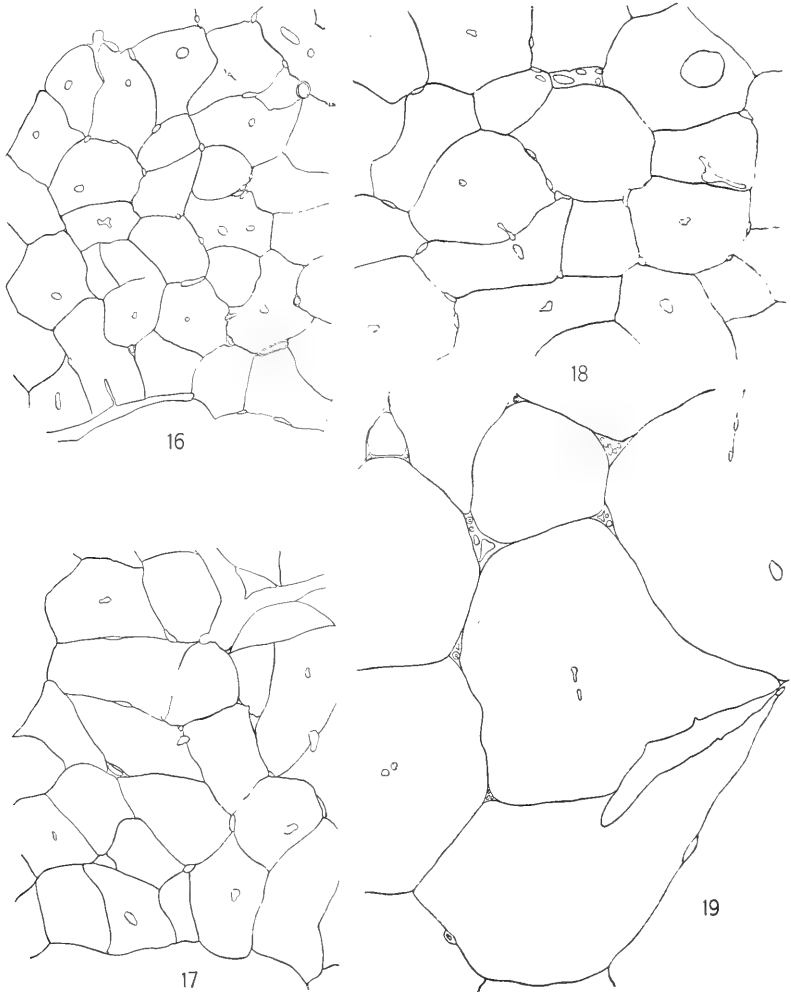
We may unhesitatingly conclude, therefore, that the connective tissue septa play no active part in the formation of lobules in the pig's liver. The boundaries of the lobules are determined by the vascular system; these in turn become apparent by the parallel arrangement of the border cells; finally the connective tissue fibers invade the reticulum between the parallel layers of cells and the septum becomes established. Just what may be the stimulus which causes the growth of the connective-tissue fibers, I have not determined; it may or it may not be due to certain influences of the circulatory system. When this problem is solved we may understand why it is that in certain animals the septa are complete, in others partially, and in still others entirely absent; and further, why in the seal (Mall, '06) the connective tissue septa bound the portal rather than the hepatic lobules.

THE GROWTH OF THE LIVER

I have thus far considered the formation of new lobules without regard to the changes which they produce in the liver as a whole. The growth of the liver is accomplished by two means: first, by an actual increase in size of the lobules; second, by a multiplication of lobules. I have shown in a previous paper the approximate rate of growth of the hepatic lobule of the pig. In the table below, it will be seen that the size of the larger lobules remains constant between the 80-mm. and the 154-mm. stages. From the 229-mm. stage on they show a gradual increase. The growth of the lobule is shown graphically in figures 16 to 19, all of which are camera-lucida drawings of equal magnification.

It was believed by Illing ('05) and Theopold ('10) that after the connective-tissue septa are laid down the growth of the liver takes place entirely by an enlargement of its lobules. Theopold, however, states that the septa are not completely formed until

the first few weeks of postnatal life and that during this time innumerable new lobules are forming. He further states that in the early stages of the liver the hepatic branches outnumber the portal, and that lobule formation ceases when a single portal



Figs. 16 to 19 Outline camera-lucida drawings of lobules of four different stages to show increase in size of hepatic lobules. Fig. 16, 254 mm.; fig. 17, four weeks old; fig. 18, two months old; fig. 19, adult. $\times 25$.

TABLE 1

Table showing the average diameters of some of the larger lobules of the pig's liver at various stages of the development

AGE	DIAMETER	AGE	DIAMETER
	<i>mm.</i>		<i>mm.</i>
80 mm.....	0.33	3 days.....	0.54
111 mm.....	0.33	3 weeks.....	0.49
154 mm.....	0.33	4 weeks.....	0.51
229 mm.....	0.35	2 months.....	0.59
254 mm.....	0.43	Adult.....	1.2 ¹

¹ The diameter of the lobules of the adult pig as given here (1.2 mm.) is the same as that given previously (Johnson, '18 a). Mall ('06) gives it as 1.4 mm. There can be no question that Mall obtained his figures as I did, by averaging only the diameters of large lobules as seen in sections of the liver. The actual 'average diameter' of the liver lobule is an altogether different thing, one difficult to calculate. It must be pointed out, as I have recently shown ('18 a), that the hepatic lobules of the pig vary greatly in size within a single liver, and also that the average size varies for different adult livers. Reference to the table given in my former paper will show how I obtained the 'average weights per lobule' given in the table. From an average of these 'average weights per lobule,' I have attempted to calculate the average diameter, assuming a spherical form for the lobule. This gives 0.8 mm. Since, however, the lobules are not spherical, the diameter would in reality be less than 0.8 mm. With regard to the relatively average diameter of the lobules in the young stages, I am confident that there is less variation in size than in the adult, and that the average diameter of the lobules of the stages 80 to 154 mm. is only slightly less than 0.33 mm.

branch has formed for each hepatic branch present. These observations, however, I have been unable to confirm.

The growth of the lobules likewise takes place in two ways: first, by an increase in the numbers of the hepatic cells and sinusoids; second, as has been pointed out by Toldt and Zuckerkandl ('75) and by Illing ('05), by an actual increase in the size of the hepatic cells. The latter, however, is counterbalanced to a certain degree by a decrease in the diameter of the sinusoids. The rate of increase in size of the cells and sinusoids, and numbers of the cells, is shown in table 2.

The formation of lobules begins at an early stage (Mall's one-lobule stage), and, I believe, continues throughout all stages to the adult. This is in agreement with the statement of Lewis ('12),

that "the multiplication of lobules continues long after birth, and partly divided, compound forms were recognized in the adult by Kiernan." At just what time lobule formation is fully completed I have not determined; there are some evidences that a few lobules are undergoing division in the so-called 'adult' stages I have studied.

In studying the growth of a solid mass of tissue such as the liver, we must consider the possibility of both peripheral and central growth; in the former the increase takes place by a laying down of successive layers on the surface; in the latter the growth takes place by an increase in the size and number of the units within the organ. The growth of the liver may be described as

TABLE 2

STAGE	SIZE OF HEPATIC CELLS IN MICRA	DIAMETER OF SINUSOIDS IN MICRA	ESTIMATED NUMBER OF CELLS IN AVERAGE-SIZED LOBULE
80 mm.....	13.9	22.9	
152 mm.....	12.5	13.6	
254 mm.....	16.0 ¹	8.0	21,000
4 weeks old.....	11.7	9.8	79,000
2 months old.....	13.1	12.1	97,000
Adult.....	19.8	8.0	465,000

¹ The cells in this stage were unusually large and vesicular.

central, that is, taking place more or less evenly throughout. After a study of sections of developing livers, I was at first led to believe that mitosis proceeded somewhat more rapidly in the surface lobules than in the deeper seated ones ('18 b) but the further study of this point does not confirm this view. Mitotic figures even in favorable sections of well-preserved livers are not abundant,¹ making it extremely difficult to note any actual variation in their distribution. I am inclined to believe that in general all parts of the liver are growing at the same rate, since the liver

¹ Illing ('05), who has studied the liver cells of growing and adult animals, states: "In hiesigen Institute (Tierärztlichen Hochschule zu Dresden) sind im Laufe der Jahre Tausende von Leberpräparaten von allen Haustieren untersucht, aber niemals mitotische Kernfiguren gefunden worden."

tissue is everywhere of the same type, since all its parts are equally favored by the circulation, and since, so far as can be determined, dividing cells and lobules are uniformly distributed in sections.

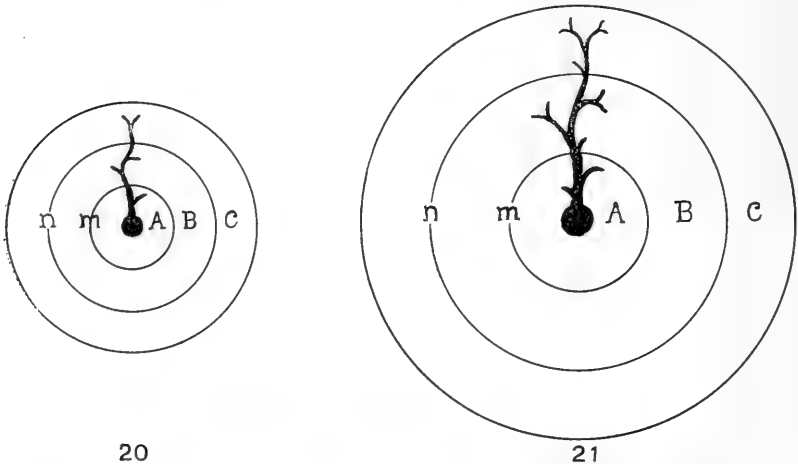
Concerning the growth of the liver, Mall ('06) states:

In development the liver structure shifts distalwards, successively tearing off its capillary connections with the main veins, gradually rearranging the architecture of the lobules, often fracturing and scattering them.

Although I agree with Mall that the liver parenchyma shifts distalward as the liver grows, I do not believe that the lobules become fractured and scattered or that capillary connections are torn away. I find no instances of fractured lobules other than those undergoing normal binary fission and no instances of the scattering of lobules since the lobules maintain their connections with the hepatic veins throughout. As for the tearing away of capillary connections along the beginning of sublobular veins, it seems more probable that such capillaries retract (Clark, '18), because of the decreased flow of blood through them. I believe that the shifting of the liver substance peripherally produces no destructive changes in the arrangement of its units other than that the form of the lobules is altered by the pressure of one lobe against another due to their manner of growth.

That the shifting of the liver tissue from the center towards the periphery is taking place constantly in the growing liver, there can be no doubt. This does not mean, however, that certain lobules or groups of lobules are shifting or slipping past one another or that they shift along the walls of the blood-vessels. In fact, the shifting takes place in such a way that the general relations are not at all disturbed. The blood-vessels, ducts, connective tissue, etc., grow and shift correspondingly with the lobules, and while the liver tissue is shifting from the center toward the periphery, it is not to be inferred that the deeper-seated lobules will eventually come to lie on the surface or even nearer to it. On the contrary, they are continuously getting further and further away from the periphery for the simple reason that the more peripheral lobules are likewise constantly increasing in number.

These points concerning the growth of the liver can best be exemplified by the following diagrams. In figure 20, let the circle *A* represent a circumscribed mass of liver tissue surrounding a large vein of either the hepatic or portal systems. The zones *B* and *C* represent concentric zones of liver substance about *A*. When *A* increases in size (fig. 21), it might at first seem that it would press against the zone *B* and this in turn against *C*, tending to produce changes in them. But the zones *B* and *C* are likewise growing at the same rate as *A*. In their growth they expand just as metal rings expand when they are heated. The



Figs. 20 and 21 Diagrams to show manner of growth of liver as a whole.

fact that the center is filled by *A* alters in no way the shape the zone *B* will assume. The expansion of *C* similarly makes room for *B*. The process is exactly similar to that which takes place in the expansion of any solid ball of metal when heated evenly. A lobule in figure 21 at the point *m* would be further away from both center and periphery than at its former point *m* in figure 20. Similarly, the vein increases in length as the liver expands. Its increase is due in part to the growth at the tips of its branches and in part to an increase in length of its trunk.

The above hypothesis explains in a general way the growth of the liver and is based on the assumption that the liver tissue

is everywhere growing at an equal rate. While this assumption is probably true for groups of lobules taken collectively, it is not always true within individual lobules. I have shown above that when a lobule grows, it may increase more in one diameter than in another. It is probable that this type of unequal growth gives rise to local pressures here and there and that these in turn determine to a certain degree the shapes of the lobules.

CONCLUSIONS

1. The first evidence of connective tissue septa found was in an embryo of 254 mm. in length. The growth of the septa is gradual and they are not fully formed until about two months after birth. Their origin is first indicated by the arrangement of the border cells of the lobules in parallel layers. The connective tissue of the portal canals sends sprouts into the reticulum between the layers of border cells. These sprouts, coming from opposite directions, meet in the region of the nodal points thus completing the septa. Additional septa are formed with the development of new lobules. Their paths are similarly marked out by the parallel arrangement of border cells. The collagen fibrils of these septa sprout out from the connective tissue about the portal veins and from that of those septa already present.

2. The collagen fibrils of the capsula fibrosa (Glissoni) appear first in the region of the porta hepatis and spread over the surface of the liver. They completely cover the liver in a pig of 111 mm. The capsule remains as an extremely thin and delicate layer until birth, after which time it gradually thickens.

3. The formation of new lobules may be described as a necessary readjustment on the part of the parenchyma to circulatory difficulties. It is accomplished by a binary fission of lobules already present, the cleavages taking place only in lobules which have developed two central veins. The new central veins may arise, 1) by a bifurcation of the tip of a growing central vein, or 2) by a sprout from the side of an existing vein. The plane of cleavage bisects the angle formed by two new veins. The cleavage is evidenced by the arrangement of the hepatic cells into parallel

layers, into the reticulum between which collagen fibrils push from the surface of the lobule. In the case of 1) the septum completes itself gradually in the plane of the old central vein, which, when the septum is complete, becomes a sublobular vein. Usually before the septum is fully completed the newly formed lobules show evidences of further segmentation.

4. The growth of the portal veins takes place by an increase in length and by the formation of new branches which spread themselves between the lobules. They grow into the nodal points and split them up into additional ones.

5. The central veins grow by an increase in length and by the formation of new branches which are always intralobular in position. They are directed and grow toward certain nodal points, but never reach them.

6. In their growth both the terminal hepatic and portal veins never approach nearer one another than one-half the diameter of the lobules, as pointed out by Mall.

7. The connective tissue septa of the pig's liver play only a passive rôle in the formation of new lobules. They grow in between the new lobules after they have really formed.

8. The growth of the liver takes place throughout all stages, 1) by an increase in the number of its lobules; 2) by an increase in size of its lobules.

9. The growth of the lobules likewise takes place, 1) by an increase in the numbers of its hepatic cells and sinusoids; 2) by an increase in the size of the hepatic cells. The latter is counterbalanced to a certain degree by a decrease in the diameters of the sinusoids.

10. In general, all parts of the liver grow simultaneously and equally. There is a constant shifting of lobules peripherally, but this takes place in such a way as to produce a minimum amount of change in the relation of one lobule to another.

11. It is probable that the lengthening of lobules in their growth (not an equal swelling in all directions) produces local disturbances which manifest themselves by giving rise to the great variety in shapes of the lobules.

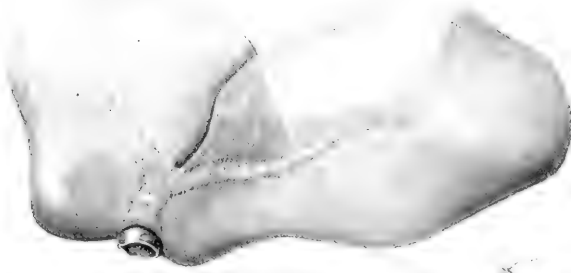BIBLIOGRAPHY

- CLARK, E. R. 1918 Studies on the growth of blood-vessels in the tail of the frog larva—by observation and experiment on the living animal. *Am. Jour. Anat.*, vol. 23, pp. 37-88.
- DEBEYRE, A. 1910 Morphologie du lobule hépatique. *Bibl. Anat.*, T. 19, pp. 249-263.
- ENGEL, C. S. 1899 Die Blutkörperchen des Schweines in der ersten Hälfte des embryonalen Lebens. *Arch. f. mikros. Anat.*, Bd. 54, S.24-59.
- FELIX, W. 1892 Zur Leber- und Pankreasentwicklung. *Arch. f. Anat. und Entw.*, S. 281-328.
- ILLING, G. 1905 Vergleichende histologische Untersuchungen über die Leber der Haussäugetiere. *Anat. Anz.*, Bd. 26, S. 179-193.
- JOHNSON, E. P. 1917 The later development of the lobule of the pig's liver. *Anat. Rec.*, vol. 11, pp. 371-372.
1918 a The isolation, shape, size, and number of the lobules in the pig's liver. *Amer. Jour. Anat.*, vol. 23, pp. 273-283.
1918 b Additional notes concerning the development of the pig's liver. *Anat. Rec.*, vol. 14, p. 40.
- KIERNAN, F. 1833 The anatomy and physiology of the liver. *Trans. Roy. Soc. of London*, pp. 711-770.
- KÖLLIKER, A. 1879 Entwicklungsgeschichte des Menschen und der höheren Wirbeltiere. II Aufl., Leipzig.
- KOSTANECKI, K. V. 1892 Die embryonale Leber in ihrer Beziehung zur Blutbildung. *Anat. Heft.*, Bd. 1, S. 303-322.
- LEWIS, F. T. 1912 The development of the liver. In Keibel and Mall's *Human Embryology*, vol 2, pp. 403-428. Philadelphia and London.
- LOBENHOFFER, W. 1908 Über extravaskuläre Erythropoëse in der Leber unter pathologischen und normalen Verhältnissen. *Beitr. zur. path. Anat. und zur Allg. Path.*, Bd. 43, S. 124-146.
- MALL, F. P. 1896 Reticulated tissue and its relation to connective tissue fibrils. *Johns Hopkins Hospital Reports*, vol. 1, pp. 171-208.
1906 A study of the structural unit of the liver. *Am. Jour. Anat.*, vol. 5. pp. 227-308.
- MINOT, C. S. 1900 On a hitherto unrecognized form of blood circulation without capillaries in the organs of vertebrata. *Proc. of the Boston Soc. of Nat. Hist.*, vol. 29, pp. 185-215.
- ROUX, W. 1895 Gesammelte Abhandlungen über Entwicklungsmechanik der Organismus. I. Functionelle Anpassung. Leipzig.
- THEOPOLD, J. 1910 Untersuchungen über die Entwicklung der Leberläppchen des Schweines. Bern. 32 pp.
- TOLDT, C., UND ZUCKERKANDL, E. 1875 Über die form und Texturveränderungen der menschlichen Leber während des Wachstums. *Sitz.-Ber. der Kais. Akad. der Wiss. Wien*, Bd. 72, Abt. 3, S. 241-295.
- VAN DER STRICHT, O. 1892 Nouvelles recherches sur la genèse des globules rouges et des globules blancs du sang. *Arch. di Biol.*, T. 12, pp. 199-344.

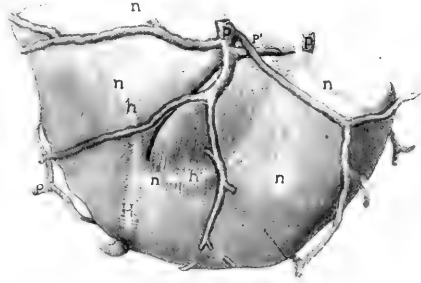
PLATE 1

EXPLANATION OF FIGURES

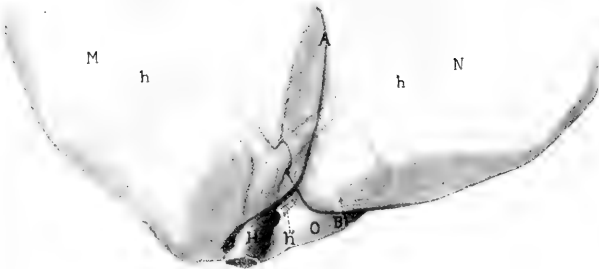
- 22 Dividing lobule of the liver of a two-months-old pig. × 55.
- 23 Dividing surface lobule of same liver. × 55.
- 24 Dividing lobule of same liver; for description see page 314. × 55.
- 25 Dividing surface lobule of same; for description see page 314. × 55.
- 26 Dividing lobule of same, showing both portal and hepatic veins; for description see page 315. × 55.



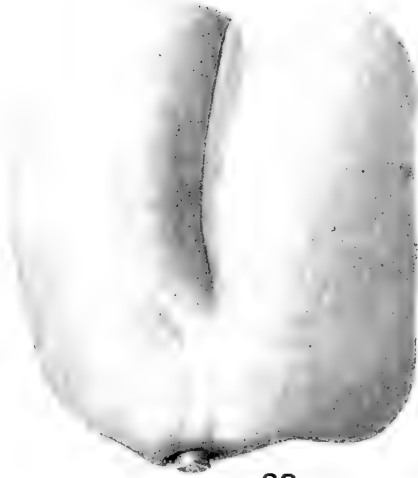22



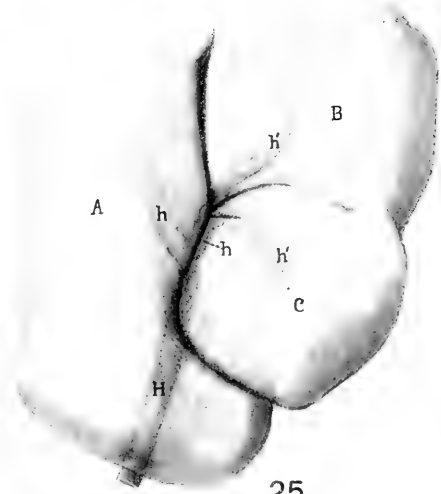
26



24



23

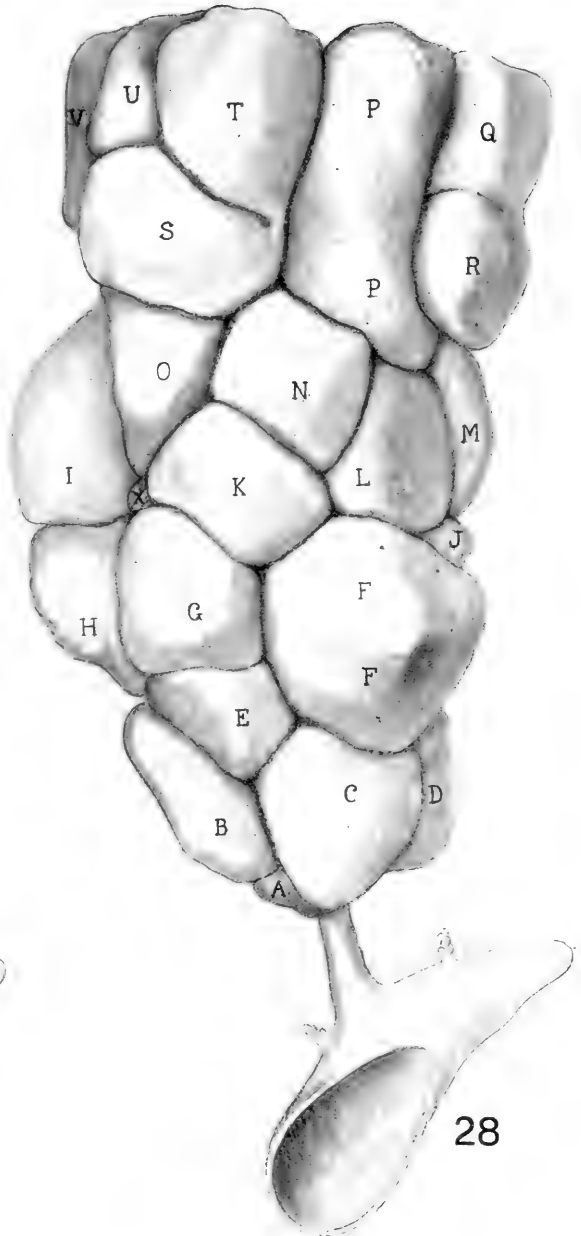
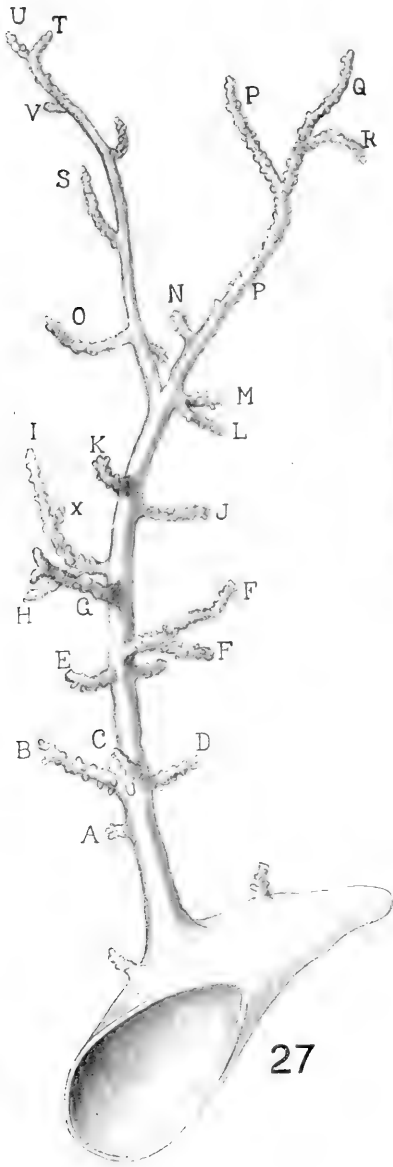


25

PLATE 2

EXPLANATION OF FIGURES

27 and 28 Wax reconstructions of hepatic tree with the group of lobules which it drains. The central veins and the lobules which they drain have corresponding letters. Those central veins not lettered belong to lobules not shown in figure 28.



Resumido por la autora, Lucile Witte.

Histogénesis del músculo cardíaco del cerdo con relación a la aparición y desarrollo de los discos intercalados.

1. El tejido cardíaco del cerdo tiene al principio estructura celular y está compuesto de células fusiformes que más tarde se anastomosan terminal y lateralmente para formar una red de fibras. 2. La estriación aparece más temprano en los discos que en las otras partes, pero en focos diseminados en toda la extensión del tejido. 3. Los discos aparecen en el estado de embrión de 76 mm. de longitud, mucho más pronto que en cualquiera de los animales estudiados hasta el presente, con la excepción del embrión del gato de cuatro días. 4. Los discos aparecen primero como puntos o bandas incompletas que comienzan en la periferia de la fibra y crecen hacia su interior. Avanzando el desarrollo se transforman en discos planos que atraviesan toda la fibra extendiéndose después a dos o más fibras y finalmente adoptan el tipo más complejo de discos. 5. Los discos no son más numerosos en las áreas contraídas que en las relajadas. 6. Los discos no se presentan en los extremos de una serie de núcleos, constituyendo de este modo una célula, porque se presentan invariablemente en íntimo contacto unos con otros, apareciendo en manchas, y raras veces existe un núcleo entre ellos. 7. La autora propone la teoría que supone a los discos como bandas encargadas de reforzar las fibras musculares, puesto que aparecen próximamente durante la transformación de las células en fibras y aumentan en número y complejidad con el crecimiento y actividad del corazón.

HISTOGENESIS OF THE HEART MUSCLE OF THE PIG IN RELATION TO THE APPEARANCE AND DEVELOPMENT OF THE INTERCALATED DISCS

LUCILE WITTE

Department of Zoology, University of Kansas

EIGHTEEN FIGURES

INTRODUCTION

It is the purpose of this paper to discuss the histogenesis of the heart muscle of the pig with special emphasis upon the time of appearance and the development of the intercalated discs. It is a much-disputed question whether the intercalated discs are true cell boundaries of muscle cells or whether they are only peripheral, darker staining substances in the regular form of bands. A further aim of this paper is, if possible, to throw some light on the question stated above, by tracing carefully the formation of the discs with regard to their probable function.

METHODS

In making this study, pig embryo and young pig hearts were used in the following series, respectively, 25 mm., 38 mm., 76 mm., 89 mm., 95 mm., 102 mm., 115 mm., 120 mm., 140 mm., 165 mm., 176 mm., 182 mm., 201 mm., 238 mm., 251 mm., 277 mm., and 303 mm., and four months, five months, eight months, and one year. Only the ventricular muscles were examined. The method of technic found most satisfactory for demonstrating the discs clearly was that employed by Zimmerman¹ and his students Palczewska² and Werner.³ The tissues were fixed in a solution of absolute alcohol and 25 per cent nitric acid and stained 'in toto' in Grüber's haemalum, after which they were embedded according to the usual paraffin method. Sections were cut at 5 μ and 8 μ .

Other methods of staining were used with no success at differentiating the discs. The iron-hematoxylin method was used on the earlier tissues with no results and the Delafield's hematoxylin with an eosin counterstain was used on the older tissue where the discs are known to exist, with equally unsuccessful results. The striations, however, were very evident.

HISTORICAL REVIEW

Zimmerman,¹ Palczewska,² and Werner³ in 1910 worked out very complete studies of adult human and mammalian heart muscle with regard to the function of the intercalated discs and they all concluded definitely that the discs did form distinct cell boundaries. Palczewska, in her work on the human heart, evolved some diagrams (figs. 2, 9, and 10) which at first glance would seem very convincing. However, on closer study, they cannot be accepted. H. E. Jordan⁴ has reviewed both Palczewska's and Werner's papers in his study of the heart muscle of the humming-bird, and the reader is referred to his paper for a more detailed review. Werner, in making her study of the mammals, worked out the cardiac muscle of the adult pig quite thoroughly, and she noticed a striking peculiarity which was that the nuclei of the 'muskeltterritorien' tended to range themselves in long rows, numbering in multiples of from 2 to 32, though the most usual number was 8. The intercalated discs seemed to divide these series of nuclei into distinct cells, as her figures 1, 2, 3, and 4 show. She compared the ventricular muscles with those of the auricles and found that the nuclei were not nearly so numerous in the auricles ranging usually in number from 1 to 2 and 4. The discs occurred in zigzag lines in both ventricle and auricle.

Concerning the structure of heart tissue, Jordan⁴ stated briefly that in the humming-bird the muscle "is syncytial in character, the fibers anastomosing laterally and apically." A distinct membrane or sarcolemma existed and seemed to cover the entire fiber.

J. B. MacCallum,⁵ in his study of the histogenesis of heart tissue, used the pig embryo in a series of from 10 to 100 mm.

He found that there were four different types of cells in the heart of the 10-mm. pig. One presented a network of irregular meshes in which there was a clear, unstained substance; another, a regular network; a third, a network in which some of the meshes were broken up into smaller discs by radial division, and fourth, a network in which a single row of fibrils began to appear. The later stages of development showed an increased number of fibril bundles. The cells of 55-mm. embryo hearts were still spindle-shaped, but very much lengthened, and in the 72-mm. and 100-mm. stages the cells had lost the spindle form and had taken almost the form of the adult muscle. The fibrils were found to be all through the cell rather than just at the periphery. MacCallum described the adult muscle of the human heart as being composed of rhomboidal cells two or three times wider than long. They sometimes broke up into branches which united with branches from other cells. The lines of union were at acute angles to the length of the fibers and each fibril of the cells sent out two or three processes which ran through these lines of union and met each other. He represented by his figure 1 a very complex structure and stated that the same structure was not to be found in other animals, but that the structures commonly known as protoplasmic bridges corresponded to his lines of union in the human heart. The cells were composed of fibrils which were stained dark and surrounded by unstained sarcoplasm. He described the fibrils with their surrounding sarcoplasm as made up of discs separated from each other by a narrow line known as Krause's membrane. He found the sarcoplasmic discs also to be divided somewhat radially and the lines of separation were continuous with Krause's membrane.

In the embryonic tissue MacCallum noticed that the cells at the periphery of the heart were farther developed than those at the anterior, indicating that the cells grow on the inside of the muscle. He considered that the development of the cells from an irregular network to cells of the adult form with numerous fibril bundles increased the heart's capacity for work and that the network of the earlier stages must be contractile.

To return to Jordan's paper on the humming-bird, he gave fourteen very conclusive points as to why he thought the intercalated discs could not be cell boundaries. One point which seemed very readily to contradict the cell-boundary theory was that he had found discs which lay over the nucleus. They usually were peripheral in the fiber, and they also varied to a great extent in coarseness—a condition which is not common to cell walls. As has been stated, Jordan concluded from his fourteen observations that intercalated discs were not cell walls or cement lines. As to the function of the discs, he only conjectured. They might have something to do with contraction, since they were found in patches and much more numerous in contracted than in relaxed fibers. His figures, however, failed to prove his statement that the discs were more numerous in contracted than in relaxed areas. Figures 2 and 4 represented discs in contracted fibers, while figures 1 and 3 represented normal areas of the fiber. According to these, there were not as many discs in contraction (fig. 4) as in relaxation (fig. 1 and 3). Figures 1 and 2 might easily be explained as discs occurring in normal relaxed fibers.

Up to the time of writing his paper, Jordan had not found discs in fetal hearts. This would seem to disprove any idea that the discs were related to the rhythmic beat of the heart. His final conclusion was that the discs "were of the same nature as the anisotropic bands, were closely related to them in position, and might represent a definite physiologic or functional state."

H. E. Jordan and K. B. Steele⁶ in 1912 worked out a comparative study of vertebrate hearts in which they attempted to show that intercalated discs were to be found in animals lower than birds and also in fetal material. In this they succeeded, for they were able to demonstrate discs in amphibians (frogs and toads), reptiles (turtles and lizards), and fishes (trout), and in the fetal guinea-pig hearts during the last week of gestation.

The technic used was Zimmermann's. The discs in the fetal hearts appeared simultaneously with the striations and increased in number with the growth of the animal after birth. The discs were also found to be present in a cat embryo of four days.

There is some doubt here, whether this statement refers to the embryo four days after conception or to the animal four days after birth.

The lower vertebrates presented discs which were much less numerous and complex as the animals went down the scale of complexity. These discs presented no evidence in favor of the cell-boundary theory, since they were superficial in position, often lay over a nucleus, were situated at random with relation to the nucleus, and did not appear earlier than the striations. They seemed to be a part of, or closely related to, the anisotropic lines, since they shaded into these and were parallel to them in all cases.

H. E. Jordan and J. B. Banks⁷ in 1917 worked out a study of the intercalated discs in the heart of the beef. In this paper the fetal heart was used after a study of the adult heart had been completed. The youngest fetal heart was one of approximately two and one-half or three months of age. In this, the cells were found to be fusiform, showing some signs of anastomosing laterally and terminally. Slight striations were visible and the intercalated discs appeared as large dots, shading into the telophragma. They were situated at random in the cells, but did not occur at the point of terminal fusion of two cells. None of them were more than peripheral. With the increasing age of the embryo, the discs became more distinct and more complex until in the adult heart they took the form of step-like formations very much complicated in structure.

No investigator, as far as I have been able to find, has taken up the study of fetal heart tissue in any animal with the thought of especial investigation as to the time of appearance of the discs, their development, and their function. Whatever work has been done on fetal material concerning the discs has been more or less superficial, rather than very detailed.

DESCRIPTION

In this description the early stages of the series of pig embryos will be considered briefly with regard to the histogenesis of heart muscle. The later stages will be considered more in detail since they show the origin and development of the discs.

In the 25-mm. embryo heart the cells are spindle-shaped in longitudinal section with a large central nucleus. The cytoplasm of the cells remains clear and here and there very faint striations appear. In cross-section the cells present the same condition that MacCallum describes. The cells seem broken up into smaller sarcoplasmic discs by walls which are continuous with the bounding membrane of the sarcoplasm. Some fibrils have appeared at the centers of these discs.

At 38 mm. the cells have developed into a more fibrous structure. There are still some of the spindle-shaped cells to be found near the center of the ventricle, but the cells of the auricle and peripheral part of the ventricle have elongated into fibers in which the cross-striations appear more distinctly, especially at the periphery of the heart. The fibers are finer and the nuclei are still large and centrally located.

At 76 mm. the cells seem to have lost all semblance to spindle cells, practically all through the heart. They have elongated and anastomosed until there is a complete network or syncytium of fine fibers, all of which are definitely striated. At this stage, darker portions of the striations occur at intervals, beginning at the periphery of the fiber and proceeding across at right angles to the length of the fiber. The discs, as these dark portions very clearly seem to be, do not extend across the entire width of the fiber, but gradually shade into the striations or telophragma (fig. 1). In a few instances, there are faint discs extending entirely across a fiber (fig. 2).

At 89 mm. the general structure of the tissue is the same as that of the preceding stage. The discs, however, are more distinct and almost invariably extend across the fiber. They are no more numerous than in the 76-mm. stage (fig. 3). Figure 4 represents a type of disc which occurs only very rarely at this stage.

The 115-mm. embryo heart presents much more development in the discs. They are much more numerous and distinct and in every case extend entirely across the fiber. In this tissue some of the fibers are wide while others are still narrow (fig. 5). There is no change in the 120- and 140-mm. stages. The discs

are numerous, straight, and occur in patches in areas devoid of nuclei. The general arrangement of the striations is different in that some of the bands present a greater density than others. These light and dark bands occur alternately and are considered by most observers as areas of contraction. I have been unable to find any difference in the distribution of discs in this region and in other relaxed areas. There is also no marked change in the 165-mm. stage.

At 182 mm. we have the first example of a disc extending over more than two fibers. In figure 6 the fibers anastomose terminally and the disc runs across the four fibers.

The 201-mm. embryo heart shows the colorless cytoplasm which exists invariably as a streak through the center of the fiber in older tissue, and surrounds the nucleus. This has not been noticed in the earlier tissues nor is it constant at this stage. The discs run to this cytoplasm, but not across it (fig. 7).

In the periphery of the heart muscle of the 238mm. stage, the polynuclear fibers are first noticed. The nuclei tend to arrange themselves in rows consisting of two or four, rarely three. The mononuclear state exists farther toward the center of the ventricle. The fibers are very compact and give the appearance of broad fibers. The discs take the step formation more regularly than heretofore (figs. 8 and 9).

Figure 10 represents the discs at the 251-mm. stage. They are quite frequent in occurrence and many of them, as here represented, are thick.

Figures 11 and 12 represent the condition of the discs in the 277-mm. and 303-mm. stages, respectively. There is no marked change. The risers occur more frequently and the discs often extend over two or more fibers.

In all of the tissue studied so far the discs have increased in number by means of new and incomplete discs developing and gradually growing across the fiber. Figure 7 is an example of such discs.

There is a gap between the embryonic tissue and the postnatal, since no stages were studied between the 303-mm. pig, which is very close to the age for birth, and the four-month-old tissue. There are, however, no very marked changes between the two.

At five months a new feature in the discs appears. Instead of the discs' extending across the fiber in a compact formation, they seem to be made up of coarser granules on each separate fibril, as is shown in figure 13. Figure 14 shows three fibers which are parallel and are separated by wide, clear spaces. The discs are at the same level in the three fibers, but instead of their being straight bands, they are zigzag, as though the separate fibrils had been pulled back and forth till the regions of coarse granules were out of line with each other. This type of disc occurs quite frequently throughout this stage.

The year-old tissue shows almost entirely the zigzag bands running across several fibers. They cannot be described as exact step formations, for they do not lie parallel to the telophragma (figs. 15 and 16). Those discs which are straight are short. The type of discs and the arrangement of the nuclei in the tissue are just as described by Miss Werner. However, I cannot verify her statement or her drawing showing that the nuclei are bounded at either end of the series by discs. If the discs were visible at one end of the series of nuclei, they were not at the other end.

The year-old tissue, then, represents the limit reached in this study, where the discs extend over several fibers at nearly the same level, or go up and down in a series of 'steps' and 'risers.' These last represent the most complex of the discs found.

DISCUSSION

As regards the early embryonic structure of the heart muscle, I have been able to verify J. B. MacCallum's statements. The early tissue exists as spindle-shaped cells, and it is very evident how the individual cells gradually anastomose and form the fibers of the adult heart tissue. MacCallum contends that these spindle-shaped cells gradually lengthen and branch and unite with each other at the ends of the branches by definite lines of demarcation. He adds that these lines of demarcation correspond to the protoplasmic bridges found in tissues of other animals described by some investigators.

Thus MacCallum places himself on the side with Zimmermann and his students and contends that adult heart muscle does not

become truly syncytial, but remains cellular with the lines of demarcation, or discs, as I shall call them, representing the walls between the cells.

In my study of this change from cellular to fibrous tissue, I cannot show that the discs form cell walls. They are too irregular in position and too infrequent in occurrence at such an early stage.

Observations show that striations and discs do not appear simultaneously in the heart tissue of the embryonic pig. The striations appear first. These facts need not contradict what Jordan and Steele said, for they studied the embryonic heart of the guinea pig and cat. Nor should they contradict Jordan and Banks' statement that the discs appeared in the heart of beef simultaneously with the striations. The other work done on fetal material with regard to the discs has been more or less superficial. However, it may be true that the time of appearance of the discs varies widely among the different animals.

It cannot be said that the discs in the embryonic pig's heart are cell walls or cement lines. In the first place, they are only peripheral, for they pass out of focus very readily. Nowhere in the tissue is it possible to keep the discs in focus through the entire thickness of the fiber. Also, they occur so many times in rather close proximity with no nucleus between them, as is shown in figures 5, 7, 9, 10, and 11. The discs do not present a different structure in the older material except that they are more complex and occur more frequently in step-like forms. They are still peripheral in the five-month tissue and they are very distinctly darkened, portions of each fibril arranged in the form of a band, rather than extending across the fiber as a connected disc (figs. 13 and 14). These facts would disprove what Zimmermann, Palczewska, and Werner concluded concerning the intercellular nature of the discs.

✓ Jordan presents the theory that the discs may be functional in connection with the contraction of the heart. From the facts observed in this study, it seems improbable that the discs would be caused by the contractions of the heart muscle or would result from the rhythmic beat of the heart. The striations do not ap-

pear till the heart has attained definite form, some time after the beating of the heart begins. The discs do not appear till some time after the striations, so that any theory that discs were formed at contraction or with the beginning of contraction of the heart would be disproved.

It may be that the discs develop physiologically for the purpose of strengthening the muscle fibers. They appear shortly after the striations and at about the time the muscle cells begin to anastomose and form fibers. The fact that the discs become more numerous and complex with the increasing growth and activity of the heart seems to strengthen the theory mentioned above.

SUMMARY

1. The early heart tissue of the pig is cellular in structure, composed of spindle-shaped cells which later anastomose terminally and laterally to form a network of fibers.

2. The striations appear earlier than the discs, but only here and there throughout the tissue.

3. The discs appear at the 76-mm. stage, much earlier than in any other animal studied, with the exception of the cat embryo of four days.

4. The discs are at first dots or incomplete bands beginning at the periphery of the fiber and growing across. With the advance in development, they become straight discs across the entire fiber, then across two or more, and finally assume the more complex type of discs and 'risers.'

5. The discs do not appear more numerous in contracted areas than in relaxed areas.

6. The discs are not to be found at either end of a series of nuclei, thus forming a cell, for they are almost invariably in close proximity to each other, occurring in patches, and seldom is a nucleus to be found between them.

7. The theory is put forth that the discs serve as strengthening bands in the muscle fibers, since they appear at about the time of the change from cells to fibers, and increase in number and complexity with the growth and activity of the heart.

In conclusion, I wish to acknowledge my indebtedness to Prof. W. J. Baumgartner for his aid in obtaining material and for his very helpful suggestions and criticisms.

BIBLIOGRAPHY

- 1 ZIMMERMANN, K. W. 1910 Über den Bau der Herzmuskulatur. Arch. f. Mik. Anat., Bd. 75, S. 40.
- 2 PALCZEWSKA, IRENE VON 1910 Über die Structur der menschlichen Herzmuskelfasern. Arch. f. Mik. Anat., Bd. 75, S. 41.
- 3 WERNER, MARIE 1910 Besteht die Herzmuskulatur der Säugetiere aus alseits scharf begrenzten Zellen oder nicht? Arch. f. Mik. Anat., Bd. 75, S. 101.
- 4 JORDAN, H. E. 1911 The structure of the heart muscles of the hummingbird, with special reference to the intercalated discs. Anat. Rec., vol. 5, p. 517.
- 5 MACCALLUM, J. B. 1897 On the histology and histogenesis of the heart muscle cell. Anat. Anz., Bd. 13, S. 609.
- 6 JORDAN, H. E., AND STEELE, K. B. 1912 A comparative microscopic study of the intercalated discs of vertebrate heart muscle. Am. Jour. Anat., vol. 13, p. 151.
- 7 JORDAN, H. E., AND BANKS, J. B. 1917 A study of the intercalated discs of the heart of beef. Am. Jour. Anat., vol. 22, p. 285.

DESCRIPTION OF PLATES

The illustrations were made with the aid of the Bausch & Lomb camera lucida.

All figures are of tissue fixed in the alcohol nitric-acid mixture and stained in hemalum according to Zimmermann's technic, and are magnified 3500 diameters, except 17 and 18, which are 2000. The original magnification is reduced one-fifth in reproduction.

PLATE 1

EXPLANATION OF FIGURES

- 1 Fibers from ventricular tissue of 76-mm. pig embryo, in which the discs first make their appearance. The bands here are short or merely granular dots in line with the anisotropic bands.
- 2 Portion of fiber from 76-mm. pig embryo, showing a completely developed disc.
- 3 Type of disc commonly found in an embryo of 89-mm.
- 4 A disc taking the step formation, only rarely found in the 89-mm. stage.
- 5 Fibers from heart muscle of the 115-mm. pig, showing the variable width and the larger number of complete discs.
- 6 Fibers showing terminal anastomosing and a disc running across all four fibers (182-mm. embryo).
- 7 Fibers showing the definite unstained cytoplasm which surrounds the nuclei in older heart tissue almost invariably. Also developing and completed discs are shown which explains how discs become more numerous (201 mm.).
- 8 A definite example of the step and riser found in 238-mm. heart muscle.

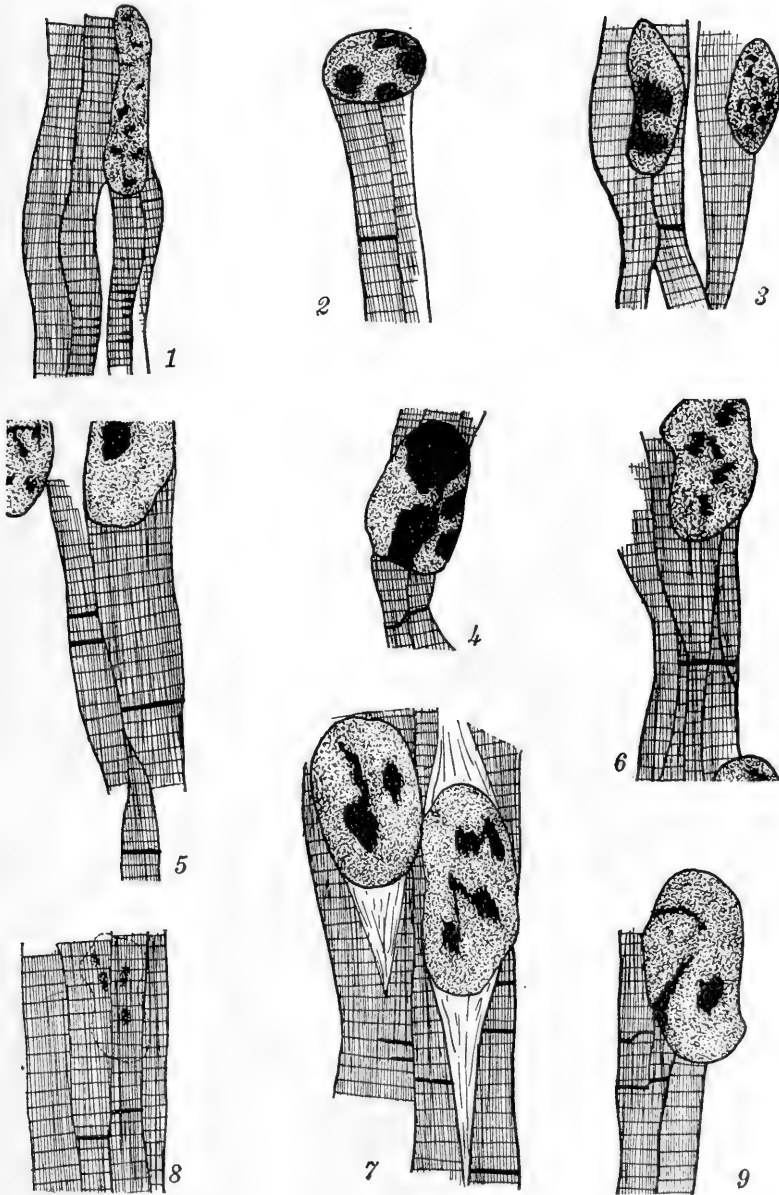


PLATE 2

EXPLANATION OF FIGURES

9 Another example of the 'step' and 'riser' forms of discs found in 238-mm. heart muscle.

10 Discs from the 251-mm. stage. They are thicker at this stage than in the earlier stages.

11 Fibers from the 277-mm. stage, showing a typical grouping of discs.

12 Fibers from the 303-mm. stage, showing a more developed 'step' and 'riser.'

13 Fibers from five-month tissue in which the discs appear as granules laid down on the separate fibrils.

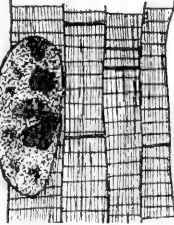
14 Three parallel fibers from five-month tissue in which a peculiar type of zigzag disc occurs.

15 and 16 Zigzag discs as found in year-old tissue. These are very characteristic of this tissue.

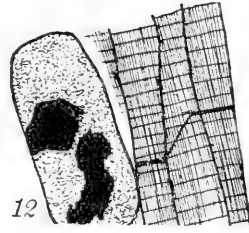
17 and 18 These figures were drawn from 277-mm. tissue at a magnification of 2000 diameters, to show a larger area and thus show the comparison between the number of discs in a contracted area (17) and a relaxed area (18).



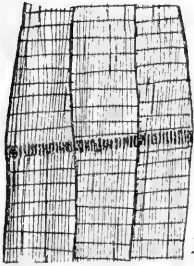
10



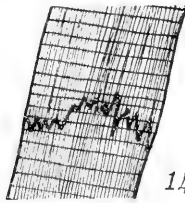
11



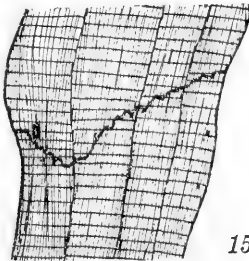
12



13



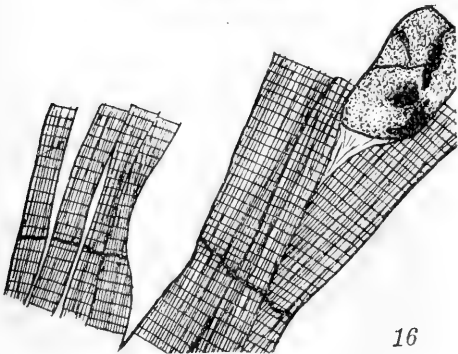
14



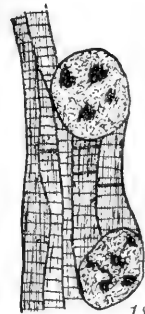15



17



16



18

THE HOMOLOGIES OF THE MAXILLARY AND VOMER BONES OF POLYPTERUS

EDWARD PHELPS ALLIS, JR.

Menton, France

EIGHTEEN FIGURES (THREE PLATES)

In a work published in 1900, on the maxillary and premaxillary bones of Polypterus, I came to the conclusion that those bones were each formed by the fusion of two components usually found separate and distinct in the Holostei and Teleostei, one of those components being developed in relation to the teeth that the bone in question bears, and the other in relation to adjacent portions of the laterosensory canals. The teeth on the maxillary were said to not be the homologues of the maxillary teeth of *Amia* and the Teleostei, and to be, in all probability, dermopalatine ones and the homologues of the maxillary teeth of the Mammalia. The so-called vomer was considered to be developed in the maxillary breathing-valve of the fish.

In a later work (Allis, '14), I described in certain of the Selachii a fold of the mucous lining of the buccal cavity that enclosed the mesial portion of the palatine process of the palatoquadrate. This fold had so strikingly the position of the maxillary breathing-valve of the Teleostei that I suggested that, in the latter fishes, the cartilage enclosed in the fold had been resorbed, thus leaving the fold itself as the breathing-valve of the fish. The so-called vomers of Polypterus, considered to have been developed in this fold, were then mesial dermopalatines, and the maxillary bone a lateral dermopalatine.

In a still later work (Allis, '17, '18), I described the lips and labial folds in certain fishes, and came to the conclusion that the definitive lips of the Crossopterygii, Holostei, and Teleostei were secondary ones that had been developed external to the primary lips, and that that part of the buccal cavity that lies between

these two lips was primarily a part of the external surface of the head. The teeth on the maxillary and premaxillary bones were said to have been developed in relation to the upper one of these two secondary lips, and hence to lie external to the primary lip. The upper labial cartilages of the Selachii were said to occupy a similar position in relation to the secondary lip of those fishes, and, whenever a labial fold had been differentiated, to both lie in that fold.

The maxillary and premaxillary bones of fishes, like the tooth-bearing bones of all vertebrates, are generally considered to have been primarily formed by the fusion of the bases of the teeth they bear. Gaupp ('05), however, says that while these tooth-bearing bones of fishes were undoubtedly thus primarily developed, they frequently later become so completely emancipated from the teeth to which they owe their origin that they develop wholly independently of them, never, in certain cases, having, ontogenetically, any relation to teeth of any kind, while in other cases the teeth and bone may develop independently of each other, and the teeth later become implanted on the bone. Gaupp then further says that the maxillary and premaxillary bones of vertebrates in general consist of two components, a tooth-bearing one derived from fusion of the basal plates of the teeth they bear, and a non-toothbearing, or facial portion, of independent integumental origin.

The tooth-bearing bones of the buccal cavity are said by Gaupp to probably all have been primarily developed in topographical relations to underlying parts of the preexisting cartilaginous skeleton, for there would be no sense in their being developed where there was no firm support beneath them. The underlying structures in relation to which the maxillary and premaxillary were developed are said to have probably been, primarily, cartilages belonging to the category of the labial cartilages, but that, later, secondary relations to the ethmoidal cartilage were acquired. Gegenbaur ('98) apparently held a similar view, and he considered the underlying cartilages in relation to which the maxillary and premaxillary were respectively developed to be the anterior and posterior upper

labials of the Selachii. Teeth could, however, evidently have been developed in relation to any other firm underlying support found in the region included between the primary and secondary upper lips, for, that whole surface having been primarily a part of the external surface of the head, no one part of it was probably better suited than another to the production of teeth. The maxillary teeth of *Polypterus* would then not necessarily belong to the primary dental arcade, and hence be dermopalatine ones, as I formerly concluded, simply because they occupy a position definitely internal to that of the teeth of *Amia*.

This view of the subject has led me to reexamine my *Polypterus* material, and as I find that the labial folds and furrows of that fish were not properly identified in my earlier work, they will be fully redescribed after first describing the condition in *Acanthias*, specimens of which I have received since my recent work (Allis, '18) was sent to press, and also those in *Amia*. The conditions in *Lepidosteus*, *Polyodon*, and certain of the Teleostei will then be considered, and the maxillary bones of these several fishes then compared with those in certain of the early fossil fishes.

ACANTHIAS BLAINVILLII

In this fish (figs. 1 and 2) the labial fold of either side extends dorso-anteriorly beneath the supralabial fold, and the latter fold, pressing upon the labial fold, separates from its oral edge a smaller fold which is all that is seen in external views. This smaller fold encloses the anterior upper labial, and as it is represented, in *Polypterus* and certain of the Teleostei, by a flap-like structure, it may be called the maxillary labial flap. The slight furrow that, in *Acanthias*, separates this fold from the remainder of the labial fold is then the maxillary labial-flap furrow, and it runs anteriorly into the supralabial furrow. The supralabial furrow has, as stated in my earlier work (Allis, '18), supralabial and postlabial portions, and my present work shows that these two parts of the furrow are, in certain fishes, distinctly different morphological structures.

In the lower jaw there is a mandibular labial flap and a labial-flap furrow similar to those in the upper jaw, but much more

strongly developed. This mandibular labial flap and labial-flap furrow both lie external to the mandibular labial cartilage, and, because of this, they were called, in my descriptions of other Selachii (Allis, '18), the supramandibular fold and furrow, but the names above given to them seem more appropriate. Another deep furrow lies internal to the mandibular labial cartilage, and is the mandibular furrow of my recent work, but sublabial furrow seems a better name for it. This sublabial furrow is continuous, posteriorly, with the postlabial furrow, a labial fold with both maxillary and mandibular portions thus being formed.

A deep furrow extends upward between the hind ends of the anterior and posterior upper labial cartilages, and extending laterally (morphologically posteriorly) from the secondary angle of the gape across the labial fold, falls into the postlabial furrow. This furrow thus separates the lateral (morphologically posterior) portion of the labial fold into two parts, a superficial one which encloses the anterior upper labial and a deeper one which encloses the posterior upper and mandibular labials. This furrow may be called the submaxillary one, because in the Holostei and certain of the Teleostei, it lies beneath the hind end of the maxillary bone. In the fishes described in my earlier work (Allis, '18) this furrow was but slightly developed, this being due to the fact that the hind end of the anterior upper labial there articulated with, or was bound by ligament to, either the posterior upper or mandibular labials.

The primary upper lip of *Acanthias* is strongly developed, and between it and the pterygopalatine teeth there is a deep sulcus, which may be called the primary superior alveololabial sulcus. A maxillary preangular crease, such as I described in my recent work, runs symphysially and aborally from the angle of the primary gape, and gradually vanishes on the oral surface of the labial fold, this crease lying external to the primary upper lip, but internal to the posterior upper labial. If teeth were to be developed internal (oral) to this preangular crease, they would evidently still be secondary teeth, but they would not be the homologues of teeth developed along the edge of the labial fold. The crease is continuous, posteriorly, with the anterior end of

a deep furrow that lies along the lateral edge of the posterior portion of the palatoquadrate, and which may be called, for reasons that will later appear, the dorsolateral diverticulum of the buccal cavity. In the other Selachii that I have examined this diverticulum was not so pronounced and evident as in *Acanthias*.

Internal to the primary teeth of *Acanthias*, there is, as in *Mustelus* (Allis, '14, p. 355), a relatively large groove, from the bottom of which a thick fold of tissue arises and projects posteroventrally. I formerly considered this entire groove of *Mustelus* to represent the suprapalatine recess of my earlier descriptions of *Chlamydoselachus*, but a reexamination of my material shows that it is the furrow that lies postero-dorsal to the fold that alone represents that recess, and this furrow is in *Acanthias*, as in *Mustelus*, simply a postpalatine groove and not a suprapalatine recess. Which of these two conditions is the more primitive, I am unable to determine, but the fold of *Acanthias*, which may be called the palatine fold, is certainly the homologue of the mucous fold that forms the posterior portion of the palatine shelf of my descriptions of *Chlamydoselachus*. This fold is found in all of the several species of the Selachii that I have examined, but it varies greatly in different species. In *Scyllium* it is a simple flap which strikingly resembles the maxillary breathing-valve of the Teleostei, but is related to the primary dental arcade instead of to the secondary one. In *Lamna* and *Triakis* it is as in *Mustelus* and *Acanthias*. In *Centrina* it is, as in *Scyllium*, a simple flap, but it projects exteroventrally instead of posteriorly, and there is no furrow along its posteromesial edge.

AMIA

In this fish the conditions were examined in specimens varying from 10 mm. to 45 mm. in length.

The supralabial furrow first appears as a pit-like depression that lies dorsal to the angle of the gape and immediately ventral to the suborbital laterosensory line, as shown in my figure of a 10-mm. specimen of this fish (Allis, '89, fig. 4, pl. 31). In

a 11½-mm. specimen (*l.c.*, fig. 6, pl. 31), this pit-like depression has become a long slit-like furrow which extends posteriorly beyond the angle of the gape and there vanishes on the outer surface of the cheek. The posterior portion of the upper lip, which in the 10-mm. specimen was nearly straight, has, in the 11½-mm. one, grown ventrally so that it overlaps externally the dorsal edge of the mandible. This overlapping portion of the lip forms the ventral half of the future labial fold, and its internal surface is formed by part of the internal surface of the secondary lip. The maxillary preangular crease of the Selachii should accordingly, if present, be found on this surface. In the lower lip a furrow has been developed which, for reasons to be later given, would seem to be a labial-flap furrow and not a sublabial one.

In later stages the hind edge of that part of the upper lip that overlaps externally the dorsal edge of the mandible is prolonged posteriorly, and becomes separated from the side of the head by a crease, rather than furrow, which extends a short distance posterior to the angle of the gape and corresponds to the submaxillary furrow of *Acanthias*. A postlabial furrow is then formed, this furrow extending downward from the supralabial furrow to the hind end of the submaxillary crease. The hind end of the entire labial fold then grows posteriorly, and the fold is completely differentiated, this apparently taking place at different ages in different specimens, for the completed fold is shown in my figure of an 18-mm. specimen, but not yet completely differentiated in a 31-mm. one (*l.c.*, figs. 12 and 13, pl. 34). In these older specimens the supralabial furrow extends anteriorly to the anterior end of the lachrymal bone, and there ends immediately posterior to the articular head of the maxillary. It is, however, the relation to the lachrymal, and not that to the articular head of the maxillary, that determines the length of the furrow, for when the lachrymal has an anterior extension, as in *Gadus*, the furrow continues to its anterior end.

On the roof of the mouth (figs. 15 to 18), immediately external to, and concentric with, the pterygo-palato-vomerine teeth, there is a sulcus which is the homologue of the primary superior

alveololabial sulcus of *Acanthias*. This sulcus begins, posteriorly, somewhat anterior to the transverse plane of the angle of the gape, and is there a slight furrow along the lateral edge of the ectopterygoid, but farther forward it becomes a small but well-developed groove. Still farther forward, in the region of the anterior end of the dermopalatine, the internal edge of this groove begins to flatten out, the external edge at the same time increasing in height and becoming the slightly developed maxillary breathing-valve. That valve is thus formed by the anterior portion of the primary lip of the fish, the posterior portion of that lip being represented in the lateral edge of the slightly developed primary alveololabial sulcus. In a 45-mm. specimen, the line of origin of this lip lies wholly internal to that of the labial fold. In one of two adult specimens examined, its external surface had partly coalesced with the internal surface of the fold in the region of the anterior end of the maxillary, this undoubtedly being an initial step in that attachment of the base of the breathing-valve to the internal surface of either that bone or the premaxillary that is probably found in most, but certainly not in all, of the Teleostei, for in small specimens of *Ameiurus* this fusion does not take place, the primary lip (breathing-valve) having strictly the course and position that it has in *Amia*, and everywhere projecting as a definite lip.

Lateral to the posterior portion of the primary upper lip, there is a maxillary preangular crease, which extends upward lateral to the bottom of the supralabial furrow, these two furrows enclosing between them a thin sheet of integumental tissue which connects the dorsal end of the labial fold with the side of the head slightly dorsal to the lateral edge of the roof of the mouth. This crease is directly continuous, posterior to the angle of the gape, with a dorsally directed diverticulum of the buccal cavity which lies along the lateral edge of the palatoquadrate, and, continuing posteriorly, vanishes in the region of the angle of the primary gape. This diverticulum is thus the homologue of the deep furrow that lies in *Acanthias*, along the lateral edge of the posterior portion of the palatoquadrate of that fish, and in both fishes it lies posterior to the secondary angle of the gape.

The dorsal end of the preangular crease forms the mesial boundary of a slight ridge, or fold, of the tissues at the dorsal edge of the internal surface of the labial fold, this ridge enclosing a ligament which extends from the internal surface of the maxillary bone, near its anterior end, to the top of the coronoid process of the mandible (Allis, '97, p. 548).

The secondary upper lip, represented in the ventral edge of the labial fold, is continued forward to the anterior end of the snout, where it is continuous with its fellow of the opposite side.

The labial fold of *Amia* is thus a strictly maxillary fold, containing no mandibular component and differing markedly in this from the fold of *Acanthias*. The maxillary labial flap of the latter fish is also wanting in *Amia*. It nevertheless seems unquestionable that the supralabial and postlabial furrows of the two fishes are homologous, and, this being so, the deeper part of the maxillary portion of the fold of *Acanthias*, the part that encloses the posterior upper labial, must be contained in the fold of *Amia*, and it is probably represented in that little ridge on the internal surface of the fold of *Amia* that encloses the ligament just above referred to. The mandibular portion of the fold of *Acanthias* must then be represented either in some part of the mandible itself of *Amia* or in the fold of tissue that lies dorso-external to the little furrow that I have described in the mandible. That fold has decidedly the position and appearance of a labial flap, and it contains no tissues that would seem to represent a mandibular labial; and, furthermore, there is, in *Amia*, a tall coronoid process of Meckel's cartilage that may, perhaps, represent a mandibular labial. That process is not found, according to Pollard ('95, p. 413), in any of the Selachii, and in most, if not all, of those fishes there is a mandibular labial. The process lies external to, or gives insertion to, all parts of the adductor muscles of the mandible; and its dorsal end lies posterior to, and approximately in the line of, the secondary angle of the gape. This process and the stout ligament that arises from its dorsal end and runs forward in the little ridge at the dorsal edge of the internal surface of the labial fold, thus have to each other and to the adjacent parts quite closely the relations

of a mandibular and posterior upper labial, and it is quite probable that they represent those labials.

The maxillary bone of *Amia* lies in the labial fold, and although it is found in 12-mm. specimens, the teeth related to it do not appear until much later, when the fish is about 40 mm. in length, and they are implanted only along its ventral edge (Allis, '00, p. 273). This bone is thus certainly not developed, ontogenetically, in any relation whatever to those teeth, and, in my opinion, it is a dermal bone strictly similar, in origin, to the bones that cover the cheek of the fish. That it may have been primarily developed in some relation to underlying labial cartilages is possible, but it seems to me improbable. The teeth that later become implanted upon it were, however, quite probably primarily developed in relation to an anterior upper labial, for the primordium of that labial must lie in the ventral portion of the labial fold. That these teeth and the dermal plate on which they are actually implanted were primarily independent structures would seem to be further shown by the conditions found in most of the Teleostei, for, in those fishes, the dental component of the bone of *Amia* has become attached to the hind end of the premaxillary, and forms a posterior prolongation of that bone, the dermal component of the bone of *Amia* becoming an independent and always non-dentigerous maxillary.

The maxillary and premaxillary teeth all issue from the secondary lip slightly internal to its ventral edge, and there is no sulcus formed external to them. The maxillary teeth are much smaller than the premaxillary ones, and seem to be a later and wholly independent acquisition. The premaxillary teeth have the appearance of completing the pterygopalatine arcade; as if they had primarily occupied the existing interval between the dermopalatine teeth of opposite sides, and had then been carried bodily forward onto the ventral edge of the secondary upper lip, as seen in my figures of this fish (Allis, '98). But if this had been the case, the fold that I consider to be the primary upper lip would evidently be formed by the palatine fold of *Acanthias*, and that cannot be, for the fold of *Amia* is continued posteriorly external to the external edge of

the palatoquadrate, while the fold of *Acanthias* lies, throughout its entire length, posteromesial to that cartilage. There apparently is in *Amia* no fold that corresponds to the palatine fold of *Acanthias*.

The vomer bones of *Amia* lie posterior to the primary upper lip, and hence are ossifications in the roof of the buccal cavity. The dermopalatine is a lateral dermopalatine.

POLYPTERUS

In *Polypterus* there are, as is well known, thick fleshy upper and lower lips, each of which has the appearance of having been folded back upon the remainder of the lip. In my earlier work on this fish (Allis, '00), I considered these apparently folded-back portions of the lips to, alone, represent the maxillary and mandibular labial folds, but it was said that there were, internal to each of these folds, another smaller one. I now find that the so-called labial folds of these earlier description are simply labial flaps, apparently strictly similar to those above described in *Acanthias*, and that they and the so-called smaller folds that lie internal to them together form the entire labial fold. The folds and furrows of this fish must accordingly be fully redescribed, and for this purpose I have made use of serial sections of a 75-mm. specimen of *Polypterus senegalus*, certain of the sections being reproduced in the accompanying figures 5 to 14. Figure 3 gives a lateral view of the head of a small adult *Polypterus*, with the mouth slightly opened, and figure 4 a similar view with the mouth forced widely open.

The maxillary labial-flap furrow, which separates the maxillary labial flap, above referred to, from the remainder of the labial fold, begins immediately anteromesial to the nasal tube, encircles the lateral edge of that tube and then continues posteriorly to the ventral corner of the labial cartilage, where it ends external to that cartilage. The maxillary labial flap, which lies external to this furrow, thus encloses no portion of the labial cartilage, and there is no other cartilage or bone enclosed in any part of it. Otherwise, the flap and furrow apparently correspond strictly to those in *Acanthias*, excepting in

that they have a greater anterior extension, which is doubtless due simply to the greater extension of the secondary lip.

Slightly posterior to the nasal tube, the labial-flap furrow crosses the anterior section of the main infraorbital laterosensory canal, passing across the primary tube that issues from that canal between the lachrymal bone and the antorbital process of the premaxillary. If the furrow were to be here deepened, it would evidently interfere with the development of the laterosensory canal, and this is apparently what has taken place in many of the Teleostei, for a furrow is there found that is either the homologue of this labial-flap furrow or is a closely adjacent, but independent furrow, and it extends across the dorsal surface of the anterior end of the snout to fall into its fellow of the opposite side. In all such fishes, so far as I know, the antorbital section of the infraorbital canal is short, or even wholly wanting, and associated with this absence of the canal there is no independent antorbital bone. Furthermore, it is, so far as my material permits me to judge, only in these fishes that the premaxillary is prolonged more or less posteriorly into the labial fold, and that the upper jaw becomes more or less protrusive.

The supralabial furrow of *Polypterus* begins near the anterior edge of the eyeball, along the ventral edge of the lachrymal bone, as a slight furrow which lies internal to the dorsal edge of the maxillary labial flap. Proceeding posteriorly from there, this furrow deepens and soon becomes a deep cleft which arches upward beneath the laterosensory component of the maxillary bone and then downward to a line that lies, in its anterior portion, lateral to the bases of the maxillary teeth, but, in its posterior portion, along the lateral edge of the ectopterygoid.

On the roof of the mouth, internal to the labial fold and immediately external to, and concentric with, the premaxillo-maxillary dental arcade, there is a furrow which, because of its relations to that arcade, may be called the secondary superior alveololabial sulcus. The bottom of this sulcus is, in the region of the anterior end of the maxillary labial-flap furrow, directed toward the bottom of that furrow, the bottoms of the two furrows being separated from each other by a narrow band of in-

tegumental tissue which connects the labial fold with the lateral surface of the head immediately dorsal to the bases of the maxillary teeth. Proceeding posteriorly in the sections, these two furrows deepen, the bottom of the maxillary labial-flap furrow passing downward lateral to that of the secondary alveololabial sulcus and diverging gradually from it. The narrow band of integumental tissue that connects the anterior end of the labial fold with the side of the head thus becomes considerably widened, and, at the same time gradually thickening, becomes the deeper and larger part of the maxillary portion of the entire labial fold. Farther posteriorly, where the anterior end of the supralabial furrow is first cut in the sections, the bottom of that furrow is directed toward the bottom of the secondary alveololabial sulcus, the bottoms of these two furrows there enclosing between them a thin and narrow band of integumental tissue which connects the labial fold with the side of the head. Proceeding posteriorly from there, the supralabial furrow deepens, its bottom passing downward lateral to that of the alveololabial sulcus, and the anterior end of another furrow is soon cut in the sections. This latter furrow lies lateral to the secondary alveololabial sulcus and lateral also to the bottom of the supralabial furrow, and as its course and position indicate that it is quite certainly the homologue of the maxillary preangular crease of *Acanthias*, it may be so designated. The supralabial furrow now gradually becomes arched in transverse section, running at first upward and then downward beneath the canal-bearing component of the maxillary bone, and when the region of the lateral process of the ectopterygoid is reached, the dorsal portion of the labial fold is wholly concealed beneath the overhanging, canal-bearing component of the maxillary. The anterior portion of the labial cartilage is here cut in the sections, and the sheet of integumental tissues that connects the dorsal end of the labial fold with the side of the head is, when the mouth is closed, markedly U-shaped in transverse section. When the mouth is opened and the labial fold extended, this 'U' is pulled out into a flat sheet, but its proximal and distal (labial) edges are still marked, respectively, by the bottoms of the secondary alveololabial sulcus and the maxillary preangular crease.

Internal (posteromesial) to the maxillary and premaxillary teeth, between them and the external edges of the ectopterygoids and so-called vomers, there is a well-developed sulcus, and internal (posteromesial) to the vomers there is a depressed region bounded on either side by a sulcus which passes slightly beneath (dorsal to) the vomer and ends, posteriorly, along the mesial edge of the anterior end of the ectopterygoid. This latter sulcus thus certainly corresponds to the postpalatine furrow of *Acanthias*, and the vomers certainly lie, in part, in a palatine fold. The only question then is, does the furrow that, in *Polypterus*, lies between the vomer and the premaxillary teeth correspond to the furrow that, in *Acanthias*, lies between the palatine fold and the palatine teeth, or to the sulcus that lies external to the latter teeth; and there seems no question that it corresponds to the latter sulcus, and hence is a primary superior alveololabial sulcus, for its posterior continuation lies definitely along the lateral edge of the ectopterygoid.

The premaxillomaxillary dental arcade of *Polypterus* is thus a secondary one, but it apparently lies directly along the line of the primary lip, instead of anterior to that lip. A slight sulcus, only, separates the premaxillary teeth from the ventral edge of the secondary lip, this sulcus becoming, opposite the maxillary teeth, the well-developed secondary alveololabial sulcus already described. Posterior to the most posterior maxillary tooth, this secondary alveololabial sulcus and the primary one are separated, for a certain distance, by a ridge of the mucous lining membrane of the roof of the mouth, but this ridge gradually diminishes posteriorly, and vanishes at the anterior edge of the lateral process of the ectopterygoid. The primary and secondary alveololabial sulci are then represented, for a certain distance, by a single sulcus, which passes ventral to the lateral process of the ectopterygoid and vanishes posterior to the angle of the gape.

The fold of the secondary upper lip has thus been carried forward until it falls into its fellow of the opposite side at the anterior end of the snout, but in its anterior portion it passes so close to the primary lip that it is there but slightly differentiated from it. In accord with this, and also in confirmation of it,

there is, in this fish, no maxillary breathing-valve, that valve being formed, as already explained, by the anterior portion of the primary lip.

In the lower jaw there are two furrows that correspond, in their relations to the lower lip, to the supralabial and maxillary labial-flap furrows in the upper lip. One of these furrows separates the dermal flap of the lower lip from the remainder of that lip, and is the mandibular labial-flap furrow. Like its fellow in the upper lip, it begins far forward and extends posteriorly to the ventra end of the labial cartilage, being deep in its middle portion and vanishing at either end. The other furrow is a sublabial one, and separates the mandibular portion of the labial fold from the external surface of the mandible. It begins anteriorly in about the transverse plane of the anterior end of the supralabial furrow, and there lies, like that furrow, internal to the free edge of the related labial flap. Posteriorly it becomes deeper, and at its hind end passes upward beneath the hind end of the labial fold and is confluent with the hind end of the supralabial furrow. These two mandibular furrows lie, the one directly beneath the lateral edge of the oral surface of the lower lip and the other beneath the mesial edge of that surface (figs. 8 to 11). The lip here presents, in transverse sections, three surfaces, one presented mesially, one dorsolaterally, and the other ventrolaterally. The surface that is presented dorsolaterally increases in width posteriorly, and at the angle of the gape coalesces with the internal surface of that posterior portion of the maxillary portion of the entire labial fold that encloses the labial cartilage. Along the median line, approximately of this surface of the lower lip, there is a furrow formed by a fold in the lip that is related to its attachment to the top of the ascending process of the splenial, this furrow corresponding approximately to the mandibular preangular crease of *Acanthias*. Internal to the lip, between it and the dentary teeth, there is a secondary inferior alveololabial sulcus, and between the dentary and splenial teeth a primary inferior alveololabial sulcus.

When the upper and lower lips have coalesced at the angle of the gape, as above explained, the labial fold projects ventro-

laterally, its ventral end being free and its dorsal end attached to the side of the head by two sheets of integumental tissue, one of which extends to the lateral edge of the ectopterygoid and the other to the dorsal edge of the mandible. These two sheets of tissue enclose between them a dorsolateral diverticulum of the buccal cavity similar to that in *Amia*, and it corresponds, in position, to what Greil ('13) calls, in *Ceratodus*, the premandibular furrow (*Praemandibularfalte*). This furrow is a direct posterior continuation of the maxillary preangular crease, and, diminishing in depth posteriorly, vanishes near the quadrato-mandibular articulation. Posterior to the angle of the gape, the ascending process of the splenial rises in the integumental sheet that connects the dorsal end of the labial cartilage with the dorsal edge of the mandible, and the dorsal end of the labial now becomes attached to the dorsal end of this process. This process of the splenial is called by Traquair ('70) the opercular process, but it is the homologue of that process of reptiles, formed by the so-called complementary, and not of the opercular process of *Amia*, which is a process of Meckel's cartilage and wholly wanting in *Polypterus*.

The labial cartilage is, as described in my earlier work, somewhat triangular in shape, with a long straight dorsoposterior edge, and anterior and anteroventral edges that are somewhat rounded and separated by a rounded angle. The ventral corner of the cartilage is also rounded, but a pad of tough ligamentous tissue lies against the posterior surface of this rounded angle and gives to the entire structure a right-angled postero-ventral corner, the posterior edge of this angle lying in the line of the straight posterior edge of the labial cartilage, while the ventral edge forms a short straight ventral edge to that cartilage. The anterior end of this so-formed short ventral edge of the labial cartilage lies directly posterior to the secondary angle of the gape, its hind end forming the ventral end of the posterior edge of the labial fold. There is no furrow running from the angle of the gape across the labial fold and corresponding to the submaxillary furrow of *Acanthias*. When the mouth is widely opened (fig. 4), the labial cartilage lies in a nearly horizontal

position, the hind end of the labial fold, in which the cartilage lies, forming a narrow horizontal shelf which projects posteriorly from the angle of the gape. Anterior to this cartilage, the oral edges of the maxillary and mandibular portions of the labial fold lie, at first, at right angles to the cartilage, and then each curves gradually forward toward the anterior end of the jaw to which it is related.

The maxillary and dentary bones are both somewhat scooped out, on their external surfaces, to lodge the related portions of the labial fold, this being particularly marked on the maxillary. No bone is found in any portion of the labial fold. The labial cartilage is, in my 75-mm. specimen, apparently of cartilage that is strictly similar to the other cartilages of the head.

Posterior to the hind end of the labial fold, the supralabial and sublabial folds coalesce, excepting as they are in part separated by a thin web of integumental tissue, and the dorsal edge of the one furrow and the ventral edge of the other meet at an acute angle which forms what I called, in *Ceratodus* (Allis, '18), the tertiary angle of the gape. The lines that bound this angle in *Ceratodus* I considered to represent tertiary upper and lower lips, the upper lip alone becoming functional and forming the definitive upper lip of the fish. The secondary upper lip was said to be hardly recognizable in my specimen of *Ceratodus*, and to be found at the angle of the gape. My present work tends to confirm this conclusion, and I now definitely identify the secondary lip in the short fold shown lying immediately anterior to the secondary angle of the gape in the figure given in my earlier work (i.e., fig. 9). I, however, now find that the exposed lateral edge of the labial fold of *Ceratodus* corresponds to the ventral edge of that part of the fold of *Polypterus* that lies posterior to the secondary angle of the gape, and not, as I formerly concluded (Allis, '00), to the dorsal edge of the maxillary labial-flap. The labial fold of *Ceratodus* has accordingly not been turned upward and inward upon the roof of the buccal cavity, as I formerly concluded. It has simply acquired a permanently nearly horizontal position, similar to that in *Polypterus* when the mouth is widely opened, and has then

coalesced with, or never been completely separated from, the tissues of the roof of the mouth.

The lips and labial folds and furrows of *Polypterus* are thus strictly comparable to those of *Acanthias*, and the labial fold is, as in that fish, a maxillomandibular one. The labial cartilage, which lies in that fold, must then be the homologue of one or more of the labial cartilages of *Acanthias*. If the labial flaps of *Polypterus* are the homologues of those of *Acanthias*, as seems so probable, the anterior upper labial must be greatly reduced, if not wholly wanting, in *Polypterus*; and as the labial cartilage of *Polypterus* seems definitely related to the upper lip, the mandibular labial must also be greatly reduced, or wholly wanting. The labial cartilage of this fish is thus certainly in large part a posterior upper one, remnants only, at the most, of the other labials persisting. Pollard's conclusion ('95, p. 407), that this labial is a coronoid one, is then certainly in error if, as the name coronoid would seem to imply, the labial was considered by him to be a mandibular structure.

The premaxillary teeth of my 75-mm. specimen are implanted upon a bone that lies in part along the ventral surface of the anterior end of the ethmoidal cartilage, and in part encloses the ethmoidal section of the infraorbital laterosensory canal, and they are apparently, as already explained, secondary teeth and the homologues of the corresponding teeth of the *Holostei* and *Teleostei*.

The anterior maxillary teeth are implanted upon a plate of bone that corresponds to the palatal process of the maxillary bone of the adult, and that lies in a layer of fibrous tissue that lies slightly internal to the epithelial lining of the buccal cavity. This plate lies, in its anterior portion, beneath, but not directly against, the cartilage of the nasal capsule, and in its posterior portion directly beneath the anterior end of the palatoquadrate cartilage. It extends mesially beyond the primary alveololabial sulcus, to the mesial edge of the vomer, and the anterior maxillary teeth arise from its lateral edge and issue, as already stated, along the line of the primary lip. The bone is somewhat thickened along its lateral edge, where the teeth are implanted

upon it, but it is, in this part of its length, wholly separate from, and independent of, the bone that encloses the overlying section of the laterosensory canal. Slightly posterior to the anterior end of the palatoquadrate cartilage, this dental component of the maxillary bone loses its mesial, palatal extension, and then fuses with the overlying canal bone, the teeth now being implanted upon the so-formed bone, and that bone being separated from the lateral edge of the ectopterygoid by the primary alveololabial sulcus. The line of the maxillary continues to follow the line of the primary lip, and when the primary and secondary sulci fuse with each other at the anterior edge of the lateral process of the ectopterygoid, the line of the maxillary teeth comes into contact with the lateral edge of the ectopterygoid, as described in my earlier work (Allis, '00). These teeth lie wholly internal to the labial fold, and hence cannot have been developed in any relation to either of the upper labial cartilages.

The maxillary and premaxillary bones of *Polypterus* thus both have dental and facial components, which Gaupp says is characteristic of higher vertebrates, and they seem to certainly be the homologues of those bones. The maxillary bone of this fish is thus properly so-called, and as it and the teeth it bears are not the homologues of the bone and teeth of *Amia*, the bone and teeth of the latter fish should be otherwise designated, and I shall refer to them as the holostean maxillary bone and teeth, and to the dental arcade of the fish as a premaxillolabial one.

The so-called vomers occupy a position that corresponds, as already explained, to that of the palatine processes of the *Selachii* plus the palatine fold, and they are accordingly mesial dermopalatines. These bones and the teeth they bear were accordingly not developed, primarily, in any direct relation to the base of the neurocranium, differing radically in this from the parasphenoid. The anterior end of the basal plate of the latter bone of *Polypterus* lies in the roof of the depressed region between the vomers of opposite sides, that is, in the roof of what corresponds to the suprapalatine recess of the *Selachii*. The vomers of *Polypterus* lie, morphologically, in the floor of that recess, and they are, in my 75-mm. specimen, nowhere in

contact with the parasphenoid, and their hind ends lie, even in the adult, ventral to the anterior ends of the ectopterygoids.

The position of these bones of *Polypterus* thus, in itself, indicates that they are quite probably not the homologues of the unpaired vomer of the Teleostei, which bone lies in part directly upon the base of the chondrocranium and in part directly upon the anterior end of the parasphenoid, and conclusive proof of the non-homology of these bones is given by the conditions in *Macrodon*. In the latter fish Sagemehl ('84) describes an accessory palatine which is said to be but loosely bound to the other bones of the palatine arch, and to be unknown in other fishes. I find these bones of *Macrodon* having exactly the relations to the other bones of the palatine arch that the so-called vomers of *Polypterus* have, and I have twice suggested ('00, p. 278, and '09, p. 26) that they might be the homologues of the latter bones. I, however, then considered these bones of both these fishes to have been developed in the maxillary breathing-valve of the fish, which, as my present work shows, is incorrect in so far as *Polypterus* is concerned, and reference to Müller and Troschel's ('45) figure of the widely opened mouth of *Macrodon* shows that it is incorrect for that fish also, for what is apparently a well-developed maxillary breathing-valve is there shown, and the accessory palatine lies posterior to it.

It is thus certain that the so-called vomers of *Polypterus* do not contain the homologue of the basal plate of the unpaired vomer of the Teleostei. The teeth implanted upon that basal plate may, however, be the homologues of those of *Polypterus*, for with the disappearance of the suprapalatine recess and the disintegration of the mesial portions of the palatine processes of the palatoquadrates, these teeth of *Polypterus* would lie directly superficial to a vomer such as is found in *Macrodon*, and if they persisted they would necessarily become implanted upon it. And in accord with this view, the vomer of *Macrodon* is non-dentigerous (Sagemehl, '84).

The vomer of the Teleostei is thus quite probably formed of two primarily independent components, one dermal and the other dental, but this may possibly not apply to the paired

vomers of *Amia*. In any event, Sagemehl's suggestion ('83, p. 187), that the vomer bone of fishes might have been primarily the most anterior one of the investing bones of the palatine arch, is quite certainly true in so far as the teeth on the vomers of *Amia* are concerned.

LEPIDOSTEUS

In *Lepidosteus* there is a small labial fold, similar to that in *Amia*, and it encloses an holostean maxillary bone which Parker ('82) refers to as the edentulous mystaceum of an Acanthopterosus Teleostean. That part of this bone that lies in the labial fold is, as Parker states, edentulous, but in both 40-mm. and 80-mm. specimens that I have examined in serial transverse sections, I find two or more teeth related to an anterior portion of the bone that extends anteriorly beyond the root of the labial fold. These teeth lie in the line prolonged of a series of teeth that are implanted upon those laterosensory canal bones that Parker refers to as the maxillary chain, but the holostean maxillary is not, as Parker states, one of that chain of bones, for its anterior end lies definitely ventral to them, and ventral to the line prolonged of the supralabial furrow, while the canal bones lie dorsal to that line prolonged, and hence, as they normally should, in the line of an anterior prolongation of the supralabial fold. The teeth that are implanted upon these canal bones were, however, quite certainly not developed in relation to the supralabial fold, for the posterior ones pierce the ectoderm ventral to the anterior end of that fold. These teeth are, as above stated, implanted upon the canal bones, and they form the row of small sharp teeth said by Parker (*l.c.*, p. 478) to be implanted along the outer edges of those bones of the adult. Internal to these teeth there is, in my embryos, a row of teeth that are not implanted upon any bone whatever, their bases not reaching the overlying portions of the canal bones. In the adult most of these teeth are firmly implanted upon those bones, some of them, however, still remaining unattached, and, being held only by the surrounding tissues, are loose and movable. They form the row of large sharp teeth said by Parker to lie in the

long valley between the palatine splints and the maxillary chain of canal bones. In embryos this long valley is a large and low rounded ridge of the tissues of the roof of the mouth, with a slight furrow at either edge, and this ridge probably represents the primary upper lip. On the palatine splint there are two rows of teeth, the teeth of the inner row being slightly larger than those of the outer row.

In my embryos the outer row of teeth related to the canal bones are somewhat larger than those of the inner row. In the adult, on the contrary, the teeth of the inner row are much the larger. The smaller teeth of the outer row are, in the adult, directly continuous with the premaxillary teeth, the large teeth of the inner row ending posterior to the premaxillary teeth, in practically the positional relation to them that the dermopalatine teeth of *Amia* have to the premaxillary ones. External to the main row of premaxillary teeth there may be a second, but shorter row of teeth. These premaxillary teeth are all large ones, similar to those of the inner row of the canal bones.

There is a well-developed dorsolateral diverticulum of the buccal cavity, but it is not prolonged anteriorly as a recognizable preangular crease. There is, as in *Amia*, a tall coronoid process to Meckel's cartilage, and from this process a ligament arises and has its insertion on the holostean maxillary. There is no maxillary breathing-valve. It is therefore quite certain that both of the rows of teeth related to the canal bones of this fish are secondary ones, and those of the outer row quite certainly correspond to the maxillary teeth of *Amia*. The teeth of the inner row are perhaps similar to those of *Polypterus*, but it seems much more probable that they lie external to the primary lip, along a ridge that corresponds to that ridge on the internal surface of the labial fold of *Amia* that encloses the ligament that I consider to represent the posterior upper labial cartilage.

POLYODON

Bridge ('79) considered the cartilages in the upper jaw of this fish to be similar to those in the upper jaw of the Selachii, and he says that these cartilages of all these fishes are pterygoquadrate, without "even rudiments of recurrent palatine outgrowths," the palatine being considered by him to be a preoral structure. It nevertheless seems best to refer to the upper jaw of this fish as a palatoquadrate, that being the term usually applied to it in the Selachii.

In the one adult specimen of *Polyodon* that I have examined, and also in three young specimens 154 to 300 mm. in length, I find the external surface of the palatoquadrate looking laterally in its posterior portion, as Bridge states, and anterodorsally in its anterior portion. Its quadrate portion has the leaf-like outgrowth that Bridge describes and calls its orbital process, this process projecting forward lateral to the musculus adductor mandibulae. The hind end of the so-called maxillary splint is closely applied to the external surface of the orbital process, the surface of the process being slightly excavated to receive it. For a certain distance anterior to the anterior end of the orbital process, the maxillary splint is not in contact with the palatoquadrate, but farther forward its dorsal edge is V-shaped, fits closely upon the ventrolateral edge of the palatoquadrate, and so extends to the point where that cartilage articulates, in the median line, with its fellow of the opposite side of the head. The anterior portion of the ventral edge of the splint is furnished with small teeth, and, extending approximately the same distance along the dorsomesial edge of the palatoquadrate, there is a row of somewhat stronger teeth. The bone to which these latter teeth are attached fits closely upon the related edge of the palatoquadrate, and although fused anteriorly with the pterygoid splint of Bridge's descriptions, it has markedly the appearance of being of independent origin. It is called by Gegenbaur ('98, p. 342) the palatine, but it is to be noted that it is, even in my quite young specimens, definitely of membrane origin, and that it lies along the dorsomesial, instead of the

ventrolateral, edge of the palatoquadrate cartilage. The pterygoid bone is also of membrane origin, and I find, in my specimens, no indications of the so-called ectosteal scales described by Bridge and said by him to probably represent mesopterygoid elements.

The maxillary splint lies in the upper lip of the fish, and the posterior portion of this lip overlaps externally the dorsal edge of the mandible, this overlapping portion of the lip enclosing the ventral corner of the orbital process of the palatoquadrate, but no portion of the maxillary splint. A slight labial sulcus lies along the external surface of the ventral edge of the anterior portion of the maxillary splint and separates the teeth on that splint from the definitive and quite small upper lip. There is no slightest indication of a supralabial furrow, but that furrow and the overlying supralabial fold are apparently well developed in embryos of *Acipenser*, as shown in my recent work (Allis, '18), the fold and furrow there being called the supra-maxillary ones. In the mandible there is a short furrow which extends upward a short distance immediately posterior to the angle of the secondary gape, and it is apparently the homologue of the sublabial furrow of *Polypterus* and the *Selachii*, and in apparent correlation to this there is no coronoid process to Meckel's cartilage.

The conditions in this fish are thus similar to those in 11½-mm. embryos of *Amia*, excepting in that the furrow in the mandible is probably a sublabial one instead of a mandibular labial-flap furrow. The posterior portion of the upper lip of *Polyodon* is then certainly a secondary lip, and the slightly differentiated labial fold is probably, as in *Polypterus*, a maxillomandibular one. The orbital process of the palatoquadrate, which lies in this fold, must then be a labial cartilage, as Gegenbaur ('98 p. 342) concluded, but there seems nothing to indicate that it is a posterior upper labial alone, as Gegenbaur concluded, rather than a cartilage formed by the fusion of both upper labials, for the labial fold certainly encloses the primordia of both upper labials. This upper labial, or labials, of *Polyodon* having fused with the palatoquadrate, supralabial, and submaxillary furrows could naturally not be developed.

The fold of the secondary upper lip, thus well developed in its posterior portion, probably extended forward far enough to fall into its fellow of the opposite side on the anterior end of the snout, but it was probably not there completely differentiated from the primary lip. Because of this failure to there be completely differentiated, no premaxillary bone has been developed, and the maxillary splint has been prolonged anteriorly to replace it. This latter bone is a superficial one, and, as it extends into the oral edge of the secondary lip, it is quite certainly an holostean maxillary. The attachment of a maxillary bone to the ventrolateral edge of the palatoquadrate thus does not, in itself, necessarily imply that the bone is the homologue of the maxillary of *Polypterus*.

A so-called vomer is found in this fish, but it lies wholly anterior to the buccal cavity, on the ventral surface of the long spatula-shaped snout. This bone thus actually lies external to the primary lip, and if it actually be a vomer, its anomalous position needs explanation.

TELEOSTEI

In these fishes the labial folds and furrows vary greatly, sometimes resembling those in *Amia* and sometimes those in *Polypterus*, but usually differing, in certain details, from those in either of those fishes. In *Esox*, for example, there is a maxillary labial fold and a mandibular labial flap that are apparently similar to those in *Amia*, but the supralabial furrow lies at a certain distance dorsal to the labial fold and is definitely a sublachrymal furrow, the dorsal edge of the labial fold being bounded by an anterior prolongation of the postlabial furrow. This thus suggests, as does the development of these furrows in *Amia*, that the supralabial furrow is primarily a sublachrymal one, and only secondarily comes to bound the dorsal edge of the labial fold. In *Gadus* the labial fold is a maxillomandibular one, as in *Polypterus* and *Acanthias*, but there is a suprapremaxillary furrow which lies between the premaxillary and maxillary bones and is continued anteriorly until it falls into the anterior end of its fellow of the opposite side on the anterior end of the snout.

This furrow is apparently found only in those fishes in which the premaxillary has that posterior prolongation in the labial fold, ventral and parallel to the maxillary, that has already been referred to, and it is associated with a premaxillary that is more or less protrusive. This suprapremaxillary furrow has a position markedly similar to that of the maxillary labial-flap furrow of *Polypterus* and *Acanthias*, and it is probably its homologue, but there may, nevertheless, be two distinctly different furrows here. This suprapremaxillary furrow, the posterior prolongation of the premaxillary ventral and parallel to the maxillary, the transference of the teeth along the ventral edge of the labial fold from the maxillary to the premaxillary, and the acquisition of a protrusive premaxillary are apparently all correlated features and are distinctly characteristic of the higher Teleostei, for Sagemehl says ('84, p. 101) that this type of premaxillary is found in all of the non-physostomous fishes and in many of the physostomous ones, while the holostean type of maxillary is found only in the remaining physostomous fishes.

There are thus, in the Teleostei, at least two distinctly different secondary dental arcades in the upper jaw, the teeth in these two arcades being homologous, but the bones on which they are implanted totally different. Whether or not a third and still different arcade is also found in certain of these fishes, the Apodes, for example, I am unable as yet to definitely determine. These latter fishes are classed with the Physostomi, and Boulanger ('04) says that the premaxillaries are absent in all of them. Gegenbaur ('98, p. 357) says that these bones are present in the Muraenidae, but reduced, and fused with each other and with the vomer to form the anterior end of the snout. Smith Woodward ('01) also says that the premaxillaries are present in the Muraenidae, but he considers them to have there fused only with the ethmoidal rostrum. Maxillary bones are said by Boulanger to be present in the Anguillidae and certain other families of the suborder, but absent in the Muraenidae, and there replaced by the palatopterygoids. Smith Woodward considers these so-called palatopterygoids of the Muraenidae to be maxillaries, and I, in an earlier work (Allis, '03), concluded

that they must be palatopremaxillaries, the so-called premaxillaries of certain descriptions being maxillary breathing-valve bones.

Because of these differing opinions regarding these bones of the Apodes, I have reexamined my old material of Conger, and I find that the anterior portion of the maxillary bone of that fish has the relations to the lips and labial folds either of the maxillary bone of *Polypterus* or of the inner row of teeth on the so-called maxillary chain of canal bones of *Lepidosteus*, while the posterior portion of the bone apparently has the position of that ligament of *Amia* that I consider to apparently represent the posterior upper labial cartilage of the Selachii. This maxillary bone has, however, fused with some element of the palatoquadrate, that element being either a dermopalatine or a dermopalato-ectopterygoid, and bearing, along its ventrolateral edge, a row of small teeth that lie immediately internal to the maxillary teeth and are separated from them by a slight sulcus. This sulcus is continued forward between two groups of teeth on the ventral surface of the anterior end of the neurocranium, one of those groups evidently being vomerine teeth and the other premaxillary ones. The latter teeth are implanted upon a bone that encloses the two anterior organs of the ethmoidal laterosensory canal, and the bone so formed has fused with the vomer and with the anterior end of the neurocranium. There is in this fish, as in *Polypterus* and *Polyodon*, no trace of a maxillary breathing-valve.

The conditions in the Teleostei thus vary greatly and need special investigation that my material does not at present permit me to undertake. They are accordingly here left out of further consideration.

FOSSIL FISHES

Of these fishes I have only considered certain of the earliest known Chondrostei and Crossopterygii, the Chondrostei being the order to which the Holostei, Teleostei, and the recent *Polyodon* all belong.

A premaxillary is said by Smith Woodward ('95) to be found in all of the Palaeoniscidae, the earliest known family of the

Chondrostei, and although it is said by him to be comparatively small and insignificant, it was nevertheless well developed in certain of these fishes. This indicates that a complete secondary upper lip had already been developed in these fishes, but possibly, in certain of them, not yet markedly differentiated from the primary lip. In *Nematoptychius greenocki*, the premaxillary is shown well developed by Traquair ('77), and there in articular contact, posteriorly, with the anterior edges of a large median supraethmoid and a lateral bone on either side that is called both a prefrontal and an anterior frontal. This anterior frontal is traversed by what is apparently the anterior portion of the supraorbital laterosensory canal, that canal ending immediately lateral to the single nasal opening of these fishes, approximately in the relation to that opening that it has in *Amia* (Allis, '89) to the anterior nasal opening. The anterior frontal of this fish is thus apparently a canal bone, and hence, as Traquair states, cannot be the homologue of the prefrontal (ectethmoid) of the Holostei and Teleostei. The relations of the bone to the supraorbital canal would seem to show that it is the homologue of the nasal of recent fishes, but the bone lies lateral to the single nasal opening, while the nasal bone of recent fishes lies mesial to both nasal openings. There is no indication, in any of the Palaeoniscidae, of a posterior nasal aperture either mesial or lateral to this bone.

The maxillary of the Palaeoniscidae forms a direct posterior continuation of the premaxillary, and hence, like the maxillaries of *Amia* and *Polypterus*, is definitely posterior in its relations to that bone. It has a narrow anterior portion and a broad posterior one. Its dorsal edge is said by Traquair ('77) to be cut away so as to follow exactly the contours of the suborbital and postorbital bones, and to be in articular contact with them and also with the preoperculum. It is not said that these bones were firmly attached to each other, but this seems implied in the descriptions, and they are apparently shown so attached in a figure of the head of *Oxygnathus*. In that figure the head of the fish has been flattened out in such a manner that the mouth is shown widely opened, but the maxillary nevertheless retains

its contact with the suborbitals, postorbitals, and preoperculum, excepting only along the ventral end of the latter bone. There was thus apparently no supralabial furrow in these fishes.

The ventroposterior corner of the maxillary projects ventroposteriorly and forms a process-like portion which overlaps externally the dorsal edge of the mandible, there covering the quadratomandibular articulation. The ventral margin of the bone is furnished, throughout its entire length, with teeth. In *Palaeoniscus* these teeth are said to be very small and to be closely set, the more internally placed ones being larger than the external ones. In certain other genera of the family there is said to be a set of strong and powerful conical or laniary teeth placed in a row internal to an outer series of closely and somewhat irregularly placed smaller ones. The ventral portion of the bone is said by Traquair to be slightly reflected inward so as to form a sort of narrow ledge, and some part of this ledge is said to have apparently come into contact with the ventrolateral edge of a somewhat narrow and elongated bony lamina said to represent the palatoquadrate arch. This bony lamina is said to be apparently composed of two parts, one of which represents the quadrate while the other is probably the equivalent of the ectopterygoid of the osseous fishes. This latter part of the lamina is nevertheless called the palatopterygoid, and it is with it that the reflected ventral edge of the maxillary is in contact.

The maxillary of these fishes would thus seem to be a superficial bone that had, as in *Polyodon*, acquired attachment to the ventrolateral edge of the palatoquadrate, and the two rows of teeth on the ventro-internal surface of the bone would seem to be, one a row of holostean maxillary teeth, and the other a row corresponding to the inner row of teeth on the bones of the so-called maxillary chain of *Lepidosteus* or to those on the maxillary of *Conger*. With the disappearance of the inner row, the acquisition of articular connections of the maxillary with the neurocranium, and the development of a supralabial furrow, the bone of *Amia* would arise, while the retention of the inner row alone might give rise to the bone of *Conger*.

The hyomandibula of the Palaeoniscidae is said by Traquair to be an elongated and slender bone which descends downward and backward from the squamosal region to the neighborhood of the quadrate articulation, thus apparently articulating with the neurocranium dorsal to the vena jugularis, as it does in all recent Teleostomi; this showing that these early Chondrostei had already departed markedly from the Plagiostoman type.

In the Platysomidae, a family of the Chondrostei closely related to the Palaeoniscidae, the teeth were feeble or wholly wanting (Traquair, '79). The feeding habits of these fishes could not then have required a fixed and rigid support for their teeth, and doubtless in correlation to this the maxillary is not fixed in position by attachment either to the palatoquadrate or to the suborbital and cheek bones. That it was not attached to the cheek bones is evident from the fact that its dorsal edge is no longer cut away to fit against those bones, as it is in the Palaeoniscidae, and in *Platysomus* it even overlaps them externally. There must then have been a more or less developed supralabial furrow in these fishes, and quite possibly it existed in the condition that I have described in 11½-mm. embryos of *Amia*. These fishes thus presented conditions favorable to the development of a maxillary bone such as is found in *Amia*.

In the *Crossopterygii* there are apparently two distinctly different types of maxillary, one resembling somewhat that found in the Palaeoniscidae and the other that found in the recent *Polypterus*. The former type is found in fishes of the suborder *Rhipidistia* of Smith Woodward's classification, and the other in those of the suborder *Actinistia*.

In the *Rhipidistia* there are, according to Smith Woodward ('91), dentigerous premaxillaries which are usually fused with each other, and also, more or less, with small plates which intervene between them and the frontals. The maxillary is said to be dentigerous, and to be bounded above by the suborbital and cheek bones; and in restored figures of these fishes it is apparently shown in articular contact with the latter bones and frequently tuberculated. In restored figures of *Rhizodopus*, its hind end is shown overlapping externally to a considerable

extent the dorsal edge of the mandible. Smith Woodward says that there are some traces of an inward palatal extension both of the maxillary and the premaxillary, and that there are paired vomers, each of which bears a formidable tooth.

Aside from these very general description of these fishes, I only have at my disposal Huxley's descriptions of *Glyptolaemus kinnairdi*, and Traquair's descriptions of *Tristichopterus*, the one belonging to the family *Osteolepidae* and the other to the family *Rhizodontidae*.

In *Glyptolaemus*, called by Smith Woodward *Glyptopomus*, the maxillary is not particularly described by Huxley ('61), but he shows it, in one of his figures, lying along the lateral edge of the anterior end of the palatosuspensorium and overlapped externally by a large tooth-like structure which apparently either issues from beneath the suborbital bones, or has its origin on the palatosuspensorium. If this be the 'very strong tooth' mentioned by him in the text, and there said to be implanted on the anterior portion of the palatosuspensorium, it must be greatly displaced in the fossil. It somewhat strikingly resembles, in general position and appearance, the labial cartilage of *Polypterus*, and if it be that labial, here ossified, as it is in *Macropoma*, the maxillary of this fish cannot be an holostean one. The maxillary is, however, shown strongly tuberculated in restored figures of certain of these fishes, particularly so in *Osteolepis*, and if it was a superficial bone, as this would indicate, it cannot be the homologue of the bone of *Polypterus*.

In *Tristichopterus*, the maxillary is said by Traquair ('75) to be a long and narrow bone, the oral edge of which is distinct in the fossil, but the dorsal edge not. Internally, along its anterior two-thirds, it is said to be certainly very firmly united to the outer margin of the palatoquadrate arch, an interval being left posteriorly for the passage of the muscles of the lower jaw. The bone is shown, in a restored figure, in contact with the suborbital and preopercular bones, and slightly overlapping externally the dorsal edge of the mandible. The palatosuspensorium is shown extending forward approximately to the anterior end of the maxillary, and its posterior border, which

contains the hyomandibula, gives articulation, externally, to the hind edge of the preoperculum. The palatosuspensorium is said to be immovably fixed to the maxillary along the anterior two-thirds of its outer margin, and at what appears to be the hind end of this region of attachment—that is, at the posterior third of the length of the palatosuspensorium—there is a laterally directed process on its lateral edge which somewhat resembles the process on the lateral edge of the ectopterygoid of *Polypterus*; this process coinciding, in the latter fish, with the hind end of the tooth-bearing component of the maxillary. In two of Traquair's figures the maxillary of *Tristichopterus* is shown ending at this process, and hence having a much less extensive posterior prolongation than that shown in the restored figure.

The maxillary of *Tristichopterus* was thus probably more or less firmly attached both to the suborbital bones and the preoperculum, and firmly attached to the outer margin of the palatoquadrate. It was therefore certainly incapable of independent movement. In this it agreed with the maxillary of both *Conger* and *Polyodon*, and if the bone were tuberculated it would seem as if it must be the homologue of the bone of one of these two fishes, and probably of that of *Polyodon*.

In the suborder *Actinistia* there is but one family known, that of the *Coelacanthidae*, and there has been marked disagreement as to the homologies of the bones related to the upper jaw of these fishes.

Macropoma mantelli, one of this family, was described by Huxley in 1866. The proötic is said by him to be "a large plate of bone, rising perpendicularly towards the roof of the skull, which it nearly reaches in front. Further back it sends out two great processes, one superior and the other inferior, at right angles to its own plane." These two processes are said to be separated by a deep oval fossa, and comparison with *Polypterus* would indicate that this fossa occupies the position of the interspace of cartilage that lies between the sphenotic and parietopterotic bones above, and the dorsal edge of the ascending process of the parasphenoid below, this cartilage forming part of the lateral wall of the trigemino-facialis chamber. The

fossa therefore probably represents that chamber, the superior process of the proötic of *Macropoma* then being represented in the sphenotic and pterotic of *Polypterus*. The inferior process of *Macropoma* gives off certain smaller processes, one of which, called the process 'h,' evidently corresponds to that posterior portion of the ascending process of the parasphenoid of *Polypterus* that passes dorsal to the foramen faciale (posterior opening of the trigemino-facialis chamber). Another process, called the process 'i,' corresponds to the lateral point of the base of the ascending process of the parasphenoid of *Polypterus*. The deep fossa said to lie posterior to the process 'h' would seem to be the large posterior opening of the canal that traverses the ascending process of the parasphenoid of *Polypterus* and which I have lately referred to as the posterior opening of the canalis parabasalis (Allis, '18).

The lateral surface of this portion of the neurocranium of *Macropoma* thus evidently quite closely resembled that of *Polypterus*, and this would naturally suggest that there should also be some resemblance in the bones related to its ventral surface, and if Huxley's figure (i.e., fig. 3, pl. 8) of that surface of the skull of *Macropoma* be compared with my figure ('00, text fig. 1), giving a similar view of the skull of *Polypterus*, there is seen to be a marked similarity. The anterior portions of the parasphenoids of the two fishes are strikingly similar, and on either side of that bone there is, in *Macropoma*, a single tuberculated bone, and in *Polypterus* two such bones, both related to the palatoquadrate. Along the lateral edge of the single bone of *Macropoma* there is a dentigerous bone that Huxley considered to be the maxillary, the posterior portion of the maxillary of *Polypterus* having similar relation to the lateral one of the two bones of that fish. Anterior to the lateral one of these two bones of *Polypterus*, and overlapped ventrally by the anterior end of that bone, there is a palatal process of the maxillary, and in *Macropoma*, in strictly similar position, there is a bone that Huxley calls the palatine. No teeth were found on this bone in the specimen of *Macropoma* used by Huxley for the figure given, but teeth apparently belonging to it were found by

him in other specimens; and Smith Woodward ('91) says, in his list of the characteristic features of the Coelacanthidae, that this bone, also called by him the palatine, is furnished with more or less formidable teeth. These teeth were quite certainly arranged in line along the lateral edge of the bone, and hence formed an anterior continuation of the teeth on the maxillary of Huxley's descriptions, these two bones together thus corresponding exactly to the tooth-bearing component of the maxillary of Polypterus, but here not yet fused with each other and with the overlapping suborbital bones. On the anterior end of the snout there is a triangular bone, beset with small cylindrical teeth, which Huxley considered to be either the fused premaxillaries or the vomer.

Macropoma thus probably had a maxillary bone similar to the tooth-bearing component of the maxillary of Polypterus, but the single bone of Polypterus was represented by two separate bones. The anterior one of these two bones of Macropoma might be part of an holostean maxillary, but the other one certainly could not be part of such a bone. Fritsch ('78), in a specimen of *Macropoma speciosum* shows these two bones of Huxley's descriptions fused to form a single bone, and immediately in front of, and in line with it, he shows a well-developed premaxillary.

Posterior to the maxillary, there is a bone that Huxley calls the postmaxillary. It is said by him to be an elongated triangular bone which fills up the interval between the suborbitals opercula, and mandible, and covers the quadrate articulation. Its anterior corner abuts against the hind end of the maxillary, and it is in contact dorsally with the suborbitals. Reis ('88, pp. 74 to 79) says that the upper one of its three corners lies upon the outer surface of the pterygoid, that it projects laterally (seitlich) into the buccal cavity, and that its oral surface is covered with tooth-like structures (Zahnstreifen oder Zahnkörnchen). It is said to lie internal to the quadratojugal and jugal, and in a figure (i.e., fig. 11, pl. 5) giving a diagrammatic transverse section through this part of the head, it is shown extending upward internal to the suborbital bones, along the lateral surfaces

of Huxley's maxillary and the pterygoid. Its ventral edge is in articular contact with a bone that Reis calls the postsplenic, and it is said that the arrangement of the tubercles on the outer surfaces of the dentary and articular show that the fish had thick lips (eine starke Lippenbildung), and that the angle of contact of the postmaxillary and postsplenic lay immediately posterior to the angle of the gape of those lips. Reis accordingly compares these two bones of *Macropoma* with the posterior upper and mandibular labial cartilage of the *Selachii*, and with the single labial of *Polypterus*. Zittel ('87-'90) accepts the homologies thus proposed for these bones, and my work strongly favors them in so far as they refer to the labial cartilages of the *Selachii*. Reis further considers these bones to be rudiments of a preoral visceral arch; but if they be such structures, one related to the upper and the other to the lower jaw, the mouth could not represent the coalesced mandibular visceral clefts of opposite sides of the head, for those clefts would lie posterior to the labial cartilages, between them and the mandibular cartilages.

The conditions in *Macropoma* were thus strikingly similar to those in the recent *Polypterus*, the only noteworthy differences being that the labial cartilage of *Polypterus* is replaced by bone in *Macropoma* and that there is a mandibular labial bone as well as a maxillary one. The retention of the maxillary one of these two bones, the so-called postmaxillary, and its fusion with the hind end of the maxillary would apparently give rise to the conditions found in the recent *Apodes*, while the development of a labial fold, and the persistence of a cartilaginous labial, would give rise to the conditions in *Polypterus*, and if this be the origin of the bones in these fishes; then the maxillary bone of the *Apodes* must be the homologue of that bone of *Polypterus*.

AMNIOTA

In my work on *Polypterus* (Allis, '00), I concluded, as already several times stated, that the maxillary teeth of that fish were probably the homologues of the maxillary teeth of mammals, the teeth of the latter animals then not being the homologues of the maxillary teeth of the *Holostei* and most of the *Teleostei*.

To control this statement I have now endeavored to trace the labial folds and furrows in the Amniota, and for this purpose I have used exclusively Fuchs's ('07, '08) very careful descriptions of the development of the primary and secondary palates in these animals.

In all of the Amniota the crest of the secondary upper lip passes either between the nasal apertures of either side or across the oral nasal aperture, the fold thus either simply traversing the nasal bridge, without overlapping its oral edge, or slightly overlapping that edge and so adding somewhat to the width of the bridge (Allis, '18). The lateral portions of the secondary upper lip are formed by the so-called maxillary processes of embryos, and Fuchs says ('08, p. 221) that those processes take part in the formation of the primary palate in mammals, but not in the Sauropsida. In early embryos of *Emys* he, in his figures, shows the process running forward along the lateral edge of the oral (internal) nasal aperture and then forward along the external surface of the lateral nasal process nearly to the oral end of the aboral (external) nasal aperture. The ridge of the process is bounded on either side by a furrow, and another furrow overlies the line of fusion of the nasal processes above the nasal groove. This latter furrow is joined, somewhat anterior to the oral nasal aperture, by the furrow that bounds mesially the maxillary process, and Fuchs considers this fusion of these two furrows to mark the oral end of the nasal process and the beginning of the fusion of the maxillary process with the lateral edge of the ventral end of the nasal septum (Vomerpolster). Posterior to this point, the nasal bridge is said to no longer form a primary palate, but a secondary one, and the oral nasal apertures, lying posterior to this secondary palate, are choanae reliquae, and represent remnants only of the primary choanae. The maxillary process bounds laterally the choana of either side, and the bottom of the nasal groove opens directly into the angle formed by the inner surface of the maxillary process and the roof of the mouth. The furrow that forms the lateral boundary of the maxillary process has, in this transverse plane, become the bounding line between the maxillary

process (secondary upper lip) and the side of the head, and on the external surface of this process (secondary lip) there is, in slightly older embryos (l.c., pl. 23), a shallow longitudinal depression. In still older embryos of *Emys* and also in those of *Chelone* (l.c., pl. 24), this depression becomes a furrow which lies dorsal to the ventrolateral edge of the maxillary bone, and hence in the position of the supralabial furrow of fishes.

The oral nasal aperture has thus been enclosed in the buccal cavity without having to cut through the premaxillo-maxillary dental arcade, as I formerly suggested must be the case (Allis, '00), and it even lay, primarily, aboral to the primary lip. Later, it cut through that lip and opened into the primary superior alveololabial sulcus, a median remnant of the lip apparently being left between the apertures of opposite sides and being represented in the choanate papilla, or papilla palatina, of Fuchs's descriptions, this papilla being said by him to always lie, excepting in certain of the Sauria, immediately posterior to the primary palate, between the anterior ends of the primary choanae (oral nasal apertures). Having cut through this primary upper lip and reached the primary alveololabial sulcus, the nasal groove encountered, in its posterior progression, the primary alveolar ridge, and was apparently there at first deflected laterally along the external surface of that ridge, for it is so shown by Fuchs ('08, figs. 1a and 1b, pl. 61) in *Hatteria*, where the conditions are considered by him to be the most primitive found in the Amniota. The nasal groove, thus prolonged, evidently interfered somewhat with the free development of the bones in the primary dental arcade, and the groove eventually acquired a passage between the vomerine and palatine portions of that arcade and then had a sagittal course along the lateral edge of the body of the vomer. The continued coalescence of the lips of the nasal groove and the invasion of the bridge so formed by processes of the vomer, palatine, and maxillary, then gave rise to the conditions described by Fuchs in *Chelone*. In the sections of *Hatteria* that are given, the supralabial furrow is not shown, but it is shown, well developed, in the sections of *Lacerta*, and the lachrymal duct leads from this furrow to the primary choana.

The primary upper lip is apparently represented in the so-called median lateral-fold of Fuchs's descriptions. This fold is not described by him in embryos of *Chelone*, but it is in embryos of certain others of the *Sauria*, there lying lateral to the lateral lip of the nasal groove, the so-called choanate fold, between that fold and the maxillary teeth, and where there are palatopterygoid teeth, as in *Tropidonotus*, they apparently develop immediately internal to this fold. This fold thus certainly represents the primary upper lip, and is the homologue of the maxillary breathing-valve of fishes. In mammals it is said by Fuchs to become the secondary palate, that palate thus being represented in the maxillary breathing-valve of fishes, as I suggested in my earlier work on *Polypterus* (Allis, '00).

SUMMARY

There are thus, in recent teleostoman fishes, several distinctly different types of secondary dental arcade in the upper jaw.

In one of these types the maxillary and premaxillary each has two components, one dental and the other dermal, the latter component being formed by bones developed in relation to the laterosensory canals. The teeth on each of these bones apparently issue approximately along the line of the primary upper lip, the maxillary teeth lying internal to the labial fold and hence definitely internal to both upper labial cartilages. This dental arcade is found in *Polypterus*, and also in *Macropoma*, one of the fossil *Crossopterygii*, and it apparently corresponds to the dental arcade of the *Mammalia*.

A second type is found in *Conger*, the premaxillary here being represented by teeth that have fused with the dermal ethmoid, and the maxillary corresponding either to the maxillary and post-maxillary bones of the fossil *Macropoma*, or, more probably, being a bone developed in relation to teeth that correspond to the inner row of teeth on the so-called maxillary chain of canal-bones of *Lepidosteus*, those teeth having apparently been primarily developed in relation to tissues that represent the posterior upper labial cartilage.

A third type is found in the Holostei, and probably also in certain of the physostomous Teleostei, a premaxillary being present, and the maxillary having dental and dermal components. The dental component of the maxillary is formed by the fusion of the basal plates of teeth developed in relation to tissues that represent the anterior upper labial, the dermal component being a bone similar in origin to the dermal plates on the cheek of the fish.

A fourth type is found in Polyodon. Here there is no premaxillary, and the maxillary resembles that of the Holostei, but, because of the absence of a premaxillary, it has been prolonged anteriorly until it meets its fellow of the opposite side in the median line.

A fifth type is found in most of the Teleostei; the dental component of the holostean maxillary here becoming part of the premaxillary, and forming a posterior prolongation of that bone which lies ventral and parallel to the maxillary and excludes it more or less from the upper margin of the mouth, while the dermal component of the holostean maxillary becomes the teleostean maxillary.

In *Amia* and most of the Teleostei, an anterior portion of the primary upper lip persists as the maxillary breathing-valve. In *Polypterus*, *Polyodon* and *Conger* this breathing-valve is not found, the fold of the secondary upper lip apparently not here passing sufficiently anterior to the primary one to permit of the retention of the latter as an independent structure. In the Mammalia the primary upper lip (maxillary breathing-valve) becomes the secondary palate.

The so-called vomers of *Polypterus* are mesial dermopalatines, lie morphologically in the floor of the suprapalatine recess, and do not contain the homologue of the basal plate of the unpaired vomer of the Teleostei, which plate lies, morphologically, in the roof of that recess. The teeth on the two bones may, however, be homologous.

LITERATURE CITED

- ALLIS, E. P., JR. 1889 The anatomy and development of the lateral line system in *Amia calva*. Jour. Morph., vol. 2, no. 3, Boston.
1897 The cranial muscles, and cranial and first spinal nerves in *Amia calva*. Jour. Morph., vol. 12, no. 3, Boston.
1900 The premaxillary and maxillary bones, and the maxillary and mandibular breathing valves of *Polypterus bichir*. Anat. Anz., Bd. 18, no. 11/12, Jena.
1903 The lateral sensory system in the Muraenidae. Intern. Monatsschr. f. Anat. u. Phys., Bd. 20, Hft. 4/6, Leipzig.
1904 The latero-sensory canals and related bones in fishes. Intern. Monatsschr. f. Anat. u. Phys., Bd. 21, Hft. 9/12, Leipzig.
1909 The carnial anatomy of the mail-checked fishes. Zoologica, Hft. 57 (Bd. 22), Stuttgart.
1914 Certain homologies of the palato-quadrate of Selachians. Anat. Anz., Bd. 45, Jena.
1917 The lips and the nasal apertures in the gnathostome fishes, and their homologues in the higher vertebrates. Proc. Nat. Acad. Sci., vol. 3, no. 2, Baltimore.
1919 The lips and the nasal apertures in the gnathostome fishes. Jour. Morph., vol. 32, no. 1.
- BOULENGER, G. A. 1904 Fishes (Systematic account of Teleostei). The Cambridge Nat. History, vol. 7, Fishes, Ascidians, etc., London.
- BRIDGE, T. W. 1879 The osteology of *Polyodon folium*. Phil. Trans. Royal Soc., vol. 169, London.
1904 Fishes (Exclusive of the Systematic account of Teleostei). The Cambridge Nat. History, vol. 7, Fishes, Ascidians, etc., London.
- FRITSCH, A. 1878 Die Reptilien und Fische der böhmischen Kreideformation. Prag.
- FUCHS, H. 1907 Untersuchungen über Ontogenie und Phylogenie der Gaumenbildungen bei den Wirbeltieren. Erste Mittheilung: Über den Gaumen der Schildkröten und seine Entwicklungsgeschichte. Zeit. Morph. Anthrop., Bd. 10, Hft. 3, Stuttgart.
1908 Ibid. Zweite Mittheilung: Über das Munddach der Rhyngocephalen, Saurier, Schlangen, Krokodile und Säuger und den Zusammenhang zwischen Mund- und Nasenhöhle bei diesen Tieren. Zeit. Morph. Anthrop., Bd. 11, Hft. 2, Stuttgart.
- GAUPP, E. 1905 Die Entwicklung des Kopfskelets. Handbuch d. vergl. u. experim. Entwicklungslehre d. Wirbeltiere von Oskar Hertwig, Bd. 3, Teil 2, Jena.
- GEGENBAUR, C. 1898 Vergleichende Anatomie der Wirbelthiere mit Berücksichtigung der Wirbellosen, Bd. 1, Leipzig.
- GREIL, A. 1913 Entwicklungsgeschichte des Kopfes und des Blutgefäßssystems von *Ceratodus forsteri*. Zweiter Teil: Die epigenetischen Erwerbungen während der Stadien 39-48. Jenaische Denkschriften, Bd. 4, Jena.

- HUXLEY, T. H. 1861 *Glyptolaemus Kinnairdi*. Memoirs of the Geological Survey of the United Kingdom. Decade X., pp. 41/46. London.
1866 British fossils. Illustrations of the structure of the cross-opterygian ganoids. Mem. Geol. Survey of the United Kingdom. Decade XII. London.
- MÜLLER, J., AND TROSCHEL, F. H. 1845 *Horae Ichthyologicae*. Beschreibung und Abbildung neuer Fische. Die Familie der Characinen. Hft. 1/2, Berlin.
- PARKER, W. K. 1882 On the development of the skull in *Lepidosteus osseus*. Phil. Trans. Royal Soc., vol. 173, London.
- POLLARD, H. B. 1895 The oral cirri of Siluroids and the origin of the head in vertebrates. Zool. Jahrb. Abth. f. Anat., Bd. 8, Hft. 3, Jena.
- REIS, O. M. 1888 Die Coelacanthinen, mit besonderer Berücksichtigung der im Weissen Jura Bayerns vorkommenden Gattungen. Palaeontographica, Bd. 35, Lief. 1, Stuttgart.
- SAGEMEHL, M. 1883 Beiträge zur vergleichenden Anatomie der Fische. I. Das Cranium von *Amia calva* (L). Morph. Jahrb., Bd. 9, Hft. 2, Leipzig.
1884 Beiträge zur vergleichenden Anatomie der Fische. III. Das Cranium der Characiniden nebst allgemeinen Bemerkungen über die mit einem Weber'schen Apparat versehenen Physostomenfamilien. Morph. Jahrb., Bd. 10, Hft. 1, Leipzig.
1891 Beiträge zur vergleichenden Anatomie der Fische. IV. Das Cranium der Cyprinoiden. Morph. Jahrb., Bd. 17, Hft. 4, Leipzig.
- TRAQUAIR, R. H. 1870 On the cranial osteology of *Polypterus*. Journ. Anat. and Phys., Ser. 2, vol. 5 (No. 7), London.
1875 Structure and affinities of *Tristichopterus alatus*. Trans. Royal Soc. Edin., vol. 27, Pt. 3.
1877 The Ganoid fishes of the British Carboniferous formations. Pt. 1. Palaeoniscidae. Palaeontographical Society, London.
1879 On the structure and affinities of the Platysomidae. Trans. Royal Soc. Edin., vol. 29, Pt. 1.
- WIJHE, J. W. VAN 1882 Über das Visceralskelet und die Nerven des Kopfes der Ganoiden und von *Ceratodus*. Nederl. Archiv. f. Zoologie, Bd. 5, H. 3, Leiden.
- WOODWARD, A. S. 1891-1901 Catalogue of the fossil fishes in the British Museum (Natural History). Pts. 2, 3, 4. London.
- ZITTEL, K. A. 1887-1890 Handbuch der Palaeontologie, Vertebrata (Pisces, Amphibia, Reptilia, Aves), Bd. 3, München und Leipzig.

PLATES


ABBREVIATIONS

<i>al</i> , anterior upper labial	<i>mzpc</i> , maxillary preangular crease
<i>d</i> , dentary	<i>nc</i> , nasal cavity
<i>div</i> , dorsolateral diverticulum of the buccal cavity	<i>nt</i> , nasal tube
<i>ect</i> , ectopterygoid	<i>pas</i> , superior or inferior primary alveololabial sulcus
<i>ent</i> , entopterygoid	<i>pl</i> , posterior upper labial cartilage
<i>ioc</i> , infraorbital laterosensory canal, and the enclosing bone	<i>pmx</i> , premaxillary bone, or its teeth
<i>lc</i> , labial cartilage	<i>ps</i> , parasphenoid
<i>lf</i> , labial fold	<i>pul</i> , primary upper lip, or maxillary breathing-valve
<i>lg</i> , ligament from maxillary bone to coronoid process of mandible	<i>sas</i> , superior or inferior secondary alveolo-labial sulcus
<i>mdf</i> , mandibular labial flap	<i>sbf</i> , sublabial furrow
<i>mdff</i> , mandibular labial-flap furrow	<i>slf</i> , supralabial furrow
<i>mdl</i> , mandibular labial cartilage	<i>smf</i> , submaxillary furrow
<i>mdpc</i> , mandibular preangular crease	<i>sp</i> , splenial
<i>mx</i> , maxillary bone, or its teeth	<i>spr</i> , suprapalatine recess
<i>mxj</i> , maxillary labial flap	<i>vo</i> , vomer
<i>mxjf</i> , maxillary labial-flap furrow	

PLATE 1

EXPLANATION OF FIGURES

- 1 Ventral view of the head of *Acanthias blainvillii*, showing the labial folds and furrows. $\times 2/5$.
- 2 The same, dissected on one side to show the labial cartilages. $\times 2/5$.
- 3 Lateral view of the head of a small adult *Polypterus*, the mouth slightly open. $\times 2$.
- 4 The same, the mouth forced widely open. $\times 2$.



1

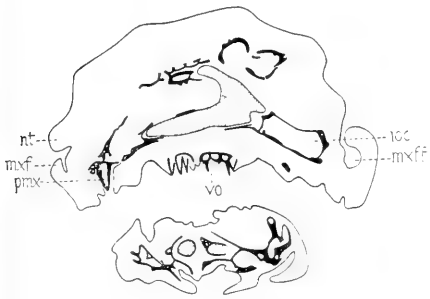


3

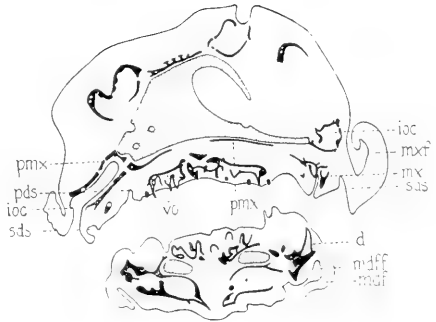
2

PLATES 2 AND 3

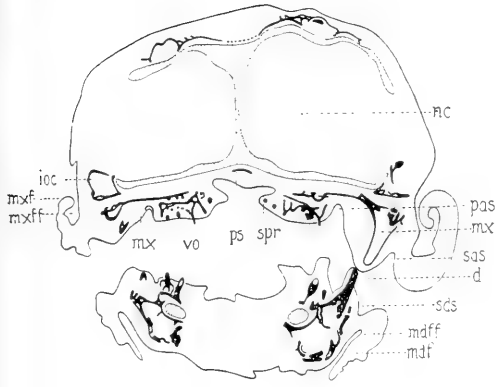
- 5 to 14 Transverse sections of the head of a 75-mm. specimen of *Polypterus senegalus*, showing the lips and labial folds and furrows.
- 15 to 18 Similar sections of the head of a 43-mm. specimen of *Amia calva*.



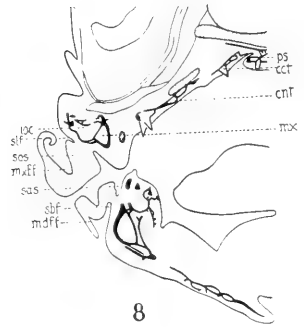
5



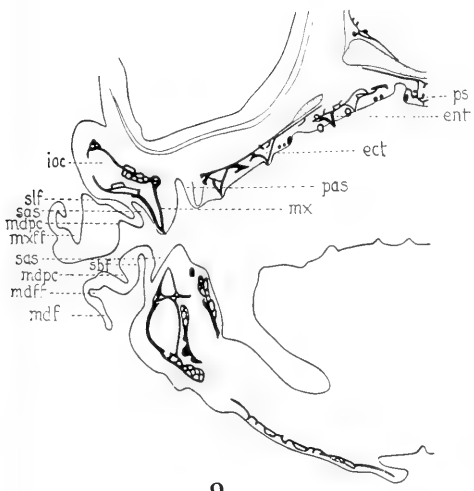
6



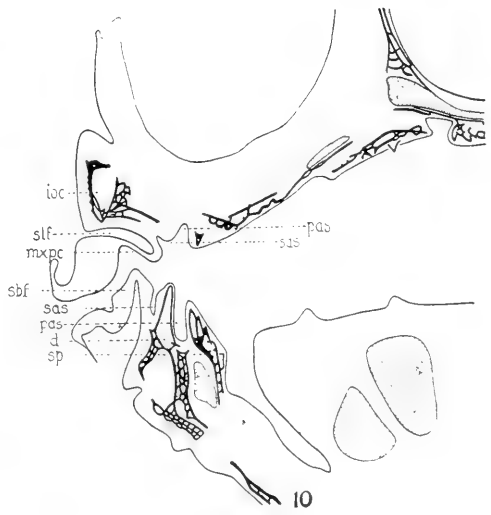
7



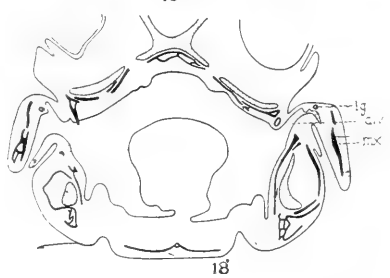
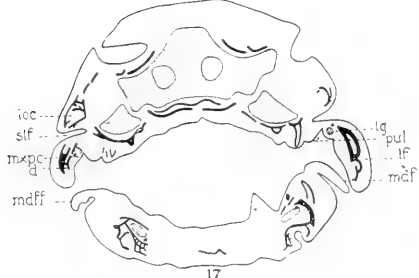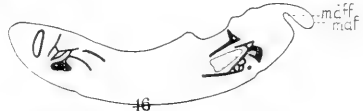
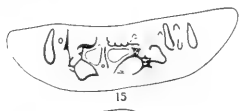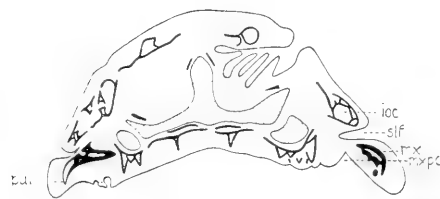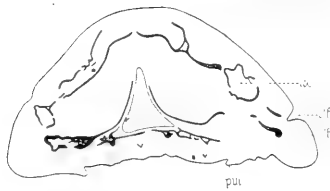
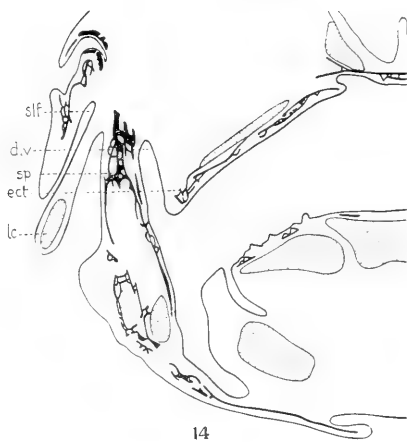
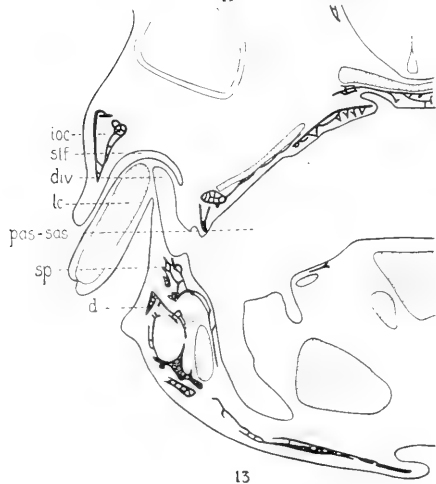
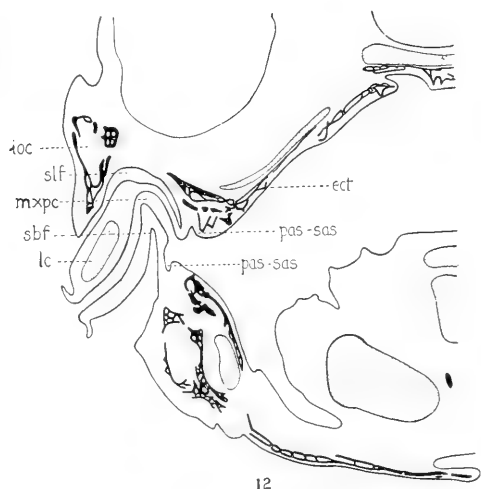
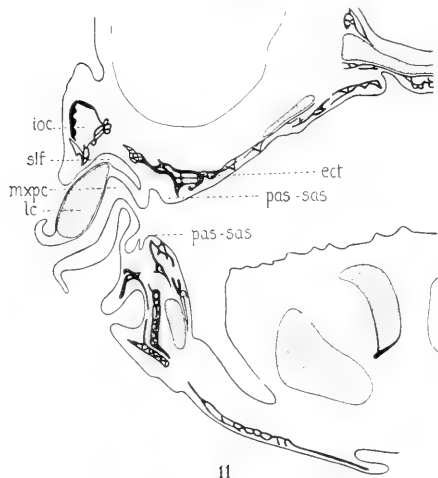
8



9



10



STUDIES ON THE MAMMARY GLAND

IV. THE HISTOLOGY OF THE MAMMARY GLAND IN MALE AND FEMALE ALBINO RATS FROM BIRTH TO TEN WEEKS OF AGE

J. A. MYERS

Institute of Anatomy, University of Minnesota, Minneapolis

NINETEEN FIGURES (ELEVEN TEXT FIGURES, TWO PLATES)

In earlier works (Myers, '16 and '17 b) the growth and distribution of the milk-ducts in male and female albino rats from birth to ten weeks of age were studied. Owing to the fact that the finer structure of the gland during these ages has not been carefully studied and that a knowledge of such structure is essential before proceeding with the changes in the gland during pregnancy, the present work was undertaken. An abstract of the results has already been published (Myers, '18).

MATERIAL AND TECHNIQUE

In this work approximately forty apparently healthy rats of about normal weight were used. The age ranged from birth to ten weeks. These individuals were fairly evenly distributed among the described stages. For general histological work the glands were fixed in Zenker's fluid, paraffin sections cut 7 or 8 μ and stained with iron-hematoxylin or Mallory's anilin-blue connective-tissue stain. Other glands were stained with Dominici's combination stain. For the study of elastic fibers, glands were fixed in 10 per cent formalin and stained in Weigert's resorcin-fuchsin stain or Unna's orcein stain. Mayer's mucicarmine was also applied to some glands with the hope of determining more accurately the nature of the contents of the intraepidermal portion of the primary duct.

The method described by Lane-Clayton and Starling ('06) was used in making cleared preparations.

Born's method was used in making the wax reconstructions.

For the study of the secretion in the new-born, animals were killed by bleeding, and fresh glands were cut with the freezing microtome. Others were fixed in 10 per cent formalin for an hour or so, after which frozen sections were cut. Frozen sections were stained in 1 per cent osmic acid, plain scarlet red (prepared by adding an excess of the stain to boiling 70 or 80 per cent alcohol) or Herxheimer's alkaline scarlet red. Other glands were fixed in Flemming's fluid, paraffin sections cut at $5\ \mu$ and stained with safranin. Still others were fixed, cut, and stained according to the method described by Bell ('14).

OBSERVATIONS

New-born

Microscopic sections show that the epidermis over each nipple area of the new-born female albino rat is nearly two times as thick as that in the skin adjacent to this area (fig. 1). Such a thickening renders the skin more opaque, thus preventing the blood in the deeper layers from giving a red appearance to the surface. Therefore, the nipple area appears much lighter than the immediately surrounding skin.

On the surface in the central portion of the light area is a very slight elevation which represents the developing nipple, while partially surrounding the nipple is a shallow depression (fig. 1) which in most cases is partly filled with cornified cells. Peripheral to the depression the epidermis becomes continuous as a much thinner layer surrounding the mammary gland area.

Deep to the depression is the epithelial hood described in earlier papers (Myers, '16, '17 a, and '17 b). In the new-born the free projection of the hood extends slightly further into the corium than in twenty-day fetuses. The outer and inner surfaces of this projection are smooth and are covered with the stratum germinativum. The stratum corneum dips slightly between the two surfaces of the hood.

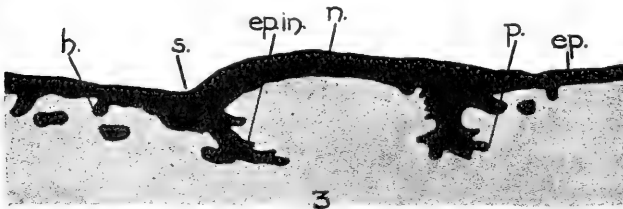
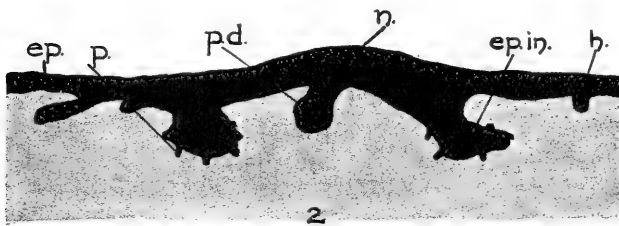
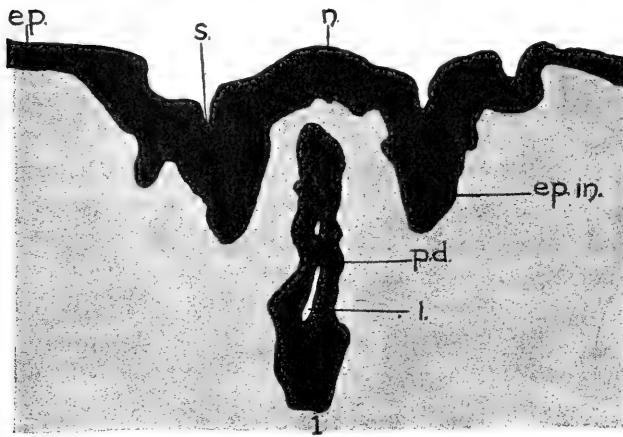


Fig. 1. Drawn from a section through the left first inguinal nipple of a female albino rat at birth. *ep.*, epidermis adjacent to mammary gland area; *ep. in.*, epithelial ingrowth or hood; *l.*, lumen; *n.*, nipple; *p.d.*, primary duct. $\times 100$.

Fig. 2. Drawn from a section through the left second thoracic nipple of a female albino rat of one day. *ep.*, epidermis adjacent to mammary gland; *ep. in.*, epithelial ingrowth; *h.*, hair follicle; *n.*, nipple; *p.*, developing processes on epithelial hood; *p.d.*, primary duct. $\times 100$.

Fig. 3. Drawn from a section through the right third thoracic nipple of a female albino rat of five days. *ep.*, epidermis adjacent to mammary gland; *ep. in.*, epithelial ingrowth; *h.*, hair follicle; *n.*, nipple; *p.*, developing processes on epithelial hood; *s.*, sulcus partially surrounding nipple. $\times 100$.

Traced toward the nipple from the free end of the epithelial projection the stratum germinativum extends toward the surface of the skin thus lining the inner surface of the epithelial hood. Traced away from the nipple from the free end of the epithelial projection it forms the outer surface of the projection and becomes continuous as the stratum germinativum of the surrounding integument. Mitotic figures are numerous in the stratum germinativum covering the epithelial projections.

The contents of the hood are densely arranged connective-tissue cells, small blood-vessels, small nerves, white blood corpuscles, and the developing primary milk-duct. The connective-tissue cells are densely placed as in other parts of the corium. Near the walls of the epithelial hood these cells are arranged somewhat parallel to the stratum germinativum. In other parts of the hood they are arranged in a more irregular manner except around the developing primary duct, where they are concentrically placed, thus forming the sheath of the duct.

In microscopic sections near the highest part of the developing nipple a very shallow pit is being formed by the process of desquamation. This pit represents the future opening of the primary milk-duct—the milk-pore. As this pit deepens in the later stages it becomes a part of the lumen of the primary milk-duct. This part of the lumen becomes greater in extent than the thickness of the epidermis covering the nipple, for the sake of convenience in description, however, it shall hereafter in this paper be known as the intra-epidermal part of the primary duct. From this very shallow pit a solid cord of cells extends through the thickened epidermis. This is the anlage of the intra-epidermal portion of the primary milk-duct. At birth there is no trace of a lumen in this portion of the duct. That part of the duct within the epithelial hood takes a course perpendicular to the surface of the integument. Near the surface the duct is represented by a solid cord of cells, but as it is traced deeper an occasional lacuna representing the first trace of a lumen is encountered. In some glands several lacunae have flown together, thus representing a larger lumen with an irregular outline (fig. 1). The cells in the walls of this part of the duct present no definite

arrangement into layers (fig. 7). As the primary duct leaves the epithelial hood and passes into the tela subcutanea, nearly to its bifurcation, the lumen presents a very irregular outline, in some sections being absent entirely. The walls of the duct are from three to four cells thick.

The secondary ducts which result from the bifurcation of the primary duct possess lumina with more regular outlines. The cell walls appear somewhat thinner and there are indications of the cells beginning to arrange themselves into layers. From the secondary ducts to the ends of the terminal ducts there is, in most cases, a fairly definite layer of low columnar or cuboidal cells surrounding the lumen. External to this layer is a second layer of somewhat irregular-shaped cells which is present in most places, but may be partly or entirely lacking in some parts of the terminal ducts. The free ends of the terminal end-buds are composed of solid masses of epithelial cells.

The milk-ducts are usually spread out so as to occupy a single plane (fig. 18) except in the case of the second inguinal gland (Myers, '16), where the limited space for the distribution of ducts forces them into two or more planes. Immediately surrounding all segments of the ducts are a few concentrically placed layers of connective-tissue which represents the future mantle layer. The irregularly arranged connective-tissue between the adjacent ducts and the mantle layer may be regarded as representing a part of the true stroma found in later stages.

As previously shown (Myers, '17 b), no trace of a mammary gland appears on the surface of the skin of new-born male rats. This is due to the fact that the epidermis in most cases presents no thickening in the region of the mammary gland. The skin, therefore, is as transparent over this region as in that immediately surrounding the gland, so the color of the blood in the corium gives a uniform appearance to both areas.

The end of the primary duct attached to the epidermis in the male is represented by a solid cord of cells. The free end of this duct and the secondary ducts possess lumina in slightly more advanced stages of development than in females of corresponding age. The remaining parts of the gland correspond closely in structure and development with the glands of the female.

Twelve hours

In female rats twelve hours after birth the epidermis covering the developing nipple appears slightly thinner than at birth. There is no noticeable change in the epithelial hood. The attached end of the primary duct is still without a lumen. The remaining ducts possess quite well-developed lumina and their walls are generally lined with two layers of epithelial cells, as described in the preceding stage. However, in some cases the outermost layer is almost entirely absent from a small part of the ducts. These parts with a single layer of cells constituting their epithelial lining are not confined to the terminal ducts only, but may be found in any of the other ducts except the primary duct.

There is a considerable extravasation of red blood-cells in the stroma around the ducts in some specimens. A considerable number of such cells are present in the walls of the milk-ducts, while a few appear in the lumina.

In addition to some red blood-cells in the lumina of the ducts, a few leucocytes are present. A somewhat homogeneous substance is also present in some segments of the ducts. In no case have degenerating cells and nuclei been observed in the lumina of the milk-ducts. The cells and other contents present exist in such small quantities that distention appears in no part of any system of ducts examined. Special fat stains failed to reveal any trace of fat in the walls or lumina of milk-ducts. In the fetus it was found (Myers, '17 a) that the lumina of the milk-ducts are formed by the process of rearrangement of the cells and not, as was formerly believed, by the degeneration of the central cells of the ducts. At birth and for some time after no degenerating cells have been observed in the lumina; moreover, the free borders of the cells immediately surrounding the lumina are quite sharply indicated. It therefore is evident that the substance contained in the lumina of the milk-ducts outside of normal cells is not a detritus, but is probably a secretion produced by the cells surrounding the lumen.

The stroma very distinctly presents the anlagen of its two parts, the mantle layer immediately surrounding the ducts and the true stroma intervening between the ducts of a system of ducts. The true stroma is rather compact and contains many developing fat cells located toward the free ends of the ducts.

Twenty-four hours

Twenty-four hours after birth the developing nipple presents about the same appearance as in the preceding stage. The epithelial projection of the hood now possesses a few very short processes, some of which are located on the inner surface and extend toward the primary duct, while others are on the outer surface projecting away from the hood (fig. 2). Such processes are formed by a thickening of the stratum germinativum. In some cases the cells of this layer have only elongated, while in others at least two layers of cells enter into the formation of the processes.

The contents of the lumina are approximately the same in quality and quantity as in the last-described stage. In the walls of the ducts just outside the lumen an occasional vacuole is seen.

In the inguinal region laterodorsal to the inguinal and abdominal glands a long mass of fat is beginning to appear in the tela subcutanea. This mass extends from the lateral surface of the abdomen just anterior to the ilium to a position posterolateral to the vagina. In the remainder of the present paper this mass of fat will be designated as the inguinal fat pad. Adipose tissue is also developing rapidly laterodorsal to the second and third thoracic glands and cephalic to the first thoracic gland, but it does not present such a definite mass as in the inguinal region.

Four and five days

In female rats of four and five days the nipple is somewhat more elevated above the surface of the surrounding skin than at the end of the first day of life (figs. 3 and 12). The nipple is now represented by a somewhat oblong elevation (fig. 12). Starting at a point slightly posterior to the first thoracic nipple and passing

cephalad, we find a very gradual elevation until the highest part of the nipple is reached. If we start a short distance cephalic to the nipple, we enter a shallow groove or sulcus before reaching the base of the nipple. From the bottom of this groove we find a steep approach to the summit of the nipple elevation. The groove appears cephalic to and passes slightly to the medial and lateral sides of the nipple. In the case of the second and third thoracic glands, the abdominal gland and the first inguinal gland, the groove is on the medial side and extends slightly to the cephalic and caudal parts of the base of the nipple (fig. 5). It is absent on the lateral side of the nipple. In the second inguinal nipple the relations of the groove to the nipple are just opposite to those in the first thoracic. Near the highest part of the nipple the lumen of the intra-epidermal portion of the primary duct appears somewhat deeper than when it was observed in an earlier stage.

The projection of the epithelial hood extends more deeply into the corium than in the earlier stages (fig. 3). The processes which appeared on the epithelial projection in rats of one day are now longer and have the appearance of rather sharp spines. A few of them possess secondary processes.

The lumen of the primary duct now extends nearer to the surface, yet it is not in continuity with the lumen of the intra-epidermal part of the duct. No degenerating cells have been observed in the formation of the lumen of the primary duct proper. This lumen apparently is formed by a process of rearrangement of cells as was shown to be the case (Myers, '17 a) in the other milk-ducts of the fetus. From the secondary ducts through the terminal ducts the amount of secretion present in lumina has increased somewhat since the end of the first day. While it is present in considerable quantities, yet the ducts are by no means engorged. In sections stained with Weigert's iron-haematoxylin the secretion fails to take the stain, while in those stained with Dominici's mixture it takes a light pink color. In fresh frozen sections very rarely a fat droplet was observed in the walls of the milk-ducts. The infrequency of such droplets, their relation to the cells, and their absence in sections fixed, sectioned

in paraffin, and stained in other fat stains, proves fairly conclusively that they were carried by the razor from the fat in the connective-tissue stroma to the epithelial walls of the ducts. Leucocytes inside the lumina are very rare at this stage. A few normal cells with nuclei resembling those of the epithelial wall are present in the lumina. In a few instances normal nuclei with apparently no accompanying cytoplasm were observed in the lumina. Such elements are slightly more numerous toward the free ends of a system of ducts. In only one or two instances have the cells within the lumina shown any signs of degeneration.

Dominici's combination stain reveals some leucocytes in the stroma outside the ducts and in the epithelial hood, but no infiltration of such cells in the stroma around the ducts has been observed. There apparently is no extravasation of red blood-cells as was observed in rats of one day.

End of first week.

At the end of the first week the nipple is more elevated, the lumen of the intra-epidermal part of the primary duct and the projection of the epithelial hood extends deeper into the corium. The lumen of this part of the primary duct is now nearly filled with debris in which appear some desquamated epithelial cells. The processes on the epithelial projection of the hood are very conspicuous.

The milk-ducts in most places possess two layers of epithelium. The inner layer is formed of very compact epithelial cells of the low columnar or cuboid type. The cells of the outer layer are less compact and in fact may be absent in some places. They are irregular in size and shape. The amount and quality of the secretion in the lumina is approximately the same as at four and five days.

At this stage the primary duct of the male rat is attached to the epidermis, there being no nipple at any stage. Its attached end does not possess a lumen. In some cases there is a very slight excavation on the surface of the skin immediately over the attached end of the primary duct which resembles the developing

milk-pore. As the primary duct is traced toward the tela subcutanea a distinct lumen appears and the wall is seen to be composed of two layers of cells which are similar in shape and arrangement to those of the walls of ducts of corresponding thickness in the female. The remaining ducts in the male resemble in number, distribution and structure the corresponding ducts in the female. The secretion in the lumina appears the same in every respect as in the female except that it appears present in slightly larger quantities in the male.

In both sexes the free ends of the milk-ducts of the abdominal and inguinal glands are imbedded in the medial margin of the inguinal fat pad, but in most cases they have not penetrated this pad very deeply. Besides the ducts growing toward the inguinal fat pad, the pad itself has increased in size.

Two weeks

It has been pointed out by Myers ('16) that the nipple (in the female rat) takes on a very rapid development during the second week. The present study shows that the greater part of that development occurs in the latter part of the second week. The nipple becomes so large that it is very conspicuous to the naked eye in living animals and has been used to determine the sex at this age (Jackson, '12). Microscopic sections and wax reconstructions (fig. 13) show that the nipple is much more elevated than in the preceding stage. It is at this time a somewhat elongated structure and has not yet taken on the typical form of a nipple. The shallow groove which was present around a part of the base of the nipple in earlier stages is now somewhat deeper. This groove now entirely surrounds the base of the first thoracic nipple, except on the caudal side where the base of the nipple becomes continuous with the surface of the surrounding skin without a groove. In case of the second and third thoracic glands, the abdominal gland, and the first inguinal gland, the groove extends around the base of the nipple except on the lateral side. In the second inguinal gland the groove is absent on the cephalic side. From the bottom of this groove, which lies immediately

superficial to the attached end of the epithelial hood, may be seen short strands of epithelial tissue which react to the stains differently from the surrounding epithelium. Higher magnification shows that the cells in such strands are undergoing degeneration and are being cast out, thus deepening the groove.

The epithelial projection of the hood has taken on a marked development since the fifth day. It still presents processes which are now more numerous on the inner side of the projection. Such processes are likewise present on the inner surface of the epidermis covering the nipple.

As the layer of smooth muscle which lies immediately below the hair follicles reaches the neighborhood of the nipple, it turns toward the surface and enters the epithelial hood. Here many of the fibers take a course parallel with the primary duct and apparently enter into the formation of the sheath of the duct. Others soon take an oblique direction and apparently attach to the processes on the inner surface of the epithelial projection. Some muscle fibers, after extending into the nipple, take an oblique course and appear to attach to the processes on the inner aspect of the surface epidermis of the nipple. The function of the smooth muscle fibers will be dealt with in studies on the activity of the mammary gland.

The lumen of the intra-epidermal part of the primary duct contain debris apparently in sufficient amount to distend the walls of this part of the duct. Near the milk-pore the wall is reduced to a rather thin structure. As the bottom is approached, the wall becomes thicker. It is here that desquamation is taking place at present. The cord of epithelial cells, which in all of the previous stages separated the lumen of the intra-epidermal part of the duct from the lumen of the primary duct proper, is at this age perforated by a very narrow canal. Thus for the first time a communication is established between the lumina of the system of milk-ducts and the exterior.

The lumen of that part of the primary duct within the epithelial hood and nipple now has a fairly regular outline as far as the region intervening between it and the lumen of the intra-epidermal part of the duct. Here the walls consist of cells

(three or four deep) that have not yet arranged themselves into definite layers. As the primary duct is traced from the epithelial hood into the tela subcutanea, where it turns at right angles and courses parallel with the surface of the skin, the walls of the duct become thinner. The cells are here arranged in layers, rarely more than two layers present. The lumen has a well-defined outline which is occasionally interrupted by the budding off of short lateral buds. Many of these buds likewise possess lumina. The remainder of the ducts has the same general appearance in structure as at the end of one week. The epithelial walls are composed of two layers of cells (fig. 8).

The contents of the milk-ducts have diminished in quantity since the earlier-described stages.

Hair follicles are very numerous peripheral to the sulcus surrounding the nipple superficial to the epithelial projection, but they have in no specimen been observed medial to this groove.

Three, four, five, six, and seven weeks

From the end of the second to the beginning of the eighth week the growth of the mammary gland, as shown in an earlier work (Myers, '16), in the female albino rat is apparently only sufficient to keep pace with the general body growth. Cleared preparations show that beyond question the ducts of the mammary gland grow in length and, moreover, send out numerous new collateral branches during this period. The nipple makes a gradual increase in height. The groove has approximately the same extent around the nipple as in rats of two weeks, but it becomes deeper as age advances. The projection of the epithelial hood retains its processes (fig. 4). The epithelium between the lumen of the intra-epidermal part of the primary duct and the lumen of the primary duct proper at the end of the second week is completely broken down about the fifth or sixth week. The lumen of the primary duct proper therefore becomes directly continuous with that of the intra-epidermal part of the duct and communicates with the exterior through the milk-pore. The lumen of the intra-epidermal portion of the duct is through the seventh week

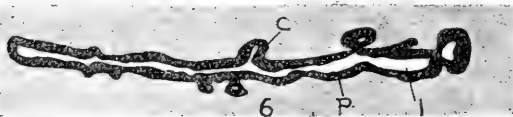
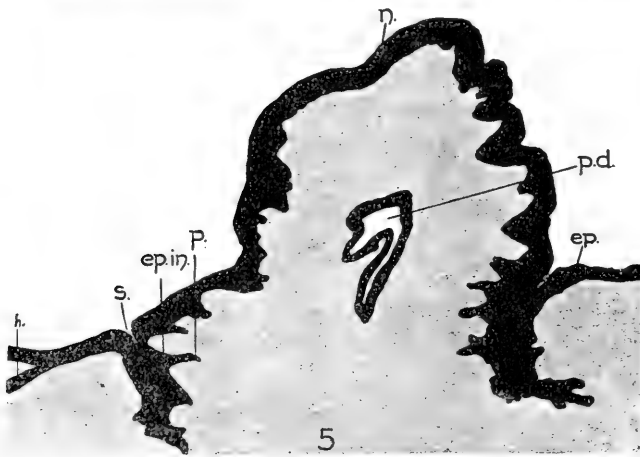
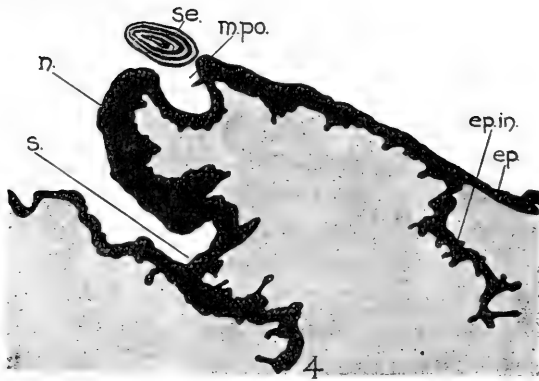


Fig. 4. Drawn from a section through the right second inguinal nipple of a female albino rat of six weeks. *ep.*, epidermis adjacent to mammary gland area; *ep.in.*, epithelial ingrowth; *m.po.*, milk-pore; *n.*, nipple; *s.*, sulcus surrounding a part of base of nipple; *se.*, secretion apparently solidified and dislodged from milk-pore. $\times 66\frac{2}{3}$.

Fig. 5. Drawn from a section through the right first inguinal nipple of a female albino rat of nine weeks. *ep.*, epidermis; *ep.in.*, epithelial ingrowth; *h.*, hair follicle; *n.*, nipple; *p.*, process on epithelial ingrowth; *p.d.*, primary duct; *s.*, sulcus surrounding a part of base of nipple. At the bottom of this sulcus may be seen indications of degeneration. $\times 66\frac{2}{3}$.

Fig. 6. Drawn from a longitudinal section through the primary duct of the right first inguinal gland of a female albino rat of nine weeks. *c.*, collateral duct; *l.*, lumen; *p.*, primary duct proper. $\times 66\frac{2}{3}$.

still engorged with debris. That part of the debris which occupies the milk-pore and is in contact with the exterior apparently becomes solid, thus forming a plug. In some specimens this plug has been removed from the milk-pore during the process of sectioning and lies as a solid body outside of, and independent of the milk-pore (fig. 4). Owing to the presence of such a plug, the contents formed in the lumen of the intra-epidermal part of the primary duct are unable to escape.

The contents of the milk-ducts gradually diminish in quantity after about the second or third week. However, considerable debris is present in the lumina at the beginning of the eighth week.

In all specimens examined the smooth muscle fibers of the nipple have the same arrangement and distribution as in the earlier described stages.

The terminal end-buds of the ducts are prominent in the above-described stages. The lumen of the terminal duct gradually increases in size until it reaches a point near the middle part of the end-bud (fig. 11). Here the lumen ends abruptly, and the remainder of the end-bud is represented by a solid mass of epidermal cells.

It has been pointed out (Myers, '17 b) that the milk-ducts of the male fail to proliferate as rapidly as those of the female after about the fourth or fifth week. This difference together with the absence of the nipple and epithelial hood constitute the only characteristics that serve to distinguish the glands of the male from those of the female from the second to the beginning of the eighth week. As far as the structure of the remaining parts of the gland is concerned, one is unable to distinguish between the sexes. Figure 16 shows the milk-pore on the surface of the skin of a male rat of six weeks. The intra-epidermal part of the primary duct contains a shallow lumen. A solid mass of epithelial cells separates this lumen from that of the primary duct proper.

The connective-tissue sheath or mantle layer surrounding the milk-ducts becomes somewhat thicker as age advances. This sheath is quite thick around the primary and secondary ducts, but when traced toward the free end of a system of ducts gradu-

ally becomes thinner until it forms only an extremely thin layer around the terminal ducts. Previous to the third week, no elastic tissue fibers were observed in the mantle layer. At the end of the third week, however, Weigert's resorcin-fuchsin stain reveals a few elastic tissue fibers sprinkled among the other fibers of the mantle layer of the primary and secondary ducts. During the fifth, sixth, and seventh weeks more elastic fibers are present in the sheath of the primary and secondary ducts, and they are found in the sheath nearer the free end of a system of ducts than at three weeks. The true stroma is formed of loose connective-tissue in which various kinds of leucocytes are found. In no instance has an abnormal number of leucocytes been observed. The stroma also presents a great deal of adipose tissue. The connective tissue which occupies the nipple and epithelial hood is much more compact than in other parts of the gland.

About the third week the free ends of the milk-ducts of the abdominal and inguinal glands are observed to extend some distance into the inguinal fat pad where they send off numerous ramifications. As age advances the fat pad becomes more voluminous. It is not only thicker and longer, but wider than in the preceding stages. Hence its medial margin extends to the level of the abdominal and inguinal nipples. A great deal of adipose tissue has developed also in the stroma of the thoracic glands, so that the ramifications of many of the ducts are surrounded by fat cells.

Eight, nine, and ten weeks

It may be recalled that between the eighth and tenth week it was found in an earlier work (Myers, '16) that the ducts of the mammary gland of the female grow and proliferate very rapidly. Cleared preparations show that a tremendous number of new ducts bud out from the already existing ducts. These ducts bud off not only at the ends of the terminal ducts, but also as collateral ducts from the sides of all other ducts represented, including that part of the primary duct which lies parallel with the surface of the skin. In some of the ten weeks' stages the proliferation of ducts is not as marked as in those of nine weeks.

The nipple has enlarged somewhat and now at ten weeks more closely approaches the form of the nipple of the adult female rat. The groove at the base of the nipple has deepened apparently by the process of desquamation. In some individuals the tissue at the base of the nipple caudal to the first thoracic, cephalic to the second inguinal and lateral to the remaining nipples which in earlier stages connected the base of the nipple with the adjacent skin without the interruption of a furrow has now broken down so as to form a groove. This groove therefore extends completely around the base of the nipple. In fresh preparations the basal half of the nipple rests in the pocket formed by the groove. Such changes have not yet occurred, however, in all rats of nine and ten weeks of age (fig. 17). This furrow lies immediately superficial to the projection of the epithelial hood into which its cavity slightly extends. From the bottom of the furrow in some specimens may be seen the degenerating strands which were described in animals of two weeks (fig. 5). This furrow may contain debris which reacts to stains and appears under high magnification similar to the contents of the lumen of the intra-epidermal part of the primary duct.

The intra-epidermal part of the primary duct is still engorged with debris. Its walls are lined with stratified squamous epithelium of approximately the same thickness as that covering the surface of the nipple. At the end of the intra-epidermal part of the duct there is a gradual transition from the stratified squamous epithelium of this part of the duct to the epithelium of the primary duct proper. The walls of this part of the primary duct are composed of two or three layers of cells. The innermost layer is composed of low columnar cells, while the remaining layers are composed of cells of more irregular form. As the primary duct leaves the nipple and enters the deeper layers of the skin, its epithelium is arranged in two layers. The inner layer is composed of low columnar or high cuboidal cells containing elongated nuclei with their axes perpendicular to the lumen of the duct. The cells of the outer layer are somewhat irregular in size, shape, and position (fig. 9). In a longitudinal section of the primary duct, as it courses parallel with the surface of the skin,

numerous processes may be seen some of which have lumina opening into the duct (fig. 6). These processes represent the collateral ducts. Some possess lumina and are lined with the same kind of epithelium as the primary duct, others are merely in the bud stage of formation and consequently have no lumina. Longitudinal sections of other ducts, as the secondary, tertiary, etc., likewise show numerous collateral ducts in various stages of formation. As the collateral ducts bud from the main ducts they carry with them a thin sheath of the connective tissue surrounding the main duct. Mitotic figures are numerous in the epithelial cells in these stages.

At this stage very little more than the ducts or excretory part of the gland is developed. However, at the end of some of the collateral ducts which branch from the secondary ducts one may observe several outpouchings which somewhat resemble a small cluster of grapes. Microscopic sections show that such outpouchings possess lumina which are surrounded by a layer of cuboidal cells, external to which may be seen an occasional somewhat flattened nucleus (fig. 10). These outpouchings may contain a slight amount of secretion, but they can hardly be called alveoli in the true sense of the word. True lobules are not yet present, although the above-mentioned clusters are doubtless an early indication of lobulation. The ramifications of ducts have become so numerous that they no longer occupy a single plane (fig. 19) as in the earlier stage (fig. 18), but form a rather dense arborization which in places reaches a thickness of 0.8 mm.

No true milk sinus, such as has been observed by various authors in several animal forms, has appeared in any of the described stages of the rat.

Elastic fibers are prominent in the mantle layer of the primary and secondary ducts. They are present in this layer of all the larger ducts, but tend to decrease in number as one passes toward the free end of a system of ducts. No elastic fibers have been observed in the sheath of the terminal ducts. The connective-tissue stroma is similar to that described in earlier stages except that it contains a greater amount of adipose tissue (fig. 19). The inguinal fat pad is so extensive that a thin layer of it now extends

somewhat medial to the abdominal and inguinal nipples. Just under the nipple and partially occupying the epithelial hood is a condensed mass of fibrous tissue which becomes continuous with the less dense fibrous tissue of the nipple. Deep to and surrounding this mass of tissue is the loose stroma of the gland.

During this stage the blood-vessels in the stroma become enlarged so that in fresh specimens one notices a considerable increase in the vascularity of the gland as compared with the preceding stages.

As in the six weeks' stage, the primary duct in the male does not communicate with the exterior on account of a short solid cord of cells existing between its lumen and the very shallow lumen of the intra-epidermal duct. Moreover, it has been pointed out Myers ('17 b) that the marked growth of the female gland at the time of puberty does not usually occur in the male. The terminal enlargements appear similar to those in females of six and seven weeks. The walls of the ducts are composed of two layers of cells with the same arrangement as in the female. However, observations have revealed no indication of lobulation or developing alveoli in the male.

DISCUSSION AND CONCLUSIONS

In the following discussion, the nipple, the epithelial hood, milk-ducts, secretion in the new-born, and gland stroma will be successively considered.

The nipple pocket and epithelial hood

It will be recalled that in female fetuses of twenty days and six hours the nipple appears as a small elevation lying at the bottom of the mammary pit (Myers, '17). After the twenty days and six hours' stage the nipple grows so that at the time of birth in the female albino rat it nearly fills the mammary pit and appears as a somewhat round light area lying at the same level or very slightly elevated above the surrounding epidermis. At the end of the first week of postnatal life (fig. 12) the nipple is only a little more elevated than in the new-born. During the second week

and especially in the last half of this week the nipple takes on a rapid development (fig. 13). At this time the nipple has reached a height of approximately 0.4 mm. From the third to the eighth week the nipple increases in size and gradually becomes somewhat conical in shape (fig. 15). During the eighth and ninth weeks, the time when the first ovulation normally occurs, the nipple begins to appear in size and form similar to the nipple of the adult virgin rat. In some individuals it now closely approaches the shape of a cone with a height of 1 mm., while in others it has not taken on its definitive conical form (fig. 17).

It is perhaps due to the fact that the nipple has no function to perform in the early life of the individual that it remains in a somewhat rudimentary state of development during this period. The rapid elevation during the second and third week may be closely related with the secretion that has already been produced in the milk-ducts. After the second and third weeks there seems to be nothing to stimulate a rapid growth of the nipple as it grows very gradually until near the time of puberty. As the first opportunity for pregnancy or the first ovulation approaches, the nipple takes on the shape and size of that of the adult virgin rat. This development of the nipple is apparently closely correlated with contemporaneous changes in the ovary as macroscopic observations show that Graafian follicles are rapidly growing in the early part of this stage. Furthermore, the vascular supply to the ovary very materially increases as the period of puberty is approached.

Rein ('82) found in the mammary glands of the rabbit two months after birth that the nipple presents a slight elevation in the form of the head of a pin. This elevation is about 1 mm. in height with a basal diameter of 1 to 1.5 mm. In rabbits of six months Schil ('12) found the nipples are conical elevations 1 to 1.5 mm. in height and 4 mm. in diameter at the base. Schil also states that the nipple is rarely indicated in the new-born human. Herz ('00), however, found that the nipple may or may not be elevated in new-born children.

While measurements on the nipples are lacking for many forms of animals, the present work together with general state-

ments found in the literature are sufficient to substantiate the conclusion that the nipple remains in a rudimentary state during the early life of the individual. In the female it takes on its adult virgin form during the prepubertal and pubertal stages. In most animal forms a rudimentary nipple is present in the male at birth; however, it usually remains rudimentary throughout life. A more complete discussion on this subject may be found in an earlier paper (Myers, '17 b).

Epithelial hood

Immediately peripheral to the basal part of the developing nipple of the new-born the basal layer of the epithelium dips deeply to form the epithelial hood. Beginning about the second week of postnatal life, degenerative changes appear in the central part of the attached end of the epithelial hood. Such changes apparently have for their purpose the deepening of the groove which at first partially and later completely surrounds the base of the nipple.

At the time of birth a very shallow furrow may be seen surrounding the base of the nipple (fig. 1). A few days after birth this furrow in most cases has nearly disappeared. However, on the fifth day an apparently new depression (fig. 12) appears around only a part of the base of the nipple. As age advances, this depression or groove becomes deeper and extends around a greater part of the base of each nipple, until finally about the tenth week in some specimens it completely surrounds the base, thus forming a definite pocket in which approximately the basal half of the nipple rests.

Hair follicles appear lateral to the furrow surrounding the nipple (figs. 2 and 3), but have not been observed within this furrow.

Through the ten-weeks stage there is no indication of furrow or epithelial hood in the male albino rat.

In 1876, Gegenbaur called attention to the fact that in *Mus decumanus* and *Mus musculus* the basal part of the nipples lies in a pocket-like depression of the integument. Gegenbaur be-

lieved the depression or pocket to be like the nipple pocket of marsupials. Rein ('82) studied the gland in a few of its stages in the white mouse and white rat. He concluded that the pocket surrounding the nipple in the adult has nothing to do with the nipple pocket of marsupials, but that it is identical with the marsupial pouch. Bresslau ('02, '10, and '12), in a series of studies, finally concluded that the sheath or pocket surrounding the nipple of the adult rodent and insectivorous mammals develops quite independently of the nipple pocket of marsupials or the marsupial pouch. The groove or sulcus at the base of the nipple in the albino rat was mentioned in my earlier work (Myers, '16), but its formation was not discussed at that time. The shallow groove which appears around the nipple in the newborn (fig. 1) is undoubtedly a remnant of the prenatal mammary pit which the growing nipple has not yet completely occupied. Sections through nipples of twelve hours, one day, two and three days after birth show that the sulcus around the new-born nipple has disappeared; in other words, the nipple completely fills the mammary pit. The very slight depression that surrounds only a portion of the base of the nipple at five days and continues to deepen and become more extensive until it forms a pocket containing nearly the basal half of the nipple at the tenth week apparently develops independently. We must therefore conclude that the pocket in which the base of the nipple of the adult virgin mouse and rat rests is not, as Gegenbaur believed, homologous with the nipple pocket of marsupials, but, as Bresslau suggested, it is an entirely independent structure which in the albino rat at least develops after birth.

The epithelial projection or hood was described in *Mus decumanus* and *Mus musculus* by Gegenbaur ('76). Later Rein ('82) observed such projections in white mice and white rats and described them from sections of fetuses as two solid epidermal thickenings which surround the mammary anlage. He described them as being somewhat curved with concavities directed toward each other. Rein found similar structures present in the mole. He believed that they have to do with the formation of the pocket around the nipple. Klaatsch ('84) also

called attention to such projections. Bresslau ('12) observed these projections developing in *Talpa europaea*, white mouse, *Mus musculus*, *Mus rattus*, and *Mus decumanus*, and concluded that they develop into the secondary sheath or pocket of the nipple. In the albino rat wax reconstructions have been used by me to show that the epithelial projections seen in sections form a continuous hood around the primary duct. The attached end of this hood lies immediately peripheral to the base of the nipple. In view of the fact that the present work shows that the sulcus is deepened through degeneration and desquamation of the attached end of this hood, we must conclude that a portion of the sulcus is formed at the expense of the hood. In other words, the lateral wall of the attached part of the hood becomes the lateral wall of the deep part of the sulcus, while the medial wall of the attached end of the hood becomes the medial wall of the deep part of the sulcus. At present I am unable to say whether the sulcus forming the pocket around the nipple continues to deepen in the same manner during pregnancy and lactation until the free end of the hood is reached.

Milk-ducts

It will be recalled that the milk-ducts present several branches in female fetuses of about twenty days (Myers, '17 a). A considerable growth and branching occurs between this stage and the time of birth (compare fig. 12, p. 223, vol. 22, *Am. Jour. Anat.*, with figs. 3 to 6, inclusive, pp. 361-365, vol. 19, *Am. Jour. Anat.*).

At the time of birth the lumina of the milk-ducts are not completely formed. The attached end of the primary duct for a short distance has no trace of a lumen. However, as one passes toward the deeper part of the duct one observes isolated lacunae. A little further along the duct one meets larger spaces which result from the flowing together of several lacunae (fig. 7). Finally, a slit-like lumen appears in the still deeper part of the duct, which extends through the secondary ducts. In the remainder of the ducts a fairly well-developed lumen is present. As age advances the lumen of the primary duct becomes com-

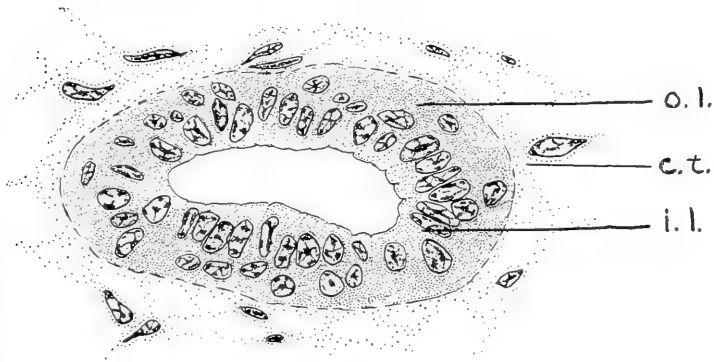
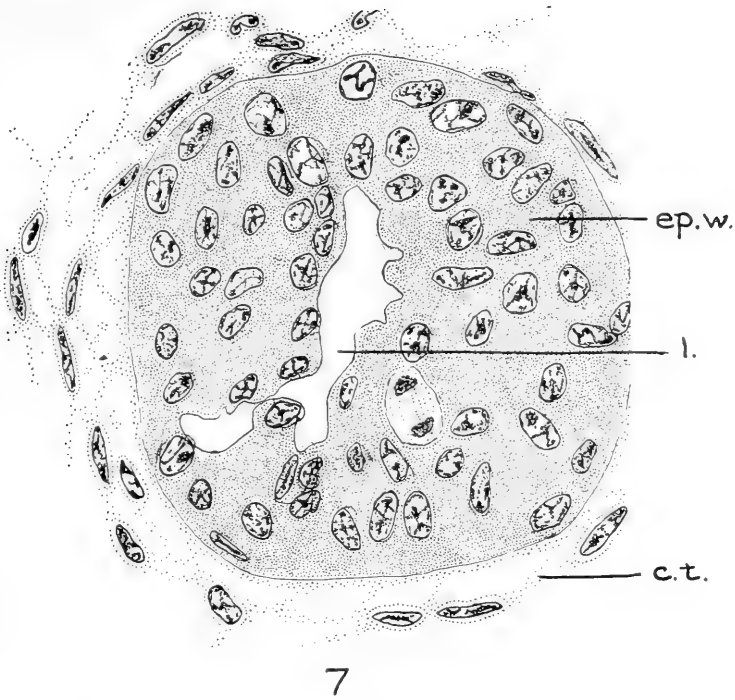


Fig. 7 Drawn from a cross-section through the primary milk-duct of the left first inguinal gland of a female albino rat at birth. Zenker's fixation; Weigert's iron-hematoxylin stain. Drawn with the aid of a camera lucida. *c.t.*, developing connective tissue forming sheath around the duct; *ep.w.*, epithelial wall composed of epithelial cells without definite arrangement into layers; *l.*, developing lumen. $\times 800$.

Fig. 8 Drawn through a cross-section of a terminal duct (about 20μ from its termination) of a female albino rat of eleven days. Zenker's fixation; Weigert's iron-hematoxylin stain. Drawn with the aid of a camera lucida. *c.t.*, connective tissue; *i.l.*, inner or glandular layer of epithelial cells; *o.l.*, outer or myo-epithelial layer of cells. $\times 800$.

pletely formed. Near the highest part of the nipple elevation in the new-born female appears a shallow pit, the first indication of the milk-pore and the beginning of the intra-epidermal part of the primary duct. As age advances, this pit deepens and enlarges until at five or six weeks it comes in contact with the lumen of the primary duct proper. Thereafter the system of ducts is in direct communication with the surface through the milk-pore.

The walls of the ducts, especially the primary and secondary ducts, are quite thick at birth. The free half of each terminal enlargement is composed of a solid mass of epithelial cells. At birth some of the ducts toward the free end of a system present a wall composed of two definite layers of cells. After the first week all of the milk-ducts except the attached end of the primary duct are surrounded by an inner layer of very compactly placed low columnar or cuboidal cells and an outer layer of irregularly shaped cells with no regular arrangement (figs. 8 and 9).

Ancel and Bouin ('09) found in rabbits as many as ten milk-ducts radiating from the nipple. Each duct in animals before the stage of puberty, however, does not exceed 2 mm. in length. The diameter of the gland reaches about 3 or 4 mm. The fact that there is a single duct leading from the nipple in the albino rat perhaps accounts for the much greater length and branching of the ducts in the prepuberty stage. Steinhaus ('93) found in young guinea-pigs that the glands are composed only of excretory ducts. Dulcert ('93) arrived at the same conclusion. They did not observe many mitotic figures. In a heifer of one year Dulcert ('93) reported only excretory canals and observed no mitotic figures. O'Donoghue ('12) found in the deeper parts of the glands of *Dasyurus* a few structures of doubtful significance which may or may not represent mitotic figures, but he found that the actual formative growth of the gland does not appear to start until after ovulation.

Langer ('51), Raubitschek ('04), and others have reported true alveoli in the mammary gland of human after birth and before puberty. Berka ('12), however, was unable to find true

alveoli present in these stages. Schil ('12) states that from birth until shortly before the puberty period the mammary gland of the rabbit undergoes very little or no growth, that the slight elongation of the ducts is due to a stretching produced by the developing stroma. He states that there are two facts which characterize this period: first, the gland maintains the development already reached at birth; second, some of the cells produce a very slight secretion. These facts, he believes, prove that the gland does not receive any impulse of growth or secretion. However, Schil thinks that during this entire period the glands are under the influence of the ovaries, for after double ovariectomies in young animals the free parts of the ducts not only fail to produce a slight secretion, but disappear so that the gland is reduced to some short ducts centering around the nipple. On the other hand, he cites the experiments of Knauer and Foges which show that after simple hysterectomies without ablation of the ovaries the gland remains as in normal or control animals. Schil concludes, therefore, that the presence of the ovary is necessary to maintain the mammary gland in the stage it has reached at the time of birth.

My previous work (Myers, '16) shows beyond doubt that the ducts do grow and proliferate a great deal after birth and before the period of puberty is reached. According to the castration experiments of Steinach ('12) and others, it seems probable that this gradual growth in the milk-ducts of the albino rat from birth to a short time before puberty is under the influence of the ovaries. Further castration experiments are being attempted to confirm this point. It has been pointed out, however, (Myers, '17 b) that the milk ducts of the male albino rat undergo a similar but less extensive growth and proliferation from the time of birth to puberty. If, as Schil believes, the presence of the ovaries is necessary even to maintain the gland of the rabbit in its infantile state until puberty, we are at present unable to locate the factor which stimulates the growth of the glands of the male during this period.

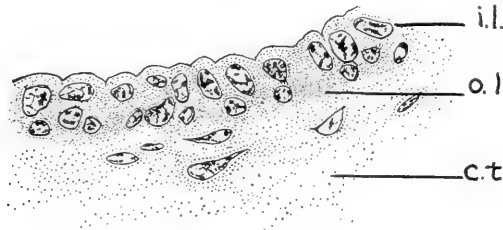
The rapid growth and proliferation of the milk-ducts at the time of puberty has been mentioned by a number of investigators,

but only a few have made a detailed study of this growth. Langer ('51) called attention to the growth of ducts at this period in human. Ancel and Bouin ('10 and '11) showed that during the period of puberty the mammary gland in the rabbit reaches a diameter of 2 to 3 cm. Frank and Unger ('11) showed that a very decided growth occurs in the mammary glands of rabbits during puberty. Schil ('12), in a careful series of observations on rabbits, found that the glands gradually increase throughout the first period of heat, after which they undergo slight regressive changes until the next period of heat. If pregnancy does not occur, the glands proliferate with each heat. The regression following heat depends upon the interval between two periods. Brouha ('05) has shown in *Vespertilio murinus*, in which there appears a single ripe follicle each year, that between two pregnancy periods the gland may return to the infantile stage. The fact that the glands of some rats at ten weeks of age show less development than those in others at nine weeks may be due to slight regressive changes since the first ovulation, as this ovulation may occur earlier than nine or ten weeks (Lantz, '10; Jackson, '12). However, owing to the fact that careful studies on the oestrus cycle in the albino rat have not yet been published, the question as to changes in the mammary gland between and during successive periods of heat has been omitted in this study.

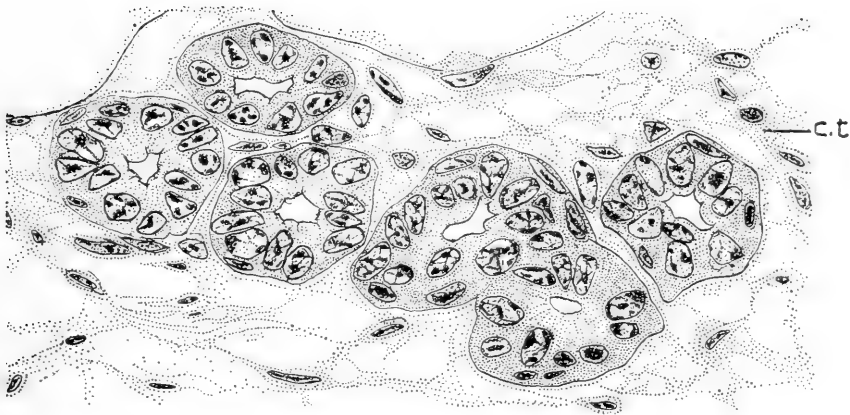
The present study, my previous work (Myers, '16), and the findings of the above-mentioned authors lead to the conclusion that there is in the female of several animal forms a very marked development of the mammary gland at the time of puberty. Since such development does not ordinarily occur in the glands of the male or in castrated females, it seems probable that these changes are at least stimulated by simultaneous changes in the ovaries.

The time and manner of formation of the lumina of the milk-ducts were previously discussed (Myers, '17 a). Suffice it to say here that the method of formation of the lumen already begun in the fetus is continued in the postnatal stages until the lumina are completely developed. The lumen of the intra-epidermal part of the primary duct forms an exception, however, as it develops by the process of degeneration and desquamation.

The lining of the milk-ducts in the adult virgin human has been described by von Ebner as consisting of a single layer of epithelial cells. Starling and Lane-Clayton ('06) also reported a single layer of epithelium surrounding the ducts in virgin rabbits. Rein ('82) divided the duct in rabbits of two months into



9



10

Fig. 9 Drawn from a cross-section of a secondary milk-duct of a female albino rat of nine weeks. Zenker's fixation; Weigert's iron-hematoxylin stain. Drawn with the aid of a camera lucida. *c.t.*, connective tissue; *i.l.*, inner or glandular layer of epithelium; *o.l.*, outer or myo-epithelial layer. $\times 800$.

Fig. 10 Drawn from a section through the terminal branches of a collateral duct of a female albino rat of nine weeks. Zinker's fixation; Weigert's iron-hematoxylin stain. Drawn with the aid of a camera lucida. *c.t.*, connective tissue. The cross-sections through the six terminal parts show in general a single layer of epithelium. An occasional flattened nucleus represents the outer or myo-epithelial layer. $\times 800$.

three parts: first, the short excretory duct which extends from the milk-pore to a noticeable enlargement; second, the enlargement or milk-sinus, and, third, the milk-duct or canal. He found the excretory duct lined with a stratified pavement epithelium, while the sinus and milk-ducts possess two epithelial layers. Benda ('94) found the epithelium near the attached parts composed of two layers of cells, while in the deeper and free parts of the ducts the epithelium was described as consisting of a single layer. Raubitschek ('04) found in a human female of seven days that the epithelium and the ducts is composed of two layers. Brouha ('05) described this epithelium as consisting of two layers throughout the entire system of ducts in virgin *Vespertilio murinus*, the rabbit, and the domestic cat. Schil ('12) observed two distinct layers of cells around the ducts before the stage of puberty. O'Donoghue ('12) confirms Brouha's finding in the domestic cat and writes concerning *Dasyurus* as follows: "As in the foetus, so in the adult *Dasyurus*, all the branching tubules of the mammary gland are lined by a double layer of cells, at any rate in the resting animal, and for some time after ovulation."

The fact that a few ducts were observed in the early postnatal stages of the albino rat with small areas covered with a single layer of epithelium probably has no significance as in later stages all ducts observed were lined with a double layer of cells. The outer layer of cells doubtless represents the so-called basket cells or myo-epithelial cells of the active mammary gland, while the inner layer represents the true glandular cells.

True alveoli lined with a single early of cells have been reported in the glands of various animal species before puberty by several writers. Such alveoli or acini have probably been observed, as there is no reason to doubt that through individual variation a few acini might develop just as a mature Graafian follicle sometimes appears in the ovary of the human fetus or new-born. However, Schil ('12) concluded that during this period the mammary gland in the rabbit ordinarily presents no glandular acini. O'Donoghue ('12), after studying the glands of *Dasyurus*, made the following statement: "The true secre-

tory alveoli of the gland with their simple epithelial lining do not make their appearance until the last few days of pregnancy or until some time after ovulation when this has not been followed by fertilization." The work of these investigators, the present work, and my previous work (Myers, '16) prove that in certain animals true alveoli do not usually appear before puberty.

It has been proved quite conclusively that true secretory alveoli do appear after the first ovulation. In fact, Ancel and Bouin ('11) and Schil ('12) showed that in the rabbit the mam-

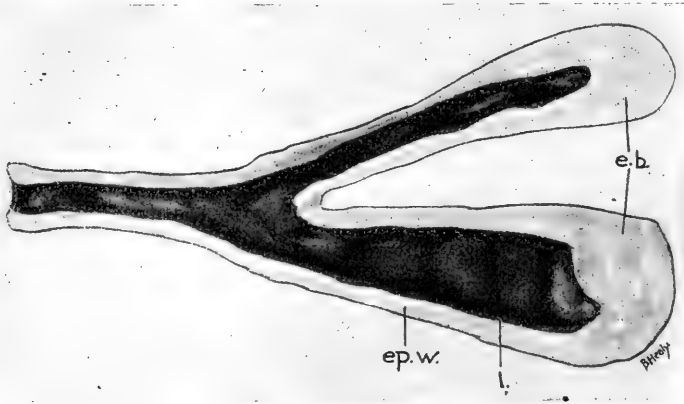


Fig. 11 Internal view of a wax model reconstructed from two terminal duct and end-buds of the right first thoracic gland of a female albino rat of seven weeks. *e.b.*, end-bud; *ep.w.*, epithelial wall; *l.*, lumen. $\times 100$.

mary gland develops after each ovulation not followed by pregnancy to the same extent as it develops during the first half of pregnancy. O'Donoghue ('12) and Hartman ('18) reported somewhat similar changes in the mammary glands of *Dasyurus* and the opossum. Most of the investigators believe this development is due to the corpus luteum. The enlarged terminations of the ducts which resemble alveoli in some ten-week rats were perhaps developed during the first period of heat or some time after the first ovulation.

Secretion in the new-born

It will be recalled that twelve hours after birth a slight secretion appears in the lumina of the milk-ducts. This secretion is more abundant at the fourth and fifth days and remains present in approximately the same amount during the first week. At no time does it completely fill the lumina of the ducts. After the second week the secretion gradually appears present in smaller amounts; however, at the ninth and tenth weeks there is still some secretion to be found in the lumina. There is only a very occasional free epithelial cell present in the secretion. During the first few days of postnatal life such cells manifest no signs of degeneration, however, later a few were observed undergoing degeneration. A few red blood corpuscles were observed in the lumina of the ducts at twelve hours after birth, but none appeared in any of the later stages. An occasional leucocyte may be seen in the lumina at any stage from birth to ten weeks. In none of the stages studied could fat be demonstrated in the lumina or the epithelial cells lining the ducts.

The secretion in the new-born or witches' milk has been observed in human by a large number of investigators. According to Brouha ('05), Aristotle called attention to it. The writers of the second half of the nineteenth and the early part of the twentieth centuries presented different theories concerning the origin of this secretion. For example, De Sinety ('75), Rein ('82), Barfurth ('82), Czerny ('90), Unger ('98), Schalachta ('04), Brouha ('05), Berka ('11), Schil ('12), and others regarded it in the human new-born as a true milk secretion, while Kölliker ('54), Milne Edwards ('70), and Raubitschek ('04) believed it is the product of necrobiotic changes which result in the formation of the lumina. Still another view is that of Keiffer ('02), who described the formation of milk in the new-born as a pathological process.

Several theories have been offered to account for the stimulus which excites the secretion in the new-born human. The fact that Brouha concluded that the new-born secretion in well-developed human may completely precede the birth of the child

and that Schil observed true milk secretion in the ducts of a human fetus at the beginning of the eighth month, proves fairly conclusively that a secretion capable of stimulating the glands to action is formed in the placenta or ovary of the mother and transmitted to the blood of both mother and offspring, thus bringing about the formation of milk in both maternal and fetal mammary glands.

Berka ('11) believes the contents of the lumina of the milk-ducts through the virgin stage is a part of the witches' milk which has been retained in the ducts. On the other hand, Schil ('12) thinks this results from a constant slight secretory activity of the epithelial cells. O'Donoghue ('12), after studying *Dasyurus* agrees with Schil in the following:

A trace of a secretion somewhat resembling colostrum is always to be found as a coagulum in the lumen of the tubules and ducts until it is removed by the more active secretion of colostrum or milk. It would appear, then, that the gland, quite apart from the proper milk flow, is the seat of slow secretory activity, although this secretion is quite different in microscopic appearance from true milk.

Aristotle is said to have observed witches' milk in the goat. Creighton ('78) reported it in the guinea-pig in the following manner:

The fluid expressed from the nipple of the new-born guinea-pig had the appearance of a watery kind of milk; on microscopic examination, the milk-globules of ordinary milk were not found, but a more uniform fluid mass irregularly broken up under the cover-slip into large or small drops, and without any mixture of cellular elements.

Barfurth noticed such a secretion in the guinea-pig, bitch, and rabbit and regarded it as a coagulum resulting from simple transudation. After studying it in *Vespertilio murinus*, rabbit, and the domestic cat, Brouha ('05) came to the following conclusions in regard to these forms; "la sécrétion natale existe également, mais elle n'aboutit pas, au moins dans les trois premières semaines de le vie, à une véritable lactation." Schil ('12) observed secretion in the ducts of rabbit embryos as well as postnatal stages. No secretion has been observed in the ducts of rat fetuses by me. Brouha's work and the present

study lead to the conclusion that in the rabbit, cat, bat, and white rat the so-called new-born secretion does not contain fat and hence is not a true lactation as is found in human. This failure to produce true milk in some of the lower forms may be due to the feeble development of the mammary gland in the new-born. The lumina are not completely formed at birth in the rat, cat, and rabbit, therefore the cells may be unable to produce a true milk secretion when the stimulus is received. On the other hand, Brouha found the lumina quite well represented in *Vespertilio murinus* at the time of birth. The question then arises as to whether the stimulus which produces a true lactation in the human new-born is actually present in the lower forms of animals. Further experimental evidence is necessary to decide this question.

Gland stroma

Attention was called to the fact that the stroma in the fetus is divisible into the mantle layer closely surrounding the ducts and the true stroma between the ducts. This arrangement of the stroma persists through the ten weeks' stage. The mantle layer increases somewhat in thickness as age advances. This layer diminishes in thickness as one passes from the primary to the terminal ducts. About the third week of postnatal life a few elastic fibres appear in the mantle layer surrounding the primary and secondary ducts. In later stages elastic fibers are more numerous and extend further toward the free end of a system of ducts. The true stroma is at first composed of loose connective tissue, but soon after birth there appears such a tremendous invasion of fat that the mantle layer of the ducts is almost entirely surrounded by fat cells.

Free red corpuscles were observed in the stroma twelve hours after birth, but were not seen in any of the later stages. White blood-cells were observed in the true stroma in all stages studied, but in no stage did they appear in greater numbers than they are usually found in the neighboring tissues.

Berka ('11) called attention to the presence of elastic fibers in the mantle layer of the virgin human ducts. Schil ('12)

observed elastic fibers in rabbits six months of age and at the age of puberty.

Red blood corpuscles were observed in the true stroma of the glands of premature and mature infants by Schlachta ('04). Brouha ('05) found capillary hemorrhage exists in the stroma of all infants that died from abrupt asphyxia. He noticed, however, that in infants dying from other causes there may be a considerable extravasation of red blood corpuscles. Both of these authors concluded that the red corpuscles probably reached the stroma through the process of diapedesis. Owing to the presence of red blood-cells in the mammary-gland stroma of the albino rat in comparatively small numbers, it is possible that they reach the stroma through the process of diapedesis. However, it must be borne in mind that during parturition and the removal of the skin there is considerable danger of trauma.

Several authors have reported the presence of an abnormally large number of leucocytes in the true stroma of the mammary gland at or soon after birth. Czerny ('90) believed they play an important rôle by entering the lumina of the ducts and carrying the secretion into the lymphatics. Schlachta ('04) was unable to confirm Czerny's finding. Brouha ('05), however, found the immigration of leucocytes in the gland stroma to be less marked during the activity of the new-born gland than before or after such activity. The fact that the secretion in the albino rat is very slight and never becomes a true milk secretion probably accounts for the absence of an infiltration of leucocytes.

SUMMARY

The results of the present study on the mammary gland of the male and female albino rat from birth to ten weeks of age may be summarized briefly as follows:

1. Owing to the thickening of the epidermis over the developing nipple of the new-born female albino rat, the mammary-gland area appears lighter than the surrounding epidermis. In the male no epidermal thickening is present, hence the mammary-gland area is not visible.

The nipple elevation is oblong in shape and very slightly elevated at the fourth or fifth day. At the end of the second week it is still oblong, but much more elevated. After the second week its growth is a gradual one until the time of puberty, when it takes on the size and shape of the adult virgin nipple.

2. The sulcus around the nipple in the new-born female rat is apparently a remnant of the prenatal mammary pit. During the early days of postnatal life this sulcus disappears, but on the fourth or fifth day an apparently new depression makes its appearance. This depression deepens so that by the tenth week there may be developed a definite pocket in which the basal part of the nipple is located.

3. The epithelial ingrowth (hood) at birth presents a smooth and quite regular outline. Two or three days after birth, however, the stratum germinativum becomes somewhat thickened in some places, thus forming short processes. Such processes appear on both the outer and inner surfaces of the hood throughout the stages studied. The central portion of the proximal part of the hood apparently degenerates, thus deepening the sulcus around the base of the nipple.

4. Hair follicles are numerous in the integument peripheral to the hood and sulcus, but have not been observed nearer the nipple.

5. Near the highest part of the nipple there appears, a few days after birth, a slight excavation—the developing milk-pore, communicating with the intra-epidermal part of the primary duct. At two weeks there is a slight connection between this cavity and the lumen of the primary duct. About the sixth week a complete connection is established with the primary duct. When the nipple becomes cone-shaped, the milk-pore appears near the apex.

6. The lumina of the milk ducts are apparently formed by the process of rearrangement of the cells. The lumen of the primary duct is not completely formed until after the second week. The other ducts possess fairly well-developed lumina at the time of birth.

7. The walls of the milk-ducts are for the most part lined with a two-layered epithelium. The inner or glandular layer being composed of cuboidal to low columnar cells, while the outer (or so-called myo-epithelial layer) is composed of cells irregular in size, shape, and arrangement. At nine or ten weeks some of the terminal processes show indications of developing into alveoli. The walls of the intra-epidermal part of the primary duct are lined with stratified epithelium similar to that covering the surface of the nipple.

8. Masses of subcutaneous fat develop soon after birth. Such masses increase in size as age advances, and it is in this fat that many of the milk-ducts ramify.

9. The stroma is divisible into its usual parts. The mantle layer forms a thin sheath immediately surrounding the milk-ducts. At the third week and thereafter elastic tissue fibers were visible in this layer surrounding the larger ducts. The true stroma is formed of a loose connective-tissue network in the early stages, but later shows a very marked infiltration of fat. Extending through the adipose tissue may be seen an occasional fair-sized connective-tissue lamina.

10. In no stage was an infiltration of leucocytes observed in the stroma.

11. A slight secretion appears in the lumina of the milk-ducts soon after birth. In no case has such secretion appeared in sufficient quantities to cause distention of the ducts. A trace of secretion may be seen in the milk-ducts through the ten weeks' stage. Specific fat stains fail to reveal fat in the secretion of the milk-ducts or in the epithelial walls, notwithstanding the fact that much fat was seen in the true stroma outside the walls of the ducts.

BIBLIOGRAPHY

- ANCEL, P., ET BOUIN, P. 1909 Sur la fonction du corps jaune. Action du corps jaune vrai sur la glande mammaire (troisième note préliminaire). *Compt. rend. Soc. Biol.*, T. 66, p. 605. 1911 Recherches sur les fonctions du corps jaune gestatif. 11. Sur le déterminisme du développement de la glande mammaire au cours de la gestation. *Journ. de phys. et de path. générale*, no. 1, p. 31.

- BARFURTH, DIETRICH 1882 Zur Entwicklung der Milchdrüse. Inaug. Diss., Bonn.
- BELL, E. T. 1914 On the differential staining of fats. *Journal of Pathology and Bacteriology*, vol. 19, p. 105.
- BENDA, L. 1894 Das Verhältnis der Milchdrüsen zu den Hautdrüsen. *Dermatolog. Zeitschr.*, Bd. 1.
- BERKA, F. 1911 Die Brustdrüse verschiedener Altersstufen und während der Schwangerschaft. *Frankfurter Zeitschrift für Pathologie*, vol. 8.
- BRESSLAU, E. 1902 Beiträge zur Entwicklungsgeschichte der Mammarorgane bei den Beuteltieren. *Zeitschrift f. Morphologie u. Anthropologie*, Bd. 4.
1910 Der Mammarapparat (Entwicklung und Stammesgeschichte). *Ergebn. d. Anat. u. Entw.*, Bd. 19.
1912 Die Entwicklung des Mammarapparates der Monotremen, Marsupialier und einiger Placentaler. III. Entwicklung des Mammarapparates der Marsupialier, Insectivoren, Nagethiere, Carnivoren und Wiederkäuer. *Semon's Zoolog. Forschungsreisen*, Bd. 5.
- BROUHA, DR. 1905 Recherches sur les diverses phases du développement et de l'activité de la mamelle. *Archives de Biologie*, T. 21.
- CREIGHTON, CHARLES 1878 *Physiology and Pathology of the breast*. London.
- CZERNY, A. 1890 Über die Brustdrüsensecretion beim Neugeborenen u. über das Verhältniss der sogenannten Colostrumkörperchen zur Milchsecretion. *Festschr. d'Henoch*.
- DE SINETY, 1875 Recherches sur la mamelle des enfants nouveau-nés. *Arch. de physiol. norm. et patholog.*, T. 2.
- DULCERT 1893 Étude histologique de la sécrétion lactée. Thèse de Montpellier.
- FOGES, ARTHUR 1905 Zur physiologischen Beziehungen von Mamma und Genitalien. *Zentralblatt f. Physiol.*, Bd. 19.
1908 Zur Physiologischen Beziehungen von Mamma und Genitale. *Wien. klin. Woch.*, Bd. 21.
- FRANK, R. T., AND UNGER, A. 1911 An experimental study of the causes which produce the growth of the mammary gland. *Archives of internal medicine*, vol. 7.
- GEGENBAUR, C. 1876 Zur genaueren Kenntniss der Zitzen der Säugethiere. *Morpholog. Jahrb.*, Bd. 1.
- HARTMAN, CARL 1918 Personal communication. Work in progress at The Wistar Institute of Anatomy, Philadelphia.
- HERZ, P. 1900 Klinische Untersuchungen an 100 Neugeborenen. Inaug. Diss. Freiburg i. B., S. 1-61.
- JACKSON, C. M. 1912 On the recognition of sex through external characters in the young rat. *Biol. Bull.*, vol. 23.
- KEIFFER, H. 1902 La glande mammaire chez le foetus et chez le nourrisson. *Bull. Soc. Belge de Gyn. et d'Obstet.*, T. 13.
- KLAATSCH, H. 1884 Zur Morphologie der Säugethierzitzen. *Morph. Jahrb.*, Bd. 9.
- KNAUER, EMIL 1900 Die Ovarientransplantation. *Arch. f. Gyn.*, Bd. 60.
- KÖLLIKER, TH. 1850 *Mikroskopische Anatomie*, Bd. 2.

- LANE-CLAYPON, MISS J. E., AND STARLING, E. H. 1906 An experimental enquiry into the factors which determine the growth and activity of the mammary glands. Proc. of the Royal Society, Series B, vol. 77.
- LANGER, CARL 1851 Über Bau und Entwicklung der Milchdrüse. Denkschrift der Wiener Akad. d. Wiss., Bd. 3.
- LANTZ, DAVID E. 1910 The natural history of the rat. In "The rat and its relation to the public health," by various authors. P.H. and M.H. Service, Washington, D. C.
- LOEB, LEO, AND HESSELBERG, CORA 1917 The cyclic changes in the mammary gland under normal and pathological conditions. Jour. of Experimental Medicine, vol. 25.
- MILNE-EDWARDS 1870 Leçons sur la physiologie et l'anatomie comparée de l'homme et des animaux. Paris, T. 9.
- MYERS, J. A. 1916 Studies on the mammary gland. I. The growth and distribution of the milk-ducts and the development of the nipple in the albino rat from birth to ten weeks of age. Am. Jour. Anat., vol. 19. (Abstract also published in the Anat. Rec., 1916, vol. 10, p. 230.)
 1917 a Studies on the mammary gland. II. The fetal development of the mammary gland in the female albino rat. Am. Jour. Anat., vol. 22. (Abstract also published in the Anat. Rec., 1917, vol. 11, p. 390.)
 1917 b Studies on the mammary gland. III. A comparison of the developing mammary glands in male and female albino rats from the late fetal stages to ten weeks of age. Anat. Rec., vol. 13. (Abstract also published in the Anat. Rec., 1917, vol. 11.)
 1918 The histology of the mammary gland in the male and female albino rat from birth to ten weeks of age. (Abstract.) Anat. Rec., vol. 14, p. 46.
- O'DONOGHUE, CHARLES H. 1912 The growth-changes in the mammary apparatus of *Dasyurus* and the relation of the corpora lutea thereto. Quarterly Journal of Microscopical Science, vol. 57.
- RAUBITSCHK, H. 1904 Über die Brustdrüsen menschlicher Neugeborenen. Zeitsch. f. Heilkund., Abth. f. pathol. Anatomie, Heft 1.
- REIN, G. 1882 Untersuchungen über die embryonale Entwicklungsgeschichte der Milchdrüse. Archiv für mikr. Anatomie, Bd. 20 and 21.
- SCHLACHTA 1904 Beiträge zur mikroskopischen Anatomie der Prostata u. Mamma des Neugeborenen. Arch. f. mikros. Anat. u. Entwick.
- SCHIL, L. 1912 Recherches sur la glande mammaire, sur les phases qu'elle présente au cours de son évolution et leur déterminisme. Thèse, Lyon.
- STEINACH, E. 1912 Willkürliche Umwandlung von Säugetier-Männchen in Tiere mit ausgeprägt weiblichen Geschlechtscharakteren und weiblicher Psyche. Archiv für die gesammte Physiologie (Pflüger's).
- STEINHAUS, JULIUS 1892 Die Morphologie der Milchabsonderung. Arch. f. Ant. u. Physiol., Suppl. Bd.
- UNGER, E. 1898 Beiträge zur Anatomie u. Physiologie der Milchdrüse. Anat. Heft.
- VON EBNER 1902 Handbuch der Gewebelehren des Menschen von Kölliker, Bd. 3.

PLATE 1

EXPLANATION OF FIGURES

12 External view of wax model reconstructed from the right third thoracic gland of a female albino rat of five days. Reconstruction built by A. H. Nerad. *ep.*, epidermis; *n.*, nipple eminence; *s.*, sulcus. $\times 37\frac{1}{2}$.

13 External view of a wax model reconstructed from the right second inguinal gland of a female albino rat of two weeks. Reconstruction built by A. F. Branton. *ep.*, epidermis; *m.po.*, milk-pore; *n.*, nipple; *s.*, sulcus. $\times 37\frac{1}{2}$.

14 Internal view of a wax model reconstructed from the right second inguinal gland of a female albino rat of two weeks. Reconstruction built by A. F. Branton. *ep.*, epidermis; *ep.in.*, epithelial ingrowth; *p.d.*, primary duct. $\times 37\frac{1}{2}$.

15 External view of a wax model reconstructed from the right second inguinal gland of a female albino rat of six weeks. Reconstruction built by Nellie Pederson and Frieda Radusch. *ep.*, epidermis; *m.po.*, milk-pore; *n.*, nipple; *s.*, sulcus. $\times 37\frac{1}{2}$.

16 External view of a wax model reconstructed from the right abdominal gland of a male albino rat of six weeks. *ep.*, epidermis; *m.po.*, milk-pore. $\times 37\frac{1}{2}$.

17 External view of a wax model reconstructed from the right first inguinal gland of a female albino rat of nine weeks. Reconstruction by M. H. Litman and A. F. Branton. *ep.*, epidermis; *m.po.*, milk-pore; *n.*, nipple; *s.*, sulcus. $\times 37\frac{1}{2}$.

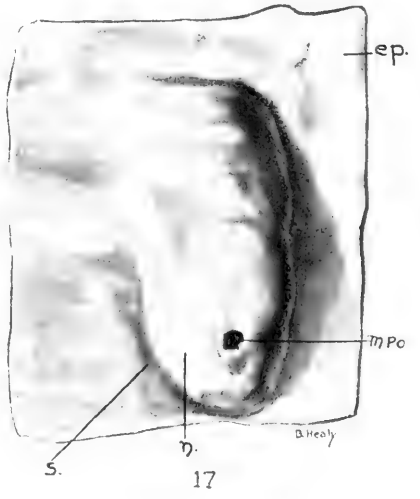
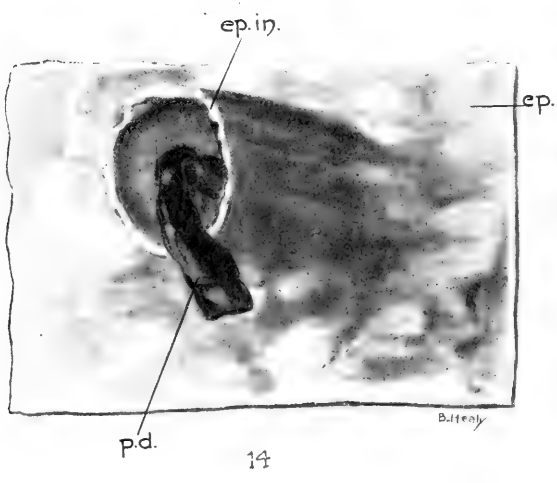

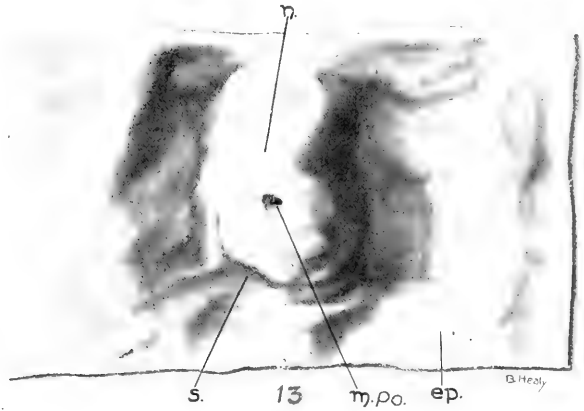
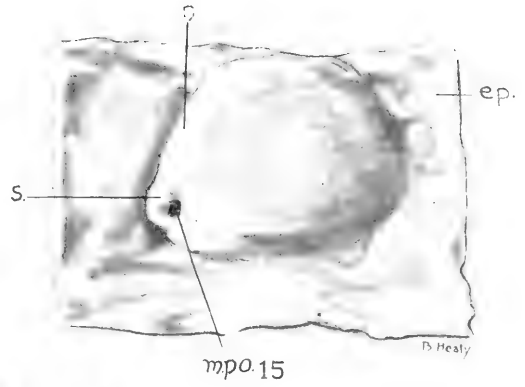
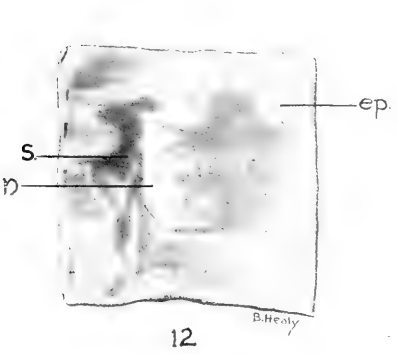
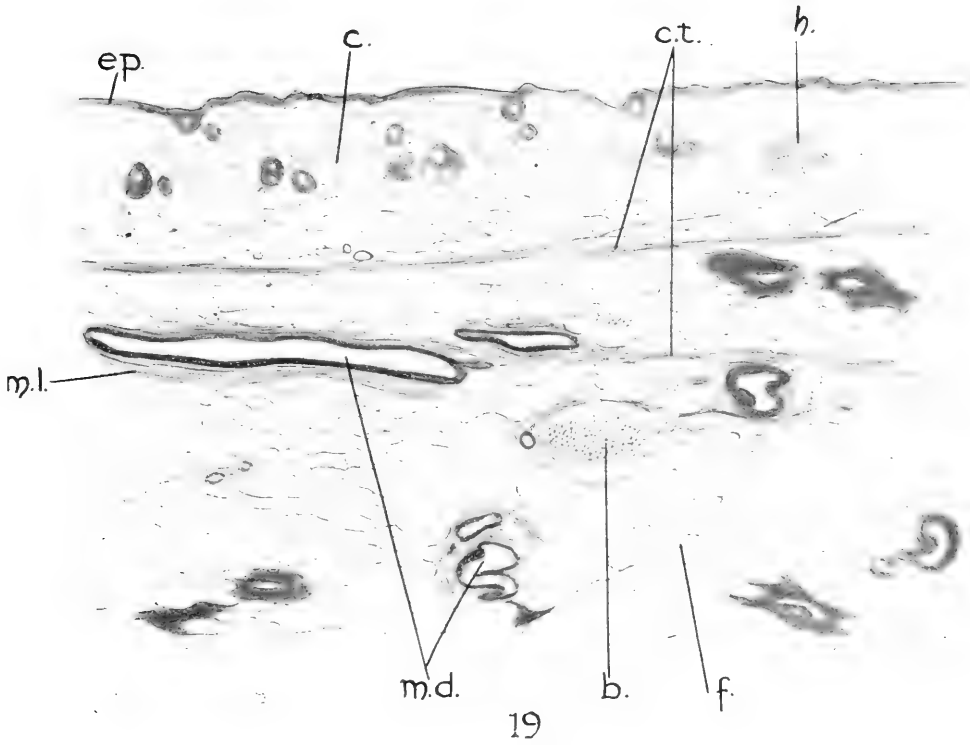
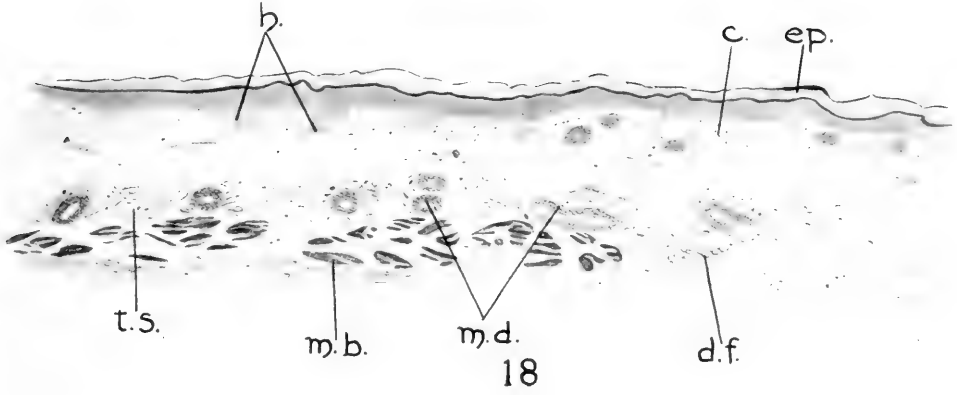


PLATE 2

EXPLANATION OF FIGURES

18 Drawn from a section through the right first inguinal gland of a female albino rat at birth. Zenker's fixation; Mallory's connective-tissue stain. *c.*, corium; *d.f.*, developing fat cells; *ep.*, epidermis; *h.*, hair follicles; *m.b.*, muscle bundle; *m.d.*, milk-ducts; *t.s.*, tela subcutanea. $\times 83\frac{1}{3}$.

19 Drawn from a section through the right first inguinal gland of a female albino rat of nine weeks. Zenker's fixation; Mallory's connective-tissue stain. *b.*, blood vessel; *c.*, corium; *c.t.*, connective-tissue lamina; *ep.*, epidermis; *f.*, fat cells; *h.*, hair follicles; *m.l.*, mantle layer; *m.d.*, milk-ducts. $\times 83\frac{1}{3}$.



Resumen por el autor, Harvey Ernest Jordan.

Histología de la sangre y médula ósea roja en la rana leopardo,
Rana pipiens.

El autor susministra pruebas de que el homólogo del megalocariocito de los mamíferos no es la célula fusiforme de los anfibios sino una célula gigante mononucleada que se deriva, como el megalocariocito de los mamíferos, de un hemoblasto. Todos los tipos de leucocitos, incluso las células gigantes, pueden formar pseudópodos, los cuales pueden segmentarse para formar cuerpos semejantes a plaquetas, granulares o hialinos. Los que tienen gránulos metacromáticos son idénticos a las plaquetas de los mamíferos. Tales corpúsculos se producen también por un proceso de fragmentación del protoplasma de un leucocito o un trombocito. La formación de plaquetas es, aparentemente, una producción secundaria de la actividad normal de los leucocitos, la cual se expresa en la formación y segmentación de pseudópodos y la degeneración de estas células. La hematopoesis tiene lugar según el modo monofilético. Los leucocitos neutrófilos de núcleo polimorfo contienen un sistema astral bien patente, cuyo centrosoma adopta diversas formas y puede ser sencillo, doble o múltiple; pero estas células no se dividen por mitosis en su condición de nucleares polimorfas. El autor discute la importancia de estos hechos sobre la significación de la amitosis.

Translation by José F. Nonidez
Columbia University

THE HISTOLOGY OF THE BLOOD AND THE RED BONE-MARROW OF THE LEOPARD FROG, RANA PIPIENS

H. E. JORDAN

Laboratory of Histology and Embryology, University of Virginia

TWO PLATES (SEVENTY-THREE FIGURES)

CONTENTS

Introduction.....	437
Material and methods.....	438
Description.....	439
a. The histology of the circulating blood.....	439
1. The erythrocytes.....	439
2. The lymphocytes.....	439
3. The eosinophilic leucocytes.....	441
4. The basophilic leucocytes.....	442
5. The neutrophilic leucocytes.....	442
6. The thrombocytes.....	443
b. The histology of the red bone-marrow.....	445
1. The development of the erythrocytes.....	446
2. The development of the lymphocytes.....	447
3. The development of the eosinophilic leucocytes.....	448
4. The development of the basophilic leucocytes.....	449
5. The development of the neutrophilic leucocytes.....	450
6. The development of the thrombocytes.....	451
7. The development of the plasma-cells and giant-cells.....	451
Discussion and Conclusions.....	452
Summary.....	471

INTRODUCTION

This investigation was begun with the study of the bone-marrow. Special interest in this tissue was first aroused through a previous investigation¹² of the giant-cells of the red bone-marrow of certain mammals. The primary object of this work concerns the identification of the amphibian homologue of the hemogenic giant-cell of mammals, the so-called megakaryocyte.

Since the latter cell, under certain conditions, becomes the source of the blood-platelets, interest centers also on the amphibian homologue of the mammalian platelet.

It became apparent early in this investigation that a confident interpretation of the developmental stages of the hemal elements of the marrow demanded a precise knowledge of the types of cells of the circulating blood. Accordingly, blood and marrow were studied coincidentally and with the same techniques. As regards the blood, the cells of special importance in this connection are the polymorphonuclear neutrophilic leucocytes and the spindle cells, both containing similar metachromatic (azurophil) cytoplasmic granules.

In the red marrow the origin and development of these same elements claim first attention. Incidentally must be considered also the developmental history of the eosinophilic and basophilic leucocytes, the origin of the lymphocytes and of the erythrocytes, the genetic relationships among the several series of blood-cells and the bearing of these data on the prevalent monophyletic theory of blood-cell origin.

MATERIAL AND METHODS

The species of frog used in this work is *Rana pipiens*. Smear preparations of blood were stained according to Wright's technic. The frogs employed had been left over from the early fall, kept in cages until the middle of January. Blood smears were made in October, in January, and in April. The bone-marrow was taken from the femurs of frogs killed in January, in a certain number of which the shaft was well filled with red marrow. The marrow was fixed in a mixture of 100 parts of a saturated normal-salt solution of corrosive sublimate and 10 parts of formalin. Paraffin sections were cut at 5μ and stained according to Wright's²⁶ technic. This technic gave very excellent results.

DESCRIPTION

a. The histology of the circulating blood

Though the study was begun in the reverse order, it seems preferable to pass from a description of the blood to that of the marrow. The cellular elements include the following types which will be described in the order enumerated: erythrocytes, lymphocytes, eosinophilic leucocytes, basophilic leucocytes, neutrophilic leucocytes, and thrombocytes.

1. *The erythrocytes.* The typical elliposidal, centrally nucleated, discoid erythrocytes of amphibia are well known and need no special description for this species of frog. However, certain atypical forms, comparable to those previously specified for certain turtle bloods, should again be noted, namely, larger, smaller, and senile types and their transition forms. The largest type, comprising a relatively small number of cells, is approximately one and a quarter times the average size; the smallest type, likewise including only a few cells, may be less than half the average size; these are generally stoutly oval with a spheroidal nucleus situated nearer one pole; the senile type (fig. 3) is relatively abundant in the frogs kept under laboratory conditions over winter; this cell has a large, spheroidal, lilac-colored nucleus and an expansive shell of very faintly-staining cytoplasm. The typical erythrocyte (figs. 1 and 2) has a much smaller oval nucleus which stains deeply blue, and a greenish-yellow cytoplasm. Account must of course be taken of the fact that in smear preparations the cells are spread out under varying pressures and tensions which operate to produce definitive size variations; nevertheless, the above-enumerated atypical forms occur in some degree. This classification agrees in general with that of Werzberg²⁵ except that he makes no mention of the senile forms.

2. *The lymphocytes.* Under this head may be listed a relatively large group of mononuclear leucocytes, varying greatly in size, but with the same nuclear and cytoplasmic characteristics. The smallest are but slightly larger than the nucleus of a thrombocyte, with a scarcely perceptible shell of basophilic cytoplasm (fig. 4); the largest (fig. 9) have a diameter approximately twice

that of the smallest, with a larger nucleus and a more expansive shell of cytoplasm. All the various sizes of lymphocytes have a common type of nucleus, which stains deeply as a whole, due to a coarse close-meshed reticulum with many net-knots. It assumes a deep lilac color. Grouped according to size, the lymphocytes may be classified as large and small, but abundant transition forms occur (figs. 6 to 10). Their resemblance to mammalian lymphocytes is striking.

The most characteristic features of these lymphocytes are their apparently granular cytoplasmic content and their numerous pseudopods (figs. 5 and 7). Various distortions, nuclear as well as cytoplasmic, demonstrate that these cells are extraordinarily delicate. The cytoplasm is extremely viscid. Some of the 'pseudopods' are most probably artifacts. But that at least many should not be so interpreted is sufficiently indicated by the fact that these same cells, or their ancestors, in the sections of bone-marrow likewise are covered with abundant pseudopods. For the same reason certain isolated portions of such pseudopods (fig. 7) must be regarded as actual constrictions or segmentation products.

In the bone-marrow the lymphocytes have a homogeneous basophilic cytoplasm (figs. 34 to 40); in the blood smears they appear to have a coarsely granular basophilic cytoplasm; the 'granules' are very irregular in form and size and frequently appear massed into clumps (fig. 9). It seems possible that the granules in question are in fact fixation artifacts, that is, proteid coagula of the basophilic cytoplasm. However, certain of the lymphocytes in the blood contain also metachromatic granules scattered throughout the basophilic substratum. These would seem to correspond with the 'leucocytoid lymphocytes' of Werzberg,²⁵ which this author regards as a distinct class. The evidence seems to indicate that the potentiality to form metachromatic granules is a common property of the lymphocytes. There is no good reason, in my opinion, for classifying lymphocytes on the basis of the presence of 'azuophil' granules. 'Lymphocytes' comprise a group of cells characterized by common nuclear and fundamental cytoplasmic (basophilic) characteristics; they vary

greatly with respect of size, and the presence or abundance of metachromatic granules. Moreover, certain of the pseudopods, especially isolated portions, contain masses of this basophilic and metachromatic granulation. Such bodies resemble very closely the blood-platelets of mammals.

There is abundant evidence, which will be detailed below, to show that the various blood-cells undergo further growth and development in passing from the blood spaces of the marrow to the general circulation; in view of which it may be inferred that the non-granular lymphocytes of the marrow elaborate metachromatic granules after entering the blood stream.

The nucleus of the lymphocyte likewise suffers a considerable change during the passage of the cell from the marrow to the circulation. The nucleus of the medullary lymphocyte is vesicular; it contains a distinct plasmosome, several deeply chromatic karyosomes, many smaller chromatic granules ranged mainly along the nuclear membrane, and a very delicate chromatic reticulum (figs. 35 and 37). In general appearance it is much clearer and lighter staining than the nucleus of the circulatory lymphocyte.

The attraction sphere of the lymphocytes is usually masked by the basophilic granulation. Occasionally it appears very conspicuously as a spheroidal clear area containing a centrosome or diposome (fig. 10).

While the evidence at hand does not permit of a final conclusion regarding the genetic relationship between lymphocyte and platelet, the striking resemblance of the lymphocyte pseudopods and their constriction products to mammalian blood-platelets is unmistakable.

3. *The eosinophilic leucocytes.* This type of cell will be fully discussed below in connection with the description of its myelocyte ancestors. It will suffice here to state that in its adult condition it contains a polymorph or, in rare instances, a multiple nucleus, generally located at one pole of the spheroidal cell. Occasionally a mononucleated form may occur. Figure 11 shows a binucleated form. The spheroidal eosinophilic granules are of approximately uniform size. They appear hollow, or annular,

due probably to difference in density between center and periphery. The granules are imbedded in a lightly basophilic substratum. Eosinophils constitute only a very small proportion of the leucocytic content of the frog's blood. In the winter specimens the eosinophils are rarer than the basophils; in the fall specimens they are relatively more numerous.

4. *The basophilic leucocytes.* This type of cell is somewhat smaller than the eosinophil. It is approximately the size of the medium-sized lymphocyte (fig. 12). Its nucleus is centrally located and vesicular. The nucleus contains a very delicate reticulum. The cytoplasm is closely packed with spherical basophilic, lilac-colored granules, larger on the average than the eosinophilic granules, but varying somewhat in size and shape, certain granules having an oval form. In the marrow these cells have a deeply staining nucleus (figs. 51 to 53) and the cytoplasmic granules take a deep blue color with Wright's stain.

5. *The neutrophilic leucocytes.* This is by far the most abundant type of leucocyte (figs. 13 to 26). Its nucleus is generally polymorphous. Mono- and binucleated forms also occur. The cytoplasm consists of a homogeneous basophilic (blue-staining) substratum, throughout which are scattered fine metachromatic (neutrophilic) granules. The granules are always very small, but vary in size from a scarcely perceptible dust to very definite spheroidal granules of light lilac color. The resemblance to the polymorphonuclear neutrophilic leucocytes of mammals (compare figs. 22 and 23) is striking. In areas where the neutrophilic granules are sparse, the basophilic (blue) substratum also appears granular.

The most conspicuous feature of these cells, aside from their characteristic polymorphous nucleus, is the attraction sphere. This is generally situated within the concavity of the lobulated nucleus (figs. 13, 16, 18, and 19). The neutrophilic granules are arranged in lines radiating from the sphere (fig. 17). The attraction sphere may consist of a spherical mass of minute granules imbedded in a denser protoplasm (figs. 16, 21, 23, and 25) or it may occur as a clear area (centrosphere) containing centrally a deep-staining granule or centrosome (centriole) (figs. 13, 17, 18,

and 19). The latter may be simple, bilobed, or double (diplosome). These cells were never seen in mitosis in the circulating blood. The persistence of such a definite and conspicuous attraction sphere in a cell whose nucleus undergoes successive constrictions in the formation of a polylobular condition (figs. 13 to 21) is of much theoretical interest, a point which will be discussed below in connection with its myelocytic history.

The relationship between the two types of attraction spheres is not perfectly clear. However, they correspond closely with similar types occurring in other cells, e.g., maturing eggs of *Cummingia*,⁹ where the clear sphere with its central granule (centrosome) of earlier stages becomes converted into a granular darker sphere through division of the centrosome. In these leucocytes of the frog the monosome and diplosome occur more commonly in those cells with the less complex nucleus, the finely granular spheres in those with the more complex polymorphous nucleus (compare figs. 13 and 19 with fig. 25). Though figures 16 and 24 show that this relationship is not invariable, it may be said that no cells with nuclei like that of figure 13 were seen with the granular type of sphere. The inference seems justified that here also the granular type of sphere arises from the clear type with diplosome, by repeated division of the centrosome. The granular type would thus represent a disintegration or partition product. The bearing of this conclusion will be discussed in connection with the description of these same features of the medullary neutrophilic leucocytes, where also these same two types of attraction spheres occur.

6. *The thrombocytes.* These cells typically are stout fusiform elements with central, deeply staining (violet), dense, oval nucleus (figs. 28 and 30). The cytoplasm stains only very faintly (pink) and contains metachromatic spherical granules of uniform size. These granules appear identical with the larger granules of the neutrophilic leucocytes. The granules are generally aggregated more or less closely into small groups. The cytoplasm is apparently extremely viscid and is drawn out at numerous points into pseudopod-like projections (figs. 27 and 31). These contain the majority of the granules. Certain of

these pseudopods appear to constrict off spheroidal granular fragments, resembling blood-platelets of mammals (figs. 30 and 31.) The extreme viscosity of the thrombocyte cytoplasm would seem to account fully for the fact that these cells generally occur in larger and smaller closely adherent groups. One line of evidence casts doubt upon the interpretation of the projections of the thrombocytes as pseudopods and the isolated bodies as segmentation products: The cytoplasm is unmistakably very delicate and very viscid; in contrast with all of the leucocytes of the marrow, the spindle cells of the marrow do not show pseudopods. This would seem to indicate that the 'pseudopods' of the thrombocytes are artifacts, formed through the operation of mechanical factors in the process of making the smears. On the other hand, numerous naked and disintegrating nuclei of thrombocytes occur in the blood (fig. 32); these recall the naked nuclei of the megakaryocytes of mammalian marrows, and in a measure support Wright's suggestion that the megakaryocytes of mammals and the spindle cells of amphibia are homologous elements.

The resemblance between the granular cytoplasm of the megakaryocytes of mammals and that of the thrombocytes of amphibia is very close; but it appears no more close than between this cytoplasm and that of the neutrophilic leucocytes. Moreover, the constriction products of the pseudopods of thrombocytes, neutrophilic leucocytes and certain lymphocytes of the frog, and those of the pseudopods of the megakaryocytes of rabbit and guinea-pig are very similar. These corpuscles consist in common of a spheroidal viscid mass of faintly basophilic cytoplasm containing a central group of fine metachromatic spherical granules. The question of homology will be further discussed below.

At this place must be noted the character of the nucleus. In the smear preparations this appears dense and chromatic (deep lilac) with numerous irregular vacuoles. In the marrow this nucleus is more oval, it contains a chromatic reticulum with numerous karyosomes, it stains much less deeply and it takes a blue color (figs. 42 and 43). Moreover, it shows several deep,

approximately longitudinal grooves; certain of these are so deep as to appear to completely divide the nucleus. Similar conditions were previously reported also in blood smears of certain turtles.¹¹ Downey⁶ questions the accuracy of this interpretation and inclines to regard all these phenomena as simply deep furrows. One could hardly base final conclusions regarding this point on smear preparations; the process of spreading the blood on the slide might very readily divide the already deeply constricted (grooved) nucleus. But similar appearances occur also in the marrow sections. However, here it could always be argued that in such cases the plane of section passed above the bottom of the groove, thus giving the deceptive appearance of a division of the nucleus. Against the interpretation that certain of the thrombocyte nuclei are actually split must be cited the fact that these cells in the circulating blood of the frog contain generally a more compact, more nearly spherical and ungrooved nucleus (figs. 27 to 32). If a certain groove of the nucleus of the immature thrombocyte of the marrow is conceived to lead to a direct division of the nucleus, then certain mature thrombocytes should be binucleated, which is apparently never actually the case in the frog. On the contrary, the mature nucleus seems to have lost the grooves of its immature condition, apparently through a process of dilatation of the nuclear vesicle, involving a change from oval to spherical form and an obliteration of the grooves by reason of a filling up of the nucleus.

b. The histology of the red bone-marrow

This description is based almost exclusively on the bone-marrow of the shaft of the femurs of an adult specimen killed the middle of January. This particular specimen had an especially abundant red marrow in its femurs. Practically the entire shaft was packed with red marrow. Other specimens examined at the same time and during the following month, as also specimens from a new shipment in April, showed only small patches of red marrow in the shaft of the femur. Sections were made of this essentially yellow marrow and also stained according to Wright's²⁶

technic. This tissue proved helpful for comparisons in the course of this study, but the hemopoietic sequences were worked out on the one specimen with the abundant red marrow. In the frog the process of blood-corpusele formation is said to occur only in the early summer, at which time only the bones contain red marrow (Starling).²³ The specimen under consideration had presumably simply anticipated his fellows in this process of converting the yellow into red marrow.

The reticular stroma of the red marrow is packed centrally with fat cells, blood-vessels, and hemogenic vascular spaces (angiocysts), and covered peripherally by a layer of differentiating leucocytes. Erythrocytes are seen only centrally within the vascular spaces.

The development of fat cells from the mesenchymal stroma can be traced through a complete series of stages. The process, however, presents nothing new except that a certain number of practically adult fat cells contain two nuclei. Endothelium, erythrocytes, lymphocytes, and leucocytes can likewise be traced through a complete series of developmental stages back to the marrow mesenchyma. Hemopoiesis is an essentially similar process, involving the formation of 'blood-islands,' in yolk-sac and red marrow. The spindle cells arise only intravascularly as differentiation products from small lymphocytes and from endothelium. Endothelium may also produce hemoblasts secondarily.

It seems preferable to describe the developmental history of the blood-cells in the marrow in the following order: erythrocytes, lymphocytes, eosinophilic leucocytes, basophilic leucocytes, neutrophilic leucocytes, and thrombocytes.

1. *The development of the erythrocytes.* This history can be read in the smaller blood spaces of the central portions of the red marrow. The larger spaces and blood-vessels contain only more mature erythrocytes, mingled with the granular leucocytes of extravascular origin. The erythrocytogenic process passes from a stage of solid strands of hemoblasts (marrow 'blood-islands') to one of forming vessels in which the central cells are free mature erythrocytes and the peripheral cells represent

various stages of the differentiation from original hemoblasts. A certain number of the latter are in intimate connection with the superficially differentiating endothelium. Endothelial cells and blood-cells have differentiated from the same primitive cell mass, and subsequently for a time young endothelium may give origin to hemoblasts, including thromboblats.

The original progenitor of the erythrocyte is a cell with a relatively large vesicular nucleus and a narrow shell of slightly basophilic cytoplasm. The nucleus is granular in character (figs. 37 and 38). At first irregular in shape, i.e., polyhedral or even fusiform, the hemoblast soon assumes a spheroidal form. These cells proliferate mitotically. In becoming an erythrocyte the hemoblast (erythroblast) again changes into a stoutly oval form (fig. 41), the cytoplasm becomes oxyphilic as it elaborates hemoglobin, and the nucleus becomes more compact and more chromatic.

The great difference in size between the red cells of the marrow and those of the circulating blood is surprising (compare figs. 1 and 41). Those of the smear preparations are approximately twice the size of those in the sections of the marrow. A certain large amount of this difference may be accounted for on the basis of a spreading out in the process of making the smear, but the residue can only be explained in terms of continued growth after leaving the marrow. The same phenomenon of postmedullary growth is evident in some degree in the case of all of the other types of blood-cells except the basophilic leucocytes (compare figs. 12 and 52).

2. *The development of the lymphocytes.* As in the circulating blood, so in the marrow two main types of lymphocytes can be distinguished, differing in no essential nuclear or cytoplasmic features, but only in size (figs. 34 to 41). Transition forms occur abundantly. These intravascular lymphocytes are structurally indistinguishable from similar extravascular cells from which the granulocytes develop (compare figs. 38 and 41). Furthermore, the smaller varieties correspond with the hemoblasts from which erythrocytes, and in part thrombocytes, develop intravascularly. Intravascularly, the original hemoblast is more

generally of the smaller lymphocyte type with granular vesicular, nucleus; this may grow into the larger type. Extravascularly, the original hemoblast is more generally of the large lymphocyte type (figs. 34 and 35); this may divide mitotically to form small lymphocytes. These marrow types correspond with the large and small lymphocytes of the blood smears, except that in the latter the originally basophilic homogeneous cytoplasm of the marrow cells becomes granular and may in addition elaborate metachromatic granules. Similarly, the small lymphocytes form metachromatic granules in becoming thrombocytes within the blood spaces of the red marrow.

3. *The development of the eosinophilic leucocytes.* The eosinophilic myelocytes arise in the extravascular connective tissue. Their progenitor is indistinguishable from the large and medium-sized medullary lymphocytes. The mature eosinophils secondarily enter the vascular spaces, and continue their development during their passage into the peripheral circulation (compare fig. 49 with fig. 11). The first indication of the beginning of differentiation of a 'lymphocyte' into an eosinophilic myelocyte is the appearance of a few, very minute, purplish-red granules (figs. 36 and 44). The first granules are most commonly aggregated in a certain restricted region, generally in the vicinity of the centrosome, and only gradually appear in all portions of the cytoplasm. They increase gradually in number and in size, always maintain a fairly uniform size for any particular stage (figs. 45 and 46), and during their later phases resemble those of the circulating eosinophils in that their centers are less dense, giving them the appearance of rings (figs. 47 to 50). The granules apparently grow by a process of swelling involving, beside increase of diameter of the granules, a rarefaction especially of the core, and a slight general decrease in staining capacity.

The original eosinophilic granule has a purplish-red color, the definitive form a slightly orange-red color. This material gives no indication of the primitive basophilic granules described by Downey⁸ for the eosinophilic myelocytes of the guinea-pig. Nor does either the developing or the definitive eosinophilic leucocyte contain intranuclear eosinophilic granules, as claimed

by Niegolewski¹⁹ for *Rana esculenta*. We are in like disagreement with Niegolewski regarding the basophilic granules of the mast-cells. Nor is there any evidence that the original eosinophilic granules of the myelocytes have a nuclear origin, nor any that they have an extracellular origin, as claimed by certain investigators, e.g., Weidenreich.²⁴ The eosinophilic granules arise gradually within the cytoplasmic area, apparently as a result of some specific activity of this protoplasm.

Coincident with the above-described changes in the granules, the nucleus also passes through a series of structural and slight tinctorial alterations. At first the nucleus is approximately spherical, centrally located, contains a distinct plasmosome, and is vesicular in character (figs. 44 to 48). It gradually moves excentrically, meanwhile showing a coarser network and more numerous karyosomes, and a modification in shape leading through a reniform to a polylobular, and eventually, in some cases a multiple, character. Only the younger forms with spherical or stoutly reniform nucleus are seen in mitotic division. In common with all myelocytes, including the lymphocytes, these cells also form pseudopods which may constrict and fragment to form free 'hyaline bodies' (fig. 36) or, very rarely, globules with eosinophilic granules. Pseudopod formation and segmentation seem to be a common property of leucocytes, both circulatory and medullary.

4. *The development of the basophilic leucocytes.* The basophilic leucocytes or mast-cells likewise take origin from the common lymphocyte progenitor, of medium size, in the extravascular tissue (figs. 38, 39 and 51). The nucleus is characteristically deep-staining, apparently homogeneous except for a few, barely visible, large nucleoli (fig. 52). The granules are at first small, but always larger than the eosinophilic granules, and stain very deeply blue (fig. 53). The granules become coarser, meanwhile maintaining their deep coloration. These same cells in the blood smears have a lighter-staining, centrally located nucleus, and their basophilic granules show a violet or lilac tinge (fig. 12). The nucleus of this cell in the marrow, due to its deep-staining and apparently homogeneous character, suggests degeneration.

However, if this nucleus were properly interpreted thus, it could scarcely attain a more normal appearance in the circulating blood. It appears that these cells undergo a further differentiation in passing from marrow to the circulation. They are the rarest type of leucocyte, but are most probably to be interpreted as normal and specific blood elements, as maintained by Maximow.¹⁶ There is no evidence that the granules are nuclear extrusions, nor that they result from a mucoid degeneration of the cytoplasm. As in the case of the eosinophilic granules, they appear to represent the result of some metabolic activity of the cytoplasm.

5. *The development of the neutrophilic leucocytes.* These cells are in certain respects the most interesting among the blood elements of the frog. It is only in the light of their origin in the marrow that their true significance can be determined. Such study shows that they correspond much more closely to the polymorph neutrophils of mammals than to the leucocytes with special eosinophilic granules of sauropsida, rabbit, and guinea-pig. They are in fact the amphibian homologues of the neutrophilic leucocytes of certain mammals (compare figs. 21 and 22).

These cells also originate from the common lymphocyte ancestor (figs. 34, 35, and 54). The first indication of their differentiation is the appearance of an oxyphilic halo about the centrosome in the otherwise basophilic cytoplasm. This halo becomes finely granular and spreads in radiating fashion toward the periphery of the cell (fig. 54). This disposition of the neutrophilic granules in radii is maintained in the definitive forms (figs. 17 to 26). The granules vary somewhat in size and in the degree of their lilac coloration, but are always smaller than the eosinophilic granules. The basophilic substratum remains visible, and is variably conspicuous in different regions. Coincident with the differentiation of the metachromatic granules, the nucleus undergoes great morphologic changes, passing ultimately into a polylobular (figs. 69 and 70), and occasionally a polynuclear, condition (figs. 66 to 68). Only the earliest types, in which the nucleus is still spheroidal or reniform (fig. 54), divide by mitosis. The same statement can be made for the

eosinophils; basophils were not seen in division. A conspicuous and significant feature of these cells is the abundance and length of their granular pseudopods, certain of which may be seen segmenting or fragmenting into faintly basophilic globules with granular centers, simulating thus very closely the blood-platelets of mammals in their structure and in their origin from megakaryocytes (figs. 62 and 68). However, no naked nuclei could be found. The cells form common lyin the extra vascular tissue (fig. 69), but a few may possibly arise also from hemoblasts within the developing blood spaces of the marrow (fig. 41).

6. *The development of the thrombocytes.* These cells only arise intravascularly, from small lymphocytes, and in small part directly from endothelium. As they take on their definitive oval or fusiform shape they develop metachromatic granules. In their passage into the circulation they undergo further nuclear and slight dimensional changes as described above. They are never seen to arise extravascularly, nor do they undergo division; and the nucleus never assumes the crescentic lobulated condition characteristic of certain leucocytes. In the marrow they occur singly, in the blood smears generally in groups. The blood smears show thrombocytes with pseudopods, certain of which apparently constrict to produce platelets, as first described by Wright²⁶ for *Amblystoma*, leaving eventually disintegrating naked nuclei (figs. 31 and 32).

7. *The development of the plasma-cells and giant-cells.* Certain large lymphocytes undergo a type of differentiation leading to typical plasma-cells. These plasma-cells are characterized by the coarse chromatic reticulum of their deep-staining nucleus, their irregular shape, and their very faintly basophilic, extensively vacuolated cytoplasm (fig. 71). This observation agrees with Downey's⁵ conclusion regarding the chief source of origin of the plasma-cells from lymphoid cells in the mesentery of *Rana*.

A small number of lymphocytes undergo also a hypertrophy leading to mononuclear giant-cells. These cells contain a relatively enormous nucleus very like that of the younger lymphocytes, and a variable shell of basophilic cytoplasm containing many fine metachromatic (lilac) granules (figs. 72 and 73). Con-

stricting pseudopods of such cells produce bodies comparable with the blood-platelets of megakaryocyte origin in mammalian marrows.

DISCUSSION AND CONCLUSIONS

This search for the amphibian homologue of the mammalian giant-cell from which the blood-platelets take origin has revealed two types of cells which in a measure fulfill requirements, namely, the polymorphonucleated neutrophilic leucocytes and the thrombocytes. That the so-called megakaryocytes of red bone-marrow of mammals (e.g., of rabbit and guinea-pig) do actually at certain stages liberate blood-platelets can be abundantly demonstrated by the Wright²⁶ technic. These mammalian cells are commonly polymorphonucleated, occasionally polynucleated. Their faintly basophilic cytoplasm contains an abundance of fairly uniform metachromatic granules. These cells are not phagocytic, their occasional content of a leucocyte or two, generally eosinophilic, is probably to be interpreted as an invasion following early stages of degeneration. Under certain conditions these cells are erythrocytopoietic. The mammalian megakaryocyte also traces its origin to the common lymphocyte (hemoblast) ancestor of the blood-cells, both in the yolk-sac and in the red marrow. In both locations the nuclear characteristics are very similar, and the apparently identical granular cytoplasm produces comparable blood-platelets in an identical manner (Jordan).¹³ Moreover, in the yolk-sac the smaller, usually binucleated, type of these giant-cells may differentiate into erythrocytes (Jordan).¹²

Wright²⁶ has suggested that the thrombocytes of *Amblystoma* represent the megakaryocytes of mammalian red marrow. But the thrombocyte resembles the megakaryocyte only in respect of its metachromatic granules scattered throughout a lightly basophilic cytoplasm, and its elimination within the blood of granulated globules similar to platelets, leaving eventually a naked nucleus. Within the bone-marrow it apparently does not liberate 'platelets,' in which respect it contrasts sharply with the mammalian giant-cells. Moreover, these cells differ greatly in regard to nuclear characteristics. The thrombocytes resemble

platelets in respect of a very adhesive protoplasm, in consequence of which they frequently become grouped into larger and smaller masses. But this property of adhesiveness is characteristic also especially of the lymphocytes, certain of which also have a variable amount of metachromatic granules.

The polymorphonucleated neutrophilic leucocytes of the frog seem at first to bear a much closer resemblance to mammalian megakaryocytes. They are of course smaller than the megakaryocytes. While not of the extreme 'basket' form, the nucleus is frequently extensively lobulated. The centrosome is always conspicuous and frequently multiple, as described by Heidenhain for megakaryocytes. These cells contain, moreover, a very similar metachromatic granulation, which is likewise scattered through a basophilic substratum, the latter forming an exoplasmic layer of variable width. The granules of the amphibian neutrophilic leucocytes stain less deeply than those of the mammalian megakaryocytes, but otherwise they are very similar. Moreover, these leucocytes protrude pseudopods, which fragment to form platelet-like bodies, like those of megakaryocytes (figs. 61 to 68). These pseudopods even project into blood-vessels, as do those of the megakaryocytes (fig. 63). The presence of these alleged giant-cell homologues in the amphibian blood, as compared with the restriction of the megakaryocytes of mammals to the bone-marrow, might be due simply to the fact of the great size of the latter prohibiting entrance into the capillary circulation. It would seem on the basis of the histologic evidence that the neutrophilic leucocyte of amphibia meets more nearly the requirements of a megakaryocyte homologue than does the thrombocyte.

However, the fact that no naked nuclei of these neutrophilic leucocytes occur, while such are numerous of thrombocyte origin, contravenes in a measure the assumption of homology between the polymorphonuclear neutrophilic leucocytes of the frog and the megakaryocytes of the marrow of the rabbit. In addition to this objection, there is the further contradiction that certain mammals have a red marrow containing both typical megakaryocytes and typical polymorphonuclear neutrophilic leucocytes (e.g., cat, dog).

On the other hand, the common property of pseudopod formation and constriction possessed by all the types of leucocytes within the marrow casts doubt upon the specific nature of the process as restricted to megakaryocytes of mammalian marrow. In the frog marrow, primitive lymphocytes, eosinophilic leucocytes and hemoblasts produce 'hyaline' bodies by this method of pseudopod 'segmentation.' The neutrophils produce granulated bodies, resembling platelets. Basophilic leucocytes, and to some extent eosinophiles, likewise produce granulated globules. The evidence seems to indicate that this property is common to both lymphocytes and granulocytes, and that platelet-like bodies are formed only incidentally. A thorough study of the giant-cells of rabbit and guinea-pig also leads to the conclusion that these cells produce platelets to some extent by a constriction of pseudopods, but chiefly by a process of fragmentation of large cytoplasmic areas of degenerating giant cells. The degeneration is indicated chiefly by the irregular and pyknotic character of the nucleus. Similarly, in the case of thrombocytes and leucocytes with metachromatic granules, degeneration involves a fragmentation of the cytoplasm and the incidental formation of platelet-like bodies.

In this connection must be considered the question whether the cells above described as polymorphonuclear neutrophils are actually such or only types of non-granular leucocytes, as maintained by Werzberg.²⁵ Werzberg's failure to interpret these cells as granulocytes must be ascribed to his disregard of the Wright or a similarly favorable technic. Studied with the Wright technic, the metachromatic granular content is conspicuous and indubitable. This conclusion agrees with the earlier one of Niegolewski¹⁹ and the later one of Downey.⁶

Downey⁶ made a special study of the polymorphonucleated leucocytes of the amphibian *Amblystoma*. He employed only smear preparations; these were stained with Wright's blood stain. He describes their granules as 'azurophil,' which he regards as close to the 'special' granules of the higher animals, i.e., the neutrophilic granules of the polymorphs of certain mammals. He agrees with Werzberg²⁵ that the lymphocytes of most

other amphibia, including the frog, lose their azurophil (i.e., neutrophilic, metachromatic) granules when they differentiate into polymorphonuclears, and maintains that the cytoplasm of the definitive polymorphs of these forms is oxyphilic. Neumann¹⁸ likewise denies the presence of granules in the polymorphonuclear leucocytes of the frog. However, my preparations of frog marrow very clearly show that the neutrophilic myelocytes retain and increase their 'azurophil' granules as they differentiate into the definitive forms of the circulating blood. Downey⁶ states further that all possible intermediate stages between larger lymphocytes (with neutrophilic granules) and neutrophilic polymorphs occur in the circulating blood of *Amblystoma*. This finding is at variance with that of Maximow¹⁴ in the case of *Axolotl*.

In view of the fact that the complete developmental history of the polymorphonucleated neutrophilic leucocytes from non-granular basophilic primitive lymphocytes can be traced in the sections of the red marrow, Downey's interpretation of transition forms between 'definitive' lymphocytes and neutrophilic granulocytes in the circulation of *Amblystoma* at first seems quite improbable. The nucleus of the circulatory lymphocytes is very different from that of the medullary lymphocytes (compare figs. 4 and 37), a change which indicates progressive differentiation. However, a careful study of the different types of circulatory lymphocytes in the frog forces the conclusion that these lymphocytes do actually metamorphose into the neutrophilic granulocytes, as urged by Downey⁶ for *Amblystoma*, but denied for the frog. Moreover, the nuclei of the medullary and circulatory neutrophils and of the circulatory lymphocytes are practically identical in their fundamental features. It would seem that a lymphocyte with an already considerably differentiated nucleus may develop neutrophilic granules abundantly and so pass over into a neutrophilic granulocyte whose nucleus may subsequently undergo lobulation. Such a developmental process is illustrated in figures 8, 13, 16, and 19.

Figure 8 is a typical lymphocyte with a reniform nucleus. The only perceptible cytoplasmic difference between it and a

lymphocyte like that illustrated in figure 6 pertains to the relative proportion of neutrophilic and basophilic granules. The designation 'basophilic granules' in connection with lymphocytes is always used here with the reservation that the 'granules' may be actually a coagulation phenomenon in an essentially homogeneous cytoplasm. Certain circulatory lymphocytes contain only a few neutrophilic granules; these types lead through transition forms to neutrophilic granulocytes which show many granules and interspersed small areas of only basophilic granular material. The conclusion seems inescapable that lymphocytes may, and continually do, differentiate into polymorphonucleated neutrophilic granulocytes within the circulation. This would seem to dispose of Werzberg's²⁵ classification of the lymphocytes of frog as nongranular large and small lymphocytes, 'leucocytoid lymphocytes with azurophil granulation,' and 'lympholeucocytes.' In the frog the lymphocytes differ in their cytoplasmic features only in respect of the relative abundance of neutrophilic (azurophil) granules. This conclusion has an important bearing upon the discussion regarding the validity of the monophyletic theory of hemopoiesis. The circulatory lymphocyte, the slightly modified persistent medullary lymphocyte which functions as the common progenitor (hemoblast) of all types of blood-cells, still maintains its capacity to differentiate at least into a neutrophilic granulocyte.

The question then arises whether the Amphibian neutrophils are actually the homologues of the mammalian megakaryocytes or of the mammalian polymorph neutrophils. If these cells are regarded as representing polymorph neutrophils of higher mammals, then amphibian blood, except for thrombocytes, would seem much closer to mammalian than to sauropsid bloods. This would conflict with the accepted phylogenetic seriation. However, neither neutrophilic leucocytes nor recognized hemogenic giant-cells occur in sauropsid marrows, while leucocytes with 'special' (eosinophilic, ellipsoidal) granules are abundant, facts which favor Downey's⁶ interpretation. The evidence seems to point to the homology of the amphibian and mammalian polymorph neutrophils. Whether both are the homologues of the

'special leucocytes' with minute or ellipsoidal eosinophilic granules characteristic of those forms which lack neutrophils, namely, certain mammals (e.g., rabbit, guinea-pig) and sauropsids, respectively, is a question of a different order, and one that need not here be further discussed.

Having thus disposed of both these alleged amphibian homologues of the mammalian megakaryocytes, we may analyze the possibilities of still another type of cell. This cell occurs only sparsely. It contains a relatively enormous nucleus, with one or several plasmosomes, numerous irregular karyosomes, and a delicately reticulated vesicular nucleoplasm (fig. 73). The nucleus is enveloped with a variable shell of lightly basophilic cytoplasm containing metachromatic, lilac-colored granules. It may be assumed that this cell forms pseudopods which may constrict and become free corpuscles. This amphibian giant-cell develops from a primitive lymphocyte and represents a hypertrophied hemoblast. In all these respects, then, it corresponds with the mononucleated giant-cells of the red marrow of the femur of the rabbit. It has been shown that the polymorphonucleated giant-cells, the so-called megakaryocytes, develop from mononucleated giant-cells through nuclear modifications (Jordan¹²). It seems that in the frog the marrow giant-cells develop only to the mononucleated stage. Possibly at certain periods this marrow also would show later polymorphonucleated phases. The usual statement that giant-cells are not found in the red marrow of forms below the mammals must therefore be revised. Careful study of the marrow of sauropsida may possibly also reveal giant-cell homologues of even closer correspondence.

Another important body of evidence supplied by this material concerns the monophyletic theory of blood-cell origin. Maximow¹⁵ has published a brief preliminary report on hemopoiesis in *Rana temporaria*, and interprets his evidence in accord with this theory. His material includes larvae and the adult bone-marrow. As regards the process in the latter, his statements are especially brief. However, the chief points are touched. My results agree completely with his earlier findings except in

one important respect. Maximow claims that in *Rana temporaria* lymphocytes arise only in the blood-vessels. He notes that this is a significant departure from what occurs in the case of selachians, birds, and mammals, where the lymphocytes form both extra and intravascularly, and he suggests that this difference may inhere in ontogenetic differences associated with holoblastic and meroblastic cleavage. My preparations of the marrow of *Rana pipiens* show, however, that in this species lymphocytes arise in both locations. If a difference actually exists in the case of *Rana temporaria* it must be a specific difference or a chance variation in Maximow's specimens and not one characteristic of amphibia as a group. Maximow¹⁵ further calls attention to the fact that in amphibia the lymphoid and myeloid tissues are not sharply separated topographically, there being here no sharply defined lymphoid organs with the specific function of lymphocyte production, like the lymph nodes of mammals, and another tissue with specific granulopoietic function. This mingling of lymphoid and myeloid tissues and functions in the bone-marrow gives additional support to the monophyletic theory.

The erythrocyte, lymphocyte, and leucocyte series in common, can be traced through gradual steps of development from a type of cell which is indistinguishable in the several series, namely, a lymphocyte-like cell, the 'hemoblast.' The determining differentiation factor seems to be exclusively environmental. 'Lymphocytes' that become enclosed by endothelium differentiate into erythrocytes, or in small part they may proliferate or persist as lymphocytes which undergo slight differentiation in passing into the blood stream, or some may differentiate into thrombocytes. Furthermore, the already slightly differentiated endothelium may to some extent during its younger stages further differentiate into erythroblasts and into thromboblats. Consideration of the common origin of the endothelium and the hemoblasts, from the original medullary 'blood-islands,' makes such differentiation intelligible. Neutrophilic leucocytes may also to some extent differentiate from intravascular hemoblasts and from circulatory lymphocytes. But extravascular condi-

tions seem more favorable for the neutrophilic differentiation in the case of the majority of the lymphocytes. Eosinophilic and basophilic granulocytes, apparently differentiate only extravascularly. These enter the blood-channels secondarily through ameboid activity.

Danchakoff³ calls attention to an apparent contradiction in the argument of the supporters of the monophyletic theory of blood-cell origin: they note that morphologically identical mesenchymal cells and hemoblasts in the same limited regions develop into both erythrocytes and granulocytes, and infer from this fact the equipotentiality of these blood-cell ancestors. Danchakoff argues that if these 'stem-cells' develop into different products in the same region, then they must have had dissimilar potentialities and were in fact originally distinct, as claimed by the adherents of the polyphyletic theory. But this argument must postulate an identity of the environmental factors playing upon the hemoblasts in these restricted areas; this involves an assumption which cannot be supported by tangible data. It is not at all inconceivable that two adjacent, identically endowed, cells are nevertheless under environments sufficiently dissimilar to determine erythropoiesis in one case and granulopoiesis in the other case. It is no doubt generally true, as abundant recorded observations show, that hemoblasts enclosed by endothelium develop into erythrocytes, while extravascular hemoblasts differentiate into granulocytes. But Danchakoff⁴ herself observed in regions in the allantois of the chick embryo upon which had been grafted particles of adult spleen, that extravascular hemoblasts could develop into erythrocytes. She, however, interprets her sections to mean that the extravascular hemoblasts in these instances had received an erythropoietic bias while previously confined by endothelium, which could not be reversed under the influence of the new environment, or that the extravascular spaces containing these displaced hemoblasts are actually in continuity with the original lumen of the blood-vessel through breaks in the endothelial wall. However, there are other instances in which such explanations will not suffice. For example, in the area vasculosa of the

young turtle embryo I have seen an eosinophilic granulocyte within an early blood-island, otherwise differentiating largely into erythrocytes. Until it can be actually demonstrated that the environment is identical in such instances, these facts do not contradict, but sustain the monophyletic view.

Unless we assume an identity of developmental potencies in the case of the hemoblastic mesenchymal cells, one is forced to the position that the mesenchymal ancestors of fat cells, pigment cells, endothelium and smooth muscle cells also differ in respect of specific developmental potencies. But such unqualified position must ignore a large group of histogenetic data. Mesenchyme cells are apparently of identical nature and endowed with multiple potencies, that is, 'equipotential' and 'polyvalent.' The expression of any one type of mesenchymal differentiation—whether as endothelium, erythrocytes, granulocytes, or fat—seems accordingly dependent upon extrinsic factors of a type or degree not yet detectable or measurable by our means of investigation. Indeed, Danchakoff describes endothelial cells of the spleen graft separating from the wall of small blood-vessels both centrally, where they pass into the lumen as hemoblasts and differentiate into erythrocytes, and peripherally where they become reincorporated with the mesenchyma and may redifferentiate into granuloblasts. I have observed comparable phenomena in the bone marrow and the body mesenchyma of the turtle embryo. These observations show that the same cell, an endothelial hemoblast, may become either an erythrocyte or a granulocyte according as the environmental stimuli change ever so slightly. They furnish, moreover, the very strongest support to the monophyletic theory. But they show also that adjacent identically differentiated cells, namely, young endothelial cells, suffer divergent further differentiation in an apparently identical environment, namely, inclusion in an endothelial wall with luminal and mesenchymal surfaces. But since the cells are identical, i.e., mesenchymal cells slightly differentiated into functional young endothelial cells, then the environment of extrinsic stimuli determining the direction of migration and the initial steps in the further differentiation into

different varieties of blood corpuscles, must indeed have differed to some extent, however slightly.

An interesting feature of this marrow concerns further the fact of a more or less sharp grouping of the several types of cells at the various phases of development, very much as is the case in the red marrow of the femur of the pigeon and of the rabbit during stages of intense hemopoiesis, that is, a certain group of cells comprises predominantly small lymphocytes, another large lymphocytes, another neutrophilic leucocytes, and another eosinophilic leucocytes. Intravascularly, developing erythroblasts predominate; among these are intermingled lymphoblasts, thromboblats, and neutrophilic leucoblats.

Here again it might be argued in favor of the polyphyletic theory that since the general environment is apparently the same, the progenitors of the several groups were cells with different and specific developmental potencies, in spite of their apparent morphologic identity. But in view of the fact that relatively slight environmental differences apparently determine developmental differences in early ontogeny, as, for example, in the developing gut of the mammalian embryo where smooth muscle, connective tissue, and blood develop in the same restricted regions, it seems more in accord with histogenetic data to conclude that the several regions filled with different segregated groups of cells were under the influence of different metabolic (fundamentally perhaps only relational, both temporal and spatial) factors, which determined the specific type of development.

This brings us to the question of the development of the eosinophilic leucocytes. The red marrow of the frog offers an especially favorable material for the study of the developmental history of the eosinophilic granulocytes. Unequivocal histologic evidence accrues with respect to the debated questions regarding the origin of the cells, whether heteroplatic or homoplatic; source of the eosinophilic granules, whether endogenous or exogenous; the alleged basophilic 'unripe' eosinophilic granules, and the genetic relationship between mast-cells and eosinophilic leucocytes. An enormous literature of conflicting opinion and

conclusions exists covering these disputed points; this need not be here again reviewed; it is fully covered in a number of recent works (e.g., Downey,⁸ Ringoen²¹).

The superior feature of the frog material pertains primarily to the absence of special eosinophilic leucocytes. The presence of such types—with fine eosinophilic granules, as in guinea-pig and rabbit, and ellipsoidal eosinophilic granules, as in sauropsida and certain fishes—greatly confuses the picture in these forms. In the marrow of the frog the neutrophilic 'special' granulocytes and the eosinophils are clearly distinguishable from their earliest stages of development from the common lymphocyte ancestor. The neutrophilic granulocytes show at first an oxyphilic halo about the centrosome, which early becomes granular, the granulation spreading throughout the entire cell, the granules always being of a lighter or darker lilac color. The eosinophils, on the other hand, begin their differentiation from the parent lymphocyte by the elaboration of a few minute deep-staining (purple) eosinophilic granules. These gradually increase in number and size, and assume a more brilliantly red (or orange-red) color. No basophilic granules (i.e., blue-staining) were seen among the eosinophilic granules at any stage of the development of this type of granulocytes. The earliest granules are, it is true, of purple-red color and apparently less oxyphilic than the definitive granules, but there is no evidence of a differentiation of definitely basophil granules into eosinophil granules. The definitive granules, moreover, have a lighter-staining (less dense) center, giving the appearance of a ring-shaped structure. This appearance is due to a rarefaction of the center of the granules coincident with its growth. The growth of the granules, and their change into more intensively oxyphilic granules is apparently due largely to a dilution of their substance, specially pronounced in the center.

Downey⁸ comes to the conclusion, on the basis of his study of the marrow of the guinea-pig, that the eosinophilic granules develop from basophilic predecessors. His illustrations show deep blue-staining granules among eosinophilic granules in the eosinophilic myelocytes. Such blue-staining granules never appear in the eosinophilic myelocytes of frog in my material;

they are present only in the mast-cells. However, I find abundant examples of just such cells as depicted by Downey in sections of young turtle embryos in the periaortic connective tissue. It must be emphasized that the fixing and staining fluids in these instances (turtle embryo, Jordan; guinea-pig, Downey) were the same, namely, Helly's fluid followed by the Giemsa stain (Downey employed also other similar stains but not Wright's combination). In the case of the frog's marrow the fixation was secured with a corrosive-sublimate-formalin mixture and the staining was done with Wright's stain. It seems probable that a difference of appearance, as concerns presence or absence of blue-staining granules among the red granules in eosinophilic myelocytes depends upon the type of fixing fluid and staining combinations employed. In the frog material under consideration, it can only be said that less oxyphilic granules precede more oxyphilic granules, and that the former are always smaller than the latter.

All the evidence in this material, moreover, clearly points to a heteroplasmic origin of these cells from lymphocyte ancestors, and the endogenous origin of the eosinophilic granules. Only the younger types of myelocyte, i.e., with non-polymorphous nucleus, are capable of mitotic division and thus of forming new eosinophilic myelocytes. The granules are in no case ingestion products of hemoglobin-containing fragments of disintegrating erythrocytes, but result from the specific activity of the myelocyte protoplasm. Moreover, the nucleus is never invaded by these cytoplasmic granules, as maintained by Niegolewski,¹⁹ nor is there the slightest evidence in support of Weidenreich's²⁴ theory that eosinophilic granules are the ingested fragmentation products of erythrocytes. In this material the erythrocytes develop only intravascularly, where they also fragment; the eosinophils, on the other hand, develop only extravascularly. All the evidence inclines towards the interpretation of these granules as the product of a specific cytoplasmic activity.

The chief question regarding the basophilic leucocytes (mast-cells) is whether they represent a specific type of normal blood-cell or whether they represent degenerations of lymphocytes or

other leucocytes. This study does not touch the disputed question of the genetic relationship between the so-called histogenous and hemotogenous types of basophilic leucocytes. The literature on this subject has been very fully reviewed in the recent papers of Maximow,¹⁶ Downey,⁷ and Ringoen.²⁰ This study is concerned only with the hemotogeneous type of mast-cells. My results are in accord with those of the above-mentioned authors, who conclude that in the mammals investigated (including guinea-pig and rabbit) the mast leucocytes represent a specific and independent line of granulocytes, of heteroplasmic origin, with basophilic granules resulting from a specific activity of the protoplasm.

In the marrow of the frog the first indication of mast-cells appears in the nuclear modification of the lymphocyte parent, namely, a relatively greater contraction and condensation of the central spheroidal nucleus, giving a deep-blue coloration and a more homogeneous character to this body. Coincident with these early nuclear alterations, minute basophilic (deep blue-staining) granules appear; these granules are, however, from the beginning larger than the ancestors of the eosinophilic granules. They grow in size, exceeding that of the definitive eosinophilic granules, and maintain their original deep blue coloration. These cells also liberate granulated globules through segmentation of pseudopods. As found in the blood, these cells show a centrally located, more vesicular nucleus, a somewhat larger size, and cytoplasmic granules of deep lilac color. There is not the slightest indication of a transformation of these basophilic granules into eosinophils at any stage, nor of any degeneration process connected with the formation of the granules. None of these cells were seen by me in mitosis at any stage. The cells apparently originate only heteroplasmically from parent lymphocytes, and form their granules by an endogenous process. These observations agree with those previously reported for the basophilic granulocytes in the turtle embryo.¹¹ Not only can both eosinophils and basophils be traced to the same type of lymphocyte, but the smaller granules of the youngest basophils are always considerably larger than the smallest eosinophilic

granules, and the nucleus of the mast-cells is at all stages after the earliest quite different from that of the eosinophils. The presence of these cells in the smear preparations in considerable numbers renders inadmissible their interpretation in terms of a disintegration of other types of cells. The deep blue-staining granules of the basophilic myelocytes change to a violet color as seen in blood smears. The nucleus also changes from a deep-staining homogeneous body to a vesicular body with a delicate reticulum. It maintains an approximately central position in this cell throughout its history.

The most perplexing matter regarding the thrombocytes concerns their origin. In a study of hemopoiesis in the turtle, Jordan and Flippin¹¹ have described their origin in part from the endothelium of the original vascular spaces of yolk-sac and red marrow and in part from small lymphocytes. Danchakoff² claims that they arise exclusively from lymphocytes (thromboblats), while Werzberg²⁵ maintains that they are a type *sui generis*, having origin neither from endothelium nor lymphocytes. The evidence from this study of the red marrow of the frog confirms our former conclusion regarding their origin, as described in a study of turtle embryos. The thrombocytes arise only intravascularly. They can be traced directly to small lymphocyte-like cells. Secondarily, both lymphocytes and thrombocytes may arise from endothelium. The close relationship of small lymphocytes and thrombocytes appears throughout their entire history. This is especially emphasized, aside from the close similarity in structure of the nucleus, by the presence in certain of the small lymphocytes of a variable quantity of metachromatic granules.

The mode of multiplication of the constituent cells of this marrow centers interest upon amitosis and throws additional light on the question of this variety of cell division. The original blood-cell progenitor (lymphocyte; hemoblast) arises from a mesenchymal cell. Relatively little proliferative activity occurs among these mesenchymal cells; the multiplication of hemoblasts results mainly from a division of already differentiated mesenchymal cells. This differentiation process consists essentially in

the rounding up of an irregular, generally stellate cell (fig. 33), and a condensation and increase in basophily of the cytoplasm (fig. 34). The nuclei of the typical mesenchymal cells and the derived hemoblasts are practically identical. These nuclei are of a vesicular lightly-staining character, with a pale nucleolus, several deeply chromatic karyosomes, and many very minute chromatic granules scattered among a very delicate chromatic reticulum. This description fits also the smaller types of hemoblasts, both intra- and extravascular. In general, further differentiation into the various types of blood-cells involves first an increase in the number of larger, more regular karyosomes, so that the nucleus has a coarsely granular appearance, many granules lying peripherally upon the more robust, chromatic, nuclear membrane. The plasmosome meanwhile persists. Later stages are characterized mainly by increase in the general chromaticity of the nuclear sap, giving the entire nucleus, now with a coarser reticulum, a deep blue coloration. Only the larger lymphocytes divide mitotically; the smaller lymphocytes do not divide as such; they may grow to larger size and then divide mitotically. Excessive growth of the large lymphocytes leads to giant-cells (fig. 73). Both neutrophilic and eosinophilic leucocytes also divide mitotically during their earlier stages, while the nucleus remains of spheroidal shape. Similarly, young spheroidal erythroblasts may divide mitotically within the blood-vessels. Neither basophilic leucocytes nor thrombocytes were seen in either mitosis or amitosis.

Besides proliferation by mitosis, large lymphocytes, young erythroblasts, and young neutrophilic leucocytes also divide amitotically. What determines whether a lymphocyte or erythroblast shall divide directly or indirectly remains obscure; possibly the two modes of division are determined by divergent metabolic conditions as expressed in the nucleo-cytoplasmic relationship. However, the amitotic division of the neutrophilic leucocytes, of which the extreme lobulation of the later nucleus must probably be reckoned a phase, is the more surprising, since here an astral system is maintained intact and is at all stages conspicuous. Possibly here the mitotic incapacity of the

centrosomes is related to the high stage of differentiation as expressed fundamentally in the neutrophilic granules. This suggestion is in harmony with the facts that the later eosinophilic myelocytes, the basophilic myelocytes, the thrombocytes, and the giant-cells also do not divide mitotically. All of these cells express in their peculiar cytoplasmic condition a high degree of differentiation. The reason for the failure of basophilic myelocytes, thrombocytes, and giant-cells for the most part, to proliferate even amitotically is under this view not clear. However, if we assume that the lobulated nucleus of the neutrophilic myelocytes represents an unfinished amitosis, then possibly the bilobed nucleus of the basophilic myelocytes, the deeply grooved condition of the thrombocyte nucleus, and the polymorphous character of the giant-cell nucleus (in mammals) may legitimately be similarly interpreted.

The nuclear amitosis of the neutrophilic myelocytes and the amitosis of the hemoblasts (large lymphocytes and erythroblasts) are apparently similar phenomena resulting from quite different causes—cytoplasmic specificity or high differentiation and intense proliferative demands, respectively. These dissimilar causative factors may, however, be brought under a common head as regards their effect on the potency and integrity of the kinetic center, the centrosome. Both conditions may be conceived to reduce relative nutritive conditions below the possible minimum for centrosomal activity. In essence, amitotic proliferation, in contrast with mitotic proliferation, results presumably when the metabolic demands of the protoplasmic mechanism are such as to deprive the astral system of its minimum nutritive requirements. This assumption can at least harmonize the apparently contradictory facts that amitosis occurs in the cells of rapidly growing tissues as well as in highly specialized and degenerating cells, an idea first suggested by Child.¹

In this connection attention must again be directed to the two main types of astral systems in the neutrophilic granulocytes: one clear with a central monosome or diplosome, the other consisting of a larger or smaller granular sphere. As described

above, these types correspond with those found in the earlier and later stages respectively, of the first maturation spindle of the *Cummingia tellinoides* egg, where the pluricorpuscular is derived from the unicorpuscular sphere, and represents a disintegration or partition product.⁹ This conclusion respecting the significance of the pluricorpuscular centrosphere is supported by the facts that the second maturation spindle of *Cummingia* has almost invariably this type of sphere and that the segmentation spindles again show spheres of both types. It would seem a legitimate inference that the two types of centrospheres of the neutrophilic leucocytes of frog bear to each other the same genetic relationship, and that the pluricorpuscular variety also signifies disintegration. The medullary neutrophils support this inference; certain examples with lobulated nuclei contain a granular sphere (fig. 56), but here the sphere is smaller, the granules less numerous and more conspicuous. It seems very probable that the mitotic incapacity on the part of these cells results from an untoward influence upon the centrosome due to a relative lack of nutritive materials following the maintenance of the high degree of specialization involved in the elaboration of metachromatic granules.

In a paper dealing with amitosis in the cells of the ductuli efferentes of the testis of the mouse, I¹⁰ suggested that the amitotic division of these cells was a consequence of the loss of the integrity of the centrosome through partition into the basal granules which give rise to the cilia. While confirming the observation that ciliated cells of vertebrates do not multiply by mitosis, but may divide amitotically, Saguchi²² claims to be able to demonstrate the presence and integrity of the centrosome in ciliated cells of vertebrates, and the origin of the basal granules and the cilia from mitochondria. Apart from the fact that his illustrations are far from convincing, both as regards identification of the centrosome and the genetic relationship between mitochondria and cilia, the divergence of such a process from the known functional behavior of mitochondria in general renders his claims dubious. The recent investigations on mitochondria have demonstrated that these cytoplasmic elements have no

direct genetic relationship to such structures as nerve, muscle or connective-tissue fibrils, but are intimate cytoplasmic constituents most probably subserving general cell metabolism, not specific differentiations. On the other hand, we have the very suggestive fact that the axial filament of the flagellum of the sperm (comparable to a coarse cilium) does grow out from one of the partition products of the centrosome of the spermatid. The fact that a centrosome can still be detected in a ciliated cell is not disproof that some of the original partition products served as basal bodies for the development of the ciliary apparatus. Not all of the partition products need have been thus employed; several might have remained as discernible granules near the central portion of the cell. Nevertheless, Saguchi's²² general conclusion that the "occurrence of amitosis in ciliated cells is not owing to the lack of centrosome," but is "due essentially to the degree of differentiation of the cell-plasm" (p. 262) is not in contradiction with my earlier suggestion that the primary common cause of amitosis is some deleterious influence of variable type upon the centrosome. This might be narcotization, relative lack of sufficient materials to meet metabolic demands as in conditions of very rapid growth or differentiation, lack of sufficient supply of oxygen, or the presence of toxic substances as in degenerating or pathologic tissues.

The theory that can in my opinion best harmonize the apparently contradictory observations that amitosis occurs in rapidly growing tissues, degenerating tissues, highly specialized cells (e.g., secretory, ciliated, granulocytes) and in tissues grown under experimental conditions (e.g., root tips grown in water with ether) is one expressed in terms of primary influence upon the centrosome, effecting either a loss of morphological integrity as by partition in ciliated cells and certain leucocytes, or loss of specific physiologic capacity as in narcotized, degenerate, or secretory cells. The effective factor may in the latter case still be fundamentally a disturbance of the optimum nucleo-cytoplasmic relationship (producing a nutritive want, subsequently affecting the centrosome), as recently suggested by Nakahara¹⁷ for 'secretory or reserve-forming cells,' where he concludes that amitosis

in adipose cells of insects "may be for the purpose of securing an increase of the nuclear surface to meet the physiological necessity due to the active metabolic interchange between the nucleus and cytoplasm" (p. 509). Even in cases where the original centrosome has fragmented, presumably under the influence of cytoplasmic specialization, the effective factor in determining amitotic division may still in part be the metabolic condition following a certain degree of nucleo-cytoplasmic balance. That the fragmentation of itself is not in all cases effective seems proved by the case of the mitotically dividing blastomeres of the *Cummingia* embryo in which pluricorpuscular centrosomes abound. In the ciliated cells of vertebrates a partitioned centrosome, under the metabolic conditions underlying the type of differentiation characteristic of a cell developing cilia, is generally incapable of supporting mitotic division; in the more vigorous blastomeric cells of *Cummingia*, characterized by presumably different metabolic conditions, such a centrosome may still be able to function in indirect division.

Probably the most important result of this search for the amphibian homologue of the mammalian giant-cell turns out to be the light shed upon the significance of the hemogenic giant-cells, especially the so-called megakaryocytes of mammals, and upon the morphologic and genetic significance of the blood-platelets. Though both thrombocytes and polymorphonucleated neutrophilic leucocytes show certain characteristics in common with the mammalian megakaryocytes, the genuine amphibian homologue is a very large mononucleated cell, comparable with a similar giant-cell of mammalian marrow from which the polymorphonucleated megakaryocytes develop. These cells are the homologues also of the mono- and polymorpho- and polynucleated hemogenic giant-cells of the mammalian yolk-sac during its hemopoietic phase.¹² These cells in all of these locations develop from the primitive lymphocyte or hemoblast. This study of frog's marrow has shown that pseudopod formation and constriction is a characteristic common to leucocytes at all stages of their history. Moreover, it is well recognized that cytoplasmic fragmentation is a concomitant of degeneration. The processes by

which blood-platelets arise from megakaryocytes in mammalian marrow thus appear to be coincidences of these two cytoplasmic properties of active and degenerating leucocytes respectively. This conclusion is further strengthened by the fact that the hemogenic giant-cells of the yolk-sac (e.g., 12-mm. pig embryo) likewise produce typical platelets in abundance.¹³

SUMMARY

1. The blood of the leopard frog contains the following cellular elements; erythrocytes, thrombocytes, large and small lymphocytes, and neutrophilic, eosinophilic, and basophilic granulocytes.

2. Thrombocytes, neutrophilic granulocytes, and lymphocytes contain a variable quantity of metachromatic granules. Both thrombocytes and lymphocytes show conspicuous granular pseudopods which may constrict to form platelet-like bodies.

3. The polymorphonuclear neutrophilic leucocyte of the frog resembles the cell of this designation in certain mammalian bloods. It is characterized especially by its conspicuous astral system, its extremely lobulated nucleus, and the presence of metachromatic granules arranged in lines radiating from the centrosphere.

4. The red bone-marrow contains the following types of myelocytes; erythroblasts and thromboblats, only intravascularly; lymphoblats, both intravascularly and extravascularly; granular myelocytes, including neutrophilic, eosinophilic, and basophilic cells. All of the leucocytic series show pseudopods, which may constrict to form 'hyaline' bodies and granular platelet-like corpuscles. Certain lymphocytes differentiate also into plasma-cells and giant-cells extravascularly.

5. All the types of myelocytes can be traced back to a similar, apparently identical, progenitor, a lymphocyte-like cell or hemoblast arising from the mesenchyma. The evidence from this material is wholly in accord with the monophyletic theory of blood-cell origin. Environmental conditions are apparently the chief factors which determine the line of differentiation a certain hemoblast shall take. Cords of hemoblats enclosed by endothelium produce erythroblats and thromboblats, or persist in

part as lymphoblasts. The extravascular hemoblasts develop into lymphocytes and granulocytes, which may enter the vascular spaces secondarily. The lymphocytes of the circulating blood are apparently only slightly modified marrow lymphoblasts or hemoblasts, which occur both intra- and extravascularly. A certain number of neutrophilic leucocytes also originate intravascularly. Circulatory lymphocytes also may differentiate further into neutrophilic leucocytes.

6. Pseudopod constriction and cytoplasmic fragmentation of leucocytes are two fundamentally distinct processes leading to similar results, namely, the production of free cytoplasmic globules. Pseudopod formation and constriction is a common property of leucocytes; fragmentation is a degeneration phenomenon associated with nuclear pycnosis and subsequent disintegration. Lymphocytes and eosinophilic leucocytes produce the hyaline bodies; neutrophilic granulocytes, thrombocytes, and certain lymphocytes with metachromatic granules produce platelet-like bodies. Globules with basophilic granules arise from pseudopods of mast-cells. Platelet formation from megakaryocytes in mammalian red bone-marrow is apparently a by-product of this common property of leucocytes and their derivatives, and especially of the disintegration of senile types of these cells.

7. The amphibian homologue of the mammalian hemogenic giant-cell is a large mononucleated cell with a relatively large nucleus, comparable to the similar mononucleated giant-cell of mammalian marrow from which develop the polymorphonucleated ('megakaryocyte' with 'basket nucleus') and multinucleated older types. Both cells differentiate from a hypertrophied primitive lymphocyte or hemoblast.

8. The polymorphonucleated neutrophilic leucocytes contain a conspicuous centrosphere which may include a simple, a bilobed, a double, or a multiple centrosome. These cells do not divide mitotically. It is suggested that mitotic incapacity on the part of these cells is the result of a relative nutritive want in consequence of the high degree of specialization involved in the elaboration of the metachromatic granules. The underlying

metabolic demands are conceived to effect an untoward influence upon the kinetic center, a morphologic aspect of which is expressed in the pluricorpuscular variety of centrosome.

LITERATURE CITED

- 1 CHILD, C. M. 1907 Studies on the relation between amitosis and mitosis Biol. Bull., vol. 12, nos. 2, 3 and 4.
- 2 DANCHAKOFF, VERA 1910 Über die Entwicklung der embryonalen Blutbildung bei Reptilien. Bd. 37 (Ergänzungsheft).
- 3 1918. Cell potentialities and differential factors considered in relation to erythropoiesis. Am. Jour. Anat., vol. 24, p. 1.
- 4 1918. Equivalence of different hematopoietic anlagen (by method of stimulation of their stem-cells). II. Grafts of adult spleen on the allantois and response of the allantoic tissues. Am. Jour. Anat., vol. 24, p. 127.
- 5 DOWNEY, HAL 1911 The origin and structure of the plasma cells of normal vertebrates, especially of the cold blooded vertebrates, and the eosinophils of the lung of *Amblystoma*. Folia Haematologica, Bd. 11, S. 275.
- 6 1913 a The granules of the polymorphonuclear leucocytes of *Amblystoma*, with a few notes on the spindle cells and erythrocytes of this animal. Anat. Anz., Bd. 44, S. 309.
- 7 1913 b The development of histogenous mast cells of adult guinea-pig and cat, and the structure of the histogenous mast cells of man. Folia Haematologica, Bd. 16, S. 49.
- 8 1915 The origin and development of eosinophil leucocytes and of haematogenous mast cells in the bone marrow of adult guinea-pig. Folia haematologica, Bd. 19, S. 148.
- 9 JORDAN, H. E. 1910 A cytological study of the egg of *Cummingia* with special reference to the history of the chromosomes and the centrosomes. Arch. f. Zellforsch., Bd. 4, S. 243.
- 10 1913 Amitosis in the epididymis of the mouse. Anat. Anz., Bd. 43, S. 589.
- 11 JORDAN, H. E., AND FLIPPIN, J. C. 1913 Haematopoiesis in *Chelonia*. Folia Haematologica, Bd. 15, S. 1.
- 12 JORDAN, H. E. 1918 A contribution to the problems concerning the origin, structure, genetic relationship and function of the giant-cells of hemopoietic and osteolytic foci. Am. Jour. Anat., vol. 24, p. 225.
- 13 1918 The histogenesis of blood-platelets in the yolk-sac of the pig embryo. Anat. Rec., vol. 15, p. 391.
- 14 MAXIMOW, A. 1906 Über entzündliche Bindegewebsneubildung beim Axolotl. Zeigler's Beitr. z. path. Anat. u. z. Allgem. Path., Bd. 39.
- 15 1910 Über embryonale Entwicklung der Blutzellen bei *Selachiern* und *Amphibien*. Anat. Anz., Bd. 37 (Ergänzungsheft), S. 64.
- 16 1913 Untersuchungen über Blut und Bindegewebe. VI. Über Blutmastzellen. Arch. f. mikr. Anat., Bd. 83, Abt. 1.

- 17 NAKAHARA, W. 1918 Studies of amitosis: its physiological relations in the adipose cells of insects and its probable significance. *Jour. Morph.*, vol. 30, p. 483.
- 18 NEUMANN, E. 1903 *Haematologische Studien*. *Virchow's Archiv.*, Bd. 174.
- 19 NIEGOLEWSKI, F. 1894 Die Ehrliche Granulation der weissen Blutkörperchen bei einigen Tierspezies. *Inaug. Dissert.*, München (cited from Werzberg).
- 20 RINGOEN, A. R. 1915 a Observations on the origin of the mast leucocytes of the adult rabbit. *Anat. Rec.*, vol. 9, p. 233.
- 21 1915 b Observations on the differentiation of the granules in the eosinophilic leucocytes of the bone-marrow of the adult rabbit. *Anat. Rec.*, vol. 9, p. 683.
- 22 SAGUCHI, S. 1917 Studies on ciliated cells. *Jour. Morph.*, vol. 29, p. 217.
- 23 STARLING, E. H. 1915 *Principles of human physiology*, p. 833. Lea & Febiger, Phila.
- 24 WEIDENREICH, F. 1905 Zur Frage nach der Entstehung der eosinophilen Leukozyten. *Folia Haematologica*, Bd. 2.
- 25 WERZBERG, A. 1911 Studien zur vergleichenden Haemozytologie einiger poikilothermer Vertebraten. *Folia Haematologica*, Bd. 11, S. 17.
- 26 WRIGHT, J. H. 1910 The histogenesis of the blood platelets. *Jour. Morph.*, vol. 21, p. 263.

EXPLANATION OF PLATES

All figures were made by aid of $\frac{1}{16}$ Leitz oil-immersion lens and a drawing camera at an original magnification of 2000 diameters, which was reduced one-third in reproduction. Figures 1 to 32 are from smear preparations of blood, stained with Wright's stain; figures 33 to 73 are of sections of the red marrow of the femur, fixed in a corrosive-sublimate-formalin solution and stained according to Wright's technic for demonstrating the origin of blood-platelets from megakaryocytes.

PLATE 1

EXPLANATION OF FIGURES

Blood

1 to 3 Normal, older, and senile types, respectively, of erythrocytes. The color of the nucleus changes from violet to lilac, the cytoplasm from bluish green to yellow, in passing from 1 to 3.

4 to 6 Small, ameboid, and medium-sized lymphocytes, respectively. The nucleus stains a deep lilac or violet color; the cytoplasm contains finer and coarser irregular and clumped basophilic (blue) granules, among which may appear a variable number of small spheroidal metachromatic (lilac-colored) granules.

7 Similar medium-sized lymphocyte with numerous pseudopods, some of which have liberated spheroidal granulated globules by a process of constriction. Except for the blue color of their granules, these globules are apparently identical with blood-platelets of mammals.

8 Large lymphocyte with reniform nucleus. The cytoplasm contains a small amount of a metachromatic granulation scattered among the predominating basophilic (blue) granules.

9 Large lymphocyte, with nuclear and cytoplasmic characteristics like those of small lymphocytes.

10 Similar large lymphocyte, with reniform nucleus and a conspicuous diplosome opposite the nuclear concavity.

11 Binucleated eosinophilic leucocyte (mononucleated, polymorphonuclear, and polynuclear types also occur). The nucleus has a deep lilac color. The eosinophilic granules are imbedded in a homogeneous basophilic (blue) substratum. The granules maintain a fairly uniform size; they appear ring-shaped, indicating a difference in condensation between center and periphery. The nucleus almost invariably takes a polar position.

12 Basophilic granulocyte (mast-cell). The nucleus is located centrally; it is relatively large and vesicular, staining a light blue color, and showing a delicate reticulum. The granules have a deep lilac color, are fairly uniform in size, and in general slightly larger than the granules of the eosinophilic leucocytes.

13 to 15 Mononucleated (young) types of neutrophilic granulocytes. The nucleus has a lilac color. The fine neutrophilic granules are imbedded in a lightly basophilic (blue) cytoplasm. Figure 13 shows a conspicuous diplosome about which the granules are disposed in radiating lines. Figure 15 shows two pseudopods.

16 Neutrophilic granulocyte with bilobed (dividing) nucleus, and conspicuous, finely granulated centrosphere.

17 Binucleated neutrophilic leucocyte.

18 to 21 Various types of polymorphonucleated neutrophilic leucocytes.

22 Polymorphonucleated neutrophilic leucocyte of blood of dog.

23 to 26 Various, more complex types of polymorphonucleated neutrophilic granulocytes. Figure 23 shows a dense granular centrosphere; figure 24, a clear sphere with a dumb-bell-shaped centrosome (centriole).

27 to 29 Types of thrombocytes. The nucleus is a dense granular body, staining a violet color. The cytoplasm forms a meagre shell of viscid homogeneous character. This contains a variable amount of fine uniform, meta-chromatic (lilac) granules. The general shape of the thrombocytes is fusiform, but spheroidal and oval forms also occur (fig. 29).

30 and 31 Thrombocytes with pseudopods, some of which liberate granulated stellate globules. The latter simulate very closely the blood-platelets of mammalian bloods.

32 Naked disintegrating nucleus of a degenerating thrombocyte.

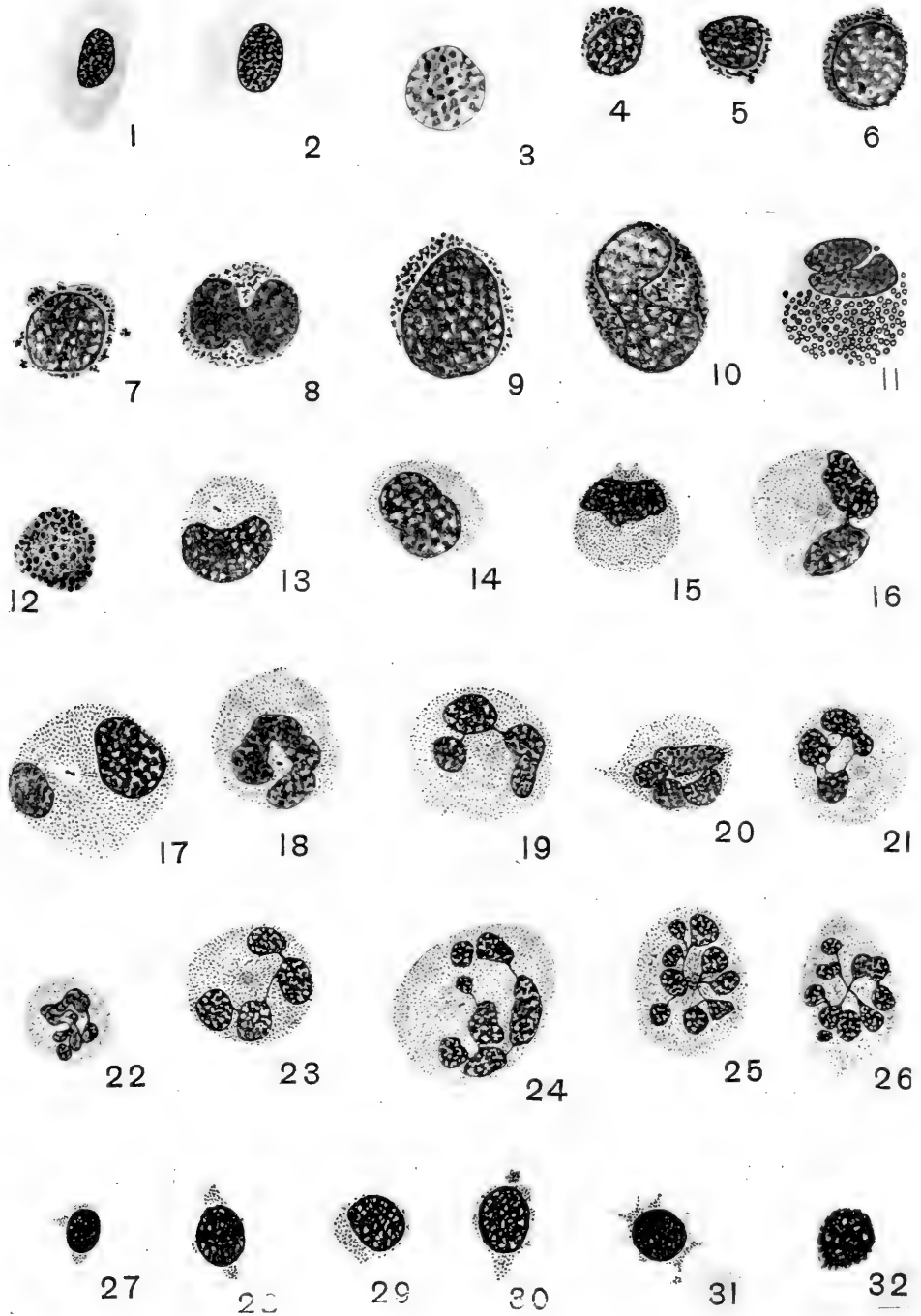


PLATE 2

EXPLANATION OF FIGURES

Bone-marrow

33 A mesenchymal marrow cell, source from which hemoblasts develop. The cytoplasm is only very slightly basophilic, staining very faintly blue, and of homogeneous character. The nucleus is relatively large. It invariably contains a faintly staining plasmosome, occasionally several, and a number of larger karyosomes and innumerable minute chromioles scattered over a very delicate chromatic reticulum. The nucleus is vesicular in character and takes only a faintly blue stain.

34 Primitive large lymphocyte (hemoblast). The nucleus is practically identical with that of its mesenchyme ancestor. It stains only slightly darker. The cytoplasm likewise seems more condensed and slightly more basophilic, of light blue color.

35 Slightly older extravascular lymphocyte, in amoeboid activity. The pseudopods may constrict off hyaline globules, similar to non-granular 'platelets.'

36 Eosinophilic myelocyte; a slightly differentiated lymphocyte, with pseudopods forming hyaline 'platelets.'

37 Medium-sized primitive lymphocyte (hemoblast); a slightly differentiated mesenchyme cell. Note the mesenchymal character of the nucleus. This cell may likewise develop into a granulocyte.

38 Small extravascular primitive lymphocyte.

39 Slightly later stage in the development of an extravascular small lymphocyte, leading to a large lymphocyte or a granulocyte.

40 Similar small lymphocyte with numerous pseudopods, which may form hyaline 'platelets.'

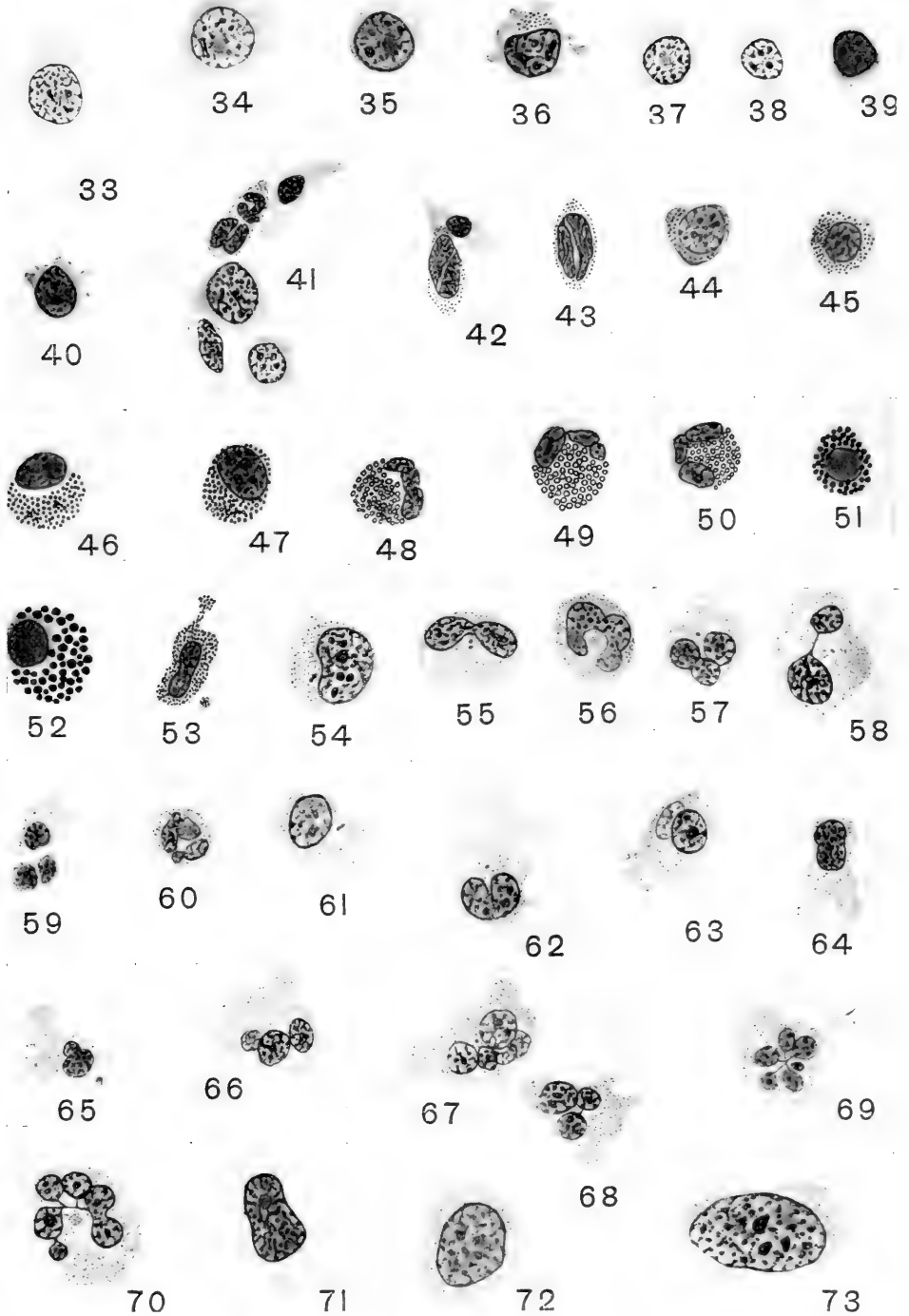
41 Group of myelocytes from the periphery of a developing, small marrow blood-space. The cells include in order from above an erythrocyte, a polynuclear neutrophilic leucocyte, a large lymphocyte, an erythroblast, and a small lymphocyte. From the latter type of cell develop intravascularly both erythrocytes and thrombocytes; from large lymphocytes develop intravascularly only neutrophilic granulocytes. From these large and small intravascular lymphocytes develop also the various definitive lymphocytes of the circulating blood.

42 A medullary erythrocyte (above) and a thrombocyte. (Compare with figs. 1 and 28 for demonstration of growth in passage from narrow to peripheral blood stream.) The cytoplasm of the thrombocyte varies in color from a very faint blue to a very light pink. It contains minute metachromatic (lilac) granules of uniform size, grouped at the poles, and ranged apparently in single file along the lateral border. Thrombocytes apparently do not protrude pseudopods within the marrow. Their nucleus has in general the features of a small or medium-sized primitively lymphocyte, from which cell the thrombocyte develops, but it is characteristically furrowed by deep oblique and longitudinal grooves.

43 Similar medullary thrombocyte.

44 to 50 Successive steps in the development of an eosinophilic myelocyte from a primitive lymphocyte or hemoblast (compare figs. 50 and 11).

(Continued on page 480)



51 and 52 Basophilic myelocytes (medullary mast-cells). (Compare with ancestral cell, fig. 39, and circulatory mast-cell, fig. 12.)

53 Earlier stage of medullary mast-cell with finer basophilic (deep blue) granules and a long pseudopod in process of constricting off a 'platelet' with basophilic granules.

54 Young neutrophilic granulocyte. (Compare with the ancestral large lymphocytes, figs. 34 and 35.) The centrosome is conspicuous in the concavity of the reniform nucleus. The neutrophilic granules have not yet spread throughout the entire cytoplasmic mass; a relatively wide non-granular hyaline area appears at the left.

55 to 59 Successively later stages in the development of the neutrophilic myelocytes. The polylobular nucleus may constrict to form a polynuclear cell (fig. 57); this amitotic division of the nucleus may in some cases be followed by a fission of the cytoplasm (fig. 59). These cells contain astral stems like those of the circulatory cells.

60 Small polymorphonuclear neutrophilic myelocyte. (Compare with fig. 22, a polymorphonuclear neutrophilic leucocyte of blood of dog.)

61 and 62 Young neutrophilic myelocytes with pseudopods.

63 A neutrophilic myelocyte which has protruded four pseudopods into a capillary space of the marrow, a phenomenon duplicating that by which megakaryocytes of mammals pass platelets directly into the blood stream.

64 to 68 Various forms of neutrophilic myelocytes with pseudopods which constrict to form typical platelets (fig. 65).

69 Complex polymorphonuclear neutrophilic myelocyte arising directly from mesenchyme among a group of fat cells, two of which are indicated at the right.

70 Similar neutrophilic myelocyte from the fatty mesenchyme. (Compare with fig. 24.)


71 Plasma-cell from the medullary mesenchyme, a derivative from a large lymphocyte. (Compare with fig. 35.)


72 and 73 Mononucleated giant-cells from the marrow mesenchyme. These are strictly comparable to the mononucleated hemogenic giant-cells of mammals, from which the polymorphonuclear giant-cells (so-called megakaryocytes), the source of blood-platelets, develop. These amphibian homologues of mammalian hemogenic giant cells likewise possess a basophilic cytoplasm with metachromatic (lilac colored) granules, and arise from hypertrophying hemoblasts. Segmenting pseudopods of such cells produce typical platelets.

SUBJECT AND AUTHOR INDEX

- A**DRENAL gland in the albino rat. The relative volumes of the cortex and medulla of the 291
- Albino rats from birth to ten weeks of age. Studies on the mammary gland. IV. The histology of the mammary gland in male and female 395
- Albino rat. The postnatal development of the suprarenal gland and the effects of inanition upon its growth and structure in the 221
- Albino rat. The relative volumes of the cortex and medulla of the adrenal gland in the 291
- ALLIS, EDWARD PHELPS, JR. The homologies of the maxillary and vomer bones of *Polypterus* 349
- Arteries of the human lower extremity. The development of the 55
- B**ADERTSCHER, J. A. The ultimobranchial bodies in postnatal pigs (*Sus scrofa*) 13
- Blood and the red bone-marrow of the leopard frog, *Rana pipiens*. The histology of the blood. The origin of the phagocytic mononuclear cells of the peripheral 27
- Bone-marrow of the leopard frog, *Rana pipiens*. The histology of the blood and the red 437
- Bones of *Polypterus*. The homologies of the maxillary and vomer 349
- Brachydaetyly in the domestic fowl. The developmental relations of 97
- Burrowing mammals. A study of the correlation of the pelvic structure and the habits of certain 185
- C**ELLS of the peripheral blood. The origin of the phagocytic mononuclear 27
- CHAPMAN, ROYAL NORTON. A study of the correlation of the pelvic structure and the habits of certain burrowing mammals 185
- CORPUS luteum. Studies on the ovary of the spermophile (*Spermophilus citellus tridecemlineatus*) with special reference to the 117
- Correlation of the pelvic structure and the habits of certain burrowing mammals. A study of the 185
- Cortex and medulla of the adrenal gland in the albino rat. The relative volumes of the 291
- D**ANFORTH, C. H. The developmental relations of brachydaetyly in the domestic fowl 97
- Developmental relations of brachydaetyly in the domestic fowl. The 97
- Development of the arteries of the human lower extremity. The 55
- Development of the intercalated discs. Histogenesis of the heart muscle of the pig in relation to the appearance and 333
- Development of the lobule of the pig's liver. The 299
- Development of the suprarenal gland and the effects of inanition upon its growth and structure in the albino rat. The post natal 221
- Discs. Histogenesis of the heart muscle of the pig in relation to the appearance and development of the intercalated 333
- Domestic fowl. The developmental relations of brachydaetyly in the 97
- DONALDSON, JOHN C. The relative volumes of the cortex and medulla of the adrenal gland in the albino rat 291
- DRIPS, DELLA. Studies on the ovary of the spermophile (*Spermophilus citellus tridecemlineatus*) with special reference to the corpus luteum 117
- E**XTREMITY. The development of the arteries of the human lower 55
- F**ILUM terminale. Factors involved in the formation of the 1
- Fowl. The developmental relations of brachydaetyly in the domestic 97
- Frog, *Rana pipiens*. The histology of the blood and the red bone-marrow of the leopard 437
- G**LAND and the effects of inanition upon its growth and structure in the albino rat. The postnatal development of the suprarenal 221
- Gland in the albino rat. The relative volumes of the cortex and medulla of the adrenal 291
- Gland. IV. The histology of the mammary gland in male and female albino rats from birth to ten weeks of age. Studies on the mammary 395
- Growth and structure in the albino rat. The postnatal development of the suprarenal gland and the effects of inanition upon its 221
- H**ABITS of certain burrowing mammals. A study of the correlation of the pelvic structure and the 185
- Heart muscle of the pig in relation to the appearance and development of the intercalated discs. Histogenesis of the 333
- Histogenesis of the heart muscle of the pig in relation to the appearance and development of the intercalated discs 333
- Histology of the blood and the red bone-marrow of the leopard frog, *Rana pipiens*. The 437
- Histology of the mammary gland in male and female albino rats from birth to ten weeks of age. Studies on the mammary gland. IV. The 395
- Homologies of the maxillary and vomer bones of *Polypterus*. The 349
- Human lower extremity. The development of the arteries of the 55
- I**NANITION upon its growth and structure in the albino rat. The postnatal development of the suprarenal gland and the effects of 221
- Intercalated discs. Histogenesis of the heart muscle of the pig in relation to the appearance and development of the 333

- JACKSON, C. M.** The postnatal development of the suprarenal gland and the effects of inanition upon its growth and structure in the albino rat. 221
- JOHNSON, FRANKLIN PARADISE.** The development of the lobule of the pig's liver 299
- JORDAN, H. E.** The histology of the blood and the red bone-marrow of the leopard frog, *Rana pipiens*. 437
- L** **LEOPARD** frog, *Rana pipiens*. The histology of the blood and the red bone-marrow of the 437
- Liver,** The development of the lobule of the pig's 299
- Lobule of the pig's liver.** The development of the 299
- Lower extremity.** The development of the arteries of the human. 55
- Luteum.** Studies on the ovary of the spermophile (*Spermophilus citellus tridecemlineatus*) with special reference to the corpus 117
- M** **MCJUNKIN, FRANK ADAM.** The origin of the phagocytic mononuclear cells of the peripheral blood. 27
- Mammals.** A study of the correlation of the pelvic structure and the habits of certain burrowing 185
- Mammary gland.** IV. The histology of the mammary gland in male and female albino rats from birth to ten weeks of age. Studies on the 395
- Maxillary and vomer bones of Polypterus.** The homologies of the 349
- Medulla of the adrenal gland in the albino rat.** The relative volumes of the cortex and 291
- Mononuclear cells of the peripheral blood.** The origin of the phagocytic 27
- Muscle of the pig in relation to the appearance and development of the intercalated discs.** Histogenesis of the heart. 333
- MYERS, J. A.** Studies on the mammary gland. IV. The histology of the mammary gland in male and female albino rats from birth to ten weeks of age. 395
- O** **OVARY** of the spermophile (*Spermophilus citellus tridecemlineatus*) with special reference to the corpus luteum. Studies on the 117
- P** **PELVIC** structure and the habits of certain burrowing mammals. A study of the correlation of the 185
- Peripheral blood.** The origin of the phagocytic mononuclear cells of the 27
- Phagocytic mononuclear cells of the peripheral blood.** The origin of the 27
- Pigs in relation to the appearance and development of the intercalated discs.** Histogenesis of the heart muscle of the 333
- Pig's liver.** The development of the lobule of the 299
- Pigs (Sus scrofa).** The ultimobranchial bodies in postnatal 13
- Pipiens.** The histology of the blood and the red bone-marrow of the leopard frog, *Rana*. 437
- Polypterus.** The homologies of the maxillary and vomer bones of 349
- Postnatal development of the suprarenal gland and the effects of inanition upon its growth and structure in the albino rat.** The 221
- Postnatal pigs (Sus scrofa).** The ultimobranchial bodies in 13
- R** **ANA** pipiens. The histology of the blood and the red bone-marrow of the leopard frog 437
- Rats from birth to ten weeks of age.** Studies on the mammary gland. IV. The histology of the mammary gland in male and female albino. 395
- Rat.** The postnatal development of the suprarenal gland and the effects of inanition upon its growth and structure in the albino 221
- Rat.** The relative volumes of the cortex and medulla of the adrenal gland in the albino 291
- Red bone-marrow of the leopard frog, Rana pipiens.** The histology of the blood and the 437
- S** **SENIOR, H. D.** The development of the arteries of the human lower extremity. 55
- Spermophile (Spermophilus citellus tridecemlineatus)** with special reference to the corpus luteum. Studies on the ovary of the 117
- STREETER, GEORGE L.** Factors involved in the formation of the filum terminale. 1
- Structure and the habits of certain burrowing mammals.** A study of the correlation of the pelvic 185
- Structure in the albino rat.** The postnatal development of the suprarenal gland and the effects of inanition upon its growth and 221
- Suprarenal gland and the effects of inanition upon its growth and structure in the albino rat.** The postnatal development of the 221
- T** **TERMINA E.** Factors involved in the formation of the filum. 1
- U** **ULTIMOBRANCHIAL** bodies in postnatal pigs (*Sus scrofa*). The 13
- V** **VOLUMES** of the cortex and medulla of the adrenal gland in the albino rat. The relative 291
- Vomer bones of Polypterus.** The homologies of the maxillary and 349
- W** **WITTE, LUCILE.** Histogenesis of the heart muscle of the pig in relation to the appearance and development of the intercalated discs. 333





MBL WHOI Library - Serials



5 WHSE 02077

15532

