



THE AMERICAN JOURNAL OF ANATOMY

EDITORIAL BOARD

CHARLES R. BARDEEN
University of Wisconsin

HENRY H. DONALDSON
The Wistar Institute

SIMON H. GAGE
Cornell University

G. CARL HUBER
University of Michigan

GEORGE S. HUNTINGTON
Columbia University

J. PLAYFAIR McMURRICH
University of Toronto


GEORGE A. PIERSOL
University of Pennsylvania

HENRY McE. KNOWER, SECRETARY
University of Cincinnati

VOLUME 26

SEPTEMBER, 1919—JANUARY, 1920

THE WISTAR INSTITUTE OF ANATOMY AND BIOLOGY
PHILADELPHIA, PA.



CONTENTS

No. 1. SEPTEMBER, 1919


- H. E. JORDAN. The histology of the umbilical cord of the pig, with special reference to the vasculogenic and hemopoietic activity of its extensively vascularized connective tissue. Fifteen figures..... 1
- HENRY A. MURRAY, JR. The development of the cardiac loop in the rabbit, with especial reference to the bulboventricular groove and origin of the interventricular septum. Seven figures..... 29
- FRANK BLAIR HANSON. The ontogeny and phylogeny of the sternum. Twelve plates (forty-nine figures)..... 41
- GEORGE W. CORNER. On the origin of the corpus luteum of the sow from both granulosa and theca interna. Twenty-six figures..... 117

No. 2. NOVEMBER, 1919

- HAROLD J. COOPER. The hypophysis cerebri of the California ground-squirrel, *Citellus beechyi* (Richardson). Eleven figures..... 185
- RALPH DOUGALL LILLIE. The early histogenesis of the blood in *Bufo halophilus* Baird and Girard. Seven figures..... 209
- HENRY H. DONALDSON. Quantitative studies on the growth of the skeleton of the albino rat. Twenty-three charts..... 237

No. 3. JANUARY, 1920

- LESLIE B. AREY. The origin, growth, and fate of osteoclasts and their relation to bone resorption. Twenty-four figures..... 315
- S. SAGUCHI. Studies on the glandular cells of the frog's pancreas. Five plates..... 347
- FREDERIC T. LEWIS. The course of the Wolffian tubules in mammalian embryos. Thirteen figures..... 423
- WILLIAM H. F. ADDISON. Histological study of the spleen of the rabbit under heightened phagocytic activity. Six figures (one plate)..... 437



THE HISTOLOGY OF THE UMBILICAL CORD OF THE PIG, WITH SPECIAL REFERENCE TO THE VASCULO- GENIC AND HEMOPOIETIC ACTIVITY OF ITS EXTEN- SIVELY VASCULARIZED CONNECTIVE TISSUE

H. E. JORDAN

Department of Anatomy, University of Virginia

FIFTEEN FIGURES

The umbilical cord of the pig differs markedly from the human cord in that it is extensively vascularized, its connective tissue maintains throughout the gestation period largely its original embryonal character, and vasculogenic and hemopoietic activity persist to full term.

The material upon which this investigation is chiefly based is a complete cord, 4 cm. in length, from a fetus of 16-cm. length. This fetus was secured in utero at the abattoir and preserved in 10 per cent formalin. Reckoned by length, it lacked between one and two weeks of full term. Portions of the cord from the proximal end, the middle, and the distal end, were imbedded both in celloidin and in paraffin. Serial sections were cut from the paraffin blocks and stained with hematoxylin and eosin. Some of the celloidinsections were similarly stained; others were stained with resorcin-fuchsin and counterstained with picric-acid-fuchsin, for a study of the elastic and collagen fiber content. A second specimen of a nearly full-term cord, for which I am indebted to Prof. George S. Huntington, was used for comparison. Cords of pig embryos from 9 to 21-mm. length and five full-term and three fetal (three to seven months) human cords, variously fixed and stained, were also employed for comparative study.

Though primary interest centers upon the vasculogenic and hemopoietic activity of the connective tissue, it seems desirable to preface the description and discussion of these phenomena

with a brief description of the comparative histology of this cord. Compared with the human cord it is very short, of considerably lesser girth, and only slightly twisted. It has the same light gray, pearly appearance, and feels of about the same consistency. In transverse section it has an irregularly oval shape (fig. 1), measuring 5 by 7 mm. Its three main blood-vessels have an approximately equal caliber and thickness of wall. It contains a large open allantoic duct and remnants of the occluded yolk-stalk. The connective tissue contains many arterioles, venules, and capillaries. Only one of the post-embryonic human umbilical cords in my collection, a full-term specimen, contains any blood-vessels besides the usual umbilical arteries and vein. In this cord occurs a venule of considerable size, lying near the surface and completely filled with red blood-corpuscles. The human umbilical cord is typically non-vascular except for an occasional capillary at the extreme proximal end. None of my sections of these eight human cords contains any vestige of the allantois. One cord contains a small, still patent yolk-stalk; three contain a double, occluded yolk-stalk remnant. One of the full-term cords of the pig also contains a double occluded yolk-stalk (figs. 1 and 3), the other only a single, small, occluded remnant in only a few sections. In one of the human cords the persistent, double, occluded yolk-stalk is enveloped by a double layer of smooth muscle, an inner longitudinal and an outer thinner circular layer.

THE UMBILICAL ARTERIES AND VEIN

In the cord of the pig the wall of the umbilical arteries only contains circularly disposed smooth-muscle cells, more compact centrally; the vein in one of the two specimens contains also scattered, longitudinally placed cells beneath the intima. The disposition of the muscle differs from that in the human cord where the arteries and the vein contain, in addition to the chief circular layer, also a thin internal longitudinal layer and scattered bundles of longitudinally arranged cells externally. With regard to the elastic tissue content also, the pig's cord differs sharply from the human cord. The arteries of the latter lack

an internal elastic membrane, but several muscle layers beyond the tunica intima the elastic tissue forms complete fenestrated membranes through many layers; toward the periphery of these vessels the elastic tissue only occurs as scattered delicate fibrils. The vein, on the contrary, contains a very robust internal elastic membrane, while through the central half of the wall occur relatively coarse scattered fibers. In the pig's cord neither arteries nor vein contain an internal elastic membrane. The elastic fibers are practically limited to the inner half of the wall, only very delicate and widely scattered fibrils occurring peripherally. In the arteries the elastic tissue forms membranes for from three to five layers beyond the central two or three layers. Considerable variation occurs with regard both to the amount and the disposition of both the smooth muscle and the elastic tissue constituents of the wall of the umbilical vessels both in the pig's cord and the human cord.

ECTODERM

The covering ectoderm constitutes a stratified epithelium of generally four layers of cells (fig. 2). In certain restricted areas the epithelium only consists of three layers of cells, in others of as many as eight layers of cells. This epithelium resembles the transitional rather than the stratified squamous type. It is comparable to the thicker portions of the epidermis of the three-month human fetus, which consists of from four to six layers of cells, including a superficial periderm. It differs from the ectoderm of the full-term human cord, which includes only two or three layers of flattened keratized cells. It differs also from the continuous abdominal ectoderm in that the latter includes about eight layers of cells, all of which, except the basal cuboidal layer, consist of greatly flattened cells. Small patches of partially fused, keratized cells occur in five different regions of the section here shown. The lowermost layer of the epithelium consists of cuboidal cells; the outermost variously of thick, rectangular, flattened or dome-shaped peridermal cells; the intervening layers include polyhedral and stout fusiform types. In those portions

where the epithelium consists of more than four layers, the one next the basal cuboidal layer is generally composed of more flattened cells. The basal layer seems to rest directly upon the adjacent connective tissue, without the intervention of a definite basement membrane. After picric-acid-fuchsin counterstain, however, a narrow subepithelial layer of the connective tissue stains more deeply red.

None of the cells contains mitotic figures. An occasional cell of the superficial layer contains two or even four nuclei or a nucleus in process of fission. The nuclei of the cells of the basal layer are of spheroidal shape and contain a clear, lightly staining nucleoplasm and a distinct granular reticulum. These cells are completely filled with a slightly basophilic cytoplasm. The nuclei of the several outer layers are irregular in shape and they have a homogeneous, cloudy, more deep-staining character, and the nuclear wall is generally wrinkled. The cytoplasm of the cells of the intermediate layers is aggregated next the cell wall so that the cell appears hollow. This condition is probably a fixation artifact. The nucleus almost invariably lies next the outer wall, as if moved by currents passing toward the surface of the ectoderm. The cells of the outermost layer are again completely filled with an acidophilic cytoplasm. The latter is keratized to an extent which could resist the action of the fixation currents that caused the peripheral shrinkage and central excavation of the cells of the intermediate layers.

YOLK-STALK

The yolk-stalk remnant of one of the two practically full-term specimens of the pig's cord, and of four of the specimens of human cord used for comparative study, is a double structure. In the specimen of the pig's cord the two portions are of nearly equal size (fig. 3). They are approximately circular in outline and perfectly solid. The cells of the peripheral layer are squamous or very low cuboidal. The more central cells are polyhedral or spheroidal. The cells next the outermost layer are generally flattened and appear fusiform in longitudinal section. About

twelve cells occupy the diameter of each of the two elements. Most of the central cells appear hollow, the nuclei having become moved to one side, almost invariably to that side nearest the center of the structure. These cells have a superficial resemblance to fat cells. The hollow condition is probably the result of the coagulative action of the fixing fluid upon the delicate cytoplasm. A few of the cells appear keratized, and are acidophilic in staining reaction, and solid. The nuclei of the outermost cuboidal cells are deep-staining, granular, greatly elongated bodies. Those of the more central cells have a generally irregular shape with wrinkled contour and a generally non-granular homogeneous nucleoplasm. No mitotic or amitotic figures can be detected. Each member of the double structure is enveloped by a very thin inner connective-tissue theca, forming a delicate, fibrillar, nucleated basement membrane. Both are inclosed in a common, more external theca. The intervening partition only consists of the fused basement membranes.

The fact that four of the five specimens of human cords used in connection with this study also contain a double yolk-stalk indicates that this doubling is a common condition. Two explanations suggest themselves: 1) That the doubling is due to the partition of the originally single stalk by the ingrowth of a connective-tissue septum related to the regressive changes by which the stalk becomes obliterated. 2) That the 'doubling' is only apparent, it being due in section to a sharp turning of the stalk in certain regions. The latter interpretation is supported by the evidence from one of the human cords: here one of the 'halves' is cut transversely, the other half is very obliquely cut, and the two are in continuity. In other words, the condition is such as would result if the section passed obliquely through the proximal end of one of the limbs and the connecting loop of a U-shaped structure. Opposed to the latter interpretation, however, is the fact that in the specimen of the pig's cord here described a common connective-tissue sheath envelops both moieties.

ALLANTOIC DUCT

The allantoic duct (fig. 1, *All.*) is shown highly magnified in figure 4. It has an irregularly oval shape in cross-section. Its wall is thrown into deep folds. Within the depth of the folds the epithelium consists of a single layer of cuboidal or even squamous cells, comparable to its condition throughout in the 21-mm. fetus; over the crests the epithelium is of the stratified columnar type, consisting of from three to four layers of cells. No distinct basement membrane can be discerned other than as indicated by the deeper red color of the immediately subjacent connective tissue after picric-acid-fuchsin counterstain. The nuclei have an irregularly oval form; their wall is wrinkled, and the nucleoplasm generally lacks a distinct network or granules. A number of the cells are hollowed out centrally. The cells next the lumen have a more condensed, probably slightly keratized, broad distal border. The enveloping connective tissue is less differentiated and denser than in any other portion of the section. It resembles early embryonic connective tissue or young mesenchyma. It contains many vasofactive cells ('angioblasts'), and one large blood-island (*B. I.*), which will be described below.

THE CONNECTIVE TISSUE

The character of the connective tissue varies in different portions of the transverse section (compare figs. 2, 3, 4, and 5). In the region immediately surrounding the allantoic duct (fig. 1) it is least differentiated. Here it is compact and resembles embryonic connective tissue or young mesenchyma (fig. 4). In this region also are numerous vasofactive cells (fig. 15). Along the peripheral border of the specimen the connective tissue is somewhat more differentiated and represents an older type of mesenchyma (fig. 2). Here the cells have generally a stellate or fusiform shape and are more widely separated. In this region also the capillaries are most abundant; these for the most part lie along the radii of the section and appear to be growing towards the ectodermal covering. Here also are found abundantly initial stages in the formation of the blood channels (figs. 8, 9, and 10).

In the area between the lower umbilical artery on the left and the vein on the right, the connective tissue is in part of the type characteristic of the human cord; that is, it is typical mucous connective tissue, but with an occasional capillary. In this region also occur small bundles of collagen fibrils. The area around the yolk-stalk contains vascular connective tissue of an intermediate type, with occasional collagen fibers (fig. 5). In the narrow space between the two umbilical arteries, extending to a point below the allantoic duct, there occur several blood-islands (figs. 6 and 7). About midway between the central umbilical blood-vessels and the periphery occur numerous arterioles and venules. Occasionally these are arranged in pairs (fig. 5). These vessels terminate in capillaries. The arterioles are enveloped by a thin layer of smooth muscle; the wall of the venule only consists of endothelium resting upon the slightly more condensed enveloping connective tissue.

Certain of these smaller blood-vessels can be traced into connection with the umbilical arteries and the vein at their proximal (fetal) end. This is true both in the case of the younger cords (of embryos from 9 to 21 mm.) and in those near full term. In the 21-mm. fetus branches from the proximal end of the umbilical vein can be seen entering the body wall as well as the connective tissue of the cord. It may be confidently assumed that all of the blood-vessels, including the numerous capillaries, connect with vessels which ultimately connect with the main umbilical vessels proximally. But not all of these vessels are properly interpreted as *vasa vasorum*. Undoubtedly many function thus, as is indicated by the numerous capillaries directed towards the walls of the umbilical arteries and vein; but others are equally certainly nutrient vessels for the allantoic duct, the ectodermal covering, and the general connective tissue. Nor can the assumption be properly made that all of these vessels arise by sprouting from originally direct umbilical branches. If the capillaries grew exclusively by sprouting, their tips should show mitotic figures. Mitotic figures are practically absent in these capillary terminals. On the contrary, these tips seem to fuse with the general connective tissue, the cells of which become hollowed out, arrange

themselves in line with the capillaries and ultimately become incorporated as part of the capillary network. In the full-term condition of the cord, blood-vessels arise in a manner identical with their primary origin in the original body-stalk, and become secondarily connected with the preexisting vascular net. The connective tissue of the full-term cord maintains the primitive vasculogenic mode by which the primitive blood-vessels were formed. The full-term cord is relatively much more extensively vascularized, and it consists of connective tissue largely of a less differentiated type than the cord of the 21-mm. fetus. Since the larger blood-vessels extend to the distal end of the cord, it may be inferred that they supply also the proximal pole of the allantois.

VASCULOGENESIS AND HEMOPOIESIS

In the description of the mode of vasculogenesis illustrated in this cord, we may begin most conveniently with the stage represented by the cell of figure 8. This cell has the general characteristics of an irregular mesenchymal cell. Three vacuoles can be seen to the right of the nucleus. A later stage may be represented by the upper cell of figure 9. Here the cell is binucleated, and the originally smaller discrete vacuoles have presumably coalesced to form a single large vacuole, the precursor of the initial capillary lumen. The appearance of the lumen has effected a modification of one of the nuclei so that it begins to assume endothelial features. In figure 10 is shown a still later phase of vasculogenesis. Here, moreover, the more typical endothelial 'cell' has taken on hemoblast features and has differentiated an erythroplastid (*ep.*) intracellularly. Figure 11 may be conceived to represent a transection of the cell of figure 9 or 10. Cells like those of figures 8, 9, 10, and 11 are very numerous in the more peripheral regions of the cross-section. Figure 12 illustrates a binucleated cell with essentially mesenchymal features, which has differentiated an erythroplastid and a lumen centrally. The cell shown in figure 13 has the nuclear and cytoplasmic characteristics more of a young hemoblast. This cell represents a mesenchymal cell which has rounded up and differen-

tiated into a hemoblast, and subsequently differentiated an erythroplastid intracellularly.

The mesenchymal cells of this primitive 'mucous' connective tissue may apparently undergo any one of several types of differentiation: 1) They may separate from the mesenchymal syncytium, round up and differentiate into potential hemoblasts, which may lie freely among the undifferentiated mesenchymal cells, but apparently never in this condition directly metamorphose into erythroplastids; but grouped into blood-islands, about which the adjacent mesenchyme differentiates into endothelium, they develop into erythroblasts (fig. 7). 2) They may become bi- or multinucleated and, as hemogenic giant-cells, differentiate erythrocytes intracellularly (figs. 6, *e*, and 15, *f*). 3) A mesenchymal cell may acquire a lumen and join with other cells to form an initial capillary, incidentally differentiating also erythroplastids intracellularly (fig. 12). Erythroplastids may originate intracellularly also in young endothelial cells (fig. 10). Hemoblasts can, therefore, apparently differentiate into erythrocytes only when inclosed by endothelium; or in the multinucleated condition, hemoblasts can differentiate intracellular erythrocytes. The latter phenomenon is essentially like that where a hemoblast is inclosed by endothelium.

Figures 6 and 7 illustrate an earlier and later stage, respectively, in the differentiation of a blood-island. In figure 6 the blood-island is still largely a syncytium. However, endothelium can be seen forming on its surface, and several of its cells are taking on erythroblast ('megaloblast') features (*a*, *b*, and *d*). The cell *d* has developed a large vacuole at one pole; this vacuole may form part of the subsequent lumen. Cell *e* has differentiated an erythrocyte. Several intercellular spaces have appeared in the syncytium; these are the forerunner of the subsequent lumen, to which certain intracellular spaces may also contribute. In figure 7 the endothelium and the lumen are developed further, and the hemoblasts are mostly in the erythroblast stage and are generally separated from each other by cell membranes.

It seems desirable at this point to indicate the chief differences, nuclear and cytoplasmic, between the young mesenchymal

cell, young endothelial cell, hemoblast, erythroblast ('megaloblast'), and the erythrocyte. The mesenchymal cell has in general a light-staining, spheroidal or oval nucleus with a delicate reticulum; its cytoplasm contains delicate fibrillae. The young endothelial cell has a similarly light-staining, but generally more elongated nucleus; and its cytoplasm is less distinctly fibrillar. The hemoblast is generally spheroidal in shape, but it may assume various forms due to its ameboid capacity; its nucleus also generally has a spheroidal shape, but it contains a more distinct and more granular network, and the cytoplasm appears homogeneous. The nucleus of the young erythroblast ('megaloblast') has a spheroidal shape, a robust chromatic membrane, a generally deeper-staining nucleoplasm; and it contains one or several small nucleoli and numerous granules scattered over its delicate reticulum. Its cytoplasm is distinctly granular, and it stains deeply in eosin. The granular condition of the cytoplasm of the erythroblast is the most distinctive mark of this cell. This cell corresponds to the megaloblast of certain writers. The erythrocyte has a considerably smaller, generally deeper-staining, spherical nucleus, and a clear cytoplasm delimited by a distinct membrane (figs. 6, *e*, and 15, *b* and *e*). The erythroplastid has in contrast a brownish-yellow color.

In figure 15 (*a* to *i*) are illustrated various vasofactive and hemogenic cells. In fact, as these figures clearly indicate, vasofactive and hemogenic activities are intimately associated. The cell *a* may be regarded as at the stage of a late hemoblast or a young erythroblast. The cell *b* is similar, but has produced an intracellular erythrocyte. Cell *c* has developed a lumen, and it has differentiated an inclosed erythroplastid. Cell *d* is essentially a young endothelial cell with vestiges of cytoplasmic hemoblast features. Cell *e* has become essentially a young endothelial cell with an included small erythrocyte and an erythroplastid. Cells *g* and *i* are essentially hemoblasts ('angioblasts') which have become differentiated into binucleated endothelial cells. Cells *f* and *h* should be interpreted together; *h* is essentially a multinucleated hemoblast or small 'giant-cell,' one of whose nuclei is apparently undergoing amitotic division;

f may be regarded as a later stage in the intracellular erythrocytogenic function of *h*, in which two of the nuclei and their enveloping cytoplasm have differentiated into erythroplastids (*ep*). Cells *h*, *f*, *b*, and *e* of figure 15 and *e* of figure 6, when considered in common, demonstrate that erythroplastids in these vasofactive cells do not arise as such out of the cytoplasm, but under the direct influence of a nucleus of a bi- or multinucleated hemoblast ('hemogenic giant-cell'). The absence of free erythrocytes and erythroplastids in the regions from which these cells are taken contravenes any suggestion that the intracellular red blood-corpuscles should be interpreted in terms of phagocytosis.

Figures 12 and 14 supply similar evidence. The erythroplastid of figure 12 may appear to have arisen directly from the cytoplasm of this vasofactive cell. But figure 14 shows an essentially similar cell at a slightly earlier stage of differentiation, in which the chief nucleus has liberated a small bud. About this bud an erythrocyte and a lumen may be conceived to originate in the manner shown in *e* of figure 15, and so lead to a condition like that of figure 12. In other words, the cells of figures 12 and 14 are essentially multinucleated hemoblasts. In this sense multinucleated hemoblasts, hemogenic giant-cells, and blood-islands ('angioblasts') are fundamentally and potentially alike; that is, they are essentially multiple erythroblasts enveloped by a layer of potential endothelium.

DISCUSSION

From the foregoing description it will be clear that the connective tissue of the full-term umbilical cord of the pig is extensively vascularized and that it is actually for the most part still in the condition of young mesenchyma or embryonal connective tissue. The conditions are essentially similar to those described for the body-stalk of very young human embryos. The question arises whether the connective tissue of this cord is in the primitive mesenchymal condition because it is vascularized or whether it is vascularized because the connective tissue is in the condition of undifferentiated mesenchyma. Since the blood-vessels have apparently arisen to a considerable extent in situ,

the latter interpretation would seem to be the correct one; that is, that this cord has maintained early embryonic conditions, like that of its anlage, the body-stalk, and in consequence retained its original capacity for vasculogenesis and erythrocytogenesis. The cause of this maintenance of early embryonic vasculogenic and hemopoietic potentialities, especially singular in connection with the advanced developmental condition of the umbilical arteries and vein, and the several small areas of fully differentiated mucous connective tissue, remains for the present undetermined. It is most probably associated with the large functional allantois, but the nature of this association is not clear. The relatively highly developed character and healthy condition of the covering ectoderm may be secondary to the presence of the large number of capillaries in the subjacent connective tissue.

Though this study can throw no light on the cause of the vascularized condition of the umbilical cord of the pig, the intense hemopoietic activity of its connective tissue supplies valuable data with respect to the initial steps in vasculogenesis. This is the chief point of value in this specimen. In this connection interest centers upon the mesenchymal cell, which becomes hollowed out to form an endothelial cell and at the same time differentiates erythrocytes (figs. 6, 12, 13, and 15). This cell combines the functions of an endothelioblast and an erythroblast. The process appears to be quite similar to that first described by Ranvier⁸ ('74) in the mesentery of the seven-day rabbit and in the great omentum of the cat, and independently by Schaefer¹⁰ ('74) in the subcutaneous tissue of the new-born rat, and subsequently confirmed by other workers on other forms. Ranvier named the cells concerned in the process 'vasoformative cells.' According to these investigators, mature (non-nucleated) 'erythrocytes' of greatly varying sizes are formed directly within the protoplasm of connective-tissue cells (vasoformative cells) by a process involving the coalescence of scattered granules of hemoglobin into condensed globules, which then come to lie in vesicles within the cells, the precursors of the capillary lumen.

The method of erythrocytogenesis here described for this specimen of umbilical cord of the pig, however, differs radically from that described by Ranvier and Schaefer, in that the erythroplastid in this case differentiates from a nucleated portion of a vasofactive cell (figs. 6, *e*; 15, *b* and *e*, and 14). That is, the erythroplastid differentiates from a typical erythroblast in the usual mode. The nucleus of the erythrocyte disappears by karyolysis (fig. 15, *e*). This is apparently a very rapid process, since it can be detected in only relatively few cells. If one considered only cells like those of figures 12 and 13, the process would appear to be identical with that described by Ranvier and Schaefer; but figures 15, *b*, *e*, *h*, and *f* demonstrate the essential difference.

Certain investigators (Spuler,¹² Fuchs,³ et al.) have expressed dissent from Ranvier's and from Schaefer's interpretation of their observations; they explain these phenomena, the occurrence of which they confirm, in terms of regressive changes and phagocytosis. They believe that the so-called 'vasoformative cells' are either isolated portions of a disintegrating embryonic vascular plexus or erythrophagic connective tissue cells. It is obvious that since the vasofactive phenomena here described for the umbilical cord of the pig are fundamentally different, while superficially apparently identical with those described by Ranvier and Schaefer, the criticisms of Spuler and Fuchs have no pertinancy to this case. Moreover, the red cells involved in this process in the umbilical cord of the pig show no distinct nuclear or cytoplasmic marks of degeneration. This cord, except for the almost complete absence of mitotic figures, appears in perfectly healthy condition. No free erythrocytes are available for phagocytosis in the regions here described. There is no indication of a disintegration of blood-vessels; on the contrary, the full-term cord is relatively more extensively vascularized than the cord of the 21-mm. fetus. Finally, and most significantly, this intracellular mode of erythrocytogenesis is strictly comparable to that described for other hemopoietic organs, e.g., yolk-sac of 10-mm. pig embryo,⁵ yolk-sac of mongoose embryos,⁶ and red bone-marrow.⁷

The matter may be summed up with figures 15, *a*, *b*, and *e*, and 15, *h* and *f*. A connective-tissue cell becomes transformed into a hemoblast (erythroblast) with vasofactive capacity. This cell may become bi- or multinucleated. One or several of the nuclei with their enveloping cytoplasm may differentiate into erythrocytes. Meanwhile a lumen appears within the cell, and one or two of the original nuclei may persist as the nuclei of the peripheral cytoplasm of the differentiating cell, which now forms the endothelial wall of the initial capillary. In later stages in the yolk-sac and in the red bone-marrow generally, the peripheral 'endothelial' layer of the original 'vasofactive' cell disappears, thus freeing the intracellularly differentiated erythrocytes into the confining blood spaces. The mesenchymal cell thus appears endowed with divers hemogenic potentialities: it may become an endothelial cell or a hemoblast (erythroblast). The endothelial cell may secondarily differentiate into a hemoblast. These hemoblasts may differentiate into erythroblasts or, as multinucleated cells, they may differentiate both intracellular erythrocytes and a potential endothelial cell. These facts demonstrate the very close relation between mesenchyme, endothelium, and hemoblasts.

Sabin⁹ records a similar vacuolization of mesenchymal 'angioblasts' in the living blastoderm of the two-day chick embryo grown in Locke's solution, by which the blood-vessel lumen forms. But these observations do not justify her conclusion that they prove "that the lumen of a blood-vessel is intracellular" (p. 200). The data supplied by the umbilical cord of the pig show that the definitive lumen of the blood-vessel derived from a blood-island is of both inter- and intracellular origin.

This brings us to the matter of the factors which determine whether the mesenchymal cell shall become an endothelial cell or a hemoblast, and relates this investigation to the discussion regarding theories of hemogenesis, that is, whether blood development proceeds according to the monophyletic or the polyphyletic mode. This much seems certain regarding this tissue: single hemoblasts, freed from the mesenchyme and wandering within its meshwork, do not differentiate into erythrocytes. It

is only when such a cell becomes inclosed by endothelium that it differentiates into a red blood-cell. Thus a group of such cells may form and in consequence produce pressure upon the surrounding mesenchyme, which then becomes transformed into endothelium. Under these conditions the enveloped hemoblasts become erythrocytes (figs. 6 and 7). Such endothelium is simply an adaptive form of mesenchyme, as originally maintained by Huntington⁴ and by Schulte,¹¹ and it may subsequently return to mesenchyme, remain as endothelium, or differentiate hemoblasts either intra- or extraluminally. Endothelium, accordingly, develops originally by two different methods, both clearly represented in the specimen under consideration: 1) By adaptation of mesenchyme about a blood island; 2) by vacuolization of vasofactive mesenchymal cells ('angioblasts').

A point of special interest concerns the fact that the nucleated periphery of a multinucleated hemoblast supplies the same favorable conditions or factors for determining erythrocytogenic differentiation as an endothelial wall. This phenomenon becomes intelligible when we consider that both endothelial cells and hemoblasts are only slightly modified mesenchymal cells, and that the latter, as vasofactive cells, may become hollowed out to form the lumen of an original capillary or differentiate intracellular erythrocytes. The central fact here pertains to the obviously very minute difference between the environmental conditions or stimuli that determine whether the same cell (the potential hemoblast, 'vasoformative cell', or 'angioblast') shall become an endothelial cell or an erythroblast. This suggests that also the factors which determine whether the hemoblast shall become a leucocyte or an erythrocyte, in accordance with the monophyletic theory of blood-cell origin, are similarly relatively subtle and of minute degree. Original confinement by endothelial walls furnishes the stimulus which determines erythrocytogenesis; extravascular differentiation leads to granulopoiesis. As shown by the recent experiments of Danchakoff,^{1,2} the original polyvalency of the hemoblast, however, is lost by the erythroblast, and this degree of differentiation is irreversible. An erythroblast freed from its endothelial confines and

thrown into the surrounding mesenchyme, as in the allantoic spleen grafts of Danckhoff, will not differentiate into a leucocyte, but into an erythrocyte. A mature endothelial cell does not normally, as originally, differentiate into a hemoblast. And an extravascular hemoblast which is in process of differentiation into a granulocyte apparently cannot redifferentiate into an erythrocyte after it has wandered into the blood-vessel lumen.

SUMMARY

The results of this study of the umbilical cord of the pig, which maintains to full-term largely the embryonic condition of the original body-stalk, emphasize the polyvalent capacity of the mesenchymal cell and its hemoblast derivative, and supply further evidence in agreement with the monophyletic view of hemogenesis. The multinucleated hemogenic giant-cell furnishes the same essential stimuli for the differentiation of erythrocytes as does an inclosing endothelium. It is comparable to a blood-island, and produces erythrocytes intracellularly in a manner similar to that by which erythrocytes separate out of a blood-island syncytium. This tissue demonstrates also the origin of endothelium both by adaptation of mesenchyme about a blood-island and by vacuolization and fusion of vasofactive mesenchymal cells. It shows, moreover, that the lumen of the original blood-vessels includes both inter- and intracellular contributions.

LITERATURE CITED

- 1 DANCHAKOFF, VERA 1918 Cell potentialities and differential factors considered in relation to erythropoiesis. *Am. Jour. Anat.*, vol. 24, p. 1.
- 2 1918 Equivalence of different hematopoietic anlagen (by method of stimulation of their stem-cells). II. Grafts of adult spleen on the allantois and response of the allantoic tissues. *Am. Jour. Anat.*, vol. 24, p. 127.
- 3 FUCHS, H. 1903 Über die sogenannte "intracelluläre" Entstehung der roten Blutkörperchen junger und erwachsener Säuger. *Anat. Hefte*, Bd. 22, S. 95.
- 4 HUNTINGTON, G. S. 1914 The development of the mammalian jugular lymph sac, of the tributary primitive ulnar lymphatic and of the thoracic ducts from the viewpoint of recent investigations of vertebrate lymphatic ontogeny, together with a consideration of the genetic relations of lymphatic and hemal vascular channels in embryos of Amniotes. *Am. Jour. Anat.*, vol. 16, p. 259.
- 5 JORDAN, H. E. 1916 The microscopic structure of the yolk-sac of the pig embryo, with special reference to the origin of the erythrocytes. *Am. Jour. Anat.*, vol. 19, p. 277.
- 6 1917 Hemopoiesis in the mongoose embryo, with special reference to the activity of the endothelium, including that of the yolk-sac. Pub. 251 of the Carnegie Institution of Washington, p. 291.
- 7 1918 A contribution to the problems concerning the origin, structure, genetic relationship and function of the giant-cells of hemopoietic and osteolytic foci. *Am. Jour. Anat.*, vol. 24, p. 225.
- 8 RANVIER, L. A. 1874 De développement et de l'accroissement des vaisseaux sanguins. *Arch. de Physiol.*, T. 6, p. 429.
- 9 SABIN, F. R. 1917 Preliminary note on the differentiation of angioblasts and the method by which they produce blood-vessels, blood plasma and red blood cells as seen in the living chick. *Anat. Rec.*, vol. 13, p. 199.
- 10 SCHAEFER, E. A. 1874 The intracellular development of blood corpuscles in mammals. *Mon. Micr. Jour.*, vol. 11, p. 261.
- 11 SCHULTE, H. VON W. 1914 Early stages of vasculogenesis in the cat (*Felis domestica*) with special reference to the mesenchymal origin of endothelium. *Memoir, Wistar Inst. Anat. and Biol.*, no. 3, pp. 1-92.
- 12 SPULER, A. 1892 Über die "intracelluläre" Entstehung roter Blutkörperchen. *Arch. f. mikr. Anat.*, Bd. 40, S. 530.

PLATE 1

EXPLANATION OF FIGURE

1 Photomicrograph of transverse section of umbilical cord of pig. The cord is covered with a stratified epithelium from three to eight (generally four) layers thick, resembling somewhat the transitional type. Tufts of keratized cells occur at certain points (*E*). To the right of the allantoic duct (*All*) are the umbilical arteries. The umbilical vein lies below the double remnant of the occluded yolk-stalk (*Y.S.*). At *B.V.* is one of the larger arterioles of the extensively vascularized connective tissue. In the area between the lower umbilical artery and the vein, the connective tissue resembles the mucous type; elsewhere it resembles more young mesenchyme, and contains many capillaries, arterioles and venules (*A.V.*), and also numerous hemoblasts and several typical blood-islands. (Photos. by W. S. Dunn, Cornell University Medical College, N. Y. City. The illustrations were made from the Columbia specimen.) $\times 18$.

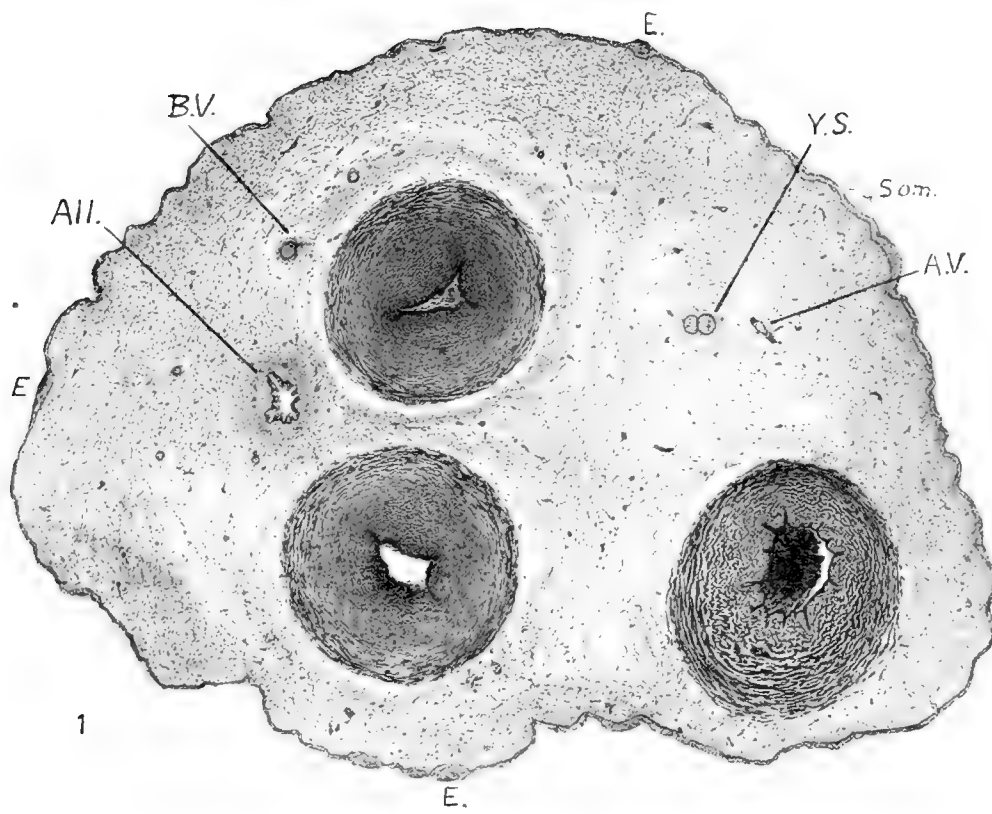
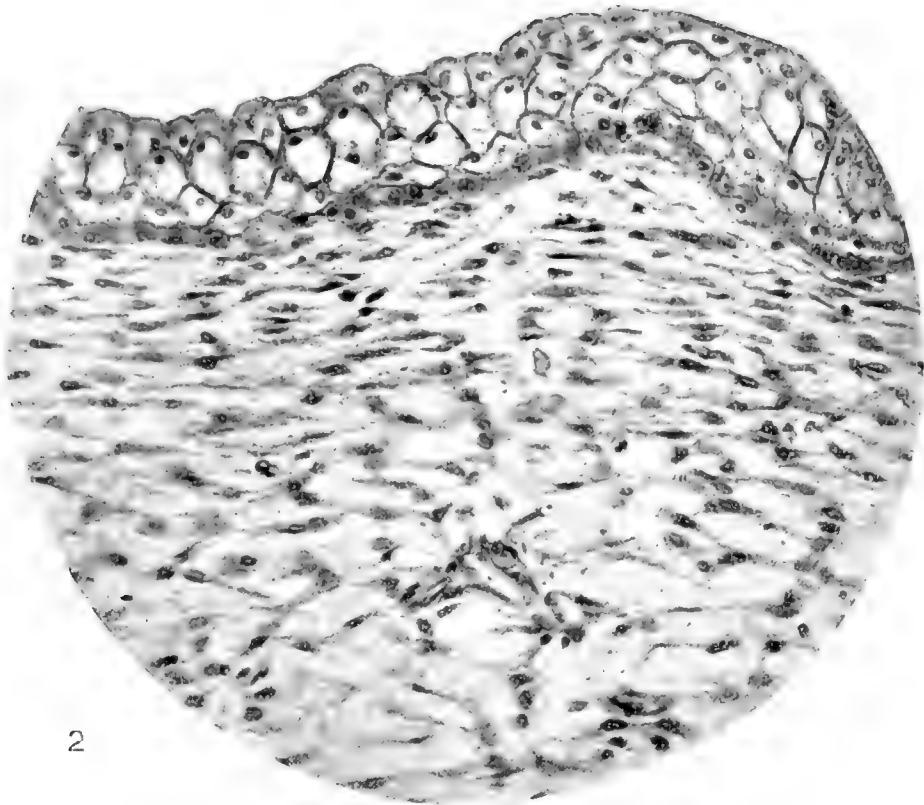


PLATE 2

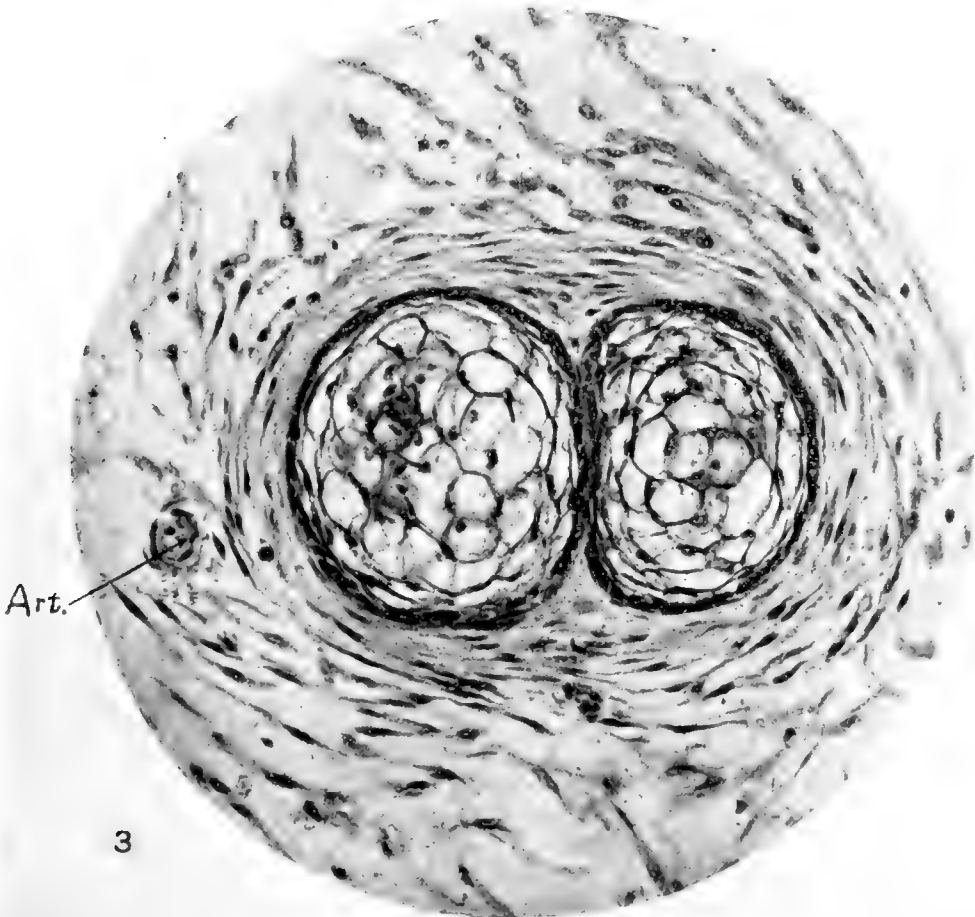
EXPLANATION OF FIGURES

2 Photomicrograph of the ectodermal covering of the cord in the region, *Som.*, of figure 1. It includes four or five layers of cells and resembles transitional epithelium. The lowermost layer is composed of cuboidal cells; the outermost layer includes dome-shaped, rectangular, and flattened peridermal cells; the intermediate layers include spheroidal and polyhedral cells. $\times 300$.

3 Photomicrograph of remnant of yolk-stalk (fig. 1, *Y.S.*). It is double and occluded, and each moiety includes about twelve cells in its diameter. *Art.*, arteriole. $\times 300$.



2



3

PLATE 3

EXPLANATION OF FIGURES

4 Photomicrograph of allantoic duct. The lining epithelium is thrown into folds. In the troughs of the folds the epithelium consists of a single layer of cuboidal or flattened cells; over the crests, of from three to four layers, constituting a stratified columnar epithelium. *Art.*, arteriole; *B. I.*, 'blood-island' of erythroblasts. $\times 235$.

5 Photomicrograph of pair of blood vessels (the branching venule cut obliquely) and the surrounding mesenchyme (region *A.V.* of fig. 1). $\times 300$.

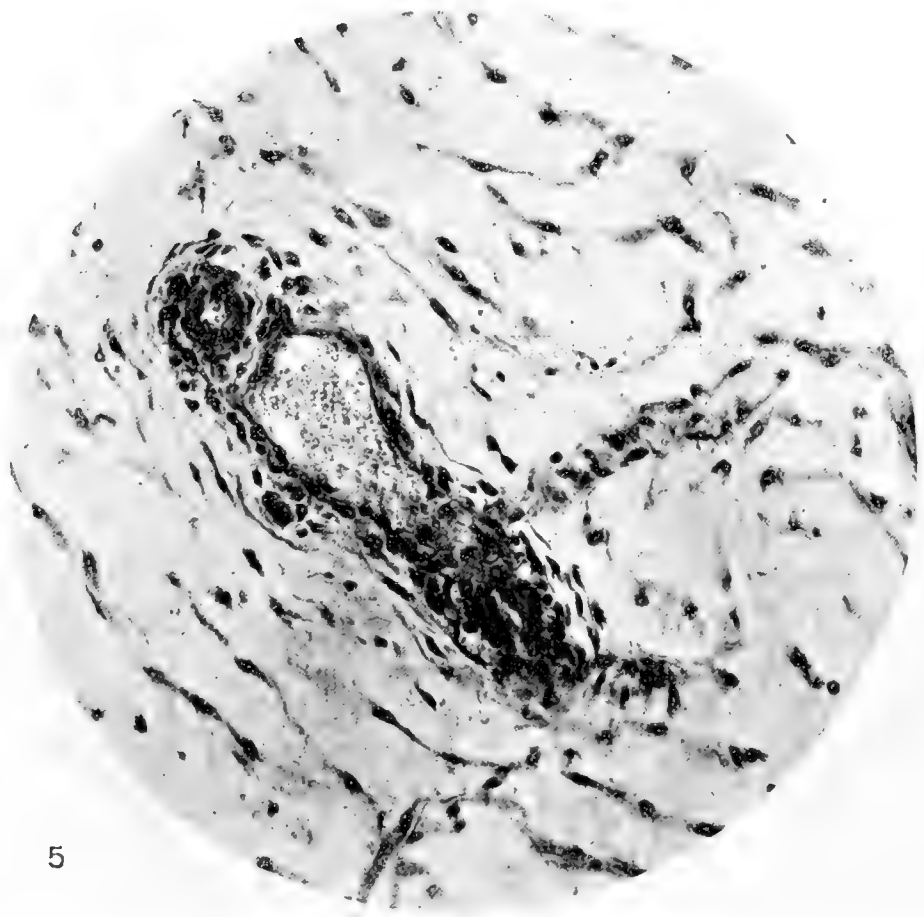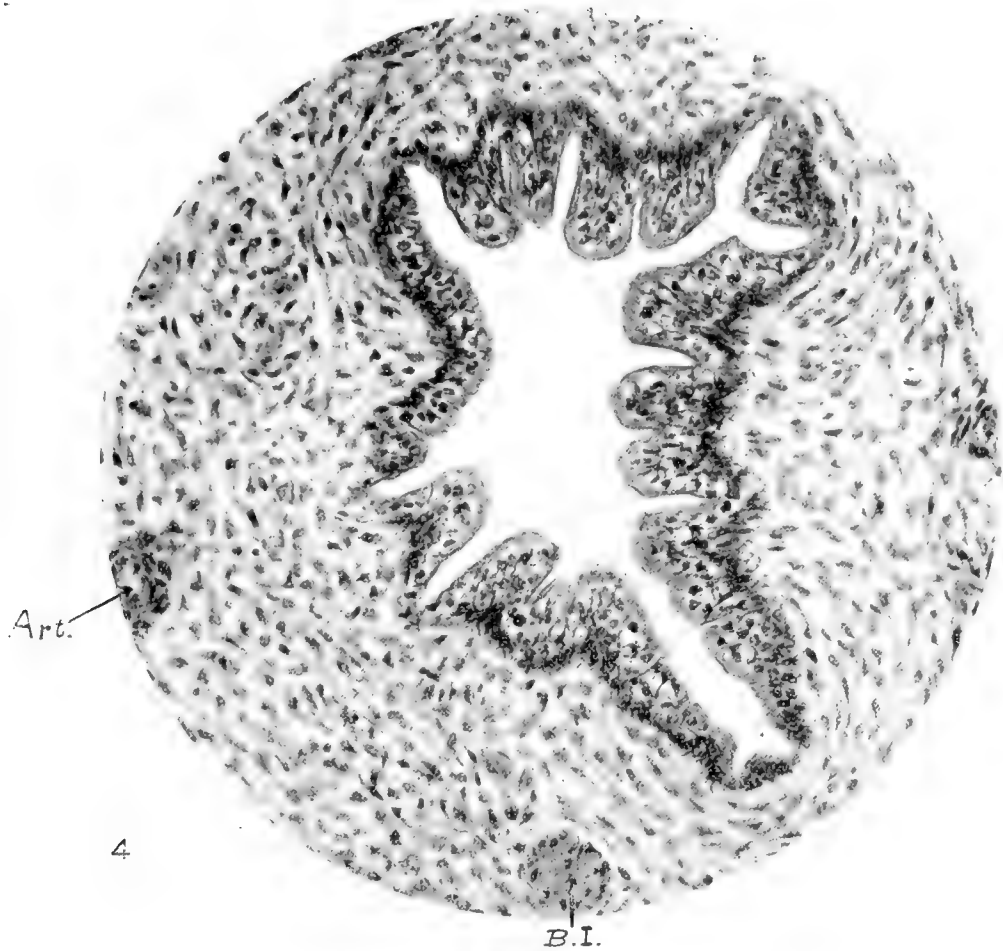


PLATE 4

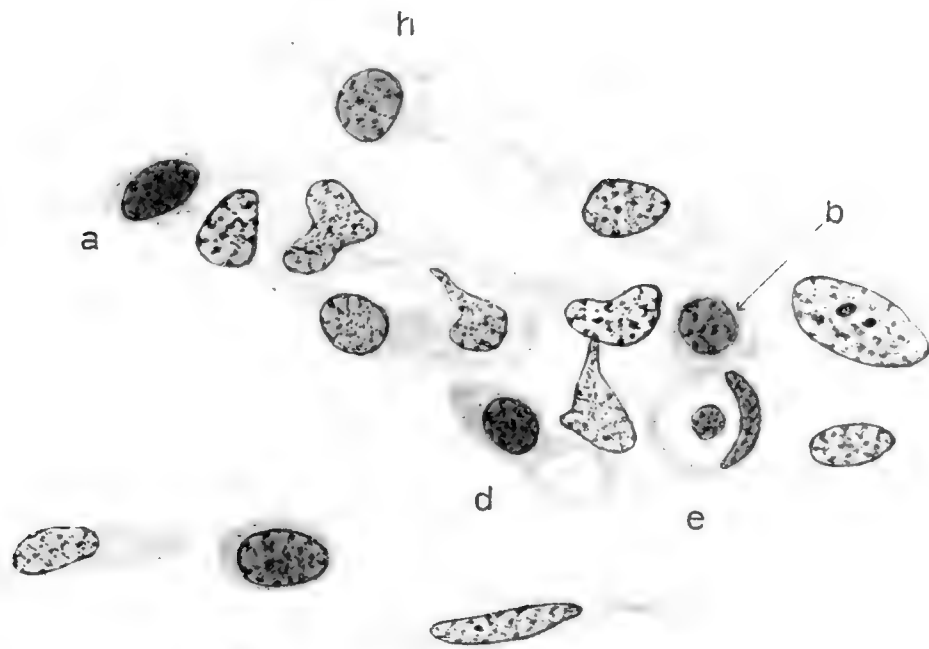
EXPLANATION OF FIGURES

6 Drawing of blood-island, from region just below the allantoic duct (fig. 1, *All.*). Peripherally the cells are becoming differentiated into an endothelium. Centrally the syncytial mass is becoming vacuolated through the appearance of intercellular spaces, and certain of the cells have entered the early erythroblast ('megakoblast') stages (*a* and *b*). One erythroblast (*d*) contains a large vacuole. A hemoblast (*e*) has differentiated an intracellular erythrocyte. A hemoblast (*h*) is separating from the differentiating endothelium. Between the two endothelial cells below, appears another hemoblast. Figures 6 to 9 are magnified 1500 diameters.

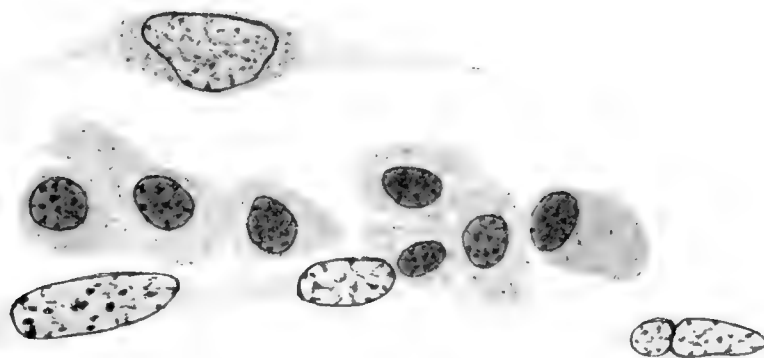
7 Blood-vessel in process of differentiation from the mesenchyme. This drawing is from the region to the right of the allantoic duct between the two umbilical arteries (fig. 1), and includes approximately the middle third of this entire vascular anlage. The forming lumen contains seven young erythroblasts ('megakoblasts'), separating out of an originally syncytial mass.

8 Young vasofactive cell, with generally mesenchymal features and three vacuoles, the precursors of a capillary lumen.


9 Slightly older vasofactive cell with large vacuole, the underlying nucleus assuming endothelial features.



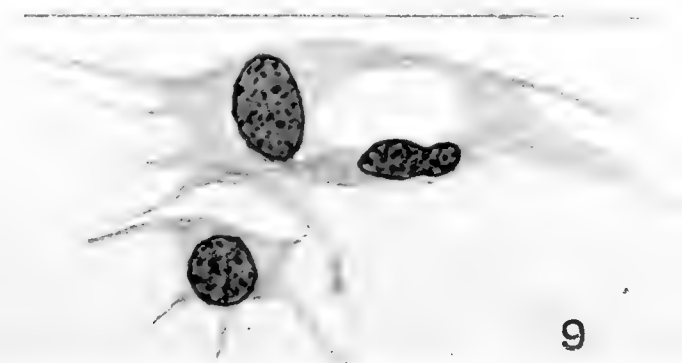
6



7



8



9

PLATE 5

EXPLANATION OF FIGURES

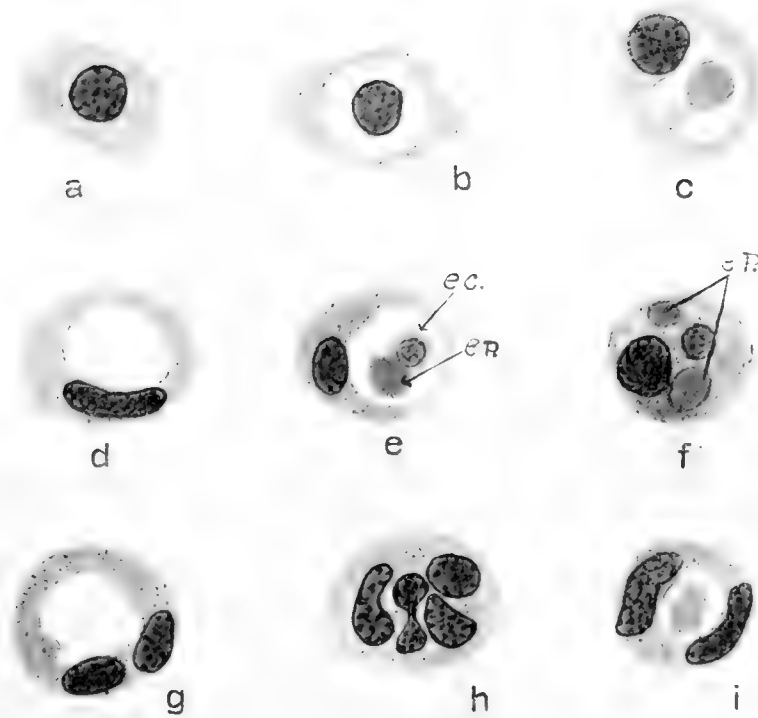
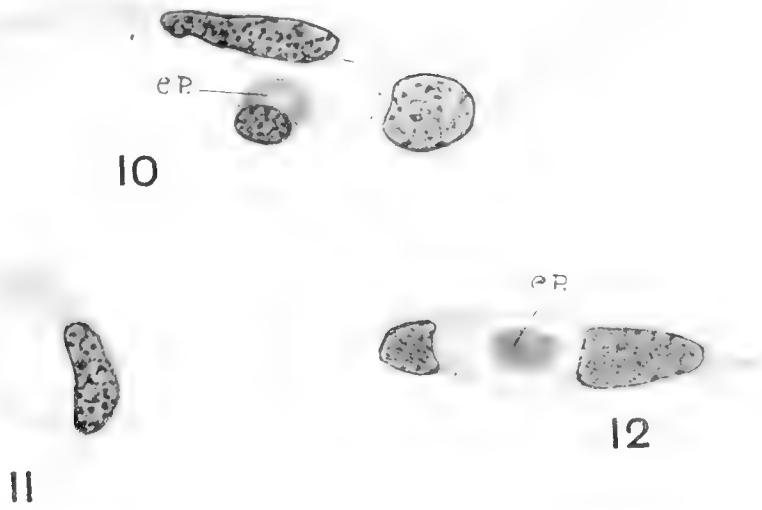
10 Vasofactive cell with three nuclei. The nucleus at the right has original mesenchymal features; the endothelial 'cell' below the lumen has assumed hemoblast features, and has differentiated an intracellular erythroplastid (*ep*). Figures 10 to 15 are magnified 1500 diameters.

11 Vasofactive cell differentiating a lumen. This figure corresponds to a transverse section of figure 10.

12 and 13 Vasofactive cells with an erythroplastid in the lumen.

14 Vasofactive cell in early stage of differentiation from mesenchyme. The cell has in general hemoblast features. The larger nucleus has produced a small bud at the left. From such nuclear buds and their enveloping cytoplasm develop intracellular erythroplastids.

15 (*a* to *i*) Vasofactive mesenchymal cells at various stages of differentiation: *a*) Typical young erythroblast ('megaloblast'). *b*) Hemoblast that has differentiated an erythrocyte intracellularly. *c*) Cell with vascular lumen and an intracellularly differentiated erythroplastid. *d*) Cell with lumen, having assumed endothelial features. *e*) Cell with lumen, containing an erythrocyte (*ec*, 'normoblast') and an erythroplastid (*ep*). *f*) Binucleated cell with two intracellularly differentiated erythroplastids (*ep*). *g*) Cell with lumen and two nuclei, both with endothelial features. *h*) Cell with four nuclei, one apparently in process of amitotic division. The centrally located nuclei with their enveloping cytoplasm may differentiate into erythrocytes. *i*) Binucleated cell, endothelial in character, with lumen containing an erythroplastid.



15

Resumen por el autor, Henry Alexander Murray, Jr.
Colegio de Médicos y Cirujanos, Columbia University.

El desarrollo del asa cardiaca en el conejo, con especial mención
del surco bulbo-ventricular y el origen del
tabique inter-ventricular.

El autor ha estudiado varios embriones de conejo para determinar si la formación del asa cardiaca en esta especie es semejante a la descrita por Schulte en el gato. Los procesos de formación son semejantes en ambas especies en lo referente al origen del asa primaria, que se produce a consecuencia del hundimiento de la hendidura bulbo-ventricular izquierda, y la fusión de los tubos miocárdicos se verifica por la intervención de la placa cardiaca media, que está representada temporalmente por una cresta bien distinta situada en la pared interna del miocardio. En las series de embriones de conejo, sin embargo, esta elevación se oblitera algunas veces por completo y no susministra prueba alguna sobre su intervención en la formación del surco inter-ventricular primitivo.

Translation by José F. Nonidez
Carnegie Institution of Washington

THE DEVELOPMENT OF THE CARDIAC LOOP IN THE RABBIT, WITH ESPECIAL REFERENCE TO THE BULBOVENTRICULAR GROOVE AND ORIGIN OF THE INTERVENTRICULAR SEPTUM

HENRY A. MURRAY, JR.

College of Physicians and Surgeons, Columbia University, N. Y.

SEVEN FIGURES

The process of union of the two lateral cardiac vessels to form the heart has recently been described in detail by Doctor Schulte as exemplified in the series of young cat embryos of the Columbia Collection. It was at Doctor Schulte's suggestion and under his supervision that I undertook to ascertain whether fundamentally the same processes took place in the embryo rabbit.

Earlier investigators had described how the lateral plexuses of blood-vessels, forming into two longitudinal endothelial tubes in the splanchnopleure, unite in the midline to create a cylindrical median structure—the heart; and they considered that during subsequent growth the heart became coiled to accommodate itself within the pericardium. Doctor Schulte's investigation, previously mentioned, showed that it was not such a simple process, but that a number of very interesting factors were responsible for the changes that took place. Through the kindness of Dr. F. T. Lewis in putting at my disposal the beautiful Harvard series of rabbit embryos and by his guidance and suggestions, I was able to study the fusion and subsequent history of the heart in another species. Approximately forty embryos from the Harvard rabbit and Columbia cat series were examined under the microscope and a dozen and a half models were constructed in wax, according to the Born method. The cat embryos were cut in 13.3μ sections, whereas the rabbits were cut in 6μ or 10μ sections, mostly transverse. The thicker sections are less apt to be damaged, pile into better models, and under

some conditions are to be recommended. For the finer details, however, thin sections are naturally the more desirable. The embryos were variously stained. My observations lead me to believe that the development of the rabbit heart tallies in every important respect with that of the cat.

In the accompanying diagram (fig. 1), the schema usually presented to portray the formation of the cardiac loop may be contrasted with a parallel series of figures representing Doctor Schulte's findings. Note that the initial and final stages in each

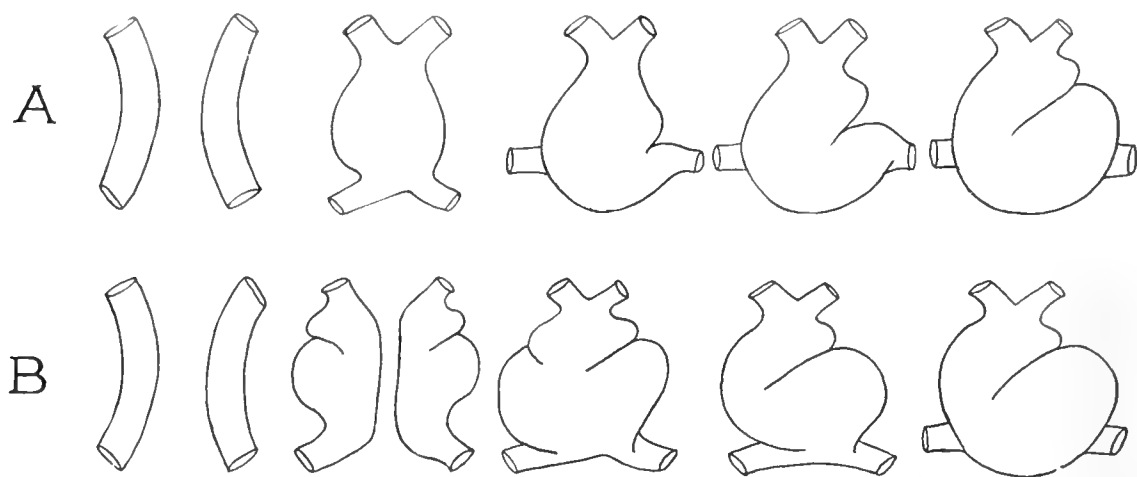


Fig. 1 A. Schema of cardiac loop formation; as presented in most modern text-books, based on the His models. B. Schema representing the same period of development, as observed by Doctor Schulte in the Columbia Laboratory. (Note that the bulboventricular clefts are formed in both hearts before fusion takes place, that the left groove together with the left shoulder of the ventricle becomes accentuated, that there is a corresponding obliteration of the right groove and shoulder, and that the venous end of the heart migrates to the left. These are the principal factors in the formation of the loop.)

case are the same, but that the intervening processes are dissimilar. Instead of reiterating Doctor Schulte's conclusions, I will ask the reader to examine carefully figure 2 before reading the following explanation. It is a model of the endocardial cavity in a nine-day rabbit. The myocardial mantles, not represented in the model, have completely fused, but the endothelial tubes have not as yet entirely coalesced. The picture presents a condition previous to the complete amalgamation of the vessels to form a common cavity. Those points where the endocardia

are still separate mark out the line of fusion of the two primitive tubes, and it is thus quite evident what portions of the cavity are derived from the right cardiac vessel and what portions from the left.¹

The elements represented are: *a*) the sinus venosus at the confluence of the vitelline veins; *b*) the canal between the sinus venosus and the ventricle, which, as the atrium develops at this point, we may call the atrial canal; *c*) the common ventricle,

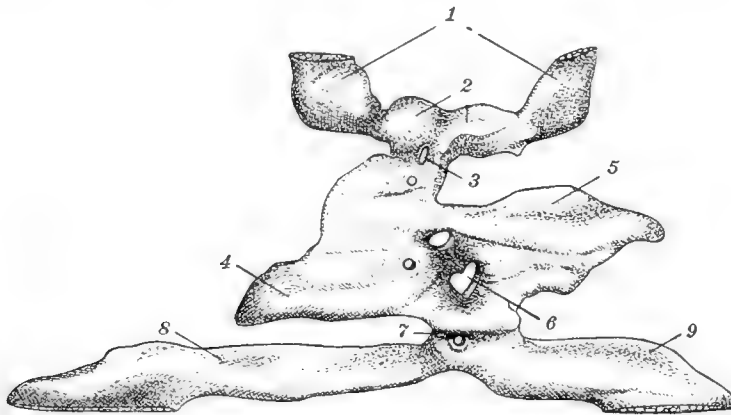


Fig. 2 Model representing a cast of the cavities within the heart and the connecting vessels in a rabbit embryo of nine days. Ventral view. Harvard Embryological Collection, Series 619. 1, aortic branches; 2, right and left bulbs; 3, apertures formed by the septum dividing the bulboventricular canal; 4, right shoulder; 5, left shoulder; 6, aperture formed by the septum dividing the common ventricle; 7, atrial canal; 8, right vitelline vein; 9, left vitelline vein. $\times 100$.

¹The valuable study of the development of the pericardium in ferrets by Professor Robinson (Journ. of Anat. and Phys., 1902, vol. 37) has recently been extended by his pupil, Doctor Wang, with results which deserve more critical consideration than can be given here. Being concerned especially with early stages, Wang does not discuss the questions raised by Schulte, and his interpretation of the model shown in figure 2 would differ from ours, as may be seen by comparing it with his figure 31 representing the heart of a ferret of 13 to 14 segments. Wang's most interesting observation is of a 'primary heart rudiment,' a vessel crossing the median line and subsequently dividing into two endothelial tubes. The lateral vessels thus formed, or others somewhat posterior and leading to them, then reunite to make a 'secondary' heart. In the rabbits of the Harvard Collection, as Doctor Lewis informs me, there may be seen a strand of presumably angioblastic tissue in the region of the primary heart of Wang, but nothing which should be interpreted as a heart. At present, therefore, we are not inclined to recognize a heart previous to the union of the lateral cardiac vessels.

with a right and left shoulder; *d*) the restricted portion between ventricle and bulb, which may be called the bulboventricular canal; *e*) the bulb, and *f*) the arterial branches. The following points should be particularly noted: 1) the atrial canal has been forced to the left, and that portion of the canal contributed by the right heart has become relatively much reduced; 2) the left shoulder of the ventricle is elevated, the right depressed; 3) the left bulboventricular cleft is pronounced, the right is obscure, and 4) on account of the greater impression made by the left bulboventricular cleft that portion of the bulbar canal contributed by the left heart is diminished. Later, the right bulboventricular cleft disappears, the left becomes more pronounced and vertical, the atrium develops from the atrial canal growing cephalad behind the ventricles, and the cardiac loop is then complete. My observations commence at a stage when the original lateral tubes have become ventrally placed and are united through the intervention of a middle cardiac plate. The process by which this change is effected—a subject upon which Wang speculates at some length—will not be discussed. Attention will be focused on what may be considered the most fundamental aspects of the succeeding modifications, namely, 1) the middle cardiac plate with a consideration of its future history and possible connection with the interventricular septum, and 2) the bulboventricular groove.

MIDDLE CARDIAC PLATE AND INTERVENTRICULAR SEPTUM

In figure 3 observe the middle cardiac plate connecting the two hearts. It will be noticed that it is narrow cephalad, connecting the bulbs, and broad caudad between the ventricles. This mesothelial element gradually becomes incorporated into the myocardial walls of the enlarging ventricular cavity and is later represented in the rabbit by a ridge or series of ridges marking the original line of fusion. The ridges which are quite apparent on the inner aspect of the ventral wall are well shown in figure 4; they are placed opposite the septa which still remain between the two endothelial tubes (compare fig. 2). The early embryos of the cat in the Columbia series show similar ridges

and also some intermediate stages. The rabbit differs from the cat in that this ental protrusion of the myocardia is a simple ridge and is not surmounted by a groove. Has this ridge any definite relation to the future interventricular septum? I think not. After modeling a number of rabbit and cat hearts between this stage and the stage when the interventricular septum is first apparent, I find no connection between the two. As shown in figure 4, when last observed the median ridge is directed towards the atrial canal. As the latter does not change its position until a later date, if the interventricular septum were a product of this ridge we should expect to find it at first obliquely placed

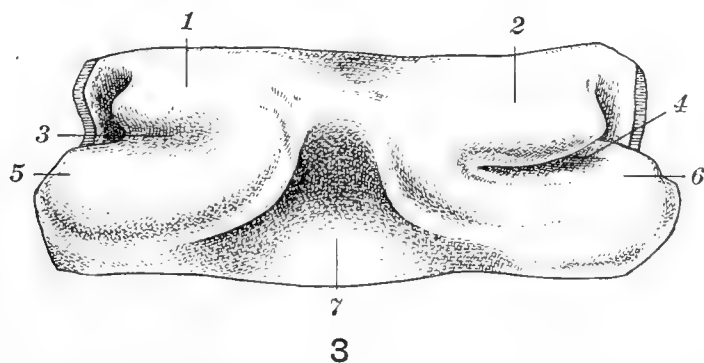


Fig. 3 Model of the myocardium (ventral view) from a rabbit embryo of nine days; H. E. C., Ser. 620. 1, right bulb; 2, left bulb; 3, right bulboventricular groove; 4, left bulboventricular groove; 5, right ventricle and shoulder; 6, left ventricle and shoulder; 7, middle cardiac plate. $\times 100$.

and in line with the canal. This is not the case. On the contrary, we find a septum arising apparently as a thick muscular ridge from the most caudal portion of the ventricular loop, corresponding to a groove on the exterior.² Both septum and groove are sagittally placed and are not at this early stage directed towards the atrial canal (compare fig. 6). Furthermore, the septum appears at a considerably later date, after the common atrium is well formed and the ventricular wall has undergone great expansion and growth with considerable trabecular formation. In both the rabbit and cat embryos the increased

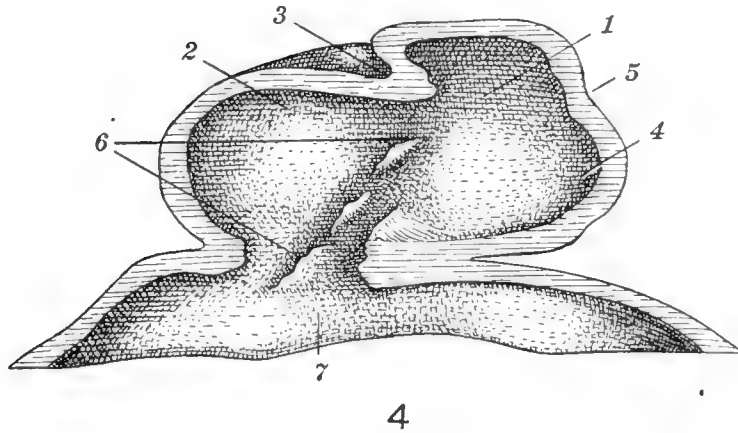
² As Mall says, it is more correct to speak of the downward growth of the apices of the two ventricles than the upward growth of the septum.

growth in thickness of the ventricular wall is first manifest on the ventral wall and gradually spreads laterally and dorsally. In my series, the actual height³ of the heart in the rabbit when the last sign of a middle cardiac plate can be determined is 0.32 mm., whereas the earliest sign of an interventricular septum is found in an embryo with an actual heart length of approximately 0.75 mm. Doctor Schulte, in the latest stage in which a middle cardiac plate was present in his material, found it continued caudad by a sulcus which he regarded as the beginning septum ventriculorum. Beyond this stage there was a gap in his material to the period of a well-developed septum with no remnant of the middle cardiac plate. My reason for dissenting from his conclusion that the median plate gives rise to the septum is that in the rabbit models and in embryos of the cat subsequently obtained the sulcus mentioned is found to disappear and the ventricle becomes evenly convex without a trace of indentation referable to the middle cardiac plate. Only later does the ventricular septum arise in the manner I have described. The interior of the model portrayed in figure 5 shows a smooth wall with no sign of a ridge, although at two points the endothelial tubes have not yet completely united. Considerably later, as the atrial canal is moved to the right while the interventricular septum remains fixed, the canal comes to be immediately dorsal to the septum; the septum will then be seen to extend toward the centre of the canal and still later to become fused to the endocardial cushion. The subsequent development of these parts is beyond the scope of this paper.

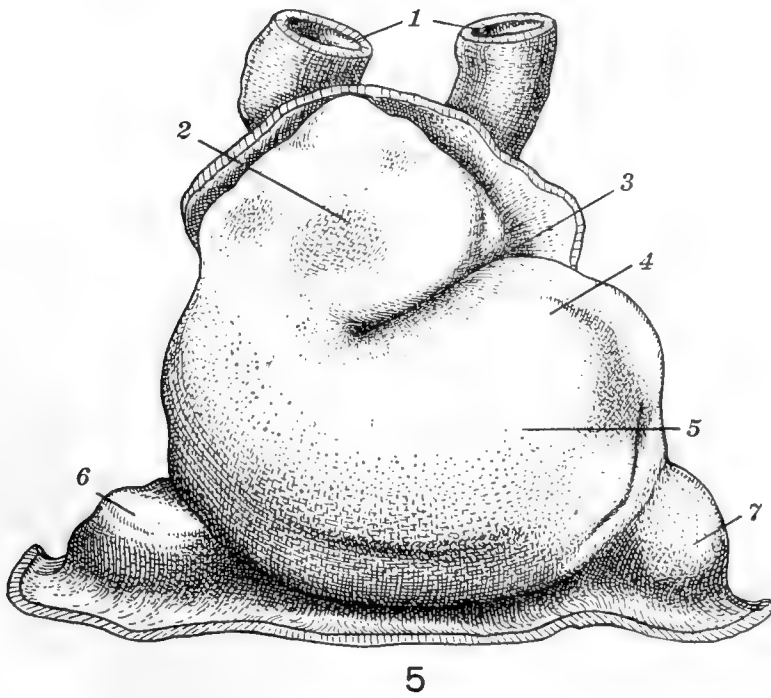
THE BULBOVENTRICULAR GROOVES

These clefts first appear on each side before the lateral cardiac vessels have fused. They have been given this name because in their primary position they separate primitive bulb from primitive ventricle. Later, as we shall see, the bulb contributes to the right ventricle, and the left bulboventricular cleft may then be termed an 'interventricular groove.' In figure 3 the

³ As measured from the most cephalic to the most caudal points, regardless of what portions of the heart these may be.



4



5

Fig. 4 Model of the myocardium (dorsal view of the ventral wall) from a rabbit embryo of nine days; H. E. C., Ser. 619. 1, bulboventricular canal; 2, left shoulder; 3, left bulboventricular groove; 4, right shoulder; 5, right bulboventricular groove; 6, inward protrusions of the myocardium in a line directed toward the center of the atrial canal; 7, sinus venosus. $\times 100$.

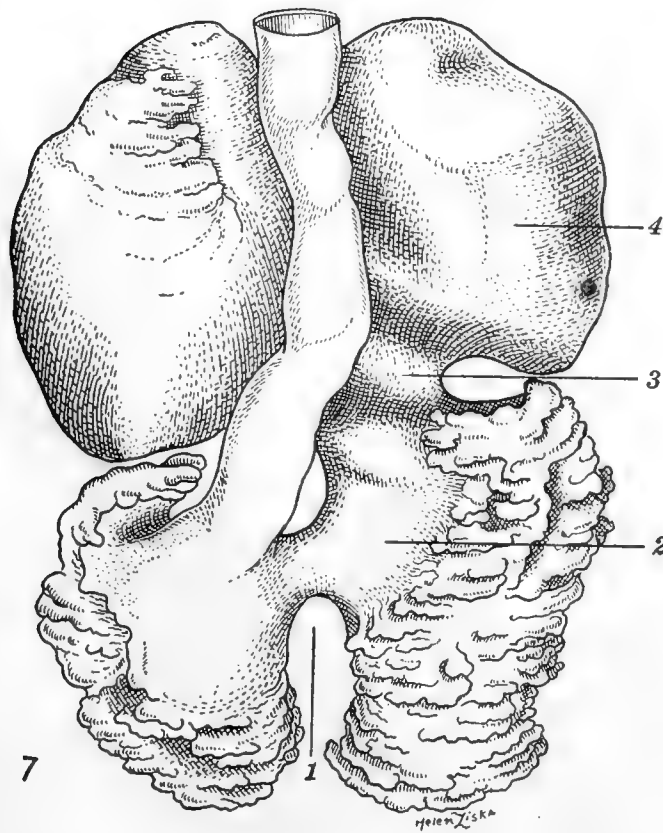
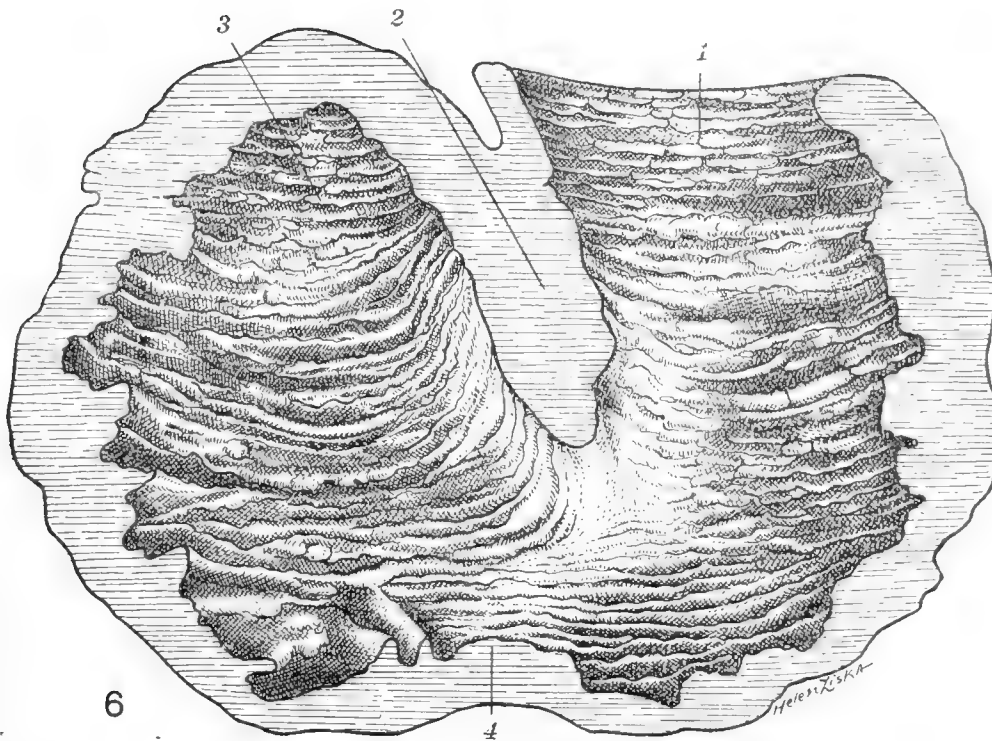
Fig. 5 Model of the myocardium (ventral view) from a rabbit embryo of nine and one-half days; H. E. C., Ser. 565. 1, aortic branches; 2, bulb; 3, bulboventricular groove; 4, shoulder; 5, common ventricle; 6, right vitelline vein; 7, left vitelline. $\times 100$.

grooves are horizontal. The left groove is already assuming a more significant rôle and the asymmetry forecasts future changes. In the cat this prominence of the left cleft is not accentuated until somewhat later. A subsequent stage in the rabbit is represented in the endothelial model, figure 2, and in figure 5 a fully developed cardiac loop is seen. The bulboventricular cleft (there is now only one, the right having become obliterated) is more oblique.

From this stage onward there is a continual progressive extension of this furrow, and as it develops, its plane is modified so that in figure 6 we find it very nearly vertical. Notice in this drawing its relationship to the primitive septum. It is not in line with the latter structure. In the next period, however, the bulboventricular groove, formerly horizontal, is now vertical, protrudes into the ventricular chamber, becomes continuous with the septum, and together with it divides the cavity into right and left portions. This is well shown in figure 7. The division of the common ventricle then seems to be the result of four processes: 1) the interventricular septum growing cephalad from the floor of the loop; 2) the bulboventricular groove becoming vertical and forming the ventral portion of the septum; 3) the migration of the atrial canal to the right, allowing the endothelial cushions to play their part, and finally, as His has shown, 4) the downgrowth of the pulmonoaortic septum which fuses with the above-mentioned elements so as to form a continuous partition between the right and left hearts.

Fig. 6 Model of the myocardium (dorsal view of the ventral wall) from a rabbit embryo of ten and one-half days; H. E. C., Ser. 559. 1, bulb; 2, ridge extending into the common ventricular cavity and corresponding to the bulboventricular cleft; 3, shoulder; 4, interventricular septum (this is the first indication of the ridge found at the apex of the ventricular loop). $\times 100$.

Fig. 7 Model of the endocardial cavity (ventral view) from a cat embryo of 7 mm.; Columbia Collection, Series 266. By kind permission of Dr. A. J. Brown. In the Harvard Laboratory there is a very similar model of the cavities in the heart of a 4.4-mm. pig embryo, made in 1909, under Dr. Minot's direction, by Mr. A. E. Meyers. 1, cleft made by the ridge growing upward from the caudal extremity of the loop, which is continuous with 2, the impression made by the bulboventricular groove. Together they partially subdivide the ventricular cavity; 3, atrial canal; 4, left atrium. $\times 50$.



SUMMARY

The processes in the early development of the rabbit's heart are fundamentally the same as in the cat. 1) The primary loop is due to the deepening of the left bulboventricular cleft and a disappearance of the right, accompanied by a reduction on the part of the right shoulder of the ventricle and a very marked growth of the left. 2) The middle cardiac plate, marked temporarily after myocardial fusion by a distinct ridge which corresponds precisely to the line of fusion of the endothelial tubes, eventually becomes entirely obliterated. 3) The primitive interventricular septum arises de novo from the floor of the loop in a sagittal plane. 4) The left bulboventricular cleft, at first horizontal, becomes oblique and then vertical; protruding into the common ventricular cavity as a well-marked ridge, it meets the septum developing in the apical portion of the heart and contributes to the formation of the interventricular septum of the adult.

BIBLIOGRAPHY

- BREMER, J. L. 1912 Development of the aorta and aortic arches in rabbits. *Am. Journ. Anat.*, vol. 13, no. 2.
- LEWIS, F. T. Intraembryonic blood vessels of rabbits from 8½ to 13 days. *Am. Journ. Anat.*, vol. 3.
- MALL, F. P. 1912 On the development of the human heart. *Am. Jour. Anat.*, vol. 13.
1912 Bifid apex of human heart. *Anat. Rec.*, vol. 6.
1912 Aneurysm of membranous septum. *Anat. Rec.*, vol. 6.
- PARKER, K. M. The early development of the heart and anterior vessels in marsupials with special reference to *Perameles*. *Proc. Zool. Soc.*, London, 1915, Pt. 3.
- ROBINSON 1902 Early stages of development of the pericardium. *Journ. of Anat. and Physiol.*, vol. 37.
- ROUVIÈRE, H. 1904 Études sur le développement du péricarde chez le lapin. *Jour. de l'anat et de la physiol.*, vol. 11.
- SCHULTE, H. W. 1916 The fusion of the cardiac anlagen and the formation of the cardiac loop in the cat. *Am. Journ. Anat.*, vol. 20, no. 1.
1914 Early stages of vasculogenesis in the cat with especial reference to the mesenchymal origin of endothelium. *Memoirs of Wistar Institute of Anat. and Biol.*, no. 3.
- STRAHL AND CARIUS 1899 Beiträge zur Entwicklungsgeschichte des Herzens und der Körperhöhlen. *Arch. f. Anat. und Physiol.*, Bd. 15.
- TANDLER, J. Keibel and Mall. *Manual of human embryology*, vol. 2.
- WANG, CHUNG-CHING 1917 Earliest stages of development of the blood-vessels and of the heart in ferret embryos. *Journ. of Anat.*, vol. 52, part 1,

Resumen por el autor, Frank Blair Hanson.
Universidad Washington, San Luis.

La ontogenia y filogenia del esternon.

Existen en la literatura tres teorías diferentes sobre el origen del esternón, suponiéndose generalmente que este hueso no es homólogo en los amniotos e ictiopsidos. El autor demuestra que el esternón de los vertebrados está mas intimamente ligado con la cintura escapular que con las costillas, y describe diferentes estados de desarrollo en los embriones de un cierto número de mamíferos—gato, rata, ratón, cerdo y hombre—en los cuales las barras esternales son estructuras bien manifiestas antes de su unión con las costillas, cuyo hecho es contrario a la teoría de Ruge sobre el origen costal del esternón. El presternón está intimamente asociado con los coracoides en todas las clases de los vertebrados, incluso los monotremas. En los embriones jóvenes del ratón y el hombre se forma una cintura mesenquimatosa continua comparable a la cintura pectoral del tiburón, de la cual se derivan la cintura escapular y el manubrio. Por consiguiente, el elemento anterior del esternón tiene un origen común con la cintura escapular y, en el embrión o durante toda la vida del animal, está en íntima relación con los coracoides. Las bandas esternales son derivados del rudimento anterior medio, pudiéndose asociar secundaria pero no genéticamente con las costillas. El esternón es una estructura homóloga en todos los grupos de vertebrados y se presenta en las formas comprendidas entre el tiburón *Hexanchus* hasta el hombre.

Translation by José F. Nonidez
Carnegie Institution of Washington

THE ONTOGENY AND PHYLOGENY OF THE STERNUM

FRANK BLAIR HANSON

Zoological Laboratory of Washington University, St. Louis, Missouri

TWELVE PLATES (FORTY-NINE FIGURES)

CONTENTS

I. Introduction.....	41
II. Critical estimate of existing theories.....	42
1. Ruge's theory of costal origin.....	42
2. Paterson's coracoidal theory.....	43
3. Work of Parker and Howes.....	45
4. Whitehead and Waddell's 'in situ' theory.....	47
5. Work of Rathke, Kravetz, Mueller, etc.....	52
III. The ontogeny of the sternum.....	58
1. The sternal bands.....	58
2. The anterior median sternal rudiment.....	60
3. The sternebrae.....	61
4. Stages in the ontogeny of the mammalian sternum.....	63
5. Conclusions.....	63
IV. The phylogeny of the sternum.....	64
1. Fishes.....	64
2. Amphibia.....	66
3. Reptiles.....	70
4. Birds.....	76
5. Monotremes.....	78
6. Marsupials.....	78
7. Aquatic mammals.....	81
8. The adult human sternum.....	83
9. Conclusions.....	87
V. Summary.....	88

I. INTRODUCTION

The shoulder-girdle complex presents some of the most fascinating and difficult problems of vertebrate morphology. In all the lower vertebrates the sternum, because of its intimate relation to the coracoids, enters into and constitutes one of these problems. Its origin, development, and homologies have been

the subject of numerous contributions for a century past, yet to-day there is no general agreement upon many of the points involved.

For several years the writer has been studying the shoulder-girdle region in the vertebrates. This included also a restudy of the origin of the sternum, the results of which are embodied in this paper. The fact that my conclusions are at variance with the usually accepted theory of sternum origin only adds to the interest of the undertaking. If this paper settles the points at issue or stimulates further investigation upon the part of others, it will in either case not have been in vain.

One of the recognized deficiencies of much of the previous work is that general and far-reaching conclusions have been deduced from the study of only one or two forms, and these most often the more highly specialized ones. The author has attempted herein to bring together corroborating lines of evidence from both ontogeny and phylogeny, believing that a theory of sternal origin only so demonstrated can command consideration.

I desire to express my deep appreciation for the constructive criticisms and helpful suggestions given by Prof. J. Sterling Kingsley during the course of this investigation.

II. CRITICAL ESTIMATE OF EXISTING THEORIES

1. *Ruge's theory of costal origin*

Ruge ('80) was the first investigator to work up and present a well-developed and illustrated paper containing a theory of the origin of the sternum. His fifty pages of text and twenty-two figures gave his theory a commanding place in the literature. Most books on human and comparative anatomy, until the present day, copy his figures and accept his view that the sternum arises as a product of the ventral costal cartilages. As an example of this, Keibel and Mall in their two-volume *Embryology* give the following statement concerning the origin of the sternum: "The cartilage of the sternum arises mainly from the cartilage of the ribs, from which it is secondarily separated by the formation of the costosternal joints." So completely has Ruge's

work dominated the field that even in the latest editions of Human Anatomy texts his work is alone mentioned, or at most, a footnote is added to the effect that this view has of late been questioned by some.

However, there are at least two later views as to the origin of the sternum. Paterson ('00, '02, '04), on the one hand, and Whitehead and Waddell ('11), on the other, have propounded theories which are at once contradictory of Ruge's view and also antagonistic to each other. Thus there are at the present time three distinct and opposing theories concerning the origin of the sternum, and it was with a view to clearing up this confusion and also to give the prominence deserved to this later work that the present investigation was undertaken. For while a study of the papers representing these theories may not convince one of the validity of any one of them as opposed to the others, the latter two mentioned do point out very clearly that there are data which Ruge did not consider; and further, that our commonly accepted view concerning the origin of the sternum, held for nearly forty years, must be greatly modified and possibly cast aside altogether.

2. Paterson's coracoidal theory

Professor Paterson in a series of papers ('00, '02, '04) was the first to attempt to overthrow Ruge's theory of the origin of the sternum from the ventral ends of the ribs. His observations were made upon the rat, rabbit, and man. He describes a single median rudiment which is directly continuous with the mass of cells destined to form the shoulder-girdle. From this median mass two strands of cells grow caudally to form the sternal bands. Whitehead and Waddell ('11) say, "thus in the final analysis, according to Paterson's view, the sternum is derived from the shoulder-girdle." This seems an unwarranted statement. It would be as correct to say that, according to Paterson, the shoulder-girdle is derived from the sternum as to say, as do Whitehead and Waddell, that Paterson makes the sternum to be a derivative of the shoulder-girdle. What Paterson does succinctly say is, "that the presternum and shoulder-girdle are

originally derived from the *same* (italics mine) element; a primitive band of cellular tissue which crosses the midline." Paterson has no interest in deriving the sternum from the shoulder-girdle or vice versa; his contention being, first, that the sternum is not a product of the costal cartilages, and, second, that it is yielded from a common, continuous, mesenchymatous element which gives rise to the shoulder-girdles and the sternum.

Paterson ('02) compares this continuous cellular element in the rat to the girdle in the elasmobranchs. He exhibited before the British Medical Association his sections of rat embryos side by side with embryos of *Acanthias vulgaris* to demonstrate that "essentially the same method of development occurs in the dogfish and in the rodent. But a marked difference is produced in the process of development. Instead of a jointed and highly differentiated structure such as is characteristic of mammals, a simple continuous bar of cartilage is formed, across the middle line and below the heart, which gives rise laterally to the primitive shoulder-girdle."

Paterson ('00) also points out, and gives several figures in substantiation, that the parts of the sternum opposite the costal attachments remain longest in a cellular condition. His point being, of course, that if the sternum were ossified from the ribs, these regions should ossify first, and not last as is actually the case.

This comparison of the girdles in the shark and rat embryos is very suggestive. Many other structures of present-day mammals may be traced directly back to homologous structures in the elasmobranchs, and since in the cartilaginous girdle of the shark we have all the necessary material and in proper position for differentiation into scapulae, coracoids, and sternum, we might even upon a priori grounds expect to find in the higher groups of vertebrates an embryonic stage in which the rudiment of the girdles and sternum might be represented by such a "continuous bar . . . reaching across the middle line" as Paterson found in the rat.

3. *Work of Parker and Howes*

Parker ('91) claims to have found a sternum in the shark *Notidanus indicus*. A small blunt process is set in between the two cartilages which unite later to form the girdle. This structure was earlier described in the same shark by Haswell ('84) who says "the intercepted cartilage is temptingly like a presternal, but the absence of such an element in the skeleton of any group nearer than the Amphibia seems to preclude this explanation." Parker's ('91) figures 1 and 2 would indicate that this was a presternum, and that Haswell was more nearly correct in his observation than in his deduction therefrom. Had Paterson used *Hexanchus* rather than *Acanthias*, he might have found an even more striking resemblance of stages between the rat and shark than he did.

By the courtesy of the officials of the U. S. National Museum, I was permitted to examine their type specimen of *Hexanchus*. The body wall had been laid open along the ventral side to allow the preserving fluid to bathe the viscera. By means of a short anterior and two lateral incisions I was enabled to lay bare the median ventral portion of the pectoral girdle without otherwise disturbing the value of the specimen as a type. The girdle (fig. 1) was exactly as described by Haswell ('84) and Parker ('91). The median cartilage in a young specimen was distinctly marked off from the coracoids and in general appearance was not unlike the fetal girdle of the marsupial (fig. 35). Later I dissected two specimens of *Acanthias* that measured 4 inches and 7 inches, respectively, in order to confirm Paterson's statement of its likeness to the early embryonic girdle of the rat. In both these specimens the girdle was approximately the same as in the adult. Figure 2 shows the girdle of the 7-inch specimen, and if compared to the marsupial girdle (fig. 35) and the mouse girdle (fig. 5), the morphological relations are apparent. In these early stages of the marsupial and mouse no suture has as yet appeared between coracoids and presternum, giving the resulting shark-like girdle, complete across the midventral line.

Parker ('91), accepting in common with others the validity of Ruge's theory of a costal sternum in reptiles, birds, and mammals, but being unable to relate a sternum of such derivation with the sterna of the Ichthyopsida, suggested that there must be two distinct types of sterna: 1) a costal sternum, characteristic of the Amniota, and 2) a coracoidal or clavicular sternum, characteristic of the Ichthyopsida.

This classification of the sternum was adopted by Howes ('91) who says, "the distinction indicated by the two terms 'costal sternum' and 'coracoidal sternum' is but the expression of a fundamental morphological difference between the two structures." Howes slightly altered the terminology of Parker. He would distinguish between a 'coracoidal archisternum' of the Ichthyopsida and a 'haemocoracoidal neosternum' of the Amniota. This latter term was based upon his idea that the "interclavicle may be, throughout, the vanishing vestige of the coracoidal sternum of the Ichthyopsida." The acceptance by Parker ('91) and by Howes ('91) of this division of two morphologically different sterna in the group of the vertebrates indicates how completely Ruge's theory dominated their thoughts, and the thought and teaching of that day concerning the origin of the sternum. If, however, the conclusions of later workers regarding Ruge's theory prove valid, and all the facts at the present time seem to substantiate their validity as we shall later see, it is no longer necessary to divide the sterna of the various classes of vertebrates into coracoidal and costal, for no sternum is costal in origin, the union of ribs and sternum being but a late and secondary stage in development. This is obviously an important item, if proved, for it enables us to homologize all vertebrate sterna. Heretofore it has been impossible to homologize the sterna of the Ichthyopsida and the Amniotes because of their supposed dual origin. One of the objects of the present paper is to determine this matter of a single or dual origin for the sternum and the solution of its homology throughout the vertebrates.

4. *Whitehead and Waddell's 'in situ' theory*

In 1911 Whitehead and Waddell undertook to settle the whole vexed question by a reexamination of all the evidence and by a study of younger stages than had hitherto been used. Their work was based on observations made upon three forms: the pig, cat, and man. These studies, however, instead of settling the dispute between the theories of Ruge and Paterson, led the authors to reject both of them and to propound an entirely new one. So, as a result of this latest paper, there are at the present time three, instead of two, rival theories of sternal origin. For neither of these two latter theories had been able of its own weight effectually to settle the points in question; Ruge's theory of costal origin still maintains its hold upon the minds of most morphologists; but nevertheless, new evidence produced by later work throws very strong doubt upon the conclusions of Ruge.

Ruge apparently had no stage prior to that in which the sternal bands were united with the costal cartilages; but it must be admitted, that his conclusions, based upon the material that passed through his hands, are clearly valid for the stages described—in fact, the only ones that could possibly be deduced therefrom. It is probably this fact that gave Ruge's theory its persistence through the years. The later workers, however, have had as their goal stages much earlier than Ruge's, and, while they have succeeded in finding them, are still very far apart in the interpretation thereof.

As Whitehead and Waddell's paper is of considerable importance and has never been reviewed, a brief summary of its contents and conclusions is necessary here.

They studied first the pig, because the absence of clavicles in this form tends to simplify matters at the cranial end of the sternal rudiment; next the cat, for here the clavicle is a rudimentary bone and does not articulate with the sternum, and finally the human embryo, where the clavicle reaches its fullest development.

These authors began with pigs of 24 mm. and worked through successively smaller stages, until the sternal rudiment was very

feeble, while in specimens smaller than 15 mm. no rudiment could with certainty be detected.

In a pig 24 mm. long, to follow the description of Whitehead and Waddell, the sternal rudiment is an aggregation of mesenchymal cells lying transverse to the median plane of the body. In cross-section it is triangular, with the apex directed ventrally, and each lateral angle of the base connected with the corresponding first rib, there being a perfect and direct continuity of tissue between the rudiment of the first rib and that of the sternum. Proceeding backward in the series of sections two bands of mesenchymal cells separate from the mass and extend as far back as the level of the seventh rib, all seven ribs being connected with and shading off into the sternal bands without any definite demarkation. This is the stage in which Kravetz ('05) found that the first ribs did not reach the sternal rudiment, and the junction of the other six ribs was too feeble to have any morphological significance. Whitehead and Waddell think this is not a tenable conclusion in light of the intermediate position occupied by this specimen, i.e., between older stages in which no doubt of the absolute continuity of ribs and sternum exists, and younger stages in which they seek for new facts concerning the earliest relation between these two structures.

In a 20-mm. pig the pericardial cavity extends into the neck, the ventral ends of the ribs are wide apart, and, in the region anterior to the level of the first rib, the sternal rudiment is present and is composed of three parts: the two sternal bands and a plate of more diffused mesenchymal cells connecting the two across the middle line. This stage presents two facts worthy of note: the sternal bands are well defined separate structures at a level considerably anterior to that of the first rib, and, further, in this anterior region the two sternal bands are connected by a median aggregate of cellular tissue. Posteriorly, in the region of the ribs, there is the same continuity between costal extremity and sternal band as in the 24-mm. stage.

Just as the older stage of Whitehead and Waddell (24-mm. pig) corresponded to the youngest studied by Kravetz, so does this 20-mm. stage in the pig correspond essentially to the youngest

stage in man found by Mueller ('06), yet the interpretations of these stages by the three authors are totally at variance.

The next stage was a 22-mm. pig, longer than the preceding by 2 mm., but distinctly a younger stage in so far as development of these parts was concerned. The sternal bands and connecting bridge of mesenchymal cells are still anterior to the first ribs; the pericardial cavity reaches far into the neck and separates the sternal band and first rib of each side. Passing caudally in the series of sections, the first rib falls just short of reaching the sternal band; the extremity of the second rib approaches more nearly to the sternal band, and the remaining five present the same continuity as before.

In the next younger stage, the 18-mm. pig, the heart is far forward in the neck, with the consequent wide separation of the sternal bands in this region; the median connecting portion is now absent; the remaining parts of the sternal bands were traced from a point 150 μ anterior to the level of the first ribs back to the level of the ventral extremity of the seventh; the first two pairs of ribs do not reach the sternal bands, but the other five are firmly fused with it.

The earliest stages in which any sternal rudiment could be detected were in 15- and 16-mm. pigs. The bands are not very clearly defined and stop at the level of the third and fourth ribs, respectively; again the first and second ribs fail to reach the sternal bands, and it is the opinion of the authors that, "judging from the behavior of the ventral extremities of the first and second ribs in somewhat older stages, we think it probable that a stage exists in which no rib is connected directly with the sternal bands, but we were unable to detect such a stage."

The cat embryos studied by Whitehead and Waddell (from the Princeton Embryological Collection) ranged in size from 25 mm. to 10 mm. From the description given, they are essentially the same as the several corresponding stages of the pig. In the 12-mm. cat the first three ribs clearly did not reach the sternal bands, the fourth was uncertain, while the three posterior pairs made the connection. Since, from the account given, the early stages in the pig and cat are practically identical, nothing further need be said of the sternum in the cat.

Several human embryos from the Johns Hopkins Embryological Collection, ranging in size from 17.2 to 10.5 mm. are described in the paper now under review. The 13-mm. human embryo corresponds essentially to the 18-mm. pig and 13-mm. cat. The pericardial cavity extends far forward; the sternal bands are traceable to the level of the ventral extremities of the fifth ribs; the ventral tips of the ribs are non-cartilaginous, and any possible continuity between them and the sternal bands is much too slight to suggest that the latter is a derivative of the former; neither median sternal rudiment nor clavicles were detected, though this was probably due to the loss of an entire slide of sections from the very region in which one would expect such a structure to occur, if present.

In a 10.5-mm. human embryo, the sternal bands reach posteriorly only as far as the fourth rib; and although the cells composing the bands are not sharply differentiated from the surrounding tissue, they are still recognizable and "it is evident that they are not continuous with the tips of the ribs, but are connected with them only by loose mesenchymal cells."

In these stages which are far earlier than any Ruge describes, there is a history quite different from that which later stages had led us to expect. In the first place, there was no indication of segmentation in the sternal bands, which might be expected were these bands due to proliferated cells from the tips of the costal cartilages, and, second, in the pig the first two ribs in the earliest stages studied did not reach the sternal bands at all; three did not do so in the cat, while in the 10.5-mm. human embryo none of the ribs reached the band.

These results also contradict the statement of Paterson that the median rudiment is a part of the scapular arch, and that the sternal bands are derivatives of the single median blastema. Whitehead and Waddell do not mention the condition or extent of the girdles in any of the forms studied by them, merely stating that at no point was there any connection discernible between sternum and girdles; and that in every case "the appearance of the paired portion of the rudiment, the sternal bands, antedates that of the median portion."

Since the observations of Whitehead and Waddell accord with neither those of Ruge nor of Paterson, the formulation of a new theory of sternal origin was necessary.

Their discovery of the single median rudiment would not allow of Ruge's conclusion, for he thought the sternum a product of the costal extremities; neither would they square with Paterson's view, for he derived the sternal bands from the median rudiment; and further, it was apparently not a product of the sternal ends of the clavicles. So recourse was had to either of two other theories, each possible so far as their observations go: "first, it may be formed 'in situ,' or, second, it may be derived from the anterior ends of the sternal bands by each of them sending a prolongation medialward to join its fellow in the median plane. The fact that we never found this rudiment in a paired condition, but always as a single band of cells uniting the anterior ends of the sternal bands leads us to believe that the first interpretation is the more probable."

Thus Whitehead and Waddell say there are two possibilities remaining for the formation of the anterior median rudiment, either that it arises 'in situ' or as a derivative of the sternal bands. They overlooked another possibility, its derivation from and relation to the shoulder-girdle. This may not have been an unnatural error in view of the fact that they studied chiefly the pig where the clavicle and that associated coracoidal mesenchymatous material of the early embryo is lacking. Their view-point was derived from the developmental stages in one or two mammals only, and they paid little attention to the comparative anatomical and the phylogenetic side.

This median rudiment is considered by Whitehead and Waddell to be the homotype of the presternum of monotremes, but no reasons or arguments for such a belief are set forth. This conclusion, however, is clearly invalid, for it is impossible to reconcile the theory of 'in situ' for this anterior rudiment with their statement that it finds its homologue in the presternum of lower forms or the so-called prosternum of monotremes. If these be homologous, then the presternum and prosternum also arise 'in situ,' and no morphologist believes that they do.

The paired rudiments, or sternal bands, also arise very early, according to Whitehead and Waddell, 'in situ,' one on either side of the body and unattached in the earlier stages to the ventral extremities of the ribs. The paired rudiments antedate the appearance of the median rudiment.

While Whitehead and Waddell and Paterson are very far from being in accord as to the origin of the sternal rudiments, they agree in demonstrating that the attachment of ribs and sternum is a secondary fusion of parts, and that Ruge, while essentially correct in his description of the stages he had under observation, did not have the earlier stages and therefore was not in a position to frame a theory of sternal origin. Without stopping now to consider the relative merits of these two later theories, it must be pointed out that their united efforts in overthrowing the Ruge theory are of great value because of the hitherto widespread, almost universal acceptance of this view.

5. *Work of Kravetz, Rathke, Mueller, etc.*

Kravetz ('05) worked on the pig. His youngest stage (24 mm.) was also the oldest stage of Whitehead and Waddell. In the 24-mm. pig he found that the first ribs did not reach the sternal rudiment, and, from the conditions in a series of later stages, came to the conclusion that primarily there is no connection whatever between the sternal rudiment and the costal cartilages at their ventral ends.

Bruch ('52) describes the early stage of the sternum as two longitudinal rods, one on either side, which later unite with each other and with the ribs of their respective sides. He thus indirectly denies a costal origin, but fails to indicate just what his views were in this respect. It is highly probable that the question was never raised in his mind at that early date. Whitehead and Waddell add but little to the description of this early worker, except that they have a theory of 'in situ' origin for the structure in question.

Rathke ('48) has an early, but very important paper in connection with this discussion. His views are set forth in two short paragraphs which are quoted in full as follows:

According to the researches I have made on the development of the sternum in mammals, birds, and batrachians, this bone (sternum) may be formed in a two-fold fashion. In mammals and birds it occurs under the form of *two very slender, long rods* (italics mine), divided into two lateral halves, and already at an early period consisting of cartilaginous tissue, *each of which rods unites itself with the extremities of several ribs of its own side* (italics mine) when these project themselves through a small part of the lateral wall of the body. The two halves, therefore, at first, lie at a considerable distance from each other. Gradually, however, these two rods are approximated to one another by the extension and development of the ribs, until, at length, they come into contact throughout their whole length, and ultimately coalesce, forming the sternum.

As regards the Batrachia, even in those which possess ribs, there is never at any time two rods which unite the ribs and coalesce with one another to form the sternum, but in some of these Amphibia there originates a single cartilaginous lamina; in others a row of two or three such laminae quite independent of the lateral rays of the vertebral column.

Rathke's account of the origin of the sternum in birds and mammals gives us a description of a stage far earlier than Ruge's youngest sternum. Ruge saw these 'rods, long and slender' only after they had been united with ribs, and therefrom made his deductions that they originated from ribs. Over thirty years before Ruge's paper, Rathke accurately described this very early stage, which had only been rediscovered in a few mammals very recently. Ruge mentions Rathke's work, but, strange to say, makes no reference to this earlier stage in his account.

This earlier account by Rathke is hidden in a discussion of the homologies of the Chelonian plastron, and has not been mentioned by any writer since Ruge. Its confirmation by Paterson, Whitehead and Waddell, as well as by my own observations, renders Ruge's theory of the sternum untenable.

However, accurate as this description of Rathke's is, we must not forget that he did not recognize its significance; in fact, it is introduced into a paragraph describing and maintaining that the sternum of the mammals is different in origin from that of batrachians, not realizing as we do to-day that in separating it completely in its genesis from the costal cartilages, he made unnecessary a dual theory of sternal origin.

Charlotte Mueller ('06) worked out the development of the thorax in a series of human embryos. She modeled the entire thoracic framework, including vertebral column, ribs, and sternum. The series of models as pictured in her paper are fine examples of the possibilities in careful modeling of large and complicated structures. However, her youngest stage had the sternal bands, though remote from each other, firmly fused on either side with the costal cartilages, and, following Ruge, she describes the sternal bars as arising from the ribs. She makes little other contribution to the subject of sternal genesis, for her material, like Ruge's, was far too advanced for the early history of this bone.

It is at once apparent that the theory of Parker, Ruge, Mueller, etc., on the one hand, and those of Paterson, Whitehead and Waddell on the other are mutually exclusive. But it would seem that those of Paterson and Whitehead and Waddell have only an apparent incompatibility, and that at least in so far as their observations go, each was correct in reporting what he saw, but the fact that they worked on very different forms and interpreted their results in a widely different manner, leads to the belief that they were looking on opposite sides of the same shield, and that it is possible to reconcile the two.

The 'in situ' theory of Whitehead and Waddell is hardly to be taken seriously. So ancient a structure as the sternum, dating back to the Elasmobranchs, as we have seen, and found in every higher group of vertebrates, including at least one or two teleosts, and having an enormous and highly complex development in many of the groups, can scarcely be accounted for in this simple fashion. The 'in situ' theory took form from the material upon which its authors worked. The pig is the basis of their main conclusions and this form is peculiarly unsuited for this work, because of the degenerate character of the shoulder-girdle, which is lacking at once in both clavicle and coracoid process (the so-called subcoracoid now being thought to be an epiphysis). For a proper interpretation of the sternum and shoulder-girdle in the mammals those groups with well-developed clavicles, episternals, suprasternals, and other appurtenances of this

region are the only ones which can be lined up with the lower groups of vertebrates. The rat was used by Paterson and the mouse is the basis of the present paper, and this would seem to be the ideal form; for the rodents, while highly specialized in some respects, are primitive in others, and are to be grouped with the Edentates and Insectivores somewhere near the monotreme stem. They are also small enough so that when sectioned, comparatively high powers of the microscope may be used, and it is possible to section all stages up to the ripe fetus.

Discarding, then, Whitehead and Waddell's theory of sternal origin, while retaining an appreciative memory for their valuable work in combating one of the remaining theories, we can reduce the great mass of papers and discussion on this subject to just two absolutely irreconcilable theories of sternal origin, which may for convenience in treatment be designated as Ruge's 'theory of costal origin,' and Paterson's 'theory of coracoidal origin.' All other workers, except Whitehead and Waddell, have supported one or other of these theories or modifications of them.¹

¹ Through the courtesy of Doctor Kingsley, I have just received two papers on the sternum, one of which requires mention. This is by Albrecht: *Sur les Copulae Intercostoidales et les Hemisternoides du Sacrum des Mammifères*. Bruxelles, 1883. It contains a most curious modification of Ruge's theory of costal origin. Albrecht's idea is that the first and second ribs of each side at first are united by an arch of cartilage, giving, according to his schematic figures, a structure similar to a horseshoe magnet, the two arms of the magnet being the ribs, the arch connecting them the sternal band. Then by a union of the two sides in the midline, and the fusion of the consecutive pairs of such magnet-shaped structures, a sternum is derived. This is ingenuous and is the only theory of costal origin which gives the sutures between the sternebrae their proper position, i.e., opposite the ends of the ribs, making the sternebrae intercostal as they actually are. However, the arguments used to overthrow Ruge's theory apply equally here. This theory does not account for the anterior and posterior extension of the sternal bands for a considerable distance beyond the region of ribs; it does not explain the appearance of the bands prior to their union with ribs; and fatal to Albrecht's hypothesis is the fact that the bars are continuous, unsegmented structures throughout their entire length from their earliest appearance in the mesenchyme, and never occur in short, semicircular segments connecting the ends of the ribs. Albrecht was evidently unable to find any stages in actual material in support of his theory, for his figures without exception are diagrammatic, and do not fit the observed facts of sternal development.

To sum up, then, there are extant at the present time in the literature three opposing theories as to the origin of the sternum in the Mammalia. The oldest and most generally accepted of these is that proposed by Ruge in 1880, which in substance states that the sternum is a direct derivative of the ventral ends of the costal cartilages.

In 1900 and more fully in 1902 and 1904, Paterson was led to doubt the validity of Ruge's theory, claiming that there was an earlier history than that of which Ruge was aware. Paterson derived the presternum from the same element which gives rise to the shoulder-girdle, describing a continuous cellular element crossing the midline in the rat. He derived the sternal bands from this presternum as backward prolongations, which later and secondarily are fused with the ventral ends of the ribs.

Whitehead and Waddell ('11) agree with Paterson that Ruge did not have the earliest stages, and that his theory is therefore untenable, but they disagree with Paterson as to the interpretation of these early stages. They deny any connection or relation between sternum and shoulder-girdle, believing that both presternum and sternal bands arise 'in situ.'

This discussion of the literature is one of selected papers which supports one or other of the different theories of sternal origin and is fairly representative of the literature. However, only a few papers are mentioned in comparison with the voluminous literature extant. The author has collected a bibliography of about one hundred titles on the sternum, but has considered it necessary to treat only a few of the more prominent ones in this connection, with the assurance that those omitted contain nothing new or affect the situation as outlined here.

It has added greatly to the confusion existing between these opposing theories that most of the more important papers (Ruge's excepted) are very inadequately illustrated. Paterson ('02) does not give a single figure in this paper and his figures in the 1900 paper are small and inadequate. Important stages are described in the Whitehead and Waddell paper, but those upon which they base their chief conclusions are not supported by any figures. If we had clear-cut drawings of Paterson's continuous

cellular element extending across the middle line, and could compare this with equally well-drawn stages from the material of Whitehead and Waddell, an unprejudiced worker, from a study of the figures, supplemented by his own observations, might bring the whole tangled mass into harmony. As it is, the present author has but little to start with except the verbal statements of the opposing theorists.

Table 1 gives at a glance the position of several of the leading workers in their attitude toward the problem.

TABLE 1

	ORIGIN OF STERNUM	FORMS STUDIED	HOMOLOGY OF PRESTERNUM
Ruge, G. ('80)	Ventral ends of ribs	Man	
Paterson ('00) Paterson ('02) Paterson ('04)	Shoulder girdle	Rat, rabbit, man, dogfish	Middle part shark girdle
Kravetz ('95)	Two longitudinal bars	Pig	No morphological importance
Mueller ('06)	Ventral ends of ribs	Man	Episternum
Parker ('91)	Coracoidal and costal	Hexanchus Apteryx	Omo-sternum in shark; omo-sternum in amphibia
Whitehead-Waddell ('11)	'In situ'	Pig, cat, man	Episternum; prosternum
Rathke ('48)	Two longitudinal bars	Batrachia, chick, pig	

III. THE ONTOGENY OF THE STERNUM

The earliest development of the sternum in a number of mammals has been worked out by Paterson, Kravetz, Whitehead and Waddell, and myself. An attempt is made to compare the steps of development in ontogeny with those in the phylogeny of the sternum, or in other words to make a practical demonstration of Haeckel's recapitulation theory as applied to sternal development.

1. The sternal bands

One decisive result of this investigation has been to demonstrate the existence of the sternal bands as independent structures far earlier in development than Ruge and the older workers suspected. Hence a new theory of sternal origin was demanded, and as above indicated, this has taken two directions: Whitehead and Waddell do not relate the sternal rudiment genetically to any preexisting structure, while Paterson identified it with the coracoidal girdle of lower forms.

The conclusive evidence against Ruge's theory of costal origin led the author to examine the material of Paterson and Whitehead and Waddell, in an effort to confirm one or other of these workers or reject both, as the case might be. Paradoxically enough, I have been able to corroborate Paterson's account of the shark-like girdle, found by him in the rat, both in the mouse and human embryos; and in the identical slides² of cat and human embryos used by Whitehead and Waddell have been equally able to confirm their observations. In pig embryos of 24-mm. length, Kravetz found that the first rib did not reach the sternal band, and the connections of the remaining six ribs were too feeble to have any morphological importance. Whitehead and Waddell studied a 24-mm. pig in which the first rib did just reach the sternal rudiment and the union of the other six ribs was marked. My 24-mm. stage agrees with that of Kravetz in that the first rib does not reach the band, and with Whitehead and Waddell's in that the connection of the other

² My sincere thanks are tendered Dr. C. W. F. McClure, of Princeton University, and Dr. George L. Streeter, of The Johns Hopkins University, for the loan of the series of cat and human embryo studied by Whitehead and Waddell.

six is marked. No special significance attaches to these variations since individual differences in development as well as in measurements and amount of shrinkage gives form for considerable variation. However, in stages of the pig 22 mm., 20 mm., 18 mm., and smaller, there is no doubt of the failure of several pairs of the anterior ribs to meet the sternal rudiment.

Figures 3 and 4 are of two cat embryos from the Princeton Embryological Collection. Camera-lucida drawings were made of the sternal bands and ventral ends of the ribs. These structures were then plotted upon millimeter-ruled paper, which gives a graphic reconstruction made to scale. Several wax models were also made from the early pig and mouse embryos. Figure 3, of the 12-mm. cat embryo, shows clearly that in this stage the first three pairs of ribs do not extend to and unite with the sternal bands. It is also apparent that no anterior sternal rudiment or presternal rudiment is present at this age. It is undoubtedly true, as claimed by Whitehead and Waddell, that in the ontogeny of the mammalian sternum the two sternal bands antedate in appearance the median and anterior rudiment. However, in the phylogeny of the sternum, as will be shown further on, the presternum is the first to arise, and from this come the sternal bars. I am unable to account for this discrepancy by any observed facts, but think the history from phylogeny must take precedence over that from ontogeny; explaining the rise of the sternal bands in the mesenchyme of the mammal as the result of protoplasmic memory, which dates back to the early reptilian ancestor in which the presternum grew backward as two prolongations that became the mesosternum and the xiphisternum,

In human embryos from the F. P. Mall Collection studied by Whitehead and Waddell and myself, is found the best evidence of the complete separation of ribs and sternal bars in the early stages of development. In embryos 10.5 mm. and 13 mm. long none of the ribs reaches the sternum, the presternum has not yet appeared, and no clavicles are apparent. These stages, if graphically represented, would appear similar to figure 3 of the cat, except that all the ribs would be in the same relation to the sternum as are the first three in the stage of the cat figured.

2. *The anterior median sternal rudiment*

In the mouse, rat, and human embryos occurs a stage in which a mesenchymatous girdle appears, in shape and relations comparable to the pectoral girdle of the shark. Figures 5 and 6 show this girdle in the mouse and human embryos. It is composed throughout of mesenchyme cells, and the structural development of each part may be followed in later stages. In the mouse girdle the two dorsally extending wings on either side are the rudiments of the scapulae; the medial and ventral extensions are the coracoids and clavicles; the enlarged portion in the ventral midline is the fundament of the presternum. This is conclusive evidence that the presternum is intimately associated with the shoulder-girdle in the earliest ontogenetic stages in the mammals, just as they are also phyletically bound together in the evolution of the vertebrate shoulder-girdle (*infra*).

The mesenchymatous material extending from the scapulae to the presternum (fig. 5) is the track in which the clavicles will soon develop. In the human embryo (fig. 6, *cl.*) this has already commenced on one side. According to Gegenbaur and his followers, the core of the clavicles is the old cartilaginous precoracoid of the Amphibia. If it be true that the clavicles do have a precoracoidal core of cartilage, as Gegenbaur thought, here is the coracoidal extension in the human embryo reaching the presternum in the ventral midline, just as it does in *Hexanchus*, Amphibia, Reptilia, Aves, Monotremes, and fetal Marsupialia (*infra*).

Gegenbaur's clavicle containing a precoracoidal cartilaginous core has been attacked in several papers by Broom, who denied the presence of any cartilage in the earliest stages of the clavicle. However, Broom admits that cartilage does appear at a later stage in the development of the clavicle, and it may be assumed that cartilage appearing either as a clavicular basis (Gegenbaur) or at some later stage (Broom) would in this region in highest probability be coracoidal tissue. This position is strengthened when it is recalled that in the Anura a precoracoid actually functions as the core of the dermal clavicle. Huntington³ is

³ From a private communication containing Huntington's views on several shoulder-girdle problems, kindly prepared and sent to the author October 30, 1918.

the latest defender of the Gegenbaurian hypothesis, and, going a step further even than Gegenbaur, declares that in the case of the frog's girdle there is a "preparatory action on the part of the coracoid cartilage directed toward the reception and assimilation of the corresponding dermal accession of the clavicle."

In later stages of the mouse and human embryos, after the mesenchymatous girdle has become broken up into its component parts, the coracoid process is relatively much larger than in the adult and has a medial and ventral extension. I have observed this repeatedly in embryos of pigs, mice, cats, and man. In one mouse embryo, 7.75 mm., there seemed to be a distinct thickening of the mesenchyme between the very large coracoid process and the yet partly mesenchymatous clavicle. This was a striking spectacle in the pig, because of the well-known fact that in the adult no coracoid process is present, but only the subcoracoid, glenoid-sharing portion.

3. *Sternebrae*

The segmentation of the sternum into *sternebrae* occurs late both in phylogeny and ontogeny. A glance through the figures in the literature assures one that *sternebrae* are unknown in four of the five classes of vertebrates, being found only in the mammals. Hence they play little or no part in the origin or development of the sternum phyletically.

Likewise, they are a secondary and-acquired character in ontogeny. It is contrary to all expectation, if sternal bands are derived from ribs, to find that the *sternebrae* are invariably intercostal, and not at the point opposite the ends of the ribs. Figures 7 to 10 show what is the true condition in all fetal mammals as regards the formation and ossification of its *sternebral* elements. The center of ossification always occurs at a point midway between two ribs, while the line of transverse division crosses the sternum exactly in the center of the area of union of ribs and sternum. According to Ruge's theory, this should be just the reverse. The sutures between the *sternebrae* should be intercostal, the *sternebrae* themselves opposite the costal cartilages.

Furthermore, if the sternum is ossified from the ribs, segmentation of that structure should be apparent at its earliest appearance. On the contrary, however, the sternal bands exhibit no trace of segmentation until a late period of development. The bands may be followed carefully from section to section, or the parts reconstructed in wax, but no one has ever reported the slightest indication of an early division of the bands into segments.

The sternebrae may be interpreted as arising by a process of segmentation in response to the demand for as great a measure of elasticity on the ventral side of the animal as is allowed by the more or less flexible vertebral column on the dorsal side.

Sutures arising in this manner, as a response to strain, will naturally appear at the weakest parts along the sternum. At the points of attachment for the ribs the sternum is often deeply notched, weakening this region, and here, as expected, occur the lines of divisions of the sternum into segments or sternebrae. That this is the cause and manner is indicated by the fact that there are always the same number of sutures as there are pairs of ribs attached to the sternum. By cutting a typical sternum out of cardboard or a wax plate, and notching the sides for the reception of ribs, it is possible by applying a lateral strain to produce sutures or cracks across the cardboard or wax sternum, dividing it into sternebrae exactly as in the actual sternum.

In many of the reptiles and such animals as the cats among the mammals, where a long, lithe body in making its way through thick undergrowth or over rough ground is often twisted into almost an S-shape, the advantage of a segmented sternum is obvious. How large a part this plays in breathing is not so apparent, but doubtless has some bearing.

In the Primates where the semi- and upright position obtains, there is less need of flexibility, and the sternebrae tend to become fused into the three typical parts of the primate sternum. That the entire sternebrae development is a secondary and late acquisition and has no bearing on the origin of the sternum is quite apparent.

So far as I am aware, this will constitute the only explanation in the literature of the rise of the sternebrae, other than the statement that they represent the original costal contributions, which is, as we have shown, absolutely untenable.

4. Stages in the ontogeny of the mammalian sternum

1. Appearance of two laterally situated sternal bands, independent of ribs.

2. Appearance of a single median anterior rudiment, intimately associated with the shoulder-girdle.

3. Gradual approximation and union of sternal bands with the anterior sternal rudiment on the one hand, and with the ventrally growing tips of the ribs upon the other.

4. Gradual approach and fusion of sternal bands in midline of body to form a sternum.

5. Division of sternum into a number of sternebrae. Lines of division (sutures) always appearing opposite the ends of each pair of ribs.

6. Ossification of the intercostal sternebrae by the appearance of one or more centers for each segment.

7. Fusion of the sternebrae in Primates into three parts: manubrium; gladiolus, and xiphisternum.

5. Conclusions

1. That the sternal bands arise and remain as two unsegmented structures until the relatively late process of ossification begins.

2. That the sternebrae are invariably intercostal; arise by reason of functional demands for greater freedom of movement, and play no part in the origin of the sternum.

3. That in the mouse and rat embryos a mesenchymatous horseshoe-shaped girdle extends across the ventral midline; from this material are derived presternum, coracoids, and scapulae; this girdle being the homologue of the adult cartilaginous pectoral girdle of *Hexanchus*.

4. That in early stages of the cat, pig, mouse, and human embryos, the sternal bands exist as well-defined, separate, mesenchymatous entities, prior to their union with the costal cartilages, thus indicating their independence of, and the secondary nature of their relation to, the ribs.

IV. THE PHYLOGENY OF THE STERNUM

Paterson's comparison of the "continuous bar across the middle line" in the rat with the cartilaginous scapular arch of *Acanthias*, suggested the idea of following this structure found by Haswell, and later independently by Parker, in the middle ventral line of the shark *Notidanus* and identified by them as a presternum, up through the various groups of vertebrates to see how nearly it could be carried up in a phylogenetic series to the rodents, in which Paterson thought he had detected it again. For this purpose recourse was had to all available figures extant in the literature, and especially to that monumental monograph on the shoulder-girdle and sternum, by Parker ('68). From these sources a series of figures has been adapted, beginning with Parker's ('91) figures of the presternum in the shark, and including one figure from the Ganoids, and one each from the Teleosts and Dipnoi; then numerous figures from the Amphibia, Reptilia, Birds, and Mammals. Such a search through the literature, though wearisome, has rewarded the labor far beyond any expectations.

It is believed that the evidence presented in this phylogenetic survey would alone go far toward convincing any one of the truth of the conclusions arrived at in this paper, even though it were not preceded by the corroborating evidence of the section on the ontogeny of the sternum. It is the hope of the author that it may lead to a general agreement as to the homology and origin of the mammalian sternum.

1. Fishes

It is pretty clearly demonstrated by Haswell ('84) and also by Parker ('91) that at least in one shark there is a presternum

derived from the ends of the coracoidal portions of the usually single continuous pectoral girdle characteristic of sharks. Figure 11 shows the girdle of *Notidanus* from the ventral side with the "intercepted cartilage temptingly like a presternal" (Parker, '91). Figure 43, the first of the series of girdles shown in plate 12, is another drawing from the same form. It would seem that here is the initial material from which all later pre-sterna might possibly be derived.

The author is of course aware that neither *Notidanus* nor any other living shark is the direct ancestor of the vertebrates, and that the following phylogenetic series of figures does not necessarily mean that the successively higher animals are direct descendants of those immediately lower which are used for illustrating the points.

Among the teleosts a complete girdle across the midventral line is ordinarily lacking. However, several do have the clavicles prolonged toward the center, and when so, there is quite uniformly a cartilaginous element in the midline which Parker ('68) calls the 'epicoracoid.'⁴ This lies between the coracoids, in the identical position of a presternum. It is interesting to note from figures 12, 13, 14, and 15, that this condition is so closely alike in a ganoid, *Polypterus* (fig. 12); a teleost, *Gobius niger* Linn. (fig. 13); and a dipnoan, *Lepidosiren* (figs. 14 and 15). A description of the condition in these three fishes may be given in the account of Parker ('68) for that of *Lepidosiren annectens*: "Lepidosiren agrees with the elasmobranchs in a well developed epicoracoidal belt. Originally the epicoracoid mass must have been double, and perhaps in a very early stage each moiety was continuous with the coracoid proper, but a wide transverse cleft was soon formed which separates epicoracoid and coracoid."

⁴ In this paper the term 'epicoracoid' is employed to designate the cartilaginous ventral ends of the posterior coracoids. The author is following here the usage of Parker and others from whom many of the figures have been borrowed. That this is not the correct term, he is well aware, and in another paper is suggesting the term 'infracoracoid' as probably a more suitable one for these parts. The term 'epicoracoid' was applied to the anterior element of the monotremes by Cuvier, and this use should be retained.

Figures 14 and 15 show the epicoracoid to have a large mid-ventral portion, rounded out anteriorly and posteriorly (comparable directly with the so-called presternum of the shark and the omosternum and sternum of the Amphibia), while laterally extend two bars, the parts which originally were continuous with the coracoids. Here there is cut off from the coracoids that material which nature will use in all higher classes of vertebrates in the construction of a presternum. And if it be said that this dipnoid fish is not the direct ancestor of the Tetrapoda, it may be replied that every consideration points to the same condition in the direct ancestor, whatever form it was. Both Paterson, in the rat, and the author, in the mouse, found stages in early embryo of these mammals where the clavicles, extending toward the midline, are closely invested with mesenchymatous bars which unite into a single, median mass, comparable at once to this epicoracoid in the dipnoid fish and to the 'presternum' of Haswell's shark, and actually in the rodents uniting to form the manubrium.

2. *Amphibia*

A similar sternum is found in the Amphibia. As Howes remarks, "that the Amphibian sternum is for the most part, if not wholly, a derivative of the shoulder-girdle, there can be no longer a question; and although the researches of Goette ('77) leave us in doubt concerning the hypo (post-omosternum) they show that that can be no derivative of the costal apparatus."

Parker ('91), believing in the diverse origins of the sternum in the Ichthyopsida and Amniota, also describes a dual origin for the sternum in the Amphibia. He says, "a pair of narrow strips are separated off from the posterior borders of the coracoids," also "a pair of cartilaginous bands appear in the inscriptiones tendineae of the *mm. recti abdominis*. From these four elements the sternum is produced." Ruge considers that these cartilaginous bands are to be looked upon as vestigial ribs. The narrow strips are admitted to be from the shoulder-girdle.

This description of two cartilaginous bands appearing in the inscriptiones tendineae is strikingly similar to the account of the sternal bands in the pig by Whitehead and Waddell. There seems to be no antagonism anywhere to the view that in the Amphibia the anterior part of the sternum is the product of the shoulder-girdle.

Nor is it necessary to stretch any morphological relations unduly to see this coracoidal sternum reproduced in the Dipnoi, Gobius, Polypterus, and Notidanus. We must agree with Parker ('91), Haswell ('84), and others, that the sternum in the Ichthyopsida is coracoidal in origin and homologous throughout that group.

From here on, however, we part company with all early workers, and most later ones as well, for all of them accept Ruge's conception of a costal sternum in the Amniotes, and deny any homology between the sterna of Ichthyopsida and Amniota. One of the designs of this present phylogenetic sketch is to show from figures and data already in the literature that the two are one and the same thing in origin and development, and therefore homologous.

As practically all are agreed that the sternum in the Amphibia is coracoidal in origin, while but few are agreed that it is so in the Amniotes, we are brought to the necessity of bridging in some manner the alleged gulf between the amphibian and reptilian sternum.

In order later to make direct comparisons between amphibians and reptiles, when treating the latter group, it is necessary to introduce here a number of figures and remarks thereon for several representative amphibians. Starting with the frog, figures 16 to 19, inclusive, give a very good idea of the development of the coracoids and sternum in this form. It is hardly necessary to point out the close relation between coracoid and sternum nor to suggest that the figures can lead only to one conclusion, that of a coracoidal origin for the sternum.

Pipa (fig. 20) has a sternum which, as Parker says, challenges attention. A little study of this figure will convince one that the sternal region must have been at one time a part of, and

continuous with the epicoracoids. The ossification in each is at exactly the same stage; the amount of soft cartilage around the edges is the same in coracoid and sternum. At the anterior end is differentiated a small region that corresponds to the larger omosternum in the frog. We shall come back to *Pipa* when treating some of the reptiles, and by a comparison attempt to show that this subreptilian creature has a sternum essentially like certain reptiles.

Does *Bufo* (fig. 21) have a sternum? Kingsley ('17) would say that since no ribs are in this region, no one can say. On the theory of Ruge, this would be true, but if we compare the sternum of *Bufo* with that of *Pipa* and the early stages in the frog, it is hard to believe that there is any essential difference between the two structures, although the connection of the sternum with the epicoracoids in *Bufo* is not so extensive as in many other Amphibia. The entire body of evidence in this paper and many others on the shoulder-girdle in the Amphibia can only lead to the conclusion that *Bufo* does have a sternum and that it can only be derived from the coracoidal portions of the shoulder-girdle.

Siredon (fig. 22) has large coracoids and a considerable overlapping of their epicoracoidal edges. The interesting feature to us is that the sternum lying immediately behind the overlapping epicoracoids also shows very distinctly two grooves corresponding exactly to those made by the overlying edges of the epicoracoids. It is the condition precisely to be expected of the sternum if it were in an early stage a posterior continuous extension of the cartilage, sharing in the overlapping, and then later had been cut off by sutures from the main element, but retaining these evidences of its formation from the two epicoracoids.

Little need be said concerning such a girdle as that of *Dactylethra* (fig. 23). There is no overlapping of the coracoids and no sutural evidence in the sternum of the union of the two sides; however, as this is an adult specimen, none need be expected. Nevertheless, the intimate relation of sternum and girdle is evident.

In *Calamites* (fig. 24) we see a sternum that for the first time

has two backward prolongations, or sternal bars. This sternum is very suggestive of several in the reptiles, and embryos of the mammals, where a single median anterior rudiment is continued backward as two rods or bars. This is an adult specimen and therefore the permanent form in this species; if, however, we compare this with several of the reptiles, such as shown in figures 26, 27, and 28, and with descriptions by Rathke, Bruch, Paterson, etc., of the early sternum in the mammals, there appears to be more than a mere resemblance—there is genetic relationship and homology. If in *Calamites* the coracoids were to retreat to a mere process attached to the scapula, leaving only the clavicle and sternum in this region, and the sternal bars of the latter fused together in the midline, leaving a fossa at the upper end of the union as in many reptiles, and the posterior ends were but incompletely fused leaving two small blunt laterally projecting horns, we would have a sternum such as is actually found in *Chirotes* (fig. 30) and the embryos of mammals.

Wilder ('03) describes several cartilaginous rudiments found in *Necturus* and related by him to the sternal apparatus. These are a series of thin cartilages located in the myocommas of the pectoral region. One of them is usually larger than the rest and situated near the posterior part of the overlapping coracoids. This element is identified by Wilder as the homologue of the sternum of the higher Urodeles.

If Wilder's theory be correct, *Necturus* presents an exception to the rule established in this paper that the presternum is a derivative of the coracoids, for obviously this element in *Necturus* could not possibly be derived from that source. My own dissections of *Necturus*, however, do not bear out Wilder's hypothesis. My interpretation of these cartilages is, that they are simply chondrifications of the outer part of the connective tissue of the intermuscular septa and have no relation whatever to the formation of the presternum in higher forms.

They are rather to be looked upon as subcutaneous splints and find their homologues in the inscriptiones tendineae of other forms, and also possibly in the abdominal ribs of *Chamaeleo* and *Polychrus*. It is significant to note in this connection that many

animals have both the inscriptiones tendineae and also a complete sternal and costal apparatus. If the latter be the derivative of the former, why this persistence of the two structures side by side in nearly all groups above the lower Urodeles?

3. Reptiles

Fossil reptiles constitute the next group in which we have looked for a sternum or any part of one which either originates independently of the ribs or which has intimate relations with the shoulder-girdles. The author has studied figures and plates of much of the recent work done on fossil reptiles, of which the investigations of Credner ('81-'93), Gregory ('15), Seeley ('92, '94), Woodard ('98), and Zittell ('00, '13) are typical, and, in addition has examined a number of mounted specimens in the U. S. National Museum. It may be said in general that in those skeletons which have the shoulder-girdles preserved there is a strong tendency for the coracoids to grow around the side of the body ventrally, though never meeting in the midline, for the soft epicoracoids are not preserved, and that the coracoids are enormously developed in size.

Gunther ('67), Schauinsland ('00), and Howes and Swinnerton ('01) worked on the development and anatomy of that primitive and now almost extinct reptile from New Zealand, *Hatteria punctata* or *Sphenodon*. In one of Gunther's figures the shoulder-girdle and sternal bars are shown in their natural relation at that stage. The coracoids do not have a large ventral extension, but are capped on their medial ends by slender processes which later unite to form the presternum. Three pairs of ribs reach each sternal bar, so that the sternal and costal connections are much too far advanced for any statement as to the origin of the sternal bars in *Sphenodon*. So far as I am aware, this is the youngest stage of the *Sphenodon* sternum figured in the literature.

From the condition in the embryos of living reptiles, as well as in many of the adult species, it may be assumed that in the early condition of fossil reptiles the coracoids were in intimate relation to the sternum.

When we come to consider the living reptiles the material and evidence is abundant and of the greatest significance.

Among the recent forms, Goëtte ('77) has studied *Cnemidophorus*. While he does not show conclusively that the two anterior triangular rudiments are products of the nearby coracoids, he demonstrates that only the first ribs have reached and attached themselves to the sternum, while that part of it opposite the second and third ribs is formed independently of them, as a backward prolongation of the anterior paired rudiments.

These results of Goëtte showing that the sternum is the result of a backward growth of tissue from an anterior portion are in striking anticipation of what Paterson claimed to see in the rat, where it is stated that the anterior median portion of the sternum is derived from the same element as is the shoulder-girdle, and this in turn yields the sternal bands as posterior prolongations.

Anguis fragilis (fig. 25) has a sternum that in many respects is typically amphibian in character, as may be seen at once by a comparison of this form with that of *Pipa*. As in *Pipa*, there is only present an anterior or presternum, separated by sutures only from the epicoracoids, and as in *Pipa*, ossification and the amount of soft cartilage around the borders are the same for sternum and coracoids. Of this form Parker ('68) says, "there is a well developed sternum, not continuous with the ribs;" and Rathke, describing two embryos of *Anguis*, says, "with the coracoids the sternum was intimately united, but it was not very closely connected with the neighboring ribs, lying at a much greater distance from them than in adult Blindworms. There cannot be any doubt that in the Blindworms the two latter halves of the sternum do not originate under the ribs, and unite with them, but develop at a distance from the ribs." Barring the presence of the interclavicle in *Anguis*, it would be difficult to recognize this shoulder-girdle as being that of a reptile, for in the relations of its girdle and presternum and in the absence of ribs it is characteristically amphibian.

Stellio cordylinus (fig. 26) has a sternum in which the anterior part is enormously enlarged; is in intimate relation to the epicoracoids, and in addition has two greatly extended xiphisternal

horns. No ribs are attached to these horns, but three pairs reach the anterior portion, to which they are but feebly attached. If it be assumed that the presternum here is of necessity derived either from the coracoids or from the ribs, the answer can only be that it must have come from the former. This sternum with its great horns reappears in *Manis longicauda* (Parker, '68).

A series of three figures (figs. 27, 28, and 29) gives an idea of how the mesosternum and xiphisternum are formed. In figure 27 the presternum is as before, and the two bars extend caudally. This is very similar to the amphibian *Calamites* (fig. 24), and the suggested series of changes outlined in the description of *Calamites* necessary to make of it a typical reptilian or mammalian sternum are progressively illustrated in these three reptiles.

In figures 28 and 29 the xiphisternal bars, by a fusion along their medial surfaces, have formed a middle sternal piece or mesosternum. The posterior ends of the coalesced bars remain apart in the xiphisternum.

In the mesosternum is a sternal fossa, where the union was not complete. This may persist throughout life in many forms (*Varanus*, *Crocodylia*) or, as in others, close up later, leaving a whitish streak to indicate the line of fusion. This fontanelle is also common in mammals, but there it is usually located in the xiphisternum, and I have also repeatedly observed the whitish streak of hyaline cartilage in the mesosternum in fetuses of pigs and mice. It would seem from this reptilian material, and avian and mammalian material agree, that the presternum is a product of the coracoids, and this in turn gives off two backward prolongations, which, fusing throughout a greater or lesser part of their extent, form the mesosternum and xiphisternum. It is hardly necessary to again point out the feeble relation of ribs and sternum in these last three figures.

Chirotes (fig. 30) gives the completion of the series; it is a sternum of the utmost importance in the consideration of the problem. Parker's description is so trenchant that a part is quoted:

In the whole range of vertebrate morphology there is nothing more beautiful or more instructive than the relatively large sternum of Chi-

rotes; for if the sternum of the human embryo were to be demonstrated apart from the costal girdles, one diagram would serve to explain both that and what we find in this little snake-like lizard . . . and if ribs had not been arrested we might have seen the counterpart of the ribs of the mammalian embryo.

The figure is of an adult, and, as Parker says, it might also be described as that of the mammalian embryo, except that no ribs are present and the sides of the presternum are closely applied to the coracoids. Now, if Paterson and the author be correct in their contention that the presternum and coracoids in the rat and mouse are continuous at an early stage, and this stage precedes the fusion of ribs and sternum, then the adult *Chirotes* sternum is a structure that far more closely approximates the early embryonic sternum of mammals than Parker suspected when he made the comparison above quoted between the two. This is a more striking parallel than is usually met between the adult structure in a lower group and an embryonic stage of the same structure in a higher group.

While probably all will admit the above argument, since both are Amniotes, the question may be raised as to whether there is any evidence for relating such a sternum as occurs in *Chirotes* with the amphibian sternum, for the crux of the whole matter of sternal homology lies between these two groups. It would seem that a direct comparison might be made with the *Calamites* sternum, and this structure, as has already been indicated, by a fusion of the sternal bars, and a retention of the sutural relation to the epicoracoids might be metamorphosed directly into the adult sternum of *Chirotes*, and this is especially strong evidence when we consider that in neither the reptile nor amphibian compared does the question of ribs enter at all, since there are none in either form in the region of the sternum.

Using the crocodile (fig. 31) as a contrast to *Chirotes* in showing the extreme of fusion of ribs and sternum in reptiles, it may be remarked at once that aside from the presence of ribs this sternum is directly comparable with the last one considered. The difference is due to the ventral growth and attachment of ribs to the sternum, otherwise it is essentially the same as more primitive

reptilian sterna having a presternum in close conjunction with the coracoids; a middle piece composed of the union of two longitudinal bars, with the line of fusion clearly evident, and the xiphisternal horns wide spread. A close comparison may be made between this and the later stages of the mammalian sternum, except that in them all connection with coracoids is early lost.

A *Chamaeleo vulgaris* adult sternum (fig. 32) is the last reptile considered here. It is mammalian-like and well ossified for a lizard. The presternum is a large, lobate structure, bearing two strong notches on either side on its posterior end, "this constriction answering to the transverse cleft so constant in the mammalian sternum" (Parker, '68). In the mesosternum the line of fusion of the two halves is well marked and extending also into the presternum. The ribs articulate by synovial joints with a series of enlargements on either side of the mesosternum. In describing the xiphisternum, Parker ('68) says, "The xiphisternum has a bilobate extremity that is quite mammalian in character and no ribs ever reach this part . . . the horns being free from ribs, grew not only towards each other and fused, but also grew backwards, so as to form a free, single xiphisternum, exactly like that of an ordinary mammal. That there is no real difference between these two classes in the formation of the xiphisternum, I feel certain. . . ."

The interesting fact about *Chamaeleo* is the statement of Parker that behind the xiphisternum there are seven pairs of floating ribs which later become fixed by growing toward each other and unite by suture at the midline. This is significant in the light of our contention of the non-relationship between pleural ribs and sternum. There is a distinct tendency in all vertebrates with ribs for these to grow ventrally. Now, if a sternum be present, it is likely that they would form an articulation with it; if none is present, that they should either remain free (floating) or unite (true ribs) with each other in the midline. In the chamaeleon both conditions are present in one animal; those anterior thoracic ribs which, growing ventrally, met the sternum and articulated with it, while those ribs immediately behind the

sternum kept on growing until the respective pairs met and fused in the midventral line. *Chamaeleo* is considered to present strong evidence of the secondary character of the relation between ribs and sternum, and it is an important intermediate stage in the development between the typical reptilian sternum and the same structure in the mammals.

The preceding account of the development and anatomy of the sternum in the Reptilia and a comparison with the same structure in the Amphibia must inevitably lead to the conclusion that, if the presternum be coracoidal in origin in the Amphibia, it is equally so in the Reptilia. For, beginning with that most primitive reptilian sternum in *Anguis*, and comparing with *Pipa* and other Amphibia, the gulf was bridged between these two phyla, and then by a series of successively more highly developed sterna in the reptiles a stage is reached (*Chirotes*) which spans the divide between the reptiles and mammals. We have also seen how in one amphibian (fig. 24) the beginning of sternal bands arises, and in the reptiles these are developed in the same way, and in higher reptiles fuse to form the mesosternum and xiphisternum, preparing the way for the typically mammalian sternum, soon to be considered.

The last fact concerning the Reptilia is in regard to the extremely variable relation of ribs and sternum, both as to number and position. Rathke ('53) had an interesting paragraph on this which is quoted in part:

In typical scaly lizards several ribs are always in relation with the sternum; still . . . it may be either only the anterior division (manubrium) which is connected with ribs, or it may be exclusively the posterior part. But, generally speaking, the number of ribs which are intimately connected with the sternum, and to which the name of true ribs can be applied, not only varies with the genus, but is also very variable in different species.

Both Rathke and Parker give long lists of species of reptiles showing this variability in the number and position of ribs reaching the sternum. Their lists comprise some fifty species, but only a few are mentioned here as indicating the range of variation found by them. Their figures show that in some species

with the largest number and most intimate union of ribs to breast bone the sternum is but feebly developed; while, on the other hand, some of the largest sterna have the fewest number of ribs and feeblest connection of the two; or, as in *Chirotes*, a fully developed sternum showing the three typical divisions is present, but no ribs reach the sternum—conditions hardly to be expected if the ribs contribute the sternal materials.

The following table is a composite one from several authors and shows but a few of the numerous forms they list.

	RIBS TO MANUBRIUM	RIBS TO MESOSTERNUM
<i>Chirotes canaliculatus</i>	0	0
<i>Anguis fragilis</i>	0	0
<i>Chamaeleo pumilis</i>	1	0
<i>Monitor dracaena</i>	2	1
<i>Draco viridis</i>	3	0
<i>Stellio vulgaris</i>	3	1
<i>Calates pictus</i>	3	3
<i>Iguana tuberculata</i>	4	2
<i>Crocodylus acutus</i>	2	5
<i>Gavialis schlegelii</i>	2	7

4. *Birds*

Birds, although not in the line of descent of the mammals and also having a sternal apparatus highly modified for purposes of flight, are still not difficult to bring into line in this argument. However, it is hardly necessary to do this as we are following successively more complex and highly differentiated groups in their phylogenetic course. Nevertheless, to show that there is nothing contradictory to our thesis among the birds, one figure of a bird is introduced. This is *Vanellus cristatus* (fig. 33) and is of a stage at the end of the first third of the incubation period. Parker's remarks upon this sternum give us the pertinent facts: "The longitudinal bands are long and wide, and in great contrast to the very slender pairs of ribs attached to them. On the other hand, a transverse cleft between the epicoracoids and the antero-lateral margins of the longitudinal bands would give us the con-

dition as here found. The sternum of *Vanellus* is not a highly complex structure, as such structures go in the higher birds, but shows many affinities to the reptilian stock."

It would be absurd to think that these large, heavy sternal bands were originally derived from the feeble and loosely attached pairs of ribs, while it is entirely plausible to suppose that in an earlier stage a continuous sheet of cartilage on either side was subsequently differentiated into sternal bands, coracoid, and scapula. That this is actually the state of affairs in early embryos of several mammals will soon be shown.

That the development of the sternum is largely independent of ribs in the birds, as in reptiles, is further shown by Parker's observations on *Apteryx*:

In the earliest stage in which the sternum is present it extends backwards to the level of the third thoracic rib; the first two ribs are united to it by joints, the third loosely attached by connective tissue. In the next stage, the first three ribs are attached by joints, and the fourth by connective tissue, that is, as it appears to me, the portion of the sternum corresponding to the third and fourth ribs is formed by *a backward growth of the anterior region and quite independently of the last two ribs* (italics mine), the union of which with it is a secondary process.

This is just about what Paterson says concerning the development of the sternum in the rat, except that it leads him to conclude that the sternum is not of costal origin, while Parker, giving all the evidence necessary to substantiate Paterson's view, is nevertheless himself oblivious of the logic of his own work, and makes the surprising statement that "the relation of the shoulder girdle to the sternum is altogether secondary, and forms no part of the axial skeleton, as the Transcendentalists vainly teach."

The above account of conditions in the birds seems to be sufficient to relate genetically the sternum in birds to that of reptiles and mammals, and while of little or no philogenetic value in this connection, yet the evidence shows the avian sternum to be homologous with the sterna throughout the entire vertebrate series, one of the theses for which this paper contends.

5. *Monotremes*

The monotremes (fig. 4) have long been held to have a sternum closely reptilian in character. In addition to the coracoids, which are firmly attached to the sternum, there is also an anterior paired element, usually called the epicoracoid. In these there is an overlapping in the midline much as in certain amphibians, and in a recent paper Watson ('17) holds that the epicoracoids of the monotremes are nothing other than the precoracoids of the lower forms. That typically reptilian structure, the interclavicle, is also present. As seen in the figure, there is noticeable a compactness of the elements of the shoulder-girdle and sternum, as if these might have been in the early embryo or in the ancient progenitor a single shield-like plate, such as occurs in *Pipa* (fig. 20) or in many of the reptiles.

6. *Marsupials*

In 1897 Broom discovered in the marsupial *Trichosurus vulpecula*, measuring 17 mm., a well-developed coracoid, which was at birth "structurally continuous with the sternum." Figure 35 is an anterior view of the entire scapular arch which in general outline is strikingly like that of the shark. Its ventral middle portion is a part of the sternum, yet the parts are, as Broom says, not jointed, but constitute a single bar of cartilage.

In a smaller specimen (fig. 36) of 8.5 mm. of the same animal both cartilaginous and mesenchymatous elements are present in the coracoid; the cartilaginous part being that nearest the glenoid cavity, and the mesenchymatous spreading out in a fan-shape portion, which is continued without any interruption into the mesenchymatous sternum. It is apparent that this marsupial has a complete scapular arch crossing the middle line; and that, from the history of the later stages, the sternum as well as the girdles are known to be its derivatives. Furthermore, just in front of the coracoid and posterior to the clavicle, there was "a thin, feebly developed continuous sheet of mesenchymatous cells;" lying therefore in the exact position of that anterior coracoidal element of the monotremes generally called the epicoracoid,

but by some the precoracoid. That the two structures, i.e., the epicoracoid of the monotremes and this "sheet of mesenchymatous cells" are homologous is the belief of Broom. In the larger specimens (37 mm. and over) the coracoid becomes detached from the sternum by a process of degeneration, and this continues until the well-known adult condition is reached (fig. 37) where coracoids and sternum are far apart.

However, in a mammary fetus 23 mm. long an intermediate condition was found. As Broom describes it:

The coracoid process is similar to that in the large foetus, but from it there is produced backwards and inwards a small cartilaginous process, which nearly meets the outer process of the presternum. It may thus be concluded that during the later intra-uterine development of *Trichosurus*, and probably of other marsupials (later verified in other marsupials), there is a well developed coracoid, which, as in the adult Monotremes, most reptiles, birds, and amphibians, articulates with the sternum, and that shortly after birth, the coracoid loses its attachment with the sternum, and becomes rapidly absorbed, only the anterior part remaining as the coracoid process.

From this description it appears that the degeneration of the coracoid begins in its middle part and absorption progresses toward each end. In the marsupials that part of the coracoid attached to the sternum is completely absorbed and no trace of it is found in the adult, while the half connecting with the scapula is represented in the adult by the coracoid process. In this connection mention may be made of a peculiar structure I find in the mouse and rat, and an almost constant structure in rodents, as figured by Parker ('68). In most of his figures of the Rodentia, there is a small bony process on either side of the presternum between the juncture of the clavicle and the first rib with the sternum (fig. 38). Parker calls this process the epicoracoid and says it was left by the retreating coracoids of the lower forms. It would seem from my observations on the mouse, described above, that Parker is correct to the extent that this is the median end of the coracoid, but wrong in making it simply an hereditary rudiment. It is, rather, the end of a complete embryonic coracoid, which in the rat, mouse and man, as in the marsupial, extends across to the sternum in an early stage. Whereas in the

marsupial and most other mammals, all trace of this sternocoracoidal piece is lacking in the adult, it persists in the rodents, and also in the narwhal (*Monodon monocerus*), and the blackfish (*Globicephalus melas*), and possibly other animals. In other words, in the rodents there is at first a complete coracoid reaching from the scapula to the sternum; later, degeneration of the coracoid sets in at its middle portion, and working toward each end, stops just in time to leave the coracoid process attached to the scapula and the epicoracoid to the sternum.

From the foregoing it is apparent that *Trichosurus* passes through a stage in its development, as regards girdles and sternum, which is directly comparable with that of the adult condition in the monotremes.

In a series of later papers ('98, '99, '02, '08) Broom studied a number of marsupials, both Polyprotodonts and Diprotodonts, and found that conditions throughout the Marsupialia were as described for *Trichosurus*. In a mammary fetus of the common phalanger, 14 mm. long, the well-developed coracoid articulates with the sternum almost exactly as in the adult monotremes. In the earliest stage of *Dasyurus* (fig. 39) studied by Broom, the coracoid is still large and reaches nearly to the sternum. It would seem that here absorption had commenced at the medial end rather than in the middle of the cartilage. Figure 48 (petrogale) shows a complete, unjointed arch similar to that of *Trichosurus*. *Pseudocheirus* and permales were studied in various stages and agree in general with other marsupials, so that this is obviously a normal and constant phenomenon of the marsupial embryonic girdle, as it is of the adult girdle in the monotremes.

Prior to Broom's work, it was difficult, practically impossible in fact, to pass from the monotreme shoulder-girdle to that of the marsupial, albeit the relationship of monotreme girdle to that of the reptile was apparent. Since Broom's discovery, however, of the complete girdle in the early marsupial, and also in the rat by Paterson and the mouse and man by the present author, it is clearly seen that the girdles and sternum of the higher mammals are directly comparable to that of the marsupial fetus, and this in turn to the girdle of monotremes, which are unquestioned in

their reptilian affinities. It is thought that this makes a strong case for the homology of the sternum in the Amniota and its origin in connection with the coracoids; and since this same structure is undoubtedly coracoidal in the Ichthyopsida, the two, Amniote and Ichthyopsidan sternum, are homologous.

As this work of Broom's is of considerable importance to our argument, it may be stated that Broom in his later papers verified his first discoveries in representatives of all groups of marsupials and made graphical reconstructions of the parts. His work has been checked up by Watson ('17), who made wax models of the girdles and sternum, and completely confirmed Broom's results.

7. *Aquatic mammals*

Among the aquatic mammals there are several interesting sterna. In the adult *Manatus americanus* (fig. 40) the sternum is moderately large and is typically divided into the usual three parts. This animal has seventeen pairs of ribs, but only three come anywhere near the sternum, and Parker ('68) says that only the second pair of ribs reaches it. The first and third pairs are connected with it by ligament only. Here in this adult mammal is a stage comparable to the embryo of the pig, man, etc., where ribs either do not reach the sternum or are connected with it by fibrous tissue. It is difficult to believe that this entire sternum was derived from the costal ends of three pairs of ribs, of which only one pair even approaches it.

According to W. K. Parker ('68) the sternum of the dolphin embryo (fig. 41) has reached its highest development in aquatic mammals. In the stage figured the sternal bands have fused, leaving a prominent longitudinal groove to mark the line of fusion, several centers of ossification are present, and in the pre-sternum is an oval fontanelle such as is common in the lizards. In fact, this entire structure is very reptilian in character, as is seen by a comparison with *Trachydosaurus* (fig. 28), even to the number of ribs.

In orders of mammals higher than those already mentioned the literature is scanty. Practically all papers based upon the

human embryo accept Ruge's view, and the reason is apparent when we consider that in working exclusively with the highest mammals, one is at the disadvantage of not knowing what stages may have been suppressed in evolution. It would seem that, beginning with the lowest forms and working up through each successive group, as is attempted in this present paper, a foundation is laid upon which to interpret the greatly reduced history in the higher mammals.

Does the complete girdle, sternum, coracoid, and scapula, cross the midline in forms higher than the marsupial? Since the permanent adult coracoid articulating with the sternum in the monotreme is reduced to only a fetal stage in the marsupial, we might expect this stage to be very transitory or entirely suppressed higher in the scale. Since the marsupials, edentates, rodents, and insectivores are all ancient orders and probably lie not far from the monotreme stem, among them such a stage might be found, if present. Paterson was the first to discover this in an early embryo of the rat, and I found the same thing (section on ontogeny) in the mouse of 7.75-mm. and 17.2-mm. human embryo. This is shown in figures 5 and 6, where the girdles are very similar indeed to that of a shark (fig. 2). The next stages indicate that scapulae, coracoids, and sternum are all derivatives of this single mesenchymatous element. This stage is exceedingly brief in the mouse, as compared with the marsupial, for it cannot be detected with certainty in a 6-mm. mouse, and is hardly recognizable in the 8.75-mm. mouse. This rapid suppression would lead us to suppose that possibly no such stage is present in the human embryo, yet figure 6 shows man to have retained it identically as in the rodents.

Huntington ('18) identifies the costocoracoid ligament of man as indicating "the original path of the sternal extension of the coracoid." It is interesting in this connection that the costocoracoid ligament often contains fibrocartilaginous nodules. Figure 42 shows this ligament in relation to the other parts in man on the left side of the figure, while on the right side, the fundamental plan of the vertebrate girdle as illustrated in the *Anura* is shown. Huntington does not say whether he considers the

costocoracoid ligament to be the remains of an embryonic coracoid occurring in man or only the rudimentary indication of man's phylogenesis. If this interpretation of the costocoracoid ligament as the evidence of a coracoidal connection with the sternum be correct, then from the elasmobranch to man the closest relation between coracoids and sternum is maintained. On the other hand, if Huntington's hypothesis is not sustained by later investigation, no harm is done to our attempt to overthrow Ruge's theory, for Rathke, Paterson, Whitehead and Waddell, and myself have already shown that in man and other mammals the sternum is an established structure prior to the union of ribs with it.

8. *The adult human sternum*

In the literature of the adult sternum in man there is evidence of a secondary, but interesting and corroborative sort. It may be related back to the tendency of the ribs to grow toward the ventral median line and fuse or articulate with each other, as was noted in *Chamaeleo*. This has been shown by several workers, Cunningham ('90), Dwight ('90), Tredgold ('97), Paterson ('09), and Lickley ('04), to be especially prominent in the human subject. Lickley, whose work is typical, studied a series of fifty-one human sterna with special reference to the relations of the seventh and eighth ribs to the sternum.

The number of ribs reaching the sternum in Lickley's material is shown in the following table:

	RIGHT	LEFT
Sixth ribs.....	2	1
Seventh ribs.....	43	43
Eighth ribs.....	6	7
Total.....	51	51

This constitutes a considerable percentage of variation at the posterior end of the thorax, yet whether six or eight ribs enter into union with the sternum, that structure is apparently not

affected in length or shape. Advocates of a costal origin for the sternum derive the xiphisternum from the ends of the seventh or eighth ribs or both. However, when these are absent, the formation of the xiphisternum does not seem to be affected in the least. As in the reptiles, it is a constant feature regardless of the absence or presence of ribs.

In the work of Paterson ('09) and Lickley ('04) an even more suggestive fact is clearly apparent. This relates to the tendency of ribs to grow to the ventral side and fuse as was also seen in *Chamaeleo* and noted in the discussion of reptiles. In man the seventh rib normally reaches the sternum, but in its mode of attachment we have the remarkable statement of Lickley that in over 50 per cent the seventh costal cartilages are either fused or articulate with each other in a plane anterior (ventral) to the xiphisternum. That is to say, these ribs which are anterior to the posterior end of the sternum reach the median line and fuse just as did the ribs posterior to the posterior end of the sternum in *Chamaeleo*. In all the accounts here under review the ribs act as if entirely independent of and irresponsible for the being or well-being of the sternum.

Paterson's results are not so striking in large percentages as Lickley's, but sufficiently so to give us pause, even if considered alone. He examined 236 human fetal sterna and found that the seventh costal cartilages articulated in front of the sternum in 14.4 per cent.

In this connection three special cases may be cited, the first two reported by Lickley and the last by Dwight:

1. The sixth costal cartilages articulated dorsally with the lower end of the mesosternum and ventrally with one another. The seventh cartilages articulated with the lower borders of the sixth cartilages and by their extremities with one another.

2. Girl, eighteen years. Mesosternum terminated at level of insertion of fifth ribs. The extremities of the sixth and seventh cartilages on the left side were fused together, those on the right were closely united by fibrous tissue. The two bars formed in this way articulated with the mesosternum above, and with one another in front.

3. The body of the sternum ends at the level of the fourth ribs. The fifth pair is attached to its lower end. The fifth, sixth, and seventh pairs meet one another and fuse.

Kirchner ('98) and Adolphi ('05) also describe sterna in large numbers and find many cases of variation in the posterior thoracic ribs much in accord with the above. The results of these papers on the adult sterna of the human subject, together with similar observations on the lower forms, which are pertinent to our thesis are four:

1. Ribs posterior to the level of the sternum may grow ventrally and meet by fusion or articulation in the midline (Chamaeleo).

2. Ribs at the level of the sternum may articulate firmly with it, as is the usual case in man.

3. Ribs may pass on the ventral side of the posterior end of the sternum and fuse in the midline much as they do when farther back where no sternum is present (Chamaeleo, man).

4. All ribs may fail to meet the sternum at any point without affecting the full development of that structure (Amphibia, Chirotos, Manatus, human embryo).

Plate 12, figures 43 to 49, inclusive, is designed to give at a glance a series of shoulder-girdles representing the main groups of vertebrates, in an effort to show how from the elasmobranch to the rodent, either in the embryo or throughout life, there is an intimate relation in all between shoulder-girdle and sternum, and in some it is demonstrated that they are for a time one structurally continuous element. In some (shark, lissotriton, lizard, and monotreme) this relation is maintained throughout life; in others (marsupial, mouse, rat, and man) it is of short duration in embryonic life. In all, however, it indicates a phylogenetic relationship between the shoulder-girdle and sternum in all stages of vertebrate evolution that cannot possibly be duplicated or even remotely approximated by a similar comparison of sterna and costal cartilages.

In most adult Amniotes the sternum is in close relation with both ribs and shoulder-girdle; in some, however, the connection with either ribs or shoulder-girdle may be lost (Chirotos, fig. 30,

being an example of the first, and the pig of the second); but none is known in which the relation to both ribs and shoulder-girdle is lacking. Assuming that the sternum must be either a derivative of the shoulder-girdle or of the ribs, it is clearly evident from a phylogenetic viewpoint that since the costae verae extending to the ventral side of the body were not acquired by the vertebrates until the rise of the Reptilia, whereas the sternum and shoulder-girdle, in an ever-increasing closeness of relation and association, may be traced back to the very beginning of the Ichthyopsida in the elasmobranchs, that we cannot hope to find in the ribs any clue to sternal origin. If the sternum be homologous throughout, as the conclusions of this present investigation seem to warrant, then its origin may be sought in a structure which is coexistent with it and also in the closest possible relation to it in the lowest forms. In the shoulder-girdle of the Ichthyopsida we seem to meet with both of these requirements, while in each of them the ribs fail us.

In Huntington's ('18) paper, which appeared after this work was practically completed, are certain fundamental conceptions of the shoulder-girdle and its phylogenetic relationships which indirectly corroborate my conclusions. In the first place, Huntington recognizes the elasmobranch pectoral girdle as "the primordial fundament upon which all other vertebrate modifications are built." By a dual process of segmentation and replacement by bone, all structures of the complicated girdles of the higher classes of vertebrates are derived from this simple continuous unsegmented bar of cartilage found in the dogfish, sharks or rays. Huntington was not, however, primarily interested in the sternum and did not see in the midventral portion of the elasmobranch girdle the fundament of the presternum. Like other investigators, he finds the "first appearance of the sternal apparatus" in the amphibian girdle, but notes its intimate association with the epicoracoids, which latter cartilages are beginning to loosen by sutures on either side of the ventral midline. However, it must be pointed out that these structural relations of the Amphibia (clavicle excepted) are also present in *Hexanchus*, where a suture on either side of the ventral midline gives the

'intercepted cartilage' interpreted by Howes ('91), Parker ('91), and myself as the rudiment of the presternum. If two dotted lines be added to the *Hexanchus* girdle (fig. 1), a sternum comparable to that of *Rana* is produced, with epicoracoids meeting in the midline and the fundamentals of the omosternum and sternum present.

9. Conclusions

This somewhat lengthy review and discussion of the phylogeny of the sternum in the different classes of vertebrates, together with the accompanying figures, which have been adapted and modified from various sources, has revealed very clearly several facts of outstanding importance in relation to the problem of sternal origin:

1. That there is present a median ventral rudiment, derived from the coracoids, which may be identified as a presternum as far back in the vertebrate series as the shark, and can be followed up through a ganoid, a teleost, a dipnoan, and from there on through the Tetrapoda.

2. That in all cases of vertebrates, and as high as man in the Mammalia, there is in the embryo or throughout life a continuous girdle across the ventral side and connecting the two scapulae above.

3. That this girdle in its ventral aspect is in the most intimate relation to the anterior part of the sternum; sometimes the mesenchymatous material passes over insensibly from one structure into the other without any line of demarkation; or at most, adults of Amphibia and Reptilia, there being but a suture between the two parts.

4. That in all these forms from the lowest to the highest, the relation of sternum and ribs is purely secondary and the result of a comparatively late fusion of the two structures in the embryo. The presence or absence of ribs does not seem to affect the development or size of the sternum in any degree.

5. That plural ribs extending to the ventral side of the body are a recent acquisition of the vertebrates, while the shoulder-girdle and sternum are coexistent and intimately related from the earliest appearance of the Gnathosomes.

6. That the number of ribs reaching the sternum varies from zero to a large number; sometimes the ribs are attached to the anterior part of the sternum, again exclusively to the posterior part, but apparently whatever the number or relation of ribs, the sternum remains unaffected, indicating strongly its independence of the costal cartilage.

7. That the evidence presented seems to bear out the homology of the sterna throughout the vertebrates; therefore, to classify them as coracoidal for the lower groups, and costal for the higher is unnecessary and artificial, for in the Amniota the sternum is as truly coracoidal in origin as it is in the Ichthyopsida.

8. That the mesosternum and xiphisternum are two backward prolongations of the coracoidal presternum, sometimes uniting in the midline (some reptiles, birds, and mammals), again remaining distinct as horns or bars (some Amphibia, some reptiles).

V. SUMMARY

At the close of the section on the ontogeny of the sternum a number of conclusions were listed, and likewise at the close of the section on phylogeny. These results may now be gathered up in the three main theses of this paper, which are stated thus:

1. That the sternum is an homologous structure throughout all groups of vertebrates, and occurs in forms ranging from *Hexanchus* up to the highest mammals.

2. That the anterior element of the sternum has its origin in common with the shoulder-girdle, and in the embryo or throughout life is in intimate relation to the coracoids.

3. That the sternal bands are derivatives of the anterior median rudiment, and may be secondarily, but never genetically, associated with ribs.

LITERATURE CITED

- ADOLPHI, H. 1905 Über die Variation des Brustkorbes und der Wirbelsäule des Menschen. *Morph. Jahrb.*, Bd. 33.
- ANTHONY, R. 1901 Notes sur la Morphogenie du sternum chez Mammiferes a propos de l'etude de Paterson sur le developpement de cet os. *Bull. Soc. Anthropol. Paris* (5), T. 2, pp. 19-43.
- BROOM, R. 1897 On the existence of a sternocorocoidal articulation in a fetal marsupial. *Jour. of Anat. and Physiol.*, vol. 31.
 1898 Description of the shoulder-girdle in an 8.5-mm. embryo of *trichosurus* (not exact title). *Proc. Linn. Soc. N. S. W.*, 1898.
 1899 On the development and morphology of the marsupial shoulder-girdle. *Trans. Roy. Soc. Edinb.*, vol. 39, pt. 3, pp. 749-770.
 1902 On the early condition of the shoulder-girdle in the Polyprotodont Marsupials *Dasyurus* and *Permales*. *Linn. Soc. Jour. Zool.*, vol. 28.
 1908 On the nomenclature of the elements of the amphibian shoulder-girdle. *Report S. Afr. Assoc. Adv. Sc.*, 6th. Meet., pp. 162-166.
- BRUCH, CARL 1852 Beiträge zur Entwicklungsgeschichte des Knochensystems von Dr. Carl Bruch. *Neue Denkschriften der allgemeinen Schweizerischen Gesellschaft für die gesammten Naturwissenschaften*. Bd. 12, Zurich (quoted by Ruge).
- CREDNER 1881-1893 Stegocephalen und Saurier. *Zeitschr. deutsch. Geolog. Gesellsch.*, 1881-1893.
- CUNNINGHAM, D. J. 1890 The occasional eighth, true rib in man and its relation to right-handedness. *Jour. Anat. and Physiol.*, vol. 24, p. 127.
- DWIGHT, THOMAS 1890 Irregular union of the first and second pieces of the sternum in man and the apes. *Jour. Anat. and Physiol.*, vol. 24, pp. 536-542.
- GOËTTE, A. 1877 Morphologie des Skelettsystems der Wirbeltiere: Brustbein und Schultergürtel. *Arch. f. Mikr. Anat.*, Bd. 14.
- GOODRICH 1909 Vertebrate Craniata (first fascicle): Cyclostomes and fishes. A treatise on zoology, pt. 9, by E. Ray Lankester. London.
- GREGORY, W. K. 1915 Present status of the problem of the origin of the Tetrapoda. *Ann. N. Y. Acad. Sc.*, vol. 26.
- GUNTHER 1867 Anatomy of Hatteria (*Sphenodon*). *Phil. Trans.*, 1867.
- HASWELL, W. A. 1884 Studies on the elasmobranch skeleton. *Proc. Linn. Soc. N. S. W.*, vol. 9.
- HOFFMANN, C. K. 1879 Zur Morphologie des Schultergürtels und des Brustbeins bei Reptilien, Vögeln, Säugetieren, und dem Menschen. *Niederland. Archiv. f. Zool.*, Bd. 5.
- HOWES, G. B. 1891 Morphology of the sternum. *Nature*, vol. 43.
- HOWES AND SWINNERTON 1901 Development of the skeleton of *Sphenodon*. *Trans. Zool. Soc. Lon.*, vol. 16.
- HUNTINGTON, G. S. 1918 Modern problems of evolution, variation, and inheritance in the anatomical part of the medical curriculum. *Anat. Rec.*, vol. 14, no. 6.
- KEIBEL and MALL 1910-1912 A manual of human embryology. J. B. Lippincott Co., Phila.

- KINGSLEY, J. S. 1917 Comparative anatomy of vertebrates. 2nd ed. P. Blakiston's Sons & Co., Phila.
- KIRCHNER, A. 1898 Das obere Brustbeinende und das ligamentum interclaviculare nebst zusammenstellungen über das Verhältnis des oberen sagittalen Brustdurchmessers und der Brustbeinlänge zur Körperlänge. Anat. Hefte., Bd. 10, S. 127-149.
- KRAVETZ, L. P. 1905 Entwicklungsgeschichte des Sternum und des Episternalapparatus der Säugetiere. Bull. Soc. Imper. Natur. Moscow, 1905, 1906.
- LICKLEY, J. D. 1904 On the relations of the seventh and eighth ribs to the sternum. Anat. Anz., Bd. 24.
- MARKOWSKI, J. 1905 Sollte der Verknöcherungsprozess des Brustbeins von keiner morphologischen Bedeutung sein? Aus anlass einer Publikation von Paterson. Anat. Anz., Bd. 26, S. 248-269.
- MUELLER, CHARLOTTE 1906 Zur Entwicklung des menschlichen Brustkorbes. Morph. Jahrb., Bd. 35.
- PARKER, W. J. 1868 Structure and development of the shoulder-girdle and sternum in the vertebrates. Ray Soc. Pub., London.
- PARKER, T. J. 1891 On the presence of a sternum in *Notidanus indicus*. Nature, vol. 43, p. 142.
1891 On the origin of the sternum. Trans. New Zealand Instit., vol. 23.
- PATERSON, A. M. 1900 The sternum; its early development and ossification in man and mammals. Jour. Anat. and Physiol., vol. 35, N. S., vol. 15, pt. 1.
1902 Development of the sternum and shoulder-girdle in mammals. Brit. Med. Jour., vol. 2.
1904 The human sternum. Liverpool.
1909 Two abnormal sterna in living subjects. Jour. Anat. and Physiol., vol. 43, pp. 322-323.
- RATHKE, H. 1838 Sur le developpement du sternum. Arch. Anat. et Physiol.
1848 Über die Entwicklung der Schildkröten. Brunswick.
1853 Über den Bau und die Entwicklung des Brustbeins der Säurier. Königsberg.
- RUGE, G. 1879 Über die Entwicklung des Sternum. Morph. Jahrb., Bd. 5.
1880 Untersuchungen über Entwicklungsvorgänge am Brustbein und der Sterno-clavicularverbindung des Menschen. Morph. Jahrb., Bd. 6.
- SABATIER, A. 1897 Morphologie du sternum et des clavicules. C. R. Acad. Sc. Paris, T. 124, no. 15.
1902 Du systeme sternal des vertèbres. C. R. Ass. Anat., 4me, pp. 99-102.
- SCHAUINSLAND 1900 Entwicklungsgeschichte der Hatteria (*Sphenodon*). Arch. f. Mikr. Anat., Bd. 56.
- SEELEY, H. G. 1892 Researches on the structure, organization and classification of the fossil Reptilia. Phil. Trans., vol. 183-B, pp. 334-338.
1894 Researches on the structure, organization, and classification of the fossil Reptilia. Phil. Trans., vol. 185-B.

- TREDGOLD 1897 Variations of ribs in the Primates, with especial reference to the number of ribs in man. *Jour. Anat. and Physiol.*, vol. 31.
- WATSON, D. M. S. 1917 The evolution of the tetrapod shoulder-girdle and forelimb. *Jour. of Anat.*, vol. 52, pt. 1.
- WHITEHEAD AND WADDELL 1911 Development of the human sternum. *Am. Jour. Anat.*, vol. 12, pp. 89-106.
- WILDER, H. H. 1903 The skeletal system of *Necturus maculatus* Rafinesque. *Mem. Bost. Soc. Nat. Hist.*, vol. 5, no. 9.
- WILLISTON, S. W. 1903 North American Plesiosaurs. *Field Col. Mus. Pub.* 73. *Geol. Ser.*, vol. 2, no. 1.
- 1903 On the osteology of *Nyctasaurus* (*Nyctodactylus*). *Field Col. Mus. Pub.* 78. *Geol. Ser.*, vo. 2, no. 3.
- 1911 American Permian vertebrates. Chicago.
- 1914 Water reptiles of the past and present. Chicago.
- WOODWARD 1898 Vertebrate paleontology. Cambridge.

PLATE 1

EXPLANATION OF FIGURES

1 Median portion of pectoral girdle of *Hexanchus*. Note the medial 'intercepted cartilage' which bears all the relations of a presternum in higher forms. The dotted lines indicate how this girdle may be transformed into that of the Amphibia with pre- and post-omosternum. Drawing from a dissection made by the author in the U. S. National Museum.

2 Pectoral girdle of *Acanthias vulgaris*. Note that all the parts of the girdle of higher forms are present, including a sternum. Compare with figure 35 of the fetal marsupial.

Cr, coracoid

POSt, pre-omosternum

PSt, presternum

PtOSt, post-omosternum

Sc, scapula

SSc, suprascapula

St, sternum

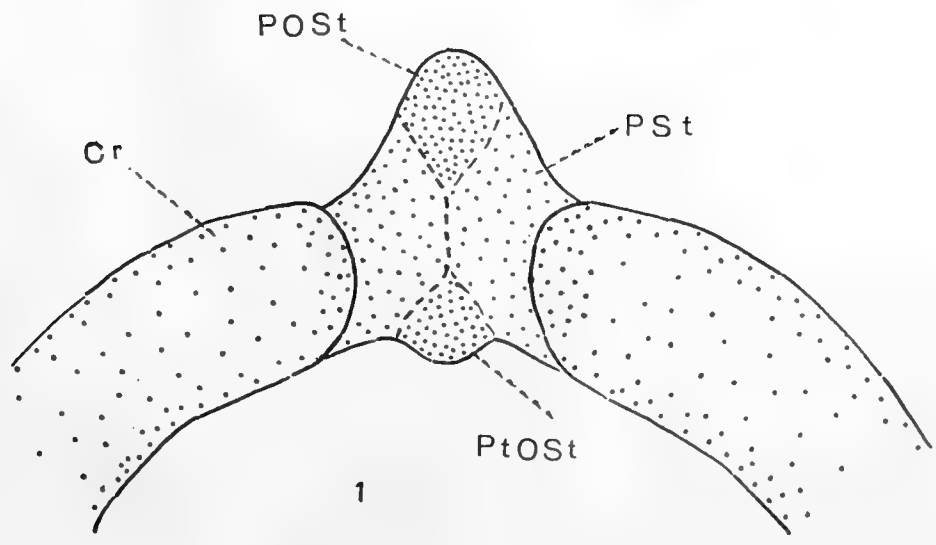
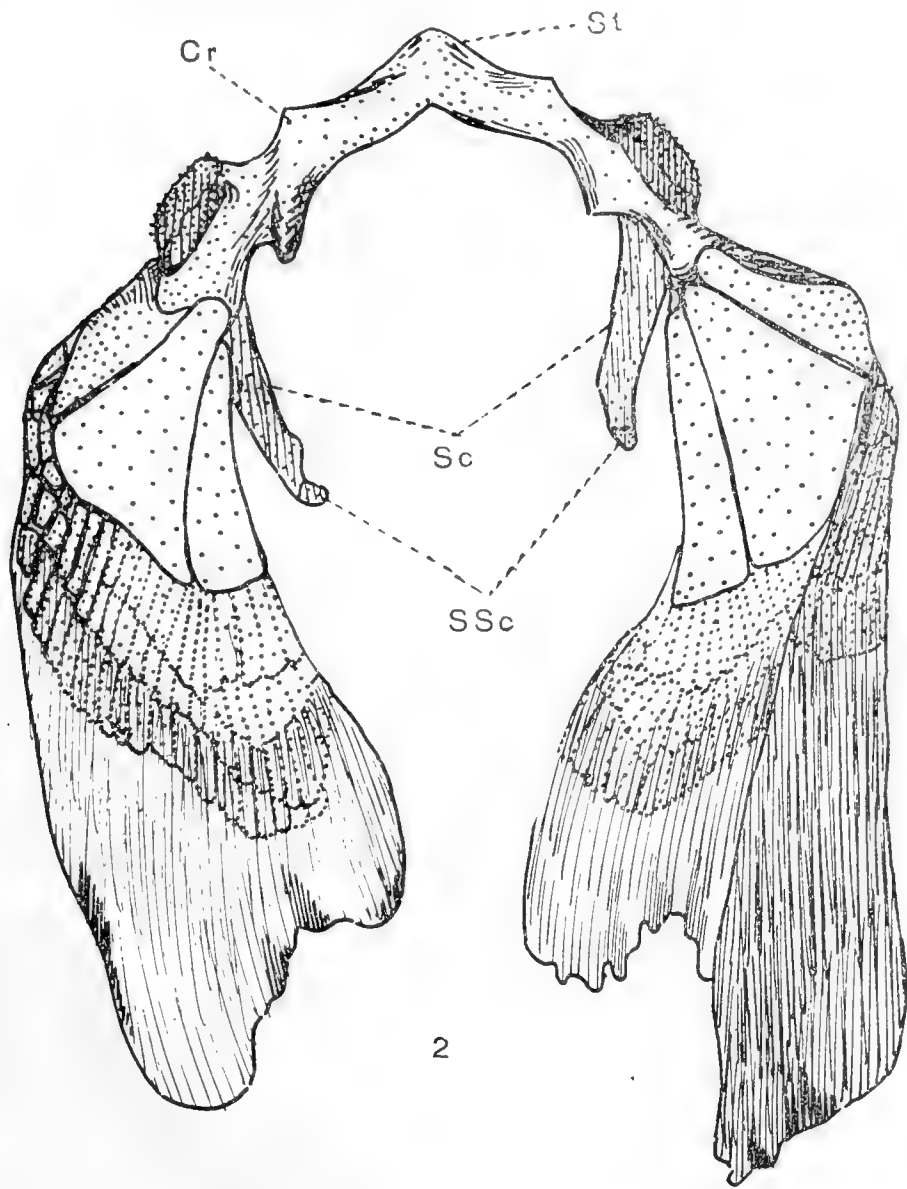


PLATE 2

EXPLANATION OF FIGURES

3 Cat embryo, 12 mm. Sternal bands are far apart. No presternum present at this stage. The first three pairs of ribs fail to reach the sternal bands. From the Princeton Embryological Collection, series no. 401. Graphic reconstruction.

4 Cat embryo, 14 mm. Sternal bands nearer to each other. Presternum has arisen and connects the anterior ends of sternal bands. All ribs reach the sternum. From the Princeton Embryological Collection, no. 37. Graphic reconstruction.

PSt, presternum

*R*¹, first rib

*R*³, third rib

*R*⁴, fourth rib

*R*⁷, seventh rib

StB, sternal bands

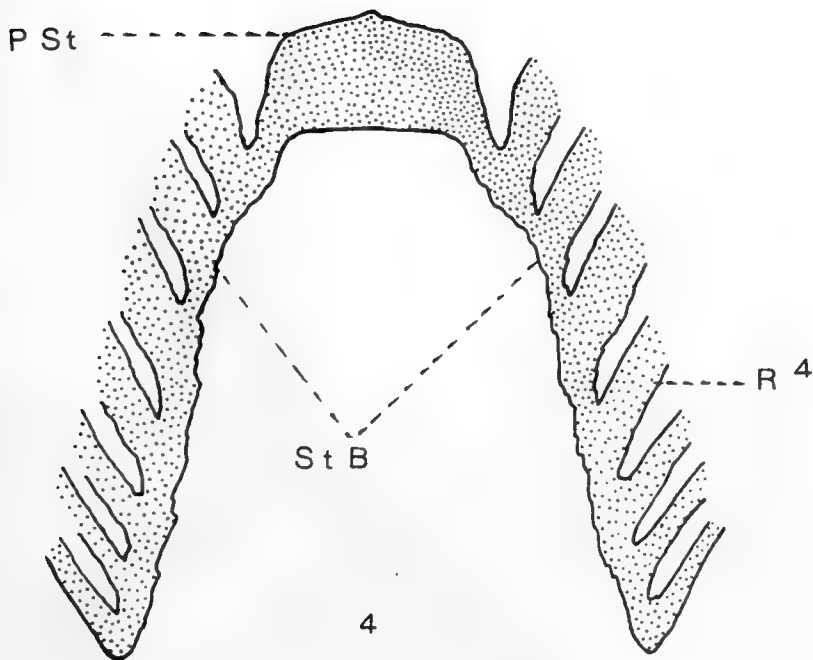
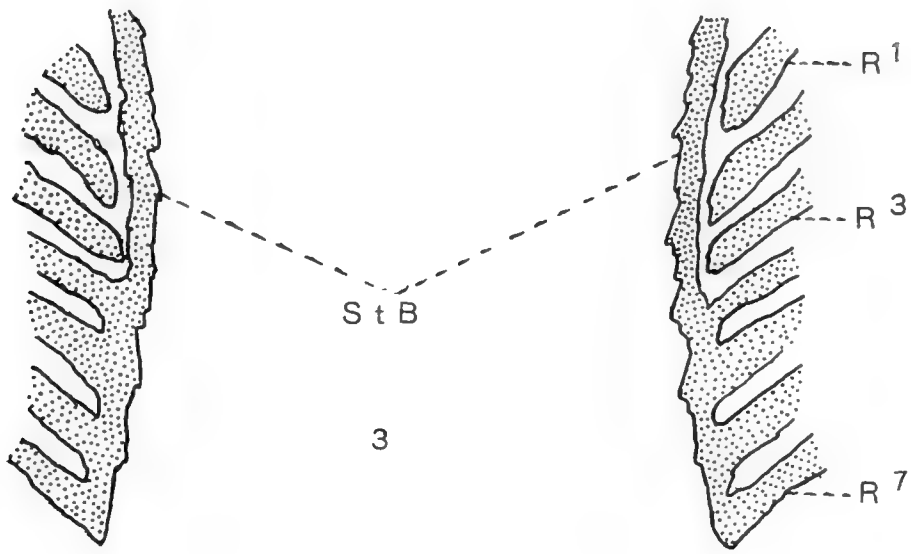


PLATE 3

EXPLANATION OF FIGURES

5 Mouse girdle. Scapulae, coracoids, clavicles, and presternum, all in one continuous mesenchymatous girdle, which is similar to that of the dogfish (fig. 1) and the marsupial fetus (fig. 35). From the Washington University School of Medicine Embryological Collection, series no. 102, slide 4, section 16.

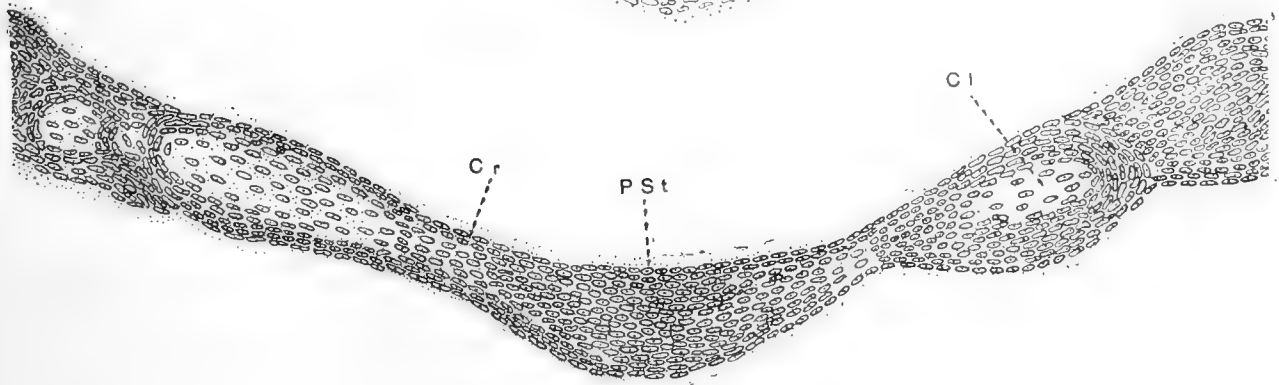
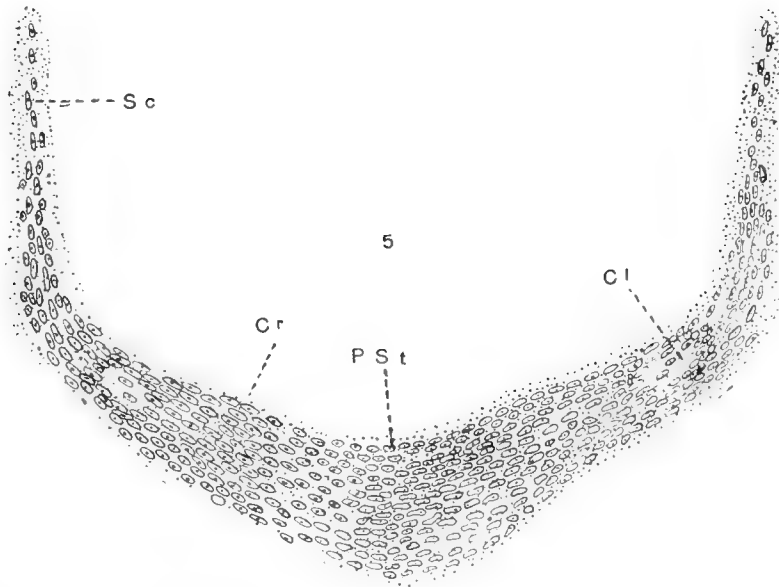
6 Human embryo girdle. Mesenchymatous stage. First appearance of clavicle; presternum and coracoids present. From The Johns Hopkins Embryological Collection, series no. 424, slide 5, section 16.

Cl, clavicle

PSt, presternum

Cr, coracoid

Sc, scapula



6

PLATE 4

EXPLANATION OF FIGURES

7 Sternum and ends of costal cartilages in pig two weeks old. Note in this and later figures that centers of ossification are intercostal.

8 Fetal sternum of *Bradypus*. After Hoffmann.

9 The ape sternum. After Anthony.

10 Sternum of *Dasypus*. After Hoffman. From the lowest to the highest mammals the sternebrae and centers of ossification are between the ribs, and not at their ends as would be expected according to Ruge's theory.

Oc, ossific center

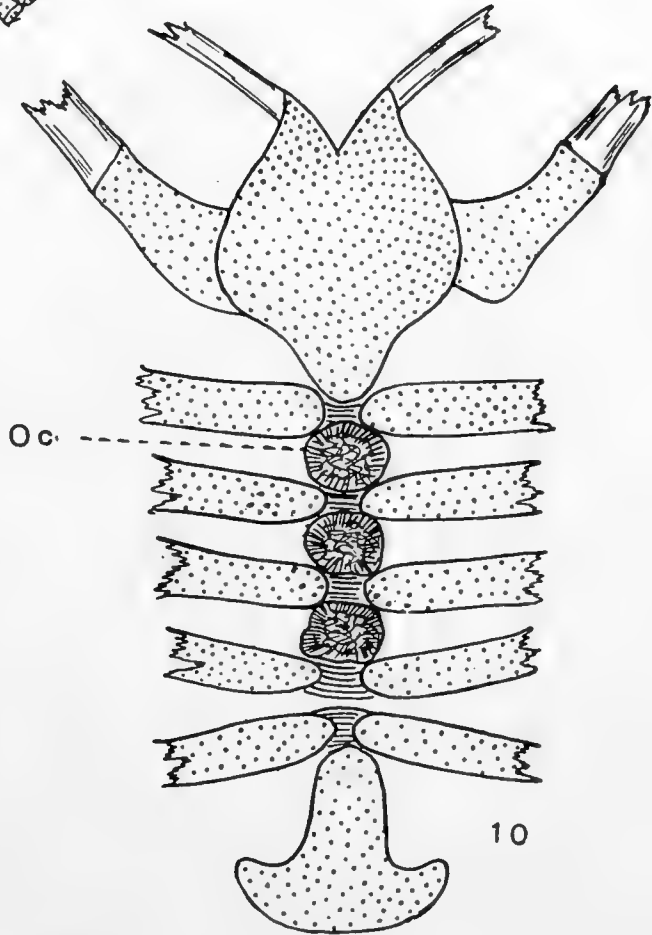
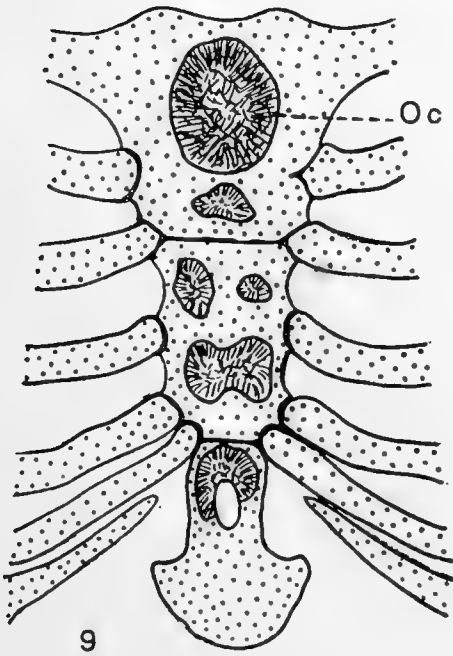
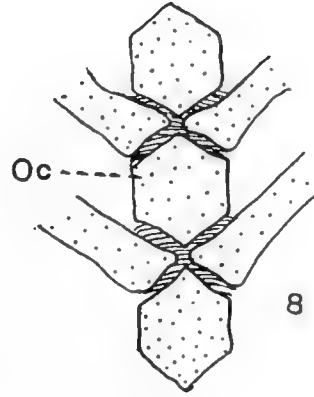
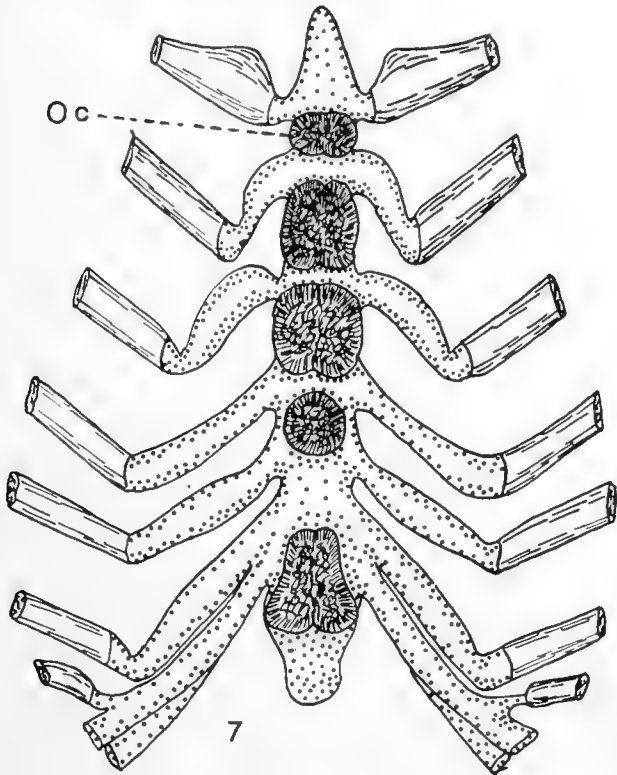


PLATE 5

EXPLANATION OF FIGURES

11 Ventral portion of shoulder-girdle of the shark, *Notidanus indicus*, showing the presternum in the midline. After Parker.

12 Ventral part of the shoulder-girdle of *Polypterus*. Note epicoracoid at junction of the clavicles. From Gregory, after Goodrich.

13 Clavicles and epicoracoid of the tropical fish, *Gobius niger* Linn., after Parker.

14 to 15 Upper and lower views of the girdle of the Dipnoid, *lepidosiren*. After Parker.

16 to 19 A series of stages in the development of the sternum of the frog, *Rana temporaria*, indicating that the sternum is coracoidal in origin. After Parker.

Cl, clavicle

Cr, coracoid

ECr, epicoracoid

PrOmSt, pre-omosternum

PtOmSt, post-omosternum

OSt, omosternum

Sc, scapula

St, sternum

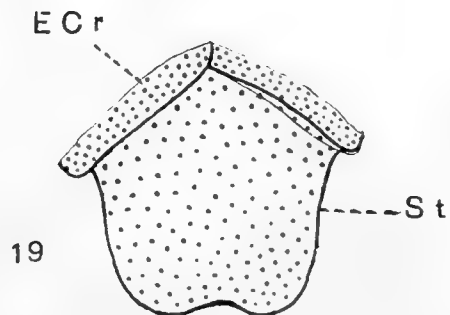
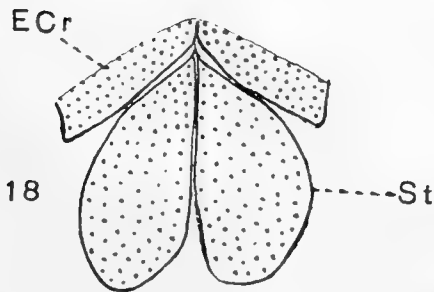
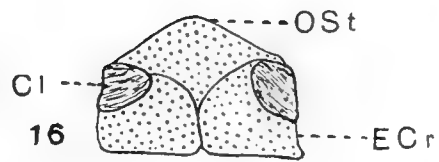
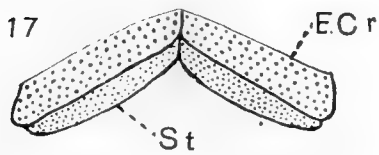
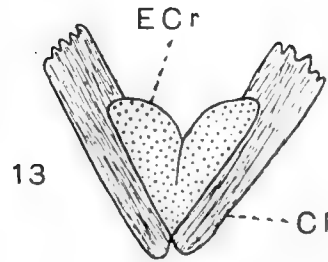
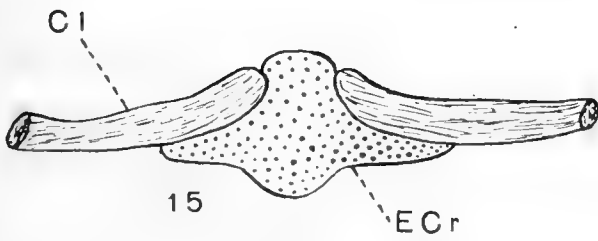
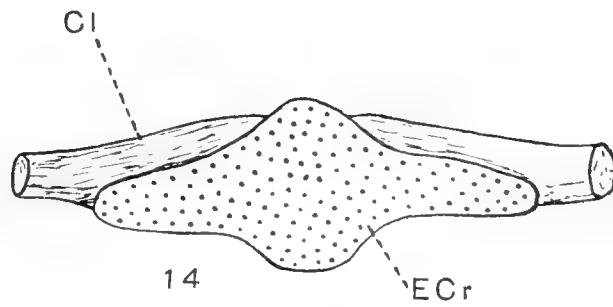
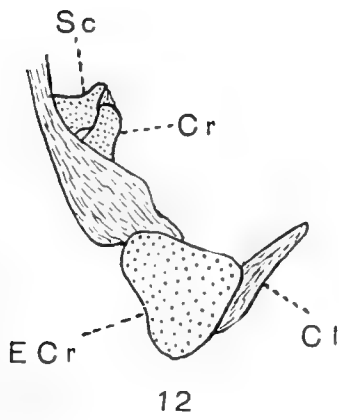
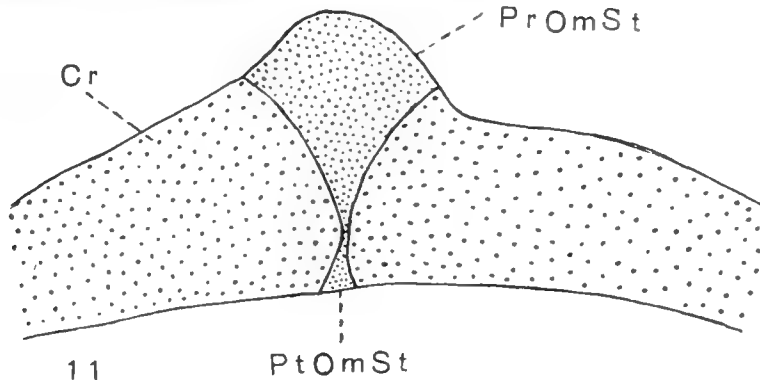


PLATE 6

EXPLANATION OF FIGURES

20 Shield-like plate on ventral side of *Pipa dorsigera*. Adult female, upper view. Would seem to indicate that sternum and coracoids were at one time structurally one; omosternum but feebly separated from coracoidal portion. After Parker.

21 *Bufo vulgaris*. First summer. Lower view. After Parker.

22 Large specimen of *Siredon pisciformis*. Sternum cut off from coracoids in adult, but retain evidences of having come from the overlapping epicoracoids. After Parker.

23 *Dactylethra capensis*. Adult female. After Parker.

24 Note the beginning of sternal bands in *Calamites cyaneus*. Compare with same stage in low-type reptile. After Parker.

Cl, clavicle

Cr, coracoid

*Cr**f*, coracoid fossa

ECr, epicoracoid

Gl, glenoid

Ost, omosternum

PCr, precoracoid

Sc, scapula

SSc, suprascapula

St, sternum

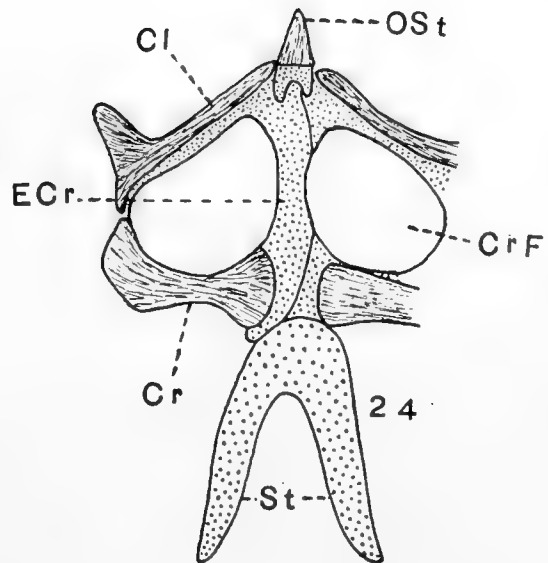
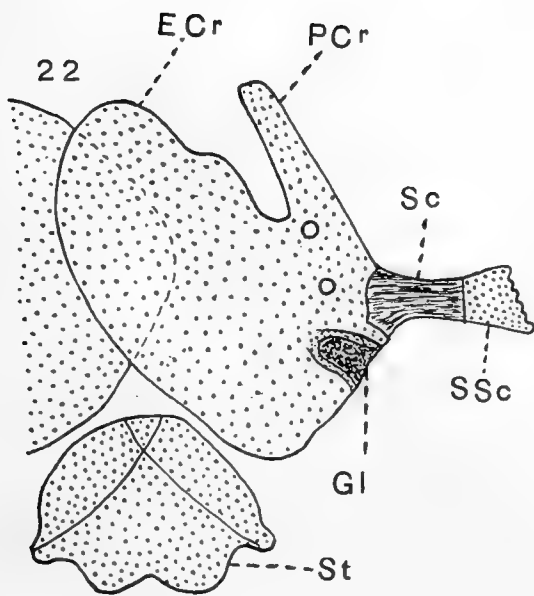
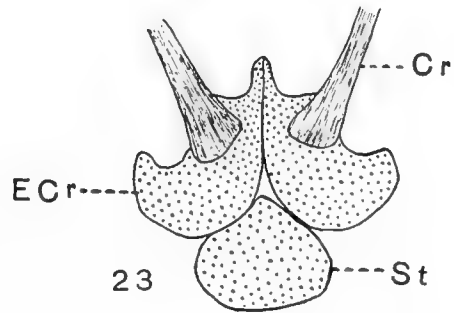
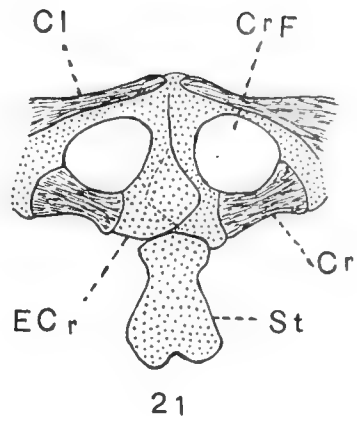
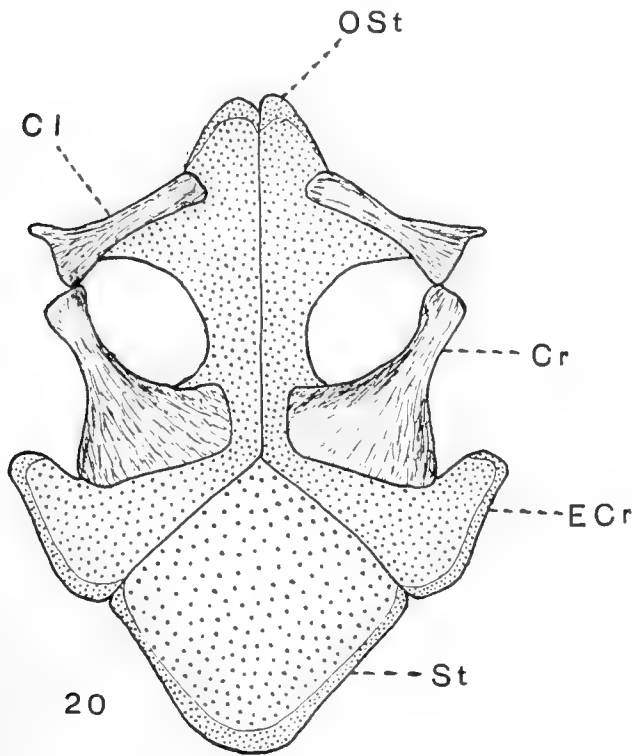


PLATE 7

EXPLANATION OF FIGURES

25 An old specimen of *Anguis fragilis*. Very similar to amphibian girdle. No ribs attached. Same intimate relation of sternum and coracoidal part as in the Amphibia. Modified after Parker.

26 In *Stellio cordylinus* long sternal bars make their appearance. No ribs are attached to them. Adapted from Parker.

27 *Laemanctus longipes*. After Parker.

28 *Trachydosaurus rigosus* adult. Sternal bars are fused and ribs are approaching. Adapted from Parker.

ECr, epicoracoid

Gl, glenoid

ICl, interclavicle

PCr, precoracoid

PSt, presternum

*R*¹, first rib

Sc, scapula

St, sternum

Stf, sternal fossa

XSt, xiphisternum

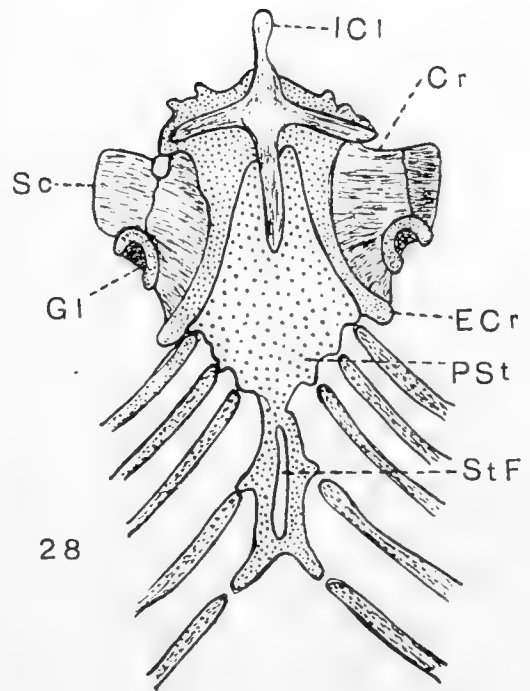
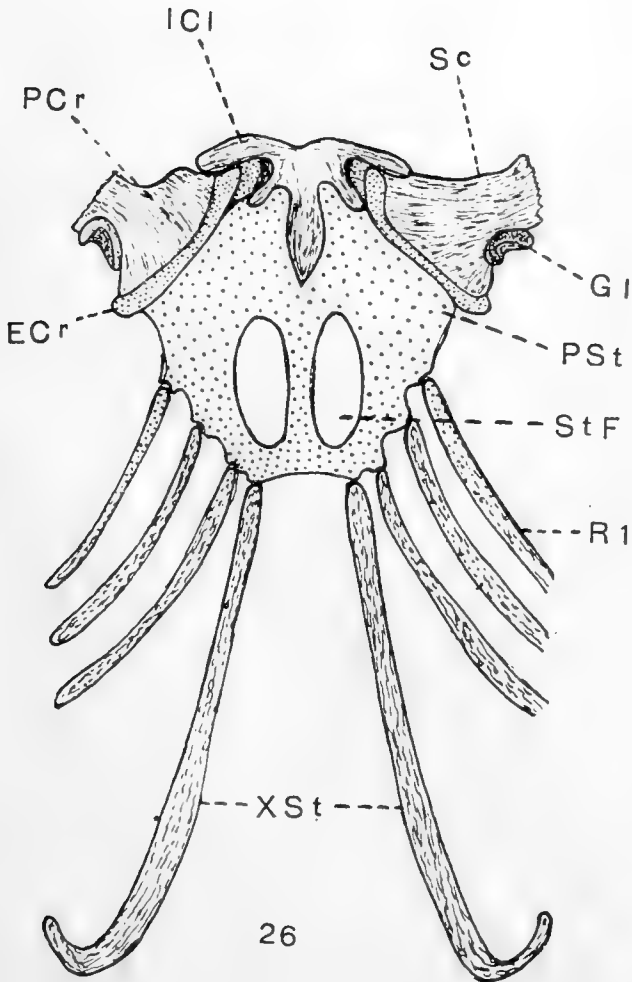
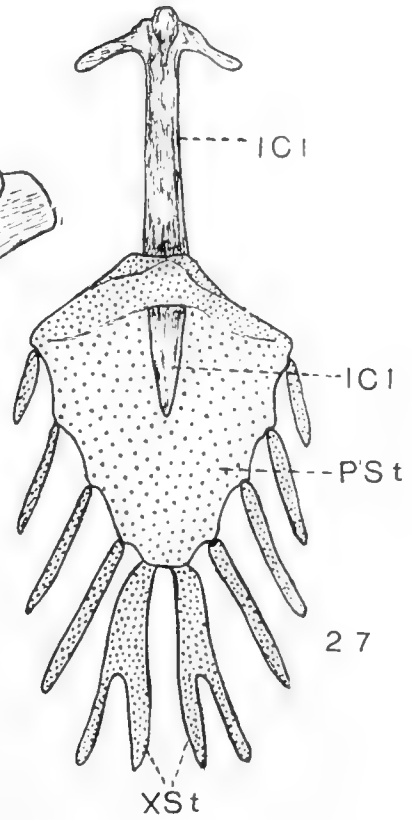
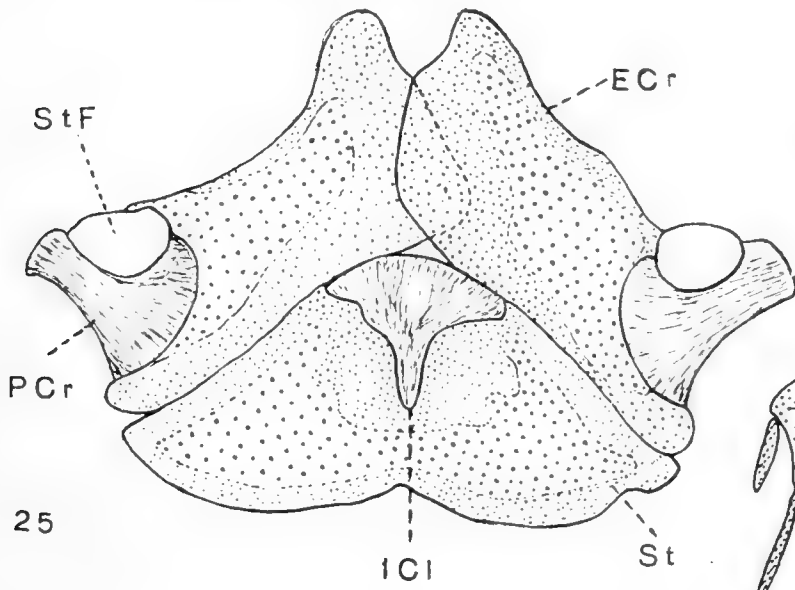


PLATE 8

EXPLANATION OF FIGURES

- 29 *Cyclodus nigroluteus*. Adult, lower view. After Parker.
30 *Chirotos canaliculates*. Adult male. Upper view. Mammalian-like sternum. No ribs ever reach sternum. After Parker.
31 *Crocodilus acutus*. Ripe embryo. Lower view. After Parker.
32 *Chamaeleo vulgaris*. Adult, lower view. After Parker.

Cr, coracoid

ECr, epicoracoid

Gl, glenoid

ICl, interclavicle

MSt, mesosternum

PSt, presternum

*R*¹, first rib

*R*², second rib

Sc, scapula

Stf, sternal fossa

XSt, xiphisternum

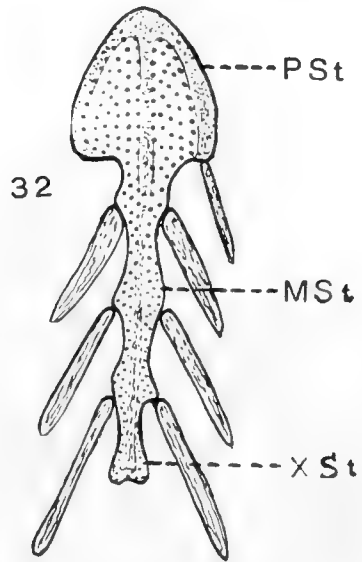
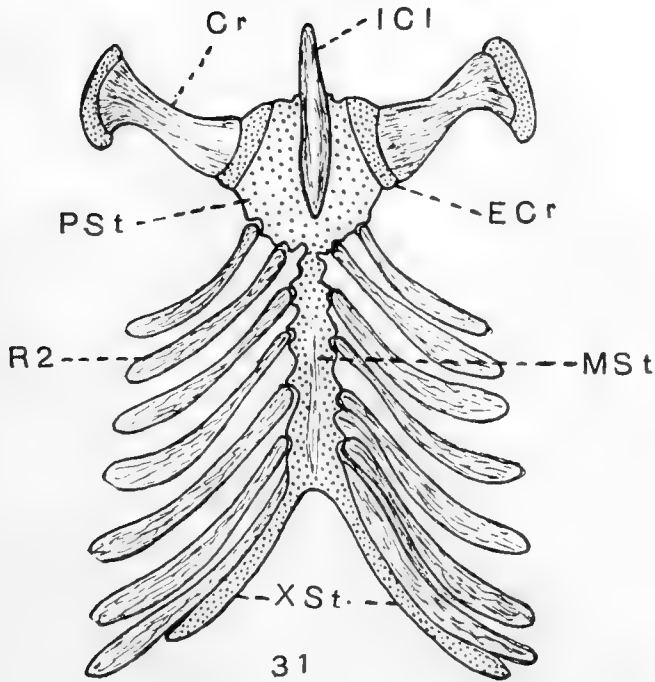
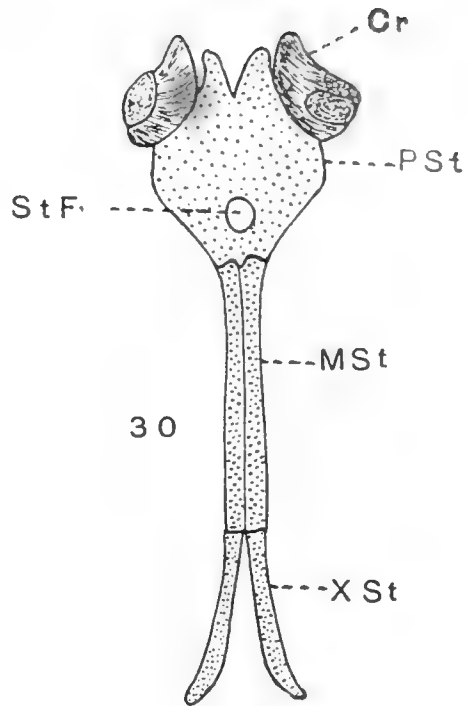
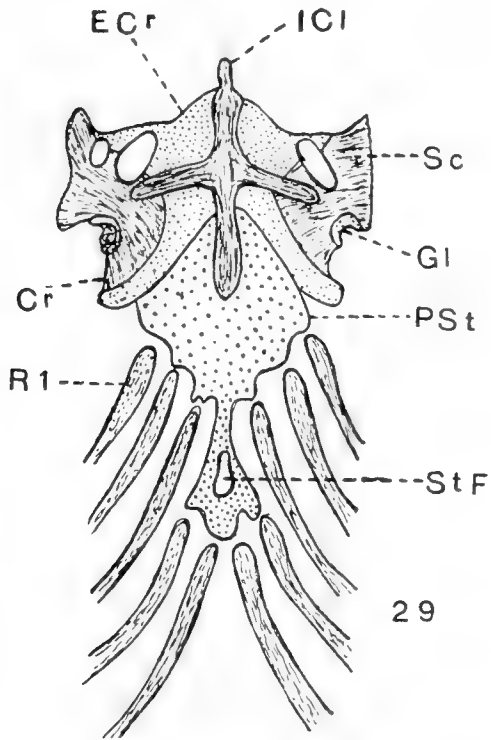


PLATE 9

EXPLANATION OF FIGURES

33 *Vanellus custatus*. One-third of incubation period. Lower view. Note slight attachment of ribs, but only sutural separation of sternum and coracoid. After Parker.

34 *Echnidna histrix*. Upper view of adult specimen. Drawn from a specimen in Washington University, Department of Zoology, and in part after Parker.

35 Shoulder-girdle of a marsupial embryo, *Trichosurus*. Scapulae, coracoids, and sternum are continuous parts as in the shark embryo. After Broom.

36 Anterior view of girdle in an 8.5-mm. *Trichosurus* embryo. Dotted portions are mesenchymatous. After Broom.

Ac, acromian

Cl, clavicle

Cr, coracoid

ECr, epicoracoid

Gl, glenoid

ICl, interclavicle

OSt, omosternum

PCr, precoracoid

Pro, pre-omosternum

*R*¹, first rib

*R*², second rib

Sc, scapula

Sp, spine

SSc, suprascapula

St, sternum

XSt, xiphisternum

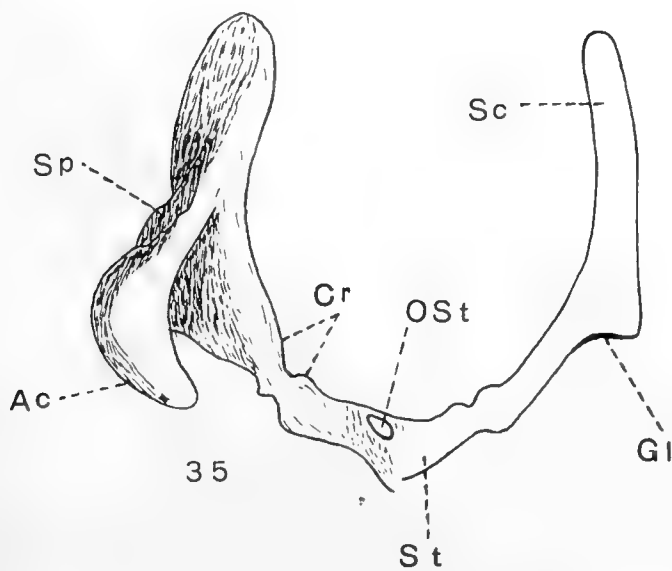
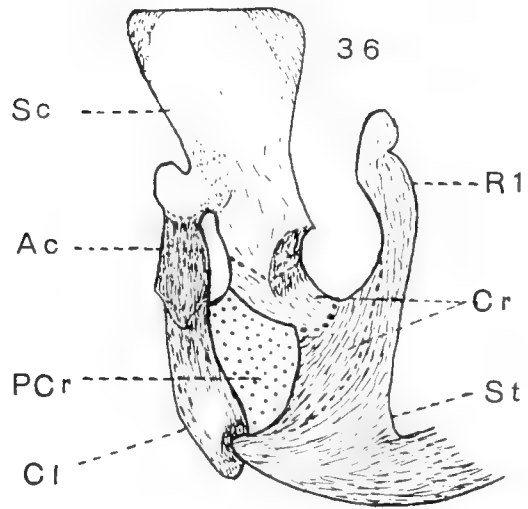
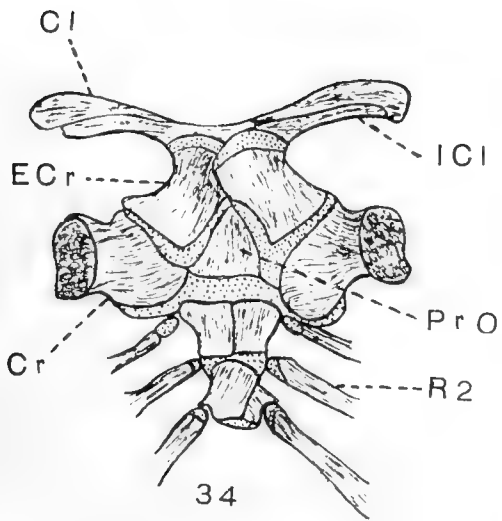
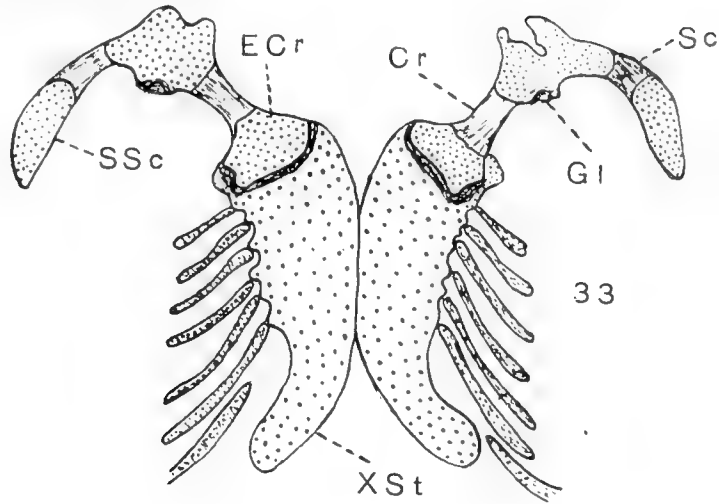


PLATE 10

EXPLANATION OF FIGURES

37 *Petrogale xanthopus*, 3 inches long. Right scapula, outer view; sternum, inner view. After Parker.

38 *Mus musculus*, adult, inner view. Anterior end of sternum and medial end of clavicles, showing omosterna, and epicoracoids. After Parker.

39 Shoulder-girdle seen in a reconstruction of *Dasyurus viverrinus*. Front view of mammary fetus.

40 Sternum of adult *Manatus americanus*. Left half, inner view. After Parker.

41 Sternum of the embryo of the Dolphin. Inner view. After Parker.

<i>Ac</i> , acromian	<i>PST</i> , presternum
<i>Cl</i> , clavicle	<i>R</i> ¹ , first rib
<i>Cr</i> , coracoid	<i>R</i> ² , second rib
<i>ECr</i> , epicoracoid	<i>R</i> ³ , third rib
<i>F</i> , fontanelle	<i>R</i> ⁸ , eighth rib
<i>Gl</i> , glenoid	<i>Sc</i> , scapula
<i>MSt</i> , mesosternum	<i>SSc</i> , suprascapula
<i>Ost</i> , omosternum	<i>XSt</i> , xiphisternum

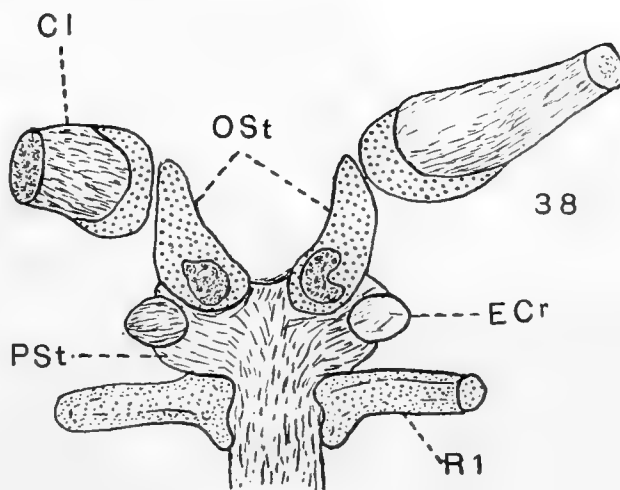
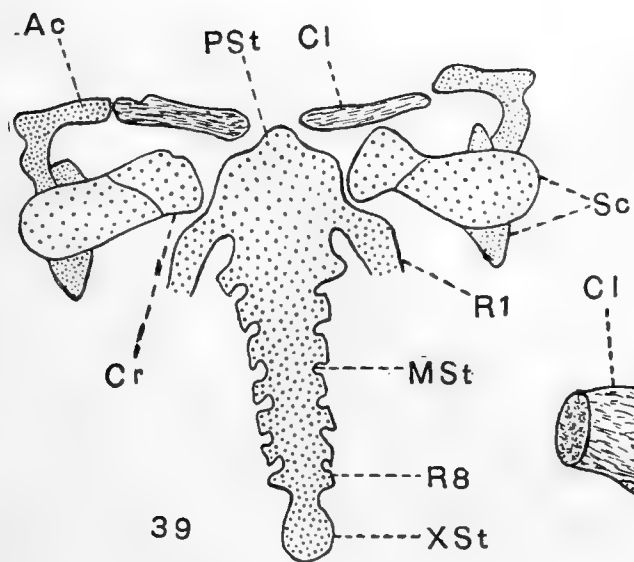
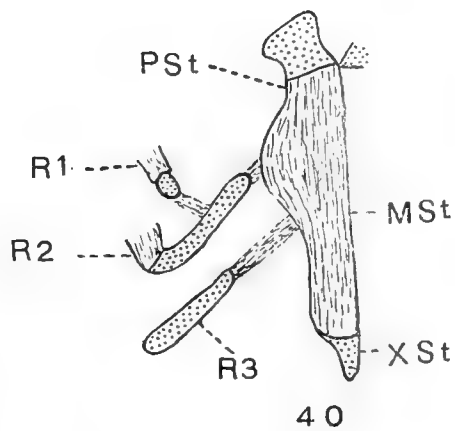
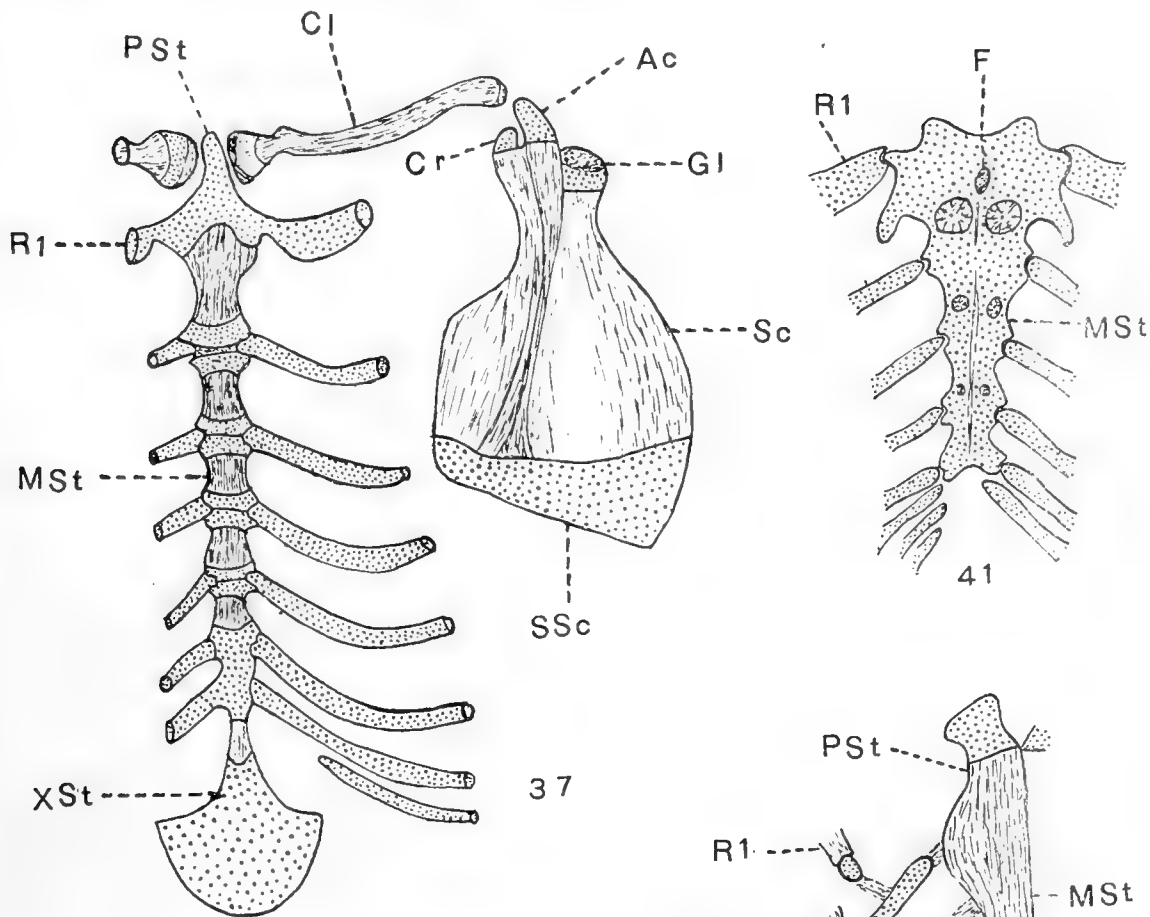


PLATE 11

EXPLANATION OF FIGURES

42 Comparison of the fundamental type of vertebrate shoulder-girdle as illustrated in the Anura with that of man. Modified after Huntington.

<i>Ac</i> , acromian	<i>Oss</i> , ossa suprasternalia
<i>Cc</i> , costocoracoid ligament	<i>OSt</i> , omosternum
<i>Cl</i> , clavicle	<i>PCr</i> , precoracoid
<i>Cr</i> , coracoid	<i>R</i> ¹ , first rib
<i>ECr</i> , epicoracoid	<i>Sc</i> , scapula
<i>Ep</i> , epiphysis of clavicle	<i>SSc</i> , suprascapula
<i>Hu</i> , humerus	<i>St</i> , sternum
<i>Ic</i> , interclavicular ligament	

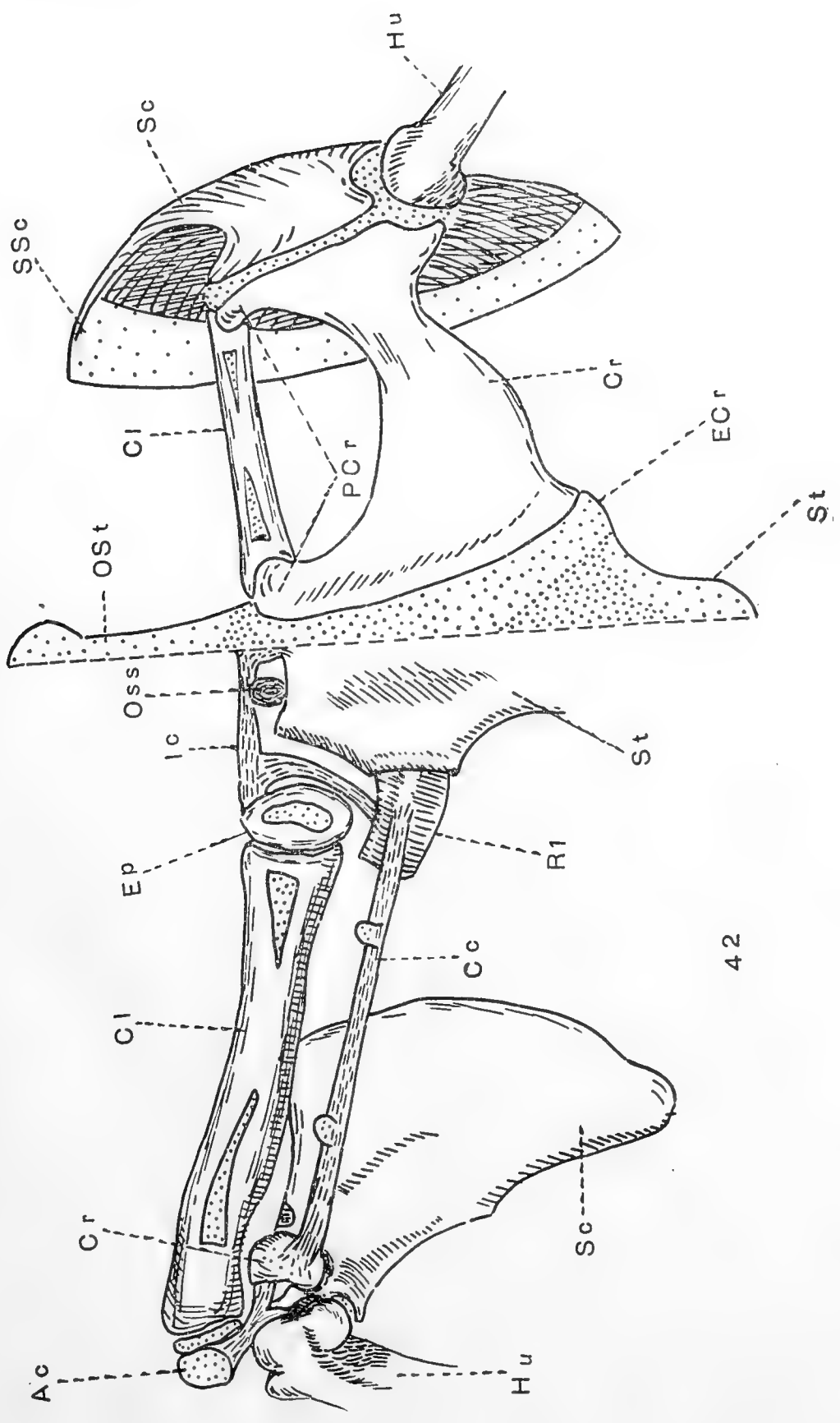
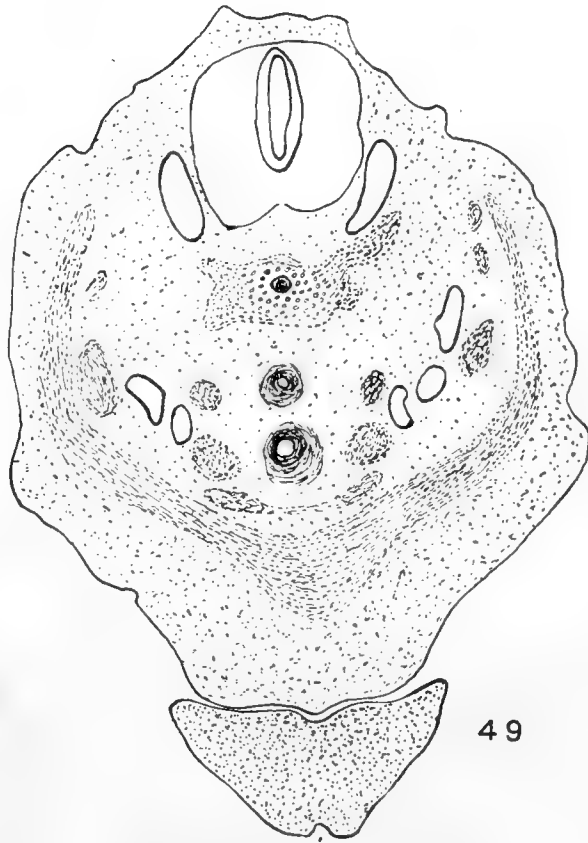
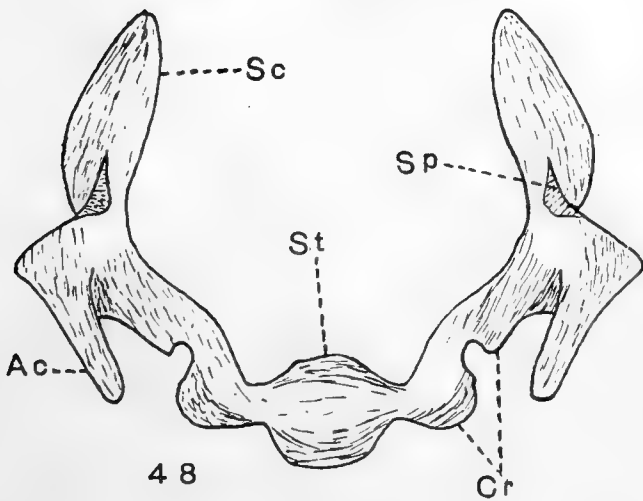
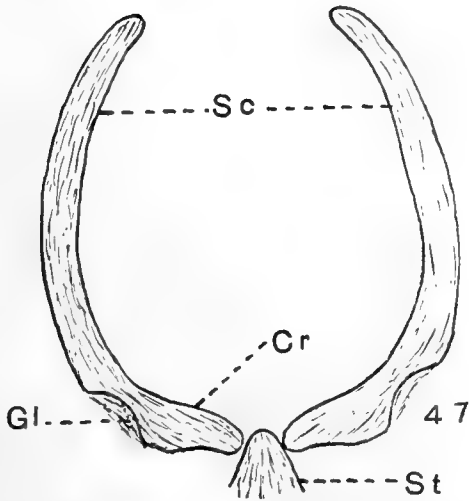
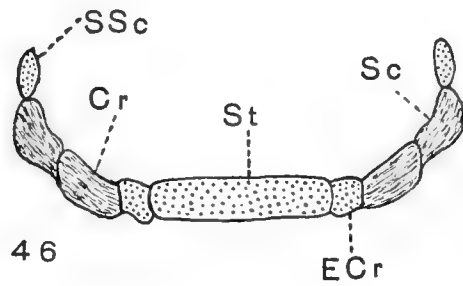
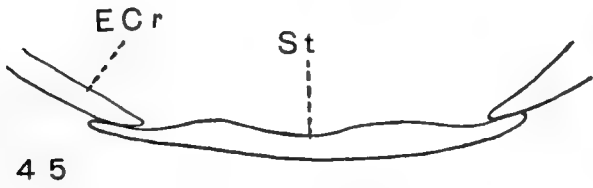
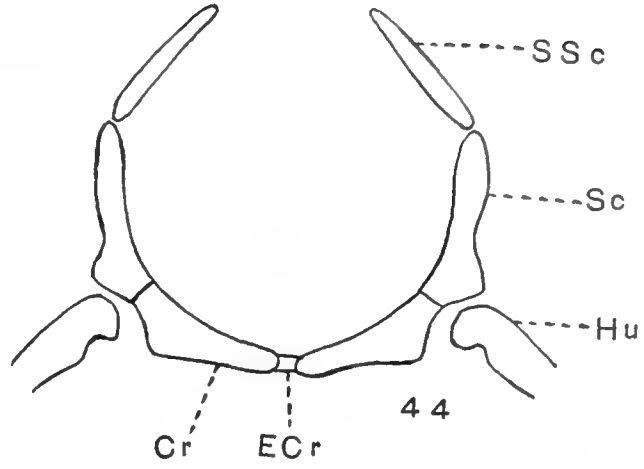
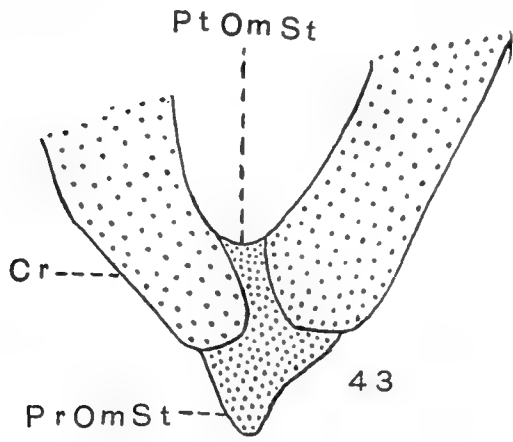


PLATE 12

EXPLANATION OF FIGURES

- 43 Girdle of *Hexanchus*. Pre- and post-omosterna. After Parker.
- 44 Diagrammatic transverse section through shoulder-girdle of adult frog.
- 45 Section through edges of shoulder-girdle and sternum of adult *Lissotriton punctatus*. After Parker.
- 46 Diagrammatic transverse section of arch in the Australian lizard, *Trachydosaurus rugosus*.
- 47 Diagrammatic transverse section of *Echidna histrix*, from a mounted specimen in Washington University.
- 48 Anterior view of cartilaginous girdle of petrogale, 21 mm. in length. The different parts of the girdle are outlined, but the whole is a continuous piece of cartilage. After Broom.
- 49 Transverse section of mouse embryo, 7.75 mm. long. Washington University School of Medicine series no. 102, slide 4, section 16. $\times 38$.
- | | |
|--------------------------|---------------------------------|
| <i>Ac</i> , acromian | <i>PrOmSt</i> , pre-omosternum |
| <i>Cr</i> , coracoid | <i>PtOmSt</i> , post-omosternum |
| <i>ECr</i> , epicoracoid | <i>Sc</i> , scapula |
| <i>Gl</i> , glenoid | <i>SSc</i> , suprascapula |
| <i>Hu</i> , humerus | <i>St</i> , sternum |



Resumen por el autor, George W. Corner
Universidad de California.

Sobre el origen del cuerpo amarillo de la cerda a expensas de la granulosa y teca interna.

El ovario de la cerda presenta algunas ventajas para la solución de este problema. El presente trabajo está basado en la inspección de una larga serie en la cual se determinó el estado del ciclo reproductor por la observación de los animales vivos y sus óvulos. Los resultados obtenidos pueden resumirse del siguiente modo: En la cerda la membrana granulosa persiste intacta después de la ruptura del folículo de Graaf. Sus células aumentan de tamaño sin dividirse; su citoplasma se carga de substancias lipoides y finalmente se transforman en los grandes elementos del cuerpo amarillo completamente formado, llamados comunmente "células luteínicas." Los capilares sanguíneos procedentes de la teca interna invaden la membrana granulosa ramificándose para formar un extenso plexo vascular en la nueva estructura. Las grandes células cargadas de lipoides, presentes en la teca interna, aumentan en número a consecuencia de divisiones mitóticas perdiendo muchas o la mayor parte de sus inclusiones grasas y pasando al cuerpo amarillo, alojándose entre las células de la granulosa, en toda la extensión de esta última. No hay pruebas de la transformación de la células de la teca interna en fibroblastos de tipo fusiforme corriente ni tampoco de su participación en la formación de las fibrillas del retículo de mallas angostas que existe en el cuerpo amarillo. El autor ha encontrado pruebas sobre la persistencia de algunas de las células de la teca interna durante la preñez, las cuales forman elementos bien patentes en el cuerpo amarillo; pero su destino no puede reconocerse por los métodos actuales, a causa de la semejanza entre algunos de los derivados de la teca y la granulosa.

Translation by José F. Nonidez
Carnegie Institution of Washington

ON THE ORIGIN OF THE CORPUS LUTEUM OF THE SOW FROM BOTH GRANULOSA AND THECA INTERNA

GEORGE W. CORNER

From the Anatomical Laboratory, University of California

CONTENTS

Introduction.....	117
Recent investigations.....	122
Previous work on the corpus luteum of the sow.....	127
Material and methods.....	131
Special cytology of the lutein cells of the sow.....	137
The mature follicle.....	140
The freshly ruptured follicle.....	148
Invasion of the granulosa.....	157
The fully formed corpus luteum, until the termination of pregnancy.....	168
Retrogression of the corpus luteum.....	177
Discussion.....	178
Conclusions.....	180

INTRODUCTION

The history of the discussion, now of more than seventy years' standing, as to the origin of the corpus luteum, has been repeated so many times that it has become traditional, and the names of von Baer and Bischoff have been passed down to us as the original proponents of the two chief doctrines in question. It is said that the former, in his monograph "De ovi mammalium genesi" ('27) first stated that the corpus luteum is derived from the theca interna of the Graafian follicle, and that Bischoff first discarded this view in favor of the membrana granulosa as the site of origin. I have not been able to see von Baer's work, but judging at least from Bischoff's account of the early embryology of the rabbit ('42), there was no such clear-cut opposition of view as tradition declares, for Bischoff considered himself, rather, as an upholder of von Baer (and was so quoted by contemporary investigators).

It must be remembered that the first of these monographs appeared a decade before Schleiden and Schwann's enunciation of the cell theory, and the other not five years after; histology was studied with pincettes and the needle rather than by sections, and the first nuclear stain was not discovered. The layers of the follicle were as yet imperfectly differentiated, and the early descriptions are so vague that it is difficult to interpret them in present-day terms. New steps toward the solution of this problem have always followed fast upon the development of histological technique, and thus it is in the writings of Wilhelm His ('65) and Waldeyer ('70) that we first find opinions and descriptions approaching those of recent years.

The studies of His led to the complete formulation of the view that the corpus luteum is derived from the theca interna of the Graafian follicle, which in the next two decades was supported by a number of investigators and still holds a place in the field against strong opposition. The chief arguments in favor of this view are that, first, the membrana granulosa of large follicles is often degenerated, and is believed to be cast off at the time of rupture; second, as the Graafian follicle ripens, the cells of the theca interna show marked changes—they swell in volume, become rounded, in some species they acquire granules of a yellowish pigment, and in short come to present a striking resemblance to the large cells of the corpus luteum; third, this resemblance is enhanced by the fact that not only are the large cells of the theca interna folliculi and the corpus luteum similar, but the presence of many blood-capillaries and connective-tissue cells causes a resemblance as well in the general structure of the two tissues; and, fourth, such follicles as do not rupture lose their granulosa by degeneration, become obliterated by proliferation of the theca interna, and in this process of atresia attain also a resemblance to the corpus luteum.

None of the contributions disagreeing with this view in favor of the granulosa origin of the lutein cells were at all convincing, until the appearance in 1895 and 1896 of Sobotta's first researches, which mark the beginning of modern work upon the question. Here again the chief contribution was one of method. Sobotta

pointed out that the arguments quoted above are based merely upon analogies between the layers of the follicle and the fully formed corpus luteum, and that from the writings of his predecessors it is apparent that few had actually seen corpora lutea in process of formation. Even when descriptions are given of mature follicles or supposed early corpora lutea, there is usually no proof that the structures in question actually represent the results of normal follicular development or recent ovulation. The problem should be worked out from a series of specimens gathered at known periods after rupture of the follicle; and in order to avoid confusion with atresia or other irrelevant processes, each follicle or corpus luteum studied should be certified as to its normal condition and stage of development by comparison with the fertilized ovum or embryos proceeding therefrom. To fulfill these high requirements calls for long and tedious labors—the investigator must spend hours and days in observation of his animals; the reproductive cycle of the species used must be known well enough to acquaint him with the time of ovulation, the animals must be killed at definite times thereafter, and the ova must then be sought in the ovary, the oviducts, or the uterus. Sobotta himself chose the mouse, in which he had found that an ovulation takes place about twenty-one days after the birth of a litter, and in which the small size of the animal permits serial sectioning of the entire ovaries and Fallopian tubes. It must be admitted that his own postulates could not be followed to the full; the individual corpus luteum corresponding to a given ovum cannot be identified, because many ova are extruded at one ovulation in this species; the exact time of ovulation may vary by hours, and again there is so much variation of the interval between ovulation and the entrance of the spermatozoön into the egg that the condition of the ovum cannot be used as an exact measure of the age of the corpus luteum. Study of the ova merely provides assurance that the corpora lutea are normal and gives a rough means of determining their ages. The judgment of the investigator must finally be used to rank the corpora lutea in an orderly series. It is beyond denial, however, that Sobotta possessed such a series, collected from about 200 mice and based upon the

study of nearly 1500 ova during the stages of maturation, fertilization, and the segmentation of the blastomeres. He found no degeneration of the membrana granulosa; instead the cells of this layer remain and undergo hypertrophy (without division), finally becoming the characteristic large cells of the corpus luteum. Meanwhile the cells of the theca interna undergo mitotic division, are converted into spindle-cells and invade the granulosa to form the connective-tissue reticulum of the corpus. In this process all the theca interna cells are used up, and the layer therefore disappears. Capillary blood-vessels grow in from the vessels of the theca interna, ultimately providing the corpus luteum with a rich circulation.

There will be no need to enter here upon a detailed account of the debate which began immediately upon the publication of these epoch-making studies. A full analysis of the literature upon the origin of the corpus luteum up to 1901 will be found in the papers just quoted and in the two reviews of Sobotta in the *Ergebnisse der Anatomie* ('99a, '02). In 1897 Sobotta himself studied corpus luteum formation in the rabbit, and found the process in all important points exactly as in the mouse. A year later, Stratz ('98) printed a research upon which he had been engaged before the publication of Sobotta's work, in which he had followed the early stages of the corpus luteum on ovaries of an insectivore, *Tupaia javanica*, the lemuroid ape *Tarsius spectrum* (the specimens being those of Hubrecht's well-known Javanese collections,) and of the 'Spitzmaus' or shrew, *Sorex vulgaris*. Although he did not have large numbers of cases, all were checked by the study of the ova or embryos. As far as the persistence of the granulosa cells and their direct conversion into the lutein cells was concerned, Stratz agreed fully with Sobotta, but with regard to the fate of the theca interna there is a minor difference. If I understand Stratz correctly, he considers the theca interna of the mature follicle merely as a zone of blood-vessels, in which all the cells are either constituents of the vascular wall or of the adventitia. Considered in this light, it is easy to see how this angioma-like thecal tissue would enter into the growing corpus luteum to form its blood-vessels and its connective tissue without

the necessity of transformation or regression of the specialized theca cells into fibroblasts, as described by Sobotta. So far as is known to me, no subsequent investigator has confirmed the view of Stratz, all others being agreed that the theca interna consists of a distinct layer of highly specialized cells derived from the mesenchymatous elements of the ovarian stroma, and containing a network of blood-vessels, supported by cells and fibrils of connective tissue.

A third theory as to the fate of the theca interna is proposed in the important papers of O. Van der Stricht, of which the first appeared in 1901. The study was carried out upon the ovaries of large numbers of European bats, chiefly *Vesperugo noctula*. As with the two previously cited investigations, the animals were collected primarily for the study of the ova and the early embryos of the species used, and the series is therefore accurately controlled by the condition of the ova. Van der Stricht demonstrates beyond doubt that in these species the granulosa layer persists in situ after rupture of the follicle, and that its cells enlarge, acquire granules of lipoids staining black with osmium tetroxide, and finally become the typical lutein cells. Contrary to Sobotta, he thinks that mitotic division may occasionally occur in these cells, so that the filling of the follicular cavity is brought about by a slight increase in their number as well as by the vast increase in their individual bulk. The connective tissue of the corpus luteum arises chiefly as Sobotta described it in the mouse. After rupture of the follicle the membrana propria disappears, and fibroblasts invade the metamorphosing granulosa layer. Van der Stricht thinks that these are the spindle-cells of the theca interna or their descendants. Of the distinctive cells of the theca, some seem to disappear, but others remain, chiefly about the periphery of the new corpus luteum, or enter a short distance into the granulosa, and here they remain almost in their original condition. After a few days, however, when the deposition of fatty droplets in the granulosa cells has progressed, the two types of cells so closely resemble each other that Van der Stricht could no longer distinguish them in his Flemming-fixed tissue. He believes, in fact, that they have become identical, and therefore

that in the fully formed corpus luteum most of the lutein cells are of granulosa origin; a few of them, however, are from the theca interna.

A nearly identical theory is that proposed by Rabl ('98), who studied human corpora lutea (the youngest estimated at ten days), and found in them about the periphery a layer of cells differing from the rest of the lutein tissue; this, he suggested, might be the theca interna, which he supposed to persist in its original position until its cells were lost to view, some by becoming converted into lutein cells, others by degenerating.

During these five years from 1896 to 1901 there was no lack of publications restating the total loss of the granulosa before rupture, in opposition to the descriptions of Stratz, Sobotta, and Van der Stricht. A few of these investigations were carried out upon the ovaries of swine, and will therefore be discussed more fully later in this paper. As Sobotta pointed out in his résumé of 1902, not one writer among those who taught the non-participation of the granulosa in corpus luteum formation had been able to prove that his specimens were normal mature follicles and corpora lutea by presenting the ova which had proceeded therefrom.

RECENT INVESTIGATIONS

From 1901 to 1917 there have been about thirty-five more publications upon the question, of which some twenty-five represent actual original investigations. As the subject has not been brought up to date in any publication in English, it may be as well to take up in some detail the work of the past sixteen years, especially as the old differences of opinion still persist.

Jankowski ('04) reports studies upon a series of ovaries of sows and guinea-pigs, collected without an attempt to learn the reproductive cycle of the animals or to test the normal conditions of the specimens according to the postulates of Sobotta (which he says he had found impracticable to apply and whose value he questions). He believes the granulosa to be intact until the rupture of the follicle and even afterward, but to degenerate before the ingrowth of the theca interna, to which he ascribes the

origin of the lutein tissue. The value of his results with the pig will be discussed below; Sobotta has presented directly opposite evidence and a vigorous criticism with regard to his work on the guinea-pig ('07).

The contributions of Pottet ('10) on the human corpus luteum and Delestre ('10) on that of the cow are based on evidence which can hardly be considered conclusive. Delestre had no bovine corpora lutea of pregnancy at an earlier stage than two and a half months. He had twelve corpora lutea from non-pregnant animals, four of which he thought to be in the first stages of formation, but there was no effort, by observing the animals alive or by searching for the ova, to determine that ovulation had actually been recent. Pottet studied twenty-two human corpora lutea of pregnancy, the youngest already six weeks old. Both of these authors speak for the degeneration of the granulosa before rupture.

We cannot judge the work upon the human ovary very critically until the relation of ovulation to menstruation is better known or some other method of estimating the age of young human corpora lutea and of obtaining really young specimens is at hand. Bühler ('00) collected ovaries of rabbits according to Sobotta's methods, but found the distinction between theca and granulosa so difficult that he turned to the human corpus luteum. The only specimen of importance described by him is one from an operative case, without menstrual history or other means of estimating its age, except that it showed a point of rupture in process of healing (see below, p. 179, as to the possibility of error on this point). In this supposedly early corpus luteum the granulosa is degenerating and a 'typical lutein tissue' appearing in the place of the theca interna. Cristalli ('03), a pupil of Paladino, whose peculiar views will be quoted below, believes also in the total degeneration of the granulosa layer before rupture, but gives no data as to his specimens. Teacher, in discussing the Teacher-Bryce-Kerr case of early ovarian pregnancy ('08), states that he had been studying corpus luteum formation in the human, and interprets his preparations to indicate quite clearly that "whatever the source of the cells (of the corpus luteum) may be in the

lower animals, they do not in man arise from the membrana granulosa," which latter membrane he thinks is probably shed with the ovum. Hegar, in 1910, reported an examination of six human ovaries removed four and two days before the onset of menstruation, all containing corpora lutea which he supposes to be fairly young. While admitting the epithelial origin of the structure in mammals lower than man, he is inclined to view his preparations as indicating a thecal origin of the lutein cells in the human species. J. Whitridge Williams, whose text-book of obstetrics ('03-'17) is based to so great an extent upon original study that it is regularly quoted in scientific literature as authoritative, retains in his last edition the views of the preceding writers, of whose correctness he feels convinced by the study of several hundred corpora lutea.

This completes the list of recent authors who see in the corpus luteum a structure of connective-tissue origin alone. All other investigators of the past sixteen years uphold in general the epithelial origin of the lutein cells, but among themselves they vary according to their views as to the fate of the theca interna. The rabbit has been studied in 1897 by Sobotta, who found the process exactly as in the mouse, but Honoré, three years later, in the same animal, found that not all the theca interna cells are converted into fibroblasts, but that some of them linger about the periphery of even the fully formed corpus luteum. Cohn, in 1903, repeated the work, apparently without study of the ova, but dating his specimens from an observed copulation, (in the rabbit ovulation occurs only after coitus), and confirmed the results of Sobotta. Marshall, in the next year, described the corpus luteum of the sheep, dating his specimens from observed copulation. He did not seek the ova, but as in this species ovulation and coitus can occur at no time except during a short oestral period, so that coitus dates the time of ovulation within a very few hours, the presumption is great that Marshall possessed normal corpora lutea of ages accurately known. He found the granulosa to persist and to be vascularized by sprouts from the theca interna, all the cells of which were finally used up, having been converted into spindle-cells of connective tissue. A part of

the connective tissue of the corpus is contributed also by the theca externa, which is drawn inward in places by the folding of the follicular walls. O'Donoghue ('12, '14, '16) has given a confirmation of Sobotta's views for the marsupials (which I believe were first studied by Sandes ('03), whose paper was not accessible to me). Strakosch ('15) is the last to repeat the Sobotta theory in its original purity, basing his statements upon the human ovaries which were used by Robert Schroeder in his study of the time relation between ovulation and menstruation ('14).

Van der Stricht's belief that the theca interna cells are not converted into fibroblasts, but remain in the corpus luteum, no longer distinguishable from other lutein cells, found support in the study of L. Loeb ('06) upon the guinea-pig. The specimens were collected in a series dated from copulation without study of the ova. The theca interna cells, after a few hours, could no longer be distinguished from the granulosa lutein cells. This work is open to the criticism that haematoxylin and eosin (the only staining combination used) do not accentuate differences between cells of the types met with in this problem. In 1908 Van der Stricht himself repeated his ideas as the result of researches upon the ovaries of dogs, carefully checked up by examination of the ova, and in 1912 he repeated his findings in the bat.

A somewhat different view has found exposition in the very careful work of Völker ('05) upon *Spermophilus citellus*, a European marmot allied to the gophers of the western United States. The ova and embryos were recovered and examined in all cases, and there appears to have been a sufficient number of stages, though the author does not state the number of specimens studied. The theca interna cells were found to persist unchanged between the granulosa and the theca externa, even until the end of pregnancy. The few spindle-cells found in the fully formed corpus luteum are said to proceed from the theca externa. Practically the same view is presented in the thesis of Niskoubina ('09), who worked on the rabbit, but does not give an account of the methods used. Cohn ('09) studied the human ovary, but appears to have seen no really young stages. His descriptions agree with

those of Rabl, and he thinks the layer of theca cells is not destined to persist, but is a 'matrix' or source of origin for the newly forming connective tissue of the corpus luteum.

With this group should be placed one of the most ambitious of the recent attempts to work out the origin of the human corpus luteum, that of R. Meyer ('11 a). The paper describes five corpora lutea in process of formation, of which one is claimed by the author to be the youngest ever obtained in the human. The appearance of the structures and the menstrual histories were the only guides to their age. The specimens show first a proliferative stage, during which the granulosa cells swell and acquire granules of a fatty substance, and, second, a stage of 'glandular metamorphosis' through vascularization of the granulosa layer. The first spindle-cells seen in the lutein layer arise from the blood-vessels, which are sprouting inward. The wall is thrown into folds, in which the larger fat-infiltrated theca interna cells are crowded. Here they remain until the pressure of the swelling lutein tissue crushes them out of existence, an event which may be early or late according to the internal conditions of pressure. Groups of them, serving as sources of nutrition for the growing organ, may be seen about the periphery of the corpus luteum and in the folds of its wall, until fairly late in the life of the corpus luteum. The name theca-lutein cells has been given them.

As an example of the difficulty of proving anything about the origin of the corpus luteum by specimens whose age can only be guessed, it may be mentioned that the genuineness of Meyer's first and supposedly youngest corpus luteum has been sharply attacked. Ricker and Dahlmann ('12) have hinted that it is not even a naturally ruptured follicle, and J. W. Miller ('11) believed it was an atretic follicle, because Meyer had stated the granulosa cells to contain 'Fett,' while, according to Miller, neutral fat is never found in the normal fresh corpus luteum. It must be admitted that this criticism was rescinded when Meyer ('11 b) stated that 'Fett' meant merely lipoids in general, and that Miller is himself no opponent of Meyer's views. But after all we shall never be certain of the early human corpus luteum until skill and good fortune enable someone to obtain the tubal ovum with the ovary.

Four recent writers upon the human ovary have repeated the same views as Meyer with but slight modifications. Elizabeth Wolz ('12), from the study of a few specimens, believes that none of the theca interna cells suffer change into connective tissue. Some degenerate by atrophy, others remain in situ a long time. Timofeiev ('13)¹ and Wallart ('14) appear to have given as accurate and modern a description as is possible in the face of the particular difficulties of the human material. Careful menstrual histories are given, and both used varied and interesting histological methods. According to both, the theca interna cells remain in groups about the periphery of the corpus luteum for a long time, as described by Meyer, and they slowly atrophy. None of them are converted into spindle-shaped connective-tissue cells. Timofeiev describes also the deposition of lipid bodies in the granulosa lutein cells during the first days of the new corpus luteum. Lastly, Novak ('16) reports five early corpora similar to those of Meyer, whose conclusions he follows.

PREVIOUS WORK ON THE CORPUS LUTEUM OF THE SOW

It is said that von Baer's celebrated monograph ('27) announcing the discovery of the mammalian ovum, contains a description of the early corpus luteum of the sow. The first account of the histological development in swine which has come into my hands, however, is that of Zwicky ('44), entitled "De corporum luteorum origine." Zwicky was a medical student who was set to work by the distinguished Henle to study the formation of connective tissue in fibrin clots, Henle being under the mistaken impression that the corpus luteum represented the conversion of the clotted follicular haemorrhage into scar tissue. The student was acute enough to correct his master's error, even though he found haemorrhage into the follicle in two-thirds of the early corpora lutea of swine. As a result of his studies, he announced himself as on the side of von Baer and Bischoff in favor of the granulosa

¹ This Russian dissertation seems to me the best contribution to the origin of the human corpus luteum yet presented. As it was abstracted for me by a Russian-speaking scientific colleague, not especially acquainted with histological methods, I quote it with some slight hesitation, but I believe our interpretation is correct.

origin of the corpus luteum, but his description shows that he was probably including the theca interna as part of the granulosa. The little dissertation must remain as a not uninteresting example of the effect produced upon the work of an active student by the recently announced cellular theories, rather than as an important contribution to its subject.

The next to use the sow for study was Paladino ('79, '80, '81, '87), who collected about 500 corpora lutea of 100 sows. His extensive papers propose a peculiar theory of his own, namely, that the entire granulosa is lost before rupture of the follicle, and that the theca externa, carrying blood-vessels, proliferates inward, to form the corpus luteum tissue, pushing the theca interna before it to form a central connective-tissue core. In 1900 and 1905 he repeated his views of twenty years before in criticism of Sobotta, who pointed out in return that Paladino's writings contain no evidence at all, in text or plates, that he had ever seen developing stages of the corpus luteum; a just criticism, as study of the originals has convinced me.

Far different is the work of Benckiser ('84), who has given a very careful description of a small series of stages. He had, without doubt, normal and mature Graafian follicles just prior to rupture. These contained the membrana granulosa intact. In his recently collapsed follicles, containing large clots, the granulosa had been torn off in places; when there was no hemorrhage, this layer remained very largely in situ. His next stage is much further developed, its wall showing only one homogeneous layer, and the gap was bridged by the assumption that the granulosa had degenerated during the interval. The account is clearly written, its author was describing what we can now state to be normal specimens, and it was only lack of sufficient intermediate stages that led him into an error of interpretation.

One of the most frequently quoted works is that of Clark ('98), whose material consists of ovaries collected at random in the slaughterhouse. It is said that among the sows used by the butchers there were many undergoing oestrus, but it is not stated that any of those ovaries used in the research were known to be from the animals in heat. Clark gives a good description of the

immature follicle at growing stages. For study of the mature follicle he selected large follicles, without discovering whether or not they contained normal maturing ova. From these large follicles all the granulosa cells had disappeared. The author was willing to consider the possibility that they might be atretic, but inclined to rate them as normal because they seemed logical predecessors of his next stage. Much is made of the fact that the theca interna cells of ripening follicles contain granules of yellowish fat, which are taken to be the 'lutein' already present in the future lutein cells before rupture. This assumption rather overreaches itself, as one glance at fresh corpus luteum tissue of the sow will show that there is no microscopic yellow pigment present in the so-called lutein cells. In the one pair of ovaries next described, some follicles were ruptured, others were not. In the latter, the granulosa was no longer visible, except for a few cells lying in the cavity. The theca interna was thickened and closely resembled lutein tissue. In a later stage there was a central cavity rimmed by connective tissue, supposed to represent the membrana propria pushed before the thickening theca interna. Sobotta ('99 b) has given a vigorous criticism of Clark's specimens, explaining his so-called mature and just-ruptured follicles as cases of atresia. Völker ('05) has also pointed out what he considered errors of interpretation of the specimens.

However, Doering ('99) came to the defense of Clark, also using material collected at random. He states that the wall of a recently ruptured follicle shows no granulosa. His principal evidence, however, is from one corpus luteum of the sow, which shows, near the center of the section he figures, a flattened circle of granulosa cells. This he interprets as the granulosa of the same follicle in which the corpus luteum formed, which had been pushed inward by the proliferating theca interna, and which for some reason had not degenerated. I have seen very much the same appearance when a young growing follicle had crowded itself into the side of an old corpus luteum, so that a tangential section appeared to show a follicle within a corpus luteum.

Jankowski ('04), using the same method of collection, would seem to have had normal mature follicles of swine; at any rate,

the granulosa was intact. The ova were not seen. His very early corpora lutea, showing stigmata at the point of rupture, also contain the granulosa in situ and completely preserved, except that the cells are swollen, irregular in form, and contain vacuoles. The theca interna cells are large, contain lipoid granules, and resemble lutein cells. No specimens between this and the solid corpus luteum are presented. Upon such evidence he confirms Clark's account.

Kopsch ('01) demonstrated at a meeting of the Anatomische Gesellschaft certain preparations by Menzer of the corpora lutea of swine three, six, and ten days after copulation. This contribution appeared by title only, and our sole information as to its nature is the statement of Sobotta that Menzer's specimens are in general agreement with his own views.

It is fair to say that the theory of the origin of the corpus luteum from the theca alone, though it still holds a place in current literature, has no good evidence in its favor. Every investigator whose methods assure us that accurately dated specimens of a sufficient number of stages were in his hands has declared the persistence of the granulosa cells and their transformation directly, with little or no mitotic division, into the characteristic large 'lutein cells' of the corpus luteum. The problem has shifted during the sixteen years whose progress I have reviewed; the present point of interest is as to the fate of the theca interna. Are its cells all converted into connective tissue; do they persist as a special peripheral layer of the corpus luteum; do they assume an impenetrably close resemblance to the granulosa lutein cells; or can we find some other and clearer explanation of the problem of their disappearance?

The following pages contain the results of an attempt to answer these questions. Choice of the species to be studied was influenced by several reasons. There is a frequently expressed idea that perhaps the larger and smaller animals differ in the formation of their corpora lutea, as they do in many other features of their reproductive cycles; the sow is large and has an ovulation cycle not unlike the human species. Other considerations in-

clude previous experience of the author with the ovaries of swine; certain presumed histological advantages of the species, to be explained later, and, above all, the fact that the previous work on swine has been much quoted by writers in confirmation of the thecal-origin theory. Here, if anywhere, the application of modern methods of research should settle the old difference once for all.

MATERIAL AND METHODS

As it has been pointed out that the only hope of trustworthy results in this problem depends upon the possession of an unbroken series of normal specimens of known ages, a description of the material in the author's hands and the methods of obtaining it will be given in detail. The first step was a preliminary investigation to obtain exact knowledge of the period in the reproductive cycle at which the ova are shed from the ovary in order that mature follicles and very early corpora lutea might be obtained. The results of this study have already been published (Corner and Amsbaugh, '17) and will not be repeated in detail here. We were able to confirm the current supposition that in swine ovulation is coincident with the oestral period, and by this fact we are at once provided with the means of obtaining the desired stages of corpus luteum formation.

The females of the wild swine of Europe are monoestrous, according to Kaeppli ('08), having but one period of heat in the year; but under domestication the sow becomes polyoestrous, coming in heat at intervals of two to four weeks, usually about every twenty-one days, as all breeders agree. The period of heat commonly lasts three days and is characterized by sexual excitement and in some individuals by swelling, reddening, and slight eversion of the vulva, or even at times by a serous, mucous, or partially sanguineous discharge from the genital orifice. If a boar be present, the sexual excitement is made apparent by ready acceptance of coitus (commonly on the second or third day of oestrus); if none but females are in the pen, the sow in heat will be seen to sniff at the genitals of her neighbors and 'ride' them in imitation of coitus. Frequently the sow is the recipient

rather than the donor of these attentions. The period is not terminated by coitus, but continues until the end of three days.

For the purpose of the present investigation, the condition of oestrus was observed while the animals were alive in the yards of the packinghouse. The sows were marked, and on the day of killing they were traced through the processes of the abattoir and the internal genitalia received from the hands of the eviscerator. The Fallopian tubes were then removed by cutting across the upper portion of the uterine horns, were carried to the laboratory in 0.7 per cent saline solution, and there washed out by inflating them with salt solution through a slit in the wall near the fimbriated extremity. After inflation with the fluid, the tubes were gently 'milked' into a Syracuse dish, and the washings examined with the dissecting microscope. This simple and almost infallible method of finding the ova was suggested to us by Professor Evans as an improvement upon Martin Barry's practice of milking the tube without injected fluid ('39). As we have subsequently found, it had been used by Sobotta (in the rabbit) and no doubt by others as well.

We found that ovulation occurs on the first or second day of oestrus, and that the stimulus of copulation is not necessary to cause rupture of the follicles. The ovaries of all sows killed during heat contain mature Graafian follicles ready to rupture or just ruptured, in which latter case the ova are in the tubes and may be recovered therefrom for study by the method described below. Little or nothing has been known of the mature ovum of the sow, and we have found no record of any previous observation of the unsegmented ovum from the tube. We measured fourteen fresh tubal ova from nine sows and found the diameter, including the zona pellucida, to vary from 155μ to 165μ , the zone being about 10μ in thickness. The ova are plainly visible to the naked eye if placed against a strong light. We have not noticed a radial striation of the zona pellucida either in fresh or fixed ova. The ovum is filled with yolk granules of varying sizes, usually about 3μ to 5μ in diameter, which are so numerous and so refractile that they quite conceal the nucleus.

The author has presented ('17 c) a brief study of the maturation of the pig's ovum, based upon some of these specimens, which indicate that the sequence of events is the same as in other mammals. The first polar body and the second polar spindle are formed in the ovary just before rupture. After the entrance of the spermatozoon, which occurs in the tube, the second spindle completes its division, and the presence of two polar bodies is therefore a sign of fertilization. If the ova are not fertilized, they degenerate in the tube with the second spindle undivided. Just how long they survive is not known, but by analogy with the smaller and better-known mammals, we may assume that after three or four days they are no longer capable of segmentation; the degenerating ova may be found in the tubes a few days longer. It is said that pregnancy is more likely to result when the sow is served on the second day of oestrus. The number of ova extruded at one ovulation, and consequently the number of fresh corpora lutea in one animal, may be quite large. One prolific sow is known to have given birth to twenty-three pigs in one litter. However, in the mixed stock, not especially adapted for breeding, which is found in the abattoirs, small litters are the rule. Records of 128 sows raised in Maryland, presented in my paper of 1915, show that the corpora lutea of pregnancy in both ovaries numbered one to sixteen, averaging eight, and that the number of foetuses in the uteri of the same sows varied from one to ten, averaging six. Failure of fertilization, abortion, and resorption of embryos dying in utero account for the fact that not all the eggs of one ovulation proceed to full development.

About 133 embryos of the sow younger than two weeks, taken from twenty-three sows, have been observed and described in the literature. The youngest of all are the three ova found in three different sows by the present writer and Amsbaugh ('17), in which conjugation of the pronuclei had not occurred. It was not possible to know the exact time of insemination in these animals, but in one case it is believed that the animal had not been in heat, and consequently had not copulated, more than forty hours before killing. R. Assheton ('99) studied about 100 specimens during the first ten days, the youngest stage being that of two blastomeres. It

would seem that fertilization may occur about the end of the first day or may be postponed until two or three days after copulation—a conclusion which he draws from finding embryos of the same stage in two sows killed on the fourth, fifth, and sixth day post coitum. Likewise, embryos in the same uterus may vary rather markedly as to their state of development, for instance, one uterus contained ova of two segments, of nine segments, and completed morulae. For this reason it is possible to give only an approximate time schedule of early development. The ova pass down the tube rapidly and enter the uterus about the fourth day post coitum. Assheton did not find any stage further advanced than four blastomeres in the Fallopian tubes. (A specimen found by the present writer and Mr. Felix H. Hurni contained ova of two, four, and six blastomeres, all in the tube.) Assheton found that various sows killed on the sixth day presented uterine embryos from the stage of six blastomeres to fairly well-developed blastodermic vesicles. By the seventh day the zona pellucida has usually disappeared and the inner cell mass of the early vesicle has differentiated into two layers, the epiblast and the hypoblast. By the twelfth day the great elongation of the blastodermic vesicle which is so characteristic of the pig, is well under way and the vesicle is already 10 to 12 mm. long. By the fourteenth day each vesicle may measure 20 cm.; in the embryonic area the primitive streak is well developed and there are from one to three somites. In addition to Assheton's studies, thirty embryos of the ninth, tenth and eleventh days have been described by Weysse ('94), and from the fourteenth day to about the twenty-fifth we have the accurate tables of Keibel ('97). For older (foetal) stages, no good age-length ratios have been determined. The period of gestation is usually 116 to 120 days. It is stated that sows undergo oestrus and may become pregnant again five weeks after littering.

During the progress of this investigation the ovaries and uteri of several thousand sows have been examined macroscopically, and the corpora lutea of about 300 have been studied under the microscope. The permanent preparations upon which the following description is based comprise sections from the Graafian

follicles and corpora lutea of 171 sows of which there are records sufficient to determine the stage of the reproductive cycle. In 162 of them the ova, developing embryos, or fetuses were examined and recorded.

Twenty-four were killed during the oestral period or within the first week after the onset of heat. Some of the tubal ova found were unfertilized, others were fertilized and were in stages from the one-celled to the six-celled embryo. Five of the twenty-four sows mentioned were obtained before a method of discovering the ova had been acquired, and the ova were therefore not sought, but as the dates of copulation were noted at the University of California Farm by Professor Thompson, it seems proper to include them, since their corpora lutea agree with the others in structure.

Six sows were taken in the second week after ovulation. As the ova were unfertilized, they had degenerated, and were not found, except shriveled eggs in two of the sows. It chanced that none of those sows which had copulated were killed during this period, and thus the opportunity to obtain embryos of the second week did not fall to my lot.

Fifteen contained embryos of the third week, from five to thirty-nine somites. The ovaries of the eleven youngest of these were given me by Prof. F. R. Sabin; some of the embryos to which they were related are described and pictured in her recent contribution to the early vasculogenesis of the pig (Carnegie Institution of Washington, Contributions to Embryology, No. 18, 1917).

One hundred and twenty-four compose a complete series from animals containing embryos of the fourth week to the end of pregnancy, the embryos or fetuses being measured in each case. Two were obtained from sows which had littered seven and ten days before killing, respectively. Most of the older corpora lutea of pregnancy were prepared in the Anatomical Laboratory of Johns Hopkins University, and formed part of the material for my previous monograph ('15). They have been restudied in the light of the results gained from the specimens of the first fourteen days after ovulation, all of which were obtained in California.

The collection of this material would have been impossible without the special and unusual coöperation which has been extended to this laboratory by the Western Meat Company of San Francisco. I refer to their donation of permanent laboratory quarters in their West Berkeley plant (Oakland Meat and Packing Company) to the Anatomical Laboratory of this institution. I owe especial thanks to Mr. J. O. Snyder, general superintendent of the Western Meat Company, and to Mr. Ralston B. Brown, superintendent of the Oakland Meat and Packing Company, and to many other members of the staffs and employes of both these establishments; to Dr. H. H. Hicks, U. S. Supervising Inspector, Dr. G. R. Ward, and other members of the U. S. Inspection Service at the South San Francisco plant, and to Dr. Thomas Presst, of the California State Inspection Service. To Mr. R. B. Brown in particular I owe the opportunity of observing living animals and of obtaining their pelvic organs, often at the cost, I fear, of some inconvenience to the routine of his plant. The permanent laboratory space provided by him at the packing-house has been invaluable during the prosecution of this work. I am further indebted to Professors Evans and Sabin for the contribution of ovaries with the corresponding early embryos; to Prof. J. I. Thompson, of the Department of Agriculture of the University of California, for observing and marking five animals, and to Messrs. A. E. Amsbaugh and Felix H. Hurni for assistance in the collection and preparation.

In general the younger specimens were fixed in Bouin's fluid, the older in 10 per cent formol, these fluids being selected to secure the advantage of fixation in slow aqueous coagulants, as will be explained in the next section; small pieces of many ovaries were placed in osmium tetroxide for study of the lipoids. Blocks were imbedded in paraffin and celloidin. The chief stains used with the specimens herein described comprised haematoxylin and eosin, Heidenhain's iron haematoxylin, Mallory's triple connective-tissue stain, Van Gieson's mixture, and several lipoid-soluble dyes (Nile-blue sulphate, Sudan III, Scharlach R), besides many special procedures applied to fresh and fixed tissues.

SPECIAL CYTOLOGY OF THE LUTEIN CELLS OF THE SOW

Four years ago the writer undertook, at the suggestion of Professor Mall, to study the corpus luteum at different stages of pregnancy, with the aim of learning through the varying appearances to standardize the stages as a means of determining the ages of embryos and fetuses (Corner, '15). It was very good fortune that led to the choice of the pig for the first studies, for a useful peculiarity of cytoplasmic structure was found to occur in this species. If we take a section of the corpus luteum of a pregnant sow whose fetuses are perhaps 100 mm. long, fixed in formol, and stain it with any strong cytoplasmic stain, study of the lutein cells shows that the cytoplasm contains unstained areas which are roughly concentric to the nucleus, and which appear to form canal-like paths in the cell (fig. 1). In the younger corpora the canals grow more and more complex, assuming the form of wide V-shaped spaces, long clefts, and circles in the cytoplasm, so extensive that the nucleus is surrounded only by a narrow zone of endoplasm. But it is in the corpora lutea of pregnancies under 30 mm. that the highest development of the exoplasmic zone is found. Here the entire outer part of the cell is occupied by a curiously elaborate system of vacuoles, almost every one of them in turn containing a spherule of substance which, although it takes the same stain as the cytoplasm, yet has a more hyaline appearance, and is seen in the section as a bright ring. Within many of the spherules is found another and tiny vacuole (fig. 2, *r*). Corpora lutea of pregnancies with fetuses more than 140 mm. long contain no trace of this system (figs. 23 and 24), and by careful attention to the degree of its development it is possible, therefore, to estimate the age of the corresponding embryo with some accuracy. Taking other histological features into consideration, I find myself able to detect the stage of pregnancy within close limits by examination of the corpus luteum alone. The same bodies are present in the corpora lutea of dogs, and were seen in the lutein cells of rabbits by Cohn ('03), who undertook certain microchemical studies upon their nature, which I have been able to extend. It was tentatively suggested, in my former paper, that they represent an elaborate

modification of the Golgi-Holmgren intracellular apparatus. This view I have had to discard as a result of work which had led to the correct interpretation (Corner, '17 a, b). The spherules are due to the presence of a lipid, probably of phosphatid nature, which is sufficiently oily to round up in the presence of water. The round droplets thus produced usually surround the preëxisting globules of neutral fat present in consider-

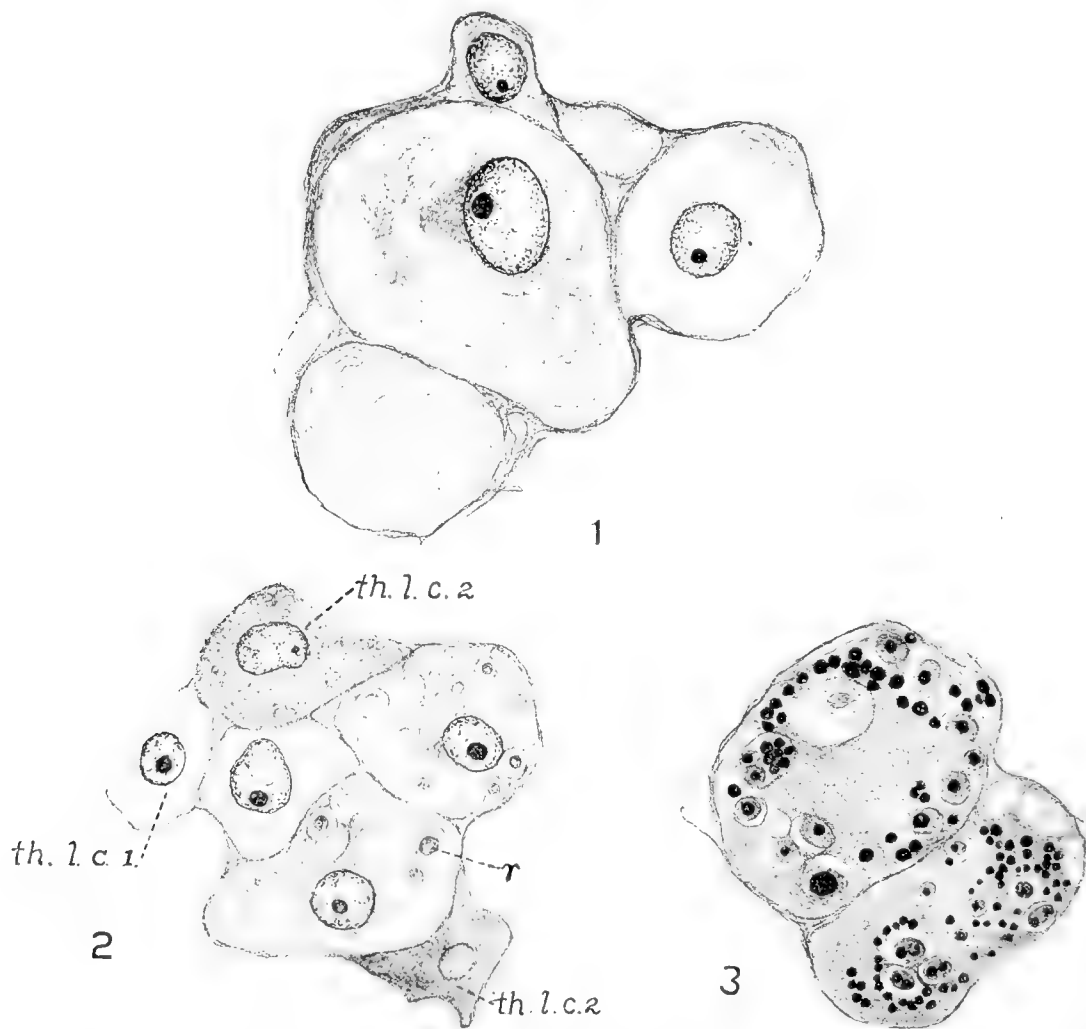


Fig. 1 Cells of corpus luteum of pregnant sow (foetuses 100 mm. long), showing spaces in cytoplasm. Mallory's connective-tissue stain. Formol fixation. $\times 810$.

Fig. 2 Cells of corpus luteum of pregnant sow (embryos 20 mm. long). Formol fixation. Mallory's connective-tissue stain. $\times 810$. *r*, vacuoles in lutein cell; *th.l.c.1*, theca lutein cell, type 1; *th.l.c.2*, theca lutein cell, type 2.

Fig. 3 Cells of corpus luteum of pregnant sow (embryos 20 mm. long). Formol fixation followed by osmium tetroxide. $\times 810$.

able numbers in the early corpus luteum cells of swine (fig. 3). After immersion in alcohol, xylol, ether, or other lipoid solvents, both the fatty center and the phosphatid substance of the spherical droplet are dissolved out, leaving only a hollow sphere (appearing as a ring in thin sections), probably composed of proteid constituents of the cytoplasm precipitated in the spherules during fixation. The bodies are not seen in fresh tissues nor in material fixed with very rapid coagulants like osmium tetroxide, which precipitate the proteids before the oil droplets round up. The microchemical evidence of these conclusions is given in the articles cited.

The appearances in question, therefore, are simply the result of methods of fixation which do not preserve certain obscure lipoids in their natural diffused state. But the artifact is a useful one. In the first place, it enables us to follow the changes in amount of the phosphatid substance during the advance of pregnancy. It also allows us to estimate the age of a corpus luteum of pregnancy from the histological appearance alone, and it gives us a constant (even though artificial) cytological characteristic of the cell which can be used in determining the early history of the lutein cells. Due no doubt to different physical state of the cell lipoids, the phenomenon does not occur in the human and bovine corpora lutea (a former statement of the author to the contrary).

THE MATURE FOLLICLE

As the reader has perceived, one of the crucial points in this debate has been as to the condition of the granulosa of the mature follicle. Some investigators think that this layer degenerates before rupture, others that it remains intact. It would seem, offhand, an easy matter to obtain mature follicles and settle the question at once. To be certain that a given follicle is really mature is very difficult, however, and particularly so in some species. Mere size is no criterion, for full-sized follicles are not infrequently in a state of advanced atresia. The presence of maturation processes in the ovum is no more certain

a sign, for the formation of the polar bodies, as was pointed out by Flemming ('85), is a frequent occurrence in early atresia. As atresia may set in at any time in the life of a follicle, even up to the last, it is obvious that we can never state with complete assurance whether a given Graafian follicle is doomed to degeneration or is about to rupture and give rise to a corpus luteum.

We shall probably not be in error, however, in assuming that a follicle is normal and mature if it is taken from the animal at a time when ovulation is known to be imminent, and if it contains a normal ovum in which the process of maturation is under way.

To satisfy these requirements is easy when the animal is small enough to be under observation in the laboratory, when an impending ovulation can be predicted (as, for instance, in the rat and mouse, which are now known to ovulate about eighteen hours after littering) and when the small size of the ovaries and tubes readily permits serial sectioning. In animals like the hog, however, it is more difficult to observe these two criteria of the mature follicle, and no previous investigators of this species have watched the animal during life in order to determine the imminence of ovulation, nor have any taken the pains to find and study the ova of the follicles which they described as ripe.

In the author's material, of sixteen animals known to have been in heat when killed, only two were taken early enough in oestrus to contain unruptured follicles. In one, all the follicles were still unruptured. Three of them were successfully sectioned; two of them contained ova with nuclei presenting 'germinal vesicles,' the third showed the first polar body and the second polar spindle. In the second sow, one of the follicles had ruptured; the tubal ovum could not be found; one of the remaining follicles, upon sectioning, showed its ovum to be in the matured state, with the second polar spindle formed. There can be little doubt, therefore, that the follicles in question were perfectly normal and would have immediately shed their ova and developed into corpora lutea had the sows not been slaughtered.

These follicles possessed clear, translucent, almost spherical walls, protruding a great part of their bulk from the ovary, as is characteristic of the species. They all measured about 7 mm.

in diameter, the measurement ranging from 6 to 8 mm. in some which were distorted by crowding.² The surface presented no 'stigma' or other sign of impending rupture. On section, they were found to possess the usual three layers, and the membrana granulosa was present and intact, showing no sign of degeneration. The wall of that part of the follicle lying deepest in the ovary presents a slightly wavy contour toward the cavity.

The cells of the granulosa (fig. 4, *a*) form a layer about six to nine cells deep, or about 0.13 to 0.17 mm. thick. Those cells nearest the membrana propria form an irregular columnar layer, but the upper cells show less semblance of order in their arrangement. The cells are round or polyhedral, from $8 \times 8\mu$ to $10 \times 16\mu$ in diameter (in celloidin sections), with round nuclei 5μ or 6μ in diameter. The cytoplasm appears homogeneous after the usual fixing reagents, except for a few vacuoles due to the presence of lipoid substances, as will be explained later. Often the cells possess short processes which meet those of the neighboring cells so as to make the tissue resemble a syncytium.

The theca interna is about 0.09 to 0.10 mm. thick, or a little more than half as thick as the granulosa. Its most striking characteristic is the presence of three to five layers of large 'epithelioid' cells, usually from $10 \times 17\mu$ to $12 \times 17\mu$ in diameter, but occasionally reaching larger sizes, up to perhaps $16 \times 24\mu$ (fig. 4, *b*). On section, they are oval, spindle-shaped, or almost rectangular, with their long axes in the circumference of the follicle, so that they usually lie at right angles to the columnar layer of the membrana granulosa. Between the larger cells, and especially along the inner border of the layer formed by them, are others of small size (though still somewhat larger than the granulosa cells), which are similar in appearance to the large theca cells. In material fixed in Bouin's fluid the theca cells

² In a previous publication ('15) I fell more or less into the same error of method which I am now imputing to others, and attempted to determine the size of the 'ripe' follicle without knowing the state of the enclosed ovum. The larger follicles there mentioned, however, agree histologically with the accurately known specimens described in these pages, and it is therefore likely that my previous conclusions were correct, namely, that the normal mature follicle may attain a diameter of 10 mm.

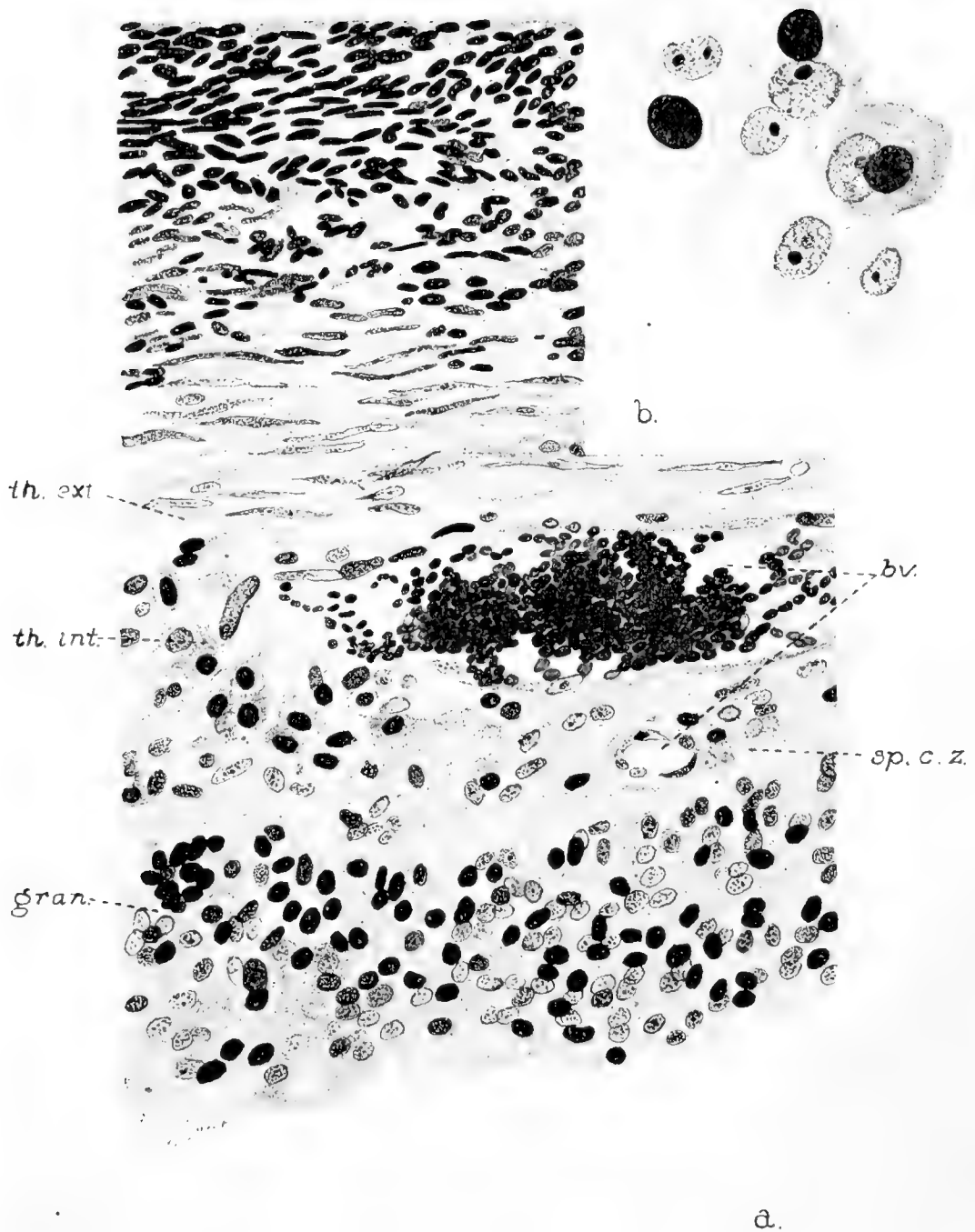


Fig. 4 *a*, Portion of wall of unruptured Graafian follicle (sow in heat, ova maturing). Iron haematoxylin. $\times 380$. *b*, A few cells from theca interna of same specimen. $\times 800$. *gran.*, membrana granulosa; *th.int.*, theca interna; *th.ext.*, theca externa; *sp.c.z.*, spindle-cell zone of theca interna; *b.v.*, blood-vessels.

are notable for the presence in their cytoplasm of a number of vacuoles, giving them a striking honeycombed appearance (fig. 4, *b*). These vacuoles are due, at least in part, to the presence in the fresh tissue of granules of fat-like substance, packed closely into the theca cells, whose chemical nature has not been determined (fig. 5, *b*). In some species they are quite yellow, since they hold in solution some of the lipochromes common in the ovaries of certain animals, but in the pig they are practically colorless. It is of course the appearance of these large fatty cells of the theca which has helped establish the belief that they are the precursors of the 'lutein cells' of the corpus luteum. The granules are soluble in alcohol; in osmium tetroxide they take a color varying from gray to deep black; they take a decided reddish color with Herxheimer's alkaline Scharlach Rot, but appear not to stain at all with Nile-blue sulphate; they are not anisotropic. From these reactions we may assume that the substance is of lipid nature, but is perhaps not a neutral fat. The granules are variable in diameter, from 0.5μ to 1.5μ , a few even reaching 2.5μ . Many of the theca cells contain, instead of lipid granules, vacuoles which are not stained even in osmium preparations, and which therefore must contain either a modified form of the lipid or some other substance which is not rendered insoluble by combining with OsO_4 (fig. 5, *b*). The smaller cells of the theca interna mentioned above usually have finer granules, but there are all transitions between the large and small types. The cells of the granulosa contain a few very small granules, uniformly black after osmium fixation; these are usually more numerous in the basal layer of the follicular epithelium.

Between the granulosa and the cellular layer of the theca interna just described is a narrow zone (0.03 to 0.04 mm.), which contains chiefly spindle cells without fatty inclusions or vacuoles (figs. 4, *a*, and 5, *a*). These cells appear to be of two types: first, the endothelium of the blood-vessels which lie in this zone and, second, the fibroblasts of the perivascular tissue, which are part of a light network of connective-tissue reticulum supporting the theca and forming a base for the granulosa, for I agree with J. G. Clark that the membrana propria is nothing more

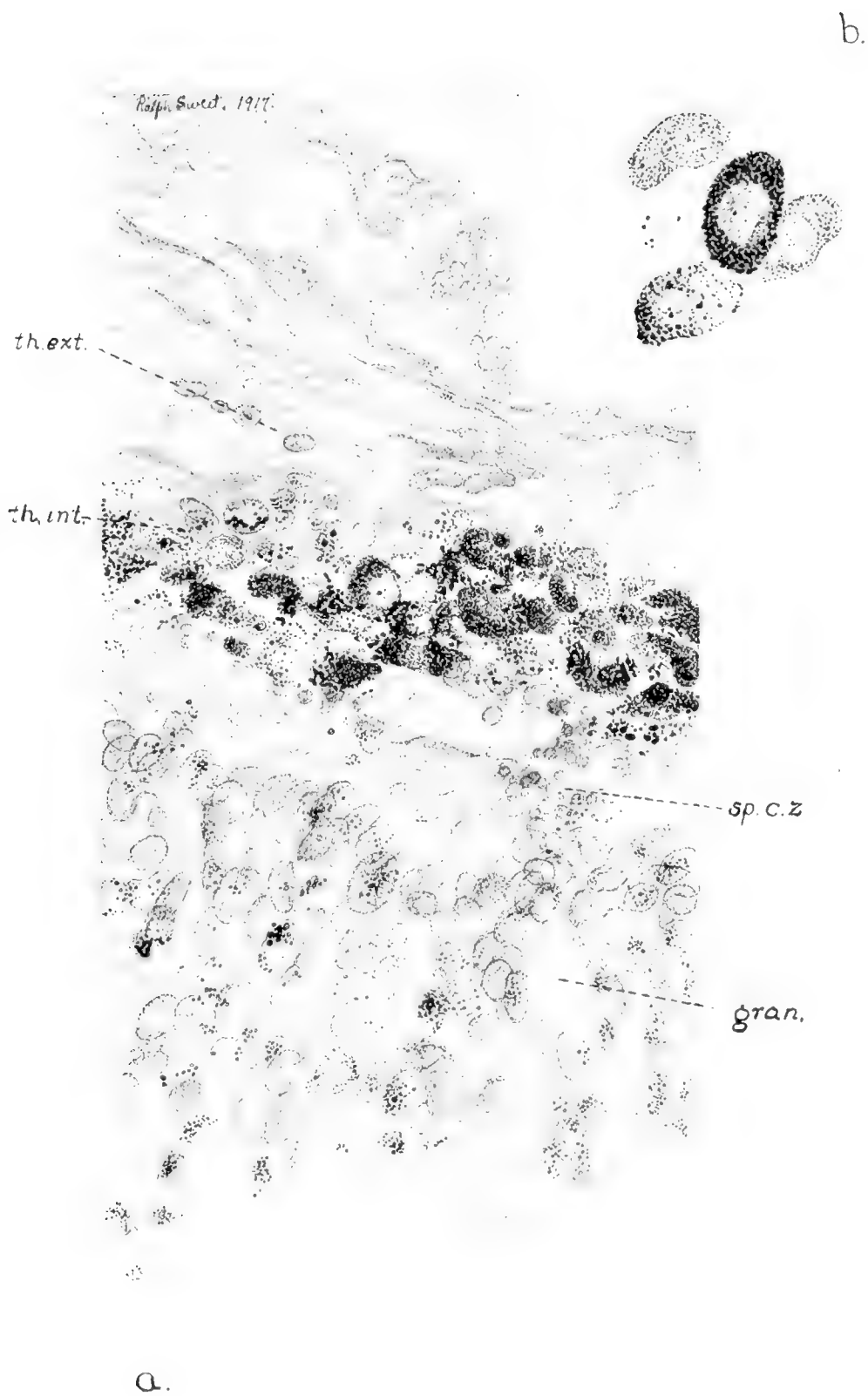


Fig. 5 a, Portion of wall of unruptured Graafian follicle (sow in heat, ova maturing). Osmium tetroxide fixation without further stain, showing distribution of fats. $\times 380$. b, A few cells from theca interna of same specimen. $\times 800$. *gran.*, membrana granulosa; *th.int.*, theca interna; *th.ext.*, theca externa; *sp.c.z.*, spindle-cell zone.

nor less than a network of these fibrils applied closely to the base of the granulosa layer.

The theca externa consists of a layer of long spindle-shaped cells, shading off into the stroma of the ovary (or into the capsular connective tissue, over that part of the follicle which is jutting out from the ovary). It is composed chiefly of collagenous fibrils and their associated fibroblasts, but it is highly interesting to note in connection with the subsequent collapse of the follicle, that there are also a good many smooth muscle fibers, as is readily seen by the use of Van Gieson's stain. There are no elastic fibers, except in the walls of the larger blood-vessels.

Just before rupture there are many mitotic figures in the cells of the theca externa, but only occasional signs of cell division in the theca interna and the granulosa.

Injected specimens show the blood-vascular distribution to be as described by His and J. G. Clark (fig. 6). Large vessels form a network in the theca externa, sending twigs inward to form a generously anastomosing plexus which lies in the above-described spindle-celled zone of the theca interna.

I have found a curious arrangement of the blood-vessels in the ovum-bearing area of the follicle. The discus proligerus is a cone-shaped or rounded projection of the granulosa bearing the ovum near its apex, which until shortly before maturation of the ovum is composed of densely packed granulosa cells. At its base, in this particular species, are found a number of little vascular loops sprouting up from the vessels of the theca interna well into the granulosa of the discus, and pushing before them the cells of the basal columnar layer (fig. 6, *loops*). The basal cells appear as if radiating from the loops, and like all the cells of the area occupied by the loops are enlarged and have a much less dense cytoplasm than the other granulosa cells. Those loops which are near the center of the discus are longer than those toward the periphery. Such vascular loops penetrating the granulosa have apparently not been mentioned previously. They are not to be found in the rat and mouse, the only other species which I have studied in this regard. It would seem that

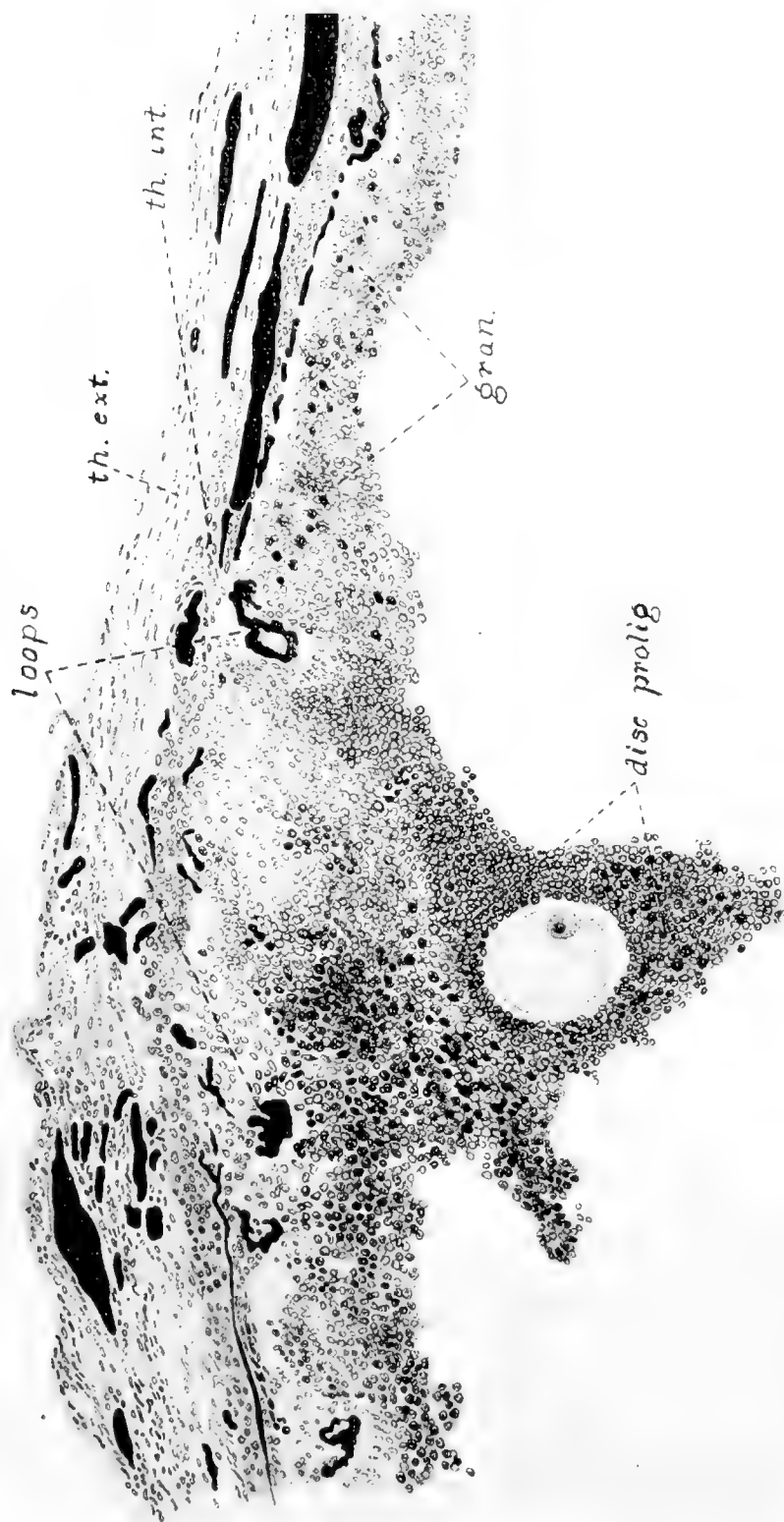


Fig. 6 Portion of wall of nearly mature Graafian follicle, ovum showing 'germinative vesicle.' Blood-vessels injected with India ink. $\times 120$. *disc. prolif.*, discus proliferans; *gran.*, membrana granulosa; *th. int.*, theca interna; *th. ext.*, theca externa; *loops*, vascular loops entering granulosa.

the large size of the discus proligerus (as large as the entire follicle of the mouse) places the ovum at such a distance from the vascular bed that special vessels are needed for its nutriment.

Be this as it may, by the time maturation of the ovum is in progress, the character of the discus proligerus has become considerably modified (fig. 7). Its cells are very much swollen by a

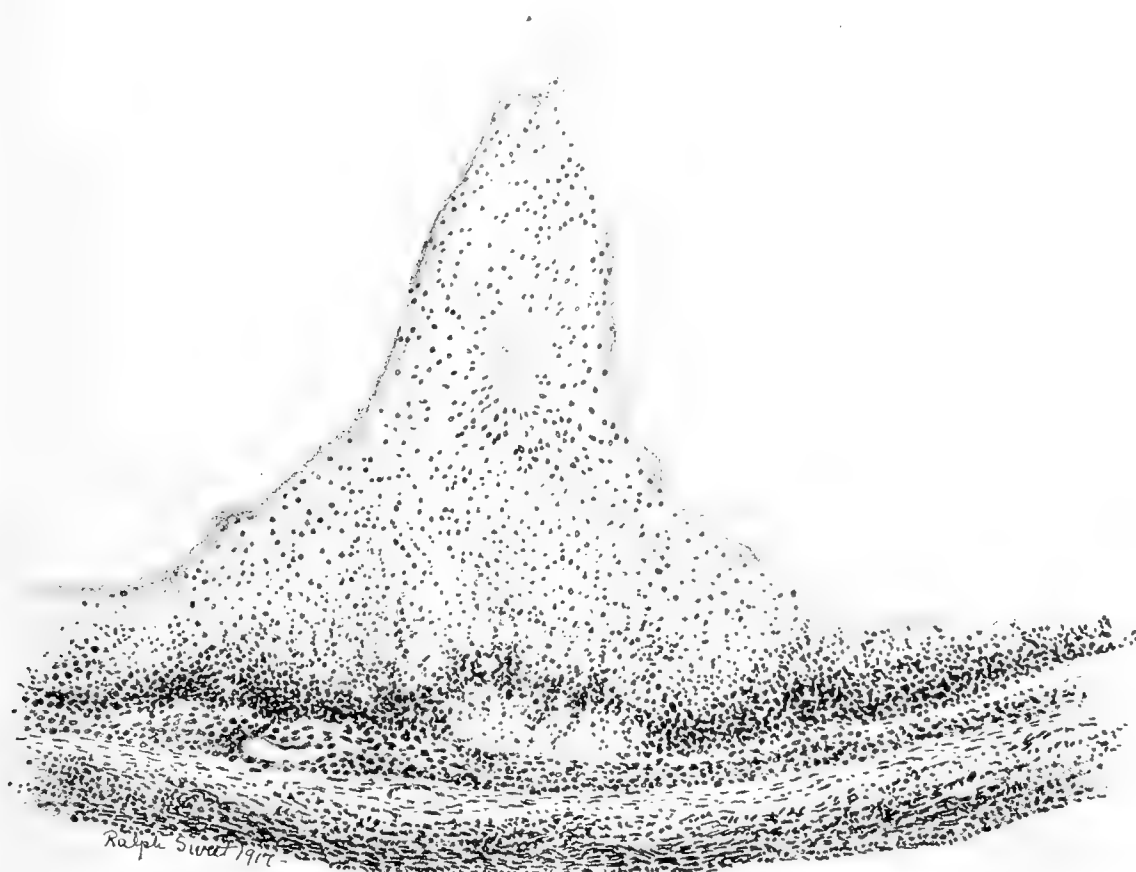


Fig. 7 Portion of wall of mature Graafian follicle (sow in heat), showing mature ovum in situ, and discus proligerus in process of dissociation. $\times 50$.

vacuolization of the cytoplasm, so that they stand farther apart from each other, and in many places seem to be no longer in contact. About the ovum the cells of the corona radiata still hold together, but the rest of the discus has nearly crumbled away, and the slightest disturbance must complete the freeing of the ovum, bound as it now is to the parietal granulosa only

by a few strands of cytoplasm. This rearrangement of the discus proligerus was long ago shown by Bischoff ('78) to be a trustworthy sign of impending rupture of the normal follicle. Certain subsequent observers, wondering how the ovum could be freed from its apparently secure moorings, were led to conjecture that there is a total desquamation of the granulosa—an error in which they were confirmed by the fact that for lack of the proper stages they did not see the mechanism for cutting off the ovum described by Bischoff, but did see, on the other hand, the complete dissolution of the granulosa, in follicles which we now know to have been atretic.

THE FRESHLY RUPTURED FOLLICLE

Four animals of my series contained follicles which had ruptured very recently. One of these sows had shown the first signs of heat at some time between thirteen and twenty-two hours before killing, another between sixteen and thirty-nine hours before killing, and the other two were in the second or third day of oestrus (probably the second). As we have shown on page p. 132, rupture of the follicle occurs on the first or second day of oestrus. In all four of these cases, unfertilized ova were found in the tubes, there having been no copulation.

Apparently the act of rupture begins by the production of a small slit in the exposed part of the follicle, through which the ovum escapes to enter the tubal fimbria (figs. 8 and 9). A varying amount of the follicular fluid, usually a considerable portion, is extruded with the egg, and the follicle collapses as the volume of its contents suddenly lessens. It seems that an important part in this collapse must be taken by the fibers of involuntary muscle which lie in the theca externa; through their contraction the follicle is greatly diminished in all dimensions. At the point of rupture, the muscle fibers draw the theca externa away from the torn area, and the result is a slight eversion of the wound, through which the theca interna and granulosa protrude, forming a small reddish papule 1 mm. or less in diameter, the so-called stigma (fig. 12). The eversion of the inner layers

appears at times to close the orifice immediately, but in other cases the follicular walls do not come together about the opening at once; the tiny slit is first plugged by fibrin, and later closed permanently by proliferation of its edges, much as described by Strakosch ('15) in the human corpus luteum. From the minute blood-vessels whose torn ends lie in the stigma there is often a slight oozing of serum or of blood, so that the surface of the ovaries at this time may be roughened by tags of pale or bloody

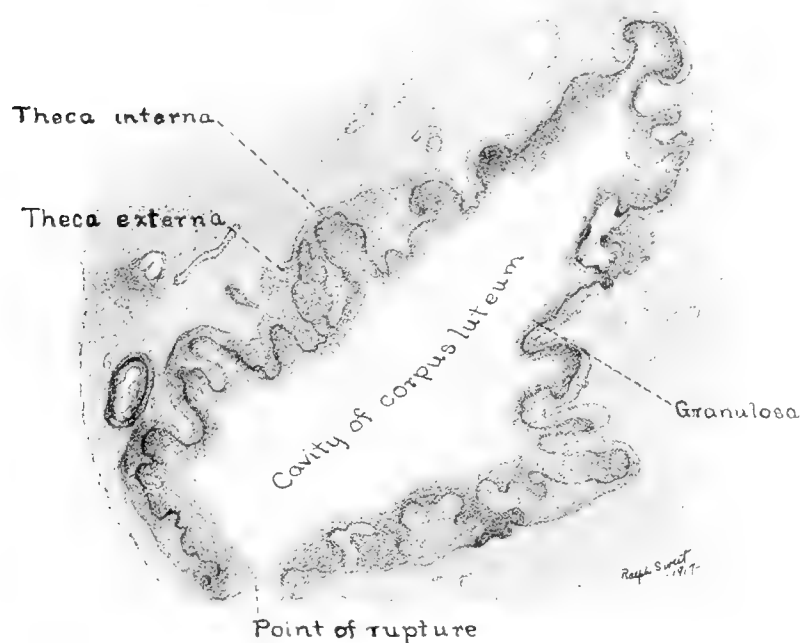


Fig. 8 Diagram of ruptured Graafian follicle (sow in heat, ova in tubes), illustrating partial collapse without great infolding of walls. $\times 14$. (Compare with figure 9.)

fibrin, sometimes forming temporary adhesions to the fimbriae of the tubes. The entire ovaries and the tubes are usually much congested during oestrus.

On section, the follicular cavity is collapsed to a mere slit in some cases, in others it is still partially distended, owing to the continued presence of more or less of the follicular fluid. For this reason, the size of the structure varies, but in general it is much smaller than the mature unruptured follicle, its diameters vary-

ing from 3.5 to 6.5 mm. when not distended by hemorrhage. Most frequently the ruptured follicles are ovoid in form, about 4 x 4 x 5 to 5 x 5 x 6 mm. in diameter. Owing to the collapse of the follicle and to the contraction of the theca externa, the inner walls of the cavity are no longer smooth, but are thrown into folds whose complexity varies from that of low ridges in those

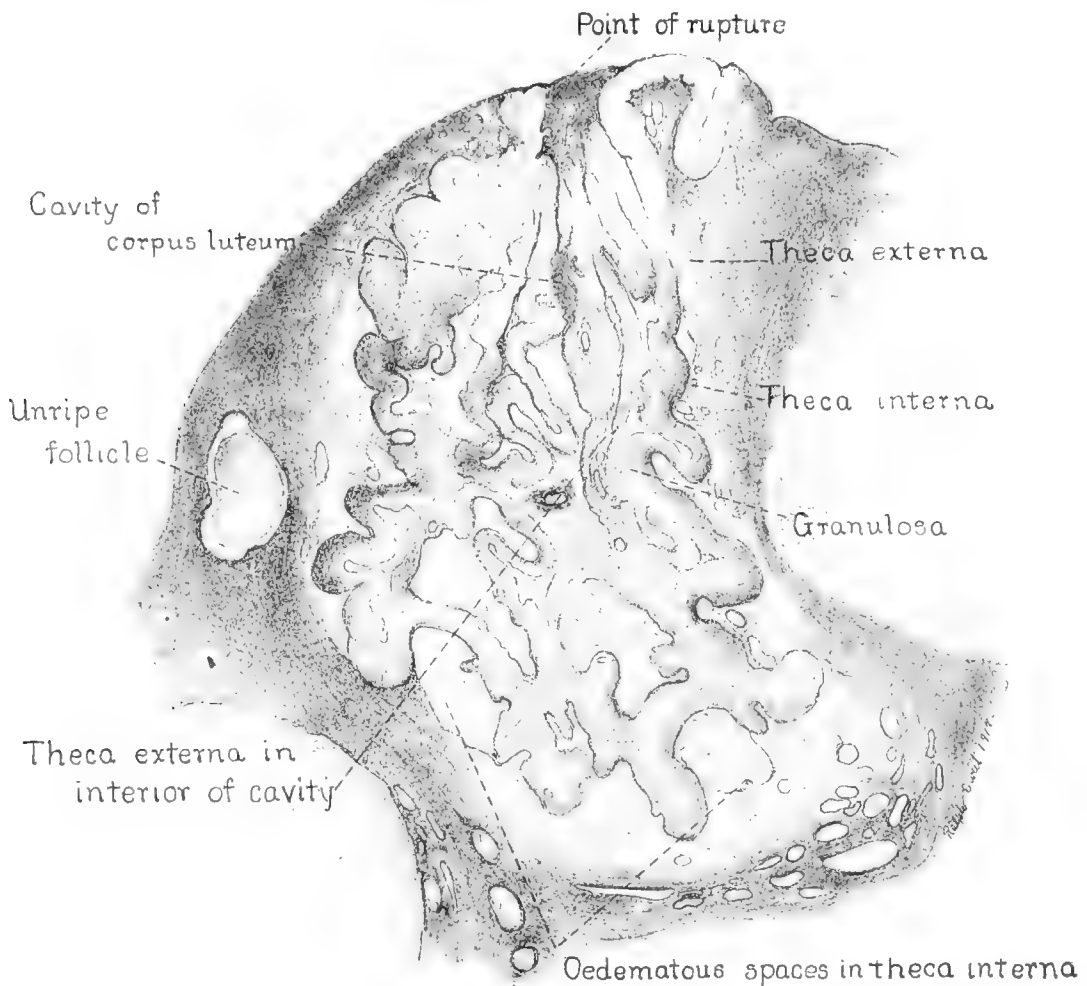


Fig. 9 Diagram of ruptured Graafian follicle (sow in heat, ova in tubes), illustrating complete collapse with much infolding of walls. $\times 14$. (Compare with figure 8.)

follicles where much follicular fluid still lingers (fig. 8) to elaborately interwoven folds such as those shown in figure 9.

Microscopically, the follicular wall is found to consist of the same layers as before rupture (fig. 10). There is no sign of any degeneration of the granulosa, which is now somewhat thicker,

since it lines a smaller cavity than before. The individual cells are about the same size as formerly, but in many places are now elongated into oval or spindle forms by the stresses of the collapse, appearing to have slid upon each other as the granulosa thickened. The theca interna is the layer most affected, in a mechanical way, by the sudden collapse, for in some of the

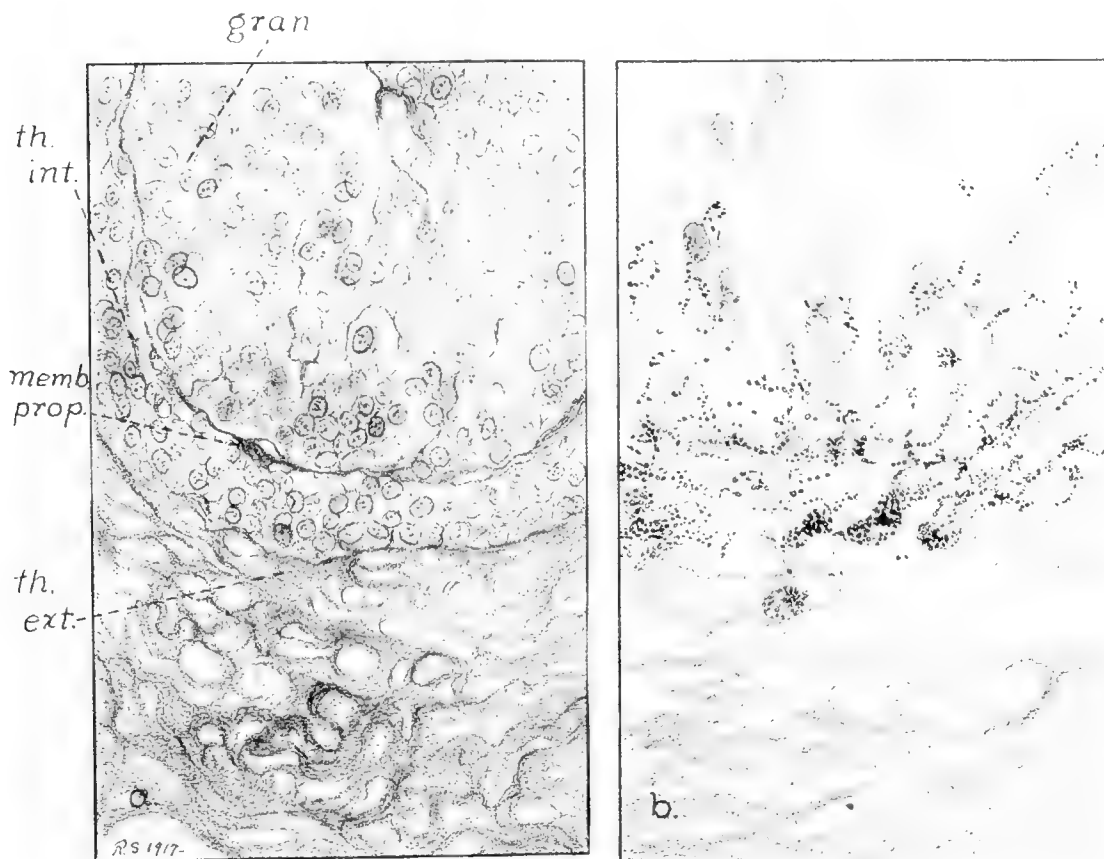


Fig. 10 Portions of wall of recently ruptured Graafian follicle (sow in first day of oestrus, ova in tubes). $\times 330$. *a*, Mallory's connective-tissue stain, Bouin's fixation. *b*, Osmium tetroxide after formol fixation, showing distribution of fats. *gran.*, membrana granulosa; *th.int.*, theca interna; *th.ext.*, theca externa; *memb. prop.*, membrana propria.

fold it is violently torn apart, so that there are many wide spaces either within the theca interna or between the two thecae (fig. 11, *tear*). These spaces are occupied either by networks of fibrin, which may be altogether devoid of cells, or contain an occasional theca interna cell, or a leucocyte; or the space may

not be an actual tear, but merely an oedematous area in which the cells, connective-tissue fibers, and blood-vessels of the thecae interna and externa are held apart by the tissue fluids. However, over many of the folds, and always in the depressions between the folds, the theca interna is neither torn nor oedema-

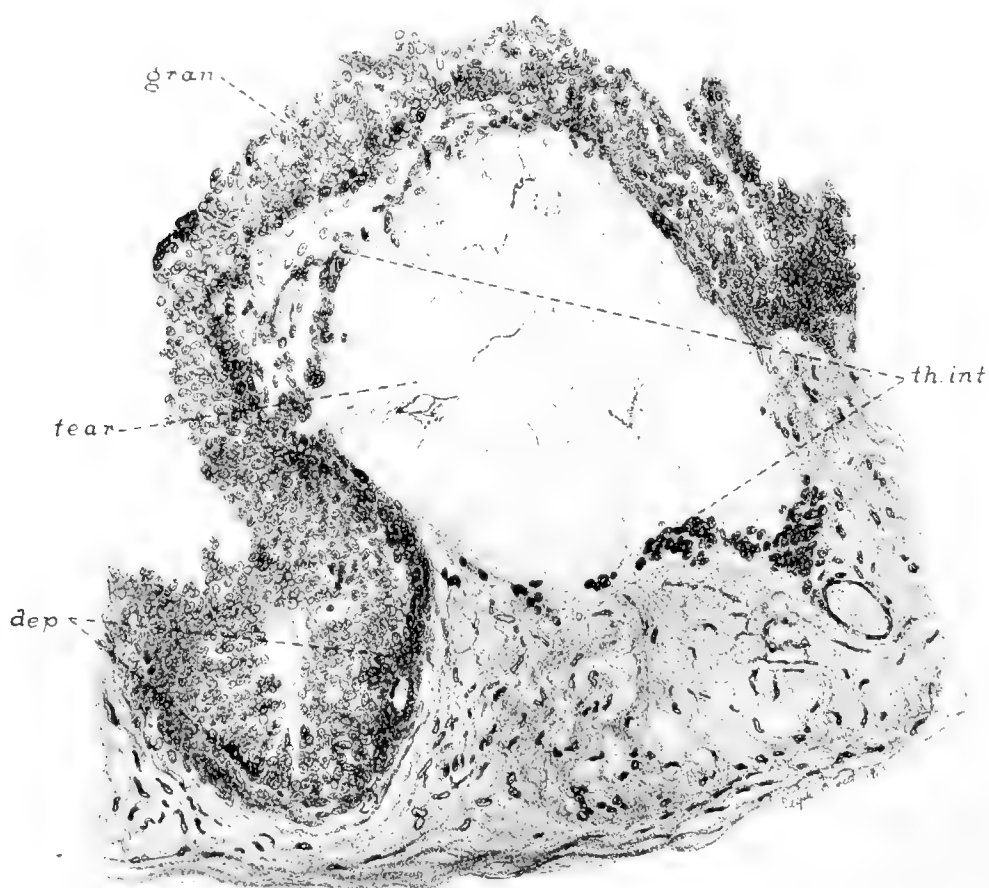


Fig. 11 Portion of wall of recently ruptured Graafian follicle (sow in heat first day of oestrus, ova in tubes; same animal as in figures 9 and 10), showing torn area in theca interna in a fold of the wall. $\times 80$. *gran.*, membrana granulosa; *th.int.*, theca interna; *tear*, torn area in theca interna; *dep.*, depression or recess between folds of wall.

tous (fig. 11, *dep.*). The tears do not separate the theca interna from the granulosa; these two layers are everywhere in apposition, and the boundary between them is still marked at most points by the slight wall of condensed connective-tissue fibers, originating in the innermost layer of the theca interna, the so-called

membrana propria (fig. 10). The theca externa is of course drawn into the folds of the wall, and where these folds are very deep, long spindle-cells of the externa may thus penetrate almost to the center of the former follicular cavity—though of course they are walled out by the inner layers (fig. 9). Dividing cells are found not infrequently in the theca externa, but are quite rare in the inner layers. The distribution of lipoid substances, as indicated by the use of osmium tetroxide and Herxheimer's stain, is exactly as in the mature unruptured follicle (fig. 10, *b*). Leucocytes are found in the walls of all developing corpora lutea.

The blood-vessels are exactly as in the unruptured follicle, the picture presented by them being modified only by the elaborate infolding of the walls (fig. 12). At the point of rupture the torn vessels of the thecal plexus present to the outside, and within a few days of rupture have sprouted into a little rosette of capillaries about the stigma, which helps to make this spot conspicuous by its redness. In the production of the curious torn spaces of the theca interna, described above, vessels of the theca interna are not infrequently ruptured, with resultant haemorrhage into the theca. If the loss of blood is very slight, the broken-down blood is taken up by the large cells of the theca interna, in which the phagocytosed golden-brown pigment may remain for some days at least (fig. 13). In one of my cases there was a single local haemorrhage into the theca externa; and the nearest cells of the theca interna were full of blood-pigment granules. However, when the thecal haemorrhages are large, the resultant haematomata may burst through the granulosa into the cavity. I am inclined to think that we have here the source of most of the bleeding into the early corpus luteum cavity. The now almost forgotten doctrine of Henle and Paterson, that the corpus luteum is formed from the blood clot of the newly ruptured follicle, naturally led to investigations into the importance and constancy of the haemorrhage in various species, which have been summed up by Sobotta in his paper of 1896. In the pig, Zwicky ('44) held that bleeding is frequent, Paladino ('80) that it occurs in two-thirds of the cases, Benckiser ('84) that it is inconstant, Spiegelberg ('65) that it is important, and Bonnet ('91) that it is constant and



Fig. 12 Recently ruptured Graafian follicle (ova found in tubes), blood-vessels injected with India ink. $\times 15$. *gran.*, membrana granulosa; *th.int.*, theca interna; *th.ext.*, theca externa; *stig.*, stigma (blood-vessels at point of rupture).

marked in extent. Sobotta ('96), reviewing the evidence, is inclined to the last view. Pflüger ('63), in an experimental investigation, found that in cats and rabbits killed violently there was much more frequent bleeding into young corpora lutea than in animals killed without struggle and very carefully autopsied. In my own specimens, out of sixteen sows whose ovaries contained very early corpora lutea, dressed at a packing-house using the relatively gentle method of scraping by hand, four showed more or less blood in the corpora lutea and twelve

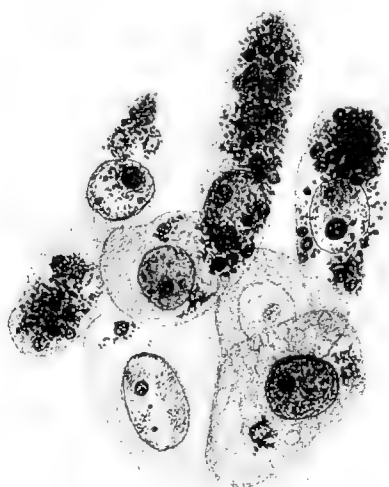

Fig. 13 Cells from theca interna of recently ruptured follicle (sow in heat, ova in tubes). Iron haematoxylin stain, showing pigment and broken-down erythrocytes in theca cells. $\times 1000$.

were entirely free of macroscopic haemorrhage. In another establishment, where the carcasses are conveyed 150 feet dangling from a chain and are scraped by engine-driven revolving vanes (so that in the bodies of pregnant sows, young foetuses frequently suffer an effusion of blood into the amniotic sac), there chanced to be a somewhat higher proportion of haemorrhagic follicles; but even there, in spite of such excessive violence, it is common enough to see delicate corpora lutea one or two days old come through with no blood at all in their cavi

ties. Again, trauma at the time of killing does not explain away all the haemorrhages; for instance, in those cases in which among a number of solid, bloodless corpora lutea several days old, one or two others are found distended with dark clotted blood to a size exceeding the normal corpora. I feel that the present evidence indicates that haemorrhage into the corpus luteum of the sow, while not uncommon, is the exception rather than the rule, and is of no anatomical or physiological importance. Indeed, the arrangement of the follicle seems well adapted to prevent any considerable loss of blood into the cavity, for the tiny vessels at the place of rupture are promptly directed outward toward the peritoneal cavity, while the follicle is provided with smooth muscle, which keeps the walls tensely contracted, even after rupture. When small haemorrhages occur, undoubtedly they are readily resorbed, and the corpus luteum then goes on to develop normally. When great enough to distend the follicle and compress the growing wall, inhibition of corpus luteum formation presumably occurs, and we have here one of the causes of corpus luteum cysts, which are very common in swine.

INVASION OF THE GRANULOSA

The next stage is represented by seven animals in my collection, all of which were killed during oestrus, as normal ova were found in the tubes. Moreover, four of them were observed during life, and were actually seen to be in the second or third day of oestrus. In three, copulation had not occurred; in three others, fertilization had taken place, the ova showing the pronuclei approaching conjugation; and in the seventh, the ova were segmented into two, four and six blastomeres.

The first sign of an advance upon the previous stage consists of the breaking-down of the membrana propria, at first at the apices of some of the folds, later over the entire follicle, so that the former sharp line of division between granulosa and theca interna is no longer present (fig. 14). Wherever the membrana propria is disappearing, slender spindle-cells are seen to be insinuating themselves between the still closely packed granu-

losa cells (fig. 14, *sp.c.*). The nature of the inwandering cells is difficult to decide. In places there can be no doubt that they are endothelial in nature and represent the first sprouts from

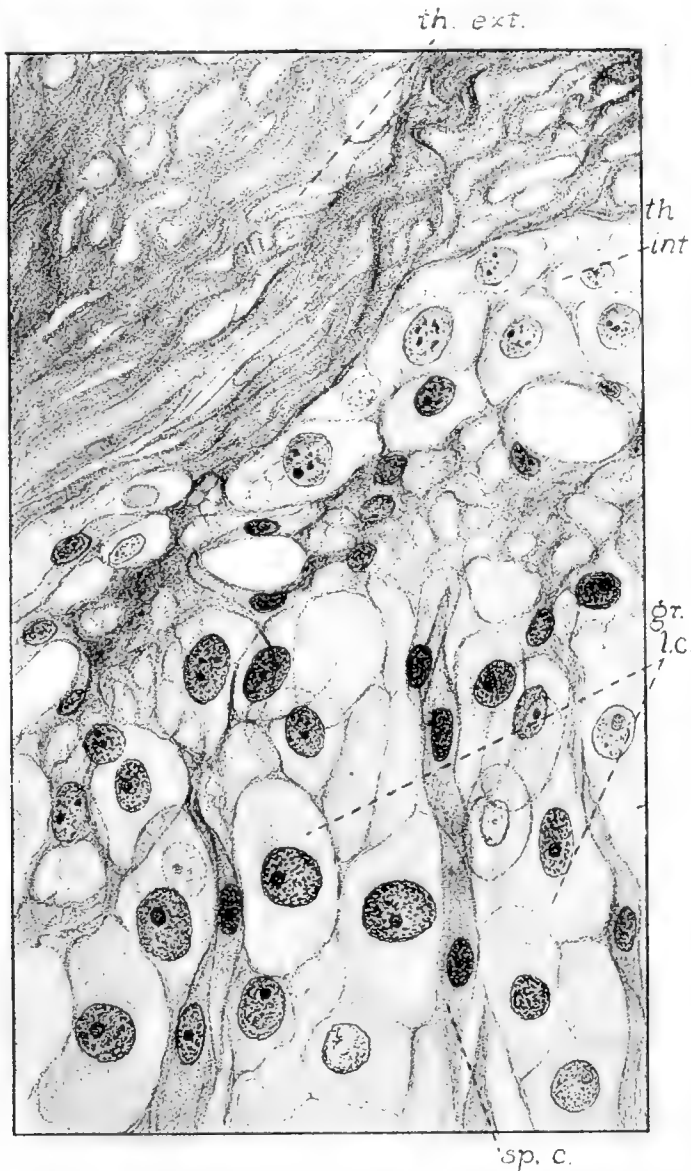


Fig. 14 Portion of wall of young corpus luteum (ova found in tubes), showing swollen cells of granulosa with inwandering spindle-shaped cells. Mallory's connective-tissue stain, formol fixation. $\times 810$. *gr.l.c.*, granulosa lutein cells; *th.int.*, theca interna; *th.ext.*, theca externa; *sp.c.*, spindle-shaped cells.

the walls of the thecal capillaries, growing inward to the granulosa. In the endothelial cells mitoses are not uncommon at this time. It seems quite likely that all the early invading cells are

of endothelial nature, but at some few points, however, it is impossible to convince oneself that the spindle-cells have any connection with the vessels, for they are not always arranged in tubular form and are sometimes well disseminated throughout the granulosa in advance of any circulation of blood. It cannot be denied absolutely, therefore, that some of them may be inwandering cells of the perivascular spindle-cell zone of the theca interna. During these early changes the large cells of the theca interna remain in their place, and I have never seen convincing evidence of their conversion into spindle cells.

Practically all of those observers who have been convinced of the persistence of the granulosa have described such an early invasion of the innermost layer by spindle-cells, a stage which was called by Robert Meyer the stage of proliferation, but as in the pig there is doubt as to the interpretation of the observed facts. Sobotta ('96) holds that all the cells of the theca interna are converted into spindle-cells (fibroblasts), and wander into the granulosa, dividing frequently, to form the connective-tissue framework of the corpus luteum. In this view he is supported by Marshall ('04) in his work on the sheep, and by O'Donoghue ('16), who studied the marsupial ovary; but several authors, including Völker ('05), Loeb ('06), and R. Meyer ('11), working, respectively, with the corpora lutea of the marmot, the guinea-pig, and man, are inclined to consider the first inwandering cells as endothelial, and deny the conversion of the theca interna cells into fibroblasts.

It has been mentioned that the breaking-down of the membrana propria and the invasion of the granulosa by spindle-cells does not take place at once over the entire inner surface of the collapsed follicle, but begins first at the apices of the folds, where the structure has presumably been subjected to the greatest mechanical strain. Because of this very important fact, we are able to observe a definite stage at which, while in places there is an actual intermingling of the two layers going on in part of the structure (fig. 15 *a*, *X*), in other parts the two inner layers of the wall maintain their original relations. During the same period there is a marked and rather sudden change in the granu-

losa cells (fig. 15 *b*). Their cytoplasm increases in volume so that the cells are now much larger in size, varying from $9.5 \times 11 \mu$ to $14 \times 21 \mu$ in diameter in sections, or half again as large in diameter as before rupture. The nuclei become rather more vesicular. Most important is the fact that many of the larger

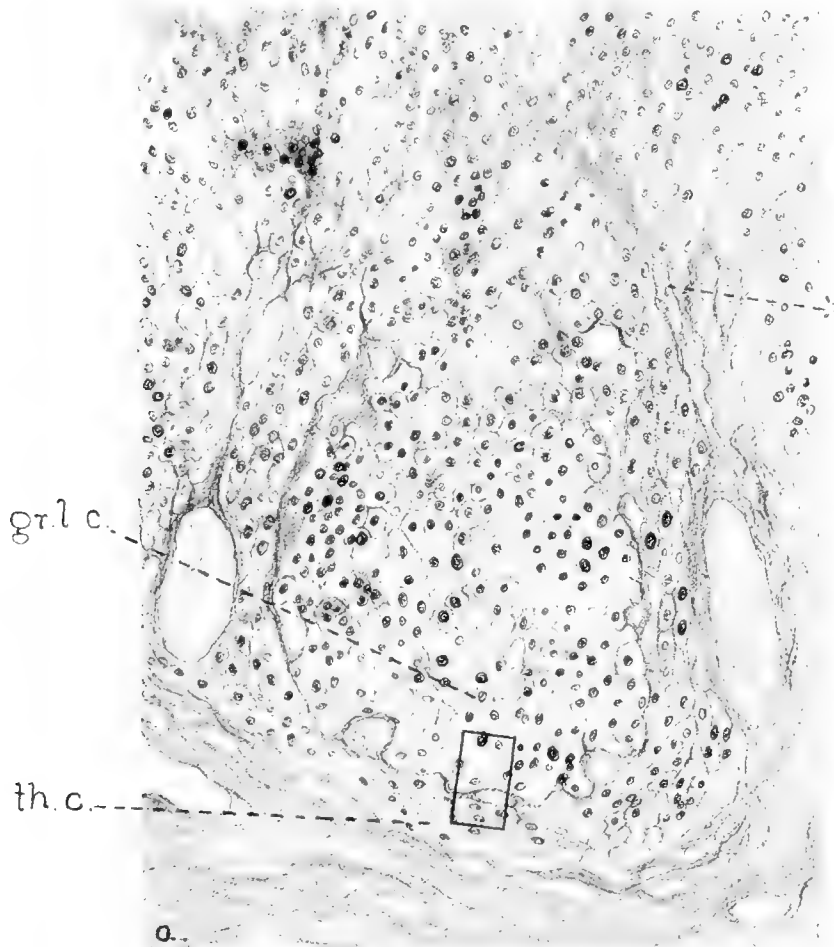


Fig. 15 *a*, Part of wall of developing corpus luteum in stage of spindle-cell invasion (ova in tubes). Formol fixation, Mallory's connective-tissue stain. $\times 110$. X, area of active invasion by spindle-cells (at apex of fold in wall).

cells now have in their cytoplasm large spaces containing rounded bodies resembling rings in section, which we have already seen (pp. 137, 139) to be characteristic of the so-called 'lutein cells' of the young corpus luteum in swine and to be due to the presence in the cytoplasm of an oily lipid substance.

Furthermore, these changes in the granulosa cells are found to occur in all parts of the wall, as well in those areas as yet uninvaded as in those where granulosa and spindle-cells are already intermingled. To sum up the evidence, there is a time in the development of the corpus luteum, about three days after the

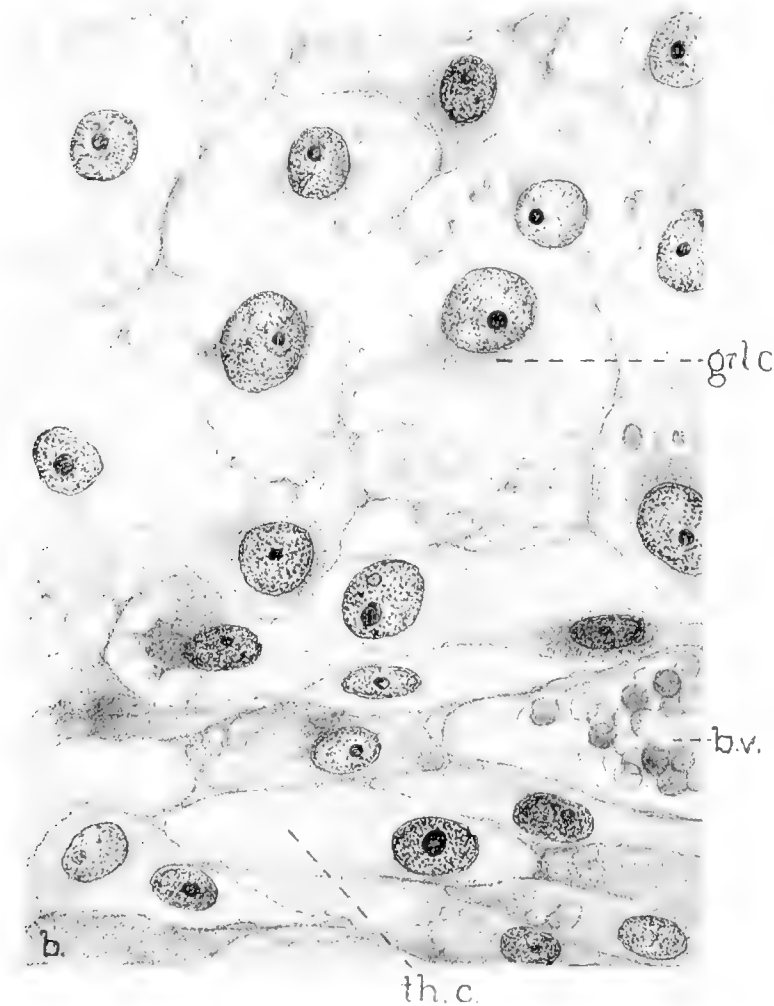


Fig. 15 *a*, Enlarged view of portion of same as shown by rectangle. $\times 1000$. *gr.l.c.*, granulosa lutein cells; *th.c.*, theca cells; *b.v.*, blood-vessel.

rupture of the follicle, when changes of structure within the organ are already under way, and when many of the cells have begun to acquire adult characteristics, but in some parts of the organ the original relations of granulosa and theca interna are

still intact; in these areas we find that it is the granulosa cells alone which have assumed the appearance of the large cells of the corpus luteum, commonly called lutein cells.

The breaking-down of the membrana is followed by a rapid sprouting and branching of the blood-capillaries throughout the entire granulosa (figs. 16 and 17). This stage is represented, in my material, by seven sows, of which one contained fertilized ova (some unsegmented and some with two blastomeres); one was killed about five days after the onset of heat, no ova being found, probably having degenerated; one was killed about six days after the onset of heat, one degenerate ovum being found; the other four were among those received from the University Farm School, in which the ova were not sought, but in which the dates of copulation were accurately known, in two on the third day and in two on the fifth day before killing.

Coincidentally with the spread of the blood-vessels in a network throughout the granulosa, there continues a marked swelling of the cells of this layer, which double or more than double in diameter, thus making an eightfold increase in volume; some of them reach dimensions of 30μ to 35μ . The nuclei are larger and more vesicular. I have never seen a mitotic figure in a cell of the granulosa at this or later stages, and feel sure that the generalization of Sobotta on this point is correct. In the formol- or Bouin-fixed specimens, the periphery of the cells is studded with the striking ringlike phosphatid artifacts of fixation (fig. 18, *gr.l.c.*). The rest of the cytoplasm is thin and contains irregular vacuolar spaces, due partly perhaps to the shrinking away, during fixation, of the cell-substances which form the ring bodies, and partly to the solution in the alcohols, xylol, or ether, of other lipoid substances, which osmic preparations show as small black globules in the center of each ring and also scattered about the nucleus or throughout the cytoplasm. I have not been able to apply other microchemical tests to the tissues at this stage, but the globules are morphologically like the neutral fat of later stages (fig. 3), and I assume that they are indeed the neutral fat or its forerunner.



Fig. 16 Young corpus luteum (segmenting ova with one and two blastomeres found in tubes); blood-vessels injected with India ink. Compare with figure 12. $\times 15$.

Meanwhile, changes have also been taking place in the large cells of the theca interna. Mitoses are more common, and the former definite internal limit of this layer has been blurred by the breaking-down of the membrana propria and the ingrowth of the capillaries at all points of the follicular wall. Within the

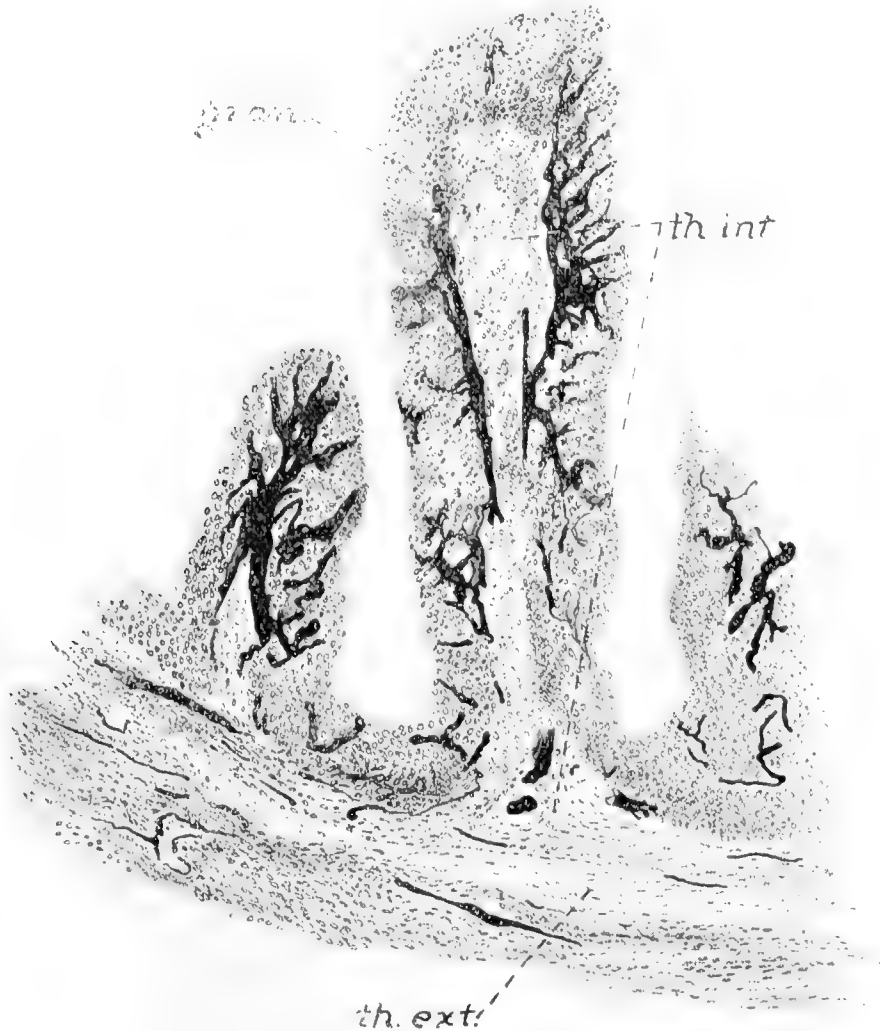


Fig. 17 Enlarged view of small part of figure 16 as indicated by rectangle, showing blood-vessels of theca interna branching throughout granulosa. $\times 45$.

cells there are changes in the lipid inclusions which are their chief distinguishing characteristic. In some cells of osmic preparations the granules are larger, in others smaller than before; in some they do not form an insoluble black compound with

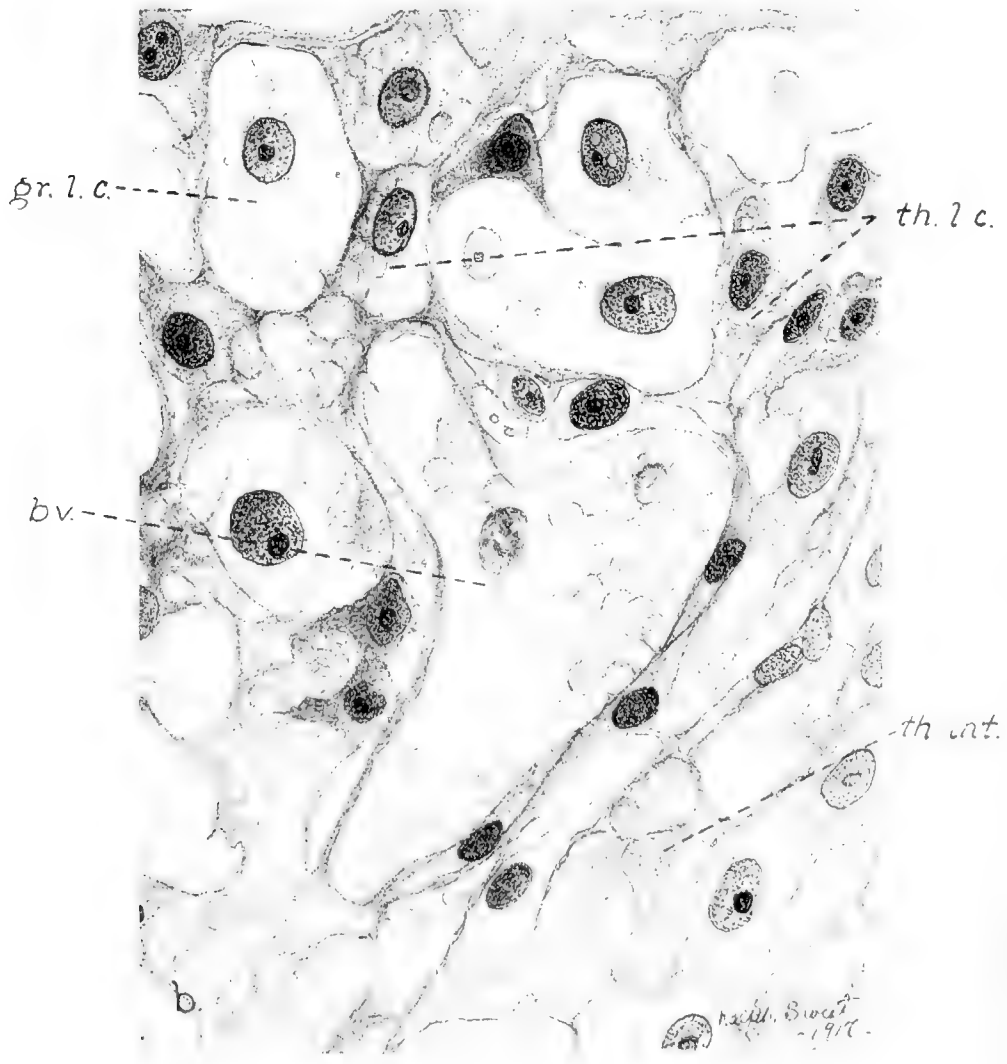
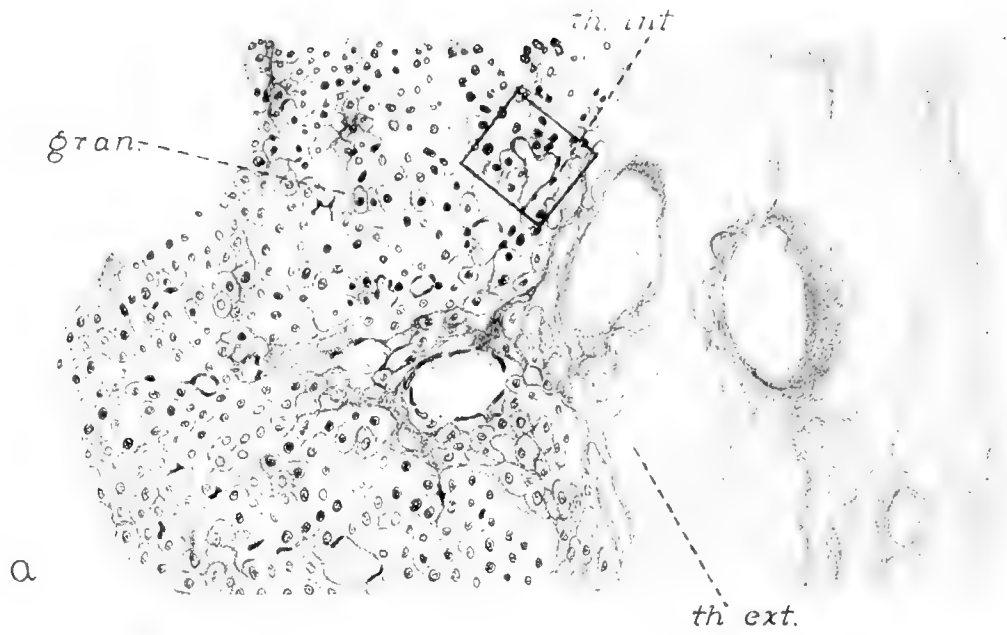

Fig. 18

mium tetroxide, but leave vacuoles of varying sizes, between which a few stained granules may remain giving a characteristic foamy appearance to the cytoplasm (fig. 19); and in others practically all the fatty bodies and vacuoles have disappeared, leaving a smooth homogeneous cytoplasm. In ordinary stained sections, then, the theca interna cells are of about the same size as before rupture, their nuclei are perhaps slightly more vesicular, and the cytoplasm is either homogeneous or contains many densely packed vacuoles, usually uniform in size within any one cell, resulting in the foamy appearance.

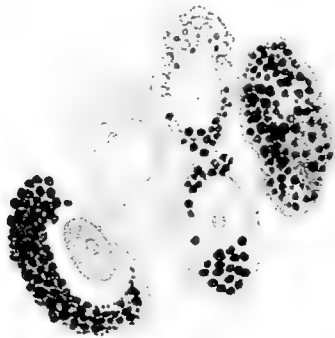


Fig. 19 Theca interna cells of corpus luteum in stage of invasion, osmium tetroxide fixation without further staining, showing varying degrees of fatty inclusion. $\times 1000$.

It will be obvious that the previous clean-cut distinction between the two layers is now lost. Heretofore we have been able to distinguish them by position, size, and content; there has been a wall of connective-tissue fibrils between the layers; the cells of the granulosa have been smaller than those of the theca interna; and the former have contained but small numbers.

Fig. 18 *a*, Part of wall of developing corpus luteum in stage of invasion (ova in tubes). Bouin fixation. Mallory's connective-tissue stain. $\times 110$. *b*, Enlarged view of portion of same as indicated by rectangle. Mallory's connective-tissue stain. $\times 1000$. *gr.l.c.*, granulosa lutein cells; *th.l.c.*, theca lutein cells; *th.int.*, portion of original theca interna, near a fold in wall of corpus luteum; *b.v.*, blood-vessel.

of lipid granules, the latter considerable amounts. But now the *membrana propria* is done away with, the *granulosa* cells have increased in size and are becoming rich in lipoids, while the *theca interna* cells are losing their lipoids. It is not strange that investigators have become involved in uncertainty regarding the further fate of the *theca* cells. I have seen the abrupt ending, at stages similar to those now being described, of two careful attempts, by students in our histological courses, to follow the *theca* cells of the mouse and rat by means of their osmium-staining inclusions, owing to failure to observe further distinctions between the two cell types. In the pig, however, we possess a peculiar advantage in the tendency of the phosphatid material to form the previously mentioned cytoplasmic rings when fixed with slow aqueous fixatives, giving the *granulosa* cells a distinctive appearance. There are other less regularly present criteria, which when added together afford the practiced observer means of partially distinguishing the two cell types; these are a tendency of the cytoplasm of the *theca* cells to take acid stains somewhat more deeply than the *granulosa* cells (perhaps this indicates merely a denser cytoplasm) and also the regularity in size and closely packed disposition of the lipid granules or the vacuoles left when they disappear or are dissolved.

Following these clues, we find that many of the *theca interna* cells remain in their original location about the periphery of the follicle, running into the interior of the folds produced by the collapse; but also that many of them, as the blood-vessels grow inward, are carried or wander with the vessels, and become disseminated among the cells of the *membrana granulosa*, where they are finally lodged, either singly or in small groups, frequently along the capillaries (fig. 18). It must be remembered that a general scattering of the *theca* cells among the *granulosa* in this way will not require a longer journey for any single cell than the thickness of the inner layer, which is not more than 0.2 mm. The cells thus immigrating resemble in every way their mates left behind at the periphery and in the folds, some of them containing large granules, staining black with osmium tetroxide, others showing almost no fatty inclusions (fig. 19).

They are often broadly spindle-shaped or irregular in form, sometimes compressed between the granulosa cells or applied demilune-fashion to one of them.

Further changes are brought about by the great swelling of the granulosa cells, which proceeds so far that the contents of the follicle begin to equal and finally to exceed the capacity of the contracted theca externa. The first effect of the internal pressure is to fill whatever remains of the original follicular cavity solidly with new tissue, then to compress the thecal cores of the folds of the walls so that all fibrin-containing cavities and

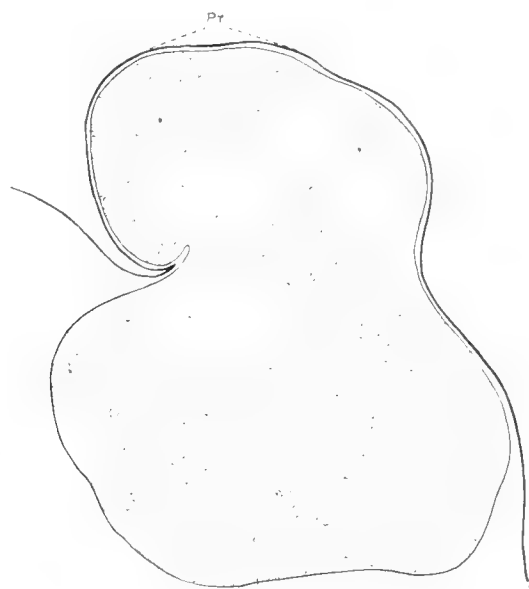

Fig. 20 Diagram showing outline of section of a corpus luteum about four days after ovulation. $\times 5$. *pr.*, 'Ppropf' or hernia-like bulging of contents through point of rupture.

oedematous spaces are obliterated, and the folds become merely connective-tissue septa containing the remains of the theca interna in the shape of a diminished number of theca cells enmeshed by reticular fibrils; in the bases of the folds the blood-vessels of the young corpus luteum enter, usually accompanied by fibroblasts and fibrils proceeding from the theca externa. In many young corpora lutea the swelling of the granulosa cells finally causes a bulging of the contents through the outer pole of the wall, at the point previously weakened by the rupture; which in the prolific ovaries of the sow may be exaggerated by

the pressure of the many neighboring corpora lutea of the same crop, until there is produced a knoblike hernia of corpus luteum tissue sometimes containing a tenth or more of the whole corpus luteum (fig. 20). This appearance is sometimes called by the handy German name 'Pfropf.' In some species, as, for instance the cow, it seems to occur invariably and to persist throughout pregnancy, but in swine the hernia is not always produced, the whole wall of the corpus distending evenly instead; and later it seems to subside, as in most corpora lutea in more advanced pregnancy there are no 'Pfropfen.'

THE FULLY FORMED CORPUS LUTEUM AND ITS MORPHOLOGICAL CHANGES UNTIL THE TERMINATION OF PREGNANCY

Invasion of the granulosa by the thecal vessels and cells begins about the third day after the onset of oestrus (or about the second or third day after rupture of the follicle) and is completed about the sixth or seventh day. My series contains five sows killed during the second week after ovulation and a large number from all stages of pregnancy from fifteen days after ovulation on to full term and into the period of lactation, so that altogether there is an unbroken series representing almost every day of the entire reproductive cycle.

By the seventh day the corpus luteum may be considered to have completed the first stage of its metamorphosis. It is solid (unless there has been a decided haemorrhage into the cavity), and it is already larger than the follicle in which it arose, reaching diameters of 8 and 9 mm., although a slow increase in size is yet to go on until the second or third week, by which time the full diameter, 10 to 11 mm., is reached. The blood-vessels have grown into a very narrow-meshed plexus, reaching every cell. The remains of the former great folds of the walls are seen as thin septa of connective-tissue fibrils running radially into the corpus luteum, carrying the larger blood-vessels of the organ. In some specimens, just inside the theca externa capsule and along the septa is a layer of theca interna cells or sometimes a few scattered clumps of them which have not chanced to invade the granulosa. These clumps may be found as late as the

second month of pregnancy or may disappear long before (fig. 21). In appearance the cells of these clumps resemble the theca cells of the stage of invasion. In osmium-tetroxide preparations,

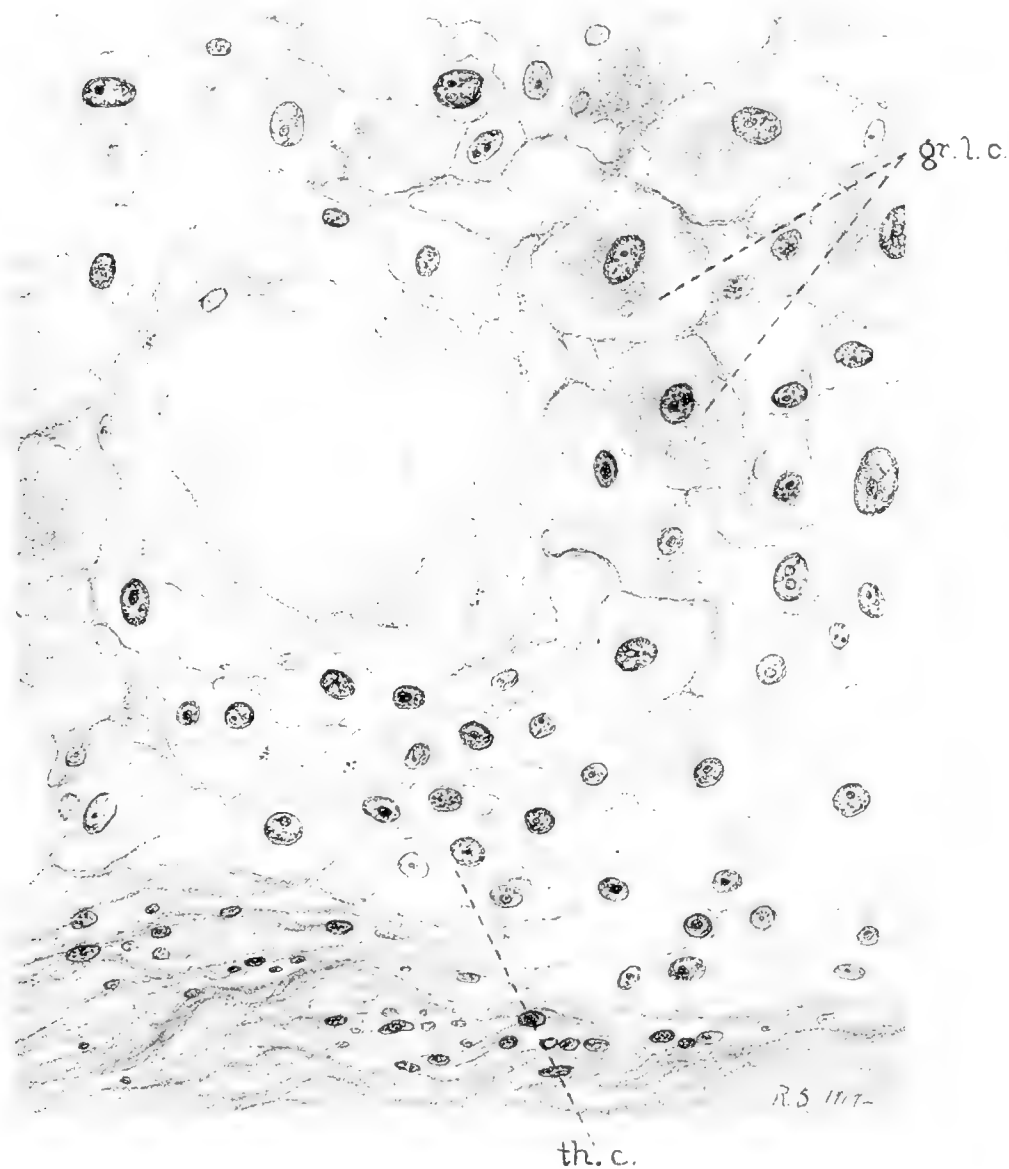


Fig. 21 Portion of corpus luteum from second month of pregnancy (foetuses 35 mm. long), showing a clump of theca interna cells still in their original position. Formol fixation. Mallory's connective-tissue stain. $\times 450$.

some retain many lipid globules, others have lost all of their fatty inclusions; but many present the previously noted foamy appearance of the cytoplasm, due to the presence of many

small evenly packed vacuoles with a few tiny black granules interspersed.

In the substance of the corpus luteum are now found two types of cells whose differing characteristics become well marked after the beginning of the third week. One type is that whose identity with the granulosa is fully demonstrated by the presence of the peculiar lipoid spherules about the periphery of the cytoplasm (figs. 2 and 21). From now on these cells grow slowly in size, until just before delivery some of them have attained the

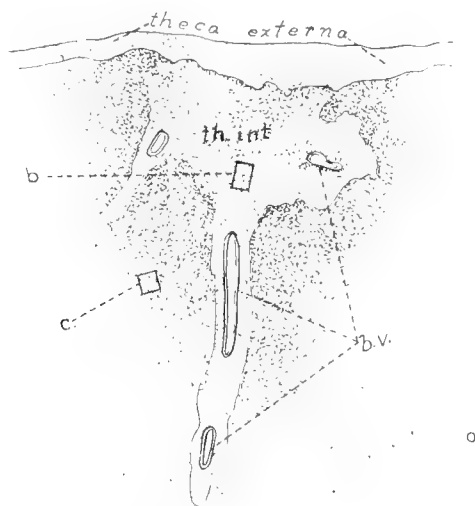


Fig. 22, a

immense size of $30 \times 45\mu$. During the first few weeks the neutral fat increases until it greatly exceeds the small amount found in the cells of the granulosa before rupture, and then grows progressively less, finally almost disappearing by the 110th day of pregnancy. The phosphatid substance which produces the artifacts of fixation, so frequently referred to, disappears also, and therefore during the last third of pregnancy the cells, in ordinary formol preparations, possess a homogeneous cytoplasm, strikingly different from the greatly vacuolated cell substance of the earlier stages (fig. 23). Just before delivery, however, great globules of an osmium-staining material, presumably a fat, appear about the periphery of some of the cells.

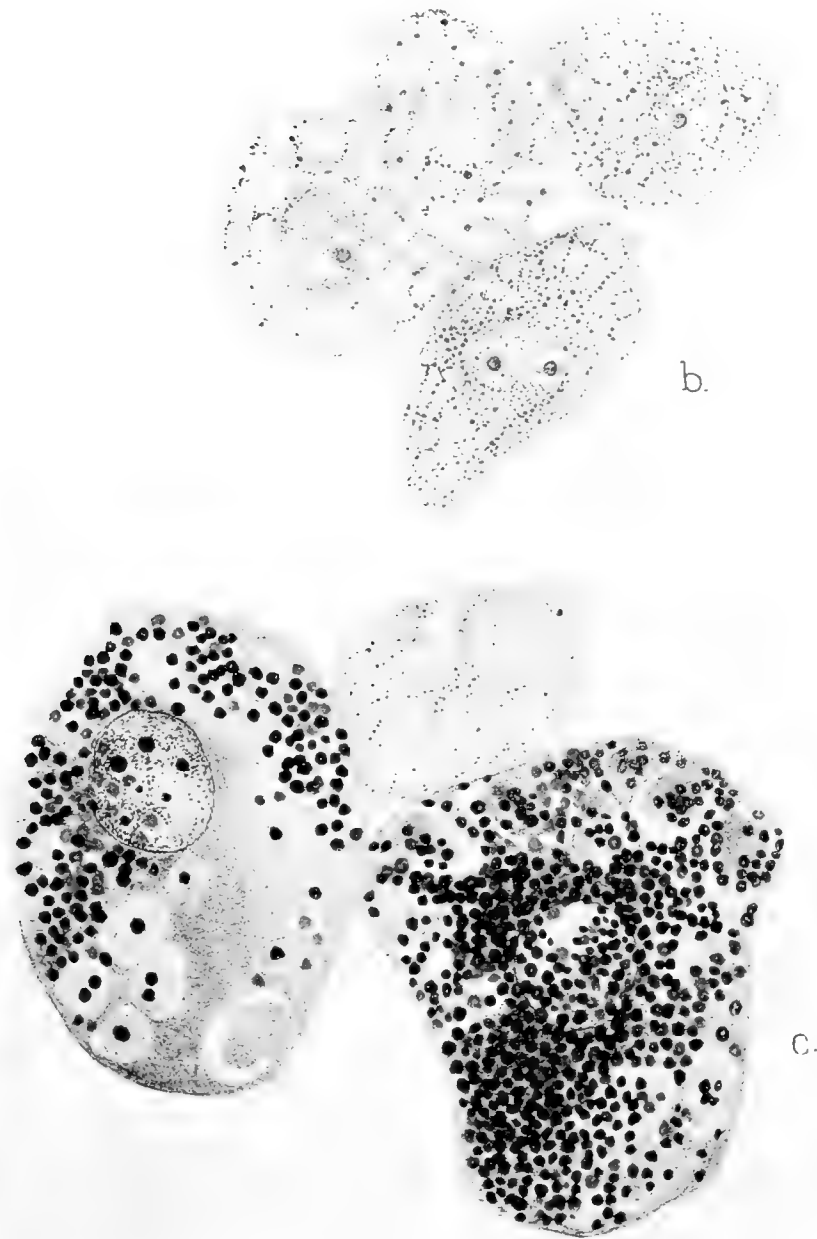
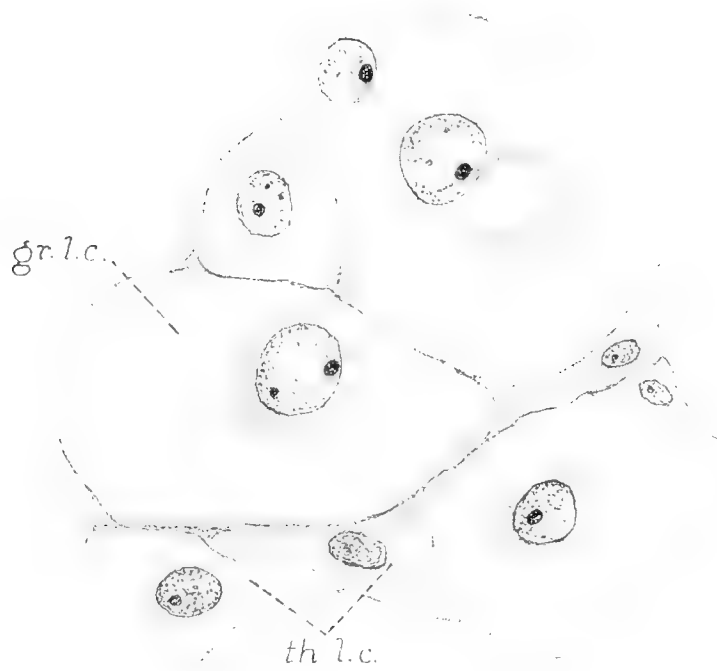


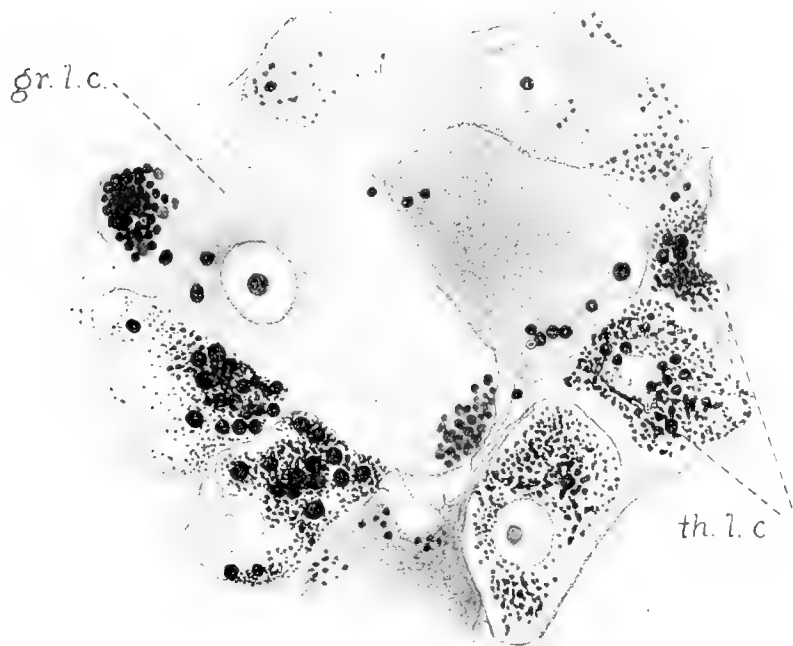
Fig. 22 Cells of corpus luteum of pregnancy eighteen to twenty days old (embryos of twenty-seven somites). Osmium tetroxide after formol fixation. *a*, Diagram of a small portion of the periphery, showing a clump of theca cells still present at the periphery at the site of a fold in the follicular wall, and indicating by small rectangles the location of the cell groups in *b* and *c*. *b*, Cells from persisting theca interna. $\times 1000$. *c*, Cells from interior of corpus luteum, showing two granulosa lutein cells and a third cell exactly resembling those of the theca. $\times 1000$.

The cells of the other type are those described in my contribution of 1915 as "additional cells of the corpus luteum, type 1." They are found throughout the corpus scattered between the larger cells or in small clumps along blood-vessels and connective-tissue septa. They are smaller than the granulosa lutein cells, having diameters of 15μ to 20μ . In form they are adapted to their interstitial position, being rounded, almost rectangular, or at times compressed into polyangular shape (figs. 23 and 24). Their cytoplasm is either finely granular or contains regular vacuoles so closely packed as to give a foamy appearance. Indeed, in form, size, and in intracellular characteristics they present a most striking resemblance to those cells of the theca interna which in the same preparations are still belatedly situated at the periphery of the corpus luteum (fig. 22). Especially in osmium preparations is the similarity so great that one is forced to the hypothesis that we have scattered throughout the organ, among the granulosa lutein cells, the multiplied and immigrated cells of the theca interna. In the light of the apparent origin of these cells, it would seem well to give them the name, already established in the literature, 'theca lutein cells,' for though there are certain just reasons for criticism of this term and the name 'granulosa lutein cells' as applied to the other great class of corpus luteum elements, there would seem to be no better names at hand.

While the cells derived from the granulosa lose their lipoids after the first few weeks, the smaller cells just described again gradually increase their content of osmium-staining lipoids during the span of gestation, and some of them come at last to be laden with these bodies, which, however, do not altogether resemble the lipid granules of their earlier days (fig. 24). At the end of pregnancy the cells of this type are still present among those derived from the granulosa, apparently having maintained separate identity during the entire term of gestation. Even those which remain for a while in clumps or a definite layer about the periphery are not found to degenerate, but seem to be drawn in among the neighboring granulosa cells as the corpus grows older.



23



24

Fig. 23 Cells of corpus luteum of advanced pregnancy (foetuses 230 mm. long). Formol fixation. Mallory's connective-tissue stain. $\times 810$. *gr.l.c.*, granulosa lutein cells; *th.l.c.*, theca lutein cells.

Fig. 24 Same stage as in figure 22, osmium tetroxide fixation without further staining, showing distribution of fatty inclusions in cells. $\times 810$. *gr.l.c.*, granulosa lutein cells; *th.l.c.*, theca lutein cells.

However, when an attempt is made to classify all the elements of the fully formed corpus luteum, the picture is complicated by the fact that numerous cells are found which are intermediate in size between the two classes described above, and whose cytoplasmic vacuoles and fatty inclusions are of nature too indifferent to place them definitely with either granulosa or theca derivatives. The evidence, therefore, is not yet conclusive as to the exact fate of all the theca lutein cells. Either the intermediate forms represent genuine transitional stages in the formation of 'lutein cells' from theca interna cells or else they are merely cells, actually of one line or the other, in which the all too slight distinguishing features of the type (size, form, lipid inclusions and vacuoles) have not been obvious. Toward the latter view—the intermingling of the two cell lines without actual conversion of one into the other—the author is inclined to lean, without more positive evidence than has already been given.

As a digression, it may be mentioned that some few of the theca lutein cells retain the primitive characteristics of the theca interna, even exaggerating them at times; they are variable in shape and size, they have a cytoplasm which stains deeply with acid stains, becoming dark blue, brown, or even orange with Mallory's triple stain and very dark with iron haematoxylin; the cytoplasm is usually somewhat shrunken, and contains clear vacuoles about 1μ to 2μ in diameter, which are quite uniform in size, are closely packed, and which either stain intensely black with osmium tetroxide or remain as vacuoles. The nuclei are often very dense, even pyknotic, and sometimes stain bright orange with Mallory's stain. The cells are often spindle-shaped, branched, or compressed in such a way that they give the appearance of amoeboid motion, as if they were active wandering cells. These are the cells described in my paper of 1915 as "additional cells of the corpus luteum, type 2" (fig. 2). Although their origin is now explained, I have no more light upon their nature or possible function than before. They appear to be more common in the earlier half of pregnancy, but their number varies greatly from animal to animal.

The cells of the young fully formed corpus luteum are supported by a reticulum of delicate connective-tissue fibrils with denser strands along the septa. In sections stained by Mallory's anilin-blue mixture and by the Bielschowsky technique as modi-

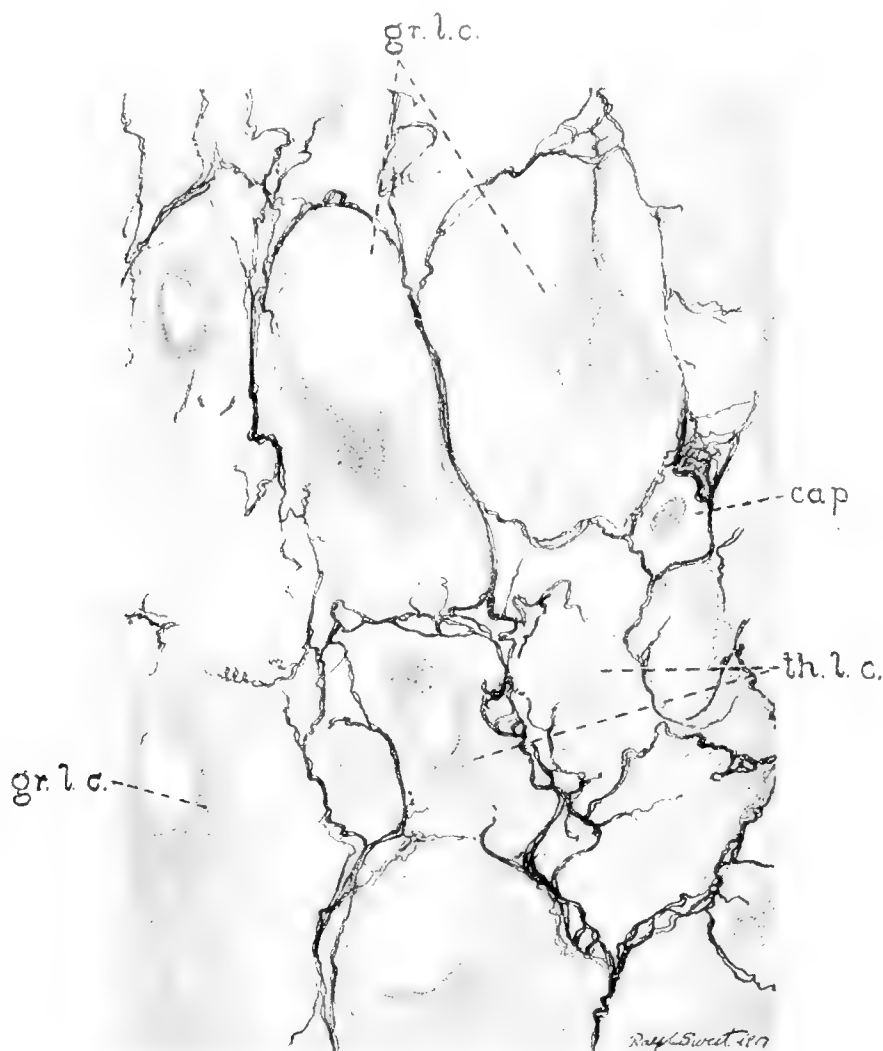


Fig. 25 Corpus luteum of pregnancy (embryos 20 mm. long). Formol fixation. Bielschowsky's silver-impregnation method, showing reticular fibrils. $\times 1000$. *gr.l.c.*, granulosa lutein cells; *th.l.c.*, theca lutein cells; *cap.*, capillary blood-vessel containing an erythrocyte.

fied by Ferguson ('11), it is clear that neither the granulosa nor the theca lutein cells are intimately related to the fibrils, which form dense baskets about them, but are not found within the cytoplasm of the 'lutein cells' of either type (fig. 25). In

other words, the activities of the theca interna cells have become so far modified in the process of their differentiation from the primitive mesoblast of the ovarian stroma that they no longer exercise the function of fibril formation. What new activities they may have assumed, whether they may not now share in producing the hypothetical internal secretions of the corpus luteum, are questions for speculation and further research.

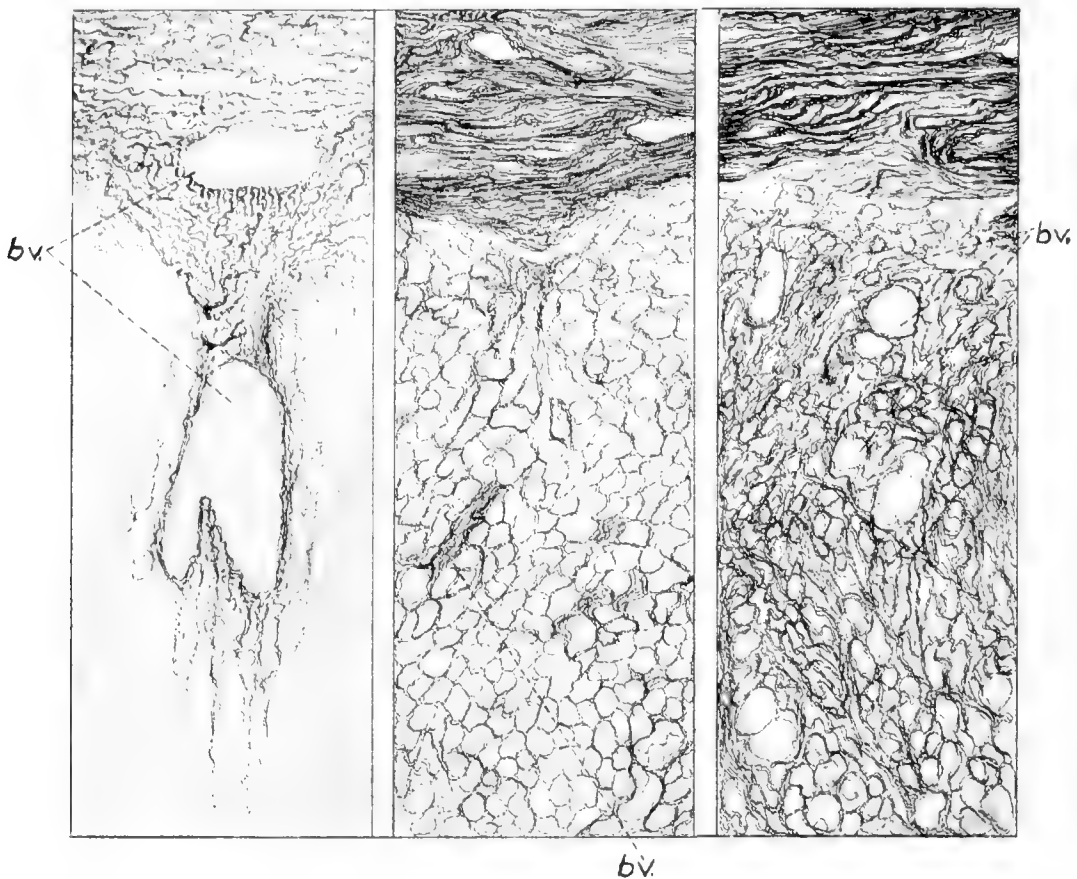


Fig. 26 Diagrams of small portions of walls of corpora lutea at different ages, showing increasing density of connective tissue. Dianol red X after Bouin's fluid. $\times 80$. 1, young corpus luteum (ova in tubes); 2, fetuses 115 mm. long; 3, seven days after birth of young.

Having found that the theca lutein cells are not the fibril-producing elements, one is further surprised to find that the corpus luteum of the sow contains very few fibroblasts of the conventional type. It is impossible to convince oneself that there are in the organ any cells other than the two types of lutein cells

beside the endothelial cells of the capillary wall, except here and there along the greater vessels which run in from the periphery. Since there are multitudinous fibrils, and no 'fibroblasts' to produce them, one is forced to suspect that, as in the liver, the endothelial cells themselves lay down the reticular fibrils. This evidence by elimination would appear to be supported by observation of the actual fact, but the question needs fuller investigation.³

Whatever be their source, the amount and density of the reticular fibrils of the corpus luteum increases steadily from the nativity of the organ until retrogression, when the organ is entirely replaced by scar tissue (fig. 26). It is along the large septa that the fibers first become dense, perhaps because a few connective-tissue cells of the theca externa are often drawn into the folds produced by the collapse following follicular rupture.

RETROGRESSION OF THE CORPUS LUTEUM

Owing to conditions of the meat-packing trade, it is difficult to obtain ovaries of sows within a few days after parturition. Study of the two specimens from the seventh and tenth days after littering shows that regression of the corpus luteum is as rapid as its appearance. By the seventh day the structure, which was a flesh-colored body 10 or 11 mm. in diameter before parturition, is only half this size; it has already shrunken until it is almost buried in the ovarian stroma, and it has acquired a yellow-brown color. By the time another ovulation occurs, the former corpora lutea are dense scar-like nodules of connective tissue rendered a pale yellowish brown by the presence of pigment in the shrunken cells caught in the meshes of the scar. The microscopic changes during this process are obscure to me for lack of material, and

³ The results of a study of the question made since the completion of this paper have proved that our hypothesis was correct, and that in the corpus luteum and a number of other organs part or all of the reticular framework is laid down by the cells of the capillary endothelium. (See a contribution by the author to the forthcoming volume in memory of Dr. F. P. Mall in the Publications of the Carnegie Institute of Washington, no. 272.)

therefore until a series including every day of the first week after parturition can be obtained, the ultimate fate of the theca interna cells of the sow must remain unknown.

DISCUSSION

It is hardly necessary to point out that the evidence just given completely negates the results of previous investigators in this species, and that it therefore removes one of the main supports of the theca-origin theory. But since this view has been held by so many anatomists, the reader will ask more than mere denial; stating their errors, we must also explain them. The reply, already pointed out by Sobotta, has become emphasized to the present writer during the course of his own studies. It would be a simple matter to select from this material a number of specimens which would duplicate the figures of Clark, Janowski, or Doering, but placed in proper position in the series, the same specimens lead to far different interpretations. The small, pale, and inconspicuous nature of the corpora lutea at their earliest stages has allowed them to escape the notice of investigators seeking, under preconceived notions, for brightly haemorrhagic structures in the ovaries, and thus the all-important stages of the first four or five days have not been at hand to explain the more difficult later conditions of development. Insufficient data, leading to confusion with the process of atresia and to failure to obtain the earlier stages, and insufficient numbers of specimens, leaving important gaps to be filled by the imagination, are the two great sources of error in the study of this difficult problem.

In the investigation of the human ovary the obstacles to the acquisition of attested material are still greater than in the mammals subject to experimental methods. With our obscure knowledge of the reproductive cycle, the only guide to the age of a corpus luteum is its appearance, and we have seen what a useless aid this can be. Even the presence of a healing point of rupture, which is so characteristic of early corpora lutea in other animals, is not entirely trustworthy in human ovaries.

The specimens have nearly all been obtained at operation upon gynecological patients, who before operation are usually subjected to palpatory examinations, often none too gentle. Any gynecologist will know that the rupture of a 'small ovarian cyst' by the examiner's hands is a not infrequent occurrence; such cysts, were they actually large follicles, immature or in early atresia, if removed a day or two after the artificial rupture, might present the anatomist with all too convincing specimens of 'early corpora lutea.' Other possibilities of error might be suggested, none of which can be ruled out until the ova are studied with the specimen. While awaiting that almost impossible outcome, we shall be wise to follow those workers with the human corpus luteum whose findings are most nearly confirmed by the evidence of comparative anatomy.

The interpretation of the origin and morphology of the corpus luteum given in these pages does not represent a wide divergence from previous views. Nearly all observers now agree in describing the persistence of the membrana granulosa and its invasion by elements arising in the theca interna. The present work, so far as it traces the fate of the theca cells, is in accord with the best of recent investigations, and the author's hypothesis of the persistence of all the theca cells as distinct elements would, if finally proved, explain the remaining difficulties.

It is not so easy to align the findings in the sow's corpus luteum with the conceptions of Sobotta and his followers, who believe that the theca interna cells revert to mesoblastic type and by division give rise to a strain of fibroblasts which lay down the connective-tissue frame of the corpus luteum. This view implies a notion of the structure of the adult corpus which differs from that found in swine, and will necessitate a new study of the cell types and the relation of the reticular fibrils to fixed cells in corpora lutea of animals such as the mouse and sheep before the discrepancy can be understood.

In conclusion, it is a pleasure to express my thanks to Professor Evans for his encouragement and generous provision of aid and materials for this work.

CONCLUSIONS

1. In swine the membrana granulosa is retained intact after the rupture of the Graafian follicle. Its cells increase in size without division, their cytoplasm becomes laden with lipid substances, and they become the larger elements commonly called 'lutein cells' in the fully formed corpus luteum.

2. The membrana granulosa is invaded by blood-capillaries from the theca interna, which ramify to form an extensive vascular plexus throughout the new structure.

3. The large lipid-laden cells of the theca interna are increased in number by mitotic division, lose many or all of their fatty inclusions, and pass into the corpus luteum to become lodged between the granulosa cells throughout the whole structure.

4. There is no evidence that cells of the theca interna are ever converted into fibroblasts of the usual spindle-cell type or that they lay down the fibrils of the close-meshed reticulum which is present in the corpus luteum.

5. There appears to be good evidence that some of the theca interna cells persist throughout pregnancy as distinct elements of the corpus luteum, but the exact fate of all of them cannot be learned by present methods because of a confusing resemblance between some of the theca and some of the granulosa derivatives.

BIBLIOGRAPHY

- ASSHETON, R. 1899 The development of the pig during the first ten days. Quarterly Journal of Microscopical Science, vol. 41, p. 329.
- VON BAER, K. E. 1827 De ovi mammalium et hominis genesi. Leipzig. Quoted by Bischoff ('42).
- BARRY, M. 1839 Researches in embryology. Philosophical Transactions of the Royal Society of London, 1839, pt. 2, p. 307.
- BENCKISER, A. 1884 Zur Entwicklungsgeschichte des Corpus luteum. Arch. f. Gyn., Bd. 23, S. 350.
- BISCHOFF, TH. L. W. 1842 Entwicklungsgeschichte des Kaninchen-Eies. Braunschweig.
1878 Über die Zeichen der Reife der Säugethiereier. Arch. f. Anat. u. Entwicklungsgeschichte, 1878, S. 43.
- BONNET, R. 1891 Grundriss der Entwicklungsgeschichte der Haussäugethiere Berlin. Quoted by Sobotta ('96).
- BÜHLER A. 1900 Entwicklungsstadien menschlicher Corpora lutea. Verh. d. Anat. Gesellschaft, XIV. Versammlung, Anatomischer Anzeiger, Bd. 18, S. 150.

- CLARK, J. G. 1898 Ursprung, Wachstum, und Ende des Corpus luteum. Arch. f. Anat. u. Entwicklungsgeschichte, 1898, S. 95.
- COHN, F. 1903 Zur Histologie und Histogenese des Corpus luteum und des interstitiellen Ovarialgewebes. Arch. f. Mikr. Anat., Bd. 62, S. 745.
1909 Über das Corpus luteum und den atretischen Follikel des Menschen und deren cystischen Derivate. Arch. f. Gyn., Bd. 87, S. 367.
- CORNER, G. W. 1915 The corpus luteum of pregnancy, as it is in swine. Publication no. 222 (Contributions to Embryology no. 5), of the Carnegie Institution of Washington, p. 69.
1917 a On the lipoidal nature of structures in the corpus luteum cells of swine. Proceedings of the American Association of Anatomists, Anat. Rec., vol. 11, p. 345.
1917 b Variation in the amount of phosphatides in the corpus luteum of the sow during pregnancy. Journal of Biological Chemistry, vol. 29, p. 141.
1917 c Maturation of the ovum in swine. Anat. Rec., vol. 13, p. 109.
- CORNER, G. W., AND AMSBAUGH, A. E. 1917 Oestrus and ovulation in swine. Anat. Rec., vol. 12, p. 287.
- CRISTALLI, G. 1903 Contributo alla istogenesi del corpo luteo della donna. Arch. d. Ost. e Gin., T. 10, p. 480.
- DELESTRE, M. 1910 Recherches sur le follicule de de Graaf et le corps jaune de la vache. Jour. de l'Anat. et de Physiol., T. 46, p. 286.
- DÖRING, H. 1899 Beitrag zur Streitfrage über die Bildung des Corpus luteum. Königsberg, dissertation.
- FERGUSON, J. S. 1911 The application of the silver impregnation method of Bielschowsky to reticular and other connective tissues. Am. Jour. Anat., vol. 12, p. 277.
- FLEMMING, W. 1885 Über die Bildung von Richtungsfiguren in Säugethiereiern beim Untergang Graaf'scher Follikel. Arch. f. Anat. u. Entwickl., 1885, S. 221.
- HEGAR, K. 1910 Studien zur Histogenese des Corpus luteum und seiner Rückbildungsproducte. Arch. f. Gyn., Bd. 91, S. 530.
- HIS, W. 1865 Beobachtungen über den Bau des Säugethier-Eierstockes. Arch. f. Mikr. Anat., Bd. 1, S. 151.
- HONORÉ, CH. 1900 Sur la formation du corps jaune. Archives de Biologie, T. 16, p. 563.
- JANKOWSKI, T. 1904 Beitrag zur Entstehung des Corpus luteum der Säugethiere. Arch. f. Mikr. Anat., Bd. 64, S. 361.
- KAEPPELI, I. 1908 Beiträge zur Anatomie und Physiologie der Ovarien von wildlebenden Wiederkäuern und Schweinen. Bern, dissertation.
- KEIBEL, F. 1897 Normentafeln zur Entwicklungsgeschichte des Schweines. Jena.
- KOPSCH, F. 1901 Corpora lutea von Schwein und zwar vom 3, 6, und 10 Tage nach der Befruchtung. (Präparate des Herrn Stabsarzt Dr. Menzer.) Demonstration. Verhandlungen Anat. Gesellsch., XV. Versammlung, Bonn. Anatomischer Anzeiger, Bd. 19, S. 210.
- KREIS, L. 1899 Die Entwicklung und Rückbildung des Corpus luteum spurium beim Menschen. Arch. f. Gyn., Bd. 58, S. 411.

- LOEB, L. 1906 The formation of the corpus luteum in the guinea-pig. *Journal of the American Medical Association*, vol. 46, p. 416.
- MARSHALL, F. H. A. 1904 The oestrous cycle and the formation of the corpus luteum in the sheep. *Phil. Trans. Roy. Soc.*, vol. 196 B, p. 47.
- MEYER, R. 1911 a Über Corpus luteum-Bildung beim Menschen. *Arch. f. Gyn.*, Bd. 93, S. 354.
1911 b Zur Corpus luteum-Bildung beim Menschen. *Zentralbl. f. Gyn.*, Bd. 35, S. 1206.
- MILLER, J. W. 1911 Über Corpus-luteum-Bildung beim Menschen. Kritische Bemerkungen zur der im Archiv für Gynaekologie, Bd. 93, Hft. 2 erschienenen Arbeit Prof. Dr. Meyer's. *Zentralbl. f. Gyn.*, Bd. 35, S. 1089.
- NISKOUBINA, N. 1909 Recherches sur la morphologie et la fonction du corps jaune de la grossesse. Nancy, thesis.
- NOVAK, E. 1916 The corpus luteum:—Its life cycle and its rôle in the menstrual disorders. *Journal of the American Medical Association*, vol. 67, p. 1285.
- O'DONOGHUE, C. 1912 The corpus luteum in the non-pregnant *Dasyurus* and polyovular follicles in *Dasyurus*. *Anat. Anz.*, Bd. 41, S. 353.
1914 Über die Corpora lutea bei einigen Beuteltieren. *Arch. f. Mikr. Anat.*, Bd. 84, Abt. 2, S. 1.
1916 On the corpora lutea and interstitial tissue in the marsupialia. *Quarterly Journal of Microscopical Science*, vol. 61, p. 433.
- PALADINO, G. 1879 Studio sulla fisiologia dell'ovaja. Struttura, genesi, e significazione del corpo luteo. Napoli.
1880 Della emorragia e del comportarsi della granulosa allo scoppio dei follicoli di Graaf. Napoli.
1881 Conseguenze dello scoppio dei follicoli di Graaf ed in particolare del corpo luteo della donna. Napoli.
1887 Ulteriori ricerche sulla distruzione e rinnovamento continuo del parenchima ovarico nei mammiferi. Napoli.
1900 Per la dibattuta questione sulla essenza del corpo luteo. *Anat. Anzeiger*, Bd. 17, S. 451.
1905 La mitose dans le corps jaune et les récentes conjectures sur la signification de cette formation. *Arch. Ital. de Biol.*, T 43, p. 292.
- PFLÜGER, E. 1863 Über die Eierstöcke der Säuger und des Menschen. Leipzig. Quoted by Sobotta ('96).
- POTTET, M. 1910 Contribution à l'étude anatomique, histologique et physiologique du corps jaune pendant la grossesse (Plus spécialement chez la femme). Thesis, Paris.
- RABL, H. 1898 Beitrag zur Histologie des Eierstocks des Menschen und der Säugethiere, nebst Bemerkungen über die Bildung von Hyalin und Pigment. *Anatomische Hefte*, Bd. 11, S. 109.
- RICKER, G., AND DAHLMANN, A. 1912 Beiträge zur Physiologie des Weibes. *Volkman's Sammlung klinischer Vorträge*. Neue Folge, no. 645/647.
- SANDES, F. P. 1903 The corpus luteum of *Dasyurus viverrinus*, with observations on the growth and atrophy of the Graafian follicle. *Proceedings of the Linnean Society of New South Wales*, vol. 28. Quoted by O'Donoghue ('16).

- SCHROEDER, R. 1914 Über die zeitlichen Beziehungen der Ovulation und Menstruation. Arch. f. Gyn., Bd. 101, S. 1.
- SOBOTTA, J. 1895 Über die Bildung des Corpus luteum bei der Maus. Anatomischer Anzeiger, Bd. 10, S. 482.
- 1896 Über die Bildung des Corpus luteum bei der Maus. Arch. f. Mikr. Anat., Bd. 47, S. 261.
- 1897 Über die Bildung des Corpus luteum beim Kaninchen. Anat. Hefte, Bd. 8, S. 469.
- 1899 a Über die Entstehung des Corpus luteum der Säugetiere. Referat, Ergeb. d. Anat. u. Entwickl., Bd. 8, S. 923.
- 1899 b Noch einmal zur Frage der Bildung des Corpus luteum. Arch. f. Mikr. Anat., Bd. 53, S. 546.
- 1902 Über die Entstehung des Corpus luteum der Säugetiere. Referat, Ergeb. d. Anat. u. Entwickl., Bd. 11, S. 946.
- 1907 Über die Bildung des Corpus luteum beim Meerschweinchen. Anat. Hefte, Bd. 32, S. 89.
- SPIEGELBERG, O. 1865 Über die Bildung und Bedeutung des gelben Körpers im Eierstocke. Monatschrift f. Geburtskunde, Bd. 26, S. 7.
- STRAKOSCH, W. 1915 Das Schicksal der Follikelsprungstelle. Arch. F. Gyn., Bd. 104, S. 259.
- STRATZ, C. 1898 Der geschlechtsreife Säugethiereierstock. The Hague.
- VAN DER STRICHT, O. 1901 a La rupture du follicule ovarique et l'histogenèse du corps jaune. Comptes Rendus de l'Association des Anatomistes, 3^{me} Sess., p. 33.
- 1901 b La ponte ovarique et l'histogenèse du corps jaune. Bulletin de l'Acad. Roy. de Médecine de Belgique, IV^e Serie, T. 15, p. 216.
- 1908 La structure de l'oeuf de chienne et la genèse du corps jaune. Comptes Rendus de l'Association des Anatomistes, 10^e Sess. p. 1.
- 1912 Sur le processus de l'excrétion des glandes endocrines: le corps jaune et la glande interstitielle de l'ovaire. Arch. de Biol., T. 27, p. 585.
- TEACHER, J. H. 1908 in Teacher, Bryce, and Kerr, Contributions to the study of the early development and imbedding of the human ovum, Glasgow, p. 85.
- TIMOFEEV, A. I. 1913 Development of the corpus luteum of the human ovary. Dissertation, Kasan. (in Russian).
- VÖLKER, O. 1905 Über die Histogenese des Corpus luteum beim Zeisel (*Spermophilus citellus*). Arch. f. Anat. u. Entwickl., 1905, S. 301.
- WALDEYER, W. 1870 Eierstock und Ei. Leipzig.
- WALLART, G. 1914 Über Frühstadien und Abortivformen der Corpus luteum-Bildung. Arch. f. Gyn., Bd. 103, S. 544.
- WEYSSE, A. W. 1894 On the blastodermic vesicle of *Sus scrofa domesticus*. Proc. Amer. Acad. of Arts and Sciences, vol. 30, p. 283.
- WILLIAMS, J. WHITRIDGE 1917 Obstetrics. New York. 4th ed.
- WOLZ, E. 1912 Untersuchungen zur Morphologie der interstitiellen Eierstockdrüse des Menschen. Arch. f. Gyn., Bd. 97, S. 131.
- ZWICKY, H. L. 1844 De corporum luteorum origine atque transformatione. Zurich, Inaug. Dissertation.

THE HYPOPHYSIS CEREBRI OF THE CALIFORNIA
GROUND-SQUIRREL, CITELLUS BEECHYI
(RICHARDSON)

HAROLD J. COOPER

Division of Anatomy, Stanford University Medical School

ELEVEN FIGURES

CONTENTS

Introduction.....	185
Material and methods.....	189
Gross features.....	190
Microscopic features.....	192
Pars buccalis.....	193
Pars distalis.....	193
Pars juxta-neuralis.....	198
Pars infundibularis.....	198
Pars tuberalis.....	200
Pars neuralis.....	200
Colloid.....	201
Summary.....	203
Bibliography.....	203

Despite the prevailing interest in the structure and functions of the hypophysis, but little attention has been paid to the rodents, and none to the common ground-squirrel, so far as I have been able to ascertain. Stendell ('14) gives a brief account of the more salient features of the rodent hypophysis. Mann ('16), working on the ductless glands of the spermophile and their possible relation to hibernation, briefly describes the changes which the hypophysis undergoes during these periods. The more detailed studies have seemingly been carried out on man and the higher mammals.

Using the terminology of Tilney ('11) and ('13), the adult mammalian hypophysis is generally recognized to-day as being made up of a buccal and neural portion whose subdivisions may be tabulated as follows:

- I. Pars buccalis (glandularis)
 1. Pars distalis
 2. Pars juxta-neuralis
 - a) Pars infundibularis
 - b) Pars tuberalis
- II. Pars neuralis
 1. Eminentia saccularis
 2. Infundibulum
 3. Processus infundibuli

Stendell ('13) describes with accompanying illustrations, in many of the lower forms the relationship existing between the different parts of the gland (glandular and neural). Sterzi and Gentes, as cited by Stendell, called the pars distalis the chromophilic and the juxtaneural portion the chromophobic, on account of the characteristic staining reactions. Tilney ('11) and ('13) pictures the parts in the human; Herring ('08), in the cat, dog, and monkey, each of which possesses its own peculiarity. Swale Vincent ('12) speaks of three types of hypophyses among the mammalia according to the degree of investment of the nervous lobe by epithelium and according to the extent to which the nervous lobe is invaded by the cavity of the third ventricle. The first type (cat) has a hollow nervous lobe, the cavity communicating freely with that of the third ventricle. The epithelial investment is very complete. The second type (dog) has a solid nervous lobe, but a patent infundibulum. Here, too, there is a very complete investment. In the third type (man) both the nervous lobe and infundibulum are solid, although traces of a lumen in the latter may exist. The epithelial investment here is not so complete.

The classification of the cells in the pars glandularis is voluminously discussed in the older papers. Flesch ('84) classified them as chromophile and chromophobe. Dostoiewsky ('86) endeavored to establish a relationship between the granular and non-granular cells in regard to their distribution. In the ox and in man he found that the alveoli lying more peripherally were made up of a greater proportion of granular cells than those lying centrally. He also found that in these forms, the cells

lying peripherally in the alveoli themselves were more frequently of the granular type. In the smaller animals, as a class, he found that the more even distribution of the two cell types made any such localization of little worth. Lothringer ('86) found a peripheral arrangement of the chromophile elements in the horse, dog and in man similar to that described by Dostoiewsky. Rogowitzsch ('89) described the so-called 'Kernhaufen' in the pars distalis. In this tissue the cell borders are fused and indistinct and appear much like embryonic connective tissue. Schonemann ('92) describes the chromophobes as having ill-defined borders and a diffusely granular cytoplasm. Scaffidi ('04), using orange G and acid fuchsin describes 'orange G staining cells' and 'fuchsinophile cells,' to each of which he attributes an independent secretion. Trautmann ('09) classified them as chromophobic, weakly chromophilic, and strongly chromophilic, the latter two types being either acidophile or basophile.

Considerable disagreement exists among the older writers concerning the functional individuality of the various cell types. Benda ('00) believes them to be of one and the same cell type in different phases of functional activity. According to him, the chromophobic cells, by the accumulation of granular matter, become chromophilic, and these, after the elimination of their secretory matter, in turn, chromophobic. St. Remy ('92), Herring ('09), Stendell, and others are of the same general opinion with slight modifications. Guerrini ('05) and Scaffidi ('04) believe in the existence of different functional types. The sum total of evidence from a number of papers seems to leave the exponents of the latter view quite in the minority. The relative changes in the cell types in pathological conditions in man and animals (hypophysectomy, thyroidectomy, acromegaly, gigantism, etc.) has led to much speculation as to the possible individuality of them. Biedl ('13) gives a general review of these papers.

The pars infundibularis is characterized by the greater abundance of basophile cells which it contains. Herring states that there are a few deeply staining cells, but that they never contain eosinophile granules.

The pars neuralis in the mammalia is made up chiefly of ependyma and glia cells, among which run many fibers. Müller ('71) regards this portion as one reduced in structure to a connective-tissue appendage of the brain. Berkley ('94) describes an elaborate arrangement of nervous elements, but his paper stands quite without substantiation from the later writers. It is not generally considered that there are any true nerve cells in the nervous lobe. Nerve fibers exist in great abundance as described by Herring and others. Clunet and Jonnesco ('10) studied in detail the pigment of this lobe, which occurs especially in the higher mammals.

The existence of colloid matter in the various portions of the gland is given mention in many references, but the best accounts are to be found in the works of Herring, Stendell, and Biedl. Steida ('90) states that the colloid in the pars distalis is found within the chromophile cells. In the pars infundibularis it may be in the cells or gathered into cysts. Benda believes the colloid in the tissue to be indicative of degeneration. Guerrini regards it as a normal product of secretion. Schonemann, Herring, and Trautmann describe colloid masses with cell remains and granules. The transitional part between the distal and infundibular lobes, which goes to make up such a distinct portion (Übergangsteil) in many of the lower forms (Stendell), is not present in the mammals as a strikingly different histological region. In it, however, much colloid can usually be found, in some forms colloid being present there when it is absent elsewhere in the gland. Cushing ('12) calls attention to the more constant basophilic character of the colloid in the pars juxtaneuralis, while after passing into the pars neuralis it forms acidophile hyaline masses. Herring states that colloid in the cleft is rare and that it is never found very far distant from the nervous lobe. Stendell describes secretory matter in the lumen and suggests that it may represent a reserve supply.

Peremeschko ('67) calls attention to cilia which line the residual lumen in man. Lothringer ('86) and Stieda ('90) describe them lining the cysts. Vanderburgh ('17), in guinea-pigs, found unmistakable patches of cilia lining the residual lumen

and in some cases being continuous with the lining of the cysts. On the other hand, Herring states that there are none in the cat, and Stendell regards their presence as extremely improbable.

Comparatively little attention has been paid to mitoses, in the adult gland at least, in which, to be sure, they are rarely seen. Jackson ('17), working on albino rats during inanition, gives an account of the disappearance and reappearance of mitoses during and after this condition.

Numerous slight differences have been described in the nuclei, but they seem to possess no radical variations from the usual forms in similar organs and tissues. Stendell calls attention to the possibility that the irregularity of outline in the nuclei, found occasionally in the deeply chromophilic cells, may be due to intercellular pressure.

MATERIAL AND METHODS

The striking lack of information upon the Sciuridae in the literature on the hypophysis led me to make some studies of this abundant material, and results secured seem to warrant publication in their present form. The common ground-squirrel, *Citellus beechyi* (Richardson), was used. The animals were obtained by shooting. They were at once dissected carefully, the hypophyses removed and placed in the fixative, care being taken to reject any of those that showed any damage to the skull or brain in the region of the organ. As fixatives, saturated corrosive sublimate in 70 per cent alcohol, Zenkerformol, 10 per cent formalin, strong Flemming's solution, Bouin's fluid, and 100 per cent alcohol were used. Delafield's hematoxylin was used throughout as a nuclear stain. Orange G and acid fuchsin mixture (Scaffidi), chromotrope 2R and 2B were used as counterstains. Alcoholic eosin was not very satisfactory. Mallory's connective-tissue stain was also used, while methyl violet, methylene blue, Wright's blood stain, thionin, and other basic and mixed stains were found invaluable.

Sections were cut in celloidin and paraffin, the latter in series of 5 μ . The former method was employed when large portions of brain and bone tissue were to be included in the sections.

A. GROSS FEATURES

The general topography of the ground-squirrel hypophysis is very similar to that of other mammals (figs. 1 and 2). Using Tilney's terminology, it has a pars buccalis (*PG*), derived from the ectoderm of the buccal cavity (but possibly also including a portion from the pharyngeal entoderm), and a pars neuralis (*PN*), derived from the nervous system. These two portions lie

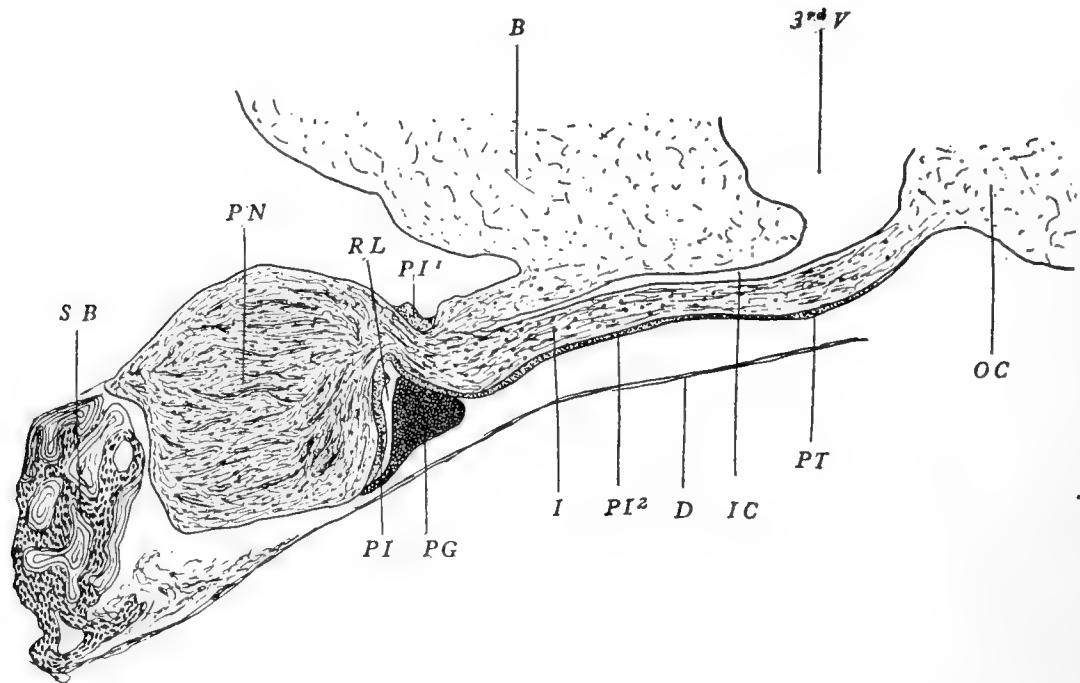


Fig. 1 Midsagittal section through the ground-squirrel hypophysis (semi-diagrammatic). *B*, brain; *3rdV*, third ventricle; *SB*, sphenoid bone; *PN*, pars neuralis; *RL*, residual lumen; *PI*, *PI*¹, *PI*², pars infundibularis; *PG*, pars distalis; *I*, infundibulum; *IC*, infundibular cavity; *D*, dura; *OC*, optic chiasma; *PT*, pars tuberalis. $\times 25$.

in contact. The original cavity of the pars buccalis (residual lumen (*RL*)) is maintained in the adult form, and serves to separate the pars buccalis into two divisions, structurally, and probably also functionally distinct, namely, the pars juxtaneuralis (*PI*, *PI*¹, *PI*², *PT*), and the pars distalis. The pars juxtaneuralis is divided into a pars infundibularis (*PI*, *PI*¹, *PI*²), investing the infundibulum and infundibular process, and a pars tuberalis (*PT*), extending over the tuber cinereum. Since the

pars infundibularis and the pars distalis are not entirely separated, a transition zone is found to exist at the periphery of the lumen where the one portion merges into the other.

The hypophysis of the ground-squirrel (fig. 1) measures about 2 mm. in the anteroposterior dimension and 2.5 mm. transversely. The dimensions vary somewhat in a series of measurements, but the ratio of length to breadth is quite constant. The organ lies in a shallow sella turcica, to which it is firmly bound by

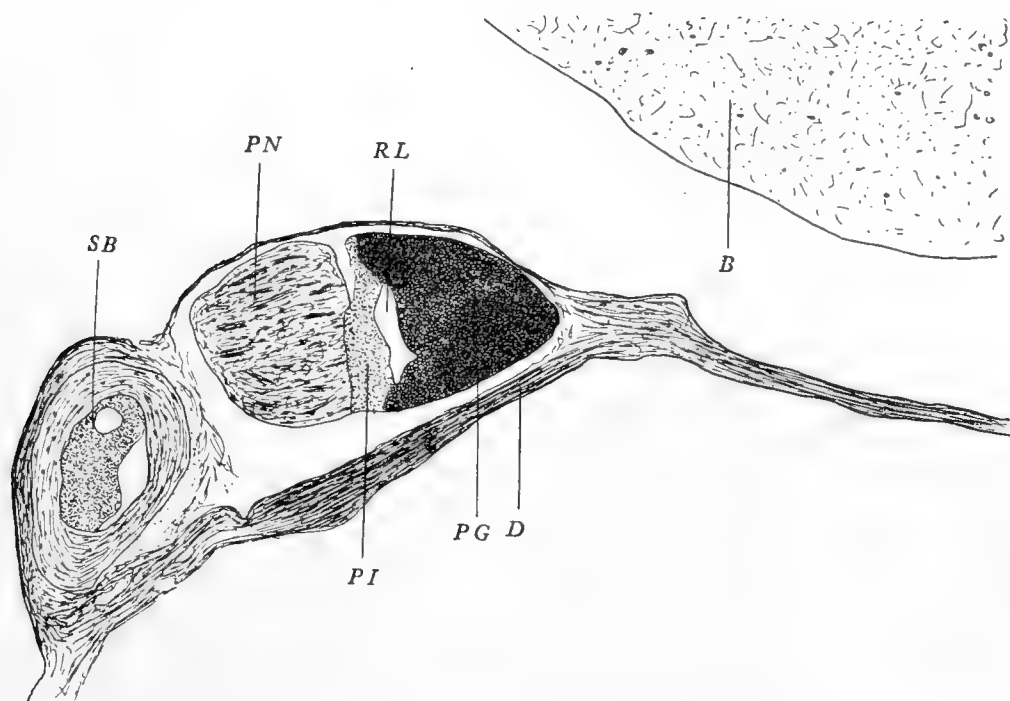


Fig. 2 Section somewhat lateral to fig. 1 (semi-diagrammatic). *B*, brain; *SB*, sphenoid bone; *PN*, pars neuralis; *PI*, pars infundibularis; *RL*, residual lumen; *PG*, pars distalis; *D*, dura. $\times 25$.

the meninges. Considerable care has to be used to avoid breaking or tearing the infundibulum during removal. The infundibulum lies almost horizontally in the anteroposterior direction, and is bordered on either side, as in all the higher forms, by the corresponding optic tract. The glandular portion is a deep blood red and the nervous portion a glistening white in the fresh condition. The glandular portion partially envelops the pars neuralis and extends further posteriorly at its lateral margins than elsewhere, thus forming a concave hinder surface (figs. 1 and

2). The organ belongs to the second class in Vincent's ('12) grouping, possessing a solid nervous lobe, but an infundibular cavity extending almost to it.

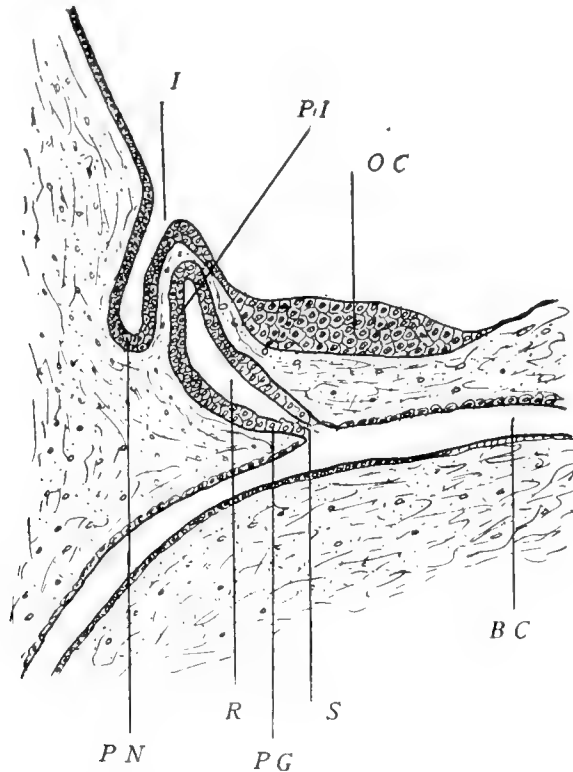


Fig. 3 Midsagittal section of the hypophysis of a 12-mm. embryo (semi-diagrammatic). *I*, infundibular cavity; *PN*, pars neuralis; *PI*, future pars infundibularis; *R*, residual lumen; *PG*, future pars distalis; *S*, epithelial stalk; *OC*, optic chiasma; *BC*, buccal cavity. $\times 35$.

B. MICROSCOPIC

Since I have had but little embryological material, I can give no details of the development. The only stage I have seen is found in a 12-mm. embryo, a midsagittal section being shown in figure 3. The hypophyseal pouch (Rathke's pouch) is just about to be cut off at *S*. At this stage there has taken place no differentiation of the glandular portion into distal and juxtaneural lobes.

I. Pars buccalis

1. *Pars distalis*. The simple classification of the cells of this part into chromophile and chromophobe is not very evident in the ground-squirrel. Transition forms exist in such great numbers that one kind is not quickly distinguishable from another. There are, however, two extreme types, one deeply granular and the other either slightly so or not at all.

The deeply chromophile cells are characterized by their larger size and less regular contour. On section they may be round, triangular, square, or polyhedral, in fact, with sufficient search almost any shape may be encountered. The nuclei are round or oval and contain a rich chromatin network. The cytoplasmic granules are coarse and usually irregular in shape. The chromophobe cells are characterized by a round, generally smaller, nucleus. The cytoplasm is more or less free from granulation and in many cases consists of only fine protoplasmic strands with no limiting membrane. In this condition they possess no acidophilic properties, the fibers staining a faint tinge with hematoxylin.

The ground-squirrel hypophysis shows a number of cells varying in granulation from those with none or a few granules to those in which the cytoplasm is practically one homogeneous acidophile mass. The granules of the weakly chromophilic cells are usually small and well separated, the intervening cytoplasm being very weakly acidophilic (fig. 8, *a* and *b*). In other cells the granules are larger but fewer in number, presumably due to the coalescence of numerous smaller granules. In the deep acidophiles (fig. 8, *c* and *d*) the cytoplasm may show little or no granulation, the cell contents apparently consisting of a mass so densely packed that the ultimate granular nature of it is obscured.

The distribution of the cells of either extreme of granulation seems to be very irregular, no particular area being recognizable in which either form is more common, for a cell of one extreme may lie adjacent to one of the other (fig. 5, *a* and *b*), or be surrounded by cells apparently intermediate between the two extremes (fig. 7). Nor does any definite arrangement of the cells

obtain in the alveoli, they being about equally distributed. This is just contrary to what is to be seen in the human hypophysis, in which the elements are usually quite distinct, the chromophiles occupying the periphery of the alveolus, but coincides more with Dostoiewsky's statement that such an arrangement is not to be observed, as a rule, in small animals. The chromophiles may be either acidophile or basophile, and the existence of a peripheral granular zone, described by some writers, is not to be found in this gland. The chromophile cells in the pars distalis are acidophilic, as a rule, when filled with granules, while in the pars juxtaneuralis the cells are exclusively basophile.

The cells of the pars distalis bordering on the residual lumen are somewhat pyramidal (triangular in section) and, filling up the angular spaces between the oval and polyhedral cells immediately beneath them, they present a smooth and regular free surface. Some of the spaces referred to are filled in by irregular cells. These have round nuclei, while those of the pyramidal cells are oval. The chromatin in their nuclei, as seen with thionin stain, appears to be more diffuse than in the others, in which it is often seen massed in one or more clumps. The nuclei of the border cells, on the whole, stain deeply and are very numerous, appearing, especially under low magnification, as one continuous row. The shape of these cells seems to conform to the arrangement of the underlying layers. Quite often the border cells give the appearance of a continuous layer of low cuboidal or flattened cells (fig. 4, A). The cells are not, however, of this nature. This appearance of the border cells is best seen in the peripheral portions of the cleft. The cells stain deeply and can easily be distinguished from the paler underlying ones. They are joined end to end, but a distinct peripheral border is discernible for each of them. The nuclei stain deeply and the cytoplasm takes on a dark tint in ordinary staining. In other regions along the cleft the cells appear wedged in between the gland cells and show the arrangement in figure 4, B.

The cells vary considerably in size, ranging from 4μ to 6μ in diameter among the chromophobes having a measurable periphery, to 6μ to 12μ among the chromophiles. As a rule, the

richer in acidophile matter the larger the cell, although this is not accurately determinable from the fact that many of the poorly granular cells have ill-defined margins. The nuclei of the chromophobes usually lie centrally. From the fact that the nuclei of these cells seem entirely intact under practically all conditions and show no signs of nuclear degeneration, it is probable that they are not degenerated, as some have suggested, but that they are in the early stages of accumulating granular matter. The nuclei of the chromophiles usually lie eccentrically, being located in that part of the cells most distant from the vascular sinuses upon which they border.

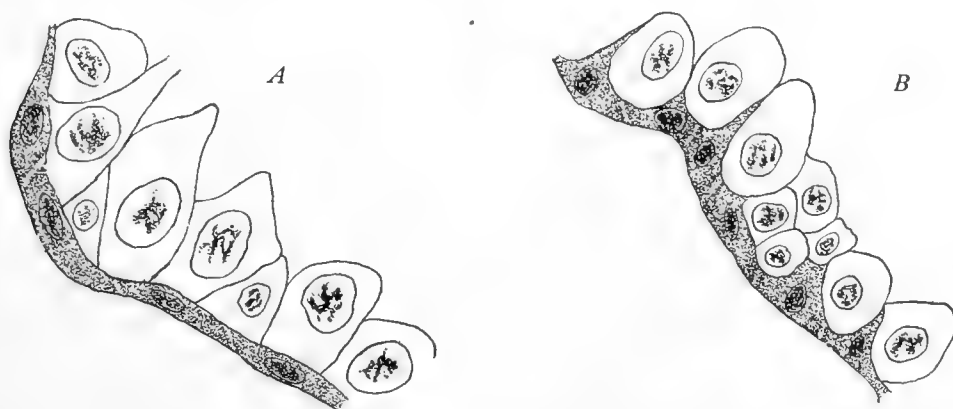


Fig. 4 (a) From the pars distalis showing the border-cells on the lumen. $\times 1200$. (b) From the pars infundibularis showing the border cells with their extensions into the gland substance. In both (a) and (b) the border cells appear darkened. $\times 1200$.

Figure 5 gives an example of the two extremes—one markedly chromophilic, *a*, and the other chromophobic, *b*. The cell outlines of the chromophobes are not usually so distinct as shown in *b*. While the two cell types here figured were adjacent in the preparation, the more common arrangement is to find various intermediate forms commingled with these, figure 7 showing such a group in one of the alveoli. It is important to bear in mind that, while the two extremes are less sharply set apart, there are, nevertheless, just as strongly chromophilic and chromophobic cells in the ground-squirrel hypophysis as in other forms.

When stained with orange G and acid fuchsin, according to Scaffidi's technic, there were seen in sections, cells staining deeply with

the orange G. No special features were observed in these except that they were perhaps slightly smaller than the cells staining with the acid fuchsin. In these cells, as shown in figure 6, the ground substance of the cytoplasm stains a clear light orange and contains a great number of irregular granules which take a deep orange color.

Scaffidi, on the basis of this method of staining sections from the human gland, differentiates between what he considered to be two different functional types. Those taking up the orange G, he states, are round, and their golden granules small, fine, and glistening. They have a small oval nucleus with large chromatin granules. The 'fuchsinophile' cells are described as larger and more irregular and their granules irregular and coarse. The nuclei are larger and generally rounded. In them occur small blocks staining deeply with the fuchsin. He mentions nothing about these blocks in detail except to say that they are never found in the 'orange G staining cells.' These blocks I was unable to find in the squirrel gland or in the human.

In order to understand the distinction made on this basis, sections of human hypophysis and adrenal, as well as the same tissues from the ground-squirrel, were first stained with orange G. Certain groups of cells were located with a mechanical stage, studied and drawn. The preparations were then decolorized and restained with acid fuchsin. In the human hypophysis, it was found, practically without exception, that those cells which had at first stained with the orange G, became restained with the fuchsin, while those remaining colorless at the first staining, continued so during the second. The same was true without exception with the squirrel hypophysis and both adrenals. Besides this set of stains, eosin and fuchsin, eosin and chromotrope 2B, and fuchsin and chromotrope 2B were used with the same results. These groups of stains, when used together (in a mixture) can be distinguished by differences in shades, and when so used, it was seen that they, too, attacked the cells somewhat differently. While there is a specificity shown by different cells toward one or the other of the stains in such a mixture, it does not seem to offer a very sound foundation alone for a division of the cells into functional individual cell types.

Vascularity. The pars distalis is pervaded throughout by numerous blood sinuses. They are of varying width, and owing to their elaborate distribution they come into close relation to the cells. By virtue of their tortuous course, no long channels are to be seen except in very thick celloidin sections, and in the usual paraffin preparations they appear as irregular areas containing blood. The cells of the pars distalis lie in strands or cords two or three layers thick. The spaces separating them being occupied by blood, it is evident that no given cell can be much more than its own diameter distant from a rich blood supply. The channels are lined by a well-marked vascular endothelium which intervenes between the blood and the cells (fig. 11). The arrangement offers strong probability of a direct secretion into the blood channels, although it is possible that the secretion is given off into the tissue spaces and taken up by a perivascular lymphatic system as suggested by Edinger ('11). Thom ('01) conceives of a mixed secretion from the chromophile and chromophobe elements as passing into interfollicular lymph spaces.

Surely, the vascularity of the organ is of considerable significance, and it very likely plays an important part in the taking up of the secretory products of the cells. In the sections which I have observed in the ground-squirrel there is abundant histological evidence that the cells secrete into the blood stream. In the region of a sinus, cells in the above-described granular stages will be seen along its margins. When the blood sinus is cut in cross-section the cells are seen to radiate from it in much the same way as other gland cells are seen to be arranged about their secreting tubules. In the deep chromophiles, which many writers consider to be cells ready to discharge their secretion, marked irregularities in outline may be found. These irregularities are always found at that end of the cell bordering on the sinus and separated from it only by the endothelium. In this region of the cell the granules may be seen in clumps outside the cell or at least exterior to the former probable limits of it (figure 11 *a*). Under these conditions the cytoplasm at the irregular end may be very light in granulation as compared with adjacent heavily granular and smoothly outlined cells. In addition to this

the basal end of the cell may be still quite filled with its acidophilic matter, while in other cells the whole cytoplasm is free from granulation and reduced to a pale meshwork, simulating characteristic chromophobic cells (figure 11*b*). The chromophobe cells seem, then, to represent those cells which have given up their secretion, which has probably diffused through the endothelium into the sinus. The intermediary granular cells present no marked irregularities. The failure of observers to definitely trace the secretion into the blood channels does not seem to me to discredit this conception, which is held by not a few investigators.

The connective-tissue framework of this lobe is taken up by Dostoiewsky ('86) in detail, and in the ground-squirrel there are no particular variations from his description. The peripheral bundles derived from the dural capsule are the thickest and form beams which divide and subdivide, until, when they reach the central regions of the gland, they consist of very slender fibers forming a reticulum which encloses small groups of cells. It is against these fibers that the cells rest, and by them and by the sinusoids the groups of cells are outlined.

2. *pars juxtaneuralis*. a) *Pars infundibularis*. The degree to which the *pars neuralis* is enclosed by the *pars infundibularis* varies according to the species. In the ground-squirrel the *pars infundibularis* is concave on the neural side, and, being somewhat cup-shaped, it extends over the *pars neuralis* peripherally. This envelopment is by no means complete, but at least half of the neural portion is so enclosed (compare figs. 1 and 2).

The basophilic character of the cells of this lobe has been indicated earlier in this paper, and in no cases did they show any acidophilic granulations. They are considerably smaller as a rule, 4μ to 7μ in diameter, but occasionally large giant-like cells are observed, which, if they are pale, look like colloid cysts. The nuclei are correspondingly smaller in the typical cells, but their nuclear characteristics are about the same. Bordering on the lumen, there are cells making up the free margin (border cells) which send processes in among the glandular ones. In the *pars infundibularis* these processes are better seen than in the distal lobe for the reason that the large cysts and an occasionally large

cell create larger triangular spaces between themselves and allow for a greater inward excursion of these cell processes (fig. 4, *B*). The cells are compactly arranged and no sturdy bands of supporting fibers are seen. The layer is four or five cells thick and is closely applied to the pars neuralis. Toward the center the layer is thinner, but where it is reflected to join the pars distalis it is again thickened with the formation of the transition zone. This zone, in many of the lower forms, according to Stendell, usually shows a characteristic structure, but here the transition is so abrupt that no such modification is apparent.

The vascularity of this part is slight in comparison with that of the pars distalis. Where in the latter lobe the tissue is richly supplied with blood and where the sinuses are extremely numerous, here only an occasional blood-vessel is seen, most of these being near the marginal region, in which the tissue turns back to join the pars distalis. As a result, the cells are not separated into well-defined groups, but are distributed quite evenly throughout the extent of the part.

In addition to forming a smooth surface facing the lumen, the pars infundibularis has a fairly regular neural border. No elaborate granular inclusions within the pars neuralis are met with. In most cases a slight undulation of the surface is all that is seen. Toward the periphery of the cleft, in the transitional zone, a few small inclusions occasionally occur, but by tracing through adjacent sections they seem to be due to slight folds in that region, and are not patches of gland tissue at all. Separating the pars infundibularis and pars neuralis is a series of blood-vessels, which, as mentioned by Dandy and Goetsch ('11), are not concerned with the pars infundibularis. This layer of vessels is thin and connective-tissue fibers are seen on either side of them which apparently serve to bind together the pars infundibularis and the pars neuralis. These fibers are derived from the dural sheath of the brain which is prolonged down the infundibulum over the nervous lobe.

The portion of the pars infundibularis investing the infundibulum is not very extensive. It is best seen on the caudal surface of the infundibulum as a layer of cells three or four deep.

On the upper surface they are not very well defined and, as a rule, only a few gland cells are scattered along its extent. The layer is closely applied to the infundibulum and consists of small cells (3.5μ to 4.5μ in diameter) packed close together. The cytoplasm is scanty and does not stain with acidophilic stains. The nuclei are hyperchromatic and a general basophilic character is imparted to the cells. Just exterior to this are numerous blood-vessels bounded still further exteriorly by a layer of the dura. These blood-vessels are in close relation to the cells and at frequent intervals they may be seen extending into the gland substance. These vessels appear to be continuous with those of the pars tuberalis above. The part, as a result, is quite vascular, being much more so than the portion investing the infundibular process.

b) Pars tuberalis. The pars tuberalis extends a considerable distance forward (fig. 1), but is not made out posteriorly except as a few scattered cells distributed along the base of the brain in much the same way as the cells of the upper surface of the infundibulum. The cells are slightly larger (6μ to 8μ in diameter), but, like those investing the infundibulum, they have a scanty cytoplasm and hyperchromatic nuclei. The most characteristic feature is the tendency of the cells to arrange themselves radially about a central point like a gland follicle. Such groups are quite numerous, and in between them the cells are distributed quite irregularly. Numerous blood-vessels are seen which seem to be continuous with those of the pars infundibularis below.

II. *Pars neuralis*

Little need be said relative to this, inasmuch as the findings agree very closely with those of Herring for the cat. The infundibulum is long and slender and is invaded by the cavity of the third ventricle as far as the nervous lobe. The fibers of the infundibulum run for the most part longitudinally. There are many which run transversely from the sides of the infundibulum toward the center where they curve either upward or downward along the stalk. The fibers which run toward the glandular part

curve outward along the periphery of the nervous lobe where they can be traced for a short distance. Those fibers in relation to the pars infundibularis come to lie in a thick layer adjacent to the gland tissue, and separated from it only by the series of vessels already mentioned. The pars neuralis is supplied by small arterial branches which enter at its posterior end, where, in sections, there is always a break at the point of entrance. Throughout the part, small vessels are very evenly distributed, but these are not very numerous. Nothing was seen of nerve cells. Many neuroglia and ependyma fibers course through the lobe.

III. The colloid

The subject of hypophyseal colloid is fully summarized by Stendell ('14) and is treated in detail in several papers, but usually only as applied to the pars infundibularis. Here, to be sure, it is found in great abundance, but it is also very noticeable in the pars distalis in several of the forms which I have observed. In the ground-squirrel hypophysis the cysts are very numerous in the pars distalis, but usually quite small as compared with those of the pars infundibularis, being 6μ to 8μ in diameter in the former and up to 8μ to 15μ and even larger in the latter.

The cysts of the glandular portion (pars infundibularis and pars distalis) can be conveniently divided into two groups according to the character of the contents. In one type the material is apparently made up of the remains of broken-down cells (fig. 10). The second type presents a wholly different picture (fig. 9). The contents of these are hyaline. They never show any particles which could in any way be associated with cell remains. This type is not confined exclusively to any particular area, but is, however, far more common in the pars infundibularis. These colloidal masses appear to have a darker peripheral portion probably due, however, to refractive differences alone. External to this sharp border, the surrounding cells are usually arranged radially.

In spite of close study, I have never found cysts in the pars infundibularis showing any communication with the cavity of

the gland, nor have I found anything in the nature of cilia within them. The residual lumen is frequently quite filled with a granular mass not unlike the contents of many of the adjacent cysts. The lumen contains no cilia, though they are common in the guinea-pig, as shown by Vanderburgh ('17).

The granular cysts stain very irregularly. The hyaline ones stain more consistently with the acid dyes in the pars distalis, but also take on a good tinge with many of the basic ones. The granular cysts show fragments in them resembling cell particles in their staining reaction, some of them even appearing connected with the cells surrounding the cyst. In addition to these fragments there may be observed small masses staining with basic dyes and seemingly derived from the nuclei of broken-down cells. The rest of the contents stain well with the acid stain. It is quite possible, that since the cysts are seen in varying degrees of homogeneity, that the hyaline ones represent later stages of the granular ones. The hyaline cysts which are usually acidophilic might then well represent an extremely fine dispersion of this nuclear material with a possible slight reduction of its basophilic properties during its retention in the cyst.

In the pars infundibularis the cysts are practically always hyaline, and while they can be made to take on acid stains they are, nevertheless, very deeply basophilic. In the pars neuralis colloid can be found distributed exactly as Herring ('08) describes. In the pars neuralis it is always hyaline and stains deeply acidophilic.

Stendell remarks that it is difficult to determine how much of this material consists of concentrated secretion and how much is cell remains, and, although it may be observed in many varying types of appearance, composition, and staining quality, that the colloid is the ultimate product.

I take pleasure in thanking Prof. F. M. MacFarland for his interest and assistance which proved invaluable in the preparation of this paper.

SUMMARY

1. The ground-squirrel hypophysis has a solid nervous lobe and a patent infundibulum, the cavity of which extends as far as the nervous lobe.

2. The gland cells, judged from their staining reactions, are in all probability of the same cell type in different phases of functional maturity.

3. The colloid cysts of the pars distalis are small and very numerous, those in the pars infundibularis being larger, but fewer in number. Relatively, the pars infundibularis contains the greater amount of colloid, but, absolutely, I believe the pars distalis exceeds in this respect.

4. No continuity between the cysts and cleft was seen and in no cases were cilia found in either.

BIBLIOGRAPHY

- ANDRIEZEN, W. L. 1894 On the morphology, origin and evolution of function of the pituitary body and its relation to the central nervous system. *Brit. Med. Journ.*, vol. 1, p. 54.
- BERKLEY, H. J. 1894 The finer anatomy of the infundibular region of the cerebrum including the pituitary body. *Brain*, vol. 17, p. 514.
- BENDA, C. 1900 Über den normalen Bau und einige pathologische Veränderungen der menschlichen Hypophysis cerebri. *Arch. f. Anat. u. Physiol., Physiol. Abt.*, Jahrg. 1900, S. 373.
- BIEDL, A. 1913 *Innere Sekretion*. 2 Auflage, 2 Teil. Berlin.
- CLUNET, J., AND JONNESCO, V. 1910 Le pigment du lobe postérieur de l'hypophyse. *C. R. Soc. Biol., Paris*. T. 69, p. 626.
- CUSHING, H. 1909 The hypophysis cerebri. *Journ. Am. Med. Assoc.*, vol. 53, no. 4, p. 249.
- 1912 *The pituitary body and its disorders*. Phila., Lippincott.
- DANDY, W. E. 1913 The nerve supply to the pituitary body. *Am. Journ. Anat.*, vol. 15, p. 333.
- DANDY, W. E., AND GOETSCH, E. 1911 The blood supply to the pituitary body. *Am. Journ. Anat.*, vol. 11, p. 137.
- DOSTOIEWSKY, A. 1886 Über den Bau des Vorderlappens des Hirnanhanges. *Arch. f. mikr. Anat.*, Bd. 26, S. 592.
- EDINGER, L. 1911 Die Ausführwege der Hypophyse. *Arch. f. mikr. Anat.*, Bd. 78, S. 496.
- FLESCHE, M. 1884 Über den Bau der Hypophyse. *Tageblatt der 57. Naturforscher Versammlung zu Magdeburg*, 1884, S. 195.
- GUERRINI, G. 1905 Über die Funktion der Hypophyse. *Centralbl. f. allgem. Pathol. u. pathol. Anat.*, Bd. 16, S. 177.

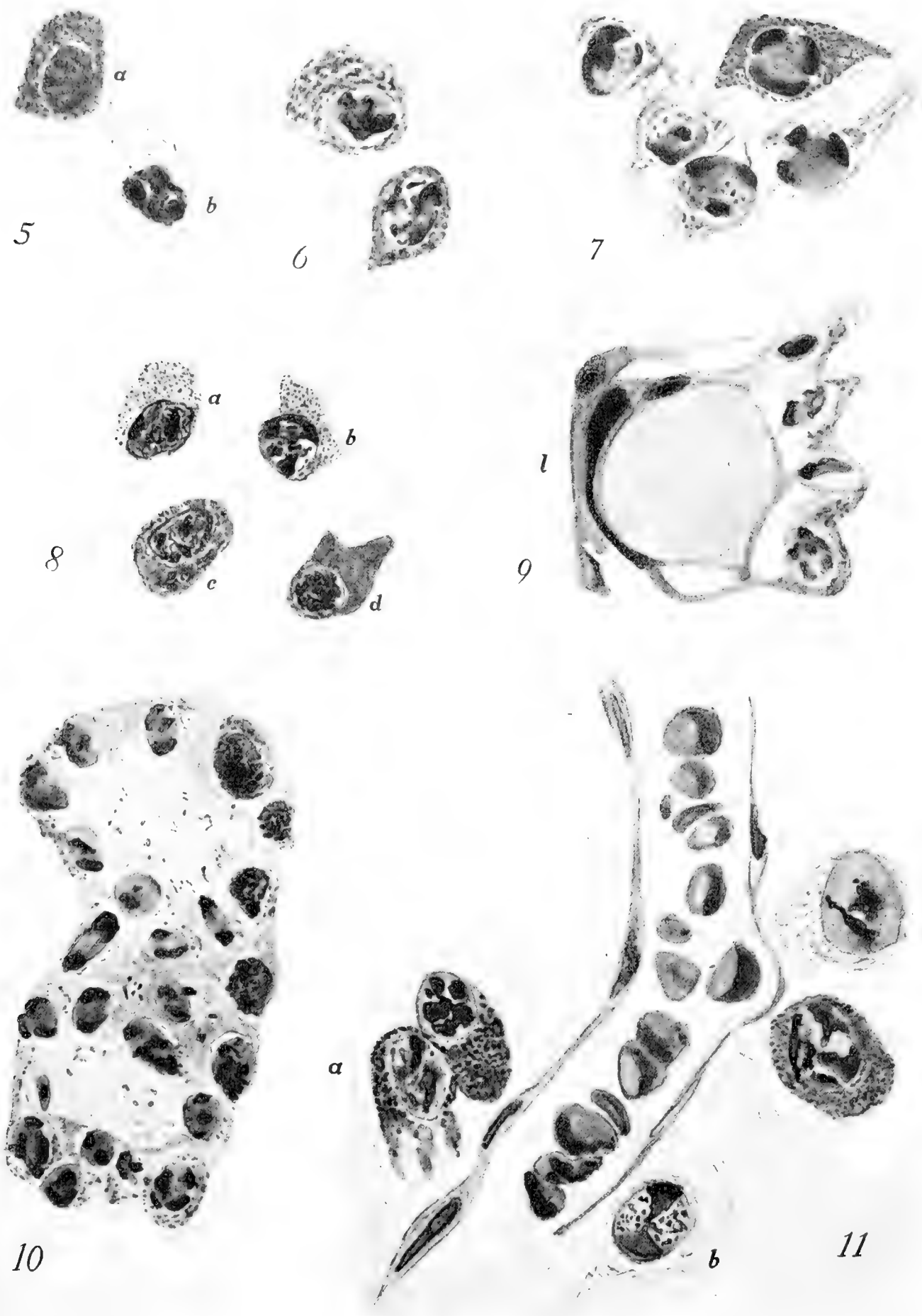
- HERRING, P. T. 1908 The histological appearances of the mammalian pituitary body. *Quart. Journ. Exp. Physiol.*, vol. 1, p. 121.
 1908 The development of the mammalian pituitary body and its morphological significance. *Ibid.*, vol. 1, p. 161.
- JACKSON, C. M. 1917 Effects of inanition and refeeding upon the growth and structure of the hypophysis in the albino rat. *Am. Journ. Anat.*, vol. 21, p. 321.
- LANGLEY, J. N. 1884 On the structure of secretory cells and the changes which take place in them during secretion. *Internat. Monatschr. f. Anat. u. Physiol.*, vol. 1, p. 69.
- LIVINGSTON, A. E. 1916 The effect of castration on the weight of the pituitary body on other glands of internal secretion in the rabbit. *Am. Journ. Physiol.*, vol. 40, p. 153.
- LOTHRINGER, S. 1886 Untersuchungen an der Hypophyse einiger Säugetiere und des Menschen. *Arch. f. mikr. Anat.*, Bd. 28, S. 257.
- MANN, F. C. 1916 The ductless glands and hibernation. *Am. Journ. Physiol.*, vol. 41, p. 173.
- MÜLLER, W. 1871 Über Entwicklung und Bau der Hypophyse, u.s.w. *Jenaische Zeitschr. f. Naturwissensch.*, Bd. 6.
- PEREMESCHKO, P. 1867 Über den Bau des Hirnanhanges. *Virchow's Archiv.*, Bd. 38, S. 329.
- RETZIUS, G. 1894 Die Neuroglia der Neuro-Hypophyse der Säugetiere. *Biol. Untersuch. N. F. VI*, S. 21.
- ROGOWITSCH, N. 1889 Die Veränderungen der Hypophyse nach Entfernung der Schilddrüse. *Ziegler's Beiträge.*, Bd. 4, S. 453.
- ST. REMY, G. 1892 Contribution à l'histologie de l'hypophyse. *Arch. de Biol.*, T. 12, p. 425.
- SCAFFIDI, V. 1904 Über den feineren Bau und die Funktion der Hypophyse des Menschen. *Arch. f. mikr. Anat.*, Bd. 64, S. 235.
- SCHONEMANN, A. 1892 Hypophyse und Thyroidea. *Virchow's Archiv*, Bd. 129, S. 310.
- STIEDA, L. 1890 Die Hypophyse des Kaninchens nach Entfernung der Schilddrüse. *Ziegler's Beiträge*, Bd. 7, S. 535.
- STENDELL, W. 1913 Zur vergleichenden Anatomie und Histologie der Hypophysis cerebri. *Arch. f. mikr. Anat.*, Bd. 82, S. 289.
 1914 Die Hypophysis cerebri. *Oppel's Lehrbuch d. vergl. mikr. Anat. d. Wirbeltiere*, 8. Teil. Jena.
- THOM, W. 1901 Untersuchungen über die normale und pathologische Hypophysis cerebri des Menschen. *Arch. f. mikr. Anat.*, Bd. 57, S. 632.
- TILNEY, F. 1911 Contribution to the study of the hypophysis cerebri with especial reference to its comparative histology. *Memoirs Wistar Inst. Anat. and Biol.*, no. 2.
 1913 An analysis of the juxta-neural epithelial portion of the hypophysis cerebri, etc. *Internat. Monatschr. f. Anat. u. Physiol.*, Bd. 30, S. 258.
- TRAUTMANN, A. 1909 Anatomie und Histologie der Hypophysis cerebri einiger Säuger. *Arch. f. mikr. Anat.*, Bd. 74, S. 311.
- VANDEBURGH, C. M. 1917 The hypophysis of the guinea-pig. *Anat. Rec.*, vol. 12, p. 95.
- VINCENT, SWALE 1912 *Internal secretion and the ductless glands.* London.

PLATE

PLATE 1

EXPLANATION OF FIGURES

- 5 (a) Typical chromophile and (b) typical chromophobe from the pars distalis. Shown in their natural relation. $\times 1800$.
- 6 Two 'orange G staining cells' from the same lobe. $\times 1800$.
- 7 Group of cells showing densely and sparsely granular cells in an alveolus in the pars distalis. $\times 1800$.
- 8 Four chromophiles from the pars distalis in varying degrees of granulation. $\times 1800$.
- 9 Hyaline cyst from the pars distalis. This cyst is bordering on the residual lumen 1. $\times 1800$.
- 10 Granular cyst from the pars distalis containing fragments resembling cytoplasmic and nuclear remnants. $\times 1800$.
- 11 Arrangement of the cell elements about a blood-vessel. Not all of the cells are represented. $\times 1800$.



Resumen por el autor, Ralph Dougall Lillie.

La histogénesis temprana de la sangre en *Bufo halophilus* Baird
y Girard.

El autor ha estudiado el desarrollo temprano de las células sanguíneas en los estados larvarios hasta los 19 mm de longitud. Las células sanguíneas primarias se originan principalmente en la masa celular mesodérmica ventral. Estas células dan lugar a eritroblastos primitivos y a grandes linfocitos. Los primeros adquieren la forma definitiva acumulando hemoglobina y multiplicándose por mitosis, transformándose en eritrocitos primitivos. En los estados estudiados no ha encontrado el autor eritropoiesis definitiva. En la masa celular ventral se originan grandes linfocitos, a expensas del endotelio endocárdico y del endotelio general, o a expensas de células mesenquimatosas no diferenciadas. De los grandes linfocitos se derivan pequeños linfocitos y los tres tipos de células granuladas, eosinófilas, basófilas y células especiales o neutrófilas.

Translation by José F. Nonidez
Carnegie Institution of Washington

THE EARLY HISTOGENESIS OF THE BLOOD IN BUFO HALOPHILUS BAIRD AND GIRARD

RALPH DOUGALL LILLIE

Division of Anatomy of Stanford University Medical School

SEVEN FIGURES

CONTENTS

Introduction and literature.....	209
Material and methods.....	211
The ventral cell mass.....	212
The primitive blood-cells.....	214
The stage of differentiation of the primitive blood-cells into primitive erythroblasts and large lymphocytes. The loss of the yolk.....	218
The further differentiation of the primitive erythrocyte stem.....	221
The hematopoietic tissue of the mesonephros.....	222
Summary and conclusions.....	228
Bibliography.....	230

INTRODUCTION AND LITERATURE

The histogenesis of the blood of Amphibia has occupied the attention of but few writers. Among these the earlier ones and Maximow ('10) in *Rana* hold that the primitive blood-cells give rise only to red corpuscles, while in other vertebrates, such as *Lepidosiren* (Bryce, '04), birds and *Tropidonotus* (Danchakoff, '08 a, 16 a), *Chelonia* (Jordan and Flippin, '13), mammals (Maximow, '09 a, and Jordan, '10), and in certain Amphibia themselves, (*Bufo*, Mietens, '10), the same cells give rise to two lines of descent, viz., an erythrocyte and a leucocyte stem. Further, it has been shown that this erythrocyte stem is a transitory one, giving place later to a definitive one which is a branch of the leucocyte line.

This difference between the Amphibia and other vertebrates and especially between the two Amphibian forms, suggested the

subject of the present paper: a reëxamination of the early development of the blood elements in *Bufo*, and for this purpose the California species *B. halophilus* Baird and Girard was found to be the most convenient.

Bryce ('04) derives the blood and endothelium from the splanchnic mesenchyme. The yolk-laden primitive blood-cells quickly differentiate into a larger type with peripheral fibrils: the erythroblasts, and a smaller lymphoid form. The larger type pass over into yolk-free, oval, flattened cells in which hemoglobin appears. The loss of the yolk may precede the appearance of hemoglobin by a short time. In the next phase erythropoiesis continues, the stem cell now being a large mononuclear cell. The mesenchyme gives rise to large mononuclear cells, polymorphonuclear leucocytes, and granulocytes. The splanchnic mesenchyme, the intrahepatic mesenchyme, and the interstitial mesenchyme of the pro- and mesonephros are the chief sites of blood formation. The last, at least, sets free leucocytes into the blood, as they are more numerous in the cardinal vein than in the aorta. Likewise, small lymphocytes appear. With the development of the spleen further hematopoiesis is confined to it, to the lymphorenal tissue, and to the gut-wall mesenchyme. The splenic trabeculum cells give rise to erythrocytes through large lymphocytes, also to lympholeucocytes, finely and coarsely granular eosinophils, and basophil granulocytes. In the later stages the lymphorenal tissue is almost entirely lympholeucopoietic. Leuco- and granulopoiesis are strictly extravascular, erythropoiesis intravascular. This last conclusion is reached also by Bizzozero ('90) in birds, Danchakoff ('08 a, '16 a) in birds and reptiles, Jordan and Flippin ('13) in reptiles, and Maximow ('09 a, '10) in mammals, selachians, and amphibians. And when erythrocytes are formed outside of the vessels they soon degenerate, while granulocytes are only formed intravascularly where the circulation has been stopped up (Danchakoff, '08 b).

In the main the differentiation of the blood-cells in the other vertebrates follows the outline given by Bryce for *Lepidosiren* (Maximow, '09 a, '10; Danchakoff, '08 a, '16 a; Mietens, '10; Jordan and Flippin, '13).

In birds (Danchakoff, '08 a) and reptiles (Jordan and Flippin, '13; Danchakoff, '16 a) the primitive blood-cell is morphologically a large lymphocyte and the primitive erythropoiesis gives way gradually to the definitive. While in Selachia (Maximow, '10 a), Dipnoi (Bryce, '04), Amphibia (Mietens, '10), and Mammalia (Maximow, '09 a) the primitive blood-cell is a distinct form and the formation of primitive erythrocytes is separated by an interval from that of the definitive cells.

Schridde ('07, '08), in human embryos of 1 to 13 mm., finds that the first blood-cells all differentiated into nucleated erythrocytes, whose nuclei began to fragment in the 6-mm. stage. Later, when blood formation in the liver commences, parenchyme cells give rise to myeloblasts, giant-cells, and erythroblasts, lymphocytes not appearing until much later.

Van der Stricht ('91, '92, '95, '99), in mammals and birds, and Weber ('07 a, b), in birds, find that all the first blood-cells become erythrocytes and that no white cells occur in the blood stream at first.

Stockard ('15 a, b) asserts that in *Fundulus* embryos without circulation erythrocytes, endothelium cells, and leucocytes all have distinct origins, no white cells being formed intravascularly and all the first blood-cells arising from a definite anlage and passing over into erythrocytes, and are not interrelated, no blood-cells being formed from endothelium. He observed red corpuscles outside of the anlage, but accounted for them by assuming a temporary circulation. White cells, on the other hand, arise from the general mesenchyme. Reagan ('15 b, '17) and Reagan and Thorington ('15) found that all the body mesenchyme of *Fundulus* could furnish both blood- and endothelium cells.

MATERIAL AND METHODS

My material consisted of eggs and larvae of *Bufo halophilus* B. and G., from the closing of the neural groove to the beginning of the metamorphosis. In this study only the earlier stages, up to 19-mm. body length, are treated fully. The larvae were fixed in Zenker-formalin for four to six hours, ten parts of formalin to

one hundred of sublimate-Müller being the proportion used. The larvae were extracted three to six days in iodized alcohol and preserved in 85 per cent alcohol. Imbedding was in paraffin, in gelatin-paraffin (Weber, '14), and in celloidin-paraffin.

Serial sections 5 μ in thickness of the larvae up to 9-mm. body length were made. From the later stages the mesonephros, liver, pancreas, and heart were dissected out and sectioned alone.

For stains Hansen's iron hematoxylin with eosin or orange G, Dominici's eosin-orange G-toluidin blue, Maximow's eosin-azure II, and thionin were used, the sections being cleared in xylene and mounted in xylene-damar. Wright's stain diluted with two parts of water was also used, staining being sufficient in about ten minutes, the differentiation being secured in alcohol rather than in water. As controls and for comparison smear preparations of adult blood and bone marrow were used.

THE VENTRAL CELL MASS

No discussion of the origin of this cell mass, whether entodermal or mesodermal, will be made here, the evidence for its mesodermal origin being deemed sufficient. In a larva of 2.5- to 3-mm. body length it forms two plates on the ventrolateral aspects of the yolk mass. It is distinguished from the latter by the greater number of nuclei, the somewhat smaller size of the yolk granules, and a line of demarkation, which, although not too well defined, is nevertheless distinguishable. There is no striking difference in nuclear structure.

This mass is apparently syncytial in character, at least, no cell boundaries are evident by ordinary methods. I believe that is largely due to the pale character of the cytoplasm, which is greatly obscured by the large rounded or elliptical yolk granules. The same indefiniteness of cell outline obtains in the yolk mass itself. But occasionally polygonal cells are seen outlined by pigment, and more clearly by the blue stained (eosin-azure II) gelatin of the imbedding mass. These cells are rich in yolk, less so than the yolk entoderm cells, their yolk granules being about 6 μ long and half as broad. These granules stain readily with

eosin or orange G and very intensely and tenaciously with iron hematoxylin. When blood elements of later stages are stained with Heidenhain's iron hematoxylin and eosin the granules of the eosinophil leucocytes readily give up the black color and become bright red. Bryce ('04) states that these granules were, in the younger stages, either derived from, or actually were finely divided yolk matter.

At the 3-mm. stage some few of the cells are seen to be rounding up and detaching themselves from the mass.

When stained with Dominici's eosin-orange G-toluidin blue, the nuclei of these cells take on a deeper blue than those of the mesenchyme, showing a finely reticular structure with dark blue nodal points. Most of the cells contain one or two purple stained, large, smoothly rounded nucleoli. With Wright-alcohol the nuclei show the reticular structure even better, the reticulum seeming more irregular. Chromatin particles lie at the nodes. The karyoplasm is basophil, with a tinge of pink in some cells, thus suggesting the faintly oxyphil condition of the later stages. The cytoplasm is usually colorless or nearly so, becoming increasingly basophil soon after, and contains many small brownish black pigment granules, which are present throughout all the cells of the embryo.

The mesenchyme cell of this stage (3 mm.) is taking on a spindle form. It has a basophil cytoplasm with fewer and smaller yolk granules than the cells of the blood anlage. The nucleus is clearer and poorer in chromatin, which lies in discrete, deeply staining particles at the nodes of a loose network of lightly colored linin threads. A deeply stained nucleolus is present.

The cell of the blood anlage and the mesenchyme cell differ in the reaction of the cytoplasm, in the number and size of the yolk granules, and in the character of the nucleus. They are alike in the possession of small dark brown pigment granules and in that both are frequently seen in mitosis.

THE PRIMITIVE BLOOD-CELLS

The ventral cell mass breaks up into large round cells at about 3- to 3.5-mm. body length. The peripheral layer of the splanchnic mesoderm forms an endothelial wall for the ventral sinus. The wall next the yolk mass is incomplete, there being but few endothelium cells on that side, so that the cavity is in part closed in above by the yolk mass itself. This sinus seems to correspond to an omphalomesenteric vein, for in later stages it can be traced forward on each side into the sinus venosus.

Endothelium cells are seen in various parts of the body. These are elongated cells with clear elliptical nuclei containing one or two large nucleoli and but little chromatin. The karyoplasm is clear and colorless. The conspicuous nucleolus is round or oval and stains violet blue with eosin-azure II. The cytoplasm is basophil.

In these earlier stages the endothelia of the blood-vessels do not seem complete, but present gaps here and there. Mietens ('10) finds this condition also in *B. vulgaris*.

In larvae of 3- to 3.5-mm. body length the ventral cell mass becomes resolved into its constituent elements. The cells gradually break apart, the mass as a whole enlarges, free space appears within the endothelial wall, and the cells round up into spherical elements which float free in the plasma. Not until about the 4 mm. stage are these free rounded cells found in the cavity of the heart or in the systemic vessels. So it would appear that the breaking up of the blood anlage occurs before the commencement of the circulation rather than after.

The primitive blood-cells (fig. 1, *pb*) are large, spherical cells about 13.5 to 22 μ in diameter, averaging 17 to 18 μ , heavily laden with yolk granules, which are evidently solid in nature, as they are not distorted by mutual pressure, while the nucleus is frequently compressed and angular from the resistance of the yolk granules. There are many extra nuclear pigment granules in these and in the endothelium cells. The dark nucleus contains a considerable amount of chromatin in angular or rounded masses of varying size on a linin network. The karyoplasm is stained blue with a reddish tinge (eosin-azure II). As a rule, it is darker and

the chromatin is more abundant than in the endothelium cells, but transition forms are found which approach the nuclear constitution of the latter. The amount of chromatin does not show any definite relation to the degree of basophilia of the cytoplasm. The chromatin, when stained with thionin, appears as angular or rounded blocks of an intensely dark blue color. The large round nucleolus or nucleoli, they being frequently two in number, stains bluish violet with eosin-azure II, and reddish violet, i.e., metachromatically, with thionin. With the former stain it shows little color difference from chromatin itself, and, as will be seen, this difference becomes less and less apparent as development proceeds. The cytoplasm is colorless or slightly basophil. The basophilia appears especially around the periphery of the cell. In some cells no basophilia is evident, though observation is difficult on account of the large volume of yolk, but in those cells in which the yolk is decreasing in amount considerable areas of cytoplasm may be observed. When in mitosis these primitive blood-cells show larger expanses of yolk-free cytoplasm, and but little basophilia is then evident.

In these stages, 3.5- to 4.5-mm. body length, the mesenchyme cells (fig. 2, *ms*) become almost free from yolk. Occasional rounded cells (fig. 2, *pbc*), rich in yolk and morphologically identical with the primitive blood-cells, are seen in the loose mesenchyme. Two possibilities exist regarding them: that they have lagged behind the spindle cells in yolk elimination, their nuclei being modified so as to resemble those of the primitive blood-cells, or that they are primitive blood-cells which have escaped from the vessels and wandered out into the mesenchyme. The second is not excluded, but the first seems more probable, for such cells are found in the head mesenchyme before the breaking up of the ventral cell mass, while the mesenchyme cells are still yolk-laden, but are taking on spindle forms with diminishing chromatin content of their nuclei.

The steady decrease in food yolk is more evident toward the 5-mm. stage, the larger cells becoming elongated and oval, with a more circular cross-section, and with this diminution a centriole sometimes becoming visible in the increasingly basophil cytoplasm.

In such larvae large cells with pale cytoplasm, a large vesicular nucleus with little chromatin, a large nucleolus, and clear karyoplasm, and but little yolk are found laden with large numbers of dark brown pigment granules. These cells circulate in the blood stream, are seen passing through vascular walls, and are found in the mesenchyme outside.

In the mesenchyme are also noted a few cells which are somewhat less elongated than the rest, more rounded up, and have a more strongly basophil cytoplasm. These probably represent the first lymphoid wander-cells. Toward the end of the phase under description, 3 to 5 mm., the period in which the primitive blood-cells are the only intravascular circulating elements aside from the pigment cells just mentioned, the mesenchyme becomes almost free from yolk, only an isolated cell here and there retaining a granule or two. At the end of this phase the primitive blood-cells have lost their spherical form and a portion of their yolk and are now roughly oval elements, all containing yolk, with cytoplasm in varying grades of basophilia, and nuclei containing somewhat variable amounts of chromatin, and slightly basophil or very slightly oxyphil karyoplasm.

My results as to the primitive blood-cells coincide fairly closely with those of Mietens ('10). He states that primitive blood-cells resemble young erythrocytes more than they do primitive leucocytes. The primitive blood-cells of *Bufo vulgaris* are sharply bounded, spherical cells with dark nuclei, rich in yolk. In *Lepidosiren paradoxa* (Bryce, '04) the primitive blood-cells are heavily laden with yolk, show a centrosome with aster, the nucleus is round or oval, not distorted by the pressure of the yolk granules as in *Bufo halophilus*, sometimes notched, the chromatin is in rounded karyosomes connected by delicate processes to form a reticulum. This, as may readily be seen, corresponds closely to the structure of my primitive blood-cells. Maximow ('10) characterizes the primitive blood-cells of *Rana temporaria* as large spherical cells, rich in yolk, and those of *Acanthias vulgaris* are hemoglobin-free, amoeboid, and basophil. In mammals (Maximow, '09 a) they are regularly spherical, smoothly contoured cells about 10 to 11.5 μ in diameter, in the guinea-

pig often amoeboid. The nucleus is large, surrounded by a narrow cytoplasm. It is round or slightly indented. Within it are pale karyosomes and one or more large distinct nucleoli, which stain with a reddish tinge with eosin-azure II or Dominici's stain, lying on a linin net. The cytoplasm is very finely reticular and fairly strongly basophil, more so than the cytoplasm of endothelium and mesenchyme cells. It contains clear round vacuoles, lying singly or in small groups. The nucleus is usually somewhat eccentric, with its indented side toward the broader part of the cytoplasm. On this side close against the nuclear membrane lies a very distinct, usually hemispherical attraction sphere, staining red with eosin-azure II or Dominici's stain. Around this lie many vacuoles. In iron-hematoxylin preparations a typical pair of centrosomes takes the place of the sphere. Many mitotic figures are found in these cells. Thus it may be seen that the nuclei are readily comparable in mammals and in Amphibia. The difference in the degree of basophilia in these forms may probably be attributed entirely to the presence and gradual digestion of yolk in the cytoplasm, for when the primitive blood-cells in *Bufo halophilus* have lost their yolk and have differentiated into red and white cells, both types show a more or less basophil cytoplasm (fig. 3). In birds and reptiles (Dan-chakoff, '08 a, '16 a; Jordan and Flippin, '13) the primitive blood-cells are morphologically large lymphocytes, amoeboid, spherical, with a more or less broad basophil cytoplasm. They have a large clear nucleus, which may be indented, with one or two well-marked, somewhat metachromatic nucleoli and well-marked chromatin particles. The nucleus is excentric and a centriole may be present. So, in the Sauropsida the primitive blood-cells are large lymphocytes, while in Dipnoi, Amphibia, and Mammalia they are a morphologically distinct form. They are neither red cells, nor are they white cells of any adult type. Their nuclei are in *B. halophilus* distinct in character from those of the primitive erythrocytes.

THE STAGE OF DIFFERENTIATION OF THE PRIMITIVE BLOOD-CELLS INTO PRIMITIVE ERYTHROBLASTS AND LARGE LYMPHOCYTES. THE LOSS OF THE YOLK

In larvae of 5- to 6-mm. body length the primitive blood-cells lose their yolk almost completely, and differentiate into two new types, one of which is a large, oval, flattened cell with much vacuolated oxyphil cytoplasm, the primitive erythroblast, the other is morphologically identical with the large lymphocyte (fig. 3, *p.eb*, *l.lb*, *l.lc*).

The yolk granules seem to disappear by intracellular solution, not by granular fragmentation. Vacuoles appear around their margins, enlarge and coalesce, while the yolk granule decreases in size, finally passing into the interior of the vacuole. The yolk granules become paler as they diminish and finally disappear completely. The contents of the vacuoles are clear and colorless, not staining with eosin-azure II. Bryce ('04) suggests that the yolk granules, when they disappear, may break up into granules which are eosinophil in nature, and that the early leucocytes may be concerned in the distribution of yolk material. The latter statement may be true, but as to the former, all yolk has long since disappeared from the blood-cells before the first eosinophil granulocyte appears in *Bufo*. We must note, however, that Bryce lacked stages which showed the complete details of the loss of the yolk, which might modify his interpretation. A third alternative exists: that the yolk granules may be extruded from the cells into the circulating blood, since one frequently sees apparently free granules in the blood stream. Usually, however, a small amount of basophil cytoplasm or a few pigment granules may be seen close to them, so it may be that they lie within a pseudopod of a cell in the next section. It seems perfectly possible, however, that the granules may be extruded from the cells and digested by the proteolytic enzymes of the blood.

Mietens ('10) merely states that the yolk disappears. Bryce ('04) notes that a vacuolization of the cytoplasm occurs and seems to be associated with the disappearance of the yolk not only in the blood-cells, but in the general tissue cells of the body as well. I have noted such an appearance in the mesenchyme cells of *Bufo*.

Now as to the erythrocytoid differentiation of the primitive blood-cells. The nucleus retains its round or oval shape and its definite nuclear membrane, which may be indented by a single remaining yolk granule. The chromatin becomes much more abundant, condensing to form a heavy network. At this stage the nucleolus reacts to basic stains in practically the same manner as the chromatin of the nucleus, and as the denser network of the latter develops, the nucleolus gradually loses its identity and becomes merged in the common chromatin content of the nucleus. The exact time of its disappearance is somewhat variable, in some cases the nucleolus persisting almost up to the first appearance of hemoglobin. The karyoplasm retains its faintly oxyphil character as long as it is at all distinguishable in the increasing density of the nucleus. This forms one of the distinct differences between the early erythroblasts and the large lymphocytes. As the yolk disappears from the cytoplasm, the latter takes on an increasingly basophil reaction, varying somewhat in intensity in different cells. With the appearance of hemoglobin this blue color soon shows a gray tint tending either toward greenish or purplish, depending on whether the developing hemoglobin takes a yellow or a pink stain with eosin-azure II. The cytoplasm becomes much vacuolated, these vacuoles persisting some little time after the disappearance of the yolk. The cells are oval, but not yet flattened, with sharply defined, smooth contours which are not necessarily perfectly uniform, but do not present any evidence of amoeboid activity.

The second type of cell differentiating from the primitive blood-cell is the large lymphocyte (fig. 3, *l.lb*, *l.lc*). In this process the cytoplasm of the former becomes very strongly basophil with the decrease of its food yolk. The cell outline shows strongly marked evidence of amoeboid activity. The cytoplasm of the large lymphocyte is broad, has no definite cell membrane, and appears reticular in some cells, in others hyaline. The nucleus is round, oval, or slightly indented, the indentation frequently facing the remaining yolk, and central or excentric in position. The karyoplasm becomes typically clear and colorless. The chromatin decreases in amount and is disposed in irregularly

scattered particles and in occasional isolated strands. A large smoothly rounded, metachromatically basophil nucleolus persists, showing but little change from the preceding stage. The cell is now a typical large lymphocyte.

Such cells arise also from other sources than the primitive blood-cells of the blood stream. Endocardial cells bulge out into the heart cavity and become constricted from the endocardium, at the same time becoming strongly basophil (fig. 3, *en.c*). These cells contain but little yolk, otherwise being identical with those arising from the primitive blood-cells. Endothelium cells in various parts of the body become thickened and more basophil, bulging out into the loose mesenchyme. Often free lymphoid wander-cells are seen lying in contact with these endothelia. Lymphoid wander-cells occur in many places in the mesenchyme: in the head mesenchyme, in the interstitial spaces of the mesonephros, around the gut. Here they arise from the indifferent mesenchyme cells by a withdrawal of their processes and an increase in the basophilia of their cytoplasm, the nuclei changing but little. It is likely that the cells resembling primitive blood-cells which were seen in the loose mesenchyme of the earlier stages (4 to 5 mm.) have gone over into lymphoid wander-cells or extravascular large lymphocytes.

Although white cells do arise from these other sources, both within and outside the vessels, they are not, as Maximow ('10) claims they are in *Rana temporaria*, the sole source of white blood-cells, for continuous series of transitions from yolk-laden primitive blood-cells to yolk-free, and also yolk-laden, large lymphocytes are found and these yolk-laden large lymphocytes cannot have been derived from either the endocardium cells, which are poor in yolk, or from the now almost yolk-free endothelium and mesenchyme cells.

At this stage, 5- to 6-mm. body length, the liver anlage is invaded by blood-vessels. These narrow vessels contain but few blood-cells, so the hematopoietic function of this organ is not yet developed at this period.

THE FURTHER DIFFERENTIATION OF THE PRIMITIVE
ERYTHROCYTE STEM

At the end of the last stage, 6 mm., the primitive erythroblast is a large, ellipsoidal, vacuolated cell with a large, round or oval, chromatin-rich nucleus. This cell is not at all flattened, but is somewhat irregular in contour. With eosin-azure II its cytoplasm stains a light blue with no trace of pink.

Between 6- and 6.5-mm. body length hemoglobin first appears, the cytoplasm now taking on a pink stain with triacid. With eosin-azure II some cells may now show a greenish-gray color, some a pink tint, but many are still pure blue. They are beginning to flatten, but a considerable margin of cytoplasm still shows on all sides of the nucleus. This body uniformly appears darker than the cytoplasm and contains much more chromatin than that of the lymphoid type. The erythroblasts now far outnumber the lymphocytes in the heart blood and frequently present mitotic figures.

Between 6.5- and 7-mm. body length the erythroblasts rapidly approach the definitive form (fig. 4, *p.eb*) of the adult erythrocyte, there being now very little cytoplasm between the nucleus and the flattened sides of the cell. With eosin-azure II the cytoplasm is of a gray color with elements of both blue and pink visible. The pink is more pronounced in some cells than in others, and is determined by the increased development of hemoglobin in their cytoplasm. Many vacuoles still remain, disappearing last from near the nucleus. A cell containing a single yolk granule may still be met with occasionally.

From the 7-mm. stage on the majority of the cells, and soon all of them, are oxyphil, hemoglobin-carrying primitive erythrocytes. Through all the stages studied, up to 38-mm. body length, no definitive erythropoiesis was observed. Mietens ('10) states that in *Bufo vulgaris* definitive erythropoiesis does not set in until the time of the metamorphosis.

At the 8-mm. stage the primitive erythrocytes (fig. 5, *p.ec*) are pink stained, hemoglobin-containing, oval, flattened, biconvex, sharp-bordered discs with a spherical, flattened, or oval chromatin-rich nucleus, showing an indistinct chromatin network.

Most of these cells have lost the vacuoles of the differentiation stages. The dark brown pigment granules of the primitive blood-cells are still present, but are very few in number. These cells are still found in karyokinesis in the circulation up to 37-mm. body length (and even in the young adult, also, according to Freidsohn, '10), which is as late as I have followed the larval development.

THE HEMATOPOIETIC TISSUE OF THE MESONEPHROS

In a stage where the mesonephros is as yet represented only by a single Wolffian duct, larvae of 8- to 9-mm. body length, one sees mesenchyme cells multiplying in the neighborhood of this duct, between it and the aorta, and undergoing a lymphoid metamorphosis (fig. 6). All transitions from branched and spindle-shaped lightly basophil mesenchyme cells (*ms*) to strongly basophil, rounded, amoeboid lymphoid wander-cells (*l.w.c*) may be found in a single field of the microscope. In addition, lymphoid cells with basophil cytoplasm and nuclei in varying degrees of polymorphism are seen in 9-mm. larvae. All transitions from slightly indented to horseshoe-shaped nuclei are found. The more polymorphous of these nuclei show an increase in chromatin and its progressive condensation about the periphery.

In this stage the first granulocytes appear. An eosinophil cell with about twenty bluish-red (eosin-azure II) granules is shown at *e.c* in figure 6. The first special cells are seen in this stage or slightly later (fig. 7, *s.c.*), and have also been noted in the circulating blood, but in very small numbers.

In a short time, however, the mesonephroic tubules become convoluted and the interstitial tissue increases greatly in amount. Much more granulopoietic differentiation is now seen. At first only eosinophil and special cells appear, but at about 16-mm. body length mast cells and small lymphocytes are likewise found. Since at this stage all the later forms of the blood elements, except spindle-cells, are represented, a description of each and its development may be taken up at this point.

Small lymphocytes. A few typical small lymphocytes (fig. 7, *s.lc*) are seen in the 16-mm. stage and more in later stages. These cells have proportionately large nuclei and a narrow rim of basophil cytoplasm. The chromatin is disposed in large angular blocks, some typical 'Radkern' or wheel-like nuclei being found, but no nucleoli may be distinguished.

Transition stages from large to small lymphocytes are found. It is evident that the small lymphocyte is a more highly differentiated cell form than the large lymphocyte, for when the latter differentiates to a granulocyte similar changes in the nuclear constitution occur, the chromatin becoming more abundant and the nucleolus disappearing.

Eosinophil cells. These cells, in the mature state in which they are found intravascularly, possess horseshoe-shaped, lobed, or segmented nuclei, cytoplasm which takes very little stain with eosin-azure II, and many coarse round eosinophil granules of varying size. The nuclear chromatin is larger in amount than in the large lymphocyte, but is still quite variable, being disposed primarily in contact with the well-defined nuclear membrane and then in variable density over the nuclear network. In this network no nucleolus can be distinguished. The karyoplasm is clear and almost colorless to eosin-azure II. The larger oxyphil granules often show a clear area in the center, staining more deeply peripherally, while in other cells smaller, more deeply staining, homogeneous granules occur. These granules become very numerous in mature cells, which may occasionally show mitotic figures. Such cells may readily be found in all phases of diapedesis from the tissue into the vessels. They are also found in the circulating blood. In one isolated but unmistakable case (fig. 7, *e.end*) an eosinophil cell was found as a part of the endothelial wall itself.

All transitions from typical large lymphocytes to mature eosinophil leucocytes are found. First a few coarse basophil granules, which, however, show no trace of metachromasia, appear, usually in the concavity of the slightly indented nucleus, soon increasing in number and changing their stain from blue to purple red with eosin-azuré II; then the nuclear membrane

becomes evident, the chromatin at the same time increasing in amount and in coarseness of karyosomes and the nucleolus losing its metachromasia and blending with the nuclear chromatin, and the cytoplasm becomes less and less strongly basophil as the nucleus assumes its final polymorphous form and the granules increase in number and come to be purely oxyphil.

Since phagocytosis of erythrocytes is absent in this extravascular tissue, it seems very improbable that these eosinophil granules arise as fragmentation derivatives of ingested hemoglobin containing cells, as maintained by Weidenreich ('11).

The interpretation of the eosinophil endothelium cell described above is a matter of difficulty, but it seems possible that this may be just another manifestation of the close relationship of the endothelium cell and the blood-cell. Danchakoff ('16 d) has used differentiation into similar end types as a proof of identity of stem cells in regard to the small cortical cells of the chick thymus and their mother cells. So it seems here that the differentiation of an endothelium cell into an eosinophil granulocyte would tend to show the identity of the endothelium cell with the large lymphocyte, which is the mother cell of the eosinophil granulocyte. According to the view of exogenous origin of eosinophil granules, it would merely be a proof of phagocytic activity on the part of the endothelium cell. Ordinarily phagocytosis is followed by intracellular digestion, and not by the preservation of the fragments of the ingested cell as an integral part of the phagocyte, even when autogenous erythrocytes are ingested by the endothelial phagocytes of the liver and spleen (Kyes, '15). The hemosiderin granules which are formed as a result of the intracellular digestion of red cells have no resemblance to true eosinophil granules.

Mast cells. This type of cell is first seen extravascularly in the 16-mm. stage. Maximow ('10) finds them in *Rana* only after the metamorphosis. Mietens ('10) does not find any mast cells at all, which is probably due to mast granules being soluble in such acid fixatives as he used. In *Bufo halophilus* these granules resist the action of water after fixation with Zenker formol.

The mast cells are mostly extravascular; one or two only being found within the vessels in my preparations, and are very few in number, not more than one occurring in each section.

The nuclei are simple, round, oval, or bean-shaped. In the younger stages the nucleus is that of a large lymphocyte, round and clear, with but little chromatin in small karyosomes, and a metachromatically basophil nucleolus, the cytoplasm is broad and usually slightly basophil, the granules are large, round, and comparatively few in number, staining an intensely dark purplish blue with eosin-azure II and violet red to blue violet with thionin. No variation in the staining quality of these mast granules could be found in any stage of their development. Thus the possibility of confusing the younger eosinophil granules with mast granules is excluded. In the older cells (fig. 7, *m.c*) the cytoplasm becomes less basophil, the mast granules increase in number, the nucleus becomes richer in chromatin, the nucleolus changes its staining quality and becomes indistinguishable from the chromatin. In some cells the chromatin is disposed in a typical 'Radkern,' being distributed in large angular blocks lying against the nuclear membrane and pointing toward a centrally located one. The karyoplasm is clear and may be slightly oxy- or basophil. Transition stages between these two types, here designated as older and younger, are seen. One cell, manifestly an old one, was found, in which the chromatin was decreased in amount, the nucleus appearing vesicular, the cytoplasm was colorless and showed ragged edges, indicating fragmentation of its periphery. In this cell the granules were large, only about six or seven remaining. Some evidence of amoeboid activity may be noted in the contour of many of the mast cells.

Special cells. Under this head are designated many cells with purplish-pink cytoplasm and simple to polymorphous nuclei (fig. 7, *s.c*). The more polymorphous of these nuclei may be lobed and segmented, as many as five lobes being found. Their chromatin is more or less abundant and lies along the nuclear membrane and in a chromatin net, or in small karyosomes in faintly oxyphil or colorless karyoplasm. The cytoplasm is the homogeneous, indistinctly granular, or, in a few cases, definitely

so. Such granules are very fine, rounded, discrete, and stain purplish pink. In these cases the cytoplasm is colorless. The staining reactions of these granules will be further treated later.

Transitions from large lymphocytes to special cells are readily found. First the nucleus becomes slightly indented, then sausage shaped, the nucleolus loses its differential stain and form and blends with the chromatin, then a pink spot appears in the blue cytoplasm (eosin-azure II) opposite the concavity of the nucleus. Or the change of stain may be more diffuse and almost simultaneous throughout the whole cytoplasm. The chromatin becomes more abundant and arranged along the nuclear membrane, which is now more evident.

One of these cells was seen in karyorrhexis. Its eosinophil cytoplasm was non-granular and contained a horseshoe-shaped nucleus whose chromatin was collected into numerous round, strongly basophil granules within the nuclear membrane, except at the tip of one lobe, where they were escaping into the cytoplasm. The karyoplasm itself was clear and colorless. Mitotic figures are not rare in the special cells.

Since it is usually stated in the literature that the special leucocytes of the Amphibia are non-granular or have at most only an azurophil granulation, I thought it worth while to investigate further the character of the fine granulation described above. It may be noted here that in air-dried films of adult blood and bone marrow of *Bufo halophilus* all the special leucocytes show a fine purplish-pink granulation on a clear karyoplasm when stained with Wright's stain in the customary manner.

In order to eliminate as far as possible variations due to age or differences in technique, sections of the mesonephros of a single larva of 19-mm. body length were used for the following series of staining reactions. All the stains used were differentiated in 96 per cent alcohol, except the thionin which was differentiated in absolute alcohol and cleared in xylene. The dilute Wright's and Jenner's stains mentioned were diluted to the same color tint as eosin-azure II-1 : 10 : 1 (Maximow, '09 c).

STAIN	TIME	RESULTS
Jenner (strong).....	10 m.	Some cells show distinct pink granules.
Jenner (dilute).....	24 hr.	Some cells show very distinct purplish-pink granules. Best granule stain of all.
Thionin (alcoholic).....	30 m.	No granules in blue cytoplasm.
Toluidin Blue.....	10 m.	No granules in blue cytoplasm.
Eosin-azure II (1:10:1).....	24 hr.	Some cells show purplish-pink granules.
Azure II (1:1000).....	10 m.	Many cells show gray or blue-gray granules in blue cytoplasm.
Wright (strong).....	10 m.	Some cells show purplish-pink granules.
Wright (dilute).....	24 hr.	Some cells show purplish-pink granules.
Unna's polychrome methylene blue.....	10 m.	No granules in blue cytoplasm.
Ehrlich's triacid.....	5 m.	Some cells show fine red granules. Most have red cytoplasm instead.
Hansen's iron hematoxylin and eosin.....	q.s.	No granules show.

The conclusions led to by the above table are as follows: 1) these granules are not soluble in water after fixation, because when stained for twenty-four hours they are no less distinct than when they are only exposed to water for ten minutes; 2) they are not azurophil, because they stain with Jenner's stain and with triacid, neither of which contains any methylene azure, and because they do not stain pink with azure II or Unna's polychrome methylene blue, both of which contain methylene azure, uncombined with eosin, however; 3) they are neutrophil, because they do not stain with eosin, or with basic analines alone, but do stain with neutral stains; 4) they have, however, a special affinity for acid fuschin, for they stain red with triacid rather than purplish pink.

My special cells are without doubt identical with Mietens' ('10) oxyphil wander-cells. Mietens' failure to observe granules in these cells can be attributed to inappropriate fixation. Maximow ('10) speaks of special granulocytes and of special leucocytes

with oxyphil cytoplasm without making it clear whether all the cells were granular or not. Downey ('13) describes in *Amblystoma* special leucocytes containing many fine purplish-pink granules (Wright's stain) which he concludes are azurophil, differing, however, from the azurophil granules of the lymphocytes, and being homologous with the granules of the special leucocytes of mammals. Werzberg ('11) finds in eight species of Urodela and eight species of Anura that the special leucocytes are non-granular, save in *Salamandra maculosa* and *Rana esculenta* in which he describes fine azurophil granules. In these same two species Niegelewski ('94) describes fine granules which are neutrophil to triacid. Grünberg ('01) gets the same results as Werzberg. Freidsohn ('10) and Weidenreich ('11, p. 75) state that granules are lacking in the special leucocytes of Amphibia. In *Rana aurora* and in *Batrachoseps attenuatus* I was unable to find any granules in the special leucocytes.

In larvae of 37- to 40-mm. total length, that is, larvae which show the beginning of hind-limb buds and measure 15 to 16 mm. from the snout to the anus, all of the above-described cell forms may be found in the loose connective tissue surrounding the bile duct. In the mesonephros there may be seen small areas in which all the cells are lymphocytes, while surrounding these islets all types of white cells are mixed. As yet, few leucocytes occur in the vessels, nor is there any definitive erythropoiesis. As in *Bufo vulgaris* (Mietens, '10), there is no interstitial hematopoiesis in the liver of *B. halophilus* up to this stage.

In closing, I take pleasure in thanking Prof. F. M. MacFarland for his aid and suggestions and for the use of his private room in the Hopkins Marine Station during the summer of 1916.

SUMMARY AND CONCLUSIONS

1. The primitive blood-cells arise from the ventral cell mass. Some isolated cells are found in various parts of the mesenchyme.
2. These cells lose their yolk by intracellular solution, differentiating at the same time into primitive erythroblasts and large lymphocytes.

3. The primitive erythroblasts soon assume the definitive form and acquire hemoglobin.

4. After this no heteroplastic formation of erythrocytes occurs, up to the latest stages studied. Homoplastic erythropoiesis continues.

5. Large lymphocytes may arise from endocardial and general endothelial cells.

6. Mesenchyme cells all over the body may develop into large lymphocytes or lymphoid wander-cells.

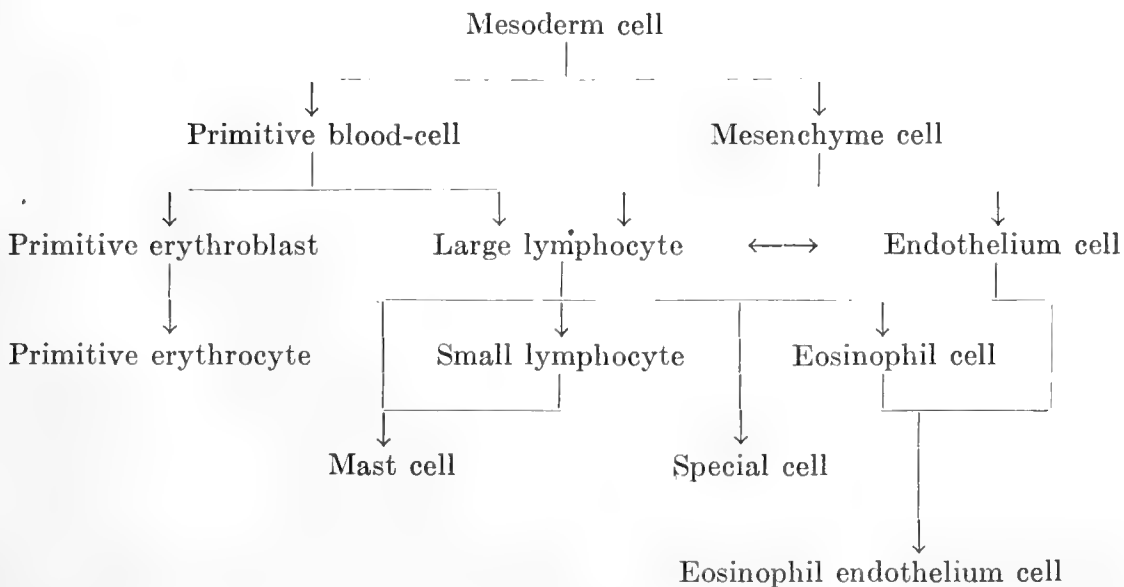
7. The large lymphocyte is the mother cell of all the other white blood-cells.

8. Three types of granular leucocytes occur: eosinophils, special cells, and mast cells.

9. The granules of the eosinophil cells are endogenous.

10. The special leucocytes of *Bufo halophilus* contain many fine granules, which are not azurophil, but neutrophil.

The histogenetic relations here described may be expressed by the following diagram, which is self-explanatory in the light of the foregoing account.



BIBLIOGRAPHY

- BADERTSCHER, J. A. 1913 Muscle degeneration and its relation to the origin of eosinophil leucocytes in Amphibia. *Am. Jour. Anat.*, vol. 15, p. 69.
- BIZZOZERO, G. 1890 Neue Untersuchungen über den Bau des Knochenmarkes bei den Vögeln. *Arch. f. mikr. Anat.*, Bd. 35, S. 424.
- BRYCE, T. H. 1904 Histology of the blood of *Lepidosiren paradoxa*. I. Structure of resting and dividing corpuscles. II. Hematogenesis. *Tr. Roy. Soc. Edinburgh*, vol. 41, pp. 291, 435.
- DANCHAKOFF, VERA 1908 a Untersuchungen über die Entwicklung des Blutes und Bindegewebes bei den Vögeln. I. Die erste Entstehung der Blutzellen beim Hühnerembryo und der Dottersack als blutbildendes Organ. *Anat. Hefte*, Bd. 37, S. 471.
- 1908 b Untersuchungen über die Entwicklung von Blut und Bindegewebe bei Vögeln. III. Das lockere Bindegewebe des Hühnchens im fetalen Leben. *Arch. f. mikr. Anat.*, Bd. 73, S. 117.
- 1916 a Über die Entwicklung des Blutes in den Blutbildungsorganen (Area vasculosa, Dottersackanhänge, Knochenmark, Thymus, Milz, und lockeres Bindegewebe) bei *Tropidonotus natrix*. *Arch. f. mikr. Anat.*, Bd. 87, S. 497.
- 1916 b Origin of the blood cells. Development of the hematopoietic organs and regeneration of the blood cells from the standpoint of the monophyletic school. *Anat. Rec.*, vol. 10, p. 397.
- 1916 c Concerning the conception of the potentialities in the embryonic cells. *Anat. Rec.*, vol. 10, p. 415.
- 1916 d The differentiation of cells as a criterion for cell identification, considered in relation to the small cortical cells of the thymus. *Jour. Exp. Med.*, vol. 24, p. 87.
- 1916 e Equivalence of different haematopoietic anlagen (by the method of stimulation of their stem cells). I. Spleen. *Am. Jour. Anat.*, vol. 20, p. 255.
- DOWNEY, HAL 1909 The lymphatic tissue of the kidney of *Polyodon spathula*. *Folia Haemat.*, Bd. 8, S. 415.
- 1913 The granules of the polymorphonuclear leucocytes of *Amblystoma*, with a few notes on the spindle cells and erythrocytes of this animal. *Anat. Anz.*, Bd. 44, S. 309.
- 1914 Heteroplastic development of eosinophil leucocytes and of haematogenous mast cells in bone marrow of guinea-pig. *Anat. Rec.*, vol. 8.
- 1915 The origin and development of eosinophil leucocytes and of haematogenous mast cells in the bone marrow of adult guinea-pig. *Folia Haemat.*, Bd. 19, S. 148.
- EMMEL, V. 1915 Concerning certain cellular elements in the coleomic cavities and mesenchyma of the mammalian embryo. *Am. Jour. Anat.*, vol. 220, p. 73.
- FREIDSOHN, A. 1910 Zur Morphologie des Amphibienblutes. Zugleich ein Beitrag zur Lehre von der Differenzierung der Lymphocyten. VIII. Fortsetzung der Studien über das Blut und die blutbildenden und -zerstörenden Organe. *Arch. f. mikr. Anat.*, Bd. 75, S. 435.

- GRÜNBERG, C. 1901 Beiträge zur vergleichenden Morphologie der Leucocyten. Virch. Arch., Bd. 163, S. 303.
- JORDAN, H. E. 1910 A microscopical study of the umbilical vesicle of a 13-mm. human embryo, with especial reference to the entodermal tubules and the blood islands. Anat. Anz., Bd. 37, S. 12, 36.
1916 Evidence of the hemogenic capacity of endothelium. Anat. Rec., vol. 10, p. 417.
- JORDAN, H. E., AND FLIPPIN, J. C. 1913 Haematopoiesis in Chelonia. Folia Haemat., Bd. 15, S. 1.
- KYES, P. 1915 The physiological destruction of erythrocytes in birds. Int. Monatschr. f. Anat. u. Phys., Bd. 31,.
- LANINE, P. 1912 Des globules blancs éosinophiles dans le sang des poissons d'eau douce. Arch. de Biol., T. 37, p. 525.
- MAXIMOW, A. 1909 a Untersuchungen über Blut und Bindegewebe. I. Die frühesten Entwicklungsstadien der Blut- und Bindegewebezellen beim Säugetierembryo, bis zum Anfang der Blutbildung in der Leber. Arch. f. mikr. Anat., Bd. 73, S. 444.
1909 b Untersuchungen über Blut und Bindegewebe. II. Über die Histogenese der Thymus bei Säugetieren. Arch. f. mikr. Anat., Bd. 74, S. 525.
1909 c Über zweckmässige Methoden für cytologische und histogenetische Untersuchungen am Wirbeltierembryo, mit spezieller Berücksichtigung der Celloidinschnittserien. Zeit. f. wiss. Mikr., Bd. 26, S. 177.
1909 d Der Lymphocyt als gemeinsame Stammzelle der verschiedenen Blutelemente in der embryonalen Entwicklung und im post-fetalen Leben der Säugetiere. Folia Haemat., Bd. 8, S. 125.
1910 Über embryonale Entwicklung der Blutzellen bei Selachiern und Amphibien. Anat. Anz. Ergänzungsh., Bd. 37, S. 64.
1912 Untersuchungen über Blut und Bindegewebe. IV. Über die Histogenese der Thymus bei Amphibien. Arch. f. mikr. Anat., Bd. 79, S. 560.
1913 Untersuchungen über Blut und Bindegewebe. VI. Über Blutmastzellen. Arch. f. mikr. Anat., Bd. 83, S. 247.
- MIETENS, H. 1909 Die Entstehung des Blutes bei Bufo vulgaris. Jen. Zeit. f. Natwschft., Bd. 45, S. 299.
1910 Entstehung der weissen Blutkörperchen und der Milz bei Bufo vulgaris. Jen. Zeit. f. Natwschft., Bd. 46, S. 301.
- MINOT, C. S. 1912 Die Entstehung des Angioblasts und die Entwicklung des Blutes. Keibel u. Mall Handb. d. Entwick. d. Menschen, Bd. 2, S. 483.
- NIEGELEWSKI, F. 1894 Die Ehrlich'sche Granulation der weissen Blutkörperchen bei einigen Tierspezies. Inaug. Diss. München, 1894.
- OPPEL, A. 1892 Unsere Kenntniss von der Entstehung der rothen und weissen Blutkörperchen. Zusammenfassendes Referat. Centbl. f. allg. Path. u. path. Anat., Bd. 3, S. 241, Bd. 4, S. 193.

- REAGAN, F. P. 1915 a Vascularization phenomena in fragments of embryonic bodies completely isolated from yolk-sac blastoderm. *Anat. Rec.*, vol. 9, p. 324.
 1915 b A further study of the origin of blood vascular tissues in chemically treated teleost embryos, with especial reference to haemopoiesis in the anterior mesenchyme and in the heart. *Anat. Rec.*, vol. 10, p. 99.
 1917 Experimental studies on the origin of vascular endothelium and of erythrocytes. *Am. Jour. Anat.*, vol. 21, p. 39.
- REAGAN, F. P., AND THORINGTON, J. M. 1915 The vascularization of the embryonic body of hybrid teleosts without circulation. *Anat. Rec.*, vol. 10, p. 79.
- RINGOEN, A. R. 1915 Observations on the differentiation of the granules in the eosinophilic leucocytes of the bone marrow of the adult rabbit. *Anat. Rec.*, vol. 9, p. 633.
- STOCKARD, C. R. 1915 a The origin of blood and vascular endothelium in embryos without a circulation of the blood and in the normal embryo. *Am. Jour. Anat.*, vol. 18, p. 227.
 1915 b A study of the wandering mesenchymal cells on the living yolk-sac and their developmental products; chromatophores, vascular endothelium, and blood cells. *Am. Jour. Anat.*, vol. 18, p. 525.
- SCHRIDDLE, H. 1907 Die Entstehung der ersten embryonalen Blutzellen des Menschen. *Folia Haemat.*, Bd. 4, Sup., S. 157.
 1908 Die Entstehung der ersten embryonalen Blutzellen des Menschen. *Verh. deutsch. path. Ges.*, XI. Vers., Dresden, 1908, S. 360.
- VAN DER STRICHT, O. 1891 Le développement du sang dans le foie embryonnaire. *Arch. de Biol.*, T. 11, p. 19.
 1892 Nouvelles recherches sur la genèse des globules rouges et des globules blancs du sang. *Arch. de Biol.*, T. 12, p. 199.
 1895 De la première origin du sang et des capillaires sanguins dans l'aire vasculaire du lapin. *C. R. Soc. Biol.*, T. 47, p. 181.
 1899 L'origin des premières cellules sanguines et des premiers vaisseaux sanguins dans l'aire vasculaire de chauve-souris. *Bull. de l'Acad. R. de Med. Belg.*, Ser. 4, T. 13, p. 336.
- WEBER, A. 1907 a Formes de transition entre les ébauches vasculaires et les flots sanguines dans l'aire opaque des embryons de canard. *C. R. Soc. Biol.*, T. 62, p. 762.
 1907 b Remarques sur le développement des vaisseaux et du sang dans l'aire vasculaire de l'embryon du canard. *C. R. Soc. Anat.*, Lille, 1907, p. 18.
 1914 Inclusion mixté a la gelatin et a la paraffine. *Bibliog. Anat.*, T. 14, p. 146.
- WEIDENREICH, F. 1911 Die Leucocyten und verwandte Zellformen. Wiesbaden, 1911.
- WERZBERG, A. Studien zur vergleichenden Haemocytologie einiger poikilothermer Vertebraten. *Folia Haemat.*, Bd. 11, S. 17.

PLATE

PLATE 1

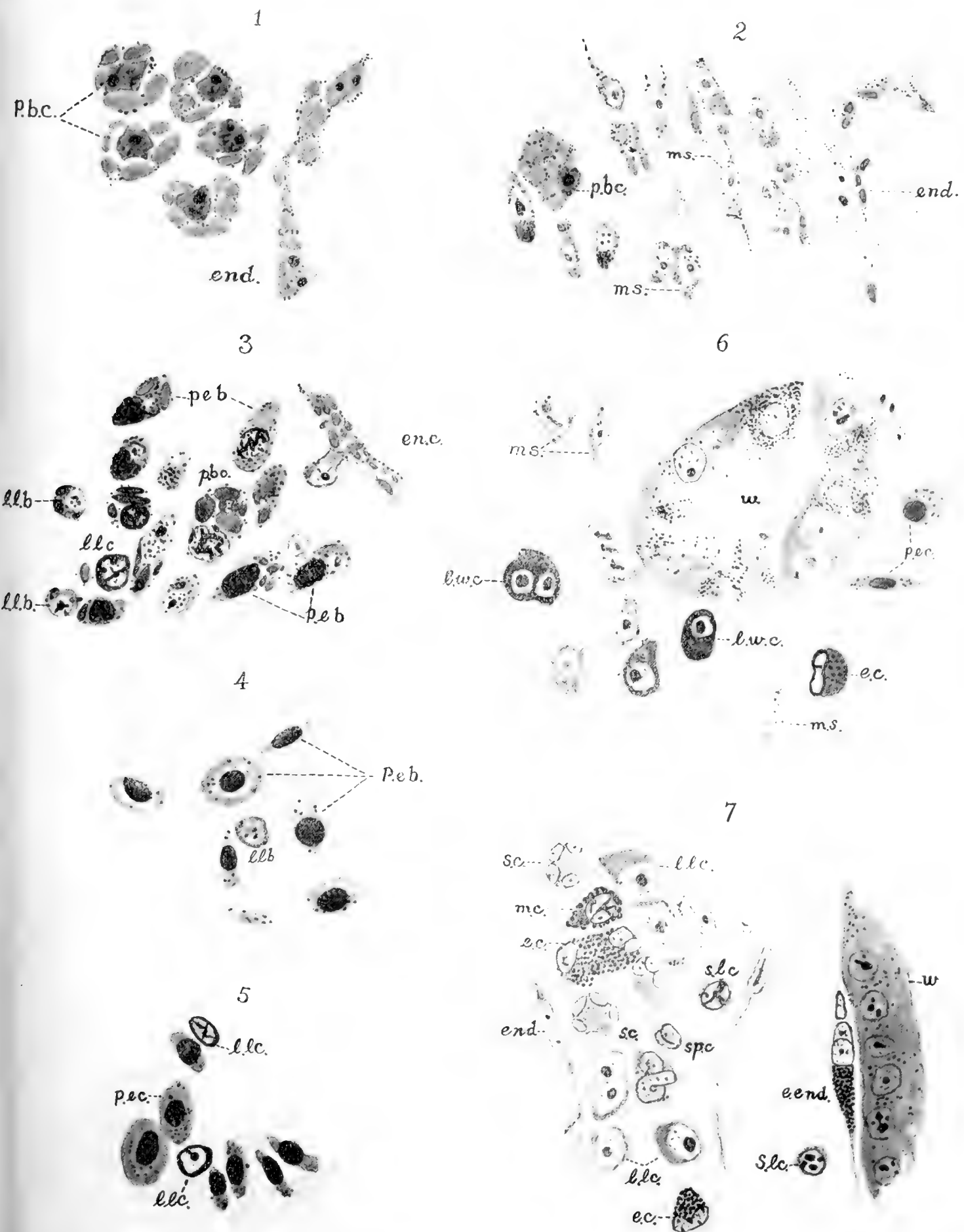EXPLANATION OF FIGURES

All the figures represent preparations stained with eosin-azure II, and are drawn with the camera, using a B. & L. 1/12-inch immersion objective with the 1-inch eye-piece.

- 1 Section through the ventral sinus of a 3.5- to 4-mm. larva.
- 2 Head mesenchyme of a 3.5- to 4-mm. larva.
- 3 Section through heart wall and cavity of a 5.6- to 6-mm. larva.
- 4 Erythrocytes of a 6.5- to 7-mm. larva.
- 5 Erythrocytes from the heart of an 8- to 8.5-mm. larva.
- 6 Section of the anlage of mesonephros of a 9-mm. larva.
- 7 Section through the mesonephros of a 16-mm. larva.

ABBREVIATIONS

<i>e.c.</i> , eosinophile granulocyte	<i>ms.</i> , mesenchyme cell
<i>e.end.</i> , eosinophil endothelium cell	<i>p.b.c.</i> , primitive blood-cell
<i>en.c.</i> , endocardium cell	<i>p.eb.</i> , primitive erythroblast
<i>end.</i> , endothelium cell	<i>p.ec.</i> , primitive erythrocyte
<i>l.lb.</i> , large lymphoblast	<i>s.c.</i> , special cell
<i>l.lc.</i> , large lymphocyte	<i>s.lc.</i> , small lymphocyte
<i>l.w.c.</i> , lymphoid wandering cell	<i>sp.c.</i> , spindle cell
<i>m.c.</i> , mast cell	<i>w.</i> , mesonephric tubule



Resumen por el autor, Henry H. Donaldson.
Instituto Wistar de Anatomía y Biología.

Estudios cuantitativos sobre el crecimiento del esqueleto en la
rata albina.

Los huesos pertenecientes a los esqueletos de 106 ratas albinas de edad variable, desde el nacimiento a los 500 días, fueron preparados por maceración en "Gold Dust"—una lejía sólida—, y después pesados y medidos en estado fresco, después de secos a la temperatura del laboratorio y a la de la estufa, pudiéndose determinar de este modo la cantidad de agua contenida en los estados primero y segundo. El autor ha seguido el aumento de peso de cada hueso o grupo de huesos y su relación con el peso del cuerpo y el peso total del esqueleto, así como el aumento en la longitud de los huesos largos comparada con la longitud del cuerpo. Las proporciones del esqueleto adulto tienden a fijarse próximamente durante la lactancia y los pesos y longitudes de algunos de los huesos largos pronto alcanzan una relación fija con el peso de todo el cuerpo o el del esqueleto, de tal modo que estos últimos valores pueden inferirse por los hallados en un solo hueso. El autor nota el cambio de forma de los huesos largos durante el crecimiento y hace algunas comparaciones con los datos referentes al hombre. Las tablas incluidas suministran valores de referencia con los cuales pueden compararse los correspondientes a ratas criadas bajo diversas condiciones.

Translation by José F. Nonidez
Carnegie Institution of Washington

QUANTITATIVE STUDIES ON THE GROWTH OF THE SKELETON OF THE ALBINO RAT

HENRY H. DONALDSON

WITH THE ASSISTANCE OF SARA B. CONROW

The Wistar Institute of Anatomy and Biology

TWENTY-THREE CHARTS

INTRODUCTION

In the following pages we shall describe several quantitative growth changes in the skeleton of the albino rat between birth and maturity. This investigation is a study of bones as part of the entire mammalian body, and not of bone as a special tissue, and this limitation of the problem explains the method of procedure.

For the 'ligamentous' skeleton of the albino rat we have the data of Jackson and Lowrey ('12) based on seven age groups. The skeleton, as prepared by these investigators, consisted of the bones, plus the cartilages and ligaments, which remained after the muscles had been rapidly dissected away from these parts in the fresh state. Their study dealt with the entire skeleton as one of the tissue systems. It has seemed to us, however, desirable to study also the skeleton as represented by the bones alone, because this would admit of dealing with the bones in detail, and also would give material which sooner or later could be compared with the corresponding material from man.

It is the main purpose of this study, therefore, to furnish data on the skeleton and its parts in albino rats of different body weights and of different ages, presenting these data in such a form that they can fairly be compared with any new set of values taken from other rats examined by similar methods.

MATERIAL

From albino rats between birth and old age, 106 skeletons were prepared by Miss Conrow, the work extending from 1913 to 1917. Of these skeletons, 85 were from inbred rats taken from Dr. King's inbred series and the remainder were from stock Albinos, all the animals having been reared in the colony at The Wistar Institute under uniform food conditions. Each skeleton contains 283 bones, including and counting the teeth. In the preparations here examined there were, however, only 230 bones, prepared separately, and these in turn were weighed in twenty-eight lots, in the case of each rat.

The details concerning the composition of the skeleton and the number of bones prepared for weighing are given in Appendix 1. All these skeletons have been stored, after being dried at 96°C. for six days.

In addition to this series of entire skeletons the long bones of the limbs were similarly prepared from 54 young albino rats (males 32, females 22; body weight 5 to 86 grams; age, birth to 64 days) and the data on these bones were combined in tables 8, 9, 11 to 14, 20, and 23 with those from the series of complete skeletons, according to body weight or to age.

With this material we purpose to show in the first instance how the entire skeleton increases in weight in relation to the total body weight and to age. Then, the growth of its several divisions and parts, 1) in relation to that of the entire skeleton, and, 2) in relation to the weight of the entire body; also the relative growth of the three divisions of the fore limbs and of the hind limbs, respectively. At the same time the change in the percentage of water with growth has been followed in both the entire skeleton and its various parts, and finally, the increase in the length of the long bones both of the fore limbs and of the hind limbs has been determined, in relation both to the body weight, to the body length, and to one another.

We hoped to discover that in some parts of the skeleton the length or weight of the bones was so well correlated with the data for the entire skeleton that it would be possible, in any instance, to compute the body length or the weight of the entire

skeleton from the value of a portion of it. Tables 9, 23, and 24 which follow show that this result has been attained.

Many series of computations and tables have been made and are complete in manuscript form, but we shall use only a portion of them for the present paper. Copies of all of the tables have been filed, however, in the archives of The Wistar Institute and are at the service of other investigators.

TECHNIQUE OF PREPARATION

For the details of the technique the reader is referred to Appendix 2. In general the procedure was as follows: The recently dissected parts of the skeletons were macerated by immersing them in 50 to 200 cc. of a hot 2 per cent solution of commercial 'Gold Dust.' This treatment left the bones from the older rats nearly unmodified as to their weight and water content.

The precise effect on the bones of rats of different body weights (=ages) are given in detail in Appendix 2.

The macerated bones were weighed in closed bottles, first fresh (i.e., immediately after maceration), then after room drying for thirty days in the open air, and finally after six days in the oven at 96°C. Where lengths were measured, these also were taken in the three conditions of moisture. All the determinations and computations were made separately for each rat, but the results were later combined in body-weight groups. Between 4.3 grams and 15 grams of body weight, the groups were made at 5-gram intervals, and after that at intervals of 10 grams. This arrangement yielded forty-two body-weight groups ranging from birth to 513 days of age, and from 4.3 to 485 grams in body weight.

The foregoing statements apply to all the records except those for the lengths of the long bones of the limbs. In these cases the data from the additional fifty-four rats were combined with those from the main skeleton series, with the result that in the records for bone length there were formed forty-seven, instead of forty-two, body-weight groups.

The tables, charts, and discussion which follow are based on these group values, but are presented in a modified form, as will

be explained later. The two sexes have been treated together, since there is no clear sex difference in the relative weight of the skeleton. All weights are given in grams and all lengths in millimeters, and it must be repeated that all the values recorded are those obtained after treatment with the 'Gold Dust,' which reduces the fresh weights of the bones and especially those from rats less than 100 grams in body weight or about 70 days in age, as shown in table 34, Appendix 2.

METHOD OF WEIGHING THE BONES

The bones were weighed in closed bottles on balances sensitive to 0.0001 gram. This procedure is simple and not subject to serious observational errors except for the weighing of the 'moist or fresh bones,' i.e., the bones immediately after maceration and before they are allowed to dry at all. To obtain this fresh value for the bones the effort has been made to remove, by wiping on filter-paper, all evident fluid adhering to the surface. This is readily accomplished in most cases, but the moist cranium requires special preparation before it is thus weighed.

In this case the external surfaces can be readily wiped, but it is also necessary to remove with strips of filter-paper any accumulated fluid from the nares, the bullae, and the cavity of the cranium. With due attention, however, to this preliminary preparation of the cranium, satisfactory weight data may be obtained. The moment one has to deal with dry bones, the difficulties just mentioned disappear.

ARRANGEMENT OF DATA IN THE TABLES

As the weight of the skeleton was the value to be found, the 106 rats in this series were arranged according to body weight. It is well known, however, that the observed body weight of the rat fluctuates readily, and especially in old animals, tends to fall off. In order to make the entries systematic, a fixed procedure was followed for the establishment of the normal body weight. The body length of each rat was taken, and, as this does not fluctuate with the nutritional condition of the animal, it was used as the standard.

In table 68 of 'The Rat' (Donaldson, '15) a series of normal body weights for each millimeter of body length is given for each sex. When the observed body weight of a rat fell 5 per cent or more below the table value given for the observed body length, the observed value was corrected to the table value, on the assumption that some unfavorable nutritional condition had reduced the body weight temporarily.

On the other hand, we had in the case of many of the old rats a record of their maximum body weights, reached earlier, and often well above those observed at the time of killing, and also above the table values, and in such instances the maximum body weight was that entered in the table. These two procedures eliminated from the table subnormal body-weight values.

To prevent a misuse or misinterpretation of the values given in the tables which follow, we repeat that the absolute weights given are those found after maceration in the 'Gold Dust' washing powder (Appendix 2).

This treatment reduces the weight of the bones in all cases, but especially in those rats less than 100 grams in body weight or 70 days of age. The percentage of water is also reduced somewhat. The lengths of the bones are but very slightly affected. The effects of the maceration are, however, sufficiently similar among the different bones to make determinations of relative values based on the macerated bones applicable to the perfectly fresh bones also.

The most evident need for the corrected values is in comparison between the body weight and that of the skeleton or some of its parts—since in these instances the true weights are needed to give the correct ratios—and when such ratios are desired the proper corrections must be made.

It should be added, however, that though the relative values of the skeleton and its parts, as shown in table 2 and chart 2, are somewhat modified by the use of the corrected data, yet the modification is slight and, moreover, does not affect the interpretation given to these records.

The values in our tables may be used therefore as standards for comparison with determinations from other rats, the bones of which have been macerated by the same or a similar process.

ON THE WEIGHT OF THE FRESH SKELETON AND OF ITS PARTS ON
BODY WEIGHT

In table 1 are given the absolute and relative fresh weights, as observed, for the entire skeleton and its two main divisions—the axial and appendicular skeleton (see Appendix 1 for the grouping of the bones). In charts 1 and 2 the absolute and the relative values, respectively, are plotted, the mean values being indicated by smooth graphs.

In table 1 it is the observed values which are given, while in charts 1 and 2 smoothed graphs have been so drawn that only those observed values which lie above or below the respective graphs are evident on the charts. Reading the values shown by the smoothed graphs, we obtain the data entered in table 2.

As stated earlier, the object in view is to present the data in such shape that new observations may be compared with them, and also to give some idea of the variability which is to be expected. After considering the several ways in which these ends might be attained, the following plan was adopted as the most satisfactory and usable.

All the tables appearing in this paper were first made on the basis of the observed values, either according to body weight, as in table 1, or according to body length or some other standard. The data were then charted, and on the chart a smooth graph was drawn free hand. The values given by this smoothed graph were then read at fixed intervals and tabulated, and these in turn appear, as in table 2, and in all the later tables of the same type.

In favor of this procedure are the facts that such a table, based on the smooth graph, is useful as a standard for reference, while the corresponding chart shows by means of the graphs the general character of the growth change, and by means of the entries which lie on either side of the graph, the variability of the records. The nature of the data hardly justifies an attempt at greater precision than this. Values between those given in the tables may, in all cases, be obtained by interpolation.

All the principal tables which follow are arranged on the foregoing plan, beginning with table 2, which gives the data of table 1 in this revised form.

TABLE 1

Absolute and relative fresh weights of the entire skeleton, axial skeleton, and appendicular skeleton of the albino rat, as directly observed after maceration in 'Gold Dust.' Data entered in forty-two groups according to body weight

SEX		AGE OBSERVED	BODY WEIGHT OBSERVED	BODY LENGTH OBSERVED	WEIGHT OF FRESH SKELETON ENTIRE	WEIGHT OF FRESH SKELETON ON BODY WEIGHT	AXIAL FRESH WEIGHT	FRESH AXIAL ON BODY WEIGHT	APPENDICULAR FRESH WEIGHT	FRESH APPENDICULAR ON BODY WEIGHT
Male	Female									
		days	grams	mm.	grams	per cent	grams	per cent	grams	per cent
2	2	B.	4.3	46	0.38	8.9	0.28	6.5	0.10	2.4
4	1	6	8.8	61	0.85	9.6	0.61	7.0	0.24	2.6
	2	19	16.4	83	1.78	10.9	1.08	6.5	0.70	4.4
4		23	24.4	95	2.23	9.1	1.4	5.7	0.84	3.4
1	1	25	35.6	107	3.18	9.0	2.0	5.6	1.2	3.4
2	1	33	45.5	119	3.56	7.8	2.2	4.8	1.4	3.0
2	1	37	53.9	127	4.02	7.5	2.4	4.5	1.6	3.0
2	1	51	65.5	137	5.07	7.7	3.1	4.7	2.0	3.0
	1	46	77.1	140	5.00	6.5	3.0	3.9	2.0	2.6
1	1	54	84.0	150	5.86	7.0	3.5	4.2	2.3	2.8
	2	91	95.0	157	7.08	7.5	4.5	4.7	2.6	2.8
1	1	83	106.0	163	7.24	6.8	4.4	4.1	2.8	2.7
	2	153	116.0	168	8.55	7.4	5.6	4.8	3.0	2.6
1	1	106	127.0	169	8.16	7.0	5.1	4.0	3.1	3.0
	2	120	144.0	182	10.30	7.2	6.5	4.5	3.8	2.7
3	1	103	156.0	182	9.85	6.3	6.0	3.8	3.8	2.5
2	1	109	174.0	186	10.85	6.2	6.7	3.8	4.1	2.4
2	2	232	195.0	196	12.32	6.2	8.0	4.1	4.3	2.1
1	1	227	205.0	198	12.24	6.0	7.9	3.8	4.3	2.2
	2	390	215.0	198	13.43	6.2	8.7	4.0	4.7	2.2
1	3	283	223.0	202	13.46	6.0	8.7	3.9	4.8	2.1
1	1	328	233.0	207	14.18	6.1	9.1	3.9	5.1	2.2
	2	448	242.0	204	14.04	5.8	9.0	3.7	5.0	2.1
	2	499	256.0	210	15.77	6.2	10.3	4.0	5.4	2.2
2		213	268.0	217	15.90	5.9	10.1	3.8	5.8	2.1
1	1	304	275.0	215	16.06	5.8	10.2	3.7	5.9	2.1
1	1	411	283.0	218	17.14	6.0	11.0	3.8	6.1	2.2
5		367	293.0	218	16.74	5.7	10.7	3.6	6.1	2.1
2		393	303.0	219	16.85	5.6	10.7	3.5	6.2	2.1
2	1	403	325.0	221	18.80	5.8	12.0	3.7	6.8	2.1
1		489	336.0	226	19.53	5.8	12.5	3.7	7.0	2.1
3	1	450	343.0	225	19.59	5.7	12.6	3.7	7.0	2.0
1		474	355.0	228	19.51	5.5	12.5	3.5	7.0	2.0
1		513	366.0	230	19.42	5.3	12.5	3.4	6.9	1.9
2		469	375.0	235	19.98	5.3	12.6	3.4	7.3	1.9
1		477	397.0	237	20.10	5.1	12.8	3.2	7.3	1.9
4		435	404.0	240	21.32	5.3	13.5	3.4	7.8	1.9
3		321	414.0	226	21.20	5.1	13.4	3.2	7.8	1.9
3		393	430.0	238	22.93	5.3	14.2	3.4	8.8	1.9
3		474	444.0	239	23.48	5.3	15.1	3.4	8.3	1.9
2		460	461.0	251	24.29	5.3	15.5	3.3	8.8	2.0
1		453	485.0	246	23.48	4.8	14.6	3.0	8.9	1.8

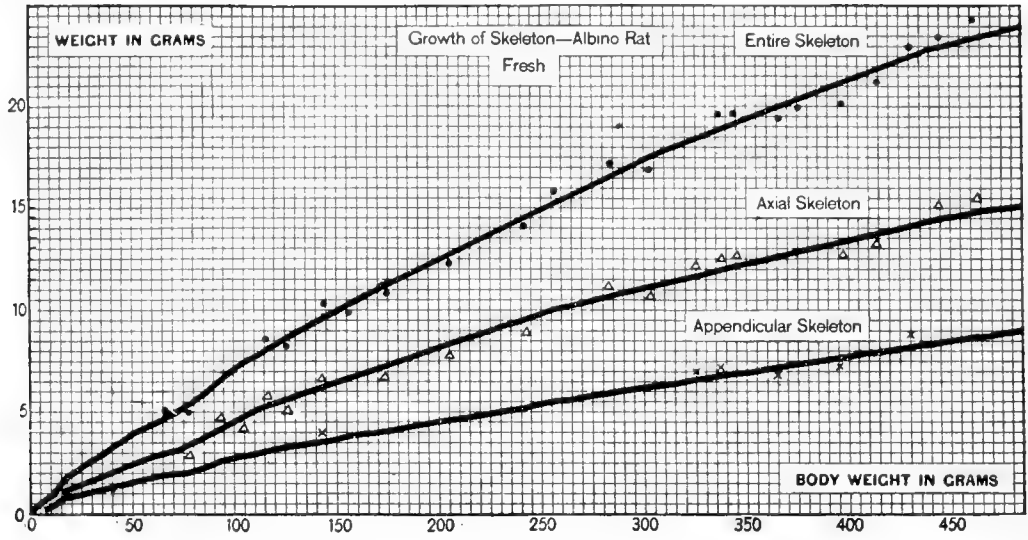


Chart 1 Absolute fresh weight of entire skeleton, axial skeleton, and appendicular skeleton in grams, on the body weight (albino rat). Table 2.

● Entire skeleton. △ Axial skeleton. × Appendicular skeleton.

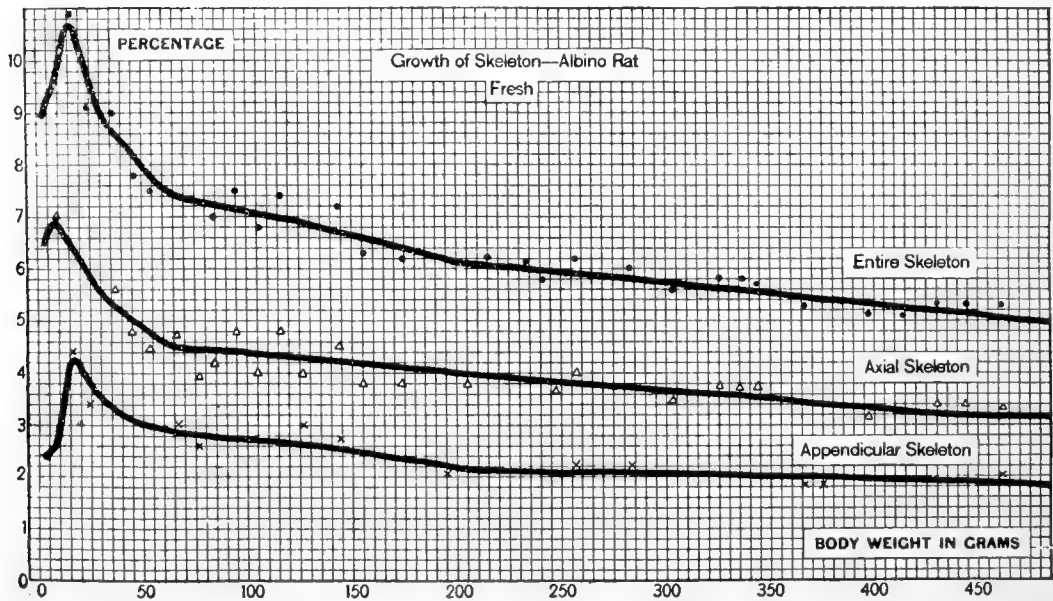


Chart 2 Relative fresh weight of entire skeleton, axial skeleton, and appendicular skeleton, on body weight (albino rat). Table 2.

● Entire skeleton. △ Axial skeleton. × Appendicular skeleton.

TABLE 2

Absolute and relative fresh weights of entire skeleton, axial skeleton, and appendicular skeleton, on body weight. From smoothed graphs in charts 1 and 2

BODY WEIGHT	FRESH SKELETON WEIGHT	WEIGHT OF FRESH SKELETON ON BODY WEIGHT	AXIAL FRESH WEIGHT	FRESH AXIAL ON FRESH BODY WEIGHT	APPENDICULAR FRESH WEIGHT	FRESH APPENDICULAR ON BODY WEIGHT
<i>grams</i>	<i>grams</i>	<i>per cent</i>	<i>grams</i>	<i>per cent</i>	<i>grams</i>	<i>per cent</i>
5	0.46	9.20	0.34	6.70	0.12	2.50
10	0.99	9.90	0.69	6.87	0.30	3.03
15	1.59	10.61	0.98	6.53	0.61	4.08
20	2.06	10.30	1.24	6.20	0.82	4.10
25	2.40	9.60	1.48	5.90	0.92	3.70
30	2.70	9.01	1.68	5.59	1.02	3.42
35	3.06	8.73	1.87	5.33	1.19	3.40
40	3.39	8.47	2.08	5.20	1.31	3.27
45	3.69	8.20	2.26	5.03	1.43	3.17
50	4.00	8.00	2.44	4.88	1.56	3.12
55	4.27	7.77	2.62	4.77	1.65	3.00
60	4.54	7.57	2.76	4.60	1.78	2.97
65	4.83	7.43	2.94	4.53	1.89	2.90
70	5.16	7.37	3.15	4.50	2.01	2.87
75	5.48	7.30	3.35	4.47	2.13	2.83
80	5.82	7.27	3.55	4.44	2.27	2.83
85	6.12	7.20	3.75	4.41	2.37	2.79
90	6.48	7.20	3.96	4.40	2.52	2.80
95	6.81	7.17	4.18	4.40	2.63	2.77
100	7.10	7.10	4.39	4.39	2.71	2.71
110	7.71	7.01	4.79	4.35	2.92	2.66
120	8.33	6.94	5.16	4.30	3.17	2.64
130	8.93	6.87	5.55	4.27	3.38	2.60
140	9.48	6.77	5.91	4.22	3.57	2.55
150	10.00	6.67	6.30	4.20	3.70	2.47
160	10.51	6.57	6.69	4.18	3.82	2.39
170	11.00	6.47	7.02	4.13	3.98	2.34
180	11.47	6.37	7.33	4.07	4.14	2.30
190	11.84	6.23	7.66	4.03	4.18	2.20
200	12.34	6.17	8.00	4.00	4.34	2.17
210	12.81	6.10	8.38	3.99	4.43	2.11
220	13.31	6.05	8.71	3.96	4.60	2.09
230	13.80	6.00	8.99	3.91	4.81	2.09
240	14.35	5.98	9.34	3.89	5.01	2.09
250	14.83	5.93	9.63	3.85	5.20	2.08
270	15.80	5.85	10.21	3.78	5.59	2.07
290	16.76	5.78	10.79	3.72	5.97	2.06
310	17.58	5.67	11.22	3.62	6.36	2.05
330	18.48	5.60	11.85	3.59	6.63	2.01
350	19.32	5.52	12.36	3.53	6.96	1.99
370	20.02	5.41	12.65	3.42	7.37	1.99
390	20.94	5.37	13.22	3.39	7.72	1.98
410	21.61	5.27	13.53	3.30	8.08	1.97
430	22.32	5.19	13.89	3.23	8.43	1.96
450	22.95	5.10	14.40	3.20	8.55	1.90
470	23.55	5.01	14.95	3.18	8.60	1.83
485	24.20	4.99	15.37	3.17	8.83	1.82

Turning now to an examination of the tables¹ and charts it is seen that the absolute increase in the weight of the skeleton (chart 1) is somewhat rapid at first; indeed, the data (table 2) show that up to 15 grams of body weight the skeleton grows more rapidly than the rest of the body (chart 2), and as a result its relative weight increases; but after that the growth is slower, so that the value of the skeleton weight (observed) on the body weight falls (table 2) from 10.6 per cent at a body weight of 15 grams to about 5 per cent at a body weight of 485 grams. If the weights of the skeleton are corrected for the action of the macerating fluid (table 34, Appendix 2) then the foregoing percentages become, respectively, 12 per cent and 5.2 per cent.

On looking at the graphs and tables for the axial and appendicular skeletons, we see that the weight of the appendicular is always smaller than that of the axial skeleton, but after a body weight of 15 grams, the graphs for relative weights of the two portions (chart 2) are nearly similar in their general course. The mature relations between the two parts of the skeleton are attained therefore at about twenty-two days, which is shortly before the time of weaning.

The striking feature in this last comparison is the approximate constancy in the weight relations of the two divisions of the skeleton from an early age, although the appendicular division grows just a trifle more slowly than the axial; falling, with slight fluctuations, from 62 per cent of the axial skeleton at 15 grams to 57 per cent at 485 grams, as shown by the values in Table 2.

¹ Intervals used in tables.

On body length: up to 95 mm. of body length values are given at intervals of 2.5 mm. From 95 mm. to 195 mm. at intervals of 5 mm. Above 195 mm. at intervals of 10 mm.

On body weight: up to 100 grams of body weight values are given at intervals of 5 grams. From 100 grams to 250 grams at intervals of 10 grams. Above 250 grams at intervals of 20 grams. The last interval is 15 grams.

On skeleton weight: up to 7 grams of skeleton weight values are given at intervals of 0.25 gram. Above 7 grams at intervals of 1 gram. Special intervals are used in tables 6 and 7 giving the proportional weights of parts of the limbs.

Values falling between those entered in the tables may be obtained by simple interpolation.

ON THE WEIGHT OF THE CRANIUM—FRESH, ROOM-DRIED, AND OVEN-DRIED (CRANIUM = SKULL WITHOUT MANDIBLES)

The determinations have been made in this case in all three conditions of moisture, as the weight of the cranium has significance not only as a part of the skeleton, but also indirectly as an index of cranial capacity and therefore of brain weight. The data from the smoothed graphs are given in table 3 and the graphs in chart 3.

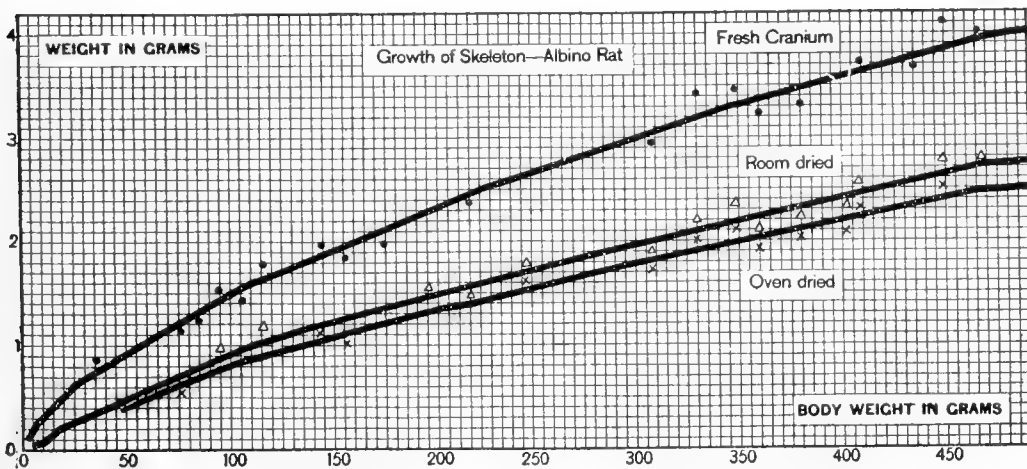


Chart 3 Absolute weight of the cranium—fresh, room-dried and oven-dried—on body weight (albino rat). Table 3.

● Fresh. △ Room dried. × Oven dried.

The form of the graphs does not call for special comment, but a comparison of the initial values with those later in the series shows that the cranium is increasing in weight at only about two-fifths of the rate of the entire skeleton.

ON THE WEIGHTS OF THE DIVISIONS OF THE APPENDICULAR SKELETON

Turning now to the two divisions of the appendicular skeleton, it is possible to compare the shoulder-girdle plus appendages with the pelvic girdle plus appendages, in their respective relations to the body weight. This has been done in table 4, and both the absolute and relative values on body weight are given in charts 4 and 5. A study of these data shows plainly that

TABLE 3

*Absolute weight of cranium—fresh, room-dried, and oven-dried—on body weight.
Values from the smoothed graphs in chart 3*

BODY WEIGHT	FRESH	ROOM-DRIED	OVEN-DRIED
<i>grams</i>	<i>grams</i>	<i>grams</i>	<i>grams</i>
5	0.19	0.04	0.04
10	0.32	0.09	0.08
15	0.42	0.14	0.13
20	0.51	0.20	0.18
25	0.61	0.24	0.22
30	0.67	0.27	0.25
35	0.72	0.32	0.29
40	0.78	0.36	0.33
45	0.83	0.41	0.37
50	0.89	0.45	0.41
55	0.94	0.49	0.45
60	1.00	0.54	0.49
65	1.05	0.58	0.53
70	1.11	0.63	0.57
75	1.17	0.66	0.60
80	1.22	0.71	0.65
85	1.28	0.76	0.69
90	1.33	0.80	0.73
95	1.39	0.85	0.77
100	1.44	0.89	0.81
110	1.56	0.96	0.87
120	1.67	1.01	0.92
130	1.75	1.06	0.97
140	1.83	1.12	1.02
150	1.92	1.18	1.08
160	2.00	1.23	1.12
170	2.08	1.29	1.18
180	2.17	1.35	1.23
190	2.24	1.40	1.28
200	2.32	1.47	1.34
210	2.41	1.51	1.38
220	2.50	1.56	1.42
230	2.56	1.61	1.47
240	2.62	1.67	1.52
250	2.69	1.72	1.57
270	2.82	1.83	1.67
290	2.96	1.93	1.76
310	3.09	2.02	1.84
330	3.22	2.11	1.92
350	3.34	2.20	2.01
370	3.44	2.29	2.09
390	3.55	2.38	2.17
410	3.66	2.47	2.25
430	3.77	2.57	2.34
450	3.88	2.65	2.42
470	3.97	2.72	2.48
485	4.01	2.74	2.50

just at birth the pelvic girdle plus appendages is relatively poorly developed, but it at once begins to grow more rapidly than the shoulder-girdle and appendages, and after the first few days forms the larger fraction of the entire body. The mature

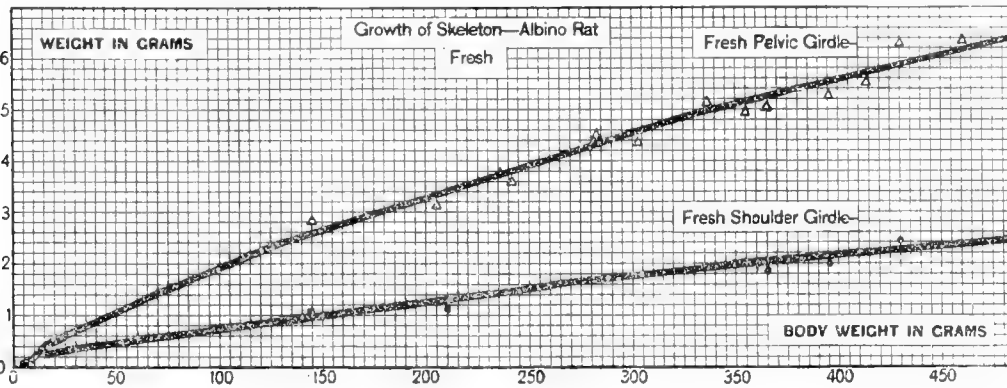


Chart 4 Absolute fresh weight of shoulder-girdle plus fore limbs and pelvic girdle plus hind limbs, on body weight (albino rat). Table 4.

● Shoulder-girdle plus limbs. △ Pelvic girdle plus limbs.

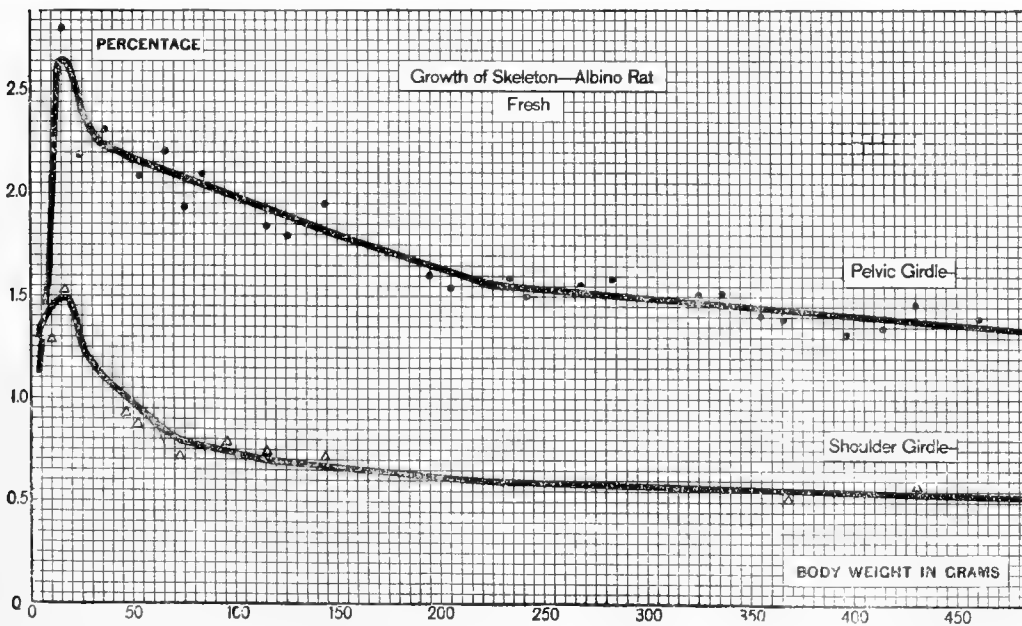


Chart 5 Relative fresh weight of shoulder-girdle plus limbs and of pelvic girdle plus limbs, on body weight (albino rat). Table 4.

● Pelvic girdle plus limbs. △ Shoulder-girdle plus limbs.

relations between the two divisions are established at puberty (body weight, 100 grams).

This completes the presentation for the weight of the fresh skeleton and its parts considered in relation to the weight of the body.

TABLE 4

Absolute and relative fresh weights of shoulder-girdle with fore limbs and pelvic girdle with hind limbs, on body weight. Values from the smoothed graphs in charts 4 and 5

BODY WEIGHT	WEIGHT SHOULDER-GIRDLE AND FORE LIMBS	SHOULDER-GIRDLE AND FORE LIMBS	WEIGHT PELVIC GIRDLE AND HIND LIMBS	PELVIC GIRDLE AND HIND LIMBS
<i>grams</i>	<i>grams</i>	<i>per cent</i>	<i>grams</i>	<i>per cent</i>
5	0.068	1.35	0.052	1.15
10	0.137	1.37	0.163	1.66
15	0.215	1.43	0.395	2.65
20	0.300	1.50	0.520	2.60
25	0.323	1.29	0.597	2.41
30	0.354	1.18	0.666	2.24
35	0.389	1.11	0.801	2.23
40	0.416	1.04	0.894	2.23
45	0.437	0.97	0.993	2.21
50	0.475	0.95	1.085	2.17
55	0.490	0.89	1.160	2.11
60	0.510	0.85	1.270	2.11
65	0.540	0.83	1.350	2.07
70	0.567	0.81	1.443	2.06
75	0.593	0.79	1.537	2.04
80	0.632	0.79	1.638	2.04
85	0.646	0.76	1.724	2.03
90	0.684	0.76	1.836	2.02
95	0.713	0.75	1.917	2.02
100	0.730	0.73	1.980	1.98
110	0.792	0.72	2.128	1.94
120	0.852	0.71	2.318	1.93
130	0.897	0.69	2.483	1.91
140	0.966	0.69	2.604	1.86
150	1.005	0.67	2.695	1.80
160	1.040	0.65	2.780	1.74
170	1.088	0.64	2.892	1.70
180	1.134	0.63	3.006	1.67
190	1.140	0.60	3.040	1.60
200	1.180	0.59	3.160	1.58
210	1.197	0.57	3.233	1.54
220	1.232	0.56	3.368	1.53
230	1.288	0.56	3.522	1.53
240	1.344	0.56	3.666	1.53
250	1.400	0.56	3.800	1.52
270	1.512	0.56	4.078	1.51
290	1.624	0.56	4.346	1.50
310	1.736	0.56	4.624	1.49
330	1.815	0.55	4.815	1.46
350	1.925	0.55	5.035	1.45
370	2.035	0.55	5.335	1.44
390	2.145	0.55	5.575	1.43
410	2.255	0.55	5.825	1.42
430	2.365	0.55	6.065	1.41
450	2.385	0.53	6.165	1.37
470	2.397	0.51	6.203	1.34
485	2.474	0.51	6.356	1.33

GROWTH OF SKELETON IN WEIGHT ON AGE

Although the determination of the skeleton weight according to age was not specially considered in this study, yet the series yields data which can be used to show this relation. If we consider the body weights as they appear in table 1 to be normal for age, the data in table 74 (Donaldson, '15) being taken as the standard, then between birth and 365 days the first twenty-seven groups can be used for the males and the first twenty-two groups for the females. The data are presented in table 5. When these data for the weight of the fresh skeleton are plotted for each sex on the base line for age, there appear the smooth graphs shown in chart 6.

It is the form of these graphs which is of value, for they show that in both the male and the female the graph for the weight of the fresh skeleton is sinuous and very similar to the graph for the weight of the entire body on age (Donaldson, '06) despite the fact already noted that after the first few days of life the relative weight of the skeleton is continually diminishing.

While the form of the graph is trustworthy the absolute values for the weight of the skeleton at the given ages are peculiar to these data and not general, and therefore should be used for comparison only with caution. The smaller absolute weight of the skeleton in the female goes, as the tables show, with the smaller body weight at the several ages.

Tables 1 to 5 and charts 1 to 6 show in a general way the growth in the weight of the skeleton and its larger parts on body weight and age. We pass now to some of the smaller divisions of the skeleton.

ON THE GROWTH OF THE PARTS OF THE LIMBS

Our records permit us to determine the manner in which each of the three divisions of the limbs increases in weight. Table 6 shows the weight of all the bones in both fore limbs and also the percentage values for the humerus (2), ulna plus radius (2), and carpus plus fore foot (2) at intervals of 0.02 gram, while table 7

gives the same information for the corresponding divisions of both hind limbs at intervals of 0.05 gram.²

Chart 7 gives the smoothed graphs for the relative weights of the three divisions of the fore limbs on the weight of the bones of both fore limbs, and chart 8 the smoothed graphs for the corresponding divisions of the hind limbs on the weight of the bone of both hind limbs. The outstanding relations shown by these graphs are the similar behavior of the corresponding bones within

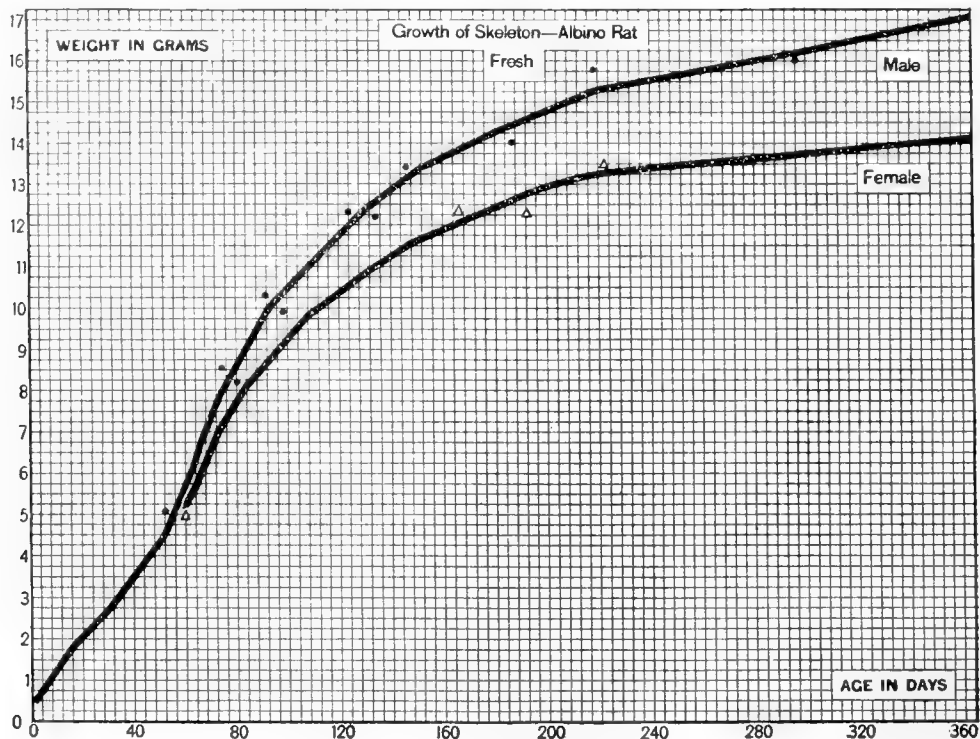

Chart 6 Absolute weight of entire fresh skeleton on age—according to sex (albino rat). Table 5.

● Males. △ Females.

each limb and the continued relative growth of the first two segments of the limb as contrasted with the behavior of the most distal segment, which in both cases diminishes in its relative weight during all the later portion of the growth period—i.e., after a limb bone weight of 0.22 gram for the fore limbs (table 6) and 0.45 gram for the hind limbs (table 7). In the fore limb

² The sign (2) after any paired bone indicates that the value given in the table applies to the two bones (right and left) taken together, although the designation of the bone is in the singular number.

TABLE 5

Absolute weight of fresh skeleton, on age (males and females). Values from the smoothed graphs in chart 6

AGE	MALES	FEMALES
<i>days</i>	<i>grams</i>	<i>grams</i>
0	0.35	0.35
4	0.75	0.75
8	1.10	1.10
12	1.45	1.45
16	1.80	1.80
20	2.08	2.08
24	2.34	2.34
28	2.57	2.57
32	2.88	2.88
36	3.20	3.20
40	3.50	3.50
44	3.85	3.85
48	4.15	4.15
52	4.50	4.50
56	5.10	4.85
60	5.70	5.25
64	6.30	5.70
68	7.05	6.30
72	7.65	6.90
76	8.15	7.32
80	8.60	7.75
84	9.05	8.15
88	9.50	8.40
92	9.94	8.73
96	10.24	9.01
100	10.50	9.33
110	11.13	9.92
120	11.75	10.38
130	12.35	10.82
140	12.83	11.25
150	13.32	11.62
160	13.65	11.89
170	13.97	12.18
180	14.25	12.45
190	14.50	12.72
200	14.77	12.92
210	15.05	13.12
220	15.30	13.25
230	15.41	13.34
240	15.51	13.40
250	15.63	13.46
270	15.87	13.56
290	16.11	13.72
310	16.38	13.82
330	16.63	13.94
350	16.89	14.05

both the proximal and the middle segments show the same relative increase in weight, between the terminal values, while in

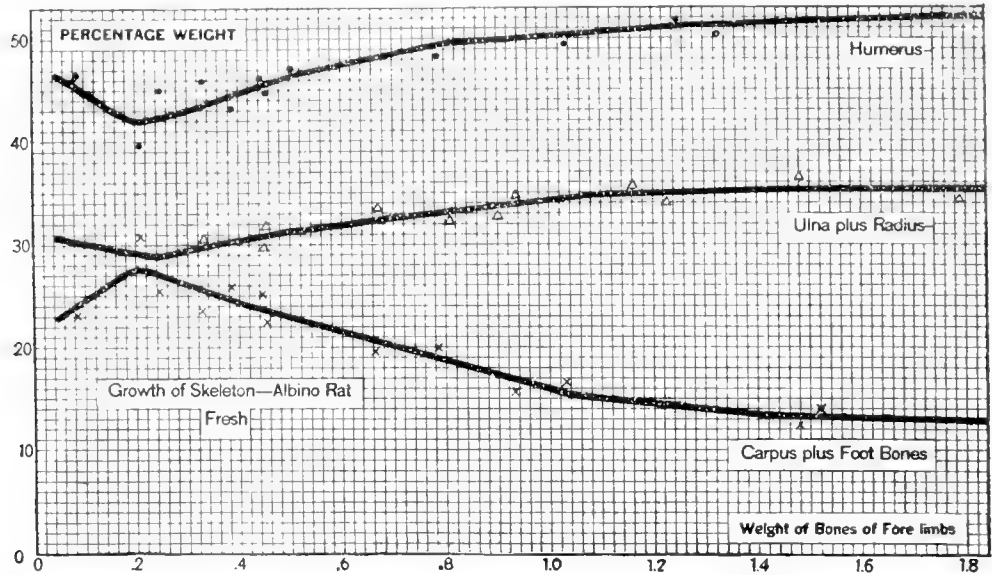


Chart 7 Relative fresh weight of the fore-limb bones, on the weight of all the bones composing the fore limb (albino rat). Table 6.

● Humerus. △ Ulna plus radius. × Carpus plus foot bones.

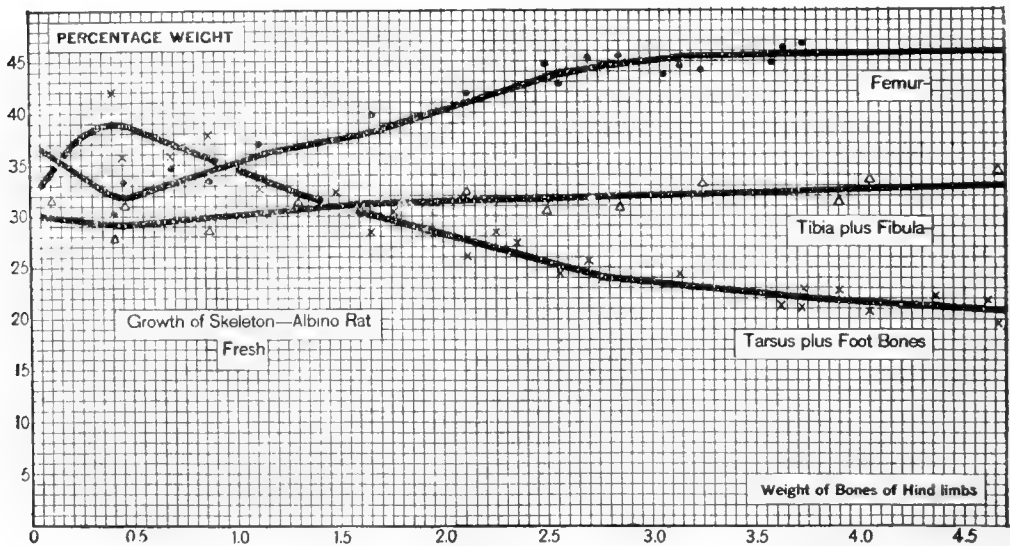


Chart 8 Relative fresh weight of the hind-limb bones, on the weight of all of the bones composing the hind limb (albino rat). Table 7.

● Femur. △ Tibia and fibula. × Tarsus and foot bones.

the hind limb the greater increase is shown by the proximal segment, the femur.

The first column in both table 6 and table 7 gives the body weights to which the respective bone weights correspond.

TABLE 6

Percentage weight of fresh fore-limb bones represented by the humerus, ulna plus radius, and carpus plus foot bones, on the weight of all of the bones of the fore limb. Entered at intervals of 0.02 gram. Values taken from the smoothed graphs in chart 7. The corresponding body weights are also given

BODY WEIGHT	WEIGHT OF FRESH FORE-LIMB BONES (2)	HUMERUS (2)	ULNA PLUS RADIUS (2)	FORE FOOT (2)
<i>grams</i>	<i>grams</i>	<i>per cent</i>	<i>per cent</i>	<i>per cent</i>
6.0	0.06	46.1	30.5	23.4
8.0	0.08	45.5	30.3	24.2
9.0	0.10	44.8	30.1	25.1
11.0	0.12	44.1	29.9	26.0
13.0	0.14	43.5	29.7	26.8
15.0	0.16	42.9	29.4	27.7
17.0	0.18	42.3	29.2	28.5
19.0	0.20	42.1	29.0	28.9
20.0	0.22	42.1	28.8	29.1
22.0	0.24	42.2	28.9	28.9
26.0	0.26	42.4	29.0	28.6
31.0	0.28	42.7	29.2	28.1
35.0	0.30	43.0	29.4	27.6
39.0	0.32	43.3	29.6	27.1
43.1	0.34	43.7	29.9	26.4
48.0	0.36	43.9	30.0	26.1
52.0	0.38	44.3	30.2	25.5
56.0	0.40	44.6	30.4	25.0
69.0	0.46	45.6	31.0	23.4
78.0	0.50	46.3	31.3	22.4
87.0	0.54	46.7	31.5	21.8
95.0	0.58	47.2	31.8	21.0
103.1	0.62	47.6	32.0	20.4
114.0	0.66	48.0	32.2	19.8
126.0	0.70	48.4	32.5	19.1
137.0	0.74	48.9	32.8	18.3
148.0	0.78	49.3	33.0	17.7
76.0	0.88	49.8	33.5	16.7
203.1	0.98	50.1	34.1	15.8
231.0	1.08	50.5	34.7	14.8
260.0	1.18	50.9	34.9	14.2
294.0	1.28	51.2	35.0	13.8
328.0	1.38	51.4	35.1	13.5
361.0	1.48	51.6	35.2	13.2
394.0	1.58	51.7	35.2	13.1
428.0	1.68	51.9	35.2	12.9
482.0	1.84	52.0	35.3	12.7

TABLE 7

Percentage weight of fresh hind-limb bones represented by the femur, tibia plus fibula, and tarsus plus foot bones, on the weight of all of the bones of the hind limb. Entered at intervals of 0.05 gram. Values taken from the smoothed graphs in chart 8. The corresponding body weights are also given

BODY WEIGHT	WEIGHT OF FRESH HIND-LIMB BONES (2)	FEMUR (2)	TIBIA PLUS FIBULA (2)	HIND FOOT (2)
<i>grams</i>	<i>grams</i>	<i>per cent</i>	<i>per cent</i>	<i>per cent</i>
5.0	0.05	36.6	30.0	33.4
7.0	0.10	36.0	29.9	34.1
9.0	0.15	35.3	29.7	35.0
11.0	0.20	34.7	29.6	35.7
12.0	0.25	34.0	29.5	36.5
14.1	0.30	33.3	29.4	37.3
16.1	0.35	32.7	29.2	38.1
19.0	0.40	32.1	29.1	38.8
21.0	0.45	32.0	29.2	38.8
24.0	0.50	32.0	29.2	38.8
27.0	0.55	32.3	29.3	38.4
30.0	0.60	32.7	29.4	37.9
33.1	0.65	33.0	29.5	37.5
37.0	0.70	33.3	29.6	37.1
40.0	0.75	33.6	29.6	36.8
43.1	0.80	33.9	29.7	36.4
57.0	1.00	35.1	30.1	34.8
71.0	1.20	36.3	30.4	33.3
87.0	1.40	37.1	30.7	32.2
106.0	1.60	37.8	31.2	31.0
126.0	1.80	39.0	31.3	29.7
148.0	2.00	40.3	31.4	28.3
175.0	2.20	41.5	31.5	27.0
214.0	2.50	43.4	31.6	25.0
250.0	2.80	44.5	31.8	23.7
285.0	3.10	45.3	32.0	22.7
321.0	3.40	45.4	32.2	22.4
356.0	3.70	45.5	32.4	22.1
392.0	4.00	45.7	32.6	21.7
426.0	4.30	45.8	32.8	21.4
467.0	4.65	45.9	33.0	21.1

INCREASE IN THE WEIGHT OF THE LONG BONES

A. According to skeleton weight

If we turn now to the growth of the humerus (2), the ulna plus radius (2), and to that of the femur (2) and tibia plus fibula (2), it seems best to follow the increase in these bones in weight first in relation to the weight of the skeleton. Tables 8 and 9 give the data for the absolute and relative fresh bone weights on skeleton weight. In charts 9 and 10 the corresponding graphs are drawn.

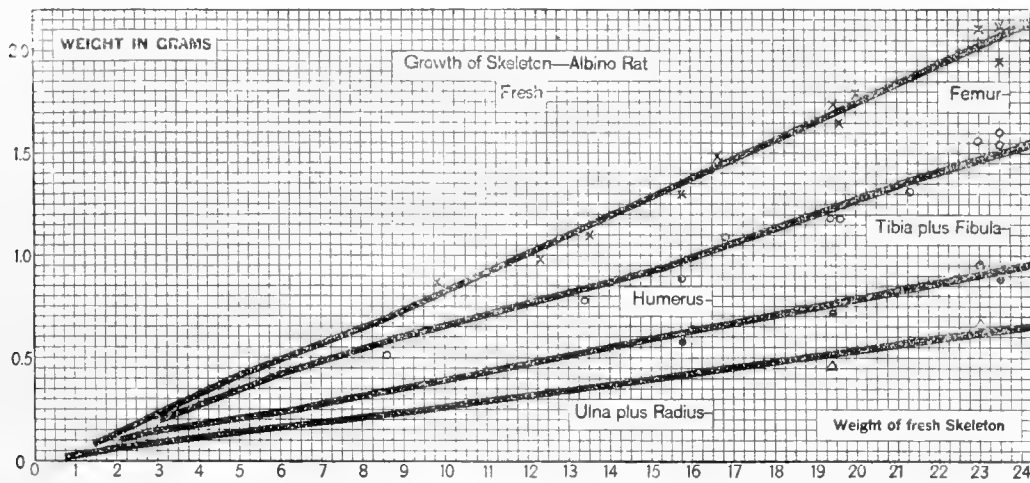


Chart 9 Absolute fresh weight of the limb bones, on the weight of the fresh skeleton (albino rat). Table 8.

× Femur. ○ Tibia plus fibula. ● Humerus. △ Ulna plus radius.

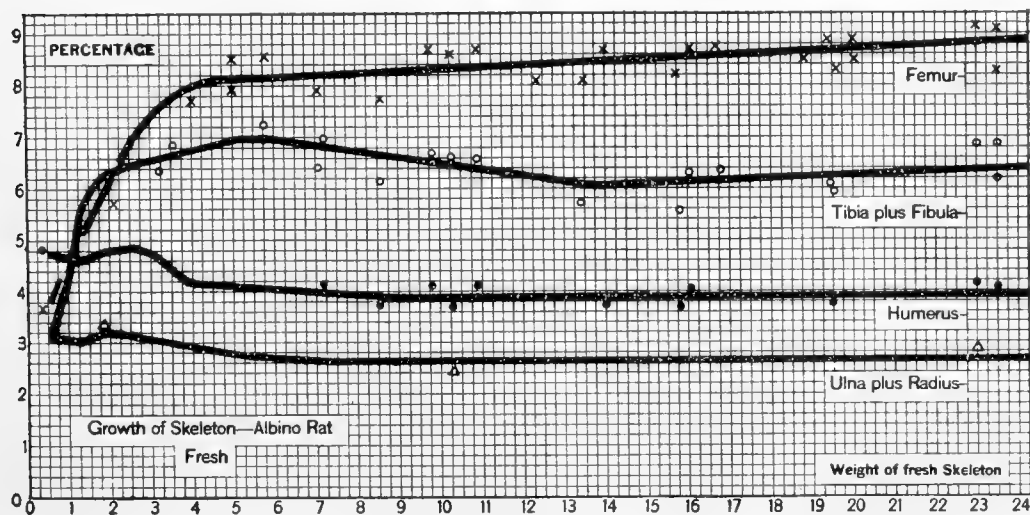


Chart 10 Relative weight of the fresh limb bones, on the weight of the fresh skeleton (albino rat). Table 9.

× Femur. ○ Tibia plus fibula. ● Humerus. △ Ulna plus radius.

TABLE 8

Absolute fresh weight of humerus, ulna plus radius, femur, and tibia plus fibula on the weight of the fresh skeleton. Values taken from the smoothed graphs in chart 9

WEIGHT OF FRESH SKELETON	HUMERUS (2)	ULNA PLUS RADIUS (2)	FEMUR (2)	TIBIA PLUS FIBULA (2)
<i>grams</i>	<i>grams</i>	<i>grams</i>	<i>grams</i>	<i>grams</i>
0.50	0.024	0.016	0.019	0.015
0.75	0.035	0.023	0.031	0.027
1.00	0.047	0.037	0.045	0.043
1.25	0.058	0.043	0.061	0.069
1.50	0.070	0.057	0.088	0.088
1.75	0.084	0.055	0.120	0.110
2.00	0.096	0.064	0.137	0.126
2.25	0.108	0.072	0.151	0.143
2.50	0.121	0.079	0.170	0.160
2.75	0.132	0.086	0.200	0.176
3.00	0.142	0.092	0.220	0.194
3.25	0.150	0.100	0.249	0.214
3.50	0.155	0.105	0.270	0.233
3.75	0.159	0.110	0.290	0.251
4.00	0.166	0.117	0.314	0.270
4.25	0.176	0.123	0.338	0.289
4.50	0.186	0.129	0.362	0.308
4.75	0.196	0.133	0.386	0.328
5.00	0.204	0.139	0.406	0.348
5.25	0.213	0.144	0.426	0.368
5.50	0.222	0.150	0.448	0.387
5.75	0.232	0.156	0.469	0.403
6.00	0.241	0.162	0.490	0.419
6.25	0.251	0.168	0.511	0.435
6.50	0.260	0.174	0.532	0.450
6.75	0.269	0.180	0.553	0.466
7.00	0.279	0.185	0.574	0.482
8.00	0.315	0.211	0.659	0.541
9.00	0.349	0.238	0.745	0.598
10.00	0.388	0.264	0.832	0.652
11.00	0.427	0.290	0.920	0.704
12.00	0.466	0.317	1.008	0.754
13.00	0.504	0.343	1.097	0.796
14.00	0.543	0.370	1.186	0.851
15.00	0.582	0.396	1.277	0.917
16.00	0.622	0.424	1.370	0.982
17.00	0.661	0.451	1.462	1.049
18.00	0.700	0.477	1.555	1.116
19.00	0.741	0.504	1.649	1.184
20.00	0.780	0.532	1.744	1.254
21.00	0.819	0.559	1.840	1.321
22.00	0.858	0.585	1.936	1.395
23.00	0.897	0.614	2.033	1.463
24.00	0.936	0.641	2.134	1.536

TABLE 9

Relative weight of fresh humerus, ulna plus radius, femur, and tibia plus fibula on the weight of the fresh skeleton. Values taken from the smoothed graphs in chart 10

WEIGHT OF FRESH SKELETON	HUMERUS (2)	ULNA PLUS RADIUS (2)	FEMUR (2)	TIBIA PLUS FIBULA (2)
<i>grams</i>	<i>per cent</i>	<i>per cent</i>	<i>per cent</i>	<i>per cent</i>
0.50	4.76	3.12	3.86	3.07
0.75	4.70	3.10	4.19	3.58
1.00	4.66	3.70	4.50	4.30
1.25	4.60	3.40	5.10	5.52
1.50	4.68	3.80	5.86	5.86
1.75	4.77	3.16	6.35	6.28
2.00	4.80	3.22	6.55	6.30
2.25	4.82	3.18	6.71	6.35
2.50	4.84	3.14	6.80	6.39
2.75	4.81	3.12	7.27	6.40
3.00	4.73	3.08	7.33	6.48
3.25	4.60	3.04	7.66	6.58
3.50	4.42	3.00	7.71	6.65
3.75	4.24	2.96	7.73	6.69
4.00	4.16	2.92	7.85	6.76
4.25	4.15	2.89	7.96	6.80
4.50	4.13	2.86	8.05	6.85
4.75	4.12	2.81	8.12	6.90
5.00	4.08	2.78	8.12	6.96
5.25	4.06	2.74	8.12	7.00
5.50	4.04	2.72	8.14	7.04
5.75	4.04	2.71	8.15	7.01
6.00	4.02	2.70	8.16	6.99
6.25	4.01	2.69	8.18	6.96
6.50	4.00	2.67	8.19	6.92
6.75	3.99	2.66	8.19	6.90
7.00	3.98	2.64	8.20	6.88
8.00	3.94	2.64	8.24	6.76
9.00	3.88	2.64	8.28	6.64
10.00	3.88	2.64	8.32	6.52
11.00	3.88	2.64	8.36	6.40
12.00	3.88	2.64	8.40	6.28
13.00	3.88	2.64	8.44	6.12
14.00	3.88	2.64	8.47	6.08
15.00	3.88	2.64	8.51	6.11
16.00	3.89	2.65	8.56	6.14
17.00	3.89	2.65	8.60	6.17
18.00	3.89	2.65	8.64	6.20
19.00	3.90	2.65	8.68	6.23
20.00	3.90	2.66	8.72	6.27
21.00	3.90	2.66	8.76	6.29
22.00	3.90	2.66	8.80	6.34
23.00	3.90	2.67	8.84	6.36
24.00	3.90	2.67	8.89	6.40

As can be seen by inspecting either chart 10 or table 9, after the age which we have designated as puberty (i.e., 100 grams body weight and 7.4 grams skeleton weight) the percentage values for the fresh weights of the several long bones become rather constant. Thus table 9 shows very little change in the relative weights of the long bones of the fore limb after a skeleton weight of 7.4 grams. Such change as appears is in the form of an increase. The bones of the hind limb, on the other hand, show greater changes. The femur steadily increases in its relative weight, while the relative weight of the tibia plus fibula decreases up to a skeleton weight of 14 grams, after which it increases again slightly.

TABLE 10

Constants for the relative weights of the fresh humerus and ulna plus radius, as these appear in the last 30 entries of table 1. These entries comprise the interval from a skeleton weight of 8 grams to that of 24 grams, as given in table 9

	MEAN RELATIVE FRESH WEIGHT ON SKELETON WEIGHT	σ	C. V.	E_c
Humerus (2).....	3.88	0.127	3.3	± 0.285
Ulna plus radius (2).....	2.64	0.077	2.9	± 0.253

σ = standard deviation; C.V. = coefficient of variability; E_c = probable error of C.V.

By the use of these ratios it is possible, therefore, to determine the weight of the skeleton from the relative weights of any of these limb bones. Some variability has to be anticipated, however, and the question also arises whether in the skeletons of animals reared on different diets the same ratios would hold. The determinations of these points requires further investigation, but in the meantime the ratios presented by the humerus and the ulna plus radius seem the most trustworthy because they show so little change over such a long range of skeleton weight, and because the variability shown by the observed values is distinctly low as indicated in table 10 by the standard deviation (σ), the coefficient of variability (C. V.), and the probable error of C. V. (E_c), which have been calculated for the

last thirty observations in the original tables (as represented by the last thirty observations in table 1).

As will be seen, the relative values are given here (Table 9) for the fresh bone weights only. The absolute weights for the room dried bones are, however, entered in table 11. From this latter table the oven-dried weights may be obtained, if needed, by using appropriate factors which appear in table 19.

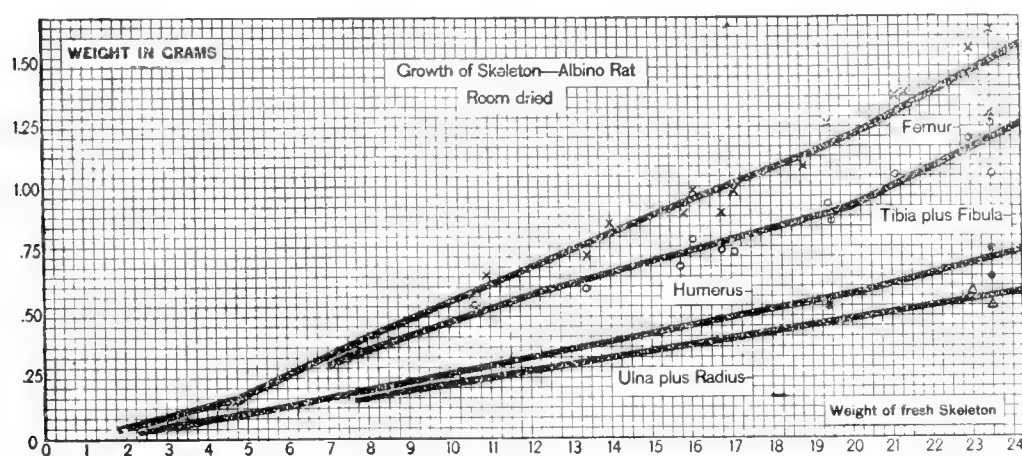


Chart 11 Absolute weight of the room-dried limb bones, on the weight of the fresh skeleton (albino rat). Table 11.

× Femur. ○ Tibia plus fibula. ● Humerus. Δ Ulna plus radius.

B. According to body weight

The foregoing tables 8 and 9 permit us to compute the probable weight of the entire fresh skeleton when the fresh weight of one or more of the limb bones is given.

While the proportions within the skeleton are probably fairly constant in a series of individuals, it seems possible that the proportion of the total body weight represented by the skeleton is subject to considerable variation. In view of this fact, it is important to know how the weights of the several limb bones stand in relation to the body weight in a standard series. For this purpose the absolute weights of the fresh, the room-dried, and the oven-dried limb bones on body weight are given in tables 12, 13, and 14. Because these relations are useful in determining, for example, the variation in the weight of the skeleton under

TABLE 11

Absolute weight of room-dried humerus, ulna plus radius, femur and tibia plus fibula, on the weight of the fresh skeleton. Values taken from the smoothed graphs in chart 11

WEIGHT OF FRESH SKELETON	HUMERUS (2)	ULNA PLUS RADIUS (2)	FEMUR (2)	TIBIA PLUS FIBULA (2)
<i>grams</i>	<i>grams</i>	<i>grams</i>	<i>grams</i>	<i>grams</i>
0.50	0.007	0.004	0.004	0.004
0.75	0.010	0.006	0.006	0.006
1.00	0.014	0.010	0.013	0.013
1.25	0.018	0.015	0.020	0.022
1.50	0.022	0.020	0.027	0.031
1.75	0.027	0.024	0.034	0.039
2.00	0.034	0.030	0.043	0.047
2.25	0.041	0.035	0.051	0.055
2.50	0.047	0.038	0.060	0.063
2.75	0.052	0.043	0.070	0.070
3.00	0.058	0.046	0.078	0.078
3.25	0.063	0.051	0.088	0.088
3.50	0.070	0.060	0.110	0.110
3.75	0.075	0.062	0.120	0.125
4.00	0.080	0.065	0.135	0.140
4.25	0.085	0.070	0.140	0.150
4.50	0.090	0.075	0.150	0.170
4.75	0.095	0.085	0.165	0.180
5.00	0.100	0.090	0.180	0.190
5.25	0.110	0.095	0.195	0.205
5.50	0.115	0.105	0.215	0.220
5.75	0.125	0.110	0.235	0.230
6.00	0.130	0.115	0.255	0.245
6.25	0.135	0.120	0.275	0.255
6.50	0.145	0.130	0.295	0.270
6.75	0.155	0.135	0.310	0.285
7.00	0.160	0.140	0.330	0.300
8.00	0.190	0.170	0.405	0.350
9.00	0.225	0.190	0.475	0.405
10.00	0.255	0.215	0.550	0.455
11.00	0.290	0.245	0.615	0.510
12.00	0.320	0.270	0.685	0.570
13.00	0.350	0.295	0.750	0.615
14.00	0.380	0.320	0.815	0.655
15.00	0.415	0.345	0.880	0.700
16.00	0.445	0.370	0.945	0.745
17.00	0.475	0.395	1.010	0.790
18.00	0.505	0.420	1.070	0.830
19.00	0.535	0.445	1.135	0.875
20.00	0.570	0.465	1.210	0.920
21.00	0.610	0.495	1.295	0.995
22.00	0.650	0.520	1.380	1.075
23.00	0.695	0.545	1.470	1.150
24.00	0.735	0.575	1.550	1.230

TABLE 12

Absolute weight of fresh limb bones, on body weight. Values taken from smoothed graphs in chart 12

BODY WEIGHT	HUMERUS (2)	ULNA PLUS RADIUS (2)	FEMUR (2)	TIBIA PLUS FIBULA (2)
<i>grams</i>	<i>grams</i>	<i>grams</i>	<i>grams</i>	<i>grams</i>
5	0.03	0.02	0.03	0.03
10	0.05	0.03	0.05	0.05
15	0.07	0.05	0.10	0.10
20	0.09	0.07	0.14	0.12
25	0.11	0.08	0.16	0.14
30	0.12	0.09	0.19	0.17
35	0.13	0.09	0.22	0.19
40	0.14	0.10	0.25	0.21
45	0.15	0.11	0.29	0.24
50	0.17	0.12	0.31	0.26
55	0.18	0.13	0.34	0.28
60	0.19	0.13	0.37	0.30
65	0.20	0.14	0.40	0.33
70	0.22	0.14	0.43	0.35
75	0.23	0.15	0.45	0.38
80	0.24	0.16	0.48	0.39
85	0.25	0.16	0.50	0.41
90	0.26	0.17	0.53	0.43
95	0.27	0.18	0.55	0.45
100	0.28	0.19	0.57	0.47
110	0.30	0.20	0.62	0.52
120	0.33	0.21	0.67	0.55
130	0.35	0.23	0.72	0.58
140	0.37	0.24	0.78	0.61
150	0.39	0.26	0.83	0.63
160	0.41	0.27	0.87	0.66
170	0.43	0.28	0.92	0.69
180	0.45	0.30	0.96	0.72
190	0.47	0.31	1.00	0.75
200	0.49	0.33	1.04	0.77
210	0.50	0.34	1.08	0.80
220	0.52	0.35	1.13	0.83
230	0.54	0.37	1.17	0.86
240	0.56	0.38	1.22	0.89
250	0.58	0.39	1.26	0.92
270	0.61	0.42	1.35	0.98
290	0.65	0.45	1.43	1.03
310	0.69	0.48	1.52	1.08
330	0.72	0.50	1.60	1.14
350	0.75	0.52	1.68	1.20
370	0.78	0.54	1.75	1.25
390	0.81	0.56	1.82	1.30
410	0.84	0.57	1.88	1.36
430	0.87	0.59	1.95	1.41
450	0.91	0.61	2.02	1.47
470	0.94	0.62	2.09	1.53
485	0.96	0.64	2.14	1.57

TABLE 13

Absolute weight of room-dried limb bones, on body weight. No chart

BODY WEIGHT	HUMERUS (2)	ULNA PLUS RADIUS (2)	FEMUR (2)	TIBIA PLUS FIBULA (2)
<i>grams</i>	<i>grams</i>	<i>grms</i>	<i>grams</i>	<i>grams</i>
5	0.007	0.005	0.007	0.008
10	0.013	0.010	0.012	0.014
15	0.021	0.018	0.028	0.033
20	0.030	0.028	0.044	0.043
25	0.040	0.035	0.053	0.054
30	0.047	0.041	0.067	0.070
35	0.052	0.045	0.082	0.082
40	0.060	0.052	0.098	0.095
45	0.067	0.060	0.120	0.113
50	0.079	0.067	0.134	0.127
55	0.088	0.076	0.153	0.142
60	0.095	0.079	0.172	0.159
65	0.102	0.088	0.192	0.178
70	0.115	0.092	0.211	0.193
75	0.124	0.101	0.229	0.214
80	0.133	0.110	0.250	0.225
85	0.141	0.112	0.268	0.240
90	0.150	0.122	0.291	0.258
95	0.160	0.131	0.310	0.276
100	0.170	0.140	0.329	0.295
110	0.188	0.153	0.370	0.337
120	0.213	0.164	0.410	0.368
130	0.233	0.182	0.452	0.399
140	0.251	0.193	0.502	0.427
150	0.267	0.211	0.540	0.446
160	0.281	0.221	0.572	0.473
170	0.297	0.230	0.613	0.500
180	0.312	0.247	0.643	0.528
190	0.328	0.257	0.674	0.553
200	0.344	0.274	0.703	0.568
210	0.353	0.284	0.733	0.591
220	0.369	0.294	0.768	0.614
230	0.384	0.311	0.799	0.638
240	0.400	0.321	0.834	0.662
250	0.416	0.330	0.861	0.686
270	0.439	0.357	0.927	0.733
290	0.469	0.383	0.987	0.774
310	0.501	0.411	1.052	0.815
330	0.523	0.431	1.112	0.864
350	0.547	0.449	1.170	0.912
370	0.571	0.469	1.224	0.952
390	0.595	0.489	1.280	0.997
410	0.620	0.499	1.325	1.047
430	0.644	0.519	1.380	1.090
450	0.675	0.540	1.433	1.138
470	0.700	0.552	1.490	1.190
485	0.717	0.571	1.528	1.227

TABLE 14

Absolute weight of oven-dried limb bones on body weight. No chart

BODY WEIGHT	HUMERUS (2)	ULNA PLUS RADIUS (2)	FEMUR (2)	TIBIA (2) PLUS FIBULA
<i>grams</i>	<i>grams</i>	<i>grams</i>	<i>grams</i>	<i>grams</i>
5	0.006	0.005	0.006	0.007
10	0.012	0.009	0.011	0.013
15	0.019	0.017	0.026	0.030
20	0.028	0.026	0.040	0.040
25	0.037	0.032	0.049	0.050
30	0.043	0.038	0.062	0.064
35	0.048	0.041	0.075	0.075
40	0.055	0.048	0.090	0.087
45	0.062	0.055	0.110	0.104
50	0.073	0.062	0.123	0.117
55	0.081	0.070	0.141	0.131
60	0.087	0.073	0.158	0.146
65	0.094	0.081	0.176	0.164
70	0.106	0.085	0.194	0.178
75	0.114	0.093	0.210	0.197
80	0.122	0.101	0.230	0.207
85	0.130	0.103	0.246	0.221
90	0.138	0.112	0.267	0.237
95	0.147	0.120	0.285	0.254
100	0.156	0.129	0.302	0.271
110	0.173	0.141	0.340	0.310
120	0.196	0.151	0.377	0.339
130	0.214	0.167	0.415	0.367
140	0.231	0.177	0.461	0.393
150	0.245	0.194	0.496	0.410
160	0.258	0.203	0.526	0.435
170	0.273	0.211	0.563	0.460
180	0.287	0.227	0.591	0.486
190	0.301	0.236	0.619	0.509
200	0.316	0.252	0.646	0.523
210	0.324	0.261	0.674	0.544
220	0.339	0.270	0.706	0.565
230	0.353	0.286	0.734	0.587
240	0.368	0.295	0.766	0.609
250	0.382	0.303	0.791	0.631
270	0.403	0.328	0.852	0.674
290	0.431	0.352	0.907	0.712
310	0.460	0.378	0.967	0.750
330	0.481	0.396	1.022	0.795
350	0.503	0.413	1.075	0.839
370	0.525	0.431	1.125	0.876
390	0.547	0.449	1.176	0.917
410	0.570	0.459	1.218	0.963
430	0.592	0.477	1.268	1.003
450	0.620	0.496	1.317	1.047
470	0.643	0.507	1.369	1.095
485	0.659	0.525	1.404	1.129

different diets, it has been thought proper to give the weight values in all three conditions of moisture. Chart 12 gives the smoothed graphs, for the fresh weights only.

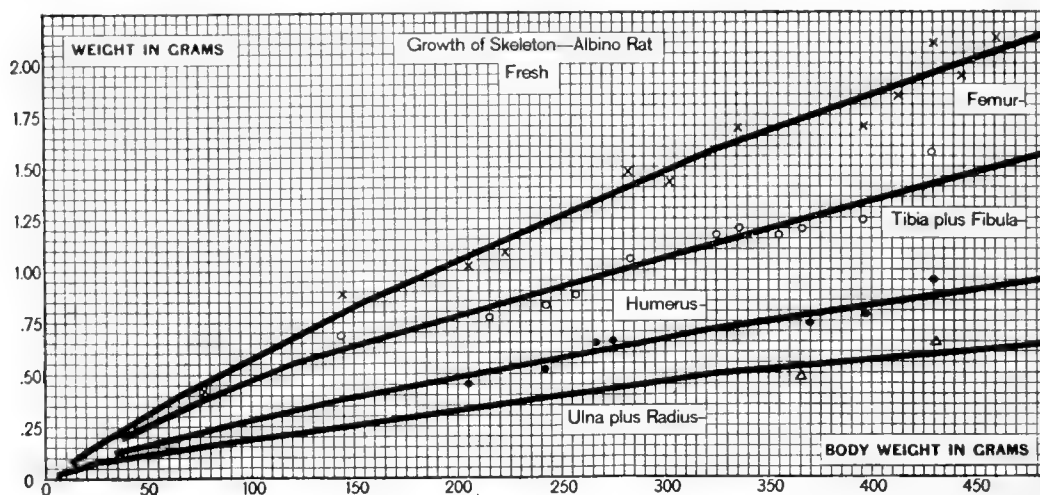


Chart 12 Absolute weight of the fresh limb bones, on body weight (albino rat). Table 12.

× Femur. ○ Tibia plus fibula. ● Humerus. △ Ulna plus radius.

PERCENTAGE OF WATER IN THE SKELETON AND ITS PARTS

1. According to age

As already stated, the skeleton has been dried in two stages, first at room temperature (18°C. to 24°C., according to season) for thirty days, and later in the water bath at 96°C. for six days. It is generally recommended that for chemical analysis bones be dried at 140°C., as this temperature drives off certain fractions of water associated with the salts, but for our purpose this was not deemed necessary, particularly as the reduction in weight is only about 1 per cent greater than that obtained by the method employed. The percentages of water here given are therefore to be interpreted in the light of the conditions under which they have been obtained. The data for the percentage of water in the entire skeleton after drying at 96°C. for six days, according to age, are given under A in the left-hand portion of table 15, and the values entered in chart 13. The percentage after oven drying was that chosen for tabulation because it was assumed that it would be

more constant than the percentage after room drying, and in one sense this is true.

As chart 13 shows, there is a rapid fall of about forty points in the percentage of water up to puberty, or to about 100 days of age, and after that a loss of about five points during the remainder of life.

As indicated by the discussion on the effects of the macerating fluid (Appendix 2), the data for the percentage of water are about 0.6 per cent low at birth, and this deficiency increases about 0.04 per cent for each 5 grams increase in body weight, up to 150

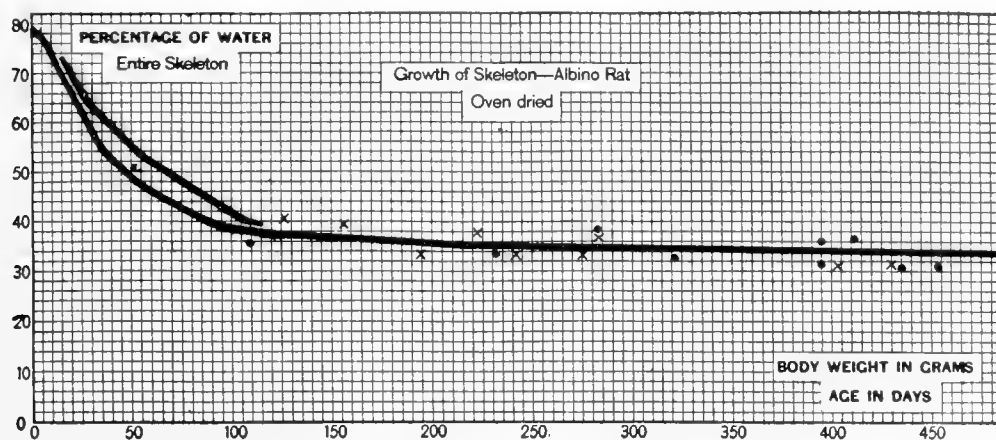


Chart 13 Percentage of water in the entire skeleton—oven dried—on age and on body weight (albino rat). Table 15.

● Age. × Body weight.

grams, after which the deficiency remains constant. The relative values in the different parts of the skeleton are, however, not affected by the maceration.

During early life calcification of bone is largely a function of age, and it seemed desirable, therefore, to compare the course of the percentage of water in the entire skeleton when the values were entered according to the observed ages as in the left-hand portion of table 15, under A, and when entered according to body weights, as in the right-hand portion of table 15, under B. The corresponding graphs for the entire skeleton are given in chart 13.

As the records show, after puberty there is no marked difference brought out by the two methods of presentation, which means merely that there is little further change in the percentage

TABLE 15

A. Percentage of water in oven-dried skeleton on age in days. B. Percentage of water in oven-dried entire skeleton and appendicular skeleton, on body weight. Values taken from the smoothed graphs in chart 13

AGE	A		B		PERCENTAGE OF WATER-APPENDICULAR SKELETON
	Percentage of water-skeleton	Body weight	Percentage of water-skeleton		
<i>days</i>		<i>grams</i>			
0	79.2	5	79.1		79.1
5	77.0	10	76.0		76.0
10	73.5	15	72.4		72.0
15	69.6	20	69.0		67.1
20	66.0	25	65.4		64.0
25	62.0	30	63.1		62.2
30	58.0	35	61.2		60.4
35	54.4	40	59.1		58.6
40	52.4	45	57.1		56.8
45	50.8	50	55.2		55.0
50	49.0	55	53.2		53.2
55	47.2	60	52.0		52.0
60	46.0	65	50.7		50.6
65	44.8	70	49.4		49.1
70	43.8	75	48.1		48.0
75	42.8	80	46.8		46.6
80	41.8	85	45.6		45.2
85	40.8	90	44.4		44.0
90	40.0	95	43.1		42.5
95	38.8	100	41.8		41.2
100	38.2	110	39.4		38.8
110	37.9	120	38.8		37.0
120	37.6	130	38.4		35.3
130	37.4	140	38.1		34.8
140	37.2	150	37.9		34.2
150	36.9	160	37.6		33.7
160	36.7	170	37.4		33.2
170	36.5	180	37.1		32.6
180	36.2	190	36.8		32.1
190	36.0	200	36.6		31.6
200	35.9	230	35.6		31.1
230	35.2	260	35.1		30.7
260	35.1	290	34.9		30.3
290	34.9	320	34.7		30.1
320	34.7	350	34.5		29.6
350	34.5	380	34.2		29.2
380	34.2	410	34.1		28.7
410	34.1	440	34.0		28.3
440	34.0	480	33.6		28.0
480	33.6				

TABLE 16

Percentage of water in oven-dried cranium and vertebrae, on body weight. Values taken from the smoothed graphs in chart 14

BODY WEIGHT	CRANIUM	VERTEBRAL
<i>grams</i>	<i>per cent</i>	<i>per cent</i>
5	80.1	80.1
10	76.8	76.8
15	72.4	70.5
20	68.4	68.4
25	64.0	66.8
30	60.4	65.1
35	58.2	63.4
40	56.3	61.8
45	54.8	60.0
50	53.1	58.4
55	52.0	56.8
60	51.0	54.8
65	50.1	53.6
70	49.2	52.1
75	48.3	50.5
80	47.4	49.4
85	46.4	48.1
90	45.6	47.1
95	44.8	46.0
100	44.0	44.8
110	43.4	42.0
120	43.2	39.6
130	42.9	38.2
140	42.7	38.0
150	42.4	38.0
160	42.2	37.9
170	42.1	37.7
180	42.0	37.5
190	42.0	37.4
200	41.8	37.3
210	41.6	37.2
220	41.4	37.0
230	41.3	36.9
240	41.2	36.8
250	41.2	36.7
270	41.0	36.4
290	40.8	36.1
310	40.5	36.0
330	40.2	35.6
350	40.1	35.4
370	40.0	35.1
390	39.7	34.8
410	39.5	34.5
430	39.3	34.2
450	39.1	33.8
470	38.8	33.4
485	38.7	33.1

of water, either on age or on body weight. The differences in the graphs before puberty are the result of the method of constructing the chart. It should be remembered, however, that age is probably an important factor in modifying the percentage of water, so that the use of the body weight as the basal datum is open to question, except where the body weight is approximately normal for the age. Such is the case, however, in our series.

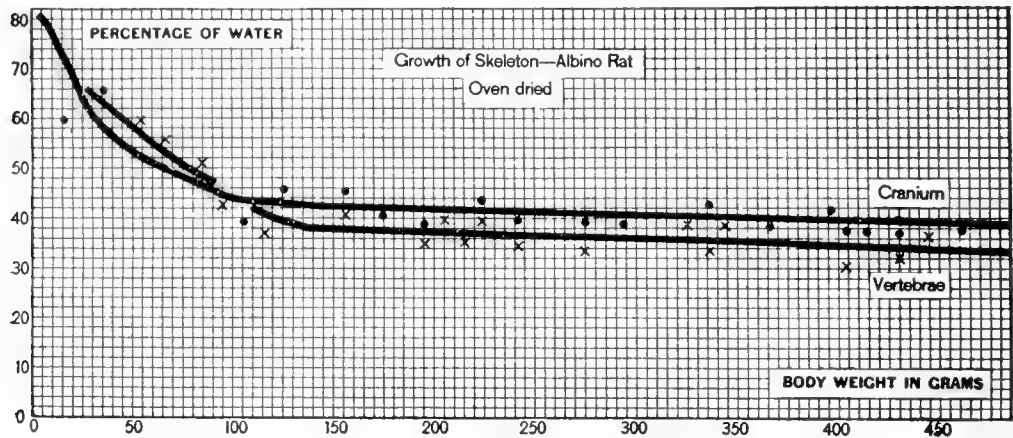


Chart 14 Percentage of water in the oven-dried cranium and in the vertebrae, on body weight (albino rat) Table 16.

● Cranium. × Vertebrae.

2. According to body weight

Since body weight is a much more common datum than age, it was felt that graphs for the percentage of water on body weight would be particularly useful, and body weight has therefore been used exclusively for the remaining charts showing the loss in the percentage of water.

This percentage is somewhat different for the several parts of the skeleton. Taking the body weight as a basis, we obtain the series of values given in table 15 B, for the entire skeleton, and the appendicular skeleton; in table 16 (chart 14) for the cranium and the vertebrae, and in table 17 (chart 15) for the humerus, the ulna plus radius, the fore foot, and table 18 (chart 16) for the femur, the tibia plus fibula, and the hind foot.

If these several values are compared with one another, there appear only slight differences between percentages of water in

the several parts at birth, the lowest values being found in bones forming the middle segments of the limbs, but very evident differences are found at puberty or somewhat earlier.

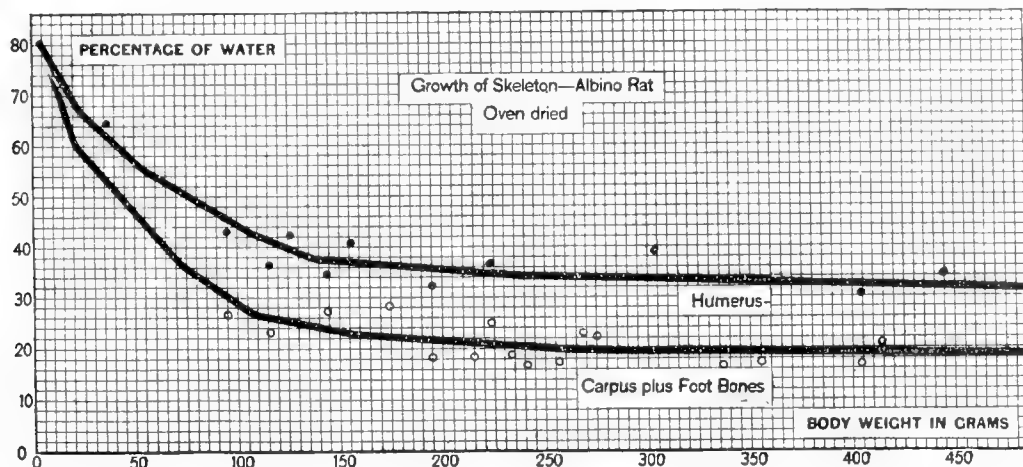


Chart 15 Percentage of water in the oven-dried bones of fore limb, on body weight (albino rat). Table 17.

● Humerus. ○ Carpus plus foot bones. The graph for the ulna plus radius coincides nearly with that for the carpus, and is therefore omitted.

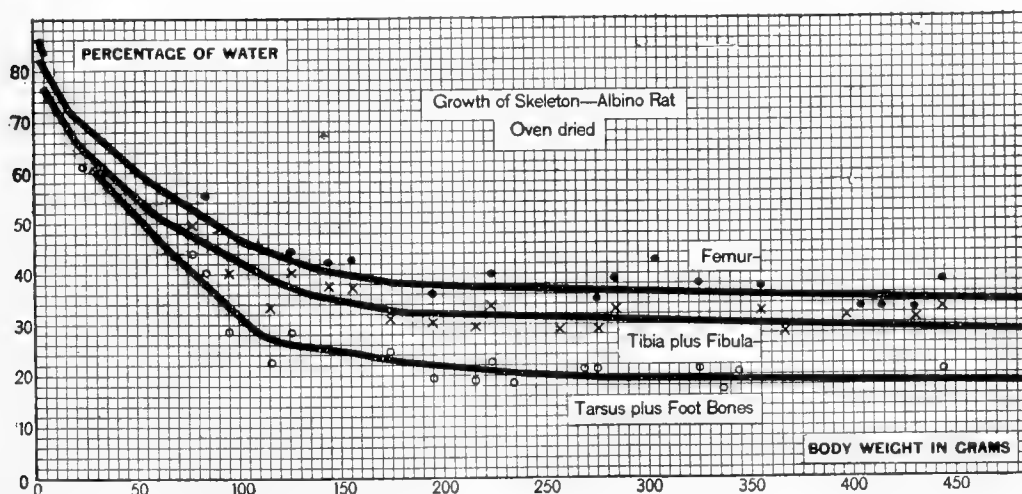


Chart 16 Percentage of water in the oven-dried bones of hind limb, on body weight (albino rat). Table 18.

● Femur. × Tibia and fibula. ○ Tarsus and foot bones.

If we compare the percentage of water in the appendicular with that in the entire skeleton (table 15, B), it is seen that after puberty the values for the appendicular skeleton are lower. This implies, of course, that the corresponding values for the axial

TABLE 17

Percentage of water in oven-dried humerus, ulna plus radius, and bones of fore feet, on body weight. Values taken from the smoothed graphs in chart 15

BODY-WEIGHT	HUMERUS (2)	ULNA PLUS RADIUS (2)	BOTH FORE FEET
<i>grams</i>	<i>per cent</i>	<i>per cent</i>	<i>per cent</i>
5	79.8	73.8	80.1
10	75.8	70.0	74.0
15	72.2	66.0	68.0
20	69.1	62.8	61.2
25	66.3	60.1	58.4
30	64.5	57.4	56.0
35	62.7	54.8	53.8
40	60.8	52.4	51.6
45	58.9	50.4	49.2
50	57.0	48.2	47.0
55	55.2	46.0	44.8
60	54.0	43.9	42.4
65	52.8	41.8	40.1
70	51.6	39.5	38.0
75	50.4	37.8	36.0
80	49.2	36.7	34.6
85	48.1	35.6	33.2
90	46.8	34.3	31.8
95	45.6	33.1	30.4
100	44.4	32.0	28.8
110	42.2	29.7	26.8
120	40.6	28.3	26.0
130	39.0	27.3	25.0
140	37.6	26.3	24.1
150	37.3	25.3	23.4
160	37.0	25.0	22.9
170	36.6	24.6	22.5
180	36.2	24.3	22.1
190	36.0	24.0	22.0
200	35.6	23.6	21.6
210	35.2	23.2	21.2
220	34.8	22.9	20.9
230	34.6	22.7	20.6
240	34.2	22.5	20.4
250	34.1	22.3	20.1
270	34.0	22.0	19.9
290	33.7	21.7	19.5
310	33.4	21.3	19.4
330	33.2	20.9	19.3
350	33.0	20.5	19.2
370	32.7	20.2	19.2
390	32.5	19.9	19.1
410	32.2	19.5	19.0
430	32.0	19.2	18.9
450	31.9	18.7	18.8
470	31.6	18.3	18.8
485	31.4	18.0	18.8

TABLE 18

Percentage of water in oven-dried femur, tibia plus fibula, and bones of hind feet, on body weight. Values taken from the smoothed graphs, in chart 16

BODY WEIGHT	FEMUR (2)	TIBIA PLUS FIBULA (2)	BOTH HIND FEET
<i>grams</i>	<i>per cent</i>	<i>per cent</i>	<i>per cent</i>
5	80.7	76.6	83.2
10	77.2	73.4	77.2
15	74.0	70.1	72.4
20	71.1	66.8	67.8
25	69.2	64.4	64.4
30	67.6	62.4	60.4
35	65.8	60.6	58.1
40	64.0	58.8	56.0
45	62.2	56.8	54.0
50	60.4	55.1	51.9
55	58.6	53.2	49.8
60	57.3	51.4	47.6
65	56.0	50.2	45.0
70	54.8	49.2	43.2
75	53.4	48.1	41.2
80	52.1	47.0	39.4
85	50.9	46.0	37.6
90	49.6	44.8	35.8
95	48.2	43.6	33.8
100	47.0	42.4	32.0
110	45.2	40.4	28.4
120	43.8	38.4	26.7
130	42.4	36.8	26.0
140	40.9	35.6	25.2
150	40.2	34.9	24.8
160	39.5	34.1	24.1
170	38.8	33.3	23.2
180	38.4	32.5	22.5
190	38.1	32.2	22.2
200	37.9	32.1	21.9
210	37.6	32.0	21.5
220	37.5	31.9	21.1
230	37.3	31.7	20.7
240	37.2	31.6	20.4
250	37.2	31.4	20.1
270	36.9	31.2	19.6
290	36.6	30.9	19.3
310	36.4	30.6	19.2
330	36.1	30.3	19.1
350	36.0	30.1	19.0
370	35.7	29.9	18.9
390	35.4	29.5	18.8
410	35.2	29.2	18.8
430	35.0	28.9	18.6
450	34.8	28.8	18.5
470	34.5	28.4	18.4
485	34.4	28.1	18.4

must be higher than those for the entire skeleton, and table 16 shows that this is true for both the cranium and the vertebrae, which form the greater part of the axial skeleton. On the other hand, while the percentage of water in the proximal bones of both the fore and hind limbs (humerus and femur, respectively) is close to that in the axial skeleton, the percentages in the middle and distal bones are much lower, being least in the distal group (charts 15 and 16).

A consideration of these various differences renders it probable that they are largely due to mechanical causes: the crevices in the cranium, the cavities in the long bones, and possibly the greater porosity of the vertebrae would tend to give these parts a higher percentage of water than was found in the more solid (distal) bones of the limbs—the radius and ulna and the bones of the fore and hind feet, which lack a central cavity.

These water values, therefore, are anatomically useful, but no general biological significance should be attached to the differences between them. Without question, the percentage of water will vary in a marked way according to the nutritional condition of the animal when this condition departs from the normal, as when, for some reason, calcification is delayed or incomplete.

On the loss of water

Between birth and maturity the densest bones, e.g., those of the feet, show a loss of sixty to sixty-five points in their percentage of water (tables 17 and 18). Just how this loss occurs we do not know. It is possible, however, to get a general notion of the process by a simple computation. If we assume that at birth the bones in question are entirely uncalcified, but at maturity have 60 per cent of their dry weight in the form of salts (assumed in the following argument to retain no water) and, at the same time, that the organic matter present maintains its initial water content of 83.2 (or 80.1) per cent, then the mixture of 60 per cent salts and 40 per cent organic matter would show at maturity 25 (or 24) per cent of water. We find, however, about 18.5 per cent in the bones of both the fore and

hind feet. This result suggests that the percentage of water in the organic matter also diminishes with age, thus supplementing the effect produced on the water content of the bone as a whole by the deposition of salts in it. Moreover, as we know, the salts carry with them some water, which they lose at 96°C.—a fact which strengthens the foregoing argument. However, so long as the exact percentage of salts is unknown, this conclusion is merely suggestive.

On the percentage value of the loss in weight on passing from the room-dried to the oven-dried condition

Although the determination of the room-dried as well as the oven-dried weights has been made for all of the parts of the skeleton, it has been deemed necessary to print the room-dried values in only a few cases, as in tables 3 and 11.

A study of the full manuscript tables has, however, brought out the fact that at all ages and in all parts of the skeleton there is a nearly constant loss in water on passing from the room-dried to the oven-dried condition. The data are given in table 19.

These results in table 19 are of interest.

TABLE 19

The percentage in weight lost by room-dried bones after oven drying at 96°C. Based on the averages of the percentages as determined for each of the forty-two groups

	ENTRIES 1-6 BODY WEIGHT 4-50	ENTRIES 7-12 BODY WEIGHT 50-100	ENTRIES 13-28, BODY WEIGHT 100-300	ENTRIES 29-42, BODY WEIGHT 300-500	AVERAGE FOR ALL BODY WEIGHTS
	<i>per cent</i>	<i>per cent</i>	<i>per cent</i>	<i>per cent</i>	<i>per cent</i>
Entire skeleton.....	8.38	8.26	8.38	8.35	8.34
Axial skeleton.....	8.24	8.62	8.23	8.38	8.37
Appendicular skeleton...	8.64	7.79	8.45	8.26	8.28
Shoulder girdle and fore limbs.....	9.74	8.10	8.35	8.13	8.58
Pelvic girdle and hind limbs.....	8.67	7.77	8.55	8.40	8.35
Cranium with teeth.....	8.64	9.13	8.83	8.89	8.87
Humerus (2).....	8.33	7.54	8.33	8.19	8.10
Ulna and radius (2).....	8.33	7.72	8.24	8.17	8.11
Femur (2).....	7.89	7.60	8.48	8.48	8.11
Tibia and fibula (2).....	7.65	7.75	8.55	8.17	8.00

In general the loss of water in passing from the room-dried to the oven-dried state is about 8.3 per cent of the room-dried value, and the oven-dried weight is therefore 91.7 per cent of the room-dried. Table 19 gives the several values, according to the part of the skeleton, as determined for the four body-weight groups which have been selected.

It is possible, therefore, from these table values to make an approximate determination of the weight of the skeleton or its parts in one state of dryness, if the weight in the other state is given.

The most peculiar feature of this table, however, is the fact that in no part of the skeleton is the percentage loss in the body-weight groups from 4 to 50 grams essentially different from that found in the heavier groups—despite the fact that in the first group calcification is far from complete in any of the bones and also tends to progress as the bones become older and heavier. The full explanation of this result has not yet been obtained, but some incidental tests indicate that in the room-dried state both the salts found in bone and the collagen retain nearly a like proportion of water, which is lost at 96°C.

LENGTHS OF BONES

It has been thought worth while to tabulate the lengths of the long bones of the limbs during growth, in order to obtain the relations between (A) the body weight or (B) the body length of the rat, and the lengths of the respective limb bones, and also to get an idea of the manner in which the lengths and weights of the bones themselves change. For comparison with the data from man these determinations are especially useful.

A. Lengths of bones on body weight

With a dial calipers measuring accurately to 0.1 of a millimeter, the lengths of the long bones, humerus, ulna, radius, femur, and tibia were taken in the fresh, room-dried, and oven-dried condition.

The symmetrical bones usually give similar values within the limits of the error of observation. All the values reported are means of the measurements of the right and left bones. As at birth all the bones are incompletely calcified, they shrink in drying enormously in the younger rats, the fresh bones losing 27 to 32 per cent of their length in the youngest group when dried at 96°C.

With the increase in age and in calcification this loss on drying diminishes so that at a body weight of 100 grams (about ninety days of age) the amount of loss is less than 2 per cent in the case of all of the bones, and at a body weight of 140 grams

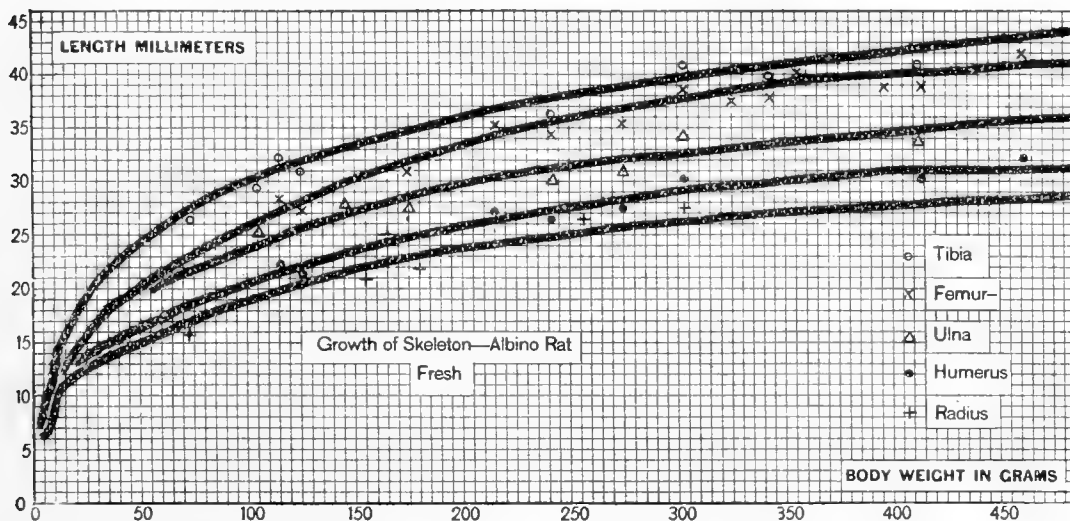


Chart 17 Length of fresh limb bones in millimeters, on body weight (albino rat). Table 20.

○ Tibia. × Femur. △ Ulna. ● Humerus. + Radius.

(about 120 days) it has become less than 1 per cent; the stable condition being attained a little less rapidly in the femur and humerus than in the tibia and ulna. The lengths of the fresh bones in millimeters are given on body weight in table 20, but instead of printing the full tables for the room-dried and oven-dried bones we have merely added a small table (21) of corrections which apply to rats above 100 grams in body weight, and by the aid of which one may obtain the room-dried or oven-dried length of any of the bones when the fresh length is given, or indeed may recover the length in any other state of moisture, provided the length in one state is known.

TABLE 20

Absolute length of fresh limb bones in millimeters, on body weight. Values taken from the smoothed graphs in chart 17

BODY WEIGHT	HUMERUS	ULNA	RADIUS	FEMUR	TIBIA
<i>grams</i>	<i>mm.</i>	<i>mm.</i>	<i>mm.</i>	<i>mm.</i>	<i>mm.</i>
5	7.0	8.0	6.4	7.4	7.0
10	10.2	11.8	9.0	11.0	12.0
15	12.0	14.0	11.1	12.9	15.6
20	12.9	15.5	12.0	14.4	17.9
25	13.7	16.5	12.6	15.7	19.3
30	14.3	17.4	13.2	16.8	20.7
35	14.8	18.2	13.7	17.9	21.7
40	15.4	18.8	14.2	18.7	22.4
45	15.8	19.2	14.6	19.5	23.3
50	16.5	19.6	15.0	20.1	24.0
55	16.8	19.9	15.5	20.9	24.9
60	17.5	20.3	16.0	21.5	25.5
65	17.8	20.9	16.3	22.0	26.2
70	18.3	21.2	16.7	22.7	26.8
75	18.7	21.7	17.2	23.2	27.5
80	19.0	22.0	17.6	23.9	28.0
85	19.4	22.6	18.0	24.4	28.5
90	19.8	22.9	18.4	24.8	29.0
95	20.1	23.2	18.6	25.4	29.6
100	20.5	23.7	18.9	25.8	29.8
110	21.2	24.5	19.5	26.8	30.7
120	21.7	25.2	20.2	27.7	31.6
130	22.4	25.9	20.8	28.7	32.2
140	22.9	26.6	21.3	29.5	32.8
150	23.6	27.1	21.8	30.2	33.4
160	24.0	27.7	22.2	31.0	33.9
170	24.6	28.3	22.7	31.6	34.5
180	25.0	28.8	23.1	32.2	34.9
190	25.4	29.3	23.4	32.8	35.5
200	25.8	29.8	23.8	33.4	36.0
210	26.1	30.2	24.1	34.0	36.5
220	26.5	30.6	24.3	34.6	37.0
230	26.9	30.9	24.6	35.0	37.3
240	27.1	31.2	24.8	35.5	37.7
250	27.5	31.5	25.0	36.0	38.1
270	28.3	32.0	25.5	36.8	38.8
290	28.9	32.3	26.0	37.4	39.5
310	29.4	32.8	26.3	38.0	40.0
330	29.8	33.2	26.7	38.7	40.5
350	30.0	33.6	27.0	39.2	41.0
370	30.3	34.0	27.2	39.7	41.5
390	30.7	34.4	27.5	39.9	41.9
410	31.0	34.9	27.8	40.2	42.4
430	31.0	35.2	28.0	40.4	43.0
450	31.2	35.6	28.3	40.7	43.3
470	31.3	36.0	28.5	41.0	43.8
485	31.3	36.2	28.6	41.2	44.1

Examination of table 21 shows that the shrinkage is somewhat greater in the humerus and femur than in the ulna and tibia and that in passing from the room-dried to the oven-dried state the shrinkage is about half that which is found in passing from the fresh to the room-dried state. The absolute values of the corrections called for are, however, very small, since in the instance where the correction is greatest, it amounts to only 1 per cent (femur—from fresh to oven-dried) and the maximum absolute value corresponding to this is 0.4 mm., as can be seen by looking at the last entry for the length of the fresh femur in table 20.

TABLE 21

Percentage losses in the length of long bones on drying. Mean values for rats above 100 grams in body weight

AMOUNT OF CHANGE	AVERAGE PERCENTAGE LOSS IN LENGTH ON DRYING				
	Humerus	Ulna	Radius	Femur	Tibia
	<i>per cent</i>	<i>per cent</i>	<i>per cent</i>	<i>per cent</i>	<i>per cent</i>
Fresh to room dried: loss.....	0.6	0.4	0.4	0.7	0.5
Room dried to oven dried: loss.....	0.3	0.2	0.2	0.3	0.2
Fresh to oven dried: loss.....	0.9	0.6	0.6	1.0	0.7

B. Lengths of bones on body length

For a strict comparison, however, we should have the relations of these bone lengths to the body length of the rats. The data are so given in table 22, which shows the absolute lengths of the bones on body length. The smoothed graphs are in chart 18 and in chart 19, respectively. In table 23 the corresponding relative values appear.

In the case of each bone the last thirteen entries in table 23 after 160 mm. (= 100 grams of body weight) are divided into three subgroups and the averages of the relative bone lengths on body lengths computed. For these subgroups we obtain the values given in table 24.

These data indicate a slight tendency for the humerus and the femur to become relatively longer, while the ulna, radius,

and tibia become relatively shorter. The changes are, however, very slight, and by the use of the mean values here given it should be possible to recover the body length of a rat over 100 grams in body weight, when the fresh length of one or more of these bones is known.

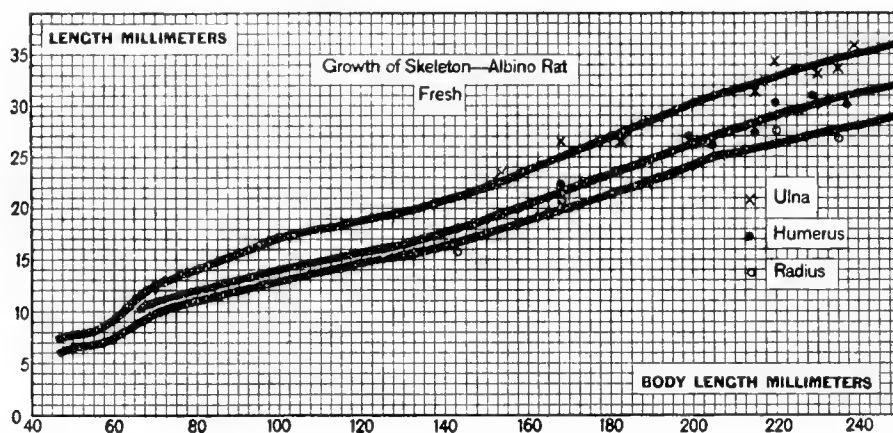


Chart 18 Length of fresh fore-limb bones in millimeters, on body length (albino rat). Table 22.

× Ulna. ● Humerus. ○ Radius.

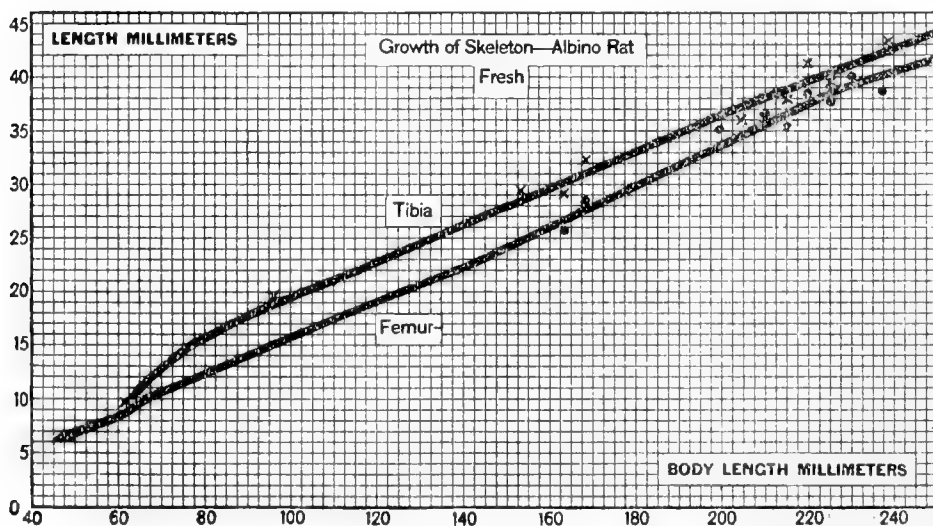


Chart 19 Length of fresh hind-limb bones in millimeters, on body length (albino rat). Table 22.

× Tibia. ● Femur.

TABLE 22

Absolute length of fresh limb bones in millimeters, on body length. Values taken from the smoothed graphs in charts 18 and 19

BODY LENGTH	HUMERUS	ULNA	RADIUS	FEMUR	TIBIA
<i>mm.</i>	<i>mm.</i>	<i>mm.</i>	<i>mm.</i>	<i>mm.</i>	<i>mm.</i>
47.5	7.0	7.5	6.2	6.4	7.0
50.0	7.1	7.7	6.5	6.8	7.3
52.5	7.3	7.8	6.7	7.2	7.6
55.0	7.6	8.1	6.8	7.6	8.0
57.5	8.0	8.6	7.1	7.9	8.5
60.0	8.6	9.3	7.4	8.3	9.0
62.5	9.4	10.0	8.0	8.9	9.7
65.0	10.1	10.7	8.6	9.6	10.9
67.5	10.5	11.4	9.2	10.2	11.9
70.0	10.9	12.3	9.8	10.6	12.8
72.5	11.1	12.9	10.3	11.1	13.7
75.0	11.3	13.3	10.6	11.5	14.4
77.5	11.6	13.6	10.9	11.9	15.2
80.0	11.9	14.0	11.1	12.4	15.8
82.5	12.2	14.4	11.4	12.8	16.3
85.0	12.4	14.8	11.6	13.2	16.8
87.5	12.7	15.2	11.8	13.6	17.3
90.0	13.0	15.6	12.1	14.0	17.8
92.5	13.3	16.0	12.3	14.5	18.3
95.0	13.6	16.4	12.4	14.9	18.7
100.0	14.1	17.2	12.9	15.7	19.5
105.0	14.7	17.8	13.4	16.6	20.3
110.0	15.1	18.3	13.8	17.3	21.1
115.0	15.6	18.8	14.3	18.2	21.8
120.0	15.9	19.1	14.7	19.0	22.7
125.0	16.3	19.5	15.1	19.8	23.6
130.0	16.8	19.9	15.4	20.7	24.5
135.0	17.2	20.4	15.8	21.5	25.3
140.0	17.9	20.9	16.3	22.2	26.3
145.0	18.4	21.6	16.9	23.2	27.1
150.0	19.0	22.1	17.5	24.2	27.9
155.0	19.9	23.0	18.2	25.1	28.8
160.0	20.6	23.9	18.8	26.1	29.7
165.0	21.2	24.8	19.5	27.0	30.5
170.0	22.0	25.3	20.1	28.0	31.4
175.0	22.8	26.1	20.8	29.0	32.2
180.0	23.3	26.9	21.4	29.9	33.1
185.0	24.0	27.8	22.0	30.8	33.9
190.0	24.9	28.6	22.8	31.8	34.7
195.0	25.8	29.5	23.6	32.8	35.6
200.0	26.3	30.3	24.2	33.7	36.4
210.0	27.6	31.5	25.4	35.6	38.0
220.0	28.9	32.8	26.3	37.5	39.6
230.0	30.2	34.0	27.3	39.2	41.2
240.0	31.3	35.0	28.2	40.5	42.6
250.0	32.2	36.1	29.1	41.8	44.2

TABLE 23

Relative length of fresh limb bones on the body length. No charts

BODY LENGTH	HUMERUS	ULNA	RADIUS	FEMUR	TIBIA
<i>mm.</i>	<i>per cent</i>	<i>per cent</i>	<i>per cent</i>	<i>per cent</i>	<i>per cent</i>
47.5	14.7	15.7	13.1	13.5	14.7
50.0	14.2	15.4	13.0	13.6	14.6
52.5	13.9	14.8	12.8	13.7	14.5
55.0	13.8	14.7	12.4	13.8	14.5
57.5	14.0	15.0	12.4	13.8	14.9
60.0	14.3	15.5	12.3	13.8	15.0
62.5	15.0	16.0	12.8	14.2	15.5
65.0	15.5	16.5	13.2	14.8	16.8
67.5	15.6	16.9	13.6	15.1	17.6
70.0	15.5	17.6	14.0	15.1	18.3
72.5	15.3	17.8	14.2	15.3	18.9
75.0	15.1	17.7	14.1	15.3	19.2
77.5	15.0	17.5	14.1	15.4	19.6
80.0	14.9	17.5	13.9	15.5	19.8
82.5	14.8	17.5	13.8	15.5	19.8
85.0	14.6	17.4	13.6	15.5	19.8
87.5	14.5	17.4	13.5	15.5	19.8
90.0	14.4	17.3	13.4	15.6	19.8
92.5	14.3	17.3	13.3	15.7	19.8
95.0	14.3	17.3	13.1	15.7	19.7
100.0	14.1	17.2	12.9	15.7	19.5
105.0	14.0	17.0	12.8	15.8	19.3
110.0	13.7	16.6	12.5	15.7	19.2
115.0	13.6	16.4	12.4	15.9	19.0
120.0	13.3	15.9	12.3	15.8	18.9
125.0	13.0	15.6	12.1	15.8	18.9
130.0	12.9	15.3	11.8	15.9	18.9
135.0	12.7	15.1	11.7	15.9	18.7
140.0	12.8	14.9	11.6	15.9	18.8
145.0	12.7	14.9	11.7	16.0	18.7
150.0	12.7	14.7	11.7	16.1	18.6
155.0	12.8	14.8	11.7	16.2	18.6
160.0	12.9	14.9	11.8	16.3	18.6
165.0	12.9	15.0	11.8	16.4	18.5
170.0	12.9	14.9	11.8	16.5	18.5
175.0	13.0	14.9	11.9	16.6	18.4
180.0	12.9	14.9	11.9	16.6	18.4
185.0	13.0	15.0	11.9	16.6	18.3
190.0	13.1	15.1	12.0	16.7	18.3
195.0	13.2	15.1	12.1	16.8	18.3
200.0	13.2	15.2	12.1	16.9	18.2
210.0	13.1	15.0	12.1	17.0	18.1
220.0	13.1	14.9	12.0	17.0	18.0
230.0	13.1	14.8	11.9	17.0	17.9
240.0	13.0	14.6	11.8	16.9	17.8
250.0	12.9	14.4	11.6	16.7	17.7

GROWTH OF THE LONG BONES IN TRANSVERSE DIAMETER

It is of interest for us to get an idea of the shape of the long bones at different ages and to determine whether there is any progressive change in shape between birth and maturity. It is not possible, however, to do this precisely without a more elaborate study than we can make now, but it is possible by some simple computations to obtain a rough idea of what is taking place.

From the data on the lengths of the fresh bones (table 20) and those on the weights of the fresh bones (table 12) we can compute the weight of a running millimeter, treating the bones

TABLE 24

The relative lengths of the several long bones on body length in rats over 160 mm. in body length (i.e., over 100 grams in body weight). Averages given in three body length groups

BONE	GROUP 1	GROUP 2	GROUP 3	GENERAL AVERAGE
	165-185 mm.	190-210 mm.	220-250 mm.	165-250 mm.
	<i>per cent</i>	<i>per cent</i>	<i>per cent</i>	<i>per cent</i>
Humerus.....	12.94	13.05	13.02	13.00
Ulna.....	14.94	15.10	14.68	14.91
Radius.....	11.86	12.08	11.82	11.92
Femur.....	16.68	16.85	16.90	16.81
Tibia.....	18.42	18.22	17.82	18.15

as if they were solid cylinders having their axes equal to the bone lengths.³

³ In making the computations which are required, the values just as they appear in tables 12 and 20 have been used. Concerning these a word of comment is necessary. The lengths used are those for the single bones—humerus, ulna, femur, and tibia, respectively. The weights, however, are in each instance for both bones—right plus left. Furthermore, the length for the ulna is used as a divisor for the weight of the ulna plus radius (2), and the length for the tibia as a divisor for the weight of the tibia plus fibula (2), so that the significance of the values for a running millimeter is not exactly the same for the humerus and femur as for the other bones with which they are compared. As, however, it is the change in the weight of the running millimeter rather than its absolute value which is here important, it has seemed best to use the table values as they stand rather than develop new tables for this special purpose.

If the weight of a running millimeter as thus obtained, and shown in charts 20 and 21, is accepted as the basis for comparison, it becomes easy by the use of this datum to follow the changes in the dimensions of the cylinders which by assumption represent the bones as they increase in size.

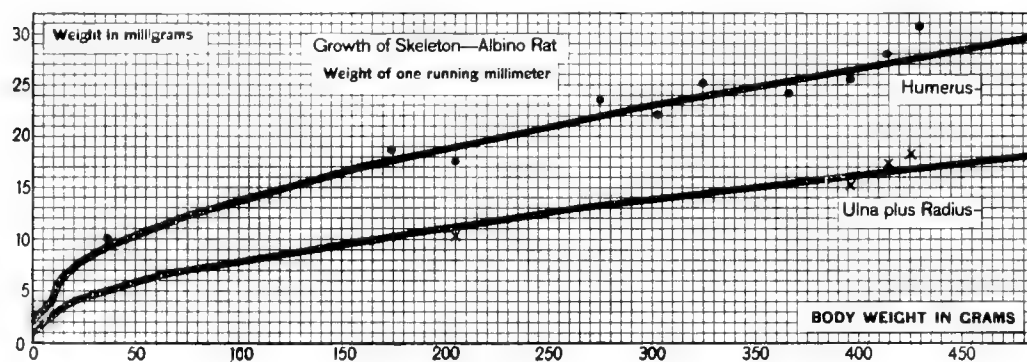


Chart 20 Weight in milligrams of one running millimeter of fresh fore-limb bones, on body weight (albino rat). No table.

● Humerus. × Ulna plus radius.

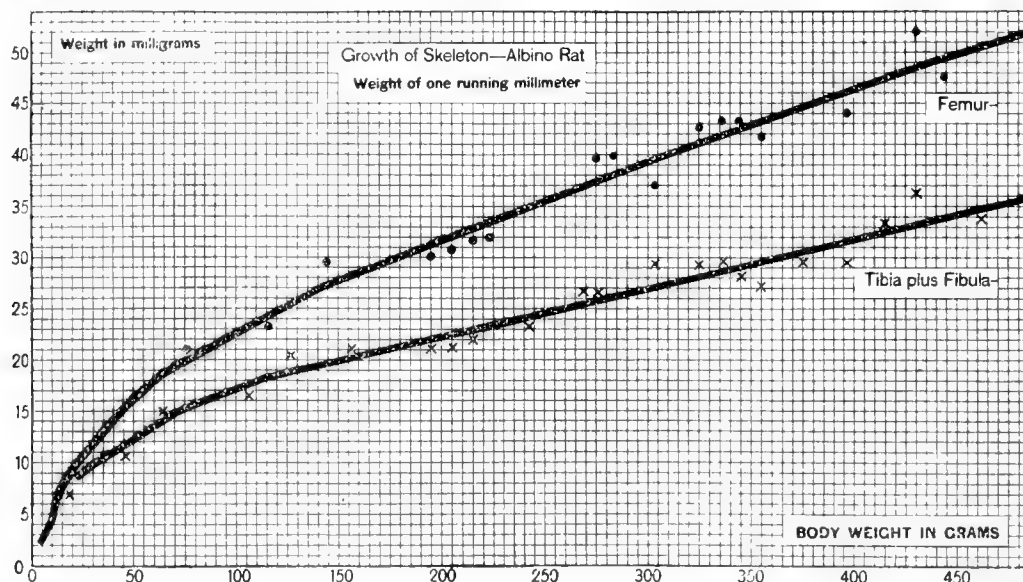


Chart 21 Weight in milligrams of one running millimeter of fresh hind-limb bones, on body weight (albino rat). No table.

● Femur. × Tibia plus fibula.

It will be sufficient for the present purpose to use the data for four body weights only, namely, at 5 grams, or birth; 20 grams, weaning time; 100 grams, or puberty, and 485 grams, or maturity.

Table 25 gives, however, not the values for the weights of a running millimeter, but the ratios of the square roots of these values. The square roots stand to one another as do the transverse diameters of the respective cylindrical segments 1 mm. in length, and it is the ratio of these transverse diameters (the value at 5 grams being taken as unity) which is required for comparison with the corresponding ratios of the bone lengths at the same phases of growth.

TABLE 25

Giving the ratios of the square roots of the values for the fresh weights of a running millimeter of the several long bones. These values are proportional to those for the diameters of the hypothetical cylinders. Based on the division of the fresh bone weights (table 12) by the fresh bone lengths (table 20)

BODY WEIGHT	HUMERUS	ULNA PLUS RADIUS	FEMUR	TIBIA PLUS FIBULA
<i>grams</i>				
5	1	1	1	1
20	1.27	1.34	1.54	1.24
100	1.78	1.79	2.32	1.92
485	2.67	2.68	3.56	2.88

TABLE 26

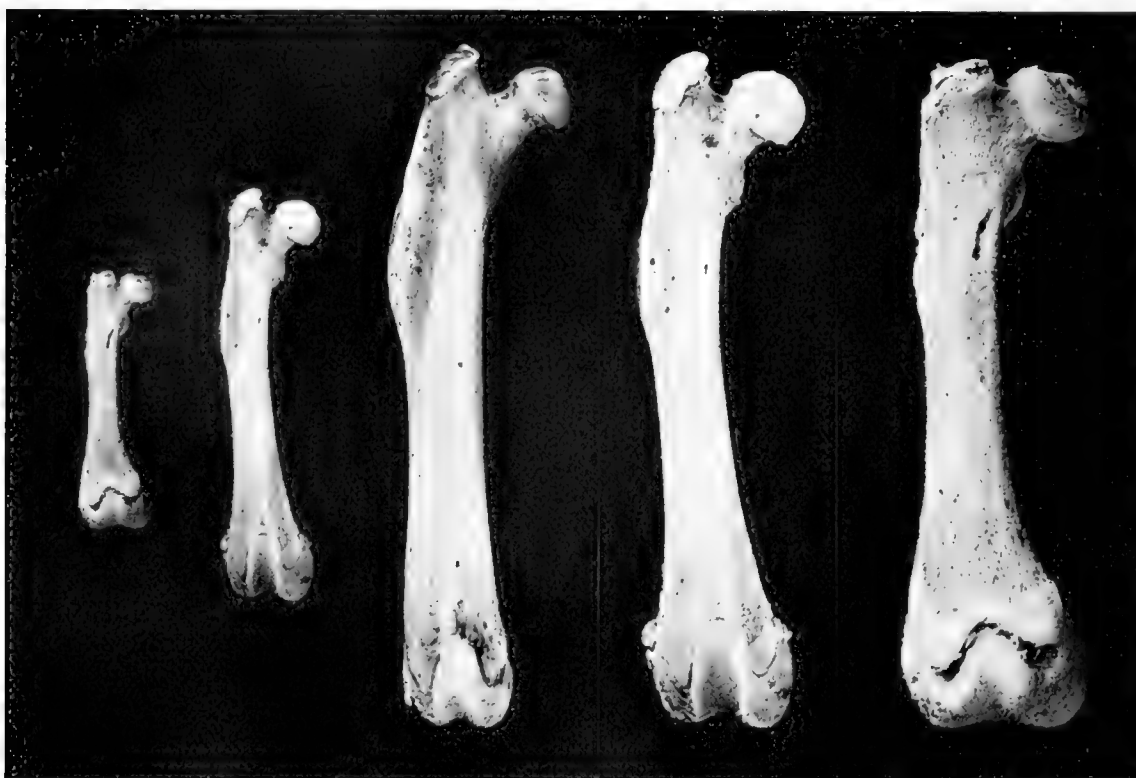Giving the ratios of the lengths of the several fresh bones. Based on data in table 20

BODY WEIGHT	HUMERUS	ULNA	FEMUR	TIBIA
<i>grams</i>				
5	1	1	1	1
20	1.84	1.93	1.89	2.56
100	2.93	2.96	3.46	4.25
485	4.47	4.52	5.56	6.30

If tables 25 and 26 are examined with care it will be seen that in a general way about one-half the total increase in diameter and two-fifths of the increase in length has occurred at a body weight of 20 grams (weaning time) and two-thirds of the total increase in both diameter and length at a body weight of 100 grams (puberty). As the ratios in tables 25 and 26 show, the growth in length is proceeding more rapidly than the growth in the computed diameter. This of course is a continuation of a change in shape, which

has been in progress since the fetal period, at which time these bones are characteristically short, thick, and clumsy.

In order to illustrate these changes, figure 1 is given in which is shown at A, B, and C the left femur at three ages, as described in the legend to the figure.



A B C D E

Fig. 1 Showing the form of the oven-dried femur at several different ages. A, B, and C represent the relative lengths and the shapes of the bones designated, while D represents B photographically enlarged to the length of C and E represents A similarly enlarged.

The data for the albino rats from which these oven-dried bones were taken are as follows:

	<i>Bd. wt.</i> <i>grams</i>	<i>Age in</i> <i>days</i>	<i>Length of</i> <i>bone</i> <i>mm.</i>
A.....	46.1	33	16.2
B.....	106.0	84	25.7
C.....	460.0	512	42.2

One notes the relative overdevelopment of the extremities of the bones in the younger animals. At D is shown the bone B enlarged to the length of C, and at E the bone A similarly enlarged. When these enlarged younger bones are compared with

the mature femur, it is seen that while enlargement by magnification does not reveal any marked differences in the thickness of the shaft, yet it does give us a bone in which the extremities are relatively very large. The actual process of growth brings about, therefore, the changes in proportion which are indicated by a comparison of E with C. The humerus also has been studied in this way and undergoes a similar change in form.

It appears, then, that as these bones pass from the immature to the mature condition, they become more nearly rod shaped and less clumsy in form, and we note in passing that this change in shape during growth opens a field for study which thus far has been little cultivated.

What cannot be determined without elaborate investigation is whether this distribution of the bony substance by weight represents the distribution as it would be brought out by compass measurements, but the impression given by a preliminary study of a series of bones, and by figure 1, is that between puberty and maturity the very slight change in the relative linear dimensions of the bones is such as to make the largest full-grown bones relatively a trifle more slender than those which are half grown and younger.

This result is, we think, contrary to the current view that during postnatal growth bones become relatively thicker as they become older. We may, however, be wrong in our impression as to the current view concerning this change.

On the relative lengths of the long bones of the limbs when compared among themselves

To obtain the relative length of the bones in the fore limb on the length of the corresponding bones on the hind limb, we divide the sum of the lengths of the humerus plus the ulna or plus the radius, on the one hand, by the sum of the lengths of the femur plus the tibia. The ratios are given as percentages in table 27 and the corresponding smoothed graphs in chart 22.

To compare the growth of the distal bone in each limb with that of the proximal bone, the length of the ulna or of the radius has

been divided by the length of the humerus, and the length of the tibia by that of the femur. The ratios are given as percentages also in table 27 and the corresponding smoothed graphs are shown in chart 22.

Finally, the homologous bones in the two limbs have been compared as to their growth in length; radius or ulna divided by length of tibia, and the length of humerus by that of the femur; (table 28, chart 23).

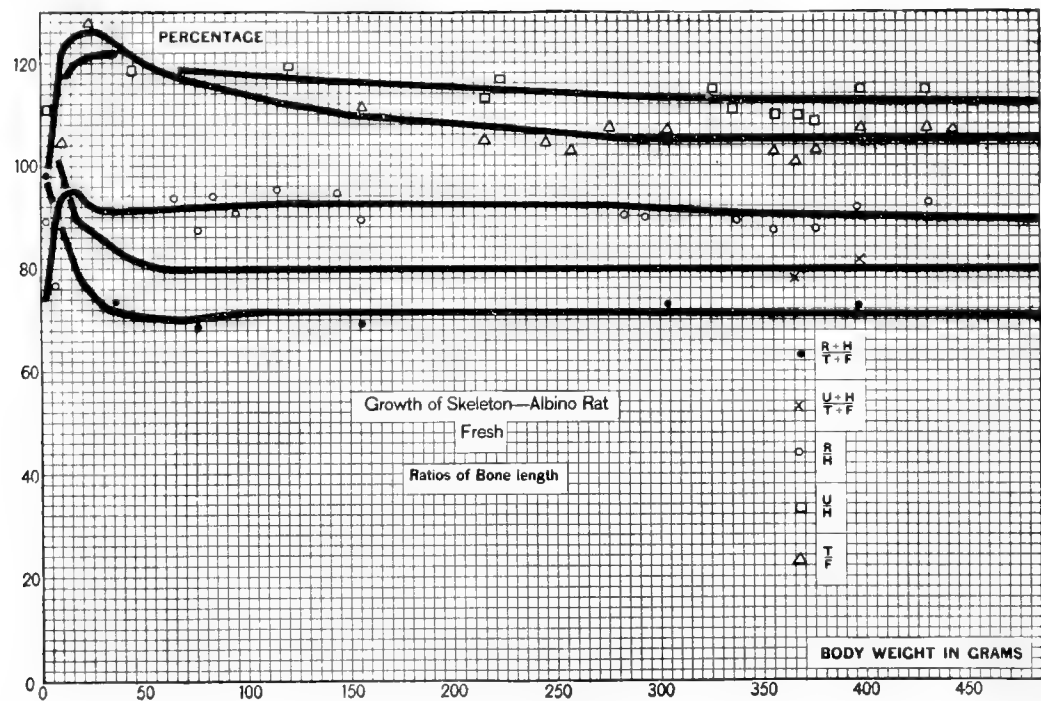


Chart 22 Ratios of fresh bone lengths, on body weight (albino rat).
Table 27.

$$\bullet \frac{\text{Radius} + \text{Humerus}}{\text{Tibia} + \text{Femur}} \times \frac{\text{Ulna} + \text{Humerus}}{\text{Tibia} + \text{Femur}}$$

$$\circ \frac{\text{Radius}}{\text{Humerus}} \quad \square \frac{\text{Ulna}}{\text{Humerus}} \quad \triangle \frac{\text{Tibia}}{\text{Femur}}$$

There are two large relations which stand out clearly in this comparison. During early life the length of the bones of the hind limb increases more rapidly than that of the bones of the fore limb (table 27, chart 22), so the percentage value for the fore-limb bones diminishes from birth, at first rapidly, up to about 50 grams of body weight (or thirty-five to forty-five days of age), but after that period it remains practically constant.

TABLE 27

Ratios of fresh limb-bone lengths, on body weight. Values taken from the smoothed graphs in chart 22

BODY WEIGHT	HUMERUS + RADIUS	HUMERUS + ULNA	TIBIA	ULNA	RADIUS
	FEMUR + TIBIA	FEMUR + TIBIA	FEMUR	HUMERUS	HUMERUS
<i>grams</i>	<i>per cent</i>	<i>per cent</i>	<i>per cent</i>	<i>per cent</i>	<i>per cent</i>
5	94.2	106.8	104.8	104.8	83.0
10	88.1	100.0	122.0	116.4	93.9
15	82.4	93.6	124.8	119.2	95.2
20	78.0	89.1	125.9	120.8	94.4
25	75.6	87.4	126.1	121.6	91.8
30	73.2	85.8	125.8	122.0	91.2
35	72.2	84.0	124.4	122.4	91.2
40	71.6	82.8	123.0	122.0	91.2
45	71.2	82.0	121.4	120.8	91.3
50	70.9	81.2	120.1	119.8	91.4
55	70.7	80.8	119.4	118.9	91.5
60	70.4	80.1	118.4	118.8	91.6
65	70.1	80.0	117.8	118.7	91.8
70	70.4	80.0	116.9	118.6	91.9
75	70.6	80.0	116.5	118.4	92.0
80	70.7	80.0	116.0	118.2	92.0
85	70.8	80.0	115.4	118.1	92.0
90	71.0	80.0	114.9	118.0	92.1
95	71.2	80.0	114.4	117.9	92.2
100	71.5	80.0	113.9	117.8	92.3
110	71.5	80.0	112.9	117.5	92.5
120	71.5	80.0	112.1	117.2	92.7
130	71.5	80.0	111.4	116.9	92.6
140	71.5	80.0	110.6	116.6	92.6
150	71.5	80.0	110.0	116.4	92.6
160	71.5	80.0	109.6	116.2	92.6
170	71.5	80.0	109.2	116.0	92.6
180	71.5	80.0	108.8	115.9	92.5
190	71.5	80.0	108.4	115.6	92.4
200	71.4	80.0	108.1	115.4	92.4
250	71.2	80.0	106.4	114.3	92.2
300	71.2	80.0	105.4	113.3	91.5
350	71.2	80.0	105.4	113.1	90.6
400	71.2	80.0	105.4	112.8	90.1
450	71.2	80.0	105.5	112.7	89.8
485	71.2	80.0	105.6	112.6	89.8

The second large relation is between the growth in length of the proximal and the distal bones of the limbs. In both the fore and the hind limb the growth of the proximal bones is at first less rapid than that of the distal bones, giving the peculiar form of graph shown in chart 22. After a body weight of 20 to 35 grams the relative growth of all the distal bones becomes less rapid, falling off steadily in the case of the tibia and the ulna, and showing a slight fluctuation in the case of the radius.

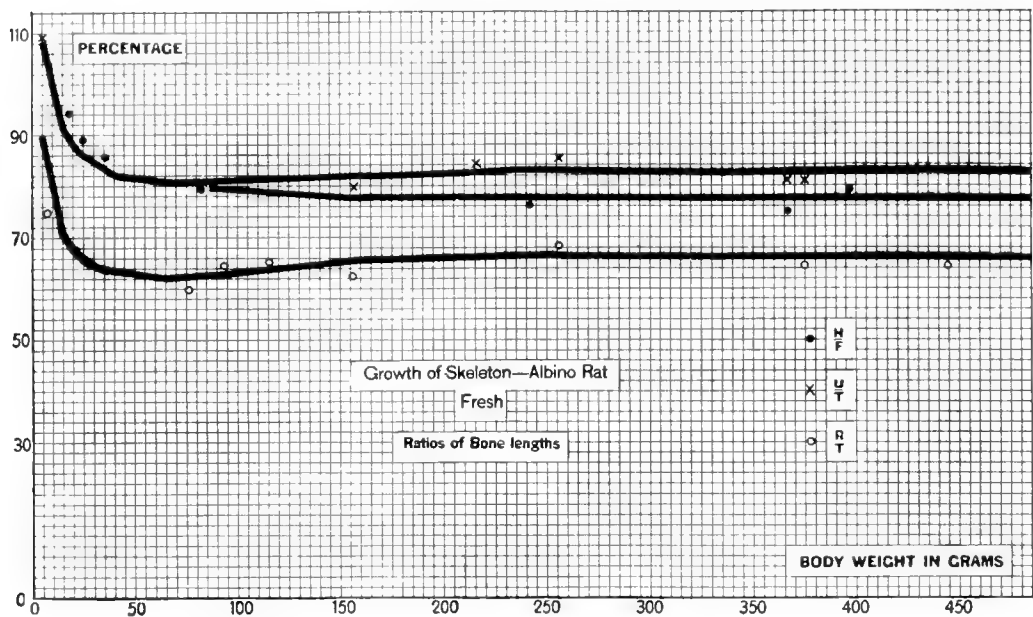


Chart 23 Ratios of fresh lengths of homologous limb bones, on body weight (albino rat) Table 28.

$$\bullet \frac{\text{Humerus}}{\text{Femur}} \quad \times \frac{\text{Ulna}}{\text{Tibia}} \quad \circ \frac{\text{Radius}}{\text{Tibia}}$$

When the ratios of the lengths of the humerus plus radius, humerus plus ulna, and femur plus tibia are taken on the body lengths, as in table 29, there appears rather a high degree of constancy in all cases after a body length of 125 mm., equivalent to about 50 grams in body weight.

TABLE 28

Ratios of fresh limb-bone lengths on body weight. Bones from corresponding segments of the two limbs. Values taken from the smoothed graphs in chart 23

BODY WEIGHT	HUMERUS FEMUR	ULNA TIBIA	RADIUS TIBIA
<i>grams</i>	<i>per cent</i>	<i>per cent</i>	<i>per cent</i>
5	109.0	108.6	89.6
10	102.0	100.0	79.2
15	95.9	91.4	70.6
20	90.8	88.1	67.6
25	87.9	86.0	65.6
30	86.4	84.7	64.4
35	85.0	83.4	63.9
40	83.6	82.2	63.6
45	82.0	81.6	63.2
50	81.3	81.4	62.9
55	80.8	81.3	62.7
60	80.0	81.1	62.4
65	80.0	80.8	62.2
70	80.0	80.8	62.3
75	79.9	80.8	62.4
80	79.8	80.9	62.6
85	79.8	81.0	62.7
90	79.3	81.0	62.8
95	79.2	81.1	62.9
100	79.1	81.2	63.2
110	78.9	81.3	63.5
120	78.6	81.5	64.0
130	78.4	81.6	64.4
140	78.1	81.6	64.8
150	77.9	81.8	65.2
160	77.7	81.9	65.5
170	77.8	82.0	65.6
180	77.9	82.0	65.9
190	77.9	82.1	66.0
200	77.9	82.2	66.1
210	77.9	82.4	66.2
220	77.8	82.6	66.3
230	77.8	82.8	66.4
240	77.8	83.1	66.5
250	77.8	82.9	66.7
270	77.7	82.9	66.6
290	77.6	82.8	66.4
310	77.6	82.6	66.4
330	77.6	82.5	66.2
350	77.6	82.6	66.2
370	77.5	82.6	66.2
390	77.5	82.7	66.2
410	77.4	82.8	66.1
430	77.5	82.8	66.1
450	77.6	82.8	66.1
470	77.5	82.8	66.1
485	77.4	82.8	66.1

TABLE 29

Ratios of fresh limb-bone lengths on body length. A body length of 125 mm. is normal to a body weight of 50 grams. No chart

BODY LENGTH	HUMERUS + RADIUS BODY LENGTH	HUMERUS + ULNA BODY LENGTH	FEMUR + TIBIA BODY LENGTH
<i>mm.</i>	<i>per cent</i>	<i>per cent</i>	<i>per cent</i>
47.5	27.8	30.4	28.2
50.0	27.2	29.6	28.2
52.5	26.7	28.7	28.2
55.0	26.2	28.5	28.3
57.5	26.3	29.0	28.7
60.0	26.6	29.8	28.8
62.5	27.8	31.0	29.7
65.0	28.7	32.0	31.6
67.5	29.2	32.5	32.7
70.0	29.5	33.1	33.4
72.5	29.5	33.1	34.2
75.0	29.2	32.8	34.5
77.5	29.1	32.5	35.0
80.0	28.8	32.4	35.3
82.5	28.6	32.3	35.3
85.0	28.2	32.0	35.3
87.5	28.0	31.9	35.3
90.0	27.8	31.7	35.4
92.5	27.6	31.6	35.5
95.0	27.4	31.6	35.4
100.0	27.0	31.3	35.2
105.0	26.8	31.0	35.1
110.0	26.2	30.3	34.9
115.0	26.0	30.0	34.9
120.0	25.6	29.2	34.7
125.0	25.1	28.6	34.7
130.0	24.7	28.2	34.8
135.0	24.4	27.8	34.6
140.0	24.4	27.7	34.7
145.0	24.4	27.6	34.7
150.0	24.4	27.4	34.7
155.0	24.5	27.6	34.8
160.0	24.7	27.8	34.9
165.0	24.7	27.9	34.9
170.0	24.7	27.8	35.0
175.0	24.9	27.9	35.0
180.0	24.8	27.8	35.0
185.0	24.9	28.0	34.9
190.0	25.1	28.2	35.0
195.0	25.3	28.3	35.1
200.0	25.3	28.4	35.1
210.0	25.2	28.1	35.1
220.0	25.1	28.0	35.0
230.0	25.0	27.9	34.9
240.0	24.8	27.6	34.7
250.0	24.5	27.3	34.4

SUMMARY OF THE OBSERVATIONS ON THE RAT

The entire cartilaginous skeleton increases in absolute weight rather steadily from birth to the end of the record (chart 1, table 2).

In relative weight it increases up to about 15 grams of body weight, and after that decreases. With the method of maceration here used, the cartilaginous skeleton represents in the mature rat about 5 per cent of the total body weight (chart 2, table 2).

On considering the two main components of the skeleton—the axial skeleton and the appendicular—it appears that the appendicular skeleton is always smaller than the axial, but that after a body weight of 15 grams, the relative weights of the two parts become nearly constant, though the appendicular division grows a trifle more slowly (chart 2, table 2).

When studied from the standpoint of relative weight, it is seen that the early rise in relative weight is more marked in the appendicular skeleton, indicating a rapid increase in the weight of the limb bones just after birth (chart 2, table 2).

The cranium shows a steady increase in absolute weight, but the rate of growth is only about two-fifths of that for the entire skeleton, and the cranium therefore diminishes in its relative weight more rapidly than the rest of the skeleton as the rat increases in size (chart 3, table 3).

If the two divisions of the appendicular skeleton are examined separately, it appears that the most marked growth before a body weight of 15 grams occurs in the pelvic girdle and appendages, indicating the relative immaturity of the hind limbs at birth, but the two girdles come into their mature relations at puberty (body weight, 100 grams) (charts 4 and 5, table 4).

When the data are plotted so as to give the growth of the skeleton on age, the general form of the graphs is sinuous, like the graphs for the growth of the body as a whole, and in addition the graphs for the two sexes diverge at about sixty days, when the differences in body weight according to sex become clearly marked (chart 6, table 5).

When the weight of all the bones in a limb is taken as the basal value, then the relative weights of the bones in each of the divisions can be computed. These relations are shown for the fore limb in chart 7 and table 6 and for the hind limb in chart 8 and table 7.

In both limbs the relative weight of the distal segment diminishes from a body weight of about 20 grams, and in about the same proportion. A comparison of the bones from the proximal and middle segments, respectively, shows in the fore limb the greater increase in the middle segment, while in the hind limb it is the proximal segment which increases most (charts 7 and 8, tables 6 and 7).

The increase in the absolute weight of the long bones of the limbs on the weight of the skeleton follows an apparently simple course (chart 9, table 8), but when the relative weights are determined, the relations, up to a skeleton weight of 8 grams and a body weight of 115 grams, are somewhat complicated. However, after that period the relative weights of the humerus and of the ulna plus radius are nearly constant, while the percentage value for the femur rises, and that for the tibia plus fibula first sinks and then rises again, but without reaching its initial value (chart 10, table 9).

From the weight of either the fresh humerus or fresh ulna plus radius it is possible, in rats weighing more than 115 grams, to compute with a high degree of accuracy the weight of the fresh skeleton.

Although it seems probable that the weight of the entire skeleton varies in relation to the body weight according to diet and the physiological condition of the rat, nevertheless a series of limb-bone weights on body weight is given in three conditions of moisture, since the weights of these bones can be used as standards for reference (chart 12, tables 12, 13, and 14)

Percentage of water

The determinations of the loss of water by the skeleton and its parts indicate a loss of fifty-five to sixty-five points between

birth and maturity, the dense bones, without cavities, showing the smallest percentage at maturity. It seems probable that the percentage of water in osseous tissue is fairly constant at maturity, but in the several bones taken as units it varies according to the presence of cavities, porosity, and other mechanical conditions. A certain amount of variation is to be expected also according to the degree of calcification and the possible age changes in the water content of the collagen. Between the room-dried and oven-dried condition there is in general and at all ages a loss of 8.3 per cent of water (charts 13 to 16, tables 15 to 19).

Length of limb bones

Although it is somewhat incongruous to determine lengths in relation to body weights, yet tests indicate that the fresh lengths of the leg bones are closely related to the body weight of the rat, and in cases where the rat is heavy for its body length, they follow the *body weight* closely (chart 17, table 20).

After puberty the change in bone length on drying is less than 1 per cent (table 21).

The limb-bone lengths on body length (charts 18 and 19, table 22), when cast in the form of percentages (table 23), yield a series of proportional values which after puberty (body length, 160 mm.) are fairly constant, notably for the humerus (table 24). By the use of the data in table 24 it is therefore possible to recover the body length of the rat from the lengths of its limb bones.

Form of the limb bones

When, on the basis of the weight of a running millimeter (charts 20 and 21), the shape of the bones at maturity is compared with that at birth it is found that at maturity the limb bones are relatively more slender than at birth (tables 25 and 26). They are close to the mature proportions of length to diameter at puberty. The comparison of these determinations with compass measurements and a comparison by means of photographs support this statement (fig. 1).

On the relative lengths of the limb bones

As is shown in chart 22 and table 27, the combined lengths of the femur and tibia first increase more rapidly than those of the humerus and radius up to a body weight of 40 grams, after which the rate of increase is similar, and the length ratios remain nearly constant. The same can be said when the ulna is substituted for radius in the comparison, only in this latter instance the constant relations do not appear until a body weight of 65 grams.

When the increase in the length of the femur is compared with that of the tibia, or that of the humerus with the ulna or radius, it appears that in all instances the more distal bones grow the more rapidly. After a body weight of 15 to 35 grams, however, the growth of the distal bone becomes the less rapid and the ratio of lengths falls, nearly regularly, to the end of the record (chart 22, table 27).

Finally, when the lengths of the leg bones in relation to the length of the body are determined (table 29), it is seen that after a body length of 125 mm. (equivalent to a body weight of 50 grams) these ratios show a high degree of constancy.

Taking all the data together, it can be stated that in many cases the mature relations of weight and length among the parts of the skeleton are attained at puberty or earlier.

DISCUSSION

In making comparisons with the results for the rat as just recorded we shall consider them very briefly in relation, first, to the available records for mammals below man, and, second, in relation to the records for man himself. So far as we know, there is no study on any lower mammal with which our results can be directly compared. The investigation nearest to our own is that by Jackson and Lowrey ('12) on the ligamentous skeleton of the albino rat. This study was based on seven age groups from 0 to 365 days. As shown in their table 4 and their chart, (page 463, loc. cit.) the maximum relative weight of the skeleton appears a few days after birth—in their ten-day group. Our data show the same relation at six and nineteen days (table 1). There

is, therefore, a period of relatively rapid increase in the weight of the skeleton shortly after birth which is shown in both studies. At maturity the fresh skeleton as prepared by them represented about 11 per cent of the body weight, while as prepared by us it represents about 5 per cent.

That this difference is due to the method of preparation was shown by the fact that when Professor Jackson kindly dissected for us in our laboratory a skeleton which was duly weighed and then further prepared by the macerating process, which we employed, and again weighed, the several values obtained in this test stood in the relation which has just been given.

In this connection we have also to consider the determinations made by Lowrey ('13) of the dry substance in the ligamentous skeleton of the albino rat. If the percentages of water are derived from the percentages of the dry substance, it appears that Lowrey's determinations give a higher water content than that found by us, especially in the later age groups. The difference is not great, however, and seems easily referable to the greater amount of soft tissue present after his method of preparation, combined on the other hand with the slight reduction in the water content caused by the maceration of our material.

In a study of the weight of the room-dried cranium (Donaldson, '12, table 4) determinations were made for five body-weight groups of Albinos grown in The Wistar Institute colony. The values there given are in close agreement with those presented in our table 3. They are as follows (table 30):

TABLE 30

Weight of cranium, room dried; albino rat

	BODY WEIGHT GROUP				
	125 grams	175 grams	225 grams	275 grams	325 grams
From Donaldson ('12 a).....	1.05	1.41	1.51	1.87	2.15
From table 3.....	1.04	1.32	1.58	1.85	2.09

We have, however, not made any measurements on the crania of our series that might be compared with the observations of

Hatai ('07) on the linear measurements of the cranium in the mature albino rat.

It may be noted that the records on the relative lengths of the limb bones of the rat which appear in tables 53 and 54 of 'The Rat' (Donaldson, '15) are based on some of the same data that have been used in this present paper, but the corresponding tables here given are more complete and are to be preferred to those published earlier.

Although the studies of Falck ('54) on the skeleton of the dog, of Weiske ('89) on the bones of birds, of Wildt ('72) and Graffenberger ('91) on the bones of rabbits, of Tribot ('06) on the skeleton of the guinea-pig, and of Sedlmair ('99) on that of the cat, all contain data which might be brought into relation with our own, yet the comparisons which could be made are so few, and are also subject to so many corrections for the effects of species, age, sex, diet, technique, etc., that it does not seem wise to attempt them.

It may be said, however, in a general way that there does not appear in our results anything contradictory to those previously reported. In the paper by Jackson and Lowrey ('12, pp. 465 and 466) the data on the relative weights of the skeleton in a series of vertebrates, man included, are given, and a number of values derived from the extensive tables of Welcker and Brandt ('03) are also given in this list, but no critical analysis of the data is there attempted. Such an analysis is, however, necessary before one can interpret the relations between the values as reported.

COMPARISON WITH MAN

The relative fresh (or moist) weight of the human skeleton is reported by several authors, although the determinations are usually deficient in the designation of race, of the relation of the body weight to the cause of death, as well as of the method of preparation. Schwann ('43), Bischoff ('63), Dursy ('63), v. Liebig ('74), Volkmann ('74), and Theile ('84) have furnished data, and the general result is that the weight of the moist skeleton is on the average about 16 per cent of the total body weight.

In the figures as published there is no conclusive evidence for a difference according to sex or to age between birth and maturity.

When the foregoing data for the rat are compared with those for man, it appears that in man there is no phase of relatively rapid growth of the skeleton in weight during the period just after birth. Further, there does not appear in man a regular diminution in the relative weight of the skeleton during the period preceding puberty corresponding to the period in the rat during which the relative weight falls from 10 per cent to 7 per cent as shown in our table 2. It should be reiterated, however, that the data for man are very incomplete.

At maturity the percentage weight of the moist skeleton in man (16 per cent) is higher than that in the ligamentous skeleton (11 per cent) or in the cartilaginous skeleton (5 per cent) of the albino rat. Since the form of the rat body is so different from that of the human body in which the limbs are relatively much longer, it is not surprising that the relative weights of the skeleton at maturity should be dissimilar, but the apparent constancy of the relative weight in man from birth on is a matter of some interest.

Theile ('84) made studies of the human skeleton according to a plan fairly comparable with our own, but these were confined to the first seven years of life. In so far as we can compare our results with his, it appears that the relative growth of the parts of the skeleton, compared with one another, takes place in man in the same manner that it does in the rat.

The observations of Stratz ('09) in man show also the relatively slower growth of the head, as noted for the cranium of the rat (p. 299) as well as the relatively slower growth of the arms in length. Indeed, at maturity Stratz gives the arm length as 80 per cent of the leg length, and this is the same ratio as is found in the rat for the length of the humerus plus ulna divided by that of femur plus tibia, as shown in table 27 and chart 22.

When the relative length of the humerus plus radius to femur plus tibia is computed, it is found to range in the rat from 94 per cent at 5 grams of body weight to about 71 per cent at 40 grams, after which it varies but slightly (chart 22, table 27).

The corresponding determinations for man based on the data given by Humphry ('58) and plotted by Duckworth ('04) show a range from 100 per cent at birth to about 70 per cent in adults. Thus the intermembral ratio is about the same in these two forms, despite the very different use of the fore limbs in the two cases. This similarity is of course a mere coincidence, as the corresponding ratios among the Simiidae, zoologically closest to man, are all much higher.

In the case of the radio-humeral index, the value in man is about 74 per cent at birth and 72 per cent at maturity, while for the rat the record, which is slightly sinuous, reaches a maximum of 95 per cent at a body weight of 15 grams, and then in general falls to about 90 per cent at maturity (chart 22, table 27). The ulno-humerus ratio for the rat follows a like course from a maximum of 122 per cent at 35 grams of body weight to a minimum of 113 per cent at maturity (chart 22, table 27).

If we turn now to a consideration of the bone relations in the leg, we find that the tibio-femoral index for man ranges from about 81 per cent at birth to 80 per cent at maturity, while for the rat the corresponding ratios are 126 per cent at 25 grams of body weight and 106 per cent at maturity. Despite the fact, therefore, that the intermembral ratios are rather similar, the radius, ulna, and tibia all have a greater relative length in the rat than in man.

The relation of the stature in man at maturity to that of the several long bones of the limbs has been carefully worked over by Manouvrier ('92). His tables are given by Testut ('96), and further refinements in the application of the data have been elaborated by Pearson ('99).

Owing to the difference in the form of man and the rat, no really comparable measurement can be made on the rat, but if it is desired to recover the body length (nose-anus length) of the rat in any case from the length of one or more of the leg bones, this can be done by the aid of table 29, which gives the ratios of the body length in relation to the sum of the lengths of the humerus plus radius, humerus plus ulna, or femur plus tibia.

In all these cases this ratio becomes nearly constant at a body length of 125 mm. (body weight, 50 grams), or some time before puberty.

In the foregoing summary of our observations on the rat, the results to which attention is especially called have been noted. To this summary have been added several comparisons with the data on other mammals, including man. It remains now only to make a few general statements.

GENERAL CONSIDERATIONS

Our records do not show just how long the growth of the skeleton in weight continues in the rat, but from the data at hand we should say it was still growing at 474 days of age, which, according to our usual computation (Donaldson, '15, p. 6) is equivalent to thirty-nine years of human life. The only datum for man with which this can be compared is the linear measurement represented by the stature, which seems to reach its maximum at about twenty-eight years in the human male and twenty-five years in the female. If the increase in the weight of the human skeleton ceases at the time when the increase in stature stops, then it is clear that the growing period for the skeleton of the rat is much longer continued, and this conclusion agrees with our general impressions concerning the growth of this animal.

It is to be noted, however, that the mature relations among the parts of the skeleton are established for the most part at puberty or earlier, while the weight of the skeleton as a whole, relative to the body weight, tends to decrease slowly as the rat becomes larger.

During the period between birth and puberty there is, however, an interesting change in the form of the long bones which we have examined in a preliminary way by the study of the weights of a running millimeter at different ages.

When the changes in the weight-length relations during the growth of the rat are followed by dividing the values in table 26 by the corresponding values in table 25, it appears that at maturity the growth in length is about 1.8 times that in diameter, while at puberty it is about 1.7 times, and at weaning about 1.5

times. We may infer, therefore, that the change in proportion takes place during the period of rapid growth preceding puberty.

This is the period of calcification, and it seems most probable that the change in form accompanies the change in material, as the bones pass from a state of cartilage, a comparatively weak material, to that of the completely ossified bone, which is remarkably strong, as well as possessing other mechanical properties that are noteworthy.

The fact that the long bones at maturity are more slender than at puberty, or earlier, is a result of interest in view of the statements made here and there that in order to maintain like structural strength, when enlarged, a bone must show an increase in diameter which is relatively greater than the increase in length. The earliest attempt to state these relations seems to have been made by Galileo (1638).

On page 130 of the translation of his work by Crew and Salvio (see Galileo) is given a figure showing the computed diameter of a larger bone three times the length of a smaller one. The larger bone there depicted is monstrous. In this case Galileo proceeded on the assumption that the material was the same in both bones—that the dimensions of the smaller bone enabled it to just resisting breaking when supported at one end—and that the strength of the larger bone, when so determined, was equal to that of the smaller.

On these assumptions his conclusion is valid and the dimensions shown are justified, but the selection of bones to illustrate these relations was unfortunate and misleading because osseous tissue has qualities quite different from those which were assumed for the argument.

The data presented have two different uses; one, to show the manner in which the weight and length of the various parts of the skeleton increase, and the other, to give a series of values to which subsequent observations can be referred for comparison.

A word of comment on this second use is in order. Despite the fact that the bones are so dense and give so direct an impression of immutability, yet a moment's consideration serves to make it plain that like the other systems of the body the osseous system

is responsive to nutritive conditions, and in reality is much more plastic than one might at first be inclined to suppose. We do not allude to the changes induced by recognized disease (Wolff, '92) or starvation (Voit, '05) or the great loss in the weight of the bones in extreme old age in man, as, for example, in the case of the centenarian described by Waldeyer ('10), a loss which is merely an extreme instance of the senile atrophy that is generally recognized, nor to those atrophies which appear in the skull of the horse (Ussow, '01), of old dogs (Schmey, '15), and in the brain case of old mustelidae as described by Thomas ('86), nor the modifications in the skulls of 'park reared' lions as reported by Hollister ('17), but to those differences in the weights or lengths of the bones which depend on diet in the narrower sense and which may be present during the prime of life.

It has been shown by Burnett ('08, '11) that the weight, strength, and composition of the bones of the pig can be modified in a very striking way by foods of different composition, and Weiske ('95) brought about changes in the chemical composition of the bones in rabbits by modification of the diet. Lactation in cows changes the salt content of the bones (Forbes, '18) and in rats which are underfed at an early age calcification can be at least greatly retarded. Moreover, observations by Weiske ('95) on rabbits, by Waters ('08, '09) on cattle, and by Aron ('11) on dogs have shown that during prolonged starvation of growing (but not very young) animals the long bones of the limbs still continue to increase in length, and the entire skeleton to increase in weight, even when the animal as a whole is losing weight.

It is worth noting in this connection that the skeleton and the central nervous system, despite the very different ways in which they grow, are alike in their ability to increase in weight under conditions which may bring about a loss in total body weight.

In addition to these differences there is of course some variability, which must be expected, even among animals living under the same conditions. This sort of variability is indicated on our charts by the relation of the several entries to the smoothed graphs.

The postnatal asymmetries which appear to arise largely from use in man (Gaupp, '09) are not evident in the rat, and there is nothing systematic in the slight deviation which we have observed for the values of symmetrical bones. But it seems not improbable that the weight of the skeleton is very responsive to nutritional conditions, even when these vary only within limits usually considered normal.

The capacity of the mammalian skeleton to respond in this way would seem to be indicated by the changes in skull and face measurements of the descendants of immigrants to the United States, shown by the observations of Boas ('11) and is implied by the use of the Bertillon system of measurements for identification ('93)—a system founded on the idea of variability within the race.

From all this it follows that the tables here given must be expected to furnish standard values only for albino rats reared under conditions very similar to those applying to the rats used for the tables, and the skeletons of which have been prepared in a similar manner, while for rats otherwise reared our tables furnish merely reference values with which the new data may be compared. How the feral Norway rat, living under the usual conditions, will differ from the domesticated Albino here studied in these skeleton characters we do not yet know, but one set of observations (Donaldson '12) shows the cranium to be heavier in the Norway than in the Albino.

Finally, it is not without interest to note that some characters of the human body which meet with aesthetic approval, and which depend on the proportions of the skeleton—the small head, well-formed mandible, length of limbs, and small feet and hands—are all of them characters which represent completed growth in both man and the rat, and thus in approving of them in man, we approve not only of constitutional vigor, but also of characters which man shares with other mammals.

LITERATURE CITED

- ARON, HANS 1911 Nutrition and growth: I. Philippine J. of Science, vol. 6, no. 1, section B, Medical Sciences.
- BERTILLON, ALPHONSE 1893 Identification anthropométrique. Instructions signalétiques. Imprimerie Administrative-Melun, 148 pp.
- BISCHOFF, E. 1863 Einige Gewichts- und Trocken-Bestimmungen der Organe des menschlichen Körpers. Zeitschr. für Rationelle Medicin, Bd. 20, S. 75-118.
- BOAS, FRANZ 1911 Abstract of the report on changes in bodily form of descendants of immigrants. The Immigration Commission, Government Printing Office, Washington, D. C.
- BURNETT, E. A. 1908 Part I. Foods supplementary to corn in fattening pigs. Part II. The effect of food on breaking strength of bones. Bull. 107 of the Agr. Exp. Station of Nebraska, vol. 21, article 1.
1911 The effect of food on the strength, size, and composition of the bones of hogs. 24th Ann. Rep. Agric. Exper. Station, Nebraska, pp. 178-208.
- DONALDSON, H. H. 1906 A comparison of the white rat with man in respect to the growth of the entire body. Boas Anniversary Volume, pp. 5-26. G. E. Stechert & Co., N. Y.
1912 On the weight of the crania of Norway and albino rats from three stations in western Europe and one station in the United States. Anat. Rec., vol. 6, pp. 53-63.
1915 The Rat. Reference tables and data for the albino rat (*Mus norvegicus albinus*) and the Norway rat (*Mus norvegicus*). Memoirs of The Wistar Institute of Anatomy and Biology, no. 6.
- DUCKWORTH, W. L. H. 1904 Morphology and anthropology. A handbook for students. University Press. Cambridge.
- DURSY, EMIL 1863 Lehrbuch der systematischen Anatomie. Lehr.
- FALCK, C. PH. 1854 Beiträge zur Kenntniss der Wachstumsgeschichte des Tierkörpers. Archiv für path. Anat., Bd. 7.
- FORBES, E. B., HALVERSON, J. O. AND MORGAN, L. E. 1918 The mineral metabolism of the milk cow. Third paper. Ohio Agr. Exp. Station Bull. 330, pp. 91-134.
- GALILEO GALILEI LINCIO 1638 Discorsi e Dimostrazioni Matematiche, intorno a due nuove scienze. Attenenti alla Mecanica & i Movimenti Locali. Appresso gli Elsevirii in Leida. Translated by Henry Crew and Alfonso de Salvio "Dialogues concerning two new sciences." The Macmillan Co., N. Y. 1914. See p. 130 et seq., p. 131, fig. 27.
- GAUPP, E. 1909 Die normalen Asymmetrien des menschlichen Körpers. Gustav Fischer. Jena.
- GRAFFENBERGER, L. 1891 Über die Zusammensetzung der Kaninchenknochen im hohen Altersstufen. Landwirtschaftliche Versuchsstationen, Bd. 39, S. 115.
- HATAI, S. 1907 Studies on the variation and correlation of skull measurements in both sexes of mature albino rats (*Mus norvegicus* var. *albus*). Am. Jour. Anat., vol. 7, pp. 423-441.
- HOLLISTER, N. 1917 Some effects of environment and habit on captive lions. Proc. of the U. S. Nat. Museum, vol. 53, pp. 177-193.

- HÜLSEN, C. 1898 Spezifisches Gewicht, Elastizität und Festigkeit des Knochengewebes. Bull. labor. Biol. St. Petersburg, Bd. 1, pp. 7-37. Abstract in Jahresberichte über die Fortschritte der Anat. u. Entwek., Bd. 4, p. 146.
- HÜLSEN, KARL 1902 Die Druckfestigkeit der langen Knochen. (Die mechanische Bedeutung der Beziehung der Länge zum Diameter der Knochen.) Verhandl. des V. Internat. Zoologen Congresses zu Berlin, 1901.
- HUMPHRY, GEORGE MURRAY 1858 A treatise on the human skeleton (including the joints). Macmillan & Co. Cambridge.
- JACKSON, C. M., AND LOWREY, L. C. 1912 On the relative growth of the component parts (head, trunk and extremities) and systems (skin, skeleton, musculature and viscera) of the albino rat. Anat. Rec., vol. 6, pp. 449-474.
- LATARJET, A. 1912 Résultats expérimentaux sur l'accroissement des os en longueur. C. R. Ass. Anat. Réunion, 14, pp. 72-91.
- LIEBIG, G. v. 1874 Gewichtsbestimmungen der Organe des menschlichen Körpers. Archiv für Anatomie, Physiologie und Wissenschaftliche Medizin, pp. 96-117.
- LOWREY, LAWSON G. 1913 The growth of the dry substance in the albino rat. Anat. Rec., vol. 7, pp. 143-168.
- MANOUVRIER, L. 1885 Sur les proportions pondérales du squelette des membres chez l'homme et chez les anthropoides. Proc. of the L'Assoc. Franc. p. l'Av. d. Sc's., Congres de Grenoble, 1885, pp. 516-521.
1892 Mémoire sur la détermination de la taille d'après les grands os des membres. Mem. de la Soc. d'Anthropol., T. 4, Paris, pp. 347-411.
- MOODIE, ROY L. 1917 Studies in paleopathology. I. General consideration of the evidences of pathological conditions found among fossil animals. Winter number, Annals of Medical History, pp. 374-393.
- PEARSON, KARL 1899 Mathematical contributions to the theory of evolution. V. On the reconstruction of the statute of prehistoric races. Philos. Trans. of the Royal Soc. of London, vol. 192, series A, pp. 169-244.
- SCHEIN, GEORG 1913 Untersuchungen über die chemische Zusammensetzung des Knochens an verschiedenen Körperstellen und bei verschiedenen Behandlungsmethoden (Halle). Leipzig, Inaug.-Diss. 64 pp.
- SCHMEY, M. 1915 Über die Veränderungen am Skelettsystem, insbesondere am Kopfe, bei senilen Hunden. Archiv für path. Anat. Bd. 220, S. 52-62.
- SCHWANN, TH. 1843 Observations des phénomènes périodiques. Mesures des organes internes du corps humain. Nouveaux Mémoires de l'Acad. Royale de Bruxelles, T. 16, pp. 51-52. For plan and method refer to Bull. de l'Acad., T. 9, no. 7, 1842.
- SEDLMAIR, A. C. 1899 Über die Abnahme der Organe, insbesondere der Knochen beim Hunger. Zeitschr. für Biologie, Bd. 37.
- STRATZ, C. H. 1909 Wachstum und Proportionen des Menschen vor und nach der Geburt. Archiv für Anthropologie, Bd. 36, S. 287-297.
- SUE 1755 Sur les proportions du squelette de l'homme, examiné depuis l'âge le plus tendre, jusqu'à celui de vingtinq, soixante ans, et au delà. Mémoires de Mathémat. et de Physique, Présentés a l'Acad. Royale des Sciences, Paris, T. 2, pp. 572-585.

- TESTUT, L. 1896 *Traité d'anatomie humaine. Anatomie descriptive—Histologie—Développement.* T. 1, see pages 2-4. Octave Doin, Paris.
- THEILE, F. W. 1884 *Gewichtsbestimmungen zur Entwicklung des Muskelsystems und des Skelettes beim Menschen.* Durch eine biographische Notiz eingeleitet von W. His. 4° Halle, E. Blochmann u. Sohn in Dresden.
- THOMAS, OLDFIELD 1886 *Notes on a striking instance of cranial variation due to age.* Proc. of the Zool. Soc. of London, pp. 125-127.
- TRIBOT, J. 1906 *Sur les chaleurs de combustion et la composition des os du squelette, en fonction de l'âge, chez les cobayes.* C. R. Acad. Sc. Paris, T. 142, pp. 906-907.
- USSOW, S. S. 1901 *Über Alters und Wachstumsveränderungen am Knochenengerüst der Haussäuger.* Arch. f. wissensch. u. prakt. Thierh. Berl., Bd. 27, S. 339-394.
- VINSON 1904 *Beiträge zur Methodik der Analyse ganzer Tierkörper.* Inaug.-Diss. Göttingen.
- VOIT, ERWIN 1905 *Welchen Schwankungen unterliegt das Verhältnis der Organgewichte zum Gesamtgewicht des Tieres?* Zeitschr. für Biol., Bd. 46.
- VOLKMANN, A. W. 1874 *Untersuchungen über das Mengenverhältniss des Wassers und der Grundstoffe des menschlichen Körpers.* Ber. d. Sächs. Gesell. d. Wissen., Math.-Phys. Kl., 14 Nov., S. 202-247.
- WALDEYER, W. 1910 *Das Skelett einer Hundertjährigen.* Sitz.-Ber. Akad. Wiss. Berlin, S. 971-979.
- WATERS, H. J. 1908 *Capacity of animals to grow under adverse conditions.* Proc. of the Soc. for the Promotion of Agr. Science, U. S. A.
1909 *The influence of nutrition upon the animal form.* Proc. of the Soc. for the Promotion of Agr. Science, U. S. A.
- WEISKE, H. 1889 *Untersuchungen über Qualität und Quantität der Vogelknochen und Federn in verschiedenen Altersstadien.* Landwirtschaftliche Versuchsstationen, Bd. 36, S. 81.
1895 *Weitere Beiträge zur Frage über die Wirkung eines Futters mit sauren Eigenschaften auf den Organismus, insbesondere auf das Skelett.* Zeitschr. für Physiol. Chemie, Bd. 20.
- WEISSENBERG, S. 1906 *Die Körperproportionen des Neugeborenen.* Jahrb. Kinderheilk., Bd. 64, S. 839-847.
- WELCKER, HERMANN, AND BRANDT, ALEXANDER 1903 *Gewichtswerthe der Körperorgane bei dem Menschen und den Thieren.* Archiv für Anthropologie, Bd. 28, S. 1-89.
- WELLS, H. GIDEON 1911 *Calcification and ossification.* Archives of Internal Medicine, vol. 7, pp. 721-753.
- WETZEL, G. 1910 *Volumen und Gewicht der Knochen als Massstab für den phylogenetischen Entwicklungsgrad. Die Porosität der Knochen.* Archiv für Ent. der Organismen, Bd. 30, S. 507-537.
- WILDT, EUGEN 1872 *Zusammensetzung des Knochen des Kaninchens in verschiedenen Altersstufen.* Landwirtschaftliche Versuchsstationen, Bd. 15, S. 404. Inaug.-Diss.
- WOLFF, JULIUS 1892 *Das Gesetz der Transformation der Knochen.* August Hirschwald. Berlin. 12 plates.

APPENDIX 1

SKELETON—ALBINO RAT

The accompanying table 31 gives the parts of the skeleton followed by the number, or groups, of bones separately weighed in

TABLE 31

Parts of skeleton

DIVISION	NAME	NUMBER OF WEIGHINGS (2 = RIGHT AND LEFT WEIGHED SEPARATELY)	TOTAL NUMBER OF SEPARATE BONES PREPARED IN EACH GROUP	
Axial skeleton	Skull	Cranium (with 6 ear bones and 8 teeth).....	1	1
		Mandibles (with 8 teeth)...	1	2
		Hyoid.....	1	1
		Vertebrae of trunk	1	30
		Vertebrae of tail		
		Ribs	1	26
		Sternum		
Appendicular skeleton	Shoulder girdle and appendages	Scapula.....	2	2
		Clavicle.....	2	2
		Humerus.....	2	2
		Ulna.....	2	2
		Radius.....		
		Carpus and bones of forefeet.....	2	56 ⁵
		Pelvic girdle and appendages	Pelvis.....	1
	Femur.....		2	2
	2 sesamoid bones behind distal end of femur.....		2	4
	Patellae.....		2	2
	Tibia and fibula.....		2	4 ⁶
	Tarsus and bones of hind feet.....		2	54 ⁵
	Totals			28

⁴ The number of caudal vertebrae is somewhat variable (twenty-eight to thirty), but in the mature rat there are about thirty. On the ventral aspect of the caudal vertebrae—in the intercentral position—are a series of pairs of

the case of each skeleton, together with the total number of separate bones in each group as these were prepared.

If we take the bones more in detail the following numbers appear:

TABLE 32

NAME	NUMBER OF BONES
Cranium.....	28
Ear bones.....	6
Teeth.....	16
Pelvis.....	6
Remaining bones as listed above (i.e., 230, less cranium, 1, and pelvis, 2).....	227
Total.....	283

There are twenty claws—also not weighed with the skeleton. In the case of forty skeletons the percentage of the weight of the room-dried claws on the weight of the fresh skeleton gives the following values:

TABLE 33
Weight of claws

NUMBER OF CASES	BODY WEIGHT—RANGE	FRESH SKELETON WEIGHT—RANGE	MEAN PERCENTAGE WEIGHT OF 20 CLAWS—ROOM DRIED—ON FRESH SKELETON
	<i>grams</i>	<i>grams</i>	<i>per cen</i>
5	4- 13	0.4- 1.5	0.30
2	20- 27	2.0- 2.5	0.21
14	30-110	3.0- 8.0	0.15
9	110-160	8.0-11.0	0.14
10	170-413	11.5-22.3	0.13

small ossicles which represent the chevron bones. About twenty-six of these pairs are found in the tail of the full-grown albino rat. These chevron ossicles were not counted in enumerating the bones, nor were they weighed with the vertebrae.

⁵ There are fourteen small sesamoid bones in each fore foot and fourteen small sesamoid bones in each hind foot. These were not weighed.

⁶ The tibia and fibula are counted separately, but have been weighed together, because at twenty days of age, or sometimes earlier, the fibula unites with the tibia, and after that age it becomes increasingly difficult to separate these two bones.

APPENDIX 2

TECHNIQUE OF PREPARATION

Theoretically, one should use as a standard for determining the effect of different methods of preparing the skeleton, fresh material which has been cleaned by mechanical methods only, since the immersion of the bones in any solution at room temperature or above necessarily alters their weight more or less.

It is, however, not feasible to make preparations without the use of some solvent for the connective tissue, and in the preparation of all of the skeletons included in this study a solution of commercial 'Gold Dust Washing Powder' was used. The approximate composition of this is: Sodium carbonate, 45 per cent; soap powder, 30 per cent; water, 25 per cent.

The rat was roughly dissected and the parts placed in 50 to 200 cc. of a hot Gold Dust solution in tap-water. For mature rats a 2 per cent solution at 96°C. was used for an hour, more or less, the material being watched and tested. The object to be attained was a complete softening of the attachments of the muscles, so that they could be readily removed with the bone scraper, or brush used for cleaning the bones. The younger the rat the weaker was the solution, the lower the temperature used, the shorter the time and the more careful the watching.

When bones are immersed in the macerating fluid, which acts mainly on the surface, it seems probable that those which are large, dense, mature, or cubical will be less affected than those which are small, porous, young, or flat, and our tests show this to be the case. We have therefore chosen as typical and as giving values which can be applied to the skeleton as a whole, the humerus and the femur.

When the macerated humerus and femur from one side of a rat were compared with those from the other side, freshly cleaned by cutting and scraping, but not macerated, the method of maceration here used causes a loss in the weights of these bones as given in table 34.

The data in table 34 are given according to the body weights of the rats, these latter being considered normal to the age.

TABLE 34

Percentage of loss in weight of bones after macerating in 2 per cent 'Gold Dust Washing Powder.' Based on the combined data for the humerus and femur. Entered according to body weight for each sex

BODY WEIGHT	LOSS—MALES		LOSS—FEMALES	
	Fresh	Oven-dried	Fresh	Oven-dried
<i>grams</i>	<i>per cent</i>	<i>per cent</i>	<i>per cent</i>	<i>per cent</i>
5	15.85	12.85	15.70	12.70
10	14.30	11.40	14.40	11.40
15	13.40	10.45	13.45	10.45
20	12.35	9.10	12.65	9.50
25	11.70	8.50	11.95	8.75
30	11.05	8.00	11.35	8.25
35	10.65	7.60	10.85	7.80
40	10.20	7.20	10.40	7.40
45	9.85	6.90	10.00	7.00
50	9.50	6.70	9.65	6.65
55	9.30	6.35	9.30	6.40
60	9.00	6.05	8.95	6.10
65	8.70	5.85	8.65	5.80
70	8.55	5.65	8.50	5.55
75	8.35	5.40	8.25	5.25
80	8.20	5.15	8.05	5.00
85	8.05	4.95	7.85	4.70
90	7.85	4.70	7.65	4.55
95	7.70	4.60	7.45	4.35
100	7.50	4.40	7.30	4.15
110	7.20	4.10	7.00	3.75
120	7.00	3.80	6.70	3.40
130	6.70	3.50	6.40	2.95
140	6.50	3.15	5.80	2.30
150	6.20	2.60	5.35	1.85
160	5.80	2.25	4.95	1.45
170	5.40	1.90	4.55	1.15
180	5.10	1.55	4.15	0.70
190	4.70	1.30	3.90	0.50
200	4.45	1.05	3.60	0.25
210	4.20	0.75	3.45	0.08
220	4.00	0.55		
230	3.80	0.35		
240	3.60	0.20		
250	3.45	0.10		

It appears from this table that the loss in fresh weight drops from about 16 per cent at birth to about 7.5 per cent at a body weight of 100 grams, and after a body weight of 200 grams the weight of the macerated may be below that of the unmacerated bones—from 4.5 to 3.5 per cent. When, however, the oven-dried weights of these same bones are compared, it is seen that while the losses after oven-drying follow the same course as was followed in the case of the fresh bones, yet the values run very consistently—about 3 to 3.4 per cent (on the average) below those for the fresh bones.

EFFECT OF MACERATION IN 'GOLD DUST WASHING POWDER' ON
THE PERCENTAGE OF WATER IN THE OVEN-DRIED BONES

Maceration reduces the weight of the moist (fresh) bones, as in table 34 under 'fresh.'

If this treatment merely dissolved some of the bone and left the remainder unmodified in constitution and in water content, then the bones oven-dried after maceration would have the same percentage of water as those mechanically cleaned. The oven-dried bones, however, show after maceration less water than those mechanically cleaned.

At birth the oven-dried macerated bones show 0.6 per cent less water, and this deficiency increases at the rate of 0.04 per cent for each 5 grams of body weight up to 150 grams. At this body weight it amounts therefore to 1.8 per cent and the same deficiency persists in the heavier rats.

The complete explanation of these changes in weight and water content as the result of maceration cannot at present be given, but it appears that in general the young bones suffer most in the destruction of their substance by the macerating fluid, whereas with increasing age the reduction of the percentage of water rises to about puberty, after which it remains nearly constant.

EFFECT OF THE INFLUENCE OF THE MACERATING FLUID ON THE
USE OF THE DATA

In the first place, it is evident that if we desire to obtain the true weight of the skeleton or any of its parts—using the values for the dissected bones as standards—it will be necessary to correct the observed values of the macerated bones in accordance with the percentages of loss given in table 34.

When, however, it is a question of the relative weights of the various parts of the skeleton among themselves, then we may safely assume that the effects of the macerating fluid are so similar on the several parts, that the relations found would be substantially those existing among the fresh bones.

Finally, if it is desired to compare the parts of the skeleton in any rat which has been subjected to conditions that might modify the weight or condition of the skeleton during life, then the observed values given in our tables may be used as a basis for this comparison, provided the skeleton of the test rat has been prepared by the same or a similar process of maceration.

It appears therefore that, despite the very considerable modifications induced by the use of the macerating fluid in the weights and water content of the bones, the observed and uncorrected values are nevertheless trustworthy for showing the relations between the parts, and may be used also as standards for comparison with other skeletons prepared in a like manner.

All the results in this paper are subject to at least the foregoing corrections, but such corrections have not been made. The values given in the tables are based on those which were observed.

WEIGHING AND MEASURING

The various groups of bones were weighed immediately after cleaning (giving the 'fresh weight'), they were then dried for thirty days or more at room temperature, and again weighed (giving the 'room-dried weight'), and finally were dried at 96°C. for six days and weighed (giving the 'oven-dried weight').

Measurements of the length of the long bones were also made with a dial calipers reading to 0.1 mm., in the three different conditions of moisture.

All of the bones of each of the 106 skeletons have been preserved.

It may be noted in passing that bones are somewhat hygroscopic and the oven-dried weights are not maintained for any length of time under usual laboratory conditions.

As a rule, the bones of the rat thus macerated are not markedly greasy and do not show evident fat. There were a few exceptions to this, however (nos. 50 and 66 in this series), but no correlated peculiarities were observed in such skeletons. When bones were heated to 96°C. for six days the glass weighing bottles sometimes became cloudy on the inner surface. This cloud formed a turbid mixture with water and was dissolved by alcohol. In no case, however, did it amount to one-tenth of 1 per cent of the weight of the bones, but nevertheless a correction was made for it.

It may be of interest to note that several trials gave eleven working hours as the time needed to prepare a skeleton—including the fresh and room-dried weighings and the necessary records. The weighings and the records for the oven-dried material added two hours more, making a total of thirteen hours.

For the preparation of the skeleton the freshly killed animal is to be preferred. If, however, the material needs to be preserved, some tests show that either saturated salt solution (brine) or 50 to 60 per cent alcohol may be used without introducing any marked modification in the results. Formalin is to be avoided, as the macerating fluid acts with great difficulty after formalin preservation.

THE ORIGIN, GROWTH AND FATE OF OSTEOCLASTS AND THEIR RELATION TO BONE RESORPTION ¹

LESLIE B. AREY

Anatomical Laboratory of the Northwestern University Medical School

TWENTY-FOUR FIGURES (FOUR PLATES)

CONTENTS

Introduction.....	315
Historical.....	316
Origin.....	316
Multinuclearity.....	318
Fate.....	319
Material.....	320
Observations.....	321
Discussion.....	328
Summary.....	334
Bibliography.....	335

INTRODUCTION

Robin ('49) appears to have been the first to distinguish clearly between the giant-cells of bone marrow (megakaryocytes) and those associated with bone itself (polykaryocytes), although it is probable that F. Bidder ('43) appreciated some such distinction.

Due chiefly to the efforts of Kölliker ('73), the multinucleate cells of developing bone are known as 'osteoclasts' and are regarded commonly as the direct agents of bone resorption.

The present communication comprises a report of certain observations made during the last three years upon the origin, growth, and fate of the osteoclasts, together with a critical

¹ Contribution No. 64, January 25, 1918. A grant from the American Association for the Advancement of Science has made possible the publication of the lithographic plate.

analysis of the evidence upon which their alleged bone-resorptive potentiality rests.²

The literature concerning polykaryocytes is voluminous, many accounts dealing confusedly with those of normal and pathological occurrence. Observations and speculations on the giant-cells of normal bone development, of bone tumors, and on those of other pathological origins so overlap that a complete literature review would be both tedious and unprofitable. For this reason the following digest of previous work will deal chiefly with the osteoclast associated with normal bone development and resorption.

HISTORICAL

Origin. Views as to the origin of the osteoclast are not in accord.

Kölliker ('73) observed the presence of osteoclasts on resorption surfaces; these appeared at first discontinuously in the osteoblastic layer and increased in number, size, and multinuclearity concomitantly with the disappearance of the latter. Admitting the absence of direct proof by observation, he nevertheless considered the circumstantial evidence sufficient to render the genetic relation of osteoblasts to osteoclasts highly probable. The latter were supposed to represent single osteoblasts which had undergone repeated nuclear division. For the earliest osteoclasts, and for those found during the resorption of milk teeth, an origin from connective-tissue cells was assumed.

² Shortly before his death Prof. C. W. Prentiss had been engaged upon a study of the osteoclasts. Except for a brief abstract ('15) of a paper on this topic delivered before a local surgical society and for a number of unlabeled drawings, there were found no notes or other data to indicate the extent or state of completion of the project. For these reasons the perhaps tentative conclusions reached by him are known in outline only. On assuming duties at this laboratory the writer became interested in the same problem and worked over the entire field independently; some of the preparations used have been identified as those upon which Professor Prentiss made observations. It is believed that the scope of the investigation has been extended considerably and that certain interpretations have been profoundly modified. With respect to an osteoblastic origin our conclusions are in accord, but as to the fate and significance of the elements our opinions clearly differ.

Bassini ('72), Pommer ('81), and Gegenbaur³ concurred fully with Kölliker's thesis; Ziegler ('78), Lewis ('13), and others have rejected it. Morrison ('73), working under the inspiration of Kölliker, likewise reported having observed intermediates (in the number of nuclei?) between the osteoblast and osteoclast.

An origin by osteoblastic fusion was inferred by Howell ('90). It is, he argues, "plausible to think that the closely packed cells might become forced to form a polykaryocyte and a number of transitional steps [in size and number of nuclei?] can be seen in sections"

Bredichin ('67) held the giant-cells of normal and pathological bone resorption to be transitional stages in the transformation of bone tissue into marrow and granulation tissue; in other words, they are nothing more than liberated bone cells become multinucleate. Murisier ('75) and Ziegler ('78) expressed a somewhat similar opinion, while Rindfleisch ('72) was likewise convinced from the study of giant-cell sarcomata that the polykaryocytes are bone cells which have become free and gone over into a peculiar hypertrophic state. The proliferation of bone cells was also noted by Morrison ('73). According to Löwe ('79), the osteoclastic nuclei arise either from bone cells or from inwandering leucocytes.

Wegner ('72) observed a close association between polykaryocytes and blood-vessels in pathological bone resorption. He also maintains that normally the osteoclasts originate as proliferations of the vessel wall. An intimate relation to blood-vessels, although not in every case an actual origin from them, has been emphasized as well by Morrison ('73), Brodowski ('75), Maas ('77), Schaffer ('88), Bidder ('06), and others.

According to Kaczander ('82), giant-cells (osteoclasts?) form from enlarged, liberated cartilage cells by coalescence. These cartilage cells may be multinucleate while within their capsules. This interpretation is modified by Geddes ('13), who considers osteoclasts to be "hybrid syncytial masses composed of fused cartilage cells containing osteoblasts."

³ Cited by A. Bidder ('06).

Ranvier ('89), Renault ('93), and Duval ('97) trace the origin to lymphoid marrow cells, whereas Mallory ('11) insists that osteoclasts arise unquestionably from fused, large mononuclear leucocytes.

The results of Jackson ('04), Danchakoff ('09), and Maximow ('10) agree in tracing the origin of the *first* osteoclasts in the early stages of bone development to enlarged reticular cells of bone marrow. These cells possess at first but two or three nuclei and the cytoplasm is basophilic. Later their cytoplasm appears oxyphilic and the nuclei may become extremely numerous.

Osteoclasts are viewed by Todd ('13) as "masses of preosseus tissue artificially separated from the fully ossified bone during its preparation for histological examination."

The views of Wegner, Kaczander, Todd and Geddes, just presented, are unusual, some of them seemingly even fanciful. In my experience they demand no serious attention. The remaining workers trace or infer an origin from osteoblasts, bone cells, or marrow tissue of some sort. The relation of these opinions to my own observations will be made clear in the pages which follow. Briefly, I recognize all three sources of origin, but the interpretation of the actual mode of genesis and growth of the osteoclast, and the relative importance of each contributory element is novel.

Multinuclearity. A variance of opinion exists also as to the manner in which the osteoclast comes to possess its numerous nuclei.

Kölliker ('73) considered the increase in nuclei to result from nuclear division. Adherents to this view include Bredichin ('67), Wegner ('72), Morrison ('73; by amitosis), Böhm and Davidhoff⁴ (by mitosis), Jackson ('04 by mitosis); and Jordan ('18; by mitosis, to a limited degree).

Morrison ('73) and Danchakoff ('09) speak of the confluence of mesenchymal cells. Maximow ('10) likewise believes that large osteoclasts arise at the expense of smaller ones; furthermore, he records having never observed nuclear division either by mitosis or amitosis.

⁴ Cited by A. Bidder ('06).

Fate. Concerning the ultimate fate of the osteoclast, there is also no general agreement.

These giant-cells were viewed by Bredichin ('67) as transitional stages in the transformation of bone tissue into marrow and granulation tissue.

Wegner ('72), observing some polykaryocytes with cavernous recesses, was led to speculate as to whether new blood-vessels might arise from such (compare p. 327). He also believed in their resolution into connective tissue, or, perhaps, marrow cells.

Kölliker ('73) noted that when bone deposition again succeeds a period of resorption, the osteoclasts disappear from the resorption area and are superseded by osteoblasts. Furthermore, where resorptive and formative areas join he found intermediate types. The conclusion is drawn that, in such situations at least, the osteoclasts fragment and return to osteoblasts. Kölliker, nevertheless, emphasizes the absence of direct proof and admits (p. 27) that: "Die letzten Schicksale der Osteoklasten sind noch in grosses Dunkel gehüllt." Allowance is also made for the degeneration of some of the giant-cells and for the possibility of a transformation of others into connective-tissue and marrow cells, as Wegner ('72) contended.

Gegenbaur⁵ and Bassini ('72) agreed with these views of Kölliker. Pommer ('81) likewise held that osteoclasts not only revert to osteoblasts, but also to cells of a different character and to intercellular material, whereas at the suppression of sufficient nutriment they degenerate.

The removal of the stimulus to absorption was believed by Morrison ('73) to lead to the disappearance of the osteoclasts by 'molecular degeneration.'

Löwe ('79) presented a curious and incredible account of the encapsulation of osteoclasts, the fragmentation of their nuclei and cytoplasm into discrete cells, the rupture of the capsular wall, and the dispersal of the individual elements into the marrow. He remarks on the similarity between these stages and those of encystment and spore formation in protozoa.

⁵ Cited by A. Bidder ('06).

Jackson ('04) described and figured osteoclasts, which by the enlargement and confluence of cytoplasmic vacuoles formed detached cells; these remain interconnected by processes and are indistinguishable from neighboring reticulum cells.

The view of Maximow ('10) differs from that of Jackson in that some osteoclasts are said to be destroyed through extreme degeneration.

Lewis ('13) holds these polykaryocytes to be degenerating cells produced by those conditions which lead to the dissolution of bone.

Thus, these opinions pertaining to the fate of osteoclasts either uphold their transformation into other cellular elements, their total destruction, or admit both possibilities.

Several provisional communications by the writer on the problem of the origin, growth, fate and significance of the giant-cells of bone have appeared previously ('17a; '17b; '08).⁶

MATERIAL

The observations recorded in this communication have been made on developing membrane bone of human and pig embryos. A favorable site for study is found about the walls of the dental

⁶ A publication by Jordan ('18) some time after the present paper had left my hands necessitates supplementary comment. Jordan states (p. 248) that "The osteoclast arises chiefly (at first exclusively) from the marrow reticulum by a fusion process essentially as previously described by Maximow; in the earliest stages the nuclei may multiply slightly by mitosis; their increase, however, is due mainly to exogenous additions either reticular, osteoblastic, or even bone cells. Smaller osteoclasts may fuse to form larger syncytia. These cells finally degenerate, as evidenced chiefly by a vacuolization of their cytoplasm and a karyorrhexis, and eventually they disintegrate. The above-described material gives no evidences of a retransformation into marrow reticulum, as maintained by certain workers (Jackson, Arey). . . . Osteoclasts may arise to some extent also from fusing osteoblasts, But the osteoblasts involved in this process are not "worn out" as Arey maintains. On the contrary, they are of the less differentiated types and strongly basophilic."

As to sources of origin, method of growth, and ultimate fate these conclusions are in harmony with my own, as set forth in former communications ('17 a, '17 b; '18) and in the present contribution. In certain details, however, our opinions diverge widely. The method of osteoclastic origin from marrow reticulum he considers chief in importance, that from osteoblasts secondary; on the contrary,

alveoli where active bone resorption is preparing for the accommodation of the rapidly growing teeth. Here osteoclasts appear in large numbers.

The material which proved most useful consisted of several series illustrative of tooth development in the pig. In these decalcified preparations the histological preservation was exceptionally good. The jaws of appropriate pig embryos were fixed in Zenker's fluid, decalcified in acid, embedded in celloidin, and stained with hematoxylin and eosin or hematoxylin and orange G. Hematoxylin and Congo red have been employed also, but the hematoxylin-eosin combination was favored for bringing out delicate tinctorial contrasts. Part of the material comprised serial sections; in view of the large size of the osteoclasts, such series are instructive and important.

Typical stages illustrative of the history of these elements were demonstrated before the thirty-third session of the American Association of Anatomists at New York.

OBSERVATIONS

The osteoclasts (named 'Ostoclast' by Kölliker) are large, multinucleate cells of irregular shape and without a definite

I have maintained that, except in the youngest stages of bone development, the reverse is true. Furthermore, those giant cells resulting from osteoblastic fusion are traced by Jordan only from young, slightly differentiated cells; in my membrane bone material these stages of osteoclast genesis have never been found, for example, among the active osteoblasts of growing spicule tips, but only farther back amid more or less 'depleted' cells; the term 'depleted' is, of course, relative, and need not necessarily signify 'worn out'—a term not of my using. In the first preliminary announcement of these studies ('17 a) I recorded the abundance of degenerative stages and intimated a probable final disappearance, but further added the tentative observation that "indications of a transformation into marrow reticulum are not lacking." At the time this last statement was penned I had studied the fate of osteoclasts only partially, but had noted the resemblance of fragmenting osteoclasts like figure 18 to those stages held by Jackson ('04) to depict a retransformation into marrow reticulum. In a later publication ('18) and in the present report these stages are believed to represent merely degenerating cells undergoing disintegration ('18, p. 237): "Neither have I seen convincing stages of a fragmentation into reticular cells of the marrow as Jackson and Maximow describe. The entire picture, from the early formation by the fusion of depleted osteoblasts, seems rather to depict a progressive degeneration, culminating in death and removal."

limiting membrane. Kölliker ('73) records their maximum size in the human new born as $38 \mu \times 91 \mu$ and with as many as 50 to 60 nuclei. I have found the measurements in the pig to run as high as $65 \mu \times 105 \mu$, with a nuclear count of about 125. These figures undoubtedly are too low, for the entire cell in all probability extended through several sections.

In shape, osteoclasts are rounded or have variably conspicuous processes (figs. 13 and 14). This latter configuration is suggestive of amœboid motility (compare Maximow, '10), but Kölliker ('73) and Bizzozero failed to confirm this in living osteoclasts examined on a warm stage.

The cytoplasm is typically strongly oxyphilic and contains a variable number of vacuoles; these Jackson ('04) believed not to consist of fat, whereas Dubreuil ('10) is convinced of their lipid nature. The cytoplasm is granular, sometimes coarsely so, and is notable for the usual absence of debris (compare p. 332). Nuclei tend to be pyknotic, especially in the older, apparently degenerating forms (fig. 16). Some nuclei appear shrunken or folded (fig. 19), but convincing amitotic stages have not been observed by me.

Certain osteoclasts exhibit a brush border along the edge in apposition with the bone. This border stains more intensely than the rest of the cell and may be finely striate or composed of coarse, block-like elements (figs. 8, 9 and 17). Some also have a fringed or toothed appearance. The significance of this condition is obscure.

In regions where bone is actively forming, the osteoblasts are typically separate units, columnar in shape and with basophilic cytoplasm (fig. 2, *obl.*); the nuclei tend to be placed toward the end of the cell farthest from the bone matrix. As development proceeds the cytoplasm diminishes in amount and in older regions the still basophilic osteoblasts flatten out and lose their distinct cell boundaries. There are thus formed syncytial masses of variable size (fig. 1, *ocl.*). That such do not result from overstaining with basic dyes is proved by the intense oxyphilic reaction of certain other elements in the same preparations. Close to the basophilic syncytium in figure 1, for example, was a brilliant eosinophilic osteoclast.

Whereas the osteoclasts may arise in the early stages of bone development from the mesenchymal or reticular cells of the marrow, as Jackson ('04), Danchakoff ('09), and Maximow ('10) contend, my observations indicate that in later stages they take origin chiefly from the osteoblastic syncytia just described. There were found all transitional tinctorial stages between these syncytia with basophilic cytoplasm, staining blue with hematoxylin, and typical oxyphilic osteoclasts, staining red with eosin. In figure 2, compare the intermediate purple shade of a very large-sized intermediate with the normal basophilic osteoblasts at the right and with a typical osteoclast such as figure 4. Here again this characteristic coloration does not result from basic overstaining as may be convincingly proved by an inspection of adjacent fields.

A comparison of the nuclei found in osteoclasts and osteoblasts can not be depended upon to furnish very reliable information as to genetic relationship. Not only do the osteoclastic nuclei commonly exhibit pyknosis, but the resemblance between the unchanged vesicular nuclei and those of osteoblasts and connective tissue is close; this is not surprising since the osteoblasts themselves originate from the connective tissue. In some instances, nevertheless, the chromatin disposition and general nuclear structure of the osteoblasts and osteoclasts clearly agree better than do either with the adjacent marrow reticulum. There is evidence that the elongate nuclei in flattened osteoblasts are restored to the spheroidal configuration upon the release of compression.

Not only are basophilic syncytia and syncytial masses of intermediate stainability found, but osteoclasts may be seen frequently continuous at one or both ends with basophilic osteoblasts and particularly with osteoblastic syncytia. This is represented in figure 3, especially at the right; both osteoclast and osteoblasts have been displaced artificially from the bone surface. Figure 4 shows on the right an osteoclast with five nuclei continuous by a bold transition with fused basophilic osteoblasts. Similarly in figure 11, from a human fetus, the osteoclast lapped over the end of a bone spicule, is abruptly

continuous at both ends, but especially at the right, with osteoblasts.

According to these observations, therefore, the osteoclast arises from depleted osteoblasts which have first formed a syncytium before being transformed into the oxyphilic osteoclast. As bone resorption continues, osteoblasts progressively lose their former relation to the bone, come into association with the advancing osteoclasts and are incorporated into them. If the spicule in figure 11 were resorbed it is believed that the simultaneously advancing (thigmotactic?) osteoclast would take up the osteoblasts in its path. In a similar manner, smaller osteoclasts may, by fusion, merge into larger ones.

But the osteoblasts, as such, are not the only source from which the nuclear and cytoplasmic contents of the osteoclasts are recruited. Bone cells, embedded in the matrix, are laid bare by the resorptive processes and are ingested by the oncoming osteoclasts. All intermediates may be found between the initial and final stages of inclusion. At the left of figure 4 a cytoplasmic process of an osteoclast is in contact with the capsule of a bone cell which is otherwise embedded in the bone matrix. Two succeeding stages appear in figure 5; on the right the area of contact is extensive; at the left the bone cell is half within and half without the osteoclast. Figure 11, from a human fetus, and figure 10 show similar steps, as do text figures A and B. A last stage appears in figure 12, at the right.

Furthermore, bone cells are enclosed normally within a capsule which is known to be resistant, for example, to the action of strong hydrochloric acid. Encapsulated and distinctly stellate cells, which resemble bone cells identically, are occasionally found, embedded in the osteoclastic cytoplasm (fig. 13; compare also figs. 2, 6, and 12). Such cells are interpreted as bone cells whose capsules have resisted cytoplasmic digestion. From the relative infrequency with which such persistent capsules are seen, it is probable that the enclosed bone cells are eventually liberated. Ingested bone cells must contribute in substantial numbers to the formation of osteoclasts. This is perhaps especially true on flat resorption surfaces.'

Hence it appears that the degree of multinuclearity is an index of the number of osteoblasts and bone cells entering into the composition of the osteoclasts. Also, in general, the larger an osteoclast, the more numerous its nuclei and the more extensive its history in relation to bone resorption (compare figs. 1, 21, and 22).




Fig. A The encapsulated bone cell, *b.c.*, is half ingested by an osteoclast, *ocl.*, which lies on a spicule of bone, *mtx.* Only a portion of the entire osteoclast appears in this section. Photograph. $\times 650$.

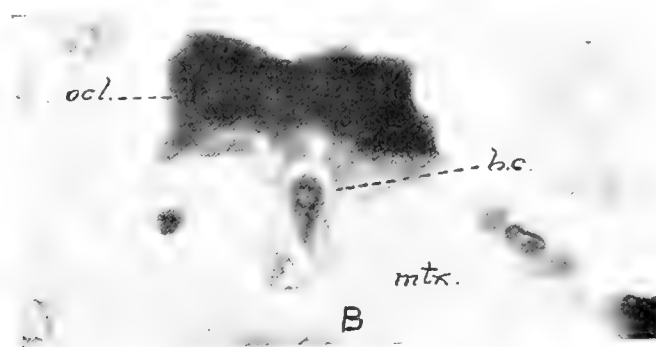


Fig. B A stage in osteoclastic phagocytosis similar to that of fig. A. The bone cell is half within and half without the osteoclast. Photograph. $\times 650$.

My observations agree with those of Maximow ('10) in that nuclear division either by mitosis or amitosis has never been observed in these older stages. Shrunken and folded nuclei do appear, especially in cells which show other evidences of degeneration, but convincing stages of amitosis have not been found by me. In much of the material used mitoses were not uncommon in the near-by germinative layer of the epithelium, so the preparations would seem to be favorable for demonstrating nuclear division did it occur.

Sometimes osteoclasts are seen which are in continuity by fine processes with the marrow connective tissue (figs. 14 and 15). The general appearance of such cells does not indicate advanced degeneration, hence it may be thought that they have arisen by coalescence of connective-tissue elements. A case illustrative of this is seen in the rather thick section shown in figure 15. Such osteoclasts which seemingly lie free in the marrow tissue usually prove to be in contact with the bone when recourse is made to serial sections. It is possible, however, that even in these later stages of bone resorption some osteoclasts are formed from the marrow reticulum, similar to the origin described by Jackson ('04), Danchakoff ('09), and Maximow ('10), and that this is an illustrative stage of such a process. Indeed, from what is known of tooth resorption and of the genesis of foreign-body and other giant-cells it seems reasonable that the osteoclast has no single source of origin. An elaboration of this topic will be found on pages 328 and 329 of the discussion.

Finally, the fate of the osteoclasts demands attention. That these cells may be resolved ultimately into osteoblasts and again resume bone formation seems improbable. Kölliker, who championed this view, was unable to produce direct evidence in its support. My preparations show nothing in favor of such a cycle, whereas pictures of degeneration in varying degrees are abundant.

A vacuolated cytoplasm is a common characteristic of many osteoclasts. The degree of vacuolization appears to be fairly closely correlated with the extent of degeneration (figs. 16, 17, 18, 19, and 6). In other cells granular degeneration of the cytoplasm occurs (figs. 7 and 20). Nuclei may show varying degrees of pyknosis while the cytoplasm still appears to be in good condition (figs. 2 and 5); on the other hand, the nuclei of cells otherwise exhibiting extreme degenerative changes appear to be constantly pyknotic. Through stages of increasing vacuolization and pyknosis conditions are reached such as are depicted in figures 6, 17 and 19. In an osteoclast like figure 6 both nuclei and cytoplasm are far from normal; the nuclei are highly pyk-

notice while the cytoplasm takes the eosin poorly and is riddled with vacuoles which at the edges produce a ragged, laced appearance. In short, the optical appearance is such as one normally associates with extreme degeneration.

As the resorption of local areas of bone is completed, the accompanying osteoclasts become left behind, stranded in the marrow tissue. Thus, one occasionally finds a small portion of bone enclosed by an osteoclastic mass (fig. 17). Only when serial sections are available is one certain that a paratangential section of a spicule-tip had not produced a deceptive appearance of an isolated bone fragment and enclosing osteoclast.

Left behind in regions where resorption has apparently finished its course are sometimes found also nests of large osteoclasts (figs. 19 and 22). Such a stage as figure 21 apparently shows in its inception how these masses become thus isolated, for this particular giant-cell is at the rear of an area of bone dissolution that is almost completed locally. Some of these stranded elements show excessive degenerative changes. Illustrations show but poorly the pale, reticulate or fragmented cytoplasm and the shrunken and distorted, pyknotic nuclei.

Jackson ('04) and Maximow ('10), in particular, have upheld the fragmentation of osteoclasts into detached cells which become indistinguishable from the reticulum of the marrow (compare p. 327). I have seen several stages which show stellate portions of the osteoclast being cut off by vacuolization (fig. 18). That these moieties, some of which may even lack nuclei, persist as elements indistinguishable from the reticulum is doubtful; on the contrary, the general appearance of such osteoclasts seems rather to point to ultimate degeneration. If my interpretation of the osteoclasts be correct, the entire course from the time of osteoblastic coalescence is one of progressive decline (see foot-note 6, p. 320). To return to a healthy, active state, the fragmentation products of such osteoclasts would seemingly have to undergo extensive rejuvenation both as regards nucleus and cytoplasm.

Large osteoclasts were observed within the blood-vessels of the marrow (figs. 7 and 20). That such gain admittance and

do not arise in situ from the endothelium is supported by their usual retrograde appearance; vacuolization, granulation and loss of stainability of the cytoplasm, and pyknosis of the nuclei occur. No stages have been observed which could be interpreted as illustrative of an origin from the blood-vessel itself; on the contrary, the condition appears to indicate a method of final removal. This admission into embryonic vessels does not of itself prove or imply an amœboid activity by the osteoclast; Meyer ('18) is wrong in assuming I hold such a belief.

DISCUSSION

The conclusions of Kölliker regarding the history and significance of the osteoclasts have gained great prominence. It should be kept clearly in mind, however, that his opinions were almost wholly inferential. He neither offered direct proof of the origin of osteoclasts nor of their fate, as has been pointed out in the historical section. The apparent reasonableness of these deductions, and the prestige of their originator, doubtless account for their acceptance by numerous later investigators and for their widespread inclusion in texts.

Concerning the validity of many of the claims advanced by other workers the writer can offer little except the negative evidence of not having seen corroborative stages. Unfortunately, in the past, too many dogmatic statements have been made wholly unsupported by appropriate evidence. Only a few have presented their claims adequately described and illustrated. Under these conditions it is not always easy to distinguish between surmises and conclusions drawn from actual observations.

Moreover, it seems reasonable to believe that several morphologically similar but developmentally distinct elements masquerade under the generic term osteoclast, so that, historically, the controversy has not always been over identical structures. The careful studies of Jackson ('04), Danchakoff ('09, and Maximow ('10) appear to show convincingly that, at least in the early stages of bone development, the osteoclasts arise from the primitive connective tissue of the marrow. At

the time of resorption of the milk teeth an osteoblastic history is likewise excluded. In the present communication are recorded observations of osteoclasts in continuity with the marrow reticulum; it is entirely probable that this is not a secondary union, but primary, and of developmental significance. My chief results, nevertheless, point to a widespread formation of osteoclasts in the later stages of development from osteoblasts and bone cells.

Polykaryocytes which resemble osteoclasts morphologically are the so-called foreign-body giant-cells produced within the body about fat (Mallory, '11) as a center, or developed experimentally about introduced foreign bodies, such as agar, paraffin, lycopodium spores, or bone dust (Maximow, '02; Lambert, '12; Mallory, '11, et al). These are said to form from fused, wandering leucocytes, and Mallory ('11) even goes so far as to derive all osteoclasts (but on insufficient evidence) from a like source. The foreign body origin is, nevertheless, an important concept. It seems reasonable that on the cessation of active growth a spicule of bone, or any quiescent portion of a spicule, becomes essentially a foreign body and the cells in contact with it, not necessarily all of one origin, may respond to whatever stimulus it offers and fuse into syncytial masses. Kölliker ('73) found that ivory pegs driven into bone became eroded, the lacunae thus formed containing polykaryocytes. Rustizky ('74) similarly produced giant-cells, but no lacunae, by introducing pieces of bone in the dorsal lymph sacs of frogs.

The causative factors of giant-cell formation are necessarily obscure. Kölliker considered it due to a pressure by the soft parts underlying bone (compare also Wegner). Pommer ('81), on the contrary, held as responsible a locally increased blood pressure. On spongy bone, at least, it may be due to the augmented mutual pressure resulting from the decreased size of the spicules and to a concomitant loss of cell individuality as a result of general osteoblastic degeneracy. The formation of ordinary foreign-body giant-cells would demand a different explanation. Presumably a definite thigmotaxis is operative in all giant-cell formation.

Finally comes the vexed question as to whether the osteoclasts actually are bone destroyers. Kölliker ('73) was the first and most persistent exponent of their bone-destroying function. He believed that their presence in the Howship's lacunae of resorption surfaces, on ivory pegs, and on milk teeth during resorption, demonstrated his thesis beyond controversy. Among the many who have subscribed to these views are Wegner ('72), Morrison ('73), Jackson ('04), and Maximow ('10). Mallory ('11) has even suggested that the erosion of bone may be accomplished mechanically by the brush border. Danchakoff ('09) refers to the dissolving action on bone, but calls attention to the relative infrequency of osteoclasts during the erosion of calcified cartilage and the irrationality of attributing the destruction of cartilage solely to them. Shaffer ('81) likewise held that they have a bone-destroying action, which, however, blood-vessels chiefly perform.

Howell ('90; p. 119) took a decided stand against the probability of the commonly accepted osteolytic function:

The function of these cells is unknown. The common view that they are concerned in the absorption of bone (osteoclasts) seems to me to rest upon very slight evidence. If we find them in developing bone lying upon the cartilage trabeculae which are being absorbed, we find them also on the partitions of sponge or pith, introduced into serous cavities where no absorption is taking place; and the conclusion in the first case that the absorption which is going on is due to the giant cells (osteoclasts) is illogical. Absorption of tissues is an occurrence common enough in the body, and it is difficult to understand why the absorption of bone or cartilage should require the activity of a special cell, when the absorption of other tissues does not. It would seem more probable that this form of cell has no specific function, and that its formation is, in fact, accidental, or, in a certain sense, pathological: that the presence of a solid substratum leads to an abnormally rapid growth of lymphoid cells, leucocytes, osteoblasts, as the case may be, and the fusion of some of these to produce multinucleated giant cells.

The evidence in favor of a dissolving activity by the osteoclasts rests upon the following relations: these elements appear at the onset of resorption and disappear at its cessation; they are closely applied to bone, sometimes being wrapped around eroded spicules (fig. 10), and sometimes occupying the so-called How-

ship's lacunae;⁷ their coloration with acid dyes often resembles that of bone. The occasional presence of a striate border (figs. 8 and 17) on the side in contact with bone might be thought to indicate cellular activity (compare the brush border of the epithelial cells of the intestine or kidney), but this phenomenon is open equally well to other interpretation.

Against the view of the osteoclast as a causative resorptive agent may be presented several objections. They are notably scarce during the resorption of calcified cartilage. Howship's lacunae not infrequently are seen without associated osteoclasts (compare Rustizky, '74); this may represent a distinct method—"lakunäre Resorption ohne Riesenzellen" (Kaufmann, '07). A 'smooth resorption' of bone occurs where Howship's lacunae are entirely lacking (Busch, '77), and they are often infrequent where osteolysis is active. In osteomalacia, leprosy, and in tumors and many inflammations (Ziegler, '78), the lime salts are removed in the absence of osteoclasts—it is significant that in these cases typical Howship's lacunae usually occur (Ziegler, '78, et al). The absorption of various other tissues in the body is accomplished without the intervention of special cells. It is not impossible that the relation of osteoclast to Howship's lacunae may be given an inverse interpretation; if the lacunae represent softer regions in the bone, or regions for some reason more directly subjected to the resorbing principle, perhaps these depressions serve merely as traps in which the giant-cells collect.

If the osteoclasts arise largely from osteoblasts and bone cells, as set forth in this communication, and if, furthermore, the subsequent course is one of progressive degeneration, it seems unlikely that such cells, which a short time before had been active bone formers, now would take over the diametrically opposed function of destruction. On the contrary, the concept of progressive degeneration seems to militate against such a view.

⁷ The relation of polykaryocytes to such lacunae is demonstrated strikingly during the resolution of deciduous teeth. At this time, the root may be completely scalloped with adjacent pits, each harboring a giant-cell. It is hoped that a subsequent report will clear up the puzzling questions of the origin and significance of these elements.

In working over this field and evaluating the total evidence the writer has become highly skeptical concerning the potency of the osteoblast in bone resorption. With Lewis ('13, p. 86) he would take the position that "There seems to be no satisfactory evidence that the osteoclasts are the active causes of bone destruction. On the contrary, they appear to be degenerating cells,"

Attention has been directed in another publication (Arey, '17 b) to the uncritical nature of the assumption that the failure of a cell to drink in vital dyes warrants the denying to it of phagocytic potentiality. The osteoclast refuses to 'stain' with trypan blue (Shipley and Macklin, '16), yet bone cells, encapsulated or naked, laid bare by the resorptive processes, are demonstrably engulfed by it;⁸ (compare also the observations of Wegner⁹ and of Rustizky ('14) on 'Kalkkörner' within polykaryocytes, and note the red blood corpuscles within the body of the osteoclast shown in figure 7 of the present communication.) Furthermore, the mere presence of cytoplasmic inclusions within an osteoclast by no means indicates that the latter was responsible for the dissolution of the material ingested; to imply such a causal relation is to exceed the limits of legitimate deduction. When Jordan ('18, p. 251) writes that "The osteolytic function of the giant-cells of reticular and osteoblastic origin is proved by the presence of globules of resorbed osseous substance [p. 262, globules of absorbed bone] within the cytoplasm," he perhaps is using 'osteolytic' as a term interchangeable with 'phagocytic;' this is supported by a further reference (p. 255) to the "'phagocytic' (osteolytic) function" of osteoclasts. Yet in another place (p. 246) we read:

⁸ The presentation of these facts ('17 b) has led Meyer ('18, p. 100) to conclude that it involved "apparently implying that fusion products never observed to undergo mitosis, nevertheless may be physiologically active and continue a progressive evolution." That these giant-cells are active enough to engulf bone cells, osteoblasts, or even fragments of bone matrix is unquestionably true, but that the osteoclasts enjoy a progressive evolution is not supported by my observations. On the contrary, both in my 1918 communication and in the present contribution the history of these elements is held to be one of advancing degeneration, culminating in death and removal.

⁹ Cited by Rustizky ('74).

“the osteoblasts are constructive osseous elements; the osteoclasts are destructive elements. The former elaborate bone; the latter resorb it.”

There is no direct evidence as to how bone matrix (inorganic and organic) is resorbed. One might assume it is essentially a double process of decalcification and of digestion of the organic substrate; conditions such as osteomalacia, in which the lime salts are removed leaving the organic framework, perhaps support such a view. In the absence of more appropriate evidence, therefore, the activity of an acid (carbon dioxide or lactic acid?) and an enzyme can be tentatively suggested.

According to Morpurgo and Satta ('08 a, '08 b), there is associated with bone a thermolabile entity, an enzyme they believe, responsible for calcium removal during experimental autolysis of bone. The provisional nature of these two communications renders their evaluation difficult.

In his Harvey Lecture, Wells ('10-'11) marshals numerous facts to support the view that bone resorption is accomplished through the agency of carbon dioxide. It is demonstrable that calcium is normally contained in the blood in amounts approximating saturation and that this content is from two to four times that soluble in water. This amount of calcium in the blood is held in solution by the colloids and the carbon dioxide. “In normal ossification, and in most instances of pathological calcification, the deposition is probably initiated by a process of colloidal adsorption Reduction in the amount of carbon dioxide in such areas, or some unknown agency, causes a precipitation in this colloid matrix,” It is well known “that, no matter how sclerotic the walls of the veins may become, they rarely, if ever, calcify so long as there is venous blood rich in CO₂ flowing through them. As soon as they are occluded, however, calcification occurs readily enough (e.g., phleboliths).” It has been long established that carbon dioxide in solution will dissolve calcium from bone but that NaHCO₃ cannot so act. Furthermore, studies on this solubility in vitro and in vivo show “that pieces of ivory are absorbed most rapidly in tissues whose metabolism is the most active, and where, by

inference, there is the most carbon dioxide." From these and other considerations Wells concludes: "It is indeed probable that it is the CO₂ which accomplishes the resorption of dead bone in the living body, and perhaps also the normal resorption of bone in the various conditions in which this process takes place."

It is, perhaps, difficult to imagine the mechanism of the localization of carbon dioxide (or the stronger lactic acid?) in sufficient concentrations to effect the selective erosion of small areas, or to account for the frequent directional polarization of the resorptive wave. However this may be, there is, of course, no basis for suspecting the osteoclast of special carbon dioxide production. On the contrary, if it is indeed a degenerating cell, its carbon dioxide output is presumably low. The conception of Wells adds to the objections already enumerated against the osteoclast as a specific osteolytic agent.

SUMMARY

The multinucleate giant-cells known as 'osteoclasts' probably include several morphologically similar but developmentally distinct elements.

In the earliest stages of bone development, and to a certain extent in later stages, osteoclasts apparently arise from the confluence of the mesenchymal cells and connective tissue of the marrow.

The chief source of osteoclasts, however, is from old osteoblasts and bone cells.

Depleted, basophilic osteoblasts coalesce to form multinucleate masses. These syncytial elements become typical osteoclasts when their cytoplasm assumes an oxyphilic stainability. All intermediate tinctorial stages are demonstrable.

True oxyphilic osteoclasts also exist in cytoplasmic continuity with basophilic osteoblasts. Increase in size and nuclear content results from the engulfing of osteoblasts met in the path of resorption and from bone cells which are ingested as the bone matrix is resorbed.

Osteoclasts undergo retrograde changes and ultimately disappear through extreme degeneration.

Only indirect and insufficient evidence points to the osteoclasts as the active, specific agents of bone resorption. That they are merely degenerating, fused osteoblasts, accords better with the known facts.

BIBLIOGRAPHY

- AREY, L. B. 1917 a On the origin and fate of the osteoclasts. *Anat. Rec.*, vol. 11, no. 6, pp. 319-322.
 1917 b Phagocytosis by osteoclasts. *Anat. Rec.*, vol. 13, no. 5, pp. 269-272, 4 figs.
 1918 The origin, fate and significance of osteoclasts. *Trans. Chicago Pathol. Soc.*, vol. 10, no. 7, pp. 231-234.
- BASSINI, E. 1872 Sul processo istologico di riassorbimento del tessuto osseo. *Nota preventica*, 1872.
- BIDDER, A. 1906 Osteobiologie. *Arch. f. mikr. Anat.*, Bd. 68, S. 137-214, 33 Fig.
- BIDDER, F. 1843 Zur Histogenese der Knochen. *Arch. f. Anat., Physiol. u. wissensch. Med.*, Jahrg., S. 372-395, 1 Fig.
- BREDICHIN, J. 1867 Über die Bedeutung der Riesenzellen in den Knochen. *Centralbl. f. d. med. Wissensch.*, Jahrg. 5, S. 563-564.
- BRODOWSKI, W. 1875 Über den Ursprung sogenannter Riesenzellen und über Tuberkeln im allgemeinen. *Arch. f. path. Anat. u. Physiol.*, Bd. 63, S. 113-135, 8 Fig.
- BUSCH, F. 1877 Die Knochenbildung und Resorption beim wachsenden und entzündeten Knochen. *Arch. f. klin. Chirurgie*, Bd. 21, S. 150-181.
- DANCHAKOFF, W. 1909 Über die Entwicklung des Knochenmarks bei den Vögeln und über dessen Veränderungen bei Blutentziehungen und Ernährungsstörungen. *Arch. f. mikr. Anat.*, Bd. 74, S. 855-926, 18 Fig.
- DUBREUIL, G. 1910 Vacuoles a lipoides des ostéoblastes, des cellules osseuses et des ostéoclasts. *Compt. rend. d. l. Soc. Biol.*, T. 69, pp. 189-190.
- DUVAL, M. 1897 *Précis. d' histologie*. Masson et Cie, Paris, 31 + 956 pp.
- GEDDES, A. C. 1913 The origin of the osteoblast and of the osteoclast. *Jour. Anat. and Physiol.*, vol. 47, pp. 157-176, 12 figs.
- HOWELL, W. H. 1890 Observation upon the occurrence, structure, and function of the giant cells of the marrow. *Jour. Morph.*, vol. 4, no. 1, pp. 117-130, 15 figs.
- JACKSON, C. M. 1904 Zur Histologie und Histogenese des Knochenmarkes. *Arch. f. Anat. u. Entw.*, Jahrg., S. 33-70, 16 Fig.
- JORDAN, H. E. 1918 A contribution to the problems concerning the origin, structure, genetic relationship and function of the giant-cells of hemopoietic and osteolytic foci. *Am. Jour. Anat.*, vol. 24, no. 2, pp. 225-269, 70 figs.
- KACZANDER, J. 1882 Über den Ossificationsprozess. *Arch. f. path. Anat. u. Physiol.*, Bd. 87, Heft 1, S. 189-193, 7 Fig.
- KAUFMANN, E. 1907 *Lehrbuch der speziellen pathologischen Anatomie*. Reimer, Berlin, 10 + 1363 S., 693 Fig.

- KÖLLIKER, A. 1873 Die normale Resorption des Knochengewebes und ihre Bedeutung für die Entstehung der typischen Knochenformen. Vogel, Leipzig, 6 + 86 S., 95 Fig.
- LAMBERT, R. A. 1912 The production of foreign body giant cells in vitro. *Jour. Exp. Med.*, vol. 15, no. 5, pp. 510-515, 7 figs.
- LEWIS, F. T. 1913 A text-book of histology. Blakiston, Phila., 11 + 539 pp., 495 figs.
- LÖWE, L. 1879 Kleinere histologische Mittheilungen. C. Über die Umwandlungen der Osteoklasten im Knochenmark nebst Bemerkungen über Knochenwachstum. *Arch. f. mikr. Anat.*, Bd. 16, S. 618-625, 6 Fig.
- MAAS, H. 1877 Über das Wachstum und die Regeneration der Röhrenknochen mit besondere Berücksichtigung der Callusbildung. *Arch. f. klin. Chirurgie*, Bd. 20, S. 708-770, 27 Fig.
- MALLORY, F. B. 1911 Giant cell sarcoma. *Jour. Med. Research*, vol. 24, pp. 463-467, 8 figs.
- MAXIMOW, A. 1902 Experimentelle Untersuchungen über die entzündliche Neubildung von Bindegewebe. S. Fischer, Jena, 7 + 255 S., 13 Taf.
1910 Untersuchungen über Blut und Bindegewebe. 3. Die embryonale Histogenese des Knochenmarks der Säugetiere. *Arch. f. mikr. Anat. u. Entw.*, Bd. 76, Heft 1, S. 1-113, 48 Fig.
- MEYER, A. W. 1918 Some observations on megacytes in lymphatic tissues. *Amer. Jour. Anat.*, vol. 24, no. 1, pp. 91-107, 18 figs.
- MORPURGO, B. ET SATTA, G. 1908 a Sur quelques particularités de l'autolyse de l'os. *Arch. Ital. de Biol.*, vol. 49, pp. 380-382.
1908 b Présence d'un ferment actif sur les composés de calcium dans les os malaciques. *Arch. Ital. de Biol.*, vol. 49, pp. 383-384.
- MORRISON, A. 1873 Bone absorption by means of giant cells. *Edinburgh Med. Jour.*, vol. 19, pp. 305-311.
- MURISIER, J. 1875 Über die Formveränderungen, welche der lebende Knochen unter dem Einfluss mechanischer Kräfte erleidet. *Arch. f. exp. Pathol. u. Pharmakol.*, Bd. 3, Heft 5 u. 6, S. 325-347, 3 Fig.
- POMMER, G. 1881 Über die lacunäre Resorption in erkrankten Knochen. *Sitzungsber. d. k. Akad. d. Wissensch., math.-naturw. Kl.*, Bd. 83, Heft 1, Abt. 3, S. 17-120.
1883 Über die Ostoklastentheorie. *Arch. f. path. Anat. u. Physiol.*, Bd. 92, S. 296-363; 449-516.
- PRENTISS, C. W. 1915 The origin and fate of the osteoclasts. *Surg., Gynecol. and Obstet.*, vol. 20, pp. 678-679.
- RANVIER, L. 1889 *Traité technique d'histologie*. 2d ed., Masson, Paris. 871 pp., 414 figs.
- RÉNAULT, J. 1893 *Traité d'histologie pratique*. Lecrosnier et Babé, Paris, T. 1, 39 + 973 pp., 354 fig.
- RINDFLEISCH, E. 1872 A text-book of pathological histology. Trans. by W. C. Kloman and F. T. Miles. Lindsay and Blakiston, Phila., 695 pp., 208 figs.
- ROBIN, C. 1849 Sur l'existence de deux espèces nouvelles d'éléments anatomiques qui se trouvent dans le canal médullaire des os. *Compt. rend. d. l. Soc. Biol., Année 1*, pp. 149-150.

- RUSTIZKY, J. 1874 Untersuchung über Knochenresorption und Riesenzellen. Arch. f. path. Anat. u. Physiol., Bd. 59, S. 202-227, 8 Fig.
- SCHAFFER, J. 1888 Die Verknöcherung des Unterkiefers und die Metaplasiefrage. Arch. f. mikr. Anat., Bd. 32, S. 266-377, 26 Fig.
- SHIPLEY, P. G., AND MACKLIN, C. C. 1916 Some features of osteogenesis in the light of vital staining. Amer. Jour. Physiol., vol. 42, no. 1, pp. 117-123.
- TODD, T. W. 1913 A preliminary communication on the development and growth of bone and the relations thereto of the several histological elements concerned. Jour. Anat. and Physiol., vol. 47, pp. 177-188, 9 figs.
- WEGNER, G. 1872 Myeloplaxen und Knochenresorption. Arch. f. path. Anat. u. Physiol., Bd. 56, Heft 4, S. 523-533.
- WELLS, H. G. 1910-'11 Calcification and ossification. The Harvey Lectures. J. B. Lippincott Co., Phila., 146 pp.
- ZIEGLER, E. 1878 Über Proliferation, Metaplasie und Resorption des Knochengewebes. Arch. f. path. Anat. u. Physiol., Bd. 73, S. 355-379, 7 Fig.

EXPLANATION OF PLATES

The figures of these plates were made with a Leitz $\frac{1}{12}$ homogeneous immersion objective and a no. 1 Leitz ocular, at an original magnification of 785 diameters. With the exception of figures 8 and 11, which are from human embryos, the illustrations represent stages from the jaws of pig embryos.

ABBREVIATIONS

<i>b.c.</i> , bone cell	<i>obl.</i> , osteoblast
<i>cap.</i> , capillary	<i>ocl.</i> , osteoclast
<i>c.t.</i> , connective tissue	<i>str.</i> , striate edge of osteoclast
<i>mtx.</i> , matrix of bone	* , junction of confluent osteoblasts and osteoclast

PLATE 1

EXPLANATION OF FIGURES

The preparations, from which the illustrations of this plate were made, are from pig embryos, fixed in Zenker and stained with hematoxylin and eosin. The reduced magnification is now 590 diameters.

1 The basophilic syncytium, *ocl.*, illustrates the first stage in osteoclast development by the fusion of osteoblasts.

2 The immature osteoclast, *ocl.*, exhibits a transitional stage in stainability between the basophilic osteoblasts, *obl.*, and a typical oxyphilic osteoclast like figure 4.

3 An asterisk, *, marks the continuity between an osteoclast at the left and the osteoblastic syncytium on the right.

4 At the right is a bold osteoblast-osteoclast junction. On the left a process from an osteoclast, in contact with the capsule of the bone cell, *b.c.*, illustrates an early stage of phagocytosis.

5 Two later stages in the ingestion of bone cells by an osteoclast; the engulfment of, *b.c.*', is farther advanced than of, *b.c.*

6 Advanced osteoclastic degeneration. The nuclei are pyknotic, the cytoplasm highly vacuolated and palely staining.

7 An osteoclast within a blood capillary. Such usually show evidence of degeneration and suggest a method of final removal.

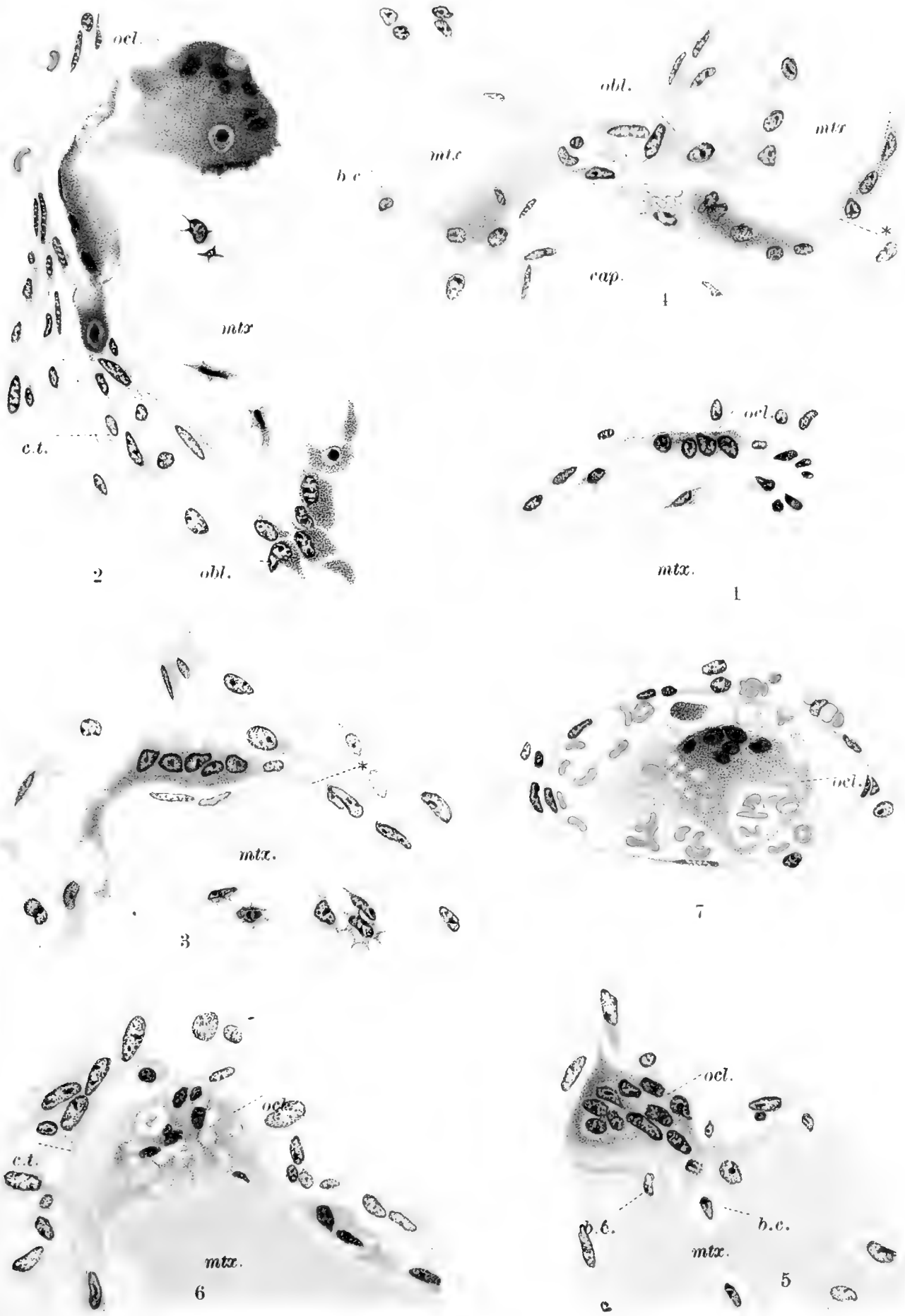

PLATE 2

EXPLANATION OF FIGURES

Figures 8 and 11 are from human embryos, the others from pig embryos. The reduced magnification is now 630 diameters.

8 An osteoclast showing a finely striate border in apposition with the bone.

9 A striate border of coarse, block-like composition.

10 An osteoclast wrapped around an eroded spicule and conforming closely to its irregularities. The bone cell, *b.c.*, is nearly incorporated.

11 Abrupt transitions, *, between an osteoclast and adjacent osteoblasts. The bone cell, *b.c.*, is confluent with the phagocytosing osteoclast.

12 On the right, the bone cell, *b.c.*, has practically lost its identity and become a part of the osteoclast. At the left, several encapsulated bone cells, *b.c.'*, lie within the osteoclastic cytoplasm.

13 Two stellate, encapsulated bone cells, have been taken up during bone resorption.

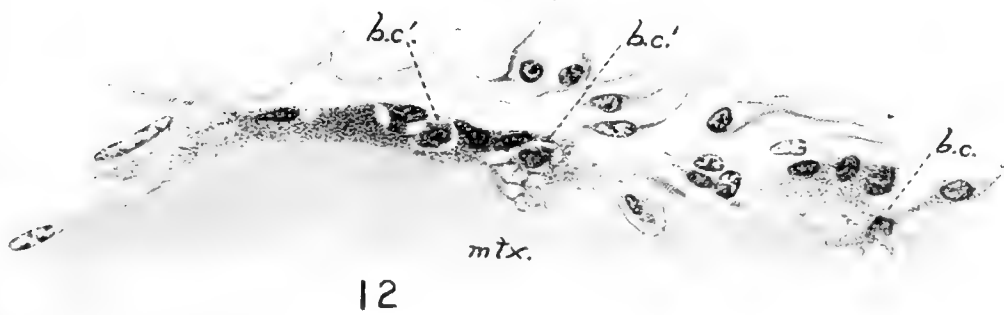
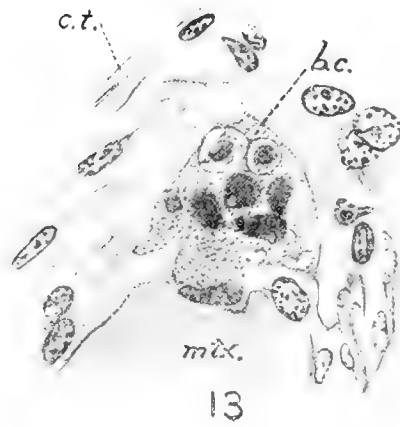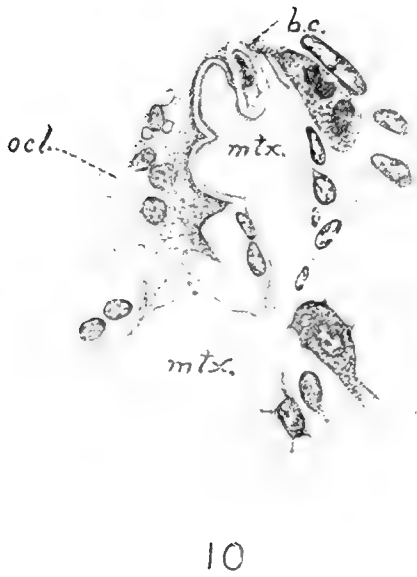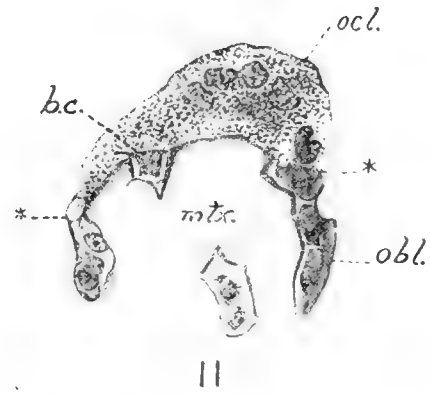
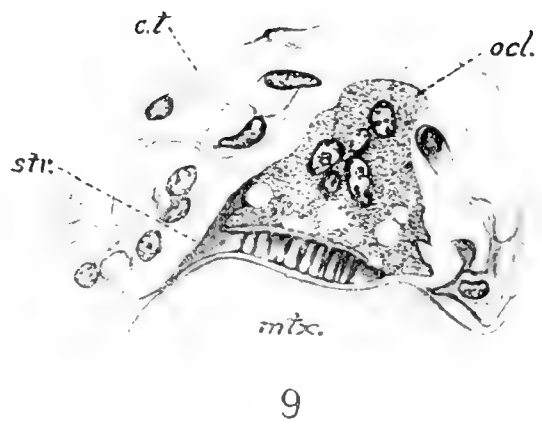


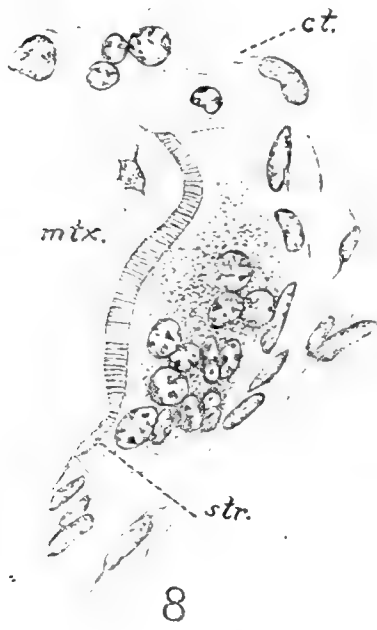PLATE 3

EXPLANATION OF FIGURES

The reduced magnification of the figures of this plate is now 630 diameters.

14 An osteoclast with irregular processes, some of which are continuous with the marrow connective tissue.

15 An oxyphilic syncytium in the marrow, apart from the bone. Continuity with the connective tissue suggests a possible origin from the latter.

16 An early stage in the degeneration of osteoclasts. Nuclei are pyknotic; cytoplasm slightly vacuolated.

17 The isolated (?) spicule of bone is surrounded by a degenerating osteoclast which shows extreme vacuolization and cytoplasmic disintegration.

18 Vacuoles have nearly cut off that portion of the osteoclast indicated by a cross. Such an appearance has been interpreted by some as indicative of a resolution into reticulum cells.

19 A highly degenerated osteoclast apparently left behind after resorption was locally completed.

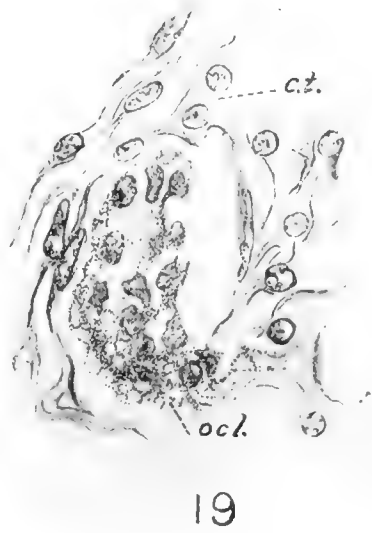
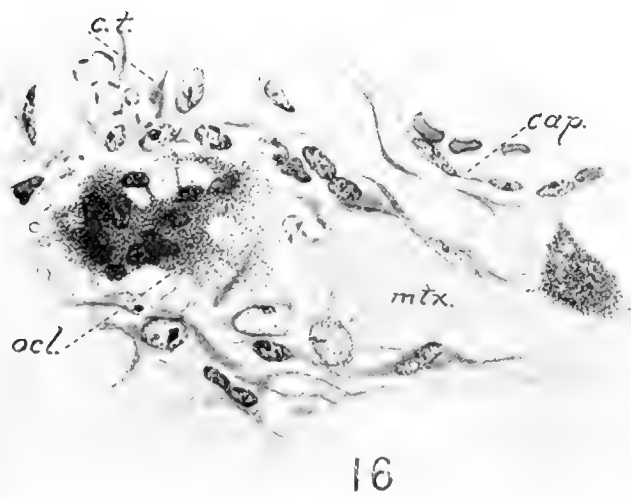
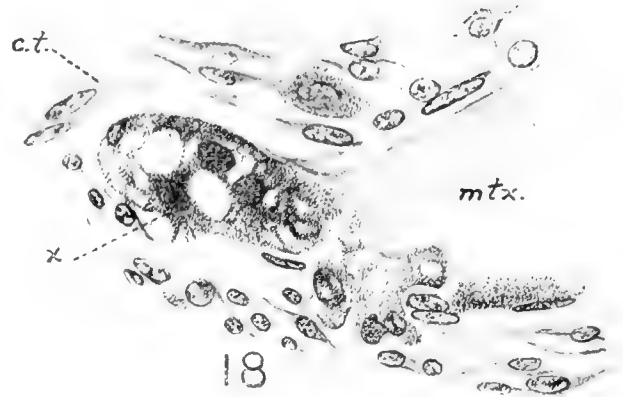
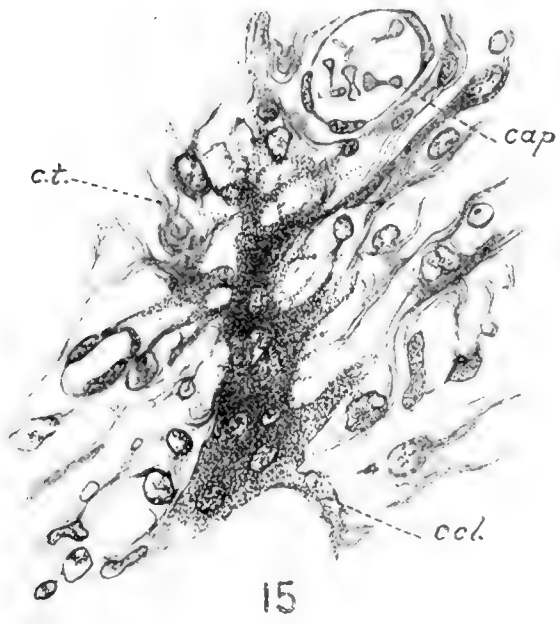
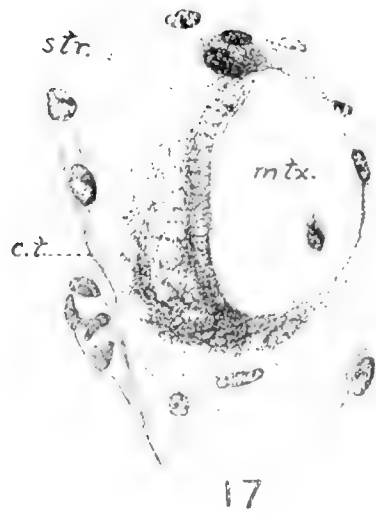
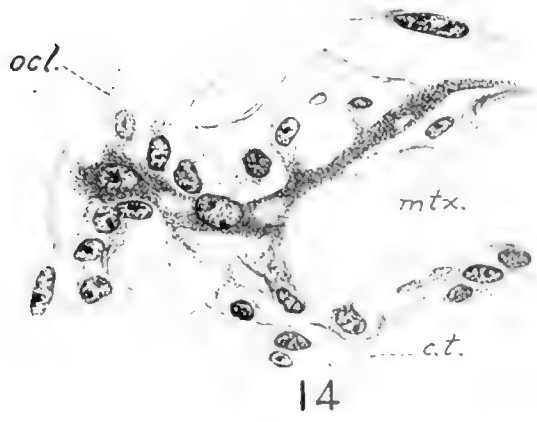


PLATE 4

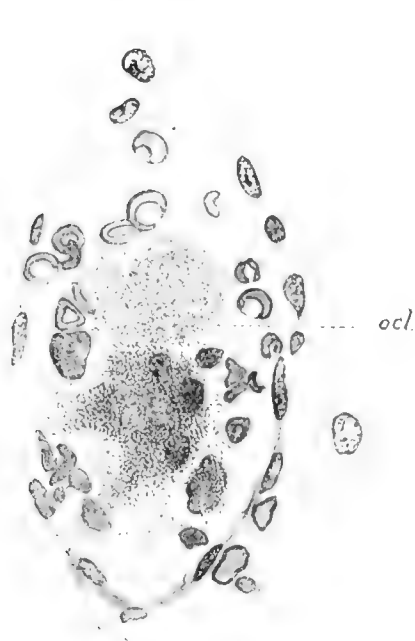
EXPLANATION OF FIGURES

The reduced magnification of the figures of this plate is now 630 diameters.

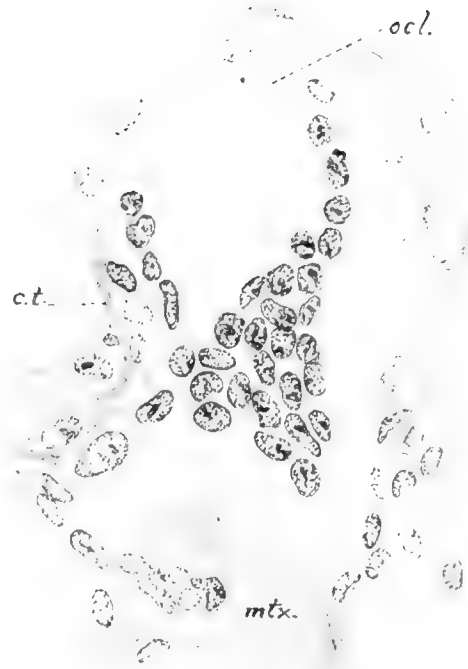
20 A degenerating osteoclast within a blood capillary (compare fig. 7).

21 A large osteoclast measuring $40\ \mu \times 80\ \mu$. It is at the rear of the local region of bone dissolution and somewhat later might have become isolated like figs. 19 or 22.

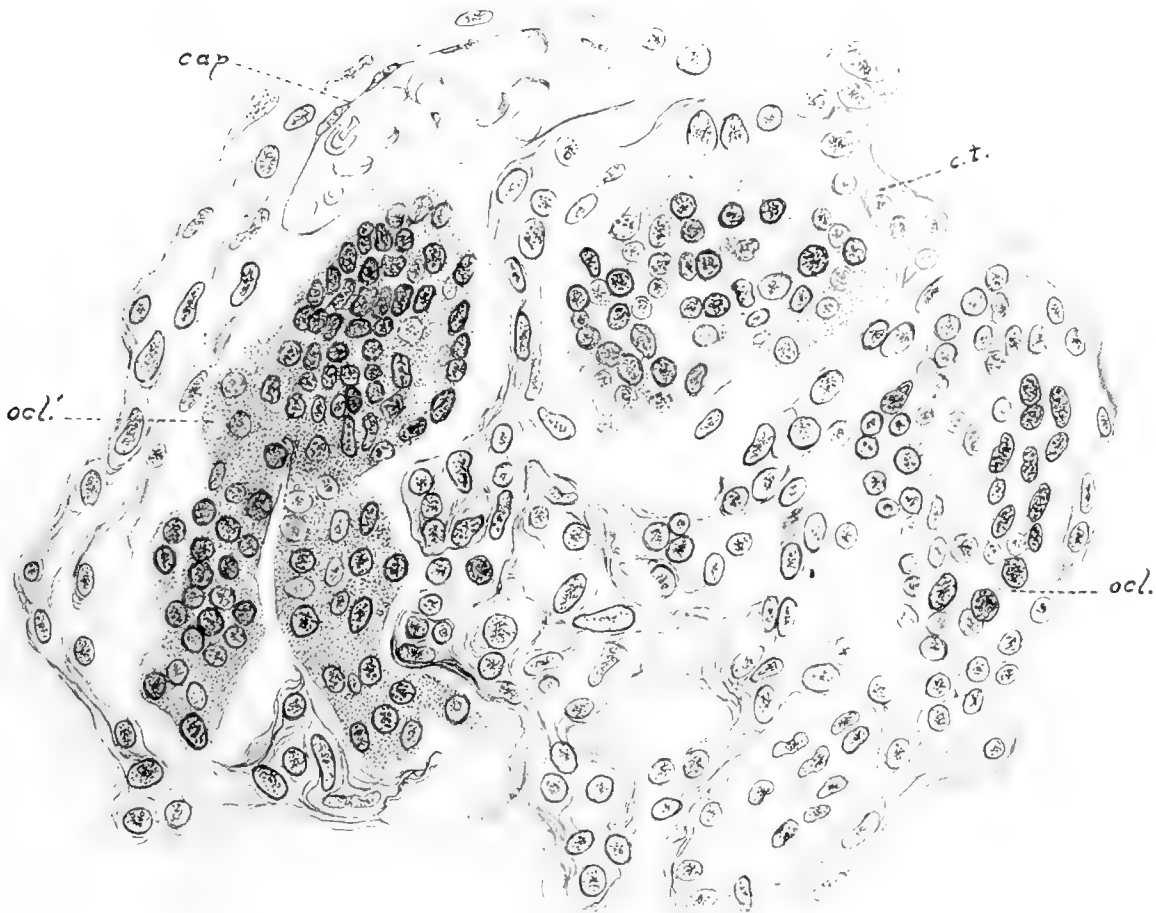
22 Several huge giant-cells lie stranded in the marrow tissue in an area where bone destruction is locally finished; possibly serial sections would have shown these elements to interconnect. Similar nests occur in the near vicinity. The osteoclast at the left, *ocl.*, measures $65\ \mu \times 105\ \mu$ and contains about 125 nuclei.



20



21



22

Resumen por Henry McE. Knower, por el autor S. Saguchi
Academia Médica, Kanazawa, Japón

Estudios sobre las células glandulares del páncreas de la rana.

El presente trabajo es un estudio crítico y práctico de la estructura histológica de las células glandulares examinadas con ayuda de varios reactivos en diferentes estados de la actividad secretora. Un concepto verdadero de la naturaleza de los elementos nucleares depende en sumo grado de la interpretación de la acción de los fijadores. El autor estudia con considerable detalle los gránulos citoplásmicos, las mitocondrias y fibrillas con referencia al papel que desempeñan con el núcleo y nucleolo en la formación de la secreción. El autor demuestra en los cortes una continuidad estructural íntima entre el nucleolo y la red nuclear, y los filamentos mitocondriales del citoplasma. Las observaciones sobre la formación de gránulos semejantes a grasa indican su origen a expensas de las mitocondrias y su probable paso a la sangre como parte de una secreción interna. Los gránulos de zimógeno se derivan de condriocitos mediante desintegración de estos últimos, formándose primero gránulos de "prozimógeno," muy pequeños, que creciendo se transforman en los gránulos de zimógeno. Las mitocondrias se están formando constantemente a expensas de la red nuclear para substituir a las usadas en la formación de los gránulos de zimógeno. El autor estudia extensamente la red intracelular o canalículos, que deben considerarse como formados por materiales de deshecho originados por una acumulación de sustancias no empleadas durante la elaboración de los gránulos de prozimógeno. También sigue la degeneración fisiológica de algunas de estas células glandulares. Una sección del trabajo esta dedicada a Los Nebenerne (núcleos accesorios) y el autor llega a la conclusión de que estas estructuras son artefactos o partes de células degeneradas.

STUDIES ON THE GLANDULAR CELLS OF THE FROG'S PANCREAS

S. SAGUCHI

Medical Academy, Kanazawa, Japan

FIVE PLATES

CONTENTS

1. Introduction.....	348
2. The nucleus.....	349
Historical.....	349
Observations.....	349
1. Chromatin network.....	349
2. Nucleoli and nucleolar corpuscles.....	350
3. The cell-body.....	356
A. Structure of the cytoplasm.....	356
Observations.....	356
Historical and critical.....	360
B. Mitochondrial apparatus.....	364
1. Technique.....	364
2. Shape, structure, and position.....	366
3. Genesis.....	369
C. Fat-like granules.....	375
1. Technique.....	375
2. Shape and position.....	376
3. Genesis.....	376
4. Significance.....	377
D. Zymogen granules.....	379
1. Technique.....	379
2. Shape, size, and position.....	379
3. Genesis.....	380
4. Extrusion.....	386
E. Intracellular net- and canalicular apparatus.....	388
Historical.....	388
Observations.....	388
1. Intracellular network.....	388
2. Canalicules.....	392
3. Significance and genesis of the intracellular net-apparatus...	393
4. Physiological degeneration.....	396
5. Mitosis.....	399
6. The so-called 'nebenkerne'.....	400
Historical.....	400
Critical.....	402

1. INTRODUCTION

The pancreas forms a favorable object for the study of the activity of secretory cells in general, and has been used by various investigators who have studied the minute structure of the pancreas cell in relation to the secretory process, since the complete processes which take place in the pancreas cell during the production of secreting matter are to be followed with great clearness. In looking over the literature, there can be found three important steps in the development of the structural particularities in the cells in question. The first step was taken by R. Heidenhain ('80). He divided the cell-body into two distinct zones; one, a light, apparently homogeneous outer zone turned toward the basement membrane, and the other, dark granular inner zone near the lumen. He suggests that the expenditure of the matter which is accompanied by the transformation of zymogen granules into secretion is going on in the inner zone, while the deposition of the nutritive material and the elaboration of zymogen granules take place in the outer zone; thus giving us an idea of the fundamental importance of the process going on in the pancreatic cell. The second step was taken by the investigations of Mouret ('95, '05), Laguesse ('99), Mathews ('99), Garnier ('00) and others, who attached considerable importance to the fibrillar structure first observed by Pflüger, in 1869, and assumed the participation of the filaments in the formation of zymogen granules. Structures of this kind have since been often described under the name of 'Solger's basal filaments' or 'Garnier's ergastoplasm,' the significance of which is not yet decided definitely. Benda ('97-'03), Meves, ('07, '08) and many others, finally, advocate a theory which makes the granules or filaments, named either 'mitochondria' or 'chondriocentes,' the most important morphological constituents of the cell. These structures were also found in glandular cells, and have formed a problem for various investigators which is still far from a satisfactory solution.

The questions as to whether these structures and others, above all the intracellular net-apparatus form essential constit-

uents of the protoplasm of the pancreatic cell, and, if this is so what are the mutual dependence among them, the mode of their formation, and their relation to zymogen granules, are of much importance not only for the study of the genesis of zymogen granules, but also for the solution of the biological significance of these structures in general.

As material of the present investigation, the pancreas of *Rana temporaria* was employed.

2. THE NUCLEUS

Historical

Ogata ('83) was the first to give fairly detailed information regarding the structure of the nucleus of the pancreas cell, though R. Heidenhain ('80) previously noted the existence of the larger nucleolus in it. Ogata worked on the amphibian pancreas, and showed that the nucleus has a distinct, deeply basic-staining boundary membrane with some thickenings or prolongations, from which numerous, extremely delicate, granular threads arise; the latter passing through the nucleus, and dividing it into a number of fields. In these fields, independent of the threads, there are one or more larger or smaller nucleoli, the staining reactions of which enabled him to distinguish two kinds; some stained with haematoxylin, and others, generally single in number, larger and stained by eosin. He termed the former 'karyosomes' and the latter 'plasmosomes.'

These observations of Ogata were on the whole confirmed by the studies of Kosinsky, Melissinos and Nicolaides ('90), Eberth and Müller ('92), Ver Eecke ('95), Mouret ('95, '05), and many others in the pancreas of various vertebrates. Mouret proposed to designate Ogata's 'plasmosome' as 'nucleolus,' 'karyosomes' as 'pseudonucleoli' or 'amas nucléiniens.'

Observations

1. *Chromatin network.* The nucleus (figs. 13, 23, 28, 37), stained with ordinary methods, e.g., with haematoxylin-eosin,

exhibits one or two spherical nucleoli, reddish in color, and numerous blue-stained chromatin granules, which, connected by faintly stained, fine threads, form the so-called 'chromatin network.' And the chromatin granules are, on the one hand, closely applied to the surface of the nucleolus and are fused together so as to envelop the latter more or less completely; thus forming what is usually called 'chromatin shell' (figs. 9, 12, 13, 22, 23, etc.), which seems to have been noticed by Ogata ('83), Mouret ('95), and Arnold ('12) in the nucleus of the pancreatic cell. Owing to the presence of this chromatin shell, it often happens that in tangential view the nucleolus shows no characteristic staining reactions, but stains blue like a chromatin mass, as noticed by Arnold. The chromatin granules are, on the other hand, applied upon the inner surface of the nuclear membrane which appears, in cross-sections of the nucleus, as a relatively thick basophilic line. The basophily of the nuclear membrane is due to the extremely thin chromatin layer, which, in surface view, reveals a delicate, faintly staining network.

The chromatin substance of the nucleus is not only accumulated, as above described, in the form of granules, but also in the form of irregularly curved cords. These chromatin granules and cords are not homogeneous, but exhibit, in various fixations and stainings, a thin, deeply staining cortex and a faintly staining main-mass, which suggests that the two parts are perhaps different in composition from each other (figs. 22, 25, 30).

2. *Nucleoli and nucleolar corpuscles.* Most of the nuclei have only one nucleolus; beside this there may exist several smaller nucleoli; the larger one is then named 'main-nucleolus' and the smaller ones are 'side-nucleoli.' There are also a number of nucleolar corpuscles in the nucleus.

a. *Main-nucleolus.* The main-nucleolus is, in most cases, of spherical form with an even contour, but sometimes oval, roundish triangular or polygonal in form. In the vast majority of cases it is single in number, but it sometimes happens that two, three, or four nucleoli of nearly equal size are seen in the nucleus (figs. 4, 23, 37); they are possibly formed by a division which is effected not by the scission, but by the stretching out of the nucleo-

lus, as seen in figure 5. The main-nucleolus is commonly located in or near the centre of the nucleus. It can never be seen applied to the nuclear membrane.

In the main-nucleolus one can notice three substances, which differ in staining reactions from one another:

Main-mass: The main-mass occupies the largest part of the main-nucleolus; it is well preserved by fixatives containing no acetic acid, and stained by iron-haematoxylin or Altmann's acid fuchsin (figs. 1 to 8, 14 to 16, 21, 24, 63 to 65). The most favorable fixatives for it are alcohol, sublimate and formalin. In fact, acetic acid in the fixatives considerably diminishes the affinity of the main-mass to the stains referred to, especially to iron-haematoxylin. In preparations which are obtained from pure sublimate material and stained by iron-haematoxylin, for instance, we see that the main-mass of the nucleolus takes a gray to black color, while the chromatin granules or cords are very easily decolorized (figs. 1 to 6). When the same method of staining is applied to sections made from the sublimate-acetic material, it will give an opposite result: the main-mass of the nucleolus appears as a perfectly clear space surrounded by a deeply staining shell (figs. 12, 80). It is probable that this aspect is not owing to the disappearance of the main-mass by the dissolving effect of acetic acid, but is to be sought in the loss of its affinity for iron-haematoxylin in consequence of the changes either of chemical or of physical properties produced by the above reagent; for, in sublimate preparations, the main-mass still can be made manifest by staining with eosin.

Cortical substance. This is the second constituent of the main-nucleolus and surrounds it in the form of a cortex (figs. 17 to 20, 55, 79, 10, 11). It always stains more heavily than the main-mass with most of the dyes; this is especially well marked in preparations which are obtained by the Benda staining of sections made from Champy or Meves material (figs. 17, 18, 26). The cortex is, in reality, comparable to a crust, so that the cortical substance passes gradually into the main-mass. The contour of the cortex is not smooth, but irregularly indented or with small granules or short rods exhibiting the same staining reaction as

the cortical substance. Thus the nucleolus as a whole assumes the confection-shaped appearance. It must especially be noted here that the cortex in question is not to be confounded with the chromatin shell mentioned before, which is closely apposed to the nucleolus; they are different from each other both in form and in staining reactions, and this can be observed with ease in such preparations as those which are made from the same fixed material, but stained in various ways (compare figs. 10 and 11 with fig. 13).

Argentophile granules. The third substance occurs in the form of minute granules in the main-mass, which stain a brown to black color with the Cajal's photographic method, using formalin prefixation (figs. 31 to 35). I will designate it 'argentophile granules,' in order to denote its affinity for silver salts. They can never be made manifest, so far as I could ascertain, by such fixatives as sublimate, formalin, trichloroacetic acid, alcohol, potassium bichromate and osmic acid, with various stains, but appear only as small clear vacuoles (figs. 1 to 4, 6, 8, 13 to 16, 29, 30). These granules are of spherical form and of variable size, although even the largest ones do not exceed one-fifth of the diameter of the nucleolus. They are single or several in number and are situated, in most cases, in the middle of the nucleolus. In case a large number of them are gathered together, it often occurs that the centre of the nucleolus presents an alveolar appearance (fig. 29). The granules are not infrequently seen near, or closely applied, to the periphery of the nucleolus (fig. 8). The granules are not entirely homogeneous, but seem to consist of a deeply staining cortical layer and a more slightly staining internal part, as seen in a Cajal's preparation (figs. 31 to 35).

I have also noticed that the same granules are present outside the nucleolus or are scattered in the nucleus; they vary in number, and are either situated near the nucleolus or are apart from it to a greater or less extent, or even are applied to the inner surface of the nuclear membrane. It is conceivable that the argentophile granules are passing out of the nucleolus and proceeding towards the nuclear membrane; from the existence of a few granules in the cytoplasm near the nucleus, as seen in some cases, it would seem that they pass through the nuclear membrane.

It is a difficult matter to determine definitely the significance of the argentophile granules. They are, in all probability, products of the metabolism going on within the nucleolus, which are to be eliminated from the latter and are to reach the cytoplasm in the manner above mentioned. It is quite within the bounds of possibility that they are associated in some way with the functional activity of the cytoplasm or they are, as waste matters, to be cast off from the cell. Of these two possibilities I am inclined to believe that the first one is more probable, since the argentophile granules are often produced in considerable number in some alveolar cells of the pancreas which are undergoing a certain change of functional activity, with which I shall have occasion to deal at another time.

The structure of the nucleolus in the egg-cells of several invertebrates and lower vertebrates has been a problem for various investigators; some believe to have found a reticulation or vacuolation of the nucleolus; others granules in it, which are known under the name of 'nucleolini.' These structures can be morphologically identified either with the argentophile granules or with the negative of them, as I have seen. That the granules in the nucleolus can be made manifest by the Cajal's photographic method is not novel; Lache ('06) Cajal ('09), and others have found the similar granules impregnated in the nucleolus of the nerve cells; moreover, Lache's figure 1, which is drawn from a Cajal preparation, shows that the same granules are in the nuclear sap outside the nucleolus. In the pancreas literature I find in this connection only the paper of Calier ('96) who suggested the existence of the nucleolini in the pancreas cell of the hedgehog and gave the name of 'endonucleolus.'

b. Side-nucleolus. Some of the nuclei of the pancreatic cells have, besides the main-nucleolus just spoken of, one or two side-nucleoli (figs. 2, 5, 6, 8, 16, 21). It seems, however, that they are lacking in many of the nuclei. The side-nucleoli are of various sizes; but even the largest one seldom exceeding one-third of the diameter of the main-nucleolus. They are spherical corpuscles with an even contour, and bear a remarkable resemblance in their staining reactions to the main-nucleolus, though, in some

respects, differences are observed between the two. In the preparations fixed in formalin, sublimate-formalin, alcohol, bichromate-formalin, Zenker's, osmium-sublimate, etc., and stained after Altmann, the side-nucleolus can be more easily decolorized than the main-nucleolus. In the preparations fixed in sublimate and stained with iron-haematoxylin, on the contrary, the former stains more deeply than the latter and exhibits also a more heavily stained cortical layer (fig. 2). The side-nucleoli have no structures in their interior. They are, in most cases, situated in the region intermediate between the main-nucleolus and the nuclear membrane, but it is not uncommon to see side-nucleoli closely apposed to the main-nucleolus (fig. 8), or appearing to be constricting off of the main-nucleolus (figs. 5, 6). The latter fact strongly suggests the derivation of the side-nucleoli from the main-nucleolus.

c. Nucleolar corpuscles. Under this appellation I include certain small corpuscles in the nucleolus, which are stained black, as seen in the preparations fixed in sublimate, alcohol, or sublimate-formalin, and stained with iron-haematoxylin (figs. 1 to 4, 7, 15, 16); in those fixed in sublimate-acetic acid, Champy's, or Meves' fluid, they stain dark blue with crystal violet, and red with acid fuchsin or safranin (fig. 20). They are either small granules or rods of all shapes and sizes, which seem to vary with the individual nuclei and the properties of the fixatives employed. They are not only scattered through the nucleus, but also are in close apposition to the nucleolus or to the inner surface of the nuclear membrane.

It is a difficult matter definitely to determine the relation which might exist between the position of the chromatin granules or cords and the nuclear corpuscles; for they cannot be brought into view by staining in one and the same preparation. They, in fact, differ from each other in staining reactions. In the preparations preserved in Champy's or sublimate-acetic mixture, and stained with Benda's crystal violet, for example, the nucleolar corpuscles take on a dark violet color, while the chromatin corpuscles are left unstained (figs. 10, 11, 17, 18). That the nucleolar corpuscles are, however, attached to the chromatin network,

may be rendered evident when we compare with each other the preparations which are fixed in the same manner, but tinged in different ways, e.g., the iron-haematoxylin stain with the Benda's, as applied to the material fixed after Meves (figs. 26 and 27), or the haemalum stain with the Benda's as applied to the material fixed in sublimate-acetic mixture (figs. 10, 11 and 13). From these observations I have gained the impression that the nucleolar corpuscles are imbedded in the chromatin granules or cords. This impression was deepened by the appearance of the clear vacuoles or canalicules in the middle of the gray- or blue-stained chromatin granules or cords, in the preparations fixed in trichloroacetic acid and stained with iron- or alum-haematoxylin (figs. 29, 30). I concluded that this was, at least in part, a negative appearance due to the nucleolar corpuscles being dissolved out or remaining unstained.

As regards the genesis of the nucleolar corpuscles, I am fully convinced that they are derived from the main- or side-nucleoli. As before stated, the main-nucleolus is surrounded by a deeply staining cortex, the outer surface of which is not only uneven, but frequently furnished with granules or rods of various shapes and sizes but of the same staining reaction as the cortical substance (figs. 17 to 20, 26, 55). These granules or rods often appear to be separating from the cortex. From these facts and from the fact that the cortex with its appendages exhibits the same staining reaction as the nucleolar corpuscles, the inference is warranted that the two are the same thing, and that the latter are formed by budding and separating from the former. Now the question arises, is the picture above mentioned not to be regarded as representing a fusion of the nucleolar corpuscles with the nucleolus in order to cause the increase in volume of the latter? I, however, insist on the view above advocated by me; for I hold that the nucleolar corpuscles are correlated with the vital activities going on in the cytoplasm, as will be described later on, and that their separation from the nucleolus and their progress toward the periphery are conditions which must be fulfilled in making the above assumption. It is quite conceivable, even rational, that the nucleolar corpuscles, in passing toward the periphery, would make their

way along or through the chromatin network, which is in accord with what has been said concerning the position of the two.

That the nucleolus is concerned in the production of the nucleolar corpuscles or similar bodies has been noticed by Montgomery ('99). This author, in a description of the subcuticular gland cells of *piscicola*, pictures the nucleolus, after having enlarged to a certain extent, as constricting off pieces of all shapes and sizes, which are distributed through the nucleus; and that this is not a picture of fusion of nucleolar corpuscles with the nucleolus is apparent from the fact that they are all cast off into the cytoplasm. On the other hand, the fuchsinophile granules which were seen, by Galeotti ('95), in the nuclei of the *Spelerpes*' pancreas and pyrenoid corpuscles which, after Meirowsky ('08), appear in the nuclei in the formation of pigment, are, in all probability, structures which have been constricted off of the nucleolus or, at least, have the same origin as this.

3. THE CELL-BODY

A. Structure of the cytoplasm

Observations. In studying the structure of the cell in general, especially of the glandular cell, it seems to me to be most essential to discriminate between two groups of the cytoplasmic contents; to one group belongs the cytoplasm proper or protoplasm that forms the ground-mass of the cell-body, and to the other, that group formed by the vital activities of the former, or, derived either from the nucleus or from the outside; and, as instances of the second group, mitochondrial granules or filaments, zymogen granules, lipoid granules, etc., may be enumerated. In the following I will first take up the cytoplasm proper, while the other constituents of the cell-body will be treated of separately.

The existence of a large number of zymogen granules and mitochondrial apparatus often renders impossible satisfactory detailed observation upon the cytoplasm proper. Under these circumstances, it will be advisable to examine a cell containing only a few zymogen granules or such portions in which they are generally wanting, i.e., the basal portion of the cell. Alveolar

structures of the cytoplasm brought about by the accumulation of zymogen granules bear no relation to the proper construction of the plasm. We know, on the one hand, from daily experience, that the plasm exhibits extraordinary diversity of structure according to the nature of fixatives, and that, therefore, it would be premature to draw any conclusion from such observations; and, on the other hand, one searches in vain, in most cases, for minute structures of the cytoplasm as studied in the fresh condition, since the cytoplasm then appears perfectly homogeneous except for some ill-defined granules or filaments. It would also be rash, from this, to conclude that the cytoplasm is entirely devoid of structure. It is, for the present, indispensable to the study of the plasm to allow various fixatives to act upon the cytoplasm and to compare the structural changes so produced with one another. In fact, some of the fixatives act in such a way that the plasm is as well preserved as seen in the fresh state; others cause so pronounced changes as often to lead to the formation of very fantastic structures. There are many gradations of the action of fixatives between these two extremes.

In general, osmic or chromic acid mixtures containing a very small amount of acetic acid or without this, such as Altmann's, Benda's, or Meves,' fix in such a manner that the protoplasm proper of the pancreatic cell, provided the fixatives acted with sufficient power upon the plasma, shows no structural particularities (figs. 44 to 47, 55, etc.). On the contrary, the fixatives which contain a larger amount of acetic acid, such as Zenker's, Carnoy's, sublimate-acetic mixture, etc., may give rise to fibrillar structures in the cytoplasm (figs. 36, 37, 48 to 52, 110, 118). These fibrillae appear in the form of striation which, at the sides of the nucleus run principally in vertical direction; while, below it, the horizontal course predominates. The horizontal fibrillae often pass into the vertical ones so that there occurs a concentric fibrillation around the nucleus. In preparations taken from the alcohol-, sublimate-formalin, or bichromate-formalin material containing no acetic acid, the above striation can also be seen (figs. 48 to 52).

These fibrillae are extremely fine and stain a blue or violet color with alum-haematoxylin, as is the case with the chromatin corpuscles of the nucleus. That this staining reaction is not conditioned by the presence of chromatin substance will be apparent from the fact that, in iron-haematoxylin preparations made from the sublimate or Zenker material, the fibrillae take no color or, at the most, a gray, whereas the chromatin network stains black.

Since it is seen that the arrangement of the fibrillar structure in question cannot be explained by the mere precipitating action of the fixatives, we are not justified in drawing the conclusion that it is not preexistent, although it cannot be seen in the fresh state or in the osmium preparation. I believe that the following explanation can be put forward to account for the genesis of the structure: It is admitted by some investigators that the cytoplasm contains, besides protein substances, a large amount of lipid substances. In the application of such fixatives as preserve lipid substances in their natural position, e.g., of osmic acid solution, the plasma remains homogeneous; whereas the fixatives containing alcohol, chloroform, acetic acid, etc., seem to dissolve out either lipoids or certain protein substances so that the fibrillae which form a morphological constituent of the plasm, and which in the fresh state are obscured in the plasma sap, become differentiated both in refrangibility and in tingibility. In other words, the plasm which holds the fibrillae in position becomes removed, and the latter are liberated. The fibrillae which have thus been individualized, I propose to name 'protofibrillae.' They are extremely fine, and it is a matter of difficulty to perceive their individuality even in thin sections. Much more is this the case in the fresh state where it is necessary to make examinations in thick layers. The fibrillae which we can recognize in fixed preparations must certainly be regarded as having to some extent undergone definite alterations, above all adhesion of the protofibrillae. It may be conceived that the latter, individualized in consequence of the dissolving out of a certain plasma portion as above presumed, can no longer be maintained in their natural position and come, as it were, to float in the cell-body, so that there is liability to adhere to one another.

The process of adhesion may proceed to varying extents according to the nature of the fixatives, the success or failure of fixation, the stage of cell function, and other unknown causes, thus leading to the formation of many enigmatic structures, as have been described by various investigators.

As above mentioned, the fixatives such as alcohol, trichloroacetic acid, formalin, bichromate-formalin, etc., cause only slight adhesion of protofibrillae, so that, in such cases, parallel striation or only a slight sign of net formation at most is produced (figs. 48 to 52). In fixatives like Carnoy's, Zenker's, sublimate-acetic, bichromate-acetic mixture, etc., on the contrary, the changes are much more pronounced; this is especially true of the deeper parts of the block where the cell is ordinarily poorly preserved. There are a great many variations in the degree of adhesion. Either fiber-bundles, or a network situated in the basal portion of the cell-body may be formed, as seen in figures 36 to 38, 110, 118. On the other hand comma-, crescent-, or shell-like structures (figs. 40, 84) may be formed by the adhesion of a large number of fibrillae and then applied either to one side of the nucleus or to the cell periphery. Finally, smaller or larger spherical corpuscles may be formed by the agglomeration of the fibers and show more or less pronounced concentric striation (figs. 37, 39, 84, 100, 101, 105). There are all grades of transition between mere striation and agglomeration of the fibers, and it often happens that not only the different cells, but also one and the same cell contains different types of structures. It must also be here noticed that the structures formed by the adhesion of a large number of fibers, such as thick bundles, commas, or crescents, etc., generally stain more deeply with haematoxylin, which is perhaps due to their compact character in consequence of the close apposition of the constituting fibrillae.

From the above description it is evident that a large amount of acetic acid in fixatives produces remarkable adhesion of the fibrillae; yet the superficial cells, even in such fixatives as bichromate-acetic or sublimate-acetic mixture, are fairly well preserved, so that there occurs only slight adhesion (figs. 80, 81) or none at all. This discrepancy can perhaps be explained by the

rapid action of potassium bichromate or sublimate, which restrain acetic acid from destructive action. The diffusibility of acetic acid, on the contrary, is great, so that it penetrates more quickly and produces changes before other constituents of the fixative could come to act. This is the reason why the products of adhesion increase in number as we proceed toward the deeper portion of the piece.

On the other hand, there are cases in which the formation of fibrillar structures cannot be ascribed to the shrinking effect of the fixative alone. Marked differences in the structures above mentioned are often observed in individual animals, so that, preserved in one and the same fixative, one exhibits no remarkable change, whereas in the other the structures are formed in so large number that almost all the cells contain them. In the latter case, the structures can well be seen even in the osmic acid fixing material, where they appear indistinctly striated or even homogeneous (fig. 88).

It happens also that certain granules, stained black by iron-haematoxylin, are interposed among the fibrillae of the structures in question (figs. 88, 105). If some of these granules, as often occurs, are located in the center of the spherical body with concentric striation, an appearance of a centrospheré with central corpuscles is produced. That this is, however, not the case is obvious from the fact that the granules are situated not only in the centre, but also in the other parts, even outside of the body (fig. 105), and also that the number of the bodies may be two or over; the granules in question are, rather, to be regarded partly as zymogen or lipid granules, partly as mere precipitates of osmium, as will be referred to later on.

Historical and critical. Regarding the cytoplasmic structure of the secretory cell, especially of the pancreatic cell, there is wide divergence of opinion among various investigators.

1. Homogeneity of the protoplasm. As early as 1869 Langerhans described that the basal portion of the pancreas cell in fresh state, is entirely homogeneous. Later observations of R. Heidenhain ('80), in fresh materials, and of Mouret ('95), in preserved cells, confirmed this. Hoven recently ('10) likewise

expressed the view that, though the inner zone of the pancreatic cell becomes alveolar after the extrusion of zymogen granules, the remaining portion of it lacks special structure with the exception of chondriocentes in it. It must be borne in mind, however, that the above investigators and others who accept the homogeneity of the protoplasm have made their observations either in its fresh state or in osmium preparations.

2. Many of the investigators believe that the protoplasm consists of two substances: spongioplasm or mitom and hyaloplasm.

It is a matter of course that, when the zymogen granules are dissolved out, the inner zone of the pancreatic cell assumes an alveolar or reticular appearance, as described by Langley ('84), Eberth and Müller ('92), Ver Eecke ('95), Zimmermann ('98), and Arnold (12). It is a mistake, however, to conclude that this is the proper structure of the plasm; for such structure is nothing other than an appearance produced by the accumulation of zymogen granules.

The fibrillar structure in the basal portion of the pancreatic cell was first noticed by Pflüger ('69), R. Heidenhain ('80) ascribed the striation in question to an appearance due to the presence of canalicules. A similar structure was observed by many of the subsequent investigators: Eberth and Müller ('92), Ver Eecke ('95), Zimmermann ('98), Mathews ('99), Laguesse ('99), and others. Solger ('94, '96) has found the same thing in the submaxillary gland of man and given the term 'basal filaments' to it, and, on the other hand, Garnier ('00), who took salivary glands, pancreas, liver, etc., of different species for study, has related the striation which he named 'formations ergastoplasmiques basales,' to the secretive activity of the glandular cell. Similar structures have been since described under the name either of 'Solger's basal filaments,' or of 'Garnier's ergastoplasm' by various workers, as Mouret ('05), Bouin ('05), Prenant ('10), Champy ('11), Bensley ('11), Arnold ('12), Mislowsky ('13), and many others. Their nature has formed a problem of much discussion. In looking over the literature one can classify the structures hitherto described, according to their form and structure, as follows: a) fine filaments which course in vertical direc-

tion through the basal portion of the cell, as described and figured by Ver Eecke, Mouret ('95, '05), Zimmermann, Mathews, Arnold, Mislowsky and others. Zimmermann and Mislowsky have found that these parallel striations appear in both longitudinal and transverse sections, and claim that this is, in reality, nothing but a figure of the section of a lamellar system; *b*) homogeneous rods or fibrillar bundles, such as seen in the figures of Eberth and Müller, Solger ('94), Garnier, Prenant, and others; *c*) comma- or crescent-shaped, or spherical, either homogeneous or fibrillar bodies which are usually classified along with the so-called 'nebenkern,' and which have been found by Eberth and Müller, Ver Eecke and Mouret ('05) in the pancreatic cells. To my mind, these three types are not distinct structures, but belong to one and the same system, for it is evidently seen from the figures of the above authors that they are connected by all grades of transition.

The opinions of investigators are not in agreement as to the genesis and significance of the fibrillar structures.

1. Mouret ('95, '05) Mathews, Laguesse ('99), Prenant, and others admit that the structures under consideration are performed in living cells and take part in the formation of secreting matter either directly by breaking down into granules or indirectly. Mouret and Laguesse have given the name 'substance or filament prézymogene' to it. The assumption that the nucleus participates in the formation of secreting matter is perhaps based upon the facts that, first, a relation in position and in tingibility exists between the nucleus and the filaments; secondly, that the latter run vertically from the base, where the nucleus lies, toward the top, and lose themselves among the zymogen granules; and, finally, that the increase and decrease of the two are reciprocal. Moreover, Mathews and Garnier believe that the filaments are connected by one extremity to the nucleus and receive by this means a certain substance necessary for the elaboration of the secreting matter from the nucleus. They explain, in this way, the similarity of the staining reactions of the two. This argument and others advanced by Mathews, Garnier, and their supporters are not sufficient, at present, to warrant the unqualified accept-

ance of the above hypothesis; since the two do not necessarily exhibit the same reaction for various stains, and also we know that secretion granules are assumed by many recent investigators to be derived from the other constituent of the cell. This matter will be more particularly discussed when the genesis of zymogen granules is considered.

2. In more recent times, Hoven ('10), Prenant ('10), Champy ('11), and Mislowsky ('13) identify the basal structures with mitochondrial filaments, assuming that the former is a modification of the latter artificially brought about by the fixation. But, I cannot agree with this view; for these two structures may be easily brought into view by staining in one and the same preparation, as already described by Regaud and Mawas ('09), Arnold ('10), and Bensley ('11); they also differ markedly from each other not only in morphology and staining reactions, but also in their biological significance.

3. The view of Eberth and Müller ('92) and Bensley ('11) approaches that of my own. The former authors state that the fibers and rods in question are products of the adhesion of protoplasmic fibers; but how this change is brought about, in other words, whether they are preexistent or postmortem structures, cannot be seen in their description. On this point, Bensley expresses himself more distinctly, maintaining that the basal filaments are fixation artifacts produced by the precipitation effect of acid. He says: "the real basal substance of the cells is homogeneous. It is quite possible, however, that the basal filaments are preexistent in the living cell though invisible because they are imbedded in a substance of the same refraction index, and that they are rendered visible in the acid fixation by contraction." There is, however, some difference of opinion between Bensley and me; he considering basal filaments as preexistent and ignoring my protofibrillae. The basal filaments which we find in fixed preparations I believe to be nothing but my protofibrillae to some extent adherent into bundles.

B. Mitochondrial apparatus

1. *Technique.* For the fixation of mitochondria I used Zenker's, osmium-sublimate, Flemming's, bichromate-formalin, bichromate-osmium-formalin, bichromate-osmium-sublimate, Meves'-formalin (without acetic acid) and Maximow's mixture, especially those advised by various investigators for mitochondria: Meves', Benda's, Altmann's, Champy's, Kolster's fluid, etc. Sections were cut from $2\ \mu$ to $5\ \mu$ in thickness and stained mainly with Heidenhain's iron-haematoxylin, Altmann's acid fuchsin, and Benda's crystal-violet.

Generally speaking, the fixatives containing a great amount of acetic acid, e.g., sublimate-acetic, Zenker's, Flemming's, etc., fix the mitochondria only in cells of the superficial layer. In the fixatives which contain a small amount of that reagent, e.g., Benda's, Meves', etc., the mitochondria in the deeper portion of the piece are well preserved; but there is no constancy in the results with these fixatives, their action being often limited to the more superficial region of the piece. The mixtures which preserve the mitochondria in a fairly satisfactory manner throughout the piece are osmic acid, osmium-sublimate, Altmann's bichromate-osmium-sublimate, Maximow's fluid, etc., all of which are without acetic acid. Of these, the bichromate-osmium-sublimate mixture works much better, for it not only preserves both cytoplasm and mitochondria in equally good manner, but also is adapted for either of the mitochondria stains above referred to.

In the following paragraphs I will try to discuss the action of the reagents commonly used for the preservation of mitochondria.

a. *Acetic acid.* That acetic acid dissolves out or destroys mitochondrial substance is a well-known fact, but it seems that this does not necessarily occur when employed in combination with other reagents. Fixed in mixtures which contain a large amount of acetic acid, such as sublimate-acetic, Zenker's or Flemming's fluid, both the cytoplasm of the superficial layer of the piece and the mitochondria in it are preserved in a satisfactory manner. This is perhaps due to the rapid action of the reagents combined with acetic acid, the fixation taking place

before the latter can exert any destructive influence. Since the penetration of acetic acid is far greater than the other reagents, it is conceivable that the mitochondria in the deeper portion may easily be destroyed by acetic acid before the other reagents could get there. Hence, the fixatives with limited acetic acid, such as Meves' and Benda's, bring to view the mitochondria in deeper parts than in the above case. Finally, the fixatives which contain no acetic acid preserve mitochondria evenly throughout the piece. In the superficial portion of the piece, however, both cytoplasm and mitochondria are always better preserved than elsewhere, no matter what fixative we use, provided that the duration of fixing is appropriately chosen. But it is worthy of remark that osmic acid or sublimate is essential in order to preserve the mitochondria, even in the cells of the superficial layer, in the fixatives containing acetic acid.

In a word, acetic acid, when a small amount of it is employed in connection with other reagents, favors the fixation of the cell without destroying the mitochondrial substance. On the other hand, it can hardly be said that the fixatives which contain no acetic acid always preserve mitochondria in a good state, since poorly penetrating reagents cannot rapidly act upon the mitochondria in the deeper parts.

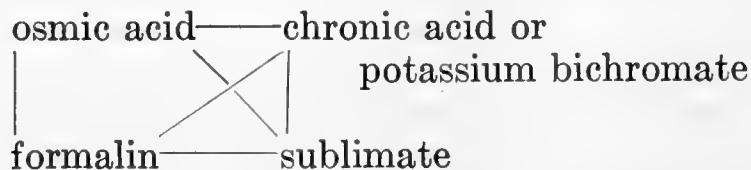
b. Osmic acid is the most excellent fixing reagent. But this alone, or mixtures with a great quantity of it, seems to cause the shortening as well as thickening of mitochondrial filaments, especially toward the centre of the piece.

c. Formalin, used singly, also well preserves mitochondria. But it cannot be said that this fixation is adapted for all of the mitochondria stains. Applied to material fixed in this way, the Benda stain gives very poor results, while iron-haematoxylin has a greater affinity for the mitochondria in the deeper portions of the piece. On the contrary, formalin material is most adapted for Altmann's acid fuchsin, so that, under favorable conditions, the most beautiful and instructive preparations can be obtained. The affinity of formalin material for iron-haematoxylin can be increased by treatment with osmic acid or osmium-sublimate mixture after the formalin.

d. Chromic acid and potassium bichromate have been frequently used for the fixation of mitochondria. So far as can be recognized from my own experience, these reagents, used singly, could not preserve mitochondria in any satisfactory manner. On the other hand, it can scarcely be said that the presence of these reagents in fixing mixtures is absolutely necessary to the fixation of the mitochondrial substance; for, even in such fixatives as osmic acid, formalin, osmium-sublimate, etc., which contain no chrom-salts, mitochondria are well preserved. But there seems to be little doubt that their presence in fixatives favors the fixing and staining of mitochondria; Benda's 'Post-chromierung' will answer this purpose.

e. Sublimate is not essential to the preservation of mitochondria; since, however, this reagent fixes the cytoplasm both rapidly and evenly, good results can be obtained when applied in combination with other reagents, e.g., bichromate-osmium-sublimate, Maximow's fluid, etc.

It will be seen from the above account that the reagents which, used singly, afford fairly satisfactory results for fixing and staining mitochondria, are osmic acid and formalin, and that chromic acid, potassium bichromate or sublimate alone do not have such action. The combination of reagents to prepare fixatives for mitochondria can be seen from the following diagram:



It is shown in this diagram, on the one hand, that fixatives can be prepared by combination of two, three or four reagents, which are connected by lines with each other; and, on the other, that osmic acid or formalin alone can also be employed as a fixative for mitochondria; acetic acid may either be added to the fixatives or omitted.

2. Shape, structure, and position. As described by Schultze ('11), Levi ('12), and others, the mitochondria in the acinus cells of the pancreas, in fixed and stained preparations, appear as rods

or filaments, i.e., chondriocotes, when the fixation is perfect (figs. 44 to 65, 71 to 74, 80, 81, etc.). They are of even thickness and of smooth contour; local enlargements and the like are usually lacking. Their course may be either straight or curved, undulatory or corkscrew-shaped. When a filament abruptly changes its direction at a certain point, an appearance as if it carried a grain, is often produced; in the same manner, undulatory or corkscrew-shaped mitochondria may appear, on superficial examination, either as filaments carrying granules or as rows of granules. So far as could be seen by most careful observation, however, there were no chondriocotes carrying the so-called plastcs, described by some investigators, nor rows of granules and free granules of mitochondrial nature, except in certain locations in the cell (figs. 57 to 66, 71 to 74, 77, etc.). Hoven's ('10, '12) observations on such granules were perhaps made in unsatisfactorily preserved materials. In fact, it will be seen that similar granules on the chondriocotes as well as granules of various sizes disseminated in the cell-body increase more and more as we pass toward the deeper parts of the piece, where the cell structure is usually imperfectly preserved. Mislawsky ('11, '13) and Ciaccio ('13) also claim that the formation of granules is either an artificial or a pathological process. The shape of mitochondria varies to a more or less extent according to the fixatives employed. Osmic acid alone or mixtures containing a great amount of it seem to cause the thickening and shortening of chondriocotes, which, at the same time, take a straighter course (figs. 62 to 64).

The chondriocotes, as seen in perfectly fixed preparations, are independent; in other words, they neither ramify nor anastomose, as described by Hoven ('10, '12), Levi ('12), and others. An appearance of the net formation, as described by Mislawsky ('11, '13), is perhaps due to the interlacement or eventual adhesion of chondriocotes. Maximow ('16), also, reached the same conclusion. The occasional occurrence of anastomosis, ramification, or rings (figs. 41-43) is probably owing to fixation artifacts of chondriocotes, for we never see such structures in perfectly preserved portions of the section. On the other hand, I

do not agree with Hoven ('10, '12) that the ramification or the close side-by-side apposition of chondriocontes are pictures showing their longitudinal splitting; for it will be seen that the multiplication of the mitochondrial filament, as will be shown later on, takes place in a quite different manner.

In addition to long filaments, relatively short ones or rods are often met with. Whether these rods are actual structures or are brought about in the act of cutting sections is difficult to decide, inasmuch as the production of short rods in such thin sections as I have made is not unusual.

A few words concerning the structure of the chondrioconte. There are some investigators who distinguish between a cortical and a marrow-substance. This claim is made when the filament is shortened or thickened, or is broken down into granules, in consequence of unsatisfactory fixation. In perfectly preserved cells, on the contrary, the chondrioconte is always homogeneous.

The position of mitochondrial filaments or chondriocontes is variable according to the degree of accumulation of zymogen granules; generally speaking, they are crowded around the nucleus more than elsewhere, so that they are never lacking here even when they cannot be detected in the rest of the cell-body (figs. 45, 47, 54). Such relation in position between the nucleus and chondriocontes was pointed out by Policard ('12), who studied liver cells. He says that this relation changes but slightly with the different stages of secretion. The chondriocontes below the nucleus course mainly horizontally, while at the sides they ascend toward the distal end of the cell, the horizontal filaments often passing over directly into the longitudinal ones (figs. 43, 56). In case the zymogen granules are few in number or are entirely lacking, the chondriocontes situated over the nucleus have irregular courses (figs. 55, 56, 58, 60). When the zymogen granules are densely packed together, the chondriocontes do not usually enter the granular zone (figs. 44, 61, 79); so, a certain region over the nucleus, which appears clear and contains only a few zymogen granules, is commonly free from chondriocontes (figs. 39, 44, 61). This is characteristic of such mitochondrial preparations as Benda's, Altmann's, and Meves'. The significance of this region will be discussed later on.

3. *Genesis.* Historical. There is considerable difference of opinion as to the genesis of mitochondria, which may be summarized as follows: 1) Benda, Meves ('08, '10), Duesberg ('08, '10), Hoven ('10), and others claim that mitochondria are plasmic structures derived from those of the male and female sex cell, and transmitted from generation to generation. According to this theory they are not derived from the nucleus. 2) Mitochondria are mere products of differentiation of the cytoplasm, as described by Lams ('06) and Vejdowsky ('07). The former author believes that the mitochondrial granules of the egg-cell of *Rana temporaria* are elaborated under the direction of the attraction sphere; Vejdowsky also claims that they are formed by the regressive transformation of the centroplasm, as products of the formative activity of the centriole. 3) Russo ('08, '10) and Comes ('13) are of the opinion that mitochondria are paraplastic structures drawn in from the outside. The authors were led to this assumption from observations that the mitochondrial substance in the egg-cell is increased by excessive nutrition or by a certain food (lecithin), whereas they decrease in the fasting. 4) There are some who accept the derivation of the mitochondrial substance from the nucleus. Goldschmidt ('04) believes to have found chromidia, first described by R. Hertwig, in various somatic cells of *Ascaris*, and identifies them with the mitochondria. According to this author, the chromatin substance of the nucleus consists of two components—idiochromatin and trophochromatin. The former remains behind in the nucleus, the latter passes over into the cytoplasm. To the category of trophochromatin belongs the chromidial or mitochondrial substance. On the other hand, Wassilieff ('07) found that deeply staining chromatin substance passes out of the nuclei of spermatogonia of *Blatta germanica*, giving rise to mitochondria; while Jordan ('12) is of the opinion that mitochondria are derived from the cast-off fragments of chromosomes in the mitosis of spermatogonia of the bat. Very recently, Alexeieff ('17) believes to have substantiated the nuclear origin of mitochondria.

The mitochondrial filaments or chondriocentes in the secreting pancreas cells must be multiplied in some way or other; for,

in spite of their continual expenditure in the formation of zymogen granules, as will be explained, they never disappear from the cell. Hoven ('10, '12) believes to have found that the chondriocontes in the pancreas cell either multiply by longitudinal splitting or by elongation of the remainder. So far as I have been able to ascertain, there was no evidence of multiplication by the splitting of the filament; the second assumption of the author is more plausible, yet it is only a hypothesis.

Observation. In my previous study of the amphibian epidermis, I observed that in the physiological degeneration of the glandular cells a certain substance in the nucleus passes, in the form of filaments, into the surrounding cytoplasm, and that these filaments cannot be distinguished by form and staining reactions from the mitochondrial filaments present. I have, further, noticed that, in the retarded formation of Leydig's granules, certain nuclear corpuscles stained deeply by iron-haematoxylin may supplement the above granules. From these observations I have been led to the view that certain constituents of the cytoplasm are in close relation to the nucleus, and that possibly those which are necessary for cell function are located in mitochondria and derived from the nucleus. In order to solve this question, I made a large number of thin sections from variously fixed materials and searched for possible relation between mitochondria and nuclear contents. It should be noted that this work is not only a matter of difficulty, but also may give rise to misinterpretation, so that great care should be taken in judging the findings.

In close examination of preparations taken from variously fixed materials, such as sublimate-acetic acid, formalin, sublimate-formalin, Zenker's, Meves', Benda's, Champy's, Rubaschkin's, Maximow's, etc., I have often met with a connection between a mitochondrial filament and the nuclear network. In these preparations, also, there are many cases where the one end of the chondrioconte appears to be attached to the outer surface of the nuclear membrane. It would be rash, however, from this appearance, to assume the close relation between the two. An actual connection must be, and, in fact, is, formed in such a way that one end of the chondrioconte present near the nucleus continu-

ously passes over to a cord of the nuclear network, which, in turn, is attached either to the nucleolar corpuscles or to the nucleolus (figs. 44 to 55, 71). In addition to those shown on the plates accompanying this paper, many other instances of such connection could be observed. Preparations fixed in formalin or Meves' fluid, and stained with iron-haematoxylin are most favorable for the study, since both the mitochondria and the cords of the nuclear network are deeply stained and the continuity of the two can easily be followed. Since this continuity cannot be established with certainty in a surface view of the nucleus, we must make cross-sections. Although it cannot be said that the connection can always be detected in such sections, it is, however, not rare that there are seen two or three connections in one and the same nucleus (figs. 48, 52).

From the above observations the conclusion seems justified that the chondriocentes of the pancreatic cell are derived from the nucleus, by a certain nuclear substance passing out through the nuclear membrane into the cytoplasm. The opposite condition is not conceivable, for, there can be little doubt that the chondriocentes, as will be afterwards described, are used up in the formation of zymogen granules. Several objections might be raised to the preceding considerations. First, if the chondriocentes pass over the nucleus, an appearance of a connection of the former with the nuclear network might be produced when viewed from the surface. I exclude such uncertain cases from consideration, drawing my conclusion only from the observations made upon the cross-sections of the nucleus. Secondly, mitochondrial filaments might be brought in contact with the nuclear membrane accidentally or be superposed upon the nuclear area, by the action of the knife in cutting. I do not, of course, profess to draw the above conclusion from such an observation; the picture of the chondriocentes passing over to the cords of the nuclear network must be continuous in order to prove that the connection actually exists. In addition to the direct evidence mentioned above of the nuclear derivation of the mitochondrial filaments, there is another, indirect: that mitochondria are never lacking near the nucleus, even when

the remaining portion of the cytoplasm is devoid of them, as already noted by Policard ('12) in the liver cell, and as I have also ascertained in the present investigation.

Since a certain substance in the nucleus appears to be squeezed out through the pores of the nuclear membrane, it must be expected that the primitive shape of mitochondria, at least in the pancreas cell, will be filamentous, and that their ramification or anastomosis, whether it may be a normal state or not, must have been secondarily formed. And, in order that these filaments maintain their form, it will be most essential that the organization of the cytoplasm remain intact. If this organization is disturbed in consequence of some external influences, either mechanical or chemical, the mitochondrial filaments can no longer exist as such, but they become thick and short; even break down into granules or small vesicles; this is always met with in such portions as have suffered mechanical injury or are imperfectly fixed.

There is no especially favorable position for the passing out of the mitochondria; it can take place on either side of the nucleus.

Now the question arises, from what nuclear substance do the mitochondria originate? As already stated, there are three kinds of substances which take part in the formation of the nuclear network: one is the basichromatic substance and the others are those forming nucleolus and nucleolar corpuscles. It has also been concluded that the substance forming nucleolar corpuscles and the cortex of the main-nucleolus is of the same nature. On the other hand, the staining reactions of the mitochondria bear a strong resemblance to those of the nucleolar corpuscles. This strongly suggests that there may exist some genetic connection between the two. In fact, it can often be seen that in the preparations fixed in Champy's and sublimate-formalin mixture and stained with iron-haematoxylin, the nucleolar corpuscles are drawn out into filaments which penetrate the nuclear membrane and pass continuously into the mitochondrial filaments (figs. 53, 55). These observations have led me to the belief that the mitochondrial substance is derived from the nucleolar corpuscles.

From the staining reactions of the mitochondria, the inference would appear justifiable that it is quite different from the chromatin substance of the nucleus. In alum-haematoxylin preparations, the chromatin takes on a violet color, whereas the mitochondrial filaments remain unstained and appear as fine, clear canalicules in a violet background (fig. 83). In the Meves', Champy's, etc., preparations, on the contrary, the nucleolar corpuscles and the mitochondria are deeply stained, while the chromatin corpuscles are easily decolorized. This difference in staining reactions is inconsistent with the hypothesis of Goldschmidt and his pupils that the mitochondria are identical with the chromidia which, according to them, are nothing other than the chromatin substance passed out of the nucleus. Since, on the other hand, there can be no doubt that the mitochondria are derived from the nucleus, I do not also agree with Benda, Meves, and their supporters in regarding them as mere plasmic structures. Just as little plausible are the views held by some that they are either products of differentiation of the plasma or bodies drawn in from the outside.

That the nucleus is the centre of propagation and metabolism of the cell is now fully recognized by various investigators; this is evidenced by the experiment that the cell-body devoid of its own nucleus cannot further continue to exhibit its vital activity. While the chromatin is generally regarded, from its behavior in mitosis, as forming the material basis of heredity, its relation to the metabolic activity of the cell has been a question which remains at present unanswered. Concerning the biological significance of the nucleolar substance, there is also wide divergence of opinion among different investigators. In the following I will first consider two opposed views advanced with regard to the relation between the nucleolus and the metabolism of the cell, and then summarize my opinion.

According to the view of some histologists (Flemming, '82; Rhumbler, '93; Montgomery, '99), the nucleolus must be considered as stored-up nutritive material for the chromatin substance or for the whole nucleus. Haecker ('93, '95) and his supporters claim, on the contrary, that the nucleolus is not nutri-

tive material, but a decomposition product which separates in or upon the chromatic elements during the vegetative activity of the cell and nucleus, and which, at the beginning of mitosis, is removed from the nucleus. This conception is termed the 'nuclear secretion theory.'

From my observations referred to above, we cannot arrive at any satisfactory solution of the problem of the origin of the nucleolar substance. In a previous investigation ('15) I have observed that, in the physiological degeneration of certain glandular cells in the amphibian epidermis, the nucleus is characterized by the increase of the nucleolar substance, accompanied by the simultaneous decrease of the nuclear substance. From this I have been led to the assumption that the former might be formed at the expense of the latter: a view which was also held, as early as 1888, by Hermann. Since it is obvious from my observations that the nucleolar substance passes out of the nucleus in order to form an essential constituent of the cytoplasm, it must be regenerated either at the expense of the nutritive material taken in from the cytoplasm or by the decomposition of the chromatin substance. I find it possible rather to accept as adequate the explanation that the nucleolus is formed by the participation of the chromatin substance than to regard it as a mere accumulation of nutritive material. This conception is strictly opposed to that of Flemming, Korschelt, and others, and is rather in favor of the view of the 'nuclear secretion theory' of Haecker. I regard, however, the nucleolar substance not as worthless decomposition product, but as material necessary to give rise to such an essential substance for the cell activity as mitochondria. The transformation of the nucleolar substance into mitochondria must be thought of as taking place in the following manner: the main-mass of the nucleolus undergoes change in staining reaction at the periphery and gradually is converted into a substance that forms the cortex of the nucleolus. The latter, on the other hand, continually emits small granules or rods, which pass toward the periphery along the nuclear network. These separated corpuscles are those which we have termed 'nucleolar corpuscles.' They, then, pass through the nuclear membrane

into the cytoplasm in the form of filaments, which are nothing other than mitochondrial filaments or chondriocentes. These steps of changes must be a visible manifestation of the nuclear and cell activity; these changes are not yet completed with the formation of the mitochondria, but the latter must undergo further changes in order to perform the special function of the cell. I will return to this question further on.

C. Fat-like granules

R. Heidenhain ('75, '80) was the first to point out the presence of fat granules in the pancreas cell. He allowed dilute alkalis to act upon the pancreas cell, and found that the zymogen granules grew pale, while certain granules, which he took to be of fatty nature, are characterized by the resistance which they offer to that reagent. The fatty granules have since been recognized by several investigators in various glands; in the pancreas by Mathews ('99) and Laguesse ('00), more recently by Bensley ('11), Arnold ('12), Mislawsky ('13), and Maximow ('16).

1. Technique. In preparations fixed in pure osmic acid or in mixtures containing osmic acid, such as Meves', Benda's, etc., the granules in question take on only a pale grayish color; in the Mislawsky's fixative and in osmium-sublimate with formalin prefixation they appear as black granules; they are also impregnated with the Fauré-Fremit's and Golgi's method. In fixatives containing a large amount of acetic acid, they appear as clear vacuoles which remain unstained in either of the stains employed; in preparations fixed in Meves', Benda's, Altmann's, Champy's, etc., fluid and stained with iron-haematoxylin, they take on a brown to black color.

It will be seen from the above account that the granules in question are not blackened with osmic acid alone, but stain a grayish color which grows more and more pale in the subsequent manipulation of the piece and sections. In order that they may be blackened by osmic acid, the action of a reducing agent is necessary. In the cases above mentioned, formalin and pyrogallic acid serve as such. In the Mislawsky's mixture formalin together with osmic acid act upon the piece. Formalin may also

be employed as a prefixing reagent for a piece which is to be treated afterward with osmic acid or osmium-sublimate mixture. From this it is evident that these granules have relatively weak reducing power, although they eagerly take on osmic acid. They seem also to have special affinity for chromic acid, as is seen from the Golgi's chromium-silver method. From these reactions and their affinity for fat stains, such as sudan III, scarlet red, etc., the inference is warranted that they are of fatty nature; hence they have been termed 'fat-like granules.'

2. *Shape and position.* The fat-like granules are not scattered through the cytoplasm, but are limited between the nucleus and basement membrane (figs. 44, 47, 57 to 70, 105). Almost all the cells contain such granules, few lacking them. They vary greatly in number being often numerous and accumulated in one or more heaps in close proximity rather to the basal surface of the cell than to the nucleus (figs. 60, 65). They also vary in size, but such as exceed the zymogen granules in bulk cannot usually be seen. In shape they are spherical with even contour. Confect-shaped granules as seen in Golgi preparations (figs. 69, 70) are perhaps due to the shrinking effect of the reagents. Small granules appear homogeneous, while in larger ones a clear distinction can be made out between a deeply staining cortex and a faintly staining main-mass (figs. 60, 61). In rare cases the fatty granules can occur in the portions above the nucleus (fig. 70).

3. *Genesis.* From the above observation that the fat-like granules are situated near the basal surface of the cell, the question arises whether they are not derived from the blood- or lymph-vessels. I will answer this in the negative, for it can clearly be seen that they take origin here from a certain constituent of the cell.

In preparation fixed in osmic acid or Meves' fluid and stained with iron-haematoxylin, we can easily find those cells which contain no fat-like granules, but some tortuous mitochondrial filaments running horizontally between the nucleus and the basal surface of the cell (fig. 56). Next, we can find in the same portion of other cells chondriocontes carrying small spherical enlargements in their course (figs. 57, 61, 63); the latter can be so

numerous that a rosary-shaped picture is produced (figs. 57, 59, 63). In still other cells, there are free small granules, the chondriocentes carrying granules having disappeared (figs. 58, 62). These three figures are connected with one another by all grades of transition and must be regarded as different stages of one and the same process; in other words, some chondriocentes below the nucleus disintegrate into granules. The latter are at first small and show the same staining reactions as the chondriocentes; increasing in size, they gradually change their staining characteristics until the fat-like granules mentioned above are formed (figs. 60-68).

The genetic connection between the mitochondrial and the fat or fat-like substance in the cell has received attention of some recent investigators. Altmann ('94) describes the fat as passing into the cell not in the form of corpuscles, but as decomposition products; the assimilation of fat within the cell takes place through the cell-granules; in other words, the granules, being loaded with fat, become gradually transformed into fatty granules. The more recent investigators, Bobeau ('11), Champy ('11), Dubreuil ('13), Mayer, Rathery and Schaeffer ('14), Cowdry ('16), and Scott ('16), point out a striking resemblance in the chemical behavior between mitochondria and fat or lipid corpuscles, and admit that the latter may be derived from the former. Concerning the fatty granules of the pancreas cell, Laguesse ('00) believes that they are products of disintegration of 'filaments baseaux' (mitochondrial filaments?), while Bensley ('11) noticed that the fat globules are often embedded in the mitochondrial filaments present at the basal portion of the cell; these observations afford direct confirmation of my view. It would be of interest to make a comparative study of this point in various kinds of cells.

4. *Significance.* Mathews ('99) relates fat-granules to the internal secretion of the pancreas and says: "Other than these bodies there is no histological evidence of the 'internal secretion' of the pancreas. It is not impossible that the substances composing the internal secretion are components of the cytolymph." Laguesse ('00), who considered the behavior of fat droplets at

different stages of secretion, has found that they disappear from the glandular cell during its activity, and that they reappear and increase during the resting period. He regards the fat-droplets as stored up material; after zymogen granules have been formed from the assimilated material, the remnant of the latter is used up in the formation of fat-droplets. At the expense of these, zymogen granules may be formed after continued fasting. Mislowsky ('13) and Maximow ('16) have also found that the fat-granules make their appearance in large numbers on pilocarpin injection. According to the former author, their appearance must be pathological.

I have above mentioned that the fat-like granules are produced by the transformation of mitochondria. The pilocarpin injection affords an indirect confirmation of this view. As Mislowsky and Maximow have observed, and I can confirm from my own experience, the fat corpuscles become largely increased in number by injection of that medicament. This is probably owing to the fact that the production and expenditure of mitochondria are thereby accelerated, which accompanies the increased production of the fat-like granules. This is also in accord with the observation of Laguesse that the fatty granules of the pancreas cell are increased in the stage of exhaustion.

In studying the ultimate fate of the fat-like granules, we must take into account that they are formed near the basal surface of the cell, and are never seen to pass toward the lumen. It is well within the bounds of possibility that they become used up here or pass out of the cell. It would seem from their staining reactions that a part of them are undergoing definite alteration (fig. 64); though it is not certain that all of them behave in the same manner. On the other hand, it must be noticed that granules of the same nature are often met with in the capillary blood-vessels (fig. 67) or in the connective tissue separating the latter from the basis of the glandular cell (figs. 66, 68). Since we have now determined that the fat-like granules are formed within the pancreas cell, the pictures just mentioned cannot be regarded as evidence of their passage from the capillary blood-vessel toward the acinus-cell, but as exhibiting their movement in the opposite

direction. If such assumption is tenable, then the question arises as to what part they play in the blood-vessel. Are they to be regarded as mere decomposition products, or are they to be taken up by other kinds of cells, exerting an influence in some way upon the activity of the latter? I will take them in the sense of Mathews as representing an internal secretion of the pancreas cell. This is in agreement with a recent tendency to ascribe the process of internal secretion not only to the islet cells, but also to the parenchyma cells of the pancreas.

D. Zymogen granules

1. *Technique.* Zymogen granules can be well preserved in a variety of sublimate mixtures and in many of the fixatives for mitochondria, and can be stained with iron-haematoxylin, acid fuchsin, etc. In preparations fixed in bichromate acetic acid, alcohol, Carnoy's and Flemming's fluid, they are either imperfectly stained by iron-haematoxylin or remain unstained. From this it appears that, in the fixatives containing a large amount of alcohol or acetic acid, even if they contain osmic or chromic acid, the affinity of zymogen granules for iron-haematoxylin is much diminished, and that the sublimate mixtures, even if they contain acetic acid, will preserve zymogen granules. That acetic acid does not totally dissolve out or destroy zymogen granules, but perhaps acts upon them in such a way that a certain constituent of the granules which has strong affinity for iron-haematoxylin is removed, is evidenced from the fact that, although the granules fixed in bichromate acetic acid remain unstained in iron-haematoxylin, they can yet be demonstrated by staining with eosin. In the preparations fixed in alcohol or Carnoy's, on the contrary, they can no longer be stained even by eosin.

2. *Shape, size and position.* As is well known, the secretion granules of the pancreas are of spherical form and are accumulated in the upper half of the cell. Their increase or decrease has, in most cases, a marked influence upon the shape and size of the glandular cell. Generally speaking, the cells containing a few zymogen granules are smaller than those which are full of

them; still there are cases where this does not hold. Zymogen granules, even when they are densely packed together in the cell-body so that the nucleus is compressed against the base, can never be seen between the nucleus and the basement membrane (figs. 39, 44, 61). Above the nucleus there is usually a light area in which zymogen granules either are wanting or are present in small numbers; in other cases, it contains smaller granules, yet it is well marked off from the remaining portion by a clear zone (figs. 61, 75, 76, 78, 81). It can often be seen that the area is subdivided by clear stripes into a number of parts, so that it exhibits a reticular appearance. This area is usually situated immediately above the nucleus, or more or less apart from the latter; it is very seldom situated nearer the cell-periphery than the nucleus. I shall return to this area a little later when the genesis of zymogen granules is considered.

Zymogen granules exhibit a little variation in size, which indicates that they have a definite limit of growth and are well individualized so that they do not flow together as such. On the other hand, we cannot find such small granules as coincide in diameter with the mitochondrial filament, at least not in mitochondria preparations (figs. 39, 44, 55) in which some believe to have found small granules, which according to them, must grow up to zymogen granules.

Macallum ('91) admits that zymogen granules present next to the lumen are larger than those near the nucleus, since they increase in size during their passage toward the lumen by the deposition of a certain substance derived from the protoplasmic area of the cell; Mathews ('99), on the contrary, describes the granules next to the nucleus as always larger. So far as can be seen from my preparations, there are no such relations between the sizes of zymogen granules and their positions. I have also noticed that the periphery of the granules is more deeply stained than the center, but not to such an extent as to lead to the formation of 'crescent-shaped corpuscles,' as pointed out by M. Heidenhain ('90) in the pelvic gland of the triton.

3. *Genesis.* Historical. Regarding the origin of secretion granules in general, there is full discussion in the papers of

Laguesse, Hoven ('12), Mislawsky ('13), and others, to which the reader is referred for details. In the following the views of various investigators concerning the origin of zymogen granules will be summarized.

a. Cytoplasmic origin. Langley ('84) and Carlier ('96) believe that zymogen granules are derived from the hyaline substance or hyaloplasm; an opinion which seems to have secured few adherents among histologists.

That the filaments present in the basal portion of the cell take part in the formation of zymogen granules was first suggested by R. Heidenhain as early as 1880. The similar filaments have since been described by various investigators under the name 'Solger's basal filaments' or 'Garnier's ergastoplasm,' and there has been much discussion as to their significance, especially as to their bearing upon the origin of zymogen granules. Mouret ('95, '05), Laguesse ('99), and others believe that they are formed by disintegration of the basal filament; hence the authors gave the term 'une substance prezymogène' to the filaments. Garnier ('00), on the other hand, has made a study of various glands, inclusive of pancreas, and has come to the conclusion that the filaments are indirectly concerned in the formation of zymogen granules. According to him, the process is as follows: the nucleus, first of all, increases in volume, accompanied by the enlargement of the plasmic nucleolus and by the diffusion of the chromatic substance through the nuclear sap. In the next stage the basal filaments come in contact with the nucleus and then is acquired the basophilic property. Garnier explains this phenomenon hypothetically by assuming that the nucleus furnishes the chromatic substance by osmosis to the filaments; he gave the term 'excretion nucléaire' to the process. Next, the basal filaments leave the nucleus, momentarily, and distribute the loaded chromatic substance throughout the cytoplasmic reticulum. Then, there appear basophilic granules at the nodes of the reticulum, while the chromaticity of the basal filaments decreases. Finally, zymogen granules make their appearance in the meshes of the network. The conception of Mathews ('99) includes the two views above mentioned: the cell-threads (basal

filaments) which, according to him, are nothing other than the chromatin passed out, give rise, by decomposition, to zymogen granules.

On the other hand, there are many investigators who hold that zymogen granules are derived from special cytoplasmic granules or filaments. Altmann ('94), who made an extensive study of the secreting process, came to the conclusion that the secretion granules, whatever kinds of glandular cells we may take, are formed by the enlargement of the 'primary granules,' which multiply by means of the formation and division of the 'vegetative threads.' Thus, he advanced the theory that "die Sekretion ist ein granulärer Process." The filaments found by Michaelis ('00) in vital stained preparations of the pancreas and salivary glands of different species are in all probability to be identified with the vegetative filaments of Altmann; it was further noticed by Michaelis, who used janus green combined with neutral red for vital staining, that, in addition to the filaments stained green and zymogen granules stained red, there are in the basal portion of the pancreas minute granules which stain partly with janus green, partly with neutral red, and which are to be regarded as young zymogen granules. From these observations the author was led to the assumption that zymogen granules are derived from the filaments in question. Since Benda's investigations, the specific granules and filaments which have been included under the term 'mitochondria' have been recognized by several investigators in different kinds of cells, inclusive of the glandular cells. That they take part in the formation of secretion granules is assumed by Bouin ('05), Regaud and Mawas ('09), and others in the salivary glands, by Hoven ('10, '12), O. Schultze ('11), Champy ('11), Arnold, ('12), Maximow ('16), and others in the pancreas. Concerning the mode of participation, there is some difference of opinion: according to Regaud and Mawas, the mitochondrial filaments can fix the substance extracted from the blood, which becomes accumulated at one or several portions of the filament in the shape of spherules; the authors regard the latter as the foundation of secretion granules, assuming that they gradually

increase in volume and then become separated from the filaments, which remain behind. On the contrary, Hoven, O. Schultze, Arnold, and Maximow believe that the mitochondrial filaments break down into granules, from which secretion granules are to be derived. On the other hand, there are some (Levi, '12; Mislawsky '11, '13; Ciaccio, '13) who definitely reject the possibility that mitochondria participate, whether direct or indirect, in the formation of secretion granules, regarding the granular decomposition either as pathological (Ciaccio) or as an artificial process.

b. Nuclear origin. That the nucleus of the salivary and pancreatic glandular cell undergoes changes in shape, position, volume, and chromaticity during the stages of secretion was first noticed by R. Heidenhain ('68, '75, '80); in the resting condition of the cell, the nucleus exhibits a shrunken appearance, whereas during activity it is spherical and contains distinct nucleoli. Similar changes have been subsequently observed by various investigators (Schmidt, '82; Hermann, '88; Carlier, '96, M. Heidenhain, '90; Steinhaus, '90) and assumed by some to be due not to the mere accumulation and disappearance of secretion granules, but to an active process associated with the genesis of secretion, without definitely involving a decision as to its mode of participation.

Some investigators (Macallum, '91; Mathews, '99; Garnier, '00; Carlier, '99, '07; Maziariski, '10) are inclined to assign to the chromatin substance of the nucleus a part in the genesis of secretion, assuming that it passes into the cytoplasm either in a corpuscular or an amorphous state. That Garnier is of opinion that the basal filaments are impregnated by the chromatin substance passed out and that Mathews even regards the filaments as the chromatin itself, has been stated before.

Finally, the nucleolus must be taken into consideration. It was maintained by many investigators, as Ogata ('83), Platner ('89), Melissinos and Nicolaides ('90), Ver Eecke ('95), Laguesse ('99, '00), and others, that the accessory nuclei (*nebenkerne*, *plasmosomes*, *corps paranuclaires*) often found in the pancreatic cell are nothing other than the nucleoli passed out, and that

they take part in the formation of zymogen granules after undergoing certain changes in the cytoplasm. Galeotti ('95) believes that both nucleoli and fuchsinophile granules pass out of the nucleus in order to form secretion granules.

Observations. In the previous section we have found that fat-like corpuscles are formed by the disintegration of mitochondrial filaments; we see here again that zymogen granules are derived from the chondriocentes.

I have before pointed out that there is an area between the nucleus and the free end of the cell, which either appears clear in consequence of the absence of secretion granules or is distinctly marked off from the adjacent cytoplasm (figs. 39, 61, 75, 76, 78). Since the elaboration of zymogen granules takes place in this area, it can well be termed 'secretogenous area.' The process is as follows: the mitochondrial filaments or chondriocentes first converge to this area; some of them being passed into it (fig. 71). In other preparations there can be seen small granules, the diameter of which is as large as, or a little larger than, that of the chondriocentes (fig. 73). To see how they have been formed, we must take another preparation, in which there can be observed chondriocentes carrying spherical swellings (figs. 72, 77). These different pictures must be regarded as one and the same process going on in such a manner that the chondriocentes disintegrate into granules in this area. These small granules, for which it will be better to reserve the name 'prozymogen granules,' because of the fact that they give rise to zymogen granules, are at first few in number, but they become gradually augmented in consequence of the breaking down of chondriocentes entering the area in succession (fig. 73). It must be observed especially, in this connection, that the chondriocentes of the pancreas cell, except those which are located close to the cell basis and in the secretogenous area, can neither be seen carrying spherical swellings nor breaking down into granules; an observation upon which I lay considerable stress as differing from those investigators who believe in the breaking down of chondriocentes into granules everywhere in the cell-body.

It is necessary to say here a few words with regard to the fixing and staining characteristics of prozymogen granules. In mitochondria preparations, such as Altmann's, Benda's, and Meves', they cannot be brought to light. The most distinct pictures have only been obtained in preparations fixed in Müller-formalin and stained with iron-haematoxylin; they can also be exhibited, though not distinctly, by Zenker-formalin (without acetic acid) fixation and iron-haematoxylin staining (fig. 77). From these reactions it follows that prozymogen granules are preserved, in a satisfactory manner, by the prolonged action of potassium bichromate, and that they are destroyed by the presence of acetic acid, even in a very small amount, in the fixatives. This is a characteristic property of the granules in question, by virtue of which they can be distinguished from mitochondria and zymogen granules; and this might be also the chief reason why investigators who employed fixatives containing more or less acetic acid for exhibiting the mitochondria, did not notice the prozymogen granules within the secretogenous area.

The first-formed prozymogen granules are very small (fig. 73); they gradually increase in volume (figs. 74, 75, 76, 78), probably owing to their growth, but not to fusion with each other. With increase in volume, they undergo changes in their staining reactions, thus becoming gradually transformed into typical zymogen granules. The young zymogen granules thus formed can persist for some time within the secretogenous area (figs. 75, 76, 78); they sooner or later leave it, however, to pass into the surrounding plasma portion. Most of them pass upward and lateralwards; but there are some which proceed toward the nucleus (fig. 76). This indicates that there is no uniformity as to the size of zymogen granules with respect to their position; the occurrence of the larger ones near the nucleus thus being explained. If the passing out of the granules of the area is, for some reason or other, retarded, they will continue to increase in volume, so as often to lead to the formation of larger zymogen granules within the area (figs. 75, 78). From the above description, it is evident that there is a marked dif-

ference between the observations of some investigators (Regaud and Mawas, Hoven, O. Schultze), who believe in the derivation of zymogen granules from the mitochondria, and my own findings. They believe to have found the disintegration of the chondriocotes and the increase in volume of the granules thus formed up to the zymogen granules, in those preparations which are usually employed to exhibit the mitochondria, such as Benda's, Meves', etc. I have, however, never been able to follow such a direct transition between the two in the above preparations; but there are granules intermediate between the mitochondria and the definitive zymogen granules. These granules, prozymogen granules are, therefore, different in behavior to fixing and staining reagents from the two other constituents of the cell. Secondly, it seems from the descriptions and drawings of the above investigators that there is no locality of predilection for the disintegration of the chondriocotes; whereas, in my cases, the process takes place in the secretogenous area only.

So far as I have been able to ascertain, there was no noteworthy relation between the shape, structure, and chromaticity of the nucleus and the elaboration of secretion granules; in spite of the great accumulation of the latter, there could not be seen any considerable flattening of the nucleus, although it is often pressed down toward the basis of the cell. The mitochondrial filaments are usually more numerous in empty cells (fig. 55); this would seem to indicate that their passing out of the nucleus mainly takes place in such cells. In fact, the connection between the chondriocotes and the nuclear network can easily be seen in such empty cells; but it is not rare, that it can be found in cells heavily laden with secreting granules. These facts are in essential harmony with the findings above mentioned that the nucleus exhibits no visible changes in the structure and staining reactions according to the stages of secretion; in other words, the mitochondria are continually supplied from the nucleus as they are used up in the formation of zymogen granules.

4. *Extrusion.* Concerning the question as to whether zymogen granules are eliminated as such or after undergoing certain

changes, there is some difference of opinion. Some investigators (Mouret, '95, '05; Galeotti, '95) believe to have found zymogen granules in the lumen of alveoli and ducts, and conclude from this that the dissolution of at least a part of them is accomplished outside the cell-body. The opinion of Steinhaus ('90), Carlier ('96), Garnier ('00), and others is adverse to this; they maintaining that the granules are dissolved by the time of elimination; while Müller ('96, '98), and Babkin, Rubaschkin and Ssawitsch ('09) claim that the granules liquefy within the cytoplasm, forming the so-called 'secretion vacuoles'. Altmann ('94), on the other hand, considers that the liquefaction of zymogen granules takes place either within or outside the cell-body, according to the kinds of glands.

So far as can be seen from my preparations, there is no indication of the extrusion of granules as such; it seems, rather, that they are eliminated after undergoing certain changes, but without having formed vacuoles with liquid. In preparations treated according to Marchi and stained with iron-haematoxylin, in which the zymogen granules remain unstained, so that the upper half of the cell-body exhibits a reticular appearance, there can be discerned in close proximity to the lumen some granules or masses, which are irregular in shape and stained a grayish color, and which show a marked tendency to fuse together (fig. 84); they can never be found elsewhere. While in many preparations the contents of the lumen appear clear and homogeneous, in the Marchi preparation there can often be seen irregularly shaped masses, the staining reaction of which agrees with that of the masses present at the free end of the cell. Under favorable conditions, even the continuity of the two with each other can be discerned. From these observations, the inference would appear justifiable that zymogen granules, after having reached the distal end, undergo changes in physical and chemical properties and form by fusion the grayish staining masses above mentioned. These pass out of the cell through the pores into the lumen, a mode of secretion, which is in full accord with that found by me ('15) in the dorsal glandular cells of *Hynobius* larvae.

E. Intracellular net and canalicular apparatus

Historical. The existence of canaliculi or vacuoles in the glandular cell has often been noticed by various investigators. Laserstein ('94) describes clear paths in the granular zone of the pancreatic cell as canaliculi running through the cytoplasm. E. Müller's investigation ('98) of the gastric fundus gland has drawn attention to these structures. These cells contain, according to this author, a network of clear distinct bands which are connected with the intercellular secretion capillary, and which are nothing other than the secreting matter formed within the cell; he identified the network with a structure previously found by him by means of Golgi's method and named 'Korbkapillaren.' These observations have been confirmed by Zimmermann ('98). The latter describes the intracellular secretion capillaries as limited to the gastric fundus gland, the sweat gland, and the liver, in contradistinction to the view of Krause ('95), who had found canaliculi both in serous and mucous cells of the salivary gland.

The existence of a typical network in glandular and epithelial cells, on the other hand, has been recorded at some length by Negri ('00). He has demonstrated the network of the pancreas cell by means of Velatti's mixture and found it independent of the intercellular secretion capillaries impregnated at the same time. Similar networks or canaliculi have since been described by Holmgren ('02), Bergen ('04), Babkin, Rubaschkin and Ssawitsch ('09), Kolster ('13), Bensley ('11), and others in the pancreatic cells of various species.

Observations. So far as I have been able to determine, there can be made manifest, in the pancreatic cells of *Rana temporaria*, either networks consisting of solid cords or canaliculi, according to the technique employed. Although both pictures seem to belong to one and the same structure, as will be afterward explained, they are conveniently treated here separately.

1. Intracellular network. *a.* Technique. By 'intracellular network' we mean the apparatus which can be made manifest by various methods, such as Kopsch's, and Weigl's osmium method,

Sjövall's formalin-water-osmium method, Cajal's uranic nitrate-silver method, and Golgi's arsenic method. Of these I have obtained excellent results with Kopsch's, Weigl's, Sjövall's and Cajal's methods, whereas Golgi's method afforded no satisfactory results in spite of repeated trial. In addition, the network may occasionally be brought into view by the Flemming fixation and iron-haematoxylin staining. The network can also be exhibited, though in an ill-defined manner, in preparations fixed in Zenker's fluid and stained by iron-haematoxylin (figs. 80, 81).

b. Shape and position. The intracellular network (figs. 88 to 96) is situated above the nucleus; it is occasionally placed near the distal end of the cell rather than the nucleus, and spreads to a greater or less extent basalward along the sides of the nucleus. The area which is occupied by the network has all sorts of indefinite shapes and varies greatly in extent. The network itself consists of thick or thin cords which ramify and anastomose in various ways. Sometimes the net is not complete, so that long or short cords or fragments of the net are scattered through the granular zone. In spite of these varieties, there can be seen no intimate relation between the network and the nucleus; they are never in close apposition to, or in direct connection with, each other.

The network, as seen in a Kopsch preparation (fig. 88), is of compact character, the cords being relatively thick and those projecting into the surrounding plasma being usually short or often lacking. In the remainder of the cell, especially in the basal portion, there can be seen fine filaments or granules stained black and often attached to the network. I am unable to determine whether these structures are to be regarded as consisting of the same substance as the network or as mere precipitation of osmium.

In preparations made according to Weigl's (figs. 92 to 94), or especially Sjövall's (figs. 89 to 91) and Cajal's methods (figs. 95 to 98), the shape of the network, as a rule, is very irregular, extending over a polygonal or elongated area. The most striking picture obtained by these manipulations is that the network

emits shorter or longer prolongations which either consist of solid cords or still exhibit a reticular structure, and which can be traced through the granular zone to varying distances; even, under favorable conditions, as far as the distal (figs. 91, 93, 95, 96) or lateral margin of the cell (figs. 89, 94). These long prolongations, if present, are usually one to three in number, and, in either case, they can never be followed toward the cell basis. Further, in the Cajal preparation, spherical corpuscles stained the same color as the cords may often be seen suspended on the network (fig. 98). If such corpuscles are present in large numbers, the typical network is no longer visible, the cords of the net being represented by rows of granules or droplets, which are arranged in such a manner as to form an ill-defined network (fig. 97). The same corpuscles are also seen scattering sparsely through the granular zone, some of them being attached to the distal or lateral border of the cell (figs. 95, 97, 98); even sometimes lying in the lumen.

From the above observations it seems most probable that the substance constituting the network is being discharged either by means of projections or in such a way that the cords disintegrate into granules or droplets, both projections and droplets passing through the granular zone to reach the cell border. It is also probable that, of these projections and granules, those which are directed toward the distal margin must be extruded into the lumen, while those which proceed toward the lateral margin reach the intercellular canaliculi. In fact, the lumen and especially the intercellular canaliculi are often found filled with substance which shows the same staining reaction, the droplets or projections in the cell-body being in direct continuity with the mass outside the cell (fig. 98). As these pictures are by no means artifacts, nor can be interpreted as representing the passage of a substance from the outside into the cell, it is, I think, impossible to avoid the conclusion that the network is composed of a secreting material which is formed within the cell and which is to be discharged into the lumen or into the intercellular canaliculi.

No mutual relation could be found between the extent of the network and the amount of zymogen granules. There are cases in which the former is well developed, while the latter are few in number, and vice versa. The zymogen granules are, in general, not found in large numbers between the meshes of the intracellular network.

A similar network to that described above can be made manifest by Flemming fixation and iron-haematoxylin staining (figs. 100 to 105). It can scarcely be said that this method is adapted to any animal, for the conditions under which the network is fixed by Flemming's fluid seem to depend either upon the nutritive state of the animal, or the functional activity of the cell, or some other unknown causes. I could demonstrate it by means of the above method in sections of the pancreas taken from an animal captured in the month of September. The structure is located above the nucleus and consists of thick or thin tortuous cords which form a network by interlacement and anastomosis with each other. The cords are stained black by iron-haematoxylin, and are, in most cases, solid, but sometimes canalized to a greater or less extent; the canaliculus is bordered by two black lines, which are the optical section of its wall. Just as has been observed in other preparations, the network also emits longer or shorter cords or canaliculi which pass through the granular zone; the longer ones often extending to the cell border. It can further be seen that the darkly staining granules or droplets are either suspended on the cords or canaliculi, or scattered through the granular zone, or even attached to the distal or the lateral margin of the cell (figs. 101 to 104). These pictures are in full accord with those obtained by means of the methods of Kopsch, Weigl, Sjövall, and Cajal, with the sole difference that, in the Flemming preparation, the cords are often canalized, which is to be regarded as due to the dissolution of their substance, rather than to the real existence of canaliculi.

It must be noticed in this connection that the granules or droplets seen in Cajal and Flemming preparations are perfectly distinct from those in Marchi preparations, although

they bear striking resemblance in shape to each other. The granules or clumps which are produced by the alteration of zymogen granules appear invariably at the distal border of the cell, close to the lumen, while those derived from the intracellular network seem to be extruded into the lumen as well as into the intercellular capillary.

2. Canaliculi. In preparations fixed in Müller-formalin, bichromate-formalin, Regaud's fluid, etc., and stained with iron- or alum-haematoxylin, the cytoplasm takes on a more or less dark color, while certain nets or canaliculi remain totally unstained. All these structures are not the same thing, but they are grouped into two classes.

a. I have described in the previous section that there is a relatively well-defined area between the nucleus and the distal cell border, and that the zymogen granules are being elaborated in this area: 'secretogenous area.' On examining this area carefully in the above preparations, especially in those cells which contain a small number of zymogen granules, we find that there are present canaliculi with clear lumen, which intertwine or anastomose with one another so as to form a sort of network from which similar canaliculi project into the surrounding cytoplasm (figs. 75, 82, 83). The meshes of the network are, in most cases, occupied by small granules, which are nothing other than prozymogen granules or zymogen granules in the earlier stages of development; in other words, the formation of the zymogen granules is taking place in the meshes of the canalicular network.

I am of opinion that the canalicular network is to be identified with the intracellular network in the sense of Golgi; the former merely being the negative of the latter, as already shown by Bergen ('04), Bensley ('11), and others. The substance which constitutes the intracellular network cannot be made manifest by the fixing and staining methods above mentioned, while the surrounding cytoplasm is stained to a more or less extent. A possible transition between the canalicular and Golgi's network is brought to light by Flemming fixation and iron-haematoxylin staining, and is formed partly of solid, partly of canalized

cords. In conclusion, it must be noticed that the three states of cords, that is to say, one, solid, and the two others canalicular with or without the wall, are probably produced according as they are perfectly preserved or are partly or entirely dissolved out.

b. There can be seen another system of canaliculi in the pancreas cell, which seems to be different both morphologically and topographically from those above mentioned. They are tortuous, fine, clear canaliculi which ascend vertically along the sides of the nucleus and lose themselves in the granular zone or in the secretogenous area (fig. 83). These canaliculi are, to my mind, to be regarded as the negative of the mitochondrial filaments, which, in the preparations we are dealing with here, remain unstained, while the cytoplasm takes on a more or less dark color.

3. Significance and genesis of the intracellular net apparatus. It has been assumed that there are in the pancreas cell two kinds of canalicular systems, one of which is located above the nucleus and is to be identified with Golgi's intracellular network. The question as to whether the intracellular network or canalicular apparatus communicates with the exterior or not has been answered in the affirmative, in contradistinction with the view of Negri ('00), Bergen ('04), and Bensley ('11). We have also been led to the conclusion that the intracellular network consists of secreting material which is to be extruded either directly into the lumen or indirectly into the intercellular capillary. The connection which may exist between the network and the intercellular capillary is expected from the other side of observation. As has already been noticed by Langerhans ('69), Laserstein ('94), and others, the intercellular capillary of the pancreas is a canaliculus which passes between the cells downward and terminates with the blind end before reaching the basal membrane. This is made evident in an injection preparation, in which we see that the injected intercellular canaliculus carries on its surface spinous or club-shaped projections, although the intracellular network cannot be injected from the duct (fig. 99). But the existence of these projections would indicate that the

injection mass is passed into the spaces within the cell. The latter, in part at least, correspond to the granules or droplets lying at the lateral cell margin and connected with the intercellular capillary, as seen in the Cajal and Flemming preparation (figs. 97, 98, 101 to 104). That the button-like secretion vacuoles communicate with the intercellular canaliculi was noticed by Kupffer, as early as 1873, in an injection preparation of the liver; Retzius ('92), using the Golgi method, found, in salivary glands, drop-like appendages on the intercellular canaliculus, which must be, according to him, the same thing as Kupffer's secretion vacuoles. In the pancreas, similar vacuoles were also described by Müller ('98) as lying near the lumen or the intercellular canaliculi. Furthermore, it must be taken into consideration that the attachment of the projections or droplets derived from the network to the lateral cell margin is limited to the upper half or two-thirds of the height of the cell, where the intercellular canaliculus will just be found. This also strongly suggests that the two are in close relation to each other.

From the preceding observations and considerations, I have been led to the conclusion that the substance composing the intracellular network is formed in some way within the cell-body and is to be eliminated from the cell. This view is strikingly at variance with that of Holmgren ('02), who claims that the intracellular network or his 'trophospongium' in the pancreatic cell, just as in other kinds of cells, especially in the nerve cell, is of exogenous origin. In spite of a more careful study, I have never been able to find out the connection between the cords of the network and the basket- or centroacinal cells, as has been described and figured by this author.

Now arises the question as to the genesis of the intracellular network. It is exceedingly difficult to determine whether the network is perfectly impregnated or not. The examination of those cells which contain no zymogen granules or only a small number of them showed that the network is well developed in some cells, while in others it is totally lacking; there being intermediate conditions between these two extremes. In the

cells destitute of the network, there can be seen minute granules or fine filaments scattered through the cytoplasm. In other cells small clumps or rods are present above the nucleus (fig. 85). Examination of still other cells shows that there are all grades of transition between these clumps or rods and the typical network (figs. 86, 87), which is formed by an anastomosis or a fusion of the former. Whether these gradations are to be regarded as developmental stages of the network or as a retrogression is a question which is difficult to answer. At any rate, it is worthy of remark that the network is fixed in a definite position above the nucleus which exactly corresponds to the secretogenous area. We have also noticed that the prozymogen granules occupy the meshes of the network; in other words, the secretogenous area is traversed by the intracellular network. It can further be seen in the preparations that the extent of the secretogenous area, which varies according as the prozymogen granules are increased or decreased, is in keeping with that of the network. Under these circumstances, it seems probable that the genesis of the zymogen granules and that of the network must be in some way correlated with each other. How this is accomplished, must for the present remain an open question. It is conceivable, however, that the formation and growth of prozymogen granules accompany an import and export of substances, and that the substance given off deposits in the secretogenous area and flows together, so as to form a network.

However this may be, it is quite certain that the secretion process of the pancreatic cell is carried on in two ways: one which is marked by the formation of granules and the other in which the secreting material is deposited as unformed masses from the beginning. In the former process the granules, from the first formed prozymogen up to the mature zymogen granules, preserve their individuality; they take up substances and perhaps give them off, too. During growth, they gradually change their properties and finally lose their individuality, fusing together in order to form the secreting mass. The other process of secretion, on the contrary, is characterized by the formation of secretion material which is to be eliminated without undergoing

any remarkable change in character, and which must be, from its behavior in the secretion process, regarded as a fluid mass. Secreting matter of this kind, in all probability, forms the greater part of the pancreas fluid and serves as a vehicle for dissolving the more viscous mass derived from the zymogen granules. Altmann's theory, that 'die Sekretion ist ein granulärer Process,' cannot be applied as such to this case; the secretion process at least of the pancreas is both granular and fluid; the specific ferments are perhaps furnished from the zymogen granules, although the substance of the intracellular network cannot be looked upon as consisting of waste matters only.

4. PHYSIOLOGICAL DEGENERATION

The secretory cells, as is the case with other kinds of cells, undergo degeneration under some unknown physiological conditions. The changes found in this process occurring in the pancreas are in full accord with those which I have observed in the epidermal glandular cells of amphibian larvae and described in the previous paper ('15), to which the reader is referred for details. The following is only a brief account of the process. The first changes consist in the chromatic and nucleolar hyperchromasy, followed by chromatic separation. The latter process is characterized by a flowing together of chromatic corpuscles, which leads to the formation of more or less large granules or thick cords (figs. 110, 111). These further fuse together or anastomose with one another so that at last a network or even a capsule is formed at the periphery of the nucleus (fig. 112), a state which is designated by pathologists as 'hyperchromasy of the nuclear wall.' The area surrounded by the above capsule is filled with nuclear sap and contains a somewhat enlarged nucleolus. At successive periods, the nucleolar hyperchromasy of the nuclear sap gradually diminishes. Meanwhile the cell-body decreases in volume in consequence of repeated fragmentation. This process is either limited to the cytoplasm or continues so that the division of the nucleus is followed by that of the cell-body (fig. 113). The fragments thus formed are

usually spherical in shape, but vary much in size, and especially in structure. Some are without nuclear fragments but full of zymogen granules; others contain one or more small chromatic corpuscles; in still other cases the nuclear portion, as compared with the plasma portion, is so large that the fragment is almost entirely filled up with it, an appearance of a free nuclear fragment being thus produced. These fragmented corpuscles are, sooner or later, taken up by neighboring normal glandular cells. This occurs either simultaneously with the process of fragmentation in such a way that the fragment presses against the neighboring cell so as to lead to the formation of a cavity which, being more and more deepened, finally encloses the fragment (fig. 113), or the fragments formed persist for some time in the intercellular space, causing depressions upon the adjacent cells. The ultimate fate of these corpuscles is the same as in the former case; that is to say, they are all embraced by the surrounding plasma of the normal glandular cells and finally taken up by them (figs. 114, 118). There is no constancy in the position in the cell nor in the size of fragments thus taken up; if they are large, the nucleus is often distorted by their pressure. The fragments gradually diminish in volume, partly by repeated fragmentation, accompanied by simultaneous changes in structure. The nuclear fragments come to stain more and more faintly with chromatin dyes (figs. 115 to 117), or their substance diffuses through the plasma portion, while the zymogen granules seems to fuse together. Thus, corpuscles of various sizes and structures are formed, which vary not only in individual cases, but also according to the stages of degeneration, so that no definite light can be thrown from merely morphological study upon the significance of the corpuscles. They seem to be digested and absorbed by the surrounding cytoplasm, finally leaving there clear vacuoles, which gradually decrease in volume and disappear.

The mitochondrial filaments in degenerating cells appear at first to be increased in number. In successive periods they thicken and gradually become faintly tinged (fig. 112), and at last disintegrate into granules, while the intracellular network is

broken down into irregular clumps or granules and disappears (figs. 119, 120).

From these observations and those which I have made in the study of the epidermal glandular cells of Amphibia, the conclusion is warranted that the physiological degeneration of these cells is characterized by nuclear and nucleolar hyperchromasy and by chromatic separation, succeeded by the constriction of the nucleus and the cell-body; and, secondly, that the formed fragments are invariably taken up by the neighboring normal glandular cells, but are never eliminated into the lumen nor, which appears very strange, absorbed by the phagocytes.

That the pancreatic cell undergoes physiological degeneration, has already been noticed by Gaule ('80) and Nussbaum ('82); Platner ('89), however, was the first to describe the nuclear changes brought about by that process. The author has found pictures corresponding to one which is designated by Flemming as 'chromatolysis' in the pancreas of various species. In consequence of the chromatolysis, there are produced smaller or larger spherical corpuscles, which at first stain with safranin a red color, but later refuse to take the stain. The structures are delineated in his figures 11 to 13. Of these, the large corpuscle in the cell *a*, figure 12, corresponds to a nucleus which has already undergone chromatic separation, while those seen in the cells, figure 12, *b*, figures 11 and 13 cannot be interpreted as anything else than fragments constricted off. In addition to these, Platner found such corpuscles in the normal cell with an intact nucleus, and assumed that they are produced by the partial chromatolysis of the nucleus. In my opinion, these corpuscles are in all probability fragments taken up by the normal cell, as is clear from a comparison of his figures 11 to 13 and those of my own (figs. 114, 118). Furthermore, he does not express himself regarding the process of his partial chromatolysis. Melissinos and Nicolaides ('90), Macallum ('91), and Garnier ('00) also describe the occurrence of karyolysis in the pancreas. According to Macallum, the product of karyolysis and cytolysis consists partly of protoplasm, partly of eosinophile substance;

the chromatic substance being limited to crescent-shaped or annular corpuscles, which are situated upon or in the protoplasmic substratum of the body. Those structures, which are described under the name of 'nebenkern' by various investigators, Ogata, Eberth and Müller, and others, belong, in part at least, to this category. I will return to this question further on.

5. MITOSIS

Since the pancreatic cells undergo physiological degeneration, it is a matter of course that they must be supplemented in some way; this is effected by mitosis, which varies more or less according to individual cases. The nucleus preparing to divide by mitosis migrates upward and comes to lie about midway between the base and the distal end of the cell (fig. 106); the cytoplasm becomes stained more or less pale, the position and arrangement of zymogen granules and mitochondrial filaments differing in no way from those of resting cells (figs. 106, 107). The plane of cleavage being vertical (fig. 108), the daughter cells acquire both zymogen granules and chondriocentes (fig. 109). I have never been able to observe that the latter are increased in number by division or that an equal amount of them passes into each of the daughter cells, as assumed by some. Sometimes there are seen glandular cells with two nuclei; whether they are produced by mitosis or amitosis I was unable definitely to determine.

The mitotic figures were observed, in the pancreas, by Gaule ('80), Nussbaum ('82), and by many of the subsequent investigators (Bizzozero and Vassale, '87, Platner, '89, Steinhaus, '90). Podwyssozki ('87) believes to have found mitosis in young animals, while Eberth and Müller ('92) deny its occurrence in any case. The most curious view concerning the regeneration of the pancreatic cell is advanced by Ogata ('83). This author believes that the plasmosome of the nucleus passes out into the cytoplasm and there forms the so-called 'nebenkern,' which is transformed through gradual increase into a new cell, while the old one undergoes degeneration. The result of this process

is not, therefore, the production of two cells from one, but the formation of a new cell from an old one, which process he has designated 'renewal of the cells.' Such a mode of cell genesis can no longer be assumed in the present state of our knowledge regarding cell multiplication, just as it is little probable that the 'nebenkerne,' are passed out nucleoli. A comparison of his figures with those of my own shows that his 'nebenkerne' are nothing other than the products of degeneration and that what he mentions as stages of renewal of the cell is but a reversal of the process of degeneration.

6. THE SO-CALLED 'NEBENKERNE'

Historical

a. Shape. Nussbaum ('81, '82) and Gaule ('81), nearly about the same time, but independently of each other, have found certain structures in the pancreatic and other kinds of secretory cells, and have given the name 'nebenkerne' to them. According to the former author, the structures are either solitary or multiple, solid oval or spirally coiled, even curly twisted. A few days after feeding they are found in every cell, while they are rarely met with in the fasting condition. Their biological significance remained unsolved, although the author brought them into the same category as the 'yolk-nucleus' of the egg-cell found by Wittich, as the 'nebenkern' of the spermatocyte discovered by La Valette St. George, and finally as the structures noticed by Leydig in the epidermal cells of *Pelobates* larvae. The same or similar structures have since often attracted attention of those investigators who have made a study of the pancreas of the higher and lower vertebrates. And a review of the literature shows that what is described and figured under the name of 'nebenkern,' 'paranucleus,' etc., is not necessarily concerned with one and the same structure, but can be classed into at least two types, as already done by Eberth and Müller ('92).

The first type includes those corpuscles which are irregular in shape, and have generally a fibrillar structure. They are

either filamentous or spindle-shaped, crescent- or comma-formed or even spherical. In some cases the structures have been described as being homogeneous. This type is described and figured by Nussbaum ('82), Steinhaus ('90), Macallum ('91), Eberth and Müller ('92), Ver Eecke ('95), Mouret ('95, '05), Carlier ('96), Mathews ('99), Champy ('11), and others.

To the second type belong those corpuscles which are spherical in shape and of various sizes. They are either homogeneous or granular, or contain spherical or crescent-shaped bodies. This type is found by Nussbaum ('82), Ogata ('83), Platner ('89), Melissinos and Nicolaides ('90), Macallum ('91), Eberth and Müller ('92), Ver Eecke ('95), Galeotti ('95), Mouret ('95, '05), Mathews ('99), Garnier ('00), Babkin, Rubaschkin and Ssawitsch ('09), and others.

b. Origin. Various views advanced concerning the origin of the 'nebenkern' can be summarized as follows:

Nuclear origin. Ogata, Galeotti, and Platner believe that the 'nebenkern' is derived from the plasmosome passed out of the nucleus; Macallum, Ver Eecke, Melissinos and Nicolaides, and Garnier maintain a nuclear origin for a part of the structures, while another part is regarded as made up of products of chromatolysis.

Plasmic origin. Mouret identifies the 'nebenkern' with the matrix of the cell or his 'prézymogenes;' Carlier also describes the accessory nucleus as indistinguishable from the neighboring dense granular spongioplasm. Eberth and Müller, Mathews, Melissinos and Nicolaides, and Garnier ascribe to a part of the 'nebenkerne' a plasmic origin; according to Eberth and Müller, they are produced by the adhesion of protoplasmic filaments; Mathews likewise holds that they are nothing other than coiled or contorted cell-threads. However, the question, how they are formed, remains unanswered. In addition, Champy identifies the 'nebenkern' with the sphere of the egg-cell, and claims to have found central corpuscles in its centre. Babkin, Rubaschkin and Ssawitsch, finally, advance the view that the 'nebenkern' is derived from zymogen granules. In their experimental study, they believe to have found that a plasmic portion

along with some of the zymogen granules becomes sharply limited from the surrounding plasma, and forms a mass which comes to lie in a vacuole. This corpuscle gradually changes its staining reactions and finally is cast off into the lumen.

Exogenous structures. The accessory nuclei, in part at least, have been regarded either as parasites (Steinhaus, Mathews, Macallum) or as leucocytes passed into the cell (Melissinos and Nicolaides).

c. Significance. There is also much diversity of opinion with regard to the significance and the final fate of the 'nebenkern.'

Ogata, Platner, Laguesse ('99), Ver Eecke, Galeotti, Mouret, Mathews, Garnier, Babkin, Rubaschkin and Ssawitsch, and many others believe that the 'nebenkern' disintegrates into zymogen granules, while Eberth and Müller believe in its indirect participation in the elaboration of secretion granules. On the other hand, Steinhaus and Macallum deny such a participation, whether direct or indirect.

A few investigators advance the very curious view that the 'nebenkern' is a plasmosome (nucleolus) passed out of the nucleus which becomes converted into a new nucleus (Ver Eecke), even into a new cell (Ogata).

Nussbaum, and Melissinos and Nicolaides reached no definite conclusion as regards the significance of the 'nebenkern.'

Critical

In looking over the literature, one is confronted with an appalling mass of conflicting observations. The corpuscles which are described under the name of 'nebenkern' show much variation not only as regards shape and structure, but also in origin and significance. These variations would indicate that the so-called 'nebenkern' either includes things which vary in origin, or, if of the same origin, must be a body which exhibits an extraordinary diversity of shape and structure. Under these circumstances, the inference would appear justifiable that the 'nebenkerne' cannot be integral constituents of the pancreatic cell, but must be considered products either of artificial or of physio-

logical or pathological changes. I am of the opinion that they must be derived from two sources totally differing in character.

a. We have seen in the section on 'structure of the cytoplasm' that the protofibrillae which may be regarded as preëxistent in the cytoplasm, adhere to one another in consequence either of the action of fixatives or of the subsequent manipulation, so that there are formed various structures according to the degrees of adhesion, such as thin or thick bundles, crescent- or shell-formed, spirally coiled, or even irregular spherical corpuscles. They are characterized, first, by fibrillar structure. It often happens, however, that they appear homogeneous, when relatively well preserved or examined with a lower magnifying power. Secondly, they vary greatly in shape. Finally, the contour of these corpuscles is very irregular, as if it had been gnawed, or fibers arise from them and continuously pass into the cytoplasmic filaments.

It will be seen when my figures are compared with those of various investigators above mentioned, that these artificial products agree in character with those 'nebenkerne' which are described as being of irregular shape or as exhibiting fibrillar structure. Of the views advanced concerning the origin and significance, that of Eberth and Müller and of Mathews is nearly in agreement with that of my own. The former workers say: "sie sind umgewandelte Protoplasmafäden, welche, indem sie mit ihren Nachbarn verschmelzen, zu spindelförmigen, sichelförmigen, kommaähnlichen Körpern werden, die vielleicht vorübergehend, vielleicht dauernd ihre fibrilläre Zusammensetzung noch mehr oder weniger bewahren oder dieselbe ganz verlieren und dann glänzende homogene Körper darstellen." Mathews also is of opinion that the structures in question are derived from the cell-threads; he says: "The threads are not, however, perfectly straight, but in all cases are more or less twisted and bent . . . and often contorted or even spirally coiled on themselves. These spiral twists, or coils, form the so-called 'Nebenkern' of the pancreas." How these corpuscles are formed, that is to say, the question whether they are produced under physiological conditions or by the action of fixatives, remains unanswered.

As already mentioned, these fibrillar structures when preserved in alcohol, sublimate mixtures, etc., stain with alum-haematoxylin a blue color, as is the case with the chromatin. From this staining reaction alone, however, it cannot be inferred that they are derived from the nucleus, as assumed by some; for, if the stains, such as safranin, iron-haematoxylin, etc., are employed, they are easily decolorized, whereas the chromatin is heavily stained.

b. I have before mentioned that the physiological degeneration of the cell is characterized by chromatic separation followed by constriction of the nucleus and the cell-body, and that the spherical fragments produced by the latter process and taken up by the neighboring glandular cells exhibit every variety of structure. The nuclear portion in the fragment, when it exists, is variable, and is either spherical or crescentic, or ring-formed according to its size and the phase of the nuclear change; while the cytoplasmic portion, small or large in amount, either contains unaltered zymogen granules or may be entirely devoid of them. There are also many corpuscles which contain no nuclear fragments.

These corpuscles are to be identified with those 'nebenkerne' which I have before summarized under the second type. The 'nebenkerne' which belong to the second type are spherical in shape and have an even contour; they are surrounded with a clear halo; in other words, they lie in vacuoles of the cytoplasm. This fact shows that these corpuscles are not closely related to the cytoplasm containing them; it is therefore not without reason that they have been supposed by some to be parasites passed into the cell. That these 'nebenkerne' cannot be interpreted as anything else than corpuscles produced by the fragmentation of the degenerated cell will be evidenced by considering their structure. In the following I will try to criticise the observations of various investigators, comparing the various types of 'nebenkerne' with our fragments.

First, in figures 4, *a*, *d*, *e*, and 5, *a*, accompanying Ogata's paper, it can clearly be seen that these corpuscles are nothing other than nuclei, which have already suffered chromatic

separation, so that the condensed chromatin is accumulated in the periphery while the nuclear sap and the nucleolus are enclosed by this chromatic capsule. On the other hand, Platner's figure 12 and Ogata's figure 7, *a*, correspond to the glandular cells containing these changed nuclei. Ogata's figure 7, *a*, especially shows an elongated cell, which perhaps will be fragmented in the next stage.

Secondly, Ogata's figure 5, *b, c, d*, Platner's figures 11 and 13, Melissinos and Nicolaides' figures 9 to 15, Eberth and Müller's figure 16, Ver Eecke's figures 17 to 24, and Babkin, Rubaschkin and Ssawitsch's figure 10 (the cell to the left) show cells which contain spherical bodies with either ring- or crescent-shaped, larger or smaller spherical chromatic corpuscles; these bodies are to be regarded as constricted off fragments of degenerated cells, which have been taken up by the normal glandular cells; the chromatic corpuscles correspond to nuclear fragments. On the other hand, there can be seen in Ogata's figure 6, *b*, and in Babkin, Rubaschkin and Ssawitsch's figure 10 (the cell to the right), seventeen bodies which contain no chromatic corpuscles, and which are, in all probability, cytoplasmic fragments with or without zymogen granules.

Finally, Ogata's figure 3, *a, b*, Galeotti's figures 28 and 29, Garnier's figures 34 and 35, etc., show that spherical, ring or crescent-shaped chromatic corpuscles are contained in the normal glandular cells; they are regarded by these authors as nucleoli passed out of the nucleus. In my opinion, they are nuclear fragments with a very small amount of the cytoplasmic portion, which have been reduced in size by repeated fragmentation. These chromatic corpuscles gradually grow pale and then stain only with plasma dyes. Under these circumstances, it is a difficult matter to decide whether the spherical corpuscles stained by plasma dyes are derived from the fragments with or without nuclear portions.

It is evident from the above comparison that the spherical corpuscles which have been regarded as belonging to the so-called 'nebenkern' are the same as the fragments produced by the fragmentation of the degenerated glandular cell. That the sig-

nificance of these corpuscles remains as yet undecided, in spite of the fact that they have attracted much attention of those investigators who were engaged in the study of the pancreas, is due essentially to the fact that their genesis was not fully followed out. In fact, there are some who regard the 'nebenkerne,' which are spherical in shape and marked off sharply from the surrounding cytoplasm in which they are embedded, as products of the chromatolysis (Melissinos and Nicolaides, Macallum, and Garnier). Nevertheless, these investigators have failed to throw light upon the process of their formation. The fact that these corpuscles are found beside the nucleus within the normal cell tends to contradict the view that they are products of the chromatolysis. This is perhaps the reason why Platner has taken them to be produced by the partial degeneration of the nucleus, and has named the process 'partial chromatolysis.'

Kanazawa, Japan, June 15, 1918.

BIBLIOGRAPHY

- ALEXEIEFF, A. 1917 Mitochondries et rôle morphologique du noyau. *Compt. rend. Soc. biol.*, T. 80.
- ALTMANN, R. 1894 Die Elementarorganismen und ihre Beziehung zu den Zellen. 2. Auflage, Leipzig.
- ARNOLD, G. 1912 The rôle of chondriosome in the cells of the guinea-pig's pancreas. *Arch. f. Zellforschung*, Bd. 8.
- BABKIN, B. P., RUBASCHKIN, W. J., UND SSAWITSCH, W. W. 1909 Über die morphologischen Veränderungen der Pankreaszellen unter der Einwirkung verschiedenartiger Reize. *Arch. f. mikr. Anat.*, Bd. 74.
- BENSLEY, R. R. 1911 Studies on the pancreas of the guinea-pig. *Am. Jour. Anat.*, vol. 12.
- BERGEN, F. v. 1904 Zur Kenntnis gewisser Strukturbilder (Netzapparate, Saftkanälchen, Trophospongium) im Protoplasma verschiedener Zellenarten. *Arch. f. mikr. Anat.*, Bd. 64.
- BIZZOZERO, G., ET VASSALE, G. 1887 Sur le tissu des glandes excrétautes. *Arch. ital. de biol.*, T. 9.
- BOBEAU, G. 1911 Mitochondries et lipoides dans les glandules parathyroides du cheval. *Compt. rend. Assoc. Anat.*, 13 Réunion, Paris.
- BOUIN, P. 1905 Ergastoplasme et mitochondria dans les cellules glandulaires sereuses. *Compt. rend. Soc. biol.*, T. 59.
- CAJAL, S. RAMÓN 1909-11 Histologie du système nerveux de l'Homme et des vertébrés. Paris.
- CARLIER, E. W. 1896 On the pancreas of the hedgehog during hibernation. *Journ. of Anat.*, vol. 30, 1899 Changes that occur in some cells of the newt's stomach during digestion. A cell study. *La cellule*, T. 16 (quoted from Maziarski, '10).
1907 De certains changements qui peuvent être observé dans les cellules du foie pendant la digestion et de leurs relations avec la sécrétion hépatique. *Compt. rend. Assoc. Anat.*, IX. Réunion, Lille (quoted from Maziarski, '10).
- CHAMPY, C. 1911 Recherches sur l'absorption intestinale et le rôle des mitochondries dans l'absorption et la sécrétion. *Arch. d'anat. micr.*, T. 12.
- CIACCIO, C. 1913 Zur Physiopathologie der Zelle. I. Entartungsbilder der Plastosomen. *Centralb. f. allgem. Pathol. u. path. Anat.*, Bd. 24.
- COMES, S. 1913 Apparato reticolare o condrioma? Condriocinesi o dittocinesi? *Anat. Anz.*, Bd. 43.
- COWDRY, E. V. 1916 The general functional significance of mitochondria. *Am. Jour. Anat.*, vol. 19.
- DUESBERG, J. 1908 Sur l'existence de mitochondries dans l'oeuf et l'embryon d'Apis mellifica. *Anat. Anz.*, Bd. 32.
1911 Les chondriosomes des cellules embryonnaires du poulet, et leur rôle dans la genèse des myofibrilles, avec quelques observations sur le développement des fibres musculaires striés. *Arch. f. Zellforsch.*, Bd. 4.

- EBERTH, C. J., UND MÜLLER, K. 1892 Untersuchungen über das Pankreas. Zeitsch. f. wiss. Zool., Bd. 53, Supplement.
- FLEMMING, W. 1882 Zellsubstanz, Kern- und Zelltheilung. Leipzig.
- GALEOTTI, G. 1895 Über die Granulationen in den Zellen. Internat. Monatsch. f. Anat. u. Physiol., Bd. 12.
- GARNIER, C. 1900 Contribution à l'étude de la structure et du fonctionnement des cellules glandulaires séreuses. Du rôle de l'ergastoplasme dans la sécrétion. Journ. de l'Anat. et de la Physiol., 36 année.
- GAULE, J. 1880 Kerntheilungen im Pankreas des Hundes. Arch. f. Anat. u. Physiol., Physiol. Abth.
1881 Die Beziehungen der Cytozoen (Würmchen) zu den Zellkernen. Arch. f. Anat. u. Physiol., Physiol. Abth.
1881 Kerne, Nebenkerne und Cytozoen, Centralb. f. med. Wiss., Nr. 31.
- GOLDSCHMIDT, R. 1904 Der Chromidialapparat lebhaft funktionierender Gewebszellen. Zool. Jahrb., Bd. 21.
- HAECKER, V. 1893 Das Keimbläschen, seine Elemente und Lageveränderung. Arch. f. mikr. Anat., Bd. 41 and 42.
1895 Die Vorstadien der Eireifung. Zusammenfassende Untersuchungen über die Bildung der Vierergruppen und das Verhalten der Keimbläschen-Nucleolen. Arch. f. mikr. Anat., Bd. 45.
- HEIDENHAIN, R. 1868 Beiträge zur Lehre von der Speichelabsonderung, Studien d. physiol. Instit., Breslau (quoted from Maziarski, '10).
1875 Beiträge zur Kenntniss des Pankreas. Arch. f. ges. Physiol., Bd. 10.
1880 Physiologie der Absonderungsvorgänge. Handbuch der Physiologie von L. Hermann, Bd. 5.
- HEIDENHAIN, M. 1890 Beiträge zur Kenntniss der Topographie und Histologie der Cloake und ihrer drüsigen Adnexa bei den einheimischen Tritonen. Arch. f. mikr. Anat., Bd. 35.
1907 Plasma und Zelle. Jena.
- HERMANN, F. 1888 Über regressive Metamorphosen des Zellkernes. Anat. Anz., Bd. 3.
- HOLMGREN, E. 1902 Weiteres über das 'Trophospongium' der Nervenzellen und der Drüsenzellen des Salamander-Pankreas. Arch. f. mikr. Anat., Bd. 60.
- HOVEN, H. 1910 and 1912 Contribution à l'étude du fonctionnement des cellules glandulaires. Du rôle du chondriome dans la sécrétion. Anat. Anz., Bd. 37 (Communication préliminaire) and Arch. f. Zellforsch., Bd. 8.
- JORDAN, H. E. 1912 Notes on the Spermatogenesis of the Bat. Anat. Anz., Bd. 40.
- KOLSTER, R. 1913 Über die durch Golgi's Arsenik- und Cajal's Urannitrat-silbermethode dargestellten Zellstrukturen. Verh. d. anat. Gesch.
- KORSCHULT, E. 1889 Beiträge zur Morphologie und Physiologie des Zellkernes. Zool. Jahrb. Abt. f. Anat., Bd. 4.
- KRAUSE, R. 1895 Zur Histologie der Speicheldrüsen. Die Speicheldrüsen des Igels. Arch. f. mikr. Anat., Bd. 45.

- LACHE, J. G. 1906 L'aspect du noyau de la cellule nerveuse dans la méthode à l'argent réduit. *Anat. Anz.*, Bd. 28.
- LAGUESSE, E. 1899 Corpuscles paranucléaires (parasomes), filaments basaux, et zymogène dans les cellules sécrétantes (pancréas, sous-maxillaire). *Compt. rend. Soc. biol.*, volume jubilaire.
1900 Sur les variations de la graisse dans les cellules sécrétantes séreuses (pancréas). *Compt. rend. Soc. biol.*, T. 52.
- LAMS, H. 1906 Le corps vitellin de Balbiani et la masse vitellogène dans l'oocyte de *Rana temporaria*. *Verh. d. anat. Gesch.*
- LANGERHANS, P. 1869 Beiträge zur mikroskopischen Anatomie der Bauchspeicheldrüsen. Inaug.-Diss. Berlin (quoted from Laserstein).
- LANGLEY, J. N. 1884 On the structure of secretory cells and on the changes which take place in them during secretion. *Internat. Monatschr. f. Anat. u. Physiol.*, Bd. 1.
- LASERSTEIN, S. Über die Anfänge der Absonderungswege in den Speicheldrüsen und im Pankreas. *Arch. f. ges. Physiol.*, Bd. 55.
- LEVI, G. 1912 I condriosomi nelle cellule secernenti. *Anat. Anz.*, Bd. 42.
- MACALLUM, A. B. 1891 Contributions to the morphology and physiology of the cell. *Transact. of the Canadian Institute*, vol. 1 (quoted from Mathews and Eberth and Müller.)
- MATHEWS, A. 1899 The changes in structure of the pancreas cells. A consideration of some aspects of cell metabolism. *Jour. Morph.*, vol. 15, supplement.
- MAXIMOW, A. 1916 Sur la structure des chondriosomes. *Compt. rend. Soc. biol.*, T. 79.
- MAYER, A., RATHERY, F., ET SCHAEFFER, G. 1914 Sur les variations expérimentales du chondriome hépatique. Parallélisme entre la composition chimique du tissu et ses aspects cytologiques. *Compt. rend. Soc. biol.*, T. 76.
- MAZIARSKI, S. 1910 Sur les changements morphologiques de la structure nucléaire dans les cellules glandulaires. Contribution à l'étude du noyau cellulaire. *Arch. f. Zellforsch.*, Bd. 4.
- MEIROWSKY, E. 1908 Über den Ursprung des melanotischen Pigments der Haut und des Auges. Leipzig.
- MELISSINOS, C., UND NICOLAIDES, R. 1890 Untersuchungen über einige intra- und extranucleare Gebilde im Pankreas der Säugetiere und ihre Beziehung zu der Sekretion. *Arch. f. Anat. und Physiol.*, *Physiol. Abth.*
- MEVES, F. 1907 Über Mitochondrien bzw. Chondriokonten in den Zellen junger Embryonen. *Anat. Anz.*, Bd. 31.
1908 Die Chondriosomen als Träger erblicher Anlagen. Cytologische Studien am Hühnerembryo. *Arch. f. mikr. Anat.*, Bd. 72.
1910 Über Aussat männlicher Mitochondrien im Ei bei der Befruchtung. *Anat. Anz.*, Bd. 36.
- MICHAELIS, L. 1900 Die vitale Färbung, eine Darstellungsmethode der Zellgranula. *Arch. f. mikr. Anat.*, Bd. 55.
- MISLAWSKY, A. N. 1911 Beiträge zur Morphologie der Drüsenzelle. Über das Chondriom der Pankreaszelle einiger Nager. *Vorl. Mitt., Anat. Anz.*, Bd. 39.

- 1913 Über das Chondriom der Pankreaszellen. Arch. f. mikr. Anat. Bd., 81.
- MONTGOMERY, T. H. 1899 Comparative cytological studies with especial regard to the morphology of the nucleolus. Jour. Morph., vol. 15.
- MOURET, J. 1895 Des modifications subis par la cellule pancréatique pendant la sécretion. Compt. rend. Soc. biol., Année 46, 47.
1905 Contribution à l'étude des cellules glandulaires (pancréas). Journ. de l'Anat. et de la Physiol., Année 31.
- MÜLLER, E. 1896 Drüsenstudien. Arch. f. Anat. u. Physiol.
1898 Drüsenstudien II. Zeitschr. f. wiss. Zool., Bd. 64.
- NEGRI, A. 1900 Über die feinere Struktur der Zellen mancher Drüsen bei den Säugetieren. Verh. d. Anat. Ges.
- NUSSBAUM, M. 1881 Einige Beobachtungen, den Nebenkern der Zelle anlangend. Verh. d. Naturhist. Vereins d. preuss. Rhein. u. West f., Jahrg. 33 (quoted from Opperl).
1882 Über den Bau und die Thätigkeit der Drüsen. Arch. f. mikr. Anat. Bd., 21.
- OGATA, M. 1883 Die Veränderung der Pankreaszellen bei der Sekretion. Arch. f. Anat. u. Physiol., Physiol. Abth.
- ÖPPEL, A. 1900 Lehrbuch der vergleichenden mikroskopischen Anatomie der Wirbeltiere. Jena.
- PFLÜGER, E. 1869 Die Endigung der Absonderungsnerven in den Pankreas. Arch. f. mikr. Anat., Bd. 5.
- PLATNER, G. 1889 Beiträge zur Kenntniss der Zelle und über ihrer Teilung. Arch. f. mikr. Anat., Bd. 33.
- PODWYSSOZKI, W. 1887 Les lois de la régénération des cellules glandulaires à l'état normal et pathologique. Bulletins de la Soc. Anat., de Paris. Année 70.
- POLICARD, A. 1912 Attitudes fonctionelles du chondriome de la cellule hépatique. Rapports des chondrisomes et du noyau. Compt. rend. Soc. biol., T. 72.
- PRENANT, A. 1910 Les mitochondries et l'ergastoplasme. Journ. de l'Anat. et de la Physiol., Année 46.
- REGAUD, C. 1909 Attribution aux 'formations mitochondriales' de la fonction générale d' 'extraction et de fixation électives' exercée par les cellules vivantes sur les substances dissoutes dans le milieu ambiant. Compt. rend. Soc. biol., T. 66.
- REGAUD, C., ET MAWAS, J. 1909 Ergastoplasme et mitochondries dans les cellules de la glande sous-maxillaire de l'homme. Compt. rend. Soc. biol., T. 66.
Sur la structure du protoplasme (ergastoplasme, mitochondries, grains de ségrégation) dans les cellules sérezymogènes des acini et dans les cellules des canaux excréteurs de quelques glandes salivaires de Mammifères. Compt. rend. Assoc. Anat. (quoted from Hoven, '10).
- RETZIUS, G. 1892 Über die Anfänge der Drüsengänge und die Nervenendigungen in den Speicheldrüsen des Mundes. Biol. Untersuch., Neue Folge. III.

- RHUMBLER, L. 1893 Über Entstehung und Bedeutung der in den Kernen vieler Protozoen und in Keimbläschen von Metazoen vorkommenden Binnenkörper (Nukleolen). Eine Theorie zur Erklärung der verschiedenartigen Gestalt dieser Gebilde. *Zeitsch. f. wiss. Zool.*, Bd. 56.
- RUSO, A. 1908 Sull'origine e sulla funzione dell'apparato mitochondriale nelle cellule sessuali dei mammiferi. *Boll. Accad. Gioenia, Sc. nat. Catania.*, Ser. 2, Fasc. 2 (quoted from Luna, '13).
1910 Ancora sui Mitocónri dell'ooite di Coniglia, sulloro aumento e sulla loro funzione. *Anat. Anz.*, Bd. 37.
- SAGUCHI, SAKAYE 1915 Über Sekretionserscheinungen an den Epidermiszellen von Amphibienlarven nebst Beiträgen Zur Frage nach der physiologischen Degeneration der Zellen. *Mitteil. der mediz. Fakultät der kais. Universität zu Tokyo*, Bd. 14.
- SCHULTZE, O. 1911 Über die Genese der Granula in den Drüsenzellen. *Anat. Anz.*, Bd. 38.
- SOLGER, B. 1894 Zur Kenntniss der secernierenden Zellen der Glandula submaxillaris des Menschen. *Anat. Anz.*, Bd. 9.
1896 Über den feineren Bau der Glandula submaxillaris des Menschen mit besonderer Berücksichtigung der Drüsengranula. *Festschr. f. C. Gegenbaur.*, Bd. 2.
- STEINHAUS, J. 1890 Über parasitäre Einschlüsse in den Pankreaszellen der Amphibien. *Ziegler's Beiträge*, Bd. 7.
- VEJDOWSKY, F. 1907 Neue Untersuchungen über die Reifung und Befruchtung. *Verh. k. böhm. Ges. Wiss. Prag* (quoted from Luna, '13).
- VER EECKE, A. 1895 Modifications de la cellule pancreatique pendant l'activité sécrétoire. *Arch. de Biol.*, T. 13.
- WASSILIEFF, A. 1907 Die Spermatogenese von *Blatta germanica*. *Arch. f. mikr. Anat.*, Bd. 70.
- ZIMMERMANN, K. W. 1898 Beiträge zur Kenntniss einiger Drüsen und Epithelien. *Arch. f. mikr. Anat.*, Bd. 52.

EXPLANATION OF PLATES

All figures are drawn with Zeiss camera under Zeiss $\frac{1}{1.2}$ oil-immersion objective and Zeiss compensating ocular 18, at the distance of 250 mm.; tube length, 160 mm. By reproduction, figures 36 to 120 were reduced to four-fifths of the original.

PLATE 1

EXPLANATION OF FIGURES

- 1 to 35 Nuclei of the pancreatic cells of *Rana temporaria*.
- 1 to 6 Sublimate; iron-haematoxylin.
- 7 Alcohol; iron-haematoxylin.
- 8 and 9 Formalin; figure 8, Altmann stain; figure 9, iron-haematoxylin.
- 10 to 13 Sublimate-acetic acid; figures 10, 11, Benda stain; figure 12, iron-haematoxylin; figure 13, alum-haematoxylin.
- 14 to 16 Sublimate-formalin; figure 14, Altmann stain; figures 15 and 16, iron-haematoxylin.
- 17 to 20 Champy's method for mitochondria; figures 17 and 18, Benda stain; figure 19, iron-haematoxylin; figure 20, safranin.
- 21 Potassium bichromate-formalin; Altmann stain.
- 22 and 23 Regaud's bichromate-formalin-acetic mixture; figure 22, iron-haematoxylin; figure 23, alum-haematoxylin.
- 24 Osmium-sublimate; Altmann stain.
- 25 Fixed and stained after Benda.
- 26 and 27 Meves' fluid; figure 26, Benda stain; figure 28, iron-haematoxylin.
- 28 Zenker's fluid; alum-haematoxylin.
- 29 and 30 Trichloroacetic acid; figure 29, Altmann stain; figure 30, iron-haematoxylin.
- 31 to 35 Cajal's photographic method.

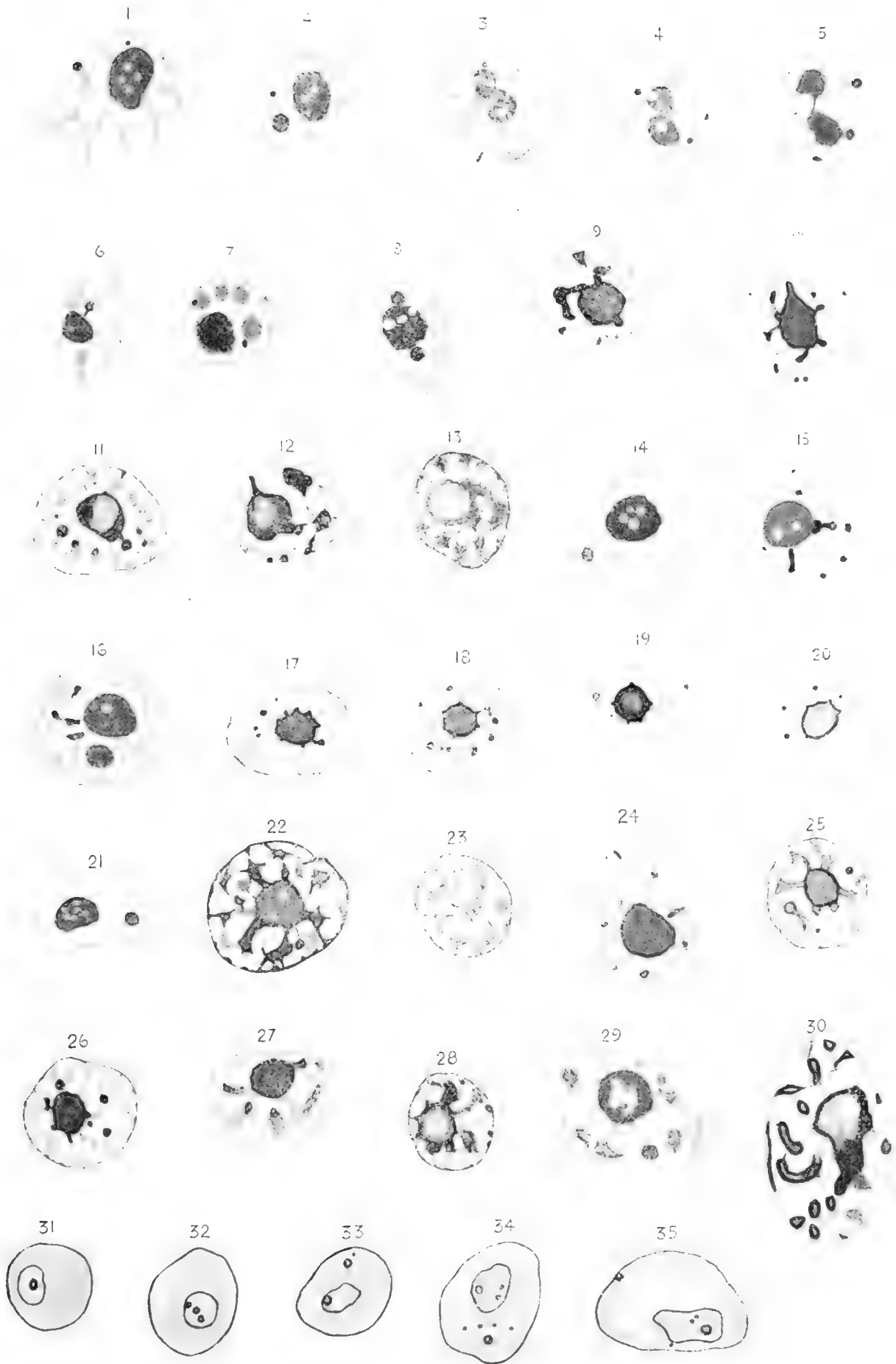


PLATE 2

EXPLANATION OF FIGURES

- 36 Carnoy's mixture; iron-haematoxylin.
- 37 Sublimate-acetic mixture, alum-haematoxylin.
- 38 to 40 Zenker's fluid; iron-haematoxylin.
- 41 and 42 Meves' fluid; iron-haematoxylin.
- 43 Formalin; iron-haematoxylin.
- 44 to 47 Meves' fluid; iron-haematoxylin.
- 48 to 52 Formalin; iron-haematoxylin.
- 53 Sublimate-formalin; iron-haematoxylin.
- 54 Zenker's fluid; iron-haematoxylin.
- 55 Champy's mixture; Benda stain.



PLATE 3

EXPLANATION OF FIGURES

- 56 to 61 Meves' fluid; iron-haematoxylin.
- 62 to 64 Two per cent osmic acid; iron-haematoxylin.
- 65 Fauré-Fremiet's method for mitochondria.
- 66 and 67 Mislowsky's fixing method for mitochondria; Benda stain.
- 68 Meves-formalin without acetic acid; iron-haematoxylin.
- 69 and 70 Golgi's chromium-silver method.
- 71 to 76 Müller-formalin, and succeeding treatment with Müller's mixture;
iron-haematoxylin.
- 77 and 78 Helly's mixture; iron-haematoxylin.
- 79 Champy's method; Benda stain.

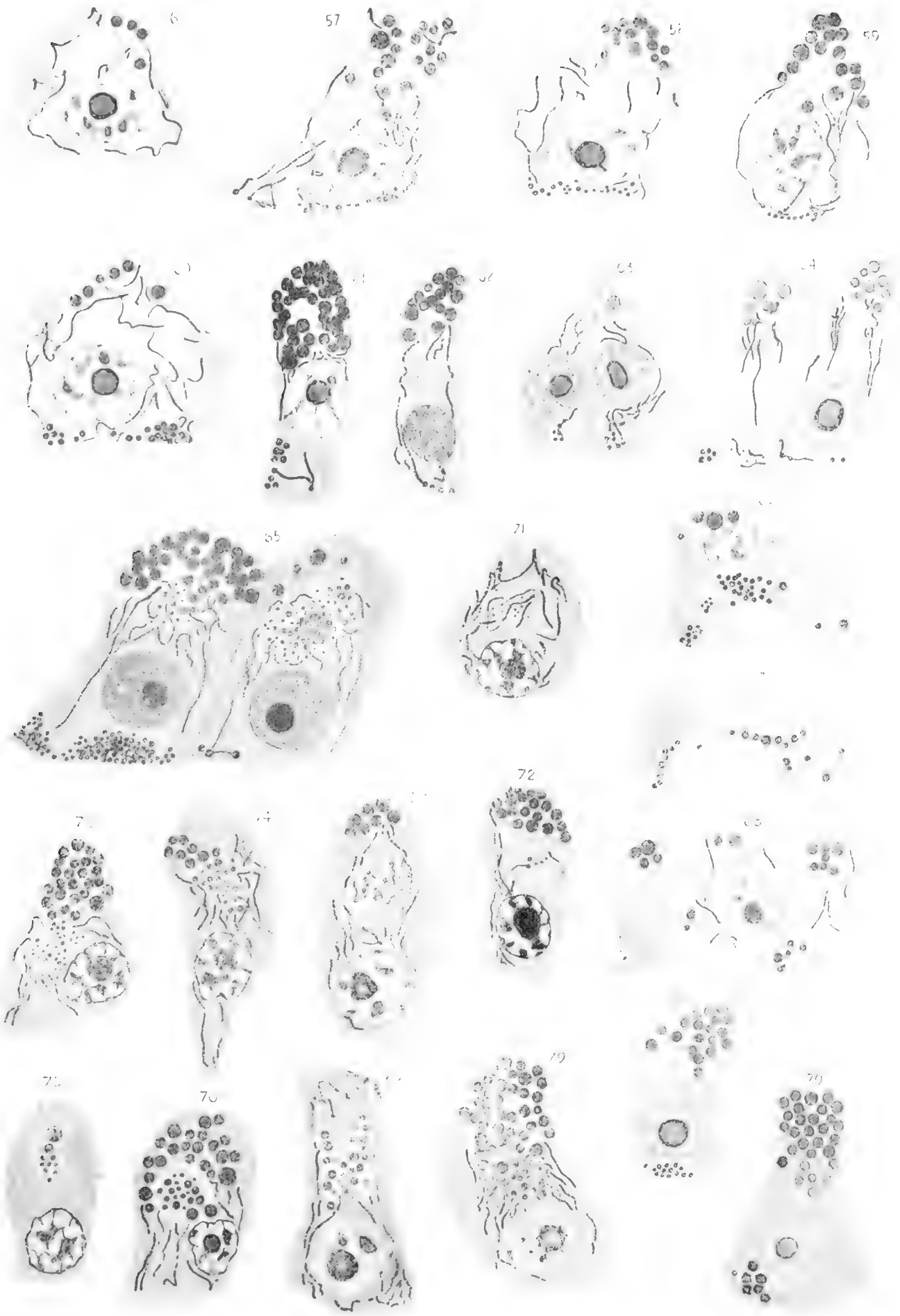


PLATE 4

EXPLANATION OF FIGURES

80 and 81 Zenker's fluid; iron-haematoxylin. The intracellular network is scarcely visible.

82 Kopsch's fixing method; iron-haematoxylin.

83 Müller-formalin and succeeding treatment with Müller's fluid; iron-haematoxylin.

84 Marchi's fixing method; iron-haematoxylin.

85 to 88 Kopsch's osmium method for the Golgi's network.

89 to 91 Sjövall's formalin-water-osmium method for the Golgi's network.

92 to 94 Weigl's method for the Golgi's network.

95 to 98 Cajal's uranic nitrate-silver method for the Golgi's network.

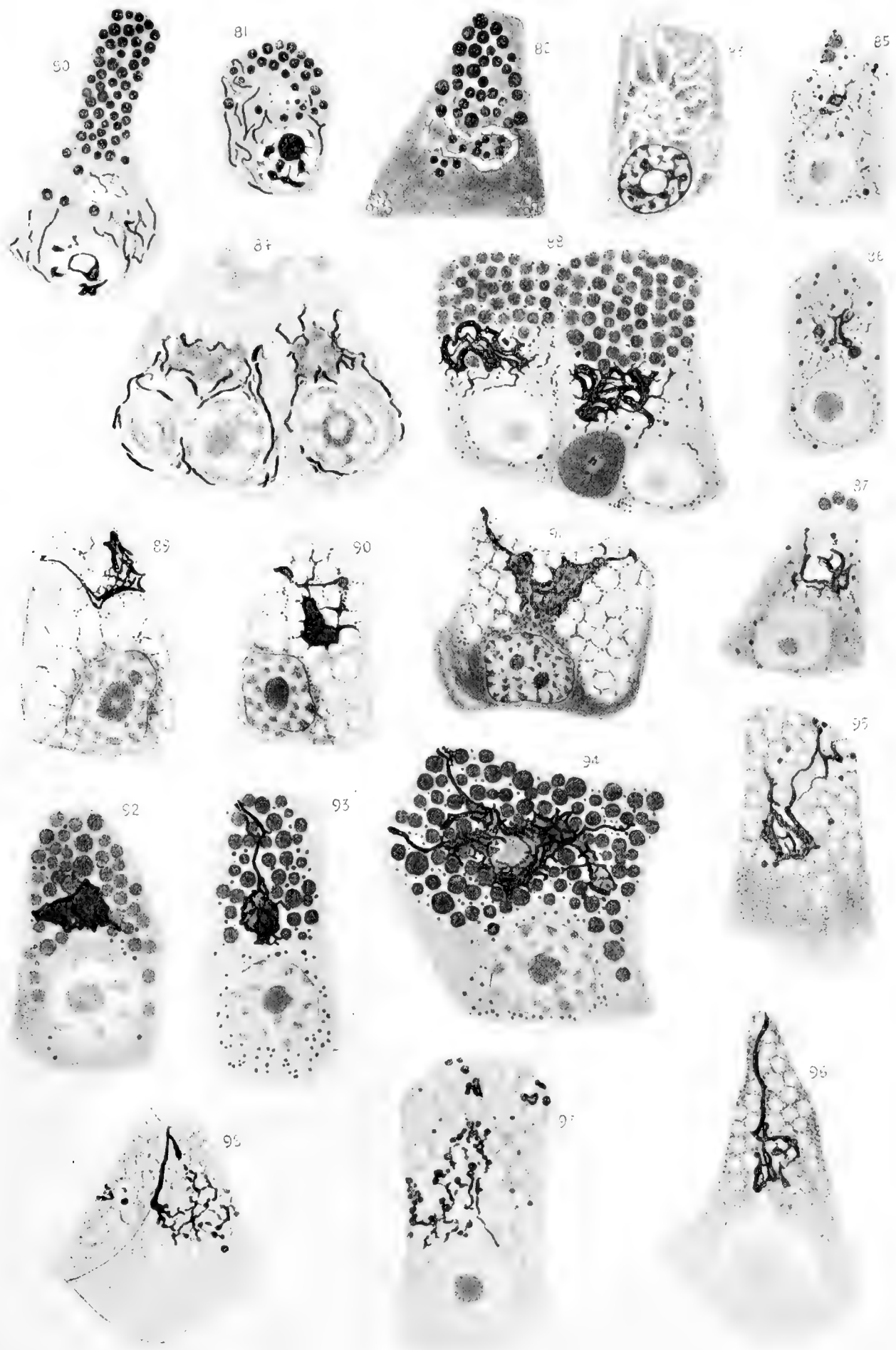


PLATE 5

EXPLANATION OF FIGURES

99 From an injection preparation.

100 to 105 Flemming's fluid; iron-haematoxylin.

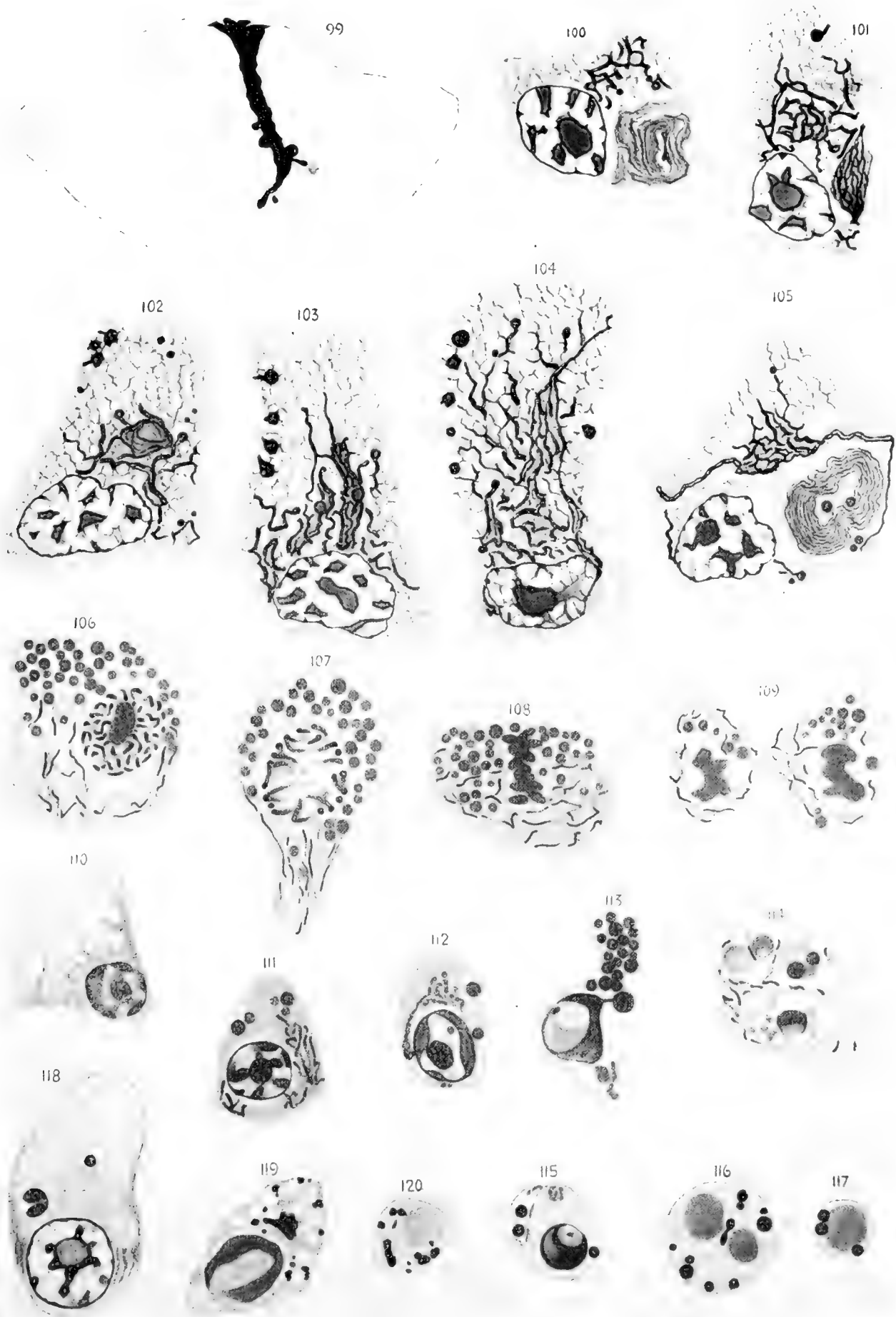
106 to 109 Bichromate-formalin; iron-haematoxylin.

110 Sublimate-acetic acid; alum-haematoxylin.

111 to 117 Meves' fluid, iron-haematoxylin. Figure 113 shows a cell which is just undergoing constriction. The fragments are to some extent invaginated the neighboring cells, which are not delineated in the figure. Figures 115 to 117, constricted fragments which still contain nuclear fragments and zymogen granules.

118 Sublimate-acetic acid; alum-haematoxylin. Figures 114 and 118 show normal cells containing constricted fragments. Some of the latter contain nuclear portion, others none and appear homogeneous, and still others contain zymogen granules.

119 and 120 Cajal's uranic nitrate-silver method.



Resumen por el autor, Frederic T. Lewis.

Escuela Médica Harvard, Boston.

El trayecto de los túbulos wolffianos en los embriones de los mamíferos.

Después del estado bien conocido de tubos en forma de S, los túbulos wolffianos del hombre, cerdo y otros mamíferos adquieren la forma de doble espiral descrita por Milhakovics (figuras 1-4). Esta doble espiral es divisible en tres segmentos que, comenzando por la cápsula glomerular, pueden designarse con las letras C, U y Z, respectivamente. El último segmento desemboca en el conducto wolffiano (fig. 8). En los embriones humanos aunque el tubo se alarga desde 0.3 mm en un embrión de 7.5 mm hasta 1.5 mm en un embrión de 22.8 mm, la disposición no se hace más compleja. Al contrario, mediante el alargamiento de los segmentos C y Z (el segmento U no aumentando de longitud) el túbulo forma una sola asa. (figs. 5-7). En el cerdo, los túbulos al principio tienen la misma forma de doble espiral que en el hombre. Pero rápidamente se hacen mucho más largos (crecen desde 1.9 mm en un embrión de 6 mm hasta 13.5 mm en un embrión de 20 mm) y son por consiguiente más complejos. Entre los segmentos Y y Z se forma un así V, proyectándose en la concavidad de la U. El aspecto así producido se ha representado en las figuras 10-13, que demuestran una sorprendente regularidad en la disposición de las vueltas de espiral.

Translation by José F. Nonidez
Carnegie Institution of Washington

THE COURSE OF THE WOLFFIAN TUBULES IN MAMMALIAN EMBRYOS

FREDERIC T. LEWIS

Harvard Medical School, Boston, Massachusetts

THIRTEEN FIGURES

In early stages, when the Wolffian tubules are so short that they may be cut throughout in single sections, their course from glomerular capsule to Wolffian duct has been thoroughly studied. Kölliker, Mihalkovics, Meyer, Schreiner, and others have described their S-shaped form. But in older embryos the length and sinuosities of the tubules are such as to require reconstruction. "Nevertheless," as Nicolas wrote in 1891, "it can be recognized without too great difficulty that their general orientation has remained unchanged—they have merely elongated and folded capriciously in different planes." The idea of capricious folds is well illustrated in the single reconstruction of a tubule from a human embryo of 10.2 mm., published by Kollmann, and many times reproduced. But Felix records that he has "studied two hundred models of mesonephric tubules from the most different stages of development," and in none of them has he found "any coiling of the tubule." Consequently he infers that Kollmann's model must represent 'a very exceptional rarity'—a conservative and accurate conclusion. The only change observed by Felix after the tubule has become S-shaped occurs near the junction of the middle and distal segments of the S (distal meaning toward the Wolffian duct), and consists in the formation of "a loop directed either cranially or caudally." Unfortunately Felix has not figured in detail any of the late stages included among the two hundred tubules modeled, presumably from human embryos, so that Kollmann's drawing appears to occupy the field alone.

In the pig the tubules are more highly developed than in man. They have been carefully studied by MacCallum, and are shown in two published reconstructions which seem to reveal more than is brought out in the accompanying text. Taken in connection with two models now in the Harvard Laboratory, they indicate that there is a pattern in the Wolffian tubule of the pig, quite as definite and interesting as that of the metanephric or renal tubule. Although a larger number of tubules should be modeled to establish this conclusion and to show the range of variation, the following interpretation of the somewhat laborious work already done may be of value. A simple pattern for the human tubules, and a more complex one for those of the pig, will be presented, showing how both may be derived from a common origin, one by simplification and the other by elaboration.

Omitting from consideration the transformation of the primary vesicle, we may begin with the S-shaped stage which was well described, and perhaps for the first time, by Kölliker in 1879. Referring to a rabbit embryo somewhat older than that here shown in figure 1, he writes:

“From the Wolffian duct there arises first a very slender tubule which passes medially along the dorsal side of the Wolffian body, clear across the organ; then, making a loop, it bends upon itself and retraces its course to the lateral side; finally, after a third coil, it ends in the Malpighian corpuscle, medially placed on the ventral side.” He disposes of the later stages as follows: “These three chief coils become complicated by the formation, at the places where the bends occur, of accessory coils in different planes, so that finally the course of a single tubule becomes so complicated that it cannot be unravelled in sections.”

That the young tubules have the form of a letter S was further established by Mihalkovics in 1885, from studies of the lizard, duck, chick, and sheep. Beginning as a detached vesicle, the tubule becomes cupped or crescentic, with the glomerulus developing within its concavity. It then takes the form of a ‘ladle’ or ‘sickle,’ as a short handle is marked off, joining the Wolffian duct. This stage, as Mihalkovics found, gives place to the S. He considered that the distal limb of the S could be set apart as the tubulus collectivus and that at the region of the distal bend it became dilated and coiled, forming a tubulus secretorius, but

to these designations Nicolas and Von Winiwarter have taken exceptions.

Of greater interest perhaps, and not open to question, is the finding by Mihalkovics that in the sheep the middle or transverse limb of the S elongates and becomes itself S-shaped, though the long axis of the second S is horizontal, being at right angles with that of the first. "Here in a narrow space," according to Mihalkovics, "a winding-up process takes place," which leads to a double or reversed spiral, as shown in figures 3 and 4. Mihalkovics did not follow the further development of this pattern.

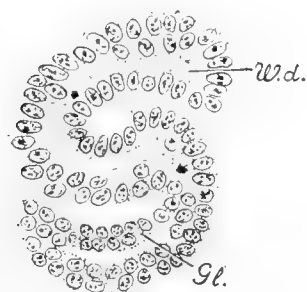


Fig. 1.



Fig. 2.



Fig. 3.

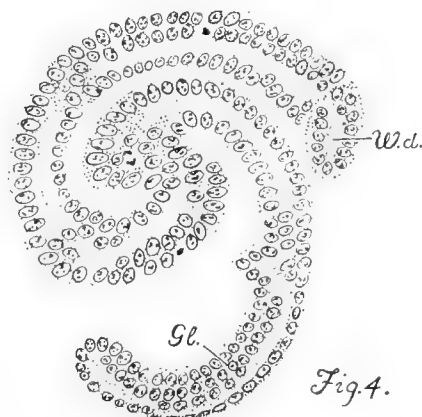


Fig. 4.

Fig. 1 Section of an S-shaped Wolffian tubule. Rabbit embryo, 10½ days, 5.4 mm. Harvard Embryological Collection, series 560, sections 158-161. × 200.

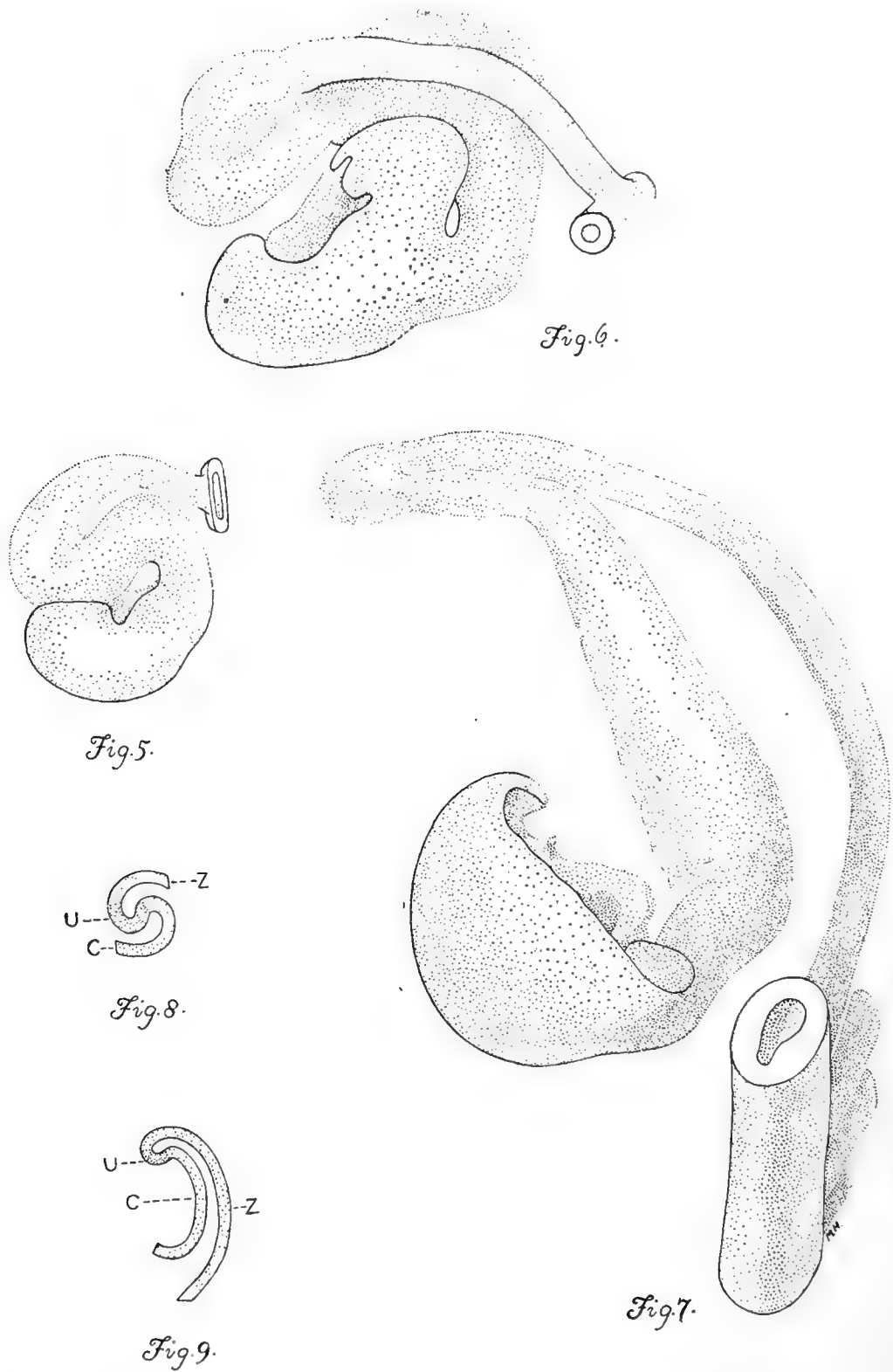
Fig. 2 Diagram of the S-shaped tubule.

Fig. 3 Diagram of the double-spiral tubule.

Fig. 4 Section of a double-spiral tubule. Pig embryo, 4.5 mm. Harvard Embryological Collection, series 1404, sections 114-115. × 200.

Gl., glomerular capsule; *W.d.*, Wolffian duct.

In 1890 Meyer described the simple S-stage in man, and in 1902, with a wealth of lithographs, Schreiner repeated the observations of Mihalkovics on the early stages in the lizard, duck, and chick, with the rabbit in place of the sheep. He refers to the double spiral pattern as a 'much-coiled S,' but there is nothing to suggest that he regarded it as a particularly significant form, essentially different from the simple S. Minot, in 1892, in an account based upon Mihalkovics, notes that the tubules of amniota "retain for some time their simple S-shape, although the curves of the S become more and more exaggerated." These appear to be the



Figs. 5 to 7 Models of Wolffian tubules in human embryos. $\times 175$ (approximately).

principal references to the double spiral which follows the simple S and which is here regarded as the common origin of the later patterns and the key to their interpretation.

A suitable designation for the form which we have called a double spiral (fig. 3) is unfortunately not available. It is a shape which occurs at the apex of the coil of large intestine in the pig, where some of its interesting properties have been discussed by Lineback, and it may perhaps be found elsewhere. Impressed with Thompson's application of mathematics to biological problems, the aid of a mathematician was sought in describing the form in figures 3 and 4, and in determining what factors of growth might account for the regular transformation of the simple S into the double spiral. There are, however, so many unknown factors in the nature of the surrounding medium, which may keep the growing coil within a circular area, and in the physical nature and method of expansion of the tube-wall itself, that a mathematical interpretation was not forthcoming, and the problem was returned as 'biological.' It may be noted that mitotic figures are rather evenly distributed, and that no evidence is found to support the idea of Mihalkovics that a special elongation of the middle segment in cramped quarters produces the double spiral. In fact, if the middle portion remains short and the two ends of the simple S elongate, continuing their respective curves, the double spiral will result, though the axis of the figure rotates. In the shifting position of the Wolffian duct in later stages, there is clear evidence that such a curved elongation of the distal segment actually takes place.

In human embryos the simple S may be expected in 6-mm. specimens and in those somewhat smaller. At 7.5 mm. the double spiral has formed, as shown in the model, figure 5. The tubule chosen was one in which the essential bends fell within the plane of section, thus lessening the chance of distortion in the process of modeling. The liberty has been taken of showing the tubule reversed in the figure, as if it belonged to the left Wolffian body, to facilitate comparison with other models. Ex-

Fig. 5 Embryo of 7.5 mm. Harvard Embryological Collection, series 256, sections 471-485.

Fig. 6 16.0 mm. Harvard Embryological Collection, series 2044, sections 1045-1067.

Fig. 7 22.8 mm. Harvard Embryological Collection, series 871, sections 887-908.

Fig. 8 Diagram of the double-spiral stage, shown in figure 5, with its subdivision into segments C, U, and Z.

Fig. 9 A corresponding diagram of the stage shown in figure 7.

cept for reversal, no difference in shape could be observed between the tubules of the opposite sides. The embryo shows thirty-four tubules entering the right Wolffian duct, which is the number credited to this specimen in Doctor Bremer's earlier study. On the left there are thirty-seven tubules, including four of somewhat retarded development at the caudal end. Beginning the count anteriorly, the tubule modeled is the twenty-seventh. As calculated from the model, which was made at an enlargement of 500 diameters, the length of the tubule from glomerular capsule to Wolffian duct is 0.3 mm.

For purposes of description this double-spiral tubule may be divided into three parts, as shown in the diagram, figure 8. Beginning with the capsule, there is a portion which may be designated *C*, this letter suggesting its shape. It curves laterally and dorsally and passes into the lateral arm of a portion named *U*, the letter again suggesting the form. Finally, the medial limb of the part *U* ends in another simple C-shaped curve, which, as it is the terminal portion, may be designated *Z*. This swings laterally to end in the Wolffian duct which at this early stage is both lateral and dorsal. The rather cumbersome subdivision of the tube into *C*, *U*, and *Z* portions will prove especially serviceable in the more complicated later stages in the pig embryo.

The second model of a human tubule (fig. 6) is from an embryo of 16 mm., excellently preserved and stained with iron haematoxylin. The tubule selected is from the left Wolffian body, in which there are thirty tubules entering the Wolffian duct, this one being the eighteenth. Presumably it has passed through a stage similar to that in figure 5, but has increased in length from 0.3 mm. to 0.8 mm. Although cytological differentiation has advanced, the coiling of the tubule has undergone a slight retrograde movement. Beginning at the glomerular capsule, there is a somewhat constricted neck, as others have frequently noted, and portion *C* is recognized as the tubulus secretorius of Mihalkovics or tubulus postglomerularis of Nicolas. It is capacious, with wide lumen, and thick walls composed of somewhat elongated cells distinctly marked off from one another. These cells have conspicuous terminal bars, a frayed brush-

border, a superficial granular zone not deeply stained, and a still paler basal zone containing the oval nuclei. In a typical manner they show the histological features of secretory activity which cannot be reconciled with Gadow's opinion that "the Wolffian body in birds and mammals appears never to function, not even in the embryo."¹

In the 16-mm. embryo, the segment *U* may be considered to begin where the tubule becomes abruptly narrower, with a corresponding radical change in the histological nature of its walls. The lumen is narrower, and the cells which are longer, with less cytoplasm, stain deeply with iron haematoxylin. The portion *U* is therefore a subdivision of the tubulus collectivus of Mihalkovics or tubulus terminalis of Von Winiwarter. Whatever its function, it must be very different from that of the preceding part. With certain minor swellings and constrictions, the portion *U* makes the bend and passes gradually into *Z*. As the Wolffian duct shifts ventrally, this terminal part of the tube has become longer and more curved. Sometimes, as noted by Felix, it does not remain in the same horizontal plane with the rest of the tubule, but may bend either anteriorly, as in the figure, or posteriorly.

In an older embryo—22.8 mm., figure 7—certain tubules are much longer than before, though degeneration of the Wolffian body has become active. Felix found that from the stage of 21 mm. onward, the Wolffian tubules are "almost all broken in one or several places," notably at the neck of the glomerular capsule, at the junction of the secreting and collecting portions, and at the outlet into the Wolffian duct, and that "all degenerating tubules show a tendency to lose to a greater or less extent their S-shape." The tubule here modeled appeared to be intact throughout, though at this stage they are so difficult to follow that errors are quite possible, either in introducing a discontinuity or in filling an actual gap. The tubule chosen for modeling

¹ This statement is found on page 829 of Bronn's *Klassen und Ordnungen des Thier-Reichs*, Bd. 6, Abth. 4, *Vögel*, von H. Gadow and E. Selenka. It appears to be in Gadow's portion of the work and is wrongly credited to Selenka by Weber, who among others, accepts it. See Weber, In *Schwalbe's Archiv*, 1897, page 621.

is the twenty-eighth to enter the Wolffian duct on the left side; three more occur below it. Of these thirty-one tubules, the anterior are extensively degenerated, and lend no support to MacCallum's statement that "the degeneration of tubules progresses from the posterior end of the organ forward." On the contrary, a posterior tubule was chosen as probably typical of those most highly developed. Its actual length, as calculated from the model, is 1.5 mm.—nearly twice that of the preceding stage. The portion *C*, with its glomerular end bent upward or anteriorly, lies within the concavity of portion *Z*, which also extends upward to enter the Wolffian duct. This disposition of parts would produce the result observed by MacCallum when injecting the tubules of the pig. The fluid could be seen, through the thin overlying tissue, to pass from the Wolffian duct into the tubules and to flow through them around the lateral surface of the gland to the dorsal border. At a certain place, in tubules just beneath the superficial ones, the fluid could be seen to run in the opposite direction.

Although the tubule at this stage is of a simpler pattern than the double spiral, and consists of two rather than three segments, the remains of the middle or *U*-portion can be identified. A narrowing of the tubule marks the place where the *U* begins, and it proceeds around the bend into *Z*, where it ends without definite boundary. An interpretation of the model in terms of the double spiral is shown in figure 9, and the group of figures (5 to 9) presents the evolution of a human tubule from a length of 0.3 mm. to 1.5 mm. without the formation of capricious folds, but according to a very simple law.

That the Wolffian body of the pig is more highly developed than in man is shown in several ways, but very clearly in the greater length of its tubules. The length in a 6-mm. pig, as calculated from a single model, is 1.9 mm., and at 20 mm. it has increased to 13.5 mm.; that is, the tubules of the pig are found to be from six to eight times longer than those of man, and more extensive coiling may be anticipated. The typical double spiral is formed early in the pig, as already shown in figure 4, from an embryo of 4.5 mm. A somewhat later stage was modeled in

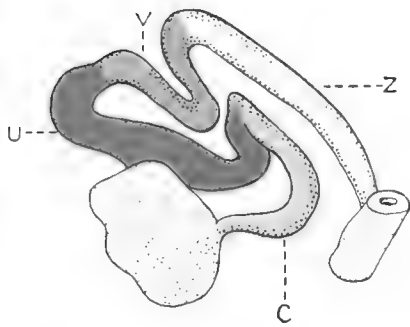
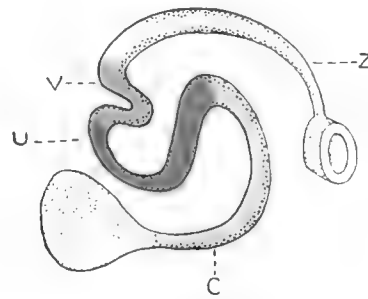
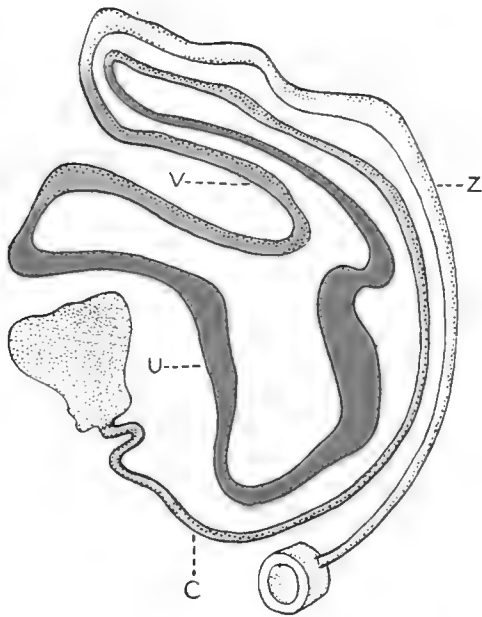
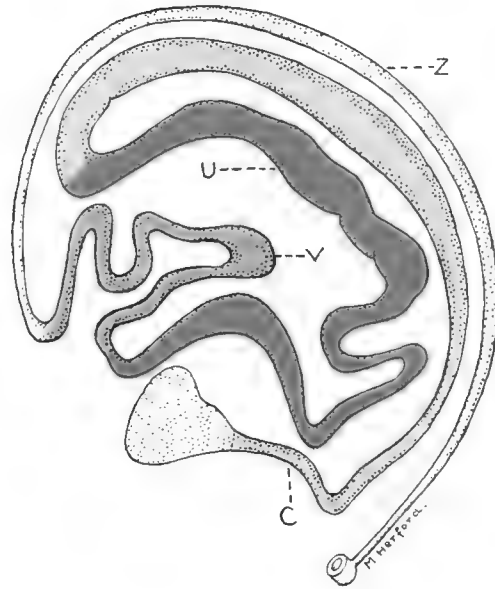
1909 by Dr. F. T. Krusen, in connection with the undergraduate course in embryology given by Professor Minot and assistants. This model, duly catalogued and placed in the Harvard Collection, has apparently never before been utilized. Its essential features are shown in figure 10, in which such slight displacements have been made as are necessary for following the coils easily. In this tubule, from a 6-mm. pig, the segment *U* is directed toward the concavity of *C*, and a new loop, *V*, intervening between *U* and *Z*, has appeared, pointed toward the concavity of the *U*; *Z* is without special features. This pattern might be regarded as a casual form were it not duplicated in MacCallum's figure, here reproduced reversed as figure 11.

MacCallum described his figure as a "diagrammatic reconstruction of Wolffian tubules" from a pig embryo of 8 mm., and he presented it as applying to "a number of tubules." Referring to an older embryo, he writes: "Special names might be given to the different parts of the tubule, but until their significance is more definitely known this could be of little value. There is, however, a very distinct division into a secretory and a conducting part." But without discussing relative values of morphological and physiological subdivisions, it is clear that we stand on firmer ground in describing the course of the tubule than in assigning a functional significance to its various bends. It is unfortunately true that the limits of the secretory portion in the pig remain unknown and MacCallum did not succeed in defining them. He put together the upper part of *C* (in fig. 11) and the adjacent limb of the *U* as the 'secretory loop,' and this loop forms the only subdivision of the tubule which he recognized. But judged by its large diameter in figure 10, the remainder of the *U* is also secretory; whereas in man none of the part *U* was of the same nature as *C*, and the latter was certainly secretory. Whether the subdivisions here imposed upon MacCallum's figure are profitable or not may be questioned, but they enable one to sketch quickly the course of the Wolffian tubule not only in the young embryos now considered, but also in older ones where previously no description was attempted.

For permission to make and publish figure 12, the writer is under special obligation to Dr. Frank H. Rose, who made the model, and to Prof. Franklin P. Johnson, who directed Doctor Rose's study in the University of Missouri. This model of a tubule in a 20-mm. pig is incidental to a comprehensive study of that embryo, being made by Professor Johnson and his pupils, and later to be published in detail. The simplified sketch, showing all the essential bends and loops in this long and involved tubule, may readily be compared with the figures of the earlier stage already discussed. From the glomerular capsule, with initial kinks, the portion *C* sweeps in a well-rounded curve to the dorsal border, and forms a *U* in the concavity of the *C* and a *V* in the concavity of the *U*, with a final sweeping curve enclosing them all—the portion *Z*.

This model again accords, in surprising detail, with MacCallum's figure of the tubule from a much larger pig, measuring 80 mm. Neither the length of the tubule nor the magnification of the figure is stated, but the tubule, here shown reversed in figure 13, is evidently much longer than in the preceding stage. A secondary coil has appeared along the portion *U* and another in connection with *V*. The coil in the descending limb of the *U* chances to be comparable with a kink in figure 12, but the constancy of this feature remains to be determined. The new loop in segment *V*, which may or may not correspond with a slight bend in the tubule at 20 mm., is not directed toward the apex of the *V*; if it should become so, it would carry the evolution of the characteristic pattern one step further than has yet been observed.

Finally, it may be repeated that the total number of tubules studied is small for drawing general deductions. But the close agreement in the findings of independent observers and the absence of a single aberrant form from the group carefully modeled are evidence in favor of the interpretation presented. In these models an easily recognized pattern exists, much more complicated than the double-spiral form from which it springs.

*Fig. 10.**Fig. 11.**Fig. 12.**Fig. 13.*

Figs. 10 to 13 Wolffian tubules of pig embryos. Small irregularities in the models have been omitted, and the coils have been slightly spread apart to display the course of the tubules. Colors have been used to mark out the segments C, U, V, and Z, thus demonstrating more clearly the type pattern.

Fig. 10 Model by F. T. Krusen. Pig embryo of 6 mm. Harvard Embryological Collection, series 918.

Fig. 11 Reversed drawing of MacCallum's 'diagrammatic reconstruction.' Pig embryo of 8 mm. *Am. Jour. Anat.*, vol. 1, p. 251, fig. 7.

Fig. 12 Model by F. H. Rose. Pig embryo of 20 mm. University of Missouri Embryological Collection, no. 1.28.

Fig. 13 Reversed drawing of MacCallum's 'wax reconstruction.' Pig embryo of 80 mm. *Am. Jour. Anat.*, vol. 1, p. 252, fig. 8.

LITERATURE CITED

- BREMER, J. L. 1911 Morphology of the tubules of the human testis and epididymis. *Am. Jour. Anat.*, vol. 11, p. 404.
- FELIX, W. 1912 The mesonephros. *Human embryology*, edited by Keibel and Mall, vol. 2, p. 807.
- GADOW, H. 1891 Vögel. *Bronn's Klassen und Ordnungen des Thier-Reichs*. Bd. 6, Abth. 4, Th. 1, S. 829.
- KÖLLIKER, A. 1879 *Entwicklungsgeschichte des Menschen*. Zweite Auflage, S. 944.
- KOLLMANN, J. 1898 *Lehrbuch der Entwicklungsgeschichte des Menschen*, S. 398-399.
- LINEBACK, P. E. 1916 The development of the spiral coil in the large intestine of the pig. *Am. Jour. Anat.*, vol. 20, pp. 488-489.
- MACCALLUM, J. B. 1902 Notes on the Wolffian body of higher mammals. *Am. Jour. Anat.*, vol. 1, pp. 250-254.
- MEYER, H. 1890 Die Entwicklung der Urnieren beim Menschen. *Arch. f. mikr. Anat.*, Bd. 36, S. 161.
- MIHALKOVICS, G. V. VON 1885 Untersuchungen über die Entwicklung des Harn- und Geschlechtsapparates der Amnioten. *Internat. Monatschr. f. Anat. u. Physiol.*, Bd. 2, S. 76-79.
- MINOT, C. S. 1892 *Human embryology*, p. 239.
- NICOLAS, A. 1891 Contribution à l'étude des cellules glandulaires. I. Les éléments des canalicules du rein primitif chez les mammifères. *Extrait du Journ. internat. d'Anat. et de Physiol.*, T. 8, p. 94 (of the reprint)—"Conclusions."
- SCHREINER, K. E. 1902 Über die Entwicklung der Amniotenniere. *Zeitschr. f. wiss. Zool.*, Bd. 71, S. 96.
- THOMPSON, D. W. 1917 *On growth and form*. Cambridge University Press.
- WEBER, S. 1897 Zur Entwicklungsgeschichte des uropoetischen Apparates bei Säugern. *Morphol. Arbeiten*. Bd. 70, S. 621.
- WINIWARDER, H. VON 1910 La constitution et l'involution du corps de Wolff. *Arch. de Biol.*, T. 25, p. 184.

ADDENDUM

The foregoing account pertains only to mammals but it may be of interest to compare the models of the Wolffian tubules in pig embryos with those of the corresponding structures in adult amphibians. For this purpose two figures are available, by Nussbaum and Huber respectively. Nussbaum (*Arch. f. mikr. Anat.*, 1886; Bd. 27, Taf. 23, Fig. 28) shows a mesonephric tubule isolated by maceration from the kidney of *Rana esculenta*. Any subdivision into C, U, V and Z portions seems impossible. Huber (*Anat. Rec.*, 1917, vol. 13, p. 310) presents a wax reconstruction of a tubule from *Rana catesbiana*, which has 'many points of similarity' to Nussbaum's figure, and yet, notwithstanding many secondary convolutions, may readily be resolved into the pattern in question. Further study is needed to show whether this interpretation of the model is of any real significance.

Resumen por el autor, William H. F. Addison.
Universidad de Pennsylvania.

Estudio histológico del bazo del conejo durante el aumento de la actividad fagocítica.

El autor ha estudiado la capacidad fagocítica de los esplenocitos del bazo del conejo después de inyectarle corpúsculos sanguíneos lavados de paloma. La hemolisis ordinaria de los corpúsculos de la paloma sigue a la inyección y, casi como un efecto inmediato, en un cierto número de casos siguió una liberación de considerable número de células sanguíneas maduras y no maduras por la médula de los huesos. La sangre hemolizada de la paloma y las células de la médula ósea del conejo, al llegar al bazo transportadas por la sangre, permanecen dentro de los canales sanguíneos cavernosos de la pulpa y comienzan pronto a ser ingeridas por las células esplénicas. Los esplenocitos crecen aumentando su contenido hasta que al cabo de 16 horas adquieren considerable tamaño. Así, por ejemplo, un esplenocito que media $55 \times 23.3 \mu$ presentaba 20 inclusiones celulares en un solo corte de 4μ de espesor. Los esplenocitos que contienen de 5 a 10 células son de menor tamaño. A medida que procede la digestión de las células ingeridas, los esplenocitos disminuyen de tamaño y al cabo de 48 horas muchos de ellos no son mayores que los que se encuentran en el bazo normal. De los productos de la hemolisis de la sangre de la paloma después de la inyección poco queda de un modo permanente en las órganos del cuerpo; la mayor parte se eliminan por los riñones durante las 16 horas. En el bazo los esplenocitos presentan un aumento de substancia férrica, mientras que las células endoteliales no presentan, en su mayor parte, un aumento de tal substancia. En este procedimiento experimental dondequiera que células o fragmentos celulares sirven de estímulo para la fagocitosis, los esplenocitos son los primeros en actuar y continúan actuando como los principales agentes fagocíticos.

Translation by José F. Nonidez
Carnegie Institution of Washington

HISTOLOGICAL STUDY OF THE SPLEEN OF THE RABBIT UNDER HEIGHTENED PHAGOCYTTIC ACTIVITY

WILLIAM H. F. ADDISON

*Anatomical Laboratory and the Department of Research Medicine, University of
Pennsylvania, Philadelphia*

ONE PLATE (SIX FIGURES)

The phagocytic reaction in the mammalian spleen has been studied under various experimental conditions and from different points of view. Histologically, the accumulated observations show that the same cell types are not the active phagocytic agents in all cases. Thus in some conditions it is found that fixed cells, such as reticular and endothelial cells, are most active (Heinz, '01; Cary, '15) while in other conditions free cells, such as splenocytes, are the predominant phagocytic cell type (Muir, '02). In other conditions, again, cells of both types take part (Paton and Goodall, '03). These findings are to be correlated with the well-recognized fact that phagocytic cells have a selective action, some types reacting to one stimulus, some to another. With the purpose of examining some of the conditions under which the phagocytic cells of the spleen act, we have studied this organ in one definite experimental procedure, paying special attention to the histological character of the cells involved in the reaction.

The stimulus used has been the injection of washed pigeon corpuscles into the circulation of the rabbit. Rapid destruction of the foreign corpuscles ensues and, as an almost immediate effect, is followed by the release of great numbers of mature and immature blood-cells from the bone-marrow. Both the hemolyzing blood of the pigeon and the bone-marrow cells of the rabbit, being brought by the circulating blood to the spleen, are delayed within the cavernous blood-channels of the pulp, and are there exposed to the phagocytic action of the splenic cells.

EXPERIMENTAL PROCEDURE

The pigeon blood was prepared for injection in the following manner. The pigeon was bled from the jugular veins into 2 per cent sodium citrate in 0.85 per cent sodium chloride solution. Usually 10 to 12 cc. of blood was available, and about 25 cc. of the citrate solution was used to receive the blood. This was centrifuged for fifteen minutes, and the supernatant fluid pipetted off. The corpuscles were next shaken up with 2 cc. of the citrate solution, and then the centrifuge tube filled with 0.95 per cent NaCl solution. The corpuscles were washed twice again, each time first shaking up the corpuscles with a small amount of the citrate solution, and the tube then filled with the 0.95 per cent NaCl solution. Finally, the volume of the washed corpuscles was made up to 10 to 12 cc. with the 0.95 per cent NaCl. Under this treatment there was no visible hemolysis and under the microscope there was seen no clumping of the red blood-cells. Usually 10 cc. of this was injected into a superficial ear vein of the rabbit. The rabbits were taken at varying intervals after injection, from one hour to forty-eight hours after injection. After etherizing the rabbit, the animal was bled through the inferior vena cava and normal saline transfused through the thoracic aorta. After the spleen was partly washed out, as shown by its paler color, the fixing fluid was run in, and attempts were made to distend the spleen as much as possible. The fixing fluid used was a mixture of commercial formalin, made neutral by previously adding magnesium carbonate in sufficient quantity to form a thin layer at the bottom of the stock bottle, and 3 per cent aqueous solution of potassium bichromate. The two fluids were mixed, just before using, in the proportion of one part of neutral formalin to nine parts of the bichromate. Small pieces of the organ were subsequently fixed for a period of twenty-four hours in the same fluid, before washing, dehydrating, etc., preparatory to embedding in paraffin. Hematoxylin and eosin or acid fuchsin were used for routine staining. Tests for the presence of iron were made by the potassium ferrocyanide and hydrochloric acid method.

NORMAL SPLEEN

In the spleen of the normal rabbit can always be found phagocytic cells with inclusions. The detection of these cells is greatly facilitated by spreading apart the constituent tissues of the spleen pulp by intravascular injection of fluids. Although part of the blood content is driven out by this procedure, one can never force out all the blood, and the great advantage is that the resultant preparation is much more easily studied.

The largest of these phagocytic cell types are the free-swimming mononuclear cells, called splenocytes. These vary in size according to the bulk of their contents. The nucleus tends to be rounded or oval in shape, and is usually eccentrically placed. The nuclear membrane is very well defined, and the chromatin is distributed in one or two larger dots and in a network of fine lines. In general the nuclear contents are pale-staining, as compared with the nuclear membrane. The most evident characteristic in the cytoplasm is the presence of inclusions. These inclusions are sometimes single, but are usually multiple. They are most frequently in the form of light yellow spots embedded in the cytoplasm. Indeed, a useful method of detecting the splenocytes is to search over the microscopic field for little clusters of golden-yellow dots. If such a cluster is in a closely compacted mass of cells, diagnosis of the containing cell is very difficult. But if the cell lies free within a pulpar blood space, then the configuration of the cell is readily seen, as shown in figure 1. These contained spots are of varying size, and may not all be of exactly the same color. Sometimes they are closely packed, making a nearly homogeneous mass. In other cells the dots are farther apart, so that the intervening cytoplasm is seen between them. All these appearances are regarded as products of the intracellular digestion of entire erythrocytes, or fragments of them, in the form of hemosiderin. In testing for iron in such cells, these clusters of dots give a strongly positive reaction. Occasionally one sees what appears to be an entire red blood corpuscle still intact within the splenocyte, but final judgment is often difficult. Or again, the inclusions may appear as hemo-

globin-bearing fragments of erythrocytes, as indicated by color comparison with adjacent red blood corpuscles. Not infrequently, too, a splenocyte is seen containing a polymorphonuclear leucocyte.

These polymorphonuclear leucocytes in the rabbit are conspicuous, for in addition to the characteristic shape of nucleus, their numerous fine cytoplasmic granules stain a vivid red color with stains containing eosin. This coloring may lead to some confusion at first in distinguishing them from true eosinophiles. However, the fact that the granules in the latter are larger than in the ordinary polymorphonuclears, and also that their color after eosin staining is more yellowish, helps one to distinguish between them.

SPLEENS OF EXPERIMENTAL ANIMALS

After injection of the pigeon blood, prepared in the manner above described, the corpuscles retain their individuality for but a short time. At the end of one hour they are found to be swollen, rounded, and the nucleus has lost its characteristic staining capacity. Most of the corpuscles are single, but some have begun to agglutinate into little masses. In some elements, the nucleus is still distinguishable by its refractivity. Brown-Sequard, in 1857 (Hunter, '01, p. 120), noted that while dog or rabbit corpuscles injected into the circulation of the domestic fowl could be found at the end of a month, the corpuscles of the fowl injected into the dog or rabbit were no longer recognizable at the end of one hour. Our preparations, in the main, confirm the latter observation.

At this stage, the spleen has grossly a purplish-black color, and its channels are congested with the masses of intermingled rabbit and pigeon corpuscles. It was found that perfusion was even less successful than usual in washing out the blood. A few splenocytes containing inclusions recognizable as entire pigeon corpuscles are seen, but splenocytes with inclusions of amorphous brownish masses are more often to be found, but not in every field, as viewed with the $\frac{1}{12}$ oil-immersion lens. Polymorphonuclears are seen more frequently than in the normal spleen, and

are readily detectable by reason of their red staining granules. No color was yet visible in the urine.

Two hours. At the two-hour period the injected pigeon corpuscles are no longer recognizable as such, having lost their original form and finally become drawn out and subdivided into smaller and smaller globoid and irregular fragments. That the amount of hemoglobin, either free or still in combination with minute portions of the substance of the corpuscles, is overtaxing the capacity of the organism is shown by the very evident hemoglobinuria. The cells of the liver show many minute brown granules in their cytoplasm. The number of pseudo-eosinophilic polymorphonuclears has increased, often a dozen being seen in one field. A new and larger type of cell, containing red-staining granules, now appears in small numbers, at most two or three in a field. These are cells with a single eccentrically placed nucleus, which has a very well-defined nuclear membrane. Within the nucleus are one or two larger dots of chromatin, but otherwise the chromatin is very finely divided. The shape of the nucleus usually tends to be spherical, but may have one side flattened or slightly concave. An examination of the bone-marrow shows that similar-appearing cells are there in great numbers. They are both in the blood-channels and in the framework tissue, and most of them, though not all, are packed with the red-staining granules. This comparison leads to the conclusion that the new type of cell now appearing in the spleen has come from the bone-marrow and is of the myelocyte type.

The splenocytes are not greatly different in number or size from before. Some are conspicuous by their multiple brownish-colored inclusions. One of these cells measured $20.5 \mu \times 12.3 \mu$, which is no larger than splenocytes, containing several inclusions, from the normal spleen. Occasionally a splenocyte is seen containing a pseudo-eosinophile, in addition to remains of red blood corpuscles.

Three hours. At three hours after injection, the pigeon corpuscles have been reduced to brown-colored masses and clumps of fine particles. Even more intense hemoglobinuria is found than at the preceding stage. Polymorphonuclears and myelo-

cytes are present in about the same numbers as before. The splenocytes contain brown masses derived from the ingested particles of blood. These may exist as a single large mass in a cell or as many small ones. The average size of the splenocytes has not increased to any extent.

Four and one-half hours. Fragments of the injected pigeon corpuscles are still abundant, intermingled with the rabbit corpuscles. The polymorphonuclears have increased in number and myelocytes are frequent. The splenocytes may contain a single brownish mass, or more frequently many inclusions, usually brownish globules and often leucocytes. One cell was seen containing seven polymorphonuclears, as well as many fine brown dots. The average size of five splenocytes was $16.7 \times 10.8 \mu$, with nucleus $6.8 \times 5.9 \mu$. Measurements of five myelocytes showed average size of cell-body of $10 \times 8.7 \mu$, with nucleus $7 \times 5 \mu$. The average size of the pseudo-eosinophilic polymorphonuclears, as seen in sections, is $6.5 \times 6 \mu$.

Six hours. After six hours, the appearance of the sections is very striking from the presence of numerous myelocytes, with red-staining granules. What appears to be mitotic division in these cells is seen not infrequently (fig. 2, *My*₁). Whether this may be considered a normal mitotic division has been questioned.

The polymorphonuclears (fig. 3) are even more numerous than the myelocytes, but the latter on account of their larger individual size form the most conspicuous elements in many fields. Splenocytes are scattered here and there and have inclusions similar to those in the preceding stage. There are occasional extracellular masses of yellowish hemosiderin. Several megacytes were seen, and these are apparently cells which have remained in the spleen from fetal life, for in rodents' spleens such cells are found not infrequently. One of these is shown in figure 3 (M), and its size is useful for comparison with the size of the splenocytes in their several stages of phagocytic activity. The hemoglobinuria still persists. Within the endothelial cells of the blood-channels very fine yellowish granules could be seen. Tests for the presence of iron showed this to be present within these cells and also very strikingly within the splenocytes.

Eight and one-half hours. The appearance at this stage is similar to the preceding. There is an abundance of myelocytes and of pseudo-eosinophiles. The splenocytes usually contain numerous small inclusions of hemosiderin and are not very conspicuous.

Twelve hours. The splenocytes are now beginning to show inclusions of nucleated cells, in addition to the blood pigment derived from the pigeon red blood corpuscles. This is the last stage at which hemoglobinuria was noted, and apparently the pigeon blood has for the most part been disposed of. The phagocytosis of the bone-marrow cells by the splenocytes is now commencing, and shows most strikingly at the next stage.

Sixteen hours. At this period, one can readily discern the splenocytes with a low power of the microscope, by reason of their increased size. In figure 4 is shown a characteristic field. Every splenocyte contains a number of nucleated cells, both polymorphonuclears and myelocytes with their granules still staining characteristically. An average size is $25 \times 20 \mu$, in contrast to their previous size of $16 \times 10 \mu$. A large one, shown in figure 5, measures $55 \times 23.4 \mu$, and in single 4μ section, twenty cells can be counted within its cytoplasm. This period evidently shows the splenocytes at the height of their phagocytic activity toward the animal's own bone-marrow cells. There are scattered extracellular masses of hemosiderin. The polymorphonuclears are still abundant, but the myelocytes are apparently not so numerous, and this is probably due to the activity of the splenocytes. At this period there was no discernible hemoglobinuria. Tests for iron showed this to be present in many endothelial cells, but in much greater amounts within splenocytes.

Twenty-one hours. The splenocytes are now smaller in size, and accordingly less conspicuous than at the preceding period. Their diminution in size is to be associated with the shrinkage of their cellular inclusions. While in some of the splenocytes, the ingested cells show both nuclei and granules stained characteristically, in others, only the nuclei of the ingested cells remain recognizable, and apparently the red-staining substance has been altered, probably by digestive ferments within the cell. Some

splenocytes also contain small yellowish or light brown inclusions derived from the original pigeon blood. Occasionally a splenocyte is seen containing one single larger rounded mass of hemosiderin. While polymorphonuclears are still scattered about, no distinct myelocytes were found.

Forty-eight hours. The splenocytes are again easily detectable in the microscopic field, because of the deep staining of the remains of the cells which they had ingested. These cellular inclusions, for the most part, no longer resemble the original cells. The nuclei show as shrunken round little masses, which stain intensely with the hematoxylin, and no remains of their cytoplasmic granules are seen. The size of the splenocytes has much diminished, and has returned nearly to the size seen at the early stages. A characteristic one, with a dozen little dark-stained dots within it, measured $18 \times 15 \mu$. Others, in which the digestion of the cells has not advanced so far, are of larger size. In some cells, in addition to the shrunken remains of the nucleated cells, are seen yellowish granules, derived from the red blood corpuscles of the pigeon. The polymorphonuclears are few in number, and no myelocytes remain.

DISCUSSION OF OBSERVATIONS

In considering the results of these experiments there are several variables, which have to be taken into account. First, in the washing out of the spleen, the perfusion is more successful in removing the contents of the vascular channels in some cases than in others. However, as mentioned before, the result is never complete washing-out, and by studying various areas in the sections one can reach definite conclusions as to the relative number of the different types of cells present. A second and even more important point is the difference in amount of reaction which the bone-marrow gives. In some animals apparently great numbers of cells are released and in others relatively few. This may depend upon the age of the rabbit, but many other factors must be considered before a solution can be arrived at.

The outstanding features of the experiments are: 1) the definite cycle which can be followed in the phagocytic activity of the splenocytes, and, 2) the bone-marrow crisis occurring as a reaction to the hemolysis of the pigeon corpuscles.

In following the phagocytic history of the splenocytes, one notes that the hemolysis of the pigeon blood is so rapid that few of these cells are taken up intact. It is true that some are taken up whole, but as dissolution proceeds, it is more and more the fragments which are ingested by the splenocytes. At the one-hour stage, the reaction has already begun, some of the inclusions being recognizable as entire red blood-cells, others as amorphous masses derived from the pigeon corpuscles. However, the splenocytes are not greatly enlarged, and even by the end of six hours, after an interval of several hours during which the splenocytes have been surrounded by the disintegrating blood-cells, their size is not conspicuously increased. Either the output from the cells keeps pace with the intake or the phagocytic process requires a number of hours for its completion. That time is a necessary factor in the engulfment stage of phagocytosis is also indicated in the action of the splenocytes toward the bone-marrow cells. These first appear in the spleen at the two-hour stage, and are abundant by the six-hour stage, but it is not until the twelve-hour stage that any conspicuous number of these cells are seen within the splenocytes. Thereafter the engulfing process continues rapidly, and at sixteen hours, practically all splenocytes are laden with these cells.

As the result of the ingestion of myelocytes and polymorphonuclear cells, the size of the splenocytes greatly increases. An average size is $25 \times 20 \mu$, but many are larger than this, and the example shown in figure 5 measures $55 \times 23.4 \mu$. In this cell at least twenty bone-marrow cells can be counted within its cytoplasm in a single 4μ section, so that one can judge that its total capacity must be several times this number.

After the stage of engulfment comes the digestion of the cells. First the pseudo-eosinophilic granules lose their characteristic staining capacity, although the nuclei still show their original form. Gradually, however, the nuclei begin to shrink, and

apparently the polymorphous nuclei separate into small pieces. These shrunken nuclear remnants stain more deeply than do the original nuclei. The twenty-one-hour material shows splenocytes containing some cells which still show red-stained granules, and other cells in which the granules are no longer apparent.

At the forty-eight-hour stage most of the inclusions have been reduced to the condition of fine dark-staining granules, while others (fig. 6) may still retain the original form of nucleus. Those splenocytes (fig. 6) which contain cells which have been altered but little, are usually larger than those in which the digestion of the cells has advanced farther. Indeed, many of the splenocytes are now but little larger than some found in the normal spleen. They are, however, quite conspicuous, on account of the intense staining of the nuclear remains within their cytoplasm. The digestion of the cells by the enzymes of the splenocytes is evidently a process which requires considerable time. At the twenty-one-hour stage no free myelocytes were found, and relatively few polymorphonuclears, and it appears that the splenocytes even at the sixteen-hour stage, were already well filled. So it would seem that the cells ingested at sixteen to twenty-one hours had not been completely digested by the forty-eight-hour stage.

These experiments indicate that the splenocytes can ingest material from a very small size to cells $16 \times 10 \mu$ in dimension. They also readily take up the ultramicroscopic aggregates of trypan blue. So it is apparent that they have a very wide phagocytic capacity as regards size of object to be ingested.

Viewing this in relation to their activity toward effete red blood corpuscles of their own circulation, one must conclude that they are capable of taking up either entire red blood-cells or fragments of them. In a recent paper, Rous and Robertson ('17) have found that phagocytosis of entire red cells is frequent in normal dogs, rats, and guinea-pigs, slight in man, the rhesus monkey, and many rabbits. This phenomenon is practically absent in cats and in some dogs and some rabbits. In these latter they find that fragmentation of the red cells occurs, and they question how the fragments are disposed of. Judging by the

range of activity of the splenocytes, one must conclude that the splenocytes are just as capable of ingesting schizocytes as of taking up the entire red blood-cells and that phagocytosis must still be regarded as a sufficient general explanation of normal blood destruction.

Cary ('15) studied the method of disposal of bovine corpuscles when injected into the blood stream of the rabbit. His method of study was by applying the reaction for iron. He found the injected corpuscles to be taken up by hemophages, which he indicates are fixed cells. In contrast to these results, we have found free-swimming cells to be the most active phagocytic agents in the spleen. Muir ('02), studying the rabbit's spleen in infections, found non-granular free cells containing as many as twenty or more red corpuscles and a half-dozen leucocytes in various stages of disintegration. This is a reaction comparable in many ways to that which we have been following.

Muir also observed myelocytes in the splenic pulp, in infectious conditions, especially when severe. The greatest numbers he found in cases of variola. Once or twice he observed them undergoing mitosis. The bone-marrow crisis is evidently the result of the action of the toxic material set free in the hemolysis of the pigeon blood. That it begins between one and two hours after the injection is indicated by the myelocytes being seen in the spleen at the two-hour stage. This time coincides with that at which the crisis of white cells takes place after acute hemorrhage, and it is to be noted how promptly the spleen reflects the bone-marrow crises. By four or five hours after injection of the foreign blood, great numbers of the bone-marrow cells have been caught within the spleen. These are detained within the cavernous blood-spaces, and finally ingested by the splenocytes.

SUMMARY

The cycle of changes associated with the phagocytic activity of the splenocytes of the rabbit has here been followed.

When washed pigeon corpuscles are injected intravenously, they are rapidly hemolyzed. The hemolysis of the pigeon blood results in the liberation of great numbers of bone-marrow cells, mature and immature. These are caught within the spleen, and quickly begin to be ingested by the splenocytes. The splenocytes grow with their increased contents, until at the sixteen-hour stage they reach a very large size. As many as twenty cells are visible in a 4μ section of a splenocyte, measuring $55 \times 23.4 \mu$. As digestion proceeds, the splenocytes become smaller, and at the forty-eight-hour stage they are much reduced in size, some not much larger than normal.

Of the products of hemolysis of the pigeon blood after a single injection, little remains within the organs of the body and most is excreted through the kidneys within sixteen hours. In the spleen, the splenocytes have an increased amount of iron-containing substances, while the endothelial cells show, for the most part, very little. The comparatively small results seen within the phagocytic cells follow from the rapid reduction of the foreign blood corpuscles to particles of a very small size, and from the short time in which these fragments remain within the blood stream.

In this special experimental procedure, where cells and cell fragments are the stimulus to phagocytosis, the splenocytes are the first to act, and they continue to act as the main phagocytic agents.

LITERATURE CITED

- CARY, W. E. 1915 The fate of foreign erythrocytes introduced into the bloodstream of the rabbit. *Journal of Infectious Diseases*, vol. 17, pp. 432-6.
- HEINZ, R. 1901 Über Blutdegeneration and Regeneration. *Ziegler's Beiträge zur Path. Anat. u. Allgem. Path.*, Bd. 29, S. 299-404.
- HUNTER, W. 1901 *Pernicious anaemia*. London, Griffin & Co., 1901.
- MUIR, R. 1902 The reaction of the bone marrow and other leucocyte-forming tissues in infections. *Transactions of Pathological Society of London*, vol. 53, pp. 379-405.
- PATON, D. N., AND GOODALL, A. 1903 The spleen in relationship to the process of hemolysis. *Journal of Physiology*, vol. 29, pp. 411-439.
- ROUS, P., AND ROBERTSON, O. H. 1917 The normal fate of erythrocytes. *Journal of Experimental Medicine*, vol. 25, pp. 651-666.

PLATE 1

EXPLANATION OF FIGURES

The outlines were first drawn with the aid of a camera lucida at a magnification of 770 diameters. In the reproducing of the drawings the illustrations were reduced to 575 diameters. The sections from which the drawings were made were 4μ thick and stained in hematoxylin and eosin.

1 Normal spleen of rabbit, showing several splenocytes with inclusions. *Sp*₁, splenocyte with single inclusion, colored with blood pigment. *Sp*₂, splenocyte with several vacuole-like areas in its cytoplasm. *Sp*₃, splenocyte with inclusions of polymorphonuclears.

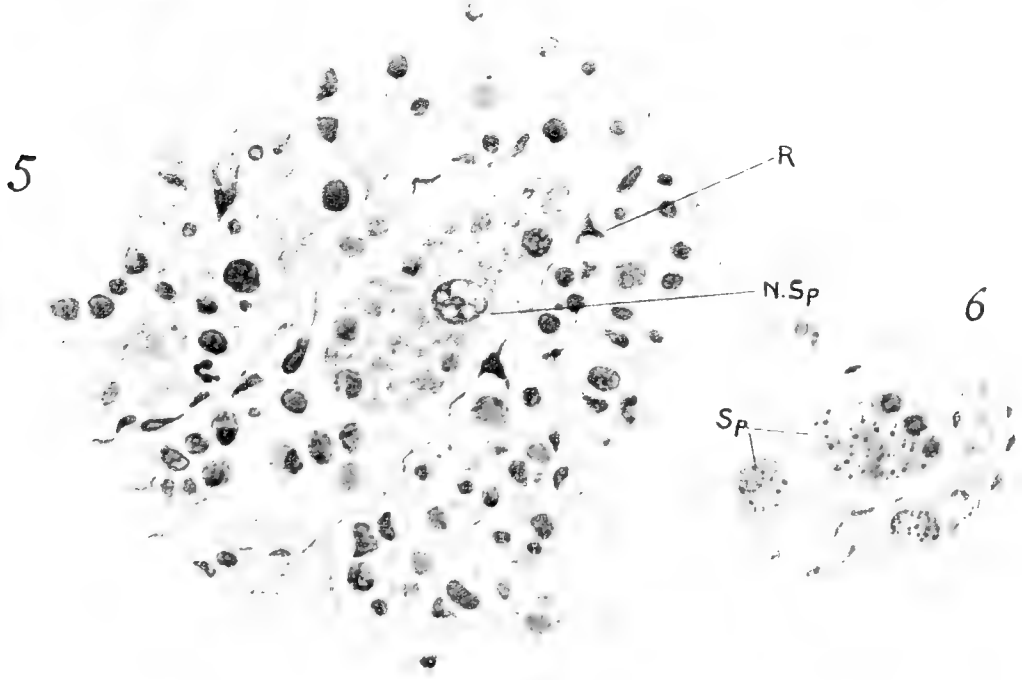
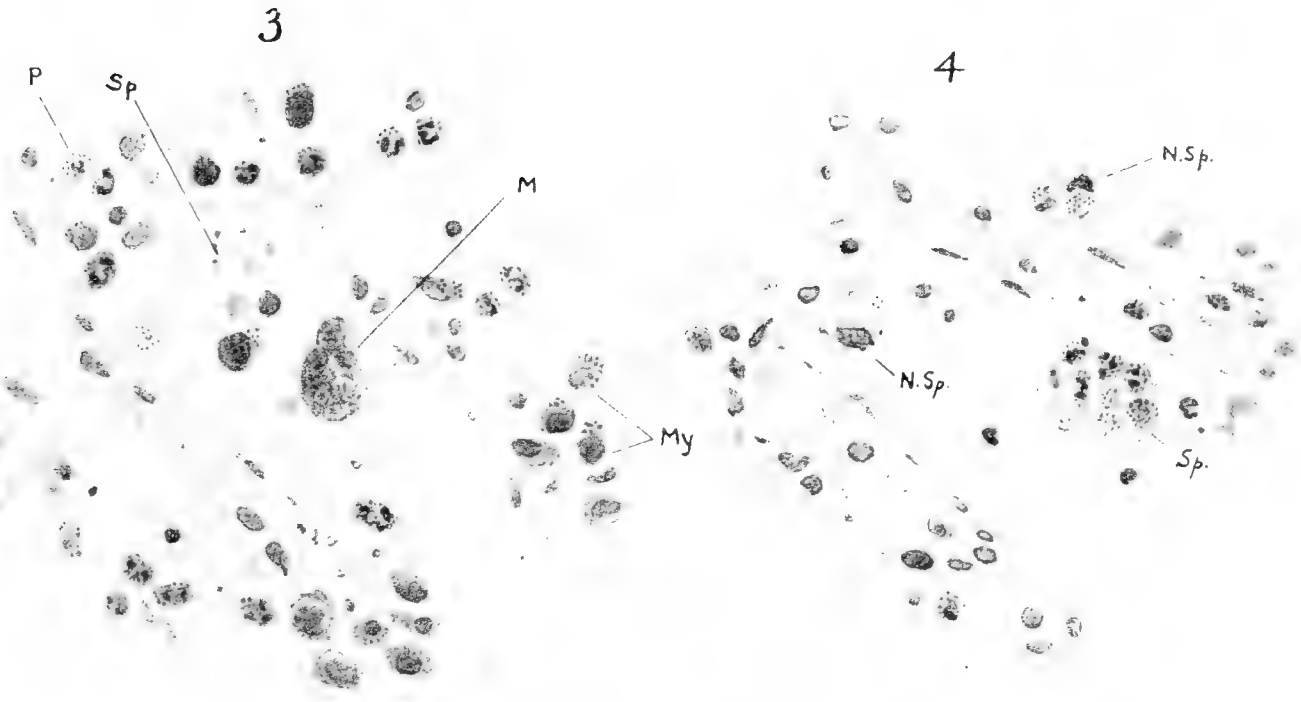
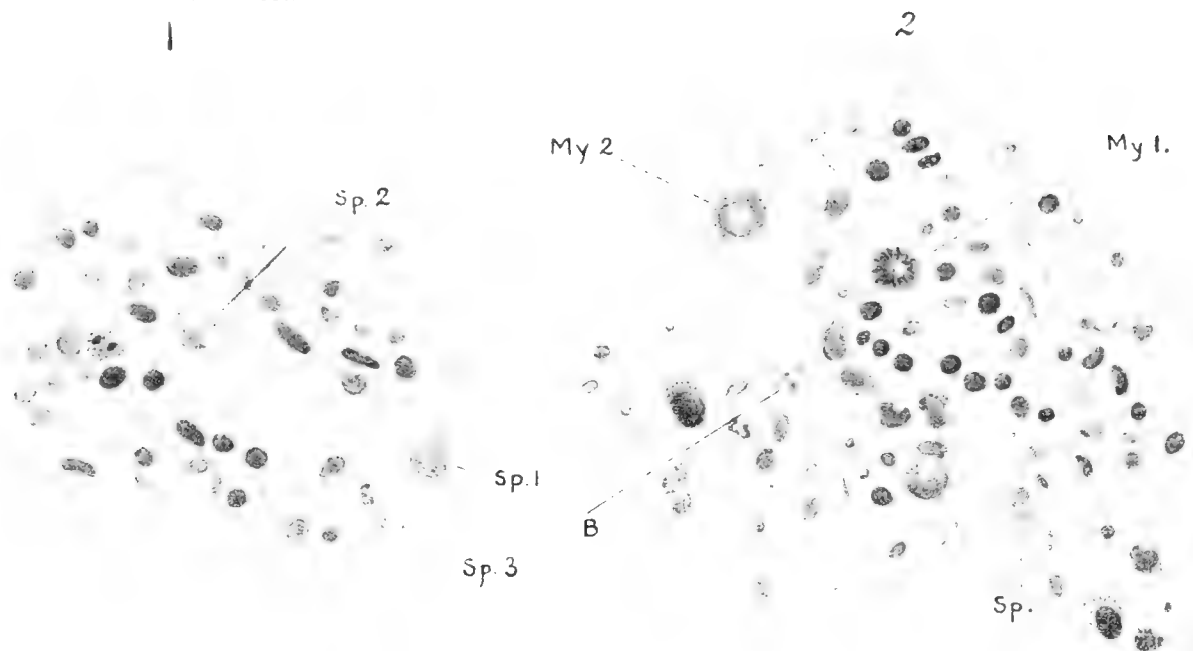
2 Spleen of rabbit, six hours after injection of pigeon corpuscles, showing myelocytes in the vascular channels. *Sp*, splenocyte with inclusion colored with blood pigment. *B*, extracellular mass of blood pigment. *My*₁, myelocyte showing stage of mitotic division, with chromosome-like masses of chromatin. *My*₂, myelocytes with pseudo-eosinophilic granules.

3 Spleen of rabbit, six hours after injection of pigeon corpuscles, showing myelocytes (*My*), pseudo-eosinophilic polymorphonuclear leucocytes (*P*), megacyte (*M*), splenocyte (*Sp*), and blood pigment, both intracellular and extracellular.

4 Spleen of rabbit, sixteen hours after injection of pigeon corpuscles, showing three splenocytes with cellular inclusions. *N.Sp.*, nucleus of splenocytes.

5 Spleen of same rabbit shown in figure 4. Shows a splenocyte greatly enlarged by reason of its numerous cell inclusions. *N.Sp.*, nucleus of splenocyte; *R*, reticulo-endothelial cells.

6 Spleen of rabbit, forty-eight hours after injection of pigeon corpuscles, showing two splenocytes with inclusions. The splenocytes (*Sp*) are now becoming smaller, as the digestion of the phagocytosed cells approaches the end of the process.



SUBJECT AND AUTHOR INDEX

- A**CTIVITY. Histological study of the spleen of the rabbit under heightened phagocytic..... 437
- Activity of its extensively vascularized connective tissue. The histology of the umbilical cord of the pig, with special reference to the vasculogenic and hemopoietic..... 1
- ADDISON, WILLIAM H. F.** Histological study of the spleen of the rabbit under heightened phagocytic activity..... 437
- Albino rat. Quantitative studies on the growth of the skeleton of the..... 237
- AREY, LESLIE B.** The origin, growth, and fate of osteoclasts and their relation to bone resorption..... 315
- B**LOOD in *Bufo halophilus* Baird and Girard. The early histogenesis of the..... 209
- Bone resorption. The origin, growth, and fate of osteoclasts and their relation to.... 315
- Bufo halophilus* Baird and Girard. The early histogenesis of the blood in..... 209
- Bulboventricular groove and origin of the interventricular septum. The development of the cardiac loop in the rabbit, with especial reference to the..... 29
- C**ARDIAC loop in the rabbit, with especial reference to the bulboventricular groove and origin of the interventricular septum. The development of the..... 29
- Cells of the frog's pancreas. Studies on the glandular..... 347
- Cerebri of the California ground-squirrel, *Citellus beechyi* (Richardson). The hypophysis..... 185
- Connective tissue. The histology of the umbilical cord of the pig, with special reference to the vasculogenic and hemopoietic activity of its extensively vascularized..... 1
- COOPER, HAROLD J.** The hypophysis cerebri of the California ground-squirrel, *Citellus beechyi* (Richardson)..... 185
- Cord of the pig, with special reference to the vasculogenic and hemopoietic activity of its extensively vascularized connective tissue. The histology of the umbilical.... 1
- CORNER, GEORGE W.** On the origin of the corpus luteum of the sow from both granulosa and theca interna..... 117
- Corpus luteum of the sow from both granulosa and theca interna. On the origin of the.. 117
- D**ONALDSON, HENRY H. Quantitative studies on the growth of the skeleton of the albino rat..... 237
- E**MBRYOS. The course of the Wolffian tubules in mammalian..... 423
- F**ATE of osteoclasts and their relation to bone resorption. The origin, growth, and..... 315
- Frog's pancreas. Studies on the glandular cells of the..... 347
- G**LANDULAR cells of the frog's pancreas. Studies on the..... 347
- Granulosa and theca interna. On the origin of the corpus luteum of the sow from both..... 117
- Groove and origin of the interventricular septum. The development of the cardiac loop in the rabbit, with especial reference to the bulboventricular..... 29
- Growth, and fate of osteoclasts and their relation to bone resorption. The origin..... 315
- Growth of the skeleton of the albino rat. Quantitative studies on the..... 237
- H**ANSON, FRANK BLAIR. The ontogeny and phylogeny of the sternum..... 41
- Hemopoietic activity of its extensively vascularized connective tissue. The histology of the umbilical cord of the pig, with special reference to the vasculogenic and..... 1
- Histogenesis of the blood in *Bufo halophilus* Baird and Girard. The early..... 209
- Hypophysis cerebri of the California ground-squirrel, *Citellus beechyi* (Richardson). The..... 185
- I**NTERNA. On the origin of the corpus luteum of the sow from both granulosa and theca..... 117
- Interventricular septum. The development of the cardiac loop in the rabbit, with especial reference to the bulboventricular groove and origin of the..... 29
- J**ORDAN, H. E. The histology of the umbilical cord of the pig, with special reference to the vasculogenic and hemopoietic activity of its extensively vascularized connective tissue..... 1
- L**EWIS, FREDERIC T. The course of the Wolffian tubules in mammalian embryos..... 423
- LILLIE RALPH DOUGALL. The early histogenesis of the blood in *Bufo halophilus* Baird and Girard..... 209
- Loop in the rabbit, with especial reference to the bulboventricular groove and origin of the interventricular septum. The development of the cardiac..... 29
- Luteum of the sow from both granulosa and theca interna. On the origin of the corpus..... 117
- M**AMMALIAN embryos. The course of the Wolffian tubules in..... 423
- MURRAY, HENRY A., JR.** The development of the cardiac loop in the rabbit, with especial reference to the bulboventricular groove and origin of the interventricular septum..... 29
- O**NTOGENY and phylogeny of the sternum. The..... 41
- Origin, growth, and fate of osteoclasts and their relation to bone resorption. The.... 315

- Origin of the interventricular septum. The development of the cardiac loop in the rabbit, with especial reference to the bulboventricular groove and..... 29
- Osteoclasts and their relation to bone resorption. The origin, growth, and fate of..... 315
- P**ANCREAS. Studies on the glandular cells of the frog's..... 347
- Phagocytic activity. Histological study of the spleen of the rabbit under heightened..... 437
- Phylogeny of the sternum. The ontogeny and..... 41
- Pig, with special reference to the vasculogenic and hemopoietic activity of its extensively vascularized connective tissue. The histology of the umbilical cord of the..... 1
- R**ABBIT under heightened phagocytic activity. Histological study of the spleen of the..... 437
- Rabbit, with especial reference to the bulboventricular groove and origin of the interventricular septum. The development of the cardiac loop in the..... 29
- Rat. Quantitative studies on the growth of the skeleton of the albino..... 237
- Resorption. The origin, growth, and fate of osteoclasts and their relation to bone... 315
- S**AGUCHI, S. Studies on the glandular cells of the frog's pancreas..... 347
- Septum. The development of the cardiac loop in the rabbit, with especial reference to the bulboventricular groove and origin of the interventricular..... 29
- Skeleton of the albino rat. Quantitative studies on the growth of the 237
- Sow from both granulosa and theca interna. On the origin of the corpus luteum of the..... 117
- Spleen of the rabbit under heightened phagocytic activity. Histological study of the..... 437
- Squirrel, *Citellus beechyi* (Richardson). The hypophysis cerebri of the California ground..... 185
- Sternum. The ontogeny and phylogeny of the..... 41
- T**HECA interna. On the origin of the corpus luteum of the sow from both granulosa and..... 117
- Tissue. The histology of the umbilical cord of the pig, with special reference to the vasculogenic and hemopoietic activity of its extensively vascularized connective..... 1
- Tubules in mammalian embryos. The course of the Wolffian..... 423
- U**MBILICAL cord of the pig, with special reference to the vasculogenic and hemopoietic activity of its extensively vascularized connective tissue. The histology of the..... 1
- V**ASCULOGENIC and hemopoietic activity of its extensively vascularized connective tissue. The histology of the umbilical cord of the pig, with special reference to the..... 1
- W**OLFFIAN tubules in mammalian embryos. The course of the..... 423

MBL WHOI Library - Serials



5 WHSE 02078

15850

