



Digitized by the Internet Archive  
in 2009 with funding from  
Ontario Council of University Libraries









ed. me  
A

799

13

# THE ANATOMICAL RECORD

## EDITORIAL BOARD

IRVING HARDESTY  
Tulane University

WARREN H. LEWIS  
Johns Hopkins University

CLARENCE M. JACKSON  
University of Minnesota

CHARLES F. W. McCLURE  
Princeton University

THOMAS G. LEE  
University of Minnesota

WILLIAM S. MILLER  
University of Wisconsin

FREDERIC T. LEWIS  
Harvard University

FLORENCE R. SABIN  
Johns Hopkins University

GEORGE L. STREETER  
University of Michigan

G. CARL HUBER, Managing Editor  
1330 Hill Street, Ann Arbor, Michigan

VOLUME 13  
JUNE-DECEMBER, 1917

PHILADELPHIA  
THE WISTAR INSTITUTE OF ANATOMY AND BIOLOGY

QL  
801  
A45  
v. 13  
cop. 3



# CONTENTS

## No. 1 JUNE

H. E. JORDAN. Studies on striped muscle structure. III. The comparative histology of cardiac and skeletal muscle of scorpion. Twenty-one figures .....	1
MARGARET REED LEWIS. The effect of certain vital stains upon the development of the eggs of <i>Cerebratulus lacteus</i> , <i>Echinorachnius parma</i> and <i>Lophius piscatorius</i> .....	21
ALBERT M. REESE. The blood of alligator <i>Mississippiensis</i> . Eight figures .....	37
S. B. GRANT. A persistent superior vena cava sinistra in the cat transmitting coronary blood. One figure .....	45
ROLLO E. McCOTTER. The vomero-nasal apparatus in <i>Chrysemys punctata</i> and <i>Rana catesbiana</i> . Seventeen figures .....	51

## No. 2 JULY

HOMER G. FISHER. Histological structure of the retractor penis muscle of the dog. Four figures (two plates) .....	69
WARO NAKAHARA. Preliminary note on the nuclear division in the adipose cells of insects. Eleven figures .....	81
J. T. PATTERSON AND C. G. HARTMAN. A polyembryonic blastocyst in the opossum. One text figure and two plates .....	87
R. M. STRONG. Some observations on the origin of melanin pigment in feather germs from the Plymouth Rock and Brown Leghorn fowls. Six figures .....	97
GEORGE W. CORNER. Maturation of the ovum in swine .....	109
LLOYD R. REYNOLDS. Hyperphalangism accompanied by supernumerary epiphyses and muscular deficiencies. Twelve figures .....	113
IVAN E. WALLIN. An inexpensive projection apparatus. Three figures .....	127

## No. 3 AUGUST

RALPH D. LILLIE. Variations of the canalis hypoglossi .....	131
MARY T. HARMAN. A case of superfetation in the cat. Three figures (two plates) .....	145
Laboratory Apparatus. I. A simple electric thermo-regulator. H. S. BURT. One figure. II. An automatic air pressure valve. III. A laboratory timing clock. One figure. AUGUSTUS F. SCHARFF. ....	159
MARSH PITZMAN. Some suggested changes in nomenclature .....	165
CHARLES EUGENE JOHNSON. On the development of the liver in the genus <i>Citellus</i> . Four figures .....	169
NEWTON MILLER AND JAMES S. GODFREY. A note on the anastomosis of arteries and veins in a cat. One figure .....	177

## No. 4 SEPTEMBER

ALBERT M. REESE. The anatomy of a two-headed lamb. Eight figures .....	179
FLORENCE R. SABIN. Preliminary note on the differentiation of angioblasts and the method by which they produce blood-vessels, blood-plasma and red blood-cells as seen in the living chick .....	199

J. A. MYERS. Studies on the mammary gland. III. A comparison of the developing mammary glands in male and female albino rats from the late fetal stages to ten weeks of age. Seven figures	205
H. E. RADASCH AND J. L. FANZ. An adjustable slide basket. Five figures	227

## No. 5 OCTOBER

J. A. HOWELL. An experimental study of the effect of stress and strain on bone development. Seven figures	233
ALICE M. BORING AND RAYMOND PEARL. Sex studies. IX. Interstitial cells in the reproductive organs of the chicken. Six figures	253
LESLIE B. ARDY. Phagocytosis by osteoclasts. Four figures	269
S. R. WILLIAMS AND R. W. RAGGIO. The anatomy of a double pig ( <i>Syncephalus thoracopagus</i> ). Seven figures	273
ROGERS K. OLIVER. Membranes of the right iliac region	281
CARLTON GILLASPIE AND HOWARD HULL HEUSTON. Detailed study of a monster with craniorachischisis and other anomalies. Six figures	289
IVAN E. WALLIN. A teaching model of a 10 mm. pig embryo. Three figures	295
EDWARD CARROLL DAY. Two conveniences for the laboratory. Three figures	299
MARCUS W. LYON, JR. An hereditary case of congenital absence of one kidney. One figure	303

## No. 6 NOVEMBER

G. CARL HUBER. On the morphology of the renal tubules of vertebrates. Twenty-two figures	305
G. CARL HUBER AND ARNOLD H. EGGERTH. On the morphogenesis of the papilla foliata of the rabbit. Six figures	341
WARREN H. LEWIS AND MARGARET R. LEWIS. The duration of the various phases of mitosis in the mesenchyme cells of tissue cultures	359
PAUL B. EATON. The coeliac axis. One figure	369
F. POYALES. Desarrollo de los músculos oculares recto externo y recto interno, en el embrión humano. Diez figuras	375
JOHN A. KITTELSON. The postnatal growth of the kidney of the albino rat, with observations on an adult human kidney	385
R. S. GUTSELL. An anomalous case of blood formation in the connective tissue of the sciatic nerve in man. Six figures	409
P. E. LINERACK. A scheme for drawings in a course in embryology. Three figures	419

## No. 7 DECEMBER

MARY T. HARMAN. Another case of gynandromorphism. One figure	425
J. M. AYRES GALVAO. The finer structure of the ciliary ganglion of Ophidians	437
A. DE LEMOS TORRES. On the cartilaginous tissue of the heart of Ophidia	443
J. MOREIRA DA ROCHA. Staining of adult cartilage by Lundwall's methods	447
JAMES R. CASH. On the development of the lymphatics in the heart of the embryo pig	451
RETH RAND. On the relation of the head chorda to the pharyngeal epithelium in the pig embryo—a contribution to the development of the bursa pharyngea and the tonsilla pharyngea. Ten figures	465
SAMUEL RANDALL DETWILER. On the use of Nile blue sulphate in embryonic tissue transplantation	493

# STUDIES ON STRIPED MUSCLE STRUCTURE

## III. THE COMPARATIVE HISTOLOGY OF CARDIAC AND SKELETAL MUSCLE OF SCORPION<sup>1</sup>

H. E. JORDAN

*Department of Anatomy, University of Virginia*

TWENTY-ONE FIGURES

### I. INTRODUCTION

The present investigation deals with the striped muscle of the Florida scorpion,<sup>2</sup> including the post-abdominal ('tail'), pre-abdominal, cephalo-thoracic, leg, and heart muscle of both the adult and the new-born. In the latter material occur important developmental stages, which throw valuable light upon the more involved adult structure.

As was to be expected the striped muscle of scorpion is very similar to that of *Limulus*, and accordingly conforms more closely to the vertebrate type of striped muscle than to the arthropod type as exemplified, for example, by the sea-spider, *Anopoldactylus lentus*, already described, and by certain insects.

Apart from being, as far as I am aware, the first detailed microscopic study of this muscle, the chief value of this investigation inheres in the information it yields, by reason of the greater

<sup>1</sup> The two earlier studies of this series concerned the muscle of the king crab (Proc. Am. Assoc. Anat., Anat. Rec., Jan., 1916; complete paper in a forthcoming publication by the Carnegie Institution of Washington), and that of the sea-spider (Anat. Rec., vol. 10, pp. 493-508, 1916). The pertinent literature is fully reviewed in these papers, and a bibliographic list included, and will not here be repeated in detail.

<sup>2</sup> This material was very kindly furnished alive by Dr. William Patten, of Dartmouth College. It was variously fixed in the strong chrom-aceto-osmic solution of Flemming, and in the alcohol-nitric-acid solution of Zimmermann, and stained by the Heidenhain iron-hematoxylin method, in certain cases followed by Van Gieson's stain.

clearness in respect of some important details in this tissue, regarding the minute structure of striped muscle in general. These details concern especially: (a) the nature of the sarcolemma; (b) the relation of the telophragma to the sarcolemma and to the nuclear wall; (c) the mode of muscle growth and development, both with respect of the multiplication of the nuclei, and the increase in the number of the myofibrils; (d) the decisive evidence in contravention of the interpretation of striped muscle structure in terms of 'muscle cells' (Apathy; Baldwin) and extra-cellular myofibrillae, in analogy with connective tissue; and (e) the relation between the muscle fibrils and the tendon fibrils.

The cardiac muscle of scorpion and of *Limulus* conforms with vertebrate heart muscle in its syncytial structure, in the more or less regular radial arrangement of the myofibril bundles (lamellae) and in the definite character of the relatively less complex cross-stripping. The skeletal muscle also of these forms agrees with vertebrate skeletal muscle with regard to the major stripes, and in the absence (or extreme tenuity) of the mesophragma and the necessary disk (N-disk) of Engelmann and Rollet, conspicuous in certain insect muscles. However, the cardiac and skeletal muscles of these forms are, in respect of minute structure, somewhat more closely similar than is the case in vertebrates generally, possibly the result of relatively closer functional similarity. Whether the above-named similarities between arachnid and vertebrates' muscles have genetic significance, as would seem probable on the basis of many other observations on other structures enumerated by Patten,<sup>3</sup> or whether they indicate only functional equivalence remains an open question.

## II. DESCRIPTIVE

### *a. Skeletal muscle of adult*

The skeletal muscle fibers are long multinucleated elements tapering towards their extremities. They vary greatly in diameter in different regions of the body. Those of the post-

<sup>3</sup> Patten, W. The Evolution of the Vertebrates and their Kin. Blakiston, Philadelphia, 1912.

abdomen are very stout and of irregular form in cross-section (fig. 1 a and b); elsewhere in the body the fibers are of much smaller girth, more uniform in size and of an approximately circular outline in cross-section. In respect of minute structure the skeletal striped muscle fibers of the several regions of the body are essentially identical. Hence the description may confine itself largely to the coarser fibers of the post-abdomen.

In figure 1 *a* and *b* are illustrated two larger and more irregular fibers, in transverse section. The vesicular nuclei are located centrally within an irregular core of finely granular, very delicately reticular, sarcoplasm. Peripheral to this is a wide border in which the myofibrils are arranged in the form of lamellae radially disposed. Many of these lamellae show a peripheral split of greater or less depth, giving to these lamellae a Y or V shape. Certain lamellae show a double peripheral splitting. This condition most probably is a growth phenomenon, increase in the number of the lamellae, and the size of the fiber, being attained by a radial longitudinal fission of parent lamellae, as is the case in growing skeletal fibers of certain teleost fishes, e.g., the rain-bow trout. Certain fibers show a grouping of the lamellae into bundles, suggestive of Kölliker's columns (Cohnheim's areas, in cross-section; fig. 1 *b*) of mammalian skeletal muscle. The irregular form of the fiber in cross-section explains the variation in width of fibers as seen in longitudinal sections.

The fibers are invested by a distinct sarcolemma, which varies in different fibers between a relatively coarse membrane and one relatively delicate. Closely adherent to the sarcolemma superficially is a more or less delicate and wide-meshed fibrillar connective tissue, with smaller more elongate and generally more chromatic nuclei. After Van Gieson's stain the connective tissue (perimysium) is colored red, while the sarcolemma remains unstained. After prolonged staining in a solution concentrated with acid fuchsin, both the telophragmata (ground membranes; z-membranes) and the sarcolemma stain pink or red.

In longitudinal sections the nuclei are seen to be elongate elements with irregular sinuous or serrated contour (figs. 2 and 3). Such sections, properly stained with iron-hematoxylin, show a

distinct cross-striation essentially like that of vertebrate voluntary striped muscle. The striations of the relaxed fiber include the lighter J-disk, the darker Q-disk, and the granular telophragma. There is not the slightest indication of an additional mesophragma (M-membrane) and the accessory disk of Engelmann and Rollet (N-line). The granular telophragma stains relatively intensely. The granules represent swellings at the points where the myofibrils are attached to the telophragma. Centrally the telophragma passes through the sarcoplasmic non-fibrillar core and becomes intimately attached to the tips of the nuclear serrations. Within the core the telophragma appears non-granular and stains less intensely (fig. 2). Peripherally the telophragma makes a close union with the sarcolemma (fig. 3). This extra-fibrillar portion of the telophragmata is also non-granular and less deeply staining. The sarcolemma is usually festooned between successive telophragmata, probably a fixation artifact. The serrated character of the nuclear wall may be in part similarly an artifact.

Figure 3, at the left, shows a peculiar condition frequently met with. Here the sarcolemmas of two adjacent fibers have become blended, and the common membrane has been thrown into a zig-zag form, the apices with their attached telophragmata alternating in the apposed fibers. Such result is made possible by reason of a local paucity or practical absence of inter-fiber connective tissue allowing thus of a fusion of the adjacent sarcolemmas. The process of such fusion can be pictured by reference to illustration figure 4, which represents the tapering end of a fiber and part of an adjacent fiber. Here the connective tissue between the two fibers is relatively abundant and closely adherent to the highly festooned sarcolemmas. If we imagine the connective tissue removed, and the adjacent sarcolemmas thus brought together so that the crest of a festoon on one side fits into the trough between successive festoons in the apposed sarcolemma, then by a blending of the two sarcolemmas, and under the opposed lateral tractions of the attached telophragmata, the condition shown in figure 3 would become realized. Certain steps in such a process, especially the one where a double

sarcolemma without intervening connective tissue occurs, can actually be traced in the sections. Similar conditions have been described in mammalian heart muscle (Heidenhain, 'Plasma und Zelle').

*b. Skeletal muscle of the new-born*

In the new-born scorpion not all of the muscles are equally well developed. Those of the cephalo-thorax, abdomen and legs seem in general functionally mature; though the oval, regularly contoured, and more chromatic character of the nuclei (figs. 5 and 6) indicate a lesser degree of progressive differentiation. Certain fibers in the region of the head are in the early stages of transformation of myoblasts into multinucleated fibers.

Figure 5 illustrates a lightly-stained mature fiber of this stage, with a festooned sarcolemma closely adherent to which is a fibrillar connective tissue. Figure 6 is more deeply stained and thus shows a more conspicuous Q-disk and the granular telophragmata. This fiber is moreover distorted, apparently by a force causing compression along the longitudinal axis. The folding or bending thus produced caused an alternate bulging on opposite sides, and the bend and the bulge are always along the levels of the telophragmata. This phenomenon demonstrates a firm connection between myofibrils and the telophragmata. It demonstrates also the absence of a mesophragma of a structure similar to that of the telophragma.

In figure 7 is illustrated a mid-phase of contraction. Here a new disk, the H-disk (of Hensen) becomes conspicuous. The H-disk is an incident of contraction. Figure 8 illustrates the completely contracted condition, in which darker contraction bands alternate with lighter disks of approximately equal or somewhat greater longitudinal width.

Figure 9 represents a contracted fiber upon which is superposed terminally a traction stress. Under such conditions a flexible mesophragma (M-membrane) if present, but supposedly ordinarily invisible in vertebrate striped muscle because of its alleged tenuity, should be brought into view by reason of a thickening after release of lateral tension. Such was the case,

is previously described, in the leg muscle of the sea-spider. But in the scorpion striped muscle no mesophragma becomes discernible.

In figure 10 is shown the region of transition from a small fiber of the jaw to its connecting tendon. The myofibrils and tendon fibrils are in direct continuity, the latter apparently representing modification products of the former. The tendon stains more deeply than the muscle in iron-hematoxylin preparations, and faintly red after Van Gieson's stain. The cross stripes fade out at the level of transition from the muscle to the tendon.

In the head region certain fibers can be seen representing early stages in the metamorphosis of a myoblast into a long multinucleated striped fiber. Figure 11 illustrates a myoblast with four nuclei, the next to the lowermost one in process of amitotic division. The lower extremity shows also a transition to the developing tendon. The sarcolemma is relatively delicate. The myofibrils are relatively compact, and give to the cell a relatively deeper color. No cross striations have yet appeared. Such arise first terminally and appear progressively towards the center. The first striations are the telophragmata; the Q-disks appear only some time later. The nuclei multiply by direct division. Coincident with the nuclear multiplication and the appearance of striations, the fiber elongates. During this process fibers occur in which as many as twenty nuclei may be counted in close series in a relatively short extent of the central sarcolemmic core.

Figure 12 shows two adjacent young fibers from the anterior region of the cephalo-thorax. The peripheral lamellae of myofibrils occupy less than a third of the radius. A few lamellae may be seen in process of radial longitudinal splitting, by which event the lamellae are increased in number and the fiber grows in diameter.

### *c. Cardiac muscle of the adult*

The heart tube consists of a single layer of muscle fibers (trabeculae), invested peripherally by a layer of connective



tissue (pericardium). Both the scorpion and the *Limulus* heart lack an endothelial lining. The myocardial fibers are for the most part arranged in an oblique circular direction. The original fibers have anastomosed in the adult heart so as to form a continuous, branching, spirally disposed, syncytial muscular membrane. The fibers of this membrane vary in the degree of compactness and the diameter of their cross-section. In a medial longitudinal section of the heart tube groups of from three to four or more, compacter cross-sections alternate with a similar number of looser cross-sections. In the transverse direction also the more compact portions of the fiber alternate with the loose portions due to the spiral arrangement of the trabeculae. And in paratangential section, the compacter portions may be seen to pass by gradual stages into the looser portions of the opposite side. It appears probable that the compacter portions represent the extremities of the original myoblasts. According to this interpretation the derivatives of an original myoblast would extend for about two and one-half turns around the adult heart.

Figure 13 illustrates a transverse section through a more compact portion of a myocardial fiber. The nuclei are located centrally in a coarsely granular sarcoplasm. The delicate sarcolemma bounds a peripheral layer of similar construction. Between the peripheral and the central granular sarcoplasmic areas, the plates of myofibrils are radially disposed, and grouped into smaller bundles which anastomose internally, thus giving to the heart musculature a double-syncytial character, as in *Limulus*. A few of the lamellae are split peripherally. At the lower pole of the drawing, the point where the fiber curves from a lateral to a ventral position, the lamellae are cut very obliquely.

The heart muscle fiber in longitudinal section is practically identical with the skeletal muscle fiber (figs. 14 and 15). This very close similarity between heart and skeletal muscle fiber was striking also in the case of *Limulus*. In figure 16 is shown a bundle of fibrils in extreme contraction. The change in shape of the nucleus, and the finely serrated character of its wall, as compared with conditions in figure 14, demonstrate a very firm union between the telophragmata and the nuclear membrane.

*d. Cardiac muscle of the new-born*

The heart tube of the new born scorpion is very like that of the adult, except that the syncytium is less compact, the fibers are smaller and more regular in cross-section, the nuclei are stouter, have a more regular contour, and are somewhat more chromatic, indicating a lesser degree of differentiation; and the myofibril lamellae are relatively few in number and more regularly disposed radially without any segregation into smaller bundles (fig. 17). A few lamellae are undergoing a longitudinal fission.

As indicated by the form of the nuclei, different portions of the myocardium are at different stages of differentiation. In the younger portions, the nuclei are actually multiplying by direct division (fig. 18); in other portions, practically adult conditions obtain (fig. 19). Certain portions have suffered contraction, imposed extraneously possibly by the coagulation effect of the fixing fluid; in such portions the nuclei are strikingly modified (fig. 20), in that they are shortened longitudinally, caused to widen transversely, and the peripheral serrations are greatly accentuated. Also the telophragmata are less widely spaced in such regions. The conditions shown in figure 20 can be readily conceived as derived from figure 19, where also four serrations with attached telophragmata are present, by compression exerted at right angles to the long axis of the fiber. Figure 21 illustrates a similar condition, and shows besides a stage in the direct division of the larger nucleus; and a mass of nucleated connective tissue is shown at the right. The plane of nuclear division passes between successive serrations, which brings it to pass that the daughter nuclei retain their connection with the telophragmata.

## III. DISCUSSION AND CONCLUSIONS

One of the most striking facts regarding the scorpion muscle, is also regarding the *Limulus* muscle which it very closely resembles is the essential identity in microscopic structure between the cardiac and the skeletal muscle. The axial location of the nuclei, the radial lamellar arrangement of the myo-

fibrils, and the relative simplicity of the striations all indicate a relatively low degree of differentiation. This circumstance is probably a reflection of a relatively low functional requirement and a coincident approximate similarity of action. Muscular movement is in both instances leisurely, and the meagre requirements are presumably satisfactorily met by a relatively simple structural condition.

Furthermore, the minute structure of the scorpion muscle resembles closely vertebrate striped muscle (especially cardiac muscle; note figs. 1 to 3). As a subdivision of the arthropods the muscle of the arachnids might be expected to resemble closely that of insects. But there is not the slightest indication of the mesophragma and the accessory disk of Engelmann and Rollet (N-disk), conspicuous in certain insect muscles. The fact that the mesophragma is not discernible in a fiber like the one shown in figure 9, where the contracted fiber has been stretched terminally, leads me to conclude that a mesophragma is actually absent in this muscle; and that this membrane is characteristic only of very highly differentiated fibers. Moreover if a mesophragma occurred, of the same nature as the telophragma as is claimed by Heidenhain, we should expect, under the conditions represented in figure 6, a double series of foldings, that is, at the levels of the alleged mesophragmata as well as at those of the telophragmata. Whether the similarity here also, that is, between the muscle structure of certain arachnids (scorpion; *Limulus*) and vertebrates (as is more probably the case as between cardiac and skeletal muscle of these forms) signifies likewise only a functional equivalence, or whether it has any phylogenetic significance, — or possibly both — is a question whose further consideration lies outside the scope of this investigation. All that need be said by way of interpretation is that these additional facts harmonize with Patten's theory of the arachnid origin of Vertebrates.<sup>4</sup> Moreover, both the scorpion

<sup>4</sup> Among the large body of evidence presented in support of this theory Patten noted that 'The arachnids resemble the vertebrates in more general ways, as in the minute structure of cartilage, muscle, nerves, digestive and sexual organs.' (p. XVIII, Historical Sketch); but he nowhere illustrates or describes in detail the microscopic structure of the arachnid striped muscle.

and *Limulus* myocardia are syneptial in structure, very like the myocardium of vertebrates; but the scorpion cardiac musculature is only one fiber in thickness, while that of *Limulus* is many fibers thick; and both musculatures practically lack longitudinally disposed fibers.

The observations above recorded regarding the relation of the telophragmata to the nuclear wall, when taken in connection with similar observations in *Limulus* muscle and that of cat and mouse, would seem to definitely dispose of any further profitable attempt to interpret striped muscle in terms of 'muscle cells,' and extra-cellular myofibrillae. The close union between the telophragmata and the myofibrils, sarcolemma, and serrations of the nuclear membrane, above described, demonstrate that the fiber is the cellular unit. There can remain no longer any question of a smaller definitive cellular element. Moreover, the history of the development of the myoblast disproves such interpretation. The myoblast is a stout fusiform cell, enveloped by a membrane which becomes the definite sarcolemma and supplied with a nucleus which divides repeatedly by amitosis. The cell becomes measurably elongated, showing first more and more conspicuously the telophragmata and then the Q-disks appearing in a medial progression, the simple myoblasts thus becoming transformed into the definite multinucleated striated muscle fiber.

Another interesting similarity between this muscle and that of vertebrates concerns the manner of growth. This is by radial longitudinal splitting of the myofibril-lamellae, a process substantially identical with that occurring in embryonic fibers of certain teleost fishes, e.g., the rain-bow trout.

This radial disposition of the myofibril-lamellae resembles also the condition in the adult heart muscle of vertebrates. But in the latter the fibrillar constitution of the lamellae is readily discernible in cross-sections of the fibers. In the case of the scorpion and *Limulus* skeletal fibers the finer fibrillar condition

of the lamellae is much less conspicuous and occasionally quite impossible to recognize in transverse sections; in the cardiac muscle of these forms the myofibrils are less compactly aggregated into lamellae, and in consequence are easier to distinguish. The condition in the post-abdominal muscles approaches that described for certain insect wing-muscle, e.g., *Libella*, in which, according to E. Holmgren<sup>6</sup> the radial lamella cannot be further analyzed into constituent fibrillae. But when one observes the scorpion muscle very carefully, especially in thin longitudinal section under the oil-immersion lens, one may satisfy himself that the lamellae here actually do consist of fine myofibrillae, some of which appear to cross between adjacent lamellae. Moreover when the coarser myofibrils are carefully followed for some distance, they may be seen to resolve into still finer fibrillae, to the limit of visibility. The internal fibrillar (lamellar) constitution of this muscle fiber thus appears to be of a synectial character, and the evidence with respect to the successively finer resolution of the lamellae into more and more delicate myofibrillae offers support to Heidenhain's protomere hypothesis of histologic structure as applied to striped muscle, namely, that the ultimate vital units are metamicroscopic fibrils.<sup>7</sup>

This material shows also very clearly that the tendon is a derivative of the myofibrils. Myofibrils and tendon fibrils are in direct continuity; the sarcolemma apparently blends with the more peripheral tendon fibrils.

A feature of *Limulus* heart muscle which brought still closer the similarity between its structure and vertebrate cardiac muscle was a simple type of intercalated disk. Such disks could not be detected in the scorpion heart. This does not necessarily mean that they were not actually present somewhere, nor that they could never appear in any heart of any age or any condition of functional strain. Such a statement could only be made with approximate certainty if a complete heart tube of an old specimen were carefully searched, which has not been done. Even

<sup>6</sup> See Heidenhain, M. 'Plasma und Zelle,' p. 581, 1911.

<sup>7</sup> Heidenhain, M. 'Plasma und Zelle,' p. 582.

in adult *Limulus* such disks are comparatively rare. If my interpretation, which is supported by a number of suggestive observations, and is in harmony with the actual histologic facts, is correct, namely, that these disks represent irreversible contraction bands, possibly the result of a local impairment of function, then one would perhaps hardly expect such disks ordinarily in the scorpion heart; but they might possibly occur sparsely in aged specimens.

The blending of the sarcolemmas of two adjacent fibers, and the ensuing alternation of the tips of the resulting zig-zag membrane, and of the attached telophragmata calls for discussion. It is interesting to note that essentially identical structures occur in vertebrate and human heart muscle.<sup>8</sup> The interpretation which at once suggests itself regarding this alternation of structure between the apposed surfaces, is that the adjacent fibers have been drawn slightly in opposite directions by the tensions exerted during development or function. But Heidenhain calls attention to the fact regarding vertebrate cardiac muscle, in opposition to this interpretation, that the numerical relationship of the serrations and the attached telophragmata on the two surfaces of the common sarcolemma is always as  $n$  to  $n - 1$ ; and he is led to the explanation of this phenomenon as the result of a spiral distortion of a fiber about a longitudinal axis.

The simpler conditions in the scorpion skeletal muscle lend support to Heidenhain's hypothesis. In the case illustrated in part in figure 3 the conditions are as follows: the two fibers are from the peripheral region of a post-abdominal segment; the fiber at the left comes to a point above, the fiber at the right terminates similarly below; above and below near the termini of the pointed ends the telophragmata of the two fibers are at the same level; between these points, the telophragmata of the adjacent fibers alternate in such a manner as to leave fifteen sarcomeres on the left and only fourteen on the right. The pointed terminus of the two fibers at the opposite end of this field may be accounted for by the assumption of a spiral twisting about a

<sup>8</sup> Heidenhain, M. 'Plasma und Zelle,' pp. 541 to 544; 615 to 617.

common axis, producing thus in a longitudinal section the asymmetrical alignment of the opposite sarcomeres, according to the conception of Heidenhain. It should again be noted that there is with respect of this phenomenon also a very close similarity between scorpion skeletal muscle and mammalian heart muscle.

One of the most puzzling and interesting features of the developing scorpion muscle, both skeletal and cardiac, concerns the multiplication of the nuclei by the direct method of division. Not a single mitotic figure appears in the muscle tissue of this form; but abundant instances of amitotic nuclear division may be seen. The plane of division is always between successive points of attachment of the telophragmata, so that the daughter nuclei remain suspended by these membranes. But in this connection it should be noted that in the earlier stages of metamorphosis of the myoblast into the muscle fibers, when nuclear multiplication is most active, telophragmata are not present, at least not in such complete form as to be recognizable under the ordinary magnification. Such device would seem to aid, by reason of the absence of possible restraining membranes, the intensive and rapid multiplication of the nuclei, necessitated by the metabolic requirements of the young, rapidly differentiating muscle fiber.

This material would seem to offer a favorable opportunity for the study of the underlying causes of amitotic nuclear division as opposed to karyokinetic division. This may constitute the basis of a future investigation. Since the technic here employed failed to disclose a centrosome or archoplasmic substance, it must remain uncertain whether such is actually lacking or whether it simply was not visibly preserved. In consequence no final argument can be made on the basis of this material for or against the hypothesis that amitosis is the consequence of some factor which puts a restraint upon the activity of the centrosome substance in a growing tissue. However, in the certain absence of pathologic factors here, it might with some reason be assumed that the possible restraining agent might be lack of relatively adequate nutriment, caused by the rapidity of growth

and differentiation of the myoblast, and thus interfering with centrosomal activity. However this may be, it seems clear, in view of the double function of the nucleus, namely, as an organ in control of constructive metabolism and of specific heredity, that the requirements of growth and differentiation are amply met by the increase and distribution of nuclear materials by direct division. The cause of amitosis in this muscle may reside in an economic adaptation to essential needs, rather than in an indirect restraining influence upon the activities of the karyokinetic mechanism.

The regular reticular system of telophragmata and sarcolemma is so conspicuous and robust that one feels inclined at first sight to interpret the whole mechanism as a connective tissue derivative. And the absence—whether apparent or real is uncertain—of the telophragmata in the myoblast and in early stages of transformation into the muscle fiber, gives further strength to this inclination: as also the fact of the very close union between connective tissue and sarcolemma. But two chief facts negate any such interpretation: (1) the intimate union between telophragmata and the nuclear membrane; (2) the difference in staining reaction to Van Gieson's solution of the connective tissues and the sarcolemma; and the similar lack of affinity of the sarcolemma and the telophragmata for the acid fuchsin. The first point is in harmony with the derivation of the telophragmata from the cytotreticulum of the myoblast, by process of condensation and growth and a rearrangement into rectilinear meshes, somewhat according to the suggestion first made by MacCallum.<sup>2</sup> Similarly, the sarcolemma is the adult representative of the original cell membrane.

The decided festooning of the sarcolemma in this material raises the question of the causal factor in the production of this condition. Huber<sup>3</sup> suggests on the basis of his studies of rabbit voluntary striped muscles in teased preparation that 'the

<sup>2</sup> MacCallum, J. B. On the histology and histogenesis of the heart muscle cell. *Anat. Anz.*, Bd. 13, 1897.

<sup>3</sup> Huber, G. Carl. On the form and arrangement in fasciculi of striated voluntary muscle fibers. *Anat. Rec.*, vol. 11, p. 166.



festooning of the sarcolemma, described by certain authors, may perhaps be brought in relation with the ends of myofibrils which do not extend the entire length of the muscle fiber. It is impossible for me to speak with certainty regarding the length of the separate myofibrils in the scorpion or the *Limulus* muscle. One gets the very clear impression from a study of thin longitudinal sections that the large myofibrils are divisible into fine fibrillar components, and that the entire fibrillar constituent forms a loose meshwork or syncytium. On this basis one might perhaps legitimately conclude that many of the myofibrils at least do not extend the entire length of a fiber. But the rather intimate interconnection of the entire fibrillar component of the fiber, coupled with the fact of the continuity of the terminal myofibrils and the sarcolemma with the tendon fibrils, makes difficult the application of Huber's suggestion in regard to the formation of the festoons of the sarcolemma. The explanation that most strongly suggests itself to me, as the result of my observations in the scorpion muscle, is that, due to the intimate union between myofibrils and the telophragmata and between the latter and the sarcolemma; and the difference between the contraction effect of the fixing fluid upon the myofibrils and the sarcolemma, the latter is forced to bulge in order to adapt itself to the greater shortening of the successive sarcomeric portions of the involved myofibrils. The same phenomenon would result in the case of functional contraction.

#### EXPLANATION OF FIGURES




The illustrations were made with the aid of the B. and L. drawing camera, the details being added free hand. The magnification in all cases is 1500 diameters, reduced one-third in reproduction in figures 1 to 12, one-fourth in figures 13 to 21. Unless otherwise specified the technic employed was fixation by Zimmermann's alcohol-nitric-acid solution followed by the iron-hematoxylin and Van Gieson's stains.

Fig. 1 Transverse sections of two large fibers from the post-abdomen. The fibers vary greatly in shape and diameter in cross-section. The nuclei are centrally placed in a very delicately reticular sarcoplasm free of myofibrils; they are circular or oval in cross-section. The fibers are closely invested by a sarcolemma of varying delicacy, which does not readily take the Van Gieson's stain. Intimately adherent to the sarcolemma is a more superficial fibrillar connective tissue ('perimysium') which stains a more or less deep red in Van Gieson's mixture. The myofibrils are arranged in the form of radially disposed plates, many of which lamellae are in process of longitudinal fission, probably a growth phenomenon. The cleavage is initiated peripherally so that many of the plates have the form of a V or Y in cross-section. In b the myofibril-plates are aggregated into columns (the probable analogues of Kölliker's columns of mammalian striped muscle) suggesting in cross-section Cohnheim's areas. The smaller cephalo-thoracic and leg muscles are nearer the size of these myofibril columns. The shape of their cross-section explains the variations in width seen in longitudinal sections of the post-abdominal muscles.

Fig. 2 Portion of a longitudinal section of a post-abdominal muscle in the relaxed condition, including three nuclei. The sarcolemma is not indicated. The fiber contains centrally a continuous non-fibrillar sarcoplasm; this sarcoplasmic core contains an extremely delicate cytoreticulum and occasional small masses of granules (myochondria). The nuclei have an irregular or spinous contour in longitudinal section, in part possibly the result of fixation distortion. To the apices of the peripheral projections or ridges are attached the telophragmata or ground (Z) membranes. Where the latter pass among the peripheral myofibrils they have a granular appearance. The granules stain more deeply and mark the point of attachment of the myofibril to the telophragmata (fig. 6). Besides the telophragmata there can be distinguished in the relaxed myofibrils also the J- and Q-disks. Not the slightest indication of an H-disk or a mesophragma (M-membrane) appears.

Fig. 3 Portion of a longitudinal section of a fiber including both surfaces, and the periphery of an adjacent fiber, showing besides the above-enumerated features also the sarcolemma. The latter is regularly festooned between successive telophragmata, to which it is intimately attached. Peripherally, beyond the myofibrils, the telophragma is non-granular. At the left where the two fibers are apposed, the intervening common sarcolemma assumes a zig-zag character, the telophragmata of the adjacent fibers alternating, and so drawing the crests of the 'festoons' into sharp points. It seems probable that in such cases the adjacent sarcolemmas become intimately blended through the medium of a sparse amount of intervening connective tissue (fig. 4), the close approximation (and fusion) and the alternation of the opposite telophragmata being the result of a spiral torsion about a common axis of the two adjacent fibers.

Fig. 4 Portion of a paratangential section through the tapering end of a fiber, and the periphery of an adjacent fiber. In this case the inter-fiber connective tissue is more abundant, and so prevents a blending of the sarcolemmas. This illustration shows well also the non-granular character of the extra-fibrillar portion of the telophragmata. The condition shown in figure 3 could be derived from the one here illustrated by an interlocking of the festoons of the adjacent



fibers, so that the crests of one would fit into the troughs between successive opposite festoons, and a subsequent blending of the sarcolemmas.

Fig. 5. Portion of a longitudinal section of a fiber from the cephalo-thorax of the new-born. This fiber is in the relaxed condition. Note the oval, regularly contoured, and more chromatic character of the nucleus in these younger fibers. At the left is shown the connective tissue, with one nucleus, closely adherent to the festooned sarcolemma. The connective tissue stains red in Van Gieson's solution; the sarcolemma remains unstained. When the staining process is greatly prolonged the telophragmata as well as the sarcolemma are colored red.

Fig. 6. Portion of a longitudinal section of a relaxed fiber from the same region, distorted by a compression-stress acting at right angles to the long axis of the fiber. The line of transverse bending is always at the level of the telophragma, thus demonstrating the close attachment of the myofibrils to the ground-membrane, and the absence of an additional membrane (mesophragma) of the nature of the telophragma.

Fig. 7. Portion of a longitudinal section of a fiber from the same region at a mid-phase of contraction. An additional H-disk has now made its appearance.

Fig. 8. Portion of a longitudinal section of a contracted fiber from the same region, showing the contraction bands alternating with lighter disks of approximately twice the longitudinal width. The positions of the telophragmata are indicated by the contraction-bands. At the right is shown the relatively coarser sarcolemma.


Fig. 9. Portion of a longitudinal section of a contracted fiber from the jaw region. Upon the contracted condition is superposed a longitudinal traction. This circumstance should bring into view the mesophragmata if actually present (as is the case in certain insect muscles); but not the slightest indication of such a membrane appears.

Fig. 10. Longitudinal section of a small fiber from the head region at the extremity where it is attached to the chitinous exoskeleton by a short tendon. The fibers of the latter are directly continuous with the myofibrils; they stain somewhat more deeply in ordinary preparations, and pink after Van Gieson's stain.

Fig. 11. Longitudinal section of a large multinucleated myoblast from the head region. The myofibrils are more compactly arranged and hence cause the fiber to stain relatively more deeply. No cross-striations have yet made their appearance. Such appear first towards the extremities in slightly older myoblasts, and progress centrally. At the lower extremity the tendinous connection is differentiating from the myoblast fibrils. The definitive striped muscle fiber arises by process of elongation of a single myoblast. Such fibers become multinucleated by a process of nuclear amitosis. In slightly older stages as many as 20 nuclei have been counted in series in the same, relatively short, sarcoplasm-core.

Fig. 12. Transverse sections of two adjacent young muscle fibers from the head region of this same specimen. The myofibril-plates are radially disposed, of relatively short width, and only a few are in process of longitudinal fission.

Fig. 13. Transverse section of a smaller trabecula (fiber) of the cardiac syncytium from a paramedial longitudinal section of the heart tube. (Flemming's fluid; iron-hematoxylin stain). The heart-tube wall is one trabecula in thickness.



13

15



14



16



17



18



19



20



21

The nuclei are centrally located in a granular, very delicately reticular, sarcoplasm, free of myofibrils. The myofibrils are peripherally arranged in radial lamellae, which increase in number by longitudinal fission. The lamellae are gathered into smaller bundles, or sub-trabeculae, which anastomose freely and thus form with the main trabeculae or fibers a double syncytium, as in the *Limulus* heart. The 'fibers' are invested by a delicate sarcolemma, between which and the pericentral myofibril-lamellae is a frequently relatively extensive, coarsely granular, non-fibrillar sarcoplasm. At the lower border of this section, at which point the 'fiber' turns from the lateral to the ventral wall of the heart tube, the

lamellae are cut very obliquely. This fiber is cut at a point where the internal syncytium is more compact, probably near the extremity of the original myoblast.

Fig. 14 Portion of a longitudinal section of a cardiac trabecula (fiber) from the same heart, anteriorly. The internal syncytial structure is here somewhat looser. Other portions are still more loosely arranged. This fiber is in the relaxed condition. Note the close similarity, an essential identity, as also in the case of *Limulus*, between cardiac and skeletal muscle (figs. 2 and 3), especially from the standpoint of shape and character of these nuclei, and the relation of the telophragmata to the nuclear wall and the sarcolemma.

Fig. 15 Portion of a longitudinal section of a cardiac trabecula in the relaxed condition, from the same heart. Compare with skeletal fibers, figures 3 and 6.

Fig. 16 Portion of a longitudinal section of a contracted smaller cardiac trabecula, from the same heart. Note the close series of contraction bands, and compare with skeletal muscle, figure 8. The shape of the nucleus and the serrated character of its wall, can be readily interpreted in terms of the condition illustrated for the relaxed fiber (fig. 14); which condition can be conceived to pass into that of this illustration by a process of a coincident longitudinal shortening and a transverse widening of the sarcomeres (*inokommata*) and the nucleus.

Fig. 17 Transverse section of five adjacent cardiac trabeculae ('fibers') from a longitudinal section of the heart tube of the new-born. To the left is shown a portion of the peripheral connective tissue ('pericardium'). The trabeculae are oval in cross-section with a large central non-fibrillar, but granular and very delicately reticular, sarcoplasmic area, in which the oval nucleus is generally located. The nuclei show the regular contour and the relatively more chromatic condition, characteristic of the earlier stages of development. The myofibril-lamellae are peripherally arranged in a radial manner. Only a few of the lamellae are undergoing a longitudinal radial splitting at this stage. The fiber is invested by a delicate sarcolemma, immediately internal to which is a narrow granular zone of non-fibrillar sarcoplasm.

Fig. 18 Portion of a longitudinal section of a cardiac fiber from the same heart tube, showing the amitotic multiplication of the nuclei, and the intimate continuity between the telophragmata and the sarcolemma peripherally, and the nuclear wall centrally.

Fig. 19 Portion of a longitudinal section of a more differentiated cardiac fiber of the same heart, in the relaxed condition. The nuclear wall is thrown into spinous processes or ridges to which are attached the telophragmata.

Fig. 20 Fiber from the same heart and in the same relaxed condition, but mechanically shortened (probably through the contracting influence of the fixing fluid), causing thus a longitudinal shortening and transverse widening of the nucleus, and a coincident accentuation of the peripheral serrations, but without a detachment of the supporting telophragmata.

Fig. 21 Similar fiber, from same heart, showing in addition a stage in the process of nuclear amitosis; and a peripheral mass of nucleated connective tissue (at right) closely adherent to the festooned sarcolemma.

# THE EFFECT OF CERTAIN VITAL STAINS UPON THE DEVELOPMENT OF THE EGGS OF CEREBRATULUS LACTEUS, ECHINORACHNIUS PARMA AND LOPHIUS PISCATORIUS

MARGARET REED LEWIS

*From the Harpswell Laboratory, South Harpswell, Me.*

The stains which were used in the following experiments were those which have been frequently used in observations upon tissue cultures of chick embryos, namely Janus green, neutral red, brilliant cresylblue 2b, gentian violet, pyrol blue and others.

The object was to determine whether any new light as to the action of these stains could be obtained by a study of the effect of these stains upon the fertilization of eggs and also upon the later development of embryos, especially as to whether the effects of these stains is in any manner harmful or whether these stains are in reality vital stains, that is whether it is possible to stain the granules of a cell without injury to either the cell or the developing embryo.

## CEREBRATULUS LACTEUS

The cerebratulus eggs proved to be the most plentiful as well as the most favorable material for observations upon the effect of the stains upon fertilization and development. The eggs lived and developed normally in the laboratory and were frequently kept in a healthy state until in the late pilidia stage or for three or four weeks.

These eggs have a so-called gelatinous membrane surrounding the characteristic egg membranes, which enclose the egg. The egg membranes have a tube-like protuberance at the end of which is an opening. The gelatinous membrane has been supposed to become dissolved off after the eggs have been in sea water for some time (Wilson), but this is not the case as can easily be demon-

strated by the use of stains. The gelatinous membrane becomes much less visible after the eggs are placed in sea water, but when a few drops of Janus green are added to the sea water this membrane takes up the stain and can be distinguished as a pinkish blue layer, which has become separated quite some distance from the enclosed egg. The membrane takes up the Janus green stain, but does not readily permit it to pass through, and thus protects the egg from the toxic effect of the Janus green so that unstained eggs may develop up to 4 or 8 cell stage within the deeply stained gelatinous membrane before they are killed by the stain. Dr. Robert Chambers found that the gelatinous membrane can be removed without causing any injury to the eggs by passing the eggs in sea water through a double layer of ordinary laboratory gauze. The egg membranes can be removed by using a fine cambric handkerchief in place of the gauze. When the handkerchief is used care must be taken not to break the eggs, as frequently happens when the eggs are handled roughly. By thus removing the membranes naked eggs are obtained upon which the stains act more rapidly than upon those protected by the egg membranes. Also these eggs which are thus unprotected by the membranes can be stained by Janus green, in which case the toxic effect of the Janus green kills the egg in the same manner as it kills the tissue culture cells. The development of the naked eggs obtained in this manner was normal; the polar bodies were given off; and the segmentation planes came in as usual, except that the ciliated blastula, instead of being confined within the membranes until the pilidia stage, became at once free swimming and developed into normal pilidia.

The eggs of *cerebratulus* are relatively large spheres full of various granules and globules. The unfertilized egg has a clearer space at one side where there were fewer granules. The unfertilized eggs were subjected to the action of these various stains. In no case throughout these observations was the cytoplasm or nucleus stained. Occasionally the nucleolus was faintly stained. When the eggs were placed in a weak solution of Janus green numerous minute granules in the cytoplasm became blue; when



placed in neutral red solution there appeared an equally great number of larger red globules; when placed in a double stain of Janus green and neutral red in addition to the blue granules and red globules many unstained globules scarcely evident before became quite prominent. These are probably yolk globules. Eggs stained from ten minutes to one hour indicated no localization of the cytoplasm. Detailed observations were not made upon the unfertilized eggs.

The spermatozoon is larger than that of the sanddollar and the head is sickle shaped. The middle piece is in the form of a round disc, as is so characteristic of this body for most Echinoderms as has been shown by Retzius, and to it is attached a rapidly moving flagellum or tail. With Janus green, the whole middle piece immediately stains blue. In a few moments the blue staining material clumps into one or more masses of granules, which later become more or less extruded from the spermatozoon due to the toxic effect of the Janus green. Retzius figures the middle piece of many invertebrate spermatozoa in the form of usually 4, sometimes 5 or 6 granules. In some cases as for instance his drawing of *Lucina*, shows these granules more or less extruded to one side of the head of the spermatozoon. This is probably due to a less rapid fixation of these particular spermatozoa. When placed in neutral red a small round granule just above the collar and on one side of the sickle shaped head becomes bright red. There was usually only one such granule, but in a few cases it appeared to be double. Brilliant cresylblue 2b stains a granule purple in the same position as that which is stained red with neutral red and in all probability the same granule stains red with neutral red and purple with brilliant cresylblue 2b. With gentian violet the middle piece first stains violet, but very shortly the whole spermatozoon becomes a stained diffuse violet, especially the head, the middle piece, and even the small granule above the latter.

## ECHINORACHNIUS PARMA (SANDDOLLAR)

The egg is quite different in shape and has different egg membranes from that of the *cerebratulus* and yet the results in regard to the various stains are practically the same. The spermatozoon is smaller than that of the *cerebratulus* and the head instead of being sickle shaped is spear shaped, but the arrangement of the stainable material is the same, i.e., there is similar shaped middle piece which stains with Janus green and above the middle piece on one side of the spear shaped head is a small granule which stains red with neutral red and purple with brilliant cresylblue 2b. Meves ('12) pictures the spermatozoon of *Parechinus miliaris* much the same as that of *Echinorachnius*. Although Meves finds that the mitochondria occupy the middle piece, he does not describe any granule on the side of the head where the neutral red granule is located in the spermatozoon of *Echinorachnius* and also in that of *Cerebratulus*. Meves describes only two types of granules in the egg of *Parechinus*, one the mitochondria, which correspond with the Janus green granules of the egg of *Echinorachnius*, and the other the yolk granule. The reason that Meves does not describe the neutral red granule either in the spermatozoon or in the egg may be due to the fact that it is difficult to fix the neutral red granule.

The eggs of the *cerebratulus* and also those of the sanddollar were studied after fertilization in various stages of development, such as 8 cell, 16 cell, etc. The granules which stained with the different vital stains could be differentiated from one another in the different types of cells of the embryos. The stained granules differ in shades of color and size. All granules are more deeply stained on the surface of the egg than in the center. The Janus green granules are very small and often are around the edge of the neutral red granules and in such cases the neutral red granules are sometimes slightly bluish.

Under the conditions in which these observations were carried out, it was impossible to weigh out the stains in order to determine the exact solution of the various stains used. A standard solution of each stain was made up in sea water, or in a few cases in distilled water, and from this standard solution three

solutions of each stain were made by adding one or more drops of the standard solution to a given amount of fresh sea water. The three solutions were as follows: a weak solution or one which contained so little of the stain that the color could scarcely be detected when held over a white surface; a medium solution or one which had a slight color; and a strong solution or one which contained enough of the stain to give it a distinct color. This strong solution corresponds in color with a 1-100,000 solution of Janus green, a 1-100,000 solution of brilliant cresylblue<sup>25</sup>, a 1-50,000 solution of neutral red, and a 1-50,000 solution of gentian violet. By this method the amount of a given stain in the solutions of the same strength in the different experiments remained the same throughout the experiments, although the exact amount of stain in gram weight present in the solution was not determined.

Pyrol blue was not soluble in sea water and even when a few drops of a solution of the dye in distilled water was added to the sea water the stain was at once precipitated. This precipitate was not toxic as the eggs continued to develop normally, although they remained unstained.

Numerous experiments to determine the effect of the stain upon the fertilization and later development were carried out with both the cerebratulus and the sanddollar eggs and spermatozoa. These experiments were repeated many times and were as follows:

1. Spermatozoa were placed in strong, medium and weak solutions of the various stains and then after different periods of time a drop of these stained spermatozoa was placed in fresh sea water together with fresh unfertilized eggs, either with or without the egg membranes.

2. Fresh unfertilized eggs were placed in strong, medium and weak solutions of the stains and after different periods of time were taken out and placed in fresh sea water to which a drop of spermatozoa had been added.

3. Unfertilized eggs which had been treated with the stain were placed in fresh sea water to which a drop of stained spermatozoa was added.

4. Unfertilized eggs and spermatozoa were placed in strong, medium and weak solutions of the stain and left in these solutions.

5. Centrifuged eggs were treated with the stain and later fertilized.

6. Fertilized eggs in various stages of development, such as the polar bodies forming, 1st division plane, 2-cell, 4-cell, 8-cell, 16-cell, 32-cell, 64-cell, blastula, gastrula, pilidia and later free swimming pilidia, were placed in strong, medium and weak solutions of the stain and left in them.

Controls were always made with either normal eggs or normal spermatozoa in place of the stained ones and only the results of those experiments whose controls developed normally were considered.

The results of the ten above experiments were as follows:

1. In only a few cases did spermatozoa which had been placed in a solution of Janus green fertilize the eggs, while those which had been placed in weak solutions of neutral red or brilliant cresylblue 2b for periods of time varying from two minutes to fifteen minutes did fertilize the eggs even though the granule on one side of the head of the spermatozoön was colored in the typical manner. Spermatozoa placed in strong solutions of the stains for long periods of time did not fertilize the eggs. The presence or absence of the egg membranes did not appear to effect the ability of the spermatozoa to enter the eggs.

2. When the unfertilized eggs were placed in the Janus green solution the egg membranes protected the egg from the stain and, even though the outside gelatinous membrane itself became deeply stained, the egg remained unstained for some time. When the egg which had been placed in weak solutions of Janus green for short periods of time (5 to 15 minutes) were taken out and placed in fresh sea water together with spermatozoa, they became fertilized and developed as far as 4 or 8 cell stage and in one or two cases as far as the pilidia. When the egg membranes had been removed before the eggs were placed in the Janus green solution, the eggs were not fertilized and so did not develop. When the eggs and the spermatozoa were placed in the

solution of Janus green at the same time, the eggs occasionally became fertilized and developed polar bodies and sometimes divided once or twice before the Janus green killed them. The brilliant cresylblue 2b and neutral red on the other hand did not kill the eggs, although the egg membranes did not protect the eggs from the stain. When the eggs were placed in weak solutions of these stains for periods of time extending from five to fifteen minutes the eggs became faintly stained, but could be fertilized and frequently developed into normal free swimming pilidia. When the spermatozoa and eggs were placed in the weak solution of the stain at the same time the eggs became fertilized and later developed into free swimming pilidia, although the pilidia were red when in neutral red and blue when in brilliant cresylblue 2b. When a strong solution of neutral red or brilliant cresylblue 2b was used the eggs usually died.

3. When the spermatozoa and the eggs had each been treated with the stain before they were placed together the results were not so good, although occasionally the eggs stained with either neutral red or brilliant cresylblue 2b were fertilized by spermatozoa correspondingly stained and developed into pilidia. When Janus green was used fertilization did not take place.

4. The results in this case were much the same as those of 2 and 3 except that only eggs left in the weak solutions of the stain developed.

5. The centrifuged eggs developed practically the same as the normal eggs except that there was a much larger percentage which died. The centrifuged eggs did not show any localization of the stain.

6. The fertilized eggs became increasingly resistant to the toxic effect of all the stains except Janus green as development proceeded. While the early stages of development up to the blastula were easily killed by even the medium solutions of the stains, the later stages of development lived and continued to develop in the medium solutions and frequently pilidia lived for some days in the strong solutions of the stains except Janus green and gentian violet. Janus green, on the other hand, was more toxic for the pilidia than for the unfertilized eggs. All

stages of development which were protected by the egg membranes lived for a short while in the medium or in the weak solutions of the Janus green, but the later stages of development which were free swimming, were rapidly killed, even by the weakest solution of the stain. The free ends of the cilia immediately matted together into deeply stained blue clumps which shortly became torn away from the embryo.

A few experiments served to demonstrate the fact that Janus green cannot be considered a vital stain in the above sense, for not only did it usually prevent fertilization of the eggs but also in every case where the solution of the stain was of sufficient strength to color any of the granules of a cell of the embryo, not only was the particular cell killed, but also the embryo itself died. The same was true in most instances where this particular gentian violet was used. The gentian violet was not the same as that used in tissue cultures, but was a stain acquired through the kindness of Dr. Neil at the Harpswell laboratory and was in all probability a more toxic stain than the one previously used in tissue cultures in which growth of cells occurred when the medium contained a very small amount of gentian violet.

On the other hand brilliant cresylblue 2b and neutral red each proved to be true vital stains, for the embryo continued to develop and the cells to divide, although certain granules of the cells were colored and the embryos were kept in a weak solution of the dye. In many experiments the granules of the cells were so deeply colored that the red (neutral red) or blue (brilliant cresylblue 2b) embryo which resulted could be seen with the naked eye.

While the toxic effect of the various stains is in a way in proportion to the concentration of the stain in the solution, the depth of color with which the stain appears in the granule is only to a small extent dependent upon the concentration of the stain in the solution. When the piliidia are left for twenty-four hours or longer in a solution of either neutral red or brilliant cresylblue 2b, which contains so little of the stain that the color can hardly be detected, the granules of the embryo take up the stain until it appears in the granules in so much greater concen-

tration that the embryos can be seen as minute red or blue bodies in the solution.

One of the interesting results of these observations is the fact that the spermatozoön and the unfertilized egg proved to be the least resistant to the toxic effect of all the stains, while the older the embryo developed the more resistant it became. However a sufficiently strong solution of any of the above stains, except pyrol blue, was toxic and caused the death, not only of the egg or young embryo, but also of the later embryo.

Each stain seemed to have an affinity for a certain type of granule. In the egg and later stage of development Janus green stained the small round granules, which are scattered abundantly throughout the cytoplasm. In the spermatozoön the Janus green in every case stained only the granules, which lie within the middle piece. In the fertilized egg and later stage of development both the neutral red and the brilliant cresylblue stained definite large and medium sized granules and in the spermatozoön only a very small granule situated at one side of the head and just above the middle piece. A double stain could be obtained by means of Janus green and neutral red or brilliant cresylblue 2b. Neutral red stained the large granules different shades of red, pink or yellow, while brilliant cresylblue 2b stained the same type of granules various shades of lavender or purple and with this stain the large granules frequently became differentiated into a pink globule or vacuole which contained one or more purple granules. If an embryo was stained with neutral red and then later by brilliant cresylblue, the blue stain replaced the red in the granules and so far as could be observed did not stain any different types of granules from those previously stained by the neutral red. Gentian violet stained diffusely both the granules which can be stained by Janus green and also those which can be stained by neutral red or brilliant cresylblue 2b.

In the spermatozoön only two kinds of granules were observed, those of the middle piece which can be stained by means of Janus green and the one above the middlepiece which can be stained by means of neutral red or brilliant cresylblue 2b. In

the egg there were observed three kinds of granules, those which can be stained by means of Janus green, those which can be stained by means of neutral red or brilliant cresylblue 2b and also a large granule which remained unstained and which may be a yolk granule. The behavior of the various sized granules or globules which stain with the neutral red or the brilliant cresylblue 2b corresponds with that of the so-called vacuole described by Lewis and Lewis in the cells of tissue cultures.

#### LOPHIUS PISCATORIUS (ANGLER FISH OR GOOSE FISH)

A few observations were made upon the eggs of *Lophius piscatorius*, which were brought into the laboratory in the gastrula stage. Unfortunately these eggs were not obtained again during the summer, so that observations could not be made upon younger stages, and these observations upon the older embryos could not be repeated. However, they are given below because they suggest that certain extremely interesting results may be obtained by the use of neutral red upon the developing eggs of this form and possibly other fish eggs.

A mass of the eggs of *Lophius piscatorius* was put into a weak solution of neutral red in sea water and the remainder of the eggs was kept in normal sea water. The water was changed once or twice a day and the eggs in the normal sea water developed into normal free swimming embryos, while those in the neutral red developed marked abnormalities. The most evident of these was that the chromatophores did not develop in the normal number and what chromatophores did develop remained small more or less round cells with black granules. The chromatophores of the normal embryo develop into large cells with many ramifying processes full of black granules which form a gray network over the greater part of the embryo. The neutral red embryo remained more or less transparent, while the normal embryo became dark gray and more or less opaque.

The yolk sac of *Lophius* is filled with a colorless transparent fluid in which is suspended a conspicuous yellow oil droplet and in the normal embryo it is not possible to distinguish the boundaries of the yolk sac. When the young embryos were



placed in the neutral red solution, certain numerous granules within the epithelial cells became stained red, although the cytoplasm of the cell remained unstained and very shortly after this the red color appeared in the yolk and continued to be taken up by the yolk until the yolk became many times pinker than the solution of neutral red in which the embryos were placed. This sphere of red fluid is considerably smaller than the membranes around it and the oil droplet did not take up the stain but remained a clear yellow. When such a pink stained yolk sac was punctured the egg membranes collapsed and the deeply stained, transparent fluid rapidly flowed out and quickly became so diluted with the surrounding medium that it could no longer be distinguished from it. The clear, yellow oil droplet usually remained within the collapsed egg membranes.

The action by means of which the neutral red was deposited in the fluid within the yolk did not correspond with that of a simple diffusion, but it appeared to be associated entirely with the large neutral red granules which seemed to take up the stain from the solution of the stain in the sea water which surrounded the egg and to give it up again to the fluid within the yolk sac.

In the embryos which had developed in the neutral red solution the cells of the central nervous system contained so many red granules that the neural tube appeared pink. This pink color of the central nervous system persisted throughout the various stages of development.

Another especially interesting abnormality in the development of these eggs of *Lophius* in a solution of neutral red was that, although the heart and the chief blood vessels developed, there was no circulation of blood cells within the blood vessels and heart. The heart did not begin to beat quite as soon as did the heart of the normal embryo, but eventually the heart contracted normally. No blood cells were ever observed to pass through the heart or the blood vessels, although the embryos remained alive in the neutral red solution for several days after the circulation of blood cells had been established in the normal embryos.

The behavior of the chromatophores and the lack of a circulation of blood cells seem to indicate that the neutral red may have somewhat the same effect upon the developing fish embryo as that of alcohol upon *Fundulus* eggs observed by Stockard, in which case the chromatophores remained small round cells and no blood cells were observed in circulation, although the heart contracted rhythmically.

Fischel ('01) carried out numerous experiments with various stains upon the embryos of the frog and also those of the salamander. Fischel found that Bismarckbraun, neutralrot, neutralviolett, nilblauchlorhydrat and nilblausulfat are all true vitals stains, i.e., that the embryo continued to live and develop although stained. Fischel describes the same type of neutral red granule as those described above in the embryo of *Lophius*. From his observations he concludes that the neutral red granule is a living plasmatic element. Fischel does not describe any changes in the chromatophores or in the circulation of the blood in the amphibian embryos which were stained with neutral red. This may be due to the fact that the embryos were first stained and then transferred to clean water, while in these observations the embryos were permitted to develop in a weak solution of neutral red.

It was impossible to obtain these eggs again, but it is hoped that some future summer it may be possible to acquire enough of these fish eggs to carry out a more elaborate series of experiments.

The study of the spermatozoa, the unfertilized eggs and the later stages of development led to the conclusion that not only the embryo, but also the unfertilized egg and the spermatozoön react in the same manner as the cells of tissue cultures of the chick embryo do to the stains, that is they contain granules which are stained blue with Janus green, probably the mitochondria, and others stained red by neutral red or purple with brilliant cresylblue 2b. The Janus green stain is toxic and resulted in the death of the embryo just as it caused the death of the tissue cultures, while the neutral red and brilliant cresylblue 2b are less toxic and the embryo may continue to live and develop, although the granules in the cells are stained. These two large groups of

granules, the Janus green granule and the neutral red granule, may be further differentiated by the use of other stains such as pyrol blue, brilliant cresylblue 2b or Nile blue. In addition to these two types of granules, the egg and certain cells of the embryo contain yolk globules or fat globules. Dr. Paul G. Shipley, who has made a careful study of the neutral red granule, has suggested the term vacuoles of segregation for this body and has studied its behavior in detail. The results of Dr. Shipley's observations will be published in the near future.

In the discussion of the plastosomes of the living cell (p. 608) Prof. J. Duesberg states that a number of authors have claimed to have stained the plastosomes in the living cell. The most used dyes according to Professor Duesberg are neutral red and methyleneblue, while dahliaviolett appears to be the most satisfactory stain. Dahliaviolett was first used by von la Valetta St. George and after him by Henneguy ('96) and Fauré Frémiet ('10). Michaelis ('00) and Laguesse ('05) found Janus green very satisfactory, while Renaut ('11) used methylviolett and Ciaccio ('11) used brilliant cresylblue. The granules stained by these different observers quoted by Professor Duesberg cannot be the same granules and therefore not in every case the mitochondria for neutral red does not stain the same granules as those stained by Janus green except in the case of the granules within certain, not all, of the vacuoles described by Lewis and Lewis ('15) (p. 382). The reason for the discrepancy in the results of the above writers is without doubt due to the condition of the tissue supposed to be living but which in many cases was probably dying, as can be seen from the following facts.

The action of most of the so-called vital stains causes the death of the cell more or less rapidly and a concentrated solution of almost any of these stains will kill the cell. In cases where animals are given increasing doses of stain until the body tissues are stained, the cells when placed under the microscope show first one picture and later as the cells begin to die the same cells show quite a different picture. This can easily be demonstrated by a study of a living embryo such as the *Cerebratulus pilidia* in which the death of the pilidia causes brilliant cresylblue 2b to fade out

of the large granules and at the same time to be taken up by the mitochondria. This same phenomenon has been described by Lewis and Lewis for the action of Nile blue upon the granules of the tissue culture cells, in which case the vacuoles of the living cell were stained pink by means of Nile blue but when formaldehyde vapor was passed under the cover slip the color faded out of the vacuoles and the mitochondria then became stained a blue color.

The results obtained with pyrol blue and possibly with other stains may also lead to confusion because of the change in color shown by certain of the granules (Levi, '16). I have observed in tissue cultures that when the cells first grow out (12 to 24 hours) into a medium which contains pyrol blue, both the many mitochondria and the few neutral red granules are stained blue. As the growth increases in age the neutral red granules become more and more deeply stained and also increase in number, while the color fades out of the mitochondria, so that the cells of a seventy-two-hour growth contain numerous very dark blue granules and many unstained mitochondria.

Fischel states that the nucleus becomes diffusely stained when dying and in previous observations upon the cells of tissue cultures, the germ cells of the grasshopper as well as in the observations above, it has been found that the slightest trace of color in the nucleus is an indication that the cell is injured. This does not hold however for the nucleolus, for the nucleolus may remain faintly stained with pyrol blue through several generations of cells and also the chromosomes may be faintly stained with certain stains during division.

Observations upon the living embryo and also upon the cells of tissue cultures show, when the cell has not been injured by the stain and the nucleus is not stained, that the cytoplasm of the cell consists of a homogeneous ground substance which contains certain granules which may be stained by means of neutral red and certain others which may be stained by means of Janus green, and in addition to these two types of granules there may be present fat globules which do not stain with either neutral red or Janus green.

Observations have shown the presence of the Janus green granule and also the neutral red granule in the nerves, the red blood cells, the endothelial cells, the ectoderm, the endoderm, the smooth muscle cells, the striated muscle cells and the connective tissue of the chick embryo and also in various embryonic tissues of the pig, the fish, the grasshopper, the hermit crab, the *Cerebratulus*, the sanddollar and the sea urchin. These granules are present in the germ cells of the grasshopper, the *Cerebratulus* and the sanddollar and in all probability they are present in all embryonic animal cells.

## LITERATURE CITED

- (1) DUESBERG, J. 1912 Plastosomen "Apparato Reticolare Interno und Chromidialapparat." *Ergeb. der Anat. und Entwicklungsgesch.* Bd. 20.
- (2) FISCHEL, A. 1901 Untersuchungen über vitale Färbung. *Anat. Hefte*, Bd. 16, Heft. 1.
- (3) LEVI, G. 1916 "Demonstrazione della natura condriosomica degli organuli cellulari colorabili col bleu pirrolo in cellule coltivati 'in vitro.'" *Reale Accademia dei Lincei*, vol. 25.
- (4) LEWIS, M. R. AND LEWIS, W. H. 1915 Mitochondria and other cytoplasmic structures in tissue cultures. *Am. Jour. Anat.*, vol. 17.
- (5) LEWIS, M. R. AND ROBERTSON, W. R. 1916 The mitochondria and other structures observed by the tissue culture method on the male germ cells of *Chorthippus curtipennis* Scudd. *Biol. Bull.*, vol. 25, no. 2.
- (6) MEVES, FR. 1912 Verfolgung des sogenannten Mittelstückes des Echinodens *permium* in befruchteten Ei bis zum Ende der Furchungsteilung. *Arch für Mikr. Anat.*, Bd. 80.
- (7) RETZIUS, G. 1904 Zur Kenntnis der Spermien der Evertebraten. *Biol. Unters.*, Neue Folge Bd. 11.
- (8) RETZIUS, G. 1910 Über den Bau des Eies der Echinodermen in unbefruchteten und befruchteten Zustand. *Biol. Unters.*, Neue Folge Bd. 15.
- (9) STOCKARD, C. R. 1915 An experimental analysis of the origin and relationship of blood corpuscles and the lining cells of these vessels. *Proceedings of the National Academy of Sciences*, vol. 1, p. 556.
- (10) WILSON, C. B. The habits and early development of *Cerebratulus lacteus* (Verrill). *The Quart. Journ. of Mier. Science*, vol. 43, part 1 new series.



# THE BLOOD OF ALLIGATOR MISSISSIPPIENSIS

ALBERT M. REESE

*Department of Zoology, West Virginia University*

EIGHT FIGURES

METHODS

In this study of the blood of the alligator both fresh and stained preparations were used. The blood was obtained from an animal kept in the laboratory, by making a small slit between the ventral abdominal scales; the wound quickly healed. This operation was repeated whenever a new preparation was needed.

By sealing the cover with a ring of oil, to prevent access of air, the fresh blood could be kept in normal condition for many days, during which period the amoeboid activity of the leucocytes could be studied.

In making stained preparations various fixing fluids were used, but the ordinary dried smears gave the best results. Of the stains used the best results were obtained with hematoxylin and eosin and with Wright's stain.

## THE ERYTHROCYTES

The red cells of the alligator's blood are, as is well known, of the usual elliptical form seen in the lower vertebrates.

According to Gulliver (2) there is some variation in the cells of closely related species. He found (3), as will also be noted below, that the corpuscles of dried blood are appreciably smaller than those of fresh blood.

He says that in *Crocodilus acutus* and in an unknown species from Vera Cruz the length of the corpuscle is somewhat less than twice the breadth.

On the other hand, Mandl (4) who studied *C. lucius* says the length is two or three times the width. In only three cases of several dozen measurements made of the corpuscles of *A. mississippiensis* did the writer find the length as much as twice the width, and in no case did it approach three times the width.

In *C. acutus* Gulliver gives the average length of the corpuscles as 20.31 + micra; the average width as 10.93 + micra. In *C. fissipes* the average length was 19.85 + micra; the average width was 10.79 + micra. As will be seen below, these variations are not nearly so great as those seen among corpuscles from the same individual animal in the Florida Alligator, *A. mississippiensis*.

Milne-Edwards (5) gives the following measurements, presumably averages: *A. sclerops*, length 23.80. micra; width 13.33 micra; *A. lucius* length 20.83 micra; width 11.11 micra.

In *A. mississippiensis* a considerable number of measurements was made, both of fresh and of stained corpuscles. The thickness of the corpuscles was also measured in a number of cases; this can be done only with the fresh blood where corpuscles can occasionally be seen in profile.

The average length of the fresh corpuscles was found to be 20.77 micra the average width 12.78 micra; and the average thickness 4.17 micra. As noted above, and as will be seen later, these measurements are apparently greater than those of stained corpuscles.

The longest corpuscle found in the fresh blood was 24 micra; the widest was 14.00 micra; the thickest was 5 micra; the shortest was 18.50 micra; the narrowest was 11 micra; and the thinnest was 3.60 micra.

Among the stained corpuscles the average length was 18.69 + micra; the average width was 10.85 micra, both measurements being noticeably less than in the fresh blood.

The longest stained corpuscle measured was 22.10 micra; the shortest stained corpuscle was 14.80 micra in length, only 0.8 micra more than the width of the widest fresh corpuscle. The widest stained corpuscle was 12.80 micra; the narrowest was 8.10 micra.



Among all the corpuscles, both fresh and stained, the one that showed the greatest difference between the length and the width was one that was 22.10 micra long and 10.40 micra wide.

On the stained slides, for obvious reasons, it was not possible to measure the thickness of the corpuscles, but the length and width of the nucleus were measured in each case. The greatest variation in the length of the nuclei was from 3.80 micra to 6 micra; in width from 2.80 micra to 4.30 micra; the average length was 4.85 micra, the average width was 3.66 micra.

The appearance of the erythrocytes, as seen in the flat, is shown in figures 1, 1*a*, 1*b*, and 1*d-h*, drawn, as were all of the figures, with a camera lucida under an oil immersion objective from a stained slide. The profile view, figure 1*c*, was, of course, drawn from a slide of fresh blood. As would be expected from the measurements given above, the ellipse varies considerably in different corpuscles. In the profile the central thickening is plain but the nucleus could not be determined.

The cytoplasm, so far as could be determined, was homogeneous, though it was examined under a magnification of 2300 diameters. The cytoplasm was so transparent that, on the ordinary stained slide, when one corpuscle lay over another the nucleus of the under corpuscle showed with the same apparent distinctness as that of the upper cell.

This structureless condition is in contrast to that described by Bryce (1) in *Lepidosiren*, where he figures a clear band beneath the membrane, a fine network throughout the cytoplasm, and one or more clear areas and vacuoles in the cytoplasm. Whether examined under a magnification of 1000 or of 2300 diameters, the cytoplasm in *A. mississippiensis* appeared the same. Possibly more refined methods of technique might have brought out some details of structure in the cytoplasm.

The nuclei, as indicated by the measurements and as seen in figures 1, 1*a*, 1*b*, etc., vary both in size and shape, though they are usually ellipsoidal. They stain easily and darkly but not homogeneously; sometimes small unstained or more lightly stained areas are scattered fairly evenly throughout the nucleus, as in figure 1; sometimes larger and more irregular areas are

seen in various parts of the nucleus as in figure 1*a*. Occasionally a nucleus is located at one end of the cell instead of its usual central position, and sometimes a nucleus is seen at each end of the cell, figure 1*g*.

No instance of mitosis was seen on any slide examined, but erythrocytes are occasionally found with two closely adjacent nuclei, figure 1*c*, which would seem to have just resulted from an amitotic division. Figure 1*f* seems an evident case of amitotic division of the nucleus just before the completion of the process. While the cells in which two nuclei are found are usually of large size and elongated form, but one case could be found in which there was indication of a division of the cell body. This cell is shown in figure 1*b*; it is possibly an artifact, but it is difficult to see how the nucleus could have been pulled apart by artificial means as is shown in the figure.

Quite infrequently erythrocytes of the form shown in figure 1*d* are seen. It would, at first, seem possible that these were halves of just-divided cells, but if this were the case they should frequently be found in pairs, while, as a matter of fact, it is but seldom that two of them are found in the same microscopic field. It is possible that they may be comparable to the spindle cells found in frog's blood, but it seems more likely that they are merely artifacts.

#### THE LEUCOCYTES

On a slide of fresh blood, mounted with a ring of oil to prevent access of air, as noted above, the amoeboid activities of the same white corpuscle may be studied for several days, though after a few days the motion is so slow that it can only be determined by making a series of drawings at intervals of several minutes, as must sometimes be done to demonstrate the changes in shape in amoeba.

In the fresh blood it is difficult to identify the various types of leucocytes that may be seen in the stained blood, not only because of the lack of stain but also because the pseudopodia are usually more or less withdrawn in the stained blood.

Figure 2 shows one type of leucocyte as seen in fresh blood. The general outline of the cell is circular and a number of small,

sharply-pointed pseudopodia project from its periphery. Being unstained, the nucleus is indistinct or invisible, but one or more small vacuoles may be seen. The cell is filled with fine, unevenly distributed granules which change their appearance as the cell changes its shape. Such a cell, while it changes its shape but little, changes quite rapidly—about as fast as the changes seen in an active leucocyte in frog's blood.

Another type of leucocyte, seen in fresh blood, is shown in figure 3; it is coarsely granular and changes its shape quite rapidly and markedly.

In stained preparations of alligator's blood several types of leucocytes may be distinguished. Of these the most numerous is shown in figure 4; since it stains with hematoxylin rather than with eosin it might be thought to be an extruded nucleus from an erythrocyte except that it is several times the bulk of such a nucleus. It is of fairly large size and is usually circular in outline though the shape is variable. It is possible that it is a corpuscle in which the nucleus is very large and the cytoplasm is so reduced as to be invisible. This would seem possible from the fact that occasional cells are found with a very large nucleus and a very thin peripheral zone of protoplasm.

Of almost, if not quite, as frequent occurrence as the cell just described is a smaller type shown in figures 5, 5 *a*, 5 *b*, and 5 *c*. This cell may, perhaps, correspond to the lymphocyte in the human blood. It varies considerably in size and shape but contains an oval or circular nucleus and a small amount of cytoplasm which generally gives the cell a pointed or spindle form, as seen in figures 5 *b* and 5 *c*.

Another type of leucocyte that is fairly common is shown in figures 6 and 6 *a*. These forms might, perhaps, be called mono-nuclear leucocytes; they are large, some of them being larger than any of the other types. The cytoplasm is clear or very finely granular, and stains, with eosin, a pale pink color. The nucleus is very large and of an oval or circular outline; it does not stain so darkly as the nucleus of the erythrocyte. The outline of the cell is usually circular or polygonal.

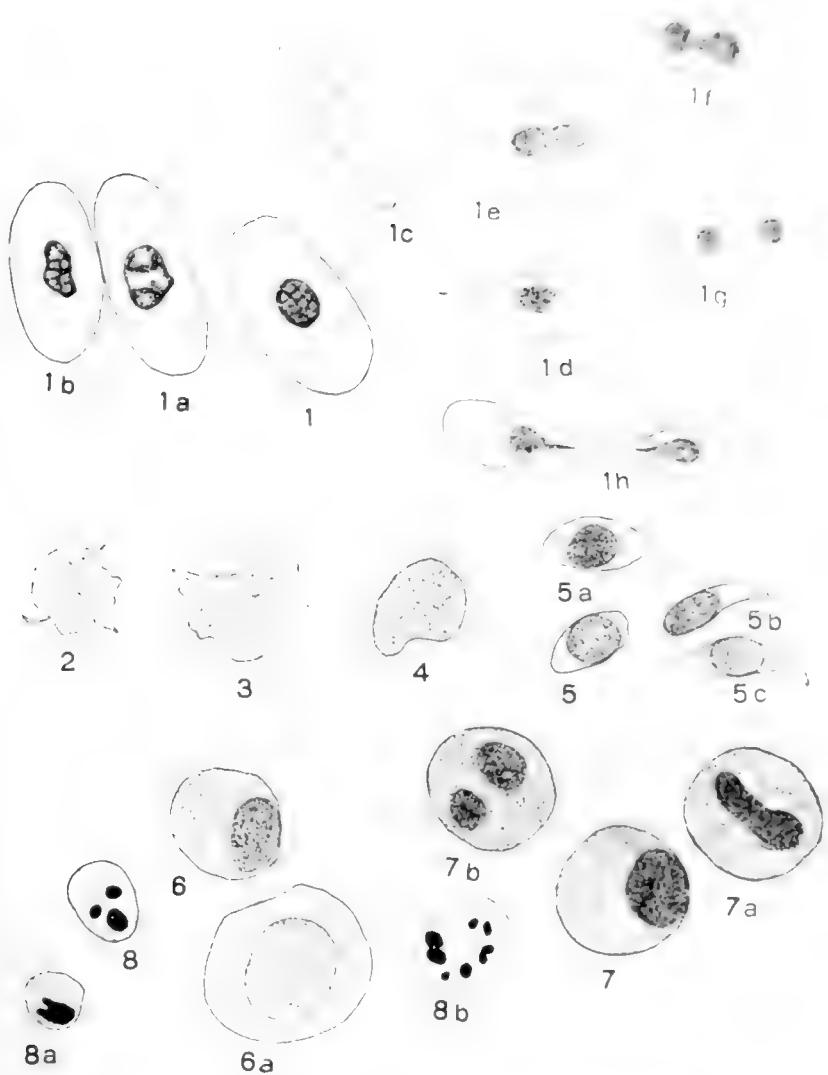
The most striking in appearance of all the leucocytes, and, possibly with one exception, the least numerous, is the type

that may be compared to the eosinophile cell of mammals. It is a large, usually circular cell that may at once be recognized by its coarsely-granular cytoplasm that take a strong pink color with eosin. The nucleus is usually round or oval, and generally lies close to one side of the cell, as shown in figure 7. Occasionally two nuclei in a single cell may be seen, figure 7 *b*, as though by division of the larger nucleus; and an occasional elongated nucleus, as seen in figure 7 *a*, would seem to indicate an impending amitotic division. No case was seen in which there was any indication of the division of the cell as a whole. In many of these eosinophile cells, especially in those in which the cytoplasm did not take the stain, there was seen a heavy outline, like a thick cell wall, possibly caused by a peripheral zone of denser protoplasm; this appearance was usually most marked on the side of the cell farthest from the nucleus. This type is the most uniform in size and shape of any of the leucocytes.

The least numerous type of leucocyte, if indeed it be a distinct type, is shown in figures 8, 8 *a*, and 8 *b*. Among the tens of thousands of erythrocytes seen, on several different preparations, but three of this possible type of leucocyte were seen; it is this extreme rarity that raises the doubt as to their being a normal type of corpuscle. They are all of rather small size and not very irregular outline. The cytoplasm is clear or very finely granular. The nucleus, or nuclei figure 8 *b* shows no less than eight—are so dark as to be almost a solid black. Whether these are really a normal element of the blood or are some artifact or other abnormality it is difficult to determine.

#### LITERATURE CITED

- (1) BRYCE, T. H. 1904-5 The histology of the blood of the larva of *Lepidosiren paradoxa*. Trans. Roy. Soc. Edinb., vol. 41, no. 9, pp. 291-311 and 435-69.
- (2) GULLIVER, G. 1840 On the blood corpuscles of the Crocodilia. Pro. Zool. Soc. London, vol. 8, p. 131.
- (3) 1842 On the blood corpuscles of the British Ophidians, Reptiles and other oviparous vertebrates. *ibid.*, vol. 10, pp. 108-11.
- (4) MANDE, — 1839 Note sur les globules sanguine du *Protée* et des Crocodiliens. Ann. des Sc. Nat., 2 Serie, T. 12, p. 289.
- (5) MILNE-EDWARDS, A. 1856 Note sur les dimensions de globules du sang chez quelque vertebres. Ann. des Sc. Nat, T. 5, pp. 165-7.



EXPLANATION OF FIGURES

All of the figures were drawn with a camera lucida under the same magnification,  $\frac{1}{2}$  oil immersion objective and no. 8 compensating ocular.

Figs. 1, 1a, 1b Three views of erythrocytes seen in the flat; figure 1c is a normal erythrocyte seen in profile, drawn from a slide of unstained and living blood. Figure 1d is one of the rather uncommon pointed erythrocytes, which may be

simply an artifact. Figure 1 *c* is a red cell with, apparently, a just-divided nucleus. Figure 1 *f* is a cell in which the nucleus is in process of division. Figure 1 *g* is a red cell with a nucleus at each end. Figure 1 *h* represents the single case that was found that seemed to show an erythrocyte in which the entire cell was in process of division.

Figs. 2 and 3 Represent two types of leucocytes drawn from living blood while exhibiting amoeboid motions; figure 3 represents a more active cell than figure 2, and one in which the granules are coarser.

Fig. 4 Represents a type of doubtful character, which may be simply a cell with an enormous nucleus and almost no cytoplasm; it is the most common of the leucocytes.

Figs. 5, 5 *a*, 5 *b*, and 5 *c* Represent a type of small leucocytes very abundantly represented.

Figs. 6 and 6 *a* Represent a type of large mononuclear cells that may possibly be the same as the one shown in figure 4.

Figs. 7, 7 *a*, and 7 *b* Show three very characteristic cells that seem to correspond to the eosinophile cells of mammalian blood; they are very coarsely granular and generally stain strongly with Eosin.

Figs. 8, 8 *a*, and 8 *b* Represent a type of small and unusual cells that are so seldom seen as to make it seem doubtful that they are a normal constituent of blood.

# A PERSISTENT SUPERIOR VENA CAVA SINISTRA IN THE CAT TRANSMITTING CORONARY BLOOD

S. B. GRANT

*Washington University*

ONE FIGURE

The anomaly of the vascular system stated in the title was found during a course in comparative anatomy in the Zoology Department of Washington University. At the suggestion of Dr. E. A. Baumgartner, a study of the literature of this form of variation was undertaken, the results of which are here given.

This anomaly was found in a young and apparently normal cat. Upon opening the thoracic cavity, a long slender vein, of uniform diameter, was exposed, which reached from the left innominate vein to the coronary sinus, about 4 mm. distant from its atrial end. This was recognized as a left superior vena cava.

The coronary veins were all of normal size and distribution, and their openings into the coronary sinus were normal. But, the coronary sinus ended blindly about 5 mm. short of the point at which it should have opened into the right atrium. At this end of the sinus it received the vena cordis media. No remnant of a connection could be found upon the blind sinus end or the right atrial wall. Upon tracing the anomalous vena cava upward it was found to open into the left innominate vein at the point where this vein joined with the right to form the normal superior vena cava (fig. 1). In the upper third of its extent the left superior vena cava received the superior intercostal vein, which was composed of two intercostal branches.

Upon examining the interior of the right atrium, no trace of an opening of the coronary sinus was seen. However, the wall

here was thin. No Thebesian valve was present. The valve of the inferior vena cava, however, was well developed. A large distinct foramen ovale was present.

I have found two references besides those given by McCotter '16—LeCat, Beyerlein and Hutton—of anomalies similar to the one under consideration. According to Marshall ('50),

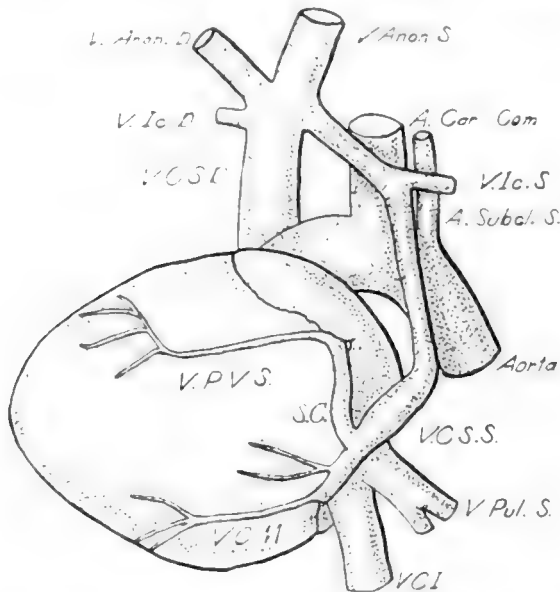


Fig. 1 The heart and vessels viewed from the left and dorsally. It shows the course of the coronary sinus and left superior vena cava. Enlarged one-half.

LeCat observed (1738) a coronary vein which emptied into the left subclavian vein in an eight days old child.

Hutton ('15) found a case in which the coronary sinus ended in a sunken pitted area against the wall of the right atrium. Within the right atrium there was a shallow circular depression corresponding to the coronary opening. There was no Thebesian valve, but a considerable remnant of the left venous valve. Hutton suggested two explanations of the closure of the coronary sinus. The partition between the sinus and atrium was either: first, a composite structure, the result of fusion between



the coronary segments of the right and left venous valves; or, second, the result of an unusually voluminous Thebesian valve, which had eventually fused with the margins of the ostium of the sinus.

Beyerlein ('14) described a case in a fifteen months old child in which the coronary sinus extended to the wall of the right atrium. Upon observing the interior of the right atrium, all the openings appeared normal, but, upon probing the coronary sinus it was found to be closed. The Thebesian valve, not being mentioned, was evidently normal. Beyerlein offered two possible explanations of his case; viz.: inflammation of the endocardium and atresia, although he saw no evidence of disease; or, a mechanical influence due to suction after the formation of the left innominate, plus pressure in the atrium from the right superior and inferior venae cavae.

Gruber ('85), described, in a fifty years old man, a coronary sinus without any atrial opening. In the right atrium in the place of the usual coronary aperture, there was a small groove leading into a blind pouch 6 mm. deep. Gruber tentatively called the free membranous margin of the groove the Thebesian valve. Anton Siding ('96) also observed a case in an adult male in which the coronary sinus ended blindly 15 mm. short of the site of its opening into the right atrium. Within the right atrium there was a narrow aperture, guarded by a feebly developed Thebesian valve, opening into a blind sac 10 mm. long. In all of these cases the coronary sinus drained through a persisting left superior vena cava.

The fact that the left superior vena cava, of the present case, opened into the left innominate so close to the right superior vena cava, instead of some distance from it, is easily explained when one reflects that in the cat, with its narrow thorax, the transverse branch connecting the two superior venae cavae becomes shorter and larger as the embryo increases in size until the left superior vena cava may appear to open into the right at an acute angle.

The closure of the normal ostium of the coronary sinus probably took place after the transverse branch between the two

superior venae cavae had been formed. As Hutton ('15) suggests, this closure may have been due to an usually large Thebesian valve, which may have closed it too effectively when pressure was exerted upon it from the inside by the flow of blood into the atrium. The left superior vena cava being still open, the coronary blood would find an easy path to the right atrium through it, the left innominate, and the right superior vena cava. If this supposedly large Thebesian valve fused with the wall and permanently closed the normal opening of the coronary sinus, the portion of the latter, or left duct of Cuvier, between the wall of the right atrium and the proximal end of the coronary sinus may have degenerated. It has been suggested by Beyerlein ('14), that the suction in the left superior vena cava, caused by the rush of blood in the left innominate vein would aid in closing the normal sinus opening. That the Thebesian valve, which is formed from the caudal portion of the right valve of the sinus venosus, may have been abnormal and possibly concerned with the closure of the coronary opening, is indicated by its absence and also by the presence of a patent foramen ovale. If the left venous valve were abnormally small, it may have resulted in the failure of the foramen ovale to close, and in such a case, the right venous valve would be likely to be unusually large, and, consequently, the Thebesian valve as well.

Gruber's and Siding's cases are similar to the present, in that the coronary sinus ended before reaching the wall of the right atrium; but differ in that in my case there is no cul-de-sac or opening in the atrium at the site of the normal ostium of the sinus. Hutton's and Beyerlein's cases differ from the writer's and the other two, in that the coronary sinus in these cases extends to the wall of the right atrium, where it is closed.

Hutton's second suggestion as to causes of the anomaly seems to suit the case here described, but the fusion of the Thebesian valve to the atrial wall in my case must have taken place so early in development that no traces of it are left. Coupled with this may have been the mechanical causes suggested by Beyerlein.

## LITERATURE CITED

- BEYERLEIN, K. 1914 Die persistierende Vena cava superior sinistra als Abflussrohr für das Coronarvenenblut. *Frankfurter Zeitsch. f. Path.* Bd. 15.
- GRUBER, W. 1885 Anatomische Notizen. *Arch. f. path. Anat.*, Bd. 19.
- HUTTON, W. K. 1915 An anomalous coronary sinus. *Jour. Anat. Phys.* vol. 49.
- KEIBEL AND MALL 1912 *Manual of Human Embryology*. Lippincott, Philadelphia.
- LECAT, 1738 *Histoire de l'Academie des Sciendes*. Paris, 1840. (Quoted from Marshall.)
- MARSHALL, J. 1850 On the development of the great anterior veins, etc. *Phil. Trans. Royal Soc., London*, vol. 141.
- MCCOTTER, R. E. 1916 Three cases of the persistence of the left superior vena cava. *Anat. Rec.*, vol. 10.
- SIDING, A. 1896 Ueber den Abfluss des Sinus coronarius cordis gegen den rechten Vorhof. *Anat. Anz.*, Bd. 12.



# THE VOMERO-NASAL APPARATUS IN *CHRYSEMYS PUNCTATA* AND *RANA CATESBIANA*

ROLLO E. M. COTTER

*Department of Anatomy, University of Michigan, Ann Arbor*

SEVENTEEN FIGURES

In a previous communication the writer ('12) described the vomero-nasal apparatus in the opossum and other mammals. It was shown that the vomero-nasal organ, the vomero-nasal nerves and the accessory olfactory bulb are parts of a special olfactory mechanism the specific function of which still remains doubtful. It is with the idea that a careful comparative study of this apparatus in the different animals may lead to a more definite understanding of its function that this study was undertaken.

The observations about to be reported were based in part on serial sections of the heads of turtles and frogs and in part on dissections of prepared specimens of the same species. Wax plate reconstructions of the olfactory apparatus were made to show, so far as possible, the form and comparative size of its component parts. Figures 7, 8, 15 and 16 represent drawings of these reconstructions.

## CHELONIA

Two views have been advanced as to the structure that should be designated the vomero-nasal organ in these forms. One group of observers believe that the vomero-nasal organ exists in a very simple condition, and that in some species it forms a shallow fossa covered by neuro-epithelium situated on the medial wall of the nasal cavity, while in others the neuro-epithelial

area has extended on to the anterior and lateral walls of the nasal fossa. Another group of workers claim that the vomero-nasal organ is a rudimentary structure and consists of a small duct that extends from the surface of the septal mucosa caudalward in the submucosa and ends blindly.

According to Seydel's (196) communication the nasal cavity in *Chelonia* may be subdivided into a cranially situated pars olfactoria and a more caudally situated pars respiratoria. The vomero-nasal organ belongs to the last named subdivision. In *testudo graeca* one can observe the vomero-nasal organ occupying a shallow fossa on the medial wall. The separation of its epithelium from the neuro-epithelium of the olfactory region is completed through a narrow intervening zone of indifferent epithelium. The ventral and lateral portions of the pars respiratoria exhibits no neuro-epithelium. He states that in *emys europaea* the pars respiratoria is more complicated than in *testudo*. Here the neuro-epithelium that comprises the vomero-nasal organ is found in four fossae which occupy the medial, the two side walls and the floor of the pars respiratoria. It is separated from the neuro-epithelium of the pars olfactoria by a low ridge that is covered by indifferent epithelium. Seydel accepts the view that the neuro-epithelium in *emys* has extended from the medial walls onto the floor and side walls of the pars respiratoria. For an explanation of this view he refers to the course of the nerve fibers of the pars respiratoria. The olfactory fibers extend from the medial wall downward and curve lateralward beneath the floor and upward on the lateral wall where they subdivide into branches. These relations have resulted from a condition where the neuro-epithelium occupied a small area on the medial wall and has extended to the anterior and lateral walls.

In one embryo of *Chrysemys punctata* Seydel observed that the neuro-epithelium of the vomero-nasal organ occupied a small area on the medial wall while on the floor indifferent epithelium was found. In another the neuro-epithelium had extended from the medial wall onto the floor of the pars respiratoria.

Mihalkovics researches on *emys europaea* has lead him to differ as to the position, form and structure of the vomero-nasal organ. He believes that the vomero-nasal organ is a rudimentary structure in these forms. He describes this organ as a small, blind, tubular structure extending from the surface of the septal mucosa caudalward in the submucosa. It receives at its distal extremity the ducts of the medial nasal glands.

Zuckerkindl ('10) observed a specimen of *emys europaea* and corroborates Seydel's important anatomical observations. In regard to the structure that Mihalkovics has designated the vomero-nasal organ he is of the opinion that it is the duct of the medial nasal glands. Zuckerkindl further observed that the olfactory nerves arise from two areas of nasal mucosa. A dorsal branch arises from the mucosa of the pars olfactoria and a ventral branch receives filaments from the vomero-nasal area. The dorsal and ventral branches unite to form a common olfactory nerve that passes through a large opening in the cranium together with the nerve of the opposite side. As these nerves approach the olfactory bulb in their course caudalward the nerve bundles become separated, the dorsal branch forms a large lateral bundle that distributes filaments to the apex and the ventral surface of the olfactory bulb and extends dorsalwards over the medial and lateral surfaces. The ventral branch becomes the more slender medial ramus that sends filaments to the upper half of the medial surface and to the dorsal surface of the olfactory bulb.

#### CHRYSEMYS PUNCTATA

The nasal fossa in *chrysemys punctata* consists of a principal nasal chamber that communicates anteriorly with a circular naris by means of a small cylindrical nasal passage and posteriorly with the choana through a larger posterior nasal canal.

By referring to figure 3 it will be seen that the principal nasal chamber is oval in transverse section with the greatest diameter in the perpendicular direction and its shortest diameter in a horizontal plane. The anterior nasal passage communi-

cates with it on the anterior wall about half the distance between the roof and the floor. The posterior nasal canal extends horizontally caudalward on a level with the floor. The otherwise smooth interior is interrupted by many low ridges which course generally in an antero-posterior direction and subdivide the cavity into numerous fossae of varying sizes and depths.

Beginning just above the communication between the principal nasal chamber and the anterior nasal passage are two ridges, one of which extends caudalward over the medial wall, the other in the same direction over the lateral wall and become less pronounced as they approach the posterior wall. These ridges which are covered by respiratory epithelium separate completely a large fossa in the roof of the principal nasal chamber. This fossa is covered by olfactory neuro-epithelium and gives origin to the olfactory nerves. Below the two ridges mentioned above is an extensive fossa that occupies the lower half of the anterior wall, the anterior portion of the floor and adjacent portions of the medial and lateral walls. This area which has a very irregular outline is covered by the vomero-nasal neuro-epithelium and gives origin to the vomero-nasal nerves. By referring to figure 2, which is a transverse section through the anterior portion of the principal nasal chamber, it will be seen that the vomero-nasal organ occupies a single and extensive fossa situated on the lateral, medial and anterior walls of the nasal chamber. By following this fossa caudalward in serial section it will be found that it becomes subdivided into four areas (fig. 3) by the apparent invasion from the caudal direction of three low ridges capped by respiratory epithelium and thereby giving to the vomero-nasal organ the appearance of occupying four separate fossae.

The olfactory neuro-epithelium (figs. 7 and 8) occupies the roof and adjacent portions of the medial, anterior and lateral walls of the nasal chamber. It extends lowest on the anterior wall where it covers one-third the distance from roof to floor. From this point the border gradually recedes dorsally until the caudal wall is reached. The vomero-nasal neuro-epithelium



occupies the lower portion of the anterior, medial and lateral walls and floor of the nasal chamber. It occupies a single irregular fossa and is separated from the olfactory neuro-epithelium by low ridges covered by respiratory epithelium. The remaining portion of the wall of the nasal chamber is covered by respiratory epithelium.

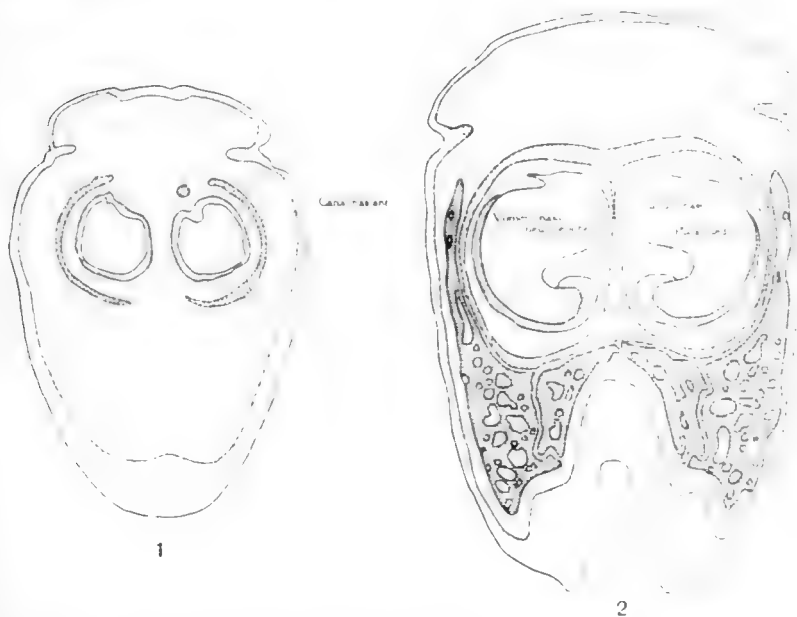


Fig. 1 A transverse section of the head of a turtle at about the middle of the anterior nasal canal. It shows the form of this portion of the nasal fossa.  $\times 10$ .

Fig. 2 A transverse section of the head of a turtle passing through the anterior portion of the principal nasal chamber to show the form of the nasal fossa and the position and distribution of the vomero-nasal mucosa.  $\times 10$ .

The anterior nasal passage extends nearly horizontally caudalward from the naris and communicates with the principal nasal chamber about midway between the roof and floor. It is nearly cylindrical in outline and presents a low ridge that courses obliquely in a caudo-lateral direction from a medio-cephalic origin.

The posterior nasal canal extends nearly horizontally caudalward from the principal nasal chamber. It is semicircular in cross section. Attached to the anterior half of the lateral wall and to the cephalic portion of the roof is a crescentic valve-like fold that separates a dorsally placed blind pouch that opens caudalward.

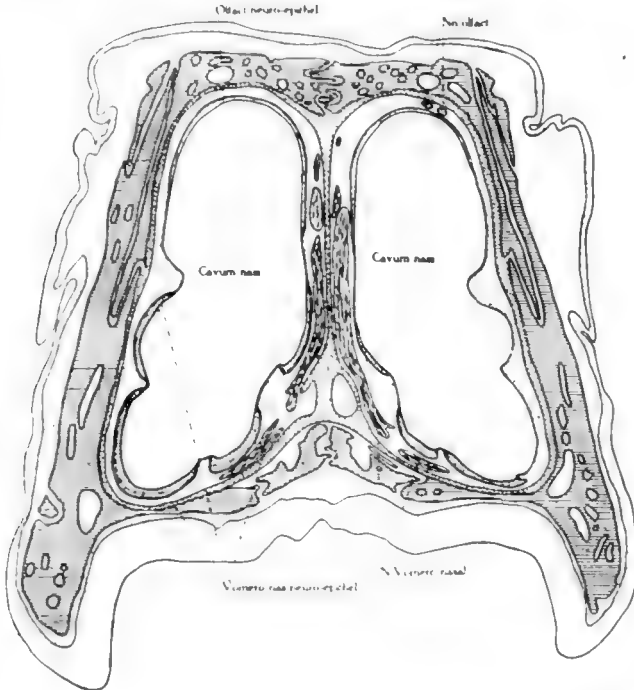


Fig. 3 A transverse section of the head of a turtle passing through the middle of the principal nasal chamber showing its form and size, the distribution of the vomero-nasal and olfactory neuro-epithelium and peripheral course of the vomero-nasal nerves.  $\times 10$ .

The nerve fibers from that portion of the neuro-epithelium of the vomero-nasal organ situated on the lateral wall collect into two limbs—an anterior and a posterior. The former is the smaller and courses downward in the lateral wall of the nasal fossa. The latter is a broad flat band that passes medially beneath the floor and is joined by the anterior limb.

These combined filaments form a broad sheet of nerve fibers coursing medially beneath the floor to the medial wall and at the same time receiving additional fibers from the neuro-epithelium. In the medial wall the broad flat band of nerve fibers becomes somewhat narrowed and thickened and courses dorsally and somewhat caudally to the roof of the nasal fossa. Here it is joined by the bundle of olfactory nerves of the same side and the

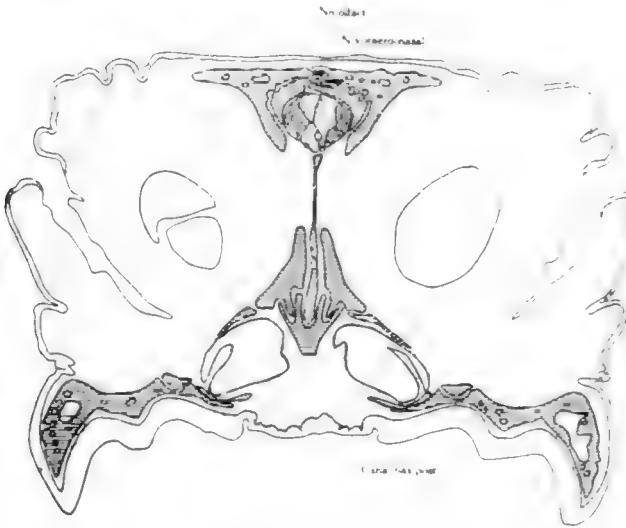


Fig. 4 A transverse section of the head of a turtle passing through the middle of the posterior nasal canal. It shows the form of this passage and the relation of vomero-nasal and olfactory nerves in their course through the cranium.  $\times 10$ .

combined filaments of vomero-nasal and olfactory fibers of the opposite side. The combined filaments form a large round nerve bundle that courses caudalward through a large opening in the cranium to the cranial cavity. Although the right and the left vomero-nasal and olfactory nerves course through the cranium together the nerve fibers of the different bundles do not intermingle. They lie contiguous to one another and may be separated from each other with little effort as will be seen by referring to figure 4.

As they enter the cranial cavity the vomero-nasal and olfactory nerves separate: the former pass dorsal to the olfactory nerves and to the dorsal surface of the olfactory bulb where the filaments spread out over the vomero-nasal area.

The nerve fibers of the olfactory neuro-epithelial area collect into numerous filaments that course dorsalward and converge to form a large oval bundle above the roof of the nasal fossa. The bundle of olfactory nerves lie lateral to the vomero-nasal fibers in its course through the large opening in the cranium.

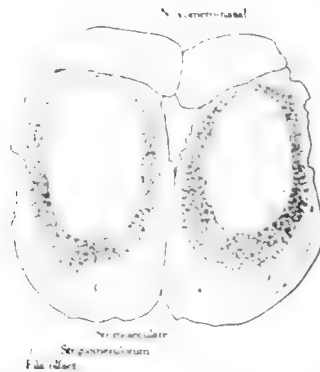

Fig. 5. A transverse section through the anterior portion of the olfactory bulbs of the turtle to show the relation of olfactory and vomero-nasal nerves.  $\times 20$ .

Upon reaching the cranial cavity olfactory fibers separate from the vomero-nasal fibers and pass ventralward to be distributed to the olfactory area on the apex and ventral surface of the olfactory bulb.

The olfactory bulb is an ovoid mass extending horizontally forward from the forebrain. It is separated from the latter by a well defined oblique groove that defines a very short olfactory peduncle. By referring to figures 5, 6, 7, and 8 it will be seen that the surface of the bulb is sub-divided into two definite and separate areas. An oval area occupying the entire dorsal surface and upper half of the medial surface of the bulb to which the vomero-nasal filaments are distributed is the vomero-nasal

area of the olfactory bulb. This area is homologous to the accessory olfactory bulb of mammals. The olfactory area of the bulb is somewhat more extensive. It occupies the apex, and ventral surface and extends some distance upward on the

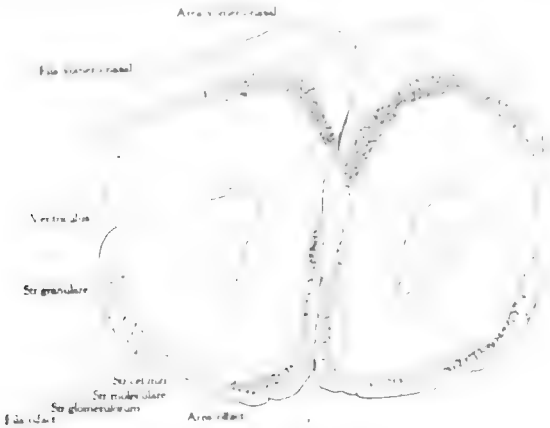

Fig. 6 A transverse section through the middle portion of the olfactory bulb to show the relation of the vomero-nasal and olfactory areas.  $\times 20$ .

lateral and medial surface. The filaments of the olfactory nerves are distributed to this area. An extension forward of the fore brain cortex separates the vomero-nasal and olfactory areas of the olfactory bulb.




Fig. 7 A medial view of a wax plate reconstruction of the olfactory apparatus of the turtle to show the origin course and distribution of the vomero-nasal and olfactory nerves.  $\times 3$ .

Fig. 8 A lateral view of a wax plate reconstruction of the olfactory apparatus of the turtle to show the origin, course and distribution of the vomero-nasal and olfactory nerves.  $\times 3$ .

In transverse section (fig. 6) the olfactory bulb exhibits a large ventricle oval in form. One can distinguish the different concentric layers that have been described for this portion of the brain in other forms. The nerve fiber layer is incomplete and presents a dorsal segment of vomero-nasal fibers and a ventral segment of fila olfactoria. The latter completely encircles the olfactory bulb in the lower mammals. The glomerular layer presents a dorsal and a ventral segment. The former is much thicker than the latter. Then follow the molecular, nerve cell, the granular and ependymal layers in order.

#### RANA

The excellent description of the nasal fossa in *Rana* by Ecker and Gaupp has been frequently consulted and, as far as possible, the same terminology has been used in this communication. While he recognized the origin of the olfactory nerves from the olfactory mucosa by two branches—a large dorsal and a small ventral—and that the vomero-nasal nerves join the dorsal ramus, he failed to determine the further course and termination of the vomero-nasal nerves as a separate bundle. He states that the olfactory nerves on entering the cranium separate into two roots, an anterior distributed to the antero-ventral surface of the olfactory bulb, and a posterior root that is distributed to the accessory olfactory bulb.

Zuckerkindl ('10) was the first to recognize a separate vomero-nasal apparatus for the amphibians. He describes the formation of the common olfactory nerves as of fibers formed by the union of the olfactory and vomero-nasal nerves but fails to state the relations of vomero-nasal and olfactory nerves in their passage from the nasal cavity to the brain.

#### RANA CATESBIANA

Although the nasal cavity of the frog has been very carefully described by Ecker and Gaupp and in text books on comparative anatomy it appears to me advisable, owing to the complexity of the arrangement of its subdivisions, to summarize briefly its more important features.

The nasal cavity of the frog is situated in the anterior part of the cranium. It is very much flattened dorso-ventrally and expands anteriorly and laterally so that in a dorsal view it presents a semicircular outline. The anteriolateral curved

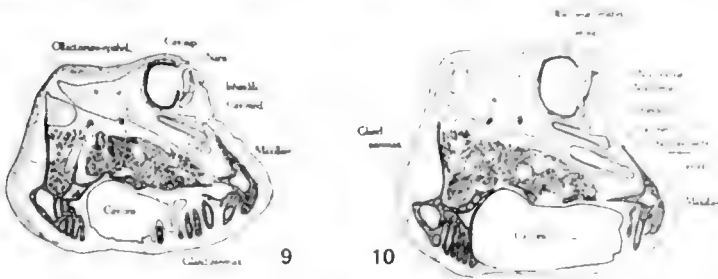


Fig. 9 A transverse section through the head of the frog in the region of the external nasal opening. It shows the form of the principal and middle nasal chambers and the distribution of the olfactory mucosa.  $\times 2.5$ .

Fig. 10 A transverse section through the head of a frog posterior to nares. It shows the relation between the superior, middle and inferior nasal cavities and the distribution of the olfactory mucosa.  $\times 2.5$ .

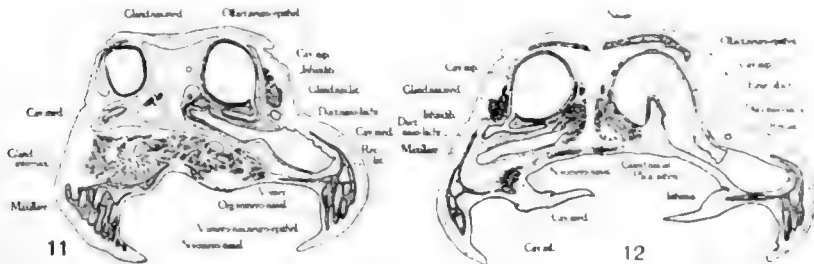


Fig. 11 A transverse section through the vomero-nasal organ of the frog showing the relation of the superior, middle and inferior nasal cavities and the distribution of the vomero-nasal and olfactory mucosa.  $\times 2.5$ .

Fig. 12 A transverse section through the middle of the principal nasal cavity of the frog showing distribution of olfactory mucosa and the relation of vomero-nasal and olfactory nerves.  $\times 2.5$ .

margins follow closely the curvature of the maxillae. It consists of two parts, the right and the left nasal fossae. Each fossa communicates with the exterior by an external nasal aperture, the nares, and with the oral cavity by an oval internal nasal aperture—the choana.

The nasal fossa is subdivided into several irregular communicating chambers which have become separated to a greater or less extent during the process of development, by the ingrowth of septa and ridges. It, therefore, presents for description a

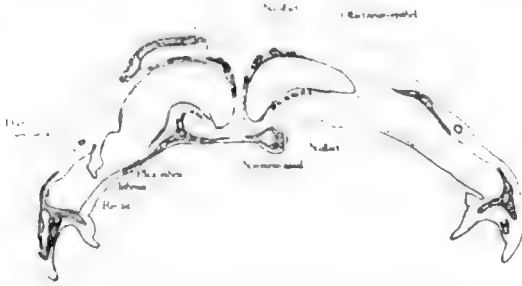


Fig. 13 A transverse section through the choana of the head of a frog. It shows the distribution of the olfactory mucosa and the relation of the vomero-nasal and olfactory nerves.  $\times 2.5$ .

superior or principal, a middle and an inferior nasal chamber, a lateral recess, the vomero-nasal organ, and two well defined narrow connecting channels, the infundibulum and the isthmus.

The principal nasal chamber occupies a dorso-medial position and comprises about three fourths of the fossa (figs. 15 and 16). By referring to figure 9, it will be seen that a transverse section

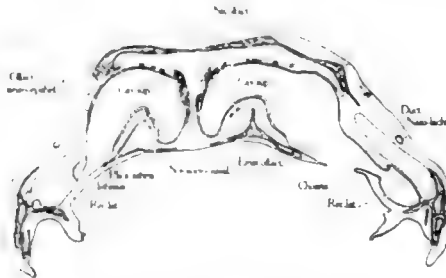


Fig. 14 A transverse section of the head of a frog passing through the posterior part of the superior nasal cavity. It shows the distribution of the olfactory mucosa and the relation of the vomero-nasal and olfactory nerves.  $\times 2.5$ .

of the cephalic portion of the superior chamber has a circular outline and communicates with the exterior by means of the naris. At the lower part of the lateral wall can be seen the



plica terminalis which marks off a deep groove which is the beginning of the infundibulum. In this region the principal nasal cavity is covered for about three-fourths of its circumference by olfactory neuro-epithelium.

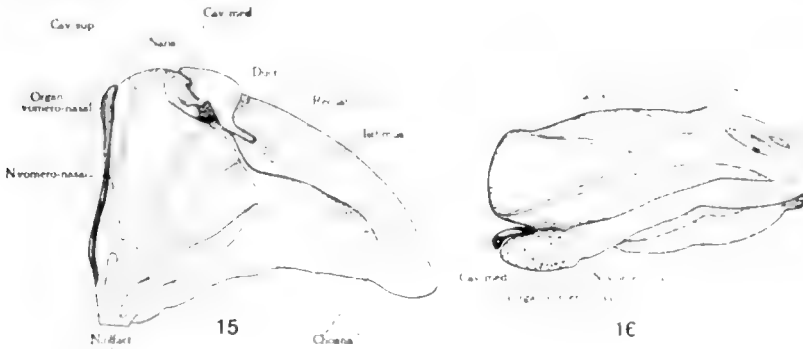


Fig. 15 A medial view of a wax plate reconstruction of the nasal fossa of the frog. It shows the origin and peripheral course of the vomero-nasal and olfactory nerves. About three times natural size.

Fig. 16 A dorsal view of a wax plate reconstruction of the nasal fossa of a frog showing the origin and peripheral course of the vomero-nasal and olfactory nerves. About three times natural size.

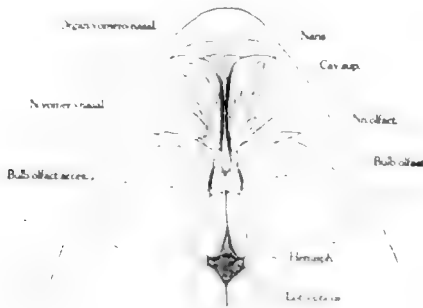


Fig. 17 Represents a dissection of the olfactory apparatus of the frog showing the origin course and distribution of the vomero-nasal and olfactory nerves. Two and one-half times natural size.

Figure 10 represents a cross-section of the principal nasal chambers posterior to the naris. It presents the beginning of the infundibulum separated from the principal nasal chamber by

the broadened plica terminalis. It may be seen that the olfactory neuro-epithelium covers the floor, the medial wall and the greater portion of the roof. The remaining one-third of the circumference is clothed by respiratory mucosa. The principal nasal chamber in figure 11 presents a nearly circular outline and communicates at its ventro-lateral margin with the middle nasal chamber by means of the infundibulum. The olfactory neuro-epithelium covers about three-fourths of its circumference. The lateral wall is covered by simple mucosa. In figure 12 the principal nasal chamber presents the form of an inverted horse shoe. The lateral limb of which communicates through the isthmus with the lateral recess. The olfactory eminence which extends dorsally from the floor aids materially in giving the peculiar form to this portion of the cavity. It will be seen that the olfactory neuro-epithelium has become separated into two areas by a narrow intervening zone of indifferent mucosa. One area covering the olfactory eminence and a more extensive layer lining nearly all of the medial and lateral walls and the roof.

Figure 13 represents a section passing through the choana. The principal nasal chamber has an outline similar to that of figure 12. It communicates directly with the choana. The olfactory eminence has increased in height and breadth. The olfactory neuro-epithelium occupies two areas on the circumference of the chamber. One caps the olfactory eminence, the other covers the upper part of the medial wall and about the medial two-thirds of the roof. The former is more extensive and the latter less extensive, than shown in figure 12. These two areas are separated by a broad intervening zone of respiratory epithelium.

Figure 14 represents a section posterior to the choana. The principal nasal chamber shows marked reduction in size and has a semilunar outline. The olfactory eminence is very much flattened. The olfactory neuro-epithelium caps the olfactory eminence and covers a portion of the medial wall and roof of the nasal chamber; the remaining circumference in this region is covered by respiratory epithelium.

The small middle nasal chamber is situated ventro-lateral to the cephalic extremity of the principal chamber. It is much flattened dorso-ventrally and broad in a transverse direction (figs. 15 and 16). The naso-lachrymal duct communicates with its postero-lateral angle (fig. 10). Posteriorly it communicates with the principal nasal chamber through the anterior part of the infundibulum (fig. 11), and more caudally with the inferior nasal chamber. In fact, the middle chamber appears to be merely an anterior sacculated expansion of the tear duct. It is lined by simple mucosa.

The inferior nasal chamber is an elongated, transversely placed cavity lying ventral to the cephalic extremity of the principal nasal chamber. It is directly continuous laterally with the lateral recess and medially with the vomero-nasal organ. The inferior nasal chamber as shown in figure 10 is an obliquely placed cavity, oval in outline, and clothed by ordinary mucosa. In figure 11 this cavity is shown in direct communication laterally with the lateral recess and medially with the medial recess, the vomero-nasal organ. It is everywhere covered by simple mucosa.

The lateral recess is the direct latero-caudal extension and expansion of the inferior nasal chamber. It is oval in outline and follows the curvature of the maxilla. It communicates anteriorly with the inferior nasal chamber (fig. 11), medially with the principal chamber through the isthmus (fig. 12), and more caudally with choana and oral cavity (figs. 13 and 14). It is lined by simple mucosa.

The vomero-nasal organ is a cup shaped structure that lies at the medial extremity of the inferior nasal chamber and communicates directly with it laterally. It is clothed by neuro-epithelium (fig. 11). The infundibulum is a broad flattened channel which permits communication between the anterior portion of the principal nasal chamber and the middle and the inferior nasal chambers.

The isthmus is an obliquely placed slit (fig. 12), broad in a sagittal plane that serves as a means of communication between the principal nasal chamber and the lateral recess.

It will be seen from the foregoing and by referring to figures 9 to 16 inclusive that the neuro-epithelium is found in two separate and distinct regions of the nasal fossa.

The olfactory mucosa consists of a very extensive and irregular area on the wall of the principal nasal chamber. From an extensive area covering the anterior wall and the adjacent portions of the floor, medial wall and roof as shown in figures 9, 10, and 11, the olfactory mucosa extends caudalward in two strips or zones separated by intervening zones of respiratory epithelium, figures 12, 13, and 14. The ventral, caudal prolongation covers the olfactory eminence and gives origin to the small ventral branch of the olfactory nerves. The dorsal, caudal prolongation covers a variable portion of the medial and lateral walls and the roof of the principal nasal chamber. This portion of the olfactory mucosa together with the extension forward on to the anterior wall gives rise to the large dorsal branch of the olfactory nerves.

The vomero-nasal mucosa lines the wall of the cup-shaped vomero-nasal organ and gives rise to the vomero-nasal nerves. All the remaining portion of the nasal cavity is lined by respiratory epithelium.

It will be seen from the foregoing description that the vomero-nasal apparatus in the turtle equals in size and importance that of the ordinary olfactory mechanism. That the olfactory bulb exhibits an olfactory and a vomero-nasal area which share about equally in its formation. In the frog, however, the vomero-nasal apparatus apparently performs a secondary roll in olfaction. It is very small compared to the olfactory mechanism. The accessory olfactory bulb is situated on the lateral surface of the hemisphere caudal to the olfactory bulb and is only about one twenty-fifth the size of the olfactory bulb.


By referring to figures 12, 13, and 14 it will be seen that the olfactory nerves collect into two separate groups. Filaments collecting into nerve bundles on the dorso-medial wall of the superior chamber form the large dorsal ramus of olfactory nerves and filaments collecting into nerve bundles from the mucosa of the olfactory eminence form the small ventral branch

of the olfactory nerves. These branches course caudalward and join to form a single bundle at the caudal extremity of the principal nasal chamber. From this point it courses to the olfactory bulb where it becomes distributed over the antero-ventral surface.

The vomero-nasal nerves formed by filaments from the dorsal, ventral and medial walls of the vomero-nasal organ form a single rounded bundle that courses dorso-caudally in the medial wall of the principal nasal chamber. At the caudal extremity of this chamber it joins the bundle of olfactory nerves. Although there is a slight intermingling of the vomero-nasal and olfactory bundles the majority of the fibers of the former can be followed in their spiral course caudalward where they wind beneath the olfactory nerves to gain the lateral side of this bundle and course over the lateral surface of the olfactory bulb to reach the accessory olfactory bulb, which lies more caudally (fig. 17).

## LITERATURE CITED

- ECKER-GAUPP. Anatomie des Frosches.
- MCCOTTER, R. E. 1912 The connection of the vomero-nasal nerves with the accessory olfactory bulb in the opossum and other mammals. *Anat. Rec.*, vol. 6, p. 299-318.
- MIHALKOVICS, V. 1898 Nasenhöhle und Jacobson'sche Organ. *Anat. Hefte*, Bd. 2, Abt. 1, s. 3-107.
- SEYDEL, O. 1895 Über die Nasenhöhle und das Jacobson'sche Organ der Amphibien. *Morph. Jahrb.*, Bd. 23, S. 453-543.
- 1896 Über die Nasenhöhle und Jacobson'sche Organ der Land und Sumpf-schildkröten. *Festschrift zum 70. Geburtstag von C. Gegenbaur*, B. 2., 1896.
- ZUCKERKANDL, E. 1910 Über die Wechselbeziehung in der Ausbildung des Jacobson'schen Organs und des Riechlappens. *Anat. Hefte*, Bd. 41, Abt. 1, S. 3-73.



# HISTOLOGICAL STRUCTURE OF THE RETRACTOR PENIS MUSCLE OF THE DOG

HOMER G. FISHER

*From the Anatomical Laboratory of the Johns Hopkins University*

FOUR FIGURES (TWO PLATES)

During the past few years, physiologists and chemists have been working with the retractor penis muscle of various animals, chiefly of the dog. The muscle has in every case been regarded by these workers as composed of non-striated fibers. The results obtained in these investigations have been discordant, differing in some regards from the customary reactions, both physiological and chemical, of other smooth muscles. At the suggestion of Dr. Charles D. Snyder, this study of the histology of the retractor penis muscle was undertaken, for it was felt that any theories of smooth muscle contraction, arising from a study of this retractor muscle, must be based upon an established histology.

The retractor penis muscle in the dog is a cord-like structure, pale and translucent in its anterior portion but somewhat darker and more fleshy in its posterior fraction. It has its origin by two separate bundles of fibers, one from each side of the sphincter ani muscle. These bundles pass ventrally and at a distance of about 1 cm. from the sphincter join in the median plane and run forward over the ventral surface of the corpus spongiosum to the base of the glans where the fused bundles are inserted into the corpus spongiosum. In the medium-sized dog of 6 to 10 kilograms, the muscle has a length of about 50 mm. while its diameter is about 3 mm. throughout its whole extent. The muscle is surrounded by a dense fibrous sheath, continuous with the fascia covering the sphincter. On both sides of this are the bulbocavernosus muscles; these are attached partly into the sheath of the retractor penis muscle and partly into the

fibrous tissue of a median raphe on the ventral side of that muscle.

In this study the retractor penis muscles of five adult dogs and of one puppy were examined. The muscles were removed, fixed in Bouin's picro-formalin-acetic fluid and embedded in paraffin. The sections were stained in hematoxylin and eosin, iron hematoxylin and Mallory's connective tissue stain. One muscle was cut serially and another was removed with the adjacent part of the bulbocavernosus intact; this block was sectioned for the purpose of determining the relations of the two muscles. Representative sections were examined from different parts of the other retractor muscles.

A study of the sections showed in every instance that the retractor muscle is mixed, i. e., composed of both smooth and striated fibers. The anterior three-fifths of the muscle is composed entirely of smooth fibers (fig. 1) while the posterior two-fifths is made up of fibers of both types (fig. 3). The number of striated fibers in the posterior part is variable but their presence is constant. The proportion of striped muscle varied in the specimens studied from one-third to one-half. The proportion of striated fibers was least in the muscle from the puppy.

A characteristic field in the anterior part of the muscle (figs. 1 and 2) shows large spindle-shaped smooth muscle cells varying in none of the essential features from the usual text-book descriptions. The cells for the most part have their long axes parallel to the long axis of the muscle but there is some tendency to interlacing of the fibers and bundles of fibers (figs. 1). With Mallory's connective tissue stain the muscle plasma takes the characteristic red color. Sections treated with this stain show the amount of connective tissue to be abundant. This tissue is partly of the white fibrous variety, but there is distributed throughout a relatively great number of elastic fibers. In certain of the sections (fig. 2) these fibers have an undulating, wavy appearance. The nuclei of many of the smooth muscle cells in such a region tend to assume spiral forms. McGill ('09) has described this phenomenon in smooth muscle from the walls of arteries and has reviewed the literature on the subject



particularly in regard to its cause and significance. The spiral form may be due, as is suggested, to the "active or passive" contraction of the muscle cells, or it may be related to the shortening of the elastic tissue. While the cause of these spiral nuclei cannot be determined from the evidence at hand, it may be noted that in the tissues in which McGill described the phenomenon, there is also associated with the muscle element a relatively large amount of elastic tissue. In the sections from the retractor muscle studied, the spiral form of the nuclei is most abundant where the elastic tissue is most undulating and presumably in the most shortened state.

The microscopic structure, then, of the anterior three-fifths of this muscle is quite characteristically that of any smooth muscle, with, however, a considerable interlacing with yellow elastic tissue. In the posterior portion of the muscle, the histology is quite different (figs. 1 and 3). Interspersed with the typical bundles of smooth muscle cells are frequent small fasciculi of striated muscle fibers. These fasciculi are often broken up with the individual fibers diverging somewhat from the original plane. In other places, a few single and isolated cross-striated fibers are found in the midst of dense smooth muscle fasciculi. In general, however, the grouping of the striated fibers is in small fasciculi, alternating with equally small bundles of the non-striated variety. This rather general arrangement can be made out in a low-power photomicrograph of a characteristic field in the posterior two-fifths of the muscle (fig. 3). In this, it is seen that the general direction of the fasciculi is parallel to the long axis of the muscle.

Under higher magnification, the cross-striated fibers are found to possess the typical structure of such voluntary muscles from other parts of the body. The striation (fig. 4) is very distinct and outspoken, very regular and at right angles to the long axis of the fiber. The alternation of light and dark bands is entirely similar to that of typical cross-striated muscle. The nuclei, oval and with only a small amount of chromatin, are found solely in the peripheral portions of the fibers. Between these fibers, a minimum amount of white fibrous connective tissue

with but few yellow elastic fibrils is found. When stained by Mallory's method, the cross-striations of these fibers are beautifully brought out, if Kingery's ('16) use of this stain after Bouin's fixation be followed. Under this higher magnification, also, the smooth muscle fibers are found to be quite similar to those of other organs (fig. 4).

In the posterior two-fifths of the retractor muscle, the proportion of striped fibers to the unstriped is about equal, or the unstriped fibers may be somewhat in excess. This proportion has been calculated from a study of the serial sections through the whole retractor muscle of an adult dog; it represents not an exact determination of the amount of either type of muscle but rather a rough judgment of the proportion. In many single sections, as illustrated by figure 3, the relative amounts of striated and smooth muscle may be easily estimated. Apparently, the amount of striped muscle in the one puppy studied was somewhat less than in the adult animals.

In the gross, it seemed possible that the striated element of the retractor muscle might be derived from direct extensions of the bulbocavernosus fibers which at their insertions attach partly to the sheath of this muscle in its posterior portion. Serial sections, however, of a block made up of the two muscles removed intact failed to demonstrate any such origin; there was always a definite fibrous sheath interposed between the fibers of the retractor and those of the bulbocavernosus. While no definite continuous prolongation of the striated fibers from the adjacent structures was demonstrated, it is possible that they are derived from the same anlage as the sphincter ani muscle with which the retractor is so closely associated. The exact origin of the retractor penis muscle is rather indefinite, for the fibers arise gradually out of the sphincter.

The nerve supply to the retractor penis muscle was not demonstrated. It was suggested that if the muscle was supplied by the sacral autonemics (as seems most likely), one might possibly be able to find nerve ganglia either in the muscle or in its sheath. Systematic search was made in serial sections for nerve-cells but with negative results as regards the demonstration of such collections of nerve-cells.

Thus it seems quite necessary to consider this retractor penis muscle as being mixed, composed of both smooth and striated fibers. Until 1915, however, this muscle, so far as it is possible to determine from the literature, was considered as a typical smooth muscle. This conception of its histology has led to its use by chemists as a relatively large mass of smooth muscle tissue, and determinations of the creatin, carnosine and other nitrogenous extractives in it have been made. The finding of a disproportionate amount of these chemical bodies in this muscle differentiated it chemically from other smooth muscles. The chemists, however, have considered that the findings harmonize with Botazzi's observation that the muscle is different physiologically from intestinal or other smooth muscle, for it has a shorter latent period and sometimes presents two types of contraction, viz., the clonic and tonic. But it seems proper to suggest here that the finding of a somewhat larger amount of creatin and other nitrogenous bodies in the retractor muscle was due to the presence of cross-striated fibers.

Retterer and his co-workers ('09-'15), in a series of articles dealing with the structure of muscle, has described the retractor muscle anatomically, both from a gross and microscopical standpoint, and has reviewed the literature on the subject. Chauveau was apparently the first to examine the muscle histologically, and in 1857 described it in the horse as composed of smooth muscle fibers (*fibres musculaires de la vie organique*). Comparative anatomists in subsequent publications either did not comment on the microscopic structure of the muscle or merely stated that it was involuntary. Retterer '15) concluded that the muscle was striated but attributed the striations to the branching of the elastic tissue fibers and not to the characteristic cross-striations of voluntary muscle. These branches were described as leaving the longitudinal elastic fibers at right angles and encircling the muscle fibers or even passing into their substance, so as to give the appearance of heart muscle. Such appearances have also been observed in the present study, but the phenomenon of the cross branching of elastic fibers was found to occur only in the smooth portion

of the muscle. It must be emphasized, however, that these lateral branchings of the elastic elements of the muscle are entirely different from the striations of the striated fibers in the posterior part of the muscle where the cross-striations observed are evidently due to the alternation of light and dark bands in the myofibrils, as in typical cross-striated muscle fibers.

Botazzi ('15), who made an extensive study of the retractor muscle from a physiological standpoint, divided the muscle into three parts—an anterior or prepuccial end, a middle portion, and a posterior or perineal end. He stated that the posterior fraction is darker than the other portions and suggested that it resembles striated muscle in its gross appearance. On direct stimulation he obtained from some specimens two types of contraction—a clonic or twitch contraction, and a tonic contraction (slow and gradual)—while from other preparations he obtained only the tonic contraction. He writes (page 11) that "if the animal is very large the muscle is excessively long and then I take only the prepuccial and middle parts. If instead the animal is small, I isolate and take out also the extreme perineal end." While he does not state with which muscle preparations he obtained the two types of contraction, it is possible that they were obtained only from those preparations comprising the entire muscle. This would include the portion of the muscle containing the striated fibers which on direct stimulation should give a clonic type of contraction. On the other hand, the smooth muscle fibers might well be expected to yield only the tonic type of contraction.

It seems, then, justifiable to conclude that the retractor penis muscle of the dog is mixed. In the anterior three-fifths the fibers are wholly smooth while in the posterior two-fifths the fibers are both smooth and cross-striated. The divergent chemical and physiological observations based on the assumption that this muscle was wholly smooth, have a possible explanation in the mixture of the two kinds of muscle fibers here described.

## BIBLIOGRAPHY

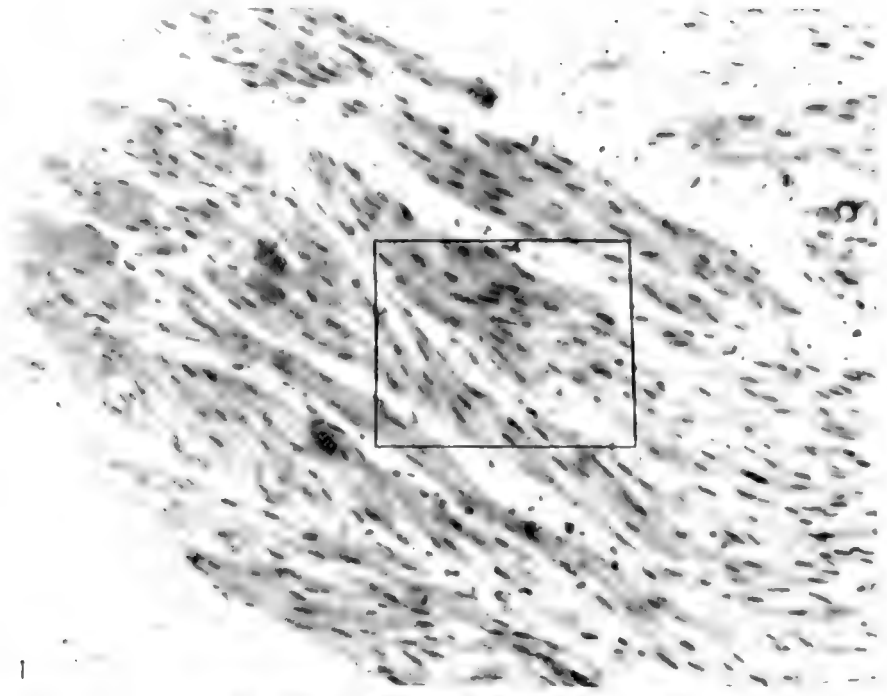
- BOTTAZZI, FILIPPO 1915 Ricerche sul M. Retractor Penis e su altri preparati Muscolari Lisci. Tipografia della R. Accademia dei Lincei, v. 2, p. 43.
- BUGLIA, G. UND CONSTANTINO, A. 1912 Beiträge zur Muskelchemie. Zeitschrift für Physiologische Chemie, Bd. 81, p. 120.
- KINGERY, H. M. 1916 Some uses of Mallory's connective tissue stain. Anat. Rec., vol. 12, p. 291.
- MCGILL, CAROLINE 1909 The structure of smooth muscle in the resting and in the contracted condition. Am. Jour. Anat., vol. 9, p. 493.
- RETERER, E. ET LELIEVRE, A. 1909 Structure du tissu musculaire lisse. Comptes Rend. Soc. de Biol., T. 61, p. 244.
- 1915 Les fibres musculaires des cordons retractor penis sont des fibre cellulés striés en travers. Comptes Rend. Soc. de Biol., T. 78, p. 136.
- ET NEUVILLE, H. 1915 Des connexion et de la structure des cordons musculo-élastiques ou retracteurs du penis. Comptes Rend. Soc. de Biol., T. 78, p. 60.

## PLATE 1

### EXPLANATION OF FIGURES

1 Retouched photomicrograph of typical field in anterior two-fifths of the retractor penis muscle of the dog. The smooth muscle fibers are shown collected in bands and converging somewhat at the anterior termination of the muscle. Enlargement, 240 diameters.

2 Retouched photomicrograph, under higher magnification, of the rectangular area shown in figure 1. The fasciculi of smooth muscle fibers are shown separated by somewhat abundant connective tissue. The nuclei of the non-striated fibers exhibit a spiral form. Enlargement, 750 diameters.



1



2


## PLATE 2

### EXPLANATION OF FIGURES

3 Retouched photomicrograph of a typical field in the posterior two-fifths of the retractor penis muscle of the dog. The alternation in the section of striated and non-striated fibers is well brought out and the equal proportion of the two types of fibers is indicated. Enlargement, 180 diameters.

4 Retouched photomicrograph of the squared area in figure 3. The typical cross striations of the cross-striated muscle fibers and the peripheral distribution of their nuclei is well brought out. On both sides of these striated fibers are dense bundles of smooth muscle. Enlargement, 750 diameters.







# PRELIMINARY NOTE ON THE NUCLEAR DIVISION IN THE ADIPOSE CELLS OF INSECTS

WARO NAKAHARA

*From the Department of Entomology, Cornell University*

ELEVEN FIGURES

As to the biological significance of amitosis, Flemming's ('91) theory that "it represents either degeneration or an aberration, or perhaps in many cases is tributary to metabolism through the increase of nuclear surface" (Wilson, '00, p. 117) is generally regarded as representing the truth. Cells which have divided amitotically and are active in their metabolic processes may eventually degenerate and perish. This, however, is no direct proof of the first part of Flemming's statements here cited.

My study on the relation of nuclear divisions and metabolic activity in the adipose cells of various insects furnishes good evidence to show that amitosis does not mean the approach of degeneration, or aberration at all, but this kind of nuclear division may be chiefly, if not entirely, to secure the increase of the nuclear surface to meet the physiological necessity which is due to active metabolic interchanges between nucleus and cytoplasm. This is the theory first suggested by Chun more than twenty-five years ago ('90), when he studied amitotic nuclear division in a giant entodermic cell of the radial canal of Siphonophores (Flemming, '91, '92; Wilson, '00), but was somewhat neglected by subsequent writers. According to this theory, amitosis is primarily concerned with the vegetative function of individual cells, and so amitosis can no longer be regarded as one of the two essential methods of cell-multiplication. It may perhaps be considered in association with such phenomenon as the ramification of the nucleus with its increasing functional activity, as in the case of silk-gland cells of many insects, and the division of

the cell-body following that of nucleus is a relatively subordinate phenomenon.

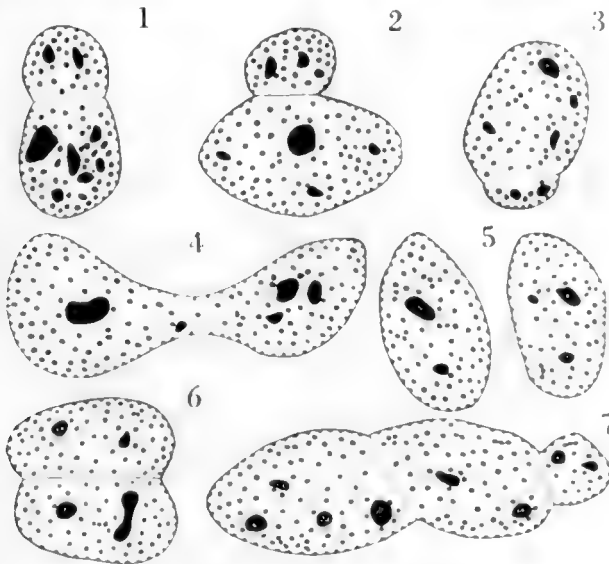
In this paper I wish to point out that in the case of the adipose cells of insects, amitotic nuclear division occurs preparatory to as well as simultaneously with a certain metabolic activity of the cell, in which nuclei take the rôle of essential importance. Fuller accounts of the relation of nuclear division and the metabolism of the cell in question, together with more extensive discussion on the general subject of amitosis, will be given in my further paper.

The following observation done primarily on larvae of *Pieris rapae*, brings out the general feature of the changes observable in larval adipose cells during their activity. Changes similar to those described below, have been observed by many previous writers and also by myself in the case of various other insects.

In an adipose cell from a larva of the first stage the nucleus is round and shows no sign of division; the cytoplasmic area is small in most cells and contains only a few vacuoles. These vacuoles we interpret as indicating the places occupied by fat-droplets. This rather unspecialized condition of the cell changes in the following stage by areal expansion and more vacuolate appearance of the cell-body and by frequent occurrence of peculiarly shaped nuclei. Some few of these nuclei show nothing but their irregularity in shape, while most of the others apparently represent different stages in the process of amitosis.

I have shown in figures 1 to 7 sketches of nuclei, all representing possible stages of amitosis, and many of which one can find in every section. I have not been able to find any particular way in which these nuclei divide, except that the division itself is effected by the constriction of the nucleus across its longitudinal axis, thus making the nucleus show a bilobed condition. More rarely, in the case of long, slender nucleus, constriction may take place at more than two different places in the nucleus, and in that case the latter shows multilobed appearance. Nucleoli and chromatin granules are apparently evenly distributed throughout the nucleus, and neither of them seems to behave unusually during the process.

In the third stage larva, one may notice the fact that some of the cells begin to show peculiar spherical granules in the cell-body. As pointed out by Berlese ('99), Pérez '02, '10., Henneguy ('04), and others, these granules are of albuminous nature, and occur more abundantly in close proximity to nucleus, than in the periphery of the cell. They become very abundant at the fourth stage and at the last larval stage almost all of the adipose cells are seen to be filled with the granules. The cell-



Figs. 1 to 7 Nuclei of adipose cells, representing possible stages of amitosis  $\times 750$ . Figure 6 represents predominating type.

body becomes larger and larger with the advancing stages of the insect; apparently correlating with this, the occurrence of nuclear division is seen more and more frequently, and finally, in old larvae, we find the condition as shown in figure 8 to be met with very commonly.

Summarizing the facts, we may say that, in the adipose cell, the nucleus continues to divide amitotically from early in the second stage, and the cell stores up albuminous granules in its cell-body, commencing the process late in the third stage. This

shows that the cell-nuclei which have undergone amitotic division, without regard to whether the cells remain multinucleate or not, do not degenerate, and the cells proceed with their active functional processes. This can be more strongly emphasized because we now see the fact that nuclei themselves take a direct part in the formation of albuminous granules, giving most conclusive evidence in support of the theory.

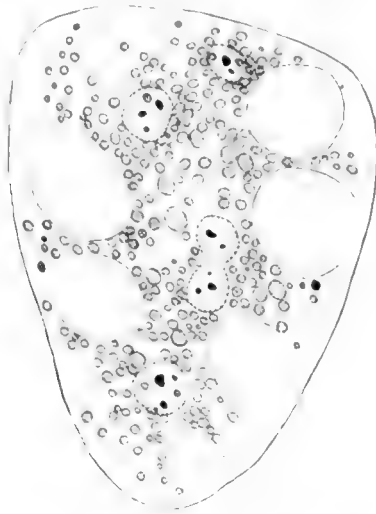
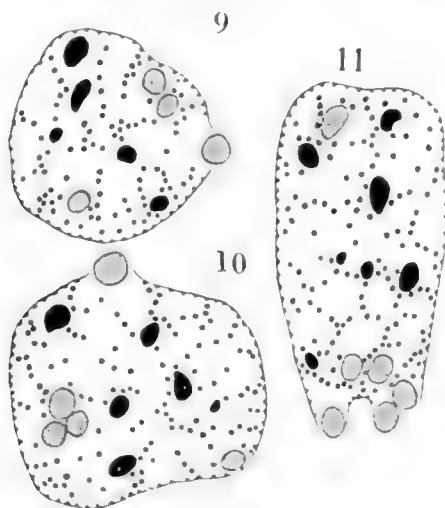


Fig. 8 A multinucleate adipose cell from an old larva, containing albuminous granules in its cell-body.  $\times 250$ .

It has been supposed by some writers that albuminous granules are derived from the blood. Hollande's ('14) recent work, from the chemical viewpoint, casts grave doubt on this assumption, and although he has given no evidence, he has suggested that the granules may be of nuclear origin. It seems quite probable, from a cytological point of view, that such might really be the case, and especially so when we recall the fact that, in the case of silk gland cells of *Pieris* and *Neuronia* at least, the nucleoli, after eliminating their phosphorus, change into albuminous granules and then extrude bodily out of the nucleus (Nakahara, '17).

Examining the nuclei of such cells as contain the granules, one can distinguish three different kinds of granules within them. One of the three kinds undoubtedly represents chromatin and another nucleoli, as can be judged from their appearances and staining reactions, characteristic of such elements. The third kind of granule is of nearly the same size as nucleoli but differs from the latter in that it shows stronger affinity for certain acid



Figs. 9 to 11 Nuclei of adipose cells, showing the extrusion of acidophile granules.  $\times 750$ .

and weaker for basis stains. This is exactly the sort of reaction shown by the cytoplasmic albuminous granules, and one may here assume that these acidophile granules in the nucleus may be extruded into the cell-body, constituting the albuminous granules in question. As evidence in support of this theory, I have shown in figures 9 to 11 some unmistakable cases of extrusion of the acidophile granules into the cell-body through the nuclear membrane. These are not cases rarely observable but are those of very frequent occurrence.

## LITERATURE CITED

- BERLESE, A. 1899-00 Osservazioni su fenomeni che avvengono durante la nin-fosi degli insetti metabolici. *Rivista di Patologia Vegetale.*, T. 8, pp. 1-444.
- FLEMMING, W. 1891 Ueber Theilung und Kernformen bei Leukocyten und deren Attractionssphären. *Arch. f. mikroskop. Anat.*, Bd. 37, pp. 249-298.
- 1892 Zelle. Entwicklung und Stand der Kenntnisse über Amitose. *Merkel u. Bonnet's Ergebnisse der Anat. u. Entwickl.*, Bd. 2, pp. 37-82.
- HENNEGUY, L. F. 1904 *Les insectes*. Paris.
- HOLLANDE, A. CH. 1914 Formations endogenes des cristalloides albuminoides et des urates des cellules adipeuses des chenilles de *Vanessa io* et *Vanessa urticae*. *Arch. Zool. Exp. Gener.*, T. 53, pp. 559-578.
- NAKAHARA, W. 1917 On the physiology of the nucleoli as seen in the silk-gland cells of certain insects. *Journ. Morph.* (in press).
- PÉREZ, CH. 1902 Contribution à l'étude des métamorphoses. *Bull. Sci. de la France et de la Belgique*, T. 37, pp. 195-427.
- 1910 Recherches histologiques sur la métamorphose des muscides, *Calliphora erythrocephala* Mg. *Arch. de Zool. Exp. et Gener.* T. 4, pp. 1-274.
- WILSON, E. B. 1900 *The cell in development and inheritance*. 2nd ed. New York.



# A POLYEMBRYONIC BLASTOCYST IN THE OPOSSUM

J. T. PATTERSON AND C. G. HARTMAN

*Contribution from the Zoological Laboratory of the University of Texas, No. 134*

ONE TEXT FIGURE AND TWO PLATES

## INTRODUCTION

While engaged in collecting material to complete the series of stages on the development of the opossum, *Didelphys virginiana*, we have recently come upon a polyembryonic blastocyst containing four embryos. The history of the female from which this specimen was taken is as follows: The female (no. 300) came from the wild, and was received at the laboratory on January 20. It was anaesthetized and the left uterus removed at 9.26 p.m. that evening. This uterus had six normal blastocysts, each measuring between 10 and 11 mm. in diameter and containing an embryo in the early somite stage. The incision was closed and the animal allowed to live until the next day, when she was killed at 12.15 p.m. In addition to the polyembryonic blastocyst, the right uterus was found to contain one dead vesicle above 7 mm. in diameter, and six normal blastocysts, each with an embryo. The average normal blastocyst from the right uterus measured about 14.9 mm. in diameter (fig. 7), while the polyembryonic specimen is not quite as large, measuring only about 12.88 mm. in diameter (fig. 4).

For several reasons this case is of especial interest. In the first place, it represents one of those rare cases in which a polyembryonic blastocyst has been discovered in a multiparous mammal. In the second place, it may have a bearing on the possibility of normal polyembryony occurring in Marsupials, as reported by Bluntsehli ('13) for the South American opossum, *Didelphys marsupiales*. Finally, as will be shown later, the

arrangement of the embryos suggests a close similarity to the paired condition that is normally found in the four embryos of the Armadillo, *Tatusia novemcincta*.

#### DESCRIPTION OF THE POLYEMBRYONIC BLASTOCYST

In the normal blastocyst of this litter the embryo has already sunk beneath the surface of the blastoderm, and owing to the well-developed cervical flexure, the anterior portion of the embryo with its membranes projects into the cavity of the blastocyst (fig. 8). In the surface view the posterior end of the embryo is dimly seen through the membranes (fig. 7). The area vasculosa covers almost the entire upper half of the blastocyst. It is limited by a sinus terminalis, which forms a distinct marginal notch at the posterior margin where the vessels lead to the embryo.

In the polyembryonic blastocyst there is also a well-formed area vasculosa, with a less distinct notch on the lower side (figs. 4, 5). There is a baying in of the sinus terminalis on the right side, suggesting a second notch, but no vessels pass from this to the embryos (fig. 6). With the exception of the united posterior ends of the two embryos lying above in the figure, the embryos have only begun to sink down into the blastoderm (fig. 5).

The four embryos are arranged approximately in the form of a square, with each embryo constituting one side (fig. 6). The area included within the square is somewhat higher than the general level of the embryos, giving to this central area the appearance of a vesicle. This is produced by the sinking of the embryos into the blastoderm. In sections the central area is seen to be structurally of the same character as the vascular area lying just outside the square.

The exact nature of the paired arrangement of the embryos can best be described by reference to the sketch shown in text figure 1. For the sake of convenience in description, the embryos are designated by the Roman numerals I-IV.

Embryos I and II are united at their posterior ends, and constitute one pair. Embryos III and IV are similarly united, and

constitute the other pair. All of the embryos have the fore-limb buds well started. The components of each pair are not equal in size, embryo I being somewhat smaller than its twin, and embryo III decidedly smaller than IV.

#### DESCRIPTION OF EACH EMBRYO

In order to be able to give a brief description of each individual embryo, it is necessary to have recourse to sections. The embryos were cut into a series of sections ( $12\ \mu$ ). The plane of

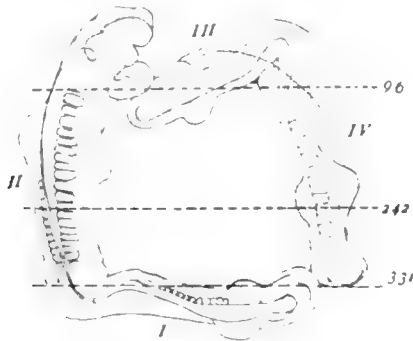


Fig. 1 Outline sketch of the four embryos. Note that they are in two pairs, embryos I and II being united at posterior ends, and likewise III and IV. The broken lines represent the planes of the three sections illustrated in figures 1 to 3. The numbers at the ends of these lines correspond to the sections in the series.  $\times 8$ .

section is approximately transverse to the long axis of embryo II (fig. 1). There are 396 sections in the series, three of which (96, 242, 331) are drawn in figures 1 to 3. Section 96 passes through heart of embryo II, oblique through embryo III, and transverse through the posterior end of embryo IV. Section 242 passes through the 12th pair of somites of embryo II, and the fore-limb buds of embryo IV. Section 331 cuts the posterior end of embryo II, and passes obliquely through embryo I.

*Embryo I.* This embryo is 4 mm. long, and has 13 to 14 pairs of somites. The neural tube is closed in the brain region, but is represented by a flat plate posteriorly. The heart is

present but highly abnormal. The anterior half of the notochord is formed, and the Wolffian ducts are well developed.

*Embryo II.* This embryo is practically normal, and bilaterally symmetrical. It is 5 mm. long, and has 20 pairs of somites. The neural folds, anterior to the level of the first pair of somites, is open, but a typical neural tube extends from this point back to the 13th pair of somites. Posterior to this a characteristic open myelon extends to the end of the embryo. It has a well-developed heart, notochord, auditory vesicles, and Wolffian ducts.

*Embryo III.* This embryo is 3.25 mm. long and has 6 pairs of somites. The embryo is so highly abnormal that it is difficult to make out all the details of structure in oblique sections. However, the central nervous system is represented by a flat plate throughout the entire length of the embryo, except at extreme anterior end, where the folds are slightly elevated. The heart is very rudimentary, but the Wolffian ducts are present. No notochord nor auditory vesicles could be distinguished in the sections.

*Embryo IV.* This embryo is 4.5 mm. long, and has 15 pairs of poorly developed somites. The neural folds are open at the anterior end, but closed at the level of the midbrain region. Posterior to this there is a flat neural plate, with a slight indication of folding in the region of the limb buds (fig. 2, IV). A notochord is present for a short distance in the region of the heart. The Wolffian ducts and auditory vesicles are both present.

#### DISCUSSION

At least three of the embryos are abnormal and would not have formed normal individuals. So far as one can tell from a study of the fourth embryo (II), it is normal, and probably would have completed its development. Regardless of whether or not any of the embryos would have reached full term, the case is none the less interesting, because it shows that the blastocyst of the opossum can produce more than a single embryo. There is no good reason to doubt that the blastocyst of this species may sometimes produce a normal polyembryonic group of indi-

viduals. But should such a group come to full term, the individuals could not be distinguished from those in the litter arising singly from the other blastocysts. This fact probably accounts for the extreme rareness of observed cases of polyembryony among multiparous mammals, in contrast to the numerous cases on record for uniparous mammals.

In reference to the bearing of this case on the probability of polyembryony occurring in the South American species, we may call attention to the brief report of Bluntschli's '13 demonstration at the 27th meeting of the Anatomische Gesellschaft, held at Greifswald. This investigator demonstrated several embryos and young from the pouch, as well as one opened uterus. It is stated that the latter contained four embryos, each in its own amnion, but all lying within a single chorionic cavity. The condition in this uterus was corroborated by analogous preparations of younger stages. Bluntschli considers the occurrence of polyembryony in *Didelphys marsupiales* as probable, not only because of the conditions of the young in the uterus, but also because he had always encountered the young from the pouch of the same sex. In the light of these facts it may be that the rare occurrence of multiple-embryo formation in *D. virginiana* has become a permanent phenomenon in the development of *D. marsupiales*.

As to the manner in which multiple embryos are formed in the blastocyst of the opossum, we cannot, from the study of a single, comparatively advanced stage, offer any definite explanation. It is, however, a significant fact that there are four embryos, and that the arrangement of these on the blastoderm suggests a certain similarity to the condition in the armadillo. As in the armadillo, the four embryos of the opossum are clearly in two pairs. Furthermore, one of the two embryos in each pair is larger than its twin, exactly as has been described for an early stage of the armadillo (Patterson, '13).

## LITERATURE CITED

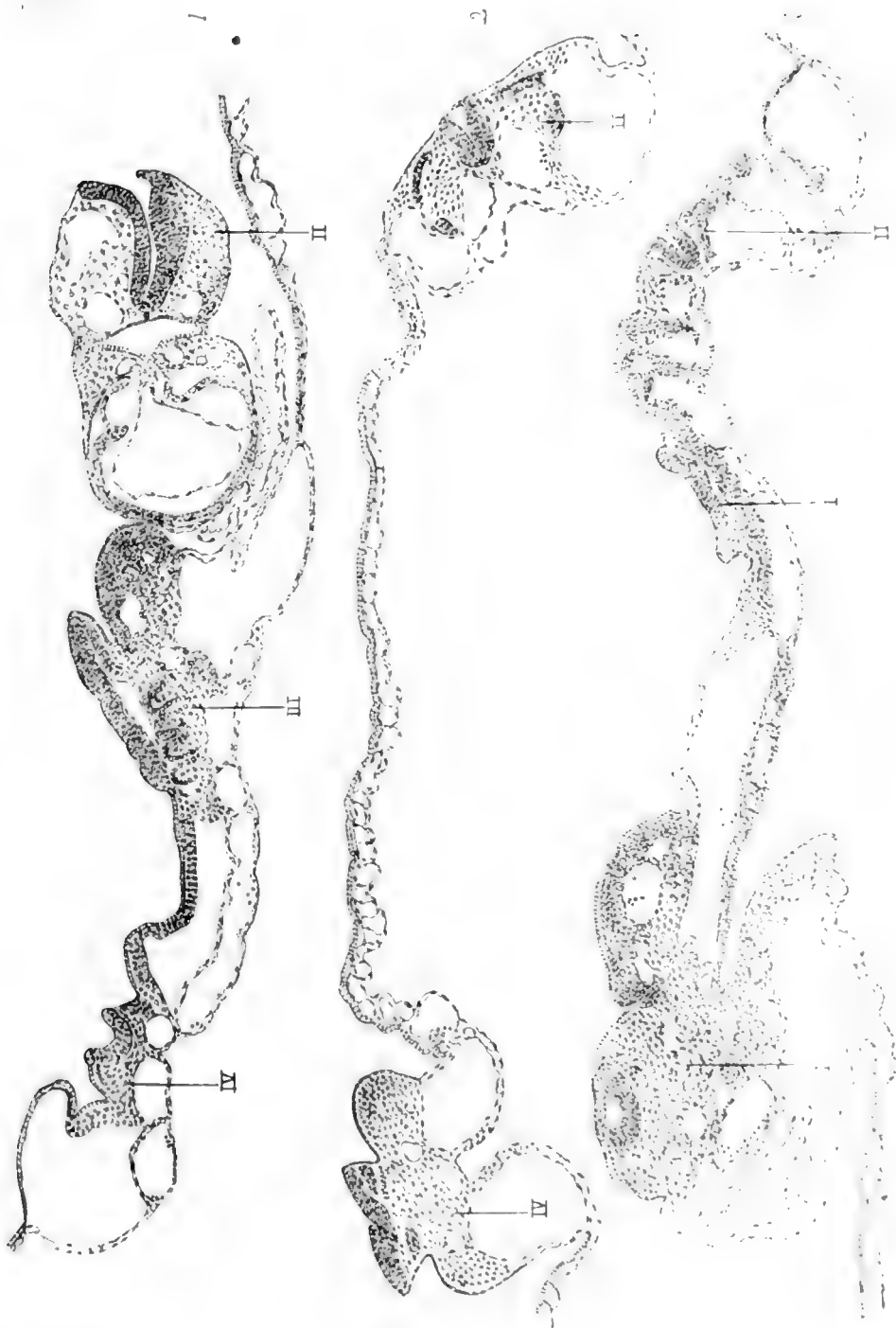
- BLUNTSCHLI, H. 1913 Demonstration of embryos of *Didelphys marsupiales*.  
Proc. of the Anatomischen Gesellschaft, 27th meeting, Greifswald,  
May 10-13, 1913. Supplement, Anat. Anz., vol. 44, p. 200.
- HARTMAN, C. G. 1916 Studies on the development of the opossum *Didelphys virginiana*. Jour. Morph., vol. 27, p. 1-83.
- PATERSON, J. T. 1913 Polyembryonic development in *Tatusia novemcincta*.  
Jour. Morph., vol. 24, p. 559-683.

## PLATE I

### EXPLANATION OF FIGURES

1 to 3 Sections 96, 242, 331, respectively, of the series. The Roman numerals indicate sections through the four embryos.  $\times 37$ .

J. T. PATTERSON AND C. G. HAIRMAN



## PLATE 2

### EXPLANATION OF FIGURES

4 Dorsal view of the entire polyembryonic blastocyst, showing the four embryos arranged in the form of a square.  $\times 2.95$ .

5 The area vasculosa with embryos.  $\times 4$ .

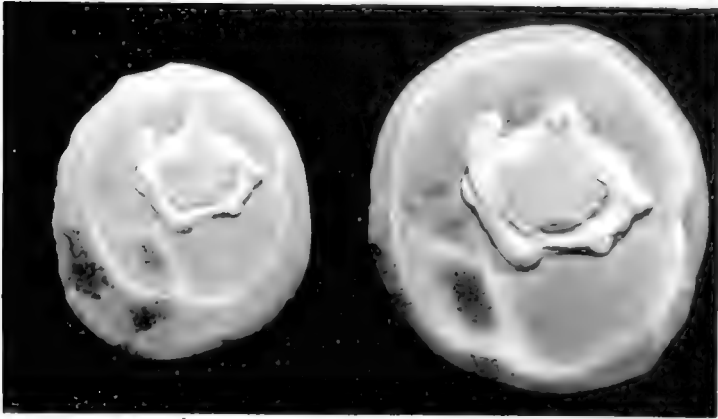
6 The same, after staining and clearing, photographed by transmitted light.  $\times 6.5$ .

7 Dorsal view of a monembryonic blastocyst from the same litter. The back of the embryo, lying in the center of the area vasculosa, is dimly seen through the membranes.  $\times 2.95$ .

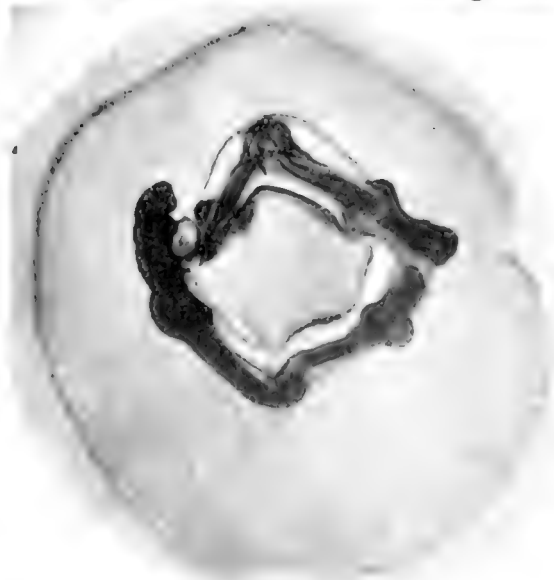8 View of the inside of the same blastocyst, from which the lower wall has been cut away. It clearly shows the embryo projecting into the cavity of the blastocyst.  $\times 2.95$ .

4, 5, 7 and 8 are each one-half of stereoscopic photographs. For all of these photographs we are indebted to our friend Dr. Chester Heuser of the Wistar Institute.

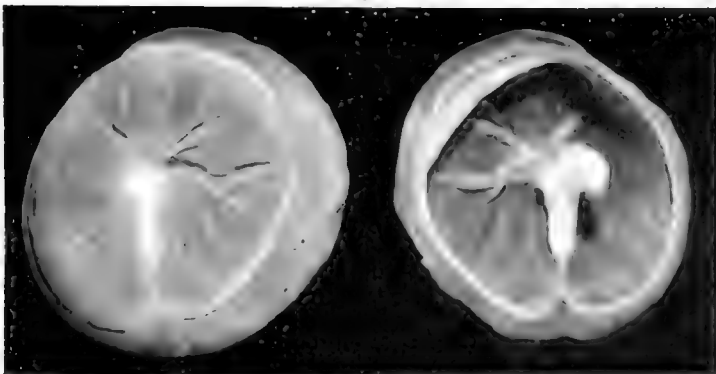




5



6



7

8

6



# SOME OBSERVATIONS ON THE ORIGIN OF MELANIN PIGMENT IN FEATHER GERMS FROM THE PLYM- OUTH ROCK AND BROWN LEGHORN FOWLS

R. M. STRONG

*From the Anatomical Laboratories of Vanderbilt University Medical School*

SIX FIGURES

## I. INTRODUCTION

This paper is a consequence of work done under my direction by Katherine Knowlton, a candidate for a Master's degree at the University of Chicago during the year 1912-1913. She was assigned comparative research on the pigmentation phenomena of feather germs from the Plymouth Rock and Brown Leghorn fowls. In the course of this work some new facts concerning the origin of pigment in feather germs were discovered. A preliminary statement concerning these results has been made (Strong, '15).

I have recently restudied Mrs. Knowlton's material, and I have prepared the illustrations which accompany this paper, as well as the manuscript.

The development of melanin pigment in feathers has been described in detail in a preceding paper (Strong, '02). Others who have written on the subject are mentioned in that publication. Since then, an important paper by Lloyd-Jones ('15) has appeared. This discusses incidentally the origin of melanin pigment in various varieties of domestic pigeons.

As stated in previous publications, the feather is purely epidermal in origin. It is differentiated from tissues which make up a cylinder surrounding a central core of dense and very vascular mesenchyma, the dermal pulp (figs. 1 to 6). The mesenchyma is separated from the epidermal cylinder by a basement membrane (figs. 1, 2, 5 and 6) which is well defined except

at the proximal end of the feather germ. The epidermal tissue includes an external sheath and a layer of stratified squamous epithelium under the sheath, the inner sheath cells, neither of which become parts of the feather structure. Between the dermal pulp and the inner sheath cells lies a broad zone of cells the intermediate cell region, (fig. 1). This zone is divided by radial extensions of the basement membrane (figs. 2 and 6) into sections called barb-vane ridges by Jones ('07), except at the proximal end of the feather germ. Each barb-vane ridge consists of so-called cylinder and intermediate cells. The cylinder

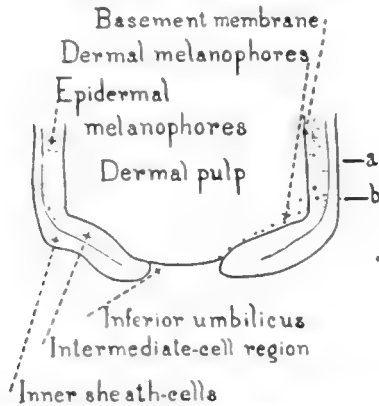


Fig. 1. Partly diagrammatic longitudinal section of proximal end of feather germ.  $\times 30$ . Melanophores are indicated by dots. Drawn with aid of camera lucida.

cells make up a layer, one cell deep (figs. 2, 4; and 6) which lies next to the basement membrane and its radial extensions. This layer has the form of a deep and narrow gutter or a letter U in cross section. The base of the U or gutter lies next to the dermal pulp except for the intervening basement membrane, and the other end is next to the inner sheath cells. The space inside the limbs of the U is filled by intermediate cells (figs. 2, 4, and 6). All of the feather structure except the loose pith in the quill is developed from these intermediate cells. Some of the intermediate cells are differentiated into melanophores which supply melanin granules to the differentiating feather cells.

For details concerning these remarkable pigmentation processes, the reader is referred to a previous paper (Strong, '02). There the histogenesis of the feather also is described in detail except in the case of the shaft and quill whose development was worked out by Davies ('89).

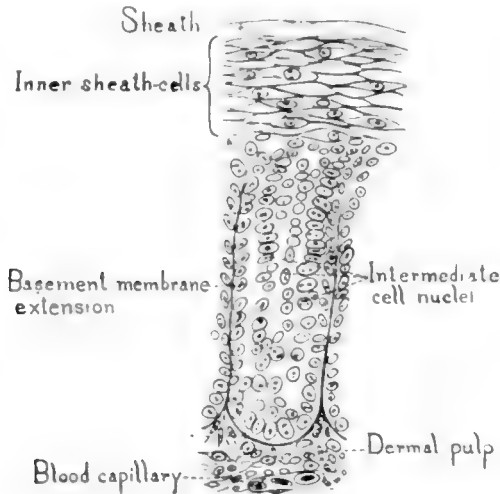


Fig. 2 Small portion of transverse section of feather germ showing an oblique section of a barb-vane ridge and cylinder cell nuclei of adjacent barb vane ridges.  $\times 500$ . Back covert of Plymouth Rock fowl. Level of section indicated by the line *a* in figure 1. This view was selected from a non-pigmented region. Drawn with aid of camera lucida.

## II. MATERIAL AND METHODS

The material used consisted of feather germs pulled from their follicles and placed in the fixing fluid immediately. The regions of the integument which supplied the feather germs were the back, breast, neck and wings. The scapulars also were used. Two Plymouth-Rock males, two Plymouth-Rock females, one Brown-Leghorn male, and one Brown-Leghorn female furnished the material. A majority of the feather germs came from the females as the males did not molt so extensively during the periods when the material was obtained.

The feather germs were mostly 1 to 2 cm. in length. In most cases they had just begun to expose the barbs at the distal end of the sheath. A few feathers in more advanced stages were also used.

Gilson's fixing fluid was employed largely, the material remaining in it for three hours. Otherwise the technique was that described by Strong ('02).

The sections were cut in paraffin 6 to 10 microns thick. About forty of the sections at the proximal end of the feather germs remained regularly in the paraffin ribbon when 10 microns thick. Succeeding sections were more and more apt to drop out of the ribbon as more and more cornified material was reached.

### III. RESULTS

#### *A. Origin of epidermal pigment*

1. *In intermediate cells.* All of the germs studied were of feathers which contain large amounts of melanin pigment. Consequently, melanophores crowd the intermediate cell region in the preparations from the two fowls.

No evidence was obtained that these melanophores were not of epidermal origin, and I believe that they are specialized intermediate cells as I have stated before (Strong, '02).

Above the region where the melanophores develop, the intermediate cells which enter into the feather structure have their cytoplasm characteristically packed with melanin granules. The pigmentation phenomena here are essentially like those described in previous publications.

According to Lloyd-Jones ('15) many ordinary intermediate cells may develop melanin granules autoethonously. It is of course impossible to prove that this is not a frequent occurrence and I have indicated its possibility (Strong, p. 170, '02). However, the mere fact that a cell containing melanin pigment is not sometimes in contact with a chromatophore process in a microscopic preparation, does not prove that this pigment may not have come from a melanophore before the material was fixed

unless it can be shown that no melanophores are near enough to have supplied the pigment.

The melanophore relationship is obvious at many points in a microscopic field. The evidence in my judgment points towards the origin of the melanin pigment in intermediate cells from epidermal melanophores as the rule. This position is not inconsistent with the observations made by Lloyd-Jones.

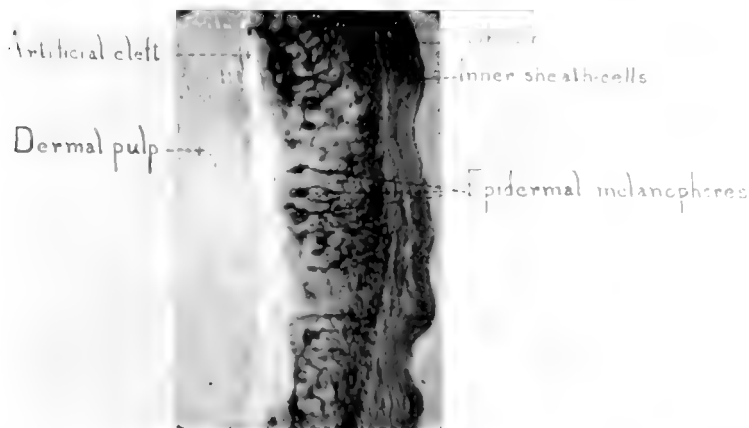


Fig. 3 Photomicrograph showing a portion (4 mm. long) of a longitudinal section of feather germ from near its proximal end.  $\times 150$ . Back covert, Plymouth Rock fowl. The region photographed was selected because it had fewer melanophores than usual, with consequent better outlines of individual melanophores. Numerous melanophores whose branching processes connect with differentiating feather barbule cells may be seen. The lower end of the view corresponds with the line *a* in figure 1, and the area extends somewhat above the region indicated in figure 1.

Ocular 10; obj. 4 mm. Bausch and Lomb; picture reduced in publication.

2. *In cylinder cells.* A small number of cylinder cells were found containing clearly defined melanin granules in their cytoplasm. These cells occurred at the level in the feather germ where the melanophores were beginning to send out processes. A few of these cells were at the deeper end of the barb-vane ridges next to the pulp except for the intervening basement membrane. Other cylinder cells containing melanin granules were at the sides of the barb-vane ridge, some distance from the

pulp. The melanin granules were always found on the outer side of the nucleus, i.e., the side away from the dermal pulp. The granules occurred in small dense groups. It was not possible to determine their origin but we believe that they were formed *in situ* and did not come from melanophores.

3. *In inner sheath cells*—Melanin granules occurred in some of the inner sheath cells of seven out of sixteen series of feather

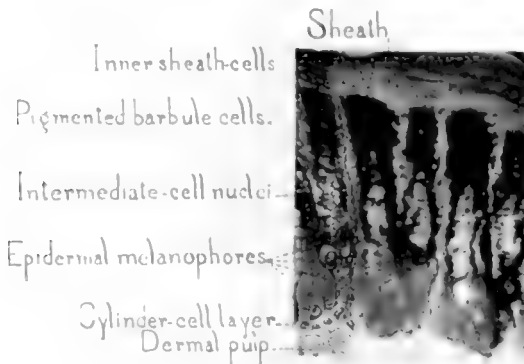


Fig. 4 Photomicrograph of small portion of transverse section of feather germ. Neck covert, Brown leghorn fowl.  $\times 300$ . Level of line *a* in figure 1. Epidermal melanophores may be seen in their usual abundance, more or less monopolizing the intermediate cell region. Intermediate cells differentiating into feather barbules are shown with their cytoplasm packed with melanin granules received from melanophores. At the left, histological details have been added with a pen, a camera lucida being employed. Oc. 10; obj. 1.9 mm. oil immersion (Bausch & Lomb). The picture was much reduced in publication. One barb-vane ridge appears completely, another at the left is almost all in the picture, and a large portion of a third at the right is included.

germ sections, according to Mrs. Knowlton. In all cases the pigmented inner sheath cells were found within the first millimeter from the inferior umbilicus, i.e., at the proximal end of the feather germ, but not in every section of this region. This pigmentation was irregular and sparse. The granules were of the same size, form, and color as those of the intermediate and cylinder cells.

The melanin granules were found usually on the outer or peripheral side of the nucleus, as in the case of pigmented cylinder



cells. As there were no melanophores near enough to have distributed melanin granules to these cells, we concluded that they also must have a capacity for forming melanin granules. Such cells never accumulate many granules, and they always retain their normal character as stratified squamous epithelium.

### *B. Origin of dermal pulp pigment*

Melanophores were found at the proximal end of the dermal pulp near the inferior umbilicus of feather germs from both the Plymouth Rock and Brown Leghorn fowls (figs. 1, 3, and 4). Dermal pulp pigment was not found in the feather germs of over ten species of birds previously studied by me, and I know of no other observations of it. Rabl ('94) found no melanin pigment in the dermal pulp of nestling-down feather germs from the chick.

The dermal melanophores we observed occurred in the mesenchyma not far from the basement membrane, as may be seen in figures 1, 5 and 6. Usually a good many were grouped near the shaft-forming epidermis. That these bodies are melanophores is indicated by the following observations. 1) They are similar in shape and size to some epidermal melanophores. 2) The nucleus is often clearly seen, proving that they are cells, which would not be the case if they were artifacts. 3) These bodies are made up of granules of the same size, shape and color as the epidermal melanin granules. 4) The arrangement of the granules is characteristic of a melanophore. The granules surround the nucleus, where they are packed densely. Naturally, some artifacts and foreign bodies resembling melanophores superficially, have been found in the sections, but they have always been distinguished without serious difficulty. A question naturally arises as to whether these pulp melanophores may not have been dragged in from the epidermal cylinder in cutting sections. Against such an interpretation we have several arguments. 1) There are too many of the melanophores to warrant concluding that their positions are accidental. 2) There is no evidence of distortion or tearing of the surrounding tissue such as

would be expected if they had been moved there by the microtome knife or by any other artificial cause. 3) These melanophores fit in too naturally in the surrounding tissue. 4) They are arranged with considerable uniformity around the periphery of the pulp near the basement membrane. If their position had

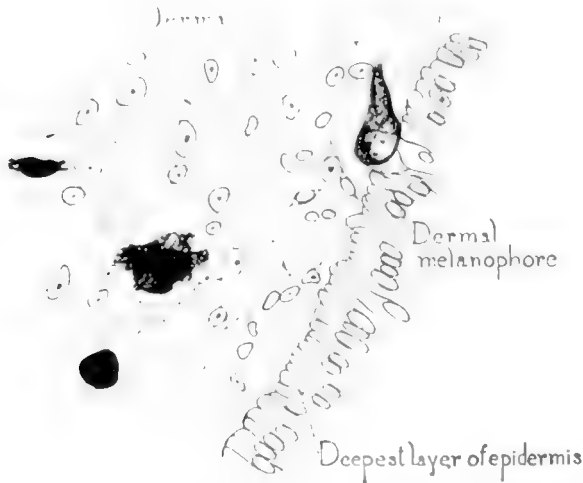


Fig. 5 Small portion of transverse section of feather germ near its proximal end. Breast covert of Plymouth Rock fowl.  $\times 700$ . Level indicated by line *b* in figure 1. The deepest portion of the epidermal cylinder next to the basement membrane is shown at the right. The elongated nuclei are separated by radiations which simulate cell boundaries. The basement membrane is poorly defined at this level. At the left the mesenchymal pulp is drawn partly diagrammatically, and its dense character is not indicated. Four dermal melanophores appear.

been the consequence of cutting, it would be expected that all of them would be on one side of the pulp.

We obtained no evidence as to what particular cells form these dermal pulp melanophores. The developmental stages resemble those of the epidermal melanophores, but the pulp melanophores do not become so large as the latter, and they do not form processes so profusely. In fact, the majority of the pulp melanophores apparently do not form processes at all. Some have small inconspicuous processes, and a few have larger processes. The largest melanophores observed had no processes.

It is characteristic of the pulp melanophores observed that such processes as occur are directed towards the epidermis either radially or in the line of a secant. These processes, as previously stated, are usually short, thick, and closely packed with melanin granules that never seem to be distributed to other cells. The following table gives observations made by Mrs. Knowlton.

	SECTIONS		
	Pulp melanophores with no processes	With radially directed processes	With processes at right angles to radius
	<i>per cent</i>	<i>per cent</i>	<i>per cent</i>
150 transverse.....	65	16	19
60 Longitudinal.....	67	13	20

The melanophores with longer processes lie near the basement membrane, and they are not frequent (figs. 2 and 3). Mrs. Knowlton found them in three feather germs. Lying so near to the epidermis, it is important to know whether they penetrate the basement membrane or not. We have been unable to find any such penetration, even when the melanophore or its process was against the basement membrane or apparently in its barb-vane extensions. These melanophores are located either near the apex of a barb-vane ridge or between two barb-vane ridges as just noted. In the former case the process follows the basement membrane until it reaches a barb-vane extension of the latter, where it runs up between the two adjacent barb-vane ridges apparently splitting the basement membrane partition. In the other type (fig. 6), the body of the melanophore lies at the deeper end of the basement membrane partition, and its process runs straight out, i.e., radially, between the adjacent barb-vane ridges. No such process was found extending more than three-fourths the radial extent of the adjacent ridges.

We are unable to explain the location and behavior of these melanophores. They are so rare that we have considered them more or less abnormal. In the region where they occur, various features indicate activity in a radial direction. Here and more

proximally, the cells of the syncytial epithelium are undergoing considerable changes in position. Proximally, pale refraction lines simulating incomplete cell boundaries lie radially between the nuclei, which are narrow and arranged radially. In figure 5 such lines have been drawn for the deepest nuclei at the right. They have not been observed to form complete cell boundaries

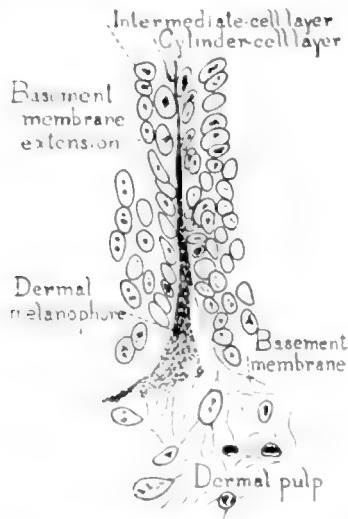


Fig. 6 Small portion of transverse section from feather germ of Plymouth Rock fowl. Near level *a* in figure 1.  $\times 700$ . Drawn with aid of camera lucida and reduced in publication. Oc. 10; obj. 1.9 mm. oil immersion, (Bausch and Lomb). A basement membrane extension separating two barb-vane ridges is shown with a dermal melanophore process lying in its inner two thirds. The cell body of the melanophore is only partly in this section. Adjacent layers of cylinder cells and intermediate cells are indicated by their nuclei.

often if ever, and they disappear at the level where the radially directed basement membrane extensions develop. The frequent occurrence of melanin pigment only on the outer side of nuclei, mentioned in this paper, is very likely another illustration of radially acting forces. It is conceivable that melanophore processes are carried radially by such forces or by the developing barb-vane extensions of the basement membrane.

In longitudinal sections some light appears to be thrown on the significance of the dermal pulp melanophores in general. In a few sections, I have found an essentially continuous series of these bodies extending to the inferior umbilicus as seen in figure 1. It is my opinion that these melanophores are homologous with those of the skin dermis. The dermal pulp being continuous with the skin dermis, such a continuance into the proximal end of the feather germ is not surprising.

### *C. Observations on the melanin granules*

So far as I could determine, all of the granules were rod shaped as is usual in birds. Even when evidently fully developed, there appears to be considerable variation in size. The longest are slightly over 1 micron in length. Others may not be more than 0.5 micron long. They are about two to four times their thickness in length. It is not easy to make exact measurements of such bodies because of their minute size and their arrangement at all possible angles with reference to the plane of the section. In the Plymouth Rock and in some Brown Leghorn feather germs, the granules were of the usual brown, almost black color.

### SUMMARY

1. Melanin pigment granules occur occasionally in the so-called cylinder and inner-sheath cells of feather germs from the common fowl.

2. Further evidence was obtained that the melanin pigment of feathers is epidermal in origin.

3. Melanophores were found in the dermal pulp at the proximal end of feather germs from the common fowl. They are presumably homologous with the dermal melanophores of the skin. Some of these pulp melanophores have processes which are usually relatively short, but they do not appear to distribute pigment to other cells, and they have no part in the histogenesis of the feather or its pigment. A few of these dermal melanophores were found in contact with the basement membrane but none had penetrated it.

## LITERATURE CITED

- DAVIES, H. R. 1889 Die Entwicklung der Feder und ihre Beziehungen zu andern Integumentgebilden. *Morp. Jahrb.*, Bd. 15, pp. 560-645.
- JONES, L. The development of nestling feathers. *Laboratory Bull.*, no. 13, Oberlin College, 18 pp.
- LLOYD-JONES, O. 1915 Studies on inheritance in pigeons. II. A microscopical and chemical study of the feather pigments. *Jour. Exp. Zool.*, vol. 18, no. 3, April, pp. 453-495.
- RABL, H. 1894 Ueber die Entwicklung des Pigmentes in der Dunenfeder des Hühnchens. *Centrabl. f. Physiol.*, Bd. 8, p. 256.
- STRONG, R. M. 1902 The development of color in the definitive feather. *Bull. Mus. Comp. Zool., Harvard*, vol. 40, no. 3. October, pp. 145-185.
- 1915 Further observations of the origin of melanin pigments. *Anat. Rec.*, vol. 9, no. 1, January, Abstract 52.

## MATURATION OF THE OVUM IN SWINE

GEORGE W. CORNER

*From the Anatomical Laboratory, University of California*

Since the first description of maturation of the ovum of the rabbit by Van Beneden in 1875, the study of this remarkable phenomenon has been extended to certain other mammals, with the result that practically all observers now agree that two polar bodies are formed by every ovum, the first of which is extruded from the egg while still in the ovary, but immediately before rupture of the follicle. Formation of the second polar body then proceeds to the formation of a division-spindle, but goes no farther until the egg is discharged and fertilized. After the entrance of the spermatozoon the second polar body is completed and extruded. In the event that fertilization does not occur, the ovum degenerates in the state in which it was freed from the ovary.

Full and comprehensive observations of the process of maturation have been made in the rat (Sobotta and Burekhard '10), guinea-pig (Rubaschkin '05), opossum (Hartman '16), a bat, *Vesperugo noctula* (Van der Stricht '08), the domestic cat (Longley '11), and the mouse. The studies of Sobotta ('95) and others, lead them to believe that in the last named species many eggs form but one polar body. The interest excited by this statement has caused the mouse to be more fully investigated than any other, with the result that the views quoted have been proven incorrect. The reader is referred to the work of Long and Mark ('11) for details of the question together with the most comprehensive account of maturation yet presented in any mammal.

The final disproof of this supposed exceptional case raises the question as to whether the process may not be identical in all mammals. To answer this a wider search will be necessary, for

the species named above comprise but three rodents, one marsupial, one carnivore, and one chiropter. There are also old or undetailed accounts or preliminary notes upon the ova of the dog (O. van der Stricht '08), the rabbit (Van Beneden '75, Heape '05), the marsupial *Dasyurus viverrinus* or Australian "native cat" (Hill '10), an insectivore, *Tupaia javanica* (Hubrecht '95), and of a lemuroid ape, *Tarsius spectrum* (Hubrecht '02), and thus of the twelve orders of mammals there are four in which the process of maturation is well known in one species or more, two in which it is very obscure, and six in which ripening ova have never been seen.

Among the last are the ungulates, in which the species are either rare and inaccessible, or if common, are so large that the search for the ova is very difficult. For these reasons it will be of interest to describe a small series consisting of 15 ova from 7 sows (*sus scropha domesticus*). I am indebted to Mr. Ralston B. Brown, Superintendent of the Oakland Meat and Packing Company of Oakland, California, for the opportunity to collect the material, and to Mr. A. E. Amsbaugh and Mr. Felix H. Hurni for assistance in its preparation. The sows were selected and the tubal ova found by the method given in a previous paper (Corner and Amsbaugh '17). Ovarian ova were studied in serial sections of the follicles (celloidin) or by cutting hardened follicles into slices, locating the discus proligerus and sectioning it in paraffin.

1. Killed during oestrus, probably on the first day. Unruptured follicles. Three ovarian ova sectioned, two show germinative vesicles, the other shows the first polar body and the second polar spindle.

2. First or second day of oestrus. One follicle ruptured, its ovum not found in the tubes. An ovarian ovum shows the first polar body and the second spindle.

3. Second or third day of oestrus. All follicles ruptured. Four unfertilized tubal ova sectioned; all show the first polar body and the second spindle.

4. History unknown. Five unfertilized tubal ova found, of which four (studied fresh) show one polar body extruded.



5. Probably second day of oestrus. Copulation observed 24 hours before killing. One tubal ovum found, covered with spermatozoa. In sections, the male and female pronuclei are in contact. Two polar bodies.

6. Second or third day of oestrus. Copulation observed 16 hours before killing. Two ova found in the tubes; both were covered by spermatozoa. One of them, studied fresh, showed two polar bodies. The other was sectioned, and showed the pronuclei in contact, but unfortunately the polar bodies were obscured by damage to the sections.

7. Tubes contained segmenting ova of 2, 4, and 6 blastomeres. One of the two-celled embryos (studied fresh) showed two polar bodies; a favorable view of the others could not be obtained.

#### CONCLUSIONS

The first ova of an ungulate mammal to be studied indicate that the sequence of maturation is the same in swine as in previously studied forms of other orders, the first polar body being extruded and the second polar division proceeding as far as spindle formation before fertilization, the second polar body being cut off only after the entrance of the spermatozoon.

#### LITERATURE CITED

- VAN BENEDEN, E. 1875 La maturation de l'oeuf, la fecondation, (etc.) chez le Lapin. Bull. de l'Acad. Royale de Belgique, T. 40, no. 12, p. 686.
- CORNER, G. W. AND AMSBAUGH, A. E. 1917 Oestrus and ovulation in swine. Anat. Rec., vol. 12, p. 287.
- HARTMAN, C. G. 1916 Studies in the development of the opossum, *Didelphys virginiana* L. Jour. Morph., vol. 27, p. 1.
- HEAPE, W. 1905 Ovulation and degeneration of ova in the rabbit. Proc. Royal Society, London, vol. 76, B, p. 260.
- HILL, J. P. 1910 The early development of the marsupialia with especial reference to the native cat (*Dasyurus viverrinus*). Quart. Jour. Micros. Sci., vol. 56, p. 1.
- HUBRECHT, A. A. W. 1895 Die Phylogenese des Amniotes und die Bedeutung des Trophoblasts. Verhandlungen der Kon. Akad. van Wetenschappen. te Amsterdam. Tweede Sectie, Deel. 4, No. 5.  
1902 Furchung und Keimblattbildung bei *Tarsius spectrum*. Ibid., Deel 8, No. 6.

- LONG, J. A. AND MARK, E. L. 1911 The maturation of the egg of the mouse. Publication No. 142 of the Carnegie Institution of Washington.
- LONGLEY, W. H. 1911 The maturation of the egg and ovulation in the domestic cat. *Am. Jour. Anat.*, vol. 12, p. 139.
- RUBASCHKIN, W. 1905 Ueber die Reifungs—und Befruchtungsprozesse des Meerschweincheneies. *Anat. Hefte*, Bd. 29, S. 507.
- SOBOTTA, J. 1895 Die Befruchtung und Furchung des Eies der Maus. *Arch. f. Mikr. Anat.*, Bd. 45, S. 15.
- SOBOTTA, J. AND BURCKARD, G. L. 1910 Reifung und Befruchtung des Eies der Weissen Ratte. *Anat. Hefte.*, Bd. 42, S. 433.
- VAN DER STRICHT, O. 1908 La structure de l'oeuf chez la chienne. *C. R. de l'Assoc. des Anatomists, Dixieme Reunion, Marseille.*
- 1910 La structure de l'oeuf des mammiferes, (Chauve-souris, *Vesperugo noctula*), Troisieme partie. *Memoire presente a la classe des Sciences, Academie Royale de Belgique, 2<sup>me</sup> Serie, Tome 2.*

# HYPERPHALANGISM ACCOMPANIED BY SUPERNUMERARY EYPIPHYSES AND MUSCULAR DEFICIENCIES

LLOYD R. REYNOLDS

*From the Division of Anatomy of the Stanford Medical School*

TWELVE FIGURES

This interesting developmental anomaly, was observed in the practise of Dr. Robert G. Reynolds of Palo Alto in March of 1916. The x-ray photographs accompanying this article were kindly taken by Dr. Reynolds, through whose courtesy I am enabled to report the case. As it usually happens in these instances the family history reveals related abnormalities. On the father's side of the family there have been several cases of abnormal development of the skeleton of the upper extremities. The paternal grandfather is said to have had syndactyly of the index finger and the thumb of the right hand, up to the interphalangeal joint of the thumb. The terminal phalanx of the thumb is said to have been flexed at right angles on the proximal phalanx so as to lie in the palm. The left hand and both feet were said to have been normal.

The father's oldest sister who died at the age of six is said to have had a deformity of the right hand similar to that of her father. Otherwise she was normal.

The father's second sister who died soon after birth is said to have had congenital absence of radius and ulna on the right arm and the father's older brother is said to have had similar deformities as the present case.

The father's hands both show muscular defects. On the left hand the thenar eminence is absent, and the opponens and abductor pollicis brevis apparently are lacking. The flexor brevis may be present. There are two groups of interphalangeal

and one of metacarpophalangeal sulci, in the thumb. Yet the x-ray photograph (fig. 1) shows that there are only two phalanges. The left thumb is straight and tapering; only about two-thirds normal size and the skin is smooth, shiny and atrophic. It is 6.4 cm. long and is rotated out a little. The mobility in the

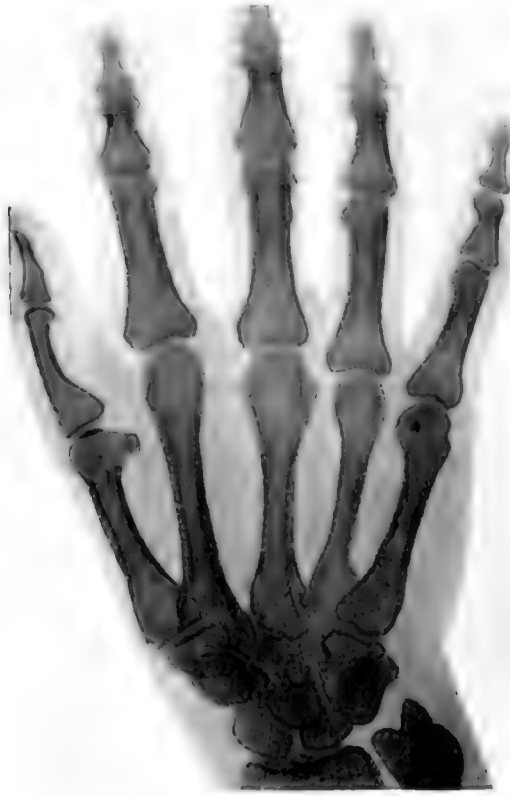

Fig. 1 Left hand of father

second terminal phalanx of the thumb is somewhat limited. The width of the left hand in the line of the metacarpophalangeal articulations is 8.6 cm. There is no webbing of the fingers; the rest of the fingers of the left hand being apparently normal.

The thumb of the right hand is somewhat longer than that of the left, but the thenar eminence is also absent; the region being

marked by a decided flattening. The right thumb is 7.4 cm. long and is rotated in rather than out, as is the case with the left. It is tapering and atrophic as in the other hand, possessing a small but apparently normal nail. The pulp of the thumb is compressed from side to side and looks atrophied. There are two prominent sulci opposite the interphalangeal joint of the thumb and the width of the hand at the metacarpalphalangeal articulations is decidedly greater than in the left hand. The other fingers are normal. The width of the right hand in the line of the metacarpalphalangeal articulations is 9.2 cm. or 0.6 cm. more than the left. The medial surfaces of both thumbs, a little distal to the metacarpophalangeal articulations are marked by an oval callosity about 2 cm. in diameter and 0.5 cm. thick which forms a prominent pad. As shown in (fig. 2) the medial surface of the thumb is concave, the distal portion being bent medially, that is toward the ulna, the distal phalanx being directed medially at an angle of about 10 degrees.

In the x-ray photographs (figs. 1 and 2) there is a pronounced mortising of the basal ends of some of the metacarpals of the thumb with the basal ends of the metacarpals of the index fingers. This condition seems to be the result of a general narrowing of the wrist bones. In each hand the greater multangular is placed medially until its medial border is almost even with the medial border of the lesser multangular. Hence the position of these bones and the consequent position of the respective metacarpals may possibly account to some extent for the lack of mobility of the metacarpals of the thumbs. The proximal phalanx in each thumb is markedly concave on its palmar surface and has a slightly bent shaft. This is more noticeable in figure 2. These peculiarities in the thumb may be explained in part by the fact that the lack of mobility of the metacarpals has made it necessary to rotate the proximal phalanx medially in order to use the thumb in conjunction with the other fingers. As a result of this rotation we see the phalanges from a lateral view rather than a dorsal and therefore the concave surface is the ventral and not the medial surface of the phalanx. There doesn't seem to be anything to account for the three distinct

bony tubercles shown in outline in the x-ray plate on the ventral surface of the distal phalanx of each thumb (figs. 1 and 2).

The distal ends of the phalanges seem large and irregular. This is more noticeable in the right (fig. 2) than in the left

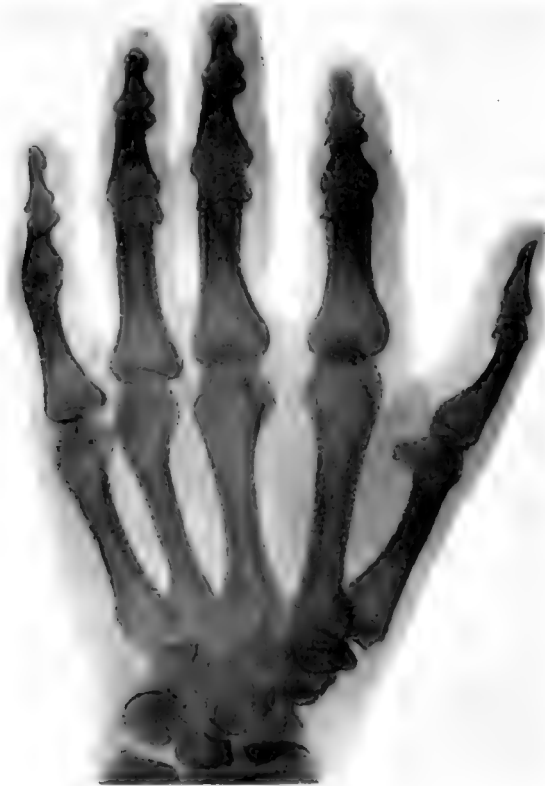
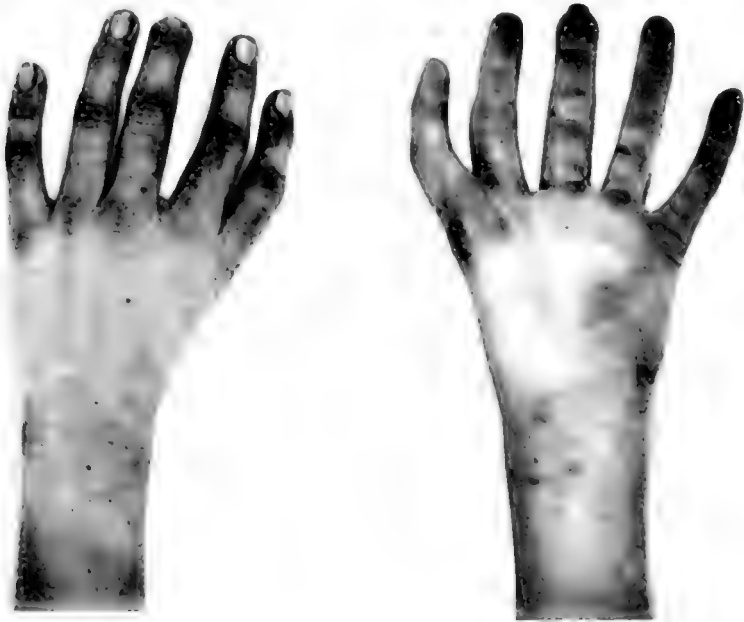
Fig. 2 Right hand of father

(fig. 1) hand, but this may be due to the fact that in figure 2 the hand was not held as flatly on the plate as in figure 1.

The son, the subject of this report is 13 years of age, 5 feet, 8½ inches in height and weighs 130 pounds. The photographs (figs. 3 and 4) show the marked deformity in the general appearance of the left hand and figs. 5 and 6 the lesser deformity in the right. The II-V fingers are developmentally quite

normal for the middle finger of the left hand was injured in a recent accident. There is no webbing of the fingers and with the exception of the second and fourth fingers the sulci are normal. On the palmar surface of the fourth finger there are two sulci about 1 cm. apart opposite the first interphalangeal joint. The index finger has a similar peculiarity. The thumb has the appearance of the little finger of either hand. It would indeed be im-

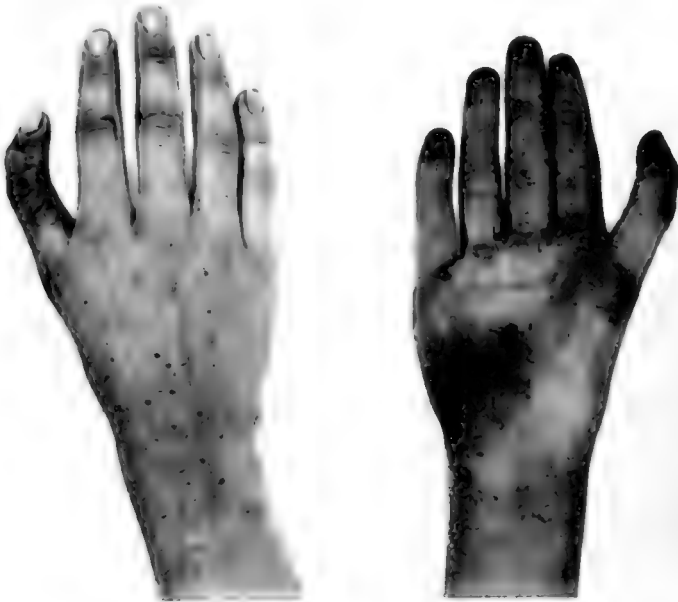

Figs. 3 and 4 Left hand of son

possible to identify it by means of a photograph of these digits alone, in the case of the left hand. The terminal phalanx and nail of the thumb are shaped exactly like the terminal phalanx and the nail of the little finger.

On the right hand the nail of the thumb, although smaller, is shaped more nearly like the normal thumb nail, and the terminal phalanx is also shorter and heavier than the terminal phalanx of the little finger. In each instance the thumb is 0.7

cm. longer than the little finger and markedly concave medially. The space between the index and middle fingers of the left hand is greater than normal and the index finger is concave medially. This is probably due mostly to the fact that the boy usually grasps objects between the index and middle fingers, rather than between the thumb and index fingers, because of the abnormal development and relation of the thumb. The thumb



Figs. 5 and 6 Right hand of son

of the right hand is also concave medially and small objects, such as a coin, when grasped by the right hand are placed between the dorsal surface of the terminal phalanx of the thumb and the tips of the fingers

The thenar eminences are absent with apparently an absence of all the thenar muscles (figs. 4 and 6). Even the adductors appear to be absent and these facts no doubt account for the peculiarity in mobility. There is a lack of mobility of the metacarpals of the thumbs which is very noticeable because it limits



the motion of the thumbs to the movements possible in the other fingers.

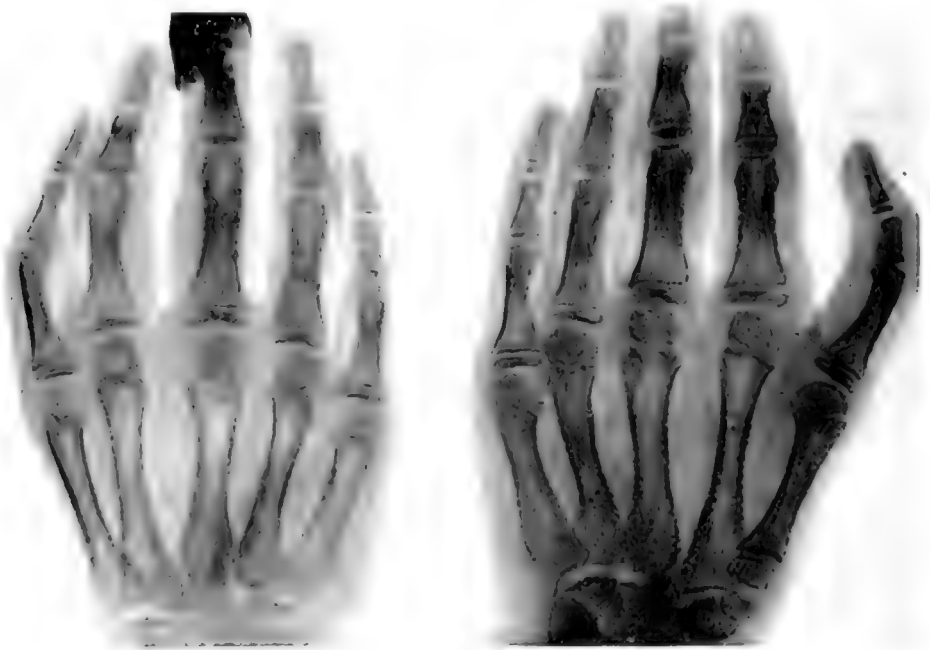The position of the thumb in relation to the other fingers gives the forearm the appearance of being much longer than normal even though measurements show it not to be exceptionally long for a boy of his height. The hand is markedly widened at the metacarpophalangeal articulations. The left hand is 9 cm. wide. The width of the four fingers being 8 cm. The right hand is 9.3 cm. wide and the width of the four fingers 8.4 cm. A similar difference was present in the father's hands as stated above.

The photograph in figure 4 shows the smooth, glistening appearance of the skin in the palm of the hand. This is characteristic of both hands although a slight movement during the taking of the picture prevented its showing in figure 6. The skin seems to be drawn tightly so that very few sulci appear.

In the x-ray photographs (figs. 7 and 10) it is shown that the thumb of the left hand has three, well-formed, phalanges which in large part accounts for its length. In this case the age is such that the epiphyses show exceptionally well. There is nothing to indicate that the middle phalanx of the left thumb is rudimentary and will later fuse with the terminal phalanx. Indeed the middle is longer than the terminal phalanx and has a well-formed, normally-located epiphysis (fig. 7). Each of the other phalanges has also a well-formed epiphysis and seems entirely separate from the middle phalanx. The metacarpal of the thumb on this, the left hand, also is of interest for its form and length seem more nearly like a true metacarpal than the corresponding bone in a normal hand. Besides, the epiphysis is at the distal instead of the proximal end of the bone, the same as the epiphyses on the metacarpals of the other fingers (figs. 7 and 10). The metacarpal of the thumb is relatively long. The x-ray photographs were taken with the hands lying directly on the plate and with the machine over the same part of each hand. Measuring the negative we find that the metacarpal of the thumb is 6.7 cm. long while the metacarpal of the little finger is only 6 cm. long. The circumference of the first meta-

carpal also seems less than the circumference of the corresponding bone of the little finger. Normally the metacarpal of the thumb is shorter and thicker than any of the other metacarpals.

The x-ray photograph of the right hand is in some respects more interesting than that of the left. The extra phalanx of this thumb is not so well formed as that on the other thumb or



Figs. 7 and 8. Left and right hands of son

those of the other corresponding phalanges but nevertheless as shown in figure 9 it is a separate bone with a distinct diaphysis and epiphysis, articular surfaces and base and head. Besides showing the same peculiarities in regard to the extra phalanx, the metacarpal of this thumb shows a double epiphysis (figs. 8 and 11).

In all of the cases of three-jointed thumbs reported, heretofore, the middle phalanx is considered the extra phalanx.

Pfitzner, '90 who has done more work than anyone else on the development of the extremities, has reported several cases of three-jointed thumbs, but in all of these cases the three joints were only temporary for the extra, middle phalanx later fused with the end phalanx to form one bone. In no case did Pfitzner find an extra phalanx that had a distinct epiphysis, articular surface, head, and which in general had the shape of a normally developed phalanx as in the present case.




Fig. 9 Thumb of right hand taken laterally

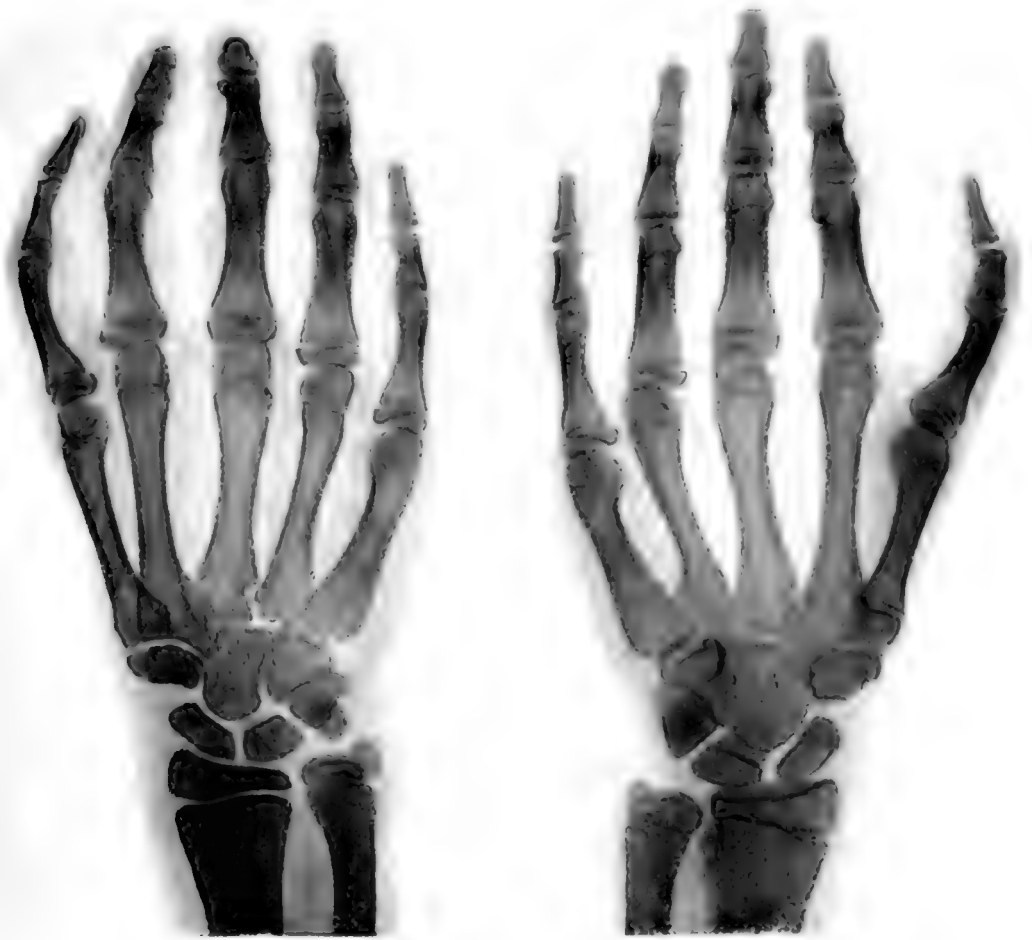Rieder '00, reported a family, most of whom had three-jointed thumbs. The father and four of the children had an extra phalanx in the thumb. Rieder claims that his cases differ from those reported by Pfitzner in that each end phalanx did have a distinct epiphysis entirely separate from the middle phalanx.

Dwight '07 in his report on the variations of the bones of the hand and foot considers the presence of an extra phalanx in the thumb. He says that in no case reported did the extra phalanx have an epiphysis in those of an age at which it could be expected to be present. He supports Pfitzner's theory that the extra phalanx is later fused with the terminal phalanx.

Salzar '98, also reported a case of a three-jointed thumb on each hand. In each instance the second phalanx was short and apparently rudimentary. The so-called pseudo-epiphysis shown in figures 8 and 11 is distinct and has the characteristics of a normal epiphysis. It would be hard to consider one a secondary epiphysis as has been done in most of the cases heretofore reported and in this case it seems quite evident that the first metacarpal had two true epiphyses. The presence of an extra epiphysis, however, has not caused any increased length as might be supposed, for although this metacarpal is longer than the metacarpal of the fifth finger of the same hand, it is not as long as the metacarpal of the thumb on the left hand, which has only one epiphysis. I am lead to believe that both epiphyses are true epiphyses, by comparing the x-ray photographs taken nine months apart. In figure 11, taken in November of 1916, both epiphyses have the appearance of true epiphyses as much as they did in the photograph taken in March of 1916 (fig. 8) or almost a year before. Hence although the supernumerary or cephalic epiphysis may fuse earlier than the basal or normal one it is clear that the former does not fall under what Thomson '06 speaks of as "scale-like epiphyses on the head of the first metacarpal which makes its appearance about eight or ten, and rapidly unites with the head." Since the first metacarpal in the left hand of this case, has a distally located epiphysis an interpretation of the latter in Thomson's sense would leave this metacarpal without an epiphysis.

Frcund '05 also reported a case in which the middle phalanx had an epiphysis at the distal as well as at the proximal end. He compares his case to those reported by Pfitzner '00, and arrived at the same conclusion regarding the spurious character of these epiphyses. Pfitzner bases his conclusion upon the variation in ossification found in many cases which came under his observation. He thinks that in these cases of apparent supernumerary epiphyses the oestoclasts, instead of breaking down the epiphyseal cartilage in a straight-line front, extend into it in the form of processes or projections and thus produce an appearance which roughly simulates an epiphyseal line.

But as the photographs (figs. 8 and 11) show the breaking down of the cartilage in this case is being carried on in a straight line front. The portion of cartilage between the diaphysis and the extra epiphysis is as even and regular as in any normally developing bone. Hence Pfitzner's explanation does not apply here and this epiphysis seems to be a true and not a pseudo-epiphysis.



Figs. 10 and 11 Same hands about one year later

The mortising of the bases of some of the metacarpals is quite pronounced. On the medial side of the basal end of the third left metacarpal, for example, there is a deep notch for the articulation of the fourth metacarpal (fig. 10). There doesn't seem to be any explanation for the presence of this unusually deep notch.

Scrutiny of figures 10 and 11 will show that the carpal bones in the right and left hand vary both as to shape and relative position. In (fig. 10) of the left hand the greater multangular is considerably larger and completely overshadows the lesser multangular bone. In the right hand (fig. 11) the lesser multangular is larger than the greater multangular but the greater multangular is more laterally placed. Figure 10 also shows the triquetral bone to have a rectangular shape. Indeed, it looks not unlike a short phalanx. The triquetral bone shown in figure 11 is triangular and considerably larger than that in figure 10.

The thumbs in this case especially the left seem to be like a little finger in most respects except their position on the hand. Their movements are limited to the normal movements of a finger; they have the same number of phalanges as the other fingers; the nails resemble the nails of other fingers rather than thumb nails and their metacarpals have the characteristics of the metacarpals of fingers rather than those of normal thumbs. I do not think that the extra phalanx in either case can be considered as rudimentary because of the perfect development of each individual phalanx, the presence of a distinct normally-located epiphysis and the absence of any indication of fusion.

Professor Meyer to whom I am indebted for suggestions and assistance has offered a possible explanation for the occurrence of such a finger or thumb. If I understood him correctly he thinks that the apparent absence of the thenar muscles may indicate that the normal impulse to development of the thumb was absent and that hence the phalanges and also the metacarpals of the thumbs, assumed the form and relations characteristic of the fingers rather than of the thumb thus accounting for the extra phalanges in the thumb, the epiphyses in the supernumerary phalanges and also for the supernumerary epiphyses

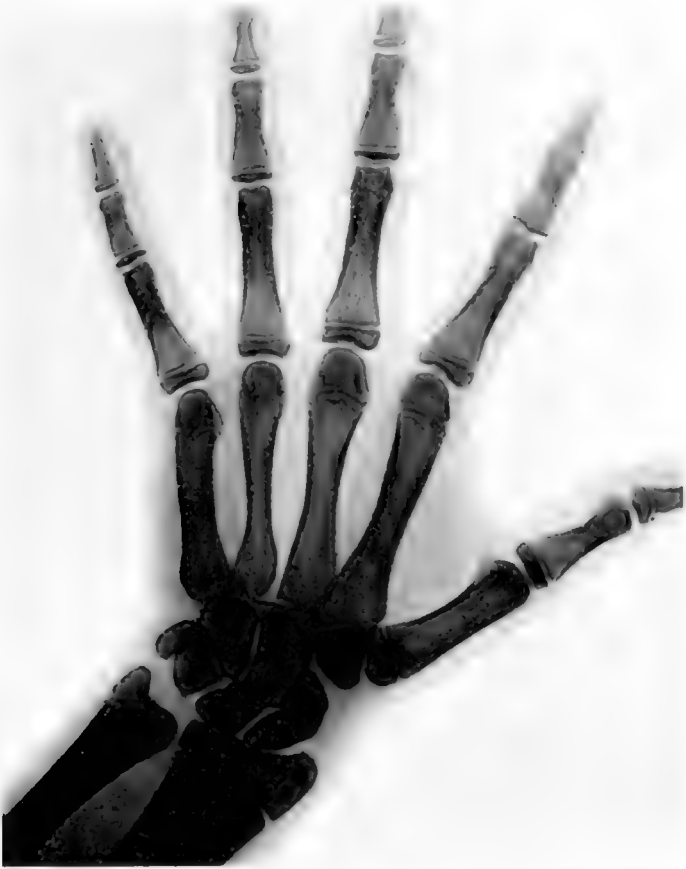

Fig. 12 Normal left hand of a boy of approximately the same age, height and weight for comparison

in the metacarpal of the right thumb as well as the distally-placed, single epiphysis in the metacarpal of the left thumb.

Although Professor Meyer's suggestions seem to account for the results found in this case, he feels that we can not be certain that the thenar muscles are entirely absent. However, as far as can be determined from external appearances and from the limited mobility of the thumb they must be exceedingly rudimentary indeed if present.

## BIBLIOGRAPHY

- ANNADALE, TH. 1865 The malformations, diseases and injuries of the fingers and toes and their surgical treatment. Edinburgh.
- BLUFF, M. J. 1826 Über das sogenannte Os metacarpi pollicis mit 3 Abbildungen. Archiv für Anatomie und Physiologie.
- DWIGHT, THOMAS 1907 Clinical atlas of the bones of the hand and foot. Philadelphia and London.
- FREUND, L. 1905 Über Pseudoepiphysen. Zeitschrift für Morphologie und Anthropologie, vol. 8.
- FALTIN, R. 1904 Ein Fall von Missbildungen der oberen Extremität durch Überzahl. Archiv für Anatomie und Physiologie.
- JOACHIMSTHAL, G. Über Brachydaktylie und Hyperphalangie. Virchow's Archiv, Bd. 151 Heft 3.
- KÜMMEL, W. 1895 Die Missbildungen der Extremitäten durch Defekte, Verwachsung und Überzahl. Biblioth. Med. E., Heft 3.
- LEBOTQ, H. 1896 De la brachydactylie et de l'hyperphalangie chez l'homme. Bull. de l'Académie royale de médecine de Belgique Seance du. 30 Mai.
- PFITZNER, W. 1890 Epiphysenbildungen, Mannigfaltigkeit derselben. Archiv für Anatomie und Physiologie, Anat. Abth.  
1892 Beiträge zur Kenntniss des menschlichen Extremitätenskelettes. Schwalbe's Morphologische Arbeiten, Bd. 1.  
Normalmasse der Phalangen 5. Beitrag zur Kenntniss des menschlichen Extremitätenskelettes. Schwalbe's Morphologische Arbeiten, Bd. 2.  
1894 Über das Skelett der menschlichen Hand. Schwalbe's Morphologische Arbeiten, Bd. 4.  
1895 Ein Fall von beiderseitiger Doppelbildungen der 5 Zehe. Schwalbe's Morphologische Arbeiten, Bd. 5.  
1897 Ein Fall von Verdoppelung des Zeigefingers. Schwalbe's Morphologische Arbeiten, Bd. 7, Heft 2.
- RIEDER, H. 1900 Eine Familie mit dreigliedrigen Daumen. Zeitschrift für Morphologie und Anthropologie.
- SALZER, H. Zwei Fälle von dreigliedrigen Daumen. Anatomischer Anzeiger, Bd. 14.
- SCHARFF, A. 1912 Zwei Fälle von symmetrischen Missbildungen der Finger. Ztschr. f. orth. Chir., Bd. 20.
- THOMSON, ARTHUR 1906 Chapter on osteology in Textbook of Anatomy, Cunningham, London. Second revised edition.
- UFFELMANN, J. 1862 Der Mittelhandknochen des Daumens, seine Entwicklungsgeschichte und Bedeutung. Göttingen.
- WINDLE, B. 1891 The occurrence of an additional phalanx in the human pollex. Jour. of Anat. and Physiol., vol. 26.
- WELCKEN, H. 1884 Die morphologische Bedeutung des 1. Daumengliedes. Preisvertheilungsprogramm der Universität Halle.



## AN INEXPENSIVE PROJECTION APPARATUS

IVAN E. WALLIN

*Department of Anatomy and Biology, Marquette University School of Medicine*

THREE FIGURES

The object of this apparatus is the substitution of an Edison Mazda lamp for the arc lamp and the reduction in cost of a serviceable apparatus for drawing. The arc lamp as an illuminating unit in a projection apparatus has certain objectionable features; the light is not always steady and it requires almost constant attention when in use. The perfection of the nitrogen-filled electric bulb has supplied a lighting unit which is only slightly less intense than the arc light.

A simple and inexpensive projection apparatus would be valuable for students' use in the laboratory. The apparatus described below, it seems to me, will supply a serviceable apparatus for class use at a very moderate cost.

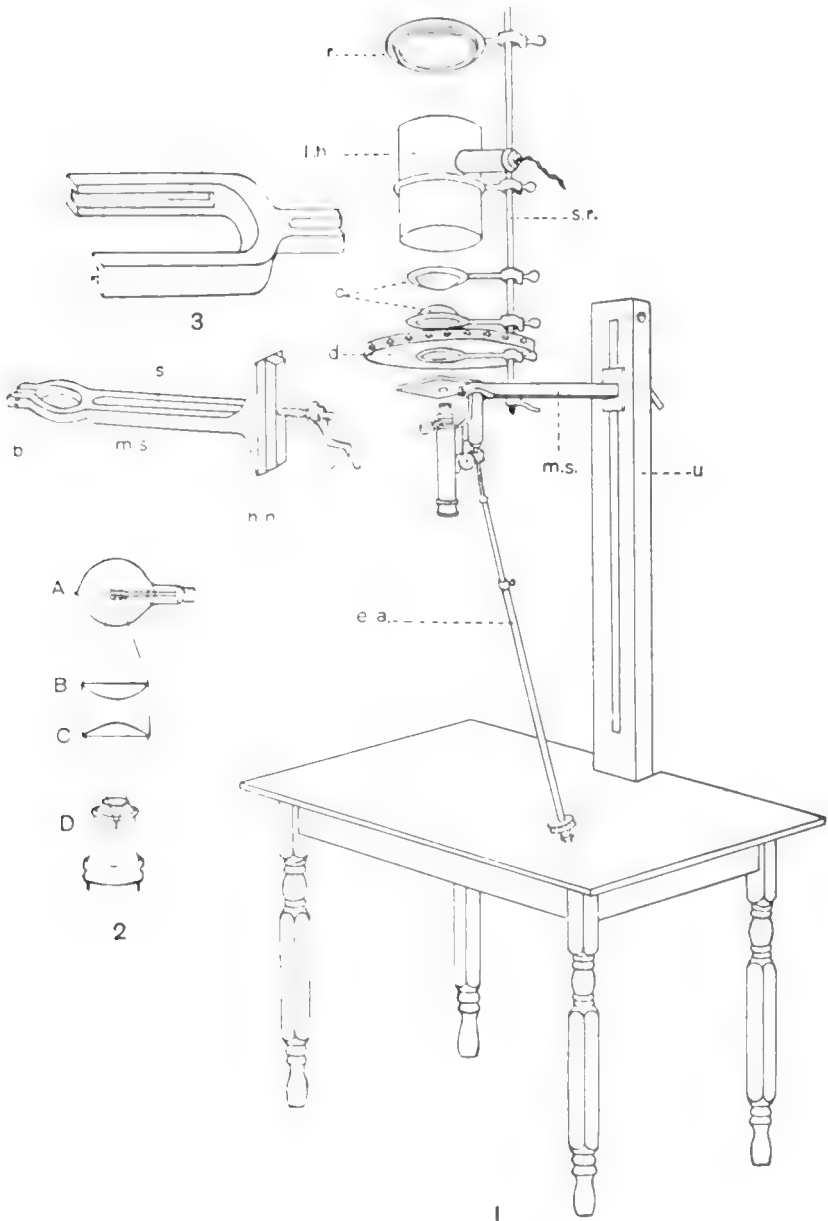
This apparatus is constructed on the plan of the Edinger apparatus (fig. 1). It consists of an upright oak beam (*u*) attached to an ordinary table, a microscope support (*m.s.*) which also supports a rod (*s.r.*) carrying reflector, lamp, condensers and diaphragm.

The upright (*u*) is an oak beam, 2 by 4 by 42 inches, containing a slot for the reception of the microscope support. It is bolted to the sides of the table and braced underneath to the top of the table.

The microscope support (*m.s.*) is a steel beam. The back has a flange which fits into the slot of the upright and serves to hold it firm. The free end is constructed in the form of a clamp to fit around the limb of the microscope and is made firm by means of a bolt (*b*). The body of the support has a slot (*s*) to receive the upright support rod (*s.r.*). The microscope support beam is movable up and down on the wooden upright and can be made secure at any point by means of the hand nut (*h.n.*).

A different type of microscope support is illustrated in figure 3. This type of support has the advantage that the microscope may be attached or removed in an instant. The stage of the microscope slides into the sleeve of the U-shaped support. The foot and pillar of the microscope are turned back at right angles to the body tube. A slot in the diaphragm would accommodate the foot. (It is an advantage to have a large diaphragm as it increases the working space.)

The support rod (*s.r.*) and the support rings which hold the lenses, diaphragm, lamp house and reflector were taken from an ordinary



laboratory support or ring stand. The support rings in this type all have a common center. The support rod is movable on the microscope support beam so that lamp and condensers may be properly centered with the microscope.

The diaphragm is a circular piece of wood which is held in place by a support ring. Curtains are attached to the diaphragm and hang down over the edge of the table. The curtains may be attached by means of hooks and eyes or glove fasteners.

The reflector (*r*) and its housing are a part of an old style gas automobile lamp.

The lighting unit is a 500 watt Edison Mazda stereopticon lamp. The filaments in this lamp are concentrated and form a compact unit. The lamp house is made of sheet iron and is held in place by a ring support. It also serves as a support for the lamp.

The condenser (*c*) consists of two 4-inch stereopticon lenses. These can be obtained from stereopticon supply houses. The adjustment of the lenses is illustrated in figure 2. The distance between the two lenses *B* and *C* is arbitrary. The filament of the lamp (*A*) should be at the point of focus of lens (*B*). The focus of lens (*C*) should fall within the objective of the microscope (*D*). The focal length may be determined by holding the lens to the sunlight in a smoky or dusty atmosphere and measuring the distance from the point where the rays cross to the center of the lens.

The microscope is an old type from which the foot and pillar have been removed. The stage has been reversed so that the slide rests on top of the stage. The fine adjustment extension (*e.a.*) consists of a rod, a pipe, a steel spring and a cap. The cap is secured to the fine adjustment by means of a set screw. The rod fits into the pipe and is made secure for any length by a set screw.

The fine adjustment extension was made in the laboratory. The microscope support was made by a blacksmith. If required in quantity the microscope supports could be cast in a foundry and obtained at a smaller cost.

The cost of the parts of this apparatus is as follows:

Upright (hard oak).....	\$1 25
Microscope support, bolts and nuts.....	3 50
Lenses for condenser.....	2 75
Reflector.....	1 00
Ring supports and support rod.....	1 75
Lamp.....	3 60
Fine adjustment extension.....	50

\$14 35

Bausch and Lomb Optical Company have recently perfected a lamp house with reflector and condensers which might be adapted to this apparatus.

I am greatly indebted to Dr. H. C. Tracy for assistance in the optical adjustment of the apparatus.



## VARIATIONS OF THE CANALIS HYPOGLOSSI

RALPH D. LILLIE

*From the Division of Anatomy of the Stanford Medical School*

My attention was attracted to the subject of the variations of the hypoglossal canal by the discovery of a double hypoglossal canal in the dissecting room. Subsequent examination of about thirty skulls, about twenty of them European, revealed ten cases of complete division of the canal. Consultation of the ordinary reference books failed to give definite figures. So Dr. Meyer placed the collection of skulls in the anatomical museum and Indian skulls in the general museum at my disposal.

Bartels ('04) found the hypoglossal canal doubled in 117 cases in 958 half skulls or in 12.2 per cent. In the seventeen varieties of skulls used by him the percentage varied from 0.0 per cent up to 27.9 per cent in Inca skulls. Weigner ('11) who examined 103 skulls in a study of the variations of the occipital bone found that the following percentages held for German skulls:

Left side	Right side
Clear, 62.1 per cent	Clear, 59.2 per cent
Incomplete or indicated division, 19.4	Indicated division, 18.5 per cent
Complete division, 18.5 per cent	Complete division, 22.3 per cent

Division into three parts was indicated in several cases. When the canal was double it was frequently divided into unequal parts so that the posterior canal was about twice the size of the anterior, or more rarely in the reverse ratio. Weigner believes that the division of the canalis hypoglossi is one of the manifestations of an occipital vertebra. Graf v. Spee ('96) notes the division of the canal and says that indications of division are almost constant in the adult but makes no mention of the character of the indications. Jaboulay and Luey ('11) attribute the division of the canal to that of the nerve and Fricke ('11) showed

that in the bovine embryo the hypoglossal nerve corresponds to three segmental nerves. Schäfer and Symington in Quain's Anatomy III, part 2, 1909, also regard the hypoglossal nerve as representing three segmental nerves. Prentiss ('10) working on pig embryos, found eight ganglionic masses corresponding to four ganglia associated with the hypoglossal nerves as their dorsal root ganglia. These ganglia were in series between those of the vagus and of the first cervical nerves. They are interpreted as representing four hypoglossal nerves. Five or six ventral roots of the hypoglossal exist, but according to Bremer ('08) the more anterior of these represent ventral roots of the vagus and glossopharyngeal nerves. Martin ('91) working on cats, found five ganglia and five ventral roots and concluded all were hypoglossal. So it would seem that either three or four nerves exist developmentally and this could account for either three or four somites and their corresponding neural foramina and their corresponding vertebrae. Hence between the jugular foramen and the synchondroses petro-occipitalis and occipito-sphenoidalis on one hand, and the atlas on the other, there must have existed four or five occipital vertebrae with three or four neural foramina or hypoglossal canals between them. Consequently we should expect to find traces of division of the hypoglossal canal into either three or four parts.

In fact we do find such divisions. As stated above Weigner noted indications of divisions into three parts, also into two parts, the posterior of which was twice the size of the anterior. I also have seen a number of such cases. Such occurrences could be interpreted as partial or complete separation of the first hypoglossal nerve while the two following remain together. I have seen indications of division into three equal parts two of which may be completely separated. However, complete division into three parts has not been observed.

McMurrich ('05) says "during the cartilaginous stage of the skull the anterior condyloid foramina are divided into three portions by two cartilaginous partitions which separate the three roots of the hypoglossal nerve," and considers this as evidence of the existence of four fused vertebrae in the occipital bone.

These facts point toward three original hypoglossal canals. But a number of cases were observed in which the canal was completely or incompletely divided into two equal parts and in which the anterior canal showed indications of further division into two equal parts. In the light of the work of Prentiss and Bremer I must look upon such instances as an indication of division of the canal into four equal parts. Of course, it may be in this case that it is really divided into three and that the third hypoglossal nerve is larger than the others. Poirier et Charpy report cases in which the canal was divided into four parts. Professor Meyer suggested to me that some of the osseous processes observed may be secondary ossification in the dural septa extending between the fasciculi of the roots instead of remnants of arches of occipital vertebrae. Such a case was noted in No. 42, a dissecting-room specimen. In this skull the dried remains of a dural or connective tissue septum extended between two spurs on opposite sides of the foramen. Whether these spurs are to be looked upon as secondary ossifications of a dural septum or whether such septa are to be considered as unossified remnants of vertebral arches can not be decided in dried skulls.

It is also probable, indeed almost certain, that in some cases these divisions are significant not of division of the nerve, but of vascular variation. Some of the variations recorded here are unquestionably due to aberrant vessels and not to division of the nerve. I refer here to those cases in which tortuous canals leave the main canal more or less obliquely to reënter in another place in similar fashion. On the other hand a large number of these variations are in all probability due to division of the nerve, for the nerve has been observed to pass through as two separate nerves, each in a canal of its own. In the more caudal parts of the body the metamerism of nerves and vertebrae holds strictly. Metamerism of the nerves exists in the head, showing best in the embryo. Indications of bony segmentation of the canal corresponding to the nervous segmentation are also found. Moreover an occipital vertebra may be partially separated. These facts all point in the same direction.

## OBSERVATIONS

*55 Indian skulls from Jersey County, Illinois*

## Character of hypoglossal canals

SUM- BER	LEFT	RIGHT
7615	A slight superior spur not at either opening	A septum a few millimeters thick at internal opening. The foramina equal
7613	Simple	Simple
7612	Simple, smaller	Simple, larger
7630	A slight superior prominence near the margin	A slight superior tubercle at the inner margin
7609	Simple, round	An inferior spine, a flattened internal opening and a slight indication above at the internal margin. Round externally
7607	A small antero-superior spur	A small antero-superior spur
7605	Simple	A rough superior internal margin
7608	A heart shaped internal opening with a prominence superior	An anterior foramen right through to a common external opening. A larger posterior foramen giving rise to a small anterior canal through to the common external opening and a large posterior blind pit. In the external opening are three small pits above and posterior to the two canals
7606	A small antero-superior notch	A small antero-superior notch
7604	The internal margin is rough superiorly	A marked internal superior spine with an indication opposite on the lower margin. The anterior division is half the size of the posterior
7616	A septum 3 mm. wide by 1 mm. thick internally. The anterior canal is smaller than the posterior	A projection on the superior margin
7618	A slight superior spur	Two equal canals
7619	Opposed spurs above and below	Compressed dorso-ventrally
7620	A broad septum within canal. Anterior canal half the size of the posterior	A broad septum within the canal. The anterior canal half the size of the posterior
7627	Simple	Simple
7626	A slight superior tubercle	A slight superior spur
7625	Simple	Simple



OBSERVATIONS—*Continued*

NUMBER	LEFT	RIGHT
7624	Simple	A deep septum half the length of the canal. Equal division.
7623	Simple	A slight double spur on the internal superior margin
7622	Simple	A slight spur from the roof near the internal orifice
7639	A superficial internal septum. Small anterior, large posterior canal	A rough superior margin internally. The medial side of the posterior condyloid canal opens into the skull posterior to canalis hypoglossi
7638	A broad superficial internal septum. Anterior canal smaller	A slight superior spur. The anterior division half the posterior
7637	Slight antero-superior spur on roof	Slight antero-superior notch
7635	Simple	Simple
7634	Simple, larger	Simple, smaller
7633	Anterior superior spur. One to two division	Slight double superior spur
7631	Antero-superior notch	Two slight superior elevations
7628	Simple	Simple
7632	Simple	Simple
7610	Simple	Simple
7624	A ridge below, a spur above	Simple
7641	Simple	Simple
7640	Simple	Simple
7643	A marked superior spur	Simple
7642	Simple	Simple

*Two Indian skulls from La Conner, Washington*

7645	An internal septum. Anterior canal half the posterior	Simple
7644	Simple	Simple

*Three Indian skulls from the Longueville graves, Plumas County, California*

7647	A superior spur	A narrow, median, superficial internal septum
7648	A broad superficial internal septum	Simple
7649	Simple	Simple

## OBSERVATIONS—Continued

*15 Indian skulls from Ponce mound near Mayfield, California*

NUMBER	LEFT	RIGHT
E.	Simple	Simple
7650	A thin, narrow septum in the mid-portion of the canal	Superior tongue-like process and a slight inferior tubercle
7651	Clear	Complete septum. Anterior canal half the size of the posterior
7652	Spur on the superior internal margin	Opposed spurs on internal margin
7653	Simple	Simple
7654	Simple	A superior anterior roughening
7655	Simple (young, first permanent molar)	Simple
7657	Simple	Simple
7656	Simple	Simple
7660	Simple, flattened	Simple, flattened
7658	Simple	Simple
7662	A deep internal septum in inner third of canal	Simple
7661	Simple	Simple
M1	A thin, superficial internal septum. Anterior foramen half the size of the posterior	Simple
M2	Both foramina round. Septum deep in middle third of canal. Anterior canal larger	Flattened from top down.

*Five Indian skulls from near San Jose, California*

M3	Median septum near internal foramen	Median septum near internal foramen. Opposed spurs divide anterior canal into two
M4	Antero-superior spur and notch	Simple
M5	Simple, round	Opposed spines. Anterior division half posterior
M6	Broad flat septum. Two internal foramina are equal. External foramen single	Basioccipital of this side is destroyed
M7	Simple	Strong superior and slight inferior spines on internal margin. Anterior division half posterior

*Twelve whole skulls or entire occipital bones*

NUM- BER	LEFT	RIGHT
1	Completely divided nerve in both canals	Clear. Only one hole in dura
2	Rough superior internal margin	Rough superior internal margin
3	Slight median superior spur	Clear. (Anterior part atlas assimilated)
4	(102.) Clear	Clear
5	Antero-superior notch	Clear
6	Medium superior spur. Also superior spur in middle of anterior division	Opposed median spurs
7	Clear	Clear
8	(13.) Strong septum anterior canal 2-3 times as large as posterior	Septum in middle third of canal. Anterior canal is twice the size of the posterior
9	An anterior-superior notch	Anterio-superior notch. (Occipital only)
10	Clear. (Occipital only)	Clear internally. At external opening a small superior canal cut off
11	Clear	Clear
12	Slight median superior elevation. Two small orifices just above internal opening	Clear

*Twenty-two European skulls*

1	IV. Clear	Antero-superior cleft and spur
2	V. Thin median septum in inner third	Thicker median septum in middle third. Spur in middle of superior margin. Small inferior spur and opposed superior ridge in middle of anterior canal
3	XIII. Large and clear, posterior condyloid canal opens laterally	Large and clear
4	II. Clear	Median superior tubercle
5	XV. Antero-superior irregular process 1 to 2 mm. long	Antero-superior and antero-medial spurs. Small canal antero-superior to two spurs
6	Thin septum in middle third of canal. Anterior two-thirds size of posterior. (6 on medial side of left mastoid)	Opposed elevations. Anterior part constricted and half the size of the posterior

OBSERVATIONS—*Continued*

NUMBER	LEFT	RIGHT
7	XII. Opposed antero-superior and -medial spurs which enclose a small canal	Same as left but enclosed canal smaller
8	XIV. Clear	Clear
9	VII. Antero-superior marginal elevation	Clear
10	III. Slight antero-superior tubercle	Clear
11	XVII. Triangular. A fossa runs back from posterior superior corner into a small pit	Antero-superior notch clear through
12	IX. Clear opening. A small venous canal runs antero-medially from roof near posterior orifice to near the external orifice of canal	Clear
13	XVI. Clear	Clear
14	VIII. Clear	Clear
15	Heavy septum. Anterior canal small, almost slit-like. The slit points toward the condyle	Clear
16	V. Clear	Clear
17	III. Clear	A long superior spine which almost divides the main canal into a smaller anterior canal and a larger posterior. A wide opening in the postero-lateral wall opening into the posterior condyloid canal.
18	II. Strong septum in inner half. Anterior canal slightly smaller	Clear
19	(04.) (Separate occipital) Clear	Median superior spur
20	B11. Opposed median spurs, the superior being stronger	Clear
21	C11. Clear	Clear
22	Clear	Clear

Summary

LOCALITY	SIDE	NUMBER CLEAR	PERCENTAGE CLEAR	DIVISION INDICATED	PERCENTAGE INDICATED	COMPLETE DIVISION	PERCENTAGE COMPLETE	TOTAL NUMBER
Illinois Indians.....	Left	17	48.6	14	40.0	4	11.4	35
	Right	15	42.9	15	42.9	5	14.3	35
	Both	32	45.7	29	41.4	9	12.9	70
California Indians.....	Left	14	56.0	3	12.0	8	32.0	25
	Right	16	66.7	5	20.8	3	12.5	24
	Both	30	61.2	8	16.3	11	22.4	49
Specimens from dissecting room.....	Left	31	43.7	30	42.2	10	14.1	71
	Right	31	43.7	31	43.7	9	12.7	71
	Both	62	43.7	61	42.9	19	13.4	142
European skulls.....	Left	13	59.1	5	22.7	4	18.2	22
	Right	13	59.1	8	36.4	1	4.5	22
	Both	26	59.1	13	29.5	5	11.4	44
Total.....	Left	75	49.02	52	33.99	26	16.99	153
	Right	75	49.34	59	38.82	18	11.84	152
	Both	150	49.18	111	36.39	44	14.43	305

*Unpaired series. Fifty-nine left sides of skulls or of occipital bones from cadavers dissected in the dissecting room*

1. Anterior superior spine and notch.
2. Anterior superior spine and notch.
3. Clear. A small canal from the lateral wall of the canal opens behind the occipital condyl. Anterior to this are two other apparently blind small canals.
4. A superior tubercle in the middle of the internal margin and another midway between the first and the antero-medial internal margin.
5. Clear.
6. A strong septum with a superior spur projecting inward. The anterior canal is smaller.
7. The superior wall of the canal is destroyed, the remainder appears clear.
8. A strong superior spur internally. The anterior division is half the posterior.
9. Clear.
10. A small superior elevation between anterior and middle thirds of the internal margin.
11. Clear.
12. Large. Rough superior and antero-medial margin.
13. (13L.) A strong complete septum clear through to the external opening. The anterior canal is half the posterior. A canal from the postero-lateral

wall of the posterior canal opens into the medial side of the posterior condyloid canal. Anterior canal has marked anterior constriction. From anterior opening the anterior canal has marked superior diverticulum which communicates with top of posterior canal. Latter has smaller anterior opening.

14. Clear.

15. Large, clear.

16. Posterior condyloid canal opens just posterior to posterior internal margin. The internal orifice had slight antero-superior notch. Opposed superior and inferior ridges near the external orifice divide the canal evenly.

17. Antero-superior cleft.

18. Clear. One pit in superior, another in postero-lateral wall of the canal.

19. Rough superior margin. A small vascular canal goes laterally then forward from the posterior internal margin and reenters the canal at the external orifice.

20. Antero-superior cleft internally.

21. The superior wall is destroyed. Rest clear.

22. Strong median superior spine internally.

23. Small antero-superior cleft.

24. Clear.

25. Clear.

26. Clear.

27. (27L.) A strong internal septum divides the canal equally. The internal orifice of the posterior canal is much larger. A wide postero-lateral opening into the posterior condyloid canal and a large superior diverticulum opening posteriorly and internally. The internal opening of the anterior canal has a sharp spine from the antero-medial wall with a deep cleft below. A superior diverticulum from the common external opening.

28. Clear.

29. Clear. Slight antero-medial constriction.

30. A septum in the outer third or half of the canal. The posterior canal is half the anterior.

31. Antero-medial or -superior notch.

32. Large. Antero-medial notch. Posterior condyloid canal has opening into postero-lateral wall.

33. Opposed spurs. Anterior division is half or third the size of the posterior.

34. Antero-superior spur.

35. (35L.) Internally an antero-superior spur has bridged the canal completely, cutting off a small antero-superior canal which has a median superior spur that makes it U-shaped.

36. Rough superior margin. Anterior constriction. Two small canals from postero-superior wall probably to the posterior condyloid canal.

37. Clear.

38. Clear.

39. Antero-superior notch. Canal from postero-superior internal margin probably to posterior condyloid canal.

40. Clear.

41. Median and anterior superior notches.

42. Clear.

43. Clear.
44. Clear.
45. Internal superior marginal spur, between middle and posterior thirds.
46. Clear.
47. Antero-superior spur.
48. Antero-medial tubercle.
49. A superior spine and an opposed inferior elevation. Almost complete division, so that the posterior division is one and half times the size of the anterior division.
50. Antero-superior internal notch includes a small spine and opposed spines in the middle of the canal dividing it equally into postero-superior and antero-inferior parts.
51. Antero-superior notch.
52. Opposed spurs. Anterior canal smaller.
53. Clear.
54. Median superior notch.
55. Strong median septum.
56. Opposed spines—superior longer. Anterior canal smaller.
57. Clear.
58. Clear. Only one hole in dura mater.
59. Large. Strong slightly anterior septum in middle third of canal.

*Fifty-nine right halves*

1. Antero-superior cleft.
2. Thin septum which is incomplete at the inner opening. Anterior canal smaller with further anterior notch.
3. Flattened from above down. An indicated spur in the middle of the superior internal margin. Anterior half of orifice especially flattened. External orifice rounded.
4. Superior median elevation and an anterior superior spur with an opposed inferior elevation.
5. Narrow septum. Anterior canal smaller.
6. Clear.
7. Clear.
8. Rough superior margin. Elevation between anterior and middle thirds of superior internal margin.
9. Antero-superior notch.
10. Constricted anteriorly.
11. Strong septum with superior internal spur. Equal canals.
12. Clear.
13. Small antero-superior cleft.
14. Opposed spurs which separate the anterior third of the canal. In addition there is an antero-medial spur.
15. Clear.
16. Greatly flattened. Median spur within the canal on its roof.
17. Clear. Flattened.

18. (ISR.) Large oval inner orifice. At the outer orifice a thin strand of bone divides off a smaller posterior division. Postero-lateral to this is a pocket opening back and inward with a round hole 1 mm. in diameter in the middle which opens through into the external orifice and a pit 2 mm. in diameter above, which opens anteriorly into a large superior diverticulum from the anterior canal.

19. Median superior spine.

20. Clear. Large canal from posterior wall to posterior condyloid canal.

21. Clear.

22. Clear.

23. Antero-superior spur and notch.

24. Strong septum. Anterior canal smaller. Common external opening has superior diverticulum.

25. Slight spur internally on upper third of antero-medial margin.

26. Clear.

27. Superior spur on inner margin posterior division half the size of the anterior.

28. Clear.

29. Antero-superior spur and notch.

30. Clear. Foramen magnum and condyle malformed.

31. Clear.

32. Large internal opening clear. A canal starts off from the middle of the postero-superior wall opening separately at outer opening. An antero-medial notch. Antero-superior diverticulum in middle of canal.

33. Clear.

34. Slight opposed elevations anteriorly on inner margin. Inferior elevation stronger.

35. Large. Clear.

36. Large. Opposed spurs between anterior and middle thirds.

37. Clear.

38. Large. Antero-superior spur.

39. Slight anterior superior eminence between anterior and middle thirds.

40. Clear.

41. Clear.

42. Opposed elevations and dried remains of a connective tissue septum. Anterior canal half posterior.

43. Slight superior spur between anterior and middle thirds of internal margin.

44. Median and anterior superior spurs with slight opposed inferior ridges. A small canal from anterior superior corner returns by a curved course to superior wall near external orifice.

45. (IV.) Antero-superior notch.

46. Two superior internal spurs equally spaced with an anterior medial spur opposed to the anterior superior spur. A canal from posterior wall probably to posterior condyloid canal.

47. An anterior constriction.

48. Small 1 to 1.5 mm. round notch on antero-medial internal margin which is set off by two spurs.

49. Antero-superior notch.



50. Median superior tubercle.
51. (51R.) Strong horizontal septum. Smaller inferior, larger superior canal.
52. Large. Clear.
53. Septum in internal part of canal not quite to inner orifice. Anterior canal half the size of the posterior.
54. A complete thin, 2 mm. wide, superficial internal septum. Anterior canal slightly smaller.
55. Two equally spaced superior internal tubercles. Antero-inferior spur opposes anterior one.
56. Anteriorly constricted internal opening.
57. Clear.
58. Clear.
59. Clear

Although the number of skulls from different groups or types was too small for a comprehensive view, the above table indicates a variation in the frequency of division among the different racial types. This was also found to be true by Bartels ('04). Complete division shows itself in the Illinois Indians in only 12.9 per cent of the cases, while in the California Indians it was seen in 22.4 per cent. In the dissecting room specimens and in the European skulls the incidence was 13.4 per cent and 11.4 per cent respectively.

Distinct differences between the right and left sides exist. Complete division is more frequent on the left side—16.99 per cent as against 11.84 per cent—while indicated division is more common on the right—38.82 per cent as compared with 33.99 per cent. The canal is clear in an equal number of cases on each side. Racial differences seem to be indicated here, too. In the Illinois Indian skulls and in those from our dissecting room there is practically no difference between the two sides, but in the California Indians and in the European skulls decided differences were found.

The canal is clear in an equal number of cases on both sides. This agrees very well with Weigner's ('11) who found the canal clear in 62.1 per cent of the skulls on the left and in 59.2 per cent on the right. I find 49.02 per cent on the left and 49.34 per cent on the right. Weigner found indicated division in 19.4 per cent on the left and in 18.5 per cent on the right—practi-

cally in equal numbers in 103 skulls. I find 33.99 per cent and 38.82 per cent for the left and right sides respectively. Complete division of the canal was present on the left in 18.5 per cent and on the right in 22.3 per cent of Weigner's specimens, but in only 17.0 per cent on the left and in 11.8 per cent on the right side in my series.

Frequently in cases of complete or indicated divisions the two canals are unequal, one being about twice the size of the other. The anterior usually is the smaller. Indications of further division of the larger of the two canals occurs in a few cases. The two canals are often equal in size. In the latter case some few examples of further indicated division of the anterior canal were seen.

From the variations in form of the hypoglossal canal in adult skulls I am unable to decide whether there were three or four hypoglossal canals developmentally.

I take pleasure in thanking Professor Meyer for his assistance and suggestions.

#### LITERATURE CITED

- BARTELS, P. 1904 Über Rassenunterscheide am Schädel I. Intern Monschr. f. Anat. u. Physiol. Bd. 21.
- BREMER, J. L. 1908 Aberrant roots and branches of the abducent and hypoglossal nerves. Jour. Comp. Neur. Psychol., vol. 18.
- FROMIËP 1911 Poirier et Charpy. Tr. d'anat. hum. Tome 1, Paris.
- JABOULAY ET LUCY 1911 Poirier et Charpy. Tr. d'anat. hum. Tome 1, Paris.
- MARTIN 1891 Die Entwicklung der neunten bis zwölften Kopfnerven bei der Katze. Anat. Anz. Bd. 6.
- McMURRICH, J. P. 1905 The development of the human body. Phila.
- POIRIER ET CHARPY 1911 Traité d'Anatomie humaine. Tome 1, Paris.
- PRENTISS, C. W. 1910 The development of the hypoglossal ganglia of pig embryos. Jour. Comp. Neur. Psychol., vol. 20.
- SCHÄFER AND SYMINGTON 1909 Quain's Anat., vol. 3, pt. 2. 11th ed. London.
- GRAF VON SPEE 1896 Bardeleben Handb. d. Anat. d. Menschen. Bd. 1, Abth. 2.
- WEIGNER, K. 1911 Über die Assimilation des Atlas und über die Variationen am Os occipitale beim Menschen. Anat. Hefte Bd. 45.

## A CASE OF SUPERFETATION IN THE CAT

MARY T. HARMAN

*Kansas State Agricultural College*<sup>1</sup>

THREE FIGURES (TWO PLATES)

### DEFINITION OF SUPERFETATION

There seems to be a lack of unity among authors as to what the phenomenon of superfetation really is. Marshall ('10) defines superfetation as a condition in which "foetuses of different ages may be present in the same uterus." He does not say that a second coition is necessary to produce this condition, but from his statement he implies that it is. He says: "If ovulation takes place during pregnancy, and if, owing to the occurrence of coition the ova become fertilized, the phenomenon of superfetation may take place." At least, he makes it perfectly plain that the eggs belong to different periods of ovulation.

McMurrich ('13), suggests that many cases which have been reported as superfetation are due to differences of nutrition, and are the result of the simultaneous fertilization of different ova. He says that it is not impossible for a second ovum to be fertilized as the result of a coition at an appreciable interval of time after the first ovum has started upon its development. However, the difference between the normal embryo and that due to superfetation is comparatively small, provided that the nutrition to both embryos are the same. He further states that for physiological reasons, the passage of the spermatozoön to the egg is very soon impossible.

Longley ('10 and '11) finds that coition is necessary to ovulation in the cat, and particularly to maturation; therefore, in

<sup>1</sup>Contribution from the Zoological Laboratory, Kansas State Agricultural College, No. 15.

order to have superfetation, it is necessary to have a second coition.

Arrowsmith ('34) gives an account of a number of cases of superfetation and suggests that it is impossible that they could be the result of the simultaneous fertilization of different ova.

Bonner ('65) classifies the reported cases of superfetation in man in three groups: 1) His first group is composed of those cases in which two mature children are born at the same time but bear marks of different parents. This group of cases, of course, is due to different coitions, but not necessarily due to different periods of ovulation. In fact, they could not be due to very different periods of ovulation and be born at the same time in the same degree of development. 2) His second group includes twins born at different times. He would say that these are the result of differences in development. 3) His third group, and the group which he would consider true cases of superfetation are those in which embryos are born at intervals too small for a second conception. He cites a number of cases in the human, ranging in intervals from two and one-half months to five and one-half months.

King ('13) distinguishes between what she considers superfetation and superfecundation. She defines superfecundation as the fertilization by successive matings of ova belonging to the same period of ovulation; and superfetation as the fertilization of ova of different periods of ovulations, followed by copulation occurring during pregnancy which leads to the simultaneous development of two sets of ova. From King's definition, it is seen, that she would confine the term superfetation to those cases in which there has not only been a second coition but also a second period of ovulation.

Sumner ('16) believes that superfetation may be the result of a second coition, but not necessarily so. He thinks that the spermatozoa (in case of mice) may be retained in the uterine passage of the female for a length of time and still be functional, and that true cases of superfetation may be the result of a single coition.

Schultze ('66) does not say that superfetation is impossible; but he explains all of the cases reported in man up to that time on the basis of either the death or the retardation of the less advanced fetus. This also seems to be the position taken by Kuntz ('16). He states that the "two cases of apparent superfetation in cats which were examined by the writer, afforded no evidence in favor of the occurrence of superfetation."

Godlewski ('14) believes that the process of superfetation is a physiological impossibility.

It will be seen from the above that there is a great difference of opinion as to what superfetation is; but all agree, at least, in one particular, that is, that embryos of different degrees of development are in the uterus at the same time. The case of the cat, which the writer is about to report, has also this characteristic in common with the other cases. There is a decided difference in the degree of development in the embryos, and neither set shows lack of nourishment, if the blood supply may be taken as a criterion, or any degree of decomposition.

The writer will use the word 'superfetation' to mean that condition in which the uterus contains embryos of different degrees of development. This condition may be the result of a second coition or a second conception may have taken place without a second coition.

#### SUPERFETATION OF THE CAT

During the dissection of the cats in the class work of general zoology, a marked difference in the size of the enlarged places of the uterus was noticed in one of them. This led to an examination of the different embryos which revealed that three embryos were developed near to term, and one apparently normal, was much smaller and showed a much less degree of development. Nothing is known concerning the periods of heat or time of coition.

Figure 1 shows the gravid uterus about one-half natural size. The enlargements, A, B, C, and D, contain embryos but no trace of an embryo could be found in enlargement E. The blood vessels had been injected and the blood supply to the uterus

is plainly shown. The supply to the smaller enlargements seems to be equally as good as to the larger ones, if the size of the blood vessels may be taken as an indication.

The right horn of the uterus contained one of the larger embryos and the smaller one. The larger embryo was next to the Fallopian tube while the smaller one was near the vagina. The left horn of the uterus had three enlargements, two of which contained embryos of the same degree of development as the larger one in the right horn. No trace of an embryo was found in the enlargement next to the vagina, although the fetal membranes extended into it and there also seemed to be an abundant blood supply.

The large embryos (fig. 2) are about 90 mm. long, not including the tail, and from the external features appear to be near to term. The limbs are well formed and normal, having joints, and on the ends of the digits are claws. The whole surface of the skin is covered with pits, although there is very little hair. The nose and mouth resemble the nose and mouth of a newly born kitten and the external ears are very prominent. The tail is more than one-third the length of the remainder of the body. The body is closed ventrally. The one represented in the drawing differs from the other large embryos in that a short distance from the body the umbilical cord divides, and a part passes around either side of the body to connect with the placenta. The fetal membranes fill the entire enlargement of the uterus and fit very closely to its walls.

The small embryo which to all appearances shows no decomposition, is only 10 mm. in length. The umbilical cord occupies about one-sixth of the ventral surface. The limbs, fore and hind, are merely buds. The tail is about one-fifth the length of the remainder of the body. There are no indications of hair follicles. The mouth is in the process of formation. The mandibular processes have met in the midventral line, but they extend only about one-third as far as the maxillary processes. The lip groove is shallow, in fact, there is merely the beginning of the separation of the lips and cheeks from the jaw proper. The oral pit is yet rectangular in shape. There is no indication

of eyelids; but the eyes are plainly visible from the outside as small dark spheres.

It seems that the smaller embryo is at a stage of not more than three weeks' development, while the larger embryos represent seven or possibly eight weeks' development.

Owing to the fact that the material was preserved merely for the examination of the gross anatomy of the mother, the tissue is not favorable for microscopic study, but the conditions for the less advanced fetus are the same as those for the larger ones. The fetal membranes of the one is in as good a state of preservation as those of the other. Both the amnion and the chorion of the smaller embryo has the appearance of being younger than they do in the case of the larger embryos, but they have no greater evidence of necrosis. The injection of the blood system of the mother before preservation has made possible a better study of the blood supply to the embryos than could have been made otherwise. If the smaller embryo should have been the result of an early death or retardation of development, this is not evidenced by any lack of blood supply.

Although, as was stated before, nothing is known concerning the periods of heat and time or times of coition, yet it seems that the condition of the fetal membranes of both the smaller and the larger embryos, the abundant blood supply to the smaller embryo as well as the lack of decomposition are evidences that it is not a result of early embryonic death, but that it is a result of a later conception.

#### DISCUSSION

The explanations of reported cases of superfetation are almost as numerous as the authors who have reported them. There are those who do not believe that the supernumerary brood or accessory birth, if the writer may use that term, is (Schultze, '66) or can be (Godlewski, '14) a result of conception during pregnancy. As has been previously stated, Schultze (in the human) considers these cases as twins in which the one has been retained in the uterus for a longer period than the other. He explains the difference in the degree of development on the basis of lack

of food supply, therefore, development is retarded. If this be true of the cases reported in the human the gestation period has been prolonged as much as five and one-half months. So far as the author is aware, this is a much longer period than is recorded for prolonged pregnancies. Furthermore, if this explanation should be applied to the cases of the mouse as reported by Sumner ('16) the period of gestation would be almost three times the normal period of gestation. At least, the period from the birth of the last normal litter until the birth of the supernumerary litter in one case was as much as thirty-seven days, which, if added to the period of gestation for the normal litter which is twenty-two days, would be fifty-nine days. This lacks only one week of being three times the normal period of gestation. It might be added that the male was removed from the nest before the birth of the first litter. The writer, in giving extremes, would not presume to say that such a phenomenon is impossible; but it seems that the evidence is scarcely enough to justify the belief in such an extended prolongation of the time of gestation.

Another explanation of the cause of superfetation which has been frequently given is that the organs of reproduction are abnormal, such as a bifid uterus, etc. Arrowsmith and others have shown that in a number of cases, at least, this could not account for the phenomenon. In the case of the sheep as reported by the above mentioned author, an examination of the slaughtered animal revealed no abnormality. While this explanation may seem perfectly plausible, it does not always agree with fact, and could not be accepted as a universal cause.

Whether or not ovulation takes place during pregnancy, has been a subject for much discussion and investigation. It is the general belief, one is safe in saying, that ordinarily during pregnancy, in man, ovulation ceases but if the condition of corpora lutea may be a safe criterion (McMurrich '13) this is not always true. Christopher ('86) reports having found a cat far advanced in pregnancy with four mature Graafian follicles each containing a mature ovule. There is also some evidence that ovulation may occur during pregnancy in the horse.



According to Marshall ('10), McMurrich ('13), Bonnar '65, Arrowsmith ('34), King ('13), Herzog ('98), and Sumner '16), superfetation may be caused by the fertilization of an egg ovulated during pregnancy. Marshall, McMurrich, and King further state that the phenomenon is also due to a second coition. Sumner suggests that perhaps there is a periodicity of ovulation which may not be interrupted by gestation, and that the spermatozoa may be retained in the reproductive organs of the female for a considerable length of time, and yet remain functional. His data show that either this must be true, or that the period of gestation is greatly prolonged, even more than doubled. In one case the last opportunity for copulation was nineteen days before the birth of the first litter, and forty-seven days before the birth of the second litter. Since spermatozoa have been found alive and active in the female reproductive organs some time after coition, it seems as reasonable to believe that these spermatozoa would function as that development would be prolonged to such an extent.

However, in the case of the cat described by the writer, another difficulty arises. The less mature embryo is next to the vagina, and in the same horn of the uterus between it and the Fallopian tube, is an embryo almost at maturity. While one would scarcely be justified in saying that the passage of an egg from the ovary to this position in the uterus under these conditions, is impossible, yet it hardly seems probable, for the fetal membranes are in very close contact with the uterine walls.

King suggests, in case of her rats, that perhaps the ovaries functioned independently, and that the first litter was the result of the ovulation of one ovary and the second litter the result of the ovulation of the other ovary. So far as the data given in her paper shows, this is merely a suggested possibility. No structures were examined to support the theory.

In the case of the cat, this would be equally as improbable as that the egg was fertilized by spermatozoa which have been retained in the uterus of the mother for, as has been stated before, in the same horn of the uterus between the vagina and the small embryo was an embryo which was near to term.

The writer would raise the question whether it would not be as reasonable to believe that the egg might be retained in the uterus some time before it was fertilized and yet be able to develop into an embryo, as that the spermatozoa could function some time after being discharged. The evidence seems to point to a good blood supply to the smaller embryo, and the implantation seems as good as the more advanced embryos. If it is small on account of retardation of development, some other cause for this arrested development must be sought. If the egg which gave rise to this embryo is of a much later period of ovulation than the eggs which gave rise to the other embryos, there is the mechanical difficulty of the passage of the egg from the ovary to the position which the embryo occupies in the uterus. This is true whether or not the egg was fertilized by a spermatozoon from a second coition, or from a spermatozoon which has been retained in the uterus for some time.

It seems reasonable to the writer that the different cases of superfetation may be the result of different causes and that it is hardly necessary to ascribe all cases to the same cause. Considering all the conditions the writer would suggest that the less developed fetus could be accounted for as a result of delayed fertilization.

#### SUMMARY AND CONCLUSIONS

1. The word 'superfetation' has been used to mean that condition in which the uterus contains embryos of different degrees of development. This condition may be the results of a second coition or a second conception may have taken place without a second coition.

2. Although superfetation is rare and abnormal, many cases have been reported in man as well as in a number of other mammals, which do not seem to be satisfactorily explained in any other way than that a second conception has taken place.

3. Perhaps not all cases of superfetation may be attributed to the same cause.

4. In the case of the cat described in this paper,<sup>2</sup> it seems as reasonable to think of the less advanced embryo as the result of delayed fertilization as to account for it on the ground of delayed development or a second coition.

## LITERATURE CITED

- ARROWSMITH, R. 1834 Superfetation (?) in the sheep. *London Med. Gazette*, vol. 14.
- BONNAR, GEORGE LINDSAY 1865 A critical inquiry of superfetation, with cases. *Edinburgh Med. Jour.*, vol. 10, part 2.
- CHRISTOPHER, W. S. 1886 Ovulation during pregnancy. *Amer. Jour. Obstetrics*, vol. 19.
- HERZOG, MAXIMILLIAN 1898 Superfetation in the human race. *Chicago Med. Recorder*, vol. 15.
- KING, HELEN DEAN 1913 Some anomalies in the gestation of the albino rat (*Mus Norwegicus albinus*). *Biol. Bull.*, vol. 24.
- KIRKHAM, W. B. 1907 The maturation of the egg of the white mouse and rat. *Biol. Bull.*, vol. 13.
- 1910 Ovulations in mammals with special reference to the mouse and rat. *Biol. Bull.*, vol. 18.
- KUNTZ, ALBERT 1916 A note on superfetation. *Interstate Med. Journ.*, vol. 23, no. 3.
- LONGLEY, W. H. 1910 Factors which influence the maturation of the egg and ovulation in the domestic cat. *Science, N. S.*, vol. 31, no. 795.
- 1911 The maturation of the egg and ovulation in the domestic cat. *Am. Jour. Anat.*, vol. 12, no. 2.
- MARSHALL, FRANCIS H. A. 1910 *The physiology of reproduction*. Longmans, Green and Co., New York.
- McMURRICH, J. PLAYFAIR 1913 *The development of the human body*. P. Blakiston's Son and Co., Philadelphia.
- SUMNER, F. B. 1916 Notes on the superfetation and deferred fertilization among mice. *Biol. Bull.*, vol. 30.
- SCHULTZE, B. S. 1866 Ueber Superfoecundation und Superfoetation. *Jenaische Zeitschrift für Medicine und Naturwissenschaft*, Bd. 2.

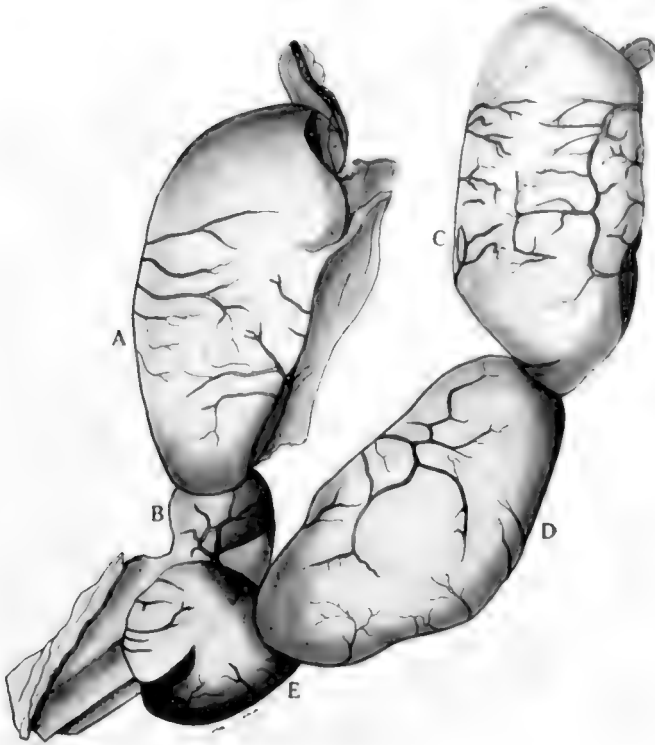
---

<sup>2</sup> The author wishes to express her indebtedness to Mr. Wallace Park, Assistant in Zoology, for calling her attention to this case.

## PLATE I

### EXPLANATION OF FIGURES

The pregnant uterus of the cat, one-half natural size. Enlargements A, C, and D contain embryos 90 mm. in length. Enlargement D contains the embryo shown in figure 3. Enlargement E does not contain an embryo.

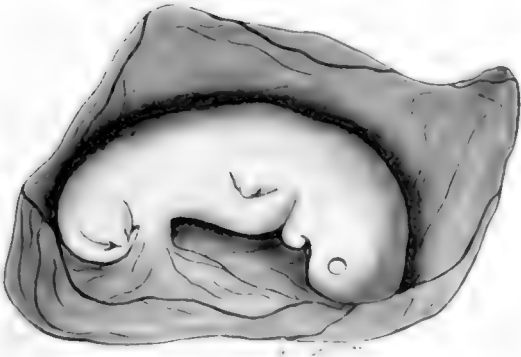
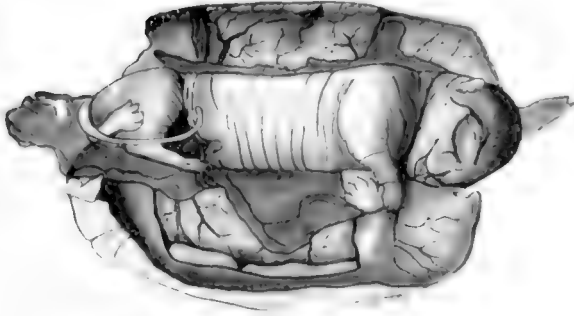


## PLATE 2

### EXPLANATION OF FIGURES

The embryo of enlargement *D*, figure 1, two-thirds natural size. The embryo is surrounded by the fetal membranes and a portion of the uterus. A part of the umbilical cord extends around one side of the body and a part of it extends around the other.

The embryo of enlargement *B*, figure 1, enlarged 5 diameters. The embryo is surrounded by the fetal membranes and a portion of the uterus.







## LABORATORY APPARATUS

### I. A SIMPLE ELECTRIC THERMO-REGULATOR

H. S. BURR

*From the Anatomical Laboratory of the Yale School of Medicine*

#### ONE FIGURE

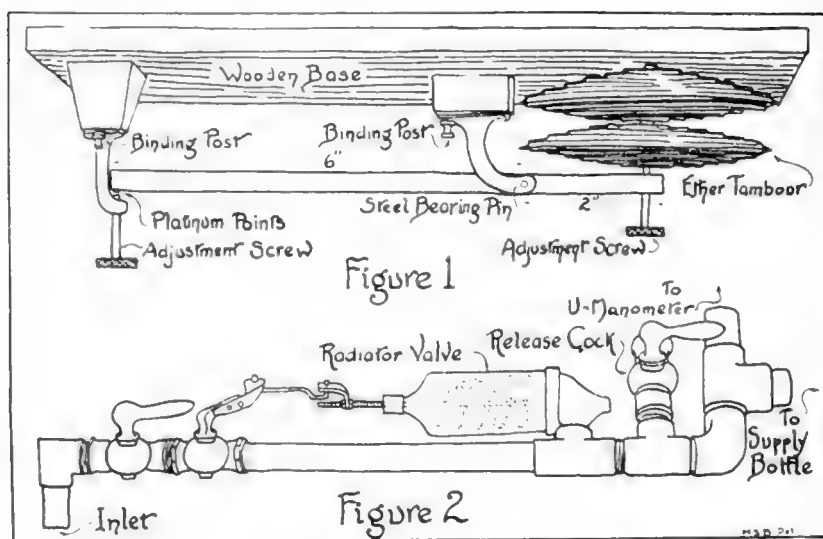
The electric thermo-regulator here described is the result of several years of sporadic experiments. The object was to design an instrument that could be readily built by any laboratory technician; that could be run on an ordinary lighting circuit without the use of a relay, condenser or other apparatus of that sort; that would be more positive and less subject to fluctuations due to jar than the mercury column; and finally that would be more accurate than a bi-metallic regulator. It is believed that this instrument fulfills many of these requirements.

The principle is simple. It consists of a walking beam actuated by an ether tambour. The expansion of the tambour forces down the reach of the walking beam so that the consequent raising of the other reach breaks the electric circuit. Figure 1 gives the details of its construction. The whole apparatus should be built of brass with the exception of the steel pin which acts as the bearing of the walking beam, and the platinum-iridium contact points which are forced under pressure into the ends of the walking beam and adjustment screw. The dimensions given may be varied to suit the convenience of the material at hand although the measurements given have been found to be the most satisfactory.

The most difficult part of the construction is the ether tambour. While it is possible to make it in a well equipped shop it will be found more satisfactory to purchase a thermostat manufactured by the Banner Incubator Company, Baraboo, Wisconsin or a Newtown thermostat manufactured by the Giant Incubator Company. A good mechanic, however, can spin a tambour provided he has a speed lathe available. The method is as follows: In the end grain of a hard wood block a series of concentric grooves and ridges of semi-circular cross section are worked. Then by fastening a sheet of thin soft brass against the wood block, the whole being fastened to the face plate of the lathe, the soft brass can be worked into the grooves. Two plates are crimped in this manner, cut into circular disks slightly larger than the diameter of the tambour and soldered gas tight over a spreader plate.

The assembled instrument should be supported upside down in the constant temperature box or room, that is to say, it should be fastened to the sidewall with the wooden base up and the instrument hanging down so that gravity will keep the long reach of the walking beam pressed against the contact adjustment screw. The expansion of the ether then depresses the short arm, raises the long arm and breaks the circuit. Two adjustments are provided so that any temperature within the range of the heating element may be maintained.

Almost any electric heating apparatus from simple batteries of carbon lights to an electric radiator may be used with complete satisfaction. Where large spaces are to be heated it will be found best to have sufficient heat on all the time to keep the temperature up to



within 5° of the required temperature, the regulator being then cut in on a circuit with a sufficient heating element to readily raise the temperature the remaining 5°.

In installing this instrument the most satisfactory result will be obtained if the box or room is thoroughly insulated from the surrounding temperature. For ordinary paraffine work in the class room or research laboratory, a tight, thick-walled wooden box serves admirably. Such an oven with inside dimensions of 12 by 12 by 18 inches is especially adapted for paraffine work since a temperature of 54° on a shelf placed just above the heating element gives a temperature on a shelf 6 inches higher that will flatten our paraffine sections and dry them. A small room may be kept at a constant temperature provided the heat elements are scattered throughout the floor of the room.

With well insulated walls any given space can be maintained at a constant temperature with less than  $0.5^{\circ}$  of variation. Little work is required to keep the apparatus in good working order; it is only necessary at intervals to clean the platinum contacts.

The author is indebted to Mr. A. E. Scharff, Laboratory Technician of the Anatomical Laboratory of the Yale School of Medicine for help and many suggestions in making this instrument.

## II. AN AUTOMATIC AIR PRESSURE VALVE

AUGUSTUS E. SCHARFF

ONE FIGURE

Those who have had to depend upon the ordinary means for applying air pressure for injecting such as a hand or water pump, recognize the difficulty of accurately regulating the pressure or maintaining known constant pressure over any length of time. The essential feature of an apparatus used in this laboratory for several years which accomplishes the above object is the automatic air pressure valve described below (fig. 2).

The valve consists of a piston working against a spring within a cylinder and connected with the lever of an air cock. The air from the reservoir, under high pressure, is led through the air cock to the rear of the cylinder and forces the piston outward, compressing the spring, which partially shuts off the supply of air through its connection with the lever of the cock.

The pressure valve was made from a steam radiator air valve. The base is unscrewed from the bowl, the parts within removed and a spring and piston inserted into the bowl. The spring is of No. 14 brass wire, coiled  $\frac{3}{4}$  inch in diameter and  $1\frac{3}{4}$  inches in length. The piston is of leather, fastened to the piston rod by a nut above and below it. The piston rod is of  $\frac{1}{4}$  inch round brass,  $3\frac{1}{2}$  inches in length, threaded for  $\frac{1}{2}$  inch at the end to which the piston is attached and for  $1\frac{1}{4}$  inches at the other end, which is fastened to the connecting rod. The vent of the air valve is enlarged to allow the piston rod free play. A connecting rod of  $\frac{3}{32}$  inch round brass,  $2\frac{3}{4}$  inches in length, with a sharp right angle bend  $\frac{1}{8}$  inch long at each end, is fastened to the piston rod by a link at one end and to the lever of the cock at the other. Both ends are burred to hold them in position. The link is made of brass,  $\frac{1}{16}$  by  $\frac{3}{8}$  by 1 inch in size, bent in the middle at an angle of  $90^{\circ}$ . A hole in one end admits the connecting rod, allowing free sideways motion. Through a hole in the other end, the piston rod is passed and clamped by a thumb nut on each side. By shifting these thumb screws along the piston rod, the distance between the piston and the lever of the air cock may be lengthened or shortened, thereby changing the tension on the spring within the valve which thus decreases or increases the pressure.

The pipe conveying the air from the reservoir to the cylinder is led to a Y tube, one branch of which leads through a low pressure reservoir (any large bottle, which acts as an air cushion on the mercury) to a U-manometer graduated to millimeters and indicating the pressure beyond the valve. The other branch of the Y tube leads to the receptacle containing the injecting fluid. As the pressure in the cylinder is reduced by the decrease in the amount of injecting fluid, the spring is released pulling on the lever of the air cock, opening it and admitting a fresh supply of air. This maintains a balance between the air pressure in the cylinder and a tension on the spring.

### III A LABORATORY TIMING CLOCK

AUGUSTUS E. SCHARFF

The device described below is of great value in measuring the length of time that pieces of tissue or slides are to be left in the different reagents. It is the experience of every laboratory worker that either his entire time must be devoted to the staining of slides or great variations in the length of time in which they remain in the different reagents are almost sure to follow divided attention. The clock as described below has been used in this laboratory for over a year and it has been found that much time may be saved in staining sections and greater accuracy in their treatment obtained from its use.

The works of an ordinary clock are removed from the case. With a number 28 drill make a hole through the face, just above the twelve o'clock mark and about  $\frac{1}{8}$  inch from the end of the minute hand. Through this hole a piece of insulated annunciator wire 6 inches in length is passed. Strip the insulation for about  $\frac{3}{4}$  inch from the end of the wire and bend the bared portion in the form of a flat loop so that the minute hand in passing will rub over it. The insulation must not be removed from that portion of the wire which passes through the hole in the clock face. Wrap the end of this wire behind the clock face, around one of the cross stays of the works and leave the end free.

Drill a hole through the shell of the clock through which the loose end of the annunciator wire may be passed. If the clock used is an alarm clock, the clapper may be removed and the wire passed out through the clapper slit. Place the works within the shell.

Fasten one wire of a 2 or 3 foot piece of double, flexible, electric light cord to the end of the annunciator wire from which the insulation has been stripped for the purpose. Wrap the union with tape. Fasten the stripped end of the other wire to any convenient portion of the clock. Fasten one wire from the other end of the flexible cord to a buzzer or bell, the other two to dry cells. Complete the circuit, interposing a simple switch so that the circuit may be broken at will.

For convenience in turning the minute hand a piece of brass tubing may be fastened to the thumb screw controlling it.

To use the clock: wind it, turn the minute hand to the desired number of minutes before the even hour that it is desired to leave the slides in the stain. Place slides in stain. Close the switch. When the time has elapsed, the minute hand connecting the contact with the wire loop will sound the buzzer, which may be stopped by opening the switch. Remove the slides from the stain and reset the clock for the next stage. In the intervals between the actual processes of setting the clock and changing the slides from one reagent to another, the mind is left free for other things.

By fastening a piece of sheet metal to the bottom of the shell of the clock so that it will project backward just behind the clock and fastening a strip of metal to the table so that the projection on the bottom of the clock may be slipped under it, the clock is rendered more stable.



## SOME SUGGESTED CHANGES IN NOMENCLATURE

MARSH PITZMAN, M.D.

*In charge of anatomical instruction, Dental Department of Washington University,  
St. Louis*

The changes in nomenclature suggested in the following notes are based on their alleged practical importance. The names objected to in my opinion tend to be a source of confusion to the student and practitioner, while the substitutes are offered as a step towards clarity and simplicity in anatomical nomenclature. All the names objected to have been accepted in the B. N. A. revision. I have not found these alleged sources of confusion commented upon in our texts, reference books or literature. Many of these notes are of such a nature that they must have been considered by others, while some may represent previously undetected errors. But any question of priority is aside from my argument, which is that our reference books should at least point out these sources of confusion. As a matter of convenience these notes will be arranged in the sequence of the B. N. A.

*Osteologia.* Instead of os ilium, os ischii, and os pubis the official names should be pars ilium (ossis coxae), pars ischium (ossis coxae) and pars pubis (ossis coxae). The practice of speaking of part of a bone as a separate bone confuses students, so that eventually they are uncertain as to what constitutes a bone.

Introduce logic into the use of the terms tuberculum, tuberositas and tuber—that is use tuberculum for small projections, tuberositas for medium sized projections and tuber for large projections. The present haphazard arrangement, as for example tuberculum humeri as contrasted with tuberositas unguicularis, is a severe tax on the memory without a compensating benefit.

The official term diploe might be dropped entirely with advantage. Students on account of the special name are bound to feel that the spongy layer of the cranium differs essentially from ordinary spongy bone.

*Syndesmologia.* It would be a great convenience to establish an official name for a group of ligaments and then designate as pars the component subdivisions, as for example:

ligamentum caraco-claviculare  
pars trapezoideum  
pars conoideum

For practical purposes the articulatio talo-cruralis is the worst offender, as no official collective name is given. My suggestion would be:

ligamentum collaterale tibiale (talo-cruralis)  
 pars tibio-naviculare  
 pars calcaneo-tibiale  
 pars talo-tibiale anterior  
 pars talo-tibiale posterior  
 ligamentum collaterale fibulare (talo-cruralis)  
 pars talo-fibulare anterior  
 pars talo-fibulare posterior  
 pars calcaneo-fibulare

*Myologia.* The term septum intermusculare is used when what is meant might be more accurately phrased as septum intergregare (musculorum)—gregare, derived from grex, a herd or group. As the suggestion is original no guarantee is offered for the correctness of the Latin. The term septum intermusculare might then be reserved for the minor partitions between the various muscles of one group.

The official term fascia superficialis might with great advantage be dropped entirely, substituting the terms tela subcutanea adiposa or panniculus adiposus throughout. Students are bound to be confused by the use of the word fascia in connection with a fatty layer, while its continuation in my opinion serves no useful purpose, but simply perpetuates the confusion of a past generation of anatomists.

Students have great difficulty in keeping clear the distinction between the ligaments, which hold down the tendons in the hand and foot regions, and the ligaments of the neighboring joints. Their protest that their name sound so much alike is in my opinion justified. I would therefore suggest that these bands be no longer called ligaments, but retaining bands—retinacula. This is already partly the custom, as in retinaculum mm. peronaeorum sup. vel. inferius.

*Splanchnologia.* The term fundus vesicae to describe what would seem to be more logically named basis vesicae might well in theory give rise to confusion. Students are bound to feel that the term fundus vesicae describes the globular upper free surface of the bladder. That even the highly trained specialist practitioners have confused the term may be noted in an article by Dr. Bransford Lewis, Journal American Medical Association, vol. 60, pp. 1765-1766. I would therefore suggest that the term fundus vesicae be discarded and that basis vesicae be substituted.

The term ductus deferens is a great improvement over vas deferens, but inasmuch as this term might be applied to the duct of any gland, in behalf of accuracy I would much prefer a specific term, as either ductus testis or ductus spermaticus.

*Angiologia.* The arteria epigastrica inferior for obvious reasons should be known as the a. hypogastrica (paries abdominis), while the a. epigastrica superior would automatically become simply the a.



epigastrica. A long established misnomer, probably carelessly named by surgeons according to the common position of the body during abdominal operations.

The arteria iliaca communis should divide into external and internal subdivisions. Granted that this not an ideal nomenclature, it is in my opinion the best that can be done and greatly superior to the present confusing arrangement.

Discontinue the use of the term plexus to describe a network of smaller vessels, substituting either rete or some other suitable term. The use of plexus to describe both a network of vessels and a weaving of nerves is both theoretically and practically wrong. The restricting of the use of the word plexus to nerves would in my opinion help not only students, but also scientists.

*Neurologia.* For the same reason as noted in the vessel discussion, discontinue the term ramus anastomaticus in connection with nerves, substituting ramus or ramulus communicans or some other suitable term.

*Diminutives.* The term glandula to describe macroscopic glands is unfortunate, as the diminutive ending keeps suggesting to the student that the gland is of sub-macroscopic size. I would like to see the term glans introduced for the macroscopic glands, retaining glandula for the glands scarcely or not visible to the unaided eye.

The word ductulus should in my opinion be substituted for ductus in connection with the terms ductus biliferi, ductus sublingualis, ductus prostatici and ductus sudoriferus.

In conclusion let me as a non-specialist in anatomy again record my enthusiasm for the practical value of the B. N. A. revision. The authors of the B. N. A. did not put out their list as an absolutely fixed and permanent thing, but specifically called for criticisms from those actually using it. I do not advocate that anyone use any of these suggested changes, but I desire to give my views publicity in order that they may receive consideration in any possible new revision. In spite of the unquestionable disadvantage of changes in nomenclature, any change which will yield an essential betterment must eventually come into its own. The knowledge that a generalist's point of view has often proven of interest and value to specialists encouraged me throughout this effort.



## ON THE DEVELOPMENT OF THE LIVER IN THE GENUS CITELLUS

CHARLES EUGENE JOHNSON

*Department of Animal Biology, University of Minnesota*

FOUR FIGURES

In a brief reference to the embryonic liver in the European ground squirrel *Citellus* (*Spermophilus*) *citellus*, Voelker ('01) states that in this animal the organ develops as two hollow outgrowths of the ventral gut wall, and from these outgrowths solid cords of cells sprout outwards to all sides. Each of the two outpocketings opens separately into the foregut. This process, he remarks, does not correspond to the accounts that have been given for other mammals.

Voelker does not state whether or not these two outgrowths are paired structures, but so far as may be judged from the figure accompanying his account—which, however, is intended for illustration of the pancreas rather than the liver and therefore does not present a favorable view of the latter organ—they represent unpaired outpocketings of the ventral gut wall, one situated caudad to and in close association with the other. If this interpretation be correct, the anterior outgrowth probably represents the *pars hepatica* and the posterior one the *pars cystica*.

In three other embryos of the same developmental stage as the specimen on which the description just given is based, he found the condition of the liver differing from that first mentioned to this extent, that the two primitive bile ducts are joined in a common diverticulum which is an outpocketing of the ventral gut wall. In a more advanced embryo (6 mm., greatest length) he found the ductus choledochus entering the gut wall on the right side, this position having been brought about by the rotation of the digestive tube.

Janöšik (1955), in his study of the development of the pancreas in the same species, examined embryos ranging in length from 6 mm. to 35 mm. He refers to the condition of the liver only in the youngest of these embryos and here he finds that it is composed of two canals, one directed toward the left, the other toward the right.

From Janöšik's meager description it is not possible to know whether these two canals represent the developing liver in its entirety, that is, both hepatic and cystic portions, or, as seems more probable, the hepatic portion alone.

Although Voelker gives no measurements for the youngest embryo examined by him, it is clear from the appearance of the liver and the pancreas as shown in his illustration that it represents a considerably earlier stage than the one Janöšik describes for his 6 mm. embryo; also, the condition described in Voelker's more advanced specimens, up to and including the 6 mm. embryo, does not agree with the statement for the 6 mm. embryo in Janöšik's series. It is therefore doubtful that the two canals noted by Janöšik correspond to the two hollow outgrowths observed by Voelker.

A study of a series of embryos of the American ground squirrels *Citellus tridecemlineatus* and *C. franklinii*, ranging from 1.5 mm. to 6 mm. in length, shows that in these members of the Genus at least the development of the liver is not essentially different from that observed in other mammals. The results of this study may be briefly summarized as follows.

#### CITELLUS TRIDECEMLINEATUS

The earliest stage in my series in which the hepatic anlage is present is a 1.5 mm. specimen. In this embryo the anlage is a thickened area in the ventral wall of the foregut, just in front of the yolk stalk, continuing laterally a short distance onto the side walls of the digestive tube. The lateral extent of the anlage is greater than the antero-posterior extent, the area representing a transverse rather than a longitudinal thickening in the wall of the foregut.

In embryos between 1.5 mm. and 2 mm. in length the hepatic thickening becomes a distinct outpouching of the gut wall. This outpouching is triangular in shape, being broadest in its posterior portion bordering the yolk stalk and from here becoming narrower toward its anterior end. It is relatively large and in these and slightly more advanced stages is decidedly asymmetrical with respect to right and left, caused by the indentation of its right antero-ventral wall by the ventricular loop of the heart. In surface view the pouch presents three lobe-like divisions, a right and a left posterior lateral lobe separated by the indented area, and an anterior median lobe lying in the angle formed by the vitello-umbilical trunks as they converge to enter the sinus venosus.

Variations in the form of the hepatic pouch occur, depending apparently upon the variable mechanical effect of the developing vitelline veins and vitello-umbilical trunks, the septum transversum and especially the heart.

In embryos about 2.5 mm. in length the hepatic anlage reaches its maximum development as a smooth-walled outpouching of the foregut wall. It is now a large, approximately symmetrical, more or less spindle-shaped pouch situated transversely upon the ventral wall of the foregut with which it is connected by a short hollow stalk. The enclosed cavity conforms to the general external shape of the pouch but its size is much reduced by the increased thickening of the enclosing walls and in the extreme lateral portions of the diverticulum it has been entirely occluded.

Trabeculae make their appearance on the surface of the hepatic pouch in embryos but slightly older than the preceding and in specimens about 3.5 mm. long the walls of the diverticulum have in large part been transformed into such sprouts.

The hepatic outgrowth in embryos up to about 2.5 mm. or 3 mm. long represents the primary hepatic diverticulum or *pars hepatica* only. But now there appears a thickening in the floor of the foregut caudal to but continuous with the primary outgrowth, and this constitutes the *pars cystica*. In embryos about 3 mm. or 3.5 mm. long the *pars cystica* has become a distinct evagination from the gut wall, occupying the angle between the *pars hepatica* and the yolk stalk.

The thickened area forming the anlage of the pars cystica is from the first continuous anteriorly with the pars hepatica and therefore is not a separate area but rather a caudal extension of that thickened portion of the tube which already has given rise to the pars hepatica, appearing later than the pars hepatica for the reason that the part of the gut floor concerned with its formation is of later development than the part in front of it which gives rise to the hepatic portion proper.

In embryos of 3.5 mm. to 4 mm. a further outpushing of the pars cystica from the digestive tube has resulted in the formation of the ductus choledochus, which is a short broad tube into which the pars hepatica and pars cystica now open by wide channels representing the hepatic and cystic ducts respectively, and through which these ducts communicate with the digestive tube. To the ductus choledochus as now constituted the pars hepatica contributes the anterior and the smaller part of the lateral walls while the pars cystica contributes the greater part of the lateral and all of the posterior wall.

The distal portion of the pars cystica is at this period distinctly marked off as the gall bladder.

In embryos about 5 mm. in length the ductus choledochus has been constricted into a tube whose diameter is about one-half that of the 4 mm. stage; the gall bladder is about double its former size, is smooth-walled, of globular form and has a sharply defined cavity the diameter of which is slightly less than the thickness of its wall.

At the junction of the ductus choledochus with the hepatic and cystic ducts there is a bladder-like dilatation about two-thirds the size of the gall bladder. This is a conspicuous structure in each of three 5 mm. specimens in my series and appears to be a point of detail which does not occur in connection with the bile ducts in the second of the two species here concerned.

#### CITELLUS FRANKLINI

The early development of the liver in this species agrees in its main features with that of *Citellus tridecemlineatus*. The chief points of difference are in size and form. In *Citellus*

*franklinii* the organ is a much less voluminous structure and the pouch-like outgrowth, in contrast with that of the first described species, is from its first appearance quite symmetrical and more evenly expanded, being on account of its much smaller size modified only to a slight extent by encroachment of the heart and other neighboring structures.

No trace of a ventral pancreas was found in any of the stages of the two species examined. The entire absence of a ventral-pancreas in the European ground squirrel has been reported by Voelker and Janöšik.

In a 6 mm. embryo the gall bladder and biliary ducts correspond closely to the condition in the 5 mm. embryos of *C. tridecemlineatus*, except that the bladder-like dilatation associated with the bile tubes of that species is here lacking.

#### BIBLIOGRAPHY

- BRACHET, A. 1895 Recherches sur le développement du diaphragme et du foie chez le lapin. Journ. de l'Anat. et de la Physiol., T. 31.  
1896 Recherches sur le développement du pancréas et du foie (Sé-laciens, Reptiles, Mammifères). Journ. de l'Anat. et de la Physiol., T. 32.
- BRADLEY, O. CHARNOCK 1908 A contribution to the morphology and development of the mammalian liver. Journ. of Anat. and Physiol., vol. 43, London.
- CHORONSHITSKY, B. 1909 Die Entstehung der Milz, Leber, Gallenblase, Bauchspeicheldrüse und des Pfortadersystems bei den verschiedenen Abtheilungen der Wirbelthiere. Anat. Hefte, Bd. 13.
- DEBEYRE, A. 1910 Le foie, est-il d'origine endodermique ou mésodermique. Bibliogr. anat., T. 19.
- FELIX, W. 1892 Zur Leber und Pankreasentwicklung. Arch. f. Anat. u. Physiol. Anat. Abth.
- HAMMAR, J. AUG. 1893 Einige Plattenmodelle zur Beleuchtung der früheren embryonalen Leberentwicklung. Arch. f. Anat. u. Entw.  
1897 Ueber einige Hauptzüge der ersten embryonalen Leberentwicklung. Anat. Anz., Bd. 13.
- HILTON, W. A. 1901 Early morphogenesis and histogenesis of the liver in *Sus scrofa domestica*. Studies of the Zool. Lab., Univ. of Nebr., No. 53.
- JANÖSIK, J. 1895 Le pancréas et la rate. Bibliogr. Anat., T. 3.
- LEWIS, F. T. 1911 Die Entwicklung der Leber. Handbuch der Entwicklungsgeschichte des Menschen. Keibel u. Mall.
- MINOT, C. S. 1910 Laboratory text-book of embryology. Blakiston's Son and Co., Philadelphia.
- PRENTISS, C. W. 1915 Text-book of embryology. W. B. Saunders Co., Philadelphia.

- SWAEN, A. 1896 Recherches sur le développement du foie, du tube digestif, de l'arrière-cavité du péritoine et du mésentère. Journ. de l'Anat. et de la Physiol., T. 32.
- THOMPSON, P. 1908 A note on the development of the septum transversum and the liver. Journ. of Anat. and Physiol., vol. 42. London.
- VOELKER, Dr. 1901 Beiträge zur Entwicklung der Pankreas bei den Amnioten. Arch. f. Mikr. Anat., Bd. 59.

## PLATE 1

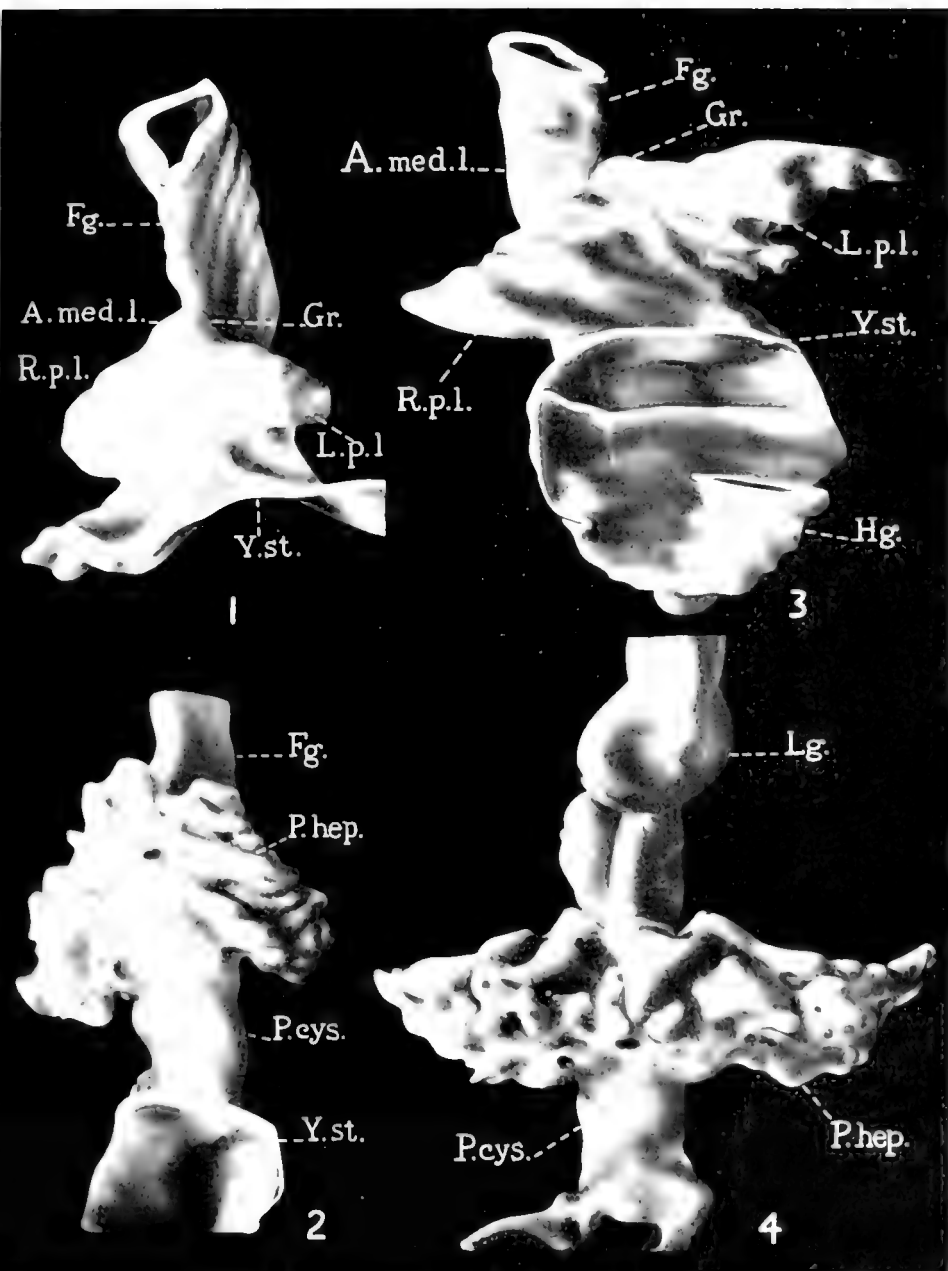
## EXPLANATION OF FIGURES

- 1 Antero-ventral view of a reconstruction of the primary hepatic diverticulum of an embryo *Citellus franklinii* 2 mm. long.  $\times 150$ .
- 2 Ventral view of a reconstruction of the liver of an embryo *Citellus franklinii* 3 mm. long.  $\times 150$ .
- 3 Ventral view of a reconstruction of the primary hepatic diverticulum and a portion of the archenteron of an embryo *Citellus tridecemlineatus* 2.5 mm. long.  $\times 150$ .
- 4 Antero-ventral view of a reconstruction of the liver and a portion of the foregut of an embryo *Citellus tridecemlineatus* 3.1 mm. long.  $\times 150$ .

## ABBREVIATIONS

- |  |  |
|--|--|
| <i>A. med. l.</i> , anterior median lobe-like division                             | <i>Lg.</i> , lungs   |
| <i>Fg.</i> , foregut   | <i>L.p.l.</i> , <i>R.p.l.</i> , left and right posterior lobe-like divisions |
| <i>Gr.</i> , anterior constriction-groove between hepatic diverticulum and foregut | <i>P.cys.</i> , pars cystica   |
| <i>Hg.</i> , hindgut   | <i>P.hep.</i> , pars hepatica  |
|  | <i>Y.st.</i> , yolk-stalk  |
|  | H. A. Sanborn, artist  |







## A NOTE ON THE ANASTOMOSIS OF ARTERIES AND VEINS IN A CAT

NEWTON MILLER AND JAMES S. GODFREY

*University of Utah*

ONE FIGURE

In the spring of 1916 a number of cats were brought into the zoological laboratory for dissection. Among this number was one which showed a very unusual degree of anastomosing of arteries and veins.

A carmine starch mass was injected into one of the carotids with the result that it passed over into some of the veins, especially those of the hind legs and those of the posterior abdominal region. Since starch grains do not pass through the capillaries, it was evident that direct union between arteries and veins were present.

Examination showed one large connection between the caudal artery and common iliac vein which permitted the filling of the post-cava. In addition four others were found in the branches of the internal iliaes; seven in the branches of the femorals; three in the branches of the iliolumbars; two between the adrenolumbars; one between the intercostals which allowed the azygos to fill, and five between the branches of the right subclavian artery and vein. This is a total of twenty-three, besides there were evidences of others which we were unable to locate.

These connecting vessels were between 0.2 mm. and 0.5 mm. in diameter in all cases except that between the caudal artery and common iliac vein, in which case the vessel was more than a millimeter in diameter. The lengths varied between 1 mm. and 4 mm.

We examined the mother and two sisters of the specimen but found no trace of anastomosing in any of them. Other members of the family are under observation and these with their offspring will be examined in due time. The specimen was about nine months old when killed and appeared to be in good condition, with the exception that its hair never laid down smooth and sleek.

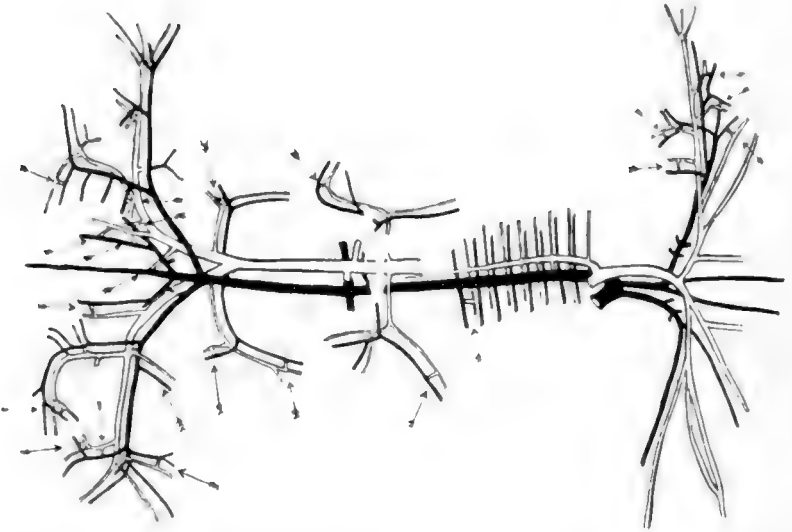


Fig. 1. Arteries are indicated in solid lines. Veins are shown in outline. The arrows indicate the anastomoses.

# THE ANATOMY OF A TWO-HEADED LAMB

ALBERT M. REESE

*West Virginia University, Morgantown, West Virginia*

EIGHT FIGURES

This lamb was born on March 24, 1916, at Bingamon Creek, W. Va., of a three-year-old Southdown ewe which is still alive. It was sent to the writer by Mr. C. O. Reed, taxidermist, of Fairmont, W. Va. According to Mr. Reed the lamb fed with both mouths, and seemed perfectly well up to the evening of June 6, 1916, but was found dead the next day. It was exhibited at various places under the name of 'Betty,' the posters announcing that "This Wonder Freak Feeds From Either Mouth, Hears From Four Ears, And Sees From Four Eyes." The animal, it will be seen, lived for about ten and one-half weeks.

When received the lamb had been skinned and all four legs had been cut off close to the body. In removing the skin so many of the muscles of the neck had been removed or torn that it did not seem worth while to make a study of this feature of the anatomy. Some of the superficial blood vessels and glands were also injured, as will be noted below, by the careless skinning. Since Mr. Reed especially requested the return to him of the skeleton, it was not possible to make a study of the nervous system.

Figure 1 is a photograph of a ventro-lateral view of the anterior region of the animal. The heads are of about the same size, and are joined in the anterior cervical region. They are so close together that the adjacent ears (they were all, of course, removed with the skin) must have been closely crowded together. With the exception, perhaps, of a slight loss of bilateral symmetry there is nothing unusual in the appearance of the thorax, unless it be a rather unusual depth in a dorso-ventral direction.

A dorso-lateral view of the animal shows a bifurcated ligamentum nuchae, the division taking place in the anterior third of the cervical region; otherwise there is no more unusual appearance than would be expected in such a monster.

Figure 2 shows the heart, and the glands of the neck and thorax, as seen in a ventro-lateral view, after the removal of the ventral and lateral portions of the wall of the thorax and the remains of the superficial muscles of the neck.

#### ABBREVIATIONS

<i>a</i> , outline of the thorax before its removal	<i>lle</i> , left carotid artery of left head
<i>aol</i> , left aortic arch	<i>lrc</i> , right carotid artery of left head
<i>aor</i> , right aortic arch	<i>lu</i> , lung
<i>ar</i> , articular surface for atlas	<i>mv</i> , mitral valve of right heart
<i>at</i> , atlas	<i>mv'</i> , mitral valve of left heart
<i>au</i> , auricles	<i>o, o'</i> , abnormal openings between cavities of the hearts
<i>ax</i> , axis	<i>p, p'</i> , parotid glands
<i>ax'</i> , extra bone of axis	<i>pl</i> , left pulmonary artery
<i>ca</i> , left precava	<i>pr</i> , right pulmonary artery
<i>ca'</i> , right precava	<i>plv</i> , left pulmonary vein
<i>cp</i> , postcava	<i>prv</i> , right pulmonary vein
<i>cr<sup>3</sup></i> , third cervical vertebra	<i>r</i> , third rib
<i>cr<sup>7</sup></i> , seventh cervical vertebra	<i>rle</i> , left common carotid of right head
<i>dao</i> , dorsal aorta	<i>rre</i> , right common carotid of right head
<i>dbl</i> , left ductus Botalli	<i>scl</i> , left supernumerary carotid
<i>dbr</i> , right ductus Botalli	<i>scr</i> , right supernumerary carotid
<i>e</i> , external auditory meatus	<i>sl</i> , left subclavian artery
<i>f</i> , auricle-like lobe of lung	<i>sr</i> , right subclavian artery
<i>fa</i> , atlantal foramen	<i>sm, sm'</i> , submaxillary glands
<i>ft</i> , foramen transversarium	<i>scl</i> , left subclavian vein
<i>il</i> , left brachiocephalic artery	<i>srv</i> , right subclavian vein
<i>ir</i> , right brachiocephalic artery	<i>t, t'</i> , left and right thymus masses
<i>jef</i> , fused external jugulars	<i>ta, ta'</i> , tracheae
<i>jif</i> , fused internal jugulars	<i>tl, tl'</i> , thymus of left neck
<i>jel</i> , left external jugular veins	<i>tr</i> , thymus of right neck
<i>jil</i> , left internal jugular veins	<i>tr<sup>2</sup></i> , second thoracic vertebra
<i>jer</i> , right external jugular veins	<i>ty, ty'</i> , thyroid glands
<i>jir</i> , right internal jugular veins	<i>v</i> , ventricles
<i>jf</i> , fused jugulars	<i>va</i> , vertebral artery
<i>l</i> , various lobes of the lungs	<i>rv</i> , vertebral vein
<i>la, la'</i> , larynx of left and of right heads	<i>x</i> , narrow interauricular septum
<i>lg</i> , lymph gland	<i>z, z'</i> , left and right azygos veins

The enormous heart, with its two apices,  $r$  and  $r'$ , and its pericardium intact, is shown nearly filling the thoracic cavity; it will be described later.

The *thymus gland* begins as two large, white masses of lobulated material,  $t, t'$ , at the anterior border of the heart. These two masses are of approximately the same size, the apparent

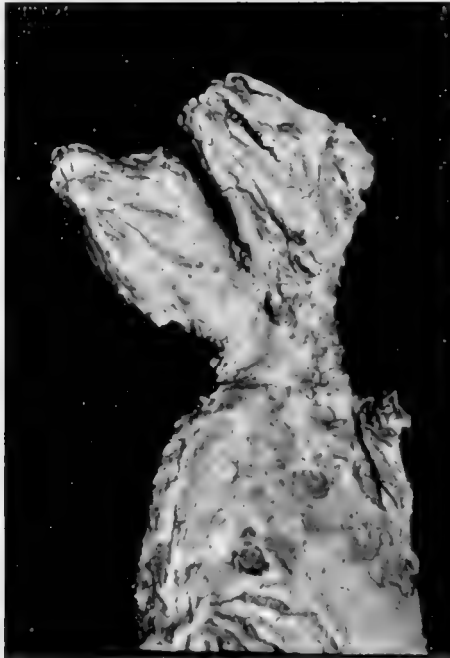

Fig. 1 A ventro-lateral view of the two-headed lamb in the condition in which it was received.

difference in size, as seen in figure 2, being due to the fact that the one on the animal's right side is seen in profile. After extending cephalad for about 5 cm, they pass out of the thorax (whose original anterior limits are indicated by the curved, broken line,  $a$ ) and lie on the ventral surface of the neck.

A short distance cephalad to the thorax the left thymus mass,  $t$ , divides into two smaller, elongated masses,  $tl, tl'$ , which lie close on either side of the trachea,  $ta$ , and extend forwards to the

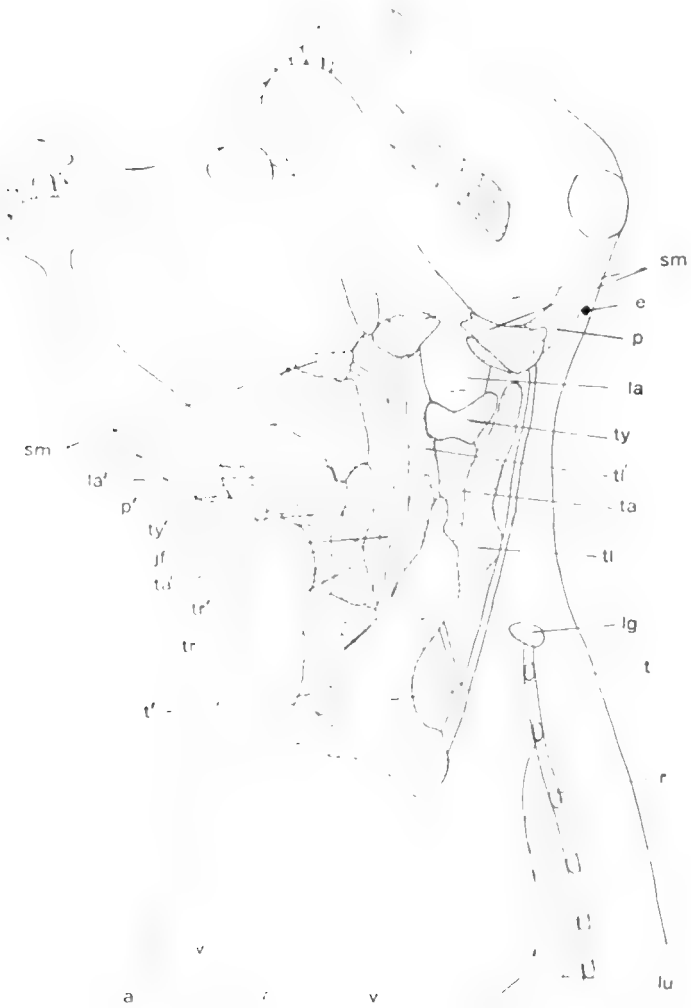

Fig. 2. A ventro-lateral view of the lamb after the removal of the ventral wall of the thorax and the superficial muscles of the neck, to show the glands of the neck and the heart in its pericardium.



angles of the jaws, where they lie, at least on the right side, beneath the submaxillary glands. These two anterior prolongations are of the same character as the main mass, but are separated from it by deep furrows.

The right thymus body, *t'*, divides in the same way anterior to the thorax, into two masses, *tr*, *tr'*, but the mass on the right, *tr'*, was almost entirely torn away in removing the skin, so that its size could not be determined; in any case but little of it would show in this view of the animal. The left mass, *tr*, is very large and extends forwards to the corresponding angle of the mandible, where it disappears beneath the submaxillary gland of that side.

Lying between the thymus masses, *tl* and *tr*, are seen the fused external jugular veins of the adjacent sides of the two necks, *jj*.

The thyroid glands, *ty*, *ty'*, are dark-colored, unsymmetrical bodies, about 2 cm. in longest diameter, lying around the ventral wall of each trachea, *ta*, *ta'*, just caudad to its larynx, *la*, *la'*. The two glands are of approximately the same size and shape, and do not have the two lobes and connecting isthmus characteristic of this gland. Whether this irregularly saddle-shaped mass represents a fusion of two lobes or merely one enlarged single lobe it is difficult to say. The greater part of each gland lies on the left side of its trachea.

The salivary glands. The submaxillary glands, *sm*, *sm'*, are seen as lobulated masses, about 2.5 cm. in longest diameter, lying at the angle of each jaw. The gland of the left side of the right head was badly torn, so that its exact outline could not be determined, but it was apparently of about the same size and form as the other three.

The parotid glands, *p*, *p'*, were all torn off in skinning except the right gland of the right head, the ventral end of which is shown at *p'*. This gland is about 3.5 cm. in length and is of a crescentic shape. It extends from just cephalad to the external auditory meatus to the angle of the jaw, where it partly overlies the submaxillary gland. On the left side of the left head a depression, *p*, in the muscles between the external auditory meatus, *e*, and the submaxillary gland, *sm*, indicates the former

position of the parotid gland of that side. So far as could be determined the parotids were all normal.

The *sublinguals* are apparently normal, as might be expected from the character of the mandibles and tongues, and are not indicated in figure 2.

A large lymph gland, *lg*, is shown at the base of the neck on the left side.

*The exterior of the heart and the main blood vessels*

Figure 3 represents a ventral view of the anterior end of the animal after removal of the ventral thoracic wall, the pericardial membrane, the superficial muscles of the neck, and the thymus glands. The veins and the pulmonary arteries are stippled; the other arteries are shown in outline.

*The heart.* At first glance, from this view, the hearts seem quite distinct, though closely pressed together; just how closely they really are united will be described later.

The two left ventricles are seen at *v, v'*; the two right ventricles, of which that of the right heart is much the smaller, are seen at *v''* and *v'''*. A distinct groove in each heart indicates the line of division of the right and left ventricles. Covering the base of the right ventricle of the right heart, *v'''*, and the origin of the right pulmonary artery is a large fold of tissue, *f*, that has the appearance of an auricle but is, in reality, a small, median lobe of the lung, to be described later.

From each left ventricle arises a large aortic arch, *aol, aor*, that from the left heart being apparently the main one; it is about 15 mm. in diameter. This left arch bends around in the usual manner to the left and extends, apparently, as the single dorsal aorta down the animal's back.

The right aortic arch, *aor*, also curves to the left in the usual manner but empties, apparently, into the left arch, dorsal to and between the left subclavian and brachio-cephalic arteries.

Connecting each aortic arch with its corresponding pulmonary artery is a ductus Botalli, *dbl, dbr*; that of the left heart is apparently completely closed, that of the right heart has a wide lumen.

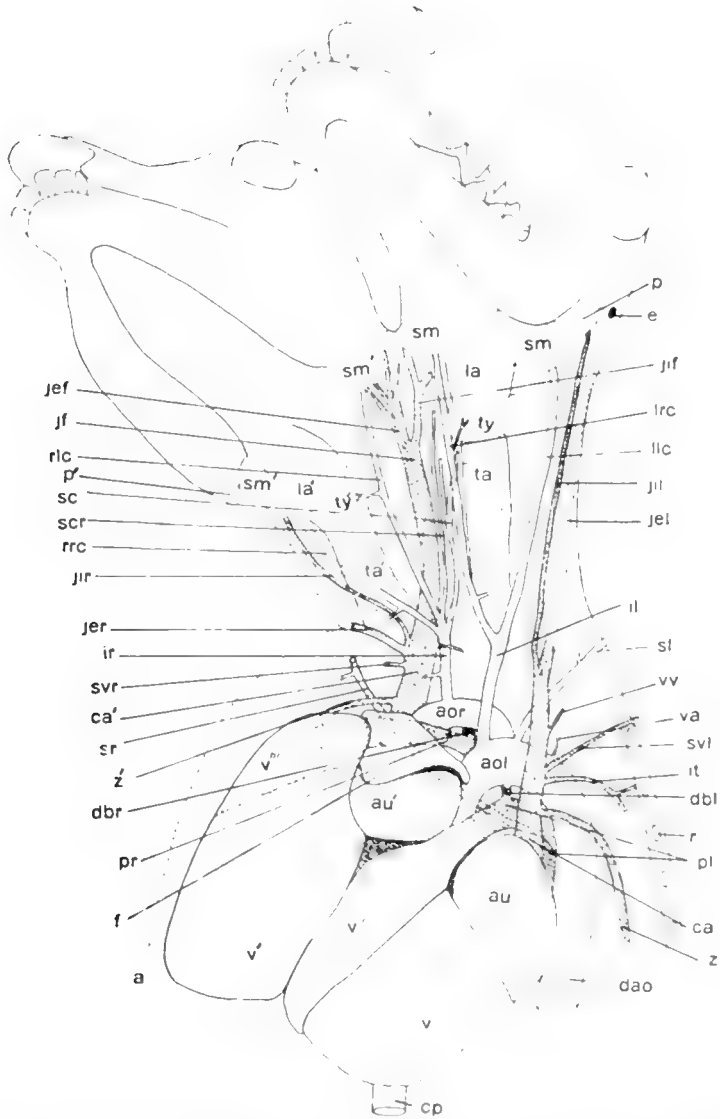


Fig. 3 A ventro-lateral view of the lamb after removal of the superficial muscles and the glands of the neck, to show the double heart and the chief blood vessels.

The branches of the left aortic arch will first be described, then those of the right arch. The first branch to leave this arch, after the coronary which leaves just above the semilunar valve, is the large innominate or brachio-cephalic, *il*; it extends directly cephalad for about 3 cm. along the ventral wall of the left trachea, *ta*, and then divides into two equal branches, the common carotids, *lc*, *rc*, which extend cephalad on either side of the trachea to disappear beneath (in a ventral view) the submaxillary glands of each side. A few branches are given off the common carotids to the thymus and thyroid glands.

A little more than a centimeter to the left of the origin of the brachio cephalic the left aortic arch gives off a vessel of about half the diameter of the brachiocephalic; this is the left subclavian, *sl*. It extends cephalad for a couple of centimeters, in a course nearly parallel to the brachiocephalic, until it passes out of the thorax. In removing the legs this vessel was of course cut, so that it could not be traced further.

Just dorsal to the origin of the left subclavian a small vertebral artery, *va*, takes its origin and passes dorsad to the base of the neck.

About 3 cm. beyond the origin of the left subclavian, from about the point where the left aortic arch straightens out to form the dorsal aorta (as it appears in this view), arises the right subclavian artery, *sr*. From this curious point of origin it extends diagonally forward, dorsal to the anterior end of the heart, and leaves the anterior end of the thoracic cavity on the right side, opposite the point of emergence of the left subclavian. Thus the right aortic arch gives rise to no subclavian artery at all.

The right aortic arch, *aor*, gives rise to but one branch, the right brachiocephalic, *ir*; this branch originates about half way between the base of the right heart and the point of union of the two aortic arches mentioned above; it passes cephalad for a little over 2 cm. along the ventral side of the left trachea, giving off one or two branches to the thymus, and then divides into two large and two small branches. The larger branches, *rlc* and *rrc*, are the left and right common carotids of the right head; they

extend cephalad on either side of the trachea, as did the corresponding arteries of the left head, and disappear behind the corresponding submaxillary glands, giving off a few branches to the thymus and thyroid glands. The two smaller branches of the brachiocephalic have, for a better name, been called the left and right supernumerary carotids, *sel* and *scr*; they extend cephalad, about half way between the two tracheae, the left branch dividing at about the middle of its course into two equal parts. The right supernumerary carotid enters an intervertebral foramen close to the bases of the two skulls; the two branches of the left supernumerary carotid enter two intervertebral foramina about 1 cm. caudad to the foramen into which the right branch entered.

The pulmonary arteries need little description. Each arises from its right ventricle in the usual manner and bends to the left to disappear beneath (dorsal to) the heart. They are of about the same calibre, though as seen in the figure the left pulmonary, *pl*, seems larger than the right, *pr*. Their further course will be described in connection with the dorsal view of the heart. Each is connected with its corresponding aortic arch by a ductus Botalli, as described above.

*The veins.* The postcaval vein, *cp*, is seen in figure 3 emerging from beneath (dorsal to) the apex of the left ventricle of the left heart; it will be described when the dorsal aspect of the heart is considered.

The two precavae will now be described. The precava of the left heart, *ca*, as seen in figure 3, emerges from beneath the left auricle and passes cephalad across the pulmonary and aortic arches into the neck to the left of the left trachea. A couple of centimeters after its emergence it receives a fairly large azygos, *z*, that curves to the left and passes caudad along the left side of the dorsal aorta and back bone, receiving the usual intercostal tributaries.

Just cephalad to the point of entry of the azygos this precava receives two veins of about the same size as the azygos: one coming from the anterior wall of the thorax, *il*, may be the internal thoracic; the more anterior one, *sel*, though cut when the

foreleg was removed, is apparently the brachial or subclavian. About 1 cm. anterior to the last vein a small vein empties into the dorsal side of the precava; it is the vertebral vein, *w*. A couple of centimeters cephalad to the vertebral the precava is formed by the union of the left external jugular, *jel*, and left internal jugular, *jil*. The former is the larger, and as it was nearly all removed in skinning the animal its probable course is indicated by dotted lines. The internal jugular follow closely the course of the corresponding common carotid artery, *lc*, described above, and the vagus nerve.

The precava of the right heart, *ca'*, is of much larger diameter than that of the left heart. It receives just cephalad to the heart a large azygos, *z'*, which is, in turn, made up of two branches, one from the right side of the vertebral column, the other from the mid-ventral line of that structure.

About 1.5 cm. cephalad to the azygos the precava receives the rather small right brachial or subclavian, *sr*, which had been cut, a short distance from its base, when its corresponding leg was removed. No vessels corresponding to the internal thoracic and vertebral can be seen on this side.

A short distance cephalad to the subclavian the precava receives from the right the large external jugular, *jer*, most of which had been removed with the skin. Just cephalad to this vein is the right internal jugular, *jir*, a much smaller vessel that follows along the right side of the right trachea, along with the corresponding carotid artery.

Opposite to these jugulars the precava receives two or three veins, on its median side, from the thymus gland. Cephalad to the above veins the precava may be followed as a very large vein, lying between the two tracheae; this vein has been called the 'fused jugulars,' *jf*. About opposite the thyroid of the left neck it divides into two vessels, *jef* and *jif*, the 'fused external jugular' and the 'fused internal jugular,' the former divides into four vessels, two passing beneath the left submaxillary gland of the right head, two passing, probably, to the skin and muscles between the two heads, though this could not be accurately determined because of the removal of the skin and super-

facial muscles of this region. The fused internal jugular divides into two vessels, one of which may be followed to the base of each skull, where it is lost, probably passing through a foramen into the skull.

*Dorsal view of the heart*

Figure 4 represents a dorsal view of the heart, with the stumps or openings of all the blood vessels. The left ventricle of the right heart is seen at  $v'$ , and above it is seen the edge of

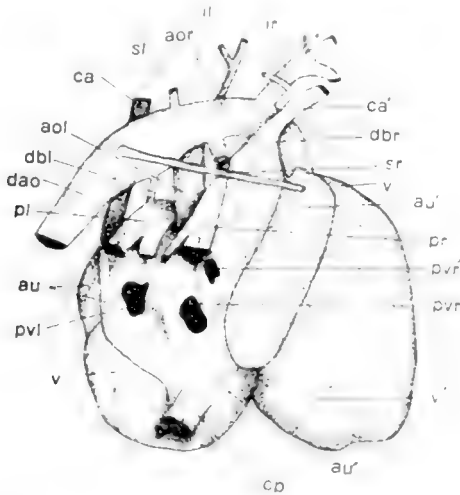


Fig. 4. A dorsal view of the double heart of the lamb, with the roots of the main blood vessels.

the right ventricle of that heart,  $v''$ ; there is no external line of demarcation between them.

The left ventricle of the left heart is seen at  $v$ ; the right ventricle of this heart does not show in this view.

The septa of the hearts are so abnormal that it is difficult to name the auricles as either right or left. On the extreme left is the left auricle,  $au$ , of the left heart; this is distinctly a left auricle since it opens into the corresponding left ventricle, and receives the large pulmonary vein,  $pl$ , from the left side of the lungs, but it is connected by a small though distinct opening

with the auricle on its right; it is seen at *au* in the ventral view of the heart, figure 3.

In the median region of the combined hearts is a large, indefinite chamber, *au'*, into which open not only the two right pulmonary veins, *pr* and *pr'*, but also the right and left precavae, *ca'* and *ca*, and the postcava, *cp*. The 'fusion auricle' is seen also in the ventral view of the heart, figure 3, *au'*. It is only partially separated, internally, from another large auricle, *au''*, which, in turn, is connected with the right ventricles of both hearts and with the left ventricle of the right heart. It is thus impossible to say whether these two auricles are right or left. The internal features will be described in more detail later. The veins entering the hearts will now be noted briefly. The left pulmonary vein, *pl*, is seen as a large opening in the left auricle of the left heart. The two right pulmonary veins enter the fusion auricle at *pr* and *pr'*; the posterior one being the larger.

Entering the fusion auricles, as above noted, is the single though partially divided trunk of the postcava, *cp*. A septum divides the trunk into two unequal parts which enter the fusion auricles at the same place.

The left precava, *ca*, extends diagonally across the dorsal surface of the auricles and empties into the fusion auricles just anterior to the opening of the postcava.

The right precava, *ca'*, which is larger than the left, is seen as a prominent longitudinal swelling extending along the median region of the combined hearts to open into the right side of the fused auricles.

The arteries leaving the heart will need but little description in addition to what was given in connection with figure 3.

In the ventral view, as noted above, the left aortic arch, *aol*, appears to form the dorsal aorta, with the right arch, *aor*, emptying into its anterior border. In the present figure the right arch seems to be continued as the dorsal aorta, *dao*, with the left arch, *aol*, emptying into its posterior border.

From the right arch arises the large brachiocephalic artery, *ir*, and from the left arch the left artery of the same name, *il*.



From the aorta at the point of union of the two arches arises the left subclavian artery, *sl*, and from the aorta, caudad to this point, arises the curious right subclavian, *sr*, that passes straight across the anterior region of the heart to the right side.

The left pulmonary artery, *pl*, is seen emerging from the ventral side of the heart between the left precava, *ca*, and the left aortic arch, *aol*: it divides into approximately equal parts that lead, as said above, to the left lobes of the lungs. The right pulmonary artery, *pr*, emerges from between the left aortic arch *aol*, and the right precava, *ca'*: it divides into a small left and a larger right branch that lead to the middle and left lobes of the lungs.

The small left ligamentum Botalli, *dbl*, and a larger ductus Botalli, *dbr*, are seen leading from the left and right pulmonary arteries to the corresponding aortic arches.

#### *Internal structure of the heart*

The cavities of the two hearts are so abnormally connected with each other that it is surprising that 'Betty' lived as long as she did.

The right ventricle of the right heart, figure 5, *v'''*, is not only connected with its pulmonary artery, *pr*, but has a fairly large opening, *o*, into the left ventricle, *v'*, of that heart; it is not directly connected with an auricle.

The left ventricle, *v'*, of the right heart besides the opening just mentioned, and its aortic outlet, opens by a wide aperture into the auricles *au'*, *au''*; this auricular-ventricular opening is guarded by a very well-developed set of mitral valves, *mv*.

The right ventricle of the left heart, *v''*, besides its opening into its proper pulmonary artery, *pl*, is connected with the auricle *au'* by a wide aperture with poorly developed tricuspid valves.

The left ventricle, *v*, of the left heart has well developed semilunar valves at its opening into the left aortic arch, *aol*, and equally well developed mitral valves, *mv'*, between it and the auricle *au*.

It is in the auricles that the greatest abnormalities occur. The left auricle, *au*, of the left heart approaches more nearly the normal than any of the others. Its appendage is shown at *au* in figure 3. This auricle receives the left pulmonary vein, *pl*, and opens, as noted above, into its corresponding left ventricle, *v*. It has also a small opening or foramen ovale, *o'*, into the large auricle to the right, *au'*.

The auricles *au'* and *au''* are so little separated from each other by a small fold of skin, *x*, that they form practically one




Fig. 5. A semidiagrammatic outline of the double heart as seen from the dorsal side, to show, by means of arrows, the course of the blood through the various auricles and ventricles.

large, irregular chamber that seems to represent three auricles. Into the half of this fused auricle to the left of the septum open the following vessels and chambers; the left precava, *ca*; the two right pulmonary veins, *pvr*, *pvr'*; the auricle *au*, through the foramen *o'*; the right ventricle, *v''*, of the left heart; and the postcaval vein, *cp*.

Into the half of the fused auricle to the right of the septum, *x*, which half forms a broad band diagonally across the dorsal side of the hearts, opens the right precava, *ca'*.

As has been said, the left ventricle, *v'*, of the right heart opens by a wide auricular-ventricular aperture into the common

chamber of the fused auricles, *au'*, *au''*, below the edge of the septum *x*. The fused auricles open widely into the auricular appendage, *au'*, seen on the ventral view of the heart, figure 3.

### *The respiratory system*

The left and right larynges, *la*, *la'*, figure 6, and tracheae, *ta*, *ta'*, have already been noted, and since they are distinct from each other, and show no unusual features, they need not be described. The trachea gradually converge towards the lungs, into which they enter by distinct but closely adjacent openings.

The lungs are not so nearly double as are the two hearts above described. The right lung, as a whole, is larger than the left.

The diaphragmatic lobes, *l*, differ but little from those of a normal sheep. The apical lobes, *l'*, are remarkable mainly for the long lobules that extend cephalad; that of the right side is the larger and is shown, in the figure, bent down and behind the rest of the lung; that of the left side, shown extending cephalad between the two tracheae, is the lobule that is shown at *f* on the ventral view of the heart, figure 3.

The mediastinal and cardiac lobes are so broken up into lobules that it is difficult to differentiate them, but it seems likely that the lobes, *l<sup>2</sup>*, *l<sup>2</sup>*, represent the two cardiac lobes, while the three small lobes, *l<sup>3</sup>*, represent the mediastinal lobes divided into three lobules.

In a dorsal or a lateral view the lungs have almost the normal appearance except for the cephalic prolongations of the apical lobes.

The tracheae enter the lungs at the anterior margin, and are, at this point, about 1.5 cm. apart.

At the base of the right trachea the two branches of the right pulmonary artery, *pr*, enter the lungs. Of these two branches the right is the larger and is distributed mainly to the right lobes of the lung; the left and smaller branch goes mainly to the central lobes of the lungs. At the base of the left trachea the

two branches of the left pulmonary artery, *pl*, enter the lungs. Of these the left is slightly the larger; both of these branches are distributed to the left lobes of the lungs.

Leaving the lungs from the region between the left and central lobes is the largest of the pulmonary veins, *pvl*, which enters the left auricle of the left heart (fig. 5). About 0.5 cm. to the right of this vein is another large vein, *pvr* (lower line), which leaves

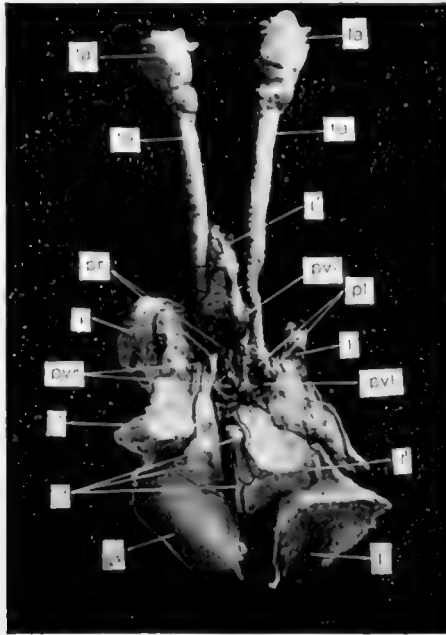


Fig. 6 A photograph of the respiratory organs of the lamb as seen from the ventral side.

the middle lobes of the lungs and enters the left auricle of the right heart (fig. 5). About 1 cm. to the right of this vein, and somewhat cephalad to it, a somewhat smaller vein, *pvr* (upper line), leaves the left lobes of the lungs and enters the left auricle of the right heart (fig. 5).

Leaving the small anterior lobe, *l'*, shown between the tracheae in figure 6, is a small vein, *pvl'*, which enters the left auricle of the left heart along with the large vein, *pvl*, described above.

*The digestive organs*

The two heads being distinct the tongue and teeth are normal for each head; the salivary glands have already been described. The two esophagi are separate and normal until they arrive within about 3 cm. of the stomach, where they unite with each other and empty, by a single opening, into that organ. The stomach is single and apparently quite normal. The liver is also normal, as are the organs caudad to this region.

*The skeleton*

As noted above, the appendages had been removed before the animal was received, so that they could not be studied, but there is no reason to suppose that they were abnormal. The thorax is apparently normal, except, as noted above, for a possible unusual depth in a dorso-ventral direction.

A dorsal view of the two skulls, and of the spinal column as far caudad as the second thoracic vertebra, is shown in figure 7.

Except for a marked lateral twist in the right skull, and a slight twist in the left skull these two organs seem normal and need no further description. The twist in the right skull is so marked that the incisor teeth must have been almost useless.

The thoracic vertebrae, *tv*<sup>2</sup>, and the posterior five cervicals, *cv*<sup>3</sup>, *cv*<sup>7</sup>, seem from this view to be normal, except that they are rather wider, laterally, than normal.

The second cervical, *ax*, bears no resemblance to the normal axis. In the dorsal view, figure 7, it exhibits two prominent ridges, separated by a deep groove; these ridges are fused in the median plane and project cephalad between the two atlases, *at*. This second vertebra articulates rather closely, in a more or less normal manner, with the third cervical, and presents a large, antero-laterally projecting process, *ar*, on each side, for articulation with one articular surface of each atlas. There is no sign of an odontoid process.

The two atlases, *at*, are essentially alike and seem nearly normal; that on the right side is slightly the larger. Two foramina are seen on each side of each atlas, the foramen transversarium,

*ft.*, and the atlantal foramen, *fa*: the latter foramen on the mesial side of each atlas is a groove or notch in the anterior margin of the bone, rather than a distinct hole.

A ventral view of the cervical and anterior thoracic regions of the vertebral column is shown in figure 8. In this view the unusual width of the cervical vertebrae is shown in contrast to

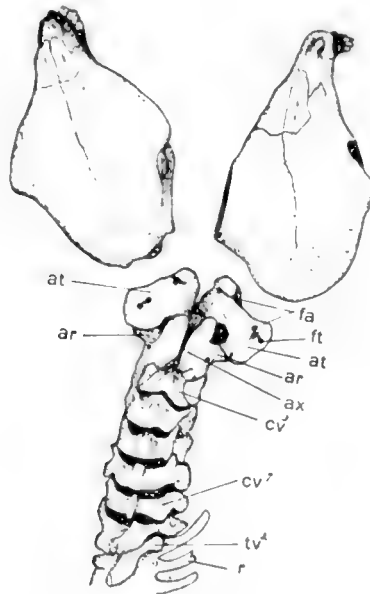


Fig. 7. A dorsal view of the skulls and the anterior vertebrae of the lamb.

the width of the thoracic vertebrae. The cervical vertebrae are also seen to be more or less closely and irregularly fused, so that it is very difficult to distinguish the boundaries of the individual vertebrae, especially of the last three.

The axis, *ax*, is seen in this view to consist of the two widely divergent articular processes, *ar*, which are not in contact with each other, and an irregularly rectangular bone, *ax'*, lying in the median line and articulating with the median articular surfaces of the two atlases, *at*. This strange-looking bone is loosely attached to the articular processes, *ar*, but seems fairly closely united, in the anterior part of its mid-dorsal region, with

the ventral side of the two median processes of the axis, described in connection with the dorsal view. It is in the region of the posterior process of this curious bone, figure 8, *ax'*, that the single spinal cord divides to pass to each brain. In this view the two atlases appear quite normal; one foramen transversarium is not visible in this view; the other foramina are very prominent.

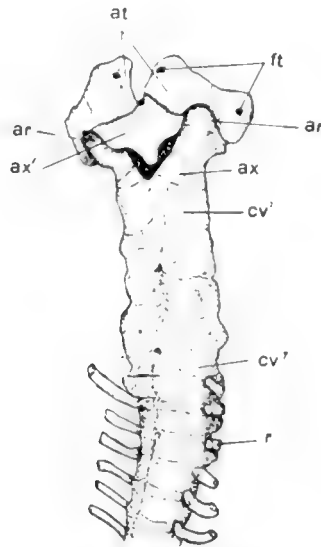


Fig. 8 A ventral view of the same vertebrae shown in dorsal view in the preceding figure.

Owing to the fact, as noted above, that Mr. Reed requested that the skulls be returned to him it was not possible to study the nervous system.

#### LITERATURE CITED

- CAREY, EBEN 1917 The anatomy of a double pig, *Syncephalus thoracopagus*, with especial consideration of the genetic significance of the circulatory apparatus. *Anat. Rec.*, vol. 12, no. 1, pp. 177-192.
- CONROW, SARA B. 1917 A six-legged rat. *Anat. Rec.*, vol. 12, no. 3, pp. 365-70.
- REESE, ALBERT M. 1911 The anatomy of a double cat. *Anat. Rec.*, vol. 5, no. 8, pp. 383-90.
- 1914 The osteology of a double-headed calf. *Amer. Nat.*, vol. 48, pp. 701-704.





## PRELIMINARY NOTE ON THE DIFFERENTIATION OF ANGIOBLASTS AND THE METHOD BY WHICH THEY PRODUCE BLOOD-VESSELS, BLOOD-PLASMA AND RED BLOOD-CELLS AS SEEN IN THE LIVING CHICK

FLORENCE R. SABIN

*Anatomical Laboratory, Johns Hopkins University*

The question of the origin of the vascular system can be solved by the method of studying the living blastoderm of the chick in hanging-drop preparations.

By watching chicks of the second day of incubation in these preparations it is possible to see all the processes by which blood-vessels and later blood-cells form. These observations can be made best on the area pellucida. Blood-vessels begin by the differentiation from mesoderm of a new type of cells, angioblasts or vaso-formative cells. They differ from mesoderm in having a much more granular cytoplasm and in being more refractile. They differ also in their behavior and in their potentialities. When a cell of the mesoderm divides, the daughter cells separate at least enough so that they can be recognized as distinct cells but angioblasts give daughter cells that remain together to form dense syncytial masses. These small masses soon join similar masses by means of tiny processes of cytoplasm put out from them exactly like the sprouts by which blood-vessels are known to grow. In this way angioblasts form a plexus of dense masses of cells in sharp contrast to the more delicate plexus of mesoderm which represents the early stages of the development of the coelom. The plexus of angioblasts increases both by the division and the growth of its cells and by the constant addition of new angioblasts which differentiate from the mesoderm.

Within the plexus of angioblasts, vacuoles appear which represent a liquefaction of the central part of the cytoplasm to form blood-plasma. The vacuoles begin against the nuclei and may occur anywhere in the mass but are especially frequent under the edges. The vacuoles just under the margins leave the cells along the border of the mass to become an endothelial lining of a cavity. The complete liquefaction of the central part of the mass into plasma takes from one to two hours and can be seen with great clearness in the living chick. The endothelial cells on the border of these cavities become less granular than the original angioblasts. Since the fluid is formed from the liquefying of the center there is no sign of distention of the cavities and no flattening of the cells along the border. There is a destruction both of the cytoplasm and of the nuclei of the mass to form the plasma.

This process of the liquefaction of the central part of the mass of angioblasts to form vessels takes place not only within the plexus but in masses of angioblasts which are still isolated and in this way small vesicles are formed which then join the main plexus by processes of cytoplasm. I have seen such a tiny vesicle form from a single angioblast proving that the lumen of a blood-vessel is intracellular.

There are two processes from which the formation of blood-vessels must be sharply distinguished in watching these living specimens. The first is the formation of the coelom. The mesoderm of the chick is originally a continuous sheet of cells as is shown in Lilly's figure 40, A and B, on page 79<sup>1</sup> and in Duval's figures 184 to 188 on plate 12.<sup>2</sup> As the chick grows larger this double sheet of cells forms a plexus with wide interspaces in the network where the mesoderm is entirely lacking leaving nothing but ectoderm and endoderm. The coelom now begins as clefts full of fluid within the solid bands, often at the nodes of the network of mesoderm. These spaces separate and, as it were, split the two layers of the mesoderm apart

<sup>1</sup>Lilly, F. R. 1908 The development of the chick. Henry Holt and Company, New York.

<sup>2</sup>Duval, M. 1880 Atlas d'Embryologie. G. Masson, Paris.

and gradually flow together to make the cavity of the coelom. The mesoderm on the borders of these spaces gradually flattens into a mesothelium. The process involves but little destruction of tissue. At the stage of about six or seven somites a living specimen thus shows a double plexus over the area pellucida, a dorsal plexus which is the developing coelom with large interspaces in the net and many tiny cavities representing the exo-coelom; and a ventral, more massive plexus of angioblasts with much more granular and more refractile cytoplasm than the mesoderm. The granules of the angioblasts are strongly basophilic and stain intensely with haematoxylin and with azur.

The second structure from which developing vessels must be distinguished I shall call endodermal blebs or blisters. They are collections of fluid beneath the endoderm, that is between endoderm and mesoderm, which are very frequent in the normal chick. They can be seen in any collection of mounted blastoderms. In the living chick they vary in appearance according to their size and shape. Their margins simulate endothelium to a marked degree. If they are distended and hence round, their margins will be thin, sharp and highly refractile; if they are flatter their walls will be still refractile but thicker. Often their nuclei seem to project into a cavity exactly like those of endothelial cells. They may be numerous, small and isolated or large and multiple reminding one of multilocular cysts. As can be readily imagined from their structure they may change in shape rapidly, far more rapidly than true vessels change. They can be analyzed with the focusing screw both by following their margins over onto the endoderm and by noting their very superficial position. They occur under the ectoderm as well as under the endoderm but I think less frequently. No one can follow the development of blood-vessels in the living chick without becoming thoroughly familiar with the appearances of these blisters. They have nothing to do with blood-vessels occurring both before the blood-vessels begin and afterward. They are however important physiological structures representing the method by which fluid is absorbed through the endoderm and ectoderm for the young chick.

Red blood-corpuscles can be seen to grow from the endothelial lining of blood-vessels. They may develop from little masses of the original angioblasts which become partially separated by the liquefaction of cytoplasm around them. Such a mass of cells becomes a blood-island by having haemoglobin develop within the cells. The color of haemoglobin can be detected in the living cells earlier than I have been able to fix and stain it. Again an endothelial cell of a blood-vessel will divide so that one daughter cell projects into the lumen. This cell becomes filled with basophilic granules and develops haemoglobin. It is then a unicellular blood-island. It divides and the mass is increased also by the addition of other cells which differentiate from the endothelium in the neighborhood and creep along the wall to join the first cell. These cells soon form a yellow syncytial mass projecting into the lumen of the vessel. At this stage the islands have a smooth, sharp contour. As they develop, cells begin to round up on their surface until the whole mass comes to look like a mulberry and then the red cells break free from the mass and float away in the blood-plasma.

These blood-islands I have seen develop in all the vessels of the area vasculosa, in the omphalo-mesenteric vein and arteries and in the dorsal aorta. In the area pellucida they are most abundant in the plexus of vessels just posterior to the area in which the omphalo-mesenteric arteries develop. In this area almost any chick of fourteen somites will show a plexus of angioblasts full of vacuoles and one of seventeen somites will show blood-islands. The circulation does not interfere with the development of the islands. If they clog the lumen the free corpuscles either lodge behind them for a time or pass on through other channels in the plexus.

One of the most interesting points about the masses of angioblasts and of the islands is that all of the cells in them divide at about the same time. Moreover all of the separate islands of a given area seem to divide at once. In these total preparations, all one can see of the process of mitosis is the nucleus in the stage of the metaphase and the actual division of the cytoplasm. When the syncytial mass is about to divide it becomes

intensely refractile and its cells become outlined; then one sees one nucleus after another pass into the metaphase and finally all of the cells appear to be half as large as the mature cells. The island then becomes large by the growth of all the cells to their original size. The blood-cells keep on dividing after they are free from the islands and after they have begun to circulate.

These studies have been made with chicks which were grown in the mixture of Locke's solution and chicken bouillon developed by Margaret Reed Lewis for tissue-cultures.<sup>3</sup> For the young blastoderms it is better to increase the amount of the sodium chloride in the solution to 1.06 per cent. A weaker solution lyses the haemoglobin and is also less favorable for all the other cells.

From these studies which are here reported briefly, certain principles are established. Blood-vessels do not arise from the dilatation of tissue-spaces, but by the differentiation of angioblasts. They cannot be spoken of as arising from spaces because they develop within the bodies of these angioblasts; that is, they arise within cells, not between them. The processes by which they form are not in any way similar to the processes by which either the coelom or great systems of tissue-spaces like the cerebro-spinal spaces develop. The coelom forms by the splitting apart of two layers of mesoderm with little destruction of tissue; the cerebro-spinal spaces form in a mass of typical mesenchyme with considerable destruction of tissue. Angioblasts differentiate throughout the wall of the yolk sac and in the embryo as well. I have seen the dorsal aorta differentiate in situ in the living chick even to some extent that part within the head. Angioblasts produce blood-plasma, endothelium and red blood-cells. Angioblasts and later endothelial cells give rise to red blood-cells by developing haemoglobin.

The term blood-island has been used since the time of the early embryologists, notably Wolff and Pander, for the masses of vaso-formative cells which can be seen in the area opaque of the chick even before the first somite. I propose however to

<sup>3</sup>Lewis, M. R. and W. H. 1911 The growth of embryonic chick tissues in artificial media, agar and bouillon. Johns Hopkins Hospital Bulletin, 22.

restrict the term blood-island to those masses of cells which can be shown to produce haemoglobin and to become free red blood-cells. These masses are attached to the wall and hence are not strictly speaking islands. The more primitive masses which do begin as isolated masses or islands of cells but must first produce endothelium and plasma, I shall call angioblasts. The red blood-cells develop after some plasma has been formed. All of the blood-cells of the chick of the second day of incubation can be seen to have haemoglobin in the living chick and hence they cannot be considered as forerunners of white blood-cells.

## STUDIES ON THE MAMMARY GLAND

### III. A COMPARISON OF THE DEVELOPING MAMMARY GLANDS IN MALE AND FEMALE ALBINO RATS FROM THE LATE FETAL STAGES TO TEN WEEKS OF AGE

J. A. MYERS

*Institute of Anatomy, University of Minnesota, Minncapolis*

SEVEN FIGURES

Schickele ('99) while studying the development, arrangement, and variation of the mammary glands in rats noticed that ordinarily macroscopic examinations do not reveal nipples in males.

In his work on the recognition of sex through external characters in the young rat, Jackson ('12) called attention to the fact that the mammary gland nipples become very conspicuous in female rats of about two weeks (post-natal life) while in male rats of the same age there is no external indication of nipples. The difference between the two sexes in this respect is so marked that he could readily distinguish the sexes at that age by the use of this single external character.

Steinach ('12) made successful reciprocal transplantations of testes and ovaries in young male and female guinea pigs. The males in which the ovaries grew gradually assumed the appearance of females even to such an extent that some of them developed functional mammary glands. The same experiments were applied to rats, and from these experiments Steinach reached the following conclusion: "Das Rattenmännchen ist für diesen Punkt des Untersuchen deshalb ungeeignet, weil bei ihm diese Anlagen nicht einmal rudimentär ausgeprägt, bzw. makroskopisch nicht sichtbar sind."

My studies (Myers, '16), which were confined entirely to the mammary glands of the female albino rat, led later to a careful macroscopic search for nipples in males of corresponding ages. No trace of nipples was found in any male individual.

The above observations made by four different workers are somewhat contradictory to the usual view that the mammary glands of male animals are parallel in their development with those of females until the stage of puberty, at which time the glands of the male stop growing and later atrophy, while those of the female undergo a very rapid development. In view of such an apparent discrepancy the present work was undertaken. A brief abstract of the results has already been published (Myers, '17 a).

#### MATERIAL AND TECHNIQUE

The fetuses for this work were collected, fixed, sectioned and stained in the same manner as the female fetuses described in an earlier paper (Myers, '17 b). Cleared preparations were made according to the method described by Lane-Clayton and Starling ('06).

In making macroscopic examinations it was very desirable to have the hair removed from the skin. At first a sharp razor was used to shave the abdominal wall. This method was later discarded, however, and the hair was removed from the entire body with sodium sulphide as suggested by Frank and Unger ('11).

Some of the litters used for this study were slightly under normal weight. Therefore in each case it became necessary to compare males and females of the same litter. In this manner it was possible to compare individuals of the same age and of approximately the same gross body weight.

In all, 70 individuals were examined, making a total of approximately 840 mammary glands. About one-half of the entire number of individuals were fetuses. The remaining 35 were fairly evenly distributed among the described post-natal stages ranging from birth to ten weeks of age.



## OBSERVATIONS

*Fifteen and sixteen days.* At fifteen days and nine hours the sex glands of the fetuses are in the indifferent stage. In the fetuses of sixteen days and twelve hours the sex glands are so differentiated that with considerable difficulty the sexes can be distinguished. In the last mentioned stage there is no apparent difference between the developing mammary glands of the two sexes. Therefore the description of the mammary glands of both of the above stages given in a previous paper (Myers, '17 b) is applicable to either sex.

*Eighteen days.* In male fetuses of eighteen days and nine hours fresh preparations show the epidermis over each developing mammary gland to be somewhat lighter than the adjacent epidermis. The epidermis is in most cases elevated so as to form a slight eminence. In one instance, however, a very shallow mammary pit was observed over a single gland.

In females of this age, it will be recalled, the area over the developing mammary gland appears lighter than the adjacent region, but instead of an eminence there is usually a distinct mammary pit present over the developing mammary gland.

The stratum germinativum and basement membrane of the epidermis in the region surrounding the developing primary duct, become continuous with the duct and form the peripheral layer of cells and basement membrane of the duct respectively. The primary duct passes through the corium into the tela subcutanea, as was found to be the case in the female. At this stage the primary duct somewhat resembles a large developing hair (fig. 1). At its free end is seen a considerable expansion which may give off one or two small buds. The mesenchyma forms a thick condensed layer around the duct.

The primary duct of the female in size and general form is similar to the duct of the male; however, it does not show such a marked expansion at its free end. Its attached end also lies deeper from the surface of the epidermis, owing to the fact that it springs from the bottom of the developing mammary pit. The layer of condensed mesenchyma surrounding the primary duct is thinner than in the male.

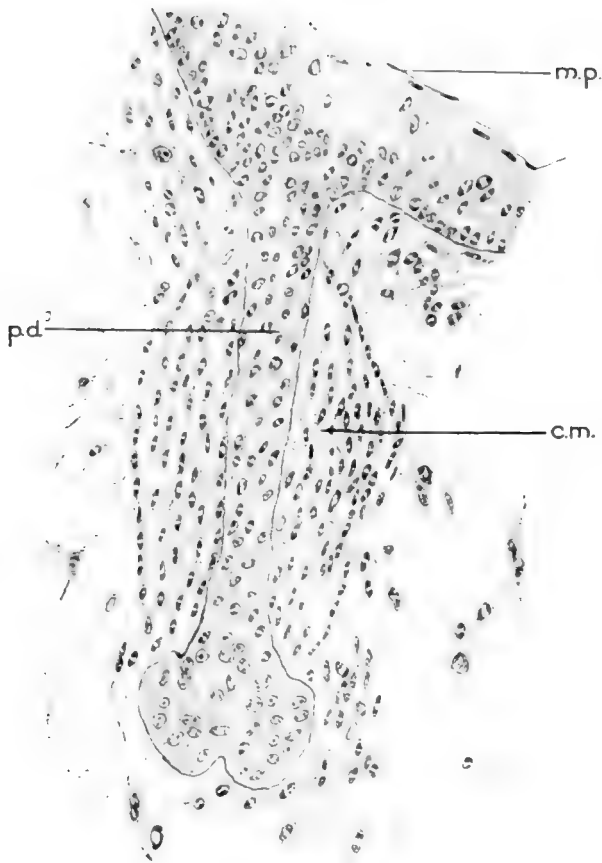


Fig. 1 Drawn from a section through the left third thoracic developing mammary gland of a male albino rat fetus of eighteen days and nine hours.  $\times 300$ . Zenker's fixation; haematoxylin-eosin stain. Drawn with the aid of a camera lucida. Comparing this figure with figure 2 of an earlier paper (Myers, '17 b) for the female, note the difference in appearance of the primary ducts (*p.d.*). The condensed mesenchyme (*c.m.*) immediately surrounding the primary duct is thicker in the male sex. There is less indication of a developing mammary pit (*m.p.*) in the male gland.

*Nineteen days.* When studied with a dissecting microscope, most of the mammary glands of nineteen day and six hour fetuses are not visible on the surface of the integument. An occasional gland, however, is represented, as in the preceding stage, by an area of epidermis slightly lighter in appearance in fresh preparations than the adjacent epidermis.

The glands of the females of this stage are very conspicuous from the surface. In the female, the gland areas are very light in appearance and a well developed mammary pit is located in the center of each area.

The primary duct (of the male) at this stage has lost its resemblance to a developing hair. The attachment of the duct to the epidermis, however, is not unlike that of a developing hair. As the primary duct approaches the deep surface of the epidermis, its basement membrane and peripheral layer of cells are seen to be continuous with the same structures of the skin. The attachment of the duct is, therefore, very near the surface. As in females of the same age, the primary duct passes into the tela subcutanea where it turns at right angles and courses parallel to the surface of the integument. Considerable variation is exhibited in the branching of the ducts. In some glands tertiary ducts are terminal while in others the primary duct is the terminal duct at this age.

The lumina develop in the same manner as reported for the female (Myers, '17 b). In general it may be said, however, that the lumina of the male mammary ducts at this stage are apparently somewhat further developed than those of females.

The stratum germinativum surrounding the attached end of the primary duct is somewhat thickened thus forming a slight ridge around the attachments of the duct. This ridge suggests the epithelial hood anlage, which is distinctly in evidence in females at this time.

The developing connective tissue of the male gland corresponds in structure and arrangement with that of the female.

*Twenty days.* At twenty days and six hours there is neither eminence nor mammary pit over the male mammary gland area in fresh specimens. The epidermis of the area is no longer

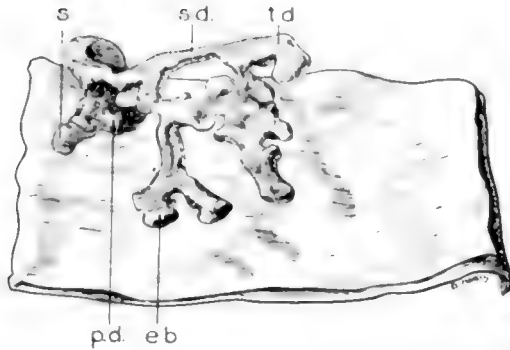


Fig. 2 Internal view of a wax model reconstructed from the left first inguinal gland of a male albino rat fetus of twenty days and six hours.  $\times 50$ . When compared with figure 12 of a previous paper (Myers, '17 b) note the absence of an epithelial ingrowth' (*ep.in.*) and the presence of a short branch (*s.*) arising from the primary duct near its attached end in the male. The structures listed below are approximately the same in both sexes. *e.b.*, end bud; *p.d.*, primary duct; *s.d.*, secondary duct; *t.d.*, tertiary duct.

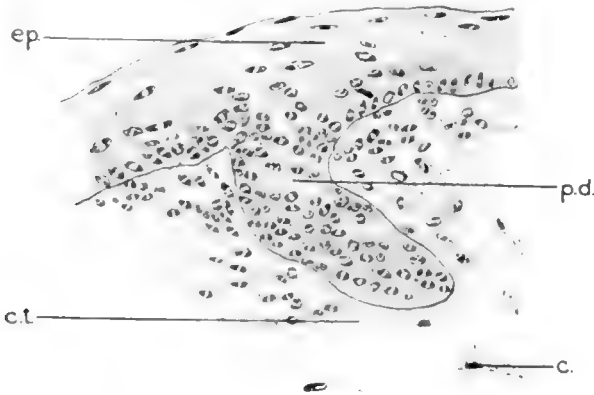

Fig. 3 Drawing of a section through the left abdominal gland of a male newborn albino rat.  $\times 300$ . Zenker's fixation; haematoxylin-eosin stain. Note the entire absence of nipple, mammary pit, and epithelial hood. Other parts similar to those of the female. *c.*, irregularly arranged connective tissue cells; *c.t.*, connective tissue forming sheath around duct; *ep.*, epidermis; *p.d.*, primary duct.

lighter than the adjacent epidermis. There is therefore no external indication of a developing mammary gland in the male rat at this stage. As previously shown (Myers, '17 b), the glands in the female are now quite conspicuous. They are distinctly visible with the naked eye. In sections, the female gland shows a distinct mammary pit with the nipple anlage at the bottom of the pit.

The primary duct in the male near its attachment to the epidermis is often seen to give off a short solid branch (fig. 2), which was not observed on the female duct. In some instances there appear more divisions of the milk ducts than have been observed in females of the same age. The second inguinal gland has failed to develop as rapidly as the others. It therefore appears somewhat rudimentary.

The lumina correspond to those described in the female, except that they are slightly larger in the male.

Hair follicles are developing in the immediate neighborhood of the attachment of the primary duct. This is contrary to the condition in the female, where hair follicles were not observed at this stage in or close around the mammary pit.

The epithelial hood anlages do not appear in the male at this age.

*Newborn.* At birth, as in the twenty day stage, all external appearances of mammary glands are lacking in the male. At this time the glands of the female may be observed with the unaided eye in living and fresh specimens as light areas in the positions of the future nipples.

Microscopic sections likewise do not reveal even the slightest trace of a nipple or an epithelial hood in the male at this time. In the female, however, the nipple almost fills the mammary pit and the epithelial hood is well formed.

The primary duct attaches to the deep surface of the epidermis, but does not reach the outer surface of the body. Leaving the epidermis, the duct passes deeply through the corium into the tela subcutanea where it turns at right angles, passes parallel to the surface of the skin and presents secondary ducts. Immediately beneath the corium the primary duct gives off a

short branch (as in the preceding stage) which courses parallel with the surface. No similar branch was observed in females. The ducts at this stage, including representatives of secondary, tertiary, quaternary, etc., present the same general appearance and the same method of branching as those found in females. The second inguinal gland, however, is an exception as it is still very rudimentary.

A continuous lumen is present in each system of ducts observed. The lumen of the primary duct, however, does not extend as far as the attached end of the duct. The short branch of the primary duct immediately subjacent to the corium likewise




Fig. 4 Drawn from a cleared preparation (internal view) of a male albino rat one week after birth (body weight 8 grams) to show distribution and relations of ducts of right abdominal gland (A); and right first inguinal gland (B).  $\times 5$ . The second inguinal glands were absent in this specimen. Nipples and epithelial hoods are absent. Otherwise the glands of the two sexes are similar in their development. Compare this figure with figure 7 of an earlier paper (Myers, '16, p. 379). *L.*, lymph node; *p.d.*, primary duct; *s.d.*, secondary duct; *t.d.*, tertiary duct; *tr.d.*, terminal duct; *e.b.*, end bud; *co.*, collateral duct.

possesses a lumen. The lumina, like those of the female at this age, have not reached their definitive stage of development.

*One week.* One week after birth the milk ducts of the glands in males apparently do not present many more branches than at the time of birth. The glands occupy the same positions as those of females and the branching has reached approximately the same stage (fig. 4). The only exception to this statement is found in the second inguinal gland. This gland has become so rudimentary that it sometimes fails to appear in cleared preparations. When it is present it presents a very small number of branches.

*Two weeks.* At the end of the second week in each of the first thoracic glands in males its duct is seen to extend cephalad

from its attachment to the epidermis. No branches were observed to take a caudal direction, as is the case in the female. The ducts of the second and third thoracic glands take a more lateral direction and are fully as well developed as those of females. In the abdominal and first inguinal glands a few lateral buds are seen on the main ducts. The ducts of corresponding glands of the females show a large number of such buds. The second inguinal gland when visible in cleared preparations presents a primary duct which courses caudad. Its branches are very few. At the free ends of the ducts of all glands at this stage are found growing end buds, as were previously described in the female.

*Three and four weeks.* At three weeks the glands show very little increase in development over the two weeks stage. The glands of four weeks' male rats, however, show further development. Each of the first thoracic glands presents a larger number of branching ducts, the majority of which are directed cephalad from the point of surface attachment. A few branches, however, take a caudal direction as was found to be the case in females in younger stages. The ducts of the second and third thoracic glands have sent out several collateral branches which in some individuals nearly obliterate the space between the ducts of these glands. The abdominal glands now present a large number of lateral buds which, as in females, are not so numerous on the primary and secondary ducts as on the tertiary, quaternary and terminal ducts. In the male rat, the first inguinal gland of one side is occasionally lacking. Frequently the second inguinal glands are absent. Neither the first nor the second inguinal glands are absent in any female observed. It is not uncommon, however, to find the second or third thoracic gland undeveloped in either sex.

*Five weeks.* It will be recalled that at the fifth week the glands of the female were observed to develop very rapidly (Myers, '16). The ducts are much longer than in previous stages. Many new branches spring from the more distal ducts of the glands. The interval between the ducts of the second and third thoracic glands has largely disappeared on both sides, there being a

slight overlapping of the ducts. The ducts of the abdominal and first inguinal glands likewise overlap, thus obliterating the interval between these two glands. Furthermore some of the ducts of the second inguinal gland have grown cephalad, have met and overlapped the caudally directed ducts of the first inguinal. The ducts of the second inguinal gland branch very profusely.

At this stage the mammary glands of the male have failed to keep pace with the rapid development of the glands of the female. While in some individuals the ducts of the second and third thoracic glands are nearly in apposition, there still exists a definite interval in most cases. There are likewise very marked intervals between the abdominal and first inguinal and the first and second inguinal glands. The second inguinal gland shows no progress in development over the preceding stages. Not only are the milk ducts of the male shorter in length, but they are less numerous than those of the female.

*Six, seven and eight weeks.* At six, seven and eight weeks the differences between the male and female glands are becoming still more obvious. The most noticeable difference is the absence or very rudimentary condition of the second inguinal gland of the male. A mere glance at any of the remaining glands will enable the observer to distinguish between male and female. The most prominent distinguishing character is the large number of collateral ducts that have grown from the chief milk ducts in the female. The collaterals have branched and each terminal branch presents a large end bud. In the males a much smaller number of collaterals appear. Thus the arborization of the male gland is much less dense. In no case have the ducts of two adjacent glands in the male overlapped so as to form a continuous mass of gland tissue.

*Nine and ten weeks.* In an earlier study (Myers, '16), it was shown that the mammary glands of female rats show a tremendous increase in growth and development about the ninth or tenth week. The overlapping of the ducts of the thoracic glands is so extensive that a continuous mass of gland tissue extends from the cephalic ends of the ducts of the first thoracic gland to



the caudal ends of the ducts of the third thoracic glands. No complete intervals exist between the glands. Furthermore ducts from each of the first thoracic glands have grown so near the mid-line that only a small space now separates them. A considerable space exists between the last thoracic and abdominal glands. The ducts of the abdominal and first and second inguinal glands also overlap so as to form one continuous mass of gland tissue, extending from the most cephalic of the ducts of the abdominal gland to a point somewhat caudad to the genital orifice. Medial branches of the second inguinal gland, extending near the mid-line, nearly surround the vagina.

A comparison of figure 5 with figure 13 of an earlier paper (Myers, '16, p. 385) shows that in male rats of nine and ten weeks there is no progressive development of the mammary glands corresponding to that just described in females. In figure 5, the second inguinal gland is seen to present very few branches, thus offering a marked contrast with the same gland of the female. In most of the individuals examined, cleared preparations failed to reveal the presence of the second inguinal gland. The first inguinal and abdominal glands are separated by a definite space, there being no overlapping. It should be mentioned, however, that in one male of nine weeks the ducts of the first inguinal and abdominal glands were found to present a rather dense arborization. The ducts of the two glands in this case overlap to some extent. Even in this individual, which apparently represents an unusual variation, the glands are still distinctly less extensively developed than in the females of corresponding age.

Microscopic sections reveal large lumina in the milk ducts of the male. As was found in females, the end buds now possess somewhat larger lumina than the ducts into which they open. The primary duct when traced toward the surface of the body is seen to pass from the tela subcutanea into the corium where it makes a very oblique angle with the surface. Before reaching the surface, however, the lumen is seen to end in the duct within the corium in all glands studied at this stage. In one case the primary duct ended in very close relation to the at-

tached end of a hair follicle. The lumen of the duct could not be traced into the hair follicle, but the relation of the duct to the hair follicle is strongly suggestive of that existing in lower forms of mammals.

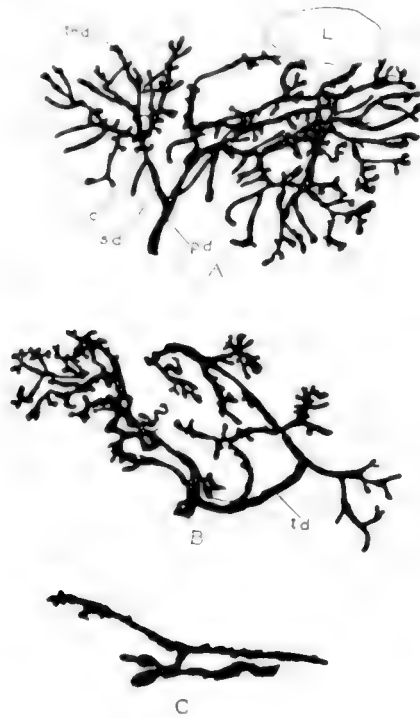


Fig. 5 Drawn from a cleared preparation (internal view) of a male albino rat nine weeks old (body weight 95 grams)  $\times 5$ . Compare this figure with figure 13 of an earlier paper (Myers, '16), p. 385), showing the much more extensive and complicated branching of the ducts in the female of corresponding age. *A.*, left abdominal gland; *B.*, left first inguinal gland; *C.*, rudimentary left second inguinal gland. The drawings do not represent the glands in their natural spatial position with reference to each other.

It is interesting to note that in several of the postnatal stages studied it was possible to obtain a few individuals of approximately the same age whose gross body weight was somewhat above or below the normal for that age. In general it may be said that in both sexes the mammary glands correspond somewhat

with the gross body weight of the animal, i.e., in those individuals noticeably under weight the glands are somewhat smaller than in those of normal and above normal weight. When the body weight is far below normal the glands of the female do not show such a dense arborization at the age when puberty normally appears. Perhaps this is due to the fact that the arrival of puberty is slightly delayed.

A few male rats between the ages of ten and sixteen weeks were examined. In all observations made the glands of the sixteen week rats were found somewhat better developed than in those of nine and ten weeks. Apparently considerable growth has taken place and new ducts have developed as the arborization of ducts appears more dense.

#### DISCUSSION AND CONCLUSIONS

##### *The nipple*

In the fetus at eighteen days in the male albino rat the surface of the future nipple area appears somewhat lighter than the surrounding epidermis. It is very rare to find a developing mammary pit in the male at this time. In nineteen day male fetuses an occasional gland can be recognized from the surface, but with difficulty, while at twenty days there is no external indication of the mammary glands in the male. About two weeks after birth, when the nipples of the female become so conspicuous owing to the lack of hair around the nipples (Jackson, '12) and to the very rapid growth of the nipple itself (Myers, '16), there is no trace of a nipple in the male. The hair develops quite uniformly over the entire abdominal and thoracic wall. From this stage through the ten weeks stage no nipples were observed in any of the male individuals studied (cf. figs. 6 and 7). Microscopic examinations of all stages likewise show the absence of nipples.

The absence of nipples in the male rats is contrasted with their presence as observed by many workers in a large number of animal species, including man. While the nipples of men are rudimentary, they are absent only in anomalous cases.

It is a well known fact that rudimentary nipples also appear in the males of many of our domestic animals. According to Schiekele, Eschricht ('49) found rudimentary nipples also in all males of the whale family.

In the monotremes, Owen ('32) noticed that mammary glands are present in both sexes. Later, Bresslau ('08) and ('12 b) in monotremes observed mammary glands in males which agree in shape and size with those of females. While nipples have been




Fig. 6 Drawing of the ventral view of a young adult female albino rat in lactation. Hair removed from ventral wall. This specimen shows the absence of the left third thoracic gland. This is one of the most common variations in the number of nipples in the female.

Fig. 7 Drawing of the ventral view of a young adult male albino rat. Hair removed from ventral wall. No traces of mammary gland nipples are present.

described in male marsupials by Laurent ('39) and Katz ('82), yet Leche ('97) and Bresslau ('12 b) believe that nipples do not ordinarily appear in male marsupials of the Australian species. According to Schickele ('99), Rapp ('52) states that generally no trace of a nipple appears in the males of Edentata.

Schickele ('99) in studying the number, position, and arrangement into groups of the nipples in the mouse, found it necessary to exclude adult males since in them he was never able macroscopically to recognize even rudimentary nipples with absolute certainty. In his macroscopic observations on adult rats he likewise found in males no nipples, not even rudiments. In one young male rat, however, he found 12 nipple anlagen arranged the same as in female mice.

Our present knowledge therefore leads to the conclusion that in monotremes, the mammary glands of the two sexes reach about the same stage of development while in the higher forms of mammals the mammary glands of the male appear in a rudimentary condition. The existence of mammary glands in the males of some species of marsupials seems doubtful. In some forms (chiefly rodents) the nipples in the males have entirely disappeared.

#### *Milk ducts*

In the present investigation the primary milk duct of the male albino rat was observed in eighteen day fetuses to resemble somewhat a large developing hair follicle. At nineteen days the duct has largely lost its resemblance to a hair follicle. It has grown in length, and in some glands presents secondary and tertiary ducts. The twenty day stage shows the ducts in approximately the same stage of development as in females of the same age. One difference, however, is in the appearance of a branch from the primary duct of males immediately beneath the corium. From birth to five weeks, the glands of the two sexes are about parallel in their development. At five weeks, the glands of the male begin to lag behind those of the female, the chief difference being that a smaller number of collateral branches appear on the ducts of the male. At nine weeks (about the time of puberty), the ducts

of the female show a vast number of branches while those of the male are but slightly further developed than at five weeks. The marked contrast at nine weeks can be best appreciated by comparing figure 5 with figure 13 of an earlier paper (Myers, '16).

The resemblance of the early primary duct to a hair follicle may possibly have a phylogenetic significance. Bresslau ('02) found in marsupials that in the regions of the future mammary glands large hair anlagen develop. From one side of each anlage a sebaceous gland buds off, while from the other side a milk duct develops. As time goes on the free end of the hair anlage and the sebaceous gland atrophy, but the milk duct develops very rapidly and retains its opening into the attached end of the hair follicle. In squirrels (*Sciurus vulgaris*), Bresslau ('12 c) found that the mammary gland anlage in both sexes divides into a medial and a lateral part; from the lateral part the milk-ducts develop, while from the medial part a bristle-like tactile hair develops, which in adult animals far surpasses in length and thickness the other hairs of the body.

Developing hairs and sebaceous glands closely related to the mammary gland anlage have also been described in man by Eggeling ('05), Brouha ('05) and Lustig ('16).

My figure 7 somewhat resembles Bresslau's figure 5 (*Münchener Med. Woch., Jahrg., 59, S. 2794*). In a later stage, it will be recalled, a branch was seen to spring from the side of the primary duct anlage near its attached end. It is possible that this branch may correspond with the sebaceous gland found in marsupials by Bresslau ('02) and in man by Lustig (see Lustig's fig. 10). Therefore the mammary gland anlage of the male rat at the time when it appears similar to a hair anlage, is perhaps repeating the conditions found in lower forms. The developing mammary gland of the female probably passes through a similar stage, but owing to the fact that it is much more highly specialized than the gland of the male it has more stages to pass through, and the earlier stages are doubtless passed over very rapidly.

The fact that after the fifth week of postnatal life the glands of the female are a little better developed than those of the

male albino rat agrees with the findings of Kolliker ('79). He states that in human from one to ten years after birth the milk ducts and end buds increase only a little, branching somewhat more richly in the female than in the male sex. Krause ('06) also states that there is no essential difference in the glands of the two sexes at birth; the differences belong to later periods of life. Broman ('11) states that in the human the glands of the male do not develop after birth. In the rat, however, my figures 4 and 5 show that in the male there is considerable growth in the ducts after birth. This growth apparently merely keeps pace with the general body growth.

The tremendous differences which appear between the glands of the two sexes of rats about the ninth week correspond to the differences which have been described as occurring in the mammary gland of many species at about the time of puberty. The extent to which the mammary gland of the male develops is somewhat variable. At nine weeks as shown above most of the male rats show a small amount of branching of the ducts while others of the same age present a fairly dense arborization of milk ducts. The male albino rats examined after puberty by me show that slight development continues after that time.

While examining the mammary glands of many men, Cooper ('40) found that there is considerable individual variation. Ordinarily it is stated that the milk-ducts of males cease to develop after puberty and very soon pass through the stage of involution (McMurrich, '15, Jordan, '16, and many others).

Kölliker ('79) in men of twenty years, found mammary gland vesicles which were not found at about the time of puberty. Schenk also found end vesicles in the glands of men, but makes no mention of their age. It was not until about the thirtieth year that Kölliker found regressive metamorphosis beginning in the mammary glands of men. Furthermore, Merkel ('99) and Kerr ('16) state that occasionally at the time of puberty some swelling and soreness are experienced in the mammary glands of men. Therefore it must be concluded that the mammary glands in the male may show some (although slight) growth after puberty.

In the descriptive part of this paper it was shown that the number of mammary glands is more variable in the male than in the female rat. In the female rat it has been pointed out by Schiekele ('99), Henneberg ('00), Frank and Unger ('11) and Myers ('16) that an occasional supernumerary gland develops. The second or third thoracic glands may be lacking, but the others are always present in the female. The first and second inguinal glands as well as the second and third thoracic glands may be missing in the male. In all males examined the second inguinal gland when present is in a very rudimentary state.

As previously shown (Henneberg, '00, Myers, '16) in the female rat the second inguinal gland of each side is located laterocephalad to the urethral orifice. The ducts of this gland for the most part take a caudal direction from their epidermal attachment. Ultimately the branches extend caudad to the vagina for a considerable distance. In the male the second inguinal glands have approximately the same location. Caudal to the genital eminence, however, the integument becomes the outer wall of the scrotum. The skin of this region, being specialized so as to form a part of the scrotum, apparently forms a poor medium for the development and ramification of milk ducts.

The fact that the ducts corresponding to several of the mammary glands are often absent, together with the fact that the nipples are very rarely developed indicate that the mammary glands may be gradually disappearing in the male rat. On the other hand, the ducts present in the male so closely resemble those of the female until the time of puberty that it is easy to believe that the male milk glands were at one time functional, and with the proper stimulus might again develop into functional glands. Steinach ('12) found that the mammary glands of male guinea-pigs sometimes become functional after a pair of ovaries have been transplanted beneath the skin. Owing to the absence of nipples, Steinach regarded the rat as unfit for such experiments.



*Occurrence of mammary glands in both sexes*

Several theories have been advanced regarding the occurrence of the mammary gland in both sexes. Barkow ('29) pointed out that in forms lower than mammals the brooding may be done by either the male or the female, or the two sexes may share equally in this work. Ruge ('95), Gegenbaur ('98) and Wilder ('08) believe that the mammary glands first appeared in the female and were later transmitted to the male. On the contrary, Haacke ('93) thinks the mammary glands were transmitted from the male to the female.

A more logical view is supported by Paul ('84), Westling ('89), and Bresslau ('08, '10, and '12) who after carefully studying the mammary glands of lower mammals concluded that from its beginning the mammary gland was developed to the same extent in both sexes. The female gradually took the responsibility of nourishing the offspring and the mammary glands in the male became correspondingly nonfunctional.

The present work on the albino rat lends support to this theory. In the earlier fetal stages the mammary glands appear the same in both sexes. As development progresses the glands of the male lag behind those of the female, and no nipple is formed. When the adult condition is reached, the glands of the male possess no nipple and the milk ducts are in a somewhat rudimentary and variable state. Such a condition, together with the relations found in lower forms, lead one to conclude that the mammary glands were in ancestral forms equally developed in both sexes. The individual male rat in which Schiekele ('99) found a complete set of nipples probably represents a reversion toward the earlier ancestral type in which the mammary glands of the two sexes were more nearly alike in structure.

## SUMMARY

The results of the present study of the development of the mammary gland in the male rat may be summarized briefly as follows:

1. While the sex glands are in the indifferent embryonal stage, there is no apparent difference between the anlagen of the mammary glands in the two sexes.

2. In fetuses of eighteen days the mammary gland anlagen of the male differ from those of the female in that they possess no mammary pit. In twenty day fetuses, when the nipple anlagen are present in females, no trace of a nipple was observed in males. In fact, nipples apparently fail to develop in the male at all, including postnatal stages. Hair develops uniformly over the ventral surface of the body of the male leaving no macroscopic indication of a mammary gland area.

3. Like the nipple, the epithelial hood is also absent in male albino rats.

4. The primary milk duct in eighteen day male fetuses resembles a hair anlage. At twenty days the branches appear approximately as were found in females of the same age. Until about the fifth postnatal week the milk ducts of the two sexes are approximately parallel in their development. After the fifth week, the ducts of the female present more branches than those of the male. The difference is not very great, however, until the ninth week (age of puberty). Then the ducts of the female branch very profusely while the ducts of the male show but little change.

5. In the male the lumina of the milk ducts develop in the same manner and at about the same time as in the female.

6. The second inguinal gland of the male is very rudimentary and may be entirely lacking. This condition is evidently due to the development of the scrotum in the region which the second inguinal gland normally occupies.

7. The number of mammary glands is more variable in the male than in the female. No supernumerary glands were observed in the male. The second and third thoracic and the first and second inguinal glands are sometimes absent in the male. Usually not more than one or two of these glands are absent in a single individual. The other mammary glands were present in all rats examined.

## LITERATURE CITED

- BARKOW, H. C. L.** 1829 Anatomisch-physiologische Untersuchungen, vorzüglich über das Schlagadersystem der Vögel. Meckel's Arch. f. Anat. u. Physiol.
- BRESSLAU, E.** 1902 a Beiträge zur Entwicklungsgeschichte der Mammarorgane bei den Beutelhieren. Zeitschrift f. Morphologie u. Anthropologie, Bd. 4.  
 1902 b Weitere Untersuchungen über Ontogenie und Phylogenie des Mammarapparates der Säugetiere. Anat. Anz., Bd. 21.  
 1908 Die Entwicklung des Mammarapparates der Monotremen, Marsupialier und einiger Placentaler. I. Entwicklung und Ursprung des Mammarapparates von Echidna. Semon's Zoolog. Forschungsreisen, Bd. 4, Lieferung 5.  
 1910 Der Mammarapparat (Entwicklung und Stammesgeschichte). Ergebn. d. Anat. u. Entw., Bd. 19.  
 1912 a Ueber Hyperthelie. Münchener Med. Wochenschr., Jahrg. 59, S. 2793-2795.  
 1912 b Die Entwicklung des Mammarapparates der Monotremen, Marsupialier und einiger Placentaler. II. Der Mammarapparat des erwachsenen Echidna-weibchens. Semon's Zoolog. Forschungsreisen, Bd. 4 (Jenaische Denkschr., Bd. 7).  
 1912 c Die Entwicklung des Mammarapparates der Monotremen, Marsupialier und einiger Placentaler. III. Entwicklung des Mammarapparates der Marsupialier, Insectivoren, Nagethiere, Carnivoren und Wiederkäufer.
- BROMAN, IVAR** 1911 Normale und abnorme Entwicklung des Menschen.
- BROUHA, DR.** 1905 Recherches sur les diverses phases du developpement et de l'activite de la mamelle. Archives de Biologie, T. 21.
- COOPER, A.** 1840 On the anatomy of the breast. London.
- EGGELING, H.** 1904 Ueber ein wichtiges Stadium in der Entwicklung der foetale Mamma beim Menschen. Anat. Anz., Bd. 24.  
 1905 Ueber die Drüsen des Warzenhofs beim Menschen. Jen. Zeitschr. f. Naturw., Bd. 39.
- ESCHRICHT,** 1849 Die nordischen Walthiere.
- FRANK, R. T., AND UNGER, A.** 1911 An experimental study of the causes which produce the growth of the mammary gland. Archives of Internal Medicine, vol. 7.
- GEGENBAUR, C.** 1898 Vergleichende Anatomie der Wirbelthiere. Bd. 1.
- HAACKE, W.** 1885 On the marsupial ovum, the mammary pouch and the male milk glands of Echidna hystrix. Proc. of the Royal Society of London, vol. 38.  
 1893 Ueber die Entstehung des Säugethieres. Biolog. Centralbl., Bd. 8.
- HENNEBERG, BRUNNO** 1900 Die erste Entwicklung der Mammarorgane bei der Ratte. Anat. Heft, Bd. 13.
- JACKSON, C. M.** 1912 On the recognition of sex through external characters in the young rat. Biological Bulletin, vol. 23.

- JORDAN, H. E., AND FERGUSON, J. 1916 A text-book of histology.
- KATZ, O. 1882 Zur Kenntniss der Bauchdecke und der mit ihr verknüpften Organe bei den Beutelhieren. *Zeitschr. f. wissensch. Zoolog.*, Bd. 36.
- KERR, A. T. 1916 The anatomy of the breast. *Reference Handbook of the Medical Sciences*, vol. 2, p. 445-458.
- KÖLLIKER, TH. 1879 Beiträge zur Kenntniss der Brustdrüse. *Verh. d. phys. med. Ges. zu Würzburg*, N. F., Bd. 14.
- KRAUSE, W. 1906 Die Entwicklung der Haut und ihrer Nebenorgane. Hertwig's *Entwicklungslehre der Wirbeltiere*, Bd. 2, Teil 1-2.
- LANE-CLAYTON, MISS J. E.; AND STARLING, E. H. 1906 An experimental enquiry into the factors which determine the growth and activity of the mammary glands. *Proc. of the Royal Society, Series B*, vol. 77.
- LAURENT, M. 1839 Recherches anatomiques et zoologiques sur les mammifères marsupiaux. *Annales d'anatomie et de physiologie*, T. 3.
- LUSTIG, HILDA 1916 Zur Entwicklungsgeschichte der menschlichen Brustdrüse. *Archiv. f. mikr. Anat.*, Bd. 87.
- McMURRICH, J. P. 1915 The development of the human body. Fifth edition, Philadelphia.
- MERKEL, FR. 1899 *Handbuch der topographischen Anatomie*, Bd. 2.
- MYERS, J. A. 1916 Studies on the mammary gland. I. The growth and distribution of the milk-ducts and the development of the nipple in the albino rat from birth to ten weeks of age. *Am. Jour. Anat.*, vol. 19. (Abstract also published in the *Anat. Rec.*, 1916, vol. 10, p. 230.)  
1917 a A comparison of the mammary glands in male and female albino rats. (Abstract) *Anat. Rec.*, vol. 11, p. 391.  
1917 b Studies on the mammary gland. II. The fetal development of the mammary gland in the female albino rat. *Am. Jour. Anat.* (in press).
- OWEN, R. 1832 a On the mammary glands of the *Ornithorhynchus paradoxus*. *Philos. Transactions*, vol. 122.  
1832 b On the mammary glands of *Echidna hystrix*. *Proceed. Comm. Science and Corr. Zoolog. Soc.*, London, p. 2.
- \*PAUL, H. 1884 Ueber Hautanpassung der Säugethiere, Jena, H. Pohle.
- RAPP, 1852 Die Edentaten.
- RUGE, G. Die Hautmuskulatur der Monotremen und ihre Beziehungen zu dem Marsupial- und Mammarapparate. *Semon's Zool. Forschungsreisen*, Bd. 2 (Jenaische Denkschriften, Bd. 5).
- SCHICKELE, G. 1899 Beiträge zur Morphologie und Entwicklung der normalen und überzähligen Milchdrüsen. *Zeitschrift f. Morphologie und Anthropologie*, Bd. 1, Heft 3.
- SCHENK, S. L. *Istologia normale dell'uomo* (ital. transl. by Monti and Golgi).
- STEINACH, E. 1912 Willkürliche Umwandlung von Säugetier-Männchen in Tiere mit ausgeprägt weiblichen. Geschlechtscharakteren und weiblicher Psyche. *Archiv für die gesammte Physiologie (Pflüger's)*.
- \*WESTLING, CH. 1889 Anatomische Untersuchungen über *Echidna*. *Bih. Svensk. Akad. Handl.*, Stockholm, Bd. 15.
- WILDER, H. H. 1909 *History of the human body*.

---

\*The original paper was not available for this work.

## AN ADJUSTABLE SLIDE BASKET

H. E. RADASCH AND J. I. FANZ

*From the Daniel Baugh Institute of Anatomy of the Jefferson Medical College*

### FIVE FIGURES

This apparatus was originally designed for use in the preparation of a students' loan collection of normal histologic specimens, in order to enable the technician to carry twenty to forty sections at one time, through the various steps of deparaffinization to clearing, without manipulating the individual slides. The great practical utility and efficiency of the device, however, were soon evident and the wide range of use to which it might be applied, seemed to warrant its description.

It is clearly manifest that in the preparation of 8000 or more slides that anything would minimize the routine labor to the extent of 20 to 30 per cent should have an important place as a labor-saving device. By using several baskets, many slides can be prepared in a short time, insuring uniformity in stain reaction, etc.

The basket can be used most satisfactorily in the following work:

1. In the preparation of students' loan sets of normal histology, pathologic histology, botany, zoölogy and wherever many slides are to be made.

2. In serial section work and in reconstruction of embryos, small organs, tumors and botanical or zoölogical specimens.

3. In routine (hospital) pathologic histology, where a variety of tissue specimens obtained at necropsy is to be studied histologically.

As the basket is adjustable and will hold any sized microscope slide, its use is extended over those types that are limited to one size. The slides today are not of uniform length, as formerly and adjustable feature has been very opportune in the present work.

In the construction of the apparatus aluminum was selected and used throughout as most suitable from a standpoint of lightness, durability and workable qualities. Aluminum is effected to a destructive degree by strong alkalis, acids and urates. These fortunately do not enter into the ordinary technic of histology or pathology. Strong iodine solutions corrode this metal slightly, but in the strength used for the removal of bichloride of mercury crystals, it does no harm in the time required for this process. The selection of this metal was the result of the experience of one of the authors who devised a ten to twenty slide basket of thin sheet aluminum which answers very well for serials, of a hundred or so, of 2 by 3 inch slides.<sup>1</sup>

<sup>1</sup>Anat. Rec. vol. 3, no. 2, February, 1909.

*Construction.* Figure 1 shows the unassembled parts and illustrates the underlying principle of simplicity and ease of construction. The base and top plates (A and B) are  $5\frac{1}{2}$  inches long,  $1\frac{5}{16}$  inches wide and  $\frac{1}{4}$  inch thick. These are grooved to hold the slides. The grooves are  $\frac{3}{32}$  inch wide and  $\frac{1}{4}$  inch deep and a full inch long, leaving a ledge at the back to prevent the slides from slipping through. The pattern for these plates was prepared by making a plaster of paris cast of the side of an old pillsbury slide box, which had unusually wide and deep




Fig. 1. Unassembled parts of the basket.

grooves. Twenty of these grooves were utilized and sufficient additional length allowed for the support rods.

The plates are drilled for and supported by four aluminum rods each 4 inches long and  $\frac{1}{4}$  inch thick. These are threaded at both ends for about 1 inch and are provided with two aluminum nuts for each end. The nuts are made out of  $\frac{1}{8}$  inch sheet aluminum. The handle is made of the same size aluminum rod and passes through only the top plate. It extends about 3 inches above this plate, thereby making it convenient to grasp the handle and support the back of the top plate with the index finger while washing the sections with alcohol or water from wash bottles. The plates were cast at a foundry, but could, no

doubt, be readily stamped from sheet aluminum with a suitable steel die.

The height of the basket over all is  $6\frac{3}{4}$  inches, the weight is 165 grams. The assembled apparatus is shown in figure 2.

One important consideration in the dimensions of the apparatus was the jar to be used. In order to have as little waste space as possible and yet accommodate the handle so that the jar could be closed to prevent evaporation of the various solutions, a specimen jar was chosen. The inside dimensions are as follows: height,  $7\frac{3}{4}$  inches;




Fig. 2. Parts assembled and filled with slides.

width,  $5\frac{1}{2}$  inches; depth,  $2\frac{1}{4}$  inches. The top edge of the jar and the glass cover are ground so that a close fit is insured. To the top three pieces of cork are cemented with asphaltum. The one at the middle of the exposed surface serves as a handle, while the other two (thinner) are underneath and near the ends. The latter serve as stops and prevent the cover from slipping off accidentally. Asphaltum answers for all covers except that for the xylol jar. The xylol softens the asphaltum and causes it to run. Figure 3 shows a set of slides in a jar of alcohol before staining. Forty of these thin slides could readily have been placed, back to back in the basket, but only twenty were

used in the illustration. An aluminum wrench for tightening the nuts is also shown in the illustration. This prevents burring produced by a wrench of harder metal.

Nine of these jars constitute an ordinary set and are labelled (both cover and jar) for the following reagents: xylol, alcohol, iodine, alcohol, water, hematoxylin, eosin, picrofuchsin and alcohol. If other stains as pararcarmin or safranin are used, extra jars are required.

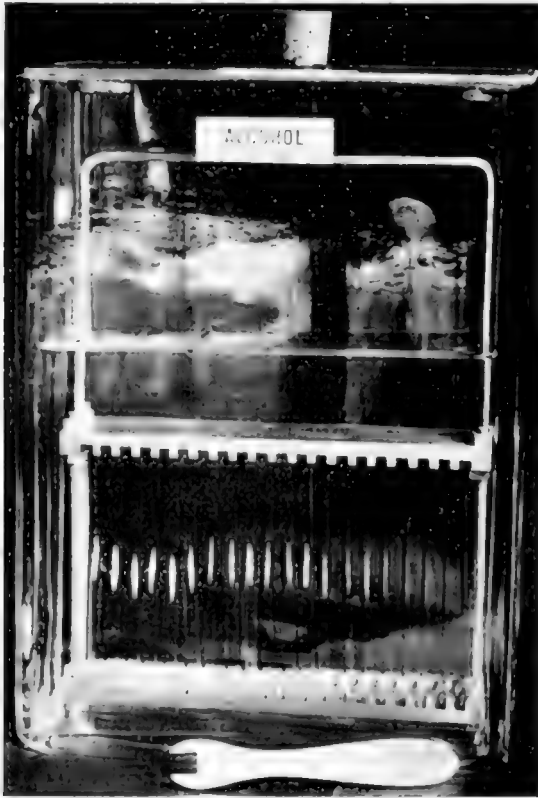


Fig. 3. The basket in an appropriate jar and aluminum wrench for the nuts.

The sections are placed in the basket and (1) transferred to the xylol jar for about five minutes to remove the paraffin. The basket is then removed, drained and washed with 95 per cent alcohol (by wash bottle) and placed (2) in the iodine jar for five minutes to remove the bichlorid of mercury crystals. The sections are again washed with alcohol and placed in (3) the first alcohol jar to remove the remainder of iodine.



If the fixing agent contains no bichlorid of mercury, these two steps are unnecessary. The basket of slides is then placed in a bucket of water (to remove the alcohol) and then transferred for five minutes to (4) the hematoxylin jar. The hematoxylin is then washed off by placing the basket in a bucket, or battery jar of water and then transferred to (5) the jar of eosin (0.5 per cent for two minutes), or picro-fuchsin (one and one-half minutes).

The slides are then washed in water as before and allowed to stand therein for several minutes. This is especially important after an aqueous eosin has been used, as the water seems to fix it in the tissues. If these are transferred to alcohol too soon, the eosin is very rapidly removed by the dehydrating alcohol.

The basket of slides is next washed with alcohol (95 per cent) to remove as much of the water as possible and then transferred to a flat dish of alcohol to (6) dehydrate. The writer prefers to clear each slide individually and not the basketful at once. The use of a flat tray for dehydration enables the technician to pick out each slide without lifting the basket. The sections are taken out one at a time, cleaned, blotted and covered with (7) cresote to clear. This is left on until all twenty have been so treated and then they are taken up in sequence, drained, blotted and (8) mounted in balsam.

The alcohol used for dehydration and removal of iodine is saved, filtered through animal charcoal and used in the embalming mixture for the preservation of cadavers, so that there is very little wasted. The cresote is also saved and used a second time, as its use has not been impaired.

As the writers are at present in the preparation of a study in which the sections are at least 1 inch by  $\frac{1}{2}$  inch, another apparatus and set of slides had to be devised to meet this special requirement. Figure 4 shows the adaptability of the preceding apparatus in which the slides are 10 inches long and 2 inches wide. For a serial consisting of about 3500 to 4000 sections, each one by  $\frac{1}{2}$  inch, it is out of the question to consider 2 by 3 inch slides. For this reason larger slides had to be considered and apparatus suitable thereto constructed. The principle of construction is the same, the support rods being cut to any desired length and threaded in the same manner as before. The slides were made from 8 by 10 inch and 10 by 12 inch and larger waste negatives from the Photographic and X-ray Department of the Jefferson Medical Hospital through the courtesy of Prof. Willis F. Manges. The emulsion was easily and thoroughly removed; the plates were then cut into the desired sizes and the edges filed. The preparation of 200 such slides required a comparatively short time. Cover glasses for these can readily be made in the same manner from thin 8 by 10 inch negatives as they suffice where general low power objectives are to be used. For higher power work photographic celluloid is being experimented with to test its applicability.

Suitable reagent dishes for these large baskets can be obtained at the various instrument dealers as the glass trays handled by them are

straight-sided. Glass plates cut to the proper size and supplied with corks as in the preceding, serve very well for covers.

Figure 5 shows three slides 2 by 10 inches. *A*, shows a plain side; *B*, shows the paraffin sections freshly mounted; *C*, shows a finished slide. These sections are through both ventricles of the heart of an adult cat.




Fig. 4. Slide basket adapted to 10 inch slides.

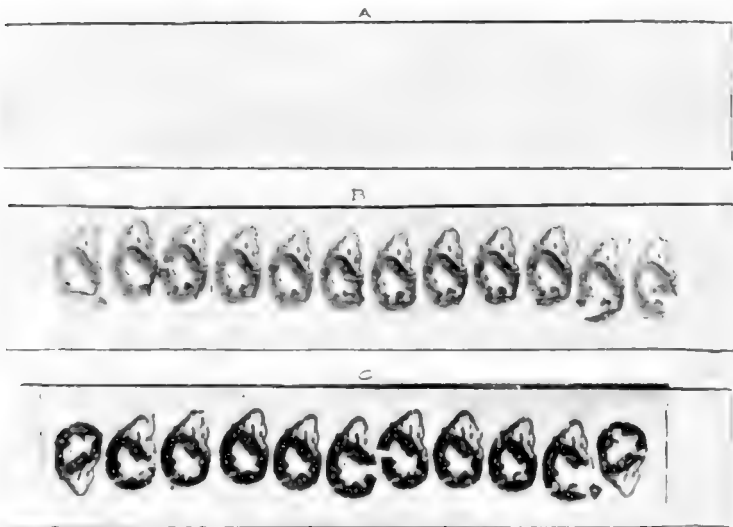


Fig. 5. Three 10 inch slides. *A*, plain; *B*, paraffin sections mounted; *C*, slide completed.

## AN EXPERIMENTAL STUDY OF THE EFFECT OF STRESS AND STRAIN ON BONE DEVELOPMENT

J. A. HOWELL

*From the Anatomical Laboratory of the University of Missouri*

SEVEN FIGURES

That the growth of the bone is dependent, to some extent, at least, upon the amount of stress and strain exerted upon the bone, has been well established. It is strongly indicated by the remarkable mechanically adapted arrangement of the trabeculae and compacta, which shows most strikingly in the vertebrae and bones of the leg in man, and which has been analyzed chiefly by H. von Meyer, J. Wolf, and quite recently by R. Koch ('17). It is proven by studies which have been made on bones in which, as a result of injury, new directions of lines of force have been introduced with a resultant formation of entirely new sets of bone trabeculae—studies which have been made especially by W. Roux and J. Wolff. This literature has been fully reviewed recently by R. Koch to whose article those particularly interested are referred.

Undeniable as it is that mechanical factors exert some governing influence over the growth of bone, there still remains open the question as to how far-reaching this control is. The extreme mechanical view is held by R. Thoma ('07), that all bone formation, even including the first bone formed in the embryo, takes place as a response of bone forming tissue to the action of stress and strain. He holds that growth in thickness, in human bones, begins when the stress and strain exceed a certain minimum, which he estimates roughly to be equivalent to a weight of 6.6 grams per square millimeter of cross-section, acting over twenty-four hours. If stress and strain become increasingly greater, new bone forms with increasing rapidity until a certain (undetermined) optimum is reached. Beyond this, new growth

become slower, until, after a certain (undetermined) maximum is passed, bone resorption takes place. Bone resorption also takes place, if the stress and strain fall below the minimum.

The growth in length differs, according to Thoma, in that no diminution takes place, no matter how high or how low the amount of stress and strain. The minimum pressure, however, needed to stimulate growth in length, he places at the same point as for growth in thickness. One gains the impression that Thoma considers the regulation of bone formation by the mechanical effect of stress and strain to be absolute.

There is, however, already much evidence against this extreme view. Thus Ollier ('67), in his classical transplantation experiments, found that periosteum, transplanted from the tibia to the comb of a rooster, forms a shell of bone—clearly without the action of stress or strain. Again, E. H. Weber (cited in Herbst, '01) found, in a new-born calf which had no spinal cord below the cervical region, and no muscle in the posterior half of the body, the skeletal parts well developed. While they were only half as heavy as normal, and the joints were ankylosed, still they had differentiated and undergone a considerable amount of growth, while deprived of the stress and strain exerted by the normal intraembryonic movements. It is, moreover, a matter of common observation, that considerable growth takes place in a paralyzed arm, particularly in length, though it lags well behind the healthy arm, in thickness.

There seems, therefore, to be need for an experimental analysis, in order to determine whether growth of bone takes place in the absence of mechanical stress and strain, and, if so, how much, and to how great an extent it compares with the normal growth.

A beginning was made by Pottorf ('16), working with puppies. He performed two experiments: in the first he diminished the stress and strain exerted on one of the fore-legs of a three weeks puppy, by holding the leg in a sling, so that no weight was borne by this leg. At the end of three weeks he found the bones of the two fore-legs to be about the same length, while the bone in the legs walked on were considerably thicker than in

the other. In a second experiment, one leg was paralyzed by cutting the nerves of the brachial plexus, thereby eliminating, in addition to the stress and strain due to the weight of the body, that due to muscle pull. After twenty days it was found, again, that growth in length had been nearly the same in the bones of the two legs, while there was a very great difference in thickness—the bones in the unoperated leg being, in some places from two to four times as thick as those in the immobilized leg. Ossification had taken place in epiphyses on the operated side, although the size of the epiphyses was slightly less than on the unoperated side.

In the present study it was suggested by Dr. Clark that the work started by Pottorf be carried to older stages. In order to obtain the maximum information from the minimum of experimental material it was decided to employ the X-ray. There would thus be obtained a series of records on the same animal, before operation, and at regular intervals afterward. While X-ray pictures give a somewhat confused record, as compared with studies of the bones themselves, and do not show the cartilages, still, for comparative purposes, they give sufficiently accurate information as regards length, diameter, shape, size of epiphyses, union of epiphysis with diaphysis, and a fair indication of thickness. This method, moreover, has the advantage that the records of the different ages are all taken from the same animal.

#### DESCRIPTION OF THE EXPERIMENT

The method of operating was the same as that used by Pottorf. Two fox terrier puppies, about four weeks old, were used for the experiment. In both animals the operation performed consisted in cutting the main nerves of the brachial plexus on the right side, in order to produce paralysis of the muscles. In both cases the operation was carried through with very little hemorrhage—the axillary artery and veins and their chief branches were undisturbed. In one of the puppies a limited amount of movement was regained after a few weeks, showing that the operation had not been complete. This animal was, therefore, discarded. In the other, control was maintained over the pectoralis and

latissimus dorsi muscles, so that a certain amount of muscle pull was exerted on the upper part of the humerus. This served to hold the limb close to the body, and made the use of a sling unnecessary. All voluntary control over the muscles moving the bones of the elbow and carpal joints was lost, the contracture of muscles produced a gradually increasing fixation of the elbow joint in a sharply flexed position. No weight was borne on the leg of the operated side.

Healing by granulation took place within a few days after the operation, and the affected limb remained healthy throughout the experiment. Especial care was taken in feeding, and the weight, recorded weekly, is shown in table 1:

TABLE 1

DATE	WEIGHT	IN-	DATE	WEIGHT	IN-
	pounds	CREASE		pounds	CREASE
		pounds			pounds
*November 11, 1916	3.0		January 20	9.4	0.4
November 17, 1916	3.9	0.9	January 27	10.0	0.6
November 25, 1916	5.0	1.1	*February 3	11.0	1.0
*December 1, 1916	5.5	0.5	February 10	11.1	0.1
December 7, 1916	6.35	0.85	February 17	11.41	0.31
December 15, 1916	7.0	0.65	*February 24	11.6	0.19
*December 21, 1916	7.3	0.3	March 3	11.61	0.01
December 29, 1916	8.0	0.7	March 10	11.61	0.0
January 6, 1917	8.5	0.5	March 17	11.6	-0.01
*January 13, 1917	9.0	0.5	*March 24	11.8	0.2

\* Dates at which X ray plates were taken.

The table shows that there was steady increase in weight, at an average rate of seven-tenths of a pound per week for the first twelve weeks. For the last seven weeks the increase dropped to an average of one-tenth of a pound per week. The general health, however, was excellent throughout, and measurements of the bones from the X-ray plates show that growth continued throughout the period of the experiment, including the last four weeks when the weight was practically stationary.

X-ray pictures were taken just before the operation, at approximately three week intervals throughout, and immediately after death. In order to obtain clear pictures light ether anesthesia

was produced. The animal was killed with chloroform, nineteen weeks after the operation. Immediately after death the bones of the two fore-legs were removed, cleaned, and various comparative studies made on the fresh bones. The bones were split longitudinally in order to study the thickness, architecture, epiphyseal lines and arrangement of trabeculae. Later they were preserved in alcohol. Before splitting the humeri a cylindrical section 1 cm. high was taken from the center of the shaft of each bone to test for compressive strength.

In taking up the results obtained, the data furnished by the X-ray records will be considered first, and later the data obtained from the study of the bones after death.

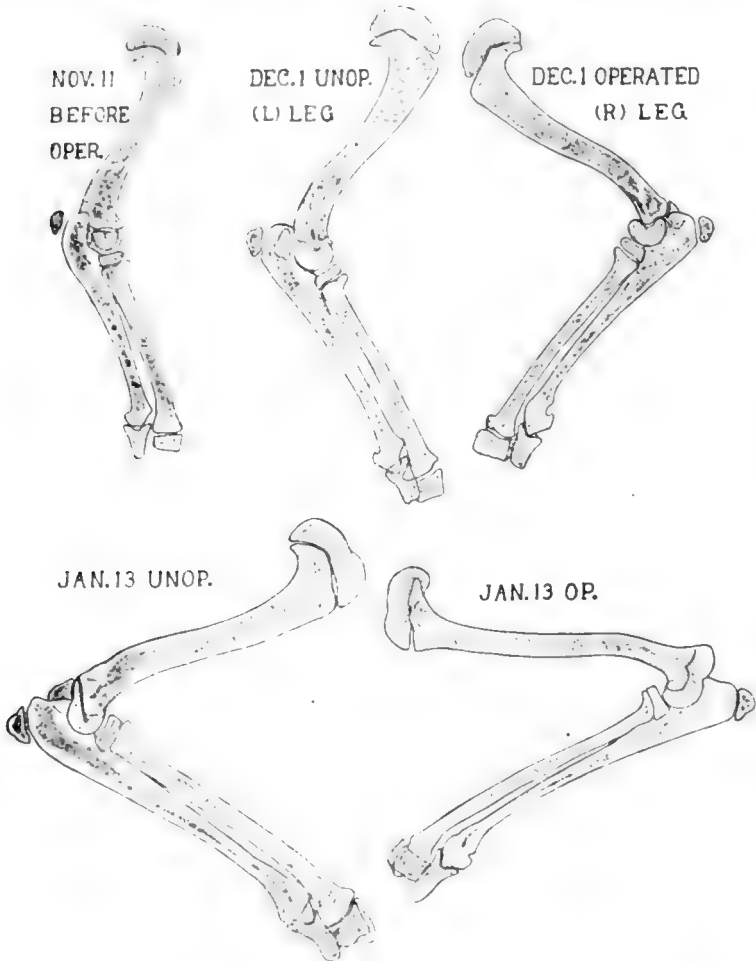
In taking the X-ray plates, the attempt was made to have the limb as near the plate as possible, in order to have the minimum of distortion. A partially successful attempt was also made to have the bones in the same approximate position. While measurements made from the plates are not so accurate as measurements from bones, still the probability of error is not great enough to interfere with the main results, particularly as regards the length of humerus, ulna and radius and the diameter of the humerus.

In figures 1 and 2 are given drawings, made from the X-ray plates, of the bones of the operated and unoperated side at various ages. A comparison of the two in the successively older stages shows, in many ways, a considerable uniformity. The shapes of the bones in the unused leg do not differ greatly from those of the bones in the used leg. In length, again, the difference is not great. In diameter and thickness of compacta, however, there is a marked difference.

In order to find out the exact lengths, etc., various measurements were made. The more striking of these are reproduced in table 2 and some of the results plotted in the form of curves, shown in figure 3. It must be remembered that the lengths do not include the cartilages at the joint ends of the epiphysis, since these do not show in the plates.

A study of the tables and chart shows that in length, growth of the bones in the operated side nearly kept pace with those in the

unoperated side for six weeks after the operation. This agrees with the results of Pottorf, who found very little difference in length on the two sides after twenty days. At nine weeks, however, the unused bones had lagged behind the used bones, and the difference increased slowly but steadily as long as the



Figs. 1 and 2 Drawings, made from the X-ray plates, of humerus, radius and ulna from the two legs. November 11 shows the left leg just before operation. Pictures of March 28 were taken after death. Two-fifths natural size.



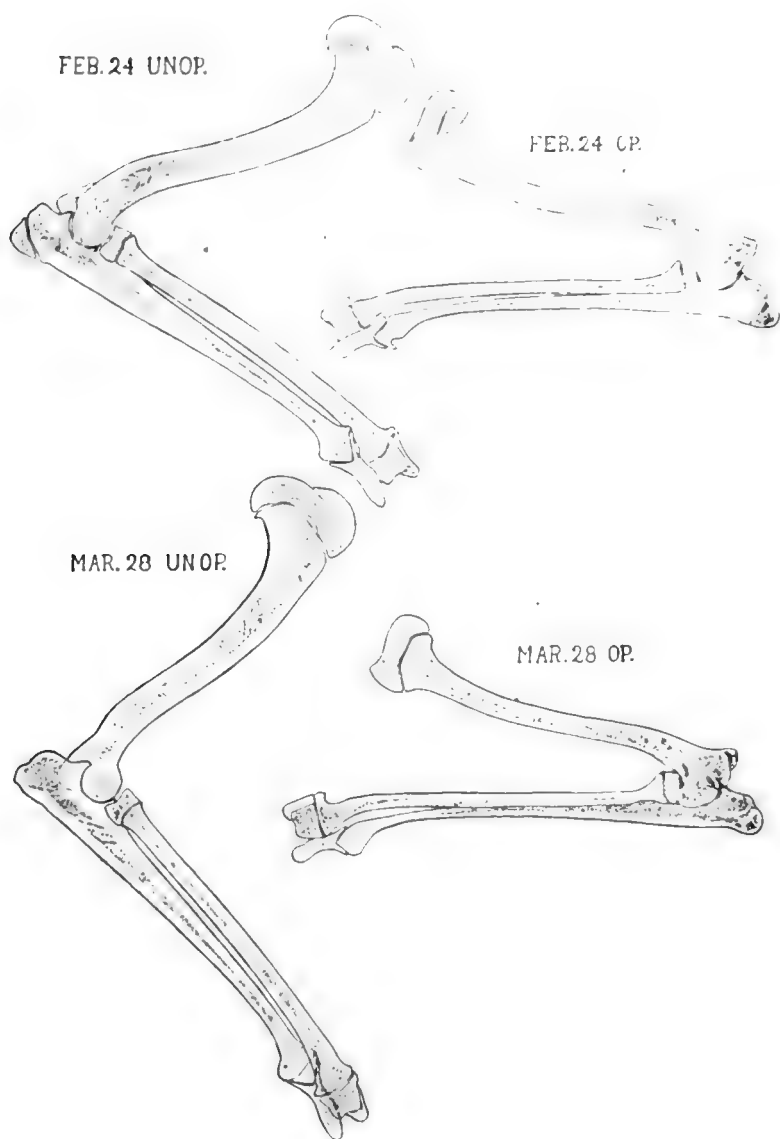


FIG. 2

TABLE 2

DATE	LENGTH OF HUMERUS IN CENTIMETERS			LENGTH OF ULNA IN CENTIMETERS			LENGTH OF RADIUS IN CENTIMETERS			DIAMETER OF HUMERUS IN CENTIMETERS		
	Operated	Unoperated	Difference	Operated	Unoperated	Difference	Operated	Unoperated	Difference	Operated	Unoperated	Difference
November 11.....	6.2	6.2		6.35	6.35		5.2	5.2		0.6	0.6	
December 1.....	7.3	7.35	0.05	8.55	8.55	0.0	7.0	7.0	0.0	0.65	0.70	0.05
December 21.....	8.2	8.3	0.10	10.0	10.125	0.125	8.1	8.15	0.05	0.65	0.75	0.10
January 13.....	8.7	9.05	0.35	10.8	11.1	0.3	8.8	9.2	0.4	0.625	0.80	0.175
February 3.....	9.1	9.5	0.4	11.55	11.9	0.35	9.35	9.85	0.5	0.55	0.875	0.325
February 24.....	9.3	9.8	0.5	11.8	12.3	0.5	9.8	10.3	0.5	0.55	0.925	0.375
March 28.....	9.6	10.15	0.55	12.4	12.95	0.55	10.25	10.8	0.55	0.55	1.0	0.45
Measurements of cleaned bones.	9.7	10.15	0.45	12.0	12.7	0.7	10.05	10.55	0.5	0.55	1.0	0.45

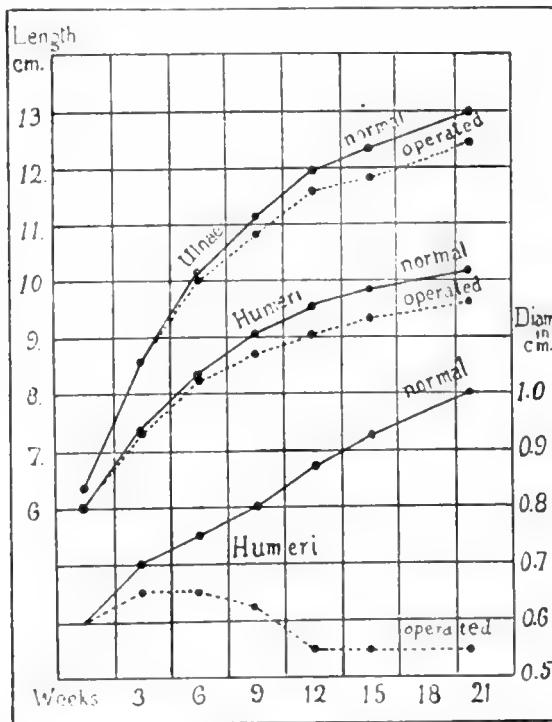


Fig. 3 Chart showing graphically the actual lengths of the two humeri and ulnae, and the diameters of the two humeri.

experiment continued, until, at the last record, the bones in the used leg were about 5.5 mm. longer than the corresponding bones in the unused leg—an excess of approximately 5 per cent. It should be emphasized, however, that, to the end, growth in length continued in the unused bones. Separate measurements show that this growth in length took place both in the diaphyses and in the epiphyses.

#### CHANGE IN DIAMETER

The measurements of the diameters at the center of the shaft of the humerus are given in table 2. Measurements of the diameters of the radii and ulnae were somewhat unsatisfactory, because these bones are not cylindrical, and slight differences in position introduced errors. This was not true of the humeri, however, which are more nearly cylindrical in the middle third, and their diameters are represented in the lower curves in figure 3. The difference between the used and unused bones is very striking, and is noticeable even after three weeks. The measurements indicate that, in the unused humerus, there was first a slight increase (from 0.6 to 0.65 cm.) and later a diminution (to 0.55 cm.) which remained unchanged for the last month and a half of the experiment, while the diameter of the used humerus increased steadily from 0.6 to 1 cm. The unused radius and ulna also showed but slight increase in diameter, while in the corresponding bones in the healthy leg, the diameter nearly doubled.

#### GROWTH IN THICKNESS OF COMPACTA

Measurements of the thickness of the compacta, as shown in the X-ray plates, were the least satisfactory of all the measurements made. An appreciable difference (0.025 cm.) between the two humeri, however, appeared at three weeks. At the end of the experiment the difference had increased to 0.1 cm., the thickness of the two bones, at corresponding points, measuring 0.15 cm. and 0.25 cm. respectively. The ulnae showed similar differences, while the radii (owing partly to difference in posi-

tion) showed a difference of only 0.025 cm. at the end of the experiment—as shown in the X-ray plates.

The differences in thickness found by Pottorf at the end of twenty days were much greater than in this study at the end of three weeks, for he found the thickness of the used humerus from two to four times as great as that of the unused, at corresponding points.

#### GROWTH OF EPIPHYSES

The X-ray plates show that the ossification of the epiphyses, and the union of epiphyses with diaphyses progress uniformly in the bones of the two legs, the only appreciable difference being that the epiphyses are larger and slightly different in shape on the active side. In the distal end of the humerus the line between epiphysis and diaphysis is obliterated between February 3 and February 24, in both legs. The proximal epiphysis of the ulna united with the diaphysis between February 24 and March 28 in both legs. The remaining epiphyses of the humerus, ulna and radius were still ununited in both legs at the end of the experiment.

The thickness of the epiphyseal cartilages was uniformly greater in the used than in the unused bones.

#### STUDY OF THE BONES AFTER DEATH

As already stated, as many studies as possible were made after the death of the animal on the fresh bones—they were cleaned, weighed, drawings and measurements were made, etc., they were split longitudinally, and blocks were taken from the humeri for testing the crushing force. They were then preserved in alcohol, and further studies made of the architecture as shown in the split bones.

The finding at the site of operation and of the muscles were as follows. The pectoralis, latissimus, serratus magnus and cephalo-humeral muscles were found to be healthy, and account for the fact that the shoulder was drawn close to the body. The other muscles of the leg were much atrophied. At the operation site there was a mass of scar tissue, into which ran

the large nerves from the proximal side, and from which on the distal side, remnants of nerves emerged. Portions of the nerves beyond the scar and the atrophied muscles were placed in formalin. In contrast to the healthy structures from the other limb, they remained floating, showing the presence in them of fat.

In order to obtain an approximate idea of the size of the arteries, an injection of red-lead was made. This showed an abundant arterial supply. The subclavian arteries of the two sides were laid open and their circumferences measured. The artery of the operated side was found to have a circumference of 5 mm., as compared with 6 mm. for the one on the unoperated side—making the diameters 1.6 and 1.9 respectively. Such a difference is to be expected, when the difference in activity and size of limb are considered. Clearly no objection can be raised on the score of lack of sufficient blood-supply to the bones of the operated side.

The gross appearance of the two sets of bones is shown in the photographs of the fresh bones, reproduced in figures 4 and 5. As may be easily seen, there is no striking difference between the two sets, except in diameter, and general size. Similar processes and grooves are present in both sets, both show approximately the same curves, the difference in length is not great, but the bones from the unused leg are much more delicate than those from the used leg.

The measurements of the bones themselves, some of which are given in table 2, show, for lengths of bones and diameter of the humerus, slight differences from the measurements, made from the X-ray plates of March 28, which were taken after death, and therefore serve as a partial control to the X-ray measurements. In nearly all measurements, those from the X-ray are slightly higher (about 3 per cent) than those from the bones themselves. In the comparison between the bones of the two sides, however, the difference between the two sets of measurements is very little, the greatest divergence being in the lengths of the ulnae, the measurements of which show a difference of 0.7 cm. as cf. with 0.55 cm. in the X-ray measurements. The percentage amounts by which the unused bone has lagged behind the used

bone in length are, for humerus, ulna and radius: 4.4, 5.5 and 4.7 per cent respectively.

As indicated by the X-ray plates, the difference in diameter of the bones from the two sides is very great. The measurement of the humeri agree very closely with those made from the X-ray plates, and are given in table 2. The measurements of the diameters of the radii and ulnae, however, show that those from the X-ray records are not reliable, owing to the flattened shape of these two bones, which causes modifications according to slight differences in position. These bones are found to have the following greatest diameters, at the middle of the bone:

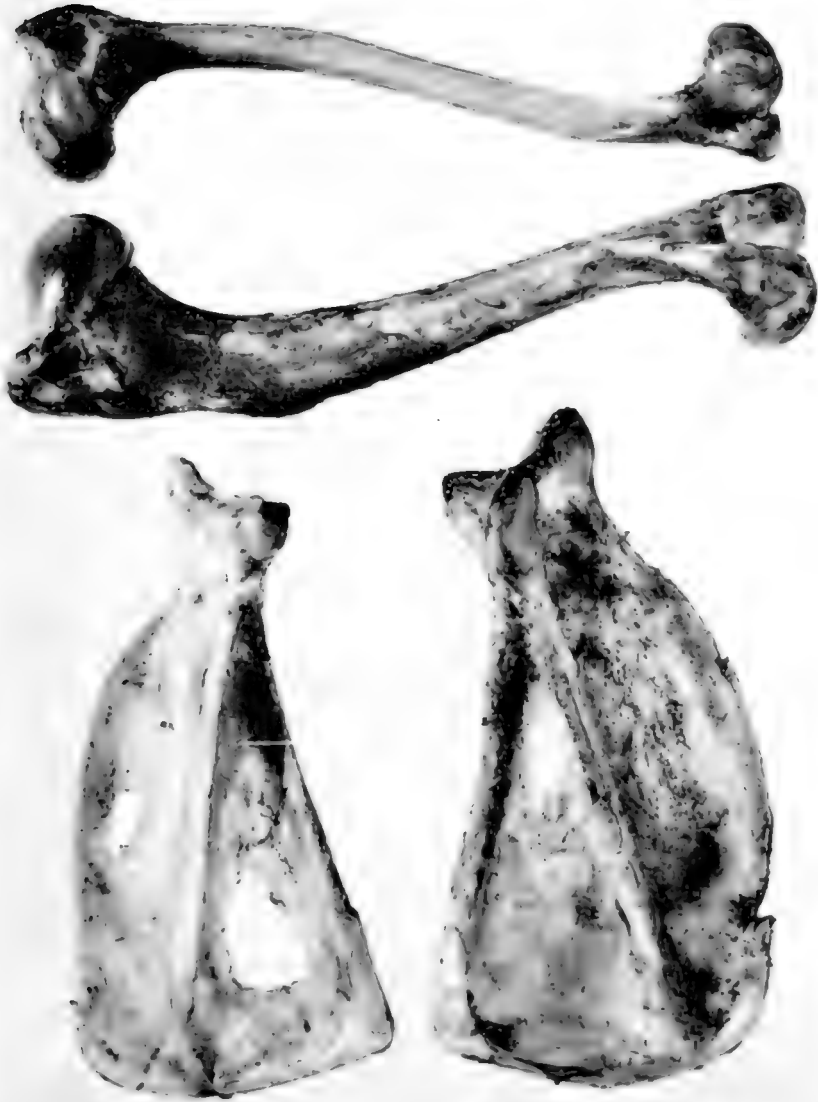	<i>cm.</i>		<i>cm.</i>
Ulna on operated side.....	0.45	On unoperated side.....	0.95
Radius on operated side.....	0.57	On unoperated side.....	0.95

TABLE 3

		THICKNESS OF COMPACTA			DIAMETER OF MEDULLARY CANAL
		<i>mm.</i>	<i>mm.</i>	<i>mm.</i>	<i>mm.</i>
Humerus	{ Unoperated leg.....	1.8	+ 2.5	= 4.3	5.2
	{ Operated leg.....	1.3	+ 1.4	= 2.7	2.8
Ulna	{ Unoperated leg.....	2.5	+ 1.25	= 3.75	1.0
	{ Operated leg.....			2.25	0.0
Radius	{ Unoperated leg.....	1.25	+ 1.75	= 3.0	2.0
	{ Operated leg.....	0.4	+ 1.25	= 1.65	0.6

Thus the radius and humerus on the unused side have diameters slightly greater than half—the ulna a diameter less than half—the diameters of the corresponding bones in the used leg.

In order to study the thickness and the strength and arrangement of the trabeculae, the bones were split longitudinally through corresponding parts. In the radii and ulnae the cuts were made through the line of narrowest diameter. Measurements of thickness, taken at corresponding points at the middle of the bone, are, for the two thicknesses, shown in the cut surface.



Figs. 4 and 5 Photographs of the bones of the two legs after death. Approximately natural size.

Thus the thicknesses of the bones on the operated side are found to be less than those on the unoperated side by 35, 40 and 41.6 per cent for the humerus, ulna and radius respectively, while the size of the medullary canal shows a still greater difference—being practically obliterated for a considerable portion of the unused ulna, and, in the unused radius, less than one-third as wide as in the used radius.

The difference in thickness comes out conspicuously in the scapulae. The unused scapula is much more delicate than the used scapula, and, as shown in the photograph, has on the operated side an area in each of the supra- and infraspinatus fossae, which is covered only by a membrane, bone being entirely absent.

The trabeculae, particularly in the humerus, show interesting differences (fig. 6). In the bones of the used leg they are decidedly larger and stronger than on the operated side. They show, at both the proximal and distal ends a definite arrangement—somewhat similar to that of the femur of man—for transmitting the body weight. Definite bars arch upward from the lateral and medial sides of the compacta toward the epiphyseal line, while in the epiphysis there are bars and sheets in the line of greatest pressure. In the unused bone there is a suggestion of a similar arrangement, but there are no sheets of bone, and the bars are very delicate, with relatively much larger spaces between. A similar difference is present in the distal extremities of the humeri, where the epiphyseal lines have disappeared. In the middle third of the shaft there are more trabeculae in the used than in the unused humerus.

The study of the split bones corroborates that of the X-ray plates as regards the union of epiphyses with diaphyses—the epiphyseal line has disappeared in the distal ends of both humeri and in the proximal ends of the ulnae. The other epiphyseal cartilages are still present in both bones, and are thicker on the unoperated side. The joint cartilages are also thicker on this side.

The gross differences in the bones of the two sides are shown in the comparative weights of the fresh bones, which are given in table 4:



TABLE 4

	WEIGHTS IN GRAMS	
	Unoperated	Operated
Humerus	16.655	6.92
Ulna	7.525	2.529
Radius	7.115	3.225



FIG. 5



Fig. 6 Drawings of the proximal and distal ends of the two humeri. The actual length is somewhat greater than is shown. Enlarged approximately 1.6 times.

From this table it appears that the humerus, ulna, and radius from the operated side are 58.4, 66.5 and 54.6 per cent less respectively than the corresponding bones of the unoperated side.

It was thought that interesting data might be obtained by testing the comparative amounts of force necessary to crush the bones from the two legs. Professor LaRue of the Engineering Department of the University of Missouri very kindly placed at my disposal one of the testing apparatuses of the department of engineering, and assisted in its operation. Following his suggestion, a block was taken from the shaft of each humerus, care being taken that the height was at least as great as the diameter, and that the two cut surfaces were ground parallel. In order to determine beforehand the total cross-sectional area, a drawing of the cut surface was made at an enlargement of 1 to 25, and the total area occupied by bone estimated by means of a planimeter. The bones had undergone partial drying (several hours) before testing.

The results of the tests, and the estimations made from them are shown in table 5:

TABLE 5

	UNOPERATED	OPERATED
Cross sectional area of bone.....	38.01 sq. mm.	14.78 sq. mm.
Crushing force.....	1075.0 lbs.	340.0 lbs.
Kilograms per square millimeter.....	12.82	10.43
Pounds per square inch.....	18,251.0	14,845.0

The relative cross-sectional areas (fig. 7) of the two bones give a better idea of the relative amount of bone than the diameters given above, and they agree fairly closely with the differences shown by weighing. Thus the cross-sectional area of the compact bone of the unused humerus is 60 per cent less than the other, while its weight as shown above is 58.4 per cent less.

Possibly the most surprising of all the findings of the present study was the amount of force—340 pounds—necessary to crush the bone from the leg which, for four and one-half months,

had been subjected to the action of a negligible amount of stress and strain.

Most interesting is the comparison between the two bones, when the figures are reduced to inch-pounds, as shown in the table. While the amount required to crush the unused bones was 19 per cent less than for the used bone, it is surprising to find that the resisting strength of the unused bone is as high as 14,845 pounds per square inch. This is not far below the

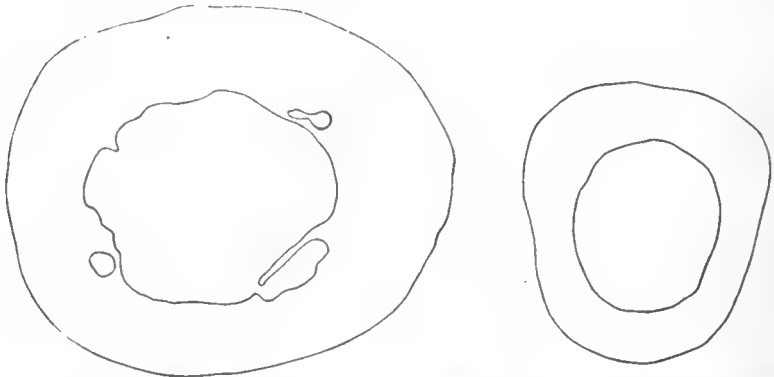


Fig. 7 Projections of the proximal surfaces of the cylindrical blocks taken from the two humeri for testing. They are placed so that, in each case, the top of the picture corresponds with the anterior (cephalad) surface of the bone. Enlarged 6.25 times.

compressive strength of human bones which lies between 18,000 and 24,000 pounds per square inch (Rauber, quoted by Koch, '17, p. 282).

#### DISCUSSION AND CONCLUSIONS

The results brought out in this study allow certain definite conclusions to be drawn, while on other points they give data which are suggestive, but which need further testing.

The answer to the question whether all bone growth is dependent upon the amount of stress and strain is definite and conclusive, and is in the negative. The growth in length of the bones deprived of the action upon them of all but a negligible amount of stress and strain, a growth of such an extent that the humerus

becomes 56 per cent longer, while the radius and ulna nearly double in length during four and a half months, does not admit of any question on this point. On the other hand the answer to the question whether bone growth is entirely independent of the action of stress and strain is equally definite and is also in the negative. This is shown conclusively by the very much smaller diameter, thickness of compacta, size of trabeculae, and greatly reduced weight of bones largely deprived of the action of mechanical stress and strain.

It is clear, then, that the growth of bone is regulated in part by the action of the mechanical factors of stress and strain, and in part by other factors. So far as shown by this experiment, which covers a period in a growing dog, between about four and twenty-three weeks after birth, the part of bone growth dependent upon the action of mechanical stress and strain includes most, if not all, growth in diameter, that is, most of the formation of bone by the apposition of new layers. This applies to the growth in thickness of the trabeculae, once they have been laid down, as well as to that of the compacta. It is probable that a part of the growth in length is also dependent upon the amount of stress and strain. This appears to be increasingly important as the animal grows older, for, while growth in length in the unused bones practically kept pace with that in the used bones, for six weeks after operation, thirteen weeks later the increase in length of the bones in the used leg had been 20 to 25 per cent greater than that of the bones in the paralyzed leg.

The part of bone growth not regulated by the action of the mechanical factors of stress and strain, so far as shown in this experiment, includes most of the growth in length, that is, the new bone which is formed at the ends of diaphyses, including extensions to the compacta and the trabeculae, as well as bone formed in epiphyses. The time at which the epiphyses unite with the diaphyses is also a factor which appears to be uninfluenced by stress and strain, for the same epiphyses have united and the same remained united in the two legs, at the end of the experiment.

This experiment does not give a clear picture of the exact changes in thickness which occur in bones deprived of the action of stress and strain, because of the uncertainty of the X-ray pictures. The amount of apposition and resorption which takes place can not be estimated, and to determine this other experiments must be carried out. That some resorption takes place is shown clearly by the windows found in the scapula, in the supra- and infra-spinous fossae. It is planned to carry the experiment over still longer periods, and also to interrupt the experiment at various shorter intervals, in order that certain studies not possible from the X-ray plates may be made.

I wish to acknowledge my indebtedness to Dr. E. R. Clark of the Anatomy Department of the University of Missouri for his kind advice and assistance in the development of this problem. I also desire to thank Mr. Harry A. LaRue, Instructor in Civil Engineering and Dr. H. C. Rentehler of the Physics department of this university for their aid in some of the technical work of this experiment, and Mr. G. T. Kline for assistance with the drawings.

#### BIBLIOGRAPHY

- HERBST, C. 1901 Formative Reize in der Tierischen Ontogenese. Leipzig.  
KOCH, J. C. 1917 The laws of bone architecture. *Am. Jour. Anat.*, vol. 21, p. 177.  
OLLIER 1867 *Traité expérimentale sur la regeneration des os*. Paris.  
POTTORF, J. L. 1916 An experimental study of bone growth in the dog. *Anat. Rec.*, vol. 10, p. 234.  
THOMA, R. 1907 Synostosis suturae sagittalis cranii ein Beitrag zur Histomechanik des Skelets und zur Lehre von dem interstitiellen Knochenwachstum *Virchow's Archiv.*, vol. 188, p. 248.

## SEX STUDIES

### IX. INTERSTITIAL CELLS IN THE REPRODUCTIVE ORGANS OF THE CHICKEN<sup>1</sup>

ALICE M. BORING AND RAYMOND PEARL

SIX FIGURES

#### I. INTRODUCTION

Two papers in this series have already dealt with the interstitial cells in the reproductive organs of the chicken. (Boring, and Pearl and Boring, '12). Further work has substantiated our former conclusions except that a few interstitial cells have been found in just hatched male chicks. We give these further facts here, together with a brief review of some of the literature on interstitial cells. These cells have been much under discussion, not only as to their origin and function, but even as to their very existence. They have been studied much more in mammals than in birds, but they have been recorded in some species of all classes of vertebrates. We are not concerned here with the question of their origin, but with that of their nature and distribution.

The term interstitial cells is used by most writers to designate cells lying in the connective tissue of the gonad and functioning as gland cells to form some sort of an internal secretion. Some writers use the term indiscriminately for all the tissue that fills in between the germ cells. Limon and Bouin used the term interstitial gland for the combination of these gland cells in any one reproductive organ. The reason for so doing is that the cells are found filled with granules of fat and protein in the manner of gland cells. Many investigators have attributed to this internal secretion the function of controlling the development of

<sup>1</sup> Papers from the Biological Laboratory of the Maine Agricultural Experiment Station, No. 114.

secondary sex characters. Limon, Bouin, Regaud, Cesa-Bianchi and Hanes are some of the names associated with this theory. Their evidence is based on observation, experiment and certain pathological cases where reproductive organs with degenerate germ cells and increased interstitial cells were coupled with sterility and normal sex behavior. Regaud records a decrease in the interstitial gland in isolated rabbits. Cesa-Bianchi records a decrease of these cells in hibernating animals. Ancel and Bouin state that roentgenization of mammalian testes destroys only the germ cells and results in sterility, but does not effect the interstitial cells or the secondary sex characters. Weichelbaum describes a case of alcoholism in which the seminal tubes were degenerated, but the interstitial cells increased in number. Des Cilleuls claims that the interstitial cells first make their appearance in the chick at thirty days after hatching, and that this time coincides with the appearance of the secondary sex characters. Regaud and Hanes both connect the time when these cells are most abundant and secreting most actively with the time of greatest sex activity and the development of the secondary sex characters. So various observational and experimental facts seem to substantiate this theory.

However, there is a great body of facts which do not fit in with this theory at all, and there are many other theories proposed as to the functions of these cells. Pflüger, van Beneden, Plato and Winiwarter, interpret the material with which these cells are packed as food material destined for the nutrition of the germ cells. Wallart finds them best developed from birth to puberty and suggests that they have a trophic effect on the circulation. Jardy credits them with a general trophic effect on the nutrition of all tissues. Winiwarter finds the interstitial cells in the human testis better developed in the foetus than in the mature individual, and even found them entirely degenerating in an individual forty-one years of age. He speaks of their secretion as the expression of an overactivity of cells destined for nutrition. Marshall and Jolly suggest that an internal secretion is formed by "the follicular epithelial cells or the interstitial cells of the stroma," in the mammalian ovary and is the cause of



heat. Pardi claims that the interstitial gland is necessary for the control of the growth of the embryo in conjunction with the corpus luteum, during the first half of the period of gestation, and entirely during the later part of gestation. He finds that the interstitial gland in the female increases in size at puberty and decreases in old age, and claims that this is connected with its influence on the nutrition of the embryo, rather than on the development of the secondary sex characters. Pearl and Surface describe interstitial cells in the normal cow ovary and in a cystic ovary of a cow which took on male secondary sex characters. In this case the interstitial secreting mechanism was the same in both animals. Therefore the change in secondary sex characters could not reasonably be ascribed to a secretion from these cells.

So much for the hypotheses about the functions of the interstitial cells. The facts about their very existence are even more at variance than the statements and theories of the above authors indicate. Fraenkel studied the ovaries of 46 different mammals and found interstitial cells present in only 22 of these species. Schaefer continued this study, working on 50 ovaries, 11 of which belonged to species already studied by Fraenkel. She also found great variation in the presence of the interstitial gland. It is not consistently present in any one order of mammals, being absent for instance, in 6 out of 11 Carnivora studied. Further, it is not consistently present even in one species, as Schaefer found an interstitial gland in 3 species where Fraenkel found none. Aimé reports it lacking in the sheep and pig. Busquet makes the general statement that the interstitial gland does not exist in the ovary of all species of mammals. Kingsbury studied the ovary of the cat, and reports great variation in the number of interstitial cells present at all different ages. He calls them "modified free lipoid-containing stroma cells." He fails to find "any peculiar relation of the interstitial cells to either blood vessels or lymph vessels" and concludes that the "interstitial cells possess no morphological individuality and hence do not deserve recognition as a distinct kind of cell." Mazzetti has studied interstitial cells in the testes of many

kinds of vertebrates and finds such great variation in the quantity of them present that he concludes that they can have nothing to do with secondary sex characters. Kirkbride records a wide difference in quantity in human testes of the same age. These facts would seem to justify Fraenkel's conclusion that "a gland existing for the specific purpose of forming a substance of very distinct value to the organism as a whole would be more constant in its presence and development."

So much for the general conflicting theories and facts about interstitial cells. These apply more particularly to mammals, but interstitial cells have been described in both male and female birds. Waldeyer first mentioned them in 1870. In hens, Ganfini describes them as found sparsely in the ovarian stroma, but abundantly in the theca interna of the follicles. He says they are characterized by granules, some of which stain with osmic and some with safranin or fuchsin. He figures two different kinds of interstitial cells, some packed with granules which stain easily, and some with protoplasm which appears clear and vacuolated. His drawings show only the nests of clear cells in the theca interna of the follicle. From the work of the present authors (cf. X and XI of these Studies) it would appear that these two kinds of cells have an entirely different function and fate. The clear cells are never loaded with acidophile granules and are therefore not the glandular interstitial cells. Loisel describes interstitial cells in the connective tissue between the follicles of the ovary, containing fat granules which stain black with osmic. He thinks the ovaries are primarily glandular in function and have acquired their function of forming eggs secondarily. Sonnenbrodt figures nests of interstitial cells in the follicular theca of the hen's ovary. These appear to have a vacuolated cytoplasm, there being no indication in the figures of stained granules. These resemble the clear cells described by Ganfini. In female hybrid birds Poll describes masses of epithelial interstitial tissue, which is glandular, while there is no trace of egg formation. Smith finds groups of interstitial cells in hybrid female pheasants, but no ova. No investi-

gator, in fact, seems to deny the presence of interstitial cells in the female bird.

In male birds, however, there is a difference of opinion as to the presence of interstitial cells. Ceni records an interstitial gland in male ducks. In birds from which he removed the cerebral hemispheres, the interstitial tissue increased coincidentally with the decrease of the seminal tubules, but the secondary sex characters remained undeveloped. He does not state whether this hypertrophied interstitial tissue is connective tissue or gland cells. It is interesting to compare these results with those of Myers on white rats with the vas deferens ligated. He finds that the seminal tubules degenerate, while the interstitial tissue remains unaffected. He states that the interstitial tissue apparently increased in quantity, but this apparent increase was merely apparent, due to the degeneration and shrinkage of the tubules. Poll records one case of a male hybrid with a large interstitial gland. Loisel says that the cells of the testis show no glandular activity, in fact, even disappear during spermatogenesis. Mazzetti pictures a small group of interstitial cells in a triangular space between the seminal tubules of the chicken, but says they are rare even though this bird has very marked secondary sex characters. Des Cilleuls records them as being first found in the chicken at about thirty days after hatching, and claims that this time coincides with the time of the first appearance of secondary characters. It may be of interest to recall here that Barred Plymouth Rocks can be correctly sexed at hatching on the basis of external appearance only. Reeves studied chicken testes of three, five and a half, nine and eighteen months, and claims to find interstitial cells in all of them, but more at three and five and a half months than later. He tested them by staining the granules with Mallory's connective tissue stain, iron haematoxylin and Sudan III.

In a previous study, one of the present authors (A. M. B.) has claimed that no cells of a glandular nature could be found in the chicken testis. In view of these conflicting statements it has seemed worth while to take up this study again on both male and female birds.

## II. MATERIAL AND METHODS

In the previous study of testes, material preserved in Gilson was stained with iron haematoxylin or Delafield's and orange G, and some material put up in Flemming was cleared in chloroform and mounted in chloroform balsam in order not to dissolve the fat blackened by the osmic. Other staining methods have been used this time. Several of the differential stains for secretion granules were tried out and finally two adopted which have been used by Whitehead, Benthin and other workers on the interstitial cells of mammals; Mann's methyl blue and eosin and Mallory's connective tissue stain. Both of these give a striking differentiation. With Mann's stain granule-laden cells stand out as reddish purple spots in the midst of a pale blue or lavender background, while blood corpuscles take the red eosin color. With Mallory's stain, the gland cells are purplish red, the corpuscles orange or bright red and the background is a bright blue. These stains react with granules of a protein nature, and the reaction is perfectly well defined. There is no possibility of missing secreting cells when these stains are used, if there are any in the material. Tests for granules of a fatty nature were not made at this time, as this had been tested in the previous study of interstitial cells in the chicken testis and had given negative results. Whitehead finds the fat content in mammals much more variable than the protein, there being no fatty secretion at all in the pig.

The ovaries used for this study were from four actively laying birds, one of which was a bantam and the other three Barred Plymouth Rock, one old Campine which had stopped laying some time previously, and several just hatched chicks and guineas. For most of these any small piece of the ovary was sectioned, but with one Barred Plymouth Rock the discharged follicles of various sizes were sectioned separately.

## III. INTERSTITIAL CELLS OF THE OVARY

The differential stain showed immediately that there is an abundance of glandular cells in all the mature ovaries. No such cells, however, were differentiated in the just-hatched chicks or guineas. These cells may be scattered through the stroma but occur chiefly near the periphery. They may occur a few near each other (fig. 1) or they may be packed so thickly in one place that they color the whole region red to a glance with a low magnification (fig. 2). In the sections of discharged follicles of different ages they show especially on the surface of the stalk of the follicle. There are no more of them on the old discharged follicles than on the recently discharged ones. In all these ovaries, the clear cells described by Ganfini were quite conspicuous, but they seemed to be an entirely distinct type of cell from the interstitial cells and were seldom found in the same location. The one place where they come in contact with each other was in the mass of cells filling up some of the old discharged follicles.

A study of the cytology of the individual interstitial cells (fig. 3) shows them to be essentially the same as those described in the cow ovary by Pearl and Surface. There cannot be the slightest doubt of the homology of these cells in birds and mammals. They are roundish cells scattered individually through the connective tissue, that is, never arranged in nests together. The nucleus is small and stains intensely. The structure of the cytoplasm is completely obscured by the mass of granules in the cells. These granules are fairly large in proportion to the size of the cell as shown in figure 3. The granules take any acid stain, eosin, orange G, or acid fuchsin, and stain black with iron haematoxylin.

It is difficult to compare the ovaries as to the quantity of interstitial cells without sectioning the entire ovary of each bird, for they are more abundant in irregular regions of the surface. But in the old Campine which had stopped laying, there were more interstitial cells to be found in the more central parts of the ovary than in the younger birds, while there were as many on

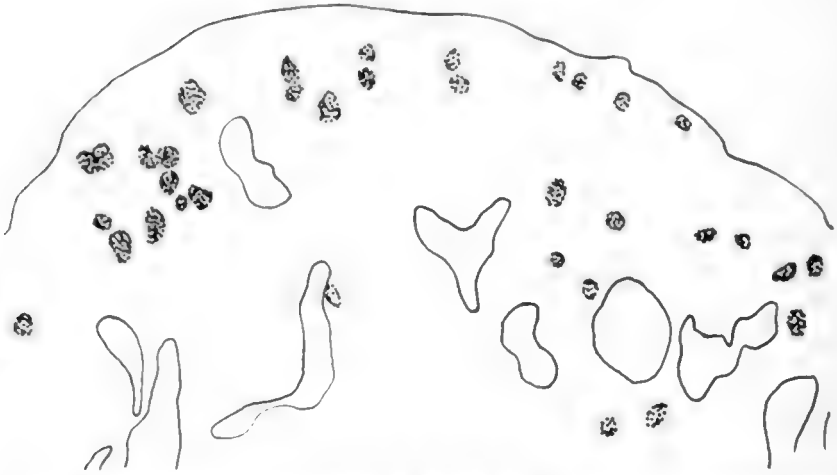


Fig. 1 From periphery of ovary of laying hen. Glandular interstitial cells sparsely scattered.  $\times 264$ .

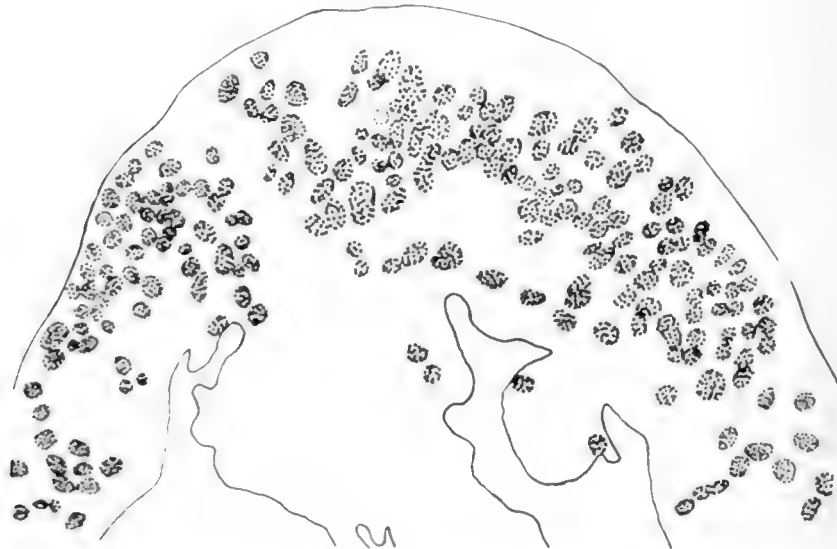


Fig. 2 From periphery of ovary of same laying hen as figure 1. Glandular interstitial cells packed close together.  $\times 264$ .

the surface, so that it seems probable that the total quantity is greater in the old bird (fig. 4). This is in accord with the findings of Kasai in human material. The results of Harms, however, appear to indicate that it can by no means be a general rule that these interstitial cells are more abundant at higher ages.

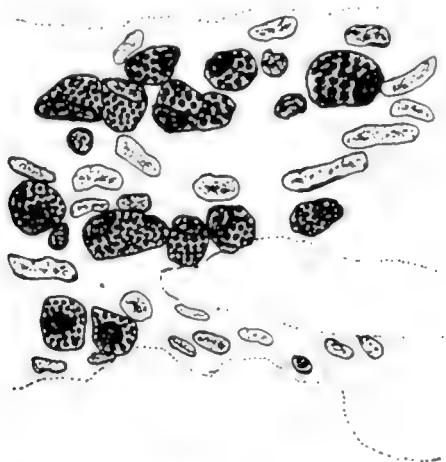


Fig. 3 Interstitial cells from ovary in figure 2.  $\times 950$ .

#### IV. INTERSTITIAL CELLS OF THE TESTIS

The same staining tests for gland cells were applied to the chicken testis. It will be recalled that 21 male birds had previously been studied for interstitial cells. These were of varying ages, just-hatched, six, eight, ten, and twelve months. More sections were made of some of this same material, and they were stained according to Mann's and Mallory's methods. Also preparations were made of a whole new series of birds from six to eighteen months old, and of a few more newly hatched chicks. This new series was prepared as part of an extensive investigation which one of us (R. P.) has under way in which data regarding the testis in monthly phases of its cyclical changes for an entire year will be studied. The material comprised sections

of the testes of 43 birds. Three or four of these birds were killed every month, the youngest group at six months, and the oldest at eighteen months. This entire series was stained for gland cells and examined carefully, and none of the mature birds, either the new ones, or those used before, showed any secreting interstitial cells. However, in the testes of four

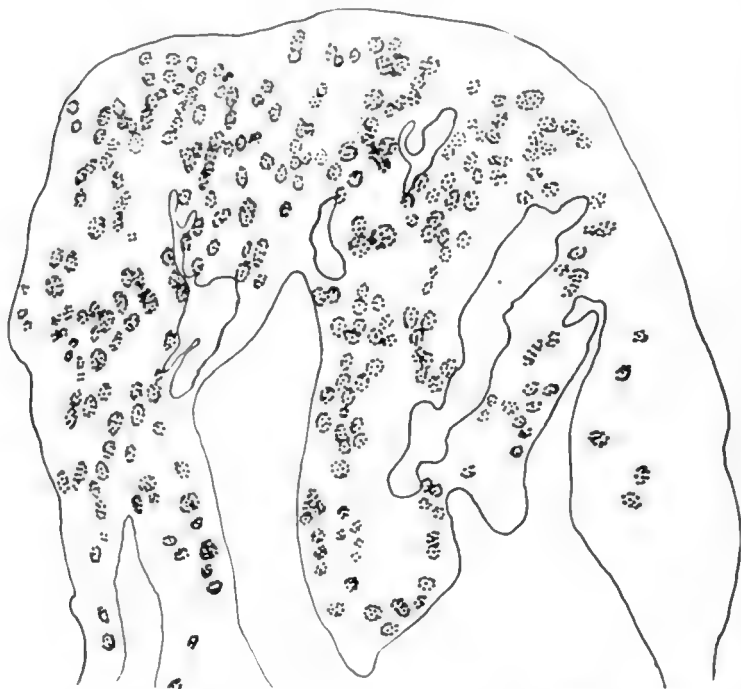

Fig. 4 From periphery of ovary of old hen past laying. Interstitial cells numerous at periphery and into central stroma.  $\times 264$ .

newly-hatched chicks some granule-laden cells were found, staining reddish purple as in the ovary. These were perfectly easy to recognize although they were found in only a few regions of the testis. They were usually grouped, several near each other, but sometimes a single cell stood by itself. (fig 5). Studied under higher magnification, these cells appear a little larger and rounder than those in the ovary (cf. figs. 4 and 6).



They contain fewer granules and these granules vary in size. The nuclei closely resemble those of the connective tissue in which they lie embedded. This investigation, then, shows interstitial cells present in the newly hatched chicks studied, but not in any of 60 mature birds though they were of various ages.

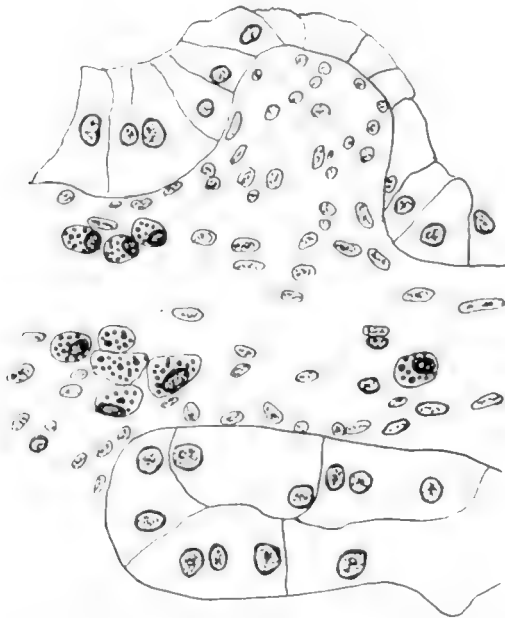


Fig. 5 From testis of just hatched chick. A few interstitial cells in connective tissue between seminal tubules.  $\times 264$ .

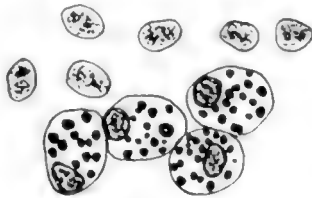

Fig. 6 Interstitial cells from testis in figure 5.  $\times 950$ .

## V. DISCUSSION

There are several possible explanations for the conflicting results of Mazzetti, des Cilleuls, Reeves, and the present authors. Interstitial cells are reported present and absent for male birds of practically every age. Des Cilleuls says they first appear at thirty days, while the only birds in which the present authors find them are just-hatched chicks. Reeves finds them at all ages, but most abundant at three and one-half and five months. Mazzetti reports them in mature birds, but says that they are rare. So they possibly may be present in male birds of any ages, but are much more frequently absent, and are, therefore, not a necessary component of the testis structure. However, it must be emphasized that the only way to be sure of interstitial cells is to use a differential stain, and then one can not fail to identify them. Neither Mazzetti nor des Cilleuls did this. It is very easy to be misled by small pieces of tubules being surrounded by connective tissue. We have observed several such places in our preparations, which resemble some of the illustrations of groups of interstitial cells. Reeves, however, used Mallory's and Mann's stains. It is interesting that he found more such cells in young birds than in mature ones in view of the fact that we have found none in such a large series of mature birds.

It appears to be definitely established that true interstitial cells are always present in the ovary. The situation appears to be very different than in the case of the testis, not only with reference to birds but to mammals also.

A point which we would emphasize, on the basis of our studies of these cells in mammals as well as in birds, is that there appears to be no doubt that the true interstitial cells are not merely homologous but indeed structurally (i. e., cytologically) identical in the male (when present) and the female. This view was expressed by Plato ('97) and we are in entire agreement with it. This point has an important bearing on the question of the influence of these cells in sex determination (cf.

Harms) and in the control of secondary characters. It will be fully discussed in a later paper in this series.

We hope to study a series of testes from the time of hatching up to six months, in order to complete the series, and clear up these points of difference finally. The discrepancy between our results for mature birds and those of Reeves is absolute. We have no desire to question the accuracy of his observations, and on the other hand we are entirely sure of, and indeed are prepared to demonstrate, the absence of these characteristic interstitial cells in our material. For just hatched chicks we agree, interstitial cells are present in the testis. The next step is to find out when between hatching and six months, they disappear. This we hope to do later.

For the present the essential point which we wish to emphasize, and which we believe that our results demonstrate, is that the characteristic, true interstitial cells are neither a necessary nor a constant element in the make-up of the testis in the male of the domestic fowl. They may be, and usually are, totally absent from the testes of males over six months of age and of full sexual normality, both in respect of primary and secondary characters. It suffices here to draw attention clearly to this fact, which emerges with great definiteness not alone from our own work, but also from a review of the literature of the subject. Later we expect to make constructive use of this evidence in connection with the problem of the causation and control of secondary sex characters. Without entering upon any discussion of the matter now it is evident that the facts regarding the occurrence and distribution of interstitial cells are such as to make it very difficult to suppose that they have any causal influence upon secondary sex characters.

## VI. LITERATURE CITED

- BAYLISS AND STARLING. 1906. Der Chemische Koordination der Funktionen des Körpers. *Erg. d. Physiol.*, Bd. 5, p. 664.
- BENTHIN, W. 1911. Ueber Follikelatresie in Säugetierovarien. *Arch. f. Gynäkologie* 94, p. 599.
- BORING, A. M. 1912. The interstitial cells and the supposed internal secretion of the chicken testis. (Sex Studies, III). *Biol. Bulletin*, vol. 23, pp. 141-153.
- BOUVIN AND ANCEL. 1903. Recherches sur les cellules interstitielles du testicule des mammifères. *Arch. de zool. exp.*, T. 1, p. 347, Series 4.  
1904. Recherches sur la signification physiologique de la glande interstitielle du testicule des mammifères. *Jour. de physiol. et de path. gen.*, T. 6, p. 1012.
- BUSQUET, H. 1910. La secretion interne de l'ovarie. *Biol. Med.*, T. 9, p. 89.
- CENI, C. 1909. L'influenza del cervello sullo sviluppo e sulla funzione degli organi sessuali maschili. *Rivista sper. di Frenatria*, S. 35, p. 3.  
1909. L'influenza di alcune sostanze d'azione prevalentemente cerebrale sulla funzione dei testicoli (Caffè, Veronal e Absinthe). *Riv. sper. di Frenatria*, 35, p. 3.
- CESA BIANCHI, D. 1908. Die alcune particolarità di struttura dei fenomeni di secrezione del corpo luteo. *Internat. Monatschr. f. Anat. u. Physiol.*, S. 25, pp. 1-43.
- DES CILLEULS, J. 1912. Interstitial testicular cells and secondary sex characters. *C. R. Soc. Biol.*, vol. 73, pp. 371-372.
- FRAENKEL, L. 1905. Verg. histol. Untersuchungen über das Vorkommen drüsigen Formationen im interstitiellen Eierstocksgewebe. *Arch. f. Gynäk.*, Bd. 75.
- GAMMA, CARLO. 1913. Sul comportamento delle cellule interstiziali del testicolo negli stati morbosi generali dell'organismo. *Arch. per le Sci. Med.*, S. 37.
- GANFINI, C. 1908. Sulla struttura e sviluppo delle cellule interstiziali dell'ovajo. *Arch. di Anat. e di Emb.*, S. 7, p. 373.
- HANES, F. M. 1911. Relations of interstitial cells of Leydig to production of an internal secretion by mammalian testis. *Jour. Exp. Med.*, p. 338.
- HARMS, W. 1911. Experimentelle Untersuchungen über die innere Sekretion der Keimdrüsen und deren Beziehung zum Gesamtorganismus. Leipzig.
- KASAI, K. 1908. Ueber die Zwischenzellen des Hodens. *Virchow's Archiv.*, Bd. 194, p. 1.
- KINGSBURY, B. F. 1914. The interstitial cells of the mammalian ovary: *Felis domestica*. *Am. Jour. Anat.*, vol. 16, p. 59.
- KIRKBRIDE, MARY B. 1911. Embryogenic disturbance of the testis. *Arch. Entw. Org.*, Bd. 32, p. 717.
- LOISEL, GUSTAVE. 1903. Elaborations grassieuses periodique dans le testicule des oiseaux. *Comp. Rend. de l'Association des Anatomistes*, 5th Session. Liege, T., p. 222.

- LOISEL, GUSTAVE Les phénomènes des sécrétion dans less glandes genitales. Revue generale et faits nouveaux. Jour. de l'Anatomie et de la Physiologie 40th Anne, No. 5, p. 536.
- MARSHALL, F. H. A. AND JOLLY, W. A. 1905 Contributions to the physiology of mammalian reproduction. Part I. Oestrous cycle of a dog. Part II. Ovary as an organ of internal secretion. Phil. Trans. Roy. Soc., Series B. 198, pp. 99-141.
- MAZZETTI, LORETTO 1911 I caratteri sessuali secondari e le cellule interstiziali del testicolo. Anat. Anz., 8. 38, p. 361.
- MYERS, B. D. 1915 Histological changes in testes following vasectomy. Anat. Rec., vol. 10, p. 228.
- PARDI, U. 1914 Osservazioni sulle cellule interstiziali ovariche della coniglia e sougli elementi della teca interna dell' ovaio muliebree al di fuori e durante la stato di gravidanza. Arch. di Biologie normale et Path. yr. 68.
- PARDI, U. 1914 Sur la fonction endocrine de l'ovaire durant la gestation. Arch. Ital. de Biologie, T. 61, p. 1.
- PEARL, R. AND BOHING, A. M. 1912 Fat deposition in the testis of the domestic fowl. (Sex Studies IV). Science, N. S., vol. 36, pp. 833-835.
- PEARL, R. AND SURFACE, F. M. 1915 Sex Studies. VII. On the assumption of male secondary characters by a cow with cystic degeneration of the ovaries. Ann. Rept. Me. Agr. Expt. Stat., 1915, p. 65.
- PLATO, J. 1896 Die interstitiellen Zellen des Hodens und ihre physiologische Bedeutung. Arch. f. Mikr. Anat., Bd. 48, p. 280.  
1897 Zur Kenntnis der Anatomie und Physiologie der Geschlechtsorgane. Arch. mik. Anat., Bd. 50.
- POLL, H. 1911 Mischlingstudien VI. Eierstock u. Ei bei fruchtbaren u. unfr. Mischlingen. Arch. f. Mikr. Anat., 78. Pt. II, p. 63.  
1906 Der Geschlechtsapparat der Mischlinge von Cairina moschata ♂ und Anas boschas ♀. Sitzber. der ges. nat. Freunde, Nr. 1, Jahr. 1906, p. 4.
- POLL, H. AND TIEFENSEE, W. 1907 Mischlingstudien: die Histologie der Keimdrüsen bei Mischlingen. Sitzber. der ges. Nat. Freunde, Nr. 6, Jahr. 1907, p. 157.
- POPOFF, N. 1911 [Interstitial tissue and corpus luteum of the ovary.] Arch. Biol., vol. 26, p. 483.
- REEVES, T. P. 1915 On the presence of interstitial cells in the chicken's testis. Anat. Rec., vol. 9, p. 383.
- REGAUD, C. AND DUBREUIL, G. 1909 Nouvelles recherches sur les modifications de la glande interstitielle de l'ovaire, consecutives a l'isolement et a la cohabitation avec le male. Comp. Rend. Soc. de Biol., T. 67, p. 348.
- SCHAEFFER, ANNA 1911 Vergleichend histologische Untersuchungen über die interstitielle Eierstockdrüse. Arch. f. Gynäkologie, Bd. 94, p. 1.
- SONNENBRODT 1908 Die Wachstumsperiode der Oocyte des Huhnes. Arch. f. Mikr. Anat., Bd. 72, p. 415.
- VAN DER STRICHT 1912 Corpus luteum and interstitial gland of the ovary. Arch. Biol., vol. 27, pp. 585-722.

- WEICHELBAUM AND KYRLE 1912 [Changes in testes in chronic alcoholism.]  
SB Akad. wiss. Wien., vol. 121, pp. 51-67.
- WHITEHEAD, R. H. 1905 Studies of interstitial cells of Leydig. II. Their  
postembryonic development in a pig. Am. Jour. Anat., vol. 4, p. 193.  
1912 On the chemical nature of certain granules in the interstitial  
cells of the testis. Am. Jour. Anat., vol. 14, p. 63.
- WINIWARTER, H. VON 1912 Observations cytologique sur les cellules inter-  
stitielle du testicule humain. Anat. Anz., Bd. 41, p. 309.

## PHAGOCYTOSIS BY OSTEOCLASTS

LESLIE B. AREY

*From the Anatomical Laboratory of the Northwestern University Medical School<sup>1</sup>*

### FOUR FIGURES

The multinucleate giant cells associated with developing bone have usually been considered as the causative agents of bone resorption, and for this reason have been termed osteoclasts. There is, however, no direct evidence that these polykaryocytes so function. The writer ('17) has contended that they may be interpreted equally well as degenerating, fused osteoblasts.

Evans and Schulemann ('14) were able to show that various cells of the body are vitally 'stained' by certain benzidine dyes. Although anatomically distinct these cells hold in common this staining response, which involves a phagocytosis of the dye granules, differing in no essential respect from the ordinary ingestion of débris by such cells in the exercise of their customary scavenger activities. It has been suggested that cells responding in such a fashion to these dyes constitute a physiologically homogenous group and can be designated macrophages.

Recently Shipley and Macklin ('16) have attempted the vital staining of osteoclasts. It was thought that since Goldmann ('12) found the pathological giant cell of experimental tuberculosis to react avidly to benzidine dyes, the anatomically similar osteoclast, with its alleged bone resorptive function, would presumably ingest the dye also. Contrary to expectations the osteoclasts of young animals, vitally stained with trypan-blue, did not take up the dye at all. The conclusion is drawn that since the osteoclasts are non-trypanophilic they are likewise non-phagocytic, any office they may perform in bone destruction being through the pressure of their bodies or by the production of a dissolving secretion. Foreign inclusions in the cytoplasm

<sup>1</sup> Contribution No. 50, May 30, 1917.

were not observed. The ordinary reticulo-endothelial cells of the marrow, on the contrary, did stain with the dye and are identified as the elements which phagocytose the residuum of bone dissolution.

It is important to keep sharply differentiated questions as to the alleged relation of osteoclasts to bone resorption from those concerning their phagocytic activity. The absence of coarse debris in the cytoplasm does not of itself imply that the osteoclasts do not resorb bone; presumably bone destruction is essentially of a dissolving and digesting nature, the end products not improbably being rather finely divided particles.<sup>2</sup> On the other hand, the presence of cytoplasmic inclusions does not indicate that the osteoclasts are actually responsible for the occurrence of the material ingested.

In a former communication (17) I have held that the osteoclasts may be interpreted as syncytial masses derived from depleted osteoblasts whose staining reaction has become oxyphilic. In that study it became evident that the osteoclasts increase in size both by incorporating new osteoblasts with which they come in contact and by ingesting the bone cells laid bare by resorptive processes. Whether or not the first method of growth is one of phagocytosis, the second unquestionably is such. The bone cell, usually enveloped by an acid-resistant capsule, constitutes a foreign body of relatively large size, and all stages of its inclusion by the osteoclast may be found in favorable material.

Figure 1 shows an elongated process of an osteoclast merely in contact with one side of a bone cell. The engulfment has proceeded to such an extent in the stages depicted by the two photographs (figs. 2 and 3) that the encapsulated bone cells are half within and half without their respective osteoclasts; these reproductions illustrate but poorly the striking appearance of such preparations. Encapsulated, stellate cells are not infrequently found in the cytoplasm of osteoclasts (fig. 4); these are interpreted as bone cells whose capsules are still resistant to cytoplasmic digestion. From the relative infrequency with

<sup>2</sup> It is, nevertheless, possible to find eroded spicules apparently entirely free and completely enveloped by large osteoclasts.



which persistent capsules are seen it is probable that the enclosed cells are eventually liberated.

It is apparent from the foregoing account that the osteoclasts exhibit all stages which we are accustomed to accept in microscopical preparations as evidential of phagocytic activity. For this reason the failure of cells to absorb such vital dyes as trypan-

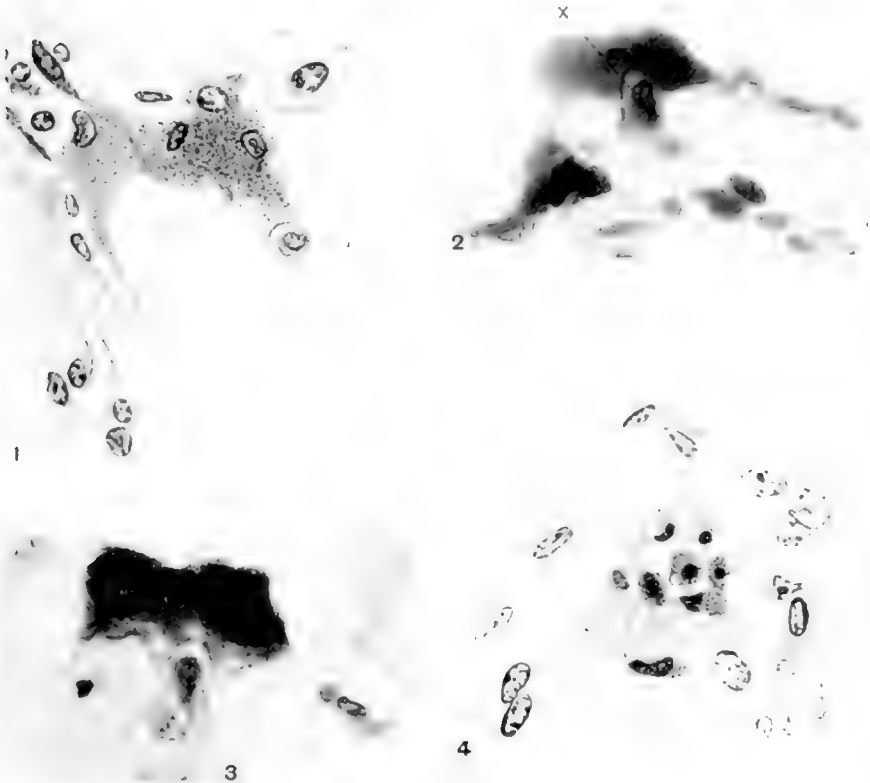


Fig. 1 A first stage in the engulfment of a bone cell by an osteoclast. A process of the granular osteoclast is in contact with the bone cell *x*.  $\times 785$ .

Fig. 2 The encapsulated bone cell *x* is half ingested by an osteoclast which lies on a spicule of bone. Only a portion of the entire osteoclast appears in this section. Photograph.  $\times 650$ .

Fig. 3 A stage in osteoclastic phagocytosis similar to that of figure 2. The bone cell is half within and half without the osteoclast. Photograph.  $\times 650$ .

Fig. 4 Two encapsulated, stellate cells lie within the cytoplasm of the osteoclast. These inclusions are interpreted as phagocytosed bone cells.  $\times 785$ .

blue would seem not to warrant the denying to them of phagocytic activity; here in the osteoclast is a type of cell which demonstrably engulfs large bodies yet fails to ingest the finer dye particles. Evans and Schulemann ('14) have likewise pointed out that none of the blood cells, even those that are notably phagocytic, take up the vital dyes; Downey ('17), on the contrary, finds that such dye particles are phagocytosed by leucocytes under especially favorable conditions.<sup>3</sup>

#### SUMMARY

Irrespective of questions as to the causative agents of bone resorption it is demonstrable that the osteoclasts phagocytose bone cells laid bare by the resorptive processes.

Hence the reported failure of osteoclasts and leucocytes to stain after ordinary treatment with vital dyes, such as trypan-blue, indicates that this negative reaction can not be relied upon to furnish final evidence concerning the absence of phagocytic activity.

#### LITERATURE CITED

- AREY, L. B. 1917 On the origin and fate of the osteoclasts. *Anat. Rec.*, vol. 11, no. 6, pp. 319-322.
- DOWNEY, H. 1917 Reactions of blood and tissue cells to acid colloidal dyes under experimental conditions. *Anat. Rec.*, vol. 12, no. 4, pp. 429-454.
- EVANS, H. M. AND SCHULEMANN, W. 1914 The action of vital stains belonging to the benzidine group. *Science*, n. s., vol. 39, pp. 443-454.
- GOLDMANN, E. E. 1912 Die äussere und innere Sekretion des gesunden und kranken Organismus im Lichte der vitalen 'Färbung.' Teil II. *Beiträge z. klin. Chirurg.* Bd. 78, pp. 1-108.
- SHIPLEY, P. G. AND MACKLIN, C. C. 1916 Some features of osteogenesis in the light of vital staining. *Amer. Jour. Physiol.*, vol. 42, no. 1, pp. 117-123.

---

<sup>3</sup> It is worth considering whether the factors emphasized by Downey as responsible for the ordinary failure of leucocytes to react to the dye are not at least in part operative in the case of the osteoclast.

## THE ANATOMY OF A DOUBLE PIG (SYNCEPHALUS THORACOPAGUS)

S. R. WILLIAMS AND R. W. RAUCH

*Miami University, Oxford, Ohio*

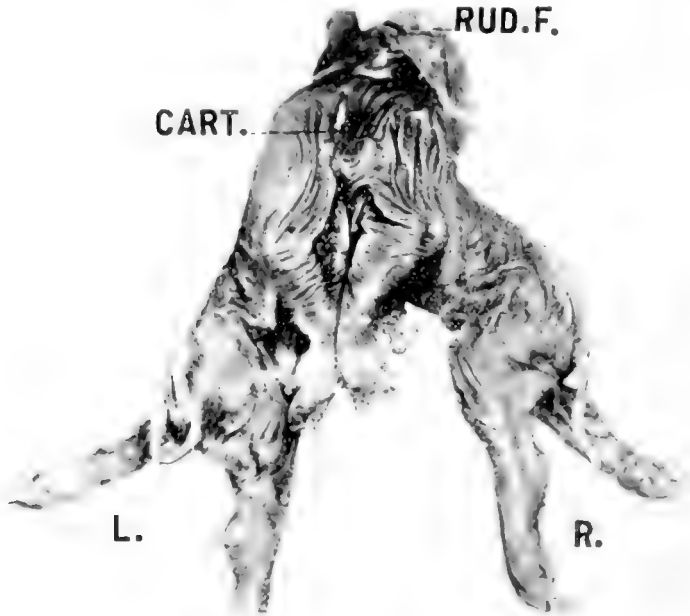
SEVEN FIGURES

In 1895, a double pig was born dead on the farm of Craig Brothers, Oxford, Ohio, breeders of Poland China stock. The specimen was collected by Prof. A. L. Treadwell and left in the laboratory of Miami University. Except for opening the body cavities no work was done on the pig until in the fall of 1916. The appearance of the article on a monster pig by Carey in *The Anatomical Record* on February, 1917, renders a detailed description of our specimen unnecessary. We present, therefore, a brief outline only, describing the peculiarities of this double monster.

Figures 1 and 2 are photographs of the animal from the dorsal and the ventral sides. As in Carey's specimen there has been a separation of the growing points of the embryo into two parts, probably two primitive streaks formed side by side, and then a fusion of the adjacent parts of these two growing points to form the monstrosity.

According to Adami and McCrae, p. 68, in double monsters there is first of all a complete cleavage and then a secondary fusion of contiguous parts. This results in this case in the production of a mono-symmetrical janiceps with a perfect ventral face and a rudimentary dorsal face not recognizable as such. The fusion continues through the thoracic region but the bodies are separate above the abdomen and as nearly as we can tell from the specimen (which was opened in 1895) there are two umbilical cords. This, however, is not certain. The reception of two blood supplies from the mother is exceptional.

The urinogenital organs are paired and normal in each body. The specimen is of the male sex. In the pig described by Carey, the heads are fused side by side with one head turned to the left and one to the right. If the head of our specimen has been formed in the same way, there has been a much greater degree of regulation, the essential suppression of the face turned to the



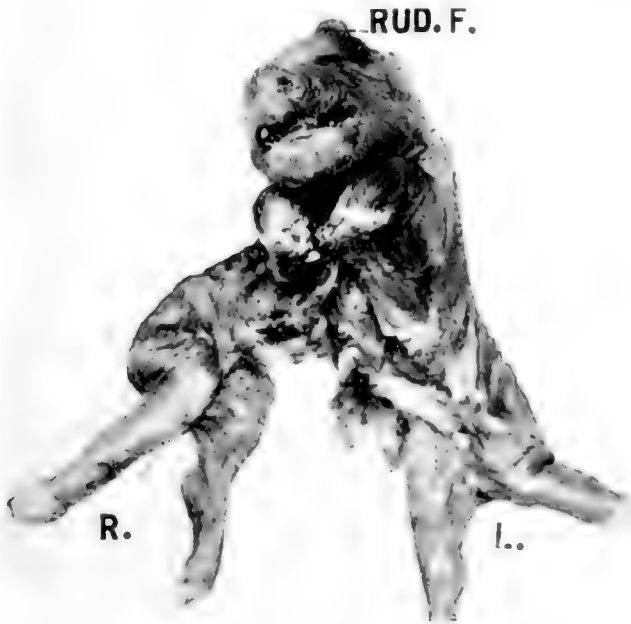
## ABBREVIATIONS

- |  |   |
|--|---|
| <i>Ao.R.</i> , right aorta   | <i>Par.</i> , partition in roof of mouth from 'dorsal' to 'ventral' |
| <i>Ao.L.</i> , left aorta  | <i>Pul.L.</i> , left pulmonary artery from left aorta               |
| <i>A.V.C.</i> , anterior vena cava   | <i>Pul.R.</i> , right pulmonary artery from right aorta             |
| <i>Card.</i> , cardiac end of stomach  | <i>P.V.C.</i> , posterior vena cava                                 |
| <i>Cart.</i> , cartilaginous bond between the two bodies in the region of the anterior end of thorax (so called dorsal side) | <i>Pyl.</i> , pyloric end of stomach                                |
| <i>Ce.</i> , cecum   | <i>R.</i> , right body  |
| <i>Cleft.</i> , division of anterior end of tongue   | <i>Rud.F.</i> , rudimentary face                                    |
| <i>L.</i> , left body  | <i>Sp.C.</i> , spinal cord, left                                    |
|  | <i>Vert.</i> , atlas and axis of right vertebral column             |

right (dorsal) and the development of the external form of the head with reference to the face turned toward the left (ventral).

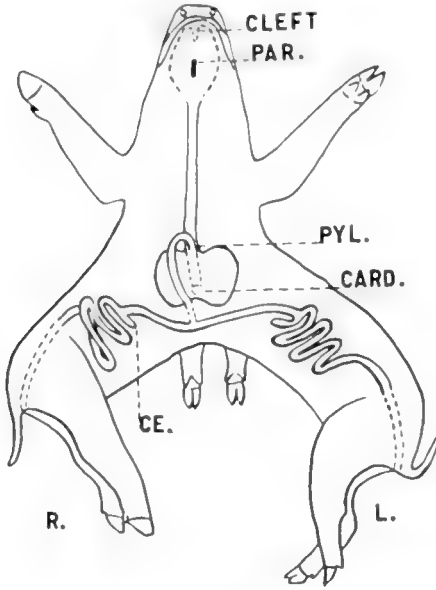
#### ALIMENTARY SYSTEM

Figure 3 is a diagram of the structures of the alimentary system. At the tip, the tongue is double, a cleft extending for a short distance back in the mid line. Further back behind the

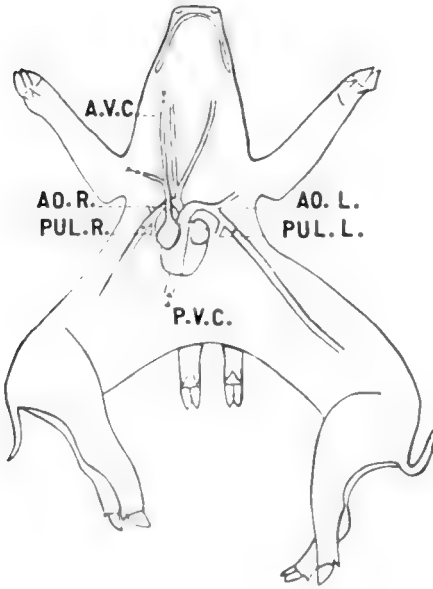


tongue, there is a connective tissue partition which extends from the roof to the floor of the pharynx. The two spaces formed by this partition unite again, when the latter stops, into a small cavity which is continued back as the single esophageal lumen.

The slender tube of the esophagus extends back to an opening on the posterior and dorsal side of the large stomach. This organ has a longitudinal constriction in its middle indicating its double origin. The intestine leaves the anterior ventral side of the stomach and turns posteriorly as a single slender coiled tube 42 inches in length. This connects with a transverse tube,



3



4

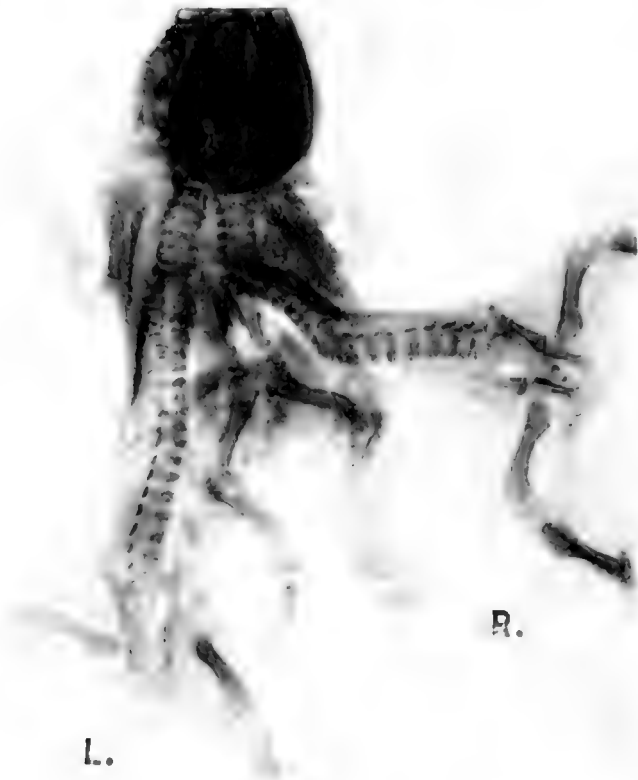at each end of which is a cecum, the beginning of the two large intestines. The large intestine for the left body is  $10\frac{1}{2}$  inches long and the one for the right smaller body is 9 inches in length. There is one spleen found in the body of the left pig. Possibly the fact that the liver mass in the right body is two to three times the volume of that in the left may have to do with the absence of symmetry in the spleen. This explanation will not hold, however, for the pancreas, which, though poorly preserved is single. It lies by the duodenum and in the right body cavity. The liver is all connected dorsally but free ventrally and, as stated above, most of it is on the right side.

#### BLOOD SYSTEM (FIG. 4)

The heart is a fused structure with two large thin walled auricles and two large ventricles with equally thick walls. The auricle of the right side receives directly the single anterior vena cava from the head and anterior extremities. The auricle on the left side is connected with a dorsal sac, possibly a sinus venosus, which also has a passageway into the right auricle. All the blood from the posterior part of both bodies comes into this sinus through a vessel we have called the posterior vena cava.

There is a passage way from each of the auricles into the ventricle of its own side. The ventricles are distinct with a thick partition between and each ventricle sends a large aorta to the body on the opposite side, these aortas crossing just anterior to the heart. The aorta from the left side supplies blood to the head while that from the right side sends no branches farther forward than the fore legs. Possibly this may explain the difference in the size of the two bodies. If approximately half the blood was pumped by each ventricle, the left body would have been better fed since none of its blood is sent to the head.

The aorta to either side sends a branch artery to each fore leg of the body it supplies. These legs are at different levels (figs. 1, 2) and between the two branches of each aorta there is given off a small branch to the lung, a pulmonary artery (fig. 4, *Pul.R*, *Pul.L*). These pulmonary arteries pass to the lung complex which is fused dorsally and free ventrally. On the right side there are three lobes and on the left four lobes of the lung.

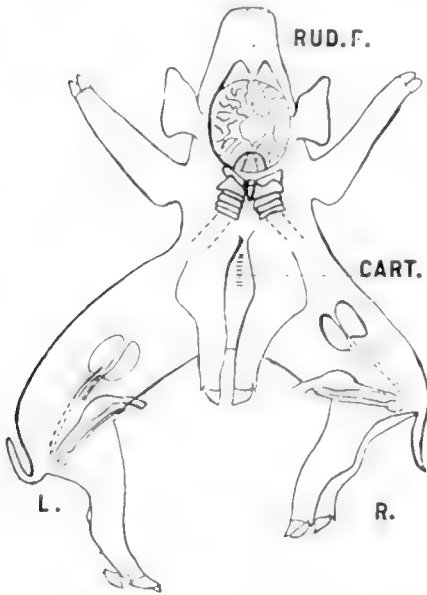


There is but one trachea not two as in the specimen described by Carey.

SKELETON (FIG. 5)

The skull is shaped much like that of a normal pig. On the dorsal side is a fontanelle covered with a mass of wrinkled skin representing the rudiment of a face and bound to the brain by connective tissue strands which are part of the dura mater (Rud F. Figs. 1, 2, 6, 7). There are two separate vertebral columns with three points of attachment to the skull, the central one being common to each column (fig. 6). There is a central bony mass between the two atlases and probably derived from them, which makes part of the middle articulation to the skull. The second and following vertebrae in each body are nearly like those in normal pigs.





6



7

There are thoracic ribs on the dorsal side some of which may connect to the cartilaginous mass (*Cart.*, fig. 6) which connects the two bodies dorsally. It is possible that this is part of a sternum. At any rate, the ventral ribs and sternum are more nearly normal.

#### NERVOUS SYSTEM (FIGS. 6, 7)

The single cerebrum is slightly larger than that of a pig of the same size, having a 'disturbed' area in the region just below the dorsal rudimentary face. In dissecting off the skull cap shown in figure 7 no identifiable brain tissue was cut, simply connective tissue such as composes the dura.

The cerebellum is normally placed and presents three lobes, one median and two lateral. The medullas are fused to each other and from each a normal spinal cord extends posteriorly.

#### SUMMARY

The dissection of this monster pig is presented because it differs in many respects from that described by Carey, in some points being more fused, in others being more distinct.

1. The head is more nearly normal with but two ears, two eyes and two nostrils.

2. The alimentary canal has a divided pharynx, a grooved stomach, a single pancreas and a single spleen.

3. The trachea is single, connecting to a ventrally lobed lung mass.

4. The heart is fused, with a single venous system. The arterial supply of the head is from one side of the heart only.

5. The nervous system is fused to a much greater degree, there being complete separation in the spinal cords and fusion from the medullas anteriorly.

We wish to thank Dr. A. L. Treadwell for the privilege of dissecting the pig, and Dr. J. A. Culler for making the skiagraph.

#### LITERATURE CITED

- ADAMI, J. G. AND McCRAE, J. 1912 A text book of pathology, pp. 759.  
CAREY, E. 1917 The anatomy of a double pig, *Synecephalus thoracopagus* with especial consideration of the genetic significance of the circulatory apparatus. *Anat. Rec.*, vol. 12, pp. 177-191.

## MEMBRANES OF THE RIGHT ILIAC REGION

ROGERS K. OLIVER

*Anatomical Department, University of Colorado*

### HISTORY

There is no place in medical literature where more confusion exists than in the discussion of the membranes and other folds of peritoneum found in the abdominal cavity adjacent to the ascending colon and caecum. Embryologists offer only brief suggestions as to their origin, and anatomists, after describing various caecal bands, and mentioning the ascending meso-colon, are silent. The existence of other so-called membranes had long been recognized by Virchow, Jonnesco, Treves, and others. Professor Binney in 1905, under the name of pericolitis dextra, first described the structure which is now called Jackson's Membrane. Three years later Jabez N. Jackson recognized it as a causative factor of pathological conditions, and wrote his initial article, *Membranous Pericolitis*, in which he ascribed this condition to a membrane which involved the ascending colon.

Other investigators, notably Pileher and Brand, have compiled statistics and theorized in regard to its development and etiology. In 1912, Professor Flint of Yale, offered the first satisfactory theory of its development and it is now generally accepted as a fact that it is a true embryological remnant, which, due to pathological changes in its normal structure, may cause kinking of the ascending colon and angulation of the hepatic flexure. The late recognition of this membrane as a distinct anatomical entity is due to its superficial similarity to the adhesions which are always present in acute and chronic inflammations of the peritoneum, so that earlier writers attributed to it a purely inflammatory origin.

## ANATOMICAL DESCRIPTION

Jackson's Membrane consists of a thin veil-like structure which originates from the postero-lateral abdominal wall, and in some instances from the lateral parietal wall. It is attached to the ventral surface of the ascending colon and caput coli, and rarely involves the caecum or appendix. It usually represents the appearance of a transparent, highly vascular peritoneal fold. In older subjects it is thicker, more fibrous and avascular, and closely resembles an adhesion. Often its point of attachment is irregular and gaps are left between tendinous slips, thus forming digital fossae. In the majority of cases examined in the dissecting room, it seemed to originate a few centimeters above the iliac crest, and to continue for a variable distance along the body wall, finally merging on the inferior surface of the liver with the hepato-renal ligament. Radiating fibers extend both downwards and upwards from this wide origin and usually blend with the anterior longitudinal band of the colon. A free lower margin can be demonstrated in most cases, although sometimes it forms a sac in which the ascending colon is placed. It has been described as extending over to the transverse colon and binding it down so that the latter parallels the ascending colon, forming the so-called, "shot gun bowel." Its blood vessels are unusually large, dilated and unbranched and parallel each other, accompanying glistening tendinous slips. The veins at their points of exit from the wall of the colon are often tortuous and engorged with blood. This characteristic vascular appearance is more marked in young subjects and implies from its arrangement a distinct blood supply. Dissection on the cadaver has substantiated this, and the origin of the vessels has been traced to the second lumbar, and more rarely the renal artery.

## PATHOLOGICAL DESCRIPTION

Only one microscopic examination has been made so far of a colon to which a membrane of this character was attached. Dr. F. J. Hall, the pathologist of the Kansas City General Hospital, under the supervision of J. N. Jackson, made such a report in

which he stated that no evidences of inflammatory processes were noted in the colon and suggested that the presence of many endothelial-clefts in the membrane denoted probably a chronic lymphstasis. A similar section was studied in this laboratory. Very slight inflammatory processes were noted in the colon wall and in the membrane itself. The case, from which the specimen was taken at autopsy, was one in which the patient had died from other causes, but with a history of chronic constipation. This condition was found to have been caused by a sharp constriction at the junction of the descending colon with the sigmoid flexure, and it was evident that this would have been sufficient to cause the conditions already referred to.

#### SIMILAR STRUCTURES

From the above description it is seen why various right sided pericolic bands have been mistaken for the Jackson Veil. Broad membranous adhesions are the most frequent source of error and can be distinguished by their irregular distribution, non-vascularity, and by the unreadiness with which they can be stripped from the colon. Caecal folds and appendiceal ligaments have each their own characteristic origin. An ascending mesocolon which occurs in 26 per cent of all cases is distinguished by its point of attachment. Two additional important points should be noted in the identification of this membrane. First, invariably a large mobile, dilated caecum is associated with it. Second, it can always be demonstrated by dissection as a fold of tissue distinct from the parietal peritoneum.

In relation to the caecum one more fold of peritoneum was noticed, a definite structure which was found in twenty out of twenty-four cadavers in the dissecting room. Its occurrence, in such a high percentage of cases, its regular origin and similarity of appearance makes it highly probable that this is another true anatomical structure. Review of works of anatomy yield no definite information, although other supra-caecal bands are described. Robinson, in 1902, stated that the caecum was fixed by the right phreno-colic ligament, to which this band bears a slight resemblance. It originates on the lateral wall of

the abdomen at a point opposite the iliac crest about 5 to 10 cm. above the anterior superior spine of the ilium and extends transversely over to the ventral surface of the caput coli. The width of its upper margin varies from 1.5 to 3 cm., and when it is made tense by traction on the colon it forms the lower boundary of a depression several centimeters deep. It is evident that when the bowel is dilated at or near the point of insertion, this ileo-colic band will form a definite dam across the right para-colic gutter, and this appears to be not an abnormal condition, for the caecum is freely mobile and dilated in 67 per cent of all cases. This may be a factor significant in relation to the drainage of this area.

#### EMBRYOLOGY

The interdependence of the various developmental processes plays a striking part in the formation of membranes of this nature. It seems probable that viscera, such as the liver, kidney, and ascending colon, aid in shaping the attachments and final position of the Jackson Veil. An element of the utmost importance is the body growth in later foetal life, which takes place principally in the region of the lumbar vertebrae.

Flint has described the Jackson Veil as merely a more complete fusion of the visceral peritoneum with the dorsal parietal peritoneum. These secondary attachments are drawn downwards by the descent and rotation of the caecum into a thin veil-like membrane. More rarely he attributes it to a lateral prolongation of the great omentum. This developmental theory has not been fully substantiated in this laboratory by the dissection of a series of foetuses and one infant at term. It will bear still further elaboration.

Let us first consider the so-called upward migration of the kidney and the descent of the caecum in relation to this membrane. Reviewing briefly the change in position of these structures during intra-uterine life, we find that the kidney in the first half of foetal life lies opposite the first three lumbar vertebrae, while in the second half of the same period the cranial pole rises to the level of the eleventh rib and the caudal pole descends to the upper border of the fifth lumbar vertebra. This is merely

a growth in length. After birth, in children of less than one year of age, in 50 per cent of cases the caudal pole is in the iliac fossa<sup>7</sup> and not until the child is over two year so of age does it rise above the iliac crest. This is purely a passive change which is due to a stronger growth of the posterior abdominal wall in the lumbar-region.

After rotation the large intestine lies transversely along the greater curvature of the stomach with the caecum in the right side in front of the duodenum and closely applied to the caudal surface of the right lobe of the liver and resting on the ventral surface of the right kidney. The descent of the caecum takes place after the third month, and in the fourth month the ascending colon is formed; at the same time fixation of the ascending colon begins and proceeds lateral-wards. The line of attachment is usually an oblique one which extends from the caudal end of the right kidney upwards from right to left. The caecum and ascending colon are originally completely invested with peritoneum. The ascending colon develops in the space made by the rapid growth of the body wall. The height of this area, being increased slightly by the decrease in size of the liver.

The descent of the caecum is relatively a passive one. At the fourth month the transverse colon occupies an oblique position; the caecum (having undergone complete rotation) is to the right, in close approximation to the body wall. At this stage it lies on the ventral surface of the kidney, midway between its two poles. The lower pole of the kidney is still in the iliac fossa. The posterior surface of the caecum has already become firmly attached to the ventral surface of the kidney, but before this peritoneal blending occurs the fixation of the caecum is accomplished by delicate secondary adhesions between the caput coli and the lateral body wall. At the fifth month the caecum lies on the caudal pole of the kidney. Later it descends only to a little lower level, so that the caput coli in the adult lies on the inferior pole of the kidney. The final position and shape of the caecum is determined by the rate of growth of its walls from a fixed point. The postero-lateral wall outstrips the medial one in growth.

The ascending colon is already completely formed but has not yet assumed its final position because of the size of the liver. Its upper three-fourths is unfixed and freely mobile. Extending from its ventral surface to the lateral body wall are secondary veil-like adhesions, closely simulating in their distribution the Jackson Membrane of the adult. It is probable that these adhesions subserve the important function of shaping the final position of the ascending colon, as later, due to the rapid growth of the body wall they will tend to pull the gut lateral-wards and upwards, so it assumes the final vertical position seen in the adult.

The Jackson Veil is therefore derived from delicate secondary adhesions between the visceral and parietal peritoneum. A series of four foetuses and one infant at term were carefully studied and the above conclusions were drawn from this data. The developmental theory evolved presents some totally new viewpoints in regard to embryology of the caecum and ascending colon in their relation to the adjoining viscera, and before complete acceptance they should be substantiated by other workers. It is shown that the early fixation of the caecum and the more rapid growth of the posterior wall of the lumbar regions are the main actors involved in the formation of this membrane. The rotation and descent of the caecum are of only secondary importance. This theory explains why the Jackson Veil possesses its peculiar vascularity and its common origin and attachment. This membrane does not attain its full development until the third year of the child's life or at even a later period when sufficient room is made between the twelfth rib and iliac crest for the reception of the kidney. At this period development of the vertebra centra causes the kidney to be pushed outward and with it necessarily the colon, so that a relaxation of any tension of this structure on the colon is accomplished.

Several facts suggest that an ascending infection may often be transmitted from the lumen of the bowel to the kidney and other viscera. In the first place, microscopic examination hints at a lymphatic stasis; in the second place, there is a lack of free drainage of the right paraecolic gutter; in the third place, there is an intimate relation between the blood supply of the



membrane and that of the kidney; and in the fourth place, it is known that a large percentage of pus infections of the kidney are due to the colon bacillus, and that the right kidney is more liable to infection than the left.

The occurrence of the Jackson Veil in sixteen out of twenty-four bodies suggests that it should be looked for in a higher percent age of cases in which there are vague abdominal symptoms that are not relieved by ordinary operative procedures.

#### SUMMARY

1. The Jackson Veil occurs normally in about 60 to 75 percent of all cases.

2. It is a definite anatomical structure with a regular distribution and characteristic vascularity.

3. An adequate explanation of its origin and development can be shown by the study of the foetus.

4. Ileo-coelic bands of the the character described in this article are an important factor in peritoneal absorption and draining.

#### BIBLIOGRAPHY

- JACKSON, J. N. 1913 *Ann. of Surg.* Transactions Western Surgical and Gynecology Association, 1908.
- LANE. 1912 *Brit. Med. Journ.*
- PILCHER 1912 *Ann. of Surg.*
- MAYO, W. J. *A. M. A.*, vol. 63.
- EISENDRATH AND SCHNOOR 1914 *Ann. of Surg.*
- FLINT 1912 *J. H. Hosp. Bull.*
- EASTMAN 1913 *Surg. Gynee. and Obst.*
- KELBEL AND MALL *Embryology*, vol. 2.
- HUNTINGTON. *Anatomy of Peritoneum and Abdomen.*



## DETAILED STUDY OF A MONSTER WITH CRANIO- RACHISCHISIS AND OTHER ANOMALIES

CARBOX GILLASPIE AND HOWARD HULL HEUSTON

*Department of Anatomy, University of Colorado*

SIX FIGURES

The subject of this report was a foetal monster of some eight months which was brought into the clinic of the Colorado University School of Medicine last December. It presented quite the usual appearance of the anencephalic monsters but it was thought that a detailed study of its general anatomy might prove of interest. The results of this study are embodied in the following description.

The general appearance of this monster is well shown in the photographs of figures 1 and 2. Here the most striking feature is the upturned face, apparently set directly on top of the head. There is practically no neck, the head and face projecting upward from the shoulders. The upturned face is a result of the cervical flexure, the cervical vertebrae being flexed sharply forward and thus throwing the face upward. This cervical flexure can be seen in figure 3. Another interesting feature is the greatly enlarged arms and hands which also show well in figures 1 and 2. Figure 3 presents the condition of craniorachischisis of which more will be said later.

Dissection of the upper and lower extremities revealed little of interest other than the abnormally large arms and hands. These made up in volume percentage about 18 per cent of the total body volume which was greatly in excess of the normal for a foetus of this age. The circulation of the extremities was apparently normal as was also the nerve supply of these parts. The brachial and lumbo-sacral plexuses were normally developed.

The condition of craniorachischisis is shown in figure 3. The bony floor of the cranial cavity and the spinal canal has been

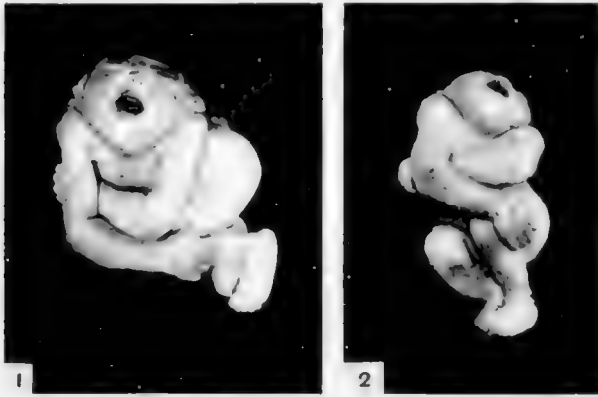


Fig. 1 Face view of the monster

Fig. 2 Ventral aspect of the monster. Note upturned face and large arms and hands.

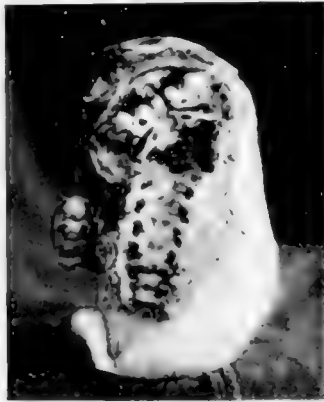

Fig. 3 Dorsal aspect showing basal bones of skull and floor of spinal canal. Craniorachnischisis.

cleaned in order to bring out more clearly the condition of bone development. There was no brain and no cord, the bones being covered only with the membrane which formed the floor of the embryologic neural groove. The squamous parts of the bones of the skull and the parts of the vertebrae forming the sides and dorsum of the spinal canal were lacking entirely. Of the basal bones of the skull there are plainly seen the sphenoid with the

anterior clinoid processes, the petrous parts of the temporal bones with the internal auditory meatus, and the basal part of the occipital bone with the jugular foramina. Immediately below the basal part of the occipital bone is a deep recess which is formed by the cervical flexure mentioned above. The spinal column shows the bodies of the vertebrae with the transverse processes and the intervertebral foramina. It is interesting to note that while neither brain nor cord was formed there was a complete and apparently normal development of the peripheral nervous system.

Dissection of the thorax showed the heart distinctly more to the right of the median line than to the left. The right side of the heart was much larger than the left due probably to an engorgement at death but otherwise there were no abnormalities. The lungs and thymus gland were normal.

In the abdomen a number of anomalies were found. A general view of the abdominal features is shown in figure 4. Here the most striking thing is the single large kidney occupying the greater part of the space of the left lumbar region. There were two separate ureters and two suprarenal glands although only the left one of each is shown in the drawing. The peritoneum has been partially removed to better display the kidney but the part remaining on the right side covers the right ureter and the right suprarenal gland. The grooves in the ventral surface of the kidney contain the left renal vessels. The uterus and bladder show a distinct displacement to the left which will be explained later. The stomach shows a bilobed fundus and a cylindrically shaped body. The spleen had a large blood clot in its ventral aspect and two or three small accessory lobes not shown in the drawing. The liver and pancreas showed nothing unusual. The volume of the various organs and parts of the body were compared with Jackson's table on the prenatal growth of the human body and none excepting the upper extremities found greatly out of proportion to the normal.

Anomalies of the circulation were found in the abdominal aorta and the vessels of the pelvis. These are shown in figure 5 which is a diagram of the circulation as found. The inferior

mesenteric artery comes off the aorta at a much higher level than normal while the coeliac axis, superior mesenteric, renal and ovarian arteries present their normal relationship. In the pelvis the aorta was continued in the median line to form a single umbilical artery which caused a displacement of the uterus and bladder to the left. This median aorta or umbilical artery gave off the uterine, right external iliac and the normal branches of the right internal iliac artery while the left common iliac

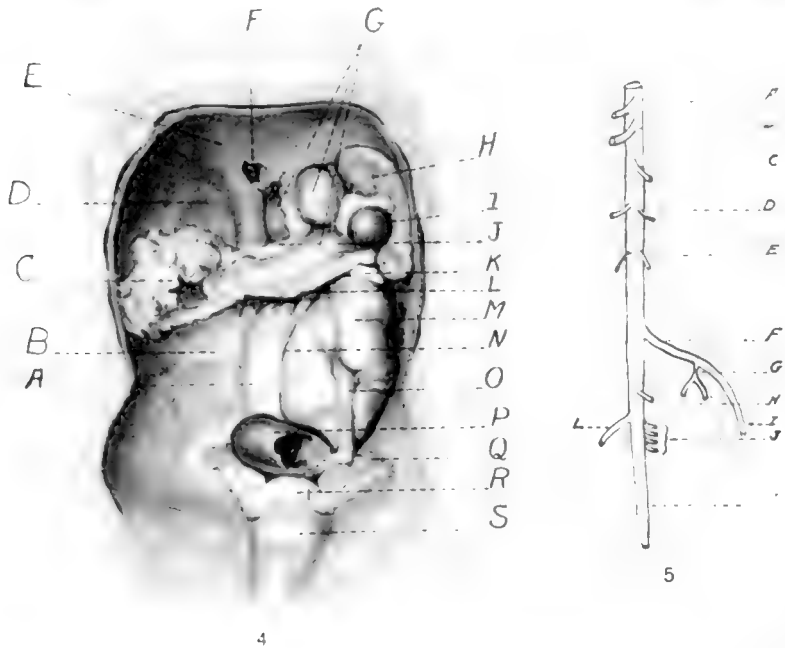


Fig. 4. Abdominal viscera after removal of liver and intestines. *A*, right margin of kidney covered with peritoneum; *B*, normal right kidney space; *C*, mesentery drawn to the right; *D*, liver space; *E*, diaphragm; *F*, vena cava; *G*, stomach; *H*, spleen; *I*, blood clot; *J*, cut edge of lesser omentum; *K*, left suprarenal gland; *L*, cut edge of great omentum; *M*, kidney; *N*, cut edge of peritoneum; *O*, left ureter; *P*, pelvic colon; *Q*, ovary; *R*, uterus; *S*, bladder.

Fig. 5. Diagram of abdominal aorta and pelvic vessels. *A*, coeliac axis; *B*, superior mesenteric; *C*, inferior mesenteric; *D*, renal arteries; *E*, ovarian arteries; *F*, left common iliac; *G*, internal iliac; *H*, uterine arteries; *I*, external iliac; *J*, branches corresponding to the remaining vessels of the right internal iliac; *K*, the single umbilical artery; *L*, right external iliac.

formed and terminated in the left internal and external iliaes with no umbilical artery. A photomicrograph of a cross section of the umbilical cord with its vein and one artery is shown in figure 6.



Fig. 6 Photomicrograph of the umbilical cord. Note vein and one artery.

Concerning the causative factors underlying the production of monsters and the various anomalies many theories have been advanced. Such are faulty implantation of the ovum, mechanical influences, diseased condition of the uterus with consequent absorption of poisons, and the action of various salts as those of sodium, calcium and magnesium. Alcohol and anaesthetics have been viewed with suspicion as to their influence. Malnutrition of the various tissues and organs due to circulatory disturbances with resulting failure of development and atrophy of the parts affected explain many anomalies. For a more complete discussion of these various theories the reader is referred to the current literature and to the many excellent textbooks of embryology.





## A TEACHING MODEL OF A 10 MM. PIG EMBRYO

IVAN E. WALLIN

*Department of Anatomy and Biology, Marquette University Medical School*

### THREE FIGURES

In an introductory course in mammalian embryology a great deal of precious time is generally lost in teaching students the values of structures in serial sections. While the standard embryological models in use are indispensable in the teaching of the subject they are of little assistance in helping the student to understand the relationship of a single section to those that follow and precede and in giving him a mental picture of the entire structure.

The model which is described below (fig. 1) is so constructed that a student working on the serial sections can go to the model and see any particular section in its relationship to the ones that precede and follow it. A part of this model was used in the laboratory during the past academic year with gratifying results. Both simple and difficult conditions in the microscopical sections were readily understood when the particular segment of the model had been examined.

I do not believe that a large model of a pig embryo has ever been constructed on this plan before. The value of such a model in the teaching laboratory it seems to me warrants a description of the construction.

The model was made of paraffined blotting paper at an enlargement of 50 diameters. The method of using the paper differed a little from the method I described in a previous publication.<sup>1</sup> The drawings of the sections were made on tracing cloth which are placed in a permanent file for future reference and by using a carbon paper the original drawing was transferred by one operation to the blotting paper. The blotting paper is afterwards soaked in melted paraffin.<sup>2</sup> Most of the general outline of the section can be cut with scissors and afterward completed with a knife cutting over a glass plate.

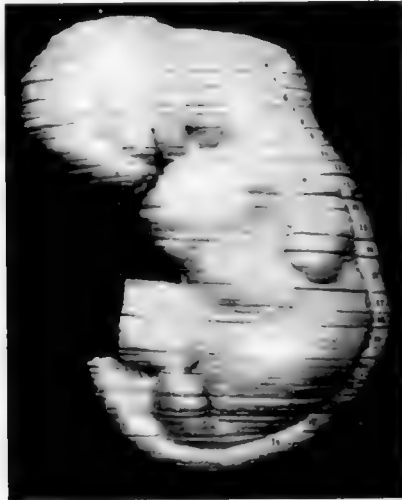In cutting the sections only that part of the mesenchyma lying next to the ectoderm is represented. This is retained to give a sufficient thickness and firmness to the blocks of segments when they are permanently stacked. Structures in the interior are held in place by means of bridges which are retained permanently.

<sup>1</sup>Am. Jour. Anat., July, 1917.

<sup>2</sup>This method, I believe, has been described before. However, I have been unable to find a reference to it.

The model was built in segments. The thickness of the segments varies and depends upon the structures within. Certain segments, for example no. 7 and no. 13, are comparatively thin. It was necessary to stack them in this way so that certain important structures would not be covered. The last segment (No. 24) is mounted on a wood stand (stand does not show in photograph). A block of wood was carved to receive the contour of this segment which was made fast to it with nails. The entire stand and segment were afterwards electroplated with copper. The other segments merely rest on top of this last segment when the entire model is set up.

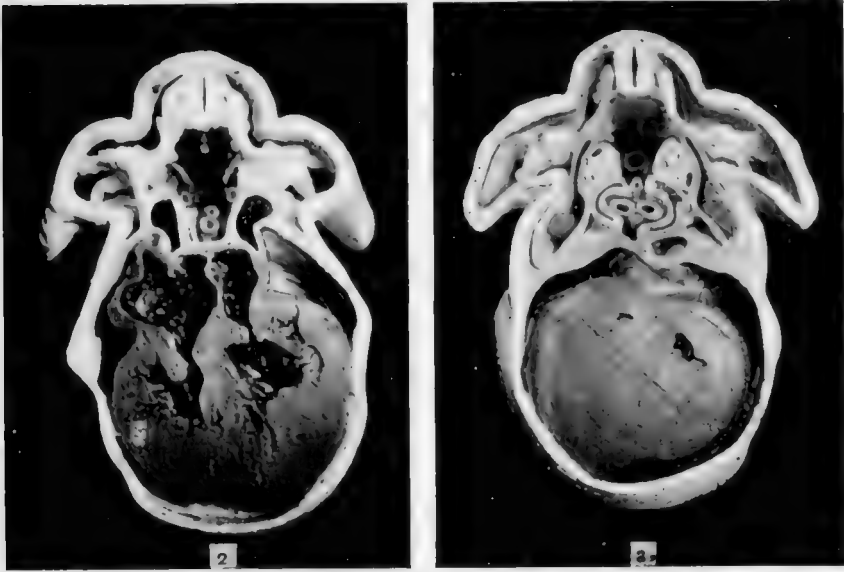
The structures in each segment were painted so as to make them stand out more prominently. The type of pigments used were the ordinary tube pigments mixed with rubbing varnish to the consistency



of thick syrup. This method was suggested by the department artist Mr. Leo Massopust. This mixture has been found to be very satisfactory. When the mixture has thoroughly dried on the model it forms a very hard coating which appears to give promise of good wear. All painted surfaces are finally covered with a coat of French varnish.

Figures 2 and 3 are photographs of the cephalic and caudal face of segment 14. This segment contains a portion of the heart with very small parts of the liver showing on the caudal face.

There may be certain advantages in building a model of this type by the use of the wax plate method. Structures, like ganglia, could be rounded off more easily than when the blotting paper is used. The wax segments could be electroplated with copper and in this way be made more serviceable for class room handling. The cutting of the



paraffined blotting paper is also more difficult than the cutting of wax plates.

I wish to take this opportunity to acknowledge the intelligent assistance of our laboratory technician Mr. Paul Kordes without whose help the completion of this model would have been delayed many months.



## TWO CONVENIENCES FOR THE LABORATORY

EDWARD CARROLL DAY

*Department of Biology, Bryn Mawr College*

THREE FIGURES

### I. A LABORATORY VEHICLE



A long-felt need for a suitable and substantial laboratory vehicle led to the construction of the car shown in the accompanying photographs (figs. 1 and 2).

The frame is of half-inch galvanized iron pipe, and measures 34 inches in length, 18 in width and 16 in height between the top and bottom trays. The front and hind wheels are 12 and 8 inches respectively and are the rubber-tired regulation type made for go-carts. The forks as well as the wheels were obtained from a manufacturer in Philadelphia. The plumber of the College did the work of cutting out and fitting the frames together and the mechanic attached the wheels.

It will be observed that both pair of wheels are carried on longitudinal bars inside of and parallel to the bars forming the bottom of the frame. The inside bar is, in each case, 3 inches from the outside one, measuring from center to center. The vertical pipes for the small rear wheels are set  $4\frac{5}{8}$  inches from the rear end and the verticals for the large front wheels are set  $2\frac{1}{2}$  inches from the front end, and are connected to the long bars with T-fittings. The vertical pipes for the rear wheels had to be bored out a trifle in order to take the shafts of the forks. A collar on the upper end of the shaft prevents the fork from falling out when the car is lifted. The axle of the front wheels is fastened with screws into the vertical pipes which have been plugged and notched at the ends for the purpose. The front wheels are braced by crossed stays running from the axle up to the long bars, while the hind ones are braced by a horizontal pipe just above the forks. The handle of the car is given the desired angle by a 45 degree elbow on either side.

The trays are of  $\frac{3}{4}$  inch hard wood and are held in place by cleats. The top one is  $2\frac{1}{2}$  inches deep and has a hand-hole at each end. White enamel gives an attractive finish to the vehicle.


In order that the equilibrium of the car may not be upset when the two hind wheels turn sideways as in rounding a corner, they must necessarily be situated near to the end and close to the sides of the frame. Although  $\frac{1}{2}$  inch pipe was used, a  $\frac{3}{8}$  size would do equally as well for the given dimensions of the car.



## II. AN INJECTION TANK

For a laboratory having compressed air available an injection tank of the type shown in figure 3 will greatly facilitate the injection of the circulatory systems of a large number of cats or rabbits for dissection purposes.

The inlet for the compressed air is on the left; the outlet for the injection mass on the right. The pulley in the center is connected to a shaft carrying a double-bladed stirring-paddle at its lower end on the floor of the tank. The slight knob just to the left of the pulley on the top surface is an inlet fitted with a screw-plug where the injection mass may be poured in. The dial is that of a 10-pound pressure gauge. To the right of this is an air-valve for regulating the pressure. An arm-hole at the bottom of the can, fitted with a brass cover which is



held in place with machine screws, facilitates the cleaning of the tank after using. A small circular glass window in this cover discloses the level of the liquid within. The glass is inserted from the inside and is held in place with sealing-wax. The bottom of the tank, like the top, is convex in order better to withstand the pressure and to concentrate the liquid toward the center as its quantity diminishes.

With a relatively thin injection-mass and a pressure of three to four pounds the apparatus works very satisfactorily when injection is made through the heart of the animal. We made a puncture in the left ventricle, inserted the cannula, holding it in place with the fingers, gently turned on the liquid, injected until the fine arterial capillaries stood out upon the surface of the viscera—which required about a minute, then ligated the dorsal aorta. The arteries were thus filled with the yellow starch mass while the venous system became surcharged with blood; thus both systems could be readily traced out by the student.





## AN HEREDITARY CASE OF CONGENITAL ABSENCE OF ONE KIDNEY

MARCUS W. LYON, JR.

*George Washington University, Washington, D. C.*

### ONE FIGURE

The following case of absence of a kidney is of interest in view of the statement in the family history of the subject that the maternal grandmother had been operated on for some abdominal condition when it was found that one kidney was absent.

The anomaly occurred in a white female, age 41, weight 139 pounds, who came to necropsy following an operation for the relief of ascites due to cirrhosis of the liver. Associated with the absent kidney there was an absence of the ovary and uterine tube of the corresponding side.

The right kidney was entirely absent and no remnants of it could be found in the abdominal or pelvic cavities. The left kidney was in the usual position, and hypertrophied. It weighed 270 grams and measured 140 by 70 by 45 mm., with a cortical thickness of from 10 to 15 mm. It was supplied with a single ureter.

The left renal artery was of normal size. The right renal artery was very small and distributed to the right suprarenal body. From its base a very fine twig came off which probably went to the suprarenal also.

The left ureter was single and normal in every way. The right ureter was present forming a distinct tube in its lower portion and reduced to a fibrous cord in its upper portion which disappeared into a mass of loose fibrous and areolar tissue. Although the right ureter was connected with the bladder, no opening from it into the bladder could be found. The interior of the right ureter contained a small amount of fine granular debris.

Both suprarenal bodies were present. The left one was in its usual position above the kidney. Unfortunately it was removed and its connections destroyed before it was learned that the right kidney was lacking. Accordingly it does not appear in the illustration.

The uterus was very small and in its usual position. It had but one uterine tube, the left, which as shown in the illustration was bent over toward the right embracing a single ovary in its fold and between it and the uterus. No other ovary could be found. There was no indication of another uterine tube. Although the single ovary actually appears on the right side, it is to be interpreted as the left ovary both on account of its relations with the left uterine tube as well as to the previously observed fact<sup>1</sup> that in congenital absence of a kidney there is

<sup>1</sup> Radasch, H. E., Amer. Journ. Med. Sci., n. s., 136, 111, 1908.

frequently an associated lack of development of the sexual glands and apparatus on the same side. The sexual history of this subject is as follows: Menstrual periods began at 13, irregular at first, but became regular, no pain, no clots, quantity normal. Married at 16, had a premature birth after being married fifteen years. Had another miscarriage at 39 years and never menstruated since. A small myoma, about 15 mm. in diameter, was in the uterine wall.



Fig. 1 Case of congenital absence of right kidney, ovary, and uterine tube. Preparation shows hypertrophied left kidney, and its connections with the abdominal aorta and bladder; the right suprarenal body and its connections with the abdominal aorta; the right ureter lost above in a small mass of fibrous and areolar tissue, and joined below with the bladder; the incised uterus with the left uterine tube curving over to the right and between it and the fundus of the tube the ovary. The dark irregular area at the right is the fimbriated end of the tube. For comparison a 10 cm. rule is placed at the bottom of the preparation.

## ON THE MORPHOLOGY OF THE RENAL TUBULES OF VERTEBRATES

G. CARL HUBER

*Department of Anatomy, University of Michigan*

TWENTY-TWO FIGURES

A comparative study of the renal tubules of the different classes of vertebrates was projected nearly twenty years ago, soon after publishing results of a study on the development and shape of the uriniferous tubules of the higher mammals.<sup>1</sup> In this study, as projected, it was purposed to reconstruct the excretory tubules of the pronephros and mesonephros of certain of the lower vertebrates, including amphibia, and the metanephric tubules of certain reptiles, birds and mammalia. In the reconstruction, by the Born wax plate method, of the pronephric tubules of a larval toad, and mesonephric tubules of an adult frog and the metanephric tubules of certain reptilia no great difficulty was experienced, and such reconstructions were made, somewhat over fifteen years ago in conjunction with Professor Ward J. MacNeal, sometime Instructor in this department. On attempting to reconstruct the metanephric tubules of birds, it was learned after unsuccessful trials that this was beyond the limits of the method, so also with endeavors to reconstruct the metanephric tubules of adult mammalia. The projected study, therefore, was abandoned for a time. The form of the adult, mammalian renal tubule was later ascertained by specially devised methods of teasing.<sup>2</sup> This special method of teasing has relatively recently been successfully used in an investigation of the form of the metanephric tubule of birds. I am in a position now, therefore, to present figures giving the morphology

<sup>1</sup> Huber, G. Carl. On the development and shape of uriniferous tubules of certain of the higher mammals. *Am. Jour. Anat.*, Supplement to vol. 4. 1905.

<sup>2</sup> Huber, G. Carl. A method for isolating the renal tubules of mammalia. *Anat. Rec.*, vol. 5, 1911.

of type forms of renal tubules from the different classes of vertebrates. Their presentation does not seem to me superfluous at the present time, even though Zarnik<sup>3</sup> has in the meantime published an excellent study of the renal tubules of certain reptilia. The duct system of the kidneys of certain of the forms studied does not lend itself readily to investigation by reconstruction methods, owing to magnification necessary to make the requisite drawings, and the size of the resultant model. Therefore, an attempt was made, relatively successful in certain of the forms studied, to ascertain the form of the duct system by means of the celluloid, corrosion injection method devised by me and presented in connection with a study of the arteriolae rectae of the mammalian kidney.<sup>4</sup> The figures here included, based on preparations collected through many years of work, therefore, are in part of reconstructions made, in part of complete renal tubules isolated by teasing and in part of celluloid, corrosion preparations. It is hoped that the figures will be sufficiently clear to obviate the necessity of extended description. This account is intended more as a pictorial summary of results obtained as concerns the morphology of the renal tubules and the kidney duct systems of certain type vertebrates, than a critical discussion of the minute anatomy of the renal tubules considered, since the literature is much richer as concerns the latter than that which concerns the morphology of the tubules. Likewise, only the pertinent literature dealing with the morphology of renal tubules is here considered, otherwise this account would be extended far beyond the limits of these pages.

#### PRONEPHRIC TUBULES

The reconstruction of the pronephric tubule here figured was obtained from a series of frontal sections of a larval toad, having a length of 10 mm. The variety of *Bufo* I am unfortunately unable to give. The ova were collected in a neighboring pond

<sup>3</sup>Zarnik, B. Vergleichende Studien über den Bau der Niere von Echinda und der Reptilienniere. *Jenaische Zeitschrift*, vol. 46, 1910.

<sup>4</sup>Huber, G. Carl. The arteriolae rectae of the mammalian kidney. *Am. Jour. Anat.*, vol. 6, 1907.

and could not be specifically identified. The reconstruction was made at a magnification of two hundred diameters. The figure is added more with a view of making the series of figures complete than with a view of adding materially to current knowledge of the amphibian pronephric tubule. The figure here given presents similarity to that given by Herbert H. Field,<sup>5</sup> figure 41, plate 4, a reconstruction of the right pronephros of a larva of *Rana* having a length of 8 mm., from anterior end to tip of tail. Field's account of the amphibian pronephros is the best available. In the brief statement here given, his nomenclature is used. The pronephric tubule shown in figure 1, pre-

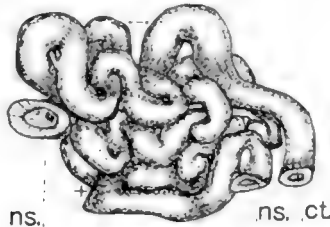


Fig. 1 Reconstruction of the pronephric tubule of a larva of *Bufo*, the larva having a length of 10 mm. from anterior end to tip of tail.  $\times 80$ . *ns.*, nephrostome; *ct.*, common trunk.

sents only two nephrostomes, *ns.* The two nephrostomal tubules join in a Y-shaped junction, hidden beneath the model as placed in the figure, in the neighborhood of the region indicated by a cross. The common trunk presents three main loops extending primarily in cephalic caudal direction, each presenting three to four secondary loops. The figure presents a sketch over an enlarged photographic print, the photograph having been taken from a direction which admits tracing the common trunk most completely. The arrow indicates the direction taken by the tubule in the one location where confusion may arise. The actual length of the common trunk reconstructed as measured on the model, is approximately 2.5 mm.

<sup>5</sup> Field, Herbert H. The development of the pronephros and segmental duct in amphibia. Bulletin of the museum of Comparative Zoology at Harvard College, vol. 21, 1891.

## MESONEPHRIC TUBULES

The mesonephric tubule here figured was reconstructed from the kidney of an adult, female frog, *Rana catesbiana*. The duct system is figured after corrosion preparations made by injecting through the ductus deferens or ureter, a solution of celluloid in acetone, colored with alkanin. Only now and then was it possible to inject anyway completely the duct system. Usually, owing to the pressure necessary, the ureter ruptures before the desired injection is obtained. After injection, the parts remained in place for fifteen to twenty minutes and were then transferred to a 75 per cent solution of hydrochloric acid, in which they remained for about twenty-four hours. The macerated pieces were then transferred to a large dish of water and the softened tissue removed by playing water against the preparation with a dropper provided with a rubber bulb. After the corrosions were thoroughly cleansed, they were placed in distilled water for a few hours, then dehydrated, and transferred to xylol and if desired mounted in xylol-balsam. The mesonephros—kidney—of the frog is a compound tubular gland, possessing numerous renal or mesonephric tubules, terminating in a series of transverse collecting ducts which unite with the ductus deferens or ureter. The ductus deferens joins the kidney near the posterior end of its dorso-lateral margin, passing forward to the cephalic end, where it becomes partly embedded in kidney substance. Into this main duct there empty at fairly regular intervals and approximately at a right angle numerous transversely coursing collecting ducts, which, with or without branching pass near the dorsal surface of the kidney to near its lateral margin. These transverse collecting ducts have a relatively straight course and are in the main parallel to each other. For the greater part of their course they are embedded in the kidney substance near its dorsal surface. In figure 2, there is presented a corrosion preparation of the ductus deferens with the connected, transversely coursing, collecting ducts from the kidney of *Rana catesbiana*. The injection in this case was fairly complete and after maceration it was possible to mount in one piece the entire corrosion.

The transverse collecting ducts are represented for about one half of their entire length. About the full extent of their branching may be observed, since scarcely any branching occurs except relatively near their termination in the ductus deferens. In figure 3, is shown a corrosion of one of the transverse collecting ducts with the terminal ends of the connected renal tubules, from a region in which the injection extended for a distance into the renal tubules. The transverse collecting tubules shown in figure 3, corresponds to one of the main side branches of the ductus deferens as seen in figure 2. The dependent tubules, hooked at the lower end (fig. 3) correspond to that portion of the recon-



Fig. 2 Corrosion preparation of ductus deferens and transverse collecting tubules of kidney of *Rana catesbiana*.

structed renal tubule, shown in figure 4, leading to the segment of the reconstructed transverse collecting duct. The manner of termination of the renal tubules in the transverse collecting ducts is clearly shown in figure 3. They end along the ventral border of these collecting ducts in two somewhat irregularly arranged rows. By an imaginary combination of the portions of the duct system of the frog's kidney as detailed in figures 2 and 3, the entire duct system of the frog's kidney to and including portions of the renal tubules, may be projected.

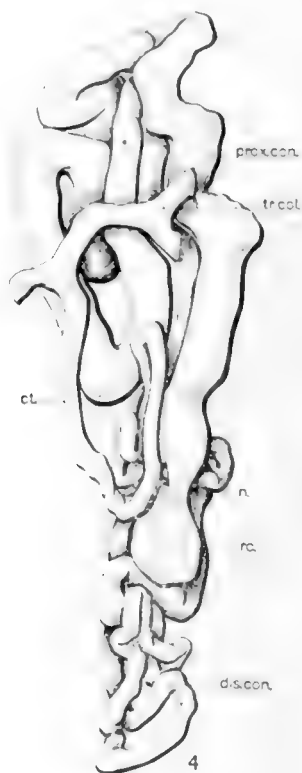
The renal tubule of the frog -mesonephric tubule -was figured by Nussbaum<sup>6</sup> many years ago. In figure 28, plate 23, Arch. f. Mik. Anat., vol. 27, 1886, he presents a complete uriniferous tubule from the kidney of *Rana esculenta*, teased after maceration in hydrochloric acid. This figure has been repeatedly

<sup>6</sup> Nussbaum, M. Ueber den Bau und die Thätigkeit der Nierenorgane. Arch. f. Mik. Anat., vol. 27, 1886.

copied and presents many points of similarity to the figure of a wax reconstruction here shown. In figure 4, is shown a reconstruction of a complete renal tubule of the frog, *Rana catesbiana*, beginning with renal corpuscle and ending in the transverse



3



4

Fig. 3 Corrosion preparation of transverse collecting duct with the terminal portions of the entering renal tubules from the kidney of *Rana catesbiana*.

Fig. 4 Reconstruction of a renal (mesonephric) tubules of a female frog, *Rana catesbiana*.  $\times 80$ . *rc.*, renal corpuscle; *n.*, neck; *prox.con.*, proximal convoluted segment; *dis.con.*, distal convoluted segment; *con.t.*, connecting tubule; *tr.col.*, transverse collecting duct.

collecting duct. The figure is placed so that the dorsal surface corresponds to the upper border of the figure. A cross section of the kidney of *Rana catesbiana* appears not unlike figure 64,



of Gaupp's<sup>7</sup> edition of Ecker's and Wiedersheim's "Anatomie des Froshes," 1905. The renal tubules traverse the entire dorso-ventral thickness of the kidney. The great majority of the renal corpuseles form an irregular layer situated near the ventral surface of the kidney. Each renal tubule begins at a renal corpusele. The renal corpuseles are relatively large, of flattened oval form, with long axes extending in a dorso-ventral direction. The one reconstructed presents the following measurements: length, 0.125 mm.; width, 0.1 mm.; thickness, 0.088 mm. The renal corpusele is joined to the tubule by a short and narrow neck, *n.*, directed dorsalward, constituting part 1. of the tubule proper. The neck is lined by relatively short, non-pigmented cells supporting long cilia. The neck is followed by a tubular portion having a relatively large diameter and extending toward the dorsal surface of the kidney there to form several bold loops which may extend to about the middle of the kidney substance. This portion is comparable to what is designated as the proximal convoluted portion of the mammalian renal tubule. Its course is clearly discernible in the figure; I have designated it *prox.con.*, proximal convoluted portion. The actual length of this portion of the tubule reconstructed, as measured on the model, is approximately 3.8 mm., and it has a diameter, on the average, of 75 $\mu$ . It extends from the narrow neck, just above the renal corpusele toward the dorsal surface where several bold loops may be observed, then returned toward the ventral surface ending near the level of the renal corpusele. In the figure this portion of the tubule is partly hidden by the small, coiled tubular portion lying to the left and slightly above the renal corpusele. The cellular lining of this portion of the tubule is not unlike that lining the proximal convoluted portion of the mammalian kidney, presenting an inner striated border and now and then pigment granules in the basal portions of the cells. The portions of the renal tubules of the frog here designated the proximal corrulated portion, taken collectively, constitute the greater portion of the dorsal half of

<sup>7</sup> Gaupp, E. Ecker's und Wiedersheim's Anatomie des Froshes, Dritte Abtheilung, 1904. Harnorgane, page, 238.

the kidney substance. This proximal convoluted portion is followed by a short and narrow segment comparable, in position only, to the medullary loop (loop of Henle) of the mammalian renal tubule. In the figure given, this portion of the tubule reconstructed is practically hidden by the tubular coil complex above referred to. This segment is said to be lined by ciliated epithelium similar to that lining the neck; it constitutes Gaupp's 'Dritter Canalabschnitt.' In the tubule reconstructed this portion presents a length of a little less than 0.2 mm.; however, in the model its delimitation is somewhat uncertain. In the succeeding tubular segment, Gaupp's 'Vierter Canalabschnitt,' the tubule again increases in size slightly, reaching a diameter of about  $30\mu$ , and presents numerous coils and loops certain of which reach the ventral surface of the kidney. The general course and relations to the renal corpuscle of these loops is well shown in the figure: they forming the tubular coil complex of the lower third of the figure. This portion presents an actual length of approximately 2.5 mm. It is lined by a short epithelium, presenting basal rodding. In cross sections of the kidney this portion of the tubule is found in the ventral portion, extending from a little above the level of the renal corpuscles to the ventral surface of the kidney. This portion of the frog's renal tubule may be compared to the thicker portion of the ascending limb of the medullary loop and the distal convoluted portion of the mammalian renal tubule and is here designated the distal convoluted portion, *dis.con.* of figure 4. This segment is succeeded by the final segment leading to the transverse collecting duct. It may be designated the junctional or connecting tubule, *con.t.*, clearly shown in the figure of the model as it joins that segment of the transverse collecting duct, *tr.col.*, reconstructed. In the tubule reconstructed it presents a length of 0.7 mm. In figure 3, the dependent, hook-shaped tubular portions represent this fifth tubular segment, the junctional or connecting tubule. This portion of the tubule is lined by an epithelium similar to that of the collecting ducts. The entire renal tubule of the frog as reconstructed and presented in figure 4, has a total length of slightly over 7 mm.

## METANEPHRIC TUBULES

A study of the metanephric tubule requires consideration of the renal tubules of reptilia, birds and mammalia. For this study the renal tubules of a number of species of reptilia were modelled after the Born wax plate method, in the hope that some data concerning the ancestral origin of the metanephric tubule might be obtained. This hope was not realized. There is found a certain resemblance in morphology between the amphibian mesonephric tubule and the reptilian metanephric tubule, but beyond such resemblance in form the kindeys of the types studied present no definite data as to their developmental relationship. Models of renal tubules from kidneys of the turtle, the alligator, the snake and the lizard are here depicted. Zarnik has considered very fully the structure of the reptilian kidney, embracing in his study, among other forms, the kidney of the lizard, the snake the alligator and the turtle. His comprehensive publication appeared after the models here figured were completed, This article is valuable for the literature reviewed as well as for the observations recorded. These as concerns the form of the renal tubules investigated are based almost wholly on teased preparations. My own observations corroborate many of his results. Their publication at this time seems never-the-less warranted in that they are based on models in which, as I have had abundant opportunity to learn, the relations of the different parts of the respective tubules are more accurately maintained than in teased preparations, and further, the forms studied by me are not identical with those investigated by Zarnik. In presenting my own results of the study of the forms of the renal tubules of reptilia it will be necessary from time to time to draw attention to Zarnik's observations, obviating the necessity of a complete review of his work.

For the study of the morphology of the renal tubule of the turtle several such tubules were reconstructed from the kidney of *Chrysemys marginata*. The kidney of this turtle presents on its surface shallow grooves, in the main parallel, and having a direction which is in general at right angles with the long axis

of the kidney. These grooves anastomose here and there. They bound indistinct folds or pseudolobules, drained by main branches of the duct system. The ureter enters on the ventral surface. Two of the several renal tubules reconstructed are reproduced in figure 5, A and B. In the folds or pseudolobules of the chelonian kidney, as also pointed out by Zarnik, the branches of the renal artery as also the branches of the *venae renalis revehentes* course through the centers of the pseudolobules, between two layers of kidney substance, which respectively meet in the center

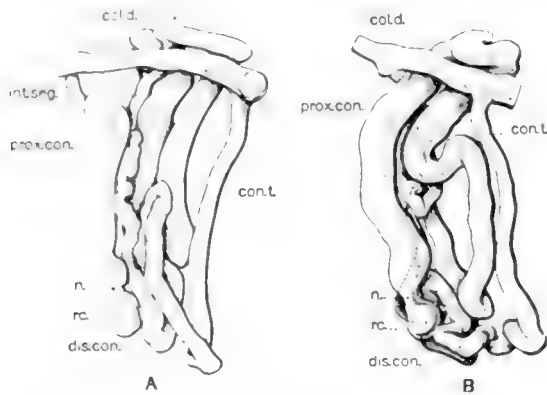
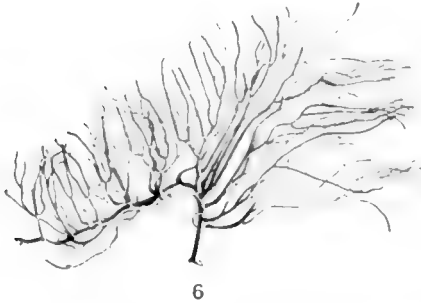


Fig. 5 A and B, two renal tubules reconstructed from the kidney of *Chrysemys marginata*.  $\times 80$ . *rc.*, renal corpuscle; *n.*, neck; *prox.con.*, proximal convoluted segment; *int.seg.*, intermediate segment; *dis.con.*, distal convoluted segment; *con.t.*, connecting tubule; *col.d.*, collecting duct.

of the pseudolobules and extend to its surfaces. The main branches of the duct system, arising from the primary branches of the ureter, radiate from the ventral to the dorsal surface of the kidney, coursing in the kidney substance, on each side near the surface of the pseudolobules. Each so called pseudolobule, therefore, is composed of two layers of kidney substance having between them branches of the renal artery and branches of the *venae renalis revehentes*, each layer being composed of masses or renal tubules, the main axis of whose coil complex is approximately at right angles to the surface of the pseudolobules, and to the main branches of the collecting ducts.

The renal tubules of *Chrysemys marginata* begin in a relatively small renal corpuscle averaging about  $55\mu$  in diameter. They are situated on each side near the centers of the pseudolobules forming on each side of the center an irregular layer. The renal corpuscle is followed by a short and narrow neck, lined by an epithelium bearing long cilia. The neck is followed by what may be regarded as the proximal convoluted portion. Zarnik's 'Hauptstück' which courses toward the periphery of the pseudolobule, overlying the associated collecting duct and forms a large and conspicuous portion of the coil complex of each renal tubule. In tubule A, of figure 5, this segment, *prox.con.* is arranged in the form of a letter N, extending from the neck, *n.*, to the region marked by a cross, found at the middle of the upper portion of the figure. The three parts of the N-form present each smaller secondary loops. In tubule B, of figure 5, the arrangement of the proximal convoluted portion has an arrangement which is essentially the same as in tubule A, though the final rising arm of this N-shaped segment is not as long. In tubule A, this tubular segment presents a length of 1.5 mm.; in tubule B, 1.25 mm. and a diameter of from 60 to  $65\mu$ . It is lined by an epithelium not unlike that lining the proximal convoluted portion of the mammalian renal tubule, presenting also a striated inner border. Collectively these tubular segments form the outer border of the pseudolobules. This large and long segment is followed by a short and narrow segment, lined by ciliated epithelium and corresponds in position only to the thin arm of the medullary loop of the mammalian renal tubule. In tubule A, of the figure this short intermediate segment *int.seg.* descends from the region of the cross to the region where the tubule again becomes larger, about the middle of the figure. It has a length of a little less than 0.3 mm., and a diameter which averages  $20\mu$ . In tubule B, this segment is represented by the dotted loop found a little to the left of the middle of the figure. This intermediate segment is followed by what I shall designate as the distal convoluted portion, forming in both tubules figured a dense coil complex in the region of the renal corpuscles, thus found near the center of the pseudolobules. In both tubules

this segment presents a length of very nearly 1 mm., and a diameter which varies from  $30\mu$  to  $45\mu$ . This segment is lined by a low columnar epithelium showing a striated protoplasm. It is followed by a junctional or connecting tubule, *con.t.*, which in both figures lies to the right, extending respectively from the loop which lies at the lower right hand corner of each tubular complex to the segment of the collecting duct which crosses each tubular complex at approximately a right angle, *col.d.* This tubular segment has a length of 0.5 mm. This gives a length to tubule A, from renal corpuscle to collecting duct of 3.3 mm. The tubules here figured are similar to those figured by Zarnick, both in form and arrangement, except that the duct segment



6

Fig. 6 Duct system of pseudolobule of kidney of *Chrysemys marginata*, corrosion preparation.



7

Fig. 7 Distal collecting duct with connecting or junctional tubular segments of renal tubules emptying therein, *Chrysemys marginata*, corrosion preparation.

figured by him crosses the coil complex a little nearer its center than in my figures, see Zarnick's figures 35 to 37 of plate 7. Other renal tubules modelled from the kidney of *Chrysemys marginata* and not here figured are in their morphology not unlike the tubules here figured.

In figure 6 is represented a drawing of a fairly complete celluloid corrosion injection of the duct system of a pseudolobule. The main duct, bottom of the figure, arises from the ureter on the ventral surface of the kidney. The primary and secondary branches radiate toward the dorsal surface of the respective pseudolobules, coursing in the kidney substance, on each side

nearer the surface of the pseudolobule than its center. Into each of the branches empty numerous renal tubules. In figure 7, is shown one of the radiating collecting ducts, many of which are figured in figure 6, taken from a corrosion injection in which the injection mass in certain parts extended for a distance into the connected renal tubules. In this figure, each dependent, hook-shaped tubule corresponds to a connecting or junctional tubule as figured in the reconstructions shown in A and B of figure 5. The segment of the collecting duct shown in figure 5, *col.d.* corresponds to a short segment of the distal collecting duct uniting the several connecting tubules as seen in figure 7, or of the radiating and branching ducts depicted in figure 6. Figures 6 and 7, give a better perspective of the duct system of the chelonian kidney than do figures 41 and 42 of plate 7 of Zarnik's contribution.

*Alligator.* For the material used in the study of the renal tubule and collecting ducts of kidney of the alligator, I am indebted to Doctor Greenman, Director of the Wistar Institute, who kindly furnished me several specimens of *Alligator mississippiensis*, measuring approximately two feet in length. All previous descriptions of the kidney of the alligator note its simple structure. It is found accurately described by Zarnik in his comprehensive contribution in which he discusses and in many points corroborates the earlier observations of Solger<sup>8</sup> and Szakall.<sup>9</sup> In the kidney of the alligator the ureter divides near the caudal end of the kidney into a dorsal and ventral branch which course respectively along the dorsal and ventral surface of the kidney. Into these two branches of the ureter empty numerous lateral, primary collecting ducts, which after division extend on each side of the ureter to near the lateral and median borders. In figure 8, is represented the cephalic end of the ventral ureter with the primary collecting ducts termination

<sup>8</sup> Solger, B. Zur Kenntnis der Krokodilniere und der Nierenfarbstoffe niederer Wirbeltiere. Zeitschr. f. wiss. Zool., vol. 41, 1885.

<sup>9</sup> Szakall, T. Über den Bau des Urogenitalsystems des Krokodils. Inaug.—Diss. Giesen, 1899. Seen by me only in review (Page, 311, Herwig's Handbuch der Vergleich. u. Experiment. Entwicklungslehre, Dritter Band, Erster Theil, 1906.

therein, as obtained from a preparation made by the celluloid injection corrosion method. In the lower left of the figure is indicated the manner of termination of the initial collection duct coming from the renal tubules. In figure 9 is given a drawing of a very completely injected corrosion preparation of one of the side branches of the ureter with the connected initial collecting ducts. These terminate in the respective collecting ducts in two fairly regular rows as is evident from the figure. A comparison of figures 8 and 9 of this article with figures 33 and 34, plate 6, of Zarnik's contribution will show a close correspondence of results obtained by methods of teasing and corrosion injection

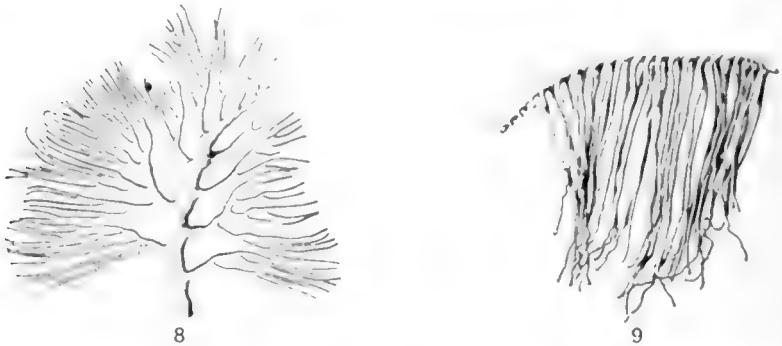

Fig. 8 Cephalic end of ventral branch of the ureter, with lateral branches, collecting ducts, alligator mississippiensis, corrosion preparation.

Fig. 9 Lateral collecting duct, receiving the distal ends of the renal tubules terminating therein, connecting tubules, alligator mississippiensis, corrosion preparation.

as concerns the duct system of the alligator kidney. The substance of the alligator's kidney is arranged in a dorsal and a ventral half, corresponding to the dorsal and ventral branches of the ureter, separated by a small amount of connective tissue and branches of the renal artery and accompanying veins. The dorsal and ventral portion of the renal substance are minor pictures, so far as tubular arrangements and ducts are concerned. This is clearly shown in text-figure 34 and figure 52, plate 10 of Zarnik's article and this is confirmed in my own serial sections. This observer successfully teased the renal tubules of the alli-



gator as may be seen from his figure 30a, plate 6. In figures A and B, of figure 10, are reproduced two renal tubules of alligator *mississippiensis* reconstructed after the Born method. They are taken from the thicker central and slightly thinner lateral portions of a series of cross-sections. The renal corpuscles of the

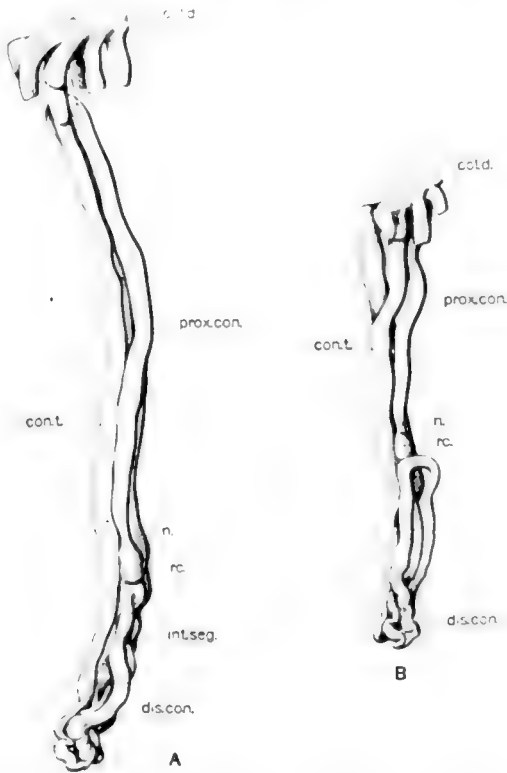


Fig. 10 A and B, reconstructions of two renal tubules of alligator *mississippiensis*.  $\times 80$ . *rc.*, renal corpuscle; *n.*, neck; *prox.con.*, proximal convoluted segment; *intseg.*, intermediate segment; *dis.con.*, distal convoluted segment; *cont.*, connecting tubule; *col.d.*, collecting duct.

several tubules form a fairly regular layer in each half of the kidney substance, a little distance away from the connective tissue septum. The renal corpuscle forming the beginning of the tubule A, figure 10, presents a flattened oval form with a cross diameter of  $45\mu$ . The renal corpuscle is followed by a narrow

neck, directed toward the periphery, which in the alligator is not lined by ciliated epithelium. The neck is followed by a long, slender loop, which extends from the renal corpusele to the periphery of the kidney, looping back again to about the level of the renal corpusele. This loop, which is very simple in arrangement, forms the proximal convoluted portion, *prox.con.*, and is lined by an epithelium having a striated inner border. Its length in this tubule is 2.3 mm. and it presents an average diameter of a little over  $40\mu$ . This segment is followed by a short intermediate segment, lined by ciliated epithelium, extending from about the level of the renal corpusele to the loop coil shown at the lower end of the figure. In the model, this portion is not clearly demarked; it presents a length of about 0.3 mm. This portion is followed by the distal convoluted portion, forming the coil complex with the short ascending loop, forming the lower end of the figure, and leading to the long connecting tubule and initial collecting duct ascending, quite free, at the left the of figure. The distal convoluted portion presents a length of 0.8 mm. and the connecting tubule and initial collecting duct, together, a length of 1.1 mm., making the entire length of this tubule 4.5 mm. Tubule B, of figure 10, is very similar in form and arrangement of parts to tubule A, differing from it only in being slightly shorter.

*Snake.* For the investigation of the snake's kidney, the common striped snake, *Eutaenia sirtalis* Baird, was chosen. Zarnik reports on the renal tubules of a number of ophidian forms, basing his study on teased preparations. The left kidney was studied; the duct system by the corrosion injection method, the renal tubules by means of wax reconstruction. In the striped snake the left kidney is an elongated, slightly lobulated organ, the ureter coursing along the ventral and ventro-menial border to near its cephalic end. In figure 11, is shown a corrosion of the ureter with the attached primary collecting ducts. These, as may be seen from the figure, enter the ureter at a very acute angle and after a short distance turn at nearly a right angle, to course over the dorso-lateral surface of the kidney; receiving the initial collecting ducts. In figure 12, is presented one of the

main side branches of the collecting duct system, taken from a very fully injected preparation, in which the injection mass extended into the initial collecting ducts. Their manner of terminating in the superficially placed collecting ducts is clearly shown in the figure. In figure A, and B, of figure 13, are presented two views of a modle of a renal tubule of the common striped snake. In B, the reconstruction as viewed from the side as shown in A, is presented as when viewed from the convex side. The renal tubules of the snake, at least in the form studied,



Fig. 11 Ureter with collecting ducts terminating therein from the left kidney of the common striped snake, *Eutaenia sirtalis*; corrosion preparation.



Fig. 12 Collecting duct of the kidney of *Eutaenia sirtalis*, the common striped snake, with the distal ends of renal tubules emptying therein, corrosion preparation.

present an arched form as seen in figure 13, A, and a quite compact arrangement, somewhat difficult to portray in a figure. In this renal tubule, the renal corpuscle is relatively small and of nearly spherical form, having a diameter of  $43\mu$ . This is attached to a long slender neck, lined by ciliated epithelium, which is followed by the proximal convoluted portion, arranged in the form of a main loop extending from the renal corpuscle to the region of the surface collecting ducts and returning again to a little below the level of the renal corpuscle. This main loop, which presents a number of secondary loops, has a length of 1.6 mm. and is lined by an epithelium having a striated inner border. The proximal convoluted segment is followed by a

short intermediate portion lined by ciliated epithelium and this in turn by the distal convoluted portion. This later portion forms the coil complex well seen at the bottom in B. of figure 13, forming in reality a long loop, directed away from the collecting duct, toward which it returns and with which it connects through a long slender connecting tubule and initial collecting duct. The

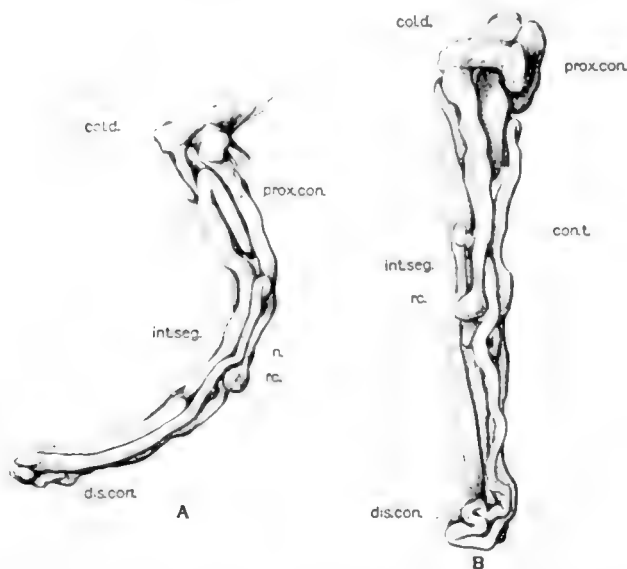


Fig. 13 A and B. Two views of the same renal tubule reconstructed from the kidney of the snake, *Eutaenia sirtalis*.  $\times 80$ . Figure A, gives a sideview, figure B, the same model as viewed with the convex side toward the observer. *rc.*, renal corpuscle; *n.*, neck; *prox.con.*, proximal convoluted segment; *int.seg.*, intermediate segment; *dis.con.*, distal convoluted segment; *con.t.*, connecting tubule; *col.d.*, collecting duct.

distal convoluted portion has a length of 1.5 mm. and the connecting tubule a length of 0.75 mm., giving the entire tubule a length of 4 mm. The figures here given showing a reconstruction of the ophidian renal tubule bears a close resemblance to figures 24 and 25, of plate 5, of Zarnik's article.

*Lizard.* The limited material at my disposal did not enable me to attempt a study of the duct system of the lizard's kidney

by means of corrosion injection methods. Several renal tubules were reconstructed from a series of cross sections of a kidney of a small lizard which unfortunately was not specifically identified. The single figure here given, figure 14, is added more for confirmation of the results of a much more complete study, by means of teasing, of the kidney of the lizard by Zarnik. As may be observed from a study of figure 14, the renal corpuscle is of nearly spherical form having a diameter of  $55\mu$ . The neck is short and is lined by ciliated epithelium. The proximal convoluted portion, Zarnik's 'Hauptstück,' forms a long N-shaped, double loop, with numerous secondary loops, having a length of 1 mm. This tubular segment is lined by relatively clear epithelium

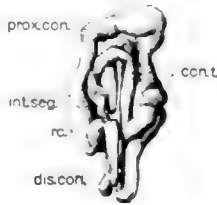


Fig. 14 Reconstruction of renal tubule of the lizard.  $\times 80$ . *rc.*, renal corpuscle; *prox.con.*, proximal convoluted segment; *int.seg.*, intermediate segment; *dis.con.*, distal convoluted segment; *con.t.*, connecting tubule.

having an inner striated border. Its relation to the renal corpuscle is not unlike that found in the mammalian renal tubule. The intermediate segment, 'Übergangsstück' and 'Schleifenstück' of Zarnik's is lined by ciliated epithelium and forms a short segment, in close relation with the renal corpuscle. This is followed by the distal convoluted portion, consisting of a U-shaped loop with numerous secondary loops, having a length of 0.6 mm. This segment joins the collecting duct by means of a short and relatively thick connecting tubule. The entire length of the tubule figured is a little less than 2 mm. The different parts of the tubule are compactly arranged, forming a coil complex more closely grouped than in the renal tubules of the other reptilian forms studied by me. Figure 14, of this article should be compared with figure 12a, plate 3, of Zarnik's contribution, both figures are very similar in all essentials.

## AVIAN METANEPHRIC TUBULES

For the study of the metanephric tubule of birds I made use of the kidneys of adult roosters, *Gallus domestica*. As stated in the introduction to this article an attempt was made quite a number of years ago to reconstruct by means of the wax plate method, the renal tubules of birds, using for this work, series of cross sections of the kidney of the dove. After a number of attempts and the consumption of much time this method was abandoned since success did not seem attainable. It is only relatively recently that time and opportunity presented itself to again take up the investigation of the avian renal tubule, this time by methods of maceration and teasing. This latter attempt has proven more successful. The material was prepared for teasing by injecting under about 20 pounds of pressure, the fresh kidney, through the renal artery with a 75 per cent solution of hydrochloric acid. After this injection, the kidneys was removed and placed in a solution of hydrochloric acid of like strength for a period of several hours, then thoroughly washed in water, stained in an alum hematoxylin solution and teased under the stereoscopic binocular.

While the isolation of complete renal tubules from the bird's kidney presents less difficulty than the isolation of complete renal tubules from the mammalian kidney, still it requires hours and hours of teasing and the passing over of many failures before one obtains a series of satisfactory preparations. The literature contains few references and fewer figures relating to the renal tubules of birds. One very brief reference is found in Chapter 21, Stricker's Manual of Histology (English translation, Wood and Co., New York, '72) written by Carl Ludwig. In figure 171 D of this text is presented a diagrammatic outline drawing representing a renal tubule from the kidney of a dove. A footnote states that this figure was designed by Hüfner. The text contains the following reference to this figure:

It will be noticed at once how strong the resemblance is to the uriniferous tubule of Mammals. The several subdivisions which we make in the latter are also to be found here, and they occur in the same order. As far as our present knowledge goes, the uriniferous tubules of all birds are made on the same plan as those of the dove.

The kidney of the bird is an elongated, distinctly, lobulated organ, with the ureter on the ventral and mesoventral side. Prominent branches pass from the ureter to the several lobules. The ventral or mesoventral portion of each lobule presents a short renal pyramid. The central core of a lobule presents an appearance which is not unlike that presented by the mammalian kidney, namely, a shallow medulla and a cortex. The cortex, particularly, extends on all sides beyond the limits of this central core, presenting an appearance not unlike that presented by the reptilian kidney, especially the chelonian kidney. It is perhaps fortunate for this work that it was necessary to resort to methods of teasing by reason of failure with the method of reconstruction in that the teasing method admits of taking tissue portions from all parts of a lobule, while with reconstruction methods one is limited, by reason of consumption of time, to a reconstruction of one or a small number of tubules. In this study it was early evident that the renal tubules forming the periphery of the lobules presented a form which is very much simpler than is presented by those forming the central core of the lobules. The former presenting a form and arrangement of parts which is not unlike that of the reptilian renal tubules, while the latter present a form and arrangement of parts which resemble the mammalian renal tubules, with transition from one type of tubule to the other in an intermediate zone. From the many renal tubules of birds, successfully and completely isolated, and permanently mounted, I have selected a small series showing this transition from the reptilian type of tubule to the mammalian type. The necessary drawings were made from permanently mounted, completely isolated renal tubules, at a magnification of 200, by aid of camera lucida. In order to bring the figures to a size making reproductions as text figures possible, and yet maintain the same magnification for all the figures of renal tubules of birds, the figures here given represent just half the magnification of the figures detailing the amphibian and reptilian renal tubules. The measurements given for the renal tubules of birds are taken from the drawings, and are perhaps not as accurate as those taken from wax reconstructions.

They give, however, very nearly the actual lengths of the respective renal tubules. In considering the diameter of the different parts of the renal tubules of birds, as here figured, it should be understood that in order to mount permanently in glycerine the completely teased renal tubules it is necessary to allow them to dry partially on the slide after the removal of the fluid in which they are teased. This fixes them to the slide sufficiently so that they are not broken and distorted when the cover glass and mounting fluid are added. However, in this process the respective tubule loses in diameter, though scarcely in length. The camera lucida drawing here reproduced, therefore, do not represent the full diameter of the tubules figured. It is further to be understood that in order to be certain that the tubule under teasing is in reality a single tubule, it is necessary to tease and separate all coils or loops and to be able to tease completely from renal corpusele to collecting ducts the entire tubule. This makes it difficult and quite impossible to bring the several parts into normal positions, though there is a marked tendency for a given tubule to do this if allowed to remain undisturbed for a few moments in the fluid in which it is being teased. However, the manipulations necessary to mounting permanently such a preparation usually leads to slight distortion and movement of parts so that the respective tubule comes to rest on the slide slightly spread out, admitting usually of readier interpretation and clearer representation in drawing, but does not present the normal relations of parts. In this latter respect tubules isolated by teasing suffer in comparison with such as are reproduced by wax reconstruction.

It is my purpose to discuss the several types of renal tubules of the bird observed, by beginning with a consideration of the simplest type and proceeding to the larger and more complex types. In figure 15, A, B and C, are reproduced three renal tubules taken from the more peripheral portions of one of the lobules of the kidney of an adult rooster. Each is complete from renal corpusele to collecting duct. A comparison of these figures with the figures here given of the reptilian renal tubule, especially A and B, of figure 5, will show that there exists a



marked morphologic similarity in form and arrangement of parts of the reptilian and certain avian renal tubules. In each of the three tubules reproduced in figure 15, the renal corpuscle is relatively small and of nearly spherical form. Each is joined to the respective tubule by a narrow neck. This is followed by a tubular segment which constitutes the proximal convoluted portion, arranged in each of the three tubules figured in the form of a letter N, each part of the N presenting numerous secondary

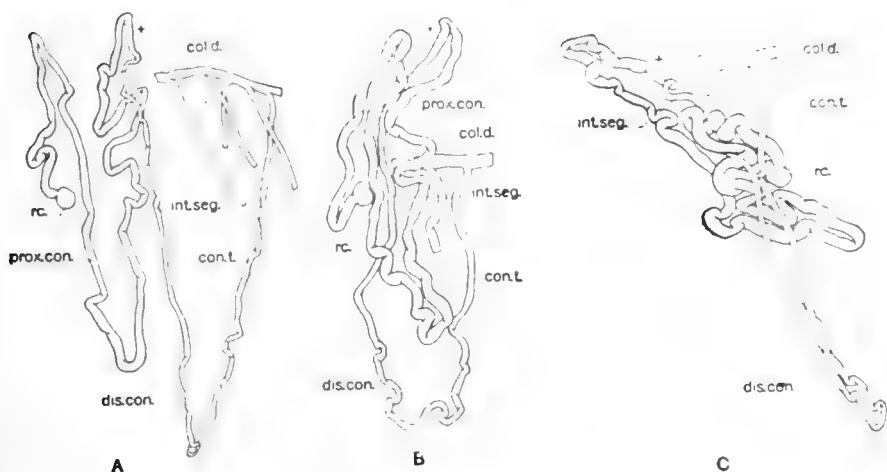


Fig. 15 A, B and C. Three renal tubules of the reptilian type, teased from the peripheral portion of a renal lobule, from the kidney of an adult rooster, *Gallus domestica*.  $\times 40$ . *rc.*, renal corpuscle; *n.*, neck; *prox.con.*, proximal convoluted segment; *int.seg.*, intermediate segment; *dis.con.*, distal convoluted segment; *con.t.*, connecting or junctional tubule; *col.d.*, collecting duct.

loops, all partly extended in the preparations as mounted. The arrangements of the tubular segment is perhaps most clearly shown in tubule A, in which its general course is clearly followed. A study of tubule B, shows the same arrangement and in tubule C, the greater part of the coil complex, tilted accidentally to the left, constitutes this tubular segment. In this part of tubule C, the normal relation of the respective loops is better maintained than in the other two tubules. If the coil complex in C, tilted diagonally to the left, be brought in line with the rest of the

figure, fairly normal relations are obtained for all of this tubule. The actual length of the proximal convoluted tubular segment in the three tubules shown in figure 5, is—A, 3.8 mm.; B—3.5 mm.; C—3.6 mm. I realize fully that there exist several sources of error in the method used in obtaining the actual length of the several tubular segments considered—measuring the tubule as drawn enlarged in the figure and dividing by magnification used—however, the length given may be regarded as approximately correct. Macerated and teased preparations, even where mounted in glycerine, present very little evidence as concerns the cellular structure of the different segments, a slight difference in the depths of staining may be observed, but the nuclei are not differentiated. In this respect the method of teasing is less favorable than wax plate reconstruction, since in the latter a very complete series of sections is a necessity. However, the proximal convoluted portion of the birds renal tubule is readily recognized and presents a structure which is similar to that shown for this tubular segment of the mammalian renal tubule. In the three renal tubules presented in figure 15, the proximal convoluted segments of each tubule terminate at the upper limits of the figure, at the region indicated by a small cross. This tubular segment is followed by a relatively thin tubular portion, comparable to the thin arm of the medullary loop of the mammalian renal tubule, though its epithelium is not of a distinctly squamous type. This segment, which may be known as the intermediate segment, in the majority of the tubules completely or only partially teased presents a number of small loops, difficult to unravel. This intermediate segment is followed by the distal convoluted portion, consisting of a number of compactly arranged loops and coils, also forming a portion difficult to tease. In the three tubules figured this portion is presented as unrolled and forms the most dependent part of each of the three figures. By means of the connecting or junctional tubular segments, the distal convoluted portions join the respective collecting ducts; the distal end of the collecting ducts in the peripheral portions of the lobule, coursing nearly parallel to the dorsal surface of the lobule and receiving connecting tubules

at short intervals. This may in part be seen in A, of figure 15, in which a short segment of a terminal collecting duct, receiving four connecting or junctional tubules is shown. The entire length of tubule A, figure 15, as measured from the drawing is 6.5 mm. In figure 16 is reproduced a drawing of a tubule completely isolated from a small portion of tissue taken from the periphery of one of the lobules. The parts indicated for the tubules described under figure 15 are present in this tubule, though it was found as a much more compact mass before teasing, and is mounted spread out in nearly a single plane. The entire length of this tubule is approximately 8 mm., of which 4 mm. falls

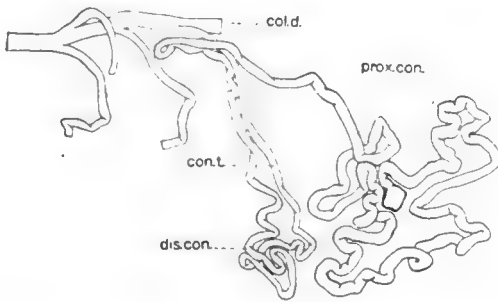


Fig. 16 Renal tubule from bird, *Gallus domestica*, teased from the peripheral portion of a renal lobule.  $\times 40$ . The proximal convoluted segment, *prox.con.*, and the distal convoluted segment, *dis.con.*, are here clearly represented.

to the proximal convoluted portion. In the figure of this tubule, the two coils complexes constituting the proximal and distal convoluted segments, are clearly seen in the two distinct groups of loops forming the right and left part of the figure. In figure 17, is presented a drawing of a completely isolated tubule with a portion of the connected duct system, taken from the more peripheral portion of the central part of a lobule. This tubule approaches in form and arrangement of parts a mammalian renal tubule, having a short medullary loop which presents, however, a number of small secondary loops. The renal corpuscle is of spherical form and is relatively larger than in the tubules shown in figures 15 and 16. The initial portion of the

proximal convoluted segment extends toward the ventral portion of the lobule toward the region of the medulla, then returns toward the periphery of the cortex to form an extended loop with many secondary, smaller loops. The length of this proximal convoluted segment, which forms the coil complex at the left of the figure and extends from the renal corpuscle to the region

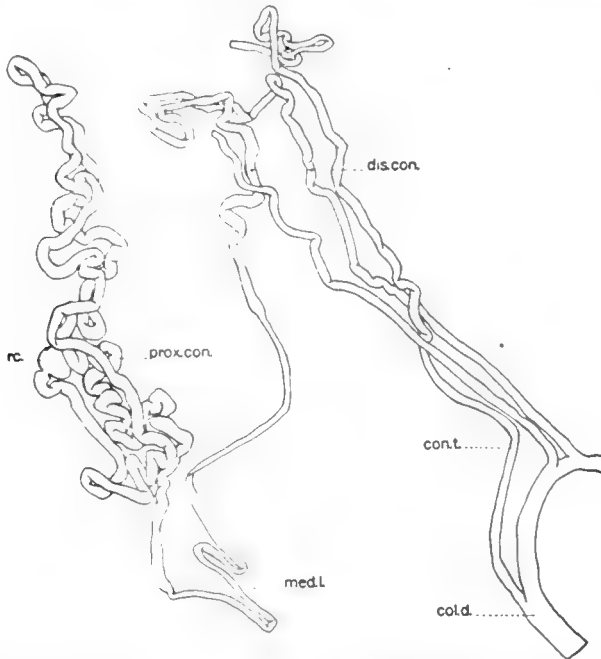


Fig. 17 Renal tubule of the bird, *Gallus domestica*, completely isolated by teasing, showing transition from reptilian to mammalian type or renal tubule.  $\times 40$ . *rc.*, renal corpuscle; *prox.con.*, proximal convoluted segment; *med.l.*, medullary loop; *dis.con.*, distal convoluted segment; *cont.*, connecting tubule; *col.d.*, collecting duct.

where the tubule becomes suddenly thinner, is approximately 7.5 mm.; thus approaching the length of the proximal convoluted segment of the mammalian renal tubule. The medullary loop of this tubule is relatively short, having a length of 1.8 mm. and ending in the region where the tubule again increases in size; about the middle of the figure. This segment is followed by a

second coil complex, forming the distal convoluted portion, practically unrolled as presented in this figure, in reality forming a compact coil complex, and leading to a relatively long connecting or junctional tubule ending in the collecting duct. The entire length of this tubule is approximately 13 mm. In figure

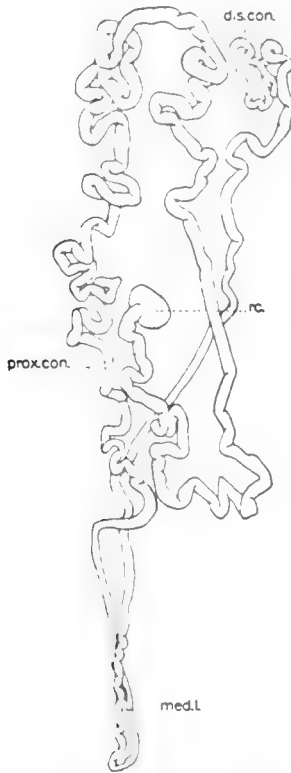


Fig. 18 Renal tubule of the bird, *Gallus domestica*, isolated by teasing.  $\times 40$ . This renal tubule possesses a short medullary loop, presenting short loops in the distal arm. The different segments are so placed as to be easily recognized. Figure legends as for figure 17.

18 is reproduced a tubule which was very successfully mounted with reference to exposing the several segments of the tubule, which is very similar to that shown in figure 17, though it was broken in teasing just distal to the distal convoluted portion, so that its relation to the collecting duct cannot be shown. The

relatively large renal corpuscle of spherical form, the long proximal convoluted segment, arranged in the form of a long loop with numerous secondary loops, the short medullary loop and the distal convoluted portion, are clearly seen in this figure. This tubule, to the extent contained in the figure, has a length of 13.5 mm., to which perhaps 1 mm. need be added to complete the length to the collecting duct. Of this length, 8 mm. falls to the proximal convoluted portion. Tubules very similar in form and relation of parts to those reproduced in figures 17 and 18 may be found in the peripheral cortical portion of the mammalian kidney, especially in the human kidney, in which tubules are found which do not pass the limits of the cortex.

In figure 19, is reproduced a camera lucida drawing of a renal tubule from the bird, taken from the central portion of one of the kidney lobules. This preparation was very successfully teased and is permanently mounted just as shown in the figure, in which the several segments are so placed that their course may be followed with ease. This renal tubule of the bird is representative of the type of avian renal tubules, which in general form, sequence and relation of parts, relation to cortex and medulla is in essentials very similar to a mammalian renal tubule. The figure seems to me so clear that lengthy discussion is unnecessary. The relatively large renal corpuscle, of spherical form, joins the proximal convoluted portion by means of a short neck. The proximal convoluted portion is arranged in the form of a long loop, with numerous secondary loops, extending toward the periphery of the cortex and returning to the vicinity of the renal corpuscle and for a distance into the medulla. The length of this tubular segment, from renal corpuscle to the region of the small cross, is approximately 8.5 mm. The medullary loop (loop of Henle) extends for a distance into the medulla. In the teased preparation it was not possible to determine definitely the character of its epithelium, though the proximal arm appears stained slightly lighter than the distal arm as though lined by a thinner epithelium. The distal arm returns toward the cortex and comes in close relation with the renal corpuscle of the tubule, this relation is not shown in the mounted preparation but was

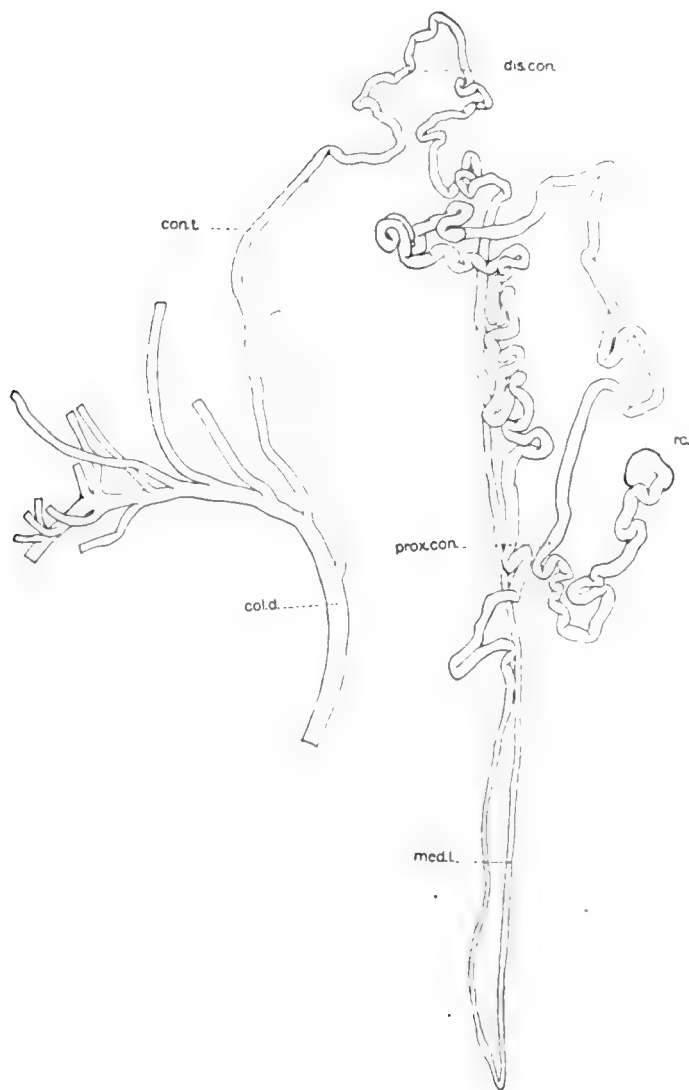
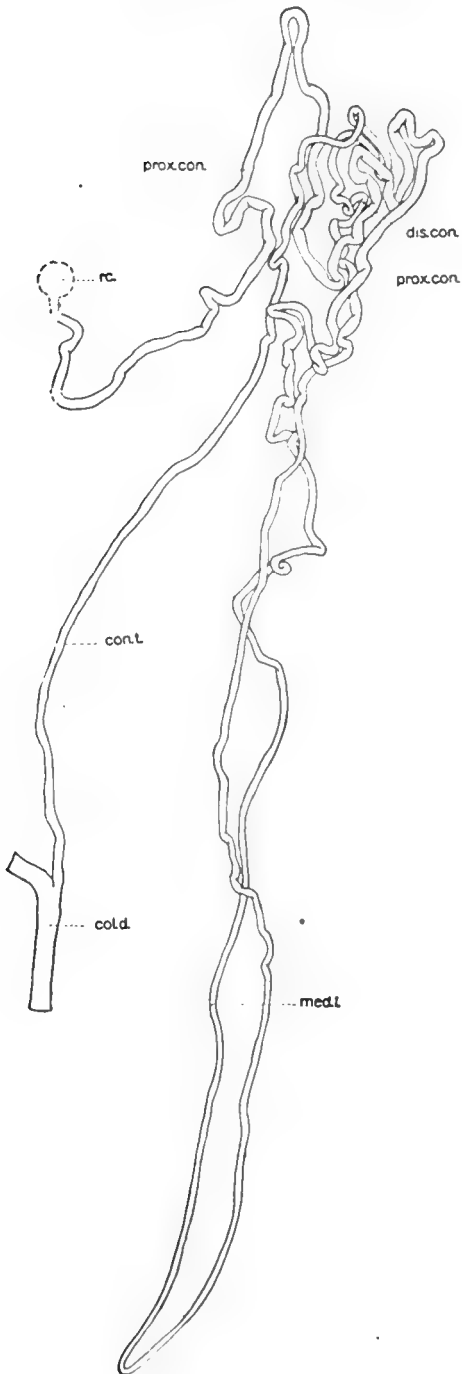


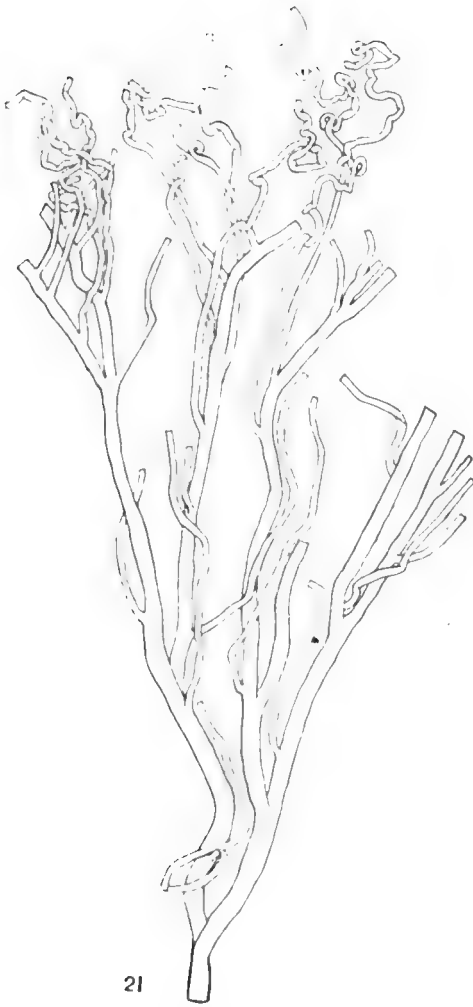Fig. 19 Renal tubule of bird, *Gallus domestica*, isolated by teasing from the central portion of a renal lobule.  $\times 40$ . This tubule is of the mammalian type of avian renal tubules. *rc.*, renal corpuscle; *prox.con.*, proximal convoluted segment; *med.l.*, medullary loop; *dis.con.*, distal convoluted segment; *con.t.*, connecting or junctional tubule; *col.d.*, collecting duct.

ascertained before the tubule was completely teased. The length of the medullary loop with the ascending limb to beginning of distal convoluted portion (coil complex, upper right of figure) is 3.6 mm. The distal convoluted portion, upper right of figure, presents two more prominent loops each with several secondary loops. Before teasing, this portion was compactly arranged and has a length of 2.2 mm. It is followed by a long connecting or junctional tubular segment leading to the collecting duct, and adding 1.2 mm. to the length of the tube. As may be seen from the figure a portion of the collecting duct system was isolated in connection with the tubule figured. The branches of the collecting duct figured represent other renal tubules connecting with the same. The entire length of this tubule is approximately 15.5 mm., as measured from the drawing. In figure 20, is reproduced a camera lucida drawing of the longest renal tubule of the bird isolated. It comes from the central portion of a renal lobule. In trying to mount permanently this preparation, I endeavored to adjust slightly the position of the renal corpusele, with the result that the renal tubule was broken in two places in the immediate vicinity of the renal corpusele. The broken pieces, represented by dotted lines, were brought to place as shown in the figure. This tubule is not so favorably placed in the permanent mount as the one shown in the previous figure. However, it is thought that the different parts can be traced. The tubule shown in figure 20, presents the following measurements proximal convoluted portion, 7.5 mm.; medullary loop with distal ascending limb to beginning of distal convoluted portion 6.5 mm.; distal convoluted segment 2.2 mm.; connecting or junctional segment—2 mm.; giving the entire tubule from renal corpusele to collecting duct a length of 18.2 mm., which is somewhat over half the length of the longest mammalian renal tubule isolated by me. In figure 21, is shown a camera lucida drawing taken from the most

Fig. 20 Renal tubule of the bird, *Gallus domestica*. Mammalian type of avian renal tubules; isolated by teasing. Tubule was broken in making permanent mount; broken parts outlined in dotted lines.  $\times 40$ . Figure legends as in figure 19.







successful teased preparation of the duct system of the bird's kidney made by me. The preparation came from the central portion of a renal lobule and traces one of the main collecting ducts through its several branches to and including the end segments of renal tubules ending in this portion of the duct system. Many of the main branches of this duct are not traced to their termination in this figure, but extend to the peripheral and lateral portions of the renal lobule receiving the renal tubules which have been described as showing a reptilian type of renal tubule. It will be observed that the renal tubules of the bird end in the several divisions of the duct system, those ending deep in the medulla having long connecting or junctional tubules as shown in figures 19 and 20.

A study of the figure of the avian renal tubule as here presented may serve to show that in the birds kidney, there is found a transition, so far as concerns the form of the renal tubule, from the reptilian type of metanephric tubule to the mammalian type of the metanephric tubule. A study of the vascular supply, with the use of the modern corrosion methods is very desirable. Zarnik gives a good account of the blood supply of the reptilian kidney, I believe as far as concerns the terminal branches of the renal artery and their relation to the renal tubule of the mammalian kidney, my own account gives correctly the essentials. It is desirable, therefore, that the details of the blood supply of the avian kidney be equally carefully studied. It is hoped that opportunity will present itself to do this in this laboratory or that some other laboratory will undertake this investigation.

Fig. 21 Primary collecting duct with branches, teased from the center of a renal lobule of the bird, *Gallus domestica*. The tortuous tubules, upper part of figure, represent distal convoluted and junctional segments of renal tubules.

Fig. 22 Renal tubule of rabbit, isolated by teasing.  $\times 20$ . *rc*, renal corpuscle; *prox.con.*, proximal convoluted segment; *med.l.*, medullary loop, from  $\times$  to  $\times$  of this loop, the thin segment lined by squamous epithelium. *dis.con.*, distal convoluted segment. The tubule ends just distal to distal convoluted portion.

## METANEPHRIC TUBULES OF MAMMALS

It is not my purpose to discuss here fully the renal tubules of the mammalian kidney. This has been done relatively recently by Karl Peter<sup>1</sup> in his comprehensive monograph, by Inouye<sup>2</sup> in an addendum to the Peter monograph, by Zarnik in his report on the renal tubules of *Echidna* and by myself, my report being based on completely isolated renal tubules of the rabbits kidney. However, in order to make this series of renal tubules of vertebrates complete in this one article, there is here given in figure 22, a new drawing of tubule B, of plate I, accompanying the contribution "A method for isolating the renal tubules of mammalia" (Huber)<sup>3</sup> reproduced here at a magnification of 20 diameters, one-half of the magnification used in reproducing the renal tubules of birds, and one-fourth of the magnification used in the reproduction of the renal tubules of the other vertebrates studied. From the text of the article mentioned it may be learned that the mammalian renal tubule here shown, and which may be taken as a type tubule, has a total length of 23 mm. It presents a mammalian renal tubule of medium length. One, the renal corpusele of which is situated at about the mid level of the cortex. In this tubule, the proximal convoluted portion with the medullary segment has a length of 9.4 mm.; the thin portion of the medullary loop, a length of 6.7 mm.; the thicker portion of the ascending limb of the medullary loop to the level of the renal corpusele a length of 6.0 mm.; the distal convoluted segment a length of 0.9 mm. The tubule was isolated completely and mounted in the position as drawn<sup>4</sup> to just beyond the distal convoluted portion. The connection or junctional segment is thus missing. This would add approxi-

<sup>1</sup> Peter, Karl, *Untersuchung über Bau und Entwicklung der Niere.* (Karl Peter, *Die Nierenkanälchen des Menschen und einiger Säugetiere.*<sup>2</sup> Michio Inouye, *die Nierenkanälchen des Rindes und des Trümmers.* Gustav Fischer, Jena, 1909.

<sup>3</sup> In the figure as here given, the loop in the lower end of the medullary loop, as drawn in tubule B, plate I, *Anat. Rec.*, vol. 5, is eliminated. This was done by first drawing the lower end of the medullary loop as found in the preparation, then placing a string over the tracing then extending the string in the form of a simple loop, as given in figure 22.

mately 1 mm. to the total length of this tubule. The epithelium characterizing the different segments of the mammalian renal tubule, I have discussed in the former publication as also the position of the different segments in the kidney substance and their relation to each other.

A careful investigation, with the use of appropriate maceration and teasing methods of the renal tubules of a number of mammals is still desirable. Peter has called attention to the difference in structure of the two arms of the medullary loop and of the loop itself in different mammals and in the same kidney for tubules of different lengths. This I have confirmed, but not in preparations showing renal tubules, completely isolated, so that the comparative and total length of the different segments of a given renal tubule could be given; which is much to be desired. Other parts of the renal tubules of mammals vary in detail of structure. In the guinea pig, for instance, the distal convoluted portion has a diameter which is approximately the same as that of the proximal convoluted portion, though it is much shorter, differing in this respect from that of the rabbit. The close relation existing between structure and function makes it desirable to be fully informed as to the details of structure of the different segments of the renal tubules.

It is hoped that this series of figures, brought together in limited space, presenting type forms of the renal tubules of the different classes of vertebrates, may not be without value to both students of morphology and functions.



## ON THE MORPHOGENESIS OF THE PAPILLA FOLIATA OF THE RABBIT

G. CARL HUBER AND ARNOLD H. EGGERTH

*Department of Anatomy, University of Michigan*

SIX FIGURES

There exist in the literature numerous contributions dealing with the form and distribution of the gustatory papillae in vertebrates and with the structure and innervation of the gustatory buds. This literature is foreign to the problem here under discussion and will not receive consideration at the present time. Relatively few observers have dealt with the development of the gustatory papillae, and fewer still have considered the development of the papilla foliata of the rabbit or of other forms in which this type of gustatory papilla is prominent. v. Wyss<sup>1</sup> who was the first to call attention to the details of structure of the papilla foliata of the rabbit and the great number of gustatory buds there found, makes only incidental mention of its development, stating that it is quite well formed in the new born rabbit and contains taste buds which have, however, a more rounded form and are smaller than in the grown animal. Lustig<sup>2</sup> states that with the aid of a lens he was able to recognize the papilla foliata in rabbit embryos having a length of 6 mm. to 7.5 mm. and that they are more developed in 10 mm. rabbit embryos, however, that it was not possible for him so define the taste buds. A fairly comprehensive account of the development of the papilla foliata of the rabbit is given by Hermann.<sup>3</sup> This observer found that

<sup>1</sup> v. Wyss, H., Die becherförmigen Organe der Zunge. Arch. f. Mik. Anat., vol. 6, 1870.

<sup>2</sup> Lustig, A., Beiträge zur Kenntniss der Entwicklung der Geschmacksknospen. Sitzungsber. Akad. d. Wissensch. Vienna, Math. Nat. Classe, vol. 89, 1884.

<sup>3</sup> Hermann, F., Beitrag zur Entwicklungsgeschichte des Geschmackorgans beim Kaninchen. Arch. f. Mik. Anat., vol. 24, 1885.

the papilla foliata was first recognizable in rabbit embryos having a length of 54 mm. (age, about twenty-three days), as an oval, slightly elevated area, with long axis horizontal and with faint grooves having a vertical direction. In longitudinal sections, papillae formed by simple infolding of the epithelium were observed. In embryos having a length of 70 mm. (about twenty-four days) the foliate area is no longer quite horizontal in position, its posterior end being nearer the median line. The epithelial papillae are longer and broader, the primary infoldings presenting at about the middle of their depth, on each side, a slight projection, most fully developed in the middle of the area. In embryos having a length of 95 mm., thus only a few days before birth the slight projectings of the primary folds have developed into secondary folds and the anlagen of the serous lingual glands are evident. In the new born rabbit the secondary folds of the papillae are longer, the whole area, however, presenting essentially the same appearance as that found in a 95 mm. rabbit. In its main feature, we confirm the observations of Hermann. As a result of a comparative study Brücher<sup>4</sup> concludes that the prototype of the gustatory papillae is the papilla fungiformis, out of which developed both the p. vallata and the p. foliata, since transition forms are observed. Gmelin<sup>5</sup> on the other hand, also as a result of a comparative study, concludes that the p. vallata is not developed from the p. fungiformis, nor the p. foliata from the p. vallata, but that both p. vallata and p. foliata are independent in their origin, each having its special seat of development, and that transition forms are not observed. Hoffmann,<sup>6</sup> Tuckermann,<sup>7</sup> and more recently, Gräberg,<sup>8</sup> have pub-

<sup>4</sup> Brücher, Über die Vertheilung und Anordnung der Geschmacks-papillen auf der Zunge der Säugethiere, spec. der Hufthiere. Deutsch. Zeitsch. f. Thiermed. u. verg. Path., vol. 10, 1884.

<sup>5</sup> Gmelin, Zur Morphologie der Papilla vallata und foliata. Arch. f. Mik. Anat., vol. 40, 1892.

<sup>6</sup> Hoffmann, Über die Verbreitung der Geschmacksorgane beim Menschen. Arch. f. Path., vol. 62, 1875.

<sup>7</sup> Tuckermann, F., On the development of the taste-organs of man. Jour. Anat. Phys., vol. 23, 1889.

<sup>8</sup> Gräberg, J., Beiträge zur Genese der Geschmacksorgane des Menschen. Morphol. Arbeit., vol. 8, 1898.



lished concerning the development of the vallata papillae of man, but since their observations bear only incidentally on those here recorded their publications will not receive review here. M. Heidenhain,<sup>9,10</sup> has in two relatively recent communications considered very fully certain aspects of the papilla foliata of the rabbit. Certain points discussed in these articles may here be touched on. He finds the foliata area of the grown rabbit to be of pear or egg-shape, with the narrower end directed caudally, the rounder end forwards. The folds, of which there are about 16, run from the ventral to the dorsal border, diverging somewhat dorsally, with the longer ones having a slight curvature. Bifurcation of the folds was observed. This division of folds he recognizes as indication of a developmental process. This thought he expresses as follows: "Wir halten es daher für möglich, dass die Leisten Histosysteme sind deren Anlage, im Laufe der Entwicklung durch Spaltung vermehrt werden, so dass gelegentlich bei unvollkommener Sonderung Gabelungen entstehen."

Though familiar with Hermann's observations on the development of the papilla foliata in the rabbit, before our investigation was undertaken, it occurred to us that a careful study of the morphogenesis of the foliata area was still desirable, especially if free use was made of the Born wax plate reconstruction method, and a complete series of timed stages, ranging from the time of its first appearance as a definite area to the time of birth could be commanded. It seemed to us desirable to determine whether a definite pattern of epithelial folds was here present, whether the area had its anlage as whole or spread by peripheral growth with increase of the numbers of folds, as well as to determine more definitely the morphogenesis of the folds and the relations of the serous lingual glands to them. To do this it was found necessary to reconstruct by means of the Born plate method the

<sup>9</sup> Heidenhain, M., Untersuchungen über die Teilkörpurnatur der Geschmacksknospen in der Papilla foliata des Kaninchens. *Anat. Anz.*, vol. 45, 1914.

<sup>10</sup> Heidenhain, M., Über die Sinnesfelder und die Geschmacksknospen der Papilla foliata des Kaninchens. *Beiträge zur Teilkörpertheorie*, III. *Arch. f. Mik. Anat.*, vol. 85, 1914.

entire foliate area in a number of stages of development. The models here figured were prepared by Mr. Eggerth and constituted a part of the work required toward a Master of Arts degree with major in Anatomy.

All of the observations here recorded are based on timed material. For the 18, 19 and 20 day stages, frontal and sagittal series of heads of embryos rabbits were used, fixed in Carnoy's fluid and stained on the slide in iron hematoxylin and Congo red. For the stages covering 21 day to 30 day embryos, the lower jaw with tongue and larynx (for younger stages), the tongue and larynx (older stages) were removed and fixed in Yoshii's fluid. The material derived from the 21 day and 22 day embryos was sectional so as to obtain frontal sections of the tongue; approximately longitudinal sections of the foliata areas. For all other stages the foliate area with a block of underlying muscle was excised, oriented in the paraffine block so that longitudinal sections, at right angle to the main folds, might be cut. Complete series of sections,  $4\mu$  or  $5\mu$  in thickness of all stages, cut by the water-on-the-knife method with sliding microtome, were at our disposal. These were stained, some of the series in iron hematoxylin, others in Minot's hematoxylin and counterstained in Congo red. For complete series of relatively thin sections, the water-on-the-knife method with sliding microtome is especially recommended in preference to series cut on a rotary microtome, especially if the series are to be used, for reconstruction purposes. The models, though very time consuming in their preparation, presented no special difficulty in execution. They were made at a magnification of 300 diameters with thickness of the plates adjusted to meet the needs. The figures of the models, greatly reduced in reproduction, present the configuration of the epithelium of the foliate area as viewed from the under or mucosal side. A series of drawings of the epithelial border, taken from approximately the center of the papilla foliata of the several stages studied, from longitudinally cut series, is presented in figure 1. These figures may with profit be compared with the figure of the model for the equivalent stage, since for the stages modelled, the drawing for the respective

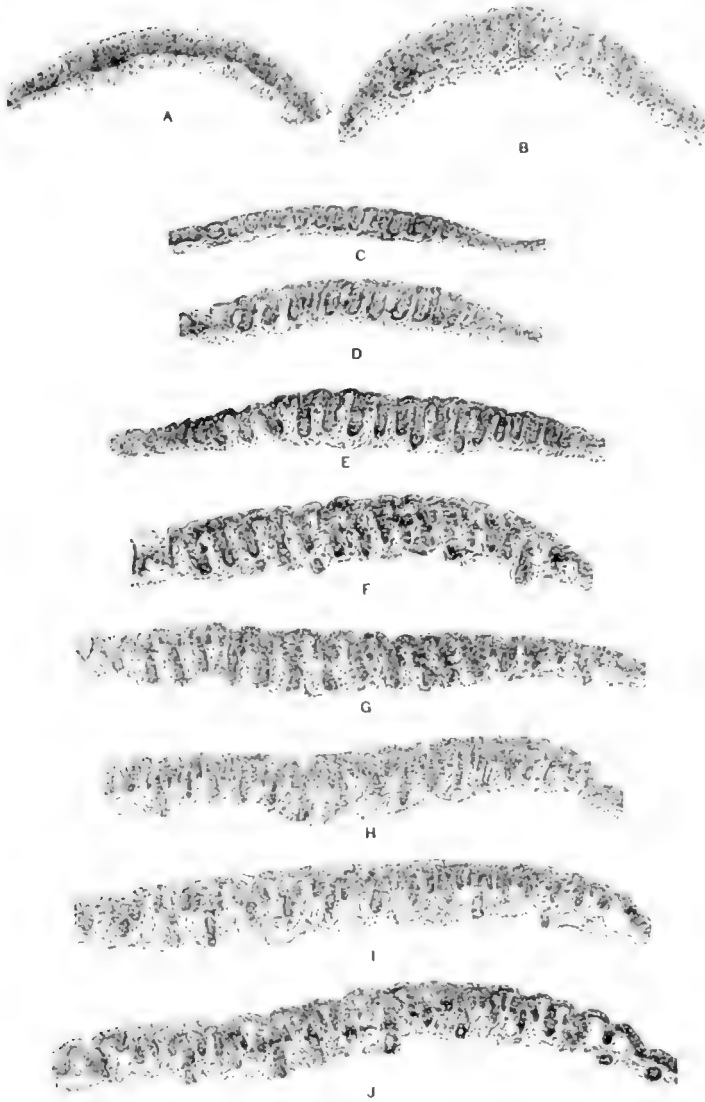
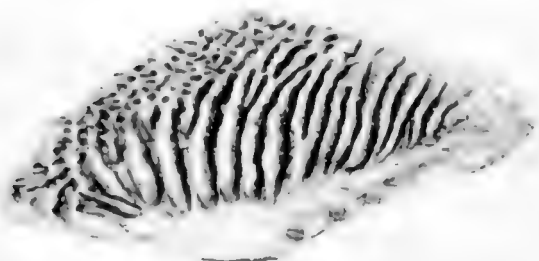

Fig. 1 Drawings of the epithelial border with the underlying mucosa of the foliate area of a rabbit embryos of different stages of development. *A* and *B*,  $\times 100$ ; *C* to *J*,  $\times 50$ . *A*, from rabbit embryo of 18 days; *B*, 20 days; *C*, 21 days; *D*, 23 days; *E*, 24 days; *F*, 26 days; *G*, 27 days; *H*, 28 days; *I*, 29 days; *J*, 30 days.

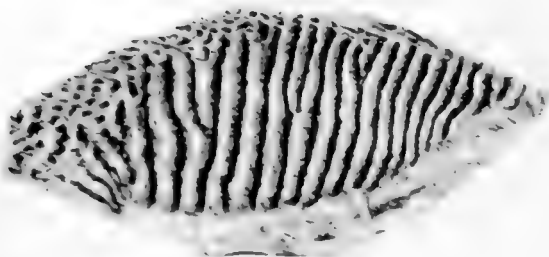
stage was taken from one of the sections of the series used in the preparation of the model covering that stage.

In presenting our own observations we will begin with the consideration of the stage in which the foliata area is first recognized and proceed in serial order of stages to the time of birth. It has appeared to us that the areas in which the foliate papillae develop, may be recognized before the appearance of the primary epithelial folds characterizing these areas. In a series of frontal sections, including the posterior portion of the tongue of a rabbit embryo of 18 days, a slightly elevated, oval area may be fairly clearly delimited on the lateral and dorso-lateral surface of the posterior part of the tongue, in front of the developing larynx and in front of the arcus palatoglossus of each side. In *A*, of figure 1, there is presented a drawing of the epithelium of approximately the middle section passing through the right pre-foliate area. A study of this series permits the conclusion that the epithelium of the anterior part of this area is cut in fairly accurate cross-sections, while that of the posterior part is cut slightly obliquely. This area, as the figure may serve to show, is covered by squamous epithelium, which in the pre-foliate area is slightly thicker than in the region anterior and posterior to this area. In a series of frontal sections of the tongue of a rabbit embryo of 20 days, the foliate area is clearly recognized, as may be observed from a study of section *B*, of figure 1. The foliate areas present at this stage, on the under surface of the epithelium, a series of epithelial folds which clearly characterize these areas. The drawing was made from approximately the middle of the series of sections passing through the right foliate area of this stage. The section drawn presents a fairly accurate cross-section of the epithelium, but passes slightly obliquely through the area, not quite parallel to its long axis. That the 10 or 11 fairly well formed epithelial papillae, as seen in the sections, are in reality sections of epithelial folds is readily determined by graphic reconstruction and is corroborated by a study of a series of sagittal sections of the head of a rabbit embryo of 19 days in which the foliate areas are cut tangentially with reference to the epithelial surfaces, so that the epithelial folds are

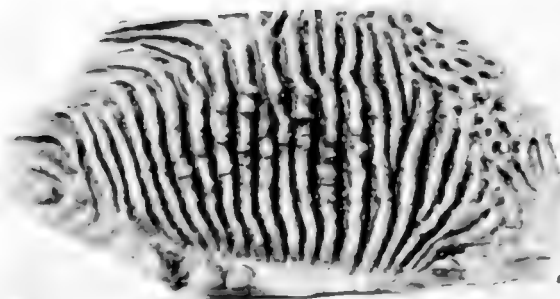
cut longitudinally for a short distance. The primary folds of the foliata areas, therefore, make their appearance about the 19th day of the rabbits' development and are clearly indicated on the under surface of the epithelium by the 20th day, although there is no definite indication of such epithelial folds on surface inspection, even when viewed with the aid of a stereoscopic binocular. The impression is gained that these folds spring into existence relatively suddenly as if by a folding of the under layer, the germinal layer, of the epithelium. As the figure may serve to show, the folding does not involve the entire thickness of the epithelium and there is observed no unusual number of mitotic figures in this foliate area. The mechanism we are unable to determine positively. In a study of the series of stages shown in figure 1, it should be recognized that *A* and *B* of this figure were drawn at a magnification of 600 diameters, while all the other sections were drawn at a magnification of 300 diameters, the whole figure being reduced to the same extent in reproduction. For the next stage, that of a 21 day rabbit embryo, we are able to present a figure of a model showing the under surface of the epithelium one of the foliate areas as well as a drawing of one of the series of sections from which this model was made. In figure 2 is reproduced a photograph of the under or mucosal surface of a model representing a cast of the epithelium of the right foliate area and immediate surroundings, made at a magnification of 300 diameters. The right foliate area was cut from the tongue of a rabbit embryo of 21 days, oriented in the paraffine block so as to enable obtaining cross-sections of the major folds, shallow grooves on the surface, clearly evident under the stereoscopic binocular indicating the direction of these folds. From the finished reconstruction it is learned that the line of the sections is not parallel to the long axis of this foliate area. This is to be given cognizance in interpreting *C*, of figure 1, a drawing of the epithelium of one of the sections of this area, which does not present a section through its longest axis, though taken from about the middle of the series and as shown by the model, passes almost exactly at right angles to the long axis of the major folds. In figure 2, the foliate area proper



2



3



4

is readily delimited. The dorsal border of the area is directed upwards and the anterior border to the left. To the left and left upper portion of this figure the presence of epithelial pits, which received mucosal papillae may be observed. Ventrally and posterior to the foliate area, the mucosal surface of the epithelium is fairly smooth. The foliate area as reconstructed presents an elongated egg-shape and in general contour, except for width, and in configuration is not unlike the foliate area of an adult rabbit as figured by Heidenhain<sup>10</sup> in his text figures d, e and f. In this area, as the figure of the model may serve to show, there are present at least 15 primary epithelial folds. It may further be observed that there is at this stage division or bifurcation of certain of the primary epithelial folds, both in a dorsal and in a ventral direction as also figured and discussed by Heidenhain, for the foliate area of the adult rabbit. The fact that about as many primary epithelial folds are present in the foliate area at this early stage in development as in the adult rabbit would seem to indicate that these primary epithelial folds may be regarded as 'Histosystems' in Heidenhain's terminology; further, the fact that about as much splitting or bifurcation of the primary epithelial folds is to be observed at this stage as in the adult rabbit may serve to indicate that the number of the primary epithelial folds is not materially increased by longitudinal splitting of folds of earlier stages of development. As may be observed from the figure, the primary epithelial folds converge toward about the middle of the ventral border, and the major folds present a slight curvature directed toward the front of the tongue, very much as described by Heidenhain

Fig. 2 Photograph of the mucosal surface of a wax plate reconstruction of the epithelium of the right foliate area of a rabbit embryo of 21 days. Magnification approximately 50 diameters.

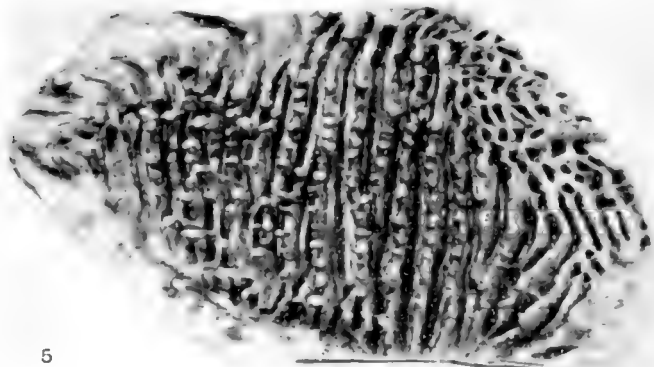
Fig. 3 Photograph of the mucosal surface of a wax plate reconstruction of the epithelium of the right foliate area of a rabbit embryo of 23 days. Magnification approximately 50 diameters.

Fig. 4 Photograph of the mucosal surface of a wax plate reconstruction of the epithelium of the left foliate area of a rabbit embryo of 24 days. Magnification approximately 50 diameters. Note the anlagen of the serous lingual glands in the center of the foliate area.


for the adult rabbit. Section *C*, of figure 1, presents a drawing of the epithelium of approximately the middle of the series from which the model of figure 2 was made. The section is so placed that the epithelium bordering the anterior part of the foliate area is directed toward the left, as with all the sections of the series shown in figure 1. Perhaps 13 definite primary epithelial folds as seen in cross-section, may be observed in this figure. It should be observed that the shallow grooves, described as seen on surface view of this foliate area, fall over the center of the epithelial folds, and are the grooves into which empty the serous lingual glands in later stages of development. The primary mucosal folds interdigitate with the primary epithelial folds. The series of sections of the foliate areas of a rabbit embryo of 22 days are in all respects so similar to those of the 21 day stage just described, that a special consideration of the 22 day stage may here be dispensed with. The 23 day stage was reconstructed from an excellent series of sections which pass almost at right angle to the major primary epithelial folds and give the epithelium of this area in very good cross-section. The under surface of the model of the epithelium is presented in figure 3, the accompanying section drawing in *D*, of figure 1. Figure 3, thus shows the mucosal surface of the right foliate area of a rabbit embryo of 23 days, with the surrounding epithelium. There are found 16 well formed primary epithelial folds, three of which show division in a dorsal direction. These folds are well formed and clearly defined and are so clearly portrayed in the figure that a detailed consideration of them is deemed unnecessary. At the lower border of the figure there may be observed the anlage of a mucous gland, budding from the epithelium just ventral to the foliate area. Three such gland anlagen are observed in the model only one of which is seen in the figure. The mucous glands of the posterior and posterior ventral part of the rabbit's tongue thus have their anlagen at an earlier stage of development than do the serous lingual glands of the foliate area. When section *D*, of figure 1, (23 days) is compared with section *C* (21 days) of this figure, it will be observed that the primary epithelial folds as seen in sections, are deeper in the older stage,



though of essentially the same form. The primary mucosal folds are likewise better developed in the older stage. It may be observed from a study of the figure that nearly every primary mucosal fold carries near its crest a capillary loop, which capillary loops, for relatively long distances, course parallel to the epithelium. We have included a reconstruction and drawing of a section of a foliate area of a rabbit embryo of 24 days, in that in this stage there is observed the first indication of the anlagen of the serous lingual glands also characteristic changes in the primary epithelial folds are seen. In figure 4, is reproduced the mucosal surface of a reconstruction of the epithelium of the left foliate area of a rabbit embryo of 24 days. (In comparing figures 4, 5 and 6, with the figures 2 and 3, it will be noted that figures 2 and 3, are of the right foliate area, while the other three figures, 4, 5 and 6, are of the left area. The pitted under surface of the epithelium, mucosal papillae, indicates the region anterior to the foliate area. In the sections of all the stages figured in figure 1, the anterior border is to the left of the figure, so as to make a comparison of sections more easy.) This area present perhaps 16 primary folds, several divided folds may be seen, one of which divides ventrally. The general arrangement of the primary epithelial folds is clearly indicated in the figure. Especial attention is drawn to the serrated edge of the middle portions of the longer, centrally placed folds. The folds, in this region present on their crests short bud-like protrusions recognized as anlagen of the serous lingual glands. As is evident from the figure, these glands appear first in the more central region of the foliate area. Hermann has previously stated that the central region of a foliate area is most fully developed. To the right and ventral in this figure there may be observed the anlagen of several mucous glands, distinctly longer than the serous lingual glands, presenting bulbous ends, having an epithelium which enables their recognition as mucous glands. In several of the more centrally placed primary epithelial folds, as seen in the reconstruction, there may be observed about midway down the respective fold, a narrow shelf passing along each side of the respective fold. These represent the first indication



5



6

Fig. 5 Photograph of the mucosal surface of a wax plate reconstruction of the epithelium and ducts of the serous lingual gland of the foliate area of a rabbit embryo of 26 days. Magnification approximately 50 diameters.

Fig. 6 Photograph of the mucosal surface of a wax plate reconstruction of the epithelium and ducts of the serous lingual glands, with the primary and secondary epithelial folds of the foliate area of a rabbit embryo of 30 days. Magnification approximately 50 diameters

of the secondary epithelial folds and are much more clearly discerned in the drawing of one of the sections of the series from which this model was made, *E*, of figure 1. In this section, the epithelium bordering the anterior part of the foliate area is directed toward the left while in the model, this region, recognized by the epithelial pits, is directed towards the right. This series of sections is cut almost parallel to the long axis of the foliate area and present good cross-sections of the epithelium of the more central part of the field. It will be observed on comparison with the former sections, that the primary epithelial folds are deeper than in earlier stages and that they are thicker and broader in their basal portions, this thickening extending to about half the depth of the respective epithelial fold. The lower border of this thickening on each side of a primary epithelial fold marks the anlagen of the secondary epithelial folds, much more clearly seen in older stages. It may be observed that certain of the primary epithelial folds extend for a greater distance into the mucosa than to others. These longer 'folds' indicate regions in the preparation in which the plane of section included serous lingual gland anlagen. The two series of sections of the 25 day stage were both cut quite obliquely to the long axis of the respective foliate areas, and thus also the primary epithelial folds, giving these folds a broader contour than is warranted from a study and part graphic reconstruction of these series. A figure of this stage is not included. This stage shows only a very slight advance in development over that shown for the 24 day rabbit embryo. The stage of the 26 day rabbit is presented both in model and in section. The model reproduced in figure 5, is of the left foliate area of a 26 day rabbit embryo. There are present in all 15 well developed primary epithelial folds and two less fully developed ones. The secondary epithelial folds are more fully developed, extending deeper into the mucous, than in the 24 day stage, though these secondary epithelial folds are somewhat difficult to discern in the figure of the model in that they are hidden by reason of the compactness of the folds; on study of the model itself, they are clearly recognized and may be seen in the section of this

stage to be discussed presently. The serous lingual glands show marked increase in length, many having pierced the musculature of the tongue for quite a distance, having bulbous, but as yet unbranched ends. There is also observed a marked increase in the number of the glands, no less than 140 gland ducts are to be counted in the reconstruction of this area. The ducts of these glands arise from the crests of the primary epithelial folds. A number of large mucous glands are evident to the left and lower left in the figure, just outside of the folds limiting the foliate area. A typical section of the epithelium, taken approximately from the middle of the series from which the model was made is shown in drawing *F*, of figure 1. The thickened bases of the primary epithelial folds, with distinct indications of the secondary epithelial folds, are easily recognized in this figure. In this figure many of the primary epithelial folds extend as gland ducts into the mucosa, and certain ones beyond the limits of the drawing, which includes the mucosal layer to the upper level of the tongue musculature. It is requested to note the positions of the capillary loops in the crests of the primary mucosal folds as seen in figure 1, *F*, and compare the same with the positions of the capillary loops in the crests of the simpler mucosal folds as seen in figure 1, *D*. The relative position of these capillary loops remains constant and thus enable an interpretation of the morphogenesis of the epithelial and mucosal folds. In the rabbit embryo of 26 days the foliate areas are readily recognized with the unaided eye. Since, as may be observed from a study of the section as drawn in *F*, of figure 1, the surface grooves have acquired depth, giving the upper border of the section a distinctly scalloped appearance; it will also be observed that these surface grooves are situated over the middle of the primary epithelial folds from the crests of which bud the serous lingual glands. Drawings *G*, *H* and *I*, of figure 1, are from series of sections of the foliate areas of rabbit embryos of 27, 28 and 29 days, respectively. They are inserted mainly to give details of the development of the secondary epithelial and the secondary mucosal folds, developing—the epithelial folds—from the bases of the primary epithelial folds with which they run parallel. In each figure

the positions of the capillary loops is to be noted. It will be seen that the secondary epithelial folds are clearly indicated in *G*, of figure 1, they are longer and more distinct in *H*, of this figure and in section *I*, in figure 1, appear in cross-sections as distinct, slender papillae, diverging slightly from each side of the bases of the several primary epithelial folds; these slender papillae representing cross-sections of the secondary epithelial folds. The serous lingual glands have acquired length during these stages extending now deeply into the tongue musculature, showing bulbous or branched ends and evidence of the presence of a lumen in many of them. In figure 6, is shown a reconstruction of the left foliate area of a rabbit embryo of 30 days, removed from the uterus just prior to birth. It represents the oldest stage modelled and gives the mucosal view of the epithelium of a foliate area which in many respects is like that of a foliate area of an adult rabbit. This area presents 16 primary folds and toward the right of the figure several small folds which have the same general directions as do the foliate folds, but without presenting their morphology in that they are not accompanied by secondary folds and have not given origin to serous lingual glands. This area has spread out to such extent, in course of development, that the secondary epithelial folds are clearly seen, as running parallel to each side of the respective primary epithelial folds. The positions of the primary and secondary mucosal folds can easily be depicted in that they fill the clefts bounded by the epithelial folds. Approximately 200 ducts of serous lingual glands are counted in this reconstruction, probably about the number present in a foliate area of the adult rabbit. The backward turn of the ducts of the serous lingual glands of the most posterior portion of the foliate area, to the left in figure 6, is to be noted. At this stage the ducts lead to the surface of the epithelium and do not empty at the bottom of the deep clefts as found in the grown and fully developed area. It seems reasonable to conclude although we have not at our disposal the necessary stages to substantiate this conclusion, that the deep clefts separating the surface folds of the fully developed foliate area, are in part formed through a desquamation of the

epithelium separating the duct lumina as they pass through the epithelium to the surface. In section J, of figure 1 is given a drawing of the epithelial border and underlying mucosa of approximately the middle section of the series from which the model in figure 6 was made. This section is in direction nearly parallel to the long axis of the foliate area sectioned and cuts the major folds at right angle, presenting also a good cross-section of the epithelium. This figure is in a large measure self explanatory, primary and secondary epithelial and mucosal folds are clearly discernible as are also the ducts of the serous lingual glands. It should be noted that in the fully developed foliate area, the capillary loops found in the crests of the primary mucosal folds, separating the primary epithelial folds, *D* and *E*, of figure 1 fall to the center of the surface folds as found in the fully developed area foliata, the clefts separating these surface folds falling in line with the rows of ducts of the serous lingual glands as seen in figure 6, each such surface fold embracing the tissue found between two rows of ducts of the lingual serous glands.

The question of the histogenesis of the gustatory buds has not formed a special portion of this investigation. The methods of fixation and staining used, have enabled us to confirm in a large measure the early observations of Hermann<sup>3</sup> as concerns the development of the gustatory buds of the rabbit's foliate area. Relatively few gustatory buds are present in the foliate areas of the rabbit at the time of birth. These few are nearly all found scattered here and there near the mouths of the ducts of the serous lingual glands. A study of the histogenesis of the gustatory buds of the foliate areas of the rabbit is projected in a future investigation, with the aid of special technical methods, of which the pyridine silver impregnation method shall receive special consideration. It seemed to us advisable to first acquire familiarity with the morphogenesis of the foliate area, before a study of the histogenesis of the gustatory buds was undertaken. The severance of official connection with the Department of Anatomy of one of us has prompted us to place on record the results of this investigation as thus far attained, namely, the

morphogenesis of the foliate areas of the rabbit from time of its first appearance to the time of birth. Our observations may be summarized briefly as follows:

1. The foliate areas of the rabbit's tongue may be recognized as slightly elevated, oval pre-foliate areas in rabbit embryos of the 18th day.

2. The primary epithelial folds characterizing these areas, begin to appear on the 19th day, and are well formed and present in approximately full number on the 21st day. These primary epithelial folds are to be recognized as 'histo-systems,' since they are found in fairly constant number throughout the period of morphogenesis of these areas; practically the entire foliate area on each side being in anlage at the same time.

3. The serous lingual glands, associated with the foliate areas, make their appearance, in the central region of the foliate area, during the 24th day. The secondary epithelial are in anlage during the 24th day, in the central region of foliate area, and show appreciable development over the entire area by the 26th day.

4. The epithelial and mucosal folds, both primary and secondary, as viewed from the under side of a foliate area of the 30th day, show an arrangement and state of development which is essentially the same as in a fully developed foliate area, although the deep clefts or grooves which separate the surface folds of the adult area are as yet merely indicated. At this period of development the gustatory buds are as yet few in number and are found in close relation to the mouths of the ducts of the serous lingual glands, which reach the surface of the epithelium.





## THE DURATION OF THE VARIOUS PHASES OF MITOSIS IN THE MESENCHYME CELLS OF TISSUE CULTURES

WARREN H. LEWIS AND MARGARET R. LEWIS

*Johns Hopkins Medical School*

Concerning the time element involved in the mitotic division of the somatic cells there is at present scarcely any data.

Retzius<sup>1</sup> found that the total time involved for mitosis in the ectodermal cells of triton punctatus was from 2 to 3 hours, sometimes more, sometimes less. He has nothing to say regarding the duration of the various phases nor whether he considered the process as ending with the division of the cell.

Clark's<sup>2</sup> observations on the division of mesenchyme cells in the tail of the living tadpole were carried on in connection with his studies on the living growing lymphatics. Unfortunately there is a fairly complete record for only one cell. The prophase and metaphase together lasted about 1 hour and 45 minutes; the duration of metaphase was not given. During anaphase which lasted about 4 minutes the movement of the chromosomes could be seen. Telophase followed immediately and constriction except for a slender strand was complete in 3 to 4 minutes; 2 hours elapsed however before separation was complete. Not until about 3 hours after the division of the cell (except for the slender strand) did it appear to be in a normal resting condition. It is interesting to note that during a period of 23 days when the tail was under observation only about one-half of the cells underwent division and none of them divided more than once.

<sup>1</sup> Retzius, G. 1881. Studien über die Zellentheilung. Biol. Untersuchungen.

<sup>2</sup> Clark, E. R. 1912. Further observations on living growing lymphatics; their relation to the mesenchyme cells. Am. Jour. Anat., vol. 13.

Lambert and Hanes<sup>3</sup> found in plasma cultures that the connective tissue cells of the cat divide in 15 to 30 minutes at 37°C., while those of the rat require from 25 to 45 minutes. They found in the cat that the time involved between the separation of the daughter chromosomes and the complete division of the cytoplasm was from 4.5 to 6.5 minutes. This corresponds very closely with the duration of telophase in the chick embryo cultures given below. It is difficult to compare with our results the duration of prophase, metaphase and anaphase since they are not given separately by these observers, and since it is not stated in precise terms whether the observations on prophase were begun with the resolving of the nuclear membrane or after the stage was already under way. It is very difficult to find cells that are just entering upon the prophase stage and our experience has been that one recognizes the prophase after it is well under way and very rarely does one have under observation a resting cell and watch its initial changes into the prophase stage. There is no indication in the paper by Lambert and Hanes that they were particular about this point, so that in all probability their observations were begun on cells already in the prophase stage. If so, it will be necessary to add from 15 to 30 minutes to their estimate of the duration of prophase, metaphase, and anaphase.

We infer from their paper that they consider mitosis to end with the division of the cytoplasm into the two daughter cells. So that if we include under mitosis the long period of reconstruction, after the cell has divided, during which various changes take place in the cell until it arrives at the resting stage, it would probably be necessary to add 1 or 2 hours to the observed duration of mitosis as given by Lambert and Hanes. This would give from 2 to 3 hours for the total duration of cell division, which corresponds fairly well with our results.

Lambert<sup>4</sup> in another paper takes up the rate of cell division in rat connective tissue cells. He finds in plasma cultures from

<sup>3</sup> Lambert, R. A. and Hanes, F. M. 1913. Beobachtungen an Gewebekulturen in vitro. *Vireh. Arch.*, Bd., 211.

<sup>4</sup> Lambert, R. A. 1913. Comparative studies upon cancer and normal cells. II. The character of growth in vitro with special reference to cell divisions. *Jour. Exp. Med.*, vol. 17.

10 to 40 days old that the time required for mitosis at 38° and 39°C. varied from 21 to 29 minutes, while at 34° to 36°C. the time varied from 35 to 50 minutes. In the cells dividing at 38° to 39° the intervals from the first appearance of constriction until complete division of the cytoplasm were as follows; 3, 5, 5, 3, and 3 minutes. It appears from his table that a period of 2 to 3 minutes intervenes between the separation of the daughter chromosomes and the beginning of cytoplasmic constriction. The duration of prophase, metaphase and anaphase taken together varied as follows; 22, 15, 18, 23 and 16 minutes. Here again we are unable to determine just what Lambert considers as the beginning of mitosis. He does not state in precise terms that his observations began at the beginning of prophase, so that we have the same difficulty here in making comparisons with our observations on chick cultures as we had with the observations of Lambert and Hanes.

While the observations recorded below were proceeding, there appeared an article by Levi<sup>5</sup> on almost the identical line of work. Levi's observations were on embryonic chick tissues cultivated for the most part in normal plasma and we are thus enabled to compare the behavior of cells in plasma and in Locke's solution while undergoing such a highly complicated process as mitosis. Since so many adverse criticisms have been made against the use of Locke's solution as a culture medium, it is of especial interest to note that our observations are on the whole very similar to those of Levi both in regard to the general behavior of the cells during mitosis and in regard to the time element involved for the various phases.

In order to record accurately the time involved during the various phases of mitotic division, it was necessary to have clearly in mind a sharp line of distinction between each phase following as nearly as possible the customary usages of the terms prophase, metaphase, anaphase and telophase.

The observations recorded below are on mesenchyme cells from embryo chicks 4 to 11 days old and cultivated in Locke's

<sup>5</sup> Levi, G. 1916. Il ritmo e le modalità della mitosi nelle cellule viventi coltivate 'in vitro.' Arch. Ital. di Anat. e di Embr., vol. 15.

solution with or without the addition of bouillon. The cultures were kept at about 39°C. with slight variation to 38° or 40°C. The cultures varied in age from 24 to 72 hours.

The prophase is usually defined as the preliminary stage in mitosis including all the phenomena prior to the division of the chromosomes. Since it is not possible to see exactly when the chromosomes divide, the term as used in this article involves the processes from the time of the first changes in the cell until the chromosomes are arranged in the equatorial plate. The latter condition is easily recognized.

The interval between the first observation of the cell in prophase and the end of prophase varied from 5 to 50 minutes, and is as follows for the various cells observed: 5+, 8+, 8+, 10+, 10+, 12+, 15+, 17+, 30+, 38+, and 50+ minutes. This indicates that prophase usually occupies from 30 to 60 minutes.

Levi gives the time involved for prophase and metaphase together as from 12 to 30 minutes but he does not specify the extent to which the prophase had advanced when the observations were begun. Levi had only three observations on the duration of metaphase, namely 8, 11 and 13 minutes; and six on prophase and metaphase together, namely 28, 12, 20, 22, 25 and 30 minutes. The duration of prophase in Levi's plasma cultures was probably between 5 and 20 minutes, to which must be added a considerable period of time on the assumption that his observations were begun after the prophase was under way. With these corrections, the duration of the prophase in plasma is similar to that in Locke's solution.

The metaphase is usually defined as embracing the period of the splitting of the chromosomes. We have considered the metaphase as extending from the time the chromosomes are first arranged in the equatorial plate until they begin to move toward the poles. During the first part of this period, the equatorial plate is thick and it is impossible to distinguish the separate chromosomes, while during the latter part of the period the plate splits into two parallel plates with only a very fine line between them. These two plates do not usually begin to move apart for a minute or more after the splitting. Metaphase

varies from 1 to 15 minutes, occasionally it may last longer, in one case 25 and in another 45 minutes. The intervals involved for this stage are as follows: 1+, 1.25+, 2+, 2.5+, 2.5, 3+, 3+, 3, 3, 4, 6+, 7, 9, 11.25, 12, 12.5, 15, 25 and 45 minutes. The metaphase is shorter on the average than it was in Levi's three observations for plasma cultures.

The anaphase involves the moving apart of the divided chromosomes to the poles of the spindle and their later union into spindres to build up the daughter nuclei. As used in this article the anaphase includes only the time during the migration of the chromosomes to the poles and varies from 1 to 5 minutes. The periods are as follows: 1, 2, 2, 2, 2, 2, 2, 2, 2, 2, 2, 2, 2.5, 2.5, 2.5, 2.5, 2.5, 3, 3, 3, 3, 3, 3, 3, and 5 minutes. The time averages from 2 to 3 minutes. Levi's observations on plasma cultures show a variation from 1.5 to 19 minutes, most of them lasting from 3 to 7 minutes.

Telophase is usually considered the final stage in mitosis: the cytoplasm divides forming the two daughter cells and the nuclear membrane reforms. As here used, it extends from the end of anaphase to the separation of the cell into two daughter cells (except, as often happens, for a thin strand of cytoplasm which may connect the two daughter cells for many minutes after the division is practically complete). An appreciable interval elapses between the end of anaphase and the first appearance of the indentation, during which the cell elongates and flattens out on the sides. This period may vary from 1.5 to 7.5 minutes but usually lasts only 1 or 2 minutes. The observed intervals are as follows: 0.5, 0.75, 1, 1, 1, 1, 1, 1, 1, 1, 1+, 1.5, 1.5, 2; 2, 2, 3, 3, 4, 5 and 7.5 minutes. This period we sometimes designate as telophase (a).

The time involved from the first appearance of indentation, usually on one side first, until complete division (except for a thin narrow stalk) varies from 2 to 10 minutes: with an average 2 to 4 minutes. The individual observations are as follows: 2, 2, 2, 2, 2.5, 2.5, 2.5, 3, 3, 3, 3, 3, 3.5, 3.5, 3.5, 4, 4, 4, 4, 4, 4, 4, 5.5, 6, 9 and 10 minutes. This period may be designated as telophase (b).

The duration of the entire telophase stage, that is, from the end of anaphase to the division of the cell, varies from 2 to 13 minutes. The observed durations are as follows: 2, 2.5, 2.5, 3, 3, 3, 3, 3, 3, 3, 3, 3, 3.5, 4, 4, 4, 4, 4.75, 5, 5, 5, 5, 5, 5, 5, 5, 5, 5, 6, 6.5, 7, 7, 7, 9, 11.5, and 13 minutes; average 3 to 6 minutes. Levi's observations show a duration of from 1 to 10 minutes and are as follows: 1, 1.5, 1.5, 2, 2, 2.5, 2.5, 2.5, 2.5, 3, 3, 3, 3, 3, 3, 3, 3, 3, 3, 4, 4.5, 5, 5, 5, 6, 6, 6, 6, 6, 6, 6, 6, 6, 9, 10 and 10 minutes. The time is about the same, therefore, in Levi's plasma cultures as in the Locke's solution.

Although mitosis is usually supposed to end with the division of the cell into two daughter cells there remains a considerable interval of time during which the daughter nuclei pass through various stages before they arrive at the normal resting condition. For convenience, we have called this the reconstruction period. It is difficult to determine just when the cell arrives at what might be called a normal resting condition. The chromosomes are first gathered together in a small mass, around which a clear substance gradually collects and as the chromosomes fade away from sight, the nuclear wall and the nucleoli become visible. This nucleus is much smaller than that of the resting stage and in fixed specimens stains deeper with iron hematoxylin than does the larger resting nucleus. The intervals involved from the end of division until the first appearance of the nuclear membrane are as follows: 8, 8, 8, 10, 10, 10, 12, 12, 13, 17, 18, 20, 20, 21 and 23 minutes. The nuclear membrane usually appears about the same time in the two daughter cells.

The period from the first appearance of the nuclear membrane until the resting stage is difficult to determine exactly. Our observations indicate that it is as long if not longer than the prophase; i.e., 10+, 10+, 15+, 30, 35+, 40, 40, 55, 60+, 80, 85, 110 and 110 minutes. During this period there is a gradual increase in the size of the nucleus and of the cytoplasm.

The records of a few of the mesenchyme cells from cultures of a 7 day embryo are shown in table 1.

Other observations on 4, 5, 6, 9, 10 and 11 day embryos do not indicate any marked differences in the rate of mitosis nor is

TABLE 1  
*Rate of mitosis of mesenchyme cells of a 7 day chick embryo*

AGE CULTURE	24	48	48	72	48	48	48	48	48	48	48
Prophase.....						8+		8+			
Metaphase.....	4	7	12.5	3+		3	2.5+	2.5	6+		12
Anaphase.....	3	2	2.5	2		3	3	2.5	2.5	2.5	3
Telophase (a).....	1.5	1	1	1	3.5	1.5	1		1	1	2
Telophase (b).....	3.5	4	2	3	3.5	3.5	2.5	9	4	5.5	4
Reconstruction (a).....	18+	23			10	13			8		
Reconstruction (b).....		55 85			110	10+					
Total.....	30+	92+			127+	42+					
		122+									

there any noticeable increase or decrease in the rate in the cultures that are 24, 48 and 72 hours old.

The time required then for the complete process of mitotic cell division would lie within the following limits: Prophase, 30 to 60 minutes; metaphase, 2 to 10 minutes; anaphase 2 to 3 minutes; telophase 3 to 12 minutes and the reconstruction period from 30 to 120 minutes: total 70 to 180 minutes. From the present data 2 to 3 hours would be a fair estimate of the time involved.

An attempt was made to compare mitosis in tissue cultures with that found under more normal conditions and for this purpose a four day chick with the amnion intact was put into a small dish of Locke's solution and the rate of division observed

TABLE 2  
*Rate of mitosis of the smooth muscle cells in the amnion of a 4 day chick embryo*

	1	2	3	4	5	6	7	8
Prophase.....	5+						33	
Metaphase.....	15		14	6	6	3.5	2	20+
Anaphase.....	3	2.5	2	2.5	1	2	3	
Telophase (a).....	1	1	1	1	2.5	1	1.5	0.5
Telophase (b).....	4	2.5	2	2	3	4	2	2.5
Reconstruction (a).....	4	5 6						9 10

in the smooth muscle cells of the amnion. The results are given in table 2. The process is more difficult to follow under these conditions than in cultures. The prophase was observed over most of its duration in the seventh case and was 33 minutes. The metaphase lasted from 2 to 15 minutes, the anaphase 1 to 3 minutes, the telophase 3 to 5 minutes and the first part of the reconstruction period from 4 to 10 minutes.

If we compare the data at hand on the various phases of mitosis as collected together in table 3, it seems very probable that the duration of mitosis is not so very different in the various types of

TABLE 3

	PROPHASE	META-PHASE	ANAPHASE	TELO-PHASE	RECON-STRUCTION
Mesenchyme tadpole tail, Clark.. . . .	< 75+ >		4	3-4	180
Connective tissue cat, Lambert and Hanes.....	< 25-45+ >			4.5-6.5	
Connective tissue rat, Lambert.....	< 13-23+ >			3-5	
Mesenchyme chick, plasma, Levi.....	5-20+	8-13	3-7a 1.5-19	2½-6a 1-10	
Mesenchyme chick, Locke.....	30-60	2-12a 1-45	2-3a 1-45	3-6a 2-13	30-120
Smooth muscle chick.....	5-30+	2-15	1-3	3-5.5	10+

Duration in minutes of the various phases of mitosis.

+ indicates that more time should probably be added.

a. Average.

cells, if we make the necessary allowances for the fact that the observations were usually begun after prophase was under way. Not until we have more accurate data however can this be decided with any degree of satisfaction. Concerning the duration of prophase the data is too meager for comparison. Metaphase is on the average somewhat longer in Levi's plasma cultures than in our Locke cultures or in the smooth muscle of the amnion. The variations are greater in our observations than in Levi's. More extended observations in plasma however might show as great variation as in Locke's solution. Anaphase also is slightly



longer on the average in the plasma than in Locke's solution and the variations are more marked and greater in the latter solution. The extremes in anaphase as in metaphase must be in the reaction of the individual cells since these great variations occur in cells side by side in the same culture. The duration of telophase which can be more accurately recorded than the other phases shows a striking similarity in all types of cells and less variation. It is rather remarkable that the telophase of the mesenchyme cells in the tadpoles tail, connective tissue cells of the cat and rat in plasma, mesenchyme of the chick in plasma and Locke's, and smooth muscle should all have about the same length of time. Variations in the duration of any one phase is one of the most characteristic features of cell division and is apparently dependent on individual cell differences.



## THE COELIAC AXIS

PAUL B. EATON

*From the Anatomical Laboratory, Johns Hopkins Medical School*

### ONE FIGURE

The classical description of the coeliac axis states that at the level of the upper border of the pancreas it divides into three branches, the left gastric, the hepatic, and the splenic arteries. A number of studies of this vessel have been published within the last few years, notably those of Rossi and Cova (1), Leriche and Villemin (2), Descamps (3), Picquand (4), de Rio Branco (5), Robinson (6), and Lipshutz (7). Of these Leriche and Villemin alone report that they found the classical "tripus" in a majority (unspecified) of cases. At the suggestion of Prof. W. H. Lewis this study was undertaken to determine as definitely as possible the normal type and to get some data on the frequency of departure from this norm.

The sketches which form the basis of this report were made by myself from dissections made for the most part by freshman medical students (to whom I am indebted for many courtesies) and the amount of material studied and its distribution are shown in the following table.

<i>Dissecting Room<sup>1</sup></i>	<i>Number of subjects</i>
Johns Hopkins University Medical School.....	47
University of Maryland Medical School.....	34
George Washington University Medical School.....	12
University of Pennsylvania Medical School.....	44
Jefferson Medical College.....	40
Woman's Medical College of Philadelphia.....	3
Temple University Medical School.....	12
Philadelphia Polyclinic.....	1
Medico-Chirurgical College of Philadelphia.....	8
Georgetown University Medical School.....	5
Total.....	<u>206</u>

<sup>1</sup> I wish here to make acknowledgment and express my thanks to those whose courtesy has made this work possible and very pleasant. In particular to Pro-

The sex and skin tint of 200 of these subjects was recorded. They were distributed as follows.

	MALE	FEMALE	TOTAL
White	53	26	79
Colored.	85	36	121
	138	62	200

The number of cases is not sufficiently large to warrant any positive statement but there does not appear to be any great sexual variation in the variability of the structures under consideration. The same may be said with respect to race. A number of observers have reported that negro subjects seem to show a greater tendency to variation than white ones but our use of the term negro is too loose to be of any value from an anthropologic standpoint. Dr. Hrdlicka (Division of Anthropology, Smithsonian Institution) informs me that

There is ground for believing that the negro of pure blood should show a greater stability, anatomically, than the white man, who is generally a pretty thorough mixture and who has been subjected to more varied environmental, occupational, and other influences; but our knowledge of the details of heredity is not sufficient to enable us to predict the effect of hybridization upon this stability.

If our dissecting rooms contain the proportion of hybrids that has been alleged of our large cities (fifty to seventy per cent) a certain degree of anthropological skill will be necessary to make the separations necessary to settle this question.

fessors F. P. Mall, and W. H. Lewis, of Johns Hopkins University, and their assistants; Professors J. Holmes Smith and Joseph W. Holland of the University of Maryland; Professor Carl E. Davis of George Washington University; Professors George A. Piersol and George Fetteroff and Drs. G. M. Dorrance and P. G. Skillern of the University of Pennsylvania; Professors J. P. Shaeffer and D. G. Metheny, and Drs. Hoffman and Lipshutz of Jefferson Medical College; Professors Henry Morris and Mary Bicking Thornton of the Woman's Medical College of Philadelphia; Professor Addinell Hewson of Temple University and Philadelphia Polyclinic; Professors John G. Heisler and H. H. Cushing of Medico-Chirurgical College; and Professors Frank L. Baker and W. F. Hemler of Georgetown University.

## GENERAL CONSIDERATIONS

The history of the discovery and naming of the Coeliac Axis is gone into very thoroughly by de Rio Branco (5), the embryology by Tandler (8) and the comparative anatomy by Rossi and Cova (1). These monographs are accessible and make further reference unnecessary.

## CLASSIFICATION

Table 1 gives the simplest classification possible. The first part is taken bodily from Branco and the remainder added to show that extending the scope of the inquiry to the point of

TABLE I

AUTHOR	NUMBER OF SUBJECTS EXAMINED	COELIAC AXIS COMPLETE (FROM AORTA)	COELIAC AXIS INCOMPLETE (FROM AORTA)	COELO-MESENTERIC TRUNK	COELIAC AXIS ABSENT SEPARATE ORIGIN OF ITS BRANCHES
Rossi and Cova.....	102	86	12	2	2
Leriche and Villemin.....	55	49	5	1	0
Descomps.....	50	44	6	0	0
de Rio Branco.....	50	45	4	1	0
Totals.....	257	224 (87%)	27 (10.5-11%)	4 (1.5-2%)	2 (0.8%)
Piequand.....	50	41	7	1	1
Lipshutz.....	83	60	21	2	0
Eaton.....	206	186	19	1	0
Totals.....	596	511 (86%)	74 (12.5%)	8 (1.0%)	3 (0.5%)

doubling the number of subjects examined makes no great change in the percentages. The inferior phrenic arteries have been disregarded and will be treated separately.

The sketch on page 372 is an attempt at a logical or geometrical classification. As is to be expected this breaks down if examined too critically. It may be extended on either side to show the separate origin of the three branches of the axis from the aorta or the absence of the splenic artery, which is much more stable than either of the others. Most of the spaces might be filled from the literature, but extension would make the dia-

gram unwieldy and it is submitted merely to cover the variations found in my series and as a suggestion for the study of other vessels. While the diagram is almost self-explanatory it may be well to call attention to the fact that starting from Type II, 2a for example (the classical tripus), movement to the right shows a displacement of the origin of the left gastric artery toward the

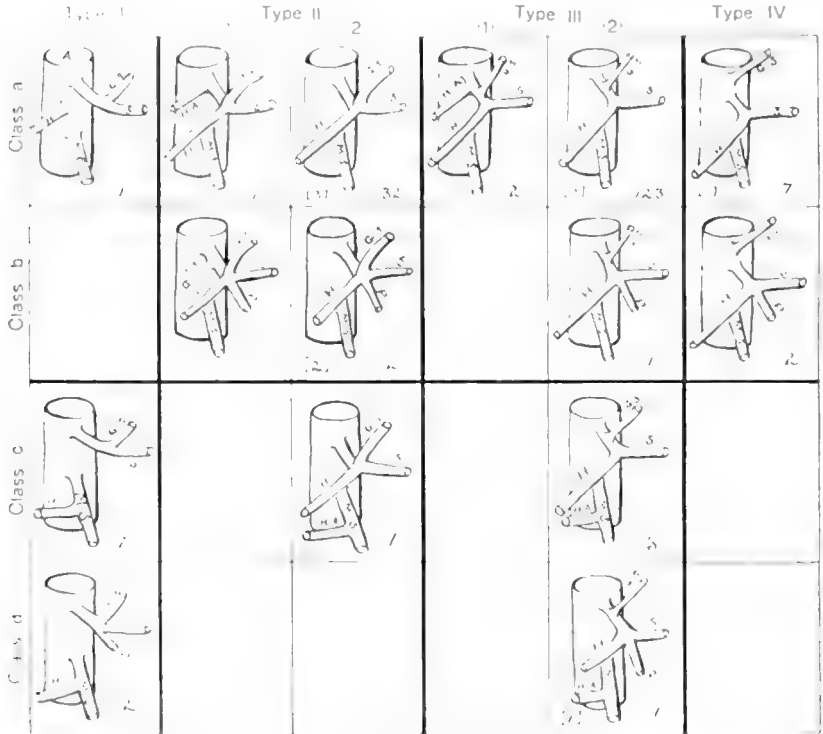


Fig. 1. A, Aorta; G.S., Left gastric artery; H., Hepatic artery; H.A., Accessory hepatic artery; S., Splenic artery; P., Pancreatic artery.

aorta and finally as in Type IV entirely off the axis. Movement to the left from the same point shows the same thing with respect to the hepatic artery. From the same point moving down one column shows the addition of a pancreatic branch. In the third horizontal column the first is repeated with the addition of a hepatic artery from the superior mesenteric artery. The

figures in the lower right hand corner of each section of the diagram indicate the number of times that particular arrangement was found in this series of cases. Those figures in parentheses in the lower left hand corners indicate the number of cases in which the left gastric artery furnished an accessory hepatic artery. If any argument were needed as to the necessity for the investigation of a larger number of cases it could easily be found in the fact that in this series that particular arrangement occurred 14 times or a fraction less than 7 per cent while Lipshutz (7) found it in 35 per cent of 83 cases. So far I have been unable to find any other way to get it into the diagram.

TABLE 2

AUTHOR	NUMBER OF SUB- JECTS	TYPE I	TYPE II	TYPE III	TYPE IV	UNCLASSI- FIABLE
Leriche and Villemin	102	2	(50)		3	
Rossi and Cova.....	55	8	26	60	6	2
Picquand.....	50	3	5	37	4	1
Descomps.....	50	0	16	28	5	1
de Rio Branco.....	50	3	15	30	1	1
Lipshutz.....	83	3	21	41	12	6
Eaton.....	206	10-4.9%	47-22.8%	140-68%	9-4.4%	0
Totals.....	596	29-4.9%	130-24%	336-62.1%	40-6.7%	

It will be noticed that there is a distinct grouping in one section of the diagram. This is as it should be, for, as urged by Ruge (9) and Lipshutz, arterial variations group themselves into distinct types in numbers inversely proportionate to the amount of their departure from the normal.

It is of course impossible to compare these results closely with those of previous investigators. Table 2 is however an attempt at such a comparison and I believe that such errors as may have crept in will not greatly affect the percentages. The columns for Types II and III are incomplete for the reason that Leriche and Villemin merely state that the three branches came off at the same level in the majority of cases. Their cases are therefore not counted in calculating the percentages for those columns.

## SUMMARY

1. The normal type of coeliac axis is that which gives off the left gastric artery as a collateral branch before the bifurcation into the hepatic and splenic arteries. (62.1 per cent of 541 cases.)

2. The classical 'tripus' occurs somewhat less than half as frequently. (24 per cent of 541 cases.)

## LITERATURE CITED

- (1) ROSSI ED COVA. Archivio italiano di Anat. e di Embriol. Florence, t. III-fas. 2, pp. 485-526.
- (2) LEUCHE ET VILLEMEN. 1907. Bibliogr. Anatom. Paris, t. 16, fas. 2, pp. 111-125.
- (3) DESCOMPS, P. 1910. Le Tronc Coeliaque, Paris.
- (4) PICQUAND, G. Bibliogr. Anatom. T. 19, fas. 4, pp. 159-201.
- (5) DA SILVA RIO BRANCO. 1912. Le Tronc Coeliaque, Paris.
- (6) ROBINSON, B. 1908. American Practitioner and News.
- (7) LIPSHUTZ, B. 1917. Annals of Surgery, February.
- (8) TANDLER, J. 1901. Anatom. Hefte. Wiesbaden, vol. 25, pp. 473-500.
- (9) RUGE, G. 1883. Morph. Jahrbuch, vol. 9.



# DESARROLLO DE LOS MÚSCULOS OCULARES RECTO EXTERNO Y RECTO INTERNO, EN EL EMBRIÓN HUMANO

F. POYALES

*De la Clínica Oftálmica del Prof. Marquez; Madrid, España*

DIEZ FIGURAS

La posición estrábica convergente que presentan los ojos de los recién nacidos es un hecho cuya interpretación no está definitivamente fijada y para la cual se han invocado no pocas teorías cuyas tesis se pueden reducir á dos grupos: falta de evolución cerebral ó desordenes en la misma por taras hereditarias ó lesiones inflamatorias (Perinaud); hipermetropía constante del ojo del niño acompañada de redución en la amplitud del campo pupilar y de la convergencia.

Ni una ni otra explican satisfactoriamente el indicado hecho ya que la primera, muy compleja, no da cuenta de porqué las propias causas degenerativas ó inflamatorias que ocasionan el estrabismo convergente no producen el divergente; y la segunda no puntualiza, como, persistiendo la hipermetropía, no persiste también el estrabismo que en algunos casos queda reducido á la primera semana.

La teoría que á mi ver explica el expresado hecho, de modo más ajustado á los procesos biológicos y con arreglo á la cual realicé mi modesta labor de investigación, me fué sugerida por la consideración del proceso evolutivo histogenético del *Anfioxus*. Creo indicada una breve recapitulación del desarrollo de dicho animal, sobre todo en lo que afecta á la formación de los músculos oculares, para que el lector pueda seguir el hilo que ha guiado mi trabajo ya que solo por conjeturas filogenéticas, deducidas de estudios practicados en vertebrados inferiores, es como nos es

dado inducir algunos hechos primitivos de la embriología humana, tan compleja en sus primeras etapas.

Digamos previamente que el sistema óculo-motor, constituido por la serie de músculos rectos y oblicuos todos de fibra estriada, tiene su origen en el mesodermo. Cuando el embrión de *Anfioxus* ha llegado al estado de gástrula se ve nacer del entodermo á los dos lados de la línea media una serie de divertículos gruesos, producidos por evaginaciones de esta hoja; estos divertículos representan la mayor parte de la metamerización del mesodermo. Los metámeros que nos interesan son los correspondientes á la cabeza y región branquial.

No hay acuerdo respecto á la finalidad y número de los segmentos primordiales que constituyen la cabeza de los embriones. Van Wijhe acepta nueve; Rabl los reduce á cinco negando la existencia de los cuatro primeros designados por Van Wijhe; Dohrn admite diez segmentos y en este modo de pensar coinciden Killian y otros embriólogos. Nosotros consideramos la segmentación admitida por Van Wijhe y la significación dada á cada segmento como la que mejor explica el complicado desarrollo de la cabeza de los vertebrados.

El primer segmento de Van Wijhe, está situado por delante de la invaginación bucal y el segundo detrás; los otros continúan en serie correlativa, por lo cual el primero corresponde á la cavidad premandibular. El primer segmento está constituido por un gran miotoma que ocupa toda su región dorsal, careciendo de parte ventral; es el miotoma origen de los músculos del ojo, rectos interno y superior y oblicuo menor, inervados por el tercer par craneal; la parte ventral no existe. La misión del miotoma dorsal al que es debida la mayor parte del sistema óculo-motor absorbe la función del primer segmento y á pesar de su independencia por su parte inferior se comunica por un tubo epitelial con los demás segmentos, tubo que queda comprendido entre las bolsas branquiales consecutivas y va á abrirse á la parte anterior de la cavidad parietal.

El segundo segmento constituido tanto por una parte dorsal como por otra ventral es el único donde parece marcarse un equilibrio entre los dos elementos que lo constituyen: á la parte dorsal

corresponde un miotoma del cual procede el músculo oblicuo mayor y á la parte ventral se deben el arco mandibular y los músculos que de él se derivan.

En el tercer segmento cuya constitución varia por completo de la del primero y la del segundo, existe un marcado desarrollo de la parte ventral, quedando la región dorsal reducida á un pequeño miotoma casi atrofiado; es el segmento más pequeño de todos, pues su parte ventral se fusiona con la parte ventral del cuarto segmento y ayuda á constituir la cavidad del arco hioideo; á su miotoma dorsal corresponde la formación del músculo recto externo. La breve descripción que antecede relativa al desarrollo de estos tres segmentos y á los elementos que de ellos nacen, nos hace pensar que estos han de correr la suerte de sus substancias progenitoras y de ello se deduce que existe una diferencia de origen entre el músculo recto interno y el músculo recto externo, en atención á que el gran miotoma dorsal del primer segmento da origen al interno y el casi atrofiado miotoma dorsal del tercero origina el externo. Por otra parte, estas diferencias de origen dan lugar á diferencias estructurales en la misma época embriológica, hechos anatómicos que hemos de utilizar para hacer ver, que el recto externo es inferior al recto interno en edad, número y longitud de sus fibras, determinando, por la mayor potencia del recto interno, el estrabismo congénito convergente que tienen los niños al nacer.

Las diferencias embriogénicas indicadas ratificéalas Wiedersheim al hacer estudios comparativos entre la disposición de los nervios craneales y raquídeos fundando su distribución de los metámeros de la cabeza, en las ideas de Van Wijhe. Así los nervios correspondientes á cada segmento los divide en raíces ventrales y dorsales; el nervio motor ocular común y la rama oftálmica profunda del trigémino corresponderían al primer metámero; el patético y el trigémino, menos la rama oftálmica profunda al metámero segundo. Al estudiar la distribución de los nervios en el tercer segmento, duda de la existencia de la parte dorsal, no negando, sin embargo, que el diminuto miotoma atrofiado colocado en la parte superior pueda ser origen del recto

externo y considera al nervio motor ocular externo distribuyéndose por este segmento.

La opinión de Wiedersheim viene á comprobar la imposibilidad de negar la misión del tercer segmento y establece una diferencia de origen entre ambos músculos.

Fundándonos en el desarrollo que da á la metamerización mesodérmica Van Wijhe, vemos que la parte dorsal del resto de los segmentos, cuya atrofia se inicia en el tercero, sigue en todos: en el cuarto y quinto no hay parte dorsal; en el sexto, queda algo sin finalidad determinada; en el séptimo, octavo y noveno sigue el desarrollo de la parte ventral y las porciones ventrales de estos segmentos producen las cavidades y músculos de los arcos viscerales llegando á unirse al primer segmento del tronco.

Froriep ha venido á modificar la teoría de Van Wijhe con sus interesantes estudios de la cabeza del embrión del torpedo. De ellos deduce la existencia de varios segmentos, que comprenden el lado craneal y la primera hendidura branquial, segmentos á los que no asigna misión determinada dándoles una duración muy efímera; mas tarde aquellos serían sustituidos por el mesoblasto insegmentado de la cabeza, situado por tanto, delante de la bolsa branquial primera. Al principio, este mesoblasto es insegmentado, más poco á poco aparece la formación de las bolsas branquiales y se determinan las cavidades de los arcos. Es especialmente á esta segmentación á la que corresponden los metámeros de Van Wijhe. Conviene no olvidar que en el mesoblasto cefálico se ha de considerar también una parte dorsal homóloga á la parte dorsal de los segmentos de Van Wijhe, donde tienen su origen los músculos del ojo. La teoría de Froriep aunque más moderna, es á mi juicio, más incompleta y solo una modificación de la anterior que con razón persiste como clásica.

Establecidas las diferencias de origen embriogénico entre los músculos recto interno y recto externo, describiré las estructurales que he observado desde el cuarto mes de la vida fetal hasta el nacimiento. Como ya he dicho, el hecho á cuya comprobación dediqué este estudio me fué sugerido al leer las diferencias de origen embriológico anteriormente expuestas y advertir la frecuencia, en casi la totalidad de los niños recién nacidos, de la

posición estrábica convergente de los globos oculares. Desde el primer momento pensé que durante la vida intra-uterina, el desarrollo del recto interno y del recto externo habría de ser diverso, de tal forma, que el mayor desarrollo del interno determinante de la posición forzada, mantenida durante todo el periodo de la gestación, sería al nacer los niños la causa del estrabismo.

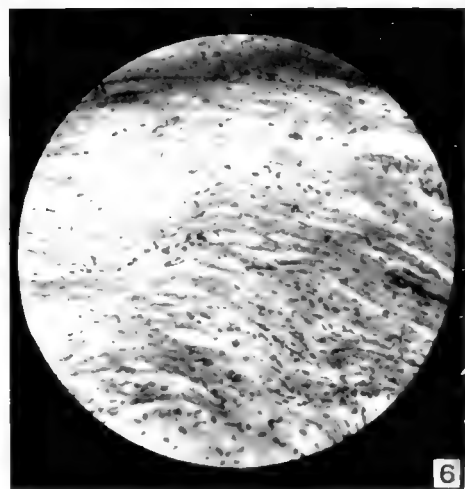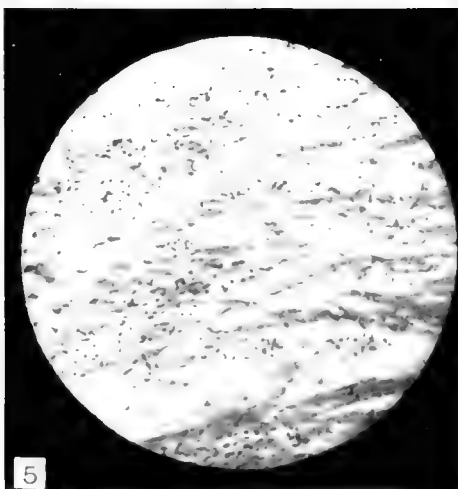
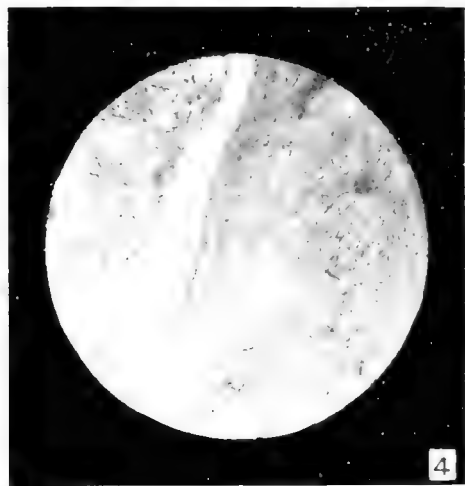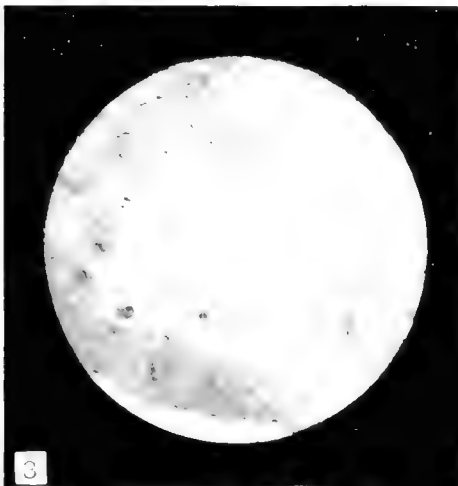
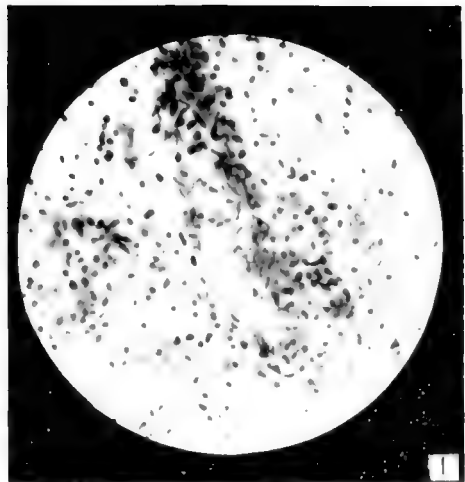
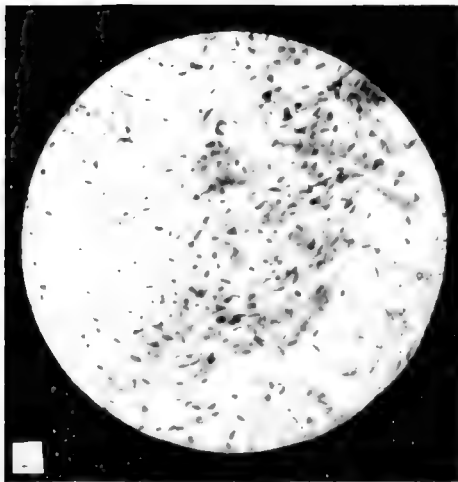
He practicado autopsias en fetos desde el cuarto mes de la vida fetal, pues la adquisición de fetos de menos tiempo es muy difícil; bien que es de presumir que si las diferencias existen desde el cuarto mes en adelante deben existir en los meses anteriores. Apuntaré que las diferencias de sexo no implican mayores diferencias en el desarrollo de dichos músculos y que los fetos de aspecto sífilítico parecen ser el material más apropiado para establecerlas, bien que sobre este punto no se pueda hacer una afirmación categórica.

Expongo á continuación las diferencias estructurales musculares apreciables en las preparaciones cuyas figuras van adjuntas.

En el corte del recto externo (fig. 1) solo aparecen marcadamente teñidos los núcleos que son numerosos, elipsoides y orientados paralelamente á la fibra muscular; sin embargo parecen estar en un magma uniforme, el protoplasma de cada célula no está delimitado, lo que manifiesta un estado rudimentario, embrionario, estado en que los protoplasmas se tiñen mal y es difícil hacer resaltar la fibra muscular.

En el corte del recto interno (fig. 2) aparecen los núcleos ocupando una posición semejante á la de los núcleos del otro corte: se ven los protoplasmas musculares bien limitados, cilíndricos, granulosos, carecen de estrías y parecen como entrelazados, es decir, que los elementos del músculo recto interno son de más edad, las substancias coloreantes redondean los límites protoplasmáticos y las diferencias en el cuarto mes de la vida fetal colocan al recto interno como músculo mas desarrollado, sobre todo en lo que se refiere á la edad de las fibras.

En las preparaciones correspondientes á las figuras 3 y 4, demuéstrase la diversa cantidad de zonas de elementos mas embrionarios que existen en el recto externo en comparación con el



recto interno lo que hace suponer que siendo ambos músculos antagonistas en esta época de la vida fetal, la menor contracción del recto interno habrá de arrastrar á la convergencia al globo ocular, ya que el recto externo por su inferioridad no puede contrarrestar su acción. En el recto interno se ven reducidas las zonas embrionarias á unas masas blancuzcas, aisladas; en el recto externo se ve dentro de una zona central embrionaria algunas masas pardas de elementos musculares más desarrollados que tienden poco á poco á invadir la zona central según avanza el desarrollo del músculo. Á más aumento, las fibras de ambos rectos aparecen perfectamente teñidas, señalándose muy bien los límites protoplasmáticos, pero en las fibras del recto interno se marca una ligera corteza estriada, elemento que no aparece en la fibra del músculo recto externo de esta época.

Examinando las figuras 5 y 6, se pueden establecer diferencias en el número de fibras, menor en el recto externo que en el interno. En el corte del recto externo las fibras están, además, separadas por bastante tejido conectivo laxo, embrionario, tejido que existe en mucha menor cantidad en el recto interno. En la misma fibra muscular adviértese además, otra diferencia y es que las del recto externo son cortas y siguen con aspecto cilíndrico, en tanto que las del recto interno, son más alargadas, caracter que se va manifestando según avanza la evolución; sus núcleos adoptan esta forma también, como si estuvieran oprimidos por el desarrollo mayor del material estriado; las fibras del recto externo aparecen más negras porque se tiñen bien y resaltan sobre un

Fig. 1 Corte longitudinal del recto externo en el cuarto mes de la vida fetal (270 diámetros).

Fig. 2 Corte longitudinal del recto interno en el cuarto mes de la vida fetal (270 diámetros).

Fig. 3 Corte longitudinal del músculo recto externo en el quinto mes de la vida fetal (45 diámetros).

Fig. 4 Corte longitudinal del músculo recto interno en el quinto mes de la vida fetal (45 diámetros).

Fig. 5 Corte longitudinal del músculo recto externo en el sexto mes de la vida fetal (180 diámetros).

Fig. 6 Corte longitudinal del músculo recto interno en el sexto mes de la vida fetal (180 diámetros).

fondo ambarino constituido por todas las células musculares y tejido conjuntivo laxo más rudimentario.

Las diferencias en fetos de siete á nueve meses no son ya tan fáciles de establecer como se puede observar en las figuras 7 y 8; sin embargo el número de fibras sigue siendo aun menor en el recto externo que en interno é igual ocurre con la longitud y cantidad de tejido conjuntivo laxo. Á más aumento del que está hecha la micro-fotografía se observa en el recto interno la multiplicación del núcleo, el engrosamiento de la corteza estriada y muchos núcleos colocados debajo del sarcolema, lo que hace pensar que aquellos, oprimidos, huyeran del protoplasma por las discontinuidades que este presenta, en virtud de la invasión creciente del material estriado; en las fibras del recto externo el núcleo sigue siendo central y ocupa la dirección del eje de la fibra.

Las figuras 9 y 10, corresponden á cortes transversales que tiene como detalle interesante la diversa manera de asociarse las fibras musculares constituyendo fascículos secundarios perfectamente individualizados por tabiques conjuntivos, fascículos que parecen estar constituidos por menor número de fibras en el recto externo que en el interno; en este músculo se observa la formación de haces terciarios resultantes de la integración de los fascículos secundarios á otras unidades mayores, hallándose aquellos limitados por septos conectivos, bastante espesos é infiltrados en el tejido adiposo. Estos haces terciarios se encuentran tambien en el recto externo pero en mucho menor número.

Las diferencias microscópicas descritas, ocurridas durante el transcurso de la vida intra-uterina en el desarrollo de los dos rectos, externo é interno, son causa de que al nacer el feto y ser su retina impresionada por la luz, se ponga en movimiento el sistema óculo-motor, el recto interno más potente y desarrollado que el externo habrá de determinar la posición estrábica del globo ocular con un estrabismo convergente no completamente transversal, sino ligeramente oblicuo, en dirección de arriba á abajo y de fuera á dentro con duración distinta de tres á diez días bien marcada. Poco a poco va desapareciendo el estrabismo y solo cuando se hace fijar la mirada al niño aparece de nuevo la posición estrábica momentánea.



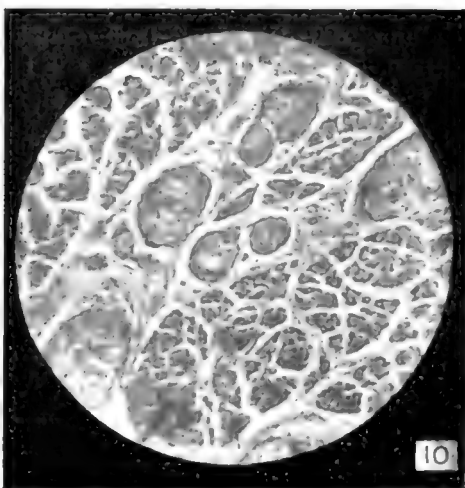
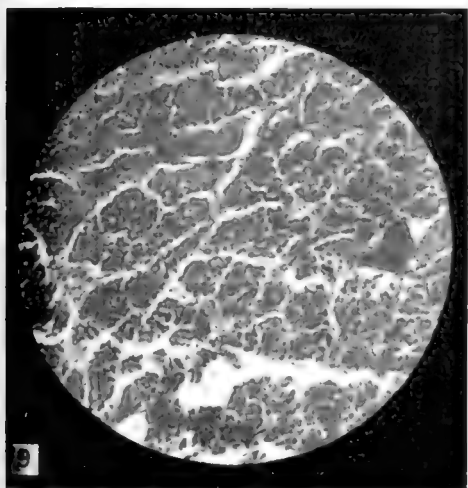
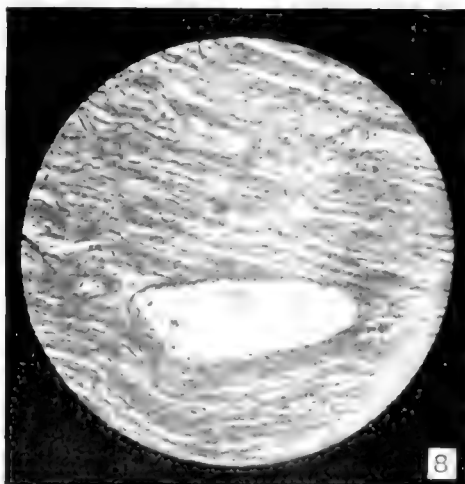
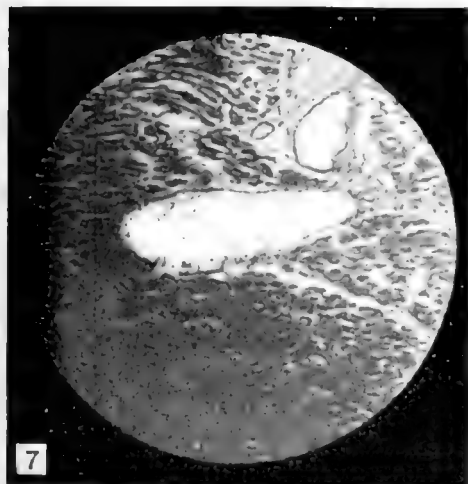
Fig. 7. Corte longitudinal del músculo recto externo (90 días de vida fetal) (90 diámetros)

Fig. 8. Corte longitudinal del músculo recto interno (90 días de vida fetal) (90 diámetros)

Fig. 9. Corte transversal del músculo recto externo (90 días de vida fetal) (90 diámetros)

Fig. 10. Corte transversal del músculo recto interno (90 días de vida fetal) (90 diámetros)

La acción combinada de todos los músculos del sistema óculo-motor, cuando las fibras musculares de todos ellos están igualmente desarrolladas y la acción de la luz sobre la retina, son las causas que hacen desaparecer este estrabismo que debe llevar el calificativo de fisiológico, teniendo presente que ningún músculo del ojo sea recto u oblicuo, tiene acción independiente característica principal que siempre está ayudada por la de otro músculo; todos unidos constituyen el delicado fisiologismo que mantiene la visión binocular. A esto hemos de añadir que los globos oculares al recibir las primeras impresiones luminosas, tienden á que por las condiciones características de que está dotada la mácula, la imagen se forme en ella y por esto es necesario el paralelismo de los ejes ópticos y visuales para que se realicen las condiciones de la visión clara y distinta.

He practicado 21 autopsias

En fetos de término.....	7
En fetos de siete meses.....	5
En fetos de seis meses.....	4
En fetos de cinco meses.....	3
En fetos de cuatro meses.....	2

Punto interesante, antes de terminar, es la delicada extirpación de los rectos para que no se confundan con los demás músculos y á más de esto procurar obtenerlos enteros. Para esto, abriendo una ventana en la conjuntiva y con gancho de estra-botomía, se busca la inserción esclerótica de ambos rectos, practicado lo cual se coloca en cada uno de ellos una pinza pequeña de Pean diseccándolos despues hasta donde se pueda, seccionando el oblicuo menor, que abraza al recto externo, y á continuación, en vez de ir á ciegas á buscar la inserción posterior, se procede á cortar la caja craneal en una sección circular, se separa la masa encefálica y queda al descubierto la pared superior de la órbita que se incinde y una vez dentro de aquella, se diseccan los músculos rectos de la inserción posterior.

# THE POSTNATAL GROWTH OF THE KIDNEY OF THE ALBINO RAT, WITH OBSERVATIONS ON AN ADULT HUMAN KIDNEY

JOHN A. KITTELSON

*Institute of Anatomy, University of Minnesota, Minneapolis*

## CONTENTS

Introduction.....	385
Material and methods.....	386
Data and discussion on postnatal growth of the kidney.....	392
1. Weights of the kidneys used.....	392
2. Growth of cortex and medulla.....	393
3. Growth of the renal corpuscles.....	396
Summary.....	405
Literature cited.....	407

## INTRODUCTION

Many questions concerning the postnatal growth of the kidney are still unsettled. In the rat, the postnatal growth curve of kidney weight in relation to body weight was worked out by Hatai ('13) and Jackson ('13). Waschetko ('14) estimated the number of renal (Malpighian) corpuscles per cubic millimeter of cortex in the albino rat at various ages from birth to five weeks. The relative growth of cortex and medulla and the total number and volume of the renal corpuscles in the kidney at various ages are the special problems for which data have been collected in the present investigation.

The work was done in the Anatomical Laboratory of the University of Minnesota. The problem was suggested by Prof. C. M. Jackson and carried out under his supervision; I wish to express my thanks for his valuable aid and criticism. I also wish to thank Dr. E. T. Bell, of the Department of Pathology, for suggestions and aid in some related work on the human kidney, a few observations on which are incidentally included in the present work.

## MATERIAL AND METHODS

The material used included the kidneys of seven albino rats (*Mus norvegicus albinus*) from the colony in the Anatomical Laboratory. The general data are given in table 2.

The identification numbers of the rats are used as follows. The letters 'V' (Vaughn) and 'K' (Kittelsson) indicate the series, the number preceding the decimal point is the litter number, while the number following the decimal point designates the individual rat. Three of the rats were from one litter (V1), and two from another (V2). Three female and four male rats are included. Their ages were newborn and one, two, three, seven, twelve and thirty-five weeks.

The rats were killed by chloroform and weighed, their nose-anus and tail lengths also being measured. Both kidneys were weighed together. The weight of each kidney used was assumed to be one-half of the combined kidney weight, as the individual kidney weights had not been recorded.

One kidney (no record made of whether right or left) in each case was fixed in Zenker's fluid for eighteen to twenty-four hours. It was then embedded in paraffin and cut in serial cross sections ten micra in thickness. The sections were then mounted in complete series and stained with haematoxylin and eosin. In the adult kidney (K1.1), only a few sections were mounted serially, for the most part every fifth section being taken.

The method used in obtaining the total volumes of medulla and cortex was the paper method similar to that used by Hammar ('14) in his volumetric work on the thymus, and by Jackson ('17) in his work on the hypophysis. The sections were enlarged by means of a Leitz-Edinger projection apparatus and the outlines of medulla, cortex and pelvis were drawn on "American Linen Record" paper (sheets 18 by 23 inches, 36 pounds per ream). The paper outlines of cortex and medulla were then cut out and weighed, the results being shown in table 1.

It was necessary, however, to find the area corresponding to a given weight of the paper. To find this, samples were taken from 100 sheets of the paper used. Each sample consisted of

TABLE 1  
*Data to illustrate the method used in finding volumes of cortex and medulla in the kidneys of the albino rat at various ages*  
 (see table 2)

RAT NO.	PAPER WEIGHT OF		PAPER WEIGHT IN TERMS OF AREA		MAGNIFICATION (DIAMETERS)	AREA DIVIDED BY SQUARE OF MAGNIFICATION (ACTUAL AREA)		NUMBER OF SECTIONS USED	VOLUME OBTAINED FROM REDUCED AREA MULTIPLIED BY THICKNESS OF SECTIONS	
	Cortex	Medulla	Cortex	Medulla		Cortex	Medulla		Cortex	Medulla
V2.1	7.50	2.46	61.115	20.024	111	4.9602	1.6252	Every other section	0.06992405	0.0032504
V2.2	4.23	1.45	34.432	11.819	60	9.5945	3.2831	Every other section	0.0191290	0.0053662
V1.3	1.113	5.50	90.614	44.770	78	14.8930	7.3580	Every other section	0.0297860	0.0147160
V13.1	7.60	5.08	61.864	41.351	52	22.8786	15.2926	Every other section	0.0457572	0.0305852
V1.7	5.50	2.51	44.770	20.472	44	22.6082	10.3381	Every fourth section	0.0904328	0.0413524
V1.8	6.87	3.23	56.087	26.292	32	54.7722	26.6525	Every fourth section	0.2190888	0.1066100
K1.1	4.11	1.44	33.700	11.722	30	37.4440	13.0260	Every tenth section	0.3744400	0.1302600

four pieces (one from each corner of the sheet), each five centimeters square, amounting to 100 sq. cm. The 100 samples weighed 122.85 grams or one sample (100 sq. cm.) weighed 1.2285 grams, on the average. From this it follows that one gram of paper corresponds to 81.4 sq. cm. of area. The total weight of medulla or cortex in paper in grams is therefore multiplied by 81.4 to obtain the corresponding area. This magnified area in square centimeters was then divided by the square of the magnification to reduce it to actual area. The actual area multiplied by the thickness of the section (or sections, since every other section, or every fourth section, or every tenth section, was used) gives the actual volume of medulla or cortex in each case (tables 1 and 2).

In table 2, the volumes of the kidneys appear much smaller than might be expected from the corresponding weights. This difference is due to three factors: (1) the volume of the capsule and of the renal sinus (pelvis), both of which were excluded; (2) shrinkage of material in the process of preparation; (3) the specific gravity of the kidney, making the volume (in cubic centimeters) somewhat less than the corresponding weight (in grams).

In counting the number of Malpighian corpuscles of the kidney by means of the mounted serial sections, a two-fold problem is presented. The corpuscles of varying sizes must all be counted once and none must be counted more than once. In order to count them all at least once, it is only necessary to cut the sections so thin that they are thinner than the diameter of the smallest corpuscle. In the newborn rat, the smallest corpuscle was found to be about 40 micra in diameter, hence sections cut at 10 micra would be certain to section every Malpighian corpuscle.

In order to be certain that no Malpighian corpuscles were counted more than once, Miller and Carlton ('95) used the following method: The average diameter of the corpuscles was determined, and sections of a piece of cortex, cut at about the average diameter obtained. Section 1 was then projected by a camera lucida and the corpuscles marked by dots. Section 2

TABLE 2  
General and volumetric data for the kidney of the albino rat at various ages

RAT NO.	SEX	AGE	NOSE-ANUS LENGTH	GROSS BODY WEIGHT	WEIGHT OF 2 KIDNEYS	TOTAL VOLUME OF KIDNEY, CORTIX AND MEDULLA	VOLUME OF MEDULLA IN 1 KIDNEY	VOLUME OF CORTIX IN 1 KIDNEY	TOTAL NUMBER OF RENAL CORPUSCLES IN 1 KIDNEY	NUMBER OF RENAL CORPUSCLES PER CUBIC MILLIMETER OF CORTIX
		weeks	mm.	grams	grams	cu. mm.	cu. mm.	cu. mm.		
V2.1	F	Newb.	51	5.2	0.055	13.1709	3.2504	9.9205	15,533 <sup>1</sup>	1580 <sup>2</sup>
V2.2	M	1	67	10.3	0.156	25.6952	6.5662	19.1290	26,598 <sup>1</sup>	1057 <sup>2</sup>
V1.3	M	2	69	11.8	0.169	44.5020	14.7160	29.7860	21,061	802
V13.1	F	3	91	22.6	0.290	76.3124	30.3852	45.7572	25,930	566
V1.7	M	7	122	41.6	0.498	131.7852	41.3524	90.4328	28,583	316
V1.8	F	12	166	122.2	1.207	325.6988	106.6100	219.0888	28,863	131
K1.1	M	35	265	207.0	1.566	504.7000	130.2900	374.4100	28,000 <sup>3</sup>	75

<sup>1</sup> Including renal corpuscles still in stages of formation.

<sup>2</sup> Including only fully formed corpuscles.

<sup>3</sup> Estimated approximately from the three preceding cases.

was then drawn upon the drawing of section 1 and the corpuseles coinciding in both sections noted and eliminated.

In my work this method was modified as follows. The work was done by the use of a Leitz-Edinger projection apparatus. A projected image of any given section, say section 1, was drawn and the Malpighian corpuseles indicated by circles (black). When the drawing was finished, the next section to be drawn, section 2, was projected on the drawing of section 1. Drawing 1 was then made to fit projection 2 and, this accomplished, drawing 1 was fastened securely. A sheet of carbon copying paper (similar to that used in typewriting) was then placed over drawing 1 and a fresh sheet of drawing paper placed over the carbon paper. Section 2 was then drawn on the fresh sheet of drawing paper, at the same time being automatically transferred to drawing 1 as a carbon copy in different color (blue). Now everything that coincides in the two sections also coincides in the two drawings, and the color of any isolated corpusele tells to which section it belongs. By using this method, the Malpighian corpuseles were seen in the drawings in three ways: (1) as double circles, one circle blue the other circle black; (2) as single blue circles; and (3) as single black circles. All the double circles were drawings of corpuseles which occurred in both sections and were not counted, since they had already been counted once. A single blue circle represents the first section of a corpusele and a single black circle represents the last section of a corpusele. Hence, the total number of all the single blue circles in all the drawings would equal the total number of renal corpuseles in the kidney. The total number of all the single black circles in all the drawings would also equal the total number of corpuseles in the kidney. The method, therefore, gives a check on itself in obtaining the total number of corpuseles in the kidney. In all cases, the two counts, for single blue and single black circles, were very close together.

Imperfect sections were avoided whenever possible. When a wrinkled section had to be used, the resulting displacement of the drawings was measured, the displacement of the renal corpuseles being established by the displacement of vessels and



section outlines. The result was also checked up under the microscope.

The problem of determining the size and total volume of the renal (Malpighian) corpuscles was more difficult. The range in size (diameter) was directly determined by using a Leitz filar micrometer. In each case, corpuscles which appeared to be the largest or smallest were followed through serial sections and measured to obtain their maximum diameter. The diameters of the largest and smallest corpuscles thus found are given in table 5 (columns, a, b, d, e), representing in each case measurements from ten selected corpuscles. The cortex was arbitrarily divided into an outer and an inner zone of equal width, and the measurements for each zone kept separate, as shown in table 5.

The average diameters of the renal corpuscles in the two zones were estimated by the modification of the paper method used by Jackson ('17) in measuring the volumes of cells and nuclei. In every case, fifty corpuscles (representing all those occurring in a given area) from each zone were drawn in outline at a magnification of 150 to 200 diameters. The paper was the same as that used in measuring cortex and medulla. The outlines of the corpuscles were cut out, weighed, and the weight (in grams) reduced to area (square centimeters) by multiplying by 81.4 (as previously explained). Dividing this area by the square of the magnification gives the actual area, and dividing again by 50 gives the average area of a renal corpuscle, as appearing in the sections. If the corpuscles be considered as spheres, this average area should represent two-thirds the area of the corresponding great circle (since according to the rules of solid geometry the volume of a sphere equals two-thirds of the volume of the circumscribed cylinder).

From the average great circle, the average diameter and volume of the renal corpuscles for each zone are easily obtained, as shown in table 5, columns e and f. To calculate the average size of corpuscles for the entire kidney, however, two additional factors must be observed. In the first place, the corpuscles are in general more numerous per unit of volume in the outer than in the inner zone. By counting the number of corpuscles ap-

pearing in equal areas in the sections in the two zones, the average ratios were determined, as given in column g of table 5. The average diameter of the renal corpuscles for the whole kidney, corrected for this factor, appears in column h. Finally, it is evident from the shape of the kidney that although the width of the two zones is equal, the outer will be much larger in volume. Since it was not practicable to estimate this difference accurately, the final average diameter of the corpuscles for the whole kidney (table 5, column i) was estimated arbitrarily as half way between the figures obtained in table 5, column h, and the average diameter for the outer zone (column c). While not absolutely accurate, this may be considered a fair approximation.

From the average diameter of the renal corpuscle, the average volume is easily obtained. This, multiplied by the total number of corpuscles, gives the total volume of the renal corpuscles in one kidney (table 5, column j).

#### DATA AND DISCUSSION ON POSTNATAL GROWTH OF THE KIDNEY

##### *1. Weights of the kidneys used*

The gross body weight and the weight of both kidneys of the rats used (table 2) correspond fairly well with those of normal rats of similar weight and body length as worked out by Hatai ('13) and Jackson ('13). The differences in weight between both kidneys in the rats used and in normal rats of the same sex and body length, as shown by the tables of Donaldson ('15), are as follows: The kidneys of the newborn rat are 0.003 gram above normal weight; those of the one week rat 0.002 gram above; those of the two weeks rat 0.001 gram above; those of the three weeks rat 0.036 gram below; those of the seven weeks rat 0.012 gram below; those of the twelve weeks rat 0.082 gram above; and those of the thirty-five weeks rat 0.227 gram below. These differences are comparatively small, with the exception of the adult at thirty-five weeks. Even the latter is probably within the limits of normal variation. Thus the kidneys used may be considered as normal in weight, since the relations between kidney weight (and volume) to body weight at the various periods agree fairly with the established norms.

2. *Growth of cortex and medulla*

The data showing the absolute growth in volume for cortex and medulla of the kidney at the various ages are given in table 2. The significance of these figures may be more readily comprehended in terms of relative growth, as given in table 3.

The ratio between the volumes of medulla and cortex (table 3) is somewhat variable. In the newborn, the ratio is 1:3.05; that is, the cortex is 3.05 times greater in volume. At one week, the ratio has changed to 1:2.91, apparently indicating a relatively smaller increase in the cortex. This continues at two weeks,

TABLE 3

*Relative growth in volumes of cortex and medulla in the kidney of the albino rat at various ages. Data derived from table 2*

RAT NO.	AGE	RATIO OF MEDULLA TO CORTIX	PERCENTAGE OF KIDNEY VOLUME FORMED BY		INDEX OF GROSS BODY WEIGHT (GRAMS) DIVIDED INTO VOLUME (CU. MM.) OF	
			Cortex	Medulla	Cortex	Medulla
	<i>weeks</i>					
V2.1	Nb.	1:3.05	75	25	1.91	0.63
V2.2	1	1:2.91	74	26	1.86	0.64
V1.3	2	1:2.02	67	33	2.52	1.25
V13.1	3	1:1.50	60	40	2.01	1.35
V1.7	7	1:2.10	69	31	2.03	0.93
V1.8	12	1:2.00	67	33	1.79	0.83
K1.1	35	1:2.87	74	26	1.81	0.63

the ratio then being 1:2.02. The cortex apparently reaches its minimum relative size (compared with medulla) at three weeks, the ratio then being 1:1.50. At seven weeks, however, a relatively greater increase in cortical volume has changed the ratio of medulla and cortex to 1:2.10, which remains nearly the same (1:2.00) at twelve weeks. The ratio in the adult rat is 1:2.87, indicating that the relatively greater growth of the cortex continues during the final period.

The volumetric relations of cortex and medulla are similarly evident from the percentages which each forms of their combined volume at the various ages (table 3). Thus the cortex decreases in relative volume from 75 per cent of the total at birth to 60

per cent at three weeks, increasing again to 74 per cent in the adult. The medulla shows a corresponding increase from 25 per cent in the newborn to 40 per cent at three weeks, decreasing again to 26 per cent in the adult.

The relative growth of cortex and medulla may also be studied from a different point of view by comparing the volume of each with the corresponding total body weight. An arbitrary index of their relative growth is thus obtained, as shown in the last two columns of table 2. In general, the growth index of the cortex appears more nearly constant, indicating that the increase in the volume of the cortex conforms more nearly to the growth of the body as a whole. There is a slight relative increase in the cortex between birth and two weeks, followed by a slight decrease thereafter. The medulla, on the other hand, shows a more varied relative growth rate. It doubles its growth index (compared with the entire body weight) between birth and two weeks, continuing its relative increase to a maximum at three weeks. Thereafter it shows continuous and rather marked decrease, indicating that its growth lags behind in comparison with that of the whole body.

In the adult (at thirty-five weeks) the ratios in the volumes of cortex and medulla, both in comparison with each other and with the whole body, have thus apparently returned nearly to those found in the newborn. On account of the possibility of individual variations, no great emphasis can be laid upon the individual data, but the general trend of the relative growth rates in the cortex and medulla appears clearly.

Jackson ('13) has shown that kidneys of the albino rat (post-natal) at first increase in weight more rapidly than the body, increasing from 0.96 per cent of the body at birth to a maximum of 1.44 per cent at twenty days, decreasing thereafter to 1.03 per cent at ten weeks, and to 0.93 per cent at five months. The data from the present investigation indicate that this early rapid increase in weight (up to three weeks) is due chiefly to growth of the medulla, the relative increase of cortex being less marked during the corresponding period. The later decrease in the relative weight of the kidney likewise appears to be due

chiefly to decrease in the growth rate of the medulla, since the growth rate in the cortex is more uniform.

Miller and Carlton ('95) found the total cortical volume in the fresh kidney of the adult cat to be 12.5 cc. and the volumetric ratio between medulla and cortex to be 3:7 or 1:2.33). In hardened kidneys the ratio was more nearly 1:2.

Schweigger-Seidel ('65) found the weight of the cortex in an adult pig's kidney to be 102 grams (volume 99,000 cu. mm.) and the weight of the medulla 12.5 grams. This gives a ratio of medulla to cortex in the adult pig of about 1:8 by weight. The pig has also been characterized by Peter ('09) as having relatively an extremely large cortex.

Toldt ('74), Külz ('09), Hauch ('03) and Felix ('12) have studied the relationship of medulla and cortex in human material at various ages, making linear measurements of the thickness of medulla and cortex from cross and longitudinal sections of the kidney. The ratio of medulla to cortex (in thickness) appears to be four or five to one at birth and about two to one from the age of twelve years on. That is, the cortex appears to increase much more than the medulla. Hauch ('03) noted great increase in the cortical mass of the human kidney between birth and seven years. Felix ('12) states that the cortex grows regularly between birth and seven years, with but little growth in the medulla; while after the age of seven years both cortex and medulla grow equally and double their diameters by the age of puberty. Such linear measurements, however, are not conclusive in showing the actual ratio between the volumes of medulla and cortex, and are apt to be misleading as an index to total volumetric or weight relations.

As a matter of fact, in work now in progress in an adult human kidney, I find the ratio between medulla and cortex to be about 1:1.9 (by volume). The data concerning this kidney are given in the following table.

*Observations on a normal kidney of an adult white male, age about thirty-five years, who was injured by a blow upon the head and died six hours later*

Body length.....	167 cm.
Body weight (estimated).....	.75 kgm. (170 lbs.)
Weight of right kidney at autopsy (Left kidney not weighed).....	115 grams
Weight of cortex (after hardening).....	90.20 grams
Weight of medulla (after hardening).....	43.00 grams
Volume of cortex (after hardening).....	.93 cc.
Volume of medulla (after hardening).....	.50 cc.
Estimated total number of renal corpuscles in entire kidney.....	1,040,000

After weighing the kidney at autopsy, the fibrous capsule was removed and the kidney was hardened by placing it for forty-eight hours in a 10 per cent formalin solution. The kidney was then cut in gross transverse sections two or three millimeters thick. Each section was then divided carefully with a fine scalpel along the border line separating cortex and medulla. The renal pelvis, fat, vessels, etc., of the sinus renalis were then removed. After weighing the cortex and medulla (not including capsule, pelvis, etc.), the volume of each was determined by water displacement in a graduated glass cylinder.

In general, therefore, it appears that in the kidney of the rat the volumetric ratio between medulla and cortex decreases from about 1:3 in the newborn to 1:1.5 at three weeks, increasing again to nearly 1:3 in the adult. In the human adult kidney the ratio is about 1:1.9, the earlier relations being uncertain. In the adult cat the volumetric ratio of medulla to cortex is about 1:2.3 (Miller and Carlton). In the pig the cortex appears relatively enormous, the ratio of medulla to cortex being about 1:8 (by weight), according to Schweigger-Seidel.

### *3. Growth of the renal (Malpighian) corpuscles*

*a. Total number of corpuscles at various ages.* As shown in table 2, the total number of (fully developed) renal (Malpighian) corpuscles apparently increases from 10,465 in the newborn to 28,863 at twelve weeks. In addition to these, however, 5068 developing renal corpuscles were observed in the newborn kidney, 6916 in the kidney at one week, about thirty at two weeks, but none in process of development in the older kidneys. This

seems to show that although the process of new formation had not yet entirely ceased at two weeks, it had become very slow. Since a developing corpuscle is usually so large and distinct that it can hardly be overlooked when searched for, it is evident that the relatively small apparent increase in the number seen after the third week is probably due to individual variation. If this be true, the permanent number of renal corpuscles in the albino rat may be placed at about 27,800, which is the average of the numbers given in table 2 for the rats at three, seven and twelve weeks. In round numbers, this would be about 28,000, the number assumed to be present in the adult rat (K1.1, thirty-five weeks) in which no actual count of the corpuscles was made.

Some data cited for comparison are shown in table 4.

Miller and Carlton ('95) estimated the number of renal corpuscles in the cat's kidney to be 16,000, which appears far too low. Peter ('09) estimated the number of renal tubules for the cat to be 250,000 (200,000 to 300,000) in one kidney. Schweigger-Seidel ('65) estimated the total number of renal corpuscles in the kidney of the pig to be 500,000. Huschke ('28) calculated the total number of corpuscles in the human kidney to be 2,100,000. Schweigger-Seidel ('65) considered this estimate impossible, since the cubical content of 2,000,000 corpuscles, at an average diameter of 0.200 mm. would equal one-eighth the total kidney volume. Sappey ('89) estimated the total number of corpuscles in one human kidney at 560,000.

In the work on an adult human kidney previously referred to, I have measured the volume of the entire cortex (by water displacement) and have counted the renal (Malpighian) corpuscles in mounted serial sections of five carefully measured pieces taken from different parts of the cortex. The same method was used as explained for the rat's kidney. From the average data thus obtained, I estimate that the number of corpuscles in the entire cortex of this one human kidney is about 1,040,000; or, in round numbers, one million. This number is intermediate between the estimates of Huschke and Sappey. There is doubtless normally some individual variation in the number of corpuscles, even in kidneys of the same size.

TABLE 4  
*Data on number, diameter and volume of the renal (Malpighian) corpuscles and their volumetric ratio to the kidney (cortex and medulla combined) and to the cortex in the adult rat, cat and man*

SPECIES	AUTHOR	NUMBER OF CORPUSCLES IN 1 KIDNEY	AVERAGE DIAMETER OF CORPUSCLES mm.	TOTAL VOLUME OF			RATIO OF TOTAL VOLUME OF CORPUSCLES TO TOTAL	
				Kidney cu. mm.	Cortex cu. mm.	Corpuscles cu. mm.	Volume of Kidney	Volume of cortex
Rat (adult)	Kittelsson	28,000	0.127	504.7	374.4	29.90	1:17	1:12
Cat	Miller and Carlton	16,000	0.1027	12900	9030	9.04	1:1427	1:996
Cat	Peter	250,000	0.124	12900 <sup>2</sup>	9030 <sup>2</sup>	141.37	1:91	1:64
Man	Huschke	2,100,000	0.200 <sup>1</sup>	143000 <sup>3</sup>	93000 <sup>3</sup>	8796.48	1:16	1:10
Man	Sappey	560,000	0.200 <sup>1</sup>	143000 <sup>3</sup>	93000 <sup>3</sup>	2345.72	1:61	1:39
Man	Kittelsson	1,040,000	0.200 <sup>1</sup>	143000	93000	4356.35	1:31	1:21

<sup>1</sup> From Schweigger-Seidel ('65).

<sup>2</sup> From Miller and Carlton ('95).

<sup>3</sup> From original observation by Kittelsson.



The time when the renal corpuscles cease to appear in the kidney of the rat, according to the data above cited, is evidently some time during the third week after birth. A few (about thirty) newly-developing corpuscles appeared in the kidney at two weeks, but none at three weeks of age or later. This would place the date of cessation in the new formation of renal corpuscles slightly later than that given by Riedel ('74), who stated that in the animals born blind (dog and cat), the new formation of corpuscles continues during the first two weeks of postnatal life. Golgi (date?) states that in the dog, cat, rabbit, guinea-pig and man he has observed a continuous formation of renal tubules and glomeruli up to several days after birth. As to the human kidney opinions may be divided into two groups. According to Toldt ('74) and Felix ('12), the new formation continues during the first week or ten days after birth. According to Eckardt ('88), Herring ('00) and Stoerk ('04), on the other hand, the new formation ceases during the late fetal period, about the eighth or ninth month.

In the following table of data quoted by Policard ('09) there is a series of apparent errors. The names of Huschke and Schweigger-Seidel are evidently interchanged. A zero has been added to the number of Malpighian corpuscles given by Miller and Carlton ('95), changing the number from 16,000 to 160,000. Peter ('09) found the number of uriniferous tubules in the cat to be 200,000 to 300,000 instead of 1024, and I cannot find his estimate of 300,000 uriniferous tubules in the dog as quoted by Policard.

*Table by Policard ('09)*

ESPÈCES	NOMBRE DE TUBES URINAIRES	AUTEURS
Homme.....	2,000,000	Schweigger-Seidel
Homme.....	560,000	Sappey
Chien.....	300,000	Peter
Porc.....	500,000	Huschke
Chat.....	160,000	Miller et Carlton
Chat.....	1,024	Peter

*b. Number of renal corpuscles per cubic millimeter of cortex.* The number of corpuscles per cubic millimeter of cortex in the rat at the various ages is shown in table 2. There is a steady reduction in the number per cubic millimeter from 1057 at birth to 75 at thirty-five weeks, considering only fully formed corpuscles. If the developing corpuscles are counted with those fully formed, the number per cubic millimeter at birth is 1586.

These results are in general agreement with those of Waschetko ('14), who counted the number of corpuscles in a microscopic field of known area, and estimated therefrom the number per cubic millimeter in the albino rat. He found a decrease in the number of renal corpuscles per cubic millimeter of cortex from 1125 at birth to 814.5 at one week, 706.5 at two weeks, 1017 at three weeks, 571.5 at four weeks, and 567 at five weeks. Aside from the exceptional figure at three weeks, the general decrease is evident. Eckardt ('88) first noted this reduction in the human kidney, where he found, in the same microscopic field area, an average of 122.1 corpuscles in the newborn and only 9.35 in the adult. Schweigger-Seidel ('65) estimated about 5 renal corpuscles per cubic millimeter in the renal cortex of the adult pig and about 6 in man. Thus in the pig and man the renal corpuscles are apparently far less abundant relatively than in the rat.

The steady decrease in the number of renal corpuscles per cubic millimeter of cortex from birth to adult life is due partly to the growth of the corpuscles themselves (as will be shown later), but chiefly to the growth and expansion of the convoluted tubules, resulting in a wider separation of the corpuscles.

*c. Diameter and volume of the renal corpuscles.* The diameters of the renal corpuscles of the outer zone (table 5, columns a, b, c) show but little change during the first two weeks, while new corpuscles are forming. The maximum diameter shows (in this series, at least) an apparent decrease from 78 to 70 micra. The minimum diameter remains stationary at about 40 micra, representing the diameter of the newly developing corpuscles during this period. The average diameter of the corpuscles in the outer zone thus shows an apparent decrease from 59 to 49

TABLE 5  
Data on size of the renal (Malpighian) corpuscles in the kidney of the albino rat at various ages

RAT NO.	AGE	DIAMETER OF RENAL CORPUSCLES FROM THE OUTER ZONE				DIAMETER OF RENAL CORPUSCLES FROM THE INNER ZONE				(g)	(h)	(i)	(j)	(k)	RATIO OF TOTAL VOLUME OF CORPUSCLES IN 1 KIDNEY	RATIO OF TOTAL VOLUME OF CORPUSCLES TO CORTICAL VOLUME			
		(a)		(b)		(c)		(d)									AVERAGE DIAMETER OF CORPUSCLES CORRECTED FOR DIFFERENCE IN VOLUMES OF OUTER AND INNER ZONES (ESTIMATED)	AVERAGE DIAMETER OF CORPUSCLES ZONES CORRECTED FOR EQUAL VOLUMES (CML)	RATIO OF NUMBER OF CORPUSCLES IN EQUAL AREAS OF OUTER ZONE AND INNER ZONE
		Max.	Min.	Max.	Min.	Aver.	Max.	Min.	Aver.										
	weeks	micro	micro	micro	micro	micro	micro	micro	micro	micro	micro	micro	micro	micro	cu. mm.				
V2 1	Newb.	78	40	59	104	56	73	57	5:42.5	64	62	1.29475	1:10	1:7.6					
V2 2	1	70	40	49	105	58	65	56.5	43.5	51	52	1.46708	1:17	1:13					
V1 3	2	70	40	51	89	51	58	56.0	41.0	51	53	1.85060	1:23	1:16					
V13 1	3	89	51	56	93	68	76	56.5	41.5	65	61	3.36586	1:22	1:13					
V1 7	7	92	72	76	103	74	87	53	47	81	79	6.84566	1:19	1:13					
V1 8	12	123	91	91	125	93	98	51	49	96	95	12.84618	1:25	1:17					
K1 1	35	140	121	127	140	123	127	50	50	127	127	29.89560	1:17	1:12					

Including cortex and medulla only.

and 51 micra, probably due to a relatively greater number of small corpuseles present at these periods. From three weeks to the adult (35 weeks) there is a constant increase in maximum diameter (89 to 140 micra), in minimum diameter (51 to 121 micra) and in average diameter (56 to 127 micra). If we compare the number of corpuseles in a field containing equal areas of the outer and inner zones of the cortex (table 5, column g) there appears a continuous decrease, however, in the relative number of corpuseles in the outer zone area from 57.5 per cent at birth to 50 per cent in the adult. That is, the corpuseles are more closely crowded together in the outer zone, which contains the younger corpuseles, a uniform distribution not being attained until the adult stage is approached.

In the inner zone of the cortex, the maximum, minimum, and average diameters of the corpuseles in the kidneys of the newborn and one week rats are accordingly considerably larger than in the outer zone (table 5, columns d, e, f). The maximum diameter in the inner zone shows an apparent decrease from 104 to 89 micra between birth and two weeks, and, in the same period, the minimum diameter decreases from 56 to 51 micra. The average diameter accordingly decreases from 73 micra at birth to 58 micra at two weeks. From two weeks on they all increase; the maximum diameter increasing from 89 micra at three weeks to 140 micra in the adult, the minimum from 51 micra at three weeks to 123 micra in the adult and the average diameter from 58 micra at three weeks to 127 micra in the adult. As compared with the outer zone, the relative number of corpuseles in the inner zone (in a field containing equal areas of each zone) shows an increase from 42.5 per cent in the newborn to 50 per cent in the adult.

The average diameter of a renal corpusele in the entire cortex (table 5, column h and i) is obtained from the preceding data, with corrections as explained previously under "Material and methods." This average diameter likewise shows a decrease during the first two weeks from 64 micra to 54 micra (column h) or from 62 micra to 53 micra as finally corrected (column i).

From the second week onward there appears a continuous increase up to an average of 127 micra in the adult (at 35 weeks).

Although the average size of the renal corpuscle decreases slightly during the first two weeks, the total volume of the corpuscles shows a steady increase during this time (table 5, column j). The smaller average size of the corpuscles is evidently more than counterbalanced by the increase in number of corpuscles between birth and two weeks of age. The increase in total volume of the corpuscles continues, increasing from 1.29475 cu. mm. at birth to 29.89560 cu. mm. in kidney of the adult rat (at thirty-five weeks).

Some data for comparison are cited in table 4.

Miller and Carlton ('95) found the average diameter of the renal corpuscles in an adult cat to be 102.7 micra, which is somewhat less than that found by me for the rat (127 micra). Owing to their extremely low estimated number of corpuscles, their resulting total volume of the corpuscles in the cat is only 9.04 cu. mm. Peter ('07), however, found a somewhat larger average diameter (124 micra) for the corpuscles in the cat's kidney, which is nearly the same as my average for the rat. He estimated the average number of corpuscles in the cat at 250,000, however, corresponding to a much greater total volume of the corpuscles (141.37 mm.).

Eckardt ('88) found the average diameter of the human renal corpuscles to increase from an average of 84.77 micra in the newborn to 195.80 micra in the adult female, and to 213.49 micra in the adult male. Külz ('99) in the cortex of the human kidney at birth found the average diameter of the corpuscles in the inner zone to be 138 micra, while those of the outer zone averaged only 99 micra. Those of the inner zone showed no increase in size up to two and one-fourth years of age, but those of the outer zone during this time increased to the same average diameter, 138 micra. He found the average diameter in the adult to be 238 micra.

Schweigger-Seidel ('65) estimated the average diameter of the corpuscles in the human adult kidney at 200 micra. Using the two estimates of the total number of corpuscles in the human

kidney, Husehke's ('28) of 2,100,000 and Sappey's ('89) of 560,000, we obtain total volumes respectively of 8796.48 and 2345.72 cu. mm. If the number of corpuseles as estimated by me (1,040,000) is used, a total volume of 4356.35 cu. mm. for the corpuseles is obtained.

*d. Ratio of the total volume of the renal corpuseles to that of the renal cortex, and to the total kidney volume.* As seen in table, 5, the ratios of the total volume of the renal corpuseles to the total volume of the cortex and of the whole kidney (cortex and medulla) are somewhat variable. Thus the ratio between corpuseles and cortex varies from 1:7.6 in the newborn to 1:17 at twelve weeks. In other words, the percentage of cortical volume formed by the corpuseles varies from a maximum of about 13 per cent in the newborn to a minimum of about 6 per cent at twelve weeks. At the other ages, the results are intermediate. In the adult rat (thirty-five weeks) the corpuseles form about 8 per cent of the cortical volume.

The corresponding ratio between total volume of corpuseles and total kidney volume (cortex and medulla) varies from about 1:10 (10 per cent) in the newborn to 1:25 (4 per cent) at twelve weeks. In the adult rat, the ratio is about 1:17, the corpuseles forming about 6 per cent of the total kidney volume.

It is therefore evident that in total volume the renal corpuseles are relatively greatest in the newborn, the older stages showing an irregular decrease in their relative volume. To what extent this irregularity is due to individual variation it is of course impossible to say.

Some data for comparison are cited in table 4.

In an adult cat, Miller and Carlton ('95) found the ratio between total volume of the renal corpuseles and the total cortical volume to be 1:996 and the ratio between total volume of the corpuseles and total kidney volume to be 1:1427. These extreme ratios are due to their low estimate for the number of corpuseles. Peter ('07), however, as before mentioned, estimated the total volume of the renal corpuseles in the cat to be 141.37 cu. mm. If we use this estimate, together with the total cortical volume and total kidney volume as given by Miller and

Carlton ('95), we find the ratio between total volume of corpuseles and total cortical volume to be 1:64, while the ratio between total volume of corpuseles and total kidney volume becomes 1:91. These ratios are more nearly comparable to the corresponding ratios for the rat, though still very high (see tables 4 and 5).

In order to make a similar estimate for the human kidney, it is necessary to have data for the total cortical volume and total kidney volume in the normal adult kidney. According to my observations on one kidney, the human renal cortex measures about 93,000 cu. mm., the total volume of the corresponding kidney (cortex and medulla) being 143,000 cu. mm. (table 4). Taking Schweigger-Seidel's estimate of 0.200 mm. for the average diameter of the renal corpusele, the ratios between total volume of renal corpuseles and total cortical volume will vary according to the estimated total number of corpuseles. The ratios accordingly are 1:10 for Huschke's ('28) estimate; 1:39 for Sappey's ('89) and 1:21 for my own estimate. The corresponding ratios between total volume of corpuseles and total kidney volume become 1:16 (Huschke); 1:61 (Sappey) and 1:33 (Kittelson). It may be further noted that Huschke's data give a ratio of 1:16 between total volume of renal corpuseles and total kidney volume instead of 1:8 as stated by Schweigger-Seidel ('65).

Even excluding the aberrant data of Miller and Carlton, it would appear that the relative total volume of the renal corpuseles, as compared with total cortical or kidney volume, is in the rat much nearer to the human than it is in the cat.

#### SUMMARY

A careful volumetric study of the cortex and medulla, together with complete numerical counting of the renal (Malpighian) corpuseles, was made upon serial sections of the kidney of the albino rat at birth, one, two, three, seven and twelve weeks of age. The volumes of cortex and medulla were also measured in an adult rat (thirty-five weeks). The volumes of cortex and medulla were also measured, and the number of corpuseles

estimated, in an adult human kidney. The principal results may be summarized briefly as follows.

1. The postnatal growth of the cortex in the rat's kidney is fairly uniform, showing in comparison with the entire body a relative increase between birth and two weeks of age, decreasing slightly thereafter.

2. The growth of the medulla in the rat's kidney is more varied. Its rate of growth between birth and three weeks of age increases much more rapidly than that of the cortex or of the entire body, and also decreases more rapidly thereafter. The characteristic curve of relative growth for the entire kidney, increasing to a maximum at three weeks and decreasing therefore is therefore apparently due largely to the varying rate of growth in the medulla.

3. The volumetric ratio of medulla to cortex in the rat's kidney changes from 1:3.05 at birth to 1:2.91 at the age of one week; 1:2.02 at two weeks, 1:1.50 at three weeks, 1:2.10 at seven weeks and 1:2.00 at twelve weeks, and 1:2.87 in the adult. Linear measurements are inadequate to indicate the volumetric relations.

4. The total number of fully formed renal corpuscles found in the kidney of the newborn rat is 10,465, or 15,533 including those incompletely formed. The number increases to 19,682 at one week, or 26,598 including those which are not fully formed. At two weeks there are 24,061 (plus about 30 incompletely formed); 25,930 were counted at three weeks; 28,583 at seven weeks and 28,863 at twelve weeks.

5. The total number of corpuscles in the rat's kidney is apparently reached during the third postnatal week, as but few could be found in process of formation at the age of two weeks and none at three weeks or thereafter. The apparent slight increase in the total number of corpuscles at seven and twelve weeks is therefore probably due to individual variation.

6. The number of fully formed corpuscles per cubic millimeter of cortex in the kidney of the rat decreases from 1057 (or 1586, including the incomplete) at birth to 131 at twelve weeks, and to 75 in an adult at thirty-five weeks.



7. The average diameter of the renal corpuscles increases from about 62 micra in the newborn to about 127 micra in the adult rat. There is an apparent decrease in the average size of the corpuscles at one and two weeks, due perhaps to a larger proportion of the small young corpuscles at these periods.

8. The total (relative) volume of the renal corpuscles forms about 13 per cent of the cortex, or 10 per cent of the kidney, in the newborn. Later the relative volume of the corpuscles decreases irregularly, forming at twelve weeks only about 6 per cent of the cortex or 4 per cent of the total kidney (both cortex and medulla).

9. In an adult human kidney, the cortex measured about 93,000 cu. mm. and the medulla 43,000 cu. mm. The number of corpuscles was estimated at 1,040,000, with a total volume of 4356.35 cu. mm., forming 1/21 of the total cortical volume of 1/33 of the total kidney volume (both cortex and medulla).

#### VI. LITERATURE CITED

- DONALDSON, HENRY H. 1915 *The Rat*. Memoirs of the Wistar Institute of Anatomy, No. 6, Philadelphia.
- ECKARDT, C. T. 1888 Ueber die compensatorische Hypertrophie und das physiologische Wachstum der Niere: *Arch. f. path. Anat., exiv*, S. 217-245.
- FELIX, W. 1912 The development of the urogenital organs. Keibel and Mall's Human Embryology, vol. 2.
- GOLGI, C. (undated) In Schenck's *Elementi di istologia normale dell'uomo*. Italian translation by Monti and Golgi.
- HAMMAR, I. A. 1914 Methode, die Menge der Rinde und des Marks der Thymus, sowie die Anzahl und die Grösse der Hassal'schen Körper zahlenmässig festzustellen. *Zeitschr. f. angew. Anat. u. Konst.*, Bd. 1, H. 4-5, Berlin.
- HATAI, S. 1913 On the weight of the abdominal and thoracic viscera, the sex glands, ductless glands and the eyeballs of the albino rat (*Mus norvegicus albinus*) according to body weight. *Am. Jour. Anat.*, vol. 15, no. 1.
- HAUCH, E. 1903 Ueber die Anatomie und Entwicklung der Niere. *Anat. Hefte*.
- HERRING, P. J. 1900 Development of the kidney and its relation to pathological changes which occur in them. *Jour. of Path. and Bact.*, vol. 6, p. 459.
- HUSCHKE, 1828 Ueber die Textur der Nieren. *Isis*, vol. 21, S. 550-599. (Cited by Schweigger-Seidel.)

- JACKSON, C. M. 1913 Postnatal growth and variability of the body and of the various organs in the albino rat. *Am. Jour. Anat.*, vol. 15, no. 1.  
1917 Effects of inanition and refeeding upon the growth and structure of the hypophysis in the albino rat. *Am. Jour. Anat.*, vol. 21, no. 2.
- KÜLZ, LUDWIG. 1899 Untersuchungen über das postfötale Wachstum der menschlichen Niere. Inaug.-Diss. Kiel.
- MILLER, W. S. and CARLTON, E. P. 1895 The relation of the cortex of the cat's kidney to the volume of the kidney and an estimation of the number of glomeruli. *Transactions of the Wisconsin Academy of Science*, 10, pp. 525-533.
- PETER, KARL 1907 Ueber die Nierenkanälchen des Menschen und einiger Säugetiere. *Verhandl. d. anat. Ges.*, 21<sup>te</sup> Vers. Würzburg, pp. 114-124.  
1909 Untersuchungen über Bau und Entwicklung der Niere.
- POLICARD, J. 1908 *Le tube urinaire des mammifères*.
- RIEDEL, B. 1874 Entwicklung der Säugethierniere. *Untersuchungen aus dem anatomischen Institut zu Rostock*.
- SAPPEY, C. 1889 *Traité d'anatomie descriptive*, T. 4, p. 499.
- SCHWEIGGER-SEIDEL, F. 1865 Die Nieren des Menschen und der Säugetiere im ihrem feinerem Bau. Halle.
- STOERK, O. 1904 Beitrag zur Kenntnis des Aufbaus der menschlichen Niere. *Anat. Hefte*, no. 72.
- TOLDT, C. 1874 Untersuchungen über das Wachstum der Nieren des Menschen und der Säugetiere. *Sitz. Ber. d. k. Akad. d. Wiss. Wien.* 69 Bd., 3 Abt. Aprilheft.
- WASCHETKO, N. P. 1914 Zur Frage von dem physiologischen Wachstum der Niere. *Centralblatt allg. Pathol.*, Bd. 25, no. 14.

## AN ANOMALOUS CASE OF BLOOD FORMATION IN THE CONNECTIVE TISSUE OF THE SCIATIC NERVE IN MAN

R. S. GUTSELL

*From the Department of Histology and Embryology, Cornell University*

SIX FIGURES

Among the slides in use in the Department of Histology and Embryology of Cornell University, Ithaca, N. Y., my attention was called some time ago to sections of sciatic nerve from a newborn child, in which were cells apparently of the hematopoietic series in the interfunicular connective tissue. A very little study under high magnification shows beyond a doubt that here in the connective tissue surrounding and very closely associated with the smaller vessels of the nerve, certain phases, at least, of blood cell formation were in progress when the tissue was fixed.

A number of questions immediately come to mind. What blood cells are being formed? From what are they derived? Are the hemoblasts arising from local mesodermal cells, or are they 'sown' by the blood vessels? Do the cells ever get into the circulation? To what other blood-forming organs are these groups comparable? What special condition caused these processes to go on?, etc. Of course all of these questions may not be answered fully and surely. The preparations themselves stand in the way of this, and also the fact that very little is known concerning the individual from whom the tissue was taken. But even with the little which is positive, the probabilities and possibilities in the case should be of sufficient interest to justify a short description.

As above mentioned, the child died at birth. The data card shows no account for the death, but a remark, added after some

of the tissue had been examined suggests the existence of leukemia. Examinations of tissue at hand shows little or no evidence of this effect. Sections of the liver, I am told, show acute parenchymatis hepatitis. In preparations of trachea and esophagus, bladder, and thymus, no pathological condition was noted. There is no data to tell what part of the nerve was sectioned, but as a good-sized artery appears attached to it in many of the sections, it would seem that this is the inferior gluteal artery, and that the section of the nerve which was prepared was taken close to its passage through the sciatic notch. Other portions of the nerve have been recently sectioned, but as little or no hematopoietic tissue appears, one concludes that the region in which the activity was going on is restricted to only a small portion of the nerve. However, the fact that similar groups of cells are found surrounding intrinsic vessels of the externa of the near-by artery, and also, to some extent in the adventitia of the bladder leads one to the belief that the hematopoiesis in the connective tissue is general and not merely of local origin.

In the nerve the connective tissue is abundant and not very dense, so that the connective tissue spaces between the nerve bundles are large. Practically no fat appears, and the blood vessels are more abundant, or at least more in evidence than in similar preparations from other individuals. In close connection with the smaller of these vessels (arterioles, capillaries, and venules), are found the groups of blood-forming cells. One notices two characteristic appearances to these groups which is striking, although transitional forms are abundant. One is small, compact, and confined to a small (round) area, closely surrounding the small vessels, and here in some cases the uniformity and arrangement of the cells would at first lead to the belief that only lymphocytes are being produced. The other extreme shows the cells diffused out into the connective tissue so that a large interfunicular space is filled with cells, densely massed around the blood vessels and scattered through the connective tissue at the periphery. Here the cells are always of a variety of types whose character and arrangement will be dis-

cussed later. Although the sections are not serial, it would seem that these groups extend longitudinally along the course of the vessels.

After a good deal of study I have come to the conclusion that only one process is going on here to any noticeable extent, and that the differently appearing groups merely represent different stages in this process, namely erythrogenesis. As all the larger groups and some of the smaller ones contain erythroblasts, and there seems to be no production of granulocytes, the presence of erythroblasts and their degree of differentiation gives some kind of a clue as to the stage of the separate groups of cells, and what seems to be the relative 'age' of the groups as well. Whether or not the stem cells migrated from the blood vessels, I believe that very few erythrocytes or erythroblasts find their way into vascular channels, and as they have not been observed degenerating in the tissues, it is fair evidence for believing that the process has not been going on long. As young stages are always found, there is no reason for believing that the activity has ceased in any of the groups observed.

The tissue was prepared under the direction of S. H. Gage in 1901 or 1902. It was fixed in Müller's fluid, and afterward put for a short time in Hermann's fluid. The several pieces were all imbedded in paraffin. The most favorable portion, by misfortune, was sectioned for class use and very well stained with Delafield's haematoxylin, and eosin. However, some of the tissue I have cut, and stained with eosin-methylene blue blood stains. Nuclear detail is naturally not well preserved.

There are a number of different types of cells present. The smaller groups in which there are no late erythroblasts or erythrocytes present, contain two types of cells which are found to intergrade. One resembles a small lymphocyte, with dark staining nucleus. The other type shows a large, pale basophilic nucleus with a narrow rim of cytoplasm. These latter are at first small with basophilic cytoplasm, but in the older groups where definite erythroblasts are present, they are larger and their cytoplasm is acidophilic to a varying degree. In the rather loose connective tissue around the periphery may often be found

fibroblasts whose processes are apparently being drawn in and whose cell bodies are rounding up. This might mean that they were contributing to the formation of the group, or at some agent emanating from the blood vessels caused them to so transform. One can easily imagine the small cells to develop from the modified fibroblasts, but the cells are not preserved well enough, or the stains specific enough to definitely determine this. Often the appearance would lead one to the opinion that the mother cells were derived from the blood vessels, so closely is the group formed around their walls.

At any rate the beginning seems to be the small cells, for they are numerous in the smaller (younger) groups, where early hemoglobin-containing cells are absent, and hardly to be found in the older stages. Forms transitional to the large cell type are very evident in the younger groups. Some groups are found consisting almost entirely of these larger cells, with perhaps one or two of the smaller type and a few in which the cytoplasmic margin is becoming thicker and is seen to contain hemoglobin, and whose nuclei are smaller and more darkly staining. Other places show every degree of change between the large cells and typical erythroblasts.

The larger groups are irregular and contain various transitional forms from the large cells to adult erythrocytes, although the latter are not very conspicuous or abundant. Around the periphery (now much farther from the vessels) may still be found the rounding-off fibroblasts. The boundaries of these proliferating centers are not well defined, the cells occupying spaces between connective tissue fibers. The different cell types are found nearly everywhere. It is interesting to note, however, that the large cells (erythrocytoblasts?) are most numerous (proliferating most) in close relation to the blood vessels, while the definitive erythroblasts and erythrocytes appear to be crowded out into the periphery of the cell group.

The production of erythroblasts and likewise erythrocytes is somewhat irregular, for the former vary greatly in size, most of them being larger than normal, while the erythrocytes found in the connective tissue spaces are as a rule larger than those in

the neighboring blood vessels. It would seem that this whole process of red blood cell formation is still at an early stage or that it is somewhat abortive, for if it was progressing to its normal conclusion, non-nucleated red cells would be more abundant. Nowhere, however, does there seem to be a superabundance of erythroblasts; nor does it seem that the mature erythrocytes

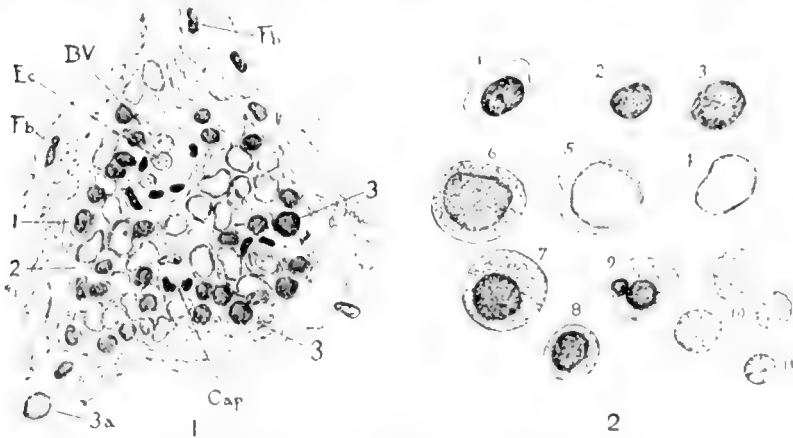
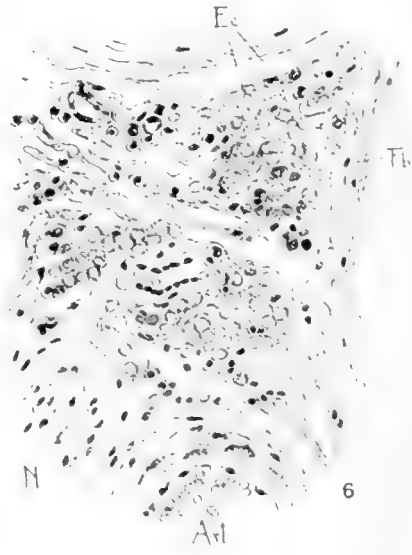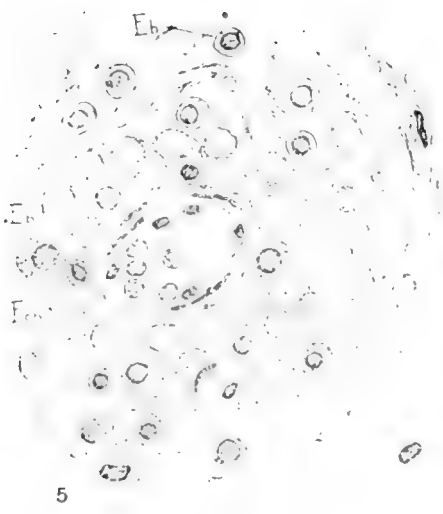
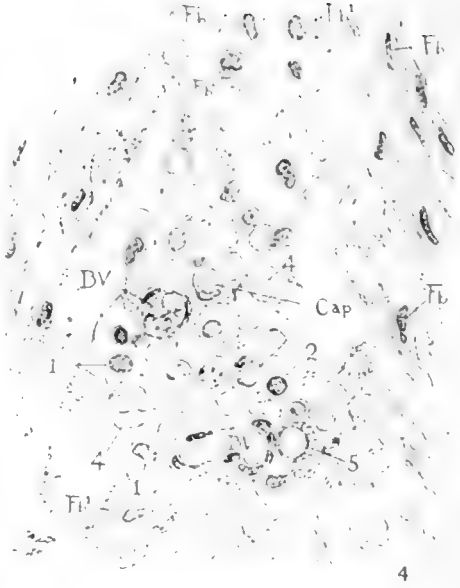


Fig. 1 Young group showing compact arrangement around small vessels. Apparently later stage than shown in figure 4, but no cells of type 5 (see fig. 2) are present. This is detail of group D figure 3. *Fb*, fibroblast; *B.V.*, small vessel; *Cap*, capillary; *Ec*, erythrocyte in blood vessel. For cell types 1, 2, 3, and 4, see figure 2. *3a*, form transitional from type 3 to 4.

Fig. 2 1. Cell type found in early cell groups and sometimes in margins of older stages. Nucleus dark, cytoplasm does not stain easily, apparently quite amoeboid. These cells very much resemble the transforming fibroblasts (figs. 1, 4, and 5). 2. Cell similar to 1, but found more abundantly in early cell groups. Although no line can be drawn between them, this would represent a cell of more regular character, with less cytoplasm and presenting a less amoeboid appearance (figs. 1, 4, and 5). 3. Type found abundantly in early groups (figs. 1 and 4). Forms transitional to 4 are easily found, (fig. 1, *3a*). 4. Cell with large pale nucleus and scant amount of slightly basophilic cytoplasm. Abundant in figures 4 and 1, and transitional to definite erythrocytoblasts (5) so extensively found in all later or 'mature' localizations of erythrogenetic activity described here, figs. 5 and 6). 5. Erythrocytoblast. Nucleus similar to that of number 4. Cells somewhat larger. Cytoplasm variably acidophilic. 6. Transitional to definitive erythroblast. Nucleus more darkly staining than the former, cytoplasm markedly acidophilic. 7. Large erythroblast. 8. Small erythroblast. 9. Erythroblast with irregularly divided nucleus, which suggests the extrusion of the smaller portion. Other somewhat similar cells were observed. 10. Erythrocytes found in the connective tissue. 11. Erythrocyte from blood vessel.





were finding their way to the blood channels, for in no place have I found the vessel walls to be incomplete, and the older cells are apt to be found somewhat removed from the vessels.

Although nothing is conclusive, there is a probability that the fibroblasts contribute to the formation of these erythropoietic cell groups. They without doubt are transformed morphologically, and the query arises, into what are they developed. In at least one place, cells of the larger type are developing between

Fig. 3 The whole nerve is shown, although the (inferior gluteal) artery, which occupies a position on the left, has been omitted. The abundance of loose connective tissue around the nerve bundles and their sheaths, should be noted. The comparatively large arteries entering the nerve at this point may account for the abundant supply of smaller vessels occupying interfunicular positions. The latter are too small to be easily demonstrated in this drawing, although their position in most cases has been indicated. At *A*, note the large group of hematopoietic cells, and their proximity to an artery of considerable size. This group is shown in some detail in figure 6. *B*, *C*, and *D* show less extensive accumulations of hematopoietic cells, similar in their size and arrangement to figures 1 and 5.

Fig. 4 Here is represented a very early group of cells. The close relation to the small vessels (*BV* and *Cap*) will be noted as well as the space in the connective tissue in which they are found. Normal fibroblasts are shown in the tissue surrounding the group (*Fb*), and also various stages of transforming fibroblasts (*Fb*<sup>1</sup>). Most of the cells present are typified by large pale nuclei and a narrow rim of slightly basophilic cytoplasm, (type 4). Cells with smaller darker staining nuclei are also shown (1 and 2). One erythrocytoblast with acidophilic cytoplasm is seen (5). No definitive erythroblasts are present.

Fig. 5 A stage later than the one in figure 4 is shown. Erythrocytoblasts predominate. These grade evenly into definitive erythroblasts (*Eb*). The nuclei at first show a deeper staining power. As this increases both cell and nucleus become more regularly spherical. Accompanying the above changes the nucleus becomes smaller, while the cell remains the same size, and hemoglobin becomes concentrated in the cytoplasm. Most of the erythroblasts are about half the volume of the larger ones. A division is implied, but good examples of division stages have not been found. No erythrocytes are present here, and the size and character of the group shows the stage to be comparatively early.

Fig. 6 Region showing an advanced stage. Detail of group shown at *A* in figure 3. Note the abundance of erythrocytoblasts in the region surrounding the small blood vessel. Here definitive erythroblasts are comparatively few, while farther out in the connective tissue they are the most abundant cell form. Erythrocytes (*Ec*) are seen scattered through the connective tissue. They are considerably larger than those in the blood vessels. Nerve bundles occupy positions at the left, top, and right. A very small strand of nerve fibers is shown in the lower left hand corner (*N*), and beside an artery is seen (*Art*).

the definitely arranged connective tissue fibers of the perineurium, and are oval, as if formed from fibroblasts without in any way changing their position. Normal fibroblasts in this region are absent, except at the margins where they seem to intergrade.

Only four or five polymorphonuclear cells (probably neutrophils) and two eosinophiles were observed in all the sections, and their presence seems of little significance.

No clue has been found regarding the reason for this abnormal localization of erythropoietic activity.

Of the well established seats of hematopoiesis, the relations are most comparable with the localizations in the fetal liver, which is recognized by Maximow to be within the connective tissue and is largely erythro-genetic. The bone marrow differs greatly in that the activity is granulogenetic as well as erythro-genetic, and this, together with whatever other processes may be going on, makes the picture very complex, instead of simple. If in the case here described, the stem cells are derived from mesodermal cells *in loco*, the comparison with early formation in the mammalian yolk-sac might be made, but here the mother cells would be fibroblasts, not mesenchyme, or the less distantly differentiated reticular cells.

The most direct comparison I have been able to find in mammals, is the condition in the interlobular connective tissue of the fetal thymus described by Badertscher.<sup>1</sup> Even here the process of erythro-genesis is accompanied by granulogenesis. It may be of some interest to note that, contrary to the general rule, no megakaryocytes were found.

The 'lymphocytes' present I believe to be lymphoid hemoblasts, so that these cells do not correspond in any direct way to the lymphocytes of the blood, unless we concede the latter erythro, or polygenetic potentialities.

I have found no reference to blood formation within a nerve. That it should in this case have localized here seems to be merely because, with the general stimulation to erythro-genesis, the

<sup>1</sup> J. A. Badertscher, 1915, Development of the thymus in the pig. II. Histogenesis. *Am. Jour. Anat.*, vol. 17, no. 3, pp. 437-487.

conditions here were favorable. The blood supply is rich, the connective tissue spaces are ample, and there is no interference with any rapidly growing organ. What might be found if various parts of this body could have been examined might very possibly show similar localizations in similarly favorable locations.



## A SCHEME FOR DRAWINGS IN A COURSE IN EMBRYOLOGY

P. E. LINEBACK

*Atlanta Medical College*

### THREE FIGURES

Probably the most beneficial part of a student's laboratory drawings is the close study he applies to minute structures in order to correctly reproduce them on paper. These two factors of inspection and reproduction give rise to the problem of how detailed his work should be. When has he seen the essentials in a given piece of work and when has he made a good drawing of them, are the gist of the problem. Usually, as in a general course in embryology, he is confronted by a great amount of detailed material, numerous textbook figures many of them elaborately overdrawn, and very limited time in which to cover the course. This means that the instructor must give him constant and special attention or he is bewildered. It is impossible for an instructor to give each student this amount of personal oversight consequently many students may go quite through the course before they have the slightest ray of light upon what they are doing. Even with the best efforts of the instructor many of the sections are selected at random and the result is a collection of drawings disconnected and unrelated. Often they adhere too closely to textbook figures rather than to original studies, and represent a vague and incoherent grasp of the subject on the part of the student. In trying to overcome some of these difficulties the writer has gradually worked out a scheme which he finds to be quite satisfactory as a definite, uncomplicated, and rounded out plan. The details of the scheme are not given here but only the principal points which it is hoped may be of use to others.

After the student has studied the introductory subjects, primitive cell masses, germ layers, and foetal membranes, and has gone over more in detail his chick material, whole mounts and serial sections, he begins a detailed study of pig and human embryos by systems. His first step is to make a careful study and drawing, from his own specimen, of the lateral surface of the pig. In this he gives special attention to contour lines of the body, and the general position, shape, and relationship of the larger structures such as branchial clefts, eye, heart, liver, mesonephros, and limb buds. Then he makes a similar drawing of a mid plane sagittal section in which he again emphasizes the general aspect of the structures. These two drawings are finished in detail

only to the extent that they show the general position, shape, and relationship of the important structures, consequently they are more easily understood and are of greater value in explaining his cross sections later. By a glance at these drawings he can easily see why he may have a portion of the fore brain and hind brain in the same section, and why the heart's apex may appear in a section with the liver. For making these and all other drawings he used a simple projection box, a modification of Begg's apparatus (*Anatomical Record*, '15) and by this means his work is not only more accurately done but is easier for him.

He now takes up the study of the entodermal or digestive tract. This system is used as a center or building line about which all other structures are studied and drawn. Earlier attempts at the formation of this plan made use of other systems as the building line, but were rejected in favor of the entodermal tract. The nervous system came more nearly giving the desired results, in that it extends through the entire series and is easy to identify and study, but on strict test it proves to be more difficult for the student to grasp its details, especially in the brain region, and its uniformity throughout the rest of its length does not permit of selecting definite important levels for study, such as are afforded by the intestinal tract and its diverticulae. His procedure is to trace the tube down the series and note certain definite places where important changes or developments are discovered. Beginning with the tongue he locates the most distinctive part of the organ, the tuberculum impar, which he finishes in detail with any other structures connected with the digestive mechanism, palate, pharyngeal pouches, etc. The section in which he found the tuberculum he draws in outline, except the structures just named, and numbers it as it comes in the series. Next he finds the section showing the pharynx proper where it appears as a transverse slit and draws it in outline, numbering it serially, but finishes the pharynx and related structures in detail. Then he studies the tube on down to where the tracheal diverticulum appears and repeats the procedure. In this way he continues the study of the tube, stopping at different places and making the outline of the sections, numbering them serially, but working out in detail all entodermal structures. The places he selects after the above named are, the right apical lung bud, the bifurcation of the trachea (fig. 1), the obliquely placed stomach (fig. 2), the entrance of the dorsal pancreatic duct into the duodenum (fig. 3) the intestinal loop in the body stalk, point of exit of the allantois from the cloaca, point of entrance of mesonephric ducts into cloaca, and tail gut.

After the completion of the digestive tract he studies the circulatory system. For this he does not make a new set of drawings, but goes over the outlines in which he studied the entodermal tract and draws the blood vascular mechanism as it appears in each. In the tongue section he draws just such aspect of carotid arteries and jugular veins that appear here. Then in the next section where he studied the pharynx he again draws the vessels which appear, and so on successively to

the last section, completing in detail the blood vessels in each (see duplicate *A*). He next goes over the urogenital system after the same manner, selecting the sections where he first studied the digestive tube, and later the circulatory system, and fills in the details of this system in each drawing (see duplicates *b*). He follows this scheme in studying all the rest of the systems and structures, nervous system, ductless glands, face, limbs, until his drawings contain the whole of the body. In all the systems he must study carefully his own series for no textbook figures will show him structures properly adjusted to his entodermal drawings with which he began. If there are important structures or places in any system which are found in sections coming between any two given sections, he draws those features as inserts, placing them at the side of an adjacent figure (see duplicate *bx*.) In his final study of the nervous system he will have several new sections of the head end to draw which may now be more easily selected by working forward from his starting point, the tongue. These sections are the seventh-eighth nerve mechanism, the origin of the third, and the origin of the fourth nerves.

The advantages of this scheme may now be briefly stated. The student has a definite plan of work; he knows where to begin and how to proceed. He studies and draws only one system at a time and at the time he is being given lectures and demonstrations upon that system. He will have the greater familiarity with all the systems since he is continually reviewing each by taking up a new one, going over the same series of drawings. The number of drawings is reduced to the minimum, fourteen to eighteen, but these are selected for a definite purpose and are structurally closely related. The collection of drawings shows a systematic, related, and completed succession of steps by which the student has gained a more concise and clearer grasp of his subject. One objection has been made to the plan that after the first system has been studied at given levels all other systems are arbitrarily studied at these same levels, thereby the student loses the selective search over the series in these systems, and he may even leave out some important feature in each. This last point may be disposed of by referring to the insert method (see duplicate *bx*), and as for the first point, while he makes his studies and drawings at arbitrary levels, selected originally for the entodermal tract, still he finds most all important features in the other systems at these levels. And as for not studying each system continuously through the series but jumping immediately to the selected levels, this still compels him to draw each system at more than one level, thus giving him greater familiarity with each under different aspects, and does not exclude such a careful scanning either. Finally it must be said that no claim of superiority is made for this scheme over the reconstruction method, in the hands of special students, but in general class work, with limited time, the students of ordinary ability will have better results with the former method.

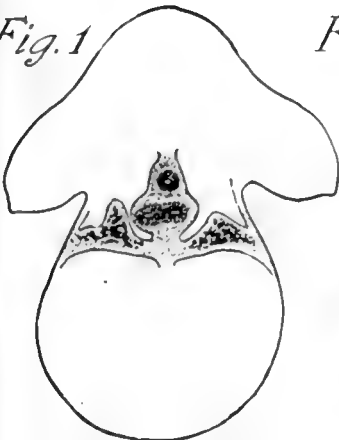
Figs. 1, 2, and 3 are selected from the whole number of drawings to illustrate how the student first makes the outline of sections at given levels, numbering them serially, but finishes all entodermal structures.

Duplicates *a* and *b* are here used to show that the student, by the aid of his serial numbers, has gone back over the same sections and has studied and drawn the vascular system in *a* and later the urogenital system in *b*. It must be understood that he does not make these duplicates in his drawings but they are used in this paper to illustrate the repeated study over the same outlines.

Insert *X* shows how he would draw an insert, in this instance the ventral pancreas attached to the hepatic diverticulum near the junction of that duct and the duodenum.

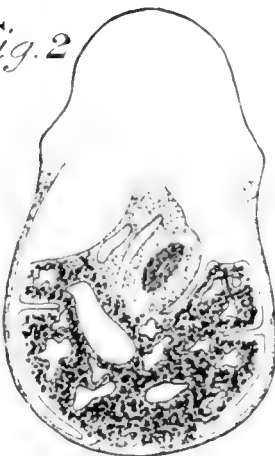


Fig. 1



Sl. 12, sec 135

Fig. 2



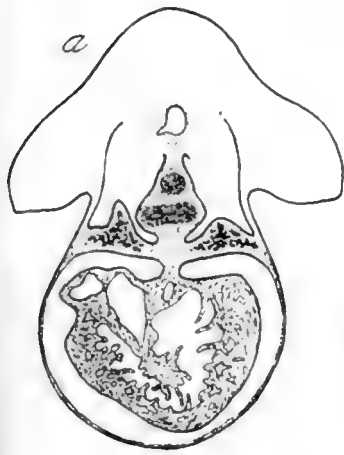
Sl. 12, sec 145

Fig. 3

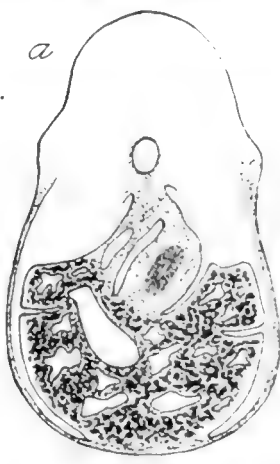


Sl. 12, sec 155

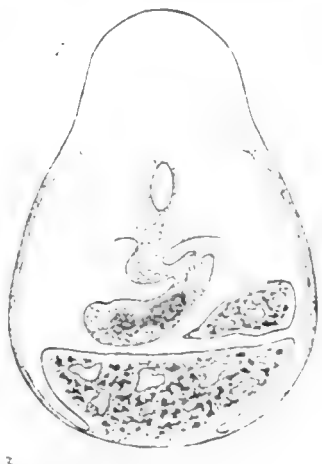a



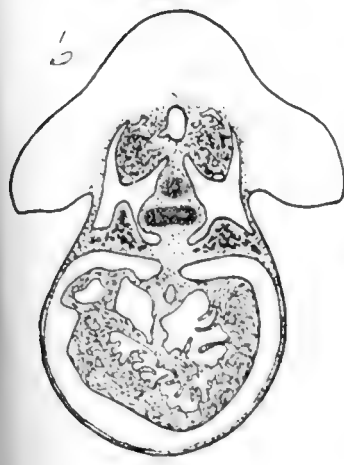
a




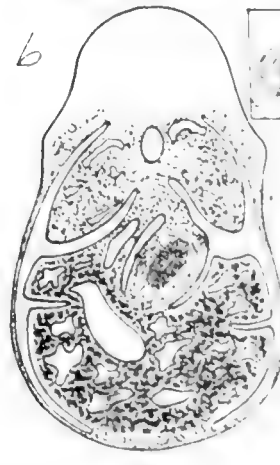
a




b



b





## ANOTHER CASE OF GYNANDROMORPHISM

MARY T. HARMAN

*Kansas State Agricultural College, Manhattan, Kansas*

ONE FIGURE

### INTRODUCTION

Morgan ('13) has defined gynandromorphism as a condition in which one part of the body is like the male and the other like the female. This difference may be one of the sex glands or merely of the secondary sexual characteristics or both.

In many groups of animals the differences in size, color and shape between the male and the female are very striking. This is particularly true among the insects where sexual dimorphism is so marked that not seldom have the male and the female been placed in different species and even in different genera. These differences are all the more noticeable when this condition appears in distinct parts of the same animal as, for example, a moth with one side very dark and without distinct color pattern and the other light with conspicuous color pattern, or a pheasant having the long brilliantly colored feathers of metallic luster of the male bird on the one side and the short somber feathers of the female on the other and one foot with a large spur, the other without a spur.

### GYNANDROMORPHS IN DIFFERENT CLASSES OF ANIMALS

More cases of gynandromorphism have been reported among insects than among any other class of animals. Except for the famous 'Eugster Bees' perhaps the greatest number are found among the Lepidoptera. Gynandromorphs are found so frequently in insects and so rarely in other forms that it is not sur-

<sup>1</sup> Contribution from the Zoological Laboratory, Kansas State Agricultural College, No. 20.

prising that Morgan should say that they occur almost exclusively in insects and rarely or never in birds or mammals. Although this statement approaches the truth, yet among other Arthropoda, Bertkau gives examples of various Crustacea and two of Arachnida. The presence of the male and female sex elements in the same animal is not uncommon in the fish and not infrequent in the Amphibia. In some Amphibia (King '10), this condition is accompanied by differences in external sexual characteristics. Among the birds, Bond ('14) gives an account of a gynandromorphous pheasant and Poll ('09) of a bullfinch. The latter author also refers to a case of a flicker and a chaffinch.

In mammals gynandromorphism has been reported to have occurred in goats, pigs and man. Pick ('14) describes testicular tissue in different regions of the same gonad in the pig. It has been suggested that the free-martin among cattle affords a close parallel to the gynandromorphs in insects, in which the secondary sexual characteristics of the two sexes are segregated to the opposite sides of the body. It might be added that this suggestion is based upon the theory that the twin calves of which the free-martin is one, arise from a single zygote which separated into two parts during the early segmentations. Lillie ('16) throws considerable doubt upon this theory of the cause of free-martins. His evidence indicates that the free-martin is a true female and that the twins are not from the same zygote but from separate ova. The writer would raise the question whether or not the cow described by Pearl and Surface ('15) which took on the secondary characteristics of a bull should not also be considered as a case of gynandromorphism in mammals.

Many cases of partial segregation of secondary sexual characters to opposite parts of the body have been known in man. Garrigues in the Medical Record, New York, states that he knew an individual who looked like a male on the left side and a female on the right side. Seldom, however, is the segregation perfectly halved. Gudernatsch ('11) says that hermaphroditism in the sense of separate ovaries and testes has not been demonstrated in man nor even in other mammals beyond a doubt. He described a case of an individual forty years old who had the ex-

ternal genitalia of the female type. The clitoris was enlarged with the opening of the urethra on the ventral side. No uterus was present and the vagina ended blindly. The Mullerian ducts had been lost. An abortive prostate-like gland was attached to the urethra. A tumor was removed from the right inguinal canal which had the form of a testis with an epididymis attached. Histological examination showed that it was an ovo-testis. In the other inguinal canal was another smaller gland, but it was not removed. There is little doubt, however, but that it was a sex gland. No other sex glands were present.

The discovery in our laboratory of a cat with a testis on the left side and an ovo-testis on the right side adds another instance of gynandromorphism among mammals. The secondary sexual characteristics as well as the structure of the external genitalia are unknown. However, each sex gland was in the normal position for a cat of that sex.

#### DESCRIPTION OF THE GYNANDROMORPHOUS CAT

The cat referred to was about two-thirds grown. It had a testis on the left side and what proved to be an ovo-testis on the right side. The animal had been killed, skinned and partially dissected before its peculiarity had been discovered. The scrotal sac and the external genitalia had been removed. The drawing shows a frontal-lateral view of the urinogenital system. The urinary bladder was pulled somewhat to the right side in order to show the entrance of the vas deferens and uterus to the urethra.

The testis which is about the size and shape of a navy bean is entirely on the outside of the body cavity ventrad and to the left of the ventral border of the pubis. It has all the appearances of a normal testis. The spermatic cord extends from the testis through the oblique muscle, where it divides into the vas deferens and the spermatic vein and artery. The vas deferens extends anteriorly until it curves over the ureter where it continues caudad dorsal to the neck of the urinary bladder. It pierces the prostate gland and enters the urethra about half between the base of the urinary bladder and the exterior. The

prostate gland of the left side is larger than the one on the right side, although there seems to be one on the right side.

The ovo-testis is located on the right side of the body a little posterior to the kidney. Anterior to the ovo-testis and partially surrounding it is the ostium tubae abdominale. The ovarian

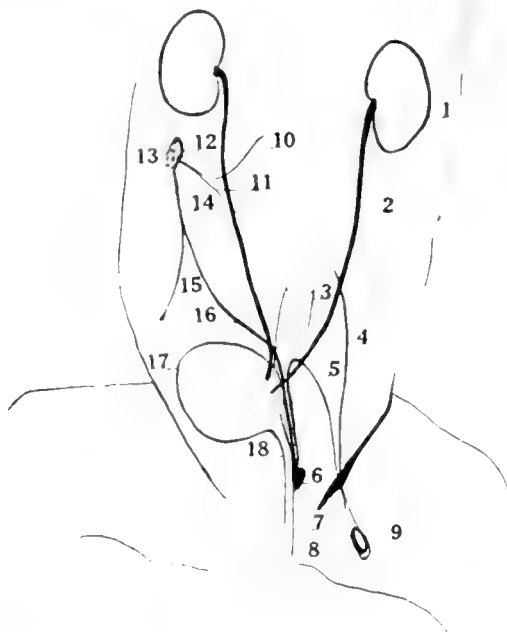


Fig. 1 The urinogenital system of a gynandromorphous cat. 1, kidney; 2, ureter; 3, large intestine; 4, spermatic vein and artery; 5, vas deferens; 6, prostate gland; 7, urethra; 8, urinogenital opening; 9, testis; 10, ovarian vein; 11, ovarian artery; 12, ostium tubae abdominale; 13, ovo-testis; 14, uterine tube; 15, round ligament; 16, cornua of uterus; 17, urinary bladder; 18, neck of bladder.

artery and the ovarian vein extend to the left from the gland. Extending from the ostium tubae abdominale is the uterine tube which continues caudad almost parallel to the vas deferens. It enters the urethra through the abortive right prostate gland. The sex gland and the uterine tube are held in place by the broad ligament and the round ligament.

Although the fixation was poor, the material being preserved merely for the gross anatomy, a histological examination reveals that a portion of the gland is arranged in strands similar to the arrangement of the semeniferous tubules of the testis, but no lumen is present. There are also parts of this gland which are made up of cells similar to the normal stroma cells of a cat ovary. Among these stroma cells are two nests of cells each of which is composed of a large central cell surrounded by a number of smaller cells. The whole group has decidedly the appearance of a young Graafian follicle.

The reproductive system of the left side of the animal has the appearance of a normal male in every respect, while the right side has the appearance of a normal female with the exception of the shape of the ovo-testis and the almost uniform size of the uterine tube and the cornua uterus. This latter difference is not significant since the cat is a young one. The angularity of the ovo-testis may be due to the pressure of the other internal organs at the time it was preserved.

#### THEORIES AS TO THE CAUSE OF GYNANDROMORPHISM

Gynandromorphs and gynandromorphism are of interest beyond the mere fact of their occurrence on account of the bearing they have upon other mooted questions such as, sex determination, heredity, the individuality of chromosomes, the rôle of chromosomes in heredity, sex dimorphism and others. The fact, that of the gynandromorphs of known ancestry a large number are among hybrids, is significant.

From the evidence obtained from the Eugster bees, Boveri ('88) suggested that gynandromorphism may be due to the uniting of the male pronucleus with only one pole of the egg nucleus which had begun to divide parthenogenetically, and that the fused male and female nucleus gives rise to the female part of the animal. Later Morgan ('05) suggested that the Eugster gynandromorphs might be the result of polyspermy. One of the spermatozoa might unite with the egg nucleus and another one or more give rise to another segmentation nucleus. The former would give rise to the female side of the body. As a corollary

to his hypothesis Morgan states that if male-determining and female-determining spermatozoa exist, that both kinds have entered the egg and the female-determining spermatozoon has united with the egg nucleus. He gives as his reason for suggesting this hypothesis that as is generally admitted but not proved beyond a doubt that, in bees, fertilized eggs produce females and unfertilized eggs produce males, that polyspermy is not assumed but is known to occur at times in bees and that such animals as the bee which produce parthenogenetically, experiment should easily show which part of the gynandromorph is paternal and which maternal.

Unfortunately von Siebold ('64) in his description of the Eugster bees did not state which side of the gynandromorphous bees was like the Italian or queen bee nor which side was like the German bee or father. Later, Boveri ('15) obtained from Munich a jar of alcoholic specimens which turned out to be those which von Siebold had obtained. On account of their having been in alcohol for so long a time the color was mostly gone, but careful examination showed that the male parts of the gynandromorphs are like the Italian bees while the female parts are like the German bees. As Morgan ('16) says, "this conclusion gives a decisive answer in favor of his (Boveri's) hypothesis and sets my own (Morgan's) aside for this case at least."

Previous to the re-examination of the Eugster bees Morgan cited the evidence obtained from a cross between two silk-worm moths as proof of his hypothesis. The female belonged to a European breed having striped caterpillars, the male belonged to the common Japanese breed having unstriped caterpillars. Two of the hybrids had the left side of the body striped and the right side unstriped. According to Morgan, the striped side is due to the combined nuclei, the other side due to the sperm nucleus alone, therefore paternal. According to Boveri the paternal side is the result of the combined nucleus. If this be true, since it is known that the striped condition is dominant both sides should be striped. Furthermore it is known that both males and females among these moths may be produced parthenogenetically.



Bridges ('16) suggests that there are not male and female spermatozoa, but the sex is determined by the presence or absence of certain specific chromosomes. When two or more X-chromosomes are present in a zygote, no matter from whence they came the resultant individual will be a female. If there are not at least two X-chromosomes in a zygote the resultant individual will be a male. He further accounts for the presence of more than two sex-chromosomes in a single zygote by non-disjunction. He suggests that if the same sort of primary non-disjunction which has been assumed to give rise to  $XX^1X^1$  cells in an XX female should take place at a cleavage stage gynandromorphs would result. If this non-disjunction should take place in a very early cleavage, particularly the first one, the individual would be a lateral gynandromorph but if it should take place in later cleavages, the individual would be a mosaic. This theory is based upon the work on *Drosophila*.

Scopoli suggested that this halved gynandromorphous *Pha-laena pini* was formed by the fusion of two pupae in one cocoon.

Doncaster has suggested that a gynandromorph is produced by the fertilization of a binucleate ovum by two spermatozoa, one a male-determining and the other a female-determining spermatozoön.

Menzel supposed in case of the Eugster bees, that the queen was malformed and that the progress of the ova were so slow that they began to segment parthenogenetically and later were fertilized.

Goldschmidt ('12) has obtained a great number of gynandromorphs in crosses between *Lymantria dispar* and *L. japonica*, which were always of three kinds, female and male gynandromorphs and 'weibchenmännchen.' These were always absent in certain crosses and present in definite proportions in others. He accounts for these on the hypothesis of the relative potencies of the sex factors in different races. With certain assumptions they occur in a perfect Mendelian ratio.

When the male factor is dominant it is more potent than the female factor, but when two such female factors are present they

are more potent than the single male factor. The factors for the secondary sexual characters behave in like manner.

As to gynandromorphism in birds, Poll ('09) suggested that the occurrence of the testis on the right side of the body was associated with the right ovary which normally atrophies and the testis of the left side is associated with the secondary male characteristics. Cockayne ('15) says that gynandromorphous birds are lateral genetic hermaphrodites and are all alike in having a testis on the male side and an ovary on the female side.

#### DISCUSSION

Both the theory of Boveri and Morgan assume that the nucleus is the bearer of hereditary characteristics which is less generally accepted than that unfertilized eggs produce male bees. While the weight of evidence is that the nucleus is, at least, a large factor in determining the hereditary characteristics it is far from being conclusively proved that it is the only factor. In the cases cited as evidence for each of the hypotheses little is known of the behavior of normal hybrids in heredity which would be necessary to account for the behavior of such abnormal hybrids as gynandromorphs. Both hypotheses assume a very early localization of the tissue, as early as the first cleavage stage, and that all the cells arising from one blastomere must give rise to one side of the body, those from the other must give rise to the other side of the body. Moreover, each hypothesis accounts for bilateral gynandromorphs only and does not account for the mosaic or mixed gynandromorphs. In addition the cases of the bird, the pig, the cat and man having an ovo-testis can scarcely be explained in accordance with these theories.

Like the two theories previously discussed, the theory of non-disjunction assumes the all-important rôle of the nucleus as the bearer of the hereditary characteristics and further more that the chromosomes are qualitatively different. The author has failed to explain the presence of secondary sexual characteristics of the sex on the side of the animal which has the gonad for that sex. In the example which the author cites (Bridges, '16, pp.

136) the male side of the animal, according to his statement, should have the sex-linked characteristics of the female, therefore, the secondary sexual characteristics of the female, if the secondary sexual characteristics are sex-linked. If the secondary characteristics are not sex-linked the arrangement of the secondary sexual characteristics has not been accounted for. The writer fails to see how this theory can explain the gynandromorph having an ovo-testis and bilateral with reference to the secondary sexual characteristics.

Doncaster's theory assumes that the important factor is the spermatozoön. However, he has shown that binucleate ova do actually exist and further he has shown the conjugation of a spermatozoön with each nucleus and has seen the resultant mitoses. Yet, he has had no cases of gynandromorphism in the race in which he found binucleate ova.

Goldschmidt's theory is based upon the assumption of relative potencies of male and female factors and as an assumption may explain cases of lateral gynandromorphs, but could scarcely explain mosaics and those cases with ovo-testis.

The case of the pheasant as described by Bond seems to be contradictory to Poll's suggestion as well as Cockayne's statement for the secondary male characters were on the left side and only one sex gland was present.

It seems that no theory thus far advanced serves to explain all cases. The solution or the cause of gynandromorphism rests upon the solution of at least two fundamental biological phenomena, the determination of sex and the determination of the secondary sexual characteristics.

#### SUMMARY

1. Gynandromorphs are comparatively common among insects and rare among other groups of the animal kingdom.
2. Of the gynandromorphs of known ancestry many of them are among hybrids.
3. The cat with an ovo-testis on one side and a testis on the other adds another gynandromorph to those recorded among mammals.

4. No one of the theories offered as an explanation of the cause of gynandromorphism seems to explain all cases of recorded gynandromorphs.

5. The solution of the cause of gynandromorphism rests upon the solution of at least two fundamental biological phenomena, the determination of sex and the determination of the secondary sexual characteristics.

## BIBLIOGRAPHY

- BOVERI, TH. 1888 Über partielle Befruchtung. Sitz. Ber. d. Ges. f. Morph. u. Phys., Münch., Bd. 4.  
1915 Über die Entstehung der Eugsterschen Zwitterbienen. Arch. f. Entw. Organismen. Bd. 41.
- BOND, C. J. 1914 On a case of unilateral development of secondary male characters in a pheasant, with remarks on the influence of hormones in the production of secondary sex characters. Jour. Gen., vol. 3.
- BRANDT, ALEX. 1889 Anatomisches und Allgemeines über die sogenannte Hahnen-fedrigkeit und über anderweitige Geschlecht Anomalien bei Vögeln. Zeitschr. f. wiss. Zool., Bd. 48.
- BRIDGES, CALVIN B. 1916 Non-disjunction as proof of the chromosome theory of heredity. Gen., vol. 1.
- CHAPIN, CATHARINE I. 1915 A case of hermaphroditism in *Spelerpes bislineatus*. Biol. Bull., vol. 29.
- COCKAYNE, E. A. 1915 'Gynandromorphism' and kindred problems. With descriptions and figures of some hitherto undescribed examples. Jour. Gen., vol. 5.
- CORBY, H. 1905 Removal of a tumor from a hermaphrodite. Brit. Med. Jour., vol. 2.
- DONCASTER, L. 1914 On the relations between chromosomes, sex limited transmission and sex determination in *Abraxas grossulariata*. Jour. Gen., vol. 4.
- FUSS, A. 1912 Über die Geschlechtszellen des Menschen und der Säugetiere. Arch. f. mikr. Anat., Bd. 71.
- GOLDSCHMIDT, R. 1912 Erblichkeitsstudien an Schmetterlingen, I. Zeit. f. ind. Abst. und Vererb., Bd. 7.
- GUDERNATSCH, J. F. 1911 Hermaphroditism verus in man. Am. Jour. Anat., vol. 11.
- KING, HELEN DEAN 1910 Some anomalies in the genital organs of *Bufo lentiginosus* and their probable significance. Am. Jour. Anat., vol. 10.
- KNAPPE, EMIL 1886 Das Biddersche Organ. Morph. Jahrb., Bd. 11.
- LILLIE, FRANK R. 1916 The theory of the free-martin. Science N. S., vol. 43.
- MORGAN, T. H. 1905 An alternative interpretation of gynandromorphous insects. Science, N. S., vol. 21.  
1907 The cause of gynandromorphism in insects. Am. Nat., vol. 41.  
1909 Hybridology and gynandromorphism. Am. Nat., vol. 43.

- MORGAN, T.H. 1913 Heredity and sex. Columbia University Press, New York.  
1916 The Eugster gynandromorph bees. *Am. Nat.*, vol. 50.
- NACHTSHEIM, H. 1913 Cytologische Studien über die Geschlechtsbestimmung bei der Honigbiene (*Apis mellifica* L.). *Arch. f. Zellf.*, Bd. 11.
- PEARL, RAYMOND AND SURFACE, FRANK 1915 The assumption of male secondary sex characters by a cow. *Science, N. S.*, vol. 41.
- PICK, LUDWIG 1914 Über den wahren Hermaphroditismus des Menschen und der Säugetiere. *Arch. f. mikr. Anat.*, Bd. 81.
- POLL, HEINRICH 1909 Zur Lehre von den Sekundären Sexual Characteren. Stzgsher. Ges. Naturf. Freunde zu Berlin.
- SIEBOLD, U. C. Th. 1864 Ueber Zwitterbienen. *Zeit. f. wissensch. Zool.*, Bd. 14. 1866 Ersatz der abgestorbenen Zwittermutter des Eugsterchen Zwitterstockes in Constanz. *Bienenzucht*, Jahrg., 1866.
- ST. GEORGE, LA VALLETTE 1895 Zwitterbildung beim kleinen Wassermoleh (*Triton taeniatus*). *Arch. f. mikr. Anat.*, Bd. 45.
- TOYAMA, K. 1906 Studies on the hybridology of insects. I. On some silkworm crosses, with special reference to Mendel's Law of heredity. *Bull. Col. Agric. Tokyo Imperial University*, vol. 7.
- WHEELER, W. M. 1903 Some new gynandromorph ants. *Bull. Am. Museum Nat. Hist.*, New York.  
1910 A gynandromorphous *Mutillid*. *Psyche*, vol. 17.



## THE FINER STRUCTURE OF THE CILIARY GANGLION OF OPHIDIANS

J. M. AYROSA GALVÃO

*From the Laboratório de Anatomia e Histologia da Faculdade de Medicina e  
Cirurgia de São Paulo; Director, Prof. A. Bovero*

Numerous gaps exist in our knowledge of the histology of the various structures of the reptilia, and among these we may include our lack of knowledge of the structures of the ciliary ganglion or ganglia of the Ophidians. At the suggestion, therefore, of Professor Bovero we undertook a series of histological researches upon the ciliary ganglia of these vertebrates; not only on account of the need of more exact knowledge of the structure of the ciliary ganglia in these forms, but also because we found it very easy to acquire the necessary material for this study, since we are located in the neighborhood of the Instituto Butantan, which possesses the largest collections of living Ophidians in the world.

The researches directed to the knowledge of the morphology of the cellular elements of the ciliary ganglion and its connections are of a relatively recent date. After the few researches made by G. Retzius, Michel and d'Erechia, with the Golgi silver-chromate method, which did not throw much light on their cellular morphology, the number of researches increased with the introduction of the photographic method of Ramon y Cajal, a method which has permitted us to extend our knowledge of this subject, especially after the investigations of G. Sala, v. Lenhossek, Carpenter, Kuntz and Pitzorno.

The sympathetic nature of the ciliary ganglion has been shown by physiological methods and has also been demonstrated histologically in a large series of observations and researches, some of a very recent date (Chiarugi, Carpenter, Kuntz, Ganfini, Riquier, Beccari, Bruni).

The purely histological studies on the ciliary ganglion of the Reptiles are much fewer in number than those dealing with the development of this and other ganglia of the cephalic sympathetic on the same vertebrates. Indeed they are limited to one contribution of v. Lenhossek,<sup>1</sup> in which he studied the ciliary ganglion of the *Lacerta agilis*, *L. muralis*, *L. viridis* among the Lacertidae; of the *Tropidonotus*, *Coluber*, and *Zamenis* among the Ophidians; of the *Testudo graeca* and *Emys lutaria* among the Chelonians; and another one of Pitzorno,<sup>2</sup> who studied the said ganglion among the following Chelonians: *Thalasseohelys carreta*, *Testudo nemoralis*, *Testudo graeca*.

If we limit ourselves more specially to the study of the Ophidians, we will then see that the only data that we possess are the observations of v. Lenhossek and this one limited to the European specimens of small size.

For this reason, when we undertook our researches upon the ciliary ganglion of the Ophidians, we endeavored to direct our attention to the greatest possible number of individuals of the most variable species, varying in size and age, giving especial attention to the specimens of large size.

The following are the species investigated by us in the present research:

*Lachesis atrox* (Jararacussú), *L. lanceolatus* (Jararaca), *L. alternatus* (Urutú), *Crotalus terrificus* (Cascavel), *Driniobius bifossatus* (Jararacussú d'agua), *Boa constrictor* (Giboia), *Elaps* (Coraes of various kinds).

It is very necessary to use a large number of individuals on account of the extreme difficulty of obtaining good staining by the method used, the reduced silver method of Ramon y Cajal in all its modifications. V. Lenhossek has previously deplored precariousness of this method and such inconvenience due to the refractiveness of the cells of the ciliary ganglion to the methods of silver nitrate reduction.

<sup>1</sup>v. Lenhossek 1911 Das ciliarganglion der Reptilien. Anat. Anzeiger, Bd. 10, no. 2 u. 3. Archiv. f. mikrosk. Anat. Bd. 80, s. 80-106.

<sup>2</sup>Pitzorno 1913 Contributo alla conoscenza della struttura del ganglio ciliare dei Cheloni. Arch. It. di Anat. e Embriol., v. 12, f. 30.



The closure of the orbital cavity on the side of the cranial cavity makes it rather difficult to isolate the contents of the orbital cavity and eventually to isolate the ganglion or ganglionic complex of the oculomotor nerve.

In the large specimens, specially in the *Boa constrictor* and *Crotalus terrificus*, it was sometimes rather easy to dissect a large and evident ganglion in close proximity to the third nerve corresponding very probably to the proximal ganglion of v. Lenhossek.

We cannot state definitely as to the existence in the several species examined by us, of the two ganglia described by v. Lenhossek, however, although we had at our disposal complete series of sections and these were carefully studied we were able to observe but one ganglionic formation.

In order to be reasonably assured of success it is advisable to use only fresh material and such as is in perfect condition; for the heads in which we found some inflammatory process in the orbital cavity, as a result of traumatic manipulation during the extraction of the venom from the respective glands, proved to be useless. We also found it advisable to change repeatedly the silver nitrate solution and to leave the preparations for about 10 to 15 days in the oven at 40°C. Even with the greatest care in many cases the impregnation is not successful or only partially so, as was the result in the great majority of our trials.

The histological data obtained by us up to the present time are in most respects in accordance with those obtained by v. Lenhossek.

All the cells are typically unipolar, there being absent protoplasmatic processes, the contour of the cells is even, as is the case, in other Reptiles and in Birds. On the other hand in the Chelonians there may exist protoplasmic prolongations, but they are few. We never observed any lobulation of the cells, as has been described in the ciliary ganglion of Chelonians by Pitzorno, said lobes not being characteristic and exclusive of the sympathetic ganglia of the Chelonians, but exist also in the cells of the spinal ganglia of these same animals. Neither did we observe in the cells of our specimens, the fenestrated cells nor the

cells with prolongations forming loops. The cells shape is generally spherical or pyriform, but many times specially in the regions of the ganglion where the cells are compactly arranged, these attain an elongated form.

Our preparations do not give distinct evidence of a neurofibrillar reticulum in the interior of the cell body, even after use of a number of the suggested variations of the Ramon y Cajal method; we have nevertheless observed an apparently homogeneous structure demonstrated by v. Lenhossek.

Each cell, no matter what its form, is enclosed in a very thin tissue capsule, which continues near the pole as a conic process.

Contrary to what has been stated by v. Lenhossek, the amphycytes nuclei are to be observed here and there.

The single axone process detaches itself from the cell body as a small cone, which with its place of origin is uniformly turned toward the oculomotor nerve. The neuraxis filament follows a retrograde root in a more or less proximal direction and then leaves the fiber of the third nerve forming with them various angles and then taking a distal direction goes to form the ciliary nerves.

Not rarely and specially in certain species, we could very frequently observe the origin of the neuraxis in the distal extremity of the cell, that is, in the opposed extremity to the habitual point of access or the oculomotor fibers to the ganglion cells.

The neuraxes of the ciliary ganglion cells may be easily distinguished from the afferent fibers of the ganglion, not only where these leave the nerve bundle, but also in the neighborhood of the cone of origin, by their smaller diameter and by reason of the fact that they take a paler tint than that taken by the afferent fibers.

The initial course of the ciliary fiber is essentially as described by v. Lenhossek, that is, coursing within the afferent fiber through the capsule cone. In the great majority of the cases, the ciliary fiber is parallel to the course of the oculomotor fiber, however, the ciliary fiber are observed in some instances to form wide spirals around the oculomotor fiber; the ciliary fiber also becomes very thin when it is in relation with the oculomotor fiber, but it enlarges abruptly as it recedes from it.

As was observed by v. Lenhossek in successful preparations, we observed between the even contour of the cell and the inner surface of the capsule, a fissure which cannot be interpreted as an artifact, but as being occupied by a thin syncytial stratum including the amphycyte nuclei of the pole and those for the remainder of the periphery of the ganglion cell, though the number of these latter may be scarce.

The afferent fibers of the ciliary ganglion are finer than those of the oculomotor nerve destined to the muscles; these fine fibers penetrate into the cone of the pericellular capsule, that is in the great majority of cases, at the same point from where the ciliary fibers have exit; the conic process is formed rather by the apposition of the capsule to the afferent and efferent fibers.

The afferent fibers, as a rule, divide within this conic prolongation, among the amphycyte nuclei in three or four very thin slightly contorted diverging branches, with few ramifications and, therefore, very rarely constituting a basket formation, which is very simple, when it exists, as has already been demonstrated by v. Lenhossek. Some of these ramifications end very quickly in the amphycyte cone, but others, which are much more numerous, pass on as far as the surface of the polar extremity of the cell, where they terminate as free endings.

The ramifications of the endocapsular fibers, by reason of their relatively straight course and their scarcity, are far from showing the very rich and elegant pericellular net, characteristic of the ciliary ganglion cells of the mammals.

The ending of the endocapsular fibers takes place immediately on the cell surface as thickening or small dilations; we had occasion to see repeatedly that these terminal expansions presented themselves as voluminous rounded or oval balls and generally placed between the cell and the capsule, or even in relation to the amphycytes cone.

Whereas the fine endings of the oculomotor fiber are immediately adjacent to the cellular body, the larger ramifications of the same afferent fibers run in the space between the cell and the capsule, that is, in the thin syncytial protoplasmic stratum to which we have already referred.

The majority of the details described by us are in essential very similar to those described by v. Lenhossek.

This present communication is to be regarded of the character of a preliminary note. Further details it is expected will be ascertained on completion of more extended investigations with more abundant material. It is then hoped to publish the more extensive data accompanied by the necessary figures.

## ON THE CARTILAGINOUS TISSUE OF THE HEART OF OPHIDIA

A. DE LEMOS TORRES

*From the Laboratorio de Anatomia e Histologia da Faculdade de Medicina e  
Cirurgia de São Paulo: Director, Prof. A. Bovero*

While stationed at the Laboratory of Histology of the São Paulo Medical School, we had the opportunity to apply to the hearts of Ophidia, the methods of elective staining and subsequent clearing of the cartilage, as proposed by Lundwall.

It was shown by the researches of Favaro<sup>1</sup> which had been in part published when we began our studies on the heart of Snakes, that there exists in the 'septum intermedium' of the *Tropidonotus natrix*, a small Ophidium which is not poisonous and very common in Europe, an accumulation of a vesicular connective tissue, known as mucous tissue, by Greil.

This was known with reference to the hearts of other reptiles. This tissue is composed of large, vesicular, polyhedral or irregularly rounded cells, among which is found a small amount of chondromucoid ground substance. This ground substance surrounds the cells, forming more or less complete septa, which make up as a whole a species of alveolar stroma.

The application of Lundwall's methods for the staining of cartilage (fixation with formalin or with alcohol, remaining in alcohol for more than 48 hours, staining with acid solution of methyl green, or of toluidine blue, discoloration with alcohol 95 per cent, dehydration, clearing with benzol), was suggested to us by Professor Bovero.

We had in mind when we applied this method to the hearts of some Ophidia, to verify the existence of cartilaginous tissue,

<sup>1</sup>Favaro, G. *Ricerche embriologiche e Anatomiche intorno al cuore dei vertebrati*. Parte prima 1913. Parte seconda 1914. Padova, Fratelli Drucker, Editori.

which had already been done for other reptiles, and to note especially if there was any modification of this cartilage so far as the size or the age of our Ophidia was concerned.

Thus, thanks to the kindness of Dr. Vital Brazil we had an opportunity to make these researches on the hearts of a great number of snakes, belonging to the following species: -*Lachesis Neuwiedii*, *Crotalus terrificus*, *Lachesis alternatus*, *Lachesis lanceolatus*, and, two more species of the *Oxirhopus* variety.

We obtained invariably the same result in all the hearts prepared by us according to Lundwall's method (we used always methyl green, Cogit), that is, at the basis of the ventricles corresponding to the 'Sulcus atrioventricularis' there is always a zone not very well marked at its periphery, which absorbs the colouring substance very readily, but the colour which is obtained is always much paler and less intense than the solution used.

This zone which appears as a green spot does not discolour, even after a prolonged lapse of time, but is only clearly evident after the clearing by benzol.

We did not observe any difference worth mentioning among the species of Ophidia which we used, we noted, however, that the larger the heart was in comparison with the size of animal, the more intense was the colouring, and the more distinct was the outlines of the coloured zone.

We made microscopical sections from several hearts, in order to demonstrate the exact position of the area which absorbs the methyl green, while the rest of the heart was discoloured. These sections were made in series perpendicularly to the axis of the heart.

A study of these serial sections enabled us to demonstrate that the zone thus coloured in green by Lundwall's methods corresponds exactly to the septum intermedium, therefore, was the vesicular connective tissue described by Greil and by Favaro in the *Tropidonotus natrix*. This tissue presented the characteristics described at the beginning of this article.

Such a form of connective vesicular tissue corresponds to one of the stages of ontogenic development of the cartilaginous tissue. We observed that the substance of the septa interposed

between the vesicular cells has a great resistance and is very refractive. This substance appears always basophile, although not intensely so, this basophilic characteristic explains to us the fact that we obtained a green colouring with Lundwall's method, elective for cartilage, so that this substance gave us the same reaction of the ground substance of the cartilage, but much less intense than if obtained by the same method applied, for instance, to hyaline cartilage.

We have thought these facts worthy of record, since this method gives a rapid macroscopic demonstration in the Ophidia of the existence of a particular form of cartilaginous tissue (Protocartilage, parenchymatous cartilage of Schäfer), the presence of which cartilage has only been demonstrable by microscopic examination (Greil and Favaro).

These experiments of ours, prove that this particular form of tissue with chondromucoid substance repeats in the phylogenesis the evolution of the cartilaginous tissue of the individual, for corresponding to the same point where we found this vesicular tissue, there exists in animals of a higher class of development a tissue which is typically cartilaginous.

We come therefore to the conclusion that Lundwall's method, which is eminently elective, demonstrates in the heart of Ophidia, as cited above, the existence of this primitive form of cartilaginous tissue in the thickness of the intermediary septum which is evident by way in which it absorbs the colouring substance.

It would be certainly very interesting to be able to continue with Lundwall's method or with such modifications as experiences has shown to be opportune (Bovero), in the various classes, orders, and species of vertebrates, perhaps even at various age of representative of the various types, the existence and distribution of the cartilaginous tissue of the heart. In this way the phylogenetic modifications of the various parts which represent or constitute the cartilaginous skeleton of the heart would be demonstrated.





## STAINING OF ADULT CARTILAGE BY LUNDWALL'S METHODS

J. MOREIRA DA ROCHA

*From Laboratories of Anatomy and Histology da Faculdade de Medicina e  
Cirurgia de São Paulo (Brazil); Director, Dr. A. Bovero*

In the Anatomical Section of the Primeiro Congresso Medico Paulista (December 5, 1916), I had the opportunity to present a series of excellent preparations from various organs of the body possessing cartilaginous skeleton, which were obtained by methods based upon the chromatic electivity of the cartilage and the clearing of the preparations.

In the same month of December, G. Noback (*Anatomical Record*, vol 11, no. 5, 1916), called attention to the excellent results which may be obtained in the embryonal cartilage, by the method proposed by Van Wijhe, which according to the author is very little known.

As we employed in the execution of our preparations of the adult cartilaginous skeleton, only the methods proposed by Lundwall (*Anat. Anz.*, vol. 25, 1904; vol. 27, 1905; vol. 40, 1912) for the study of embryonal cartilage, we think that, specially after the appearance of Noback's note, it will be timely to give some considerations to this subject.

In 1914, Professor Bovero had the occasion to present to the Sociedade de Medicina e Cirurgia de Sao Paulo, a great number of preparations of the cartilage of the plica semilunaris oculi (third eyelid) of man and other mammals, obtained with the methylgreen staining method proposed by Lundwall ('05) for the embryonal cartilage, having at that time called attention to the fact that the preparations were not only elegant and demonstrable but also permanent.

Such preparations are unstable only when prepared of embryonal cartilage, it being noticed that their degree of stability is in the direct ratio of the degree of maturity of the cartilaginous tissue.

Following such steps in the laboratory, directed by Professor Bovero, we undertook to prepare a series of cartilaginous skeletons of the larynx, trachea and bronchi, of man and other vertebrate animals and of the cartilages of the nasal alae and septum; of the fibrous cartilage of the temporo-mandibular and sterno-clavicular joints; of the semilunar cartilages of the knee and of the calcaneous-astragalus-scapoid joints; and of the cartilage of the auricle, all from man, but from different races and ages.

Some of the preparations were obtained by the methods proposed by Lundwall for the staining of cartilage alone and others were obtained by such modifications of the method as experience showed us to be of advantage.

The first method proposed by Lundwall, very well known nowadays, which may be found in almost every text-book of histological technique (Ehrlich, Mosse and Krause, '10; Carazzi and Levi, '11, et cetera), as also in some special memories (Brüni, '08), is based specially upon the staining with a 1 to 1000 solution of methylgreen in 70 per cent alcohol (lately the methylgreen has been substituted by toluidinblue) to which has been added a 7 to 1000 solution of acetic acid, with subsequent washing in 95 per cent alcohol until the preparation does not lose any more stain; dehydration by absolute alcohol; clearing by benzol changed many times; and finally conservation in a mixture of benzol, carbon sulphide and essence of peppermint. The changes made by Professor Bovero in this method, does not alter in any way the fundamental features of the method as devised by Lundwall, but they are to a certain point an incorporation in Lundwall's methods of analogous methods proposed by Bakay and by Van Wijhe.

We observed many times the fact, that the methylgreen obtained from different sources or even that obtained from the same source but at different times, does not react the same in the presence of the ground substance of the cartilage, specially in regard to the electivity of the staining and also as regards its stability. The causes of such variations in the action of the methylgreen, may be found in the fact that it is not a single stable compound, but a mixture of staining substances, and in fact that the different kinds of methylgreen employed by us, and with which we had negative or unsatisfactory results, had suffered some chemical decomposition.

Having always in mind the idea of the basophilic character of the ground substance of the cartilage, we used, besides the methylgreen, other substances such as toluidin blue, methylenblue, methylviolet and safranine. In some instances, we substituted the acetic acid by hydrochloric acid. The duration of the staining was largely modified as was also the temperature at which it took place, this, according to the size of the preparations and according to the varieties of cartilage that we tried to show. We used the benzol in very much less quantity than that advised by Lundwall, not only as a matter of economy but also because it was quite difficult to obtain this reagent here of the necessary purity. Thus, three, four or even more preparations were passed successively through the same amount of benzol. For this reason, it was necessary to leave the preparations immersed for a longer time in the benzol, to compensate for the less frequent change of the reagent.

We may say, as a general rule, that no matter which staining substance is used, its electivity for staining and its stability are in the direct ratio, as we have already said, not only to the maturity of the amorphous ground substance of cartilage, but also, what may be readily understood, to the quantity of the ground substance.

Therefore, we may establish *a priori*, that not only the adult, cartilage is stainable with greater chromatic affinity and also with greater stability than the embryonal cartilage, but that among the different

varieties of adult cartilages, the hyaline variety will take the staining with greater electivity and with greater stability than the elastic and fibrous varieties, and this is readily verified in practice.

What we have endeavored to explain may be readily demonstrated by the simple test of the way in which the cartilage of the larynx and trachea behaves as against that of the knee and of the auricle.

Bearing closely to what we have said, we may add that it is necessary to watch with greater attention the decoloration of the elastic and fibrous cartilages, whereas it is not necessary to use such care as regards the hyaline cartilage.

Another advice may be given in regard to the embryonal and foetal cartilages, that is, that the conditions being the same, the staining with methylenblue or methylviolet, or with the toluidin blue is much more stable than with the methylgreen.

By the examination of our preparations we may conclude that such methods to demonstrate the cartilaginous tissue, always give constant and sure results and explain the possibility of a coming revision of full chapters of Anatomy dealing with the morphology of certain and determined cartilaginous organs, which were previously studied by the dissecting and macerating methods, followed by the desiccation of the cartilaginous pieces.

Our assertion seems to be perfectly justifiable in as much as none of these methods are as satisfactory to the one in which the cartilage is stained.

The revision of the morphology of the cartilaginous organs may give very good results, not only in regard to the larger hyaline cartilages (larynx, trachea, bronchi, nasal septum, etcetera,) but also as regards the study of the extension and topography of the amorphous ground substance in the fibrous cartilages, for example. We believe as regards this point of view that with the methods employed by us, combined with the methods for histologic research, interesting and new results may be obtained. Certainly, the free use of the methods of staining of the cartilaginous pieces in toto and their demonstration through the soft tissues promises to give many good results in any systematic studies which may be undertaken. On some of these, we expect to contribute very soon with personal and especial researches which we will develop during this year.



## ON THE DEVELOPMENT OF THE LYMPHATICS IN THE HEART OF THE EMBRYO PIG

JAMES R. CASH

*Anatomical Laboratory of the Johns Hopkins University*

This problem was approached by way of embryology primarily, because extensive lymphatic injections, in the adult heart, are impossible due to numerous valves in the lymphatic vessels. In embryos under 60 mm. in length the valves have not formed and retrograde injection of the cardiac lymphatics is quite possible under the proper conditions. Also by observing the origin of the vessels in younger embryos and several further stages in their development it appears evident that observations made on the adult heart can be more rationally interpreted and the solution of the problem will be much nearer complete than if conclusions were drawn from the adult specimens alone.

The literature on the nature of the lymphatics of the heart is very scanty. The most pretentious and generally accepted work being that of H. Boek of Munich.

Ranvier ('95) comes to the conclusion that there is considerable free space in the myocardium (that is, space between the muscle cells and blood vessels) and that this space is lymphatic in nature. This assumption is based on the fact that pericardial lymphatics can be injected by plunging the needle at random into the myocardium at any point. Thus the intercellular spaces and the lymphatics were supposed to be in direct connection. So the entire heart is considered to be a 'lymphatic sponge,' as Ranvier expressed it.

Salvioli injected Berlin blue into the myocardium and made out what he thought were lymphatic vessels which ran in the connective tissue septa between the muscle bundles but he could find no evidence of their connection with the intercellular spaces as advocated by Ranvier.

Albrecht ('87) in his work on the heart muscle, made an apparently very painstaking investigation of the subject. He injected the living heart, thus using its natural movement to distribute the injection mass. He came to the conclusion that the large lymphatic trunks lay in the spaces between the muscle cells. These large trunks he thought, were connected by straight lymphatic vessels of smaller size, which run at about right angles to the long diameter of the heart muscle cells and arrange themselves into a capillary network in the interior of the adjoining muscle bundle. The lymphatic vessels were observed to be straight and were differentiated from blood vessels which exhibit multiple and acute branching, and by the observation that blood vessels ran parallel to the long diameter of the muscle cells. Within the muscle bundle the lymphatic capillary network includes a muscle cell within each of its meshes. Albrecht made the further observation that the intercellular spaces which contain the large lymphatic trunks were not entirely filled by them, but that the lymphatic vessels lying in these spaces had their own walls, and that when injected, they could be seen lying over to one side of the space which was apparently empty. These spaces observed by Albrecht, were probably artefacts due to shrinkage of the tissue. Thus Albrecht concluded that an intercellular lymphatic capillary network existed with its own walls, and that it was in connection with the great interfascicular vessels which lay in the large spaces in the heart muscle (Henle spaces).

Bock ('05) criticized these statements of Albrecht severely. He points out very truly that in the previous work, the great discrepancy in reports lay in mistaking blood vessels for lymphatics. He attempted solution of the problem by making injections of both blood vessels and lymphatics in the same heart with different colored injection masses. The heart was placed in physiological salt solution and heated to body temperature, then kneaded thoroughly by hand to expel as much blood as possible. Cannulas were placed in the coronary arteries and carmine gelatine injected under pressure, thus filling the blood vessels with red. Berlin blue was then introduced quite forcibly into the myocardium near the apex, by puncture with a hypodermic

needle. The lymphatics of that area were thus supposedly injected, the blood vessels being already full of gelatine. The relations of the two systems of vessels should thus be demonstrated. The injected areas were cut out and sectioned. From their examination Bock reached the following conclusions:

1) Das Lymphgefässnetz stellt ein wandhaltiges intermuskular verlaufendes Rohrsystem dar, genau wie die Blutkapillar Gefässsystem, nur noch vielgestaltiger und reichhaltiger.

2) Jede Muskelzelle hat ein Lymphkapillargefäss vielfach auch deren zwei und ein Blutkapillargefäss.

3) Lymph- und Blutkapillaren liegen meist dicht neben einander.

4) Lymphkapillaren verlaufen wie die Blutkapillaren parallel den Muskelzellen und ist die Muskelfibrille häufig von einer Anastomose zur langsverlaufenden Lymphkapillaren umspannt.

5) Die Lymphkapillaren sammeln sich in grossen Lymphbahnen.

6) Eine wirkliche Kommunikation mit spalten zwischen Muskeln konnte nirgends nachgewiesen werden.

7) Die Muskelzellen liegen in normalen Herzen ohne Spalten dicht nebeneinander und lassen nur Raum für die Lymph- und Blutkapillaren frei.

8) Spalten zwischen Muskelzellen sind pathologische und stets mit Bindegewebe ausgefüllt.

Thus Bock is of the opinion that the lymphatics of the heart, though following closely the pattern of the blood vessels, are much more numerous.

The most satisfactory method of approach to these problems in the study of lymphatics is through their embryology. The lymphatic vessels under study are thus followed through several stages of embryonic life.

Such was the method of procedure in this work, and it is offered as an addition to the series of embryological studies of lymphatics which have come from this laboratory. Embryo pigs of three stages were injected. At that time injections were made of both blood vessels and lymphatics of adult pigs' hearts.

#### MATERIAL

Pregnant uteri, recently removed from the body, were obtained from an abattoir near the laboratory. The hearts of the embryos were still beating regularly when the injections were made.

The embryos were approximately of three stages: 1) 25 to 35 mm. in length, showing the downgrowth of the right and left lymphatic ducts, both of which may be seen giving off branches to the trachea and lungs. Also the right duct may be seen sending off a branch to the heart forming a superficial plexus on its surface. 2) Embryos, 35 to 45 mm. in length, showing the formation of the aortic and tracheal plexuses by the right and left ducts. The tracheal plexus may be seen giving off a rather large branch to the heart which is joined near its origin by the cardiac vessel, seen in the earlier stage coming from the right lymphatic duct. 3) Embryos, 45 to 65 mm. in length, showing far greater richness of the lymphatic plexuses. The superficial cardiac plexus, seen in even the earliest injections, has increased greatly in area and its meshes are much smaller. The union of the two vessels from the right duct and the tracheal plexus is very well shown in embryos of this age. Embryos of greater length than 65 mm. could not be injected, due to formation of numerous valves and nodes along the course of the lymphatic vessels which prevents the injection from flowing.

#### METHODS

The embryos were injected with either a saturated aqueous solution of Berlin blue or India ink. Number 28 hypodermic needles in an ordinary hypodermic syringe were used for injecting.

Injection was made from four sites. In the smallest embryos, the needle was introduced into the right jugular sac. By this method the right duct, passing down the right anterior cardinal vein and giving off a branch to the heart, was filled. In the other specimens (45 to 65 mm.), the tracheal plexus, giving off the cardiac vessel, and the tributary from the right duct were injected by introducing the needle into the region just dorsal to the superior vena cava, which has formed at this age. (Cunningham, 16, Figs. 1-2.) Most of the injections of these older embryos were made by placing the needle directly into the thoracic duct just above the diaphragm. The entire left side of the body wall of the embryo was hurriedly dissected away and the needle quickly



placed into the thoracic duct, which may be accurately located just between the azygos veins and the aorta. When injecting, the pressure must be sudden and rather powerful. Even when the needle is properly placed in the duct and the pressure properly applied, very few embryos show heart lymphatics. This is quite different from the case of most lymphatics of the body which fill readily, once the injection mass has free access to them. There have been several instances when the thoracic duct has ruptured under pressure without filling the cardiac lymphatics. The explanation of this lies in a mechanical consideration of the origin of the cardiac vessels. The ready filling of the intestinal and mesenteric lymphatics upon injection into the retroperitoneal sac is evidently due to the numerous and large branches of origin and the rich anastomosis on the vessels springing from them: if one pathway is blocked, the injection can go by another route. Then, too, in this location, the point of injection where the pressure is applied is near the vessels to be filled. The situation of the heart is entirely different. The thoracic duct reaches the openings of the tracheal plexus, a very dense and complex mass of vessels. From this plexus only one vessel goes to the heart, and this is the vessel that must be filled before the cardiac lymphatics can be injected from the thoracic duct. The tracheal plexus must be completely injected before the cardiac branch will fill. Injections of the heart are by no means assured even when the proper technique is carried out in making them. This is due, in great part, to the fact that the thoracic duct opens into the veins. Thus, back pressure is reduced, which accordingly greatly lessens the chances of complete retrograde injection of the tracheal plexus from so low a region of the thoracic duct. Such difficulty was eliminated, to a great extent, by placing a clamp around the great vessels at the base of the heart just before injection. So, too, in this way ink was prevented from entering the right chambers of the heart by way of the veins, as it inevitably did in specimens injected without the clamp and so prevented the clearing of the heart for study. Injections were also made into the retroperitoneal sac, and, though filling the lymphatics of the lungs, diaphragm, stomach and intestines very well, all failed to fill any of the car-

diac vessels, the sac either rupturing under pressure or the injection entering the veins. Immediately after injection the specimens were hardened and bleached in Carnoy's fixing fluid. They were then transferred to 70 per cent alcohol and carried up the alcohols to absolute by 5 per cent changes and cleared by the Spalteholz method.

The gross specimens were prepared by approximately the same method used by Bock. Instead of kneading the hearts by hand to expel the blood, they were perfused through the coronary arteries with Locke's solution. It was found that freshly filled hearts could be revived to contraction in this way and that more blood was expelled by their own movement than could be squeezed out by hand. During the perfusion, the heart was suspended in physiological saline heated to 37°C. After a few minutes' perfusion, Locke's solution was replaced by a saturated solution of Berlin blue which was forced through the coronaries at 40 mm. Hg. pressure. Punctures were then made at various points into the myocardium with a hypodermic syringe, injecting India ink into the muscle in the effort to fill the neighboring lymphatics. No matter how carefully this procedure was carried out, much of the ink flowed into blood vessels and the lymphatics injected at the same time could only be distinguished by their morphological characteristics; the color of the injected vessels counting for very little in their identification.

It can readily be seen that this is a very crude method of injecting cardiac lymphatics; however, it is the only one available since retrograde injection, through one of the large lymphatic vessels, lying just under the visceral pericardium, is impractical. This is due to the stoppage of the injection mass by the numerous valves in the cardiac vessels which begin to form at about 60 mm. By injections into the myocardium at random, it is evident that it is only by chance that lymphatic vessels will be struck, and when once entered there is no reason to think that all the lymphatics of a given area will be filled. So, final conclusions should not be drawn from specimens so injected without substantiating the pictures seen in them by further investigation. In the attempt to obtain such evidence the following experiment was performed:—

The left thoracic cavity of a cat was entered and several ribs just above the diaphragm resected. The parietal pericardium was split and several drops of ink injected into the myocardium of the beating heart. The ink that entered the blood vessels was quickly washed through them into the general circulation. Part of the ink could be seen to enter the pericardial lymphatics immediately, but a good part of it remained as a circumscribed mass in the myocardium. The heart was allowed to beat from two to three hours in order that some of the ink might be absorbed by surrounding lymphatics. By this method no blood vessels were filled with which to confuse lymphatic vessels. The animal was then killed and strips of heart muscle in the regions of the injected drops of ink were fixed in 10 per cent formalin, cut in paraffin sections, stained in alum carmine for microscopic examination. One hundred mg. of luminal sodium was used as an anesthetic and found to depress the cardio-respiratory centers very little. Since one lung was collapsed, artificial respiration was given throughout the entire experiment by Quinby's method of intra-tracheal insufflation ('09) at about 10 mm. Hg. pressure. The animal's body temperature was maintained by placing the entire preparation in an asbestos lined box heated to 37 C. It was found that several drops of ink could be placed into the myocardium at various points without embarrassment of the heart's action.

This work was begun at the suggestion of Dr. R. S. Cunningham of this laboratory. I wish to thank him for the great assistance he has been to me.

#### EMBRYOLOGY

The lymphatics of the heart are found to arise from two sources: (1) the right lymphatic duct, which, in addition, gives rise to a lung vessel; (2) the tracheal plexus, which also sends vessels to the lungs.

The thoracic duct is formed by the union of vessels growing down from the left jugular sac and another plexus of vessels which bud off from the median mesonephritic vein, Baetjer ('08). The duct is shown to be a complete plexiform structure

in embryo pigs, 25 mm. long (Sabin '13, Baetjer '08, Kampmeier '12).

The development of the tracheal plexus has been carefully studied and described by Cunningham in his work on lung lymphatics ('16) from which I quote the following:

About midway between the jugular anastomosis and the arch of the aorta, the thoracic duct leaves its position lateral to the trachea and bends downward to lie near the dorso-lateral border of the esophagus. In this position it comes down just behind the arch of the aorta. This transition is shown by Sabin (1913, figs. 12-13). Just as the duct begins to bend dorsally the earliest sprout to the lung is formed. At this point a single large vessel buds off from the thoracic duct and passes down over the arch of the aorta to the hilum of the lung. This vessel usually persists in the adult as one of the drainage trunks from the hilac nodes to the thoracic duct. From the region of the thoracic duct, where this vessel buds off to a point about the level of the aortic arch, a number of other vessels are formed very soon afterwards. These vessels arise very close together and grow across to the lateral wall of the trachea where they anastomose and form the primitive left tracheal plexus. They lie in the undifferentiated mesenchymal tissue that surrounds the tracheal lumen. These lymphatics have formed a plexus by the time the embryo has reached a length of 30 mm. From this plexus vessels grow across the trachea to anastomose with other vessels from the similar plexus on the opposite side; other lymphatics grow up the trachea and form a coarse meshed plexus around it. This is the anlage of the adult supply of that structure. But the most important of the branches of this plexus, as far as the present work is concerned, are those from the lower part. These pass down the trachea, and, being joined by other vessels that leave the duct near the arch, pass up over the bifurcation into the lung.

The primary lymphatics to the heart are evidently those coming from the right lymphatics duct. Sabin (*Origin and Development of the Lymphatic System*, '13) states: "The right lymphatic duct curves ventralward and grows to the heart and lungs." Figure 13 of that work shows the right duct just anterior to the heart and located dorso-laterally to the trachea in a 25 mm. pig embryo. Heuer ('09) (figs. 4 to 7) pictures a vessel from the thoracic duct which has every appearance of going to the heart. Though apparently leading to the heart, this vessel has never been seen to actually reach it; always entering the aortic plexus. It has been very constant in all the injections, but has never been seen in any way to connect with the cardiac lymphatics.

The right lymphatic duct arises from the right jugular sac and runs posteriorly, following the right anterior cardinal vein dorsally. At the level of the right duct of Cuvier it divides into two branches, one going into the hilum of the lung and the other passing ventrally between the trachea and right duct of Cuvier behind the aortic arch and the pulmonary artery to reach the anterior aspect of the heart, just to the left of the conus arteriosus. Injections of 40 mm. embryos show a large vessel branching from the tracheal plexus at the base of the heart and turning ventrally near where the vessel from the right duct bends down. These two immediately anastomose by a single vessel and are seen to run closely parallel to each other. The branch from the right duct is evidently primary, preceding the branch from the tracheal plexus, which soon afterwards appears and follows its course to assist in the formation of the cardiac plexus. In some of the specimens, these two cardiac branches appeared almost as a single vessel from their point of anastomosis. The vessel to the heart from the right duct, together with the branch to the lungs, forms the early broncho-mediastinal trunk, the main pathway of cardiac drainage in the adult. However, they do not remain as two single vessels, but become plexiform in nature, receiving the drainage of the bronchial, anterior and posterior mediastinal, and sternal glands. The two small cardiac vessels, in the embryo, pass anteriorly under the pulmonary artery, lying between it and the left auricle, to the auriculo-ventricular groove about .5 mm. from the root of the pulmonary artery. Here, on the anterior surface of the heart, they form a primary plexus which gives rise to two main branches which in turn branch to form the pericardial plexus. One main branch passes to the left around the base of the left ventricle, following the auriculo-ventricular groove, to the posterior interventricular septum, down which it sends a branch. The other branch of the primary plexus passes around the base of the right ventricle and gives off a large branch, almost equal to itself in size, down the anterior interventricular septum, then passing around to the dorsal view of the heart, anastomoses with the left branch. Thus it is evident that the lymphatic invasion of the heart takes place

along the larger blood vessels, as is characteristic of all lymphatic development. The main vessels passing around the ventricular bases and down the interventricular septa give off numerous anastomosing branches along their course, in this way forming the pericardial plexus. This plexus lies in the submesothelial connective tissue just under the visceral pericardium. I do not feel that any of the injections of this plexus have been complete; however, at 40 mm., the vessels passing down the interventricular septa have been filled almost to the apex and the pericardial plexus extending over at least one-half the surface area has been injected. At 60 mm. the meshes of this plexus are much finer and more of the heart is covered. Whether injection is made through the right duct or the tracheal plexus there are only two vessels by which the heart lymphatics may be filled, so that, mechanically, it is very difficult to obtain good injections. In the cleared specimens of the 60 mm. stage, no lymphatic vessels could be seen extending down into the myocardium, but along the larger vessels of the pericardial plexus short lymphatic buds are visible, starting down into the heart muscle. At this stage none of the pericardial lymphatics can be filled by injecting into the myocardium, as is so readily done in the adult heart. This experiment has been tried on hearts from pigs varying in size from 60 to 150 mm., and none of them show myocardial vessels to any great extent. Even in the 150 mm. embryos any of the surface lymphatics are only occasionally filled by injecting into the myocardium. Therefore, it appears that the pericardial plexus is formed almost completely before invasion of the myocardium takes place. Such inference seems logical, for it is evidently easier for the lymphatic growth to take place in the loose connective tissue under the visceral pericardium than to invade the heart muscle itself.

#### THE ADULT HEART

Gross inspection of the adult heart reveals numerous lymphatics on its surface just under the visceral pericardium. They are slender vessels of uniform size and form frequent anastomoses. Their course may be nearly straight or zig-zag. There is a

large lymphatic vessel running down each side of the heart over the ventricular septum, and this receives a good many tributaries. The other surface lymphatics eventually drain into the large vessels along the auriculo-ventricular groove. The meshes of the pericardial plexus are much larger, relatively, than those of the 60 mm. embryo, at which time the plexus is approximately densest. As the heart increases in size the lymphatics are stretched out, so to speak, to cover it, the plexus thus becoming less dense.

If a needle is plunged at random into the myocardium, some of the surface lymphatics can generally be filled. If a section is made of the ventricular wall and injection made from the cut edge near the pericardium, numerous surface lymphatics are always filled. If injection is made at a lower level, say about half the thickness of the ventricle, surface lymphatics will generally be filled, but they are not so numerous as when injection is made nearer the surface. If injections are made at over two-thirds the distance from pericardium to endocardium, only occasionally will surface lymphatics be filled. Injections made just under the endocardium never fill pericardial lymphatics, and in no case was an endocardial plexus of lymphatics found. In several places the His bundle was entered, and I think that positive statements in regard to an endocardial lymphatic plexus are based upon injections of this system which have been mistaken for lymphatics.

These observations indicate that there is a myocardial plexus draining into the pericardial plexus; and it appears that the vessels of the myocardial plexus become smaller and less numerous as they extend into the heart muscle. The relative difficulty of injecting them at different levels in the myocardium certainly calls for such an explanation.

The method of preparation of the adult cleared specimens in which both lymphatics and blood vessels were injected, has already been discussed. By cutting free hand sections about 2 mm. in thickness from the injected regions, small areas can easily be found where blood vessels and lymphatics were both injected. The lymphatics are seen to follow the larger blood vessels, but

not as single accompanying vessels as described by Boek. In the areas where the injections seem most complete, each of the larger blood vessels was seen to be surrounded by a scanty lymphatic plexus. The vessels making up these plexuses are all about the same size, and have comparatively few branches in comparison to the blood vessels. These lymphatics surrounding the larger blood vessels are connected by smaller vessels which complete the myocardial plexus. In many instances, these smaller lymphatics follow blood vessels, and, in others, can be seen to follow the connective tissue between the layers of the heart muscle. In no case were the lymphatic vessels seen to form a true capillary plexus which followed the blood capillaries, as has been described. The lymphatics anastomose freely while the blood vessels, as is well-known, form few or no anastomoses. All the injected specimens give the impression that the patterns of the blood vessels and lymphatics differ very much; the lymphatics never forming a capillary bed, but a well-woven plexus of vessels, of which the smallest are larger than capillaries. The lymphatic vessels become fewer and smaller as they extend deeper into the myocardium, their number being exceedingly small near the endocardium. The largest lymphatics are only about one-fourth as large as the blood vessels they accompany, and the smallest ones are about the size of venules so that it is evident the cardiac lymphatics are more constant in size than are the blood vessels.

These observations are supported by the injection of living cats' hearts. Pericardial lymphatics were immediately filled in all cases when puncture was made, and myocardial vessels draining into them were seen in the sections. None of these myocardial lymphatics were seen to be as small as capillaries and their number was scanty. Absorption of the ink does not take place readily. This indicates the scarcity of lymphatic vessels in the myocardium, since India ink is readily absorbed by the lymphatics in those places where the vessels are abundant. Such slow absorption by the heart lymphatics would certainly not take place if their number did not justify it. In no case did any lymphatic vessels appear on the endocardium, which would have been most likely had they been present.



Most of the observers (to whom I have already referred) have doubtless seen both pericardial and myocardial lymphatics, but have been altogether too sweeping in drawing conclusions. Most of these vessels they have described have evidently been blood vessels. Most of Bock's illustrations of lymphatics are perfect pictures of blood vessels, while none of them resemble lymphatics. By this method, it is impossible to get complete injections of the blood vessels of the heart, and it appears that he has only described blood vessels injected with different colors. This point can be easily proven by observing a piece of heart muscle in which only blood vessels have been injected. In the double injections of the heart, many times the blood capillaries of an area will not be filled. When lymphatics of the same area are injected by puncture, some of the injection mass flows over into the unfilled blood capillaries, thus making a very misleading picture, large lymphatics and blood capillaries apparently belonging to the same system of vessels. Similar specimens probably have been the basis for statements to the effect that the lymphatics of the heart form a capillary plexus accompanying that of the blood vessels, but exceeding the blood plexus in density.

#### SUMMARY

1. The lymphatics of the heart arise from two sources: a) the right lymphatic duct; b) the tracheal plexus. Both these paths remain as ways of drainage in the adult, the branch from the right duct being the anlage for the bronchomediastinal trunk.

2. There is first formed a pericardial plexus covering the entire heart. This plexus reaches its greatest density at about 60 mm. and becomes less dense as the heart increases in size.

3. From the injections it appears that after the pericardial plexus is approximately complete, vessels arising from it invade the heart muscle, and, by forming numerous anastomoses, growing to great extent along the veins, form the myocardial plexus. This invasion of the myocardium takes place rather late, at 150 mm., there being relatively few myocardial lymph vessels demonstrable.

4. The myocardial plexus becomes less dense as deeper points of the myocardium are reached.

5. The larger blood vessels of the heart are accompanied by a plexus which are connected with plexuses around other large blood vessels by numerous anastomosing smaller lymphatics. These smaller lymphatic plexus composed of the largest lymphatic vessels compose most of the myocardial plexus.

6. Cardiac lymphatics, in like manner to all other lymphatics, develop along the blood vessels.

7. Claims for an endocardial lymphatic plexus are evidently founded on partial injections of the His bundle.

8. The pattern of the lymphatics does not correspond to that of the blood vessels nor are the lymphatic vessels so numerous as has been supposed.

It is intended that this description of cardiac lymphatics will be included in a more extensive discussion of lymphatics which will appear later and will include illustrations of all the specimens mentioned in this work.

#### LITERATURE CITED

- ALBRECHT, E. 1887 Greifswald, J. Abel.  
 BAETJER, W. A. 1908 *Am. Jour. Anat.*, vol. 8.  
 BOCK, H. 1905 *Anat. Anz.*  
 BUDGE, A. 1880 *Arch. u. Phys. Anat. Abth.*  
 CLARK, E. R. 1909 *Anat. Rec.*, vol. 3.  
 CUNNINGHAM, R. S. 1916 *Contributions to Embryology*, vol. 4, No. 12, Carnegie Institution of Washington.  
 HEUER, G. 1909 *Am. Jour. Anat.*, vol. 9.  
 HUNTINGTON, G. S. AND C. F. W. McCLURE 1906-1908-1910 *Anat. Rec.*, vol. 1, *Anat. Rec.* vol. 2, *Am. Jour. Anat.*, vol. 10.  
 KAMPMEIER, O. F. 1912 *Am. Jour. Anat.*, vol. 12.  
 QUINBY 1909 *Johns Hopkins Bulletin.*  
 RANVIER, L. 1895 *C. R. Ac. des. sc.*, vol. 121, p. 1105.  
 SABIN, F. R. 1913 *Johns Hopkins Hospital Reports, Monograph—New Series*, vol. 5.

# ON THE RELATION OF THE HEAD CHORDA TO THE PHARYNGEAL EPITHELIUM IN THE PIG EM- BRYO: A CONTRIBUTION TO THE DEVELOP- MENT OF THE BURSA PHARYNGEA AND THE TONSILLA PHARYNGEA

RUTH RAND

*Department of Histology and Embryology, Cornell University, Ithaca, N. Y.*

TEN FIGURES

## CONTENTS

Introduction.....	165
Historical.....	166
Material and methods.....	169
Description of typical stages.....	170
Discussion.....	179
Conclusions.....	189
Literature cited.....	191

## INTRODUCTION

The following study<sup>1</sup> arose from an investigation of the development of the pharyngeal tonsil. As is well known, the pharyngeal tonsil in man has been found by several observers to be in close anatomical association with a small blind pocket in the roof of the nasal pharynx, known as the bursa pharyngea or the recessus medius pharyngis. In order to discover if possible the nature and significance of the relation between the pharyngeal tonsil and the bursa pharyngea, it was decided to study the origin and development of each structure separately. The study of the development of the bursa pharyngea was undertaken first, since it is present in the embryo before the appearance of the tonsil.

<sup>1</sup> The study was undertaken at the suggestion of Dr. B. F. Kingsbury. The writer takes great pleasure in acknowledging the courtesy of the laboratory, and in expressing her appreciation of the very generous help of Dr. Kingsbury.

A number of investigators of recent years have been interested in the definite relations existing during embryonic life between the chorda dorsalis and the epithelium of the pharynx. Many indeed have noted actual contacts between the notochord and pharyngeal entoderm and have regarded such contacts as factors in the origin of the bursa pharyngea. In a paper dealing with the condition as found in the human embryo, Huber ('12) states that of the mammalian embryos, aside from those of man, which are ordinarily available for laboratory use, only the pig shows notochordal contacts with the epithelium of the pharynx, and in the pig there is present a pharyngeal pocket which has been considered homologous to the bursa pharyngea of man. A study of the relations of the head chorda of this animal was therefore undertaken with the hope of throwing still further light on the relation of these notochordal contacts to the genesis of the bursa pharyngea.

#### HISTORICAL

A brief historical sketch will be given to outline the general views regarding the origin of the bursa pharyngea. For a complete review of the early literature on the subject the reader is referred to both Killian ('88) and Oppel ('00). Reference may also be made to Huber ('12) for the more recent work on the subject.

The bursa pharyngea was first described and named by F. J. C. Mayer ('42), who, according to Oppel, found it present in many mammals including the pig. Luschka ('68) was the first to study the genesis of the structure. On the basis of an examination of a human monstrosity, this observer believed that the bursa pharyngea is a remnant of the primitive union of the mouth cavity with the hypophyseal anlage. Luschka held that the pharyngeal pocket of the pig is not homologous to the bursa pharyngea of man (cf. subseq. discussion). The observations of Ganghoffner ('79) and Schwabaeh ('87) did not confirm the view of Luschka. These investigators could regard the pocket merely as a part of the pharyngeal tonsil, being a medial depression of

the mucous membrane of the pharynx at the junction of the medial with the lateral furrows of the tonsil.

Froriep ('82) studied the development of the head chorda in six human embryos, noting especially notochordal contacts with the pharyngeal epithelium. In one of these a bursa pharyngea was present, the base of which was in close relation with an accumulation of chordal cells which had penetrated through a hole in the chordal sheath. Froriep could not positively state, but was strongly inclined to the opinion that the strain exerted by the notochord upon the epithelium of the pharynx mechanically gives rise to the bursa pharyngea. Killian ('88) made a careful study of the bursa pharyngea, basing his observations on 65 embryos ranging in age from 3 to 8 months. 42 of these presented a bursa pharyngea. According to Killian, the bursa pharyngea is a structure *sui generis*, developing always in a definite region just in front of the uppermost fibres of the constrictor pharyngis superior in close relation with the 'fibrocartilago basilaris.' Killian criticised Froriep for overlooking the invariable position of the bursa. Froriep himself had shown that many accumulations of chordal cells come in contact with the pharyngeal epithelium. On Froriep's theory, the definite location of the bursa cannot be explained, since any one of these retropharyngeal unions could logically give rise to the structure. Killian extended his studies among many of the higher vertebrates including the pig, and concluded that the *aretomys marmota* alone has a structure comparable to the bursa pharyngea of man.

Since Killian, a number of investigators interested in the development of the head of the human embryo, have noted notochordal contacts with the pharyngeal epithelium. Among these may be mentioned Guiseppe Levi, Williams, and Mrs. Gage. Mrs. Gage ('06) found that in other vertebrates examined by her the notochord, after the very early stages, is completely separated off from the pharynx, with the exception of the pig embryos, about 20 per cent of which showed notochordal contacts with the mouth similar to those of man. Mead ('09) also noted con-

tacts between the notochord and pharyngeal epithelium in the pig embryo.

It was not however until recently that Froriep's conception of a causal relation between notochordal contact and the origin of the bursa pharyngea was revived. R. Meyer ('10), basing his observations on a study of human embryos 2.5 to 40 mm. in length, concluded that the bursa pharyngea arises from the persistence of the original connection between the notochord and pharyngeal epithelium. From the fact that Froriep had noted a connection between the anterior end of the notochord and Sessel's pocket in chick embryos, and that Staderini had observed the same for rabbit and sheep embryos, Meyer was led to believe that the bursa pharyngea is identical with Sessel's pocket. A. Linck ('10) became interested in the early relations of the head chorda to the pharyngeal epithelium through a remarkable case of a tumor of the epithelium of the nasal pharynx which apparently involved notochordal tissue. Of the 16 human embryos examined, ranging from 2 to 25 cm. in length, 9 presented a bursa pharyngea. Although actual contacts between the notochord and bursa pharyngea were not observed, still the apex of the bursa in one case showed a more or less close relation with certain chordal remains in the retropharyngeal connective tissue. Linck believed that the appearance of the bursa may be explained partly through the tension exerted by the notochord on the pharyngeal epithelium, and partly through the active invagination of the pharyngeal mucosa itself.

Huber's study of the origin of the bursa pharyngea, based on the examination of a series of human embryos ranging from 5 to 145 mm. in length, is the most complete that has yet been done on the subject. The early embryos (5 to 8 mm.), at the time when the notochord is separating off from the pharyngeal entoderm, show the notochord maintaining a close contact with the epithelium of the pharynx. This point of contact is at the base of the ventral flexure of the notochord as it bends ventrad on passing into the cranial region, at a level just caudal to that of the thyroglossal pit in the tongue. If there is more than one point of contact between the notochord and the pharyngeal en-

toderm, this special one is always the most caudal, being constant in position with reference to the thyreoglossal pit. Of the embryos ranging in size from 15 to 30 mm., all but one showed a developing bursa, the blind end of which was in direct contact with the notochord, or bore a close relation to it. Still later, if there were any chordal remains in the retropharyngeal region, these were all closely related to the bursa. Since in all cases the embryonic bursae were separated from Rathke's and Sessel's pockets by practically the whole length of the vault of the pharynx, Huber was able to controvert the statement of Meyer that the bursa pharyngea and Sessel's pocket are identical. The constancy of the relation of the notochord to the pharyngeal epithelium after the notochord begins to separate from it, and the definite location of the area of contact, lead Huber to believe that this relation of the head chorda to the pharyngeal epithelium is not accidental, and that thus to a certain extent the bursa pharyngea may be regarded as a structure sui generis. However, the maintenance of the early caudal connection between the notochord and the epithelium of the pharynx seems necessary for the proper development of the bursa.

J. P. Tourneux ('12) in an extended comparative study of the relations of the cartilaginous base of the skull in mammals, arrived independently at the same conclusion regarding the origin of the bursa pharyngea. Tourneux believed that of the mammals examined only the horse and man present a bursa pharyngea in the proper sense of the word. Tourneux describes the course of the head chorda in three pig embryos, 13, 18, and 50 mm. in length respectively; in none of these did the notochord come in contact with the pharyngeal entoderm.

#### MATERIAL AND METHODS

The study was based for the most part on the examination of the pig embryos belonging to the Cornell collection, which consists of about 160 embryos cut in frontal, sagittal, and transverse sections, and ranging in length from 2.5 to 54 mm. vertex-breech measurement. Professor S. H. Gage very kindly loaned me a number of additional embryos and for this I wish to express my

appreciation. A few embryos belonging to students in the department of Histology were likewise examined.

Of the embryos used, those cut in the sagittal plane (about 60 in all) were found to be the most valuable for the study; but embryos cut in frontal and transverse sections were very useful in checking up results and in adding to the data obtained. The drawings were made only from embryos cut in sagittal sections and chosen as being representative of the particular stage under discussion. The drawings consist of reconstructions of the mid-sagittal plane of that region of the head (*pars chordalis*) including the hypophysis, the basilar plate and the anterior vertebral anlagen. For purposes of orientation, however, the first figure is extended to include the whole head. The figures were made with the aid of the projection microscope.

#### DESCRIPTION OF TYPICAL STAGES

*Pig embryo 5 mm. in length. Fig. 1.*

The notochord is seen separating off from the epithelium of the foregut. Posteriorly the separation is complete, several rows of mesenchymal cells intervening between the notochord and the entoderm of the foregut. As the notochord passes forward over the pharyngeal region, it bends slightly downward, presents an enlargement and comes in contact with the pharyngeal entoderm, which is here slightly thickened. This corresponds to the region emphasized by Huber in the human embryo as the seat of development of the bursa pharyngea. Slightly cephalad

Fig. 1 Pig embryo, I B no. 157, Cornell Collection, 5 mm. Reconstruction of midplane sagittal section of the pharyngeal region. Notochord black.  $\times 22.5$ .

Fig. 2 Pig embryo no. 10, Cornell Collection, 6.5 mm. Reconstruction of midplane sagittal section of the pharyngeal region. Notochord black.  $\times 20$ .

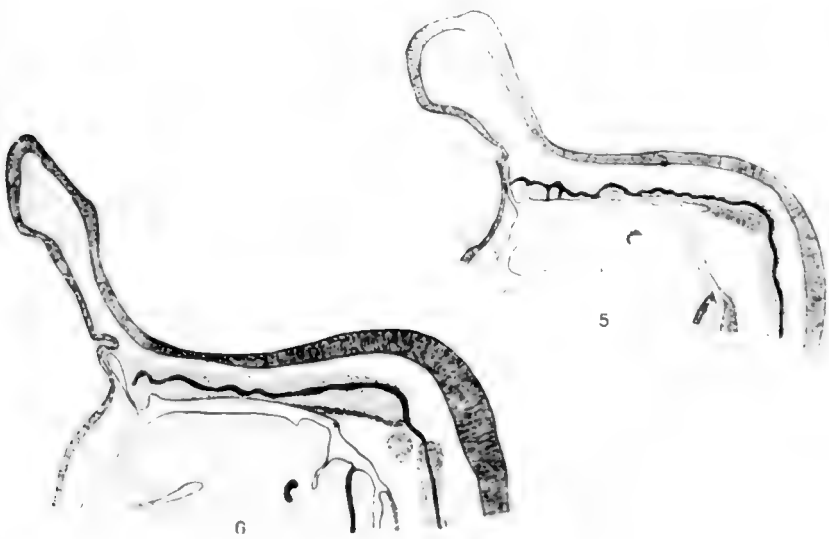
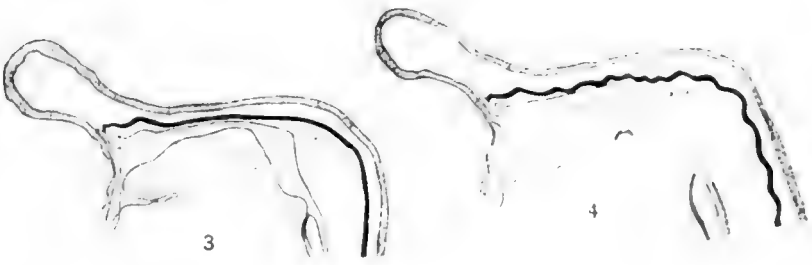
Fig. 3 Pig embryo II a no. 156, Cornell Collection, 7 mm. Reconstruction of midplane sagittal section of the pharyngeal region. Notochord black.  $\times 20$ .

Fig. 4 Pig embryo II a no. 152, Cornell Collection, 8.5 mm. Reconstruction of midplane sagittal section of the pharyngeal region. Notochord black.  $\times 20$ .

Fig. 5 Pig embryo belonging to Mr. R. S. Gutsell, 11.5 mm. Reconstruction of midplane sagittal section of the pharyngeal region. Notochord black.  $\times 20$ .

Fig. 6 Pig embryo III D, Cornell Collection, 14 mm. Reconstruction of midplane sagittal section of pharyngeal region. Notochord black.  $\times 15$ .





of this region the notochord presents another enlargement and again comes in contact with the pharyngeal epithelium - and still again, anterior to this contact. Just before the dorsal curve of the notochord as it nears the anterior end, the sheath comes in contact with the epithelium of the pharynx. The cephalic portion of the notochord presents a slightly waved course, passes over Sessel's pocket - *S.*, turns sharply ventrad, terminating in a thickened notochordal plate in close relation with the base of the forebrain. Transections of still younger pig embryos show that primitively the notochord is also in contact with Sessel's pocket, in a fashion similar to that shown by W. J. Atwell ('15) for the rabbit. The notochordal plate at this stage bears no significant relation however to the anlage of Rathke's pocket (*H*), which is here present merely as the so-called hypophyseal angle, just anterior to the remnant of the pharyngeal membrane.

*Pig embryo 6.5 mm. in length. Fig. 2.*

The mesenchyme between the neural tube and primitive esophagus has become slightly denser. The notochord at the end of its curve over the retropharyngeal region presents an enlargement and comes in contact with the epithelium of the pharynx, which is here slightly invaginated. Forward the notochord has lost all primary connection with the entoderm, two or three rows of mesenchymal cells separating it from the pharyngeal epithelium. The position of the point of contact is slightly cephalad to the vertex of the angle of the pharynx and just caudal to the level of the thyreoglossal pit in the tongue. It corresponds in position to that point of contact in human embryos emphasized by Huber as the seat of development of the bursa pharyngea. Forward, the notochord bends dorsally over Sessel's pocket, ending in a hooked formation near, but not in contact with, the posterior wall of Rathke's pocket.

*Pig embryo 7 mm. in length. Fig. 3.*

The notochord has lost all primary connection with the pharyngeal epithelium. It passes forward in a straight, even course between the hindbrain and the roof of the pharynx. Cephalad,

the notochord presents the characteristic dorsal curve over Sessel's pocket. Just below the bend of the notochord over the retropharyngeal region, a condensation of mesenchyme may be observed extending from the anlage of the vertebral column to the vertex of the angle of the pharynx. The pharyngeal epithelium in this region is slightly 'pulled out.' The extreme cephalic end of the notochord of this pig is in direct contact with the superior half of the posterior wall of Rathke's pocket.

*Pig embryo 8.5 mm. in length. Fig. 4.*

The condensation of mesenchyme in the retropharyngeal region is now clearly defined and is seen in close contact with the vertex of the angle of the pharynx. At this point the pharyngeal epithelium has been 'pulled out' to form a distinct pocket (X). The pocket bears no significant relation to the notochord, which courses in a wavy line dorsal to the condensation of mesenchyme. Forward the notochord continues in a wavy line between the hindbrain and the roof of the pharynx, ending in contact with the posterior wall of Rathke's pocket. The wavy course of the notochord was found to be characteristic of embryos a little older than the stage represented by figure 3. It can be explained only by supposing that the head chorda begins to grow faster than the surrounding mesoderm in the stage following complete separation from the pharyngeal entoderm. There remains to be noted the condensation of mesenchyme over the esophagus, indicating the anlage of the esophageal musculature.

*Pig embryo 11.5 mm. in length. Fig. 5.*

This embryo presents a remarkable picture in which the notochord takes a distinctly wavy course over the roof of the pharynx and comes in contact several times with the pharyngeal epithelium. Of the fifteen embryos examined between the ages 10 to 12 mm., six showed similar though not as many contacts, the usual number being three. There is evidence for the belief that these contacts are secondary and 'accidental,' due to the excessive growth of the head chorda at this stage (cf. subseq. discussion). The pharyngeal wall at the vertex of the angle of the

pharynx has been pulled out into a definite pocket, which is in contact at its base with the condensation of mesenchyme extending dorsal to the retropharyngeal region in the way shown in figure 4. This little outpocketing is very characteristic of embryos 8 to 12 mm. in length. In none of the pigs examined was it ever in contact with the notochord, but was always in relation with the retropharyngeal condensation of mesenchyme. In this embryo the condensation of mesenchyme has extended over and slightly beyond the pocket. Anteriorly, the notochord comes in contact with Sessel's pocket and ends in the posterior wall of Rathke's pocket in about the middle region. Attention is called to the condensation of mesenchyme in the esophagus, similar to that shown in figure 4.

*Pig embryo 14 mm. in length. Fig. 6.*

The angle of the pharynx has become greater as the cervical flexure apparently determining it has 'straightened out.' At the same time the outpocketing at the vertex of the angle of the pharynx has disappeared. In none of the pig embryos examined over 12 mm. in length did this pocket persist. The condensation of mesenchyme which passes through the retropharyngeal region bears the same relation to the pharyngeal wall as in the preceding stages, the whole region apparently having lengthened relatively. The condensation is now readily recognized as the perichondrium of the developing basal plate and includes also the anlage of the fascia pharyngobasilaris or ligamentum occipito-pharyngis, as it is sometimes called. The notochord courses through the anlage of the basilar plate in a deep ventral curve, the waves shown in figure 4 having decreased markedly in amplitude. This is possibly due to the fact that the head region in general has 'caught up' with the excessive growth of the notochord. Anteriorly the notochord has lost contact with Rathke's pocket, ending in a hooked formation near it. Contact with Rathke's pocket is lost usually at any time between the ages 13 to 18 mm. The base of the forebrain is evaginated to form the infundibular process.

The roof of the pharynx just at the opening into the esophagus is invaginated to form a distinct pharyngeal pocket, the base of

which is in close contact with the anlage of the esophageal musculature, which we have noted before (figs. 4, 5). It is important that this pocket be clearly distinguished from the bursa shown in figures 4 and 5, the position of which was cephalad as indicated by the letter x. This pocket appears regularly after 13 mm. and is constant in occurrence. It is possible that it arises primarily from the tension exerted on the pharyngeal wall at this region by the developing esophageal musculature.

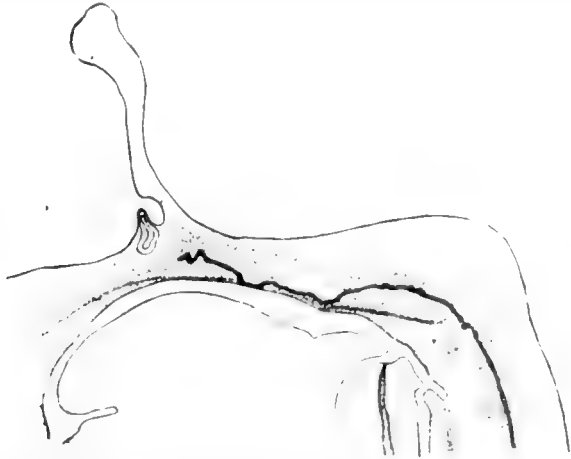


Fig. 7 Pig embryo III F, Cornell Collection, 17 mm. Reconstruction of mid-plane sagittal section of pharyngeal region. Notochord black.  $\times 15$ .

*Pig embryo 17 mm. in length. Fig. 7.*

This embryo shows the notochord extending through the basilar plate to come in contact three times with the pharyngeal epithelium. These are probably persistences of such secondary contacts as are shown in figure 5. The condition is by no means uncommon, three of the ten embryos examined ranging in length from 13 to 17 mm. having shown similar contacts. The epithelium at these points of contact is thickened slightly but not at all evaginated. Anteriorly the notochord ends in a sharp, double twist within the basilar plate. Rathke's pocket has become constricted off from the pharynx, and Sessel's pocket has disappeared. The condensation of mesenchyme indicating the

perichondrium of the basilar plate and the developing fascia pharyngo-basilaris has lost contact with the pharyngeal epithelium, a condition which occurs regularly after the embryo has attained a length of 16 mm. Close beneath the epithelium there has formed a second condensation of mesenchyme indicating the tunica propria of the pharyngeal mucosa. The pharyngeal pocket above the entrance into the esophagus has become greatly enlarged and still maintains a specific relation to the developing esophageal musculature.

*Pig embryo 35 mm. in length. Fig. 8.*

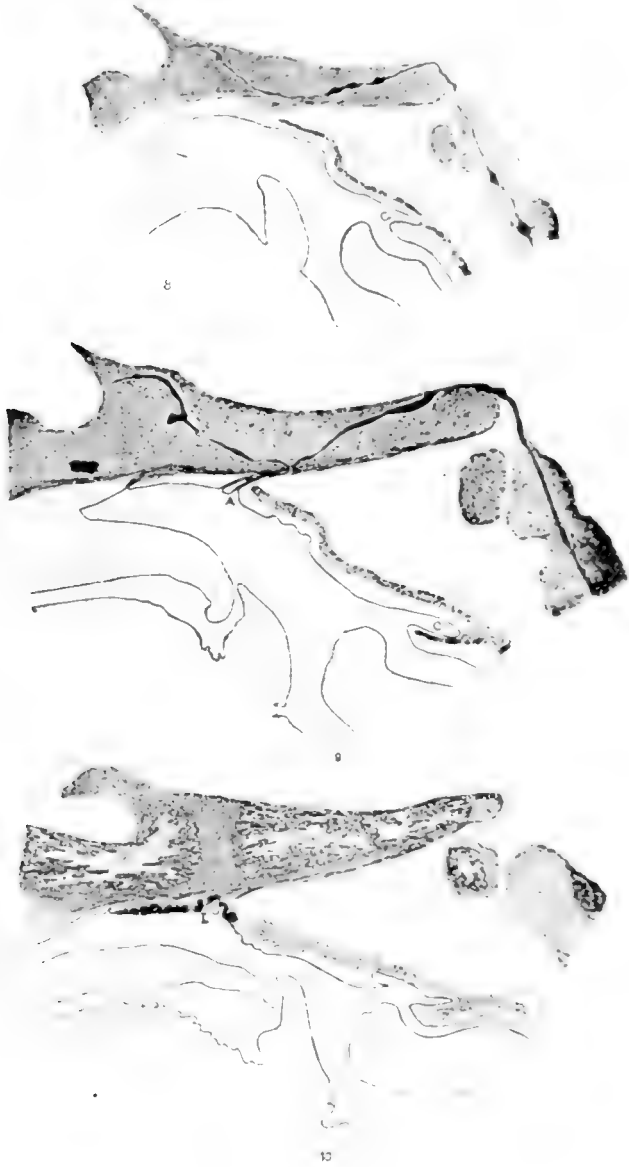
The vertebral centra and the basilar plate are present in the form of cartilage. The notochord on passing out of the epistropheus forms a knot, enters obliquely into the dorsal surface of the caudal end of the basilar plate, and passes through to the ventral surface in a long dorso-ventral curve, thence diagonally dorsal to its termination near the sella turcica. In certain areas the notochord shows signs of degeneration. It presents also several nodal swellings similar to those observed by Killian ('88), Williams ('08), Mead ('09), and others.

The pharyngeal pocket (C.) at the entrance into the esophagus has developed into a deep cul-de-sac in close relation at its blind end with the developing esophageal muscle. More anteriorly a separate condensation has appeared indicating the anlage of the constrictor muscles of the pharynx. These in the pig appear on the medial plane much later than the muscles of the esophagus, being recognizable first usually when the embryo has attained a length of about 23 mm. The angle of the pharynx has quite disappeared as such, as the head has 'lengthened out.' At some distance caudal to the upper limit of the pharyngeal muscu-

Fig. 8 Pig embryo, Serial no. 147, Cornell Collection, 35 mm. Reconstruction of midplane sagittal section of the pharyngeal region. Notochord black.  $\times 10$ .

Fig. 9 Pig embryo, Serial no. 159, Cornell Collection, 54 mm. Reconstruction of midplane sagittal section of the pharyngeal region. Notochord black.  $\times 10$ .

Fig. 10 Pig embryo, special preparation, 170 mm. Reconstruction of midplane sagittal section of the pharyngeal region.  $\times 4$ .



lature in the region of the loose retropharyngeal connective tissue, secondary folds have appeared in the pharyngeal mucosa. The fascia pharyngo-basilaris has become distinctly differentiated from the perichondrium of the basilar plate, as dense fibrous tissue.

*Pig embryo 54 mm. in length. Fig. 9.*

The most striking feature in the pharyngeal region of this embryo is the appearance of three distinct pockets in the mucosa of the roof of the nasal pharynx over the soft palate. The blind end of each pocket is in direct contact with strands of dense fibrous tissue, the developing fascia pharyngo-basilaris. The pocket which is most caudal (A.) is the largest and corresponds in position to that of the human bursa pharyngea as figured by Huber. It likewise occurs at the region designated by Killian as the place where one should look, in the pig, for a bursa pharyngea homologous to that of man, being at the level corresponding to the middle of the basal plate. There is no evidence that these pockets have ever been in relation with the notochord in the way shown by Huber for the bursa pharyngea of man.

The notochord courses through the basilar plate in a manner similar to that described for figure 8. It is interrupted, however, in the anterior portion. The pharyngeal recess is present at the entrance into the esophagus, separated from the three pockets by practically the length of the vault of the pharynx. The constrictor muscles of the pharynx and the musculature of the esophagus appear now as a rather continuous sheet in the median plane—an extension of the esophageal musculature having passed underneath the pharyngo-esophageal recess (C.) over the entrance of the pharynx into the esophagus.

*Pig embryo 170 mm. in length. Fig. 10.*

The figure shows the pharyngeal tonsil (T) developing as a series of accumulations of dense lymphatic tissue in close relation with a series of pockets or folds similar to those of figure 9 (A.). Each pocket is in contact at its base with strands of dense connective tissue, the fascia pharyngo-basilaris. Ossification in



the basioccipital and basisphenoid is now extensive. No traces of chordal tissue were observed. The pharyngeal recess above the entrance into the esophagus has become greatly folded and enlarged.

#### DISCUSSION

*Relation of the notochord to the pharyngeal epithelium.* Attention has recently been directed by numerous observers (Mrs. Gage, '06, Mead, '09, Huber, '12) to the existence of contacts between the notochord and the pharyngeal epithelium in the pig embryo, which were thought to be similar to those in man. It was therefore to this phase of the study that particular attention was paid, since in man according to Froriep, Linek, Tourneux, and Huber, notochordal contact seems intimately bound up with the development of the bursa pharyngea. The results of my study were somewhat negative, in that the relation between the notochord and the pharyngeal epithelium in the pig embryo was found to be quite different from that described for the human embryo. In the first place, the notochord of the pig at an early stage seems to become completely separated from the epithelium of the pharynx, grows more rapidly than the surrounding tissues, and then may acquire secondary contacts with the pharyngeal epithelium. It is probable that these secondary contacts are the ones noted by Mrs. Gage and Mead for the pig embryo. Notochordal contacts which Linek, Tourneux and Huber described for man are apparently primary contacts which the notochord maintains with the pharyngeal epithelium. In the second place, notochordal contacts in the pig embryo were never found to bear any specific relation to the pharyngeal pockets.

The early pig embryos—3 to 6 mm. in length—present notochordal contacts with the epithelium of the pharynx quite similar to those figured by Huber for the early human embryos. These primary contacts which the notochord maintains longest with the pharyngeal entoderm are somewhat posterior in position, usually caudal of the level of the thyreoglossal pit of the tongue (figs. 1 and 2). Embryos of approximately 7 mm. in length showed the notochord as a rule completely separated from

the pharyngeal epithelium. The notochord of these embryos passes in a straight even course between the hindbrain and the roof of the pharynx (fig. 3). At the time when the embryo has attained a length of 8 to 10 mm. the notochord apparently undergoes a period of excessive growth. Figure 4 presents a typical picture of this stage, and shows the notochord passing in a deeply waved course over the roof of the pharynx. Between the lengths of 8 to 10 mm. the notochord at no time showed true contact with the pharyngeal epithelium. On the other hand, in a large percentage of embryos 10 to 12 mm. in length, the notochord came in contact several times with the epithelium of the pharynx (fig. 5). The notochord still presents a distinctly wavy course. These contacts differ relatively in position from those of the younger embryos, lying well in front of the level of the thyroglossal pit in the tongue. A few of the older embryos showed persistences of these contacts even after the anlage of the basilar plate was well formed (fig. 7). Thus the statement of Tournoux that the notochord of the pig embryo is always entirely intrabasilar requires modification. In none of the pig embryos at my disposal that were over 17 mm. in length, were notochordal contacts observed, although Mead figures a condition similar to that of figure 7 for a 30 mm. embryo. This is clearly an exceptional case. At no time were notochordal contacts found in relation to pharyngeal outpocketings.

The following data gives in tabular form the evidence for regarding as secondary those notochordal contacts with the pharyngeal epithelium which are present in pig embryos 10 to 18 mm. in length:

LENGTH OF EMBRYO IN MM.	NUMBER EXAMINED	NUMBER SHOWING NOTOCHORDAL CONTACTS WITH PHARYNX	PERCENTAGE SHOWING NOTOCHORDAL CONTACTS	MAXIMUM NUMBER OF CONTACTS	MODAL NUMBER OF CONTACTS	RELATIVE POSITION OF CONTACTS	COURSE OF HEAD CHORDA
4-5	10	8	80	4	3	Caudal	Even
6-7	24	6	25	3	1	Caudal	Even
8-9	7	0	0	0	0		Wavy
10-12	15	6	40	5	3	Cephalic	Wavy
13-17	10	3	33	4	2	Cephalic	Deep curve
17-54	66	0	0	0	0		Deep curve

*Notochord and hypophysis.* In making the above observations the writer has had occasion to study also the relation of the notochord to the hypophyseal anlage. A number of early investigators, M. Miller ('68) and Dursy ('68), have held the view that the notochord acts mechanically in drawing out the infundibular process, basing their belief on the fact that in early stages the notochord is attached to the base of the forebrain. Observations on the pig embryos at my disposal do not permit me to confirm this view of the relation of the chorda and the infundibular process. The early embryos, 2.5 to 3 mm. in length, at a time when the anterior end of the notochord was not yet folded off from Sessel's pocket, showed the notochord in contact for a short distance along its dorsal surface with the base of the forebrain. Several of the embryos, 4 to 5 mm. in length, at a time when the separation of the notochord from Sessel's pocket is complete, also showed a point of contact between the notochord and the base of the forebrain, similar to that shown in figure 1. These however were not true contacts according to the criterion of Woerdeman, being mere juxtaposition of parts, since the notochordal sheath and margin of the brain wall could be clearly seen between the two structures. Later the notochord and base of the forebrain are separated by the ingrowth of mesenchyme (fig. 2), which occurs ordinarily when the embryo has attained the length of 6 mm. The infundibular process, however, does not begin to appear until the 11 to 12 mm. stage, at a time when the base of the forebrain is free from notochordal contact. A causal significance, therefore, cannot be attached to the relation of the notochord to the base of the forebrain in the appearance of the infundibular process.

Other investigators have held that the notochord is responsible in a similar fashion for the origin of Rathke's pocket. Among these may be mentioned Reichert ('40) and His ('68). Mihal-kovics ('74) denied that the chorda is responsible for the drawing out of the hypophyseal sac in the rabbit, on the grounds that its attachment is to the inferior portion of the posterior wall of Rathke's pocket instead of to the apex. Woerdeman ('13) however has pointed out that this argument is not conclusive, since

in the pig embryo the notochord is in contact with the superior portion of the posterior wall of Rathke's pocket; nevertheless Woerdeman does not consider this a positive argument for the existence of a causal relation between the chorda and Rathke's pocket. In 1915 W. J. Atwell published observations on the relation between the notochord and Rathke's pocket in the rabbit and chick embryos. Contacts between the chorda and Rathke's pocket were constant in the chick, but existed in a very small percentage of cases in the rabbit. Atwell explains notochordal contacts with Rathke's pocket as secondary, being due to the growth of the forebrain and sharpness of the cervical flexure. In no case could he find that the entodermal contribution to the hypophyseal sac was anything more than an accidental union of parts. Recently the old idea of the notochord acting as a causative factor in the origin of Rathke's pocket has been revived by M. M. Miller ('15). In a preliminary note on the development of the hypophysis in the pig embryo, he assigns a mechanical function to the notochord in the genesis of the structure, and states that the entoderm as well as the ectoderm enters into its structure. According to Miller's observation, the notochord pulls away with it from the foregut a mass of entodermal cells, which at first comes in relation with the apex of the hypophyseal angle. Later the contact shifts from the apex down to the constricted stalk of the hypophyseal sac. I am unable to confirm these observations of Miller on the pig embryo. In none of the pig embryos examined under 6 mm. was the notochord in contact with Rathke's pocket. All of the embryos 4 and 5 mm. in length and a few of the 6 mm. embryos showed the developing Rathke's pocket wholly free from notochordal contact. After the embryo has attained a length of 6 or 7 mm. the notochord regularly comes in contact with the superior half of the posterior wall of Rathke's pocket. The contact is brought about probably through the excessive growth of the notochord over the rest of the head, which begins at this time. The contact between the chorda and Rathke's pocket was found to be entirely similar to that described by Woerdeman, being a true contact without any intervening membrana propria. There was no

evidence that the chorda contributed any essential component to the structure of the hypophysis however. Any endodermal tissue that might be found later in the developing hypophysis may be explained as the result of an accidental union with the notochord. In later stages the notochordal contact usually shifts down relatively from the superior to approximately the middle region of the posterior wall of Rathke's pocket. Contact between the notochord and the hypophysis is usually maintained until the embryo attains a length of 13 to 15 mm., when it is lost through the ingrowth of mesenchyme.

*The pharyngeal pockets.* The material presented shows very clearly that it is necessary to distinguish among three different pharyngeal pockets in pig embryos, each one of which has appeared in the literature under the name bursa pharyngea or recessus medius pharyngis. It has been the main object of this study to determine which, if any, of these pockets is the true homologue of the bursa pharyngea of man.

With the exception of Minot, no one to my knowledge has ever noted the pocket which has been shown as the first to appear, and which arises at the vertex of the angle of the pharynx (figs. 4, X, 5, and 6, X). In an outline drawing of a model of the pharynx in a 12 mm. pig embryo as seen from the dorsal side, Minot (11) figures this pocket at the summit of the pharynx at the level of the third gill pouch, and calls it the bursa pharyngis (fig. 28, p. 26). In a drawing of the profile view of the pharynx from a wax reconstruction of another 12 mm. pig embryo, Minot again figures this pocket, but gives it no name. Farther down in the pharynx above the entrance into the esophagus and on a level with the fourth gill pouch, he figures the pocket which has been shown is the second to appear, (figs. 6 and 7) and calls this the pharyngeal bursa (fig. 173, p. 237). Thus Minot failed to distinguish between the two pockets. In none of the pig embryos at my disposal were both pockets present at once in the fashion shown by Minot, though the condition is probably not uncommon.

Although the pocket at the vertex of the angle of the pharynx which is the first to develop, is very constant in appearance

among 8 to 12 mm. pig embryos, I nevertheless believe that no special morphological significance can be attached to it. Its close approximation to the point described by Huber as the seat of development of the bursa pharyngea of man, suggests the possibility that this pocket in the pig is homologous with the human bursa. Careful study shows, however, that the region where the notochord longest maintains its primary attachment with the pharyngeal entoderm was some distance anterior to the point where the pocket develops. The pocket persists only up to the time when the angle of the pharynx increases as the 'head bending' which seemingly determines it 'unbends.' In none of the seventy-six embryos over 12 mm. in length that were examined did this pocket persist. I therefore believe that it should be regarded merely as a temporary out-pocketing of the pharyngeal epithelium arising mechanically in growth.

The pharyngeal pocket (figs. 8 and 9, C) which has been shown as the second to develop, appearing usually when the embryo has attained a length of 12 mm. and which is situated in the roof of the pharynx over the entrance into the esophagus, has likewise been called the bursa pharyngea or the recessus medius pharyngis. Luschka<sup>2</sup> ('68) was the first to point out that this pocket in the pig is not homologous to the bursa pharyngea of man, since the structure in the pig is constant and well-developed, whereas the bursa of man is inconstant and rudimentary. Later Killian ('88) also denied that this pocket was homologous to the bursa pharyngea of man. He figures the pocket in a 65 mm. pig embryo as lying in the roof of the pharynx at the level of the boundary between the second and third vertebrae and opposite the entrance into the larynx, at the same time designating the place where one must look for a bursa pharyngea comparable to

<sup>2</sup> "Mit jenem rudimentären, überdies nicht regelmässige vorkommenden beutelförmigen Anhang der Pars nasalis hat die constante, eine gesetzmässige Art von Pharynx secundarius darstellende Aussackung der Dorsalwand des Pharynx beim Schwein nichts gemein. Bei diesem Geschöpfe stulpt sich nämlich in der Richtung gegen die Speiseröhre die Schleimhaut der Dorsalwand zu einer 4 cm. langer cylindrischen fingerdicken Tasche aus, deren abgerundete, freies Ende den Rand des Constrictor pharyngis inferior überragt, und also schon am unzerlegten Organe sichtbar ist."

that of man, as farther up in the vault of the pharynx at a level corresponding to the middle of the basal plate. Since Killian, however, this pocket has been called the bursa pharyngea or median pharyngeal recess by writers among whom may be mentioned Sisson ('11), Stilling ('11), and Minot ('11). The present study has convinced the writer that Luschka and Killian were right in their statement that this pocket is not homologous to the bursa pharyngea of man, since it differs from it both in mode of development and in its anatomical position. The bursa pharyngea in man has been shown to develop in relation with the notochord and the occipito-pharyngeal fascia; the pocket under discussion arises in close relation with the developing esophageal musculature, (figs. 5, 6). The bursa pharyngea of man is constant in position, being situated always anterior to the upper boundary of the constrictor muscles of the pharynx at a level corresponding to the middle of the basal plate, and bears a definite relation to the fascia pharyngo-basilaris and the pharyngeal tonsil. This pocket of the pig, however, is situated in the posterior part of the pharynx just over the entrance into the esophagus at the level of the boundary between the second and third vertebrae, and bears a close relation to the esophageal musculature. It would therefore be advisable to call the pocket by some other name, as, for example, the pharyngo-esophageal recess. The recess is constant in appearance after the pig embryo has attained a length of 13 mm., and is therefore of morphological interest. It is not to my knowledge present in any other mammal with the possible exception of the horse. As was shown in the figures, it develops in close contact with the developing esophageal musculature, possibly arising from the tension which these muscles exert on the pharyngeal wall of this region during the growth of the head. Dissection of older pig embryos showed that the laryngeal apices fit into the recess thereby probably enlarging it. It may be that the laryngeal apices act in conjunction with the recess to shut off the esophagus, thus affording a more direct channel for the passage of air. In the adult the recess is described as 4 centimeters deep, and often the seat of pathological disturbance due to the fact that particles of food become lodged within it.

Of the pharyngeal pockets which appear in the development of the pig embryos, I believe that the series which was shown to arise last (fig. 9, A.) in close relation with the developing fascia pharyngo-basilaris, is most nearly homologous to the bursa pharyngea of man. Anatomically, the most caudal of the series of pockets in the pig embryo bears the same relations to the surrounding structures as does the bursa pharyngea of the human embryo, being situated just in front of the upper limit of the superior constrictor pharyngis at the level corresponding to the middle of the basi-occipital, in close relation with the fascia pharyngo-basilaris and the pharyngeal tonsil. On the other hand, it was found impossible to compare step by step the development of the structures in the two embryos, since the relations of the head region differ greatly in growth. Until the 6 or 7 mm. stage however, the general relations of the head region are the same in the two embryos. Huber has shown that the human bursa pharyngea develops at the most caudal point of contact which the notochord maintains longest with the pharyngeal epithelium. In the human embryo the attachment is maintained until the development of the bursa pharyngea. Pig embryos 5 to 7 mm. in length usually show the notochord maintaining its connection with the pharyngeal epithelium longest in the region corresponding in position to the point of contact emphasized by Huber in the human embryo. With the growth of the pig embryo however, this connection is early broken, and thus the landmark is lost which would enable one to locate the bursa pharyngea of the pig embryo as arising definitely at this point. On the other hand, the older pig embryos show the most caudal of the series of pockets under discussion in the same general anatomical relations as the bursa pharyngea of man at a similar stage of development, being situated in the roof of the anterior portion of the pharynx just in front of the upper limit of the *min. constrictores pharyngis* at the level corresponding to the middle of the basilar plate, and in close relation with the developing fascia pharyngo-basilaris. The fact that in both the human and pig embryos of younger stages the point of attachment between the notochord and the pharyngeal epithelium, which is



most caudal and which is maintained longest, is in the same position; the fact that the bursa pharyngea of the human embryo arises at this point of attachment; as well as the fact that the bursa pharyngea of the human embryo and the most caudal of this series of pockets in the older pig embryos possess the same anatomical relations, incline one strongly to the belief that this pocket in the pig embryo arises at the point where the notochord maintained its attachment longest with the pharyngeal epithelium, and therefore may be considered comparable to the bursa pharyngea of man. The early loss of the relation of the notochord to the pharyngeal epithelium in the pig embryo complicates a direct comparison.

Concerning the part played by the notochord in the development of the human bursa pharyngea, Froriep, Link, Tourneux, and Huber have published observations, which indicate that the tension of the notochord on the pharyngeal epithelium is the essential factor in the origin of the bursa. Froriep believes that the occipito-pharyngeal fascia is another possible factor. Link believes that to some extent the pharyngeal mucosa invaginates of itself. Tourneux considers the occipito-pharyngeal fascia an accessory factor in the genesis of the bursa. From his observations Tourneux<sup>3</sup> is led to distinguish between two kinds of pharyngeal pockets, the simple pharyngeal recess and the bursa pharyngea, which in the horse may both be present at the same time, and often not separated, the recessus opening into the bursa directly. In the pig a series of pockets (fig. 9) corresponding in general position to the bursa pharyngea of man has been shown to appear independently of the action of the notochord, the develop-

<sup>3</sup> "Il convient de différencier le récessus médian du pharynx d'avec la bourse pharyngienne . . . . Le récessus sans relation directe avec la chorde paraît résulter de l'inflexion céphalique déterminant l'angle du pharynx, et surtout des adhérences que le ligament occipito-pharyngienne contracte avec la muqueuse du pharynx. Quant à la formation de la bourse pharyngienne, elle est provoquée ainsi que l'a montrée Froriep, par une adhérence locale que la chorde a conservée avec l'endoderme dans l'épaisseur duquel elle était primitivement enclavée le long de la ligne médiane. A cette adhérence vient s'ajouter comme cause adjuvante le ligament occipito-pharyngienne, dont l'insertion supérieure répond à la partie inférieure de la bourse."

ing occipito-pharyngeal fascia apparently acting as an essential factor in their origin. Huber discusses the possible action of the occipito-pharyngeal fascia in the development of the human bursa pharyngea. In one of the embryos at his disposal there was present a small bursa in close relation with a well-developed occipito-pharyngeal ligament and free from notochordal contact. The fact that there was present only an imperfectly developed bursa independent of notochordal contact on the one hand, and a well-developed fascia pharyngo-basilaris on the other hand, seemed to Huber to argue against regarding the fascia as a factor in the origin of the bursa. Nevertheless there was present a bursa pharyngea. Moreover, examination of Huber's detailed drawings shows that at the time when the pharyngeal epithelium becomes distinctly invaginated to form the bursa, the mesenchyme about the notochord at its point of contact is thickening to form a sheath, later incorporated with the fascia pharyngo-basilaris. Huber figures also a 60 mm. human embryo in which there is present a well-developed bursa pharyngea in direct contact with the developing fascia pharyngo-basilaris, which involved at some distance from the bursa some degenerating chordal remains. It may be suggested that while the human bursa pharyngea regularly develops in contact with the notochord, it arises not so much through tension exerted on the pharyngeal epithelium by the notochord itself, as by the sheath of (developing) connective tissue surrounding the notochord. However, maintenance of the notochordal connection with the pharyngeal epithelium may influence the mesenchyme to condense earlier, since the bursa together with the fascia begins to develop in the human embryo at a relatively earlier stage than in the pig. If this be the case, Tourneux's distinction between the bursa pharyngea and simple pharyngeal recess is not valid. Indeed the fact that both kinds of pockets may be found at once, the one in contact with the notochord, the other with the occipito-pharyngeal fascia, together with the fact that sometimes these pockets are inseparable, indicates that there is no essential difference between them. Killian's distinction between the bursa pharyngea and the simple pharyngeal recess is

interesting in comparison with that of Tourneux: "Das Verhältnis zur Fibrocartilage basilaris bietet ein wichtiges Kriterium zur Entscheidung zwischen einem einfachen Recessus und einer wirklicher Bursa. Ersterer gehört stets zu der Schleimhaut an." The appearance of a series of bursae in embryos of the pig and of the horse (Tourneux), instead of a single bursa as in the human embryo, may be explained by the fact that the tension exerted by the fascia pharyngo-basilaris extends over a longer area, corresponding to the longer line of the crista pharyngea of the basi-occipital, which, as Skoda ('12) points out, corresponds in long skulled animals to the tuberculum pharyngeum of man.

As is shown in figure 10, the pharyngeal tonsil (*T*) develops at the site of this series of pockets (figs. 9 and 10). I believe that the name bursa pharyngea is preferable to that of recessus medius pharyngis. The latter term was originally proposed by Ganghofner ('79) who, with Schwabach ('87), believed that the pocket is merely a part of the pharyngeal tonsil, —being the junction of the medial with the lateral furrows. By way of comparison with the recessus laterales, (fossae of Rosenmüller) he suggested therefore the name recessus medius pharyngis, but oddly enough proposed that the term bursa pharyngea be retained for the pathologically over-developed form. The study of the genesis of the pocket, however, in both the human and pig embryo has shown it to be an independent anatomical structure. For this reason bursa pharyngea is the preferable term.

#### CONCLUSIONS

1. The relations of the notochord to the pharyngeal epithelium in the pig embryo differs essentially from that described for the human embryo, in that

a) The notochord early becomes separated off from the pharyngeal entoderm, and then may acquire secondary contacts through excessive growth and 'bendings.'

b) The notochord is never in contact with pharyngeal out-pocketings.

2. It cannot be said that in the pig embryo the notochord either acts mechanically in the drawing-out of the infundibular

process and hypophyseal sac, or contributes any essential component to the structure of the hypophysis.

3. In the pig embryo distinction must be made among three different pharyngeal pockets:

a) The first pocket, which can be regarded merely as a temporary invagination of the pharyngeal wall at the summit of the pharynx, arising from the tension exerted on the wall by the flexion of the head in its growth.

b) The pharyngo-esophageal recess above the entrance into the esophagus, a constant structure in the pig, possibly arising from the tension exerted on the pharyngeal wall by the developing esophageal musculature.

c) A series of pockets which develop in the anterior portion of the roof of the pharynx in front of the constrictor muscles and which are comparable to the bursa pharyngea of man.

4. In the pig embryo, the series of pockets corresponding to the bursa pharyngea of man arises independently of notochordal contact—the developing fascia pharyngo-basilaris acting as the essential causative factor.

5. The pharyngeal tonsil in the pig embryo develops in close connection with the series of pharyngeal pockets corresponding to the bursa pharyngea of man.

## LITERATURE CITED

- ATWELL, W. J. 1915 The relation of the chorda dorsalis to the entodermal component of the hypophysis. *Anat. Rec.*, vol. 10, pp. 19-36.
- FRORIEP, A. 1882 Kopftheil der Chorda Dorsalis bei menschlichen Embryonen. Als Festgabe für Jacob Henle, Bonn, pp. 26-40.
- GAGE, SUSANNA PHELPS. 1906 The notochord of the head in human embryos of the third to the twelfth week, and comparison with the other vertebrates. *Science, New Series*, vol. 24, pp. 295-296.
- GANGHOFNER, FRIEDRICH. 1879 Über die Tonsilla und Bursa pharyngea. *Sitzungsber. d. k. Akad. d. wiss. in Wien*, Bd. 78, pp. 182-212.
- HUBER, G. C. 1912 On the relation of the chorda dorsalis to the anlage of the pharyngeal bursa or the median pharyngeal recess. *Anat. Rec.*, vol. 6, pp. 373-401.
- KILLIAN, G. 1888 Über die Bursa und Tonsilla Pharyngea. *Morph. Jahrb.*, Bd. 14, pp. 618-711.
- KOELLICKER, A. 1879 Entwicklungsgeschichte des Menschen und der höheren Thiere, pp. 426, 441, 459, 828-832.
- LINCK, A. 1911 Beitrag zur Kenntnis der menschlichen Chorda dorsalis im Hals und Kopfskelet. *Anat. Hefte*, Bd. 42, pp. 605-736.
- LUSCHKA, H. v. 1868 Der Schlundkopf des Menschen. Tübingen, pp. 24-27.
- MEAD, C. S. 1909 The chondrocranium of an embryo pig, *sus scrofa*. *Am. Jour. Anat.*, vol. 9, pp. 167-208.
- MEYER, R. 1910 Über die Bildung des Recessus pharyngeus medius, Bursa pharyngea, in Zusammenhang mit der Chorda des menschlichen Embryonens. *Anat. Anz.*, Bd. 37, pp. 449-453.
- MILHALKOVIES, V. 1874 Wirbelsäule und Hirnanhang. *Arkiv. f. Mikr. Anat.*, Bd. 11, pp. 389-431.
- MILLER, M. M. 1915 A study of the hypophysis of the pig. *Anat. Rec.*, vol. 10, pp. 226-228.
- MINOT, CHAS. S. 1911 A laboratory text book of embryology. Second Edition, revised. P. Blackiston's Sons & Co., Phila., pp. 62, 237.
- OPPEL, A. 1900 Lehrbuch der vergleichenden mikroskopischen Anatomie der Wirbelthiere. Dritter Theil, Fischer, Jena 1900, pp. 103-117.
- SCHWABACH 1887 Zur Entwicklung der Rachen-tonsille. *Arch. f. Mikr. Anat.*, Bd. 62, pp. 187-213.
- SISSON, S. 1911 Veterinary anatomy. Saunders & Co., Phila., pp. 415-416.
- SKODA, K. 1912 Die sogenannten Tubercula pharyngea der Haussäugetiere und die Ansatzverhältnisse der Kopfbeugemuskel an der Schädelbasis. *Anat. Anz.*, vol. 42, pp. 33-37.
- STILLING, Geo. 1911 Die Rachenhöhle, die Hörtrumpete, und der Luftsack des Pferdes. *Ellenberger's Handbuch der Vergl. mikr. Anat. der Haustiere*, Paul Parey, Berlin, Bd. 3, pp. 114-124.
- TOURNEUX, J. P. 1911 Base Cartilagineuse du Crâne et Organes Annexes. Toulouse Thèse, vol. 71.
- WILLIAMS, L. W. 1908 The later development of the notochord in mammals. *Am. Jour. Anat.*, vol. 8, pp. 251-285.
- WOERDEMANN, M. W. 1913 Über einen Zusammenhang der Chorda Dorsalis mit der Hypophysen Anlage. *Anat. Anz.*, Bd. 43, pp. 378-388.



## ON THE USE OF NILE BLUE SULPHATE IN EMBRYONIC TISSUE TRANSPLANTATION

SAMUEL RANDALL DETWILER

*Osborn Zoological Laboratory, Yale University*

### INTRODUCTION

Nile blue sulphate as a vital stain has been successfully used for determining the relation of various parts of the egg to the future embryo. The first application of this method was made by Goodale ('12) in a study of the development of *Spelerpes*. After removing the outer jelly from the egg, the inner capsule was punctured, thus allowing the perivitelline fluid to escape. Dry stain which was then applied with a needle to desired positions on the jelly worked its way through the jelly and produced stained areas on the egg. These stained areas could be followed during the shifting of the egg substances, thus enabling a determination to be made of the relation of these parts to the resulting embryo.

Except for slight modifications in application, this same method was used by Smith ('14) in an experimental study of concrecence in the embryo of *Cryptobranchus allegheniensis*. In this case an aqueous solution of proper strength was applied by means of a fine pipette after the gelatinous capsule has been removed from the egg. Distinct blue spots were thus produced which did not wash out and which were not sufficiently toxic to interfere with normal development. It was observed that the stain did not spread to any extent by diffusion and that stained areas were carried from one position to another only by an actual movement of egg material. Thus, the direction and amount of movement of the cells could be determined.

## EXPERIMENTAL

Many embryonic rudiments can be located only with difficulty in early embryos because there are no surface markings to indicate their position; consequently successful extirpation or transplantation of such rudiments cannot be effectually carried out unless some method is employed whereby their exact location can be ascertained. By producing a color contrast between the tissue of the two components, this object may often be attained, for then the grafted tissue can be marked out immediately with reference to the outline of the whole embryo, and can also be correlated with local landmarks in older stages. In grafting together parts of embryos of two species differently pigmented, we have a means of doing this, as in the lateral line experiments of Harrison ('03). It was suggested by Dr. Harrison that, in homoplastic operations, this same purpose might be accomplished by staining one of the components with some vital dye before transplanting. Accordingly, with the use of Nile blue sulphate, a method was devised whereby the anterior limb rudiment of *Amblystoma* could be located in embryos with open medullary folds. At this stage the somites and the pronephros, which in later stages, indicate the position of the limb rudiment, (Harrison, '15) are not yet formed, and the limb rudiment is present merely as a *region* of mesoderm without visible local characteristics.

The method employed was as follows: Embryos, which were either removed from the capsule or allowed to remain within it, were placed in an aqueous solution of the stain until they had acquired a deep blue color, after which they were removed to tap water. An unstained embryo, which is of a brownish yellow color, and a blue stained embryo were placed side by side in a watch glass filled with 0.4 per cent salt solution. A circular cut was made in the unstained embryo just posterior to an imaginary line passing dorso-ventrally midway through the embryo. The ectoderm and mesoderm were removed and discarded and the wound was cleaned of all free mesoderm cells. The wound was then covered over by a circular piece of ectoderm



taken from the stained embryo and cut to fit the excision. In about one-half hour the stained piece had healed in. Its size and position could then be indicated by a camera drawing. The stained disc now occupied in the embryo the place of the original extirpated tissue and the position of this inserted piece of ectoderm, when development had proceeded so that the somites could be seen, served to indicate whether or not the limb rudiment had been removed.

When the stained disc eventually lay just ventral to the third, fourth and fifth somites, it could be assumed with a high degree of certainty that the limb rudiment had been removed. If the extirpated tissue was taken from a more posterior position than that indicated above, so that the stained ectoderm which covered the wound came to lie ventral to the fourth, fifth and sixth or the fifth, sixth and seventh somites, it was then clear that only a portion of the limb cells had been removed and regeneration could be predicted.

The position of the stained disc is not always an absolute indicator of the region of the excised mesoderm, since it may be changed somewhat by ectodermal shifting. There is, however, very little shifting in the immediate limb region. The more pronounced ectodermal shifting, which does not usually occur until a somewhat later stage, takes place dorsal to the limb region and proceeds in a dorso-posterior direction; the general character and direction of the movement being similar to that observed in frog embryos by Harrison ('03) in his experiments on the development of the lateral line.

The migrating ectoderm, however, occasionally involves the dorsal portion of the stained area which then loses its circular shape and lengthens out dorso-posteriorly.

Various concentrations of Nile blue sulphate have been used ranging from 1 part of the dry stain in 100,000 parts of water to 1 part of the stain in 500,000 parts of water. The optimum concentration was found to lie between 1:150,000 and 1:200,000. The length of time required to produce the desired intensity in a solution of 1:160,000 depends on whether or not the capsule was removed before the embryo was stained. Embryos removed

from the capsule were properly stained in about three hours, but when the capsule was left intact from ten to twelve hours were required. Staining in the capsule, though a longer process, produces a more uniform color and for this reason is the more desirable method.

When embryos were stained in the capsule for twelve hours in stronger concentrations, the ectoderm took on a reddish color with a distinct luster, a condition which served to indicate that the embryo had been overstained. The vitality of overstained ectoderm is decreased, its healing properties, when transplanted, are more or less impaired and some diffusion of the stain takes place.

Ectoderm taken from an embryo which has been properly stained has no reddish color, but presents a deep blue appearance; and, when transplanted to an unstained embryo, it heals as readily as normal ectoderm. There is no diffusion of the dye into the ectoderm of the host and the original color of the stained tissue is preserved for several days. As a result of continued cell division, however, the size of the stained piece becomes larger and the stain gradually loses its intensity.

Embryos stained in the capsule for twelve hours in various concentrations ranging from 1:150,000 to 1:200,000 have been kept for twenty-five days after the application of the stain, during which time development proceeded normally, and at the end of which period all reactions were normal. The larvae at this stage were still light greenish blue in color.

Neutral red was also used in a few experiments with satisfactory results. When this stain is used the optimum concentration for a fixed staining period of twelve hours lies between 1:400,000 and 1:500,000. Embryos stained in the capsule for twelve hours in solutions of such strengths stain a uniform red and such embryos were also kept for twenty-five days during which period development was normal. At the end of this time practically all of the stain had disappeared. In so far as the effects on the embryo are concerned one stain can be used equally as well as the other; yet the Nile blue sulphate is the more desirable because it produces a better contrast.

Goodale states that in *Spelerpes* the stain has a strong affinity for yolk granules and that the protoplasm is left unstained. On the other hand, Smith states that in *Cryptobranchus* the micromeres stain distinctly and keep the stain while the more heavily laden yolk parts of the egg stain with difficulty. A study of stained ectoderm taken from *Amblystoma* embryos shows that some of the yolk granules take up the stain while others are left entirely unstained.

The application of Nile blue sulphate has not been restricted to limb experiments, but has been used this season by Dr. Harrison in experiments on the ear vesicle and on the gills. In as much as the method has given satisfaction in these several types of experiments, it is hoped that it may be applied to still other experiments dealing with embryonic tissue transplantation.

The details of the limb experiment will appear in a later publication.

#### BIBLIOGRAPHY

- GOODALE, H. D. 1912 The early development of *Spelerpes bilineatus*. *Am. Jour. Anat.*, vol. 12.
- SMITH, B. C. 1914 An experimental study of conerescence in the embryo of *Cryptobranchus allegheniensis*. *Biol. Bull.*, vol. 26.
- HARRISON, R. G. 1903 Experimentelle Untersuchungen über die Entwicklung der Sinnesorgane der Seitenlinie bei den Amphibien. *Archiv für Mikros. Anat.*, Bd. 63.
- 1915 Experiments on the development of the limbs in Amphibia. *Proc. Nat. Acad.*, vol. 1.













QL  
801  
A45  
v.13  
cop.3

The Anatomical record

1977

**Biological  
& Medical  
Serials**

PLEASE DO NOT REMOVE  
CARDS OR SLIPS FROM THIS POCKET

---

UNIVERSITY OF TORONTO LIBRARY

---

**STORAGE**

