






3 1761 06704257 2









M.A.
M.

With the Author's Compliments
D. E. Munnell
September 21st 03.



ANATOMY

APPLIED TO

MEDICINE AND SURGERY

BY

D. E. MUNDELL, B.A., M.D.

Professor of Applied Anatomy, Faculty of Medicine, Queen's
University, Ex-Examiner Practice of Medicine, Ontario
Medical Council, Surgeon to Kingston
General Hospital.

83844
27/9/07

KINGSTON :
PRINTED AT THE BRITISH WHIG,
1903.



Entered according to Act of the Parliament of Canada in the year one thousand
nine hundred and three, by D. E. Mundell, M.D., at the Department of Agriculture.

ERRATA.

- Page 36, 6 lines from foot *for* latter *read* latter glands.
- “ 57, line 7, *for* these same vessels *read* the same vessels.
- “ 82, 9 lines from foot omit *er*.
- “ 88, line 9, *for* limbs *read* limb.
- “ 102, line 3, *for* begin in the second or third phalanges, it may as in the case of the first, *read* begin in the first or second phalanges, it may as in the case of the third.
- “ 104, *for* ligitated *read* ligated.
- “ 110, 4 lines from foot, *for* modified *read* a modified.
- “ 117, line 6, *for* lamina *read* laminæ.
- “ 119, line 12, *for* (Fig. 8) *read* (Fig. 9).
- “ 121, line 13 *for* dorsi muscles *read* dorsal muscles.
- “ 122, heading, *for* pessure *read* pressure.
- “ 123, 5 lines from foot, *for* surfeces *read* surfaces.
- “ 129, (Fig. 6) *for* pluræ *read* pleuræ.
- “ 133, 140, etc., *for* dilatation *read* dilatation.
- “ 165, line 11, *for* poenings *read* openings.
- “ 179, line 13, *for* aponeuroses *read* aponeurosis.
- “ 182, line 2, *for* divisable *read* divisible.
- “ 185, 6 lines from foot, *for* a portion *read* and a portion.
- “ 192, line 15, *for* fascia *read* fasciæ.
- “ 215, line 4, *for* is often present *read* are often present.
line 16, omit *ance*.
- “ 233, 5 lines from foot, *for* intussesception *read* intussusception.
- “ 269, 9 lines from foot, *for* genital organs *read* genital organs).
- “ 287, 10 lines from foot, *for* passe *read* passes.
- “ 307, 3 lines from foot, *for* the margins of the saphenous opening *read* Poupart's ligament and the pectineal aponeurosis.
- “ 321, 14 lines from foot, omit (2).
- “ 349, 9 lines from foot, *for* operating them *read* operating on them.
- “ 356, 11 lines from foot, *for* swelling bilobed *read* swelling is bilobed.
- “ 409, line 12, *for* mtioned *read* mentioned.
- “ 434, *for* commisural *read* commissural.
- “ 426, (Fig. 12), visual radiation should be in front of hearing, etc.
- “ 432, 6 lines from foot, *for* Pons Variolii *read* Pons Varolii.
- “ 455, 13 lines from foot, *for* areolar *read* alveolar.

ERRATA

Page 10	Line 12	of	10
Page 11	Line 15	to	11
Page 12	Line 18	of	12
Page 13	Line 21	of	13
Page 14	Line 24	of	14
Page 15	Line 27	of	15
Page 16	Line 30	of	16
Page 17	Line 33	of	17
Page 18	Line 36	of	18
Page 19	Line 39	of	19
Page 20	Line 42	of	20
Page 21	Line 45	of	21
Page 22	Line 48	of	22
Page 23	Line 51	of	23
Page 24	Line 54	of	24
Page 25	Line 57	of	25
Page 26	Line 60	of	26
Page 27	Line 63	of	27
Page 28	Line 66	of	28
Page 29	Line 69	of	29
Page 30	Line 72	of	30
Page 31	Line 75	of	31
Page 32	Line 78	of	32
Page 33	Line 81	of	33
Page 34	Line 84	of	34
Page 35	Line 87	of	35
Page 36	Line 90	of	36
Page 37	Line 93	of	37
Page 38	Line 96	of	38
Page 39	Line 99	of	39
Page 40	Line 102	of	40
Page 41	Line 105	of	41
Page 42	Line 108	of	42
Page 43	Line 111	of	43
Page 44	Line 114	of	44
Page 45	Line 117	of	45
Page 46	Line 120	of	46
Page 47	Line 123	of	47
Page 48	Line 126	of	48
Page 49	Line 129	of	49
Page 50	Line 132	of	50
Page 51	Line 135	of	51
Page 52	Line 138	of	52
Page 53	Line 141	of	53
Page 54	Line 144	of	54
Page 55	Line 147	of	55
Page 56	Line 150	of	56
Page 57	Line 153	of	57
Page 58	Line 156	of	58
Page 59	Line 159	of	59
Page 60	Line 162	of	60
Page 61	Line 165	of	61
Page 62	Line 168	of	62
Page 63	Line 171	of	63
Page 64	Line 174	of	64
Page 65	Line 177	of	65
Page 66	Line 180	of	66
Page 67	Line 183	of	67
Page 68	Line 186	of	68
Page 69	Line 189	of	69
Page 70	Line 192	of	70
Page 71	Line 195	of	71
Page 72	Line 198	of	72
Page 73	Line 201	of	73
Page 74	Line 204	of	74
Page 75	Line 207	of	75
Page 76	Line 210	of	76
Page 77	Line 213	of	77
Page 78	Line 216	of	78
Page 79	Line 219	of	79
Page 80	Line 222	of	80
Page 81	Line 225	of	81
Page 82	Line 228	of	82
Page 83	Line 231	of	83
Page 84	Line 234	of	84
Page 85	Line 237	of	85
Page 86	Line 240	of	86
Page 87	Line 243	of	87
Page 88	Line 246	of	88
Page 89	Line 249	of	89
Page 90	Line 252	of	90
Page 91	Line 255	of	91
Page 92	Line 258	of	92
Page 93	Line 261	of	93
Page 94	Line 264	of	94
Page 95	Line 267	of	95
Page 96	Line 270	of	96
Page 97	Line 273	of	97
Page 98	Line 276	of	98
Page 99	Line 279	of	99
Page 100	Line 282	of	100

PREFACE

This book is published in the hope that it may assist the student in the practical application of the knowledge acquired in the anatomy class and in the dissecting room. For the sake of convenience, a brief resume of the anatomy pertaining to each section is included in the respective chapter, thus obviating the necessity of referring to the standard works on that subject.

CONTENTS.

	Page
CHAPTER I.	
The Region of the Clavicle.....	11
CHAPTER II.	
The Scapula.....	19
CHAPTER III.	
The Region of the Shoulder.....	21
CHAPTER IV.	
The Axilla.....	33
CHAPTER V.	
The Arm.....	50
CHAPTER VI.	
The Region of the Elbow.....	62
CHAPTER VII.	
The Forearm.....	73
CHAPTER VIII.	
The Wrist and Hand.....	89
CHAPTER IX.	
Lesions of Nerves of Upper Limb.....	108
CHAPTER X.	
The Thorax.....	112
CHAPTER XI.	
The Pleura.....	122
CHAPTER XII.	
The Lung.....	126
CHAPTER XIII.	
The Pericardium.....	132
CHAPTER XIV.	
The Heart.....	135
CHAPTER XV.	
The Mediastinum.....	145
CHAPTER XVI.	
Thoracic Aneurism.....	156
CHAPTER XVII.	
The Diaphragm.....	165

	CHAPTER XVIII.	
The Abdomen.....		169
	CHAPTER XIX.	
The Abdomen (Continued).....		176
	CHAPTER XX.	
The Inguinal		182
	CHAPTER XXI.	
The Liver and Gall Bladder.....		193
	CHAPTER XXII.	
The Stomach.....		207
	CHAPTER XXIII.	
The Intestines.....		219
	CHAPTER XXIV.	
The Kidneys and Ureters.....		239
	CHAPTER XXV.	
The Spleen.....		250
	CHAPTER XXVI.	
The Suprarenal Capsules and Pancreas		257
	CHAPTER XXVII.	
Abdominal Vessels and Regions.....		261
	CHAPTER XXVIII.	
The Pelvis.....		268
	CHAPTER XXIX.	
The Perineum		285
	CHAPTER XXX.	
Scarpa's Triangle and Femoral Hernia.....		301
	CHAPTER XXXI.	
The Gluteal Region.....		308
	CHAPTER XXXII.	
The Hip Joint.....		314
	CHAPTER XXXIII.	
The Thigh.....		326
	CHAPTER XXXIV.	
The Popliteal Space.....		344
	CHAPTER XXXV.	
The Region of the Knee Joint.....		352

	CHAPTER XXXVI.	
The Leg.....		365
	CHAPTER XXXVII.	
The Ankle Joint.....		380
	CHAPTER XXXVIII.	
The Foot.....		384
	CHAPTER XXXIX.	
The Head and Neck.....		397
	CHAPTER XL.	
The Meninges of the Brain.....		413
	CHAPTER XLI.	
The Cerebrum.....		419
	CHAPTER XLII.	
The Orbit ..		439
	CHAPTER XLIII.	
The Ear.....		445
	CHAPTER XLIV.	
The Nose, Mouth and Pharynx.....		451
	CHAPTER XLV.	
The Face.....		463
	CHAPTER XLVI.	
The Neck.....		471
	CHAPTER XLVII.	
The Spine.....		488

ANATOMY APPLIED TO MEDICINE AND SURGERY.

CHAPTER I.

THE REGION OF THE CLAVICLE.

ANATOMY.	APPLICATION
LANDMARKS.	DISLOCATION.
FUNCTIONS.	FRACTURE.

Anatomy.—The *clavicle* is a long bone, and consists of a shaft and two extremities. The shaft is somewhat twisted on itself, and, when viewed from in front, presents a double curvature. One curve corresponds to the inner two-thirds of the bone, and is convex anteriorly; whereas, the other, representing the outer third, is concave anteriorly. The twist in the bone occurs about the junction of these curves, since it is here that the cylindrical-shaped inner portion with its three surfaces—anterior, posterior and inferior—merges into the flattened, outer third with its two surfaces—superior and inferior. The clavicle articulates, externally, with the scapula at the acromio-clavicular joint, and, internally, with the sternum, at the sterno-clavicular joint.

The *acromio-clavicular joint* is an arthrodial or gliding joint; has, only occasionally, an inter-articular fibro-cartilage, and is surrounded by a capsular ligament; while the *sterno-clavicular articulation*, also arthrodial, has an anterior and a posterior ligament (the former more lax than the latter); an inter-clavicular, between the two clavicles; a rhomboid, between the clavicle and the cartilage of the first rib, and, lastly, an inter-articular fibro-cartilage.

Landmarks.—The subcutaneous portion of the *clavicle* corresponds to the whole length of the bone, and is better appreciated, by the examining finger, at the middle of the shaft than at either extremity, since it is encroached upon, at its inner end, by the sterno-mastoid, above, and by the pectoralis major, below, and, at its outer end, by the trapezius, above, and the deltoid, below. On grasping the bone between the finger and thumb, and then moving the hand along the shaft, the two curves are readily identified, while, on passing the finger downwards, immediately below the junction of these curves, a prominence is felt at the distance of about one inch from the clavicle. This prominence is the coracoid process, hidden, to some extent, by the inner margin of the deltoid muscle. This *coracoid process* is, therefore, best felt by pushing the finger backwards and outwards in the groove between the pectoralis major and the deltoid, at a point about one inch below the clavicle. The *acromio-clavicular* articulation is directed downwards and inwards, and lies in the plane of a vertical line passing up the middle of the front of the arm, when the latter hangs by the side. This joint may be identified by passing the finger along the clavicle towards the acromion process, near which is felt the enlarged and slightly knob-like outer end of the bone, and the joint is found lying immediately external to this prominence.

The *sterno-clavicular* articulation is V-shaped, with its apex corresponding to the point where the lower border of the articular surface of the clavicle rests on the cartilage of the first rib, and its sides, to the opposed articular surfaces of the clavicle and sternum. The characteristic shape of the joint is evident when the finger is sunk into the depression between the sternal end of the clavicle and the sternum, the head of the patient being flexed so as to

relax the sternal part of the sterno-mastoid, which passes across the inner side of the articulation. When the arm hangs by the side, the base of the V is widened, and hence the patient depresses the shoulder so as to enlarge the V when the joint is inflamed. A knife, inserted immediately external to the sternal portion of the sterno-mastoid muscle, will enter the joint.

Functions.—The *clavicle* acts as an outrigger or radius, with its centre at the sterno-clavicular articulation. It keeps the scapula, and, therefore, the upper limb, at a certain definite distance from the trunk, thus permitting the lateral or rotary movements of the shoulder. In addition, it supports the limb and affords, through its connection with the scapula, a permanent base for the movements of the humerus, for, if the clavicle were absent, the scapula would be unsupported and would be thrust, here and there, between the muscular planes, when the arm is in use. The *acromio-clavicular* joint permits those movements between the scapula and the clavicle that are necessary to secure the best effects of the former in relation to the head of the humerus, for, if there were no joint here, *i.e.*, if the two bones were united, then, although the humerus could rest firmly against the glenoid fossa in one position, it could not in another, since the absence of the joint would prevent the scapula being placed directly behind the head of the humerus in the different positions of the arm. Further, this joint allows the lower angle of the scapula to be approximated to the chest wall by the serratus magnus—thus increasing its power—when it is brought into play in such actions as supporting weights on the shoulder, etc. The *sterno-clavicular articulation* permits elevation, depression, adduction and abduction of the shoulder, as well as their combination, circumduction. In elevation and depression of the shoulder, the clavicle

moves on the interarticular fibro-cartilage, but, in adduction and abduction, the clavicle and cartilage together move on the sternum. The joint, therefore, acts as a pivot for the whole of the supporting arch of the shoulder. Elevation is due to the trapezius, the sterno-mastoid and the levator anguli scapulæ; depression, to gravity, assisted by the subclavius, pectoralis major, latissimus dorsi, pectoralis minor and the lower fibres of the trapezius; abduction to the rhomboidei, levator anguli scapulæ, middle fibres of the trapezius, and indirectly, to the latissimus dorsi; adduction to the pectoralis minor, the serratus magnus and the pectoralis major.

Application.—When the sterno-clavicular joint is inflamed, the swelling is early appreciated in front, partly because of the superficial situation of the joint, and partly from the fact that the anterior ligament is more lax than the other portions of the capsule. It is said that this joint, more than any other, is affected in pyæmia, possibly because every movement of the shoulder disturbs it, with the result, that there would be greater chance of the arrest of pus organisms in it. A patient suffering from inflammation of the sterno-clavicular articulation will lower the point of the shoulder, as much as possible, since such depression of the clavicle would increase the capacity of the joint by separating the sides of the V and thus lessen the pressure of the effusion on the sensitive nerves of the inflamed synovial membrane. In inflammation of this joint, the muscles controlling the movements of the scapula and clavicle will hold these bones as rigidly as possible, since any movement of them would affect the joint and thus cause pain. In this connection it is interesting to note that both the joint itself and the principal muscles controlling it are supplied by the same nerves. The trapezius, for instance, is supplied by the fourth cervical nerve, but

the fourth cervical sends a branch to the fifth, and the fifth supplies the joint through its branch, the subclavian nerve. Again, the serratus magnus, a powerful factor in the movement of the joint, is supplied by the external thoracic nerve, and this derives one of its roots from the fifth cervical nerve. *Pain*, in synovitis of the sterno-clavicular articulation, may be local, or may be referred to the shoulder or to the region of the clavicle through the descending branches of the superficial cervical plexus, which arise from the fourth cervical nerve and are, therefore, related to the joint by the branch from the fourth to the fifth nerve.

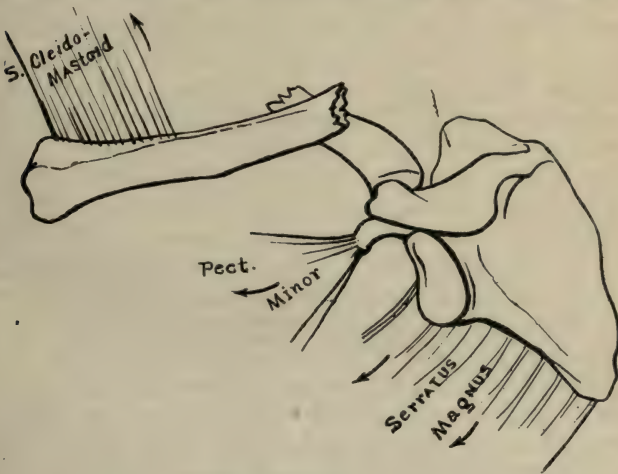
Dislocation at the *sterno-clavicular articulation* is very rare, since the tough unyielding ligaments bind the bones, firmly, together, and when it does occur, the sternal end of the clavicle is displaced, generally, forwards, as shown by Hamilton, who reported thirteen cases of sterno-clavicular displacement, of which eleven were forwards, and two upwards. *Acromio-clavicular joint*.—When dislocation is present at this joint, the acromial end of the clavicle is, as a rule, displaced on to the upper surface of the acromion process, since the oblique direction of the line of joint favors over-riding of the clavicle. The integrity of the coraco-clavicular ligament, and especially the trapezoid portion of it, prevents much lateral displacement, so that not more than half an inch of the clavicle, as a rule, rests on the acromion.

Fracture of the Clavicle, when complete, and when due to indirect violence, occurs, as a rule, at the junction of the outer and middle thirds of the bone. Vibrations, set up by a blow applied to the point of the shoulder, will alter their amplitude at the inner end of the outer third of the bone for the following reasons: (1) Since both the coraco-clavicular ligament and the trapezius mus-

cle are attached to this portion, it is more fixed than the longer, inner portion; (2) it is here that the two curves of the bone meet; (3) because of the change in the form of the bone, whereby the flattened, outer part blends with the cylindrical-shaped, inner portion. For these reasons, then, the direction and force of the vibrations are changed at this point, and the check to their onward course causes, in all probability, an expenditure of energy, which shows itself in the production of a fracture.

Deformity.—The inner fragment is slightly *elevated* by the sterno-mastoid overcoming the combined actions of the clavicular portion of the pectoralis major, the subclavius muscle and the resistance offered by the rhomboid ligament; whereas, the outer fragment, and with it the point of the shoulder, is drawn downwards and inwards and is rotated forwards. It is displaced, *downwards*, through gravity, assisted by the action (1) of the pectoralis minor on the coracoid process; (2) of the lower costal portion of the pectoralis major on the humerus, and (3) of the latissimus dorsi on the humerus. *Inwards*, by the pectoralis major and minor; by the rhomboidei and the levator anguli scapulæ; by the middle fibres of the trapezius and by the latissimus dorsi. *Forward rotation* takes place because of the action of the serratus magnus, which, normally, swings the point of the shoulder forwards through the circumference of a circle, the centre of which is the sterno-clavicular articulation (the radius of the circle being the clavicle); hence, if this radius be broken, the circle, described by the clavicle, will be less, so that the point of the shoulder moves forward, while the inner portion of the clavicle remains stationary (Fig. 1). Fractures of the clavicle, dependent on direct injury, are generally transverse, whereas, those due to indirect force are, as a rule, oblique and directed, generally, downwards and

inwards. If the fracture be situated at either end of the clavicle the displacement is, as a rule, inconsiderable, and, when occurring at the sternal extremity, it is advisable to bear in mind the fact that, although ossification occurs in this bone at an earlier period than in any other, yet the sternal end is cartilaginous until the age of eighteen, at which time a centre appears and unites with the rest of the bone about the age of twenty-five, hence, it is quite possible, in a patient under twenty-five, that the injury has caused a separation of the epiphysis, rather than a fracture. This *epiphyseal separation*, may be diagnosed, partly from the age of the patient, and partly from the fact that the inner end of the outer fragment would be smooth



(No. 1.)
Diagram illustrating Fracture of the Clavicle viewed from above.

and rounded, rather than sharply irregular, as it is in fracture.

In children, the seat of fracture is generally about the middle of the bone, since, in them, the curves are less dis-

tinct than they are in the adult, and, when a fracture of the clavicle does occur in childhood the break is generally incomplete, because of the greater elasticity of the osseous tissue and the thicker periosteum of the child, as compared with that of the adult. This is the so-called "greenstick" fracture.

A child may be brought to the surgeon with a history of a fall and a subsequent inability to use the arm. In cases of this nature, careful examination should be made over the clavicle for any point of tenderness. This examination should be thorough, since, often, the only indication of injury may be tenderness on pressure over a portion of the clavicle, generally the middle, for reasons given above. In children the fracture is, as a rule, incomplete, hence there will likely be no displacement, and so, if the surgeon, looking for displacement and finding none, treat the case lightly, the child may be brought back, some time afterwards, with a swelling involving the clavicle—the result of callus formation. *Pain*, in fracture of the clavicle, may be due to the sharp irregular ends of the fragments pressing on the skin, but, if the pain affect the upper limb, darting down it immediately after the accident, it is probably due to injury of the brachial plexus by the fragments. Should pain in the limb come on some days after the injury is inflicted, it will, likely, be due to callus formation pressing on the plexus, although it must not be forgotten that improper appliances, or imperfect bandaging, may have the same effect. The chief structures behind the clavicle that are liable to be injured in fracture of that bone are, the brachial plexus, the pleura or lung and the subclavian artery or vein, and, although the latter is protected to a great extent by the subclavius muscle, yet, cases are on record in which this vein has been injured, one such case being that of Sir Robert Peel (Ashurst).

CHAPTER II.

SCAPULA.

FRACTURES. EPIPHYSEAL SEPARATION.

Fracture of the Scapula is rare, and, when it does occur, may be of the body of the bone, of the neck, of the coracoid or of the acromion process. *Fracture of the body* depends, as a rule, on great force directly applied, because of the deep situation of the bone, and, when present, its recognition is difficult on account of the degree of swelling that rapidly ensues. Crepitus is not always evident, since the fragments may overlap, or, on the other hand, may be so much separated by the muscles attached to them that it would be almost impossible to elicit crepitation. To assist in the diagnosis of fracture of the body the posterior border and the inferior angle should be made as prominent as possible, and this may be done as follows: For the posterior border place the hand of the injured limb on the patient's opposite shoulder, and for the inferior angle have the arm of the injured side rest behind the back. By *fracture of the neck* is meant a fracture starting from the suprascapular notch and running down to the infraglenoid tubercle, so as to break off the whole glenoid fossa with the coracoid process attached. The extent of the deformity in this fracture will depend on whether the coraco-clavicular ligament, which holds the coracoid up to the clavicle, be torn or not. When the ligament is torn the deformity is quite evident, since the arm, with the separated fragment, will sink downwards, with the result that a depression occurs under the acromion, somewhat resembling the deformity in dislocation at the shoulder joint, although not so pronounced. Crepitus and the immediate recurrence of the displacement, whenever, after reduction, the arm is left unsupported, are the chief diagnostic features of this variety of fracture. A

prominent symptom of *fracture of the coracoid* is downward displacement when the process is broken off in front of the coraco-clavicular ligament. This displacement would be the result of the action of the pectoralis minor, assisted to a slight extent by the short head of the biceps and by the coraco-brachialis, but, when the fracture is situated behind the coraco-clavicular ligament, then the depression of the coracoid process would be inappreciable, since it would still be held up by the ligament.

When *fracture of the acromion* occurs in front of the acromio-clavicular joint, *i.e.*, when the tip of the acromion is broken off, there is no displacement of the arm, but if the acromion be fractured behind this joint, then the support, afforded by the clavicle, being partly removed, the scapula and arm fall, slightly, downwards, inwards and forwards. The deformity in this case would not be nearly so pronounced as in a fractured clavicle, although resembling it, since the coraco-clavicular ligament would still support the scapula.

Epiphyseal Separation.—It must not be forgotten that the scapula is developed from seven centres, two of which are for the coracoid and two for the acromion process; that the coracoid epiphysis joins the scapula about the age of fifteen, and that the acromial process joins after the age of twenty-two, hence in injuries under these ages, it is advisable to bear in mind that a separation or non-union of the particular epiphysis may be present, rather than a fracture, and one means of distinguishing a fracture of the scapula from epiphyseal separation, the result of arrested development, is that, in the latter case, each scapula would, in all likelihood, present a similar condition; whereas, in fracture, it would be the injured side, only, that would be affected.

CHAPTER III.

THE REGION OF THE SHOULDER.

ANATOMY.

ACTION OF MUSCLES.

LANDMARKS.

SYNOVITIS.

BURSÆ.

DISLOCATIONS.

ATROPHY OF DELTOID.

OPERATIONS.

The **Shoulder Joint** is an enarthrodial or ball-and-socket joint, and is composed of a humeral head, nearly hemispherical in form, pointing upwards, inwards and backwards, and articulating with the shallow glenoid fossa of the scapula. It is protected, from above, by an arch composed of the coracoid and the acromion processes with the coraco-acromial ligament uniting them. The capsular ligament which encircles the articulation is lax and does not maintain the joint surfaces in apposition, so that, were it not for the atmospheric pressure and the tonicity of the muscles, that, controlling the joint, are attached to the capsule, the humerus would be separated at least one inch from the glenoid fossa. The area of the articular end of the humerus is about three and a half times that of the glenoid fossa, and this arrangement, whereby a larger surface rests on a smaller one, permits great freedom of movement at the joint. The articular surface of the humerus is not exactly hemispherical, being longest in a direction, downwards and inwards from the upper end of the greater tuberosity, and consequently, elevation of the arm is freest in the reverse direction, viz., upwards and outwards, as evidenced by the ease with which the hand may be placed behind the head. In an antero-posterior direction the greatest movement is permitted when the arm is raised to a right angle, since this position allows the widest part of the head of the bone to be brought into play on the glenoid surface.

The Structures Surrounding the Joint, from without, inwards, are: The skin, supplied by the supra-acromial and circumflex nerves; next, the superficial and deep fasciæ, the latter blending with the fascia covering the infra-spinatus and the pectoralis major; then the deltoid, while, beneath this muscle and between it and the capsule of the joint, is a thin though strong layer of areolar tissue. To facilitate the movements of the deltoid over the head of the humerus, a synovial bursa is found in the substance of this areolar tissue, and is situated, therefore, between the capsule of the joint and the under surface of the deltoid muscle. This, termed the *sub-acromial bursa*, is somewhat lozenge-shaped, one extremity extending down the outer surface of the joint to about the level of the lower facet of the greater tuberosity; the other, upwards and inwards, beneath the inferior surface of the acromion, to a point about one inch from the free margin of that process. The *muscles* intimately connected with the joint are: Above, the supra-spinatus; behind, the infra-spinatus and the teres minor; in front, the subscapularis; below, the triceps and, within the joint, the biceps. These, with the exception of the biceps, are all attached to the capsular ligament by their under surfaces, and act as elastic ligaments for the joint, while, at the same time, they prevent the capsule and synovial membrane from being "tucked" in between the bones in the different movements of the joint.

The other muscles not directly connected with the articulation but of importance because of their action on it, are: The deltoid, the coraco-brachialis, latissimus dorsi, teres major, and the pectoralis major.

Actions of the Muscles controlling the shoulder joint: 1. The *supra-spinatus*, arising from the internal two-thirds of the supra-spinous fossa, and inserted into

the upper facet of the greater tuberosity, besides assisting in preventing displacement of the humerus upwards, acts, with the deltoid, in raising the arm from the side. 2. The *infra-spinatus*, from the inner two-thirds of the infrapinuous fossa, and inserted into the middle facet of the greater tuberosity, protects the joint, behind, and rotates the head of the bone, outwards. 3. The *teres minor* from the upper two-thirds of the posterior surface of axillary border of the scapula; into the lowest facet of the tuberosity, has the same action as the *infra-spinatus*. 4. The *triceps* by three heads—one, from the triangular depression below the glenoid cavity; a second, from the posterior surface of the shaft of the humerus above the musculo-spiral groove, and a third, from the same surface below the groove; into two fibrous lamellæ—one, occupying the posterior surface and the other, the substance of the muscle—which lamellæ, uniting, are inserted into the back part of the upper surface of the olecranon. This muscle protects the lower part of the shoulder joint, preventing displacement downwards and backwards, and extends the forearm, while its long head assists the *latissimus dorsi* and *teres major* in drawing the humerus backwards. 5. The *deltoid* from the outer third of the anterior surface of the clavicle, from the outer margin of acromion and the lower lip of the posterior border of the spine of the scapula; into the middle of the outer surface of the shaft of the humerus, raises the arm to a right angle with the body, its anterior fibres assisting the *pectoralis major* in drawing the arm forwards, while its posterior, with the *teres major* and the *latissimus dorsi*, draw it backwards. 6. The *coraco-brachialis*, from the apex of the coracoid process in common with the short head of the biceps; into the middle of the inner surface of the shaft of the humerus, assists in elevating the arm, at the same time drawing it inwards and forwards. 7. The

latissimus dorsi, from the six lower dorsal, from all the lumbar and sacral spinous processes, and from the crest of the ilium and the three or four lower ribs; into the bottom of the bicipital groove of the humerus, draws this bone, backwards, at the same time rotating it inwards. It is the principal muscle brought into play in striking a downward blow. 8. The *teres major*, from the dorsal surface of the inferior angle of the scapula; into the posterior bicipital ridge, assists the *latissimus dorsi* in drawing the humerus, downwards and backwards, and also in rotating it inwards. When the arm is fixed, this muscle, with the *latissimus dorsi* and *pectoralis major*, draws the trunk forward. 9. The action of the *pectoralis major* will be considered when dealing with the axilla. 10. The *subscapularis*, from the inner two-thirds of the subscapular fossa; into the lesser tuberosity of the humerus, prevents displacement of the head of the bone forwards; rotates the head inwards, and, when the arm is raised, assists in drawing it downwards. Lastly, the *biceps*, by two heads—one, the longer, from the supraglenoid tubercle above the glenoid fossa, arches over the head of the humerus and passes down the bicipital groove to unite with the other, the shorter, which arises from the apex of the coracoid process in company with the coraco-brachialis. This union is, however, by means of a delicate areolar tissue, only (true union not occurring until about an inch above the beginning of the tendon of insertion where the fibres of the two heads interlace with one another). The biceps tendon, after giving off an expansion from its inner border to the fascia of the forearm, is inserted into the back part of the bicipital tuberosity of the radius. The tendon of origin of this muscle lies in the interior of the shoulder joint, but is outside of the synovial membrane, just as the round ligament of the liver is outside of the peritoneum,

though within the abdominal cavity, *i.e.*, the tendon occupies the free margin of a reflection of the synovial membrane of the joint. It is the main flexor and supinator of the forearm, and harmonizes the action of the two joints (shoulder and elbow), and, at the same time, passing as it does over the head of the bone, prevents it from being displaced or pushed up against the overhanging arch in extension of the arm.

Landmarks.—The landmark for the *shoulder joint* is a line drawn from the acromion to the coracoid process, and continued around to the lower margin of the head, as felt in the axilla, the arm hanging by the side, palm to the front, and the guide to the situation of the *head* of the bone is the internal condyle which points in the same direction as the head. This fact is of assistance in the recognition of the situation of the head of the bone in dislocation at the shoulder joint. The landmark for the *bicipital groove* is the upper part of a line drawn up the middle of the front of the arm, when the latter hangs by the side, palm to the front, and the *lower limit* of the *synovial membrane* surrounding the biceps tendon will correspond to where the anterior border of the deltoid crosses this line. This groove may be readily felt by pressing on the front surface of the head of the bone and at the same time rotating the humerus. When the tendon of the biceps, occupying the groove, reaches the head of the humerus (following the tendon from below, upwards), it turns inwards to arrive at the glenoid rim, and this latter part of the tendon corresponds to the middle of the coraco-acromial ligament, which lies between the coracoid and the acromion processes.

Synovitis.—In inflammation of the shoulder joint, *i.e.*, synovitis, the arm is somewhat extended, drawn backwards, and rotated, slightly, inwards. This position may

be the result of the contraction of the muscles controlling the humerus, especially the deltoid and the latissimus dorsi, the former extending the arm, and the latter, while opposing to some extent this action of the deltoid, drawing the humerus backwards and rotating it as above. Another explanation is that the cavity of the joint contains the greatest amount of fluid when the arm is in the above position, and hence that the arm assumes this position, in synovitis, to lessen the irritation caused by pressure on the sensitive nerves of the synovial membrane of the joint. The laxity of the capsule of the shoulder joint permits the effusion, in synovitis, to produce distention, appreciable externally, just below the acromion process, and, internally, well up in the axilla. On placing the fingers of one hand on the swelling below the acromion and those of the other on the swelling in the axilla, fluctuation is evident, *i.e.*, a wave may be propelled from one hand to the other. This assists in diagnosing synovitis of the shoulder joint from *inflammation* of the *subacromial bursa*, since in the latter, while there would be swelling under the acromion, there would be none in the axilla, and, therefore, no fluctuation between these points could be elicited.

Bursae.—Besides the *subacromial bursa*, already referred to, there is one *beneath the subscapularis*, and near its insertion, which communicates, as a rule, with the joint, hence, in synovitis with much effusion, this bursa is distended and can be felt well up in the axilla along the posterior or scapular wall. *Another bursa* lies under the tendon of the *infra-spinatus*, and, when it communicates with the joint, which it occasionally does, produces a swelling, posteriorly, below the spine of the scapula, when the joint is filled with fluid. Lastly, under similar circumstances, a prominence appears in front of the upper part of the arm, because of the projection of the synovial membrane

of the joint around the biceps tendon, which extension of synovial membrane reaches down the arm to a point about half an inch below the lower facet of the greater tuberosity. The swelling around this tendon is said to be bilobed, but the tendon does not lie in the middle of the prominence, rather to the outer side of it.

Dislocation at the Shoulder Joint.—The large head of the humerus, articulating with the shallow glenoid surface—an arrangement whereby the greatest amount of freedom is secured to the joint—really proves a source of weakness, as far as protection from dislocation is concerned. Besides, the joint is not strengthened by powerful ligaments as is the sterno-clavicular articulation, nor is it dependent for strength on bony interlocking as in the elbow joint, but relies for its integrity mainly on the muscles. These muscles are really elastic ligaments, though they differ from the latter in that they may be taken by surprise, as from unexpected strain, etc., hence it follows that a sudden, severe wrench, especially in certain positions of the arm, may cause displacement of the head of the bone. It is true that the overhanging arch composed of acromion, coracoid and the ligament joining them does, to some extent, strengthen the upper part of the joint, yet the muscles surrounding the articulation are its chief means of protection. There is, however, a portion of the capsule, its lower and anterior part, between the triceps, behind, and the subscapularis, in front, that is unsupported by muscles, and not only is this part unsupported, but is itself weak as compared with the rest of the capsule, since the coraco-humeral ligament strengthens the upper part of the capsule, and Flood's accessory band, the front part, and Schlemm's accessory ligament, the under part; so that, between the last two bands there is an unprotected portion of the capsule, and, it is on this

unsupported portion that the head of the bone, in extension, *i.e.*, elevation of the elbow from the side, rests, hence, sudden over-extension of the arm may cause the head of the humerus to distend and tear through this lower part of the capsule, and dislocation result. There are *three varieties of dislocation*, the subcoracoid, the subglenoid and the subspinous (a fourth is sometimes added, the subclavicular), and this arrangement corresponds to the relative frequency of the three forms of displacement. The head of the bone having left the joint will be found, in the *subcoracoid* form, resting internally on the neck of the scapula, close to the glenoid rim, and, therefore, beneath the coracoid process; in the *subglenoid* form, the head will be below and slightly in front of the glenoid fossa, resting on the anterior surface of the triceps; while, in the *subspinous*, it will lie on the posterior surface below the spine of the scapula. The production of the different forms may be understood by considering what happens when a person falls so that the palm comes in contact with the ground, the arm at the same time being extended and adducted or abducted. In the first case, the arm, acting as a long lever, dislodges the head of the bone from the glenoid fossa, and, at the same time, the momentum of the body, continuing, drives it (the body) onward, so that the head is displaced backwards—*subspinous* form. This displacement of the head backwards may be assisted by the action of the latissimus dorsi. Should, however, the patient have saved himself sufficiently, so that, after dislocation, there would be no onward propulsion of the body, and should the action of the latissimus dorsi neutralize that of the pectoralis major, then the head remains where it was first displaced, *viz.*, in the *subglenoid* position. When, however, the patient falls, with arm extended and abducted, then the bone, on rupturing the capsule, is driven for-

wards, partly from mechanical causes and partly from the contraction of the pectoralis major, with the result that the *subcoracoid* displacement is produced.

Symptoms of Dislocation.—In each variety of dislocation the following symptoms are present: 1. *Flattening of the shoulder*.—If the finger of the surgeon be passed downwards from the acromion, in examining a normal arm, it comes in contact with the greater tuberosity. This, along with the head of the bone beneath the deltoid, forms the graceful outline of the prominence of the shoulder. In dislocation, however, with the head absent from its normal position, the finger feels a marked depression below the acromion. 2. *The elbow is abducted, i.e.,* raised from the side, and the patient cannot voluntarily press it inwards so as to touch his side, and if the surgeon attempts it, it springs out again. This is due to the tension of the deltoid, the supra-spinatus and the untorn part of the capsular ligament, since in each variety these structures are put on the stretch. In addition to the above, we find, in the *subglenoid* form, other muscles more or less affected, such as the subscapularis and the infra-spinatus, which are overstretched and tense; the biceps is rigid, thus producing flexion with supination of the forearm, or it may possibly be torn out of the groove, increasing, therefore, the present deformity and interfering with the future usefulness of the arm; while the teres major, teres minor and the latissimus dorsi are more or less relaxed. In the *subcoracoid dislocation* the deltoid, supra-spinatus and biceps are as tense as in the subglenoid, and the additional structures affected would be the subscapularis, pushed up and tense, or possibly wrenched from the lesser tuberosity; while the infra-spinatus and the teres minor are overstretched. The axillary nerves and vessels are more liable to be injured in this form than in either of the

other varieties. In the *subspinous* form, in addition to the condition of the deltoid, supra-spinatus and biceps, above described, the subscapularis is stretched across the empty glenoid fossa, the infra-spinatus is tense, so, too, are the pectoralis major and the latissimus dorsi, but the teres major and teres minor, however, are relaxed. In each form, then, the elbow is abducted, but in the *subcoracoid* variety, the head being in front of the joint, the elbow is *posterior* to the midaxillary line, partly because of the shape of the bony surface on which the head rests and partly from the traction of the latissimus dorsi and the posterior fibres of the deltoid. In the *subspinous* form, the head being behind the joint, the elbow is *anterior* to the midaxillary line, due partly to the contour of the bony surfaces in contact with one another, and partly to the traction of the pectoralis major and the anterior fibres of the deltoid; whereas, in the *subglenoid*, the elbow occupies a *midposition*, i.e., about the midaxillary line. 3. *Dugas' sign*.—In a normal arm, if the elbow be placed on the side of the chest, the hand can rest on the opposite shoulder. When, however, dislocation occurs, this is impossible, and may be explained as follows: The humerus represents a straight line, and the thorax, a circle, and, therefore, since the humerus touches the thorax at one point it cannot at another, hence it is impossible for the elbow to touch the chest wall, in dislocation, except from the application of considerable force. 4. If a *straight edge* be applied along the outer aspect of the normal arm, it lies about half an inch outside of the acromion process, since the head of the bone projects that much beyond the acromion. When, however, a displacement occurs, the straight edge, not resting on the head of the bone, will touch the acromion.

To distinguish between a dislocation at the shoulder joint and a fracture of the surgical neck of the scapula, the following points will assist:

Signs of Dislocation.	Signs of Fracture of Neck of Scapula.
Flattening below acromion.	Flattening below acromion.
Head felt in axilla or elsewhere.	Head felt in axilla.
Arm held directly or obliquely outward.	Arm hangs vertically.
Dugas' sign holds good.	Dugas' sign does not hold good.
Straight edge touches acromion.	Straight edge touches acromion.
No bony crepitus.	Bony crepitus.
When reduced remains in position.	When reduced is spontaneously displaced when unsupported.
Coracoid process normal position.	Coracoid moves separately from scapula.

The rent in the capsule is generally at the lower and anterior part, as above mentioned, although Hamilton states that in subspinous dislocations the head of the bone may leave the cavity, posteriorly, between the infra-spinatus and the teres minor.

Atrophy of Deltoid Muscle.—Impaired action of the arm may be caused by *atrophy of the deltoid muscle*, the result of injuries to the circumflex nerve from blows, falls, etc., or from pressure and laceration by the head of the bone in dislocation. In the former instance, it may be subsequent to a blow or fall, directly injuring the circumflex nerve, where it winds around the humerus, or causing inflammation and swelling of the muscle, which would compress the nerve; in the latter, it would be due to the head of the bone pressing directly on the nerve. It is worthy of note that the joint, the muscle chiefly affecting the joint, *i.e.*, the deltoid, and the skin over it, have a common nerve supply, *viz.*, the circumflex. This relationship holds good also for the supra-acromial nerve, which supplies the skin over the upper part of the deltoid muscle, since the fourth cervical forms the supra-acromial, and the fourth sends filaments through the fifth to the circumflex nerve.

Operations.—*Excision of the shoulder joint* is done through an incision starting from the beak of the coracoid process and running downwards and outwards to avoid the cephalic vein which lies between the deltoid and pectoralis major. The incision is parallel to the fibres of the former muscle, is four inches in length and close to the inner border of the muscle. The capsule and periosteum are next divided on the outer side of the biceps tendon. An assistant rotates the arm inwards and the surgeon detaches the periosteum, capsule and tendons from the greater tuberosity. The biceps is raised out of its groove, and, with the arm rotated outwards, the subscapularis and the capsule are separated from the lesser tuberosity, and the head of the bone removed.

Disarticulation at the Shoulder Joint.—To avoid hæmorrhage in this operation, apply an elastic tourniquet through the axilla, and clamp or tie it above the shoulder, and then make a circular incision around the arm, a little below the anterior border of the axilla. After retraction of the skin, the soft parts are separated from the bone and the axillary artery and vein ligated at the level of the transverse line of section. A vertical incision is now made, from the outer side of the coracoid process, down to the lower incision, and the bone disarticulated.

CHAPTER IV.

AXILLA.

ANATOMY.	STRUCTURES.
ACTION OF MUSCLES.	LANDMARKS.
AXILLARY FASCIAE.	OPERATIONS.

Anatomy.—The axilla is a space, irregularly pyramidal in form, and serves for the passage of delicate structures to and from the trunk. It has a base, an apex, and four unequal sides. The *base* is directed downwards, and is protected by the integument and superficial fascia and by a strong layer of fascia, "*axillary fascia proper*," passing from the lower border of the pectoralis major backwards to the lower border of the latiss. dorsi. The base is wide internally, but narrow externally on account of the convergence of these muscles towards their insertion into the humerus. The *apex*, directed upwards, corresponds to the triangular interval between the first rib internally, the clavicle anteriorly and the upper border of the scapula posteriorly.

Through it the axillary artery, the brachial plexus of nerves, and the external respiratory of Bell enter, while the axillary vein and the lymphatics leave the axilla.

Boundaries.—In front the axilla is bounded by the integument, fasciae, the pectoralis major, pectoralis minor, clavipectoral fascia and the subclavius muscle; internally, by the four or five upper ribs with the intercostal muscles between, and by the corresponding serrations of the serratus magnus. Postero-externally the structures are the subscapularis, the teres major and the latiss. dorsi, while externally are the humerus, the coracobrachialis and the biceps muscle.

Muscles.—The *pectoralis major* is worthy of more than a passing notice because of the peculiar manner of

its insertion and the practical application thereof. It is a triangular muscle with the base internally and the apex externally, and is composed of two distinct parts—one attached to the anterior surface of the sternal half of the clavicle—the clavicular portion, and the other—the chondro-sternal portion, to half the breadth of the sternum, the cartilages of the true ribs with the exception of the 1st, 7th, etc. The interval between these portions is more or less distinct, and may be represented by a line drawn from the sterno-clavicular articulation, when the arm is at right angles to the body, to the middle of the two condyles of the humerus. This muscle is inserted into the anterior bicipital ridge of the humerus by means of a broad tendon composed of two flat planes, or lamellae—an anterior and a posterior. The anterior—the thicker—receives the clavicular portion of the muscle as well as the upper half of the chondro-sternal portion, and the fibres are inserted into this anterior lamella in the order of their origin from clavicle and sternum. Passing obliquely downwards and outwards, the anterior lamella crosses, in a manner somewhat like the letter "X," the posterior lamella which passes obliquely upward and outward. The posterior lamella has inserted into it the lower half of the chondro-sternal portion and in addition some deep fibres from the cartilages of the 5th and 6th ribs.

This crossing of the planes permits the upper fibres to be inserted as low down on the humerus as the insertion of the deltoid, while the lower fibres of the muscle are inserted as high up on the bone as the subscapularis, *viz.*: about half an inch below the lesser tuberosity. This is brought about by means of a twisting of the fibres of the lower part of the muscle, and especially of the deep fibres. The above is the usual arrangement, though it is subject to considerable variation, as, for instance, on two

occasions I have found the posterior lamella formed by the deep fibres only, the rest of the muscle forming the anterior lamella. This arrangement serves a useful purpose in elevating the arm, for, if the muscle were inserted in the usual manner, *i.e.*, if there were no twist, it would be impossible to raise the arm beyond a right angle, because the lower fibres would allow only a limited amount of elevation, but, with the twisting, the lower fibres being inserted higher up on the humerus than the upper, steady the head of that bone just as the biceps does, and thereby assist the upper fibres, which are inserted lower down, in raising the arm. From the insertion of the anterior lamella a band of fascia is sent to join the deep fascia of the arm and, from the posterior lamella, another band is prolonged upwards over the biceps tendon holding it in position in the groove.

Other actions of the pectoralis major are: anterior adduction, *i.e.*, drawing the arm inwards and forwards across the chest, and slight inward rotation of the humerus. Acting from below, it raises the body and, with the arm fixed, acts as a muscle of forced respiration.

The function of the *pect. minor* arising from the 3rd, 4th and 5th ribs near their cartilages and inserted into the inner border of the coracoid, is to draw the shoulder downwards, forwards and inwards. The latter action, *i.e.* inwards, is very limited unless the clavicle be broken, since this bone acts as an outrigger and keeps the scapula at a definite distance from the sternum, hence this inward movement of the shoulder from the action of the *pect. minor* is produced by rotation of the scapula at the acromio-clavicular articulation. The *serratus magnus* carries the scapula *i.e.* the shoulder forward and causes rotation of this bone at the acromio-clavicular articulation,

and in addition it produces movement of the clavicle at the sterno-clavicular joint. It consists of two fan-shaped portions—the upper with its apex forward at the 1st and 2nd ribs and its base attached to the upper angle and vertebral border of the scapula—the lower with its base forward connected with the ribs from the 2nd to the 8th and its apex attached to the inferior angle. We have seen that the deltoid can extend the arm, but it cannot raise it beyond a right angle with the body, any further elevation of the arm must be done (1) by rotation of the scapula at the acromio-clavicular articulation, (2) by circumduction of the clavicle at the sterno-clavicular articulation and (3) by elevation of the humerus by means of the crossed fibres of the pect. major. These movements of rotation and circumduction are brought about partly by the lower fibres of the trapezius but chiefly by the action of the serratus magnus, and especially by its lower fibres which draw forward and upward the lower angle of the scapula. The serratus magnus assists the deltoid in raising the arm in another manner, viz., by steadying the scapula, thus giving the humerus a base from which to act. Paralysis of the serrati muscles prevents the above actions, and by allowing the inferior angles of the scapulae to project, produces a condition known as “angel-wing” deformity.

Base of the axilla.—The skin covering the base of the axilla is pigmented and has numerous sebaceous and some tubular glands which give in some people a disagreeable odor. The latter are rudimentary and for this reason it is possible for malignant disease to start in them. Beneath the integument which is supplied by the intercosto-humeral nerve and by some of the lateral cutaneous branches of the intercostals, is the superficial fascia in which, when present, the superficial external mammary

runs from the axillary artery towards the thorax. The base of the axilla is completed by the deep fascia, which is a strong dense layer called the

“Axillary fascia proper” and is formed by the union of three planes of fascia; two prolonged from the pectoralis major and one from the pectoralis minor, and these three uniting, stretch across the base of the axilla to the border of the latiss. dorsi muscle. The two layers from the pectoralis major are the *superficial* and the *deep pectoral* fascia, *i. e.*, the one in front and the one behind the pectoralis major. These, attached to the clavicle above, are separated at their origin, by the pectoralis major but are united below at the lower border of the muscle. The layer of fascia from the lower border of the pectoralis minor is the continuation downwards of the clavipectoral fascia.

The *clavipectoral* fascia is attached above to the clavicle by two projections separated by the subclavius muscle. Following this fascia downward, it passes, curtain like, to the upper border of the pectoralis minor, hiding from view the axillary vessels and nerves. At the upper border of the pectoralis minor it splits, and one plane passes down in front of and the other behind this muscle. At the lower border of the pectoralis minor these unite and the layer formed by their union blends with that from the lower border of the pectoralis major above mentioned, to form the axillary fascia proper. The portion of the clavi-pectoral fascia between the clavicle and the pectoralis-minor, being attached internally to the cartilage of first rib and externally to the coracoid process, is termed the *costo-coracoid membrane*, and a part of this, thickened so as to constitute a white band, is termed the *costo-coracoid ligament*.

Thus the general axillary space may be subdivided in-

to two compartments, one bounded in front by the pectoralis major with its two layers of fasciae; behind by the clavi-pectoral fascia enclosing the pectoralis minor; above by the clavicle; and below by the union of the clavipectoral fascia with the fasciae of the pectoralis major; the *other* having the boundaries of the axilla proper, excepting in front where the pectoralis major is replaced by the clavipectoral fascia. The knowledge of these divisions of the axillary fasciae is of practical benefit in connection with *abscess* in this region. If the pus be in the anterior compartment it would be walled in by the boundaries above mentioned and from the influence of gravity would appear at the most dependent part, viz., along the lower border of the pectoralis major as a deep-seated ridge or swelling; or, if the patient remained more or less in the recumbent position, at the outer edge of the pectoralis major, *i.e.*, in the groove between the pectoralis major and the deltoid muscle.

Should, however, the collection be in the axilla proper it would be retained there by the boundaries of that space viz., anteriorly by the clavi-pectoral fascia enclosing the pectoralis minor, externally by the coraco-brachialis, the biceps and humerus, internally by the ribs, intercostals and serratus magnus, and postero-externally by the subscapularis, teres major and the latiss. dorsi. The base formed by the axillary fascia proper, and the posterior angle formed by the junction of the serratus magnus and the subscapularis prevent the passage of the pus by these routes. Hence the only outlet is the apex and through this the fluid may find its way under the clavicle and into the neck, or by following the blood vessels, into the mediastinum.

The Structures contained in the *axilla* are: lymphatic glands, axillary artery and vein with their branches,

brachial plexus of nerves, external respiratory nerve and the adipose tissue supporting these structures. The *glands* of the axilla, ten or twelve in number, are arranged in three sets, anterior, middle and posterior. The *anterior set* is situated on the serratus magnus close to the lower border of the pectoralis minor, *i. e.*, in the region of the long thoracic artery and receives the lymphatics from the anterior surface of the trunk as low down as the umbilicus. Any source of irritation such as mammary cancer, septic wounds, etc., in this territory will first affect this set. The *posterior group* is placed near the lower border of the latiss. dorsi along the course of the subscapular artery and receives the lymphatics from the back as low down as the iliac crest. The *middle set* are found along the axillary vein and therefore at the outer part of the axilla. These latter glands receive not only the lymphatics from the upper limb but those from the anterior and posterior groups as well, so that when, for instance, the anterior set is affected in mammary cancer, as the disease progresses the middle set becomes involved and through this the disease spreads to the cervical glands involving first, however, two or three subclavian glands in the deep subclavian triangle.

Blood Vessels.—Along the outer wall of the axillary space lie the main blood vessels for the upper limb, *viz.*, the *axillary artery* and *vein*. The artery ends at the lower border of the teres major and is therefore longer than the vein, which depends for its length on the point of union of its constituents, *i. e.*, the basilic vein and the venae comites. This union generally occurs in the neighborhood of the lower border of the subscapularis, hence the vein is from one to one and a half inches shorter than the artery. The artery begins where the vein ends, *i. e.*, at the lower border of the first rib and is divided into

three parts by the pectoralis minor, viz., the first part above, the second beneath, and the third below this muscle. The vein is also divided by the pectoralis minor into three parts, but these are numbered in the inverse order to those of the artery. When the arm hangs by the side the vein lies partly in front but chiefly to the inner side of the artery, but when the limb is at right angles to the body it overlaps the artery, *i.e.*, lies principally in front of it. Both artery and vein are enclosed in the axillary sheath, a prolongation downwards of the cervical fascia. The vein is adherent to this sheath and the sheath to the costo-coracoid membrane which lies in front of it. The artery supplies the muscles and adipose tissue of the axilla by means of the superior thoracic and acromio-thoracic branches from the first part; the alar and long thoracic from the second part; the subscapular and the anterior and posterior circumflex from the third part, while an occasional branch is given off to supply the superficial structures of the lower part of the thorax, viz., superficial external mammary artery.

The *adipose tissue* of the axilla is of a pinkish hue and is more granular here than elsewhere. It is of special support to the axillary vein, since oedema of the limb has occurred from phlebitis developing as the result of the removal of this tissue in the complete operation for the relief of mammary cancer.

The *nerves* of the axilla are derived from the brachial plexus by branches from the 5th, 6th, 7th, 8th cervical and first dorsal nerves. They form a plexiform network in the neck, but the plexus is narrow where it passes under the clavicle, and, about the coracoid, it breaks up into branches for the supply of the limb. The pectoral muscles are supplied by the anterior (internal and external) thoracics, the subscapularis by the upper and lower

subscapular nerves, the *teres major* by the lower subscapular nerve, the *latiss. dorsi* by the long subscapular nerve, the *teres minor* by the circumflex, the *subclavius* by a branch from the fifth cervical, and the *seratus magnus* by the posterior thoracic or external respiratory from the 5th, 6th and 7th, while the integument of this region is supplied by the lateral cutaneous branches of the intercostals, the intercosto-humeral and the supraclavicular and supra-acromial nerves.

The brachial plexus lies on the outer side of the first part of the axillary artery. It is here narrow but it soon divides and the union of the different branches forms the outer cord which lies on the outer side of the second part of the axillary artery and the inner and posterior cords which appear on the inner and posterior parts of the vessel respectively. Lastly, these cords divide and form the nerves of the upper limb which are situated with reference to the third part of the artery as follows:—

The median and the musculo cutaneous on the outer side, the ulnar and internal cutaneous on the inner side, the inner head of the median in front, and the musculo-spiral and circumflex nerves behind.

Landmarks of the Axilla.—The lower border of the *pectoralis major* corresponds to the line of the fifth rib. The origin of the *pectoralis minor* corresponds to a line drawn almost parallel to, and about three inches from, the middle line of the sternum, from the third to the fifth cartilages. The landmarks for the blood vessels are as follows: for the *axillary artery*, a line drawn from a little to the inner side of the middle of the clavicle, to the junction of the anterior and middle thirds of the antero-posterior fold of the axilla, or, to the inner side of the coraco-brachialis, or, when the arm is at right angles, to midway between the two condyles. (Fig. 2.)

The *axillary vein* as before mentioned lies mainly to the inner side of the artery with the arm by the side, and to the inner side but chiefly in front when the arm is at right angles to the body. The superior thoracic artery arises from the axillary above the upper border of the pectoralis minor and then runs along that border towards the thorax; the acromio-thoracic arises close to the upper border of the same muscle and the long thoracic runs along its lower border. Therefore the points where the upper and lower borders of the pectoralis minor cross the axillary artery would represent the points of origin of these branches and the lines for the borders would correspond to the course of the superior and long thoracic vessels. The *course* of the *superior thoracic* will be represented by a line drawn from the upper border of the third rib, starting about 3 inches from the mid-sternal line and ending about half an inch behind the beak of the coracoid process and the *origin* of the *acromio-thoracic* will correspond to the point where this line crosses the line of the axillary artery. The landmark for the *long thoracic* or deep external mammary will be a line drawn from the lower border of the fifth rib, starting about $3\frac{1}{2}$ inches from the mid-sternal line and ending about half an inch below the beak of the coracoid process. (Fig. 2.)

The lines for the *branches* of the *acromio-thoracic* are: for the *acromial branch*, a line drawn from the point of origin of the acromio-thoracic above mentioned, to the acromion process and passing over the coracoid process; for the *thoracic branch*, the same as for the superior-thoracic, and for the *descending branch*, a line drawn from the point of origin to the inner side of the insertion of the deltoid and corresponding to the groove between the deltoid and the pectoralis major. This latter line represents the course of the *cephalic vein* also, viz: from the inner side of the

tendon of the deltoid muscle to the point where the upper border of pectoralis minor crosses the axillary artery. The *subscapular artery* arises from the line of the axillary artery and passes down along the edge of the subscapularis muscle, *i.e.* about one inch above the lower border of the posterior fold of the axilla. The point of origin of the *dorsalis scapulae* is about one inch from the beginning of the subscapular artery. The line for the *circumflex arteries* corresponds to a line starting from the line of the axillary artery and passing around the surgical neck of the bone, *i.e.* about half an inch above the middle of the vertical axis of the deltoid muscle.

The landmark for the *posterior thoracic nerve* corresponds fairly well to a line drawn from the outer border of the sterno-mastoid muscle about on a level with the cricoid cartilage, crossing the clavicle a little to the inner side of its middle, and being continued downwards to the lower part of the mid-axillary line.

Operative work on the Axilla.—In operating on the axillary region it is well to bear in mind that the greatest depth of the axilla is when the arm is at an angle of 45° , and that, in examining the head of the humerus it is best felt with the arm close to the side so as to relax the axillary fascia proper. When the arm is abducted the axilla is rendered shallower, and the greater the amount of abduction, the greater the danger of the vein being wounded, since, in abduction, this vessel lies in front of the artery. In *opening an abscess* in the main cavity of the axilla or in the removal of diseased glands, the incision should be made midway between the anterior and posterior folds, *i.e.*, between the pectoralis major in front and the latiss. dorsi behind, and it should be nearer to the thoracic than to the humeral side of the base and, as a rule, the best method of opening an axillary abscess is

that of Hilton, which is carried out as follows:—A short incision is made through the integument and superficial tissue in the situation mentioned and a grooved director is thrust, with a boring movement, through the deep fascia into the axilla until pus finds its way along the groove. In making the above incision an artery lying in the superficial fascia might be wounded, viz. the superficial external mammary running across from the axillary artery to the thorax. Having established the presence and situation of the purulent collection a pair of artery forceps follows up the director, the blades are opened and withdrawn, thus enlarging the channel. This method is perfectly safe and may be employed in the case of all deep seated abscesses. If the knife were thrust into the axilla there would be danger of wounding some of the blood vessels with resultant hemorrhage, possibly of a serious character, before the surgeon could enlarge the wound and ligate the vessel. Thus, if the knife were entered at the anterior aspect of the axilla, the long thoracic which runs along the lower border of the pectoralis minor, and therefore near the lower border of the pectoralis major, might be wounded. If entered toward the posterior boundary, the subscapular, which lies about one inch above the lower border of the latiss. dorsi, or some of its larger branches might be injured; if too near the thorax, the external respiratory nerve might be severed with subsequent paralysis of the serratus magnus. If externally, the axillary vessels, and especially the vein, might be wounded. The incision above referred to should be employed in the *removal* of *lymphatic glands* from the axilla, and in this operation it is inadvisable to tear out a gland with the finger used as a hook through a small incision, since these glands, and especially those on the outer aspect, are intimately connected with the veins,

hence a large trunk might be opened with serious results. In the removal of adipose tissue or of lymphatic glands from the axilla it is best first to identify the axillary vein and work from it inwards, rather than in the reverse direction, since in the latter case the vein might be inadvertently wounded.

Operations on Axillary Artery.—*Compression.*

—The line of the axillary artery has already been referred to, and to compress it in the case of a wound of the vessel or of its larger branches the best situation is the third part, since the first part lies too deeply placed and has the pectoralis major as well as the dense costo-coracoid membrane in front of it, while in the second part the pectoralis major and minor prevent the employment of sufficient force to compress it, and besides, there is nothing sufficiently prominent behind the artery in this second part to compress it against, whereas in the third part the artery lying to the inner side of the humerus may be compressed by means of the fingers or a pad pressing outwards against the bone, and the guide to this part of the vessel is the inner side of the humerus just behind the coraco-brachialis at the upper part of the arm. When pain or numbness down the arm results from this compression of the artery it is due to the pad or fingers pressing on the nerves in the vicinity of the vessel, viz., the trunk of the median which lies on the outer side above or the inner head of this nerve crossing and therefore lying in front of the artery. On the inner side of the vessel the pain might be due to pressure on the ulnar, the internal cutaneous or the musculo spiral nerves. *Ligation* of the artery is never performed on the second part of the vessel, as it lies too deeply situated beneath the pectoralis major and minor, nor is it advisable to attempt ligating it in the first part of its course for reasons

to be dealt with shortly, so that the third part is the portion elected for the purpose of ligation. The ligature has occasionally been applied to the first part in the following manner: an incision starting from a point one-half inch external to the sterno-clavicular articulation is carried in a semi-lunar direction, with concavity upwards, to a point half an inch from the beak of the coracoid process dividing skin, superficial fascia, root of platysma, superficial pectoral fascia, pectoralis major and deep pectoral fascia. Before incising the pectoralis major avoid the cephalic vein which crosses the outer angle of the line of incision. The sides of the wound are now retracted and the pectoralis minor and the costo-coracoid membrane exposed. The point where the cephalic vein pierces this membrane to enter the axillary vein is the guide to the artery. It is impossible to incise the costo-coracoid membrane however, at this point, since the vein lies in front of the artery and is adherent to the axillary sheath, and the axillary sheath is adherent to the costo-coracoid membrane. Should an attempt be made to open the fascia here, the incision into the membrane would likely open up the vein, and we would have a severe hemorrhage occurring from the bottom of a deep funnel-shaped wound, a wound in which there would be great difficulty in compressing the opened vein. Besides, the wound in the vein would be kept patulous, since its union to the rigid costo-coracoid membrane would prevent any retraction or occlusion of the vessel, and further, there would be grave danger of the entrance of air into the circulation on account of the "suction" action of respiration on a vessel which is in close proximity to the thorax and in which there is an open wound. Hence the opening in the membrane should be made at some distance from the vein, preferably nearer the coracoid

process and therefore away from the vessel, although in this situation there would be a possibility of mistaking one of the large trunks of the brachial plexus for the artery. With the above dangers in view one can readily understand that ligation of the first part of the axillary artery is rarely attempted, besides, when the wound of the vessel or of its branches is in such a position as to necessitate the application of a ligature to the artery high up, it is much safer and easier to ligate the third part of the subclavian artery than it is the first part of the axillary.

Ligation of the third part of the axillary is done through an incision two inches in length made in the course of the vessel, and about the junction of the anterior and middle thirds of the antero-posterior fold of the axilla. The skin and superficial fascia having been incised, the deep fascia is exposed and carefully divided and the deep landmarks sought for. These are the relations to the vessel of the coraco-brachialis muscle and the median nerve which lie to its outer side, and of the axillary vein and ulnar nerve that lie to the inner side of the artery. Should a nerve present itself in the incision it may be the median or the ulnar and gentle traction will tell which it be, for, if the median, it will be felt by the finger placed on the inner side of the biceps tendon at the bend of the elbow; if the ulnar, by the finger behind the internal condyle. Should it be the median nerve then the vessel must be sought for on the inner side of the nerve; if the ulnar, the artery will be found external to it, while if the vein present itself, the artery will be found on the outside of it also. It must not be forgotten that the median nerve occasionally lies over the vessel in this situation, and the pulsations of the artery being conveyed to the nerve may cause it to simulate the vessel. When the identity of the artery has been established it should be

ligated by passing the needle from the ulnar toward the radial side. In ligating this part of the axillary artery it will be well to bear in mind the occasional existence of a muscular slip stretching across the artery from the latiss. dorsi to the biceps or to the coraco-brachialis, since the presence of muscular tissue might confuse the operator, but the direction of the fibres and the width of the band would distinguish it. Again, it is advisable in ligating the axillary to remember that in 10 per cent. of cases there are two large trunks, one of which forms the brachial while the other is for the origin of the circumflex, thoracics, etc. In these cases the nerves would surround the latter branch and so be useless as guides to the trunk to be ligated. The *collateral circulation* after ligature of the axillary artery above the origin of the subscapular and circumflex branches consists in the anastomoses of the posterior scapular and suprascapular from the subclavian above with the subscapular and circumflex from the axillary below and of the thoracic branches of the intercostals with the subscapular. If ligated below the circumflex the circulation would be carried on by the anastomoses of the circumflex and super. profunda arteries as well as by new channels from the subscapular above to the super. profunda below. To expose the *subscapular artery* an incision should be made a little above the anterior border of the latiss. dorsi, and the artery would be found, as already mentioned, about an inch above that border having the lower subscapular nerve below, the long subscapular above, and the subscapular vein in front. To expose the *circumflex artery* and nerve, make an incision along the posterior border of the deltoid with its centre corresponding to where this border crosses the axillary border of the scapula. When the muscle is exposed its posterior border is drawn outward, and the

artery with the nerve lying above it is found emerging from the quadrangular space bounded by the *teres major* below, *teres minor* above, scapular head of the *triceps* internally, and the *humerus* externally. The operation of stretching the lower part of the *brachial plexus* is not often performed but may be done by means of the same incision as employed in the ligation of the third part of the *axillary artery*.

CHAPTER V.

THE ARM.

ANATOMY.
LANDMARKS.

OPERATIONS.
FRACTURES.

Anatomy.—The *nerves supplying* the superficial fascia and integument of the arm are the following : on the inner side of the biceps,—the internal cutaneous ; more internally, the intercosto-humeral and the nerve of Wrisberg, while on the outer and posterior aspects are the cutaneous branches of the circumflex and musculo-spiral nerves. Beneath the superficial is the *deep fascia* which receives expansions from the pectoralis major and latiss. dorsi on the inside, and from the deltoid on the outside. This fascia is thin over the biceps, thicker over the inner aspect of the arm, thickest over the triceps posteriorly, and surrounds the individual muscles forming sheaths for them. The deep fascia separates the muscles on the anterior from those on the posterior surface by means of two septa called the intermuscular septa—external and internal. The former is attached to the external condyloid ridge and extends from the insertion of the deltoid above to the external condyle below ; the latter to the internal condyloid ridge from the insertion of the coracobrachialis above to the internal condyle below. The *external septum* is pierced by the musculo-spiral nerve and superior profunda artery about two inches above the external condyle, and the *internal* by the inferior profunda artery and ulnar nerve, a little below the middle of the arm, and by the anastomotica magna about two inches above the internal condyle. By means of these openings the, closed spaces of the posterior communicate with those of the anterior surface of the arm.

The action of the biceps, arising by its long head from the same structure as the long head of the triceps, viz., the cartilaginous rim of the glenoid fossa, and by its short head from the apex of the coracoid process, and inserted into the bicipital tuberosity of the radius, is to flex the forearm. Continuing its action it flexes the arm, and, on account of its insertion into the posterior part of the bicipital tuberosity, it rotates the radius outwards, *i.e.* it supinates the hand. The expansion of fascia given off from the inner border of the biceps tendon to the fascia of the forearm brings the muscle into direct connection with the fascia of the forearm, and, since some of the flexor muscles arise from the under surface of the deep fascia of the forearm, traction on this fascia by the biceps would tend to induce a slight degree of tension of these flexor muscles, consequently flexion of the forearm by the biceps would be associated with, and the cause of, a slight degree of flexion of the fingers, and one can notice that flexion of the forearm is slightly easier with the fingers flexed than when they are extended so that the grasping power of the fingers is increased by the biceps in such actions as climbing a pole, etc.

The action of the coraco-brachialis has already been considered, while the *brachialis anticus*, from the lower half of the outer and inner surfaces of the humerus into the coracoid process of the ulna, flexes the forearm. These muscles are supplied by the musculo-cutaneous nerve, the brachialis anticus receiving in addition a few filaments from the musculo-spiral.

In the case of the *triceps*, the actions of which have already been considered, there is an expansion of fascia given off from the outer side of its tendon to blend with the fascia of the extensor aspect of the forearm, and since this fascia gives origin to some of the extensor muscles,

extension of the forearm by the triceps is associated with a very slight degree of extension of the fingers in a manner similar to the flexion of the fingers described in connection with the biceps muscle. The *subanconeus*, in reality a few of the lower fibres of the triceps, is inserted into the posterior ligament of the elbow joint and draws this ligament up and out of the way during contraction of the triceps.

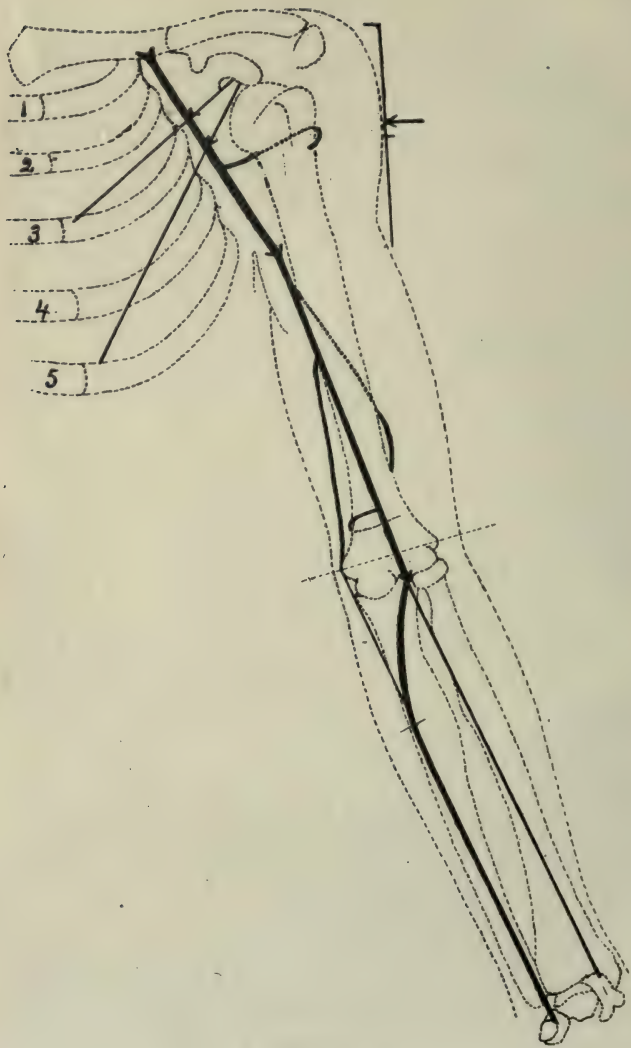
Landmarks of the Arm.—*Arteries.*—The main artery, the *brachial*, lies along the inner aspect of the arm, and its course is indicated by a line drawn from the junction of the anterior and middle thirds of the antero-posterior fold of the axilla to midway between the condyles of the humerus. The landmarks for the chief branches of the brachial artery are,—for the *superior profunda* a line starting from the line of the brachial artery on a level with the lower border of the latiss. dorsi or post-axillary fold, and passing round the arm so as to cross the middle of the shaft of the humerus posteriorly and emerge on the anterior surface about two inches above the external condyle; for the *inferior profunda*, one starting from the brachial line about the middle of the shaft and running downwards and inwards to the fossa between the internal condyle and olecranon, while for the *anastomotica magna* the line starts from the line of the brachial about one and a half inches above the int. condyle and passes transversely inwards around the arm.

Veins.—The *basilic vein*, formed by the union of the ulnar and the median basilic veins, passes up the arm to unite with the vena comites of the brachial artery at the lower border of the subscapularis so as to form the axillary vein. The basilic is represented by a line drawn from a point one half inch inside of the biceps tendon on a level about half an inch above the internal condyle to the line of the brachial at the upper part of the arm.

The *cephalic* is formed by the radial and the median-cephalic veins, and, after passing up on the outer side of the biceps muscle to the groove between the deltoid and the pectoralis major, in which groove it runs nearly as high as the clavicle, it pierces the costo-coracoid membrane to enter the axillary vein. Its course agrees with a line starting on the outer side of the biceps tendon, on a level with the external condyle and carried upwards to the groove between the deltoid and the pectoralis major, and then along this groove to the clavicle.

Nerves.—*Median.*—The landmark for the *median* is a line drawn downwards, starting from a point, close to the outer side of the upper part of the line for the brachial artery, crossing the artery about the insertion of the coraco-brachialis, *i.e.*, about the middle of the shaft of the humerus, and terminating, about half an inch inside of the tendon of biceps at the bend of the elbow. *Ulnar*, a line running down the inner side of the brachial line, leaving the latter about the middle of the arm and passing obliquely inwards to the posterior surface of internal condyle. *Musculo-cutaneous*, a line starting from the outer side of the axillary line, about one inch below the coracoid process, and passing obliquely, downwards and outwards, to a point on the outer side of the biceps tendon, one inch above the external condyle. *Musculo-spiral*, a line beginning at the inner side of the brachial line, about on a level with the lower border of the latiss. dorsi, and passing around the back of the arm, to terminate, about two inches above the external condyle.

The *lymphatics*, continued upwards from the forearm, pass mainly along the region of the brachial artery to terminate, above, in the axillary glands surrounding the axillary vein. On the outer aspect, a smaller number follow the line of the cephalic vein, and while the majority of these end



(Fig. 2.)
Landmarks for Arteries.

in the subclavian glands, a few cross the biceps, above the middle of the arm, to end in the axillary glands. The chief *lymphatic glands* of the arm are found in connection with the deep lymphatics, which accompany the brachial artery, although a few are situated in the superficial tissues in front, and, above, the internal condyle. *An analysis of the landmarks of the arm* shows, that the *middle of the shaft of the humerus* corresponds (1) to the insertion of the deltoid on the outer side, and (2) to that of the coracobrachialis on the inner side of the arm; (3) to the point where the lines for the inferior profunda artery and ulnar nerve leave the line of the brachial artery; (4) to about where the basilic vein and the internal cutaneous nerve pierce the deep fascia (in reality this point is one-half inch below the middle of the shaft); (5) to where the musculospiral nerve and the superior profunda artery cross the posterior surface of the humerus; (6) to the situation of the nutrient artery; (7) to the junction of the prismatic upper part of the humerus with the flattened lower part; (8) to where the median nerve crosses the brachial artery; and (9) to where the brachial artery is usually compressed or ligated.

Operations: *On the nerves of the arm.* To expose the *ulnar nerve* in the arm, for the purpose of stretching it, an incision should be made, beginning about three inches above the internal condyle and running, downwards, and, inwards, along the course of the nerve. After dividing the integument and the superficial and deep fasciae, the pulsations of the inferior profunda artery will be evident, and this artery forms the deep guide to the nerve, which will be found lying to the inner side of the vessel. To expose the *median nerve*, an incision may be made in any part of its course, and the structures divided in the same order as in the operation of ligating

the brachial artery. To stretch the *musculo-spiral* nerve, make an incision two inches in length, with its centre situated at a point, about one inch above, and one-half inch internal, to the apex of the external condyle. If the incision be a vertical one, it will cross the obliquely directed interval between the supinator longus and the brachialis anticus, and, if these muscles be separated, the musculo-spiral nerve, accompanied by the superior profunda artery, will be exposed lying between them.

Bloodvessels.—To compress the brachial artery in the upper part of its course, the pressure should be made from within outwards, since, in this situation, the artery lies to the inner side of the bone, but, as the vessel descends, it gets in front of the bone, so that, in the lower part of the arm the pressure should be directly backwards. It is customary, however, to compress the brachial in the neighborhood of the insertion of the coraco-brachialis—the pressure being directed outwards and slightly backwards.

Ligation of the Brachial.—The brachial may be ligated in any part of its course, the point of election, however, being about the insertion of the coraco-brachialis muscle. After the skin and the superficial and deep fasciae have been divided, and care has been taken to avoid the basilic vein and the internal cutaneous nerve, which here lie in the superficial fascia, the inner edge of the biceps is next sought for, and drawn outwards, as it slightly overlaps the vessel. The pulsations of the artery and the relations of the median nerve to the vessel, assist in identifying it. The nerve is drawn aside, since in this situation, it lies, generally, in front of the artery. The sheath is opened, the venae comites separated from the vessel and the ligature introduced from within outwards, so as to avoid injury to the ulnar nerve, which lies to its

inner side. The *collateral circulation*, after ligation of the brachial at this point, is carried on (1) by the termination of the superior profunda anastomosing with the radial recurrent artery in front of the external condyle, (2) by the communication of the inferior profunda and the *anastomotica magna* with the anterior ulnar recurrent in front of the internal condyle, (3) by these same vessels anastomosing with the posterior ulnar recurrent, behind this condyle, and (4) by the anastomoses of the posterior articular, the interosseous recurrent and the *anastomotica magna*, behind the external condyle.

Fracture of the Humerus.—The *anatomical neck* is the narrow groove, separating the rounded head of the humerus from the tuberosities, externally, and from the shaft, internally. The *epiphysis* is the cap-shaped upper end of the humerus resting upon the dome-like extremity of the shaft, while the *epiphyseal line*, slightly convex at its centre, runs from the anatomical neck, on the inner side of the bone, to a point immediately below the tuberosities on the outer side. The *surgical neck* is the triangular shaped portion of bone lying between the epiphyseal line, above, and the insertion of the pectoral muscles, below. Fracture of the *anatomical neck* is rare, and when it does occur, the fragments may be impacted, or non-impacted. Should the fracture be impacted, the fragments will be united by bony tissue, whereas if it be non-impacted, then union, if it occur, will be fibrous in character. In the latter variety of fracture—the non-impacted—one would be led to think that union would not result, since, there is no bloodvessel bringing blood to the fractured head, as there is, in the case of the hip joint, but, notwithstanding this absence of adequate blood supply, non-union, in this fracture, is very uncommon. Fracture or rather *separation of the epiphysis* should always be kept in mind when in-

juries to the shoulder joint occur in patients who are under the age of twenty years, since the epiphyseal end of the humerus unites with the shaft about that period. The age of the patient, the softer character of the crepitation, and the presence, in an abnormal position, of the smooth rounded end of the lower fragment in contradistinction to the sharp irregular end of the shaft in fracture of the surgical neck of the humerus, assist in differentiating these injuries. In epiphyseal separation the *upper* fragment is drawn up against the acromion and slightly abducted by the supraspinatus muscle, while the subscapularis, having greater leverage than the infraspinatus and teres minor together, rotates it somewhat inwards. The upper end of the *lower* fragment is drawn inwards by the pectoralis major, the teres major and the latissimus dorsi muscles. The upper fragment, which is abducted, is so small, that it cannot be brought into line with the lower fragment by means of splints and, hence, Moore advises abduction of the arm in a forward direction so as to bring the lower fragment in apposition with the abducted upper fragment. In fracture of the *surgical neck* the upper fragment would be in much the same position, as it is in epiphyseal separation, while the upper end of the lower fragment would be drawn inwards by the pectoralis major, teres major and the latissimus dorsi; the elbow would be abducted by the deltoid, and the shaft drawn upwards by the deltoid, biceps, triceps and the coraco-brachialis muscles. In *fracture of the shaft* below the insertion of the thoracic muscles and above that of the deltoid, the upper fragment would be drawn inwards by these thoracic muscles, and the lower would be displaced outwards by the deltoid and drawn upwards by the biceps, triceps, etc. When the fracture occurs between the *insertion* of the *deltoid* and the *condyles*, the lower end of the upper fragment would be drawn outwards by the deltoid,

while the lower fragment, and, with it the forearm, would be drawn upwards by the biceps and triceps. Should the direction of this variety of fracture be downwards and forwards, then, the lower fragment will be drawn up behind the upper fragment, whereas, if the break be directed downwards and backwards, the lower fragment will override *i.e.*, lie in front of the lower end of upper fragment. When the break is situated close to, and, below, the insertion of the deltoid, it may be the result of muscular action, in which case the line of fracture is very often directed transversely. In fact the humerus is more often *broken by muscular action* than is any other bone, and, when fracture thus occurs, it is the result of a sudden transverse strain being put upon the shaft, as in the act of throwing a ball. The mechanism of the production of fracture of the humerus by muscular action is as follows:—The upper part of the bone is steadied and firmly held to the scapula and thorax by the deltoid and the pectoral muscles, hence, in the act of throwing, the long lever formed by the lower half of the shaft and the forearm together, exerts a powerful strain on the bone below these muscular stays, especially when the momentum is suddenly arrested, with the result that a fracture may be produced. There is generally more or less *shortening* in fracture of the shaft, and this shortening may be ascertained by comparing the relative length of the two limbs, as measured from the “salient angle” of the acromion to the tip of the external condyle. This “salient angle” of the acromion is the point of junction of the acromion process with its spine and is opposite to the acromio-clavicular articulation. It is well to remember in measuring the humerus that the right is on an average about one third of an inch longer than the left, and that the humerus of the male is about one inch longer than that of the female. In fracture of the shaft of

the humerus there is a possibility of the ends of the fragments injuring the circumflex nerve, if the break be situated at the upper third, or, the musculo spiral nerve, if the break be near the middle third of the bone. Should symptoms of *irritation* of these *nerves*—symptoms such as pain, numbness or spasm of the muscles supplied by them—appear shortly after the accident, they are probably due to direct injury from the ends of the fragments. If, however, the symptoms of nerve disturbance come on some time after the accident, they are in all probability due to compression of the nerves by the callus that is formed. *Non-union* occurs more frequently in this bone than in any other, and various reasons have been assigned therefor, such, for instance, as separation of the ends of the fragments, interposition of muscular tissue, or over-extension of the lower fragment, etc. Hamilton in his "Fractures and Dislocations" considers that the non-union is due to the fact that, when this fracture is put up with the forearm at a right angle, as it usually is, the muscles soon become rigid, producing a certain amount of ankylosis. Any movement thereafter of the forearm causes motion at the break rather than at the joint, and such movement is of a to and fro nature. At first glance one would consider that movement would not interfere with union since the clavicle unites in spite of movement, or rather, one might seem justified in thinking that movement assists union, as evidenced by the ambulatory treatment of fractures of the leg, but, in fracture of the clavicle, or, in the ambulatory treatment of fractures of the leg, union is dependent on motion of a somewhat rotatory character, *i.e.*, along the axis of the bone. Whereas—in movement of the ankylosed arm, the motion is of a to and fro character, and such movement would tend to break down rather than to increase the callus formation.

Amputation through the arm may be performed, in the upper half, by means of antero-posterior flaps, and, in the lower half, by the circular method. In the latter operation, the anterior portion of the flap should be somewhat elliptical in shape, so that, the flap would be longer over the biceps to allow for the retraction of this muscle, since this is the only muscle that is unattached to the bone in this situation. Lastly, in amputation through the humerus in young patients, a second operation may sometimes be called for, since the bone receives its growth principally from the upper epiphysis, and grows at a greater rate than the surrounding soft parts.

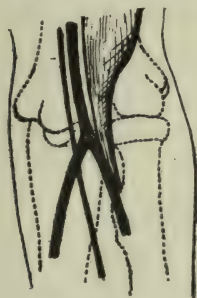CHAPTER VI.

THE REGION OF THE ELBOW.

ANATOMY.	FRACTURES.
PHLEBOTOMY.	DISLOCATIONS.
BURSAE.	EXCISION.
ELBOW JOINT.	

Anatomy.—The superficial structures in the region of the elbow are the skin, the superficial and deep fasciae, superficial veins and the following nerves, viz.: The cutaneous branches of the musculo-cutaneous and the internal cutaneous nerves in front—the lesser internal cutaneous nerve internally, and the lower external cutaneous branch of the musculo-spiral behind. The deep fascia covers in, and surrounds, the muscles of the forearm, as it does in the case of the arm, and receives fascial expansions from the tendons of the triceps and biceps muscles, as mentioned above. It is attached to the bony prominences in the neighborhood of the elbow joint, viz., to the internal and external condyles and to the olecranon. Beneath the deep fascia and in front of the elbow is a *triangular space* bounded, externally, by the supinator longus and, internally, by the pronator radii teres; the apex of the triangle is formed by the convergence of these muscles, while an imaginary line joining the two condyles forms the base. This triangle contains, along its outer side, the musculo-spiral nerve and the radial recurrent artery, the latter anastomosing with the superior profunda artery. Along the inner side of the triangle is the anterior ulnar recurrent artery running upwards to communicate with the inferior profunda and the anastomotica magna arteries, while in front and about the middle of the space are the median nerve, the brach-

ial artery with a vein on either side (venae comites) and the tendon of the biceps muscle. These structures occupy a space, half an inch in width, in front of the elbow, and are arranged in the following order from within outwards, viz.:



(Fig. 3.)

Relations of Nerve, Artery and Tendon in front of Elbow Joint.

Nerve, artery, tendon. (Fig 3.)

There is another triangle in the region of the elbow, but it is situated posteriorly and has its apex formed by the origins of the anconeus and the lower fibres of the extensor carpi radialis longior, which arise from the external condyle, and its sides by the divergence of these muscles. In this triangle the head of the radius may be distinctly felt, being separated from the integument

by the superficial and the deep fasciae and by the orbicular ligament only.

Phlebotomy.—The *superficial veins* in the region of the elbow are: The radial externally, the anterior and the posterior ulnar internally, and the median in front. The latter vein divides into two branches—median basilic and median cephalic, at a point about one and one-half inches below the level of the internal condyle and a little external to the middle line of the joint. Just before this division takes place the median vein receives a short communicating branch from the deep veins, *i.e.*, from the venae comites of the radial artery, and this branch pierces the deep fascia at the point of division of the median vein above mentioned. The *median basilic*, about two inches in length, ascends and unites with the two ulnar veins to form the basilic, while the *median cephalic*, one and one-half inches long, unites with the

radial to form the cephalic vein. The communication, above referred to, of the superficial with the deep veins is of great importance in connection with the operation of *phlebotomy*, as will be seen presently, and the veins, on which this operation is usually performed, are the median basilic and the median cephalic. The median basilic is larger and more fixed than the median cephalic, and for these reasons it is generally the one selected from which to bleed, in spite of its close relationship to the brachial artery, which, running beneath it and separated from it by the bicipital fascia only, is in danger of being wounded if the operation be carelessly performed, with the probable production, when so wounded, of an arterio-venous aneurism. As far as the arrangement of the superficial nerves with reference to these veins is concerned, they stand in danger of being wounded, especially, if the median basilic be the one chosen from which to bleed, since the internal cutaneous nerve passes, partly behind, and, partly in front, of this vein, whereas, the external cutaneous lies, as a rule, entirely behind the median cephalic. Should either of these nerves be injured, sufficient irritation may result as to cause, on the one hand, traumatic neuralgia if the internal cutaneous be injured, or flexion of the forearm if the external cutaneous be wounded, since, the latter nerve supplies the biceps and the brachialis anticus muscles—flexors of the forearm. In view of these objections to bleeding from, either the median cephalic, or the median basilic vein, one would think it preferable to employ other superficial veins, such as, the ulnar, the radial, or the median; and so it would, were it not for the fact that the amount of blood, that can be drawn from the latter veins, is comparatively insignificant, as compared with that, from the median cephalic, or the median basilic, which communicate with the deep veins of the

forearm and thus permit a steady and a continuous stream of blood to flow when the operation is performed on them.

Bursae.—To permit freedom of movement of the skin and superficial fascia over the prominence of the olecranon, a synovial bursa is interposed between the superficial and the deep fascia on the posterior aspect of the joint, and, when this bursa is inflamed, as it sometimes is, in certain occupations necessitating pressure on the olecranon, it is termed “miner’s elbow;” a *second bursa* is situated between the lower part of the triceps tendon and the back part of the upper surface of the olecranon; a *third*, over the head of the radius, between the orbicular ligament and the common tendon of the extensor muscles; and a *fourth*, between the tendon of the biceps and the front part of the bicipital tuberosity. When the first one is inflamed, *i.e.*, “miner’s elbow,” its superficial situation over the prominence of the olecranon will permit it to be readily distinguished. In inflammation of the second bursa, *i.e.*, the one beneath the triceps, there results a swelling which appears on either side of the tendon of this muscle and when the third, *i.e.*, the one over the radial head, is affected, extension of the wrist causes pain at the site of the bursa, while the fourth, when inflamed, renders pronation painful, since this position of the forearm would lessen the space between the biceps tendon and the bone and would thus increase the pressure on the inflamed bursa. *Synovitis* of the elbow joint may cause an effusion into the joint sufficient to distend it and to produce a swelling, which, because of the comparative laxity of the posterior ligament, would be more pronounced on the posterior than on the anterior aspect of the joint, and, since the triceps is inserted into the olecranon, this muscle would be stretched over the swelling so as to produce an appreciable ridge on either side of its tendon. We

have seen, however, that inflammation of the bursa beneath the triceps produces a similar bulging on either side of the tendon, hence, to differentiate the one from the other, it must be remembered, that the head of the radius is exposed in the posterior triangular space, and, that the synovial membrane of the joint surrounds the radial head, consequently in *synovitis* of the elbow joint we can elicit fluctuation by placing one finger over the head of the radius in this triangle, and another finger over the swelling on either side of the triceps tendon, but, in *bursitis*, fluctuation can be elicited from one side of the tendon to the other side only, and not to the head of the radius.

The Elbow Joint is a ginglymus or hinge joint, and depends for its strength chiefly on the interlocking of the bones that enter into its formation, rather than on the presence of ligaments as in the case of the sterno-clavicular articulation, or, on the action of muscles, as in the shoulder joint. The ligaments that assist in protecting the joint are: The anterior, the posterior, the internal and the external, and, of these, the two latter are strong and closely attached to the bones that form the joint, whereas the two former are lax—the posterior one especially. As stated above, this articulation is a ginglymus or hinge joint, but it is more than a mere hinge joint since the hinge refers to the articulation of the ulna with the humerus only, and not to the articulation of the radius with the humerus. The latter joint, *i.e.*, the humero-radial, would appear at first glance to be an enarthrodial joint, since the cup-shaped depression of the head of the radius articulating with the radial head of the humerus, would apparently allow movement in every direction, and, this it would do, were it not that the orbicular and the radio-ulnar ligaments prevent separation of the bones, and, therefore, interfere with circumduction of the radius.

Hence, instead of being an enarthrodial or ball and socket joint, the humero-radial is an arthrodial or gliding joint.

The *movements* permitted at the elbow joint are : Flexion and extension and, in addition, the gliding and rotatory movements of the radius. Since the hand is attached to the lower part of the radius, the radio-humeral joint allows the radius, and, with it the hand, to be rotated, *i.e.*, supinated and pronated, and, because of the peculiar relationship of the head of the radius to the humerus, these movements of pronation and supination of the hand may take place in any degree of flexion or extension of the joint—a wise provision, since it gives greater scope for the performance of the delicate movements necessary for the perfect action of the hand in the different occupations.

Line of Joint.—When the arm is partially flexed, a transverse crease is noticed in front of the elbow with its convexity downwards and its extremities touching the condyles. The joint lies about half an inch below this crease, and, since the inner margin of the articular surface of the humerus is prolonged downwards, *i.e.*, toward the forearm, more than the outer margin is, and, since the two condyles are on the same level, it follows that the line of joint is farther from the internal than it is from the external condyle, *i.e.*, the line of joint is one inch below the internal condyle and three-quarters of an inch below the external condyle. The articular surface of the humerus is one and one-half inches wide and is divided into two parts by an antero-posterior ridge, the inner and larger part articulating with the ulna, while the smaller and outer part articulates with the radius. When the arm is by the side and the forearm is extended the vertical axes of the arm and forearm are not in the same plane, but meet at an angle of 20° (in the negro, 35°). This is due to the obliquity of that part of the articular surface that

receives the ulna, since this part runs backwards and outwards so that the posterior end of the articular surface of the humerus is one-quarter of an inch external to the anterior end, and hence, when the ulna is extended, it inclines outwards and produces the angle referred to above. This is the "carrying angle," and is called so, because the fact of the forearm being inclined away from the body facilitates the carrying of weights, such as a pail of water, etc. On the other hand, when the forearm is flexed, the obliquity of the articular end of the humerus referred to above, causes it to incline inwards towards the centre of the body rather than vertically upwards, so that it is easier to touch the sternum than it is the point of the shoulder on the same side.

Fractures of the humerus immediately above the condyles—*supra condyloid fracture*—may be transverse or may be directed obliquely upwards and backwards, or, upwards and forwards, or, there may be added a fissure, extending downwards into the joint and producing what is called a "T" shaped fracture. Supracondyloid fracture is generally the result of violence applied directly to the olecranon and the usual *deformity*, viz., backwards and upwards, is due to the fact that the lower fragment, and with it the forearm, are carried backwards by the triceps and upwards by the biceps and triceps together. The deformity in supracondyloid fracture is more pronounced when an attempt is made to extend the forearm. The internal condyle approaches the acromion, but maintains its normal relationship to the olecranon since both are carried back together. Reduction is easily effected, but when the traction is discontinued, the deformity recurs. Crepitus and praeternatural mobility are present in this, as in other fractures. When the fracture is complicated by a fissure between the condyles there are, in addition to

the above symptoms, increased breadth of the elbow joint, and crepitation elicited by pressing the condyles together from side to side. The diagnosis of supracondyloid fracture, from dislocation of both bones backwards, is discussed on page 71. In the consideration of fractures about the elbow joint it is necessary to distinguish between the terms condyle and epicondyle—the former (condyle) includes not only the projection outside the joint, but a portion of the articular surface as well, whereas, the latter (epicondyle) means that portion, only, of the humerus outside the joint.

Zuckerkindl has shown that the projection, termed epicondyle, is composed, partly of an epiphysis, and partly of a portion of the humerus itself on which the epiphysis rests, hence, in an injury to this region producing a fracture of the epicondyle, in a patient under the age of 18, it is possible that it is the epiphysis that has become separated, whereas, in the adult, it is probably a fracture involving the epiphysis itself as well as a portion of the humerus outside of the joint.

The *epiphyscal line* of the lower extremity of the humerus may be roughly indicated by a line drawn across immediately above the two epicondyles. Fractures in the neighborhood of the elbow joint are very common in childhood, and the bones entering into the formation of the joint fit one another so accurately, that the presence of a small amount of callus, or, the slightest displacement of the component parts of the joint, may seriously interfere with its proper function. It is therefore advisable to inform the parents of the child of the possibility of impaired action of the joint resulting from the fracture. When the internal condyle is displaced upwards and unites in that position, the "carrying angle" spoken of above, is altered and the outer portion of the elbow projects, resulting in what Allis terms "gunstock" deformity.

Dislocation at the Elbow Joint.—Of the different forms of dislocation that may occur at this joint two only, will be considered, viz:—*Dislocation* of both bones *backwards* and dislocation of the radius downwards, *i.e.*, by elongation. The latter form of displacement, *i.e.* of the radius downwards, is peculiar to childhood and is probably more common than is generally believed. The size of the radial head is an important factor in its production, since, in the child, the head of the radius is comparatively small and is held in its place by a fibrous ring, the orbicular ligament. This ring is narrower below than above, and, when sudden traction with or without torsion, is applied to the radius, the head of the bone may be pulled down and out of the ligament like a button out of a button-hole. This accident occurs not infrequently in children, especially in those of a tubercular tendency in whom the ligaments may be more or less lax, and it is generally produced by suddenly lifting a child by one hand, as in dragging it over some obstacle, such as a puddle of water, &c., or in swinging it down from a height. When the dislocation occurs, the child screams and the arm is rendered useless, but, inasmuch as reduction is often spontaneous, it may be possible that, by the time the surgeon sees the patient, it has become reduced spontaneously. Should the dislocation persist, however, then the forearm is slightly flexed and may be in a position of either pronation or supination and the child will resist any movement of the forearm in an opposite direction, but there is very little, if any, deformity at the joint itself, perhaps only a slight separation of the head of the radius from the humerus.

To reduce the displacement, extend the forearm and pronate it, if it be already supinated, and then flex suddenly. If, however, it be pronated, extend and supinate. *Dislo-*

cation of both bones backward.—Normally this displacement is prevented by the curve, formed by the coronoid and olecranon processes, grasping the rounded articular end of the humerus in such a way that the coronoid curves up in front and the olecranon behind, or, as Deaver describes it “like a monkey-wrench fitted on to a screw nut.” This form of dislocation is generally the result of force indirectly applied to the joint through the radius, as, for instance, by falling on the palm when the arm is extended so that the tip of the olecranon impinges on the corresponding fossa of the humerus. This lifts up or pries the coronoid from the front of the articular surface of the humerus and thus removes the main obstacle to dislocation, so that, the momentum of the body continuing, while the hand remains stationary against the ground, the lower end of the humerus is driven forward, *i.e.*, both bones are displaced backward. The deformity in this displacement resembles that of fracture above the condyles, for, though increased mobility is characteristic of a fracture, and impaired mobility peculiar to a dislocation, yet, in supracondyloid fracture, a few hours may produce marked immobility, the result of muscular contraction, hence, to diagnose the one from the other we have to depend on features, other than the above, and, chief among these, is, the relationship of the olecranon to the internal condyle. When examining for any injury about the elbow joint, the surgeon should sit facing the patient, with the latter’s both arms flexed. He should then place his thumb on one condyle, and the middle finger on the other, and, with the index finger, should ascertain the position of the olecranon with reference to the internal condyle. Both arms should be examined at the one time and it will be found, if both be normal, that the olecranon will be on the same level as the condyles when the arm is

semi-flexed, but that it will be on a lower level than that process when the arm is fully flexed. The distance between the two bones is the best guide, however. Normally, one finger can be placed in the fossa between the olecranon and the internal condyle, but in dislocation of both bones backwards, two or more fingers may be so placed. Another means of distinguishing fracture from dislocation is that, in the case of dislocation, the deformity is lessened when the forearm is extended, whereas in fracture, the deformity is increased under similar circumstances. The explanation of this is, that, when the forearm is straightened in displacement, the beak of the olecranon sinks in towards the shaft, thus diminishing the bulk of the projection, whereas in fracture, the movement of extension of the forearm occurs through the seat of the fracture and not at the joint, so that the lower fragment and the olecranon, together, become more prominent posteriorly. Lastly, in fracture, we have seen that the internal condyle approaches the acromion, while, in dislocation, it remains at its normal distance from that process.

Excision of the elbow joint.—In this operation a vertical incision is employed so as to preserve, as far as possible, the function of the triceps, for, though the fibres of the muscle may be severed, yet the retention of the band of fascia that is prolonged from the outer side of the tendon to the deep fascia of the forearm, permits a certain amount of extension after the operation. Again, the presence of the ulnar nerve in the fossa between the internal condyle and the olecranon must be borne in mind so as to avoid wounding it during the operation.

CHAPTER VII.

THE FOREARM.

ANATOMY.	LIGATION OF ARTERIES.
ACTION OF MUSCLES.	NERVE STRETCHING.
LANDMARKS.	FRACTURES.
AMPUTATION.	

The superficial tissues of the anterior surface of the forearm are supplied by the following *nerves*:—The musculo-cutaneous externally and the internal cutaneous internally; while, on the posterior surface, the musculo-cutaneous and the radial on the outer aspect, and the posterior branch of the internal cutaneous on the inner, together with the lower cutaneous branch of the musculo-spiral, constitute the nerve supply. Beneath the superficial is the *deep fascia*, strengthened by accessions from the tendons of the biceps and triceps, and attached to the following bony projections, viz.: The olecranon, the condyles, the posterior border of the ulna and the outer border of the lower end of the radius. This fascia is composed of fibres which are circular, oblique and longitudinal in direction, and is thickest on the posterior surface, thinnest on the upper part of the anterior surface and intermediate on the lower part of the same surface.

Action of Muscles.—Beneath the deep fascia are the following muscles: 1. The *biceps*.—This muscle, inserted into the tuberosity of the radius, flexes the bone and, therefore, the forearm, at the same time rotating outwards the radius, and with it, the hand. This movement of rotation results from the fact that the tendon is inserted into the back part of the tuberosity, so that, when the muscle contracts, the radius is rotated through an axis passing up the centre of the bone. In this movement of rotation, the head of the bone rolls on the articular

surface of the humerus and inside of the orbicular ligament which binds it to the ulna. The tendon at its insertion into the tuberosity is so twisted that its external border is applied higher up on the bone than its internal border and its anterior surface is in contact with the front part of the tuberosity. 2. The *pronator radii teres*, arising from the humerus above the internal condyle by one head, and from the inner border of the coronoid process by the other, and inserted into the middle of the outer surface of the shaft of the radius, flexes the forearm, and, passing as it does from the inner aspect of the forearm to the outer side of the radius, rolls the radius inwards—an action the direct opposite to that of the biceps. Hence the biceps supinates, and the pronator radii teres pronates the forearm. 3. *Supinator longus*, from the upper two-thirds of the supracondyloid ridge of the humerus, into the forepart of the outer side of the base of the styloid process of the radius, supinates this bone and, therefore, the forearm, when it has already been pronated, or pronates it, when it has been supinated, *i.e.*, it assists in maintaining the forearm in a position midway between pronation and supination, as when placed across the chest. 4. *The supinator brevis*, from the external condyle of the humerus, the external ligament of the joint and from the ulna into the neck and oblique line of the radius, is also a supinator of the radius. 5. *The anconeus*, from the back part of the outer condyle, into the side of the olecranon and upper one-fourth of the posterior surface of the ulna, assists the triceps in extending the arm. *The pronator quadratus*, from the lower one-fourth of the anterior surface of one bone into the corresponding surface of the other, tends to pull the bones together, but, since the ulna is fixed by its interlocking with the humerus above, the radius alone can move, which it does, in the form of rota-

tion inwards, *i.e.*, pronation. The remaining muscles are concerned with the movements of the hand rather than forearm, and these muscles are : 1. The *extensor carpi radialis longior* and *brevior*, the former from the lower one-third of the external supracondyloid ridge, into the radial side of the metacarpal bone of the index finger, and the latter, from the external condyle, into the metacarpal bone of the middle finger. Their action is to extend, as their names indicate, the wrist towards the radial side. 2. The *flexor carpi ulnaris*, from the inner condyle, inner margin of the olecranon and posterior border of the ulna, into the pisiform bone, flexes the wrist towards the ulnar side. 3. The *flexor sublimis digitorum* from the internal condyle, inner margin of the coronoid and the oblique line of the radius, into the middle phalanges, and 4, the *flexor profundus*, from the upper three fourths of the anterior and inner surfaces of the ulna, into the last phalanges, are, as their names indicate, the superficial and deep flexors of the fingers. 5. The *extensor communis digitorum*, the *extensor minimi digiti*, and the *extensor indicis*, the two former from the external condyle and the latter from the lower part of the posterior surface of the ulna, into the back part of the second and third phalanges, are the extensors of the fingers. 6. The *flexor longus pollicis*, from the anterior surface of the radius below the oblique line, into the last phalanx of the thumb, flexes this phalanx. 7. The *extensor ossis metacarpi pollicis*, from the posterior surfaces of the ulna and radius ; the *extensor primi internodii*, from the posterior surface of the radius and the *extensor secundi internodii* from the posterior surface of the ulna, are inserted into the metacarpal bone and the first and second phalanges, respectively, of the thumb and extend these bones. All the muscles arising from the internal condyle, and inserted into the fingers or carpus, are, in addition to the actions

above mentioned, flexors of the forearm as well, assisting therefore, the biceps and brachialis anticus. Two muscles from the outer condyle—the supinator longus and the extensor carpi radialis longior—have the same action of flexion, the former to a marked, the latter to a slight degree, while the rest of the muscles, that arise from the external condyle, extend the forearm thus assisting the triceps and the anconeus.

Bloodvessels.—The *brachial artery* divides into ulnar and radial about half an inch below the centre of the bend of the elbow, or, about one and one-quarter inches below a point, midway between the two epicondyles. The radial artery continues downwards the direction of the brachial, whereas, the ulnar has a decided curve inwards before passing vertically downwards.

Relations of the Radial.—As the radial passes down the forearm it lies on the biceps, supinator brevis, flexor sublimis, pronator radii teres, flexor longus pollicis, pronator quadratus and the radius, and has in front, in addition to the superficial and deep fasciae, the inner margin of the supinator longus. On the inner side are the pronator radii teres above and the flexor carpi radialis below, while, on the outer side, are the supinator longus muscle and the radial nerve,—the latter gradually approaching the vessel from above. The *venae comites* of the radial artery communicate with the superficial veins by means of a short branch which pierces the deep fascia in the neighborhood of the apex of the muscular triangle in front of the elbow joint.

Relations of the Ulnar.—The ulnar artery lies on the brachialis anticus and on the flexor profundus digitorum, and, since the curved part of the artery lies beneath the superficial flexors, these muscles, along with the superficial and deep fasciae, lie in front of the artery and so,

too, does the median nerve, which, passing down the forearm between the two heads of the pronator radii teres, crosses, and is separated from the ulnar artery by the deep head of this muscle. On the outer side of the vessel is the flexor sublimis digitorum, and, on the inner side, are the flexor carpi ulnaris muscle and the ulnar nerve. Both radial and ulnar arteries supply the forearm by means of muscular, recurrent and interosseous branches, the latter constituting the main blood supply of the posterior surface.

The *nerves* of the forearm are the median, the ulnar, the radial, and the posterior interosseous. The *median* nerve continues its direction downwards in a straight line from the landmark spoken of above, viz., a point one-half inch internal to the biceps tendon at the centre of the bend of the elbow. It passes to the middle of the front of the wrist below, and lies, at first, on the brachialis anticus, then between the heads of the pronator radii teres, and, lastly, on the flexor profundus muscle. This nerve is separated from the ulnar artery by the deep head of the pronator radii teres, and the order of these structures, from before backwards, at the point where the nerve crosses the artery, is *nerve, muscle and artery*. At the lowest part of the forearm the median nerve lies behind the palmaris longus tendon, between the flexor carpi radialis externally, and the flexor sublimis digitorum internally. It supplies, in the forearm, all the muscles of the anterior surface, excepting one and a half muscles, viz., the flexor carpi ulnaris and the inner half of the flexor profundus. The *ulnar* nerve enters the forearm behind the internal condyle and supplies one and a half muscles, viz., the flexor carpi ulnaris and the inner half of the flexor profundus. As it descends in the forearm it lies on the flexor profundus, has the flexor carpi

ulnaris muscle on its inner side, and is gradually approached by the ulnar artery. The *radial* nerve is the continuation downwards of the musculo-spiral and lies on the radial side of the radial artery. It has the same relations as the radial artery, excepting that it does not rest on the biceps tendon above nor on the pronator quadratus below. The reason it does not rest on the latter muscle is that it passes from the front of the forearm, outwards under the supinator longus tendon, at a point about three inches above the wrist joint, to supply the superficial structures of the lower part of the back of the forearm below the musculo-cutaneous nerve. The *posterior interosseous nerve*, the other terminal branch of the musculo-spiral, winds around to the back of the forearm through the fibres of the supinator brevis and passes down between the superficial and deep muscles of the posterior surface. Below the extensor ossis metacarpi pollicis it passes beneath the extensor secundi internodii, and, running down on the interosseous membrane, terminates at the back of the wrist joint in a gangliform enlargement. It supplies the back of the wrist and all the posterior and radial muscles excepting the supinator longus, the extensor carpi radialis longior and the anconeus, which are supplied by the musculo-spiral nerve.

Landmarks.—*Bloodvessels.*—The superficial landmark for the *radial* artery is a line drawn from a point half an inch below the centre of the bend of the elbow, to the inner side of the fore part of the styloid process of the radius, or, since the direction of the radial is, more or less, a continuation downwards of the biceps tendon, the course of the artery would correspond to a line drawn, downwards, from the point where the biceps tendon ceases to be felt in the triangular space in front of the elbow and terminating at the styloid process as

above described. The line for the *ulnar* artery is not so simple as that for the radial because of the curve in its upper third. The direction of the lower two-thirds of the ulnar artery corresponds to a line drawn from the front of the internal condyle to the outer side of the pisiform bone, while the upper third corresponds to the curve, *i.e.*, to a line drawn from a point one-half inch below the centre of the bend of the elbow (the point of bifurcation of the brachial) to the junction of the upper and middle thirds of the first line. (Fig. 2.)

Nerves.—*Median*, a line drawn from a point one-half inch internal to the tendon of biceps, at the bend of the elbow, to the space between the two prominent tendons occupying the middle of the front of the wrist, *viz.*, the flexor carpi radialis externally and the palmaris longus internally.

Radial.—A line drawn from a point one-half inch external to the biceps tendon, on a level with the condyles of the humerus, to a point three inches above the styloid process of the radius, and from this, obliquely over the outer border of the forearm to a point on the dorsum of the hand, midway between the metacarpal bone of the thumb and the metacarpal bone of the index finger.

Ulnar.—A line drawn from the posterior surface of the internal condyle and passing, below the condyle, to the radial side of the pisiform bone, agrees fairly well with the course of this nerve.

Posterior Interosseous.—A line drawn from a point one-half inch external to the biceps tendon at the level of the condyles, downward and outward, below and in front of the external condyle, to the middle of the back of the forearm, and from this point vertically downwards to the back of the wrist joint. The knowledge of the general direction of the muscles of the forearm and of the course

of its nerves and arteries is of assistance to the surgeon in the diagnosis of certain injuries and diseases of the limb. For instance, tenderness in a direction downwards and outwards from the internal condyle, accompanied by pain on pronation, would indicate a strain of the pronator radii teres, as in "lawn tennis" arm; or, a swelling running obliquely downwards and outwards from the middle of the posterior surface, and passing over the outer border of the lower part of the forearm, would mean inflammation of the sheath around the extensor ossis metacarpi and the internodii pollicis tendons, as in "washer-woman's" strain, brought about by a sudden and severe external rotatory movement of the hand; or, a pain darting down the middle line, when the forearm is suddenly pronated, would indicate pressure on the median nerve as it passes between the two heads of the pronator radii teres. Again, pressure along the lines of the nerves would be of great assistance in the diagnosis of neuritis or inflammation of these structures.

Operative Work on the Forearm.—*Ligation of the ulnar artery* in the *upper third* of its course is very rarely called for, and when it is, is difficult of performance, since the curve, which represents this part of the vessel, is deeply placed beneath the flexor muscles and can be approached from the inner side only, of the forearm. If it be decided to ligate the vessel in this situation an incision, with its centre one and a half inches below the internal condyle, should be made in the line of the vertical part of this artery, *i.e.*, in a line drawn from the anterior surface of the internal condyle to the radial side of the pisiform bone. On exposing the deep fascia, a distinct white band formed by a thickening of the aponeurosis will be observed. This band passes downwards and outwards and its anterior margin corresponds to the interval between

the palmaris longus and the flexor sublimis, while its posterior margin represents the interval between the flexor sublimis and the flexor carpi ulnaris. On separating the latter muscles and working in a direction outwards and backwards, the ulnar nerve will be found lying on the flexor profundus, and the artery should be sought for at the distance of about one inch to the outer side of the nerve. To ligate the artery in the *middle* of its course, an incision should be made in the line of the vessel, and, after dividing the deep fascia, the deep landmarks will be exposed, and these deep landmarks are the flexor sublimis digitorum and the flexor carpi ulnaris. On separating them from one another, the artery with the nerve to its inner side will be exposed, and the vessel should be ligated by passing the needle from within outwards so as to avoid the nerve. *Ligation of the radial artery in its upper part.* An incision is made in the line of the vessel, and, on division of the fasciae the deep guides to the artery present themselves. These are the supinator longus and the pronator radii teres. The artery lies between these muscles and may be found by observing the course of the muscular fibres exposed in the line of the incision. Should the fibres be seen to pass in a direction downwards and outwards, it is, in all probability, the pronator radii teres muscle, and the artery will lie to its outer side; but, should the direction of the fibres be downward, or downward and slightly inward, it is likely to be the supinator longus muscle, and, if it be this muscle, the artery should be sought for to its inner side, and, when found, should be ligated by passing the needle from the outer to the inner side so as to avoid the radial nerve that lies to the radial side of the vessel. To ligate the artery in either its middle or lower third an incision in the line of the artery will expose the vessel lying between the flexor

carpi radialis on the inner side and the supinator longus muscle on the outer side.

Nerve Stretching.—The *median* nerve may be stretched, either in the lower part of the forearm or, at the bend of the elbow, where it lies one-half inch internal to the biceps tendon. The former situation is preferred, since it is not advisable to operate at the flexure of a joint, as, in such a case, there is always a possibility that subsequent contraction of the tissues may interfere with the future extension of the limb. To stretch the nerve in the lower part of its course, an incision should be made between the tendons of the palmaris longus and the flexor carpi radialis muscles, the two prominent tendons at the middle of the front of the wrist. After exposing these tendons, the former is drawn outwards and the latter inwards and the nerve will be found lying beneath the palmaris longus and between the tendon of the flexor carpi radialis and the outer tendons of the flexor sublimis digitorum. The *ulnar* nerve may be stretched through an incision made behind the internal condyle, but, in operating on this nerve, it is better to expose it in either the middle or the lower part of its course, through incisions similar to those employed in the ligation of the lower part of the ulnar artery. When so exposed, the nerve is found lying on the ulnar side of the artery, external to the border of the flexor carpi ulnaris. The *radial* nerve may be stretched on making an incision in the line of the radial artery about the middle third of the arm, and, on drawing the supinator longus externally, the nerve will be found lying to the radial side of the radial artery.

Fractures of the bones of the forearm.—*Radius.* The *neck* of the radius is very rarely broken, but, when it does occur, the upper fragment is supinated to a slight degree by the fibres of the supinator brevis that are

attached to it, while the lower fragment is drawn forwards by the biceps and inwards by the pronator radii teres. The biceps cannot draw it forward to any great extent, since the supinator brevis would tend to prevent such displacement, nor, is the lower fragment materially rotated since the supinating action of the biceps, and of that part of the supinator brevis attached, is about neutralized by the pronating power of the pronator radii teres.

Fracture of the *shaft* between the *biceps* and the *pronator radii teres*.—In this fracture the upper fragment is flexed by the biceps and supinated by the combined action of this muscle and of the supinator brevis, whereas the lower fragment is drawn inwards towards the ulna and pronated by the pronator radii teres and pronator quadratus. The knowledge of the actions of these muscles is of importance in the treatment of this fracture, for, were the forearm put up in the usual manner, *i.e.*, in a position midway between supination and pronation, the union that would result would seriously interfere with the future usefulness of the limb, since the upper fragment, already supinated by the biceps, would be too short to be influenced by the splints and if the arm were put up in the position referred to, the splints would partially pronate the lower fragment, hence, a partially pronated lower fragment would be united to a supinated upper fragment with the result that when union occurred the power of supination would be materially lessened.

The proper method of treating this fracture would be to put it up with superior and inferior splints, rather than with internal and external ones, because, since it is impossible to control the upper fragment by means of splints—it being too short, and, since the upper fragment is supinated, it will be necessary to bring the lower fragment into a position of supination also, so that the supinated

upper fragment will unite with a supinated lower fragment, thus preserving the function of the forearm; and this can be done only by putting the fracture up with splints that will supinate the lower fragment, *i.e.*, with superior and inferior splints.

Fracture of the shaft—immediately below the insertion of the *pronator radii teres*.—Here the upper fragment would be flexed by the biceps assisted slightly by the pronator radii teres, and would be drawn towards the ulna by the action of the latter muscle, while the lower fragment would be drawn inwards towards the ulna by the pronator quadratus, assisted to some extent by the supinator longus, because the insertion of this muscle into the styloid process would tend to “cant” inwards the upper end of the lower fragment.

Fracture of the lower end of the radius—“Colles’ fracture” occurs not infrequently in elderly people, females especially, and in this variety of fracture the bone is broken generally about $\frac{5}{8}$ of an inch above its lower articular surface. It occurs, as a rule, as the result of a fall on the palm of the hand while the arm is extended. The direction of the break is generally transverse, with a slight inclination upwards and backwards. Among the reasons assigned for the occurrence of fracture at the lower part of the radius, are the following: (1) That the compact tissue of the shaft meets at this point the cancellous tissue of the lower extremity; (2) That two forces here meet at an obtuse angle, one, being the momentum of the falling body, the other, the vibrations developed by the resistance of the ground to the palm of the hand; (3) Should a person fall on the palm of the hand, with the forearm nearly vertical, the force of impact would be conveyed directly upwards and expend itself among the carpal bones and along the course of the arm, with the possible result of a dis-

location at the elbow joint or of a fracture of the humerus, but, should he fall on the palm, with the arm extended sufficiently so as to meet the ground at an acute angle, then the line of impact would pass up in front, *i.e.*, ahead of the forearm, and would probably cause a fracture near the lower end of the radius. In *Colles' Fracture* the displacement of the upper fragment is very slight, whereas the lower fragment is affected to such an extent that instead of the articular surface pointing downwards, and slightly forwards and inwards as it normally does, it points downwards, backwards and outwards.

Causation of this displacement.—If the lower end of a radius be examined it will be seen that the posterior border of the articular surface is about $\frac{1}{8}$ inch deeper than the anterior border, and, further, that the styloid process projects about $\frac{3}{8}$ inch from the articular surface. When an injury occurs and a fracture results, the carpus is forced up against the articular surface of the radius, and the lower fragment is (1) mechanically *driven backwards*. Again, the more prominent posterior border of the articular surface will receive the impact to a greater degree than the anterior, and hence the lower fragment will be (2) *rotated backwards, i.e.*, on an axis passing transversely through it so as to cause the articular surface to point backwards. Lastly, the carpus on forcing the bone backwards impinges to a greater degree on the outer edge of the articular surface, *i.e.*, on the prominent under surface of the styloid process, and rotates, therefore, the lower fragment on a centre which passes vertically up through the styloid process of the ulna, and thus causes the articular surface to point (3) *outwards, i.e.*, towards the radial line. The latter displacement causes the styloid process to be on a higher level than normal, almost, in fact, as high as the styloid process of the ulna. This latter point is of importance, and

will be referred to again in connection with the diagnosis of dislocation at the wrist joint. These three varieties of displacement occur simultaneously, are mechanical rather than the result of muscular action, and account for the peculiar deformity present in this fracture. The displacement and rotation backwards cause the projection posteriorly termed the "silver fork" deformity, while the rotation outwards produces the inclination of the hand to the radial side—a characteristic symptom of Colles' fracture. Occasionally, when the traumatism is very severe the ligaments attached to the ulna, viz., the internal lateral, the radio-ulnar and the inter-articular fibro-cartilage are ruptured and the head of the ulna penetrates, and is held by, the annular ligament, and, when this complication exists, the ulna must first be reduced by extension and partial circumduction of the hand before attempting to reduce the displaced lower fragment of the radius. The knowledge of this triple displacement of the lower fragment in Colles' fracture assists the surgeon in its *reduction*. An assistant makes extension by holding the patient's hand as though he were shaking hands with him, and the surgeon, grasping the forearm with the fingers of both hands presses the upper end of the displaced fragment with both thumbs in such a manner as to mould it downwards beneath the upper fragment, when, as a rule, two straight splints will be all that is needed to hold the fragments in position. Proper reduction is imperative, and far more important than the style of splint employed, and the neglect to secure it is, no doubt, chiefly responsible for the deformed wrists that not infrequently follow Colles' fracture. In all of these fractures of the radius, the comparatively superficial situation of the head of the bone in the muscular triangle behind the elbow joint is of great assistance in the diagnosis, since, by feeling the head

of the bone with one hand and rotating the shaft with the other, a fracture may be recognized which otherwise might escape notice at the time of examination because of the rather deep situation of the upper part of the bone.

Fracture of the Ulna—The *olecranon* process may be torn off from the shaft by the action of the triceps, or by a fall directly on the process, and, when it occurs, the amount of displacement will depend as much on the disruption of the ligaments as on the action of the triceps itself.

Fracture of the Shaft of the Ulna.—Here there will not be much, if any, displacement of the upper fragment, since the brachialis anticus and the triceps neutralize one another; but the lower fragment will be drawn outwards towards the radius by the pronator quadratus.

Fracture of Both Bones.—In this case the upper fragment of the radius will be displaced, as described under fractures of the radius, in accordance with the situation of the break, and, while the upper fragment of the ulna will not be affected to any extent, the lower fragment of each bone will be drawn towards one another by the pronator quadratus, and, if the direction of the break be obliquely upwards and forwards then the lower fragments will be drawn up in front of the upper fragments, but if obliquely upwards and backwards the lower fragments will be drawn upwards behind the upper fragment. This drawing upwards of the lower fragments is the result of the contraction of the flexor and extensor muscles, which, arising above the fracture are inserted into the wrist or the fingers. In the *treatment of fracture of both bones*, frequent inspection and proper dressings are absolutely necessary. The application of a roller bandage beneath the splint is to be condemned, since it might press together the bones with the result that the formation of the callus

might blend the ulna and radius into one mass, thus preventing supination or pronation of the hand. Another objection to the use of the bandage next the skin is that the swelling that always occurs after a fracture would tend to cause constriction under the bandage, with the possible production of gangrene from interference with the circulation. It is in this fracture especially, that the surgeon should be on his guard against the development of gangrene. He should therefore inspect the limbs every day until all danger of this complication be over, and should also employ proper dressings. The comparatively superficial situation of the arteries of the forearm render them liable to be compressed by improperly padded splints, or by the employment of a graduated compress in the middle of the forearm for the purpose of separating the bones. The splints should be just wide enough to prevent the bandage from pressing on the ulnar or radial borders of the forearm and thus crowd the bones together, and, as mentioned above, the limb should be examined frequently, removing the splints on each occasion sufficiently to note the condition of the limb. Too much stress cannot be laid upon this inspection since the relation of the arteries to the bones is such, that a severe accident causing a break, may at the same time injure the vessels sufficiently to cause thrombosis, and, were the above precaution on the part of the surgeon neglected, he might be held responsible. *Amputation* through the lower third of the forearm is generally done by the circular method, whereas, in the upper two-thirds, equal antero-posterior flaps are employed, since the outline of the limb in this part would prevent the turning back of the flap of skin necessary in amputation by the circular method.

CHAPTER VIII.

WRIST AND HAND.

Anatomy of the Palm, Dorsum and Fingers.

LANDMARKS.

FUNCTIONS OF THE
PALMAR MUSCLES.

MOVEMENTS OF WRIST
AND CARPAL JOINTS.

DISEASES.

TUBERCULOSIS OF
THE WRIST JOINT.

OPERATIVE WORK.

DISLOCATION OF
THE WRIST.

The *structures* on the *front* of the *wrist* and *palm* are, (1) The integument; (2) The superficial fascia with the ulnar and median cutaneous nerves; (3) The anterior annular ligament, and (4) The palmar fascia; (5) The muscles of the thumb and little finger; (6) The tendons of the flexor muscles of the thumb and fingers with (7) the superficial palmar arch and the median nerve lying upon them; beneath these tendons is (8) the deep palmar arch, a deep layer of fascia intervening between it and (9) the palmar interossei muscles and the metacarpal bones. On the *dorsum* are (1) skin; (2) superficial fascia supplied by the radial and ulnar nerves; (3) deep fascia—a portion of the latter constituting the posterior annular ligament; (4) extensor tendons, each having a sheath of synovial membrane around it, and each bound down by the ligament, to the back of the lower end of the radius; (5) the radial trunk and the branches of the radial and ulnar arteries; (6) the dorsal interossei muscles and the metacarpal bones. On the *front* of the *fingers* the structures are: (1) integument; (2) superficial fascia, in which are the collateral digital arteries, (branches of the superficial palmar arch), lying beneath the digital branches of the

median and ulnar nerves; (3) vaginal sheaths, composed of transverse fibres, which arch from one side of a phalanx to the other, and thus form channels for the flexor tendons of the fingers. Inside of these channels and between their walls and the tendons are (4) closed sheaths of synovial membrane, while, passing from the parietal layer of the synovial sheath to the layer enclosing the tendon, are short reflections of synovial membrane termed "vincula vasculosa." These reflections carry small branches from the collateral digital arteries to the tendons for the purpose of nourishing them. On the *back of the fingers* are (1) skin, and (2) superficial fascia, with dorsal digital arteries and branches of the radial and ulnar nerves. Beneath this fascia are (3) the expansions of the extensor tendons.

Examining the above structures in detail and beginning with those of the palm we find: (1) That the *integument* of the *palm* of the hand is bound firmly down to the deep palmar fascia, by means of the superficial palmar fascia, and that this superficial fascia is composed of numerous inelastic fibres which cross one another in various directions and, between which, are lodged pellets of fat. The integument is so firmly held down to the palmar fascia by these inelastic fibres that very little retraction occurs in a wound of the palm, nor, is there much swelling permitted in inflammatory conditions of this part, although the pain is generally severe.

(2) *The annular ligament*, attached to the pisiform bone and the hook of the unciform internally, and to the tuberosity of the scaphoid and the ridge of the trapezium externally, is thick and strong, and has the ulnar nerve, the ulnar artery, the cutaneous branches of ulnar and median nerves, and the palmaris longus tendon in front of it. It bridges over the depression on the front of the upper part of the palm, thus forming a channel for the passage

of the flexor tendons and the median nerve to the hand. (3) The *deep palmar fascia* is composed of three parts—a central portion, occupying the hollow of the palm—an internal lateral, covering the muscles of the little finger, and an external lateral, those of the thumb. Partitions are sent backwards from the lines of junction of this central portion with the lateral portions, and these partitions join a transverse layer of deep fascia which lies behind the long flexor tendons, and thus form a fibrous canal for the passage of the flexor tendons through the hand. The *central portion* of the deep palmar fascia is triangular in shape, and is composed principally of the expansion downwards of the palmaris longus tendon, and hence its fibres are arranged, chiefly, in a longitudinal direction. Its apex is attached to the lower border of the annular ligament, while its base ends opposite the heads of the metacarpal bones by dividing into processes for each of the fingers. This fascia is very dense and strong, and affords ample protection to the delicate structures of the palm. The processes, into which the fascia divides, are bound together by means of oblique bands, and, near the webs of the fingers by a transverse band, called the *superficial transverse ligament* of the fingers. From the anterior surface of these processes, fibres run forwards to the integument of the palm, while, from the sides of the processes, some fibres pass to the deep transverse ligament and others, backwards, to the sides of the necks of the metacarpal bones. These latter form the entrances to the channels for the passage of the long flexor tendons in their course to the fingers, while the processes referred to above, blend, below, with the vaginal sheaths or channels for the flexor tendons of the fingers. These vaginal sheaths are composed of fibres directed chiefly in a transverse manner, *i.e.*, from

one side of the phalanx to the other, so as to form arches over the tendons, but all the fibres are not transverse, since, opposite the interphalangeal joints they are arranged so as to somewhat resemble a lattice work. Underneath the deep palmar fascia is (4) the *superficial palmar arch*, a continuation downwards of the ulnar artery, which, passing over the annular ligament on the radial side of the pisiform bone, enters the palm, and is directed in a curved manner towards the cleft between the metacarpal bones of the little and ring fingers. The artery then passes underneath the deep palmar fascia and ends, about the junction of the upper and middle thirds of the metacarpal bone of the index finger, anastomosing with the superficialis volæ from the radial. The superficial palmar arch supplies the fingers by digital branches, and lies on the flexor tendons and on the divisions of the median nerve. These divisions of the median nerve supply some of the muscles of the thumb and the two outer lumbricales and are then distributed to the thumb, index, middle and half of the ring fingers.

(5) The *synovial sheaths* for the flexor tendons in the palm are two in number—one for the flexor longus pollicis, and the other for the flexor sublimis and the flexor profundus digitorum. The former sheath, *i.e.*, the one for the flexor longus pollicis tendon, extends from about one inch above the annular ligament to the base of the last phalanx of the thumb, whereas, the sheath for the other is larger and extends from about one and a half inches above the annular ligament, to the middle of the metacarpal bones below. In the case of the little finger, however, this sac does not end at the middle of the metacarpal bone, but extends down to the base of the phalanx of that finger, so that the synovial sheaths for both thumb and little finger communicate with the synovial sacs beneath the



(Fig. 4.)

Synovial Sheaths of Palm and Fingers.

anterior annular ligament. (Fig. 4.). These flexor sheaths for the fingers line the interior of the vaginal or fibrous channels and are reflected from the walls of these channels to the tendons on their entrance into them, as well as, at their terminations at the bases of the last phalanges.

(6) The *deep palmar arch* is situated under these flexor tendons and is the continuation of the radial artery. This artery leaves the front of the wrist immediately be-

low the styloid process of the radius and runs outwards over the scaphoid and trapezium, and beneath the extensor muscles of the thumb, to the cleft between the first and second metacarpal bones. It then enters the palm, and, as the deep palmar arch, passes in a direction, slightly curved, across the bases of the metacarpal bones to terminate near the base of the metacarpal bone of the little finger. Underneath the deep palmar arch and separated from it by a layer of deep fascia, are (7) the *palmar interossei muscles*, which, arising from the sides of the metacarpal bones, are inserted into the borders of the phalanges and into the expansions of the extensor communis tendons behind, while (8) the *lumbricales* are inserted into the expansions only, and not into the sides of the phalanges. The remaining muscles of the palm are those for the thumb and the little finger.

Dorsal Surface.—The *deep fascia* is thickened and at-

tached to the styloid process of the radius externally, and to the ulnar styloid, the cuneiform and the pisiform bones internally, forming the *posterior annular ligament*. This ligament is somewhat oblique from without downwards and inwards, and binds down the extensor tendons, with their synovial sheaths, in the following order from without inwards: Extensor ossis and extensor primi internodii pollicis on the outer side of the styloid process; extensor carpi radialis longior and brevior behind the styloid process; extensor secundi on the inner side of a small bony ridge about the middle of the lower extremity of the radius; extensor communis digitorum and extensor indicis, internal to the extensor secundi; extensor minimi digiti, between the ulna and the radius; and, lastly, the extensor carpi ulnaris behind the head of the ulna. On the back of the hand, the *extensor communis digitorum* divides into its tendons of insertion, which, after receiving the extensor indicis and the extensor minimi digiti tendons, terminate in expansions covering the backs of the first phalanges and are then inserted into the second and third phalanges. These tendons on the back of the hand are connected by small oblique slips, especially the tendon for the ring finger, so that the latter finger cannot be freely moved without, at the same time, moving the middle and little fingers. The dorsal interossei are inserted in the same manner as are the palmar interossei above mentioned.

At the upper part of the radial side of this surface of the hand is a *triangular interval*, formed by the extensor ossis and the extensor primi internodii externally, and by the extensor secundi internally. Its floor is formed by the scaphoid and the trapezium with their connecting ligaments, while the radial vein and the cutaneous branches of the radial nerve are found in the roof of the triangle. This triangular space contains the radial artery in its

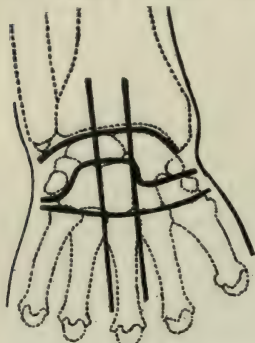
passage from the front of the wrist to the cleft between the first and second metacarpal bones.

The *synovial membranes* for the *wrist joint* and *carpus* are five in number, viz., one beneath the head of the ulna, between it and the radius externally, and the interarticular fibro-cartilage, below; a second, between the lower end of the radius and the under surface of the interarticular fibro-cartilage on the one hand, and the upper surface of the first row of carpal bones on the other; a third, between the contiguous margins of the two rows of carpal bones and extending downwards between the lower row and the heads of the metacarpal bones; a fourth, between the base of the metacarpal bone of the thumb and the trapezium; and, lastly, a fifth between the pisiform and the cuneiform bones.

Superficial Landmarks.—There are *two creases* in front of the wrist, the lower one of which is the landmark for the upper border of the anterior annular ligament, and for the lower border of the posterior annular ligament. On the hand the *lowest crease* crosses the necks of the metacarpal bones, and, therefore, represents the upper limit of the synovial sheaths around the flexor tendons of the index, middle and ring fingers, and, since the lower limit of the synovial sac for the tendons under the annular ligament, is the middle of the metacarpal bones, there is, therefore, a space of about half an inch between the synovial sheaths for the fingers and that of the palm. This lowest crease represents also the point where the palmar fascia breaks up into processes for the fingers, and, about midway between this crease and the webs of the fingers, are situated the metacarpo-phalangeal joints. Where the *second crease*, i.e., the one above the lowest, crosses the line of the metacarpal bone of the middle finger, represents the limit of the convexity of the superficial palmar arch.

Deep Landmarks.—The styloid process of the radius is situated on the outer aspect of the wrist joint and is about three-eighths of an inch lower down, *i.e.*, nearer the hand than the styloid process of the ulna, which is on the inner side of the joint. Immediately below the styloid process of the radius is felt a prominence formed by the tuberosity of the scaphoid and the ridge of the trapezium, while, internally, is another one, which corresponds to the pisiform bone and to the hook of the unciform. The line joining the upper border of these prominences agrees with the upper limit of the anterior annular ligament.

The *upper landmark* for the *wrist joint* is indicated by a convex line joining the tip of the styloid process of the radius with the tip of the styloid process of the ulna so that the highest point of its convexity is three-eighths of an inch above the straight line directly joining the processes. The *lower limit* of the joint is represented by a line, slightly convex downwards, and drawn from a point three-quarters of an inch below the pisiform, internally, to a point half an inch below the ridge formed by the tuberosity of the scaphoid, externally. The *mid-carpal joint* may be roughly represented by a convex line starting from the tip of the scaphoid externally and ending immediately below the pisiform internally. This line is shaped somewhat like the Greek letter Omega, the tip of its convexity being about half an inch below the apex of the upper line of the wrist joint.



(Fig. 5.)

Landmarks for Bones of Carpus.

The *mid-carpal joint* may be roughly represented by a convex line starting from the tip of the scaphoid externally and ending immediately below the pisiform internally. This line is shaped somewhat like the Greek letter Omega, the tip of its convexity being about half an inch below the apex of the upper line of the wrist joint.

Landmarks for the *Individual Bones of the Carpus.*—Draw a

line upwards on either side of the middle metacarpal bone, crossing the line of the mid-carpal joint and terminating above at the upper limit of the wrist joint. The two spaces, external to the outer vertical line, correspond to the trapezium with the trapezoid below, and to the scaphoid above, while between the two vertical lines, the lower space represents the os magnum, and the upper, the semilunar. Internal to the inner vertical line, the space below, corresponds to the unciform, while, that above, represents the cuneiform and pisiform bones. (Fig. 5.)

Lines for the *Bloodvessels*.—The *superficial palmar arch* may be represented by a line starting from the radial side of the pisiform bone and running towards the cleft between the metacarpal bones of the little and ring fingers, then across the palm on a level with the junction of the ulnar side of the thumb with the palm, when the former is at right angles to the latter. The digital branches correspond to lines running down the interosseous spaces and terminating about half an inch from the webs of the fingers.

The line for the *radial artery* is one starting below and in front of the radial styloid process and terminating posteriorly at the cleft between the metacarpal bones of the thumb and index finger, while in the palm, where it constitutes the *deep palmar arch*, it is represented by a line drawn from this cleft to the base of the little finger about half an inch above the line of the superficial arch. Another landmark for the deep palmar arch is: Place the thumb on the front of the wrist between the pisiform internally, and the scaphoid externally, so that the interphalangeal joint will be opposite to the pisiform bone, then the tip of the thumb will agree with the convexity of the arch. On the *dorsum* of the *hand* the line for the radial has already been described; that for the *dorsalis indicis* runs along

the radial side of the index finger; that for the *metacarpal*, lies between the index and middle fingers; while the lines corresponding to the spaces between the metacarpal bones of the middle, ring and little fingers, represent the dorsal interossei branches.

Landmarks for the *Muscles of the Thumb*.—These muscles, from above downwards, are, the opponens pollicis, the abductor, the flexor brevis and the adductor pollicis. To identify them, place the index finger on the front of the thenar eminence, so that its tip shall touch the base of the first phalanx and the body of the finger lie on the ridge of the trapezium, then the space above the finger corresponds to the opponens pollicis, that beneath the finger to the abductor pollicis, the space one-quarter of an inch below the finger, to the flexor brevis pollicis, while the rest of the thenar eminence represents the adductor pollicis.

For the *Muscles of the Little Finger*.—Place the index finger so that its tip touches the base of the first phalanx and its body rests on the hook of the unciform bone, the finger will then lie over the abductor minimi digiti, and the space, one-quarter of an inch external to it, will correspond to the flexor brevis minimi digiti.

Functions of the Muscles of the Hand.—

Those on the palm, belonging to the thumb and little finger, have actions corresponding to their respective names, while the *dorsal and palmar interossei*, being inserted into the sides of the first phalanges of the fingers, are flexors of these phalanges. In addition to this action of flexion, the interossei are extensors of the second and third phalanges, because of their insertion, along with the *lumbricales*, into the expansion of the common extensor tendon on the back of the first phalanx. These actions of the interossei and lumbricales are evident in the making of the

upper, or, hair stroke, in writing, since this movement is effected by flexion of the first and extension of the second and third phalanges, whereas the heavy, or, downstroke, is the result of extension of the first phalanx by the extensor communis digitorum, and of flexion of the second and third phalanges by the powerful flexor sublimis and flexor profundus muscles. In addition to the above actions, the palmar interossei adduct the index, ring and little fingers towards the middle line, while the dorsal interossei abduct the index, middle and ring fingers from the middle line; lastly, the *palmaris brevis* wrinkles up the integument of the inner side of the palm of the hand.

Movements of the Wrist Joint.—The movements permitted at the wrist joint proper, are flexion, extension, adduction and abduction, and their combination—circumduction. Not being a ball and socket joint, there is no rotary movement permitted here, but this movement of rotation is replaced by pronation and supination of the radius.

Extension at the wrist joint is freer than flexion, because the posterior portion of the articular surfaces of the scaphoid, semilunar and cuneiform bones, is prolonged farther downwards than the anterior portion; while adduction, *i.e.*, movement towards the ulnar side, is freer than abduction since the styloid process projects more on the radial than on the ulnar side and impinging, therefore, on the scaphoid, limits abduction. To supplement the actions of the wrist joint proper, especially flexion and extension, and to increase, therefore, the usefulness of the hand, we have the midcarpal and the carpo-metacarpal articulations. These admit of both flexion and extension, the former movement being freer than the latter, while, in the case of the mid-carpal joint, there is, in addition, a slight amount

of rotation due to the ball and socket formation of the joint between the os magnum below and the scaphoid and semilunar above. When the extended fingers are "bunched" the little and ring fingers move to the central point more easily than do the middle and index fingers, and the reasons for this are: (1) That the articulation, between the unciform above and the metacarpal bones of the little and ring fingers below, is directed slightly inwards; (2) that there is greater freedom of movement permitted at the above joints, than there is at the carpal articulations of the other metacarpal bones, with the exception, of course, of the thumb, which, being a concavo-convex joint, allows movement in every direction. This shape of the joint for the thumb explains what is called the "opposition" movement, *i.e.*, when the thumb is approximated to the fingers, it tends to roll inwards so as to face the fingers.

The wrist joint proper does not permit rotation since it is a condyloid articulation, but pronation and supination of the hand replace this movement of rotation. *Pronation* and *supination* are the result of rotation of the radius at the humero-radial joint, round an axis running downwards from the head of the radius through the styloid process of the ulna and the metacarpal bone of the little finger. In the practical application of pronation and supination, as seen in the use of boring instruments, for instance, there is another agent brought into play, and without which, these movements would be very much limited, and this agent is the shoulder joint. It will be noticed in boring, etc., that, to supination is added adduction and outward rotation of the humerus, while, to pronation there is added abduction and inward rotation. This change of position of the humerus, during supination and pronation of the forearm, adds to the efficiency of these movements, since it alters the situation of the base from which they

proceed, viz., the lower end of the humerus, and thereby increases the scope and strength of their application. Without these accessory actions of the humerus, the hand could be supinated and pronated only through an angle of about 80° ; with them, the range may reach in the neighborhood of 340° .

Diseases.—*Inflammation of the Structures of the Hand.*—When the superficial tissues of the palm are inflamed, pain is severe, although there is very little swelling present, since the integument is bound down to the palmar fascia by means of strong dense fibres, whereas, when the similar structures of the dorsum are affected, pain is less, while the swelling is greater, because of the relative laxity of the superficial tissues on the dorsum as compared with those on the palm.

Dupuytren's contraction is due to a shortening of the superficial fibres, which, derived from the processes of the palmar fascia, run to the integument of the palm and the bases of the fingers. Not only are these fibres affected, but the processes, themselves, are contracted, with the result that, the fingers are flexed, especially the little finger, and the skin is thrown into pits or folds. When the synovial sac, surrounding the superficial and the deep flexor tendons in the palm, is distended, the condition is termed "*compound palmar ganglion*," and, since the sac extends above the wrist, beneath the annular ligament, the swelling presents an hour-glass appearance, being bound down, at its middle, by this ligament. Fluctuation may be elicited by placing one finger on the front of the wrist above, and another on the palm below the annular ligament.

When septic inflammation, *i.e.*, *whitlow* or *felon* affects the last phalanges, the inflammatory action is generally confined to these phalanges, instead of spreading up the fingers, especially if the deeper structures, *i.e.*, the perios-

teum and the bone, be involved, since the tendons terminate at the bases of the phalanges, and, are therefore not involved. Should, however, the felon begin in the second or third phalanges, it may, as in the case of the first phalanx, be either superficial or deep. In the former instance, *i.e.*, when superficial, the whitlow may be local, or may, spreading through the lattice-work arrangement of the vaginal sheaths, affect the synovial membrane of the tendons beneath, and then spread up the fingers, or it may, by pressure on the vincula vasculosa, which convey the vascular supply to the tendons, cause destruction of these tendons. In the latter case, *i.e.*, in deep whitlow, the inflammatory process may primarily affect the periosteum, bone or the deeper tissues, and then, quickly involving the synovial sheaths, may spread upwards, resulting in extensive destruction of the tissues.

When the synovial membranes or thecæ are affected, the inflammation will spread up the fingers, and, in the case of the thumb and little finger, will likely involve the synovial sacs beneath the annular ligament and appear above the wrist, but, in the case of the index, middle and ring fingers, it will spread up as far as the necks of the metacarpal bones only, since the sheaths for these fingers end here.

Tuberculosis of the Wrist Joint.—It would seem probable that, in tuberculosis of the wrist joint, the tubercle bacilli first lodge in the os magnum and then, after infecting the synovial membrane around this bone, spread to the other bones. The reasons for this belief on the part of the author were stated in a contribution to the "Annals of Surgery," August, 1900, and briefly were (1) that the os magnum is the central bone of the hand and articulates with a greater number of bones than any other of the carpus, and (2) that, for this reason, traumatism

affect this bone more than any other; (3) that to it more ligaments are attached and there would, therefore, be greater chance for it to be injured, and, lastly, (4) that the examination of the skiagraphs of a number of cases of tuberculosis of the wrist joint showed, that in every one of them, the disease had started in the os magnum.

Operative Work on the Hand and Wrist.—

In *whitlow* make an incision down through the diseased structures on either side of the middle line of the finger. Do not delay, since the septic processes spread rapidly, and the only hope of saving the phalanx, or even the finger, will consist in early incision.

Should the inflammation involve the synovial sheaths for the index, middle or ring fingers, it will be limited above at the necks of the metacarpal bones; but, as explained in the preceding section, if the sheaths for the little finger and thumb be involved, there is a strong probability of the disease spreading up to the synovial sacs in the palm, so that, if neglected, there is no telling where the effects may end—destruction of the flexor tendons, involvement of the bones, septicæmia, etc., hence the necessity for early incision. *Incise a palmar abscess* in the palm, or, if pus be above the annular ligament, at the front of the wrist. In the latter situation make an incision about one-quarter of an inch internal to the tendon of the palmaris longus, thus avoiding the ulnar artery which lies half an inch internal to this tendon, and the median nerve lying immediately beneath the tendon. In the palm, make a short, deep incision, bearing in mind the situation of the superficial palmar arch. Hilton's method is not as serviceable here, as elsewhere, since the strong dense palmar fascia opposes the divulsion of the tissues necessary for the success of this method. In *Dupuytren's contraction* the fibres and the processes of the palmar fascia may be

divided subcutaneously or by the open method. In *amputation* through the second and third phalanges it is advisable to close the synovial sheath, since, if this be not done, there is left an open channel to carry upwards septic infection, should any develop.

In *wounds of the palmar arch*, ligate the vessel, even if the hemorrhage be from the deep arch. The older treatment was to employ the graduated compress, a dangerous procedure, since, in the case of the deep arch, it would be almost impossible to compress the vessel on account of its depth and because of the resistance offered by the palmar fascia, hence, the attempt to use the compress might result in gangrene of the tissues of the hand. If the compress failed, then the ulnar and radial were ligated, and if this did not check the hemorrhage—generally the case, since the circulation would still be carried on by the interosseous above, anastomosing with the carpal arches below, and by the median above, communicating with the branches of the superficial arches below—then the brachial was ligated. If this failed, the hand was amputated—another harsh procedure, to say the least. In these days of asepsis there need be no fear of opening up the synovial cavities in the palm, hence, in the case of a wound of the *superficial arch*, make a vertical incision and expose the wounded vessel and ligate. In the case of the *deep arch* a more extensive incision will be required—an incision reaching from the web of the finger, in a line with the injury, to above the carpus, dividing the palmar fascia and drawing aside the flexor tendons until the wounded vessel is exposed.

Excision of the wrist is indicated especially in tuberculosis of the joint and may be performed through a posterior, and, if necessary, an ulnar incision. In making the posterior incision two landmarks are taken: One, the

centre of the line uniting the two styloid processes, and the other, the base of the second metacarpal bone. The knife, inserted over the base of this metacarpal bone, is carried obliquely upwards to the first landmark and then vertically up to the back of the forearm for about one and a half inches. This incision skirts the extensor indicis tendon which is drawn aside, and the knife is inserted between this tendon and that of the extensor carpi radialis breviar. The incision is deepened at once to the carpus and to the posterior surface of the radius, avoiding the extensor secundi tendon at the upper part of the wound. The posterior ligament of the joint is then opened and the bones removed. Since the os magnum is the central bone, the division of its neck by bone forceps will permit ready access to the rest of the carpus. Should there not be sufficient room to remove the bones through the posterior wound, an ulnar incision may be made on the ulnar side of the extensor carpi ulnaris, extending from a point one inch above the tip of the ulnar styloid process, to a point a little above the base of the metacarpal bone of the little finger.

Dislocation at the wrist joint is rare, and yet, one would expect, from the shape of the articular surfaces, that it would be very common, exposed, as the hand is, to so many injuries from falls, etc. One factor in the prevention of dislocation at this joint is, that the carpus is composed of a number of bones, for, had these bones been replaced by one bone, then vibrations, the result of force applied to the hand, would have been intensified and a fracture or a dislocation would have had greater chance of occurring than with the existing condition of a number of bones bound together, yet separated, so that the vibrations are diffused and lessened, before the wave strikes the wrist joint. The main reason, however, that disloca-

tion is so rare at this joint is, that it is surrounded by a number of tendons—rounded cords, which are powerful agents in protecting the joint. So rare is dislocation at this joint, that Dupuytren at first absolutely denied its occurrence—his argument being, that it was not the ligaments that prevented it, but the fact that the tendons offered such resistance, that even very severe injury was insufficient to tear them, and that, the greater the extension at the joint, the more firmly the tendons are applied to the anterior surface of the wrist, thus resisting displacement. In fact he estimated that it would require a force of about 1,000 pounds to overcome the resistance of these tendons.

When *dislocation* does occur, it is generally backwards, and may be diagnosed from "*Colles' fracture*" by the fact that (1) in dislocation the projecting bones are more abrupt than in the fracture; (2) that reduction may be accomplished suddenly, and (3) that the relative position of the styloid processes is unchanged, *i.e.*, they bear their normal relationship of the radial styloid being three-eighths of an inch nearer the hand than the ulnar styloid, whereas, in "*Colles' fracture*," the styloid process of the radius is driven up to a level with, or even above, that of the ulna. *Dislocation of the first phalanx of the thumb*, backwards, is generally the result of a fall on its distal end and palmar surface causing extreme dorsal flexion, and is very difficult of reduction. The phalanx is generally at right angles to the metacarpal bone, and the obstacle to reduction has been variously stated by different writers.

They considered it due to imprisonment of the head of the metacarpal bone between the two lateral ligaments. Malgaigne and Erichsen stated that the head of the metacarpal was locked between the two heads of the flexor brevis muscle, like a button in a button-hole. Lawrie,

that the anterior ligament falls between the articular surfaces, etc. The methods of treatment are, perhaps, as varied as the causes assigned for the difficulty in reduction, but dorsal flexion is the most generally approved of, and, this failing, extension, followed by division of the lateral ligaments if necessary.

can still be raised (deltoid and supraspinatus) and rotated outwards, (infraspinatus) while the forearm can still be flexed and supinated (brachialis anticus and biceps). The serratus magnus can perform its usual actions, almost in their entirety, but the remaining muscles of the upper extremity, *i.e.*, those supplied by the other brachial nerves, are, however, paralyzed.

In **Klumpke's Paralysis**, *i.e.*, involvement of the first dorsal nerve only, there will be paralysis of the muscles supplied by the ulnar nerve (flexor carpi ulnaris, some of the muscles of the palm, etc.) and, in addition, certain ocular symptoms such as myopia on the side of the lesion, sluggish contraction of the pupil, etc., due probably to implication of the sympathetic through the rami communicantes from the first dorsal nerve.

Individual Nerves.—*Posterior thoracic*, here the serratus magnus is affected with the result that there is "angel wing" deformity and a lessening of the power of raising the arm above the shoulder. *Suprascapular*, in this the supra. and the infraspinati muscles are involved, so that elevation of the arm is slightly affected and outward rotation of the humerus interfered with. This may be shown practically by the inability of the patient to carry the arm, freely, from left to right as in writing.

Circumflex.—In the case of this nerve the deltoid and the teres minor are affected and the patient is unable to raise the arm. This inability to raise the arm might be confused with impaired elevation due to ankylosis of the shoulder joint, but may be diagnosed by the fact that, in the latter case, movement of the humerus by the surgeon would move the scapula also, whereas, in the former condition, *i.e.*, in paralysis of the deltoid, the humerus alone would move when raised by the surgeon.

Musculo-cutaneous.—Loss of power of flexion of the forearm (biceps and brachialis anticus). This loss of flexion is especially marked if the forearm be supinated so that another flexor—the supinator longus—would cease to act.

Musculo-spiral.—Loss of power of the extensors of the forearm, thumb, and of the fingers, as well as of the supinator brevis. This injury is frequently the result of pressure by a crutch in the axilla, or, of lying, while intoxicated, with the forearm under the head, etc. It may also arise from injury to the nerve in fracture of the humerus. The triceps and the anconeus, being paralyzed, cause loss of power of extending the forearm. The loss of power of the extensors of the wrist, thumb and fingers, results in “wrist drop.” The fingers are flexed from the unopposed action of the muscles supplied by the ulnar and median nerves. Extension of the second and third phalanges, however, may still be performed by the interossei and lumbricales (supplied by the ulnar and median nerves). Sensation in this injury is lost on the outer side of the arm from the insertion of the deltoid down to the external condyle; on the outer side of the forearm, except about its middle third which is supplied by the unimpaired musculo-cutaneous nerve, and, lastly, on the outer side of the dorsum of the hand, and over the greater part of the dorsal surfaces of the thumb, index, middle, and the outer half of the ring fingers. The patient will have his forearm flexed and somewhat pronated while the fingers and thumb will be flexed.

Median nerve.—Here the arm is unaffected, but, in the forearm, pronation is almost lost, although modified form of pronation is present, since the supinator longus may still pronate the hand, *i.e.*, bring it to a position of mid-pronation if it be first supinated, and then, when it is

carried this far by the supinator, the weight of the hand will cause it to fall inwards, *i.e.*, to pronate it. Flexion of the fingers is interfered with, from paralysis of the superficial and some of the deep flexors. The inner half of the flexor profundus can still flex the last phalanges of the little and ring fingers, while the interossei, along with the two inner lumbricales, can flex the first phalanges of all the fingers since these muscles are supplied by the intact ulnar nerve. Abduction and flexion of the thumb is interfered with, while median and radial flexion of the wrist is lost, although ulnar flexion is not, since the unaffected flexor carpi ulnaris can still act. Anæsthesia is present over the middle and outer side of the palm of the hand, and over most of the thumb, index, middle and the outer half of the ring fingers. The unopposed action of the intact muscles will cause the forearm to be partially supinated and the fingers and thumb extended.

Ulnar Nerve.—This nerve supplies the inner half of the flexor profundus, and hence flexion of the third phalanges of the little and ring fingers will be lost. Ulnar flexion of the wrist is lost, and the interossei and the two inner lumbricales being paralyzed, it is impossible to flex the first, or to extend the second and third phalanges of the fingers, and, therefore, the first phalanx is extended by the common extensor, and the second and third phalanges are flexed by the unopposed long flexor tendons, giving a “claw-like” appearance to the the hand, while the thumb is abducted and slightly extended.

CHAPTER X.

THE THORAX.

REGIONS OF THE CHEST. STRUCTURES FORM- ING THORACIC WALL. MAMMARY GLAND.	LANDMARKS OF THORAX. DEFORMITIES. OPERATIONS.
--	--

Regional Divisions of the Chest.—For the purpose of locating physical signs in connection with the lungs and pleuræ, the surface of the thorax is divided into regions by the following imaginary *lines*:—(1) *Sternal lines*, *i.e.*, midsternal line, in the middle of the sternum; lateral sternal, on either side of the sternum, and parasternal, midway between the lateral sternal and the mammary lines. (2) *Mammary*, from the clavicle down through the nipple to the lower limit of the thorax. (3) *Coracoid*, from the beak of the coracoid process downwards. (4) *Midaxillary*, down the middle of the axilla. (5) *Scapular*, from the inferior angle of the scapula. (6) *Midspinal*; the middle line of the spine. The *regions* are: 1. *Median*, bounded by the lateral sternal lines and divided into three parts: (a) Suprasternal, above the sternum; (b) upper sternal, bounded above by the upper border of sternum, and below by a line joining the lower borders of the cartilages of the third ribs; (c) lower sternal from the above line to the lower limit of the sternum. 2. *Antero-lateral region*, bounded internally by the lateral sternal and externally by the coracoid line and divided into (a) the supra clavicular, above the clavicle, and bounded above by a line drawn

from a little beyond the middle of the clavicle to the cricoid cartilage; (b) the clavicular, beneath the clavicle; (c) the infraclavicular, below the clavicle and bounded inferiorly by the lower border of the third rib; (d) the mammary, from the lower border of the third rib, down to the lower border of the sixth rib; (e) the inframammary, from the lower border of the sixth rib, to the lower limit of the thorax. 3. *Axillary region*, bounded in front by the coracoid line, and behind by the axillary border of the scapula, and below this by the scapular line. This region is divided into (a) the axillary from the apex of the axilla to the level of a line drawn from the lower border of the sixth rib in front and crossing this region about the lower border of the eighth rib; (b) the infra-axillary, extending from the above line downwards to the lower limit of the chest wall. 4. *Posterior region*, from the axillary border of the scapula and from the scapular line externally, to the midspinal line internally, including, therefore, (a) the supra, and (b) the infraspinous areas, above and below the spine of the scapula, respectively; (c) the interscapular between the scapulæ; (d) the infrascapular between the scapular line externally and the midspinal line internally, the upper limit of this infrascapular space being the line from the angle of the scapula to the spine, and the lower limit, the margin of the thorax below.

The Structures covering the Thorax are:

In front, the integument and fascia with the following *muscles* external to the ribs, viz., the subclavius, the pectoralis major and minor, the serratus magnus and the external oblique; posteriorly, are the latiss. dorsi, the trapezius, the scapular muscles and the deeper muscles of the lateral spinal regions. Between the ribs, the following structures are found: The external intercostals covered by the external intercostal fascia and separated from the in-

ternal intercostal muscles by an areolar tissue in which the intercostal nerve, artery and vein run. Beneath the internal intercostals are the internal intercostal fascia, the subpleural tissue and the pleura. In front, between the pleura and the internal intercostal fascia, is the internal mammary artery.

Examining some of the above structures in detail we find, 1. That the *superficial fascia* is supplied by the supraclavicular, the suprasternal, and the supra-acromial branches of the cervical plexus; by the anterior and the lateral cutaneous branches of the intercostals, and posteriorly, by the cutaneous branches of the posterior divisions of the intercostal nerves. 2. This superficial fascia splits or divides into two layers to enclose the mammary gland, hence, the gland is an epidermic structure.

The Mammary Gland is composed of from 15 to 20 lobes, each separated and supported by a fibrous partition, and each having a duct converging to the nipple, which is situated in the male, about four inches from the middle of the sternum, in the fourth interspace. From the anterior layer of the superficial fascia covering the gland, there pass forwards into the skin numerous fibres, termed "ligamenta suspensoria," while the posterior layer of this superficial fascia is separated from the deep fascia by a delicate areolar tissue in which lymph spaces of considerable size may be found, termed the "submammary bursæ." The *arteries* supplying the mammary gland are: The superior and the acromio-thoracic above and externally; the long thoracic and the external mammary below and externally; the perforating from the internal mammary internally, and, lastly, branches from the trunks of the intercostals distributed to the deep surface of the gland. The *lymphatics* of the mammary gland pass in three directions, the majority going to the

anterior set of the axillary glands, and then on, towards the set around the axillary vein. Some, piercing the intercostal muscles go to the thoracic duct in the posterior mediastinum, while others, entering the anterior mediastinum through the second and fourth interspaces, pass through glands in this mediastinum and, after communicating with the lymphatics ascending from the surface of the liver, empty into the junction of the internal jugular and the subclavian veins. This arrangement of the lymphatics explains the dissemination of *malignant disease* to the axilla when the outer quadrant of the breast is affected, and the possible involvement of the ribs, pleura and liver, when the inner quadrant is diseased. Gross states that, out of 128 post-mortems, the axillary glands were affected in 90%, the pleura in 23%, and the liver in 43% (some of the subjects having more than one region affected). The dimpling and puckering of the skin in mammary cancer is due to the disease extending along the ligamenta suspensoria, and the subsequent contraction of the newly-formed fibrous tissue. The rich lymphatic supply of the mammary gland and the early involvement thereof, warrant Halsted's operation—a very radical procedure and consisting of the complete removal of all the tissues of this region down to the ribs. The *nerves* supplying the gland are the anterior thoracics, the anterior divisions of the lateral cutaneous branches of the intercostals, the terminations of the intercostals, a few filaments of the supraclavicular nerve, twigs from the fourth, fifth and sixth intercostal trunks to the deep surface of the gland, and, lastly, the sympathetic. This nervous distribution explains the reference of the pain in mastitis, or inflammation of the mammary gland, to the region of the sternum in front (anterior divisions of the intercostal nerves); to the area over and between the scap-

ulæ (posterior divisions of the same nerves); to the neck (supraclavicular); down the arm (intercosto-humeral from the intercostal, or through the anterior thoracics to the brachial plexus); while the connection with the sympathetic explains the intimate association between the genital organs and the breast.

The circumference of the mammary gland is not circular but presents three projections, one towards the sternum and two towards the axilla—one above, and the other below. Occasionally, there exist smaller extensions from the under surface of the gland that pierce the deep fascia and even penetrate the substance of the pectoral muscle. These processes may be left behind, if the pectoralis major be not removed in the operation for mammary cancer and may, therefore, form nuclei for the recurrence of the disease. 3. The *external intercostal muscles* extend from the tuberosities of the ribs behind, to the costal cartilages in front, and pass obliquely downwards and forwards from the lower border of the rib above, to the upper border of the rib below, and, where these muscles are deficient in front, they are replaced by the anterior intercostal aponeuroses. 4. The *internal intercostals*, on the other hand, pass downwards and backwards from one rib to the other and extend from the sternum in front to the angles of the ribs behind, and are replaced posteriorly by the posterior intercostal aponeuroses.

Functions.—These intercostal muscles are concerned with respiration and enlarge the chest in its antero-posterior diameter by elevating the cartilages and the sternum, and, in its lateral diameter by rotating the individual ribs. 5. The *intercostal nerves*, derived from the dorsal portion of the spinal cord, pass forward between the two planes of intercostal muscles to about the midaxillary line, where they enter the internal muscles and continue onwards in

their substance almost as far as the cartilages, near which, they pass beneath the internal muscles, and then, piercing them close to the sternum, become cutaneous. 6. The *intercostal vessels* pass diagonally across the parallelogram bounded by the ribs, above and below; internally, by the lamina of the vertebræ, and externally, by a line joining the angles of the ribs. After giving off branches to the ribs below, they continue onwards in the subcostal grooves on the lower borders of the ribs above, and anastomose with intercostal branches from the internal mammary artery. 7. The *internal mammary* is a branch of the first part of the subclavian and descends behind the costal cartilages as far as the sixth, where it divides into the musculo-phrenic and the superior epigastric arteries. 8. The *Sternum*.—In the middle line, under the skin and superficial fascia, is the sternum, consisting of the manubrium, the gladiolus, and the ensiform cartilage. It forms the bottom of the sternal groove between the pectoral muscles. Above the sternum is the suprasternal notch, while below, is a depression called the subcostal angle, in the centre of which the ensiform cartilage projects. The sternum, with its costal cartilages, is directed obliquely downwards and forwards, so as to form an angle of 25° or 30° with the vertical line. The sternum is developed from six centres, those for the body or gladiolus being placed side by side, and hence, arrested development of this part may result in the production of a foramen or fissure between the lateral centres. Lastly, two small bones, vestigial structures, are occasionally found close to the upper border of the sternum, and are called “episternal bones.”

Landmarks of the Thoracic Wall.—The upper border of the *sternum* is on a level with the intervertebral disk between the second and third dorsal vertebræ. The *junction* of the *manubrium* and *gladiolus* forms a promi-

nent ridge—the “angulus Ludovici”—which corresponds to (a) the junction of the second costal cartilages with the sternum; (b) the arch of the aorta; (c) the bifurcation of the trachea; (d) the meeting point of the anterior borders of the right and left lungs; (e) the middle of the fifth dorsal vertebra; (f) about the upper limit of the pericardium and the lower limit of the superior mediastinum. The *lower border of the gladiolus, i.e.,* the junction of the gladiolus and the ensiform cartilage, is on a level with the disk between the ninth and tenth dorsal vertebræ. The *ribs*, twelve in number, pass in a curved manner obliquely downwards and forwards. The extent of this obliquity reaches its maximum at the ninth and decreases from this to the twelfth rib, and is such, that the anterior end of one rib is about on a level with the head of the fourth rib below—thus the second is on the same level as the head of the sixth rib, the third, as that of the seventh, etc. The ribs increase in length from the first to the seventh, below which they decrease to the twelfth, whereas they decrease in breadth from the first downwards. Lastly, they are elastic, mobile arches, and the degree of mobility increases from the first to the eleventh, which, with the twelfth, are very mobile. The intercostal spaces are wider in front than behind, and the first three are widest of all. *Rules for counting the ribs.*—In front, the simplest and most trustworthy method is to establish the situation of the second rib by feeling for the ridge of junction of the manubrium and gladiolus, which corresponds to this rib, and then count downwards. This may be confirmed by feeling for the twelfth or lowest rib, at the same time bearing in mind that this may be rudimentary, and then, counting from it upwards. The seventh can be recognized by its being the last to articulate with the sternum, while the nipple, in the male, lies between the fourth and fifth ribs,

about one inch outside their cartilages. *Landmarks for the junction of the ribs with their cartilages.*—Draw a line from a point half an inch external to the sterno-clavicular articulation, downwards and outwards, to the tip of the eleventh rib. (Fig. 7.) *Scapula.*—The upper border of the scapula corresponds to the upper border of the second rib, or, to the tip of the first dorsal spinous process. The spine of the scapula corresponds to the tip of the third dorsal spine, or, to the space between the third and fourth spines; the inferior angle is on a line with the lower border of the seventh rib, or with the tip of the sixth dorsal spine. (Fig. 8.) The *tips* of the *spines* of the *dorsal vertebrae*, from the third to the ninth, are on a level with the lower borders of the bodies of the vertebræ next below, and each, roughly corresponds to the head of the rib belonging to the second vertebra below, thus the spine of the third vertebra corresponds to the head of the fifth rib; that of the fourth to the head of the sixth rib, etc., whereas, each tip of the spinous processes of the other vertebræ, is about on a line with the lower border of the vertebra to which the spine belongs. The tip of the twelfth rib, however, is on a level with the second lumbar spine. The relative *position* of the *intercostal vessels and nerves* is, both from above downwards, and from within, outwards, as follows: Vein, artery and nerve. *Internal mammary artery.*—A line drawn from a point half an inch external to the sterno-clavicular articulation, parallel with, and half an inch from the lateral margin of the sternum and terminating about the lower border of the sixth costal cartilage. (Fig. 6.)

Deformities of the Chest.—Certain effects may result from the action of muscles on defective osseous tissue, or may arise from deficient atmospheric pressure on the inner aspect of the thorax, as seen in such diseased conditions as rickets, chronic tonsillar hypertrophy, etc.

These effects are: (a) A nodular condition of the ribs at their junction with the cartilages—"rickety rosary"; (b) a depression on the outer side of these nodules; (c) a projection anteriorly of the body of the sternum, *i.e.*, pigeon breast, and (d) a groove, "Harrison's groove," running transversely outwards from the ensiform cartilage towards the axilla—the result of the inward traction of the diaphragm during respiration.

Operations on the Thorax.—The ordinary operation for the *removal of the breast* is performed by making two elliptical incisions, joining, externally, near the axilla, and, internally, towards the sternum. The general direction of these incisions will be, if possible, from above downwards and inwards, and the upper end may be prolonged into the axilla if it be found necessary to remove any axillary glands. *Halsted's operation* for mammary cancer is employed when it is desirable to remove all the soft tissues, and the usual incision starts on the humerus and sweeps inwards over the thorax in a curved manner, so as to enclose the breast. The incision resembles an inverted figure 6, and through it, the breast and the muscles down to the ribs with the adipose tissue and the glands of the axilla, are removed. To render the operation as bloodless as possible, from sixty to one hundred pairs of forceps may have to be employed. *Thoracotomy*, or incision into the thorax, is generally performed for empyema, and in this operation the pleura is opened through an incision two or three inches in length. The arm is raised from the side and a skin incision, about half an inch higher than the intended opening in the pleura, is made, so that, when afterwards the arm is brought down to the side, the completed opening will not be valvular. The division of the intercostal muscles should be made close to the upper border of the rib below, so as to avoid any possibility of wounding the trunk of the intercostal artery

that runs along the lower border of the rib above. The wound is generally made in the axillary region, either in the eighth or ninth intercostal space, close in front of the scapular line, or higher up through the sixth or seventh intercostal space in the midaxillary line, and the structures divided are: The integument, superficial and deep fasciæ, serratus magnus muscle, external intercostal fascia, external intercostal muscle, middle intercostal fascia, internal intercostal muscle, internal intercostal fascia, subpleural tissue and the pleura. An incision made elsewhere would necessarily be much deeper than in this region, since the pectoralis major in front, and the latiss. dorsi and dorsi muscles behind, would add to the depth of the wound, while an operation in the anterior portion of the intercostal spaces might divide the internal mammary artery near the sternum, or the trunk of the intercostal artery, where it crosses the parallelogram, referred to on page 117, if the incision be made in the posterior region.

Exsection of a rib is employed when the space between the adjoining ribs is not sufficient for proper drainage, and is done through an incision similar to that of thoracotomy, with the exception that, instead of dividing the intercostal muscles to expose the pleura, this membrane, in exsection, is opened after stripping back the periosteum and dividing the rib. If the rib were sawn through before separating the periosteum from it, the intercostal artery would be wounded at an inopportune time, *i.e.*, before it could be readily ligated, whereas, when the periosteum is pushed back, it carries the vessel with it, so that, it may be divided and ligated after the rib has been removed. *Estlander's operation* consists in the removal of the parts of a number of ribs, to allow the chest wall to fall in, on a lung that has been compressed by the pressure of a long-standing empyema, and is performed in a manner similar to exsection.

CHAPTER XI.

THE PLEURA.

DESCRIPTION. PLEURISY.
PESSURE EFFECTS.

The pleural cavity is a potential space between the lung and the walls of the compartment that contains the lung—these walls are: The inner surface of the thorax, the upper surface of the diaphragm and the outer surface of the pericardium and the large blood vessels above the pericardium. The synovial membrane forming the pleural sac may be considered to have been “tucked” in, between the lung and these walls. The portion of the pleura that covers the lung is termed the visceral layer, while that lining the walls of the receiving cavity is the parietal layer. The external surface of both the visceral and the parietal layers is rough and fibrous and is attached to the structures it covers, especially over the lung and diaphragm, whereas, the free surface is smooth and glistening and secretes a fluid which permits the lung to glide readily over the contiguous surfaces. The usual quantity of the secretion is about two drachms, but it may be enormously increased when the pleura is diseased, as, for instance, in pleurisy with effusion. We have stated that the cavity of the pleura is potential, *i.e.*, that it does not exist as an actual or real cavity, except in pathological conditions, such as pleurisy, pneumo-thorax, etc., the reason being, that the two layers, visceral and parietal, are in close contact, excepting along the lower border, where the parietal layer extends for about one inch anteriorly, and two and a half inches posteriorly, below the visceral layer, so as to accommodate the descent of the lung in inspiration.

Yet even here, there is no actual space existing, since the two walls of the parietal layer are in contact, excepting when the margin of the lung descends between them. The lung is entirely free in the cavity of the pleura, except at the situation of the root of the lung, and at the point where the lung is attached to the side of the pericardium by the broad ligament. The *broad ligament* may be better appreciated, if the thorax of a subject be opened, and the hand introduced into the pleural sac. Under these circumstances, it is found, that the hand will readily pass over the apex of the lung, and then glide downwards over the inner surface, nearly as far as its middle, where it is stopped by the root of the lung. On the outer aspect the hand passes over the external surface and around the posterior border, while below, it can be inserted between the under surface of the lung and the upper surface of the diaphragm. Internally, however, it cannot pass from the anterior border to the posterior border over the inner surface of the lung; there is some obstacle to its progress in this direction, and this obstacle is composed of the root of the lung above, and the ligamentum pulmonalium latum, or broad ligament, below. This ligament is formed by a duplicature of the pleural membrane and reaches from the root above, to the diaphragm, below, and from the lung, externally, to the pericardium, internally.

Diseases of the Pleura.—*Pleurisy.*—In the early stages of this disease, *pain*, stich-like in character, is felt, due, partly to irritation of the sensory nerves in the inflamed pleura, and partly to the friction of the diseased surfaces. The side affected is kept, as much as possible, at rest, by means of reflex muscular action through irritation of the intercostal nerves, which supply the pleura as well as the intercostal muscles. Reflex action may result from disturbance of the phrenic nerve also, since this nerve sup-

plies the pleura as well as the diaphragm. In the next stage of pleurisy, *i.e.*, the stage of *effusion*, the following conditions may be present:—1. *The lung may be compressed*, but not to any great extent, unless the chest be at least two-thirds full of fluid, since the retractility of the lung prevents any decided compression, unless this amount be present. In cases of extreme effusion the lung may be forced into a bulk, one-third or even one-sixth, its normal size. 2. *The heart may be displaced*. Normally the heart and the mediastinum are held in position by the retraction caused by the elasticity of one lung counterbalancing that resulting from the elasticity of the other, and hence, when one lung is, even slightly compressed, its power of retraction is lessened, while the retractility of the sound side draws the mediastinum and heart over towards itself. This is the probable explanation of the slight displacement of the heart found in the early stages of pleurisy, when only a small amount of effusion is present. But, when the quantity of fluid is markedly increased, then it mechanically forces the heart and the mediastinum over towards the sound side. 3. *Displacement downwards, of the liver, stomach and spleen*. This occurs when the amount of fluid is considerable, so that its weight, mechanically, lowers the arch of the diaphragm, and displaces these organs downwards. 4. *Disappearance of the tympanitic sound in Traube's semilunar space*. This space is situated on the left side, is half-moon in shape, and is about four inches in width; the upper limit extends from the sixth costal cartilage in front, and passes in a curved manner, with the concavity downwards, to the tenth rib, *i.e.*, to the anterior border of the spleen. The space is bounded, inferiorly, by the lower margin of the thorax. The tympanitic sound, elicited in the normal state by percussion over this region, depends for its pro-

duction on the presence of the stomach beneath the diaphragm, but, when the pleura contains fluid and the stomach is displaced downwards, then the tympanitic note disappears and is replaced by dullness on percussion.

The landmarks for the pleura will be considered along with those for the lung.

CHAPTER XII.

LUNG.

ANATOMY. LANDMARKS FOR LUNGS.

LANDMARKS FOR PLEURÆ.

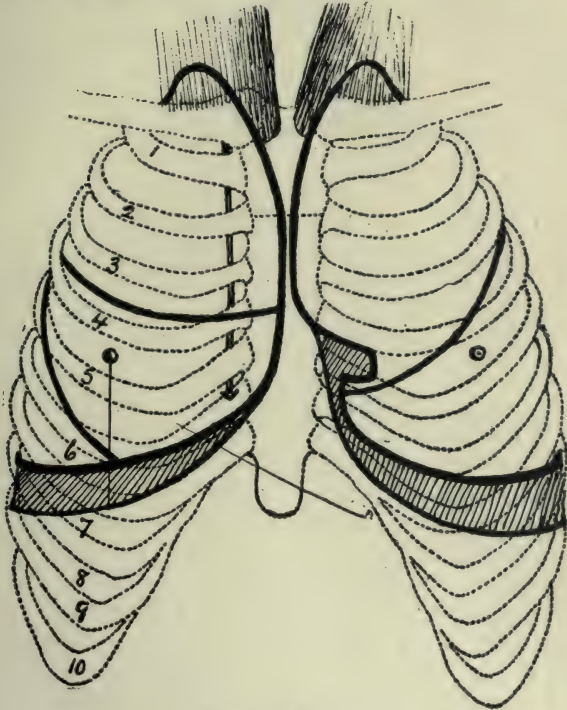
The right lung is shorter than the left, because of the higher position of the diaphragm on the right side. It is broader than the left, on account of the inclination of the heart to that side. Each lung is composed of an apex extending into the neck, of a base resting on the diaphragm, of an internal surface in contact with the pericardium and the great vessels above the pericardium, of an external surface, applied to the inner wall of the thorax, of an anterior border, thin and sharp, and of a posterior border, rounded and wide, resting in the groove on the side of the bodies of the vertebræ. The lung is held in its place by the elasticity of its tissues, and by the atmospheric pressure present in its interior. It is supported by the root and by the broad ligament. The *root of the lung* is about one and three-quarter inches, from above, downwards, and one inch, from before, backwards, and is situated a little above the middle of the internal surface of the lung and a little nearer the posterior than the anterior border. The root is composed of the bronchus, the pulmonary artery and veins, the bronchial artery and vein, the pulmonary plexus of nerves, lymphatic glands and areolar tissue. *Relations of the root of the lung.*—On the right side there are in front of it; the anterior pulmonary plexus, the phrenic nerve, the right auricle, the ascending aorta and the superior vena cava; above, the vena azygos major arches over the root to empty into the superior vena cava; behind, are the posterior pulmonary plexus and the pneu-

mogastric nerve, while below, is the ligamentum pulmonalum latum. On the *left side* the relations are: In front, the anterior pulmonary plexus and the phrenic nerve; above, the arch of the aorta; behind, the posterior pulmonary plexus, the pneumogastric nerve and the descending aorta; while below, is the ligamentum pulmonalum latum. The right lung has a chief or *greater fissure* running from the posterior border, near the apex, downwards and forwards to the inferior border, and a *lesser fissure*, beginning about the middle of the former, and passing forwards to the anterior border of the lung. The right lung is, therefore, divided into three lobes—upper, middle and lower—by means of these two fissures, whereas the left lung is divided into two lobes only, an upper and a lower one, by a fissure, which, beginning near the upper part of the posterior border, runs downwards and forwards to the lower part of the anterior border of this lung.

Landmarks for the Lungs.—To trace the *anterior border*, begin at the apex, *i.e.*, at a point about one inch above the clavicle, and a little nearer the posterior than the anterior border of the sterno-mastoid muscle, and draw a line, downwards and forwards, towards and crossing the sterno-clavicular articulation and the outer edge of the manubrium. This can represent the outline of the upper part of the anterior border of each lung. Continue these lines for the upper part of the anterior borders downwards, so as to nearly meet opposite the second costal cartilage, *i.e.*, at the junction of the manubrium and the gladiolus. Prolong these lines down the sternum, still nearly touching one another, until the fourth costal cartilage is reached, at which point, the left border leaves the sternum and passes outwards, in a manner to be described presently. The line for the *right lung* passes down, in

the original direction, until it reaches the junction of the sixth costal cartilage with the sternum, where it changes its direction, and becomes the inferior border. This passes outwards, and crosses the lower border of the sixth rib in the mammary line, the eighth rib in the midaxillary line, and the tenth in the scapular line, and then terminates behind at the level of the tenth dorsal spine. On the *left side*, after the line for the anterior margin leaves the sternum at the level of the fourth cartilage, it passes downwards and outwards, along the lower border of this cartilage for about one and a half inches. It then drops downwards, for about half an inch, to the upper border of the fifth cartilage, then inwards, towards the sternum, for a distance of half an inch along the fifth cartilage, and then, downwards, half an inch to the sixth, after which it continues outwards in a manner similar to, though at a slightly lower level than, the line already described for the lower border of the right lung. (Fig. 6.) The *posterior border* of the lung corresponds to a line starting at a point opposite the seventh cervical spine, and, at a distance of about one inch from the midspinal line and then passing downwards, to terminate about the level of the tenth dorsal spine. The *greater fissure of the right lung* may be represented by a line drawn from the third dorsal spine, downwards and forwards, to where the sixth rib is crossed by the inferior border of the lung, *i.e.*, to the point where the mammary line meets the sixth rib. Another landmark for this fissure is the situation of the posterior border of the scapula, when the arm is raised so that the hand rests on the back of the head. (Fig. 8.) The *lesser fissure* of the right lung agrees, fairly well, with a line drawn from the point where the greater fissure crosses the midaxillary line, to the junction of the fourth costal cartilage, on the right side, with the sternum. The *fissure of the left lung*

is a little higher than that of the right, and corresponds to a line drawn from the second dorsal spine to the point where the fifth rib is crossed by the anterior border of the lung (Fig. 6). The individual lobes of each lung would



(Fig. 6.)
Landmarks for Lungs and Pleuræ.

be marked out by these lines, and the physician conversant with them would be in a position to form an opinion as to the extent of the local involvement in pneumonia, etc., and would be able to recognize which lobe was affected,

and whether the disease was spreading from one lobe to another or not.

Landmarks for the Roots of the Lungs.—The *root* of the *right lung* extends from a point opposite the lower border of the second right costal cartilage, about half an inch from the right edge of the sternum, to the upper border of the fourth cartilage, the same distance from the sternum, while the *root* of the *left lung* corresponds to a line drawn from the upper border of the third left costal cartilage, down to the middle of the fourth, at a distance of about one inch from the left border of the sternum. Thus, it will be seen that the root of the left lung is farther away from the sternum than that of the right, and this is due to the projection of the mediastinum to the left side. Further, the left root is on a lower level, *i.e.*, farther down than the right, because of the presence of the aorta which arches over it and displaces it downwards, so that, while the *right bronchus* enters the lung at the level of the fifth dorsal vertebra, the *left bronchus* enters at the level of the sixth dorsal vertebra.

Landmarks for Pleurae.—The *landmarks* for the *Pleurae* agree with those for the outlines of the lungs, with the exception of the region of the fifth left cartilage, and along the lower borders. In the region of the fifth left cartilage there is considerable variation, according to the different observers, in the direction of the pleura. Sick found that, in the majority of twenty-three cases examined by him, the pleura had not left the sternum at the level of the sixth costal cartilage, *i.e.*, that it extended over the cardiac area, and did not follow the margin of the lung. Luschka (Quain) states that, at the level of the fifth cartilage, the pleura is one-twelfth of an inch; at the sixth, four-fifths of an inch, and at the seventh, one and two-fifths of an inch external to the left border of the

sternum; so that evidently the anterior margin of the left pleura does not agree with the anterior border of the lung in the neighborhood of the fifth and sixth left costal cartilages (Fig. 6). Nor does it correspond with the inferior border of the lung, since the pleura descends lower than the inferior margin of the lung, for the purpose of accommodating the latter in inspiration. The lower border of the pleura may be represented by a line crossing the mammary, the midaxillary and the scapular lines, about the level of the seventh, ninth and eleventh ribs, respectively, and terminating, posteriorly, about the level of the twelfth dorsal spine, although, occasionally, it descends as low as the first lumbar spine, in which case there would be danger of wounding it in operative work on the kidney if the lumbar incision were made close up to the last rib. *Operative work on the pleura* has been dealt with on page 120 when discussing operations on the thoracic walls; whereas, *on the lung*, the operation of pneumotomy may be performed. This means an opening into the lung, for the purpose of evacuating an abscess in its interior, and is performed by making an incision down to the pleura, as in thoracotomy, and then, with a trocar and canula, seeking for the pus which, if found, should be evacuated and the channel then enlarged by means of a pair of forceps.

CHAPTER XIII.

PERICARDIUM.

ANATOMY. PERICARDITIS WITH EFFUSION. OPERATIONS.

Anatomy.—The *pericardium* is a fibro-serous sac enclosing the heart and is situated between the pleuræ. It has, in front, the following structures: The remains of the thymus gland; the anterior margins of the lungs; the lymphatic structures and areolar tissue; the internal mammary arteries, and the triangularis sterni muscle. Behind, it rests on the aorta, the bronchi and the œsophagus, while, laterally, the phrenic nerves and the phrenic vessels lie between it and the pleuræ. Its base rests upon and is attached to the central tendon and to some of the adjacent muscular tissue of the diaphragm, while its apex is directed upwards and surrounds the great vessels. That part of the thoracic wall in front of it, is composed of the sternum with the third, fourth, fifth and sixth costal cartilages on the right side, and the corresponding cartilages with portions of the ribs on the left side. The pericardium consists of two layers—an external fibrous and an internal serous layer, and where the bloodvessels pierce the pericardium the fibrous layer ensheathes them and blends with their outer coats. In the case of the aorta, this projection of the fibrous layer of the pericardium over the vessels becomes continuous with the cervical fascia, which is prolonged downwards from the neck, so that the cervical fascia holds up the pericardium and the pericardium supports the diaphragm to which it is attached. The serous layer of the pericardium is reflected onto the vessels as they pierce the pericardial sac, and passes along them to the heart, which it surrounds. The connection of the deep cervical fascia with the pericardium

will be again referred to, when speaking of "tracheal tugging" in the diagnosis of aortic aneurism.

In **Pericarditis with Effusion** the fluid in the sac causes a muffling of the sounds of the heart and an increase in the area of cardiac dullness. In *dilatation of the heart* the sounds are also muffled or weakened and the area of dullness is increased, but, in these two conditions, *i.e.*, pericarditis with effusion and dilatation of the heart, the shape of the dullness differs, since, in the former, it is triangular in shape, with the apex upwards and the base downwards (agreeing with the outline of the pericardium itself), whereas, in the latter, *i.e.*, in dilatation, the area of dullness will depend on the particular cavity of the heart affected.

A sign of some importance in pericarditis with effusion is Bamberger's sign. This consists in an area of dullness about the size of a silver dollar, situated at the inferior angle of the left scapula and over which, increased fremitus and bronchial breathing are evident. This area disappears if the patient bends forward, to reappear when he assumes the upright position.

Operations.—To *aspirate* in pericarditis with effusion, the needle should be inserted in the fifth left interspace, about two inches from the sternum, so as to avoid the left internal mammary artery, but, when pus is present in the pericardial sac, instead of withdrawing it by aspiration, an *incision* may be made for the purpose of evacuating it. The steps in this operation of draining the sac in suppurative pericarditis, as advised by Porter, of Boston, are as follows: An incision is made from the middle of the sternum outwards along the fifth left costal cartilage as far as its junction with the rib. The soft parts are cleaned from the rib with a periosteal elevator, the cartilage is divided and removed, the internal mammary artery is ex-

posed on removal of the cartilage and is then divided between two ligatures, the triangularis sterni muscle is pushed to the right, the pericardium is exposed and the sac is opened by an incision beginning close to the sternum and running obliquely downwards and outwards. In this operation it is possible that the edge of the left pleura may not present itself sufficiently to be in the way, although, as will be seen under the subject of landmarks for the pleura, there is considerable variation in the arrangement of the pleural border in this situation.

CHAPTER XIV.

THE HEART.

ANATOMY.

LANDMARKS.

CLINICAL EXAMINATION OF HEART AND LUNGS.

PERCUSSION.

CARDIAC NEUROSES.

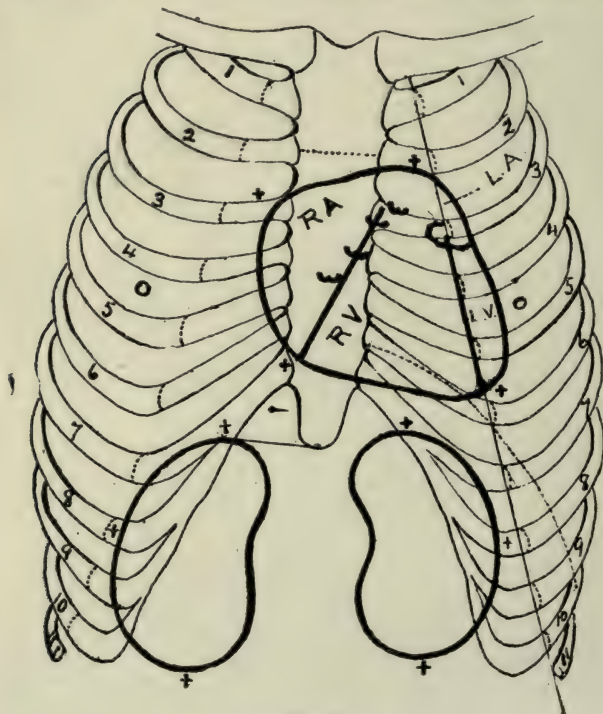
The heart is contained in the pericardium and consists of a base directed upwards and backwards towards the fifth, sixth, seventh and eighth dorsal vertebræ, and an apex, downwards and forwards, towards the ribs. This position of the axis of the heart causes the anterior surface to be directed upwards and forwards, and the posterior surface, which rests on the pericardium where it is attached to the diaphragm, to be directed downwards and backwards. The heart measures five inches in length, three and a half inches in breadth and two and a half inches in thickness, and is so situated that it extends one and a half inches to the right and three and a half inches to the left of the middle line of the sternum. The walls of the right auricle are thinner than those of the left auricle, whereas the left ventricle, having to propel the blood a greater distance than the right, is much thicker than the latter. Grooves on the surfaces of the heart, indicate the separation of the auricles from the ventricles and the ventricles from each other, thus the auricles are separated from the ventricles by the auriculo-ventricular grooves, and the ventricles from one another by the interventricular grooves. The anterior surface is composed mainly of the right ventricle, with the right auricle on its right, and the left ventricle on its left, while the very small portion of the left auricle exposed, lies above the left ventricle. The posterior surface, where it rests on the diaphragm, is formed by both right and left ventricles, the latter, however, constituting the chief part of this surface.

Landmarks. (Fig. 7).—To map out the heart on the walls of the chest, begin about an inch from the sternum, along the lower border of the left second costal cartilage, and draw a line obliquely across the sternum, to terminate at the upper border of the third right cartilage, about half an inch from the sternum. This represents the line for the base of the heart, whereas, the apex is situated about one and a half inches below and three-quarters of an inch internal to the nipple, or, in the left fifth interspace, three and a half inches from the middle of the sternum. The line for the lower border, *i.e.*, the portion that is seen to rest on the diaphragm, when viewed from the front, is drawn from the junction of the seventh right costal cartilage with the sternum, as far as the apex. The outline for the right side corresponds to a line joining the right extremity of the base-line to the right extremity of the line for the lower border, and so curved that it extends one and a half inches to the right of the middle line of the sternum; while the remaining part of the outline, *i.e.*, the left border, is represented by a curved line situated internal to the nipple and joining the left extremity of the base line to the apex of the heart. To indicate *the cavities* on the anterior surface of the heart, it is necessary to identify the separating grooves, and this may be done as follows: The anterior *auriculo-ventricular groove* is represented by a line drawn from the junction of the third left costal cartilage with the sternum, and passing obliquely downwards to the right, to terminate at the junction of the seventh right cartilage with the sternum. This groove is not permanently fixed, since it is carried to the left in systole and to the right in diastole, on account of the right auricle becoming nearly twice as wide, in the former as in the latter condition. The line for the *interventricular groove* starts at the junction of the third left rib with its

costal cartilage and runs downwards and outwards to the junction of the fifth left rib with its cartilage. Another method of marking the line for this groove is to locate the line for the junctions of the ribs with their cartilages on the left side, then, that portion of it lying between the third and fifth ribs indicates the groove. By means of the landmarks for these two grooves, the four cavities on the anterior surface of the heart may be located thus: The *right auricle* lies between the line for the auriculo-ventricular groove and those for the right border and the base; the *right ventricle*, between the line for the auriculo-ventricular groove and the line for the interventricular groove; the *left ventricle*, between the interventricular groove and the left border of the heart, while the *left auricle* constitutes the remaining part embraced within the general outline of the heart. As seen by these markings, the right ventricle is triangular in shape with its apex upwards, lies behind the left part of the sternum and the left costal cartilages, and is limited above, *i.e.*, at the apex by the third left cartilage and below by the line for the lower border of the heart, whereas, the left ventricle, viewed anteriorly, is a long narrow strip forming the left border of the heart. The *right appendix auriculæ* lies behind the junction of the third left cartilage with the sternum, whereas, the *left appendix* is beneath the third left cartilage near its junction with the rib, *i.e.*, about one inch from the left border of the sternum.

Situation of the Valves of the Heart.—The *pulmonary valves* are behind the upper border of the third costal cartilage close to the left margin of the sternum. The *aortic* lie behind the left margin of the sternum close to the junction of the third cartilage with that bone. The *mitral* are a little nearer the middle line of the sternum

than the aortic and are opposite the fourth costal cartilages, while the *tricuspid* are about the middle of the sternum opposite the fourth intercostal spaces. Thus it will be seen that the valves of the heart are situated from above downward and from without inward in the following order, viz.: Pulmonary, aortic, mitral and tricuspid,



(Fig. 7.)

Landmarks for Heart, Kidneys and Traube's Space.

memorized by the letters, P. A. M. T. On account of the proximity of these valves to one another it would be almost impossible to differentiate an abnormal sound re-

sulting from a defect in their structure, hence, points other than these situations are chosen, at which to apply the stethoscope in *auscultation*, and these are, for the *pulmonary valves*, at the second left interspace, because the artery lies behind this space and the current of blood conveys the murmur so that it is best heard here. To listen for the sounds of the *aortic valves*, apply the stethoscope to the second right interspace (the aorta lying behind this space); for sounds of the *mitral valves*, apply it over the apex of the heart, and, for the *tricuspid*, over the middle of the sternum opposite the fourth interspace, or close to the lower left border of the sternum, *i.e.*, over the right ventricle. A *penetrating wound* of the third, fourth, fifth or sixth interspace on the *right side* close to the sternum would enter the right auricle after passing through the integument, superficial and deep fasciæ, anterior intercostal aponeurosis, internal intercostal muscle, internal intercostal fascia, triangularis sterni muscle, subpleural tissue, parietal layer of pleura, lung (excepting in the sixth space) covered by the visceral pleura, and, lastly, the pericardium with the parietal layer of pleura over it. A similarly situated wound, on the *left side*, would penetrate the same structures as on the right, with the exception of the right auricle (replaced by the right ventricle), and of the lung in the lower spaces, since the heart in these spaces is uncovered by the lung. The pleura, also, may escape injury on the left side.

Clinical Examination of the Heart and Lungs.—Heart.—The apex of the heart in the adult, is normally situated in the left fifth interspace within the nipple line, but, in the young, it is, as a rule, somewhat higher up, and, in the old, somewhat lower down than this point. The apex may be displaced (1) *upwards*, when the diaphragm is raised, as in meteorism, ascites,

etc.; (2) *downwards*, from hypertrophy of the right ventricle, or from depression of the diaphragm; (3) *towards the left*, from dilatation and hypertrophy of the ventricles, or, from right-sided pleural effusions, or, left-sided pleural contraction, *i.e.*, retraction; (4) *towards the right*, from left-sided effusions, or from right-sided retractions.

Percussion.—Heart.—On percussing from above downwards, in a line immediately to the *left* of the sternum, the resonance begins to change about the lower border of the third costal cartilage. The note yielded from this point, down to the lower level of the fourth costal cartilage, is termed “relative cardiac dullness” and corresponds to the underlying heart covered by a thin layer of lung tissue, while immediately below the fourth cartilage, on this side, the note becomes completely dull—“absolute cardiac dullness.” This area, of absolute dullness, merges, below, into the dullness arising from the liver. To define the *right limit* of cardiac dullness, percuss, by placing the finger vertically on the right side of the thorax, beginning at the mammary line about the level of the fifth rib, and working in towards the sternum. To define the *left limit*, begin at the left coracoid line and percuss inwards, towards the sternum. In the normal heart the note will begin to change, a little to the inner side of the mammary line, at which point the area of “relative cardiac dullness” begins. This area of “relative” or superficial cardiac dullness merges into the area of “absolute” or deep cardiac dullness at a point about an inch inside of the mammary line, and the area of “absolute dullness” corresponds, roughly, to a circle two inches in diameter drawn around a point midway between the nipple and the lower end of the gladiolus. “Absolute cardiac dullness” is generally diminished in emphysema, but increased in hypertrophy and in those diseases in which the lung is re-

tracted, such, for instance, as fibroid phthisis, etc. Abrams, of San Francisco, in a paper illustrating, by means of fluoroscopic drawings, the situation of the heart when displaced upwards by dilatation of the stomach, showed that, in extreme cases, it may be raised to such a degree that the lower border corresponds to the level of the third rib. He drew attention to a patch of dullness that could be detected in the interscapular region, on the left side, about the middle of the posterior border of the scapula, when the heart was dislocated upwards by a dilated stomach. He found that this dullness disappeared when the patient leaned forwards and was then replaced by the normal resonance of the lung, and he, therefore, concluded that this dullness was due to compression of the lung by the displaced heart.

Lungs.—On percussing from above downwards on the *right side* and in the *mammary line*, the normal resonant note of pulmonary tissue begins to change about the upper border of the fifth rib, because of the underlying liver—"relative hepatic dullness." When the lower border of the sixth rib is reached this "relative" changes into "absolute hepatic dullness," since here the liver is uncovered by the lung, although it still has the pleura overlying it, and this "absolute dullness" continues until the lower limit of the chest is reached. On the *left side*, in the *mammary line*, there is normal pulmonary resonance, from above downwards, until the level of the sixth rib is reached, below which point, *i.e.*, in the area of Traube's semilunar space, the presence of the underlying stomach gives a tympanitic note. On the *right side*, in the *axillary line*, the normal resonance gradually lessens until about the eighth rib when "absolute hepatic dullness" is reached. This dullness ceases at the eleventh rib, to be replaced by the tympanitic note of the intestine. In the *left axillary*

line at the level of the eighth rib, the normal resonance becomes tympanitic, because of the underlying stomach and intestine. On the *back* the note is resonant, from the apex of the lung downwards, until the level of the tenth dorsal spine is reached, at which level, hepatic dullness is evident on the right side and spleno-renal dullness on the left side.

Cardiac Neuroses.—*Nerves of the Heart.*—The heart is controlled by intracardiac nerves situated in its walls, and by extracardiac nerves, which are external to the heart and are derived from the *superficial* and the *deep cardiac plexuses*. These plexuses are situated above the heart, the *superficial* one lying on the anterior surface of the right pulmonary artery, below the arch of the aorta, whereas, the *deep* one is found behind the arch of the aorta, and, between it, and the bifurcation of the trachea. The superficial plexus is formed by the left superior cardiac branch of the sympathetic, and the left inferior cervical cardiac branch of the pneumogastric along with branches from the deep plexus. The remaining cardiac branches from both the cervical sympathetic and the pneumogastric, go to the deep cardiac plexus. The branches of distribution from these plexuses constitute the anterior and the posterior coronary and the anterior and the posterior pulmonary plexuses.

In *angina pectoris* a prominent symptom, in addition to the fear of impending death, is *pain* of an excruciating character. This pain may be due to a spasm of the muscular structure of the heart from defective nutrition, the result of an atheromatous condition of the coronary arteries, or it may depend on some primary disturbance of the cardiac plexuses. The pain is frequently transmitted to the arm, occasionally to the side of the neck and rarely to the face. The nervous

paths, utilized in the transmission of *pain to the arm in angina pectoris*, may be: From the cardiac plexus to the cervical cardiac branches of the middle and inferior cervical ganglia of the sympathetic, then through the communicating branches from the middle ganglia to the fifth and sixth cervical nerves, or through the branches from the inferior ganglia to the seventh and eighth nerves, and, lastly, through these trunks to the brachial plexus and thus down the arm. Another path may be: Through the few filaments connecting the cardiac plexus with the first dorsal sympathetic ganglion, and, then, through the rami communicantes which unite this first dorsal ganglion to the first dorsal nerve and thus into the brachial plexus. When the pain is felt in the neck, it may be due to a reflex act passing up from the cardiac plexus to the superior cervical ganglion of the sympathetic, and then, by means of the external branches of this ganglion, to the four upper cervical nerves, from which nerves branches are distributed to the superficial structures of the neck. Lastly, when the face is affected, the paths are the same as in the case of the neck, excepting that the branches from the superior cervical ganglion communicate with the cranial nerves instead of with the cervical. In neurasthenia, pain and tenderness are very often present in the precordial region, and are occasionally found in the neighborhood of the second left costal cartilage, about one inch from the sternum. One explanation of the above precordial symptoms is, that they are due to a localized disturbance of the cardiac plexuses, but, while this may account for the pain, it would hardly explain the presence of the tenderness. Tenderness must be associated with irritation of the intercostal nerves themselves. The possible path, in this case, may be: From the cardiac plexus to the inferior cervical ganglion of the sympathetic, thence

down the chain of thoracic ganglion and through the rami communicantes into the intercostals. With reference to the pain felt over the second left cartilage, the path may be that referred to above, when dealing with pain in the neck in angina pectoris, the particular superficial nerve in the case of pain over the cartilage being the supraclavicular. By means of the cardiac plexuses, and, through their contributing branches from the pneumogastric and the sympathetic nerves, the heart is brought into intimate relationship with other important viscera. Thus, by them, the abdominal viscera are brought into association with the heart, so that any disturbance of these organs shows itself in disorder of the cardiac rhythm, such, for instance, as acceleration of the heart beat, through the cardiac branch of the sympathetic, or, inhibition of it, through the inhibitory branch from the pneumogastric. A clinical example of the above effects is seen in injuries to the intestine, where the irritation is conveyed to the solar plexus by the mesenteric nerves and from the solar plexus to the pneumogastric, and then through the inhibitory branch of the latter to the heart, causing slowing, and even arrest, of the action of that organ.

CHAPTER XV.

MEDIASTINUM.

ANATOMY AND DESCRIPTION OF CONTENTS.

ARTERIES.

TRACHEA.

LANDMARKS.

ŒSOPHAGUS.

VEINS.

THORACIC DUCT.

LANDMARKS.

NERVES.

STRUCTURES OPPOSITE FOURTH DORSAL VERT.

The *mediastinum* is the space in the middle of the chest formed by the non-approximation of the pleuræ. This space is bounded, in front, by the sternum; behind, by the vertebræ; laterally, by the pleuræ, and contains all of the thoracic structures with the exception of the lungs and pleuræ. When the chest of a subject is opened and the lungs removed, the mediastinum is readily appreciated and is seen to form a *pyramidal-shaped column* with a base, about five inches in breadth, resting on the diaphragm, and an apex, about three inches wide, corresponding to the thoracic inlet. About an inch below the inlet, *i.e.*, about opposite the middle of the manubrium, the mediastinal column is contracted, so as to measure only about one and a half inches from side to side. The measurements of the upper opening of the thorax are, on an average, about five inches transversely and about two and a half inches from before backwards, and, since the width of the apex of the mediastinum is about three inches, the remaining two inches of the transverse diameter of the inlet are occupied by the apices of the lungs. The mediastinal column is divided into two parts by an imaginary plane which passes through it at the upper limit of the pericardium, and which corresponds to the junction of the manubrium and the gladiolus, anteriorly, and, to

the lower part of the body of the fourth dorsal vertebra, posteriorly. This imaginary plane is not exactly horizontal, since, a horizontal plane from the junction of the manubrium and gladiolus in front, would touch the middle of the fifth dorsal vertebra behind. That portion of the mediastinal column which lies above this imaginary plane, is termed the superior mediastinum, while that below it is the inferior mediastinum. The principal part of the latter is that which contains the heart and the pericardium, and is styled the middle mediastinum; the small space in front of the pericardium, and between it and the sternum and left cartilages, is the anterior mediastinum; while the portion of the column behind the pericardium, and between it and the vertebræ, is the posterior mediastinum. All the structures, that enter or leave the thorax through the inlet, pass through the *superior mediastinum*, but, below this, they may pass through either the anterior, the middle, or the inferior mediastinum. In the *anterior mediastinum* are (1) the remains of the thymus gland, (2) lymphatics ascending from the liver with two or three lymphatic glands, and (3) the left internal mammary artery. In the *middle mediastinum* are (1) the heart enclosed in the pericardium with (2) the phrenic nerve on either side of it, (3) the pulmonary arteries and veins, (4) lower half of the superior vena cava, (5) the termination of the vena azygos major, (6) the ascending aorta, and (7) the roots of the lungs. In the *posterior* are (1) the œsophagus, (2) the pneumogastric, and (3) the sympathetic nerves, (4) the thoracic aorta, (5) the azygos veins, (6) the thoracic duct, and (7) lymphatic glands. Of the above structures we will first consider (1) **the arteries.** *The ascending aorta* is two inches in length, and passes from the left ventricle upwards, forwards and to the right. It ascends as high as the upper

border of the second rib, and, therefore, lies behind the second right intercostal space. This vessel is almost entirely within the pericardium, and, when distended, is distant from the sternum about one-quarter of an inch. The *arch or transverse aorta* passes, with a gentle curve, backwards from the level of the upper border of the second right cartilage, at its junction with the sternum, to the left side of the fourth dorsal vertebra, behind. This portion of the aorta is about two inches in length, and the convexity spoken of is directed upwards and to the right. In its course backwards, it lies behind the first piece of the sternum, and the highest point of the vessel is about one inch below the upper border of that bone. *The thoracic aorta* begins where the arch ends, viz., at the lower border of the fourth dorsal vertebra, and passes downwards in the posterior mediastinum to become the abdominal aorta after piercing the diaphragm in front of the twelfth dorsal vertebra.

From the transverse part of the arch are given off the large vessels that supply the head, neck and upper extremities, viz., the innominate, the left common carotid and the left subclavian arteries. These vessels arise from before, backwards, in the order named, and, so close are their origins to one another, that, if we removed the inferior portion of the arch and viewed the orifices of the branches, from below, it would be seen that they were separated, from each other, by a thin strip only, of the aortic wall. The *innominate* is about one and a half inches long and passes upwards, a little forwards and to the right, to terminate at the upper limit of the right sterno-clavicular articulation, where it divides into the right common carotid and the right subclavian. The *left common carotid*, about one and three-quarter inches in length, arises close to the left of the innominate and ascends, obliquely, to the upper

limit of the left sterno-clavicular articulation. The *left subclavian*, about two and a half inches in length, arises on a plane posterior to, and a little to the left of the carotid, and ascends almost vertically to the thoracic inlet, where it curves outward over the apex of the left lung and pleura to the inner border of the scalenus anticus muscle. The variations that have been met with in the aortic arch are numerous and are due to abnormalities in the development of the vessel from the embryonic vessels, *i.e.*, from the ventral aortic stem, the dorsal stem and the fourth and fifth branchial arches joining them. One of these departures from the normal condition is occlusion of the arch at its junction with the thoracic aorta just below the ductus arteriosus, and, in this condition, the anastomosis, whereby the circulation is still carried on, is as follows: The internal mammary communicates with the intercostals, with the deep epigastric, and with the phrenic branch of the abdominal aorta, by means of the musculo-phrenic and the comes nervi phrenici. The superior intercostal from the subclavian communicates with the first aortic intercostal; while the transversalis colli and the suprascapular anastomose with the intercostals and with the branches of the axillary artery.

Landmarks for the Arteries.—To mark out the *ascending aorta* draw a line, with a slight convexity to the right, from a point a little to the left of the centre of the sternum on a level with the middle of the third costal cartilages, to the upper border of the second right costal cartilage. Since the *transverse aorta* passes almost directly backwards behind the first piece of the sternum, it cannot be readily mapped out, nor, can the descending aorta, because of its depth. The *innominate* is represented by a line drawn from a point a little to the right of the centre of the manubrium and about one inch below the upper

border of the bone, to the upper limit of the right sterno-clavicular articulation. *Left common carotid*, by a line starting a little to the left of the preceding and terminating at the upper border of the left sterno-clavicular articulation. *The left subclavian* may be represented by a line, which, beginning a little to the left of the origin of the common carotid, *i.e.*, nearer to the left border of the sternum, is drawn upwards to a point, about half an inch external to the left sterno-clavicular articulation, and thence, with concavity downwards, to end a little to the inner side of the middle of the clavicle.

The Veins.—The veins of the mediastina are the left and right innominate, the superior and inferior venæ cavæ, the azygos, the bronchial and the pulmonary veins. The *right innominate*, about one inch in length, brings the blood from the right upper extremity and from the right side of the head and neck, from the region of the right internal mammary artery, and, occasionally, from the first and second intercostal spaces. It passes vertically downwards from its origin, *i.e.*, the junction of the right internal jugular with the subclavian vein, to form the superior vena cava by uniting with the left innominate vein at the lower border of the first costal cartilage on the right side. The *left innominate*, about two and a half inches long, conveys the blood from the left upper limb, left side of the head and neck, left internal mammary and bronchial veins, and from the upper two or three left intercostal spaces. It runs obliquely across the superior mediastinum from the inner end of the left clavicle to the lower border of the first cartilage on the right side, and lies behind the first piece of the sternum and in front of the large branches of the transverse aorta. There are no valves in the innominate veins. In the fœtus, and, rarely in the adult, the left innominate empties, separately, into

the right auricle, a small connecting branch uniting the two vessels. The usual arrangement is for this connecting branch to enlarge, and for the portion of the left vein below it, to become obliterated, excepting at its termination in the heart, where it becomes the coronary sinus, the obliterated portion being termed the vestigial fold of Marshall. The *superior vena cava*, formed by the union of the two innominates, is about two and a half inches in length, and empties into the right auricle near the middle of the sternum, on a level with the upper border of the third left costal cartilage. The *inferior vena cava* brings the blood from the lower half of the body, and, after piercing the diaphragm and pericardium, enters the right auricle. The *azygos veins*, right and left, arise in the abdomen from branches of the lumbar veins, and enter the thorax, the right one through the aortic opening and the left one in the substance of the left crus. These azygos veins are situated in the posterior mediastinum and act, as main sewer veins, for the majority of the intercostal spaces, but not for all of them, since the upper spaces are drained by the superior intercostal veins. The left veins cross about the level of the seventh or eighth dorsal vertebra and unite with the vena azygos major, though occasionally, the left upper vein joins the left superior intercostal. The vena azygos major arches over the root of the right lung, and, after receiving the right bronchial vein, empties into the superior vena cava just before the latter vessel pierces the pericardium.

Landmarks for the Veins.—The *left innominate vein* may be represented by a line drawn across the manubrium, from the left sterno-clavicular articulation, to the lower border of the first costal cartilage on the right side, about half an inch to the right of the sternum. *Right innominate vein*, by a line starting at the upper border of

the right sterno-clavicular articulation and passing, almost vertically downwards, to the lower border of the first right costal cartilage, about half an inch to the right of the sternum. *Superior vena cava*, by a line drawn from the lower border of the first costal cartilage on the right side, to the middle line of the sternum on a level with the upper border of the third costal cartilage. The *inferior vena cava* enters the right auricle at the level of the fifth right interspace and the adjoining portion of the sternum.

3. **The Trachea.**— *The trachea* is about four and a half inches in length and three-quarters of an inch wide, and extends from the lower border of the cricoid cartilage, on a level with the upper border of the sixth cervical vertebra, to the lower border of the fourth, or, to the middle of the fifth dorsal vertebra. The principal relations in front of the trachea are the arch of the aorta and its branches, the latter lying directly in front of the trachea at their origins, but diverging above, so as to lie partially on either side, at their terminations, and the former, *i.e.*, the arch itself passing obliquely across the bifurcation, the deep cardiac plexus lying between. Behind, the trachea rests on the œsophagus and divides into its two bronchi, right and left; the former, one inch in length, is nearly horizontal in direction, and enters the lung, about the fifth dorsal vertebra, while the latter, two inches long, passes downwards and to the left and enters the lung at about the level of the sixth vertebra, after running under the left portion of the arch of the aorta.

4. **The Oesophagus**, about nine inches long, begins at the upper border of the cricoid cartilage, and about on a level with the intervertebral disk between the fifth and sixth cervical vertebræ. It passes down the neck deviating to the left, and, on entering the superior mediastinum, inclines towards the middle line again, which it

reaches about the upper border of the fifth dorsal vertebra. Continuing its course downwards in front of the thoracic vertebræ, it again inclines to the left, about two inches above the aortic opening in the diaphragm, and, passing in front of the aorta, pierces the diaphragm on a level with the upper border of the tenth dorsal vertebra. The œsophagus is situated in the superior mediastinum, above, and in the posterior mediastinum, below, and has in front of it: The trachea, the left common carotid and left subclavian arteries, the arch of the aorta, the left bronchus, the pericardium and the left pneumogastric nerve, which forms a plexus on its surface. Behind, it rests on the longus colli muscles in front of the vertebral column; on the intercostal vessels and the thoracic duct, and on the aorta, just above the diaphragm, and has the pneumogastric forming a plexus on its posterior wall; laterally, it has the pleura and the azygos vein on the right, and the aorta and the pleura on the left. Having the same function as the intestine, viz., the involuntary passage of the food, it has a somewhat similar structure, and is, to some extent, steadied in its passage through the posterior mediastinum by accessory slips, which extend from the longitudinal muscular coat, to the pleuræ, to the left bronchus and to the pericardium. On examining the relations of the structures in the vicinity of the *left end of the transverse aorta* we notice, that the aorta and the left bronchus cross in front of the œsophagus, and that the pneumogastric nerve passes down in front of the left end of the aorta and then between the aorta and the left bronchus, so as to reach the anterior surface of the œsophagus. At the lower border of the aorta, the pneumogastric gives off the recurrent laryngeal branch, which is distributed to the larynx. So that, at the left end of the transverse part of the aorta, these important structures, viz., the œsophagus,

the left bronchus, the pneumogastric and the recurrent laryngeal nerves, are grouped closely together, and, therefore, an aneurism affecting this portion of the aorta may, at a very early stage, produce serious symptoms. This grouping occurs in the neighborhood of the *fourth dorsal vertebra*.

5. **The Thoracic Duct**, eighteen inches long, begins in front of the second lumbar as a dilatation—the receptaculum chyli, which, receives lymph and chyle, by means of three branches, one from the intestine and two from the lower extremities. This duct carries the lymph from the whole of the body with the exception of the right side of the thorax, head and neck, the right arm and lung, and the upper border of the liver. It perforates the diaphragm at the aortic opening and then passes up in the posterior mediastinum, between the aorta and vena azygos major, lying on the right side of the former until it reaches the fourth dorsal vertebra, where it passes to the left, behind the aortic arch, and then runs upwards in the superior mediastinum, on the left side of the œsophagus, to the seventh cervical vertebra, where it arches over the left pleura and lung, to empty into the junction of the left internal jugular and the left subclavian vein. Its diameter is about that of a goose quill, although it gradually narrows from below upwards until it reaches the lower border of the fourth dorsal vertebra, above which it gradually increases again. The thoracic duct has numerous valves that give it a beaded appearance, while, at its junction with the jugular and subclavian veins, there are two perfect valves which are directed towards the blood current. On reviewing the above we notice that the relative length of the trachea, œsophagus and thoracic duct is four and a half inches, nine inches and eighteen inches, respectively, and that the **fourth dorsal vertebra** corre-

sponds to: (1) The point where the aorta reaches the vertebral column; (2) the lower level of the superior mediastinum; (3) to where the œsophagus passes behind the left end of the arch of the aorta; (4) to about where the œsophagus reaches the middle line; (5) to the bifurcation of the trachea; (6) to the origin of the left recurrent laryngeal nerve; (7) to where the thoracic duct is narrowest, and (8) to where it deviates to the left; (9) to the upper limit of the pericardium, and (10) to the third dorsal spine.

6. **Pneumogastric Nerves.**— On entering the thorax, the *right* nerve takes a different course from the left, since it passes downwards, on the outside of the innominate artery, and, on reaching the side of the trachea, spreads out into a plexus behind the root of the right lung. It then passes to the posterior surface of the œsophagus, on which it forms a plexus, and terminates in the abdomen, by supplying the posterior surface of the stomach, and sending numerous filaments to the cœliac, splenic and the renal plexuses. The *left* pneumogastric enters the chest between the left common carotid and the left subclavian arteries, passes down in front of the arch of the aorta, and, then, behind the root of the left lung and along the anterior surface of the œsophagus to the stomach, which it supplies, and from which filaments are continued onwards to the hepatic plexus. The branches of the pneumogastric nerve to the larynx, viz., the *recurrent laryngeal*, convey motor fibres to all the muscles of the larynx, with the exception of the crico-thyroid; the branches to the *cardiac plexus* contain inhibitory fibres for the heart and, in addition, a few sensory fibres, which form a plexus under the synovial layer of the pericardium that covers the surface of this organ. The *pulmonary branches* supply sensation and motion to the lungs; the motor fibres of these branches influence the involuntary

muscular fibres of the bronchi, while the sensory constitute the cough exciting nerves of the lung. The *oesophageal* plexus gives motion to the muscles of the œsophagus and sensation to the upper part of the tube, the lower portion of the œsophagus being almost entirely devoid of sensation, and, lastly, the *gastric* branches afford motion to the walls of the stomach.

7. The *sympathetic* system of the thorax consists of a set of ganglia lying on either side of the spine, one ganglion for each vertebra, with branches joining them together. External branches connect these ganglia with the intercostal nerves, while internal ones connect them with nearly all the important viscera; thus, the internal branches from the upper three or four thoracic ganglia go to the pericardium, the aorta and the lung, whereas those from the lower eight form the splanchnic nerves that go to the abdomen. The sympathetic lies, partly in the superior, and, partly, in the posterior mediastinum. It carries the *cilio-spinal nerve*, which, emerging from the lower cervical and the upper dorsal segments of the cord, passes into the thoracic sympathetic system to be distributed to the head and neck. This thoracic portion of the sympathetic supplies *accelerating* fibres to the heart and *vasomotor* fibres to the thoracic and abdominal organs, as well as to the walls of the thorax and the upper extremity. The vasomotor for the lungs, etc., arise from the first thoracic ganglia, while those for the skin and walls of the thorax are derived from the dorsal ganglia and communicate with the dorsal intercostal nerves. Those for the upper extremity pass from the middle dorsal ganglia up to the first dorsal, whence they pass to the first dorsal nerve and thence to the brachial plexus. The internal branches of the eight lower ganglia pass down to the abdomen as the *splanchnics* and convey vasomotor fibres to the abdominal viscera.

CHAPTER XVI.

THORACIC ANEURISM.

ANEURISM OF THE AORTA.

Pressure Symptoms on: Œsophagus, Trachea,
Bronchi, Veins, Nerves.

ANEURISM OF BRANCHES.

Innominate, Common Carotid, Subclavian.

Aneurism of the Aorta.—Pressure Symptoms, the result of this condition, may show themselves locally, or at distant points, and may be briefly synopsised as follows :

Pain	Subject to exacerbations.
Pressure on the Œsophagus	Dysphagia.
“ “ “ Trachea	Dyspnœa.
“ “ “ Veins, sup. vena cava, etc	Cyanosis of head, neck and and upper limb.
“ “ “ Nerves. Pneumogastric	1 Disturbance of Cardiac rhythm. 2 Spasm or Paralysis of left vocal cord, hoarseness, brazen cough, etc. (recur- rent laryngeal). 3 Loss of function of cough ex- citing and motor fibres of the lung.
Sympathetic	Vasomotor disturbances— Disturbance of the pupil and of the position of the eyeball.
Intercostal	Pain and possibly herpes zoster.
“ “ “ Bones	Erosion and pain.
“ “ “ Pericardium and fascia prolonged over aorta	“Tracheal Tugging.”
“ “ “ Bloodvessels	Pulse affected as follows :
(a) Left subclavian	Left pulse delayed.
(b) Innominate	Right pulse delayed.
(c) Ascending aorta	Both pulse delayed.
(d) Innominate and ascend- ing aorta	Both pulse delayed, but the right more than the left.

Examining the above in detail we have:

1. **Pain.**—This may be due to the stretching of the aorta plexus of nerves supplying this vessel, or to the pressure of the aneurism on neighboring bones, viz., on the sternum, ribs or vertebræ. The pain is subject to exacerbations, due to increased blood pressure the result of exertion or of excitement of any kind, etc. Occasionally, the pain, like that of angina pectoris, may be referred to other regions, such as down the arm, etc. In this case, *i.e.*, when the arm is affected, the reflex path is through the ganglia of the sympathetic, especially the first thoracic ganglia, to the first dorsal nerve, and thence to the brachial plexus. Again, the pain may be felt very severely in the back or in the front of the chest; here it is due to the connection of the thoracic ganglia with the intercostals.

2. **Oesophagus.**—The result of pressure on this tube is the production of dysphagia, and this is especially liable to occur, if the portion of the aorta dilated be the left end of the arch, since, as already mentioned, this part is in intimate association with the œsophagus, trachea, thoracic duct and the pneumogastric nerve, about the level of the fourth and fifth dorsal vertebræ.

According to Bryant, these points are situated about ten and one-eighth and eleven inches, respectively, from the superior incisor teeth, and, of the remaining vertebræ, the first dorsal is eight inches; the second, eight and five-eighths; the third, nine and three-eighths, and the tenth, fifteen inches from these teeth. Great care should be exercised by the surgeon in examining any *oesophageal obstruction* with a sound, since there is always a possibility that the cause of the obstruction may be an aneurism, separated from the bougie by the comparatively thin wall of the œsophagus only. 3. Pressure on the **trachea** or *bronchi* causes dyspnoea with the production, on auscultation,

of a peculiar harsh sound, heard, at first, in inspiration only, but, later on, in expiration as well. If it be the trachea that is compressed this abnormal sound will be heard over both lungs equally, but, if the pressure be on a bronchus, then the sounds will be heard over the corresponding lung only. In dyspnœa, from such diseases as asthma, etc., the patient will sit as upright as possible and with his head thrown back, but, in dyspnœa from thoracic aneurism, the position assumed is generally with the head forward, as in resting the head on the folded arms on a table, the reason being, that the aneurism presses more on the trachea or bronchus in the recumbent than in the upright position, and hence the patient leans forward to lessen the pressure on these structures. A lesser degree of dyspnœa may be the result of irritation of one recurrent laryngeal nerve, by the aneurism, and this would cause a spasm of one side of the glottis, but, if both nerves be irritated, then the dyspnœa would be extreme.

4. **Effects on the Pulse.**—Normally the radial pulse is one-tenth of a second later than the ventricular impulse, but, should the aneurism affect the innominate artery only, then the right radial pulse would be delayed for a slightly longer period than normal. Should, however, the aneurism affect the left subclavian alone, then the left pulse, only, would be delayed, whereas, if both pulse be delayed, it is probable that it is the ascending part of the aorta that is involved. If both pulse be affected, with the right more than the left, then, it is probable that the innominate and aorta, together, are the vessels affected.

5. **Pressure on the Veins.**—Should the *lower half* of the *superior vena cava* be compressed, there would result a certain amount of cyanosis of the head, neck and upper limbs, the superficial veins becoming distinct and

tortuous. These abnormal appearances would not be very marked, if the part of the vessel within the pericardium were the only portion involved, since the vena azygos major offers a free channel for the collateral circulation; and as this vessel arises from the lumbar veins, which are radicles of the inferior vena cava, and empties into the superior vena cava, the blood can find its way backward through the azygos veins to the inferior vena cava and thence into the heart. Should, however, the whole of the superior vena cava be compressed the blood could not find its way back to the heart through the above mentioned channels, since the termination of the azygos vein in the superior cava would be obliterated, but the circulation can still be carried on through the following channels: (1) The internal mammary veins which communicate with the phrenic and the deep epigastric vessels—branches of the inferior vena cava; (2) the left superior intercostal vein, which brings the left innominate into connection with the left azygos veins, and thence into the inferior cava. Sudden swelling of the arm, or, the arm and one side of the head and neck, without any local inflammatory symptoms, should lead the surgeon to examine for an aneurism compressing the vena innominate, right or left, as the case may be.

6. Pressure on the Nerves.—When the *pneumogastric* is irritated, *i.e.*, when the pressure of the aneurism is not sufficient to completely destroy the functions of the nerve, the rhythm of the heart may be disturbed from irritation of the cardio-inhibitor fibres contained in the nerve; when, however, the degree of pressure is greater than the above, then the functions of this nerve may be entirely suspended, so that acceleration of the heart's action results, because of the unopposed activity of the intact accelerator branch of the sympathetic nerve. Should

the *recurrent laryngeal*, which supplies all the laryngeal muscles with the exception of the crico-thyroid, be disturbed, there would result spasm of these muscles, on the left side, if the nerve be only irritated, but paralysis of one vocal cord—the left—if the nerve be forcibly compressed. If both cords were paralyzed, there would be a condition of almost complete aphonia present, but, where only one cord is affected, as in thoracic aneurism, the other, passing over towards the injured side, compensates, so that the voice is altered in pitch only. When the *branches of the pneumogastric to the lungs* are implicated the cough exciting fibres and the muscular filaments may be excited, when the nerve is only irritated, with the result that there is increased frequency of coughing and, possibly, asthmatic paroxysms. Should, however, these fibres to the lungs be paralyzed, no warning could be given by them as to the presence of mucus, etc., in the bronchial tubes, so that secretions would collect in the lungs and cause irritation, and inasmuch as, the trophic filaments of the nerve would be also affected, inflammatory action would likely follow this irritation. *Motion* of the *oesophagus* and *stomach* would be interfered with if the branches to these organs were disturbed.

Pressure on the *sympathetic* will, among other effects, produce vasomotor disturbance in the parts supplied by this system (page 155). These vasomotor disturbances may show themselves in the shape of an anæmic condition of those particular regions if the sympathetic be merely irritated, but, if the nerve be compressed, a state of congestion would result. Should the cilio-spinal fibres, that emerge from the upper dorsal portion of the cord and pass into the sympathetic system, be affected, there will be dilatation of the pupil and protrusion of the eyeball, if the nerves be irritated, or, contraction of the pupil and retrac-

tion of the eyeball, if paralyzed; while the neck and face may be anæmic or flushed from interference with the vasomotor fibres. *Pressure on the intercostals* may induce pain in the territory supplied by these nerves, or, possibly, an inflammatory condition of the skin, "herpes zoster." Pressure on the *phrenic nerve* may cause hiccough if the nerve be irritated only, or one-sided paralysis of the diaphragm if it be compressed.

7. Tracheal Tugging can be elicited in the following manner: The patient should be erect, with the mouth closed and the chin well elevated. The physician should grasp the cricoid cartilage between the thumb and finger and should make steady pressure upwards, when, if an aneurism be present, a transmitted aortic pulsation may be distinctly felt. This is probably due to the connection of the cricoid cartilage with the aorta through the cervical fascia, a layer of which—the tracheal—overlying the trachea, descends into the middle mediastinum to unite with the fibrous prolongation of the pericardium over the ascending aorta, so that, the pulsation of an aortic aneurism will cause sudden tension of the tracheal portion of the fascia and produce a "jar" or "tug" which can be felt at the upper attachment of the fascia, viz., at the cricoid cartilage.

Tumors of the mediastinum may, like aneurism, cause many of the above symptoms, although there is not the same tendency to exacerbation from exertion in tumors, as there is in aneurism. An enlarged bronchial gland pressing on the vena azygos major, as it arches over the root of the right lung, may dam up the blood in the azygos veins and cause an effusion of fluid into the pleural cavity—hydro-thorax.

The above symptoms are the general results of pressure, resulting from an aortic aneurism, but to be more ex-

plicit, it would be advisable to consider the particular effects following aneurism of the special parts of the vessel, and, in addition, those resulting from dilatation of the great branches of the aorta. *Ascending part of the aorta.*—When the anterior wall of this vessel is involved the aneurism will in time erode the sternum; when the inner wall is affected, it will compress the pulmonary artery and interfere with the passage of the venous blood to the lungs. If it be on the external wall of the vessel, the superior vena cava will be compressed, and, if posteriorly, the bronchus, pulmonary veins and the artery going to the right lung. *Transverse part of the aorta.*—Here, if above, the aneurism will press on the left innominate vein and affect the large branches of the aorta; if in front, the left pneumogastric nerve, left phrenic and the left superior cardiac nerve; if behind, the trachea, the deep cardiac plexus, the œsophagus, the thoracic duct and the left recurrent laryngeal nerve; if below, the recurrent laryngeal and the left bronchus. *Thoracic aorta.*—In front, it would affect the œsophagus below, and the root of the left lung, above; internally, the œsophagus and the thoracic duct; posteriorly, the vertebral column, the intercostal nerves and the ribs. If the aneurism involve the anterior surface of the *innominate artery*, then the sternum and the left innominate vein would be affected; if externally, the right innominate vein and the pneumogastric nerve, whereas, if the aneurism be internally and behind, then the trachea would be compressed. If the *left common carotid* be the one diseased, then the sternum and the left vena innominate, in front, would be pressed upon, while externally, the left pneumogastric nerve, or, behind, the trachea, the œsophagus and the thoracic duct, would be the main structures liable to be injured; lastly, if it be the *left subclavian*, then, in front, would be the pneumo-

gastric, the cardiac and the phrenic nerves, the left innominate vein and the sternum; behind, would be the œsophagus, the sympathetic nerves and the vertebral column, while, internally, and behind are the œsophagus, trachea and the thoracic duct.

Operations on the Mediastinum.—The structures of the mediastinum, on which operative work is sometimes necessary, are: The œsophagus and the trachea. Foreign bodies not infrequently lodge in these tubes and occasionally necessitate, for their removal, an incision through the walls of the tubes. In the case of the *œsophagus*, in addition to the necessity of operation for the removal of a foreign body, it is occasionally necessary to open the canal for the purpose of dividing a stricture, or removing a localized tumor of its walls. Should the foreign body be irregular and jagged, pushing it down, or extracting it by the mouth, would not be allowable, since, extensive injury might result from its removal in this manner, hence it would be advisable to expose it by an external incision at the lower part of the neck, and, generally on the left side. This incision may be adopted for the employment of instruments to dilate a stricture, or, to remove a tumor, but, should the foreign body, or the stricture be situated lower down than the aortic arch, then, an attempt would have to be made from below through the stomach, since the finger can reach only as low down as the level of the arch of the aorta when inserted into the usual wound for œsophagotomy in the neck. After a preliminary gastrotomy, the finger, inserted through the cardiac orifice, may feel the foreign body and assist in its removal, or instruments may be employed to push it through into the stomach. When the operation is to divide a stricture it is termed retrograde dilatation. In Abbe's method, a heavy braided piece of silk is drawn

up through the stricture and the latter divided by a sawing motion. Should, however, the foreign body or the stricture be situated between these points, viz., between the arch of the aorta and the œsophagal opening into the stomach, then it may be necessary to carry out *Bryant's plan of operating through the posterior mediastinum*. This surgeon showed that the distances from the upper incisor teeth to the first, second, third, fourth, fifth and tenth vertebræ were eight, eight and five-eighths, nine and three-eighths, ten and one-eighth, eleven and fifteen inches, respectively, in a person whose stature was five feet eight inches. After establishing the vertebra opposite which the obstruction was, he made a flap, three inches square, including all the tissues down to the ribs, and with the centre rib corresponding to the seat of the obstruction. Dividing three ribs carefully, he exposed the œsophagus and demonstrated the possibility of incising the tube through the posterior mediastinum. Should the obstruction be above the level of the fourth dorsal vertebra, the opening into the mediastinum should be made on the left side of the vertebral column. If, however, it be below the fourth vertebra, then the opening should be made on the right side, and the reason for this is, that the œsophagus lies on the left side of the vertebral column about the level of the fourth vertebra, but on the right side below this point. The same method might be employed in the removal of foreign bodies from the trachea or bronchi where intra-tracheal means failed.

CHAPTER XVII.

THE DIAPHRAGM.

OPENINGS OF	LANDMARKS.
RELATIONS.	AFFECTIONS OF
ACTIONS.	SUPHRENIC ABSCESS.

The Diaphragm is a musculo-fibrous septum between the thoracic and the abdominal cavities and is composed of a tendinous centre, trefoil, or, trilobed, in shape, surrounded by muscular fibres. It presents an appearance somewhat resembling the combined transversales muscles of the abdomen, and arises, anteriorly, from the ensiform cartilage, laterally, from the six lower ribs, and posteriorly, from the sides of the vertebræ by two crura, and from the thickened portions of the lumbar fascia, termed the ligamentum arcuatum externum and internum.

The **openings** of the diaphragm are the aortic, the œsophageal and the caval. The *aortic* transmits the aorta, vena azygos major and the thoracic duct, and is situated in front of the twelfth dorsal vertebra, rather behind, than in the substance of the diaphragm. The *oesophageal*, transmitting the œsophagus and the pneumogastric nerves, is in front, and a little to the left of the aortic. This opening is oval in shape, measuring half an inch by one inch, with the long diameter forward and to the left, and is opposite to the tenth dorsal vertebra. The *caval* transmits the inferior vena cava and is quadrilateral in shape, situated in front and to the right of the preceding, at the junction of the right and middle leaflets of the central tendon, and is opposite the disk between the eighth and ninth dorsal vertebræ. The sympathetic and the greater and lesser splanchnic nerves pass through the *right crus*, whereas, the vena azygos minor and the two left splanchnics pass through the *left crus*.

Relations.—The structures above the diaphragm and in contact with it, are: The pleuræ and the pericardium, the latter being adherent to the central tendinous portion and to some of the adjacent muscular tissue. Below, the concave surface of this structure is in relation with the liver, the stomach, the pancreas, the spleen, the kidneys and the suprarenal capsules, and is covered for the most part by the peritoneum.

Actions.—The contraction of the diaphragm—the result of the flattening of its arched fibres—causes an increase in the vertical diameter of the thorax, with a corresponding diminution in the vertical diameter of the abdomen. The diaphragm is an important muscle in inspiration, since, in addition to increasing the capacity of the thorax in the manner mentioned above, it enlarges it laterally through elevation of the lower ribs by the contraction of those fibres which, arising from the central tendon, act from above, *i.e.*, from this central tendon. In the descent of the diaphragm the whole muscle does not move down uniformly, because the support given to the middle portion of the central tendon by the cervical fascia, prevents the central tendon from being depressed as much as the lateral portions, hence, the right side of the diaphragm is depressed about one inch, the left side about four-fifths of an inch and the central portion about two-fifths of an inch, in inspiration.

Landmarks.—The convexity of the diaphragm is especially marked on the right side, since the position and shape of the liver raise it up in this situation so much that its upper limit, in ordinary expiration, reaches the level of the junction of the fifth costal cartilage with the sternum. Viewed from the side, this point corresponds to the level of the sixth and seventh ribs, while from behind, it corresponds to the level of the eighth rib. The left half of the

dome is on a level with the junction of the left sixth costal cartilage with the sternum; from the side, this level is seen to correspond to the seventh and eighth ribs, and, from behind, to the ninth rib, while the central tendon is on a level with the junction of the ensiform cartilage and the sternum.

Affections of the Diaphragm.—*Diaphragmatic hernia* occurs when the stomach or intestine protrudes through the normal opening situated between the muscular bundles arising from the sternum and those from the ribs. This opening permits the passage of the superior epigastric vessels in the normal state and is filled with areolar tissue. Hernial protrusion is not confined to this portion alone, but may take place elsewhere in the diaphragm, through any abnormal opening—the result of some injury, such as a broken rib, etc. *Pleurisy*, when limited to the portion of the pleura attached to the diaphragm, is termed diaphragmatic pleurisy, and is characterized by severe pain in the region of the diaphragm when this muscle is disturbed, as in respiration, with the result that the patient tries as much as possible to prevent any movement of it, so that the respirations are shallow and principally thoracic. Locally, there is tenderness on pressing upwards in the region of the tenth rib in this affection. When the spinal cord is diseased at the levels of the third and fourth cervical segment, or, compressed in the same situation by a fracture or a dislocation of the vertebræ, or when the phrenic nerve is severely affected by a tumor, or aneurism, or by neuritis, *paralysis* of the *diaphragm* results. The inability of the muscle to contract, when the whole of it is paralyzed, causes the breathing to be almost entirely thoracic, so that the abdomen is retracted in inspiration and forced out in expiration, the opposite of the normal conditions. The patient is unable

to cough, hence, if bronchitis be present, as it frequently is, the gravity of the case is increased. These symptoms are simulated very closely in hysterical paralysis, but, in the latter condition, there is not the same degree of interference with the expansion of the lower ribs that there is in true paralysis of the diaphragm. *Hiccough* is an intermittent spasm of the diaphragm—the result of some disturbance of the phrenic nerve, while, at the same time, there is more or less involvement of the laryngeal branches of the pneumogastric which causes a spasm of the larynx as the air is inspired. In *electro-therapeutics*, one pole may be placed along the posterior border of the sternomastoid, opposite the level of the upper border of the thyroid cartilage, and the other in the region of the diaphragm, for the purpose of applying *electricity to the phrenic nerve*.

Subphrenic Abscess.—A subphrenic abscess is the result of inflammatory action localized under the diaphragm, and on either side of the suspensory ligament above the liver. In it the diaphragm may be pushed as high as the third rib, or the liver may be displaced downwards. When there is air in the abscess cavity, the characteristics of pyo-pneumothorax are closely simulated.

Operation.—The tenth rib at the side should be resected, the diaphragm divided and the abscess reached without injuring the pleura, since the latter does not extend down as far as the tenth rib.

CHAPTER XVIII.

ABDOMEN.

ABDOMINAL PARIETES. REGIONS.	MUSCLES AND THEIR ACTIONS.
STRUCTURES FORMING ANTERO-LATERAL WALLS.	APONEUROSES. NERVES, &c.
SUPERFICIAL FASCIA.	LINEA ALBA. UMBILICUS.

The abdomen is the largest serous cavity of the body, and, when viewed from in front, its anterior surface is seen to be of a somewhat hexagonal shape; the upper limit being the converging thoracic margins; the lower limit, Poupart's ligament, while the sides are represented by the edges of the lateral boundaries. The abdominal cavity is bounded above, by the under surface of the diaphragm; below, by the brim of the true pelvis; behind, by the diaphragm, the quadratus lumborum and psoas muscles, the lumbar fascia, the vertebral column and the posterior portions of the ilia; laterally, by the expanded ilia and the postero-lateral portions of the external oblique, the internal oblique, and the transversalis muscles; while in front, are these muscles with their aponeuroses and, in addition, the recti and the pyramidales muscles.

Regions of the Abdomen.—The abdomen may be divided, for the sake of convenience of description in normal or in pathological conditions, into nine regions, by means of two vertical and two horizontal lines. There have been a number of different markings proposed by anatomical writers for these divisional lines, but perhaps the best, for the *horizontal* lines, are: For the upper plane, a line joining the eleventh rib on either side and passing through the second lumbar vertebra; for the lower plane, one joining the anterior superior iliac spines and passing

about one inch below the promontory of the sacrum. The longitudinal planes may be represented by *vertical lines*, drawn upwards from the middle of Poupart's ligament (Quain, Gray), or, as suggested by Anderson, in Morris' Anatomy, the outer border of the rectal muscles. The latter boundary, *i.e.*, Anderson's, gives a broader space for the inguinal regions, and, besides, contains the whole of the inguinal canal. The names of these regions or divisions resulting from the above lines are: For the upper segment, the epigastric with the hypochondriac on either side; for the middle segment, the umbilical with the lumbar on either side, and for the lower segment, the hypogastric with the inguinal laterally. The location of the viscera occupying these regions will be summarized after the individual organs have been described.

Structures forming the Abdominal walls.—

1. The anterior abdominal muscles. These muscles are covered by the integument and by the *superficial fascia*, which is divisible into two layers, a subcutaneous and a deeper layer. The latter is denser than the former, contains a number of yellow elastic fibres and is loosely attached to the underlying aponeurosis of the external oblique, excepting at the linea alba and umbilicus, where the union between these structures is quite firm. In the inguinal region, these layers are separable and have the superficial vessels and the lymphatics between them, and in this region the deeper layer, termed the "fascia of Scarpa," passes over Poupart's ligament and is attached to the fascia lata immediately below the ligament. Internally, however, this deeper layer of the superficial fascia is unattached to the deeper structures between the pubic spine and the symphysis pubis, but spreads out to form, with some involuntary muscular tissue, the dartos of the scrotum. *Nerve supply.*—These superficial structures are

supplied by the terminal and the lateral cutaneous branches of the lower intercostal nerves, by the ilio-hypogastric, and to a very slight extent, by the ilio-inguinal.

2. Muscles of the Abdomen.—The *external oblique*, arising from the outer surfaces and lower borders of the eight lower ribs, is directed downwards and inwards and terminates, partly in the anterior half of the outer lip of the crest of the ilium, and partly in the aponeurosis to be described presently. The *internal oblique*, the general direction of which is upwards and inwards, arises from the outer half of Poupart's ligament, from the anterior two-thirds of the middle lip of the crest of the ilium and from the posterior lamella of the lumbar fascia, and terminates in an aponeurosis. The *transversalis*, from the outer third of Poupart's ligament, from the anterior three-fourths of the inner lip of the crest of the ilium, from the inner surfaces of the six lower ribs and from the lumbar fascia, is continuous with an aponeurosis also. The *rectus* muscle extends from the crest and anterior surface of the pubes to the cartilages of the fifth, sixth and seventh ribs. It is traversed by three tendinous intersections called the *lineæ transversæ*, which occupy the anterior surface only of the muscle and are adherent to its sheath. These transverse lines probably represent the membranous partitions between the vertebrate segments found in fishes, an arrangement whereby the body is divided into zones—myomeres—by partitions—myocommata. *Pyramidalis*—a small muscle contained in the sheath of the rectus and arising from the front of the pubic bone, and inserted into the linea alba midway between the umbilicus and the pubes.

Actions of the Abdominal Muscles.—When the pelvis is fixed, the abdominal muscles flex the trunk directly to the front when the muscles on both sides act

together, or, to one or the other side, when the individual muscle contracts, the trunk, at the same time, being rotated to the opposite side. When the pelvis and spine are both fixed, they act as muscles of expiration by compressing the lower ribs, but, when the pelvis and thorax are both fixed, they assist the diaphragm in compressing the abdominal viscera. When the thorax alone is fixed, the muscles, contracting, draw the pelvis upwards, as in climbing. The different directions of the fibres of the external and internal oblique, and the transversalis, give additional strength to this region, thus lessening the possibility of a hernia developing. When the recti muscles act from above they flex the pelvis on the vertebral column, and, when from below, they depress the thorax and flex the upper portion of the column, while the pyramidales render tense the linea alba.

3. **Aponeuroses.**—The aponeurosis of the internal oblique divides at the outer border of the rectus muscle (excepting at its lower fourth), and one layer passes in front and the other behind the muscle, to unite at its inner border, in the linea alba. In the lower fourth of the muscle there is no division of the fascia, so that, the whole aponeurosis passes in front of the rectus muscle. The aponeurosis of the external oblique, lying superficial to the preceding, blends with it at the median line and assists in forming the linea alba, while the aponeurosis of the transversalis muscle passes behind the rectus with the posterior layer of the aponeurosis of the internal oblique, except in the lower fourth of the muscle, where it is placed in front. The lower free margin of this posterior sheath of the rectus, formed by the deep layer of the internal oblique aponeurosis and by the transversalis aponeurosis, is termed the *fold of Douglas*, and is arched slightly, so that its con-

cavity is towards the pubes. The arrangement of these muscles and their aponeuroses in the inguinal region will be discussed under the subject of hernia.

4. Nerves of the Abdominal Muscles.—The anterior and lateral muscles of the abdomen are supplied by the lower intercostals—the internal oblique and the transversalis, however, receiving, in addition, branches from the ilio-hypogastric and the ilio-inguinal nerves. The quadratus is enervated by the last dorsal and the anterior branches of the lumbar nerves; the psoas, by the anterior lumbar nerves, while the iliacus is supplied by the anterior crural. In dealing with the upper extremity, we drew attention to the fact that the same nerve that supplies the shoulder joint, supplies, also, the chief muscle controlling that joint and the over-lying skin as well; or, that, as in the case of the sterno-clavicular articulation, the skin over the joint, as well as the chief muscles acting on it, are supplied by the same nerves that supply the joint; so, in the abdomen, we have an arrangement somewhat similar, viz., the *intercostal nerves* supply the integument, as well as the muscles that protect the abdominal viscera, and are, at the same time, intimately connected with the nervous supply for these viscera. The connection of the intercostal nerves with the abdominal organs is by means of the *splanchnic nerves*, and the relationship may be explained thus: The splanchnics arise from the lower thoracic sympathetic ganglia, and communicate by means of the rami communicantes with the intercostals which supply the abdominal muscles, but the splanchnics are the chief afferent branches to the solar plexus, and this plexus, by means of its numerous branches, controls all the abdominal organs, hence, as can be readily seen, there is an intimate nervous relationship between these organs and their protectors, *i.e.*, the abdominal muscles. The prac-

tical benefit of this association is evident in the rigidity of the abdominal muscles that accompanies inflammation of any of the abdominal viscera. There is no such bony framework provided for the protection of the delicate and easily injured abdominal viscera, as there is, for the contents of the thorax, skull or pelvis. It is true these abdominal organs are guarded to some extent by the flexion of the thorax and pelvis, and by the celerity with which the upper extremities can be brought to a position of defence when necessary, but, the principal means for the protection of the viscera is, the almost instantaneous contraction of the abdominal muscles when a possible injury is seen to threaten them, or, when even the slightest touch on the skin indicates approaching danger. The fact of the same nerves, viz., the intercostals, supplying the skin and the muscles together, explains the readiness with which this contraction occurs. Since the abdominal parietes are supplied by the dorsal nerves, pain in the region of the abdomen may be the result of irritation of these nerves, as from caries of the dorsal vertebræ, etc., hence, when examining a patient, and especially a child, it is well to bear in mind this fact, since, it has not infrequently happened that the so-called "stomach-ache" of childhood has been dependent on some irritation of these intercostal nerves, as from spinal disease, etc., rather than on some purely local trouble. The *arteries* supplying the abdominal parietes are: The lower intercostals, the superior, the superficial and the deep epigastrics, the lumbar and the ilio-lumbar. The *lymphatics* may be roughly stated to pass up towards the axilla, from the region above the umbilicus, and, down towards the inguinal glands, from the territory below that point.

The *veins* correspond to the arteries, but in this region there are in addition an occasional vertical vein on the side

of the abdomen, uniting the axillary with the femoral system, and a paraumbilical vein in the broad ligament of the liver near the umbilicus, uniting the remains of the umbilical vein in the ligament with the superficial veins of the abdomen.

5. **The Linea Alba** is a fibrous band stretching from the pubes below, to the ensiform cartilage above. It is the line along which the fibres of the aponeuroses on one side decussate with those of the other. The linea alba has, in addition to these decussating fibres, a small number of vertical fibres. Below, there is a small band given off from the under surface of the linea alba, to the upper border of the pubic bone, and this, situated behind the rectus, is termed the *adminiculum linea alba*. The linea alba is very narrow between the lower portions of the recti muscles, but is broader above, the width in the former situation being one-eighth of an inch or less, whereas, in the latter the average width is about one-quarter of an inch, although, under certain circumstances, such as pregnancy, etc., this width may be much increased.

6. **The Umbilicus** is situated at the junction of the lower two-fifths with the upper three-fifths of the linea alba, and gives passage in the foetus, to the umbilical arteries, to the allantois the inner portion of which becomes the bladder and the urachus in the adult, and to the umbilical veins, right and left,. The umbilicus is a fibrous ring in the substance, or rather composed of the tissues of the linea alba, and, to it, the integument and the superficial tissue, in front, and the peritoneum and the transversalis fascia, behind, are firmly attached. The umbilical ring is closed by scar tissue, the fibres of which interlace, some being circular and others decussating from side to side. The lower half of the umbilicus is stronger than the upper half, since the remains of the umbilical arteries and the urachus, converge to this lower half.

CHAPTER XIX.

ABDOMEN (Continued.)

FASCIÆ LINING THE ABDOMEN.
MUSCLES FORMING POSTERIOR WALL,
THEIR ACTIONS.
LANDMARKS FOR PARIETES.
INJURIES. TUMORS.

Fasciæ Lining the Abdomen.—The membranous structure lining the inner surface of the abdominal muscles is divisible into three parts, viz., the transversalis and the iliac fasciæ and the anterior layer of the lumbar aponeurosis. The *transversalis fascia* is thick where it covers the lower part of the anterior abdominal wall, but becomes gradually thinner, higher up, and, on the under surface of the diaphragm it is continued into a thin layer of areolar tissue; posteriorly, it becomes gradually continuous with the loose tissue behind the kidney and the colon. The *iliac fascia* covers the ilio-psoas muscle and is much denser than the preceding. Externally, it blends with the lumbar fascia, and internally it is attached along the inner border of the psoas, to the sacrum, the intervertebral disks, the margins of the contiguous vertebræ, and to the tendinous arches overlying the lumbar vessels, while, above, it blends with the *ligamentum arcuatum internum*. The disposition of the lower portions of both the transversalis and iliac fasciæ will be described under hernia.

The *lumbar aponeurosis* is divisible into three parts, an anterior, a middle and a posterior. The anterior layer covers the quadratus lumborum muscle and blends with the middle layer at the outer border of that muscle. Above, the anterior layer is attached to the lower border of the last rib, thus forming the *ligamentum arcuatum externum*, while below, it blends with the ilio-lumbar ligament. The

middle layer is attached to the tips of the transverse processes of the lumbar vertebræ and, at the outer edge of the quadratus lumborum, this division of the lumbar fascia blends with the anterior layer, while, on the outer side of the erector spinæ muscle, it receives the posterior layer. This middle layer forms the posterior aponeurosis of the transversalis muscle.

Muscles forming the posterior wall of the abdomen.—The *quadratus lumborum* muscle arises from the ilio-lumbar ligament and from the crest of the ilium for about two inches, and is inserted into the lower border of the last rib for about half its length, and into the tips of the transverse processes of the four upper vertebræ. Another portion of the muscle, arising from the tips of these processes, is inserted into the lower margin of this rib also.

The *psoas magnus* arises from the sides of the bases and lower borders of the transverse processes of the lumbar vertebræ and from the sides of the bodies and the intervertebral substances of the last dorsal and all the lumbar vertebræ and is inserted into the lesser trochanter of the femur.

The *psoas parvus*, from the sides of the last dorsal and first lumbar vertebræ, into the iliac fascia and the pectineal line, together with the *iliacus* from the iliac fossa, from the margin of the crest of the ilium, from the ilio-lumbar ligament, and from the anterior spine of the ilium, into the outer side of the psoas magnus muscle and into the oblique line extending from the lesser trochanter to the linea aspera, complete the muscular protection of the abdomen.

The Actions of these muscles.—The *quadratus lumborum* steadies the last rib when the diaphragm contracts and thus assists inspiration. It also, by depressing the

last rib, assists forced expiration and, when one muscle acts from above, it raises the pelvis toward that side, but, when both act, they flex the trunk when it is extended, and extend it, when already flexed. The *psaos* and *iliacus* acting from above, flex the femur, at the same time, rotating it outwards; from below, they flex the body and also assist in maintaining the upright position. The *psaos parvus* is a tensor of the iliac fascia.

Landmarks of abdominal parietes.—*Nerves*.—Brewer, of New York, gives, as the result of a number of examinations undertaken for the purpose of ascertaining the course of the lower intercostal nerves, the following landmarks: The *seventh* intercostal supplies the neighborhood of the ensiform cartilage. To represent the *eighth* nerve, draw a line from a point immediately below the junction of the eighth costal cartilage with the seventh, upwards towards the sternum. This nerve supplies the "pit" of the stomach. A line drawn from a point just below the junction of the ninth rib with its cartilage, horizontally towards the median line, will correspond to the *ninth* nerve. The *tenth* may be represented by a line drawn from a point half an inch above the tip of the eleventh rib towards the anterior superior spinous process of the opposite ilium, and crossing, therefore, the median line about the level of the umbilicus. For the *eleventh*, draw a line from a point half an inch below the tip of the eleventh rib, towards the middle of the opposite Poupart's ligament, and for the *twelfth*, one drawn from a point half an inch below the tip of the twelfth rib, towards the spine of the pubes of the opposite side. The rest of the lower part of the inguinal region would be supplied by the *iliohypogastric* emerging about one and a half inches above the external abdominal ring, while the *ilio-inguinal* would supply a very small area beneath its point of emergence from the external ring.

Junction of the Muscular and Aponeurotic Fibres of the Abdominal Muscles.—For the *external oblique*, a line drawn downwards from the tip of the tenth costal cartilage to a point half an inch behind and above the anterior iliac spine—this lower muscular angle is quite marked in well developed subjects. For the *internal oblique*, from the tip of the tenth cartilage to the spine of the pubes, *i.e.*, along the outer border of the rectus muscle, and for the *transversalis*, a curved line parallel with, and half an inch from, the seventh costal cartilage above, to about the middle of Poupart's ligament.

The *Rectus* muscle.—The outer border of the rectus corresponds, nearly, to the point of division of the aponeuroses of the internal oblique and lies in a line from the spine of the pubes to the tip of the tenth costal cartilage. The name *linea semilunaris* is given to the aponeurosis, just external to the rectus muscle, and is about three inches distant from the median line, at the level of the umbilicus. The *lineæ transversæ* are situated as follows: One, opposite the umbilicus; another, immediately below the ensiform cartilage, and the third midway between these two. The *umbilicus* is opposite the disk between the third and fourth lumbar vertebræ, is three-quarters of an inch above the level of a line joining the highest points of the iliac crests, is about the same distance above and to the right of the bifurcation of the aorta, and, lastly, is opposite the lower border of the third lumbar spine.

Injuries.—*Wounds.*—In coeliotomy, the incision is generally made in the median line between the umbilicus and the pubes. Here, the linea alba is almost lost and the wound will be between the recti muscles, or, will open the fibres of these muscles. The subsequent development of a hernia is always a possibility in wounds of the abdominal parietes whether inflicted accidentally or intentionally.

In accidental wounds of the abdomen, the important consideration is whether *penetration* or opening up, of the abdominal cavity has occurred or not, as on this depends the gravity of the injury.

The diagnosis of penetration will depend on the size of the instrument inflicting the wound, or, on the position of the wound, etc., and will be indicated by the escape of fæces or gas, extreme shock, continued symptoms of hemorrhage, etc. If it be a non-penetrating wound, the ordinary treatment of a wound, viz., opening it up, removing foreign bodies, etc., suffices. Should it, however, be a penetrating wound, then laparotomy, especially if seen early, *i.e.*, within six hours after the receipt of the injury, should be undertaken. *Contusion* of the abdominal wall may cause extravasation of blood either into the subcutaneous tissues or between the muscles. *Suppuration* in the walls of the abdomen may result from contusions, or, from wounds involving the different muscular planes, and, when present, the pus may burrow considerable distances between these muscles. *Rupture of the abdominal muscles*, especially the rectus, occasionally occurs as the result of a sudden, severe strain in lifting, etc., and is accompanied by a sharp pain as though from the blow of a stick. The treatment is rest and flexion of the lower limbs over a pillow so as to relax the segments of the muscle. *Tumors involving the abdominal wall.*—The commonest form is fibroma arising from the fibrous aponeuroses of the muscles; next, in frequency, is the fibro-sarcoma. *The diagnosis of tumors* of the abdominal walls from those of the interior of the abdomen may be arrived at by noticing the depth of the growth. In the former instance, the tumor will be comparatively superficial, in the latter, it will be more or less deep; besides, if it be superficial, then when the patient is asked to strain, the muscles, with the tumor,

are raised and the latter is made more prominent; whereas, if it be an internal growth, this contraction of the abdominal parietes would more or less obscure the growth. *Phantom tumor*, as already mentioned, is generally the local contraction of a portion of the rectus muscle, especially the upper segment; *i.e.*, that portion immediately below the ensiform cartilage, and, since, the skin overlying it is supplied by the same nerve as the muscle, we can readily understand the sensitiveness of the integument present over the tumor. Osler, in his work on "Abdominal Tumors" mentions a phantom tumor due to a local contraction of the circular muscular fibres of the stomach. In *manual examination* of the abdomen, the patient should lie on his back with his legs drawn up and the examiner's fingers (not the tips) should be gently pressed into the muscles as they are relaxed. This relaxation of the muscles may be secured by asking him to take a deep inspiration and then to hold his breath as long as possible. There naturally follows a gasp after this pause, and during this relaxation the fingers of the surgeon may be employed to ascertain the condition present. It is sometimes advisable to have the patient assume the genu-pectoral position to assist in the diagnosis of abdominal tumors, as, for instance, in distinguishing an aneurism of the aorta from a growth overlying the vessel and receiving pulsation from it. If the patient be placed in the knee-chest position the growth that merely overlies the artery will fall away from it, and pulsation will, therefore, cease, whereas, if this position has no effect on the pulsation, then it is probably an aneurism.

CHAPTER XX.

THE INGUINAL REGION.

ANATOMY. INGUINAL CANAL.

HERNIA.

Varieties of. Operations for.

The inguinal region is covered by the integument and the superficial fascia, the latter being divisible into two layers. These layers are the subcutaneous, blending with the superficial fascia of the rest of the body, and the deeper layer—Scarpa's—separated from the subcutaneous by the superficial epigastric vessels and by the lymphatics. This deeper layer of the superficial fascia passes over Poupart's ligament, and blends with the fascia lata of the thigh immediately below it, while internally, it becomes part of the dartos of the scrotum as already described. After removal of these superficial structures the aponeurosis of the external oblique is exposed, and that portion of it from the anterior superior iliac spine to the pubic spine is thickened, constituting Poupart's ligament. The outer half of this ligament is obliquely directed, while the inner half is almost horizontal and is twisted on itself, so as to form a triangular band inserted into the pectineal line for about one-half inch, and termed "Gimbernat's ligament." The base of the latter ligament is directed outwards, the apex inwards towards the spine of the pubes, and, in the upright position of the body, its surfaces are superior and inferior. Immediately above and external to the crest of the pubes, the aponeurosis of the external oblique splits so as to form a triangular-shaped area about one inch in length and one-half inch in width at the base. Through this cleft the spermatic cord finds exit, although it is not clearly visible because of the prolongation over it of a thin

tissue that, before the descent of the testicle, covered in this defect in the fascia. This thin fascia is strengthened by accessory fibres, which, slightly curved, bridge the space, passing transversely from one pillar of the ring to the other. Connecting the columns as these fibres do, they receive the name of *intercolumnar fibres* and the thin fascia, plus these intercolumnar fibres, constitute the *intercolumnar fascia*, or, external spermatic fascia. The triangular cleft between the columns is called the *external abdominal ring*, but it is not an opening since the intercolumnar fascia covers it in, nor is it a ring since it is triangular in shape. On the division of these lower fibres of the aponeurosis of the external oblique and the reflection of the flaps to either side, the *spermatic cord* is seen, covered by some looped muscular fibres, widely separated from one another, but banded together by a delicate areolar tissue. These constitute the *cremasteric fascia* and are prolonged downwards from the lower border of the internal oblique, hence their origin and insertion correspond to those of the lower fibres of this muscle, *i.e.*, they arise from the middle of Poupart's ligament, forming loops directed downwards on the sides and anterior surface of the cord, and then incline upwards to be inserted into the crest of the pubes and the front of the sheath of the rectus muscle. The lower portion of the internal oblique lies in front of the cord externally, arches over and gets behind it, internally, *i.e.*, near the pubes, where it, with the lower fibres of the transversalis, constitute the *conjoined tendon* which is inserted into the pectineal line and crest of the pubes. At the attachment of this tendon to the pectineal line, a triangular-shaped layer of fibres pass upwards towards the linea alba, in front of the conjoined tendon. This is the *triangular ligament*. Thus, we have behind the external abdominal ring, the conjoin-

ed tendon and the triangular ligament serving to strengthen what would otherwise be a weak spot in the parietes. Blake, of New York, makes the statement, that, as the result of a number of examinations of the inguinal region of the cadaver, the conjoined tendon is more or less a myth. He found that, in no case, did it extend for more than five-eighths of an inch, laterally, from the insertion of the rectus muscle; that, in the majority, it was less than half an inch and, in some, it was inappreciable. Further, the portion of the internal oblique forming the tendon did not consist of the lowest fibres, since these were inserted into the front of the rectus, but, that the conjoined tendon was formed of a few, only, of the deeper fibres. He states, further, that the structures, generally regarded as the conjoined tendon, are, in reality, a thickened portion of the fascia transversalis. On drawing down the cord and displacing upwards the overhanging internal oblique, the *transversalis fascia* is exposed with the *internal abdominal ring* at the outer part of the surface. This transversalis fascia is arranged around the ring, so that, the portion on its outer side is curved from without, inwards and downwards, below the opening, while the portion internal to it, is curved downwards and outwards to meet the former. This external portion is termed the *ligamentum inguinale laterale*, while the internal is the *ligamentum inguinale mediale*, and the union of these two parts of the transversalis fascia supports the ring and assists in maintaining its position of half an inch above the middle of Poupart's ligament. Internal to these curved parts of the fascia, we find vertical fibres, and this whole exposed portion of the transversalis fascia is much denser than any other part of the same layer.

Through the transversalis fascia the *deep epigastric artery* may be felt when injected, as it lies beneath the

fascia, immediately to the inner side of the internal ring and runs upwards and inwards from the middle of Poupert's ligament, towards the umbilicus. The internal oblique has to be drawn upwards and outwards to expose the ring, and, Turck, of Chicago, showed, from the examination of fifty cadavers, that the internal oblique arose, on an average, from the outer four-fifths of the ligament, in the female, and from the outer two-thirds, in the male, and that the internal ring derives its greatest strength from this muscle. Where the cord emerges from the ring, it has prolonged over it, a portion of the transversalis fascia, forming the *infundibuliform process*. The abdominal rings are connected by means of the *inguinal canal*, but, just as these rings, in the normal condition, are neither rings nor openings, neither is the inguinal canal, a canal or tunnel. The cord forms a part of the abdominal parietes, though it did not occupy this position until the latter months of foetal life, yet, it would be just as appropriate to say, that the last rib rests in a canal in the abdominal wall, as to say that the spermatic cord does. It is potentially a canal, capable of being converted into one, in the pathological condition of rupture, but, since there are no better terms in use, we still call them rings and canal. The *inguinal canal*, then, is about one and a half inches in length and extends from the internal ring to the external. It has above it, the arching of the fibres of the internal oblique and transversalis; below, is the junction of the transversalis fascia with Poupert's ligament; in front, are the aponeurosis of the external oblique, a portion of the internal oblique, along with the superficial fascia and the integument; behind, are the fascia transversalis, the conjoined tendon, the triangular ligament, the subserous areolar tissue, and the peritoneum. Contained in the canal is the spermatic cord, and the

mode of production of its passage through the abdominal parietes is dependent on the fact that the testicle, in the early months of foetal life, lay in the lumbar region. From this point it became shifted to the internal ring, opposite which it is found at the sixth month, and, which it enters at the seventh month; then, down the canal to the scrotum, which it enters about the end of the eighth month. Previous to this, *i.e.*, before the testicle has reached the internal ring, a process of peritoneum—the *processus vaginalis*—had descended into the scrotum, pushing before it a part of the internal oblique (cremaster muscle) and a portion of the external obliqu (intercolumnar fascia). Attached to the back of the testicle, as it rested in the lumbar region in the early months of foetal life, was a rounded cord, the *gubernaculum testis*. This arose, below, from the bottom of the scrotum, from the pubes and from the tissues in the neighborhood of the middle of Poupart's ligament. As the body grew, the testicle was pulled down towards these parts by the gubernaculum, since the latter does not keep pace in growth with the other structures, and hence, the testicle was directed first towards the middle of Poupart's ligament, then towards the pubes, and, lastly, into the scrotum. The testicle was originally surrounded by the peritoneum on all sides, except where it was attached to the posterior abdominal wall, and, to this adherent portion, the gubernaculum testis and the vas deferens are attached. Since the projection of the peritoneum, referred to above, forced the structures, above mentioned, in front of it, and, since the testicle has been drawn down behind this projection it follows that the testicle, when it arrives at the scrotum, will have in front of it the same structures, *viz.*: (1) The integument; (2) the superficial tissue; (3) the intercolumnar fascia; (4) the cremaster fascia; (5) the fascia propria,, representing the combined injundibuli-

form fascia and the subserous areolar tissue, and, lastly, (6) the peritoneum. If we examine the internal or *abdominal aspect* of the *inguinal region*, we see, two, and sometimes three, ridges converging towards the umbilicus. These are caused by the urachus, the deep epigastric artery and the remains of the obliterated hypogastric vessel. The former lies in the middle line, whereas, the latter two, frequently run together producing one elevation only. If, however, each pursues an independent course, there result, in addition to the ridge formed by the urachus, two projections. These ridges are caused by the above structures raising up or elevating the peritoneum over them, since they lie between the peritoneum and the transversalis fascia.

These elevations necessitate corresponding depressions, and, of the latter, there may be two or three. If two exist, one is external to the deep epigastric and the other is internal to it. If three ridges be present, there are three corresponding depressions, or, fossæ, viz., one external to the epigastric, one between it and the remains of the hypogastric, and a third between the latter and the urachus.

Hernia.—The inguinal region is quite frequently the seat of a hernial protrusion, and, when it is, the swelling may be due to bowel—*enterocele*, or to omentum—*epiplocele*, or to bowel and omentum, together—*entero-epiplocele*. Some of the reasons that have been assigned for the frequent presence of hernia in this region are: (1) In the erect position of the body it is against, or on, these parts that the intestines rest; (2) when pressure is applied to the abdominal contents by contraction of the parietal muscles and diaphragm, the latter acts as a piston, and forces downwards the viscera; (3) the inequalities or fossæ referred to above, tend to localize the effects of this increased intra-abdominal tension, since the pressure will be exerted on all sides of the interior of the individual depression,

thus tending to force apart, wedge-like, the fossa; (4) the vas deferens and the spermatic vessels, converging to meet in one of these fossæ, viz., the external, guide, to some extent, the intestines towards the internal ring. For these reasons, then, hernia affects the inguinal region, and especially that particular portion of it, viz., the internal abdominal ring, more frequently than it does any other situation, and would be quite common were it not for the protection and support afforded this region by the internal oblique muscle.

Varieties of Hernia.—When pressure is applied to the abdominal contents and when the bowel impinges on the external fossa, *i.e.*, to the outer side of the deep epigastric artery, and, when, for some reason, or, other, the supporting wall is weakened, or, is not strong enough to withstand the pressure, a knuckle of intestine distends the peritoneal coat, and, stretching the infundibuliform fascia, enters the canal. It cannot pass forward on account of the aponeurosis of the external oblique, and, since there is established already a line of less resistance by the presence of the spermatic cord, it follows, that the most natural passage for the protrusion will be down, along the cord, to the scrotum, resulting in the condition termed, *acquired inguinal hernia*. The neck of the sac in this form will be on the outer side of the deep epigastric artery, and is, therefore, termed, *external inguinal hernia*, although the name usually given to it is *oblique inguinal hernia*. According to statistics, this variety forms about ninety-three per cent. of inguinal herniæ. Should, however, the protrusion occur internal to the deep epigastric artery, it is termed *internal* or *direct inguinal hernia* and the bowel may enter the inguinal canal some distance to the outer side of the external ring, or, may appear, primarily, opposite that ring. In direct inguinal hernia, the protrusion,

not infrequently, pushes the conjoined tendon in front of it, or, separates the fibres forming this tendon, or, may, on the other hand, appear external to this tendon and occupy the canal for a variable distance, but, in any case, the neck of the sac is internal to the epigastric vessels. Direct inguinal hernia forms about seven per cent. of all inguinal herniæ. In discussing the descent of the testicle, reference was made to a process of peritoneum that preceded it. This usually becomes obliterated—beginning above at the internal ring, and below, at the testicle. Should, however, it remain patent, then a portion of the bowel could easily drop or slip into it, resulting in what is known as, *congenital hernia*. Again, if the process becomes obliterated, at the lower part, only, and the rest remains patulous, the bowel could go as far downwards as the top of the testicle only, in place of lying below it, or, on a level with it, as in the congenital form, and, when this condition is present, it is termed *hernia into the funicular process*. Lastly, should the upper part only, become obliterated, then the bowel may be forced downwards, behind this closed sac—*infantile hernia*—or it may insinuate itself at the point of junction, *i.e.*, at the summit of this obliterated process—*encysted hernia*.

Taxis.—The *taxis* may be employed in the attempt to reduce a hernia that does not go back readily. To effect reduction by taxis, the surgeon steadies the neck of the sac with one hand, while, with the other he endeavors to make the bowel traverse the course it took in passing down, hence, he should guide it, upwards, outwards and backwards. Taxis should be very gently employed and should not be persevered in, but should be regarded as rather preliminary to operative interference.

Operative Treatment.—The *seat of stricture* in a strangulated oblique inguinal hernia may be either at

the external ring, at the free edge of the internal oblique muscle, or, at the internal ring, and, in the operation for the relief of this condition, the position and relations of the deep epigastric artery should be borne in mind. If the stricture be at the internal ring then the incision for its relief should be directed upwards, or, upwards and outwards so as to avoid this vessel, but if the stricture be at the external ring, then the direction of the incision should be as in the case of direct inguinal hernia. In a direct inguinal hernia the seat of stricture may be at either the conjoined tendon through which the bowel has been forced, or, at the external ring itself; in either case the incision to relieve it should be upwards, since all that is necessary, as a rule, to relieve the strangulation, is to simply "nick" the obstruction, and, hence, the epigastric would be in no danger of being wounded since it lies some distance above this point.

Radical Cure of Hernia.—The object of the radical cure is to obliterate the sac and prevent a recurrence of the rupture. The latter result is arrived at by uniting the lower margins of the internal oblique and conjoined tendon to Poupart's ligament, and, of the different methods employed, Bassini's, in which the cord is raised and transplanted, gives the best results. Coley reported five hundred and forty-five cases of inguinal hernia on which he had operated, following Bassini's method, and, out of this number, there were only six relapses. Should the surgeon be unable to suture the lower edge of the internal oblique and conjoined tendon to Poupart's, then Bloodgood's method of opening the outer aspect of the sheath of the rectus on its posterior surface and suturing the muscle thus exposed to Poupart's ligament in lieu of the internal oblique may be followed.

Bassini's Operation.—The external incision begins nearly on a level with the anterior superior spine, and con-

tinues downwards, obliquely, parallel to and about half an inch from Poupart's ligament, to end at the centre of the external ring. The aponeurosis of the external oblique is divided after inserting a director under the upper angle of the external ring, and the cut edges of the aponeurosis dissected free, exposing the sac and cord, which are isolated *en masse*. The sac is now separated from the cord and, after being opened to see that there is no bowel or omentum adherent to its interior, is ligated and removed. The transversalis and the internal oblique are sutured to Poupart's ligament, beneath the cord, the cut aponeurosis is united over the cord and the wound closed.

The statistics of Macready show that 85% of hernia in the female are inguinal, and the method of treatment in this sex differs very little from that of the male. In the female, the round ligament replaces the spermatic cord and the projection of the peritoneum around it is termed the "canal of Nück."

The management of this round ligament in the radical cure for hernia in the female, is very simple, since it is left undisturbed, so that, the internal oblique and the conjoined tendon are sutured to Poupart's over the round ligament, whereas, in the male, the union of these structures takes place beneath the cord. Coley has reported a series of one hundred and thirty-four cases of inguinal hernia in the female operated on by him without a single relapse.

Hernia, affecting the abdominal parietes, may occur elsewhere than at the inguinal region. It may be due to weakness, or rupture of a muscle, or to a wound in any part of the abdominal wall other than the umbilicus, under which circumstances it is termed *ventral hernia*, but should the protrusion occur at the umbilicus it is styled *umbilical hernia*. Umbilical hernia of children may be congenital, or may be what is termed infantile. The for-

mer, *i.e.*, *congenital*, is very infrequent (one in five thousand cases), and is due to a want of closure at the umbilicus, whereby the foetal intestinal canal is not separated from the original umbilical vesicle. This congenital form causes a fusiform appearance of the cord near the umbilicus and, if care be not taken, the intestinal protrusion may be included in the ligation of the cord. The *infantile form* of umbilical hernia, on the other hand, is due to a yielding of the umbilical cicatrix, and generally occurs some weeks after birth, but it disappears, as a rule, before puberty. *Umbilical hernia of adults* is usually met with between the ages of thirty and fifty, and, generally, in females, especially those who are stout and have borne many children. The *coverings* in this form are: (1) Integument; (2) superficial and deep fascia; (3) the stretched umbilical cicatrix (occasionally this is pushed aside); (4) the transversalis fascia; (5) subserous tissue, and (6) the peritoneum. The hernia generally makes its appearance at the upper part of the umbilical ring, since the lower part is strengthened by the remains of the umbilical arteries and the urachus—the less dense vein going to the upper part of the ring. *Taxis* may be employed, but the protrusion is generally irreducible from union occurring between it and the peritoneal wall, or, from the deposition of fat, and, as it is always a source of danger, unreduced, the radical operation may be attempted. In this *operation*, after excision of the elliptical portion of the tissues over the hernia, the peritoneum is sutured, then the deeper tissues in front of the peritoneum, and, lastly, the skin. Another method that is sometimes employed is Gersuny's. In this, the peritoneum first, is sutured, then the edges of the recti muscles, and then, after the suturing of these structures, the superficial portion of the wound is packed with gauze so as to cause it to heal by granulation.

CHAPTER XXI.

THE LIVER AND GALL BLADDER.

LIVER.

Anatomy.

Relations.

Landmarks.

GALL BLADDER.

Anatomy.

Relations.

Landmarks.

DISEASES OF LIVER AND GALL BLADDER.

CLINICAL EXAMINATION OF LIVER AND GALL BLADDER.

OPERATIONS ON LIVER AND GALL BLADDER.

The liver is situated in the right hypochondriac, in the epigastric and in the inner portion of the left hypochondriac regions, and measures about twelve inches in its transverse diameter and about six inches in its antero-posterior diameter. It is somewhat wedge-shaped, from side to side, as well as from before backwards, the thick part of the wedge in the former instance being opposite the right ribs, and the thin end at the left extremity, while in the latter, *i.e.*, from before backwards, the posterior surface is the deeper, and the anterior border the thin end or point of the wedge. The liver is divided into two lobes on its upper surface by the suspensory or broad ligament, and on its lower surface by the umbilical fissure. The *posterior* surface is triangular in shape, with the base to the right and the apex to the left, and the portion of the left lobe that forms this surface is covered with peritonium, while the back of the right lobe is devoid of it; and, as the posterior surface of the right lobe passes obliquely across the body, the lobulus Spigelii, which forms a part of this surface, is opposite the tenth and eleventh vertebræ. There are five fissures connected with the liver, *viz.*: The umbilical, the fissure for the vena cava and the one for the gall bladder, that for the ductus venosus, and

the *transverse fissure*, and, of these, the latter is the largest, and is situated on the under surface nearer the posterior than the anterior border. It is about two inches long and transmits the portal vein, the hepatic ducts, the hepatic artery, the hepatic plexus of nerves and the lymphatics, all of which are surrounded by areolar tissue—Glisson's capsule.

Structures passing to and from the transverse fissure of the liver.—The *portal vein* collects the blood from the viscera of digestion by means of the gastric, the splenic and the two mesenteric veins, which unite near the upper end of the head of the pancreas to form the portal. It passes up to the transverse fissure, is about three or four inches in length, and divides near that fissure into two large branches, one for each lobe. The *hepatic duct* is about one and a half inches long and is formed by a branch from each lobe of the liver. It passes downwards and to the left and unites with the cystic duct to form the common bile duct.

The *hepatic artery* from the cœliac axis passes forwards and to the right, and then curves upwards to the liver forming the lower boundary of the foramen of Winslow. It gives a branch to the gall bladder, and, on reaching the transverse fissure divides into two branches, one for each lobe. The *hepatic plexus* of nerves is formed from the solar plexus, and, near the pyloric end of the stomach this plexus is joined by branches from the left pneumogastric nerve, while, on the upper and posterior surfaces of the liver, it is connected to extensions from both the phrenic plexus of the sympathetic and the phrenic nerve. The *lymphatics* are superficial and deep. Some of the former pass through the diaphragm into the anterior mediastinum, some to the receptaculum chyli, and some to the œsophagus, while others go to the hepatic glands in

the gastro-hepatic omentum. The deep lymphatics empty into the hepatic glands as a rule, though a few go to the receptaculum chyli, while those belonging to the gall bladder pass to the glands in the gastro-hepatic omentum.

Relations of the liver.—The *superior surface* directed upwards, forwards and slightly to the right is moulded beneath the diaphragm, and is behind the upper portion of the abdominal wall. It is covered by peritoneum and is attached to the above structures, *i.e.*, to the abdominal wall and diaphragm, by means of the suspensory or falciform ligament. The *posterior surface* crosses the posterior aspect of the abdomen in the neighborhood of the tenth and eleventh vertebræ, the lobus Spigelii (a portion of this surface) lying opposite these vertebræ and in front of the crura of the diaphragm. The portion of this surface formed by the left lobe is entirely surrounded by peritoneum and is in contact by its inner end with the œsophagus, while that part of the posterior surface formed by the right lobe is thick, and, in addition to the vena cava, which is imbedded in it, has the diaphragm and the suprarenal capsule behind it. There is no peritoneum covering the posterior surface of this lobe, excepting at its right extremity, and the layers reflected from the upper and lower borders to the diaphragm constitute the coronary ligaments. The *inferior surface* is directed downwards, backwards and to the left, and is in relation with the colon, the duodenum and the right kidney, as well as with the lesser curvature, the anterior surface of the body and the pyloric end of the stomach. It is covered by peritoneum, except at the transverse fissure and at the site of the gall bladder. The slanting direction of this under surface allows it to glide, freely, over the subjacent structures without tending to dislodge them from their respective positions. There are present slight depressions on

this surface, caused by apposition of the underlying viscera, and these depressions on the under surface of the right lobe, are: The colic in front, the renal behind, and the duodenal to the inner side and between. On the under surface of the left lobe there is one depression, viz., that for the stomach. The lobus quadratus is in contact with the pylorus. The right end of the upper surface is rather precipitous in form, and is sometimes called the *right surface*. It rests against the diaphragm, which separates it from the ribs of the right side of the thorax, and corresponds to the level of the seventh rib above, and the eleventh rib below.

Landmarks. (Fig. 8).—The *upper border* of the *right side*, when viewed from in front, corresponds to a line drawn outwards from the junction of the right fifth costal cartilage with the sternum, and having a slight convexity upwards, not sufficient, however, to include the nipple. Continuing the line from this point, *i.e.*, from immediately beneath the nipple, it passes downwards, with a gradual curve to the seventh rib in the midaxillary line, and then, parallel with the midaxillary line down to the ninth rib, and from here it curves slightly inwards to the eleventh rib. The *upper border* on the *left side* may be represented by a line drawn outwards from the junction of the sixth left costal cartilage to a point about two inches to the left of the sternum. The remaining portion of this border, *i.e.*, the *part behind the sternum*, corresponds to a line, with a slight concavity upwards, joining the fifth cartilage on the right with the sixth on the left. For the *inferior border*, draw a line from the eleventh rib on the right side along the free margin of the right cartilages, or half an inch below them, as far forwards as the ninth rib on the same side. From this point it passes across the linea alba to the tip of the eighth left cartilage, and, continuing its

course from the tip of this cartilage, it passes with a slight curve to join the extreme limit of the left upper line. This inferior line crosses the subcostal angle nearly midway between the umbilicus and the junction of the ensiform cartilage with the sternum. Since the lung ends about the level of a line drawn along the lower border of the sixth rib in the mammary line, outwards, and, since the pleura ends about the level of one drawn along the seventh rib, outwards, it follows that the portion of the liver exposed below either the lung, or the pleura, will correspond to the part of the thorax below these individual limits. Thus, in front, below the lung, the exposed portion of the liver corresponds to the seventh, eighth and ninth cartilages, and at the sides, to the ninth, tenth and eleventh ribs, while that exposed below the pleura corresponds, in front, to the eighth and ninth cartilages, and at the sides to the tenth and eleventh ribs. The longitudinal fissure, the suspensory ligament and the ligamentum teres or round ligament are situated in a line, partly a little to the right, and partly immediately behind the linea alba. On viewing the contour of the liver from *behind*, the *left extremity* is seen to be about two and a half inches from the mid-spinal line, and touching the ninth rib; the *upper border* corresponds to a line drawn from this point, crossing the ninth dorsal spine and ending at the eighth rib on the right extremity of the thorax as seen from behind; the *right border* corresponds to a line drawn from this point downwards as far as the eleventh rib. The *inferior border* agrees with a line drawn from the left extremity of the line for the upper border obliquely across the vertebræ and gradually diverging from the upper line so as to make the posterior surface two inches in depth at the vertebral column, which it crosses at the eleventh spine, and two and a half inches in depth at a point a little to the

right of the vertebral column, from which point it gradually approaches the line for the right border so as to join it about the end of the eleventh rib.

Displacement.—The situation of the liver is not the same in every normal subject, for, while the above may be taken as the usual position in the majority of cases, there are many variations even in health, both as to size and position. Respiration is constantly changing the relative situation of the liver, since, in inspiration, it is forced downwards and forwards by the diaphragm, while in expiration it is raised up, partly by the arching of the diaphragm, and partly by the compression of the abdominal muscles.

When the patient is in the erect posture, the liver projects beyond the chondral margin, but, when in the recumbent position, it disappears behind that margin. The liver is held in its normal position by the suspensory and the coronary ligaments; by the areolar tissue connecting the posterior surface of the right lobe to the diaphragm; by the attachment of the vena cava to the margin of the phrenic opening; by the viscera on which it rests; by the pressure of the abdominal muscles, and by the dome-like arching of the diaphragm. It may be drawn upwards by any disease that causes increased arching of the diaphragm, such, for instance, as fibroid phthisis, or a contracted right lung, the result of a long-continued hydrothorax. It may be displaced downwards by a subphrenic abscess or by flattening of the diaphragm, as in emphysema, or in pleurisy with effusion, or it may be displaced downwards in hepatoptosis as in Glenard's disease, where, owing to relaxed ligaments and a weakened support from pendulous abdominal walls, visceroptosis occurs; or its lower border may be increased downwards by such diseases as passive congestion, amyloid or waxy degenera-

tion, hypertrophic cirrhosis, malignant disease, etc., whereas, its upper border may be elevated by hepatic abscess, by hydatids occupying the superior surface or by malignant disease.

The Gall Bladder.—The gall bladder is conical or pear-shaped, and is directed from before, backwards and slightly to the left. It has a base or fundus projecting on the free border of the liver; a body, underlying the liver in a depression—the fossa cystis felleæ; and a neck which resembles the letter S in shape, and is directed inwards and to the left, to enter the cystic duct. The mucous membrane of the body of the gall bladder is thrown into polygonal folds, while in the neck it is arranged in a spiral manner.

Relations of the gall bladder.—The fundus is in contact with the abdominal parietes, especially the upper end of the right linea semilunaris, and is entirely surrounded, as a rule, with peritoneum. Above the body of the gall bladder is the liver, below are the first portion of the duodenum, the hepatic flexure of the colon, and frequently, depending on the amount of distention of the stomach, the pylorus. This portion of the gall bladder has the peritoneum on its sides and inferior surface only, and not, as a rule, above, where it is in contact with the liver. The neck ends in the cystic duct which is directed backwards and to the left as it lies in the gastro-hepatic omentum. The *cystic duct*, according to Brewer, of New York, who reported the results of the examination of the biliary passages in one hundred bodies, varied from a half to two and a half inches in length, the average being two and one-fifth inches. It unites with the *hepatic duct*, which is about one and a half inches in length, to form the *common bile duct*. This latter duct, about three inches long, passes downwards and to the left in the gastro-

hepatic omentum. It is about the size of a goose-quill, is situated about half an inch from the right or free margin of the omentum and lies to the right of the hepatic artery and in front of the portal vein. This duct passes behind the descending part of the duodenum and between it and the head of the pancreas to about a little below the middle of the inner side of this portion of the intestine, where it meets with the pancreatic duct, and, becoming dilated—ampulla of Vater—opens into this descending part of the duodenum. There would be no trouble in finding the situation of this part of the duct, if it were occupied by a calculus, but to do so, in the cadaver, is very difficult. Brewer suggests that, if, after an incision is made in the first part of the duodenum, the finger of the left hand be introduced into the wound, it feels a sharp crescentic fold corresponding to the junction of the first and second parts. If this fold be opposite to the middle of the second phalanx, then the tip of the finger touches the opening of the duct.

Landmarks for the gall bladder.—It lies opposite the right linea semilunaris, *i.e.*, along the outer border of the right rectus muscle, or about opposite to the cartilage of the ninth rib near its junction with the bony portion of the rib.

Diseases.—*Pain* associated with disease of the liver may be due to stretching of the peritoneal capsule, or to the direct involvement of this coat. It may be felt at the point of the shoulder, or over the clavicle, or down the arm on either side, and may be explained (Luschka) by the branches of the phrenic nerve that pass from the diaphragm, between the folds of the suspensory ligament, to the liver, and, since the phrenic is derived from the third, fourth and fifth cervical, and, since from the third and fourth cervical, the superficial cervical plexus arises

branches of which go to the clavicular and acromial regions, it is altogether likely that the course of the reflex path is through these nerves, *i.e.*, from the phrenic nerve to the third and fourth cervical, thence to the cutaneous branches over the shoulder; when pain is felt down the arm, it is transferred probably through the fifth nerve to the brachial plexus. Pain in disease of the gall bladder may be due to the same nervous relationship, while the sense of weight or discomfort felt behind the scapula, in disease of either liver or gall bladder, may be due to the sympathetic system which forms the hepatic and cystic plexuses and which communicates by means of the splanchnics with the lower six intercostals whose posterior cutaneous branches supply this region. In diseases of the liver in which the circulation through it is disturbed as, for instance, in cirrhosis, pylephlebitis, etc., symptoms referable to interference with the blood current, such as ascites, gastro-intestinal catarrh, piles, etc., do not present themselves until the *collateral circulation* fails to provide for the increasing pressure on the portal vein, and since this collateral circulation takes such a prominent part in prolonging the life of the patient it is certainly worthy of examination. The principal veins that carry on the circulation under these circumstances are: The remains of the umbilical vein communicating with the paraumbilical and the latter with the epigastric (superficial and deep), and with the superior epigastric of the internal mammary; the rootlets of the branches of the portal, especially the veins of the large intestine, communicating with the inferior vena cava through the lumbar and phrenic veins; the superior hæmorrhoidal with the middle and inferior hæmorrhoidals of the internal iliac and the pudic; the gastric vein with the œsophageal branches of the vena azygos minor; lastly, veins of the cortex of the liver, especially of

that portion of the liver at the suspensory ligament, with veins belonging to the diaphragm, viz., the phrenic, the musculo-phrenic, etc. Bile may still be formed to a slight extent even in thrombosis of the portal vein. This depends on the fact that the hepatic artery communicates with the intralobular plexus of veins. Attempts have been made to increase the number of channels for the collateral circulation by suturing the great omentum to the peritoneal covering of the anterior abdominal wall, the portal system thus communicating with the caval system through the epigastriacs, etc. *Wounds* of the liver may be produced by the passage of heavy objects, such as a wheel of a loaded cart, etc., over the hepatic region, or, wounds may result from sudden severe blows on this region, or from penetration by a broken rib, etc., and, when so inflicted, one of the causes of death may be hemorrhage. The treatment, in hemorrhage, is to expose the liver, and, with a deep-seated or a purse-string suture, to close the wound in the liver tissues. When the liver is wounded by a knife thrust through, say the fifth intercostal space in the mammary region, or, the sixth space in the axillary region, the structures divided in addition to the muscles and fasciæ of these regions would be the parietal layer of the pleura, the visceral layer covering the lung, the lung itself, the pleura covering the base of the lung, the diaphragmatic pleura, the diaphragm, the peritoneum covering the under surface of the diaphragm, and lastly, the liver. A wound situated a little lower down would divide the same structures, with the exception of the lung and the pleural layers covering it.

An Abscess in the liver may perforate the diaphragm and break into the pleura, the lung or the pericardium, or, it may burrow into the stomach, the colon, or the duodenum, or, possibly, involve the peritoneal cavity, or the connective tissue of the posterior portion of the abdomen.

Clinical Examination.—*Percussion* of the hepatic region. When the thorax is percussed from above downwards, the normal resonance begins to change as the fifth rib, in front, is reached, or, as the lower border of the sixth in the midaxillary line, or the eighth in the scapular line is reached, and from these points, the dullness, termed “relative hepatic dullness,” increases in degree until, below the level of the sixth in front, the eighth at the side, and the tenth behind, it becomes complete, and is termed “absolute hepatic dullness.” The limit of dullness may be increased upwards, as already mentioned, in hydatids, etc., and downwards in enlargement due to hypertrophic cirrhosis, etc. The area of dullness may be diminished in acute yellow atrophy, or in atrophic cirrhosis, or, it may be lost in gaseous distention of the abdomen, due to perforation of a hollow viscus, in which case the gas insinuates itself between the diaphragm and the liver, and thus prevents the normal hepatic dullness from being elicited.

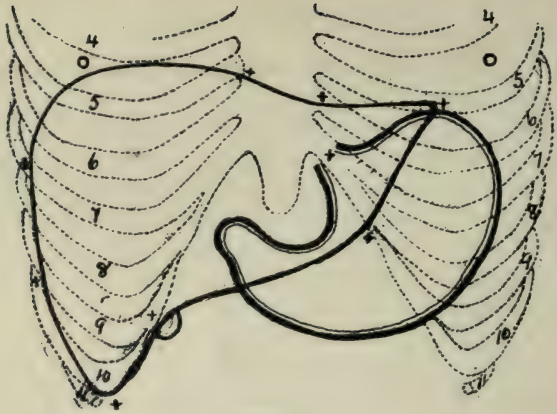
In distention of the gall bladder there may be found, on percussion, a dull area which corresponds to the dilated sac, and which merges above into the area of hepatic dullness. On *palpation*, the pear-shaped tumor formed by the dilated gall bladder, and extending somewhat inwards towards the middle line, may be felt in the manner described by Osler, viz.: “Sitting by the side of the patient, with the left hand beneath the lower ribs, and with the right on the abdomen, a little below the costal margin in the nipple line, gentle palpation with the pads of the fingers is first made during quiet breathing. The patient is then asked to draw a deep breath and gentle but firm palpation repeated, the fingers of the right hand following the receding abdominal walls. The anterior edge of a normal liver can in this way be readily felt and any mark-

ed projection of the gall bladder detected." Glenard advises palpation of the liver in the following manner: "With the left hand grasp the right flank, fingers behind, and then, with the thumb which is free, the edge and surface of the anterior part of the right lobe can be felt as the liver descends in inspiration."

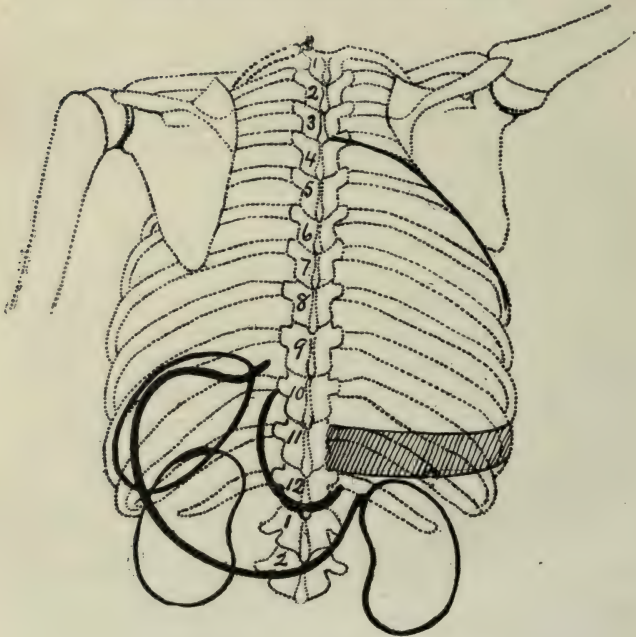
Operations on the Liver.—In a section of the liver, the hepatic veins can be distinguished from the portal branches by the fact that the former are open or patulous, whereas, the latter are more or less collapsed. The explanation of this is, that there is a close union between the walls of the hepatic veins and the channels in which they lie, so that, when divided they are held open, but in the case of the branches of the portal vein, there is no such union, since these vessels are enclosed in Glisson's capsule, and hence, when divided, they collapse. Until recently there was a great dread of hemorrhage occurring, especially from the open hepatics, during operations for the removal of a portion of the liver tissue. Keen reported in 1899 seventy-six cases of resection of the liver for neoplasms, and in his own case he used a thermocautery, but by means of the suture devised by Terrier and Auvray and improved by Thompson, of Galveston, the hemorrhage may be so controlled as to bring within the domain of surgery the safe removal of a portion of the liver. This suture, of the thickest silk, finds sufficient connective tissue in both the walls of the hepatic veins and in Glisson's capsule to securely retain it, if applied tightly enough. *Aspiration* of an hepatic abscess may be done through the right axillary region and between the ninth, tenth and eleventh ribs, since these spaces would be below the level of the lower reflection of the pleura in this situation.

Operations on the Gall Bladder.—Gall stones are very common and may never produce any symptoms, or, on the other hand, they may cause trouble by their pre-

sence in, or their passage through the neck of the gall bladder into the cystic duct. Should a stone block the neck of the bladder or the cystic duct, the gall bladder may become distended without the production of jaundice, since it is merely a reservoir, whereas, when the stone lodges in the common bile duct, in addition to pain and fever, there are symptoms of jaundice. Should the stone pass, or should it become floated up by the bile collected in the duct, or in the ampulla of Vater, the jaundice will subside to recur in another attack. In the *operation for gall stones* an incision may be made from a point below and external to the ensiform cartilage, parallel to the chondral margin, or, from a point opposite the eighth cartilage, vertically downwards to the level of the eleventh cartilage, or, as Abbe advises, one along the outer border of the rectus muscle, enlarging it, if necessary, by a cross cut through the fibres of this muscle. When the gall bladder is exposed the following operations may be performed, but, inasmuch as the steps of these operations, belong to the domain of Surgery proper, we will draw attention, very briefly, to the operations: *Cholecystotomy* means opening the gall bladder, and, after removal of the stones, suturing the wound in its walls and then replacing it in the abdomen—ideal cholecystotomy; or, leaving the wound in the bladder open and suturing the edges of the wound to the abdominal walls—the usual operation. *Cholecystectomy* consists in the removal of the gall bladder, after ligating the cystic duct and separating the peritoneum from the surfaces of the gall bladder. *Choledocotomy* means an incision into the common bile duct to remove stone or tumor. *Cholelithotrixy* is crushing the stone in the cystic or common bile duct. *Cholecystenterostomy*.—In this an anastomosis is made between the gall bladder and the large or small intestine, by means, as a rule, of the Murphy button.



(Fig. 8.)
Landmarks.—Anterior aspect—Stomach and Liver.



(Fig. 9.)
Landmarks.—Posterior aspect—Stomach, Spleen, Kidneys and Pleura.

CHAPTER XXII.

STOMACH.

ANATOMY.

ULCER.

REFLEX NEUROSES.

LANDMARKS.

DISEASES.

OPERATIONS.

The stomach is subject to variations with reference to its size and position in accordance with the amount of distention present. In the empty state, this viscus lies in the epigastric and left hypochondriac regions, and is irregularly conical in shape, with a base, or fundus, to the left of the vertebral column and an apex—the pylorus—in front of, or to the right of the vertebral column. The stomach does not lie vertically in the abdomen. It is so situated that the fundus, which is fixed to the diaphragm by the œsophagus and the gastro-phrenic ligament, is on a higher level than, and is posterior to, the pylorus, with the result that this organ is obliquely situated, both from above downwards and forwards, and from without inwards. When distended, the fundus presses up against the diaphragm, while the pylorus is shifted to the right and at the same time rotated to such a degree, that it is directed towards the back. This is possible, since the pyloric end is the most movable part of the stomach, even though it is supported by the attachment of the duodenum to the posterior wall of the abdomen. This rotation of the pyloric end causes the greater curvature to be applied to the abdominal wall, and, in addition, alters the direction of the surfaces of the stomach. These surfaces are termed anterior and posterior, and are connected above by the lesser curvature, and below by the greater curvature; while at the junction of the curvatures, on the left, is situated the œsophageal opening, and, on the right, the pyloric

opening. The *lesser curvature* varies from three to six inches in length, and is directed, starting at the œsophageal opening, in a curved manner to the right and then slightly upwards. In its descent, it lies by the side of the eleventh and twelfth dorsal vertebræ, and then crosses the first lumbar to turn upwards to the level of the twelfth dorsal, where it terminates at the pyloric opening. This curvature has attached to it the gastro-hepatic omentum, which is composed of two layers of peritoneum that descend from the transverse fissure of the liver to the stomach. On reaching the lesser curvature these two layers separate so as to enclose the stomach, one passing in front, over the anterior, and the other, behind, over the posterior surface. At the left extremity of the lesser curvature these layers surround the œsophagus and pass to the diaphragm forming the gastro-phrenic ligament, while to the left of the fundus they surround the spleen forming the gastro-splenic omentum. Between the folds of the gastro-hepatic omentum, near where it is attached to the lesser curvature, are: The gastric and the pyloric arteries, the corresponding veins that empty into the portal, and the lymphatics that pass from the stomach to the cœliac glands and thence into the receptaculum chyli. The greater curvature is about four or five times as long as the lesser, and, starting at the œsophageal opening, it passes upwards and backwards with a decided curve to form the upper limit of the fundus. It then passes downwards as the left border of the fundus, and, after turning to the right, ends at the pylorus. This curvature rests on the transverse colon and has attached to it the great omentum, which, formed by the two layers above mentioned, that cover the stomach, passes downwards in front of the intestines.

Relations of stomach.—The *fundus* lies beneath the diaphragm, about on a level with the left extremity of the liver, and is posterior to, and on a higher level than the apex of the heart, from which it is separated by the pericardium, the diaphragm and the peritoneum covering the diaphragm. The *anterior surface* is directed upwards, forwards and to the left, and is, in the empty state, behind the diaphragm, the left lobe of the liver and the anterior abdominal wall, but, when the organ is distended, this surface becomes more or less superior, while the posterior surface becomes inferior, and the pyloric end is shifted to the right so as to lie beneath the quadrate lobe.

The *posterior surface* looking downwards, backwards and to the right, rests on a concave bed formed by the upper layer of the transverse mesocolon, hence this mesocolon, with the colon below it, supports the organ. This surface is in front of and in contact with the diaphragm, the spleen, the left suprarenal capsule, the upper end of the left kidney, the pancreas and the splenic flexure of the colon. *Measurements*.—The stomach when moderately filled is about ten or twelve inches long and measures about four or five inches at its widest part.

Landmarks for Stomach on the *anterior surface* of the body. (Fig 8.)—The *cardiac orifice* is situated opposite the lower part of the tenth dorsal vertebra and lies behind the seventh costal cartilage of the left side, about one inch from the sternum. It is about four and a half inches from the anterior thoracic wall and about one inch below the œsophageal opening in the diaphragm. The *pylorus* is about two and a half inches below the junction of the sternum with the ensiform cartilage, in a line drawn downwards from the right side of the former, and is opposite to the twelfth dorsal vertebra. The *summit*, or, *high-*

est point of the convexity of the fundus is on a level with the attachment of the sixth costal cartilage on the left side, to the sternum, and is from one and a half to two inches above the level of the cardiac opening and about three inches to the left of the sternum. To map out the *lesser curvature*, join the landmark for the cardiac with that for the pyloric opening, by means of a sharply curved line with its concavity upwards. For the *right portion* of the *greater curvature*, draw a line from the pyloric opening, downwards and outwards, with a convexity sufficient to touch the level of the tips of the tenth costal cartilages, a little to the left of the linea alba. For the *left portion* of the *greater curvature*, continue this line, with the convexity outwards and to the left, as far as the landmark, above mentioned, for the summit of the fundus, and, to complete the outline of the stomach, join, by means of a slightly curved line, the landmark for the summit with that for the œsophageal opening. *Landmarks* for the stomach on the *posterior surface* of the body. (Fig. 9). The *cardiac opening* is opposite the tenth dorsal vertebra and about one and a half inches to the left of the spine, while the *pyloric*, in the empty state, is opposite the twelfth dorsal and about half an inch to the right of the spine. Join these landmarks by a curved line, to represent the *lesser curvature*, whereas, the *greater curvature* will correspond to a line curved to the left, so as to be parallel with, and about an inch from the contour of the ribs on the left side as seen from behind, and then crossing, with convexity downwards, the second lumbar vertebra, to pass upwards and to the right, to end at the pyloric opening.

On examining the outline of the stomach on the anterior surface of the body it will be observed, (1) that about two-thirds of it is covered by the ribs and the car-

tilages of the left side; (2) that a small portion, only, of the stomach is in contact with the abdominal walls, and (3) that the lowest limit of the greater curvature is a little below a point midway between the tip of the ensiform cartilage and the umbilicus, *i.e.*, that it corresponds to the breadth of two fingers above the umbilicus. That portion of the anterior surface of the stomach in contact with the abdominal parietes is somewhat triangular in shape and corresponds to the area exposed below the inferior border of the liver, and is bounded by the following lines: *Above*, by the inferior line of the liver, *i.e.*, a line drawn from the ninth right to the tip of the eighth left cartilage; *below*, by the line joining the tips of the tenth cartilages, and, *laterally*, by the margins of the eighth and ninth left costal cartilages. It is over this triangular-shaped portion, therefore, that the normal stomach may be palpated, and, in it, incisions should be made for the purpose of exposing the organ in operative work on the stomach.

Morbid Conditions affecting the Stomach.—In *diaphragmatic hernia* the stomach is the abdominal organ most frequently involved, since it has been found, that in this form of rupture, the stomach formed the protrusion in 65% of the cases reported.

Ulcer of the Stomach.—Ulcer involves, most frequently, the posterior surface of the stomach, towards the pyloric end and near the lesser curvature. Welch's statistics show, that out of seven hundred and ninety-three cases, the ulcer occupied the lesser curvature in 36%; the posterior wall in 29%; the pylorus in 12%; the anterior wall in 8% and the fundus in 3%.

As the ulcer extends, it becomes funnel-shaped, with its apex towards the peritoneum, and, when the latter is destroyed, perforation occurs, unless the inflammatory action excited in the peritoneum covering the ulcer has re-

sulted in the adhesion of this coat to the contiguous structures. It is very fortunate that such a large percentage of ulcers are situated on the posterior wall, rather than on the anterior, since the posterior surface is normally in contact with the peritoneum covering the diaphragm, pancreas, etc., and septic peritonitis, therefore, the result of perforation, would not be so apt to occur in this case, as it would, were the anterior surface involved, since the latter is some distance from the structures that lie in front of it. Lindner gives the following table to illustrate the relative frequency of the site of gastric ulcer and of the occurrence of perforation: In two hundred cases of gastric ulcer, one hundred and ninety will be on the posterior wall and ten on the anterior; of the one hundred and ninety, four will perforate, and of the ten, eight and a half will perforate. Should perforation, of an ulcer, situated on the posterior wall, occur before adhesive union of the contiguous peritoneal surfaces has taken place, then the cavity of the *lesser omentum* will be the part affected, with the result, that the inflammatory products will likely be confined to this sac, and one form of *subphrenic abscess* develop. This cavity of the lesser omentum is bounded above, by the liver and the diaphragm; below, by the reflection of the peritoneum, which, forming the great omentum, goes to the upper surface of the transverse colon; in front, by the gastro-hepatic omentum, the posterior surface of the stomach and the anterior boundary of the great omentum; behind, by the peritoneum covering the diaphragm, the pancreas, etc., while, laterally, it reaches from the foramen of Winslow to the spleen. This variety of subphrenic abscess produces, according to Lloyd, a tumor in the left hypochondriac, epigastric and umbilical regions, which varies, from time to time, both in size and shape, in accordance with the quantity of fluid in

the overlying stomach. *Hemorrhage* in *ulcer* of the stomach.—The gastric vessels along the greater and the lesser curvatures send off branches more or less parallel to one another, and these branches, after piercing the muscular coats, run in the submucous tissue. From these branches smaller vessels ascend in the mucous membrane of the stomach, and, when an ulcer destroys these capillaries, hemorrhage of a very moderate degree may ensue. When the larger vessels of the submucous coat are involved, the hemorrhage may be very profuse, and even fatal. Quickly fatal hemorrhages frequently result from erosion of the main trunks along the curvatures, or from perforation of the splenic vessels, or even the portal vein.

Pain in ulcer of the stomach may be felt in the epigastric region or it may be radiated to the back. The nervous path in these cases is through the connection of the splanchnic nerves with the solar plexus, on the one hand, and with the lower intercostals on the other.

Cancer of the stomach.—In 80% of cases there is present a tumor (Brinton), which may be readily detected by palpation if it involve the anterior surface below the inferior border of the liver, or the lower part of the greater curvature, or the pylorus, but, if situated on the cardia, or on the lesser curvature, or on the fundus, or the posterior wall, then the tumor may be felt with great difficulty, or not at all.

Dilatation or gastrectasis may cause the greater curvature to descend below the umbilicus even as far down as the pubes. Osler states that the pylorus may be palpated in gastrectasis, or in gastroptosis (downward displacement) as a transversely-placed body alternately relaxing and contracting, and through which gas is, at intervals, felt bubbling.

Hour-glass contraction may be congenital or acquired, the latter being due to cicatricial contraction after ulcera-

tion, or to adhesion from inflammatory processes outside of the stomach. The constriction is often about the middle of the organ. Walsh, of Boston, analyzed the twenty cases reported up to July, 1900, and found that the situation of the stricture was in the middle, in seven cases; at the junction of the upper and middle thirds, in three; at the junction of the lower and middle thirds, in four; not noted, in six. As to the size of the constriction, five allowed the passage of a lead pencil; six, the index finger; two, the thumb; three, two fingers; four, noted as narrow.

Gastric reflex neuroses are exceedingly common, since, by means of the pneumogastric and the sympathetic nerves, the stomach is brought into intimate relation with the various other organs. The pronounced effects of the nervous relationship between the heart and the stomach are quite frequently brought to the physician's notice in the shape of præcordial distress, disturbed cardiac rhythm, palpitation, pseudo-angina pectoris, etc. When the stomach is distended and forced upwards against the diaphragm, there may result symptoms, such as disturbances of the action of the heart, suffocating sensations, etc. These arise from mechanical causes, but the subject we are now dealing with refers solely to nervous reflex actions. The pneumogastric associates the stomach with the lungs, as seen in gastric asthma, while the sympathetic brings this organ into intimate relationship with all the abdominal viscera, although the pneumogastric may share, to some extent, this action of the sympathetic because of the connection of the pneumogastric with the solar plexus, from which arise the various plexuses for the innervation of the different viscera. Dr. Gross states that there is scarcely an internal disorder in which the gastric juice is not largely implicated, since every affection of the stomach is reflected to the other organs, and conversely every

disease of these organs acts on the stomach. Reflex gastric neuroses are the frequent accompaniments of uterine disturbances as seen in the gaseous distention, the vomiting, or the pain in the stomach, that is often present during menstruation; or in the vomiting of pregnancy, or in that resulting from instrumental dilatation of the cervix, etc. Not only do the heart, lungs and abdominal organs reflexly affect the stomach, and *vice versa*, but the head and the extremities are influenced, to some extent, by nervous association with the stomach; cramps in the legs, for instance, in cholera; anæsthesia and neuralgia of the fingers in dyspeptics (probably of angeio-spastic origin), migraine (angeio-spastic), dimness of vision, frontal headache, etc., from disorders of the stomach. Even the skin may be involved, as in urticaria from gastric disturbance.

Operative work on the stomach.—Operations may be performed on the stomach for *perforation*, the result of a *gastric ulcer*, or, for excessive or continuous hemorrhage which threatens a patient's life in hæmatemesis. In the operation for perforation, an incision is made in the median line, and after exposing the stomach, this organ is drawn out of the abdominal wound, if possible, and the ulcer sought for. Should the ulcer not be found in the anterior wall, then the posterior surface will need to be explored, and this may be done by dividing the lesser omentum between two sets of ligatures and turning down the upper border of the stomach. After identifying the ulcer, it should be infolded so as to shut it off from the peritoneal cavity. This is done by means of Lambert's sutures, which include all the coats of the stomach with the exception of the mucous membrane, in such a manner that serous membrane is approximated to serous

membrane, or, in place of infolding the ulcer, it may be first excised and the edges treated by inversion of the walls, but, if the resulting wound in the stomach be too large for this procedure to be safely adopted, then the perforation should be walled off from the general abdominal cavity by gauze packing. If the operation be for *hemorrhage*, the ulcer may be excised, or the bleeding point may be secured after the stomach has been opened. *Sub-phrenic abscess*, occupying the lesser sac of the peritoneum, may be evacuated by opening the great omentum between the stomach and the transverse colon, gauze having first been arranged so as to shut off the general peritoneal cavity around the site of the proposed opening.

Gastrostomy consists in a simple incision into the stomach for the removal of a foreign body, or for exploratory purposes, etc., and in this operation the stomach is exposed through an abdominal incision in the middle line. Hemorrhage from stomach wounds is generally of no great moment, but, to reduce it to a minimum, the incision, if small, should be made transversely to the long axis of the stomach, so as to be parallel to the vessels which run beneath the serous coat. A larger wound should, if possible, be made in a longitudinal direction and about midway between the two curvatures so as to avoid the large vessels situated at these curvatures, but should the foreign body be distinctly felt, the gastric incision is best made directly over it.

Gastrostomy is an opening into the stomach for the purpose of keeping up nutrition where the œsophagus is obstructed to such a degree that the entrance of food into the stomach by the usual channel is prevented. The abdominal incision should be placed in the left linea semilunaris, or it may be made parallel with and about one inch from the left costal margin. In making this incision,

the middle of which should be one inch below the line for the inferior border of the liver, the fibres of the external oblique will be divided at right angles to their course; those of the internal oblique will be parallel to the line of incision, while the transversalis will be cut transversely. After the abdomen has been opened, the opacity and smoothness of the surface, the faint pink color and the thickness and stiffness of its walls, assist in identifying the stomach (Treves). Farabœuf advises inserting the finger beneath the liver as far as the vertebral column so as to feel the aorta, and then carrying it to the left, when a fold—the gastro-hepatic omentum—will be felt, and on following this fold downwards, the stomach will be located. The transverse colon may be recognized and thus differentiated from the stomach by its saccular dilatation, by its muscular bands, by the thinness of its walls and by the presence of the appendices epiploicæ. In *gastrostomy* by *Witzel's method*, the serous layer of the stomach is in-folded by means of Lambert's sutures arranged in one or more tiers over a tube as it lies against the wall of the stomach, the end of the tube having previously been inserted into the viscus through a small opening. The stomach is then sutured to the abdominal wound. By this method leakage into the peritoneal cavity is avoided and the stomach is opened at the time of the operation rather than, as in other methods, by dividing it into two steps, one for the suturing of the wall to the abdominal parietes, and the other for the incision into the stomach. *Pyloroplasty* is employed for the surgical treatment of benign strictures of the pylorus and consists in a longitudinal incision through the stricture and into the adjoining healthy tissues of the stomach and duodenum. The resulting wound is now sutured transversely, so as to increase the diameter of the narrowed pylorus. *Pylorectomy* is for the purpose of removing the pylorus in

malignant growths confined to this part, or in cicatricial stenoses that cannot be dealt with by pyloroplasty. In it the pylorus is exposed through a median abdominal incision, the omental attachments of the part are divided between ligatures and the pylorus removed, care being taken to avoid the important structures behind it, viz., the aorta, the inferior vena cava, the portal vein, etc. The wound in the stomach is then reduced to a suitable size and the divided ends of the duodenum and the stomach are united by Lambert's sutures or by Murphy's button. *Gastroenterostomy* is indicated when, in a case of pyloric stenosis which cannot be relieved by pyloroplasty, the passage of food from the stomach to the intestine is prevented. In this operation an artificial channel is made connecting the stomach to the jejunum, the anastomosis being secured by sutures or by the Murphy button. *Gastrectomy*, or removal of the stomach, may be employed for malignant growths entirely limited to the stomach, and was first performed by Schlatter, of Zurich, in 1897. It may be done by dividing the omenta between ligatures and then removing the organ by incisions through the duodenum and the œsophagus, and, lastly, approximating these structures by means of sutures, or the button, as in the other operations, above referred to.

Gastroplication, introduced by Bircher in 1891 and improved upon by Wier, is for the purpose of reducing the size of a dilated stomach, and is performed by folding the wall on itself and retaining it there by Lambert's sutures.

Gastrorrhaphy, or anchoring the stomach in gastrop-tosis or downward displacement of the organ, is performed by suturing the ligaments of the liver to the abdominal parietes (Treves, 1895); or, by uniting the peritoneal coat of the stomach to the abdominal incision (Duret, 1896); or, the lesser omentum to the peritoneum near the ensiform cartilage (Davis, 1897).

CHAPTER XXIII.

THE INTESTINES.

ANATOMY.	NERVOUS REFLEXES.
THE MESENTERY.	APPENDICITIS.
RELATIONS.	OBSTRUCTION.
LANDMARKS.	OPERATIVE WORK.

The Small Intestine averages in length about twenty-two and a half feet in the male, and about twenty-three and a half in the female, and is composed of three parts, the duodenum, the jejunum and the ileum. The *duodenum* is from ten to twelve inches in length and from one and a half to two inches in width, and is either U, V or annular-shaped. It is divided into four portions. The *first portion* passes transversely, when the stomach is empty, but posteriorly, when it is distended, and is directed towards the upper border of the first lumbar vertebra. Relations: This part lies under the gall bladder and the quadrate lobe of the liver; forms the lower boundary of the foramen of Winslow; has behind it the portal vein and the hepatic vessels; is situated above the pancreas and is almost entirely surrounded by peritoneum. The *second or descending portion* lies on the right of the vertebræ extending from the upper border of the first lumbar to the lower border of the third and occasionally the fourth lumbar vertebra, and is about three inches in length. Relations: It has in front of it the liver, the transverse colon and the meso-colon; behind, are the inner border of the right kidney, the renal vessels, the vena cava and the common bile duct, the latter running downwards, near the inner border, to join the pancreatic duct in the substance of the inner wall of this second portion of the duodenum, a little below its middle. This part of the duo-

denum has the peritoneum only in front, while to its left is the head of the pancreas which moulds itself to the shape of the bowel in this situation. In the U-shaped duodenum the *transverse part* is between two and three inches long and passes almost transversely from right to left to end in the ascending portion, which is about two inches in length, whereas, in the V-shaped duodenum, there is no transverse portion. Relations of the transverse portion when present: Above, the head of the pancreas and the superior mesenteric vessels; in front, the root of the mesentery and the superior mesenteric vessels; behind, the vena cava, the aorta, the crura of the diaphragm and the third lumbar vertebra. The *fourth* or *second ascending portion* terminates at the side of the upper border of the second lumbar vertebra, where it turns abruptly forward to join the jejunum forming the duodeno-jejunal angle. Relations: It is covered by peritoneum on the front, and, to some extent, on the sides also. It rests on the psoas muscle and left renal vein and has in front of it the transverse colon which separates it from the stomach, though at times the latter organ itself lies in front of it. Internally, are the aorta and the neck of the pancreas. This ascending portion of the duodenum is supported and held in its place by a fibrous band called the "muscularis suspensorius of Trietz," which runs from the side of the left crus to this portion and even beyond it, according to Lockwood. This suspensory muscle passes beyond the duodenum, between the layers of the mesentery, and supports the rest of the small intestine and the mesentery as well as the duodenum. The arrangement of the peritoneum in connection with this part of the duodenum is such, that a pouch is formed, funnel-shaped and with mouth upwards, by a fold running from the front of the duodenum to the parietal peritoneum. This pouch admits the tip of

the index finger, and may form a sac for a retro-peritoneal hernia.

Jejunum and *Ileum*.—The name jejunum is applied to the upper two-fifths of the small intestine below the duodenum, while ileum is applied to the remaining three-fifths, and though, when a portion of the jejunum near its beginning is examined, it will be seen to differ in some respects from the ileum, especially near its termination, yet there is no point where one can say the jejunum ends and the ileum begins.

The Mesentery.—The constant peristaltic movement and the changing pressure from the action of the abdominal muscles, and from the position, etc., of the body, necessitate that the bowel should be so supported, as to permit the freest gliding of one part over the other, and for this purpose we have the mesentery. The mesentery is formed by two layers of the peritoneum, between which pass the blood vessels, lymphatics, etc., for the intestine, and it supports the bowel by connecting it to the vertebral column. As the mesentery approaches the bowel, it splits so as to enclose the latter, the separation beginning about two-thirds of an inch from the surface of the bowel, and the base of the triangular space thus exposed is formed by the muscular coat of the intestine and is about five-sixteenths of an inch in width. The length of the mesentery varies, the average being about eight inches, although that portion of the intestine between six and eleven feet from the duodenum has, as a rule, a mesentery longer than the average. The length of its vertebral attachment is about six inches and extends from the left side of the second lumbar vertebra, obliquely across the vertebral column, to the right iliac fossa, and, at its termination in this fossa, it is very short, so that, next to the duodenum, this lowest portion of the ileum is the most fixed

part of the small intestine. The mesentery is peculiar in that it forms a plane, one side of which—the vertebral—is six inches in length, while the other—the intestinal—has a length of twenty-three feet, although but eight inches distant from the spine. It would almost seem as though one border—the vertebral—had been “puckered” up, until it was only six inches in length, but in reality, the other border, *i.e.*, the intestinal, has been elongated, since this peculiar shape is due to the convolutions that have developed in the primitive intestinal loop, which originally lay in front of the posterior mesial line, and may, perhaps, be better appreciated by imagining a spiral spring twenty-three feet in length compressed to a bulk of about six inches in length. Imagine, further, an incision made through the posterior wall of the abdomen dividing all the structures, with the exception of the peritoneum, and extending from the left side of the second lumbar to the right sacro-iliac symphysis. If this spring be compressed to its minimum, *i.e.*, six inches, and be inserted through the posterior wound, pushing the peritoneum in front of it, so as to stretch it to the distance of about eight inches from the spine, and if the spring be loosened, we would then have a spring, twenty-three feet in length, attached by a mesentery, eight inches wide, to the vertebral wall for a distance of six inches. *Meckel's Diverticulum.*—In about 2% of subjects there is a pouch or diverticulum given off from the ileum near its lower end and generally about three or three and a half feet from the ileo-cæcal valve. This pouch varies in length and may be a factor in the production of intestinal obstruction. It is the remains of the vitello-intestinal duct of the foetus.

The Large Intestine differs from the small in its shorter length, five feet; in its width, three inches at its widest, to one inch at its narrowest part; in its more fixed

position; in the presence of appendices epiploicæ; in the arrangement of its peritoneal attachments and in its longitudinal muscular fibres, the latter in the case of this bowel, being arranged in muscular bands about the width of the little finger, whereas, in the small intestine, the longitudinal muscular coat is spread uniformly over its surface. The first portion of the large intestine—the *cæcum* or blind extremity—is situated in the right iliac fossa, measures three inches in width and two and a half inches in height, and terminates above at the ileo-cæcal valve. It rests on the ilio-psoas muscle and is entirely surrounded by peritoneum. In the fœtus, the apex or conical end of the cæcum, becomes the appendix in the adult, and the longitudinal muscular bands form a part of this conical end just as they do in the rest of the large intestine. The normal type of the cæcum in the adult is not conical like it is in the fœtus, since, in the former, the right portion and anterior wall have developed to a greater degree than the remainder of the cæcum, with the result that this portion lies nearest Poupart's ligament, while the appendix itself is carried upwards and backwards with the rest of the cæcum, towards the ileo-cæcal valve, so that the base of the appendix is situated about two-fifths of an inch below this valve. The apex, or tip of the cæcum, formed by this enlarged right extremity, lies, as a rule, opposite a point a little to the inner side of the middle of Poupart's ligament and about one inch above it.

The Appendix Vermiformis.—The original apex of the fœtal cæcum, which has thus become displaced to the inner and posterior aspect of the cæcum, is termed, in the adult, the appendix, and averages about three and a half or four inches in length. It has a meso-appendix coming off from the left leaf of the mesentery and attached, as a rule, to the proximal third or half of the appendix, the remain-

der of the tube, *i.e.*, the distal end, being entirely surrounded by peritoneum. The meso-appendix permits the passage of the nerves, bloodvessels and the lymphatics to the appendix, and, since the meso-appendix is shorter than the tube itself, it causes the latter to become twisted or convoluted. The artery supplying the appendix is the appendicular, a branch of the ileo-cæcal from the ileocolic and is, in the male, a terminal artery, *i.e.*, it has very little, if any, communication with other vessels, so that when the mucous membrane of the appendix is inflamed, the pressure on the vessel, especially if a concretion be present, may occlude it and a gangrenous condition of the tube result. In the female, however, there occasionally exists a branch from the ovarian artery, called the appendiculo-ovarian, so that, theoretically, gangrenous appendicitis should be less common in this sex than in the male and clinical experience confirms this theory. The veins of the appendix terminate in the mesenteric, a tributary of the portal system; the nerves are derived from the plexus around the superior mesenteric artery, while the lymphatics end in a few glands at the junction of the ileum and colon. The appendix may point in various directions, but it is usually situated behind the ileum, and directed towards the spleen. Occasionally, the appendix lies over the brim of the true pelvis, or points upwards towards the kidney. These different situations depend on whether the tube formed adhesions, or not, in its descent towards the iliac fossa. The peritoneum, in the neighborhood of the appendix, forms three, more or less persistent fossæ, one directed downwards at the junction of the ileum and the colon—the ileocolic; a second at the junction of the ileum and cæcum, directed more or less downwards—the ileo-cæcal, and a third, less common, lying behind the lower part of the colon—the subcæcal.

The *ileo-cæcal valve* projects into the lumen of the large bowel, and is a narrow slit formed by two transverse bands. Its formation and direction favor the passage of the contents of the ileum into the cæcum, but prevent backflow from the latter. The *ascending colon*, about eight inches long, passes up through the right lumbar and hypochondriac regions and terminates at the under surface of the liver, a little external to the gall bladder, at which point it bends forwards, and to the left, as the hepatic flexure. Relations: It lies in front of the quadratus lumborum, the second part of the duodenum and the right kidney, and is surrounded, as a rule, on the front and sides only, by peritoneum, though in twenty-six out of one hundred subjects examined by Treves there was a meso-colon present. The *transverse colon*, about twenty inches in length, passes across the abdomen from the hepatic flexure on the right, towards the spleen, on the left. It gradually ascends as it nears the spleen until the splenic end is on a higher level than the hepatic end and at the same time it is deeper placed in the abdomen, so that the left extremity of the transverse colon is about one inch nearer to the posterior wall than the right extremity. The transverse colon is the most movable part of the large intestine, and, since it is longer than the body is wide, the extra length is accommodated by this portion of the bowel looping downwards and forwards. Relations: It lies beneath the liver, the gall bladder, the greater curvature of the stomach and the spleen; is above the small intestines and behind the abdominal walls, with the great omentum hanging down from it, so as to cover, more or less, the intestines, thus protecting them by its heat-retaining properties, although Greig Smith states that it very rarely conforms to this description, being often coiled up or folded on itself. The cavity of the great omentum is obliterated, as

a rule, after the second year, so that it is impossible in the adult to distend it by introducing air through the foramen of Winslow. The nerves of the transverse colon are derived from the cæliac plexus of the sympathetic. The *descending colon* begins above at the splenic flexure and runs downwards and slightly inwards to terminate below in the left iliac fossa as the sigmoid flexure. It averages eight and a half inches in length and is attached, at its upper part, to the diaphragm, by the phreno-colic ligament—a concave fold of peritoneum, which acts as a stay or support for the spleen as well. Relations: The descending colon lies in front of the left kidney, the diaphragm, the outer margin of the psoas and the quadratus lumborum muscle, and has a meso-colon thirty-six times out of one hundred subjects (Treves). The *sigmoid flexure*, about seventeen inches long, begins where the descending colon ends, viz., in the left iliac fossa, and passes from left to right towards the pelvis, in which most of its length is contained, to end at the middle of the third piece of the sacrum in the median line. As it crosses the psoas muscle it lies generally at right angles to it and often midway between the lumbo-sacral angle and Poupart's ligament, and its shape is such that it resembles the Greek letter Omega. It is almost completely surrounded by peritoneum and is attached to the fossa by means of a meso-colon—the sigmoid meso-colon. The *longitudinal muscular bands* of the large intestine are three in number—one on the posterior; a second on the anterior, and a third on the internal surface of the ascending and the descending colon and on the lower border of the transverse colon. They all start at the appendix and are lost as bands over the rectum, since they spread out and blend with one another on this portion of the intestine.

Landmarks.—For the *Duodenum*.—Starting at the situation of the pylorus, *i.e.*, two and a half inches below and in a line with the right border of the sternum, draw a broad line with convexity to the right and with the widest part of the curve about one inch from the median line, down nearly as far as the level of the umbilicus. The line should now cross the *linea alba* and should pass upwards, lying the same distance on the left, as on the right of the median line, and terminating above, about one inch below the level of the starting point. The following method may be employed to roughly illustrate the situation of the duodenum below the first part: Slightly flex the index finger and thumb of the left hand so that their tips shall be about one and a half inches apart. Place the tip of the index finger on the landmark for the pyloric opening of the stomach, on the right side of the *linea alba*, and the centre of the junction of index finger and thumb in a line with and a little above the umbilicus. The concave outline of the finger and thumb so placed will fairly well represent the markings of the U-shaped duodenum.

For the *jejunum* and *ileum* there are no definite landmarks, since there is no permanent relationship of these portions of the small intestine to the regions of the abdomen. Treves states that the portions most commonly found in the pelvis are the lower part of the ileum and that portion of the jejunum with the longest mesentery, *viz.*, that found between six and eleven feet from the end of the duodenum. The ileo-cæcal valve is situated in the right iliac fossa, about three and a half inches above the middle of Poupart's ligament, or about half an inch above a line drawn horizontally inwards from the anterior iliac spine and about three inches from this spine, while the average situation of the *tip of the caecum* is about one inch above and half an inch internal to the middle of Poupart's ligament.

The *appendix* is, as a rule, found at *McBurney's point*, *i.e.*, a point about one and a half inches from the anterior iliac spine, on a line drawn from the spine to the umbilicus. Another landmark for the appendix is a point about three inches above the middle of Poupart's ligament.

The line for the *ascending colon* corresponds to one drawn from the middle of Poupart's ligament, on the right side, upwards, and terminating at the ninth rib in a line with the tip of the tenth. The *descending colon* may be represented by a line drawn upwards from the middle of Poupart's on the left side, to the eighth rib at a point about half an inch external to the tip of the ninth rib. As seen from the side this upper end or splenic flexure of the descending colon is about one inch posterior to the upper end or hepatic flexure of the ascending colon. Posteriorly, the colon corresponds to a line drawn upwards from a point half an inch internal to the middle of the crest of the ilium. A curved line joining the upper terminations of the lines for the ascending and the descending colon, and having its convexity downwards to within about two fingers' breadth from the umbilicus, will agree fairly well with the usual situation of the *transverse colon*. The course of the *sigmoid* cannot be mapped out with any degree of accuracy, but may be roughly represented by the inner portion of a curved line, with convexity towards Poupart's ligament, drawn from the middle of the crest of the ilium and passing towards the pelvis, about midway between this ligament and the lumbo-sacral angle.

Reflex Nervous Disturbances of the intestine. —The local nervous supply for the intestine consists of two plexuses, one—Meissner's—situated in the submucous coat and giving branches to the intestinal glands, etc., and the other—Auerbach's—lying between the longi-

tudinal and the circular muscular coats. The latter presides over the movements of the intestine, but both are governed by branches from the solar plexus, which itself is controlled by the splanchnics and the right pneumogastric. The action of the fibres of the latter is, when irritated, to affect the activity of Auerbach's plexus so as to stimulate the movement of the intestine, while the former, *i.e.*, the *splanchnic*, is the great vasomotor controller of all the abdominal viscera. This nerve (the splanchnic) contains, in addition, sensory fibres for the intestine as well as inhibitory fibres, *i.e.*, fibres that lessen or inhibit the intestinal movement. Normally, the presence of the usual intestinal contents stimulates Auerbach's plexus and the unconscious peristaltic movements of the bowel result. Should, however, any irritating substance be present, the afferent or sensory fibres of the sympathetic convey the impression up to the solar plexus, and the efferent fibres, which run from the pneumogastric filaments in the solar plexus to Auerbach's plexus in the intestinal wall, excite increased peristaltic movements, but, if the irritation be more marked, the afferent nerves carry the impression past the solar plexus and onwards to the cerebrum and the effect of this disturbance of the sensory fibres is appreciated as pain, as in colic. Further, should the irritation be still more pronounced, as in severe inflammation, the local centre will be overstimulated and a paralytic condition of the intestinal muscles result, and, inasmuch as the paralyzed muscles will offer imperfect resistance to the action of the intestinal gases, meteorism, or gaseous distention of the bowel occurs. The *sensory* fibres of the splanchnic nerve may be affected in lead poisoning, in which condition the pain is referred to the terminations of these sensory fibres in the intestine, and colic is experienced, whilst reflex dis-

turbance of the *vasomotor fibres* may be seen in the effect of cold applied to the cutaneous nerves, and in fright, grief, etc. In the former instance, *i.e.*, in cold, the splanchnics which supply vasomotor fibres to the intestinal bloodvessels are disturbed so that dilatation results with the possible production of diarrhœa from the overloaded bloodvessels relieving themselves, whereas, in the latter case, *i.e.*, in fright, etc., the impression acts on the vasomotor centre in the medulla and constricts, through the splanchnic nerves, the bloodvessels of the intestine. In the former instance, diarrhœa results from dilatation of the intestinal bloodvessels. In this instance, diarrhœa results from constriction of the intestinal bloodvessels, so we see that opposite conditions may bring about a similar result. The explanation of diarrhœa occurring from a constricted state of the intestinal vessels is found in the presence of the carbon dioxide which would exist in the intestinal blood in greater amount than normal, because of the condition of local anæmia present, and since carbon dioxide is an irritant to Auerbach's plexus, its presence in increased quantity causes increased peristalsis, *i.e.*, diarrhœa.

Lastly, the *inhibitory* action of the splanchnic fibres may be shown by the influence opium exercises on them, since it stimulates the inhibitory fibres and produces constipation.

The effects of reflex action from the intestine may be seen in the skin when urticaria results from intestinal indigestion, while cramps in the calves of the legs bear the same reflex relationship to intestinal disturbance in cholera, etc., as it did to stomach disturbance, and which has been referred to under gastric reflex neuroses.

Pain in affections of the intestines, such as appendicitis, obstruction of the bowels, etc., is frequently referred to the region of the umbilicus, more particularly about one

inch above this point. It is hard from an anatomical standpoint to explain the reference of the pain to this situation. The inferior mesenteric plexus for the supply of the lower portion of the large intestine arises about this point, *i.e.*, one inch above the umbilicus, but this plexus does not supply the small intestine, and it is in affections of the small intestine, especially, that the pain is referred to the umbilicus. It *may* be due to reflex irritation of this plexus, but more likely to implication of the nerves to the great omentum, which is attached to the colon in this situation. These latter nerves arise from the gastro-epiploica sinistra plexus, an extension from the splenic which itself is derived from the solar plexus.

Syncope, etc.—In injuries to the intestine impressions are carried by the sensory nerves to the cerebrum, and an efferent impulse may be sent out to the heart through the inhibitory fibres of the pneumogastric, so that syncope results, and in this condition of syncope there is, in all probability, in addition to the reflex inhibition of the heart, a co-existent reflex dilatation of the abdominal bloodvessels through the impression on the sympathetic, In *shock* there is a more profound impression made on the centres than there is in syncope, so that a marked depression of cerebral activity results. Mansell Moulin says, “shock . . . is a reflex paralysis affecting all the functions of the nervous system.”

In *collapse* there is, in addition to dilatation of the abdominal vessels, an increased density of the blood, thus reflexly affecting the heart through the medium of increased blood pressure (Cobbet).

In **appendicitis** the pain may be referred to the umbilicus, as above mentioned, or it may be reflected to the front of the thigh through the anterior crural which lies between the iliacus and the psoas muscles, and, in all prob-

ability, this involvement of the anterior crural is due to mechanical causes—the appendix lying near the nerve. In the same way irritation of the bladder may be produced by the contact of the appendix with the ureter and with the plexus of nerves prolonged from the renal and the spermatic plexuses supplying the ureter. There is, of course, a possibility that the bladder complications may be reflex through the superior mesenteric plexus, and then down to the hypogastric plexus.

In *suppurative appendicitis* the pus may be situated outside of, or behind the peritoneum, in the recto-peritoneal tissue, and an abscess of this description may be secondary to an intra-peritoneal one, or it may be primary, the inflammatory action spreading along the connective tissue between the layers of the meso-appendix and thus affecting the extra-peritoneal tissues. These abscesses may ascend behind the colon as high as the posterior surface of the liver, and have been known to perforate the diaphragm and break into a bronchus, or they may descend into the pelvis, or to the front of the thigh. In the intra-peritoneal variety of appendicular abscess the pus cavity may be postcæcal, or it may be immediately behind the anterior parietal peritoneum, being walled in by adhesions between the cæcum, the small intestines and the omentum, or it may be confined to the pelvis or, general in the abdominal cavity.

Enteroptosis.—The small intestine is suspended by the mesentery, the mesenteric vessels, the end of the duodenum and the suspensory muscle of Trietz. Of the large bowel, the ascending and the descending colon are each supported by a short meso-colon, the sigmoid flexure rests on the iliac fossa and in the pelvis, while the transverse colon is retained in its place by the transverse meso-colon, the phreno-colic and the hepato-colic ligaments. In en-

teroptosis the intestines, as a whole, are displaced downwards, the vessels and mesentery being stretched. This condition is a part of the general state of visceroptosis, to which the name Glenard's disease is applied, and in which the hepatic flexure of the colon is the first portion of the intestine to be displaced. In enteroptosis, the lower abdominal region is distended, while the upper part is flattened.

In *hernia*, in addition to the protrusion of the bowel through the abdominal walls, already referred to, the intestine may become involved in the fossa duodenalis; in the foramen of Winslow; or in the intersigmoid fossa situated beneath the sigmoid meso-colon. When strangulated in these situations, the symptoms differ in no particular from strangulation of the bowel occurring elsewhere in the abdominal cavity.

Obstruction of the bowels.—The more common causes of obstruction of the bowels are: 1. *Strangulation* by bands or through openings; 2. *Intussusception*; 3. *Volvulus*. The first affects chiefly the small intestine; the second, the ileo-cæcal region especially, and the third, the sigmoid flexure. In *strangulation by bands*, the latter may be peritoneal adhesions that have become stretched and moulded by the movements of the intestine so as to be cord-like in form, or the band may be an elongated adherent omentum or a persistent Meckel's diverticulum. The usual manner in which strangulation occurs under the above circumstances is for the bowel to become engaged under a band, which, forming a bridge or arch, prevents disengagement. In *intussusception* one portion of the bowel is invaginated into another and, of the different situations in which this may occur, the cæcal region is found most frequently involved. The ileo-cæcal variety is the most common, forming, as it does, about 45%

of all cases of intussusception. In this form (ileo-cæcal) the entering bowel is composed of the ileum and cæcum, preceded by the ileo-cæcal valve, which forms the apex of the tumor and, as it increases, it does so at the expense of the receiving bowel, in this case, the colon. As the entering bowel progresses along the colon, the mesentery becomes stretched, thus causing the tumor to assume a curved appearance, the concavity being directed towards the umbilicus. In *volvulus* the sigmoid flexure is generally affected, forming about 80% of cases of this condition, and the chief factor in its production is an elongated meso-colon, due, often, to chronic constipation, since in this, the weight of the bowel drags on the sigmoid meso-colon thus stretching it. At the same time the parietal attachment of the meso-colon becomes relatively narrower so that a twist of it around its own axis is liable to occur and a *volvulus* result. *Rupture* of the intestine may be caused by a blow or by a kick from a horse, etc., and when it does occur, the relative order of the parts of the intestines affected is, first, jejunum; then the ileum; then the duodenum and, lastly, the colon.

Operative work on the Intestine.—For closing intestinal wounds, Lambert's suture is the simplest and the one most generally employed. About two-thirds of the intestinal wall is composed of mucous membrane, while the remaining third consists of the serous, muscular and the submucous coats. Of these, the last is much the stronger, and Halstead has demonstrated that each suture should include some of this structure. He says that: "A delicate thread of this tissue is very much stronger and better able to hold a stitch than a coarse shred of the entire thickness of the muscular coat." In *Lambert's suture* a fold of about one-tenth of an inch is picked up on either side of the wound, so that the inner row of needle

points is one-tenth of an inch from the wound, and one-tenth inch apart, and, on tightening the sutures the serous coats on either side are inverted and approximated. *Enterectomy* means resection or removal of a portion of the intestine, and, in it, the ends of the bowel may be joined "end to end" or "side by side" (*i.e.*, lateral anastomosis) by a variety of forms of intestinal suture or by means of mechanical appliances. Of the former, Lambert's is the one most used, and of the latter, Murphy's button. As a rule, the site of the incision is the linea alba, although it may be over the particular part of the bowel involved, especially when the median incision would not allow the freest scope for the proper handling of the diseased portion. When the abdomen has been opened and a loop of the bowel drawn out, it is often difficult to satisfy oneself as to which is the upper and which the lower end, and, as a point of some importance in differentiating the respective ends, the relation to the posterior wall of the mesentery belonging to the loop of bowel withdrawn, may be of assistance. If the surgeon supports the exposed loop with his left hand, and, if he can pass the index finger of the right hand down the left side of the mesentery belonging to this particular portion of bowel and along it to its vertebral attachment and thence unopposed towards the left flank, that part of the exposed loop directed towards the patient's head is the upper end. If, however, the finger on passing down on the left side of the bowel be conveyed to the right flank, the bowel is evidently reversed. *Enterotomy* means an incision into the bowel and is occasionally performed in urgent cases of intestinal obstruction when the patient is in danger of immediate death from the obstruction and in it the median incision is the one usually adopted. In *appendicitis*, the *incision* may be internally near the rectus or externally towards

the iliac spine. In the former case, an incision is made parallel with and half an inch to the right of the edge of the rectus. In the latter, the incision starts about half an inch above the level of a line drawn from the anterior iliac spine to the umbilicus, and at a distance of about one and a half inches from that spine. The direction of this incision is downwards and inwards and corresponds to the course of the fibres of the external oblique, and on the separation of these fibres, the internal oblique and transversalis muscles are divided in the line of the original incision. The transversalis fascia, which is exposed on section of the last named muscle, is incised and, lastly, the peritoneum is pinched up and opened between two pairs of forceps, so as to avoid wounding any underlying bowel. A serious objection to this method of operation, is the possibility of subsequent hernia developing at the site of the abdominal wound, and to avoid this, McBurney has devised the "gridiron" operation in which no muscular structures are divided. The fibres of the internal oblique and transversalis muscles are separated in the direction of their fibres, and therefore, in a direction almost at right angles to the superficial wound. The transversalis fascia and the peritoneum are then incised in the same direction. When, however, a tumor composed of the inflamed appendix and adherent omentum or bowel, is palpable, the incision may be made directly over it. In *identifying the appendix* a reliable guide to it is the anterior longitudinal band, since this, as well as the other longitudinal bands, arose from the apex of the cæcum in the foetus, and as this apex becomes the appendix in the adult, these bands still retain their relationship to the appendix, so that by following down the longitudinal band it will be found to lead to the base of the appendix.

Lumbar Colotomy is not performed now as often as formerly, being replaced by iliac colotomy, since the danger of opening the peritoneum is now almost nil, but, when for any reason this operation is justified, the guide to the incision is the normal situation of the colon. This may be represented, posteriorly, by a line drawn upwards from a point one half inch internal to the middle of the crest of the ilium, *i.e.*, half an inch internal to a point midway between the anterior and the posterior superior spinous processes of the ilium. The following description has been synopsised from Treves' Operative Surgery: "The incision in lumbar colotomy may be made parallel to the last rib, or in an oblique direction from the anterior superior spinous process to the angle of junction of the last rib with the erector spinæ muscle. After section of the skin and fasciæ, the external oblique and the latiss.dorsi muscles are exposed and divided and the internal oblique is brought into view. On dividing and retracting its fibres the transversalis muscle and the fascia lumborum are seen, and after section of these, the transversalis fascia and the outer edge of the quadratus lumborum present themselves, and the former being incised, the subperitoneal fat is now reached. If the colon does not present itself it must be sought for, and one of the best guides to it is the feeling communicated when the bowel is picked up between the finger and thumb. If sight, only, were relied on, there would be a possibility of mistaking the subperitoneal fat for bowel, since the former is at times arranged in strata separated by distinct layers of fascia. If the colon still remain undiscovered, the index finger should be inserted into the wound and the angle of junction between the psoas and the quadratus lumborum muscles sought for, as it is towards this situation that the uncovered part of the colon presents. If the kidney be felt, the bowel will lie in front of it."

In the descending colon the posterior longitudinal band is not of as much assistance in identifying the bowel as it is in the ascending portion, since, in the former the longitudinal bands spread out more or less as the sigmoid and rectum are approached. In *iliac colotomy*, or *cœliocolotomy*, the incision may be made, one-half above and one-half below a line drawn from the left anterior superior spinous process to the umbilicus, and the same structures divided as in the operation for exposing the appendix.

CHAPTER XXIV.

THE KIDNEYS AND URETERS.

ANATOMY.	RENAL REFLEXES.
RELATIONS.	CLINICAL EXAMINATION.
LANDMARKS.	OPERATIVE WORK.

The *kidneys* are situated at the back of the abdominal cavity behind the peritoneum, and are about four inches long, two and a half inches wide and one and a half inches thick, the left being a little narrower and heavier than the right. Each organ presents two surfaces, two borders and two extremities, and is surrounded and suspended by a quantity of loose areolar tissue formed by a thickening of the subperitoneal layer and termed the "capsula adiposa." In addition to this tissue the renal vessels and the tonicity of the abdominal muscles assist in retaining the kidney in its normal position. The influence of the abdominal muscles in supporting the kidneys is shown by the effects of the pressure exerted on the surfaces of each kidney by the contiguous structures, since Cunningham has demonstrated that the kidney, when hardened in situ, presents a point of maximum convexity, which, in the case of the left kidney, is a blunt summit, and in that of the right, is a transverse ridge. On the inclined planes above and below these convexities lie the different organs that are in contact with the kidneys, and these organs, thus moulding the kidney, assist in maintaining it in its position in the abdomen and are themselves supported by the abdominal muscles. Each kidney is situated at the inter-

section of the vertical with the upper horizontal line, so that it lies partly in the hypochondriac, epigastric, lumbar and umbilical regions, there being more, however, of the organ above, than below the horizontal line and more external, than internal to the vertical line.

Relations.—The *posterior* surface is directed backwards and inwards and rests on the posterior abdominal wall in front of the interspace between the eleventh and twelfth ribs above, and in front of the transverse processes of the first and second lumbar vertebræ below. This posterior wall is composed of (1) the diaphragm separating the lower extremity of the pleura from the kidney; (2) the anterior lamella of the lumbar aponeurosis separating the kidney from the quadratus lumborum; (3) the psoas muscle; (4) the transversalis and iliac fasciæ; (5) the twelfth dorsal, the ilio-hypogastric and the ilio-inguinal nerves. The *anterior* surface of the *right* kidney has, in front of its upper portion, the liver separated from it by peritoneum, while, below this hepatic area, there is a non-peritoneal surface divided into two parts, one close to and parallel with the inner border, for the second part of the duodenum, and the other external to this, for the hepatic flexure of the colon. The lower portion of this anterior surface is covered by peritoneum and has resting against it the small intestine.

The *anterior* surface of the *left* kidney may be divided into three areas, an upper covered by peritoneum and in contact with the stomach, a middle area, non-peritoneal, for the pancreas and the splenic vessels, and an inferior one, divided into a peritoneal surface for the small intestines, and a non-peritoneal for the descending colon. The *upper end* of the *right* kidney is capped by the suprarenal capsule and the liver, and reaches as high as the level of the eleventh dorsal spine, while the *upper extremity* of the

left organ has the corresponding capsule and the spleen above it and reaches a little above the level of the eleventh spine. The upper limit of each kidney is situated about two inches from the median line. Inasmuch as the direction of each organ is from above downwards and outwards, the lower end of each kidney will be at a greater distance (generally about half an inch) from the middle line than the upper end. This lower limit of the right kidney extends to a point a little below the level of the second lumbar spine, or, to a point, about one inch above the crest of the ilium, while that of the left kidney reaches the level of the second lumbar spine, *i.e.*, about one and a half to two inches from the iliac crest. The *outer border* is convex and is distant about three inches from the spinous processes. This border has, on the right side, the liver in contact with its upper two-thirds and the ascending colon with the remainder, while, on the left side, the spleen is in relation to the upper half of this border, and the descending colon to the lower half. The *inner border* is concave, and, on the right side, lies close to the vena cava, whereas, the inner border of the left kidney is about one inch from the aorta. This inner border presents, about its middle third, a vertical fissure, the *hilum* with an anterior and a posterior lip, and, since the kidney is directed obliquely, not only from above downwards, but also from, before backwards and outwards, it follows that the posterior lip points forwards rather than inwards. The hilum gives passage to the structures entering and leaving the kidney, and these structures are: The renal vessels; the renal plexus of nerves; the ureter; the lymphatics and connective tissue, the latter continuous with the capsule.

The *bloodvessels* of the kidney are the renal artery and the renal vein, the latter on the right side being very short on account of the proximity of the kidney on that

side to the vena cava. This close relationship of the kidney with the vein should be borne in mind in nephrectomy or removal of the right kidney. The artery arises from the aorta on a level with the first lumbar vertebra, and before entering the hilum, which is opposite the spine of the same vertebra, breaks up into three or four terminal branches. Occasionally, one or more extra branches are given off that enter the renal substance at points other than the hilum, and these might cause trouble during the operation of nephrectomy. The *capsule* of the kidney is supplied by the terminal twigs of the renal, by the suprarenal, the phrenic, and the lumbar arteries, anastomosing with one another, hence a limited amount of circulation may still be carried on in the kidney when the renal itself has been occluded. The *nerves* surround the renal artery and form the renal plexus, and, although a few filaments from the pneumogastric are prolonged to this plexus, yet it is mainly formed by the sympathetic, *i.e.*, by extensions from the solar, the aortic, the spermatic plexuses, and from the smallest splanchnic nerve.

The **Ureters** are about twelve inches long and begin above at the hilum of the kidney, being continuous with the renal pelvis. They are about one-sixth of an inch in diameter when distended, and are composed of a fibrous, a muscular and a mucous coat, and, in their passage towards the pelvis, lie immediately beneath the peritoneum to which the fibrous coat is intimately adherent, so that when the peritoneum is stripped from the posterior abdominal wall it carries with it the ureter. This may be seen in extravasations behind the peritoneum in which the ureter is raised with this membrane so that it lies in the anterior wall of the cavity. At their commencement the two ureters are about three inches apart, but, as they descend, they converge slightly, so that at the brim of the

pelvis they are distant about two and a half inches from each other. In the true pelvis they at first diverge but soon approach one another as they near the bladder, and at their terminations in the bladder, in the wall of which they run for about half an inch, they are about one and a half inches apart. Three constrictions are often found in these tubes at which calculi are liable to be arrested—one above, about two inches from the hilum; a second, where it crosses the common iliac artery opposite the sacro-iliac symphysis, and a third, just before it enters the bladder.

Relations.—Posteriorly, each ureter rests, in the abdominal cavity, on the psoas muscle, the genito-crural nerve and the common iliac artery. Anteriorly, are the peritoneum, the intestine, *i.e.*, the ileum on the right and the sigmoid flexure on the left, and the spermatic vessels. Internal to the right ureter is the vena cava, while the aorta is on the inner side of the left one, and is situated at a distance from it varying from one inch, above, to half an inch, below. In the pelvis the ureter rests on the obturator muscle and fascia, and on leaving these it passes in a reflection of the peritoneum to the bladder, being crossed in its course by the vas deferens in the male. In the female it passes behind the uterine artery across the base of the broad ligament, and, passing over the upper third of the lateral wall of the vagina, enters the bladder opposite the middle of the latter canal. **Nerves.**—The ureter is supplied by nerves derived from the renal, the spermatic, the mesenteric and the hypogastric plexuses.

Landmarks for the Kidneys —(Fig. 7). To outline the kidneys in front, take a point on the seventh costal cartilage about two inches transversely from the tip of the ensiform cartilage, to represent the upper limit of the right kidney. A second point should be marked on the skin two and a half inches from, and one inch above the

level of the umbilicus for the lower extremity, and a third, one inch from and opposite to the bony part of the eighth rib, or a little over four inches from the median line, to indicate the middle of the outer border. Join the upper and the lower landmarks by a convex line passing through the middle landmark. This represents the outer border, and to complete the outline, *i.e.*, the inner border, join the upper and lower landmarks by a line somewhat concave towards the middle line of the abdomen. When this has been done, it will be seen that half of the outlined anterior surface will be under cover of the costal cartilages. The left kidney may be outlined in a manner similar to the above, excepting that the diagram for it would be situated half an inch higher up than for the right. The landmarks for the purpose of outlining the right kidney on the back (Fig. 9), are: A point about two inches from the eleventh dorsal spine to indicate the upper limit; a second one about three and a half inches from the middle of the space between the twelfth dorsal and the first lumbar spines, for the point of greatest convexity of the outer border; a third, about one inch above the iliac crest and two and a half inches from the lower part of the second lumbar spine for the lower end. Join the first and third points by a convex line passing through the second, to represent the outer border, and complete the outline with a slightly concave line between the upper and lower points for the inner border, so that about one-third of the posterior surface shall be under cover of the last rib and the eleventh interspace. The left kidney may be indicated by a similar outline about half an inch higher up than that for the right. The relative position of the more important structures at the hilum is, from before, backwards; *vein, artery, ureter*. From above, downwards, on the right side, the order is, *vein, artery, ureter*; whereas on the left it is, *artery, vein, ureter*.

Landmarks for Ureter.—The ureter may be represented by a line drawn downwards and slightly inwards from a point opposite the tip of the tenth costal cartilage, about two inches from the median line, to a point below, indicated by the junction of the line joining the two iliac spines with a vertical one drawn upwards from the spine of the pubes. This latter point, *i.e.*, this point of junction, is about where the ureter crosses the pelvic brim. The landmark for where the ureter is crossed by the spermatic vessels is a point in its course about one inch below the level of the umbilicus, or, about four inches internal to the highest point of the iliac crest.

Renal Reflexes.—The nerves of the kidney contain vasomotor, sensory and secretory fibres. The sensory nerves explain the local pain and soreness felt in the renal region when a stone is situated in the pelvis of the kidney. The shock and collapse sometimes present in renal colic are no doubt dependent on the impression made on the solar plexus through its sensory branches to the kidney, and when the pain in renal calculus is felt in other parts of the abdomen, it is probably due to reflex disturbance of the branches of the solar plexus, as in the case of the intestinal reflex neuroses, already referred to. When pain is referred to the testicle, it is dependent on diffusion of the sensory impressions along the ureteral plexus to its termination at the testicle. This ureteral plexus surrounds the ureter, and is formed by branches derived from the renal, the spermatic, the mesenteric and the hypogastric plexuses. When pain, in renal calculus, is experienced in the lower parts of the abdomen and down the thigh, it is no doubt a reflex action, the paths being from the ureteral plexus through the spermatic, etc., to the aortic plexus, thence through the rami communicantes to the origins of the upper lumbar spinal nerves, the first

two especially, and then through these lumbar nerves, viz., the ilio-hypogastric, ilio-inguinal, genito-crural, etc., to their distribution. The action of the genito-crural is seen in the retraction of the testicle—a not uncommon symptom in renal calculus, the retraction being due to the action of the cremaster muscle which is supplied by this nerve.

Clinical Examination.—*Percussion* of the kidney.—No definite information can be obtained by percussion of the normal kidney, posteriorly, because of the overlying mass of lumbar muscles, nor can any be obtained anteriorly on account of its deep situation in the abdomen. Again, it is impossible to recognize the kidney by *palpation*, except very rarely, and then on the right side, only, and in a very thin subject. Hence, when the normal organ is palpable, it means that its attachments are lax enough to permit its gliding more or less downwards—“movable” kidney. The term “movable,” applied to the kidney, has reference to its movement with or without its fatty capsule, and, as a rule, behind the peritoneum. This must be distinguished from “floating” kidney—a congenital condition, in which the kidney has a mesonephron so that it is completely surrounded by peritoneum, and, therefore, hangs free in the abdominal cavity. Movable kidney is more common in women than in men (Ebstein considers the proportion as seven to one; Einhorn, ten to one). Edebohls stated that 20% of womankind have “movable” kidney. The right is displaced more often than the left—according to Rutner (1890), seven times; to Greig Smith, four times, and to Einhorn, twenty times. Movable kidney may be a part of visceroptosis or Glendard’s disease; or it may be due to the corset or tight waist band; or to relaxation of the abdominal walls (Sulzer); or to disappearance of the fat around the kidney (Lan-

dau). Greig Smith states that long flexible spines, with sloping lower ribs and flat slender waists, is the conformation that most favors renal mobility. To examine a patient for movable kidney, Hare advises: "With the patient lying down, the physician should place the fingers of the left hand on the postero-lumbar region under the last ribs, gently pushing forward that part. The ends of the fingers of the right hand should then be placed in front just below the costal cartilages. On the beginning of a deep expiration, the kidney, if movable, will be felt between the two hands." Among the symptoms of movable kidney, Dietl's crises are not infrequent. These are characterized by attacks of severe abdominal pain, nausea and collapse, which arise from a kinking or twisting of the renal vessels and the accompanying plexus of nerves, thus disturbing the solar plexus. Edebohls states that in 80% of cases of movable kidney, chronic appendicitis is present, due, he thinks, to the compression by the kidney of the return circulation through the superior mesenteric vein.

In *perinephritic inflammation*, there are often present certain special symptoms, such as lameness of the affected side, flexion of the thigh, etc., from the involvement of the psoas muscle on which the kidney lies. Should pus form, it rarely penetrates the peritoneum, but tends to burrow towards the surface of the body, or upwards towards the thorax, possibly perforating the diaphragm or lung; or downwards towards the pelvis; or it may enter the psoas muscle and appear below, as a psoas abscess.

Operative Work on the Kidney.—Puncturing the kidney may be done in cases of hydronephrosis, hydatids, etc., and is best performed with an aspirating needle inserted, according to Morris, when on the left side, just in front of the last intercostal space, and, when on the right side, midway between the last rib and the

crest of the ilium, about two and a half inches behind the anterior spinous process. In the normal kidney a needle inserted horizontally inwards, at either of these points would transfix the colon, but, when this operation is warranted, there is present a tumor, large enough to push the bowel in front of it, so that it would be out of the way during the operation. The *lumbar incision* for such operative work on the kidney as nephrorrhaphy, or anchoring a movable kidney; nephrolithotomy, or removal of a stone from the kidney; nephrotomy, incising the organ; or nephrectomy, complete removal of it, may be made in the loin, starting about one inch below the last rib and running obliquely downwards toward the crest of the ilium and dividing the same structures as mentioned under lumbar colotomy. Should, for any reason, more room be required, it may be obtained by adding a transverse cut, extending towards the middle line, from near the lower end of this oblique wound. In nephrectomy, when the kidney cannot be dealt with from behind, it may be approached through an *abdominal incision*—Langenbuch's, placed in the linea semilunaris, half above and half below, the level of the umbilicus. The intestines are drawn to one side, and the colon made out, where it covers the kidney. The perirenal fat is exposed after dividing the outer, rather than the inner layer of the meso-colon, since the latter layer contains the vessels for the nutrition of the intestine, and gangrene of the bowel might ensue were this layer divided. The edges of the incised meso-colon may be sutured to the edges of the peritoneum at the abdominal wound, thus allowing the operation to be performed without any danger of infecting the general peritoneal cavity. One advantage of the abdominal operation is that the presence of the other kidney may be established, since cases are on record where there was only one kidney present,

and that one was removed in the lumbar operation. The improvement in the cystoscope permits the thorough examination of the entrance of the ureters into the bladder and the collection of urine from either orifice, so that it is possible to differentiate, before an operation, as to the particular kidney affected.

Operative Work on the Ureter.—The ureter may be approached, extraperitoneally, through an incision in the iliac region, and then stripping off the peritoneum, or through an anterior incision opening up the peritoneum.

CHAPTER XXV.

THE SPLEEN.

ANATOMY	CLINICAL EXAMINATION.
RELATIONS.	DISEASE.
LANDMARKS.	OPERATIONS.

The spleen averages about five inches in length, four in width, and one and a half in thickness, and is situated deeply in the left hypochondrium between the fundus of the stomach, the under surface of the diaphragm and the upper end of the left flexure of the colon. When hardened in situ it presents three surfaces, external, internal and basal, and two borders, anterior and posterior. It is obliquely placed in the abdomen, both from above, downwards and outwards, and from above, downwards and forwards, and is so situated, that its long axis is parallel to the direction of the lower ribs.

Relations.—The external surface looking upwards, backwards and to the left, is in relation with the under surface of the diaphragm. The internal surface is divided into two areas by a vertical ridge, in front of which is the hilum for the transmission of the vessels, etc., to and from the spleen. The anterior of the two areas is in relation with the fundus of the stomach and the tail of the pancreas, whereas, the posterior touches the left kidney and the left suprarenal capsule. The basal surface is triangular in shape, forms the lower end of the spleen, and is in contact with the phreno-colic ligament and the splenic flexure of the colon. The anterior border is thin and sharp and is marked by three or four notches, while the posterior border is blunt and dips in between the diaphragm and the kidney. The spleen is supported by certain peritoneal ligaments, the principal

ones being: (1) The suspensory, from the left crus to the inner surface behind the ridge; (2) the gastro-splenic, which, serving as a support for the fundus of the stomach rather than for the spleen, passes from a little behind the former to the hilum of the latter and contains the vasa brevia for the stomach; (3) the reno-splenic, passing as its name indicates, from the kidney to the spleen, contains the splenic vessels; (4) the phreno-colic, stretching from the diaphragm opposite the ends of the tenth and eleventh ribs, to the splenic flexure of the colon, forms a pocket for the support of the spleen. *Bloodvessels.*—The arteries of the spleen are branches of the splenic, which divides into three or four smaller arteries about one and a half inches from the hilum. These latter subdivide into twelve or fifteen twigs which enter the hilum. The splenic vein is about twice as large as the artery, and returns the blood from the pancreas, the spleen, the duodenum, part of the stomach, the omentum, descending colon, sigmoid flexure and part of the rectum. The nerves are derived from the solar plexus and from the right pneumogastric.

Landmarks.—The upper end of the spleen is a little above the level of the tip of the ninth dorsal spine, or is opposite to the middle of the body of the tenth dorsal vertebra, and is distant from the spine about one or one and a half inches. The lower end is a little below the level of the eleventh dorsal spine and never extends, except when diseased or displaced, beyond the line joining the left sterno-clavicular articulation to the tip of the eleventh rib. This lower end is generally situated about the midaxillary line. The body of the spleen lying between these points is obliquely placed under cover of, and parallel to the ninth, tenth and eleventh ribs. To roughly outline the situation of the spleen, stand behind the patient and place the left hand, with the thumb flexed on the

palm, upon the postero-lateral aspect of the left side of thorax, so that the lower part of the middle of the wrist will be about one inch from the spine, and the line of the middle finger will be over the tenth rib. The area covered by the hand will indicate, fairly well, the situation of the normal spleen (Fig. 9).

Clinical Examination.—*Percussion.*—Like the liver, the spleen is partly hidden by the lower margin of the lung, so that there is an area of “relative” as well as one of “absolute” dullness on percussion. When percussed from above, downwards, the “relative” dullness ends opposite the inferior limit, or lower border of the lung, *i.e.*, at the level of a line passing around the thorax crossing the mammary, the axillary and the scapular lines at the sixth, eighth and tenth ribs, respectively. Below this, and in a direction parallel to the ribs, is the area of “absolute” dullness. When the spleen is enlarged, the area of dullness is increased, and, when the organ is displaced downwards, as in visceroptosis, or, when it is forced upwards, as in distention of the abdomen from ascites, meteorism, etc., the area of dullness is interfered with. In the healthy organ, deep percussion often fails to bring out, with any degree of accuracy, the splenic area, because of the presence of a tympanitic note from the underlying stomach or colon when empty, or, on the other hand, the normal area of splenic dullness may be apparently increased when the stomach is distended with food, or the bowel with hardened fæces. When percussing vertically downwards, near the posterior part of the organ, it must not be forgotten that the splenic dullness merges into that arising from the lumbar muscles and the left kidney.

Palpation.—The spleen cannot be palpated, when normal, except in the condition termed wandering spleen, or in those cases of downward displacement, the result of in-

trathoracic growths, subphrenic abscess or pleurisy with effusion, and, when so displaced, it may be detected by the presence of the notches in the thin anterior border of the organ.

Splenic Reflexes.—The spleen, being supplied by projections from the solar plexus, is, therefore, presided over to a great extent by the splanchnics. These splanchnic nerves contain certain fibres which arise from a special centre in the medulla oblongata and pass downwards in the spinal cord to leave it in the dorsal region and enter the splanchnics. Stimulation of these fibres causes contraction of the organ (possibly this is an explanation of the statement of Botkin that exhilarating ideas diminish the size of the spleen). The same result, *i.e.*, the diminution in size may be brought about by electrical stimulation over the region of the spleen, or by the application of cold to the skin over the same region. The latter phenomena are, in all probability, reflex actions, the paths being from the lower dorsals, especially the eighth, ninth and tenth, to the rami communicantes, and through these to the splanchnics, and thence to the solar plexus and the spleen. In *splenitis*, or inflammation of the spleen, the local pain is probably due to stretching of the nerves in the capsule, whereas, the pain, felt in the back, etc., is reflexly transferred from the spleen to the dorsal nerves through the paths above mentioned. Should the inflammatory action terminate in suppuration, the pus may “point” at the abdominal parietes, adhesions having first occurred between the serous covering of the spleen and the parietal peritoneum, or it may perforate the diaphragm and open into the pleura or lung, or, passing downwards, may rupture into the stomach, colon or the abdominal cavity itself.

Hæmorrhagic infarction of the spleen is due to a plugging of one of the branches of the splenic artery by an embolus. These branches are terminal, *i.e.*, they do not anastomose with one another, but end in the splenic pulp—there being no capillaries in the spleen—and from this pulp, the radicles of the splenic vein arise. An embolus being carried to the spleen and lodging in one of the arterioles, shuts off the circulation from the area supplied by that vessel with the production of a wedge-shaped infarction. The connection of the venous radicle with the other end of the anæmic area allows a back flow of blood from the valveless splenic vein, thus forming what is known as a “hæmorrhagic infarction.” The base of the wedge-shaped infarction does not quite touch the surface of the spleen, since there is a very thin layer of healthy tissue overlying it beneath the capsule. This area of healthy tissue is nourished by small twigs from sources other than the intra-splenic vessels, *viz.*, from the supra-renal, the phrenic, etc., and is, therefore, not affected by the infarction. *Movable or wandering spleen* may be a part of the general condition of prolapse of the viscera—visceroptosis, or it may be due to a local relaxation or lengthening of the ligaments sustaining the spleen, especially the phreno-colic and the suspensory ligaments. When movable, the organ becomes more or less enlarged, and may present symptoms of dragging, or of uneasy sensations in the left hypochondriac region, or there may result the more severe and generally fatal train of shock, fever and gangrene from a twisting or torsion of the pedicle which contains the splenic vessels and nerves.

Congestion of the Spleen.—In health there is always more or less congestion of the spleen during or at the completion of the act of digestion, but, in disease, the organ may be acutely congested in fevers, etc., or, chronically,

in malarial poisoning, anæmia, etc. In diseases of the liver, heart or lungs, in which there is obstruction to the circulation through these organs, the spleen would be expected to show the effects of the retarded circulation by enlarging from the chronic congestion that is usually present. But this enlargement does not always occur since the elastic and the non-striated muscular tissues of the organ possess sufficient resisting power to prevent such enlargement. Roy has shown by means of the onco-graph that the circulation in the spleen is peculiar, in that it does not depend so much on the blood pressure present in the arteries, as it does on the rhythmical contraction of the muscular fibres of the capsule and trabeculæ, and further, that the diastolic and systolic actions together, occupy about one minute. *Rupture* of the spleen may occur spontaneously in cases in which the organ is enlarged, or, it may result from traumatism, such as from blows, kicks, penetration by the ends of a broken rib, etc. Such cases of rupture, however, are rare, because of the protection afforded by the depth of its situation in the abdomen.

Operations.—*Splenectomy*, or removal of the spleen, has been performed for leucocythemia, hypertrophy, neoplasms, wounds, or for movable spleen. Statistics show that for leucocythemia splenectomy is unjustifiable, since, in thirty-six operations recorded, there were thirty-one deaths. For simple hypertrophy, there were fifty-nine operations with twenty-five deaths, while for wounds, movable spleen, etc., there were forty-three operations with eleven deaths.

Operation.—The incision may be made either in the median line, or, at the outer edge of the rectus muscle on the left side. During the operation the spleen must be handled with the utmost gentleness on account of the ex-

treme friability of its tissues. Symptoms of collapse have occurred during the operation from a twisting of the pedicle, and the common cause of death after splenectomy is hemorrhage, frequently the result of ligating the pedicle while there is a strain on it, so that a small vessel might retract from under the ligature, and secondary hemorrhage occur. A number of methods have been devised and applied by different operators to avoid subsequent hemorrhage. Greig Smith states, that success or failure in this operation depends on the treatment of the pedicle. He advises separate ligation of each vessel while it is in a state of relaxation so as to avoid subsequent retraction, and then, as an extra precaution, he surrounds the whole pedicle with a single ligature. *Splenopexy*, or fixation of a wandering spleen, may be attempted to avoid the necessity of splenectomy. Rydygier, in 1893, introduced this operation, making a pocket of the parietal peritoneum for the purpose of receiving the spleen. Sykoff recommends the surrounding of the organ with sterilized catgut, the free ends of which are fixed to the parietes.

CHAPTER XXVI.

THE SUPRARENAL CAPSULES AND THE PANCREAS.

ANATOMY.	LANDMARKS.
RELATIONS.	DISEASE.
OPERATIONS.	

The Suprarenal Capsules.—These structures, two in number, lie against the diaphragm, opposite the eleventh ribs, and are about two and a half inches apart. The right one is pyramidal in form, with its apex directed upwards and inwards, while the left, crescentic in shape, is placed towards the inner aspect of the left kidney and extends nearly to the hilum.

Relations.—The upper portion of the anterior surface of the *right* capsule lies behind the posterior surface of the liver, while the lower part is crossed, on its inner aspect, by the duodenum. Internally, it touches the vena cava. The *left* suprarenal capsule is situated behind the stomach and a small portion of the left end of the pancreas. Externally, it is in contact with the spleen, while internally, it reaches nearly to the aorta.

The **Landmarks** for these bodies may be arrived at by remembering the outline of the kidneys, above which they lie, extending for a distance of about one and a quarter inches and continuing the upward and inward direction of these organs.

Disease.—The suprarenal capsules are the organs principally affected in Addison's disease, and some of the theories as to the causation of this disease, are, that it depends on suprarenal inadequacy of excretion (MacMunn), or of secretion (Langlois), or that it depends on interference with the nervous supply (Greenhow). This ner-

vous supply is derived from the solar plexus and contains, in addition to the sympathetic fibres, filaments from the pneumogastric and the phrenic nerves.

Operations.—Malignant disease of the right suprarenal may spread into the vena cava, the liver or the right kidney, or, if the left one be affected, it may involve the left renal vein, the stomach or the spleen. Jonas reports a case of removal of the right suprarenal through an incision extending downwards and inwards for about four inches from the right costal arch.

The **Pancreas** is situated in the epigastric and left hypochondriac regions and lies transversely in the abdomen at about the level of the first lumbar vertebra. It may be divided into a head, a neck, a body and a tail, and is about six inches in length. The *head* is bent downwards, so that it extends lower than the lower border of the body and is moulded by the different parts of the duodenum into a shape somewhat resembling the head of a hammer. It has in front of it, the transverse colon and the meso-colon, while behind, are the vena cava, the aorta, the left renal vein and the common bile duct. The *neck* is about one inch in length and is bounded above by the first part, and below, by the last part, of the duodenum. The *body* and *tail*, about four inches long, present three surfaces and three borders, and extend from right to left to terminate at the spleen, the tail turning upwards before reaching this organ, so as to rest on the lower part of its inner surface.

Relations of the body and tail.—The anterior surface is concave and has the posterior surface of the stomach resting on it. The posterior surface is grooved for the reception of the splenic artery and vein, and lies in front of the aorta, the left crus, the left kidney and its vessels. The inferior surface rests on the duodeno-

jejunal angle and on the transverse meso-colon to the left of the latter. The superior border has, above it, the solar plexus and the cœliac axis, while the inferior border is the dividing line for the two layers of the transverse meso-colon. The excretory duct of the pancreas runs from left to right, to unite, as already mentioned, with the common bile duct in the walls of the descending part of the duodenum. The *nerves* are derived from the solar plexus and have, in addition, a few filaments prolonged from the right pneumogastric.

Landmarks.—On the anterior surface of the abdomen the *head* of the pancreas lies, disk-like in shape, mostly to the right of the median line, and nearly two inches above the umbilicus. The *body*, a little over an inch in width, crosses the first lumbar vertebra from right to left, in the direction of the tip of the ninth left costal cartilage. The pancreas cannot be *palpated* on account of its depth in the abdomen.

Disease.—*Cysts* in the pancreas may be due to the retention of the normal pancreatic juice, but, according to Senn, there is something more, viz.: “An arrest of absorption due to a loss of function of the vessels which perform this task.” A pancreatic cyst develops, as a rule, in the body or tail, but very rarely in the head, and may present itself in two ways, one, the more common, in which it pushes forward the stomach, lying beneath the liver and above the transverse colon; the other, in which it grows between the two layers of the transverse meso-colon so that the colon lies above it.

Acute Hæmorrhagic Pancreatitis.—In this the interlobular tissue is infiltrated with blood and the characteristic features are, sudden onset, intense colicky pain and collapse. The latter symptoms are due to the disturbance of the solar plexus, and have been referred to when discussing intestinal reflexes.

Carcinoma of the pancreas was found one hundred and twenty-seven times in eleven thousand four hundred and ninety-two post-mortems, and, when present, generally involved the head. In addition to the usual symptoms of cancer, the common bile duct is often, in carcinoma, compressed on account of its close relationship to the head of the pancreas, thus causing an intense and persistent jaundice associated, as a rule, with a dilated gall bladder.

Surgery of the Pancreas.—In operative work on the pancreas an incision in the middle line between the umbilicus and the ensiform cartilage is generally employed, but, if a tumor be present on the left side, the incision may be placed over it. The great omentum is divided near the stomach, the latter is drawn upwards, the colon is depressed, and the pancreas, or cyst, etc., is exposed.

CHAPTER XXVII.

ABDOMINAL VESSELS AND REGIONS.

VESSELS.

Relations.

Landmarks.

Aneurism.

Ligation.

REGIONS.

Tumors of.

The Abdominal Aorta begins at the aortic opening of the diaphragm, which is situated at the level of the lower part of the twelfth dorsal vertebra. It passes downwards and terminates about the middle of the fourth lumbar vertebra, a little to the left of the median line, where it divides into the two common iliacs.

Relations.—In front are the right lobe of the liver, the lesser omentum and stomach, the solar plexus, the termination of the œsophagus, the splenic vein, the pancreas, left renal vein, transverse part of the duodenum, aortic plexus and the median lumbar lymphatic glands. *Behind*, are the bodies of the lumbar vertebræ, left lumbar veins and the origin of the left crus. On the *right* side, are the right crus, the splanchnic nerve, lobus Spigelii, receptaculum chyli, right semilunar ganglion and vena cava. On the *left*, are the left crus, left splanchnic and left semilunar ganglion. The branches of the aorta are; visceral for the supply of the different abdominal organs, and parietal for the walls of the abdomen. Between the smaller branches of these two divisions of the abdominal blood supply there is more or less anastomosis. The aorta gradually diminishes in size from above downwards, on account of the area and number of the branches given off from it in its course.

Landmarks.—From a point in the middle line of the body and about one inch below the bony ends of the seventh ribs, draw a line to a point a little to the left of the middle line, and half an inch below the level of the umbilicus. The level of the umbilicus may be more or less altered in cases of obesity, so that a better landmark for the lower end of the vessel would be a point a little to the left of the middle of the line joining the highest parts of the crests of the ilia.

The landmarks for the main branches of the aorta are as follows: The *celiac axis* is opposite the lower border of the twelfth dorsal vertebra and is about four inches from the umbilicus. The *superior mesenteric* arises opposite the lower part of the first lumbar vertebra, a little less than four inches above the umbilicus. The *renal* is opposite to the intervertebral substance between the first and second lumbar vertebræ, and about three and a half inches above the umbilicus, while the *inferior mesenteric* is opposite the middle of the third lumbar and about one inch above the umbilicus.

Aneurism of the abdominal aorta is much less common than aneurism of the thoracic, since, according to Crisp, only fifty-nine, out of a total of five hundred and eighty-one cases of aortic aneurism, were abdominal. The upper part of the abdominal aorta is more frequently involved in this condition than the lower part, as shown by Sebert, who noted that out of one hundred and three cases of abdominal aneurism only three were at or near the bifurcation (Pepper). Should rupture of the sac occur in this variety of aneurism it may take place into the retro-peritoneal tissue, or into the peritoneal cavity, or into the stomach, bowels, bladder, vena cava, pleural cavity or spinal canal. Among the *symptoms of abdominal aneurism*, pain of a severe neuralgic character occupies a promi-

ment place. This pain may shoot to the epigastric or to the umbilical regions, in which case, it is due to the connection of the solar plexus with the intercostal nerves, or it may dart towards the pubes or into the thigh as far down as the knee. When the pain is found in the latter situations it may result from the direct pressure of the sac on the upper lumbar nerves, *i.e.*, on the ilio-hypogastric, ilio-inguinal, etc., or it may be reflex in character, the irritation being conveyed from the stretched aortic plexus of the sympathetic to these lumbar nerves. Movement, such as sneezing, coughing, straining, etc., intensify the pain, since the blood pressure is increased by these actions. Should the aneurism erode the vertebral column there is added a gnawing, boring pain. Pressure on the stomach or bowels, or on the nerve plexuses supplying them, produces symptoms of a dyspeptic character, while pressure on the renal vessels may cause uræmia; on the vena cava, œdema of the lower limbs; or on the bile duct, jaundice. Direct pressure by the surgeon on the aneurism will cause increased tension in the femorals, and, if the pressure be suddenly removed, there will result a temporary cessation of the femoral pulsation because of the aspirating influence of the suddenly distended aneurismal sac. If both femorals be compressed there is an increase of tension in the tumor. These manipulations, however, are dangerous, since rupture may result from the sudden strain that is thus put upon the sac. When examining a patient for suspected abdominal aneurism it is advisable to have him change his position from back to side, or to assume the genu-pectoral position. The object of this change of posture is to assist in diagnosing a tumor involving the intestines, the mesentery or the omentum, from an aneurism. The tumor might receive pulsations from the underlying aorta, but, when the patient is made to change his position, it

would fall away from the bloodvessel and the pulsations would cease, whereas, in the case of an aneurism, pulsation would still continue. The mobility of an aneurism involving the superior or inferior mesenteric arteries, will assist in distinguishing it from one affecting the aorta itself. *The superior mesenteric artery* may be plugged by an **embolus**—a condition which generally ends fatally. This vessel supplies the whole length of the small intestine with the exception of the upper part of the duodenum, which is supplied by the pancreatico-duodenalis superior. The superior mesenteric is, therefore, distributed to the cæcum, ascending and transverse portions of the colon, and the small intestine, and is, to all intents, a “terminal” artery, since the territory supplied by it is so great, and the anastomosis, that takes place between it and the branches of the hepatic, inferior mesenteric, lumbar, ilio-lumbar, etc., is so insignificant, that, when an embolus does lodge in the vessel, it shuts off the circulation from nearly the whole of the intestines, with the result that, among other symptoms, there is intense pain. This pain, like that of intestinal obstruction, is referred to the region of the umbilicus. Static or moist gangrene may take place in the territory from which the arterial blood supply is shut off by the embolus. This is dependent on the back-flow from the veins. When an embolus lodges in the *inferior mesenteric vessel*, conditions similar to the above may result.

Ligation of the abdominal aorta.—The aorta may be ligated from in front by means of a median incision, half above, and half below the umbilicus, or, it may be approached from behind, through a curved incision reaching from the tenth rib to a point one inch internal to the anterior iliac spine. When the latter incision is employed, the abdominal muscles and the transversalis fascia

are divided, the peritoneum is stripped from the iliac fascia and the common iliac artery is identified, and, on following this vessel upwards, the aorta is felt pulsating. This vessel should be well bared before ligating it, so as to avoid the sympathetic plexus of nerves that overlies it.

The *inferior vena cava* is a little longer than the aorta, to the right of which it lies, and is formed by the junction of the two common iliacs, which unite on the right side of the intervertebral substance between the fourth and fifth lumbar vertebræ. Below, this vein is on a plane posterior to the artery, but above, it is separated from this vessel by the right crus, and, near the diaphragm, lies anterior to it.

Contents of the Abdominal Regions.—The division of the abdomen into nine regions by means of two vertical and two horizontal planes has already been considered, but, in place of naming the different viscera in each region, we prefer to illustrate their relative situations from a pathological standpoint, as follows:—

A TUMOR SITUATED IN THE RIGHT HYPOCHONDRIAC REGION
MAY BE :

- A dilated gall-bladder.
- A tongue-like projection of the right lobe of the liver.
- A movable or diseased kidney.
- Fœcal impaction in the hepatic flexure of the colon.

IN THE EPIGASTRIC REGION IT MAY BE :

- A dilated gall-bladder (the vertical plane cuts this structure).
- A tumor involving the caudate, quadrate, Spigelian or the left lobe of the liver.
- A carcinoma or cyst of the pancreas.
- A carcinoma of the middle or pyloric end of the stomach, or of the first, second, or the end of the third portions of the duodenum.

Fœcal impaction in the transverse colon.

A renal or suprarenal tumor.

An aneurism of the abdominal aorta, or cæliac axis, or superior mesenteric artery.

IN THE LEFT HYPOCHONDRIAC REGION, THE TUMOR
MAY BE :

An enlarged spleen.

A cyst of the tail of the pancreas.

A renal tumor or a movable kidney.

Malignant disease of the cardiac end of the stomach.

Fœcal impaction of the splenic flexure of colon.

A tongue-like projection of the left lobe of the liver.

IN THE RIGHT LUMBAR :

Movable kidney or hydronephrosis, etc.

Carcinoma, or fœcal impaction in the ascending colon.

Obstruction, etc., of the small intestine.

UMBILICAL REGION :

Renal tumor.

A calculus or a carcinoma of the ureter.

Fœcal impaction in the transverse colon.

Tumor of the omentum.

Cyst of the mesentery.

Aneurism of the aorta or inferior mesenteric artery.

An enlarged lymphatic lumbar gland.

Obstruction, etc., of the small intestine.

Umbilical hernia, hernia into the fossa duodeno-jejunalis.

Carcinoma of the transverse part of the duodenum.

LEFT LUMBAR :

Renal tumor, etc.

Movable kidney.

Obstruction, etc., of the small intestine.

Fœcal impaction or carcinoma of the descending colon.

RIGHT INGUINAL :

Carcinoma or intussusception involving the cæcum or ileum.

Inguinal hernia.

Appendicæcal tumor.

HYPOGASTRIC :

Obstruction, etc., of small intestine.

Volvulus, etc., of sigmoid.

A distended bladder.

Distended ureter from impaction of a calculus at its entrance into the bladder.

A pregnant or enlarged uterus.

A tumor of the ovary or one associated with a Fallo-
pian tube.

LEFT INGUINAL :

Obstruction of small intestine.

Volvulus, etc., of sigmoid flexure.

Inguinal hernia.

The *peritoneum* has been considered when dealing with the serous coverings and peritoneal attachments of the different viscera, and, for operative work in peritonitis the incision is generally made in the median line immediately above the pubes.

CHAPTER XXVIII.

THE PELVIS.

THE BLADDER.	SIGMOID FLEXURE
Suprapubic Lithotomy.	AND RECTUM.
THE UTERUS, OVARY, ETC.	Excision of Rectum.
Operations on	
Structures felt per	
Vaginam.	

The pelvis as a whole is formed by the ora innominata and is divided into the true and the false pelvis. The false is that portion which is bounded by the expanded ilia, while the true forms a canal with an inlet, a body and outlet. The line for the centre of gravity of the body, in the upright position, passes down through the odontoid process of the axis, then through the points of junction of the curves of the vertebral column, to the sacro-vertebral angle, thence downwards towards the front of the pelvic cavity, so as to bisect a transverse line joining the heads of the two femurs. The weight of the superimposed spinal column is received upon the sacrum and tends to depress that bone, so that its upper end would be forced downwards and forwards, and its lower end backwards and upwards. This rotation backward of the lower end is prevented, however, by the action of the gluteus maximus, the coccygeus, the levator ani and by the resistance offered by the sacro-sciatic ligaments, and the curve of the sacrum is probably the resultant of this downward pressure of the spinal column being opposed by the structures mentioned above. Further, the pressure would separate the innominate bones in front by pulling on the posterior spines through the sacro-iliac ligaments, were it not for the powerful ligaments uniting the bones together at the symphysis.

The inlet of the true pelvis is cordiform in shape, the bloodvessels and nerves for the pelvis being contained in the depression on either side of the prominence of the sacrum. The antero-posterior diameter averages about four inches in the male and four and three-quarters in the female; the transverse is four and a half in the male and five and a quarter in the female; the oblique four and a quarter in the male, and five in the female. The outlet, also cordiform in shape, measures antero-posteriorly (from the tip of the coccyx to the lower border of the symphysis) three and a quarter in the male and five in the female, while the transverse diameter is three and a half in the male and four and three-quarters in the female. The obliquity of the pelvis is such that the inlet, or superior strait, in the upright position, makes an angle with the horizon of 55° and the outlet or inferior strait, one of 10° . The depth of the pelvic cavity in front, *i.e.*, at the symphysis is one and a half inches, whereas, behind, *i.e.*, from sacro-vertebral angle to tip of coccyx it is four and a half inches.

The pelvis contains the termination of the intestinal canal, the bladder with the ureters, the uterus, tubes, ovaries, vagina, coils of small intestine, internal iliac arteries and veins and the sacral plexus of nerves. On viewing the pelvis from above, after the rectum, the bladder (and, in the female, the genital organs have been removed, we see that the sacral plexus is separated from the iliac arteries and veins by the pelvic fascia, and that the outlet of the cavity is protected by the following muscles, *viz.*: Behind, the pyriformis and coccygeus; laterally, the internal obturator, while in the centre of the pelvic outlet is the levator ani. The latter is the chief support of the pelvic contents, being attached, in front, to the symphysis pubis; behind, to the spine of the ischium, and on either

•

side to the white line of pelvic fascia. This muscle arches backwards, in a triangular manner, so that the apex of the triangle is situated at the side and posterior portion of the rectum. The supporting action of the levator ani is seen in the female especially, since, in addition to the rectum, the urethra and the vagina have to be supported by this muscle, the anterior fasciculi serving to draw forwards the lower part of the bowel and thus indirectly act as closures of the vagina, while the posterior fasciculi simply hold the bowel up.

The **Bladder** is divided into a summit, a body, a base and a neck. The *summit* is directed towards the umbilicus when the bladder is distended, and is connected to it by the urachus; the *body* has in front of it, the posterior surface of the symphysis pubis, the triangular ligament and portions of the internal obturator muscles. The posterior surface corresponds to the rectum in the male, and to the uterus in the female, being separated from them by some convolutions of the small intestine. Along the sides of the bladder are the vasa deferentia, which pass in an arched manner, from before backwards, and, crossing the obliterated hypogastric arteries, lie along the inner side of the ureters near their termination in the bladder. The *base* is directed downwards and backwards, and, in the male, rests on the second part of the rectum, from which it is separated, behind, by a reflection of the peritoneum—the recto-vesical fold—and, in front, by the recto-vesical layer of the pelvic fascia. The parts separated by this recto-vesical fascia correspond to the triangle bounded by the vasa deferentia and vesiculæ seminales laterally, and by the reflected fold of peritoneum, mentioned above, posteriorly. The base of the bladder, in the female, rests on the lower part of the cervix uteri and on the anterior wall of the vagina. The *neck* of the bladder

is the commencement of the urethra. The bladder is supported by ligaments formed by the pelvic fascia and the peritoneum, and is composed of three planes of muscular tissue—a longitudinal plane externally, a middle one, of circular fibres, and an internal one, of somewhat longitudinal arrangement. Externally, the muscular wall of the bladder is covered, to some extent, by peritoneum, while, internally, it is in contact with mucous membrane. The mucous membrane is thrown into folds, except that portion, which corresponds to the triangle at the base, above referred to. This portion is called the trigone, and it is almost an equilateral triangle, in shape, the angles being formed by the orifices of the ureters, behind, and by the beginning of the urethra in front, and these angles are about one and a half inches distant from each other. In the region of the trigone, the mucous membrane is paler, smoother and more firmly adherent to the subjacent coat than it is elsewhere in the bladder.

In the infant, at birth, the bladder is an abdominal organ, having been crowded out of the pelvis because of the narrowness of the latter, and has its anterior surface (uncovered by peritoneum), resting against the abdominal parietes. It is situated so high in the abdomen in infancy, that the orifice of the urethra is on a level with the upper border of the symphysis. It then begins to gradually sink until about the ninth year, after which age it remains stationary until puberty, and, after that period, it slowly sinks until it gains the position it normally occupies in the adult. The bladder when empty is either contracted or relaxed. In the former condition it is somewhat dome-shaped, whereas, in the latter, the superior part rests on the inferior part, like one saucer on another. Kelly, who has devoted considerable study to cystoscopic examination of the female bladder, states that the upper portion of the

relaxed bladder rises and sinks, in respiration, as though it were hinged. The peritoneal relations of the bladder have received a great deal of attention since the revival in recent years, of suprapubic lithotomy, and Greig Smith states, that the perusal of most of the results of investigations into the relations of the bladder, convinces one that its topography is the most variable in human anatomy. These investigations were for the purpose of ascertaining the relation that vesical distention bore to the reflection of the peritoneum that passes from the summit of the bladder on to the anterior abdominal wall. The bladder when distended cannot descend in the pelvis because of the resistance offered by the rectum (the uterus and vagina in the female), and the pelvic fascia. It has to rise out of the pelvis, and this it does by insinuating itself between the peritoneum and the posterior surface of the abdominal wall. This space into which the bladder rises, when distended, is termed, the space of Retzius. It contains delicate areolar tissue with numerous veins and is formed by a splitting of the transversalis fascia as it leaves the lower margin of the posterior or incomplete sheath of the rectus muscle. The manner in which this splitting occurs is as follows: The transversalis fascia passes down from the lower border of the sheath of the rectus and divides into two layers, one going to the summit of the bladder and the other passing over the posterior surface of the lower part of the rectus muscle, and over the posterior surface of the pubic bone, to the prostate gland, so that, a more or less triangular area results for the accommodation of the bladder when distended. When this viscus and the rectum are quite empty, the summit of the former and the reflection of the peritoneum over it are a little below the upper margin of the symphysis pubis. Greig Smith states, that, when in an adult male, the bladder is distended with fifteen or twenty ounces of fluid, the peritoneum will

be raised one inch, at least, above the pubic margin, and, probably, two inches. He believes that rectal distention has very little, if any, influence in raising the fold of peritoneum, since, he says, it will flatten out the bladder rather than raise it, though he admits it will elevate the posterior wall, and will be, therefore, of use in the removal of tumors of that wall of the bladder. Strong, of Chicago, states that an average of fourteen ounces in the rectum and twelve in the bladder raised the peritoneal fold about one and a half inches. In all probability the rectal bag has very little influence in raising the peritoneal reflection directly, although, it may do so, indirectly, by elevating the base of the bladder and thus providing a support on which the fundus of the distended organ may rest.

Landmarks.—The *neck, i.e.,* the internal urinary meatus, in the adult, lies about three-quarters of an inch behind, and opposite some point (variable) of the upper half of the symphysis pubis, and is situated two, or two and a half inches above the perineum.

Operations.—Lateral lithotomy will be considered when discussing the perineum. In *suprapubic lithotomy*, the bladder is opened above the pubes but below the fold of peritoneum that is reflected from the summit of the bladder to the anterior abdominal wall. If the rectal bag be used, it should contain, for an adult, about ten ounces of fluid, and for a child of five years of age, about two and a half ounces. The bladder itself should be distended with about ten to twelve ounces for the adult, or three ounces for a child five years old. Greig Smith does not recommend any particular amount of fluid to be employed for distending either the bladder or the rectum. He uses an irrigator, the tube of which is attached to a catheter for the bladder, or to a child's toy balloon for the rectum. This irrigator should be raised above the level of the pa-

tient, about four feet for an adult and three feet for a child. A serious objection to the employment of any fixed amount of fluid for the purpose of distending the bladder, is that, while most of the vesical fibres, when calculi are present, are hypertrophied, yet there may be some portions of the wall so thin that rupture might result if certain definite amounts of fluid were uniformly used for the purpose of distention. By the method of Greig Smith, there is sufficient pressure put on the vesical walls to distend, but not enough to rupture the bladder. An incision about three inches in length is made in the median line, above the pubes, and the skin, superficial and deep fasciæ are divided, the recti muscles are separated from each other, the transversalis fascia is incised and the areolar tissue, contained in the prevesical or Retzian space, is exposed. The peritoneum forming the roof of the space is avoided, raising it up with the finger, if necessary, and the connective tissue that occupies the space is divided so as to expose the anterior wall of the bladder. By keeping exactly in the median line while incising the prevesical fascia there is very little danger of wounding either of the large veins of this space, since these veins, two in number, lie, one on either side of the middle line of the bladder and about three-quarters of an inch apart. It is advisable in opening up the prevesical fascia to start the incision close to the symphysis and to cautiously enlarge it from below upwards. The bladder wall will be recognized by its pinkish color, rounded outline and muscular structure, and will be steadied by means of a hook while it is being opened by the surgeon. The stone is extracted and the operator sutures the vesical wall or not, as he sees fit.

The **Uterus**.—The *uterus* is pyriform in shape, is flattened from before backwards, and is divided into two

parts, a fundus or body and a cervix, by a constriction—the isthmus. This isthmus is a weak part, since, it is here that flexions usually occur. In the virgin the isthmus is midway between the cervix and the fundus, whereas, in women who have borne children, it is near the junction of the lower and middle thirds of the organ. The anterior surface of the uterus is almost flat and is covered by peritoneum, which is reflected on to the bladder at the level of the isthmus. The posterior surface is convex and is entirely covered by peritoneum, while the lateral borders have attached to them the broad ligaments formed of peritoneum. In the nullipara, the uterus averages about three inches in length and about one and a half inches in width, but in women who have borne children it is about one-fifth larger. Its direction coincides with the long axis of the body, although it may be inclined forwards 15° or 20° when the bladder is empty, or displaced to the right when the rectum is full. The cavity of the body is triangular in shape and communicates with the Fallopian tubes, at each superior angle, and with the cavity of the neck, below. The latter cavity *i.e.*, of the neck, terminates in the os internum above and in the os externum below, and presents a median ridge on each wall, which, with lateral branches, constitute the arbor vitæ. *Structure.*—The uterus is formed by three layers of muscular tissue, *viz.*, the external longitudinal, the middle circular, and the internal longitudinal, while the mucous membrane is pale, smooth and is pierced by innumerable tubular glands, and is lined with ciliated epithelium, the motion of which is directed from within outwards. The *broad ligament* is composed of peritoneum which is hung, as it were, over a cord—the Fallopian tube—and reaches from the sides of the pelvis to the cornu of the uterus. This arrangement of the peritoneum, *i.e.*, the broad ligament, forms a parti-

tion dividing this portion of the pelvic cavity into two parts, and presents two surfaces, an anterior and a posterior, and four borders, viz., a superior, which contains the Fallopian tube; an inferior, where the lower portions of the two surfaces, which are here more widely separated than above, rest on the levator ani muscle and on the rectovesical fascia; an internal border, where the ligament is attached to the side of the uterus, and an external one, where it is attached to the obturator fascia on the side of the pelvis. The structures lying between the two layers of the broad ligament are: (1) The ovary and its ligament; (2) the Fallopian tube; (3) the round ligament; (4) foetal relics, viz., the parovarium (twelve to twenty effete tubules of the Wolffian body); the duct of Gartner and the hydatid of Morgagni; (5) the uterine, ovarian and funicular vessels and the uterine plexus of nerves; (6) loose cellular tissue, a continuation of the subperitoneal pelvic tissue; (7) involuntary muscular tissue that supports the uterus and passes to it from the pelvic wall.

The **Ovary**, one and a half inches in length, by half an inch in thickness, projects from the posterior surface of the broad ligament. To understand its position with reference to the broad ligament, imagine that it had been inserted from below upwards, between the layers of the ligament, and, that on arriving near its upper border, it had been pushed backwards in such a manner that its surfaces were covered with the posterior layer of the peritoneum forming the ligament, and that these surfaces were superior and inferior. The posterior border is, therefore, free in the pelvic cavity, while the anterior is attached to the subserous tissue of the broad ligament and gives entrance to the blood vessels, nerves, etc., at the hilum. The ovary is attached to the uterus by the utero-ovarian ligament, while its outer end receives the *fimbria ovarica* of the Fallopian tube.

The **Fallopian** Tube, about four and a half inches in length, is narrow where it is attached to the uterus, but trumpet-shaped, externally, and surrounded, at this end, by fringes termed *fimbriæ*. This fimbriated end has a diameter of about one-third of an inch, and the opening in its middle is termed the *ostium abdominale* and is about one-twentieth of an inch in diameter. The Fallopian tube has four coats—serous, cellular, muscular (circular and longitudinal), and mucous, the latter being plicated and covered with ciliated epithelium, the motion of which is directed towards the uterus.

The **Vagina** extends from the vestibule, below, to the vault, above, in which is received the cervix of the uterus, and is directed upwards and slightly backwards so as to form an angle of ten or fifteen degrees with the long axis of the body. The two walls of the vagina are of unequal length, the anterior being about two and a half inches, and the posterior about three and a half inches in length.

Relations.—In front are the bladder and the urethra, separated from the vagina by loose areolar tissue. This separation does not extend farther downwards than the upper third of the urethra since the lower two-thirds of this structure is intimately adherent to the anterior surface of the vagina. Behind, is the rectum, separated from it, above, by the reflection of peritoneum which lies between the rectum and the posterior wall of the vagina for the distance of about one inch, and which forms the pouch of Douglas; while the middle of the posterior wall is separated from the rectum by connective tissue, and the lower part by the perineal body. In the latter situation, *i.e.*, in the neighborhood of the perineal body, the vagina and rectum diverge, so that, in a sagittal section, the perineal body is seen to be triangular in shape. Laterally,

the vagina is in contact with the tissue that occupies the lower part of the broad ligament, and has the vaginal branch of the uterine artery with a venous plexus, on either side, while the ureter crosses the upper part of the lateral wall to reach the bladder, which lies in front of the vagina. The lower end of the vagina pierces the triangular ligament, and, hence, it is here that resistance to dilatation is greatest.

Bloodvessels of these Structures.—The *uterine artery* from the internal iliac passes horizontally through the broad ligament towards the cervix uteri, and, when near the latter, crosses the ureter, above which it lies, along with its two accompanying veins. This artery gives branches to the vagina, and, ascending in a tortuous manner about one-twelfth or one-eighth of an inch from the uterus, furnishes to the internal os a large artery, and terminates near the cornu of the uterus by anastomosing with a branch of the ovarian artery. The *ovarian* from the aorta enters the broad ligament through the infundibulo-pelvic ligament, *i.e.*, the suspensory ligament of the ovary, and, after supplying the ovary, it then enters the utero-ovarian ligament and passes through its substance to reach the side of the uterus, where it anastomoses with the uterine and the funicular arteries. The *funicular*, a branch of the superior vesical, ascends along the round ligament to the cornu uteri where it anastomoses with the uterine and the ovarian. The *ovarian veins* empty as follows: Those on the right side, into the vena cava at an acute angle, and those on the left side, into the left renal vein at a right angle. The *lymphatics* of the uterus and its appendages form a network as delicate as the finest lace and terminate as follows: Those from the body of the uterus pass up along the suspensory ligament of the ovary to the lumbar glands, or down the round ligament to the deep inguinal

glands. Those for the lower part of the cervix and the upper part of the vagina enter glands on the pelvic floor and accompany the uterine and iliac vessels to the glands along the common iliac arteries, while those for the lowest part of the vagina and external genitals communicate with the superficial and the deep inguinal glands. *Nerves.*—The nerves of the uterus are derived from the third and fourth sacral, the hypogastric plexus of the sympathetic and the renal plexus, which, latter, supplies the ovaries and the Fallopian tubes as well. The vagina is supplied by the fourth sacral, the hypogastric plexus and the pudic nerve.

Operations.—To *locate* the ovaries in *salpingo-öorphorectomy*, or removal of the tubes and ovaries, after the abdomen has been opened, the index and middle fingers are conducted along the under surface of the abdominal wall to the symphysis, thence over the bladder to the uterus, then outwards, over the cornu uteri to the broad ligament, behind which the tube and the ovary are, as a rule, readily found. The best way to pick up these structures is to carry the fingers to the outer extremity of the broad ligament, and then, turning the palmar surfaces astride the broad ligament towards the uterus, to hook up both tube and ovary together. *Ligation of the pedicle.*—The uterine and ovarian vessels must be tied separately while the non-vascular portion of the broad ligament between them is left free. The *clear space* in the broad ligament is a triangular surface near its upper and outer extremity and is free from vessels, being bounded above by the ovarian vessels, below and on the inner side, by the round ligament, while on the outer side is the pelvic wall. The first ligature includes the ovarian artery and veins, and is passed through the clear space of the broad ligament and tied near the pelvic brim over the top of the in-

fundibulo-pelvic ligament well beyond the fimbriated extremity of the tube. A second ligature is applied to the utero-ovarian ligament (the ovarian artery runs towards the uterus in this ligament), while a third ligature is tied over the top of the broad ligament at the cornu uteri, including, therefore, the uterine vessels as well as the Fallopian tube. After ligating as above, the ovary and the tube are excised and removed.

In *abdominal hysterectomy*, Kelly advises the ligation of the uterine arteries, after splitting the broad ligament and separating the cellular tissue of the ligament by blunt dissection until the pelvic floor is reached where the artery may be felt pulsating and where it can be ligated. The reason for ligating the artery in this situation is that, near the cervix, it lies almost immediately above and at right angles to the ureter, and, besides, in the neighborhood of the cervix, there are two large uterine veins along with a large vaginal vein which are in close association with it.

Pelvic Suppuration is dependent on the presence of pus-producing organisms. These may find their way up through the vagina into the uterus, and thence through the ostium abdominale into the pelvic cavity. An example of suppuration, caused by organisms following this route, is that due to the presence of gonococci. Another route, whereby suppurative processes may invade the system, is that seen where, after a confinement or an abortion, etc., a metritis is developed, followed by a parametritis and then by a pelvic cellulitis. If the case does not improve and is not a suitable one for treatment by massage, etc., and if pus develop, then it must be evacuated, and this should be attempted by vaginal puncture, rather than by abdominal incision. If the pus be not evacuated artificially, it may find an outlet naturally by breaking into the rectum, the vagina, the bladder or the abdominal wall,

and, in the case of the two last situations, the cavity rarely heals, since the opening lies, generally, at a higher level than the bottom of the abscess cavity. *Vaginal puncture* is performed by means of a pair of long, sharp-pointed scissors which have been introduced, guarded by the index finger, to the situation in which it is intended to puncture the abscess. This latter point should be posterior to the cervix and in the median line, or immediately to the right, or left, of the median line, since, if the scissors were introduced at the side of the vagina there would be a danger of wounding the uterine artery or veins. The scissors should be made to point, *i.e.*, should be directed towards the promontory of the sacrum, otherwise, there would be danger of wounding the rectum if the puncture were made directly backwards.

Structures felt per Vaginam.—Posteriorly the rectum can be felt and easily moved from side to side, or, the presence of fœcal masses may be ascertained. Anteriorly, the base of the bladder and the urethra may be recognized, while, antero-laterally, the ureters passing along the side of the vagina near the cervix can be identified. The situation of the knob-like cervix and of the fundus of the uterus, may be recognized, and any departure from the normal position, such as ante-flexion or retroposition may be appreciated, especially if the finger in the vagina be assisted by the other hand, externally, on the abdomen, *i.e.*, if the combined or bimanual method of examination be employed. By means of the finger in the vagina the examiner may inform himself as to the condition of the tubes and ovaries as well as the presence and extent of adhesions affecting the uterus. The *landmark* for the *ovary* is a point about two inches from and a little below the level of the anterior iliac spine, and, bimanually, it may be felt in the manner described by Kelly, *viz.*, by means of one fin-

ger carried up into the lateral fornix, posterior to the cervix, and then pushing out towards the lateral wall of the pelvis while deep pressure is made, with the other hand, through the corresponding semi-lunar line. The ovary feels like a firm body about as big as the end of the thumb and is freely movable in all directions.

The Fallopian tubes are not, normally, readily felt, but, when diseased, they may be rolled, cord-like, by the finger, behind the ovary and the uterus.

The Sigmoid Flexure and the Rectum.—

The latter was formerly divided into three portions but it is better to include the first portion with the sigmoid flexure, which, Omega-shaped, and about seventeen and a half inches in length, begins where the descending colon ends, viz., on the outer side of the psoas magnus muscle, in the iliac fossa. The sigmoid, after crossing the psoas magnus muscle at right angles, and about midway between the promontory of the sacrum and Poupart's ligament, terminates where the original second part of the rectum began, viz., opposite the third sacral vertebra. The most of the sigmoid flexure is contained in the pelvis and lies more or less in contact with the bladder and uterus. Its meso-colon is from one and a half to three and a half inches wide, *i.e.*, from posterior wall to bowel, and the line of its attachment to the former, as seen when the sigmoid is removed, runs across the psoas muscle to the point of bifurcation of the iliac artery, and thence, with a slight curve, reaches the middle line of the body opposite the third sacral vertebra.

The **Rectum** extends from the third sacral vertebra to the anus, the first portion reaching from the third sacral vertebra to the tip of the coccyx, and the second portion from this point, to the anus. The first portion, about three and a half inches in length, is covered by peritoneum

on the upper part of its anterior surface only, and from this surface it is reflected on to the bladder in the male, and to the vagina in the female.

Relations.—*Behind*, this portion of the rectum is in relation with the sacrum and coccyx, being separated from them by connective tissue, chiefly, while, in front, it is in relation with, in the male, the triangular surface of the bladder, bounded by the vesiculæ seminales laterally, and by the prostate gland in front. In the female, the anterior surface is in relation with the vagina and with the cervix uteri. This portion of the rectum follows the curve of the sacrum, and is, therefore, directed downwards and forwards; whereas, the second portion, which extends from the tip of the coccyx to the anus, is about one and a half inches in length and is directed downwards and backwards. The second portion is surrounded by the internal sphincter muscle and has the levator ani muscle attached to it on either side. At its termination in the anus the external sphincter encircles it. *Bloodvessels.*—The rectum is supplied by the superior hemorrhoidal from the inferior mesenteric, by the middle hemorrhoidal from the internal iliac, and by the inferior hemorrhoidal from the internal pudic. The superior hemorrhoidal descends in the sigmoid meso-colon and bifurcates, giving a branch to either side of the bowel. These break up, about five inches from the anus, into three or four branches, which anastomose with branches of the middle hemorrhoidal, and then send smaller vessels, which pierce the muscular coat of the bowel, about two inches lower down, and run downwards towards the anus, between that coat and the mucous membrane, lying parallel to one another. The veins pursue a course somewhat similar to the artery; some, especially those corresponding to the middle and inferior hemorrhoidal arteries, going to the internal

iliac vein, while others—the superior hemorrhoidal—go to the portal system. The nerves are derived from the superior and inferior hypogastric plexuses (sympathetic), with, in addition, branches from the fourth sacral nerve that ramify in the lower part of the rectum. The lower part of the rectum and its affections will be considered, along with the reflexes of the pelvic viscera, when dealing with the perineum, so that at present it will suffice to describe, briefly, **excision** of the upper part of the rectum for carcinoma. When it is found necessary to remove this portion, Kraske's method, or some modification of it, is followed so as to permit freer access to the bowel. In these operations a portion, or the whole of the lower part of the sacrum, below the third sacral foramen, is removed. The bone should not be divided above this point, since there would be danger of permanent paralysis of the bladder resulting. The incision begins about two inches to the left of the middle of the sacrum, and is then directed towards the median line, on reaching which it is extended along the fold between the buttocks towards the anus. The soft parts are turned back from the bone, the sacro-sciatic ligaments divided, and a periosteal elevator, passed beneath the sacrum, separates the soft parts from its anterior surface (Kelsey). The bone is then divided at the level selected. The rectum is identified after incising the connective tissue between it and the sacrum, and the finger is worked around the bowel, keeping a little distance from the muscular wall to avoid branches of the superior hemorrhoidal artery, for, if these be severed, the nutrition of the lower part of the proximal end will be seriously interfered with. The diseased portion is removed after opening up the peritoneal cavity. The peritoneum is sutured and the proximal portion of the rectum is brought down to the anus and attached there, or sutured to any part of the distal portion that may have been left.

CHAPTER XXIX.

THE PERINEUM.

ANATOMY	EXTRAVASATION OF URINE
PELVIC FASCIÆ	RECTAL EXAMINATION
URETHRA, SCROTUM, &c.	DISEASES and REFLEX DIS-
LANDMARKS	TURBANCES
	OPERATIONS

The **Perineum**—The anatomy of this region will be very briefly referred to. The perineum is divided, by an imaginary line joining the two ischial tuberosities, into two parts, an anterior—the urethral triangle, and a posterior—the anal. Examining this anterior triangle, we find, after removing the integument, that the superficial fascia is divisible into two layers, a superficial, continuous with the superficial fascia of the body, and a deep—the fascia of Colles, which is triangular in shape and passes behind the transversus perinei to be attached to the posterior border or base of the triangular ligament. These two layers of fascia are continuous with the dartos of the scrotum, but laterally, the deeper layer blends with the rami of the pubes and ischium. Beneath this deep layer of the superficial fascia, in the anterior triangle, there is a space, the floor of which is formed by the anterior layer of the triangular ligament, and which contains the bulb of the corpus spongiosum and the corresponding part of the urethra, the ends of Cowper's ducts, the crura of the penis, muscles, viz., the accelerator urinæ, erector penis and transversus perinei, the superficial and transverse perineal vessels and the superficial perineal nerves, the artery of the corpus cavernosum and the dorsal artery,

vein and nerve of the penis. The triangular ligament which forms the floor of this space is composed of two planes, a superficial and a deep, united to each other, behind, near the transversus perinei but separated, in front, where they are attached to the subpubic ligament. Laterally, they are attached to the rami of the pubes and ischium. The space between the two layers contains the membranous part of the urethra and the compressor urethræ muscle, Cowper's glands and ducts, the dorsal nerves of the penis along with the internal pudic, the bulbar and the cavernosal arteries and veins. On removal of the deep layer of this triangular ligament, the prostate gland is exposed, with its apex touching this layer of the ligament and its base situated posteriorly and connected with the muscular wall of the bladder. This gland is surrounded by a fibrous capsule derived from the rectovesical portion of the pelvic fascia, and has in front of it the pubo-prostatic ligament and the vesico-prostatic plexus of veins, while its posterior surface rests on the rectum, but is separated from it by some unstriped muscular tissue and connective tissue.

The *anal triangle*.—In this, there is situated, in the median line, the anus with the corrugator cutis ani muscle puckering up the integument, and the external sphincter, which, lying immediately beneath the skin and extending from the tip of the coccyx behind, to the central tendon of the perineum, tightly closes the anus. On either side of the anus, between it, internally, and the ischial tuberosities, externally, are the superficial tissues forming the base of the ischio-rectal fossa. This fossa is a cuneiform, or wedge-shaped space, with the edge of the wedge directed upwards and received into the angle formed by the separation of the anal fascia from the obturator fascia. Each fossa is bounded in front by the base of the triangular

ligament and transversus perinei muscle; internally, by the obliquely directed levator ani and the coccygeus muscles; externally, by the obturator fascia covering the obturator muscle and by the ischium, and behind these, by the gluteus maximus muscle and the great sacro-sciatic ligament. The ischio-rectal fossa contains areolar tissue with the inferior hemorrhoidal vessels and nerves running obliquely through it, towards the rectum, while superficially, the perineal vessels and nerve run forwards, and posteriorly, the branch from the fourth sacral nerve passes to the external sphincter.

Pelvic Fasciae.—The obturator layer of the pelvic fascia is attached, above, to the pectineal line and passes downwards, covering the obturator muscle. But, at the level of the line joining the spine of the ischium with the back of the symphysis, it is thickened, forming what is known as the *white line* of the pelvic fascia. The lateral portion of the levator ani arises from this white line, and at the line, the obturator fascia splits into three layers, viz., one, that continues the course of the original layer, and, still covering the obturator muscle, forms the outer wall of the ischio-rectal fossa; a second, that is directed downwards towards the anus lying beneath the levator ani muscle, and, therefore, forming the inner wall of the ischio-rectal fossa; while a third passes down towards the median line of the pelvis, above the same muscle, and, since the pelvic viscera and the prostate gland lie above the levator ani muscle, this layer of fascia—the rectovesical—surrounds the prostate gland and the lower parts of these viscera, and thus separates them from each other.

The **Penis** is composed of two corpora cavernosa and the corpus spongiosum, enveloped in a fibrous sheath—the tunica albuginea. The two corpora cavernosa are separated behind where they form the crura, but lie, side

by side, throughout the rest of their extent, except, in front, where they again diverge to accommodate the corpus spongiosum which forms the glans penis. The muscles connected with the penis are: The erector penis, the accelerator urinæ, and the superficial transversus perinei. The erector penis aids in the erection of the penis by compressing the venous circulation; the accelerator urinæ assists in ejaculation of the semen, while the transversus perinei acts as an accessory to the accelerator by fixing the raphe from which the fibres of the latter arise. The nerves of the penis are derived from the sympathetic and from the internal pudic.

The **Urethra**, about six and a half inches in length, is divided into a prostatic portion, a membranous portion which lies between the two layers of the deep or triangular ligament, and a spongy portion. The shape of the urethra in the different parts of its course is, in the relaxed condition, as follows: At the meatus urinarius, a vertical slit, a little farther back, T-shaped because of the presence of the lacuna magna in the dorsal wall—still farther back, *i.e.*, in the spongy portion, it forms a transverse slit, while in the membranous it is stellate, and in the prostate, resembles an inverted U.

The **Scrotum**.—The integument of the scrotum is thin and presents a median raphe showing the line of union of its two halves. Beneath the skin are the following layers: (1) The dartos, containing yellow elastic tissue and unstripped muscular fibres. This layer is continuous with the superficial fascia of the abdomen and of the perineum. (2) The external spermatic fascia which is continuous with the intercolumnar fascia. (3) The cremasteric fascia. (4) The internal spermatic fascia—the projection downwards of the infundibuliform process of the transversalis fascia. (5) The tunica vaginalis, the un-

obliterated portion of the vaginal process of peritoneum that had been carried down in connection with the descent of the testicle.

The **Testicle** is suspended in the scrotum, has a fibrous sheath surrounding it—the tunica albuginea—and is covered, in front, and on the sides, by the tunica vaginalis. The tubuli seminiferi converge to form the rete testis, which end in the head of the epididymis to be continued into the body and the globus minor and thence into the vas deferens. The testicle is supplied by the spermatic plexus of nerves and by branches from the hypogastric plexus, which pass down to the testicle along the artery of the vas deferens. The *spermatic cord* which supports the testicle is composed from before backwards of: (1) The cremaster muscle; (2) the cremasteric vessels (deep epigastric); (3) behind these are the spermatic artery (aorta) and veins (pampiniform plexus), lymphatics and connective tissue; (4) the vas deferens with its artery (superior vesical).

Landmarks for the *Perineum* in the male.—The bony prominences felt in the perineum are, anteriorly, the pubic arch; posteriorly, the tip of the coccyx; laterally, the rami of the pubes and ischium and the tuberosities of the ischium. *Central tendon*.—The transversus perinei, the accelerator urinæ, the sphincter ani, a few fibres of the levator ani and the middle of the posterior border of the triangular ligament meet at a point in the central raphe, midway between the centre of the anus and the junction of the scrotum with the perineum, *i.e.*, about one and a half inches in front of the centre of the anus.

The artery of the bulb runs just in front (about one-half of an inch) of a line drawn from the anterior part of the ischial tuberosities to the central point of the perineum. The *white line of the anus* marks the junction of

the skin and mucous membrane and corresponds to where the external and internal sphincter muscles meet.

The *anus* is in the middle line of the anal triangle, about one and a half inches in front of the tip of the coccyx. In the *median raphe* no vessels cross, hence this is the line of safety of the perineum, and, when practicable, incisions are made in this line. The *ischio-rectal fossa* measures, from before, backwards, two inches. Its width, from the ischial tuberosity to the anus, is one inch while its depth is about two or three inches, the greatest depth being near the ischium. The *transversus perinei artery* runs from a point at the anterior extremity of the ischial tuberosity to the central point of the perineum. (The *internal pudic* vessel and nerve lie on the outer side of the fossa in a sheath of the obturator fascia (Alcock's canal), and are situated about one and a half inches above the lower border of the tuberosity of the ischium, while the inferior hemorrhoidal vessels are directed obliquely from the posterior part of the ischial tuberosity to the anus.)

The *triangular ligament* measures about one and a half inches from its apex at the subpubic arch, to its base at the central tendinous point. It is perforated by the urethra at a distance of about one inch from the pubes, while the dorsal vein of the penis and the subpubic ligament are situated between the opening for the urethra and the under margin of the pubic arch. The *urethra* measures about one and a quarter inches in the prostatic portion, and is also widest in this situation. The membranous portion is the narrowest, the shortest, and the least dilatable part of the canal, and measures about one-half or three-quarters of an inch in length; its anterior wall being slightly longer than its posterior wall. The bulbous portion is about one and a half inches in length, while the

rest of the spongy portion is about three or three and a half inches long. The *prostate* gland measures about one inch in length, one and a half inches in breadth, and its base is situated a little above the level of the middle of the symphysis, while its apex rests on the deep triangular ligament and is about one and a half inches behind and below the subpubic angle.

In the *female*, the labia majora correspond to the scrotum in the male and are about three inches in length, meeting, above, at the mons Veneris, and, below, at the fourchette, about one inch in front of the anus. The clitoris corresponds to the penis. The vestibule is a shallow passage leading to the vagina, while, embracing it by two folds are the labia minora which terminate, posteriorly, opposite the middle of the vaginal opening. The glands of Bartholini correspond to Cowper's glands in the male and are situated, on either side, behind the bulb of the vestibule, while their ducts, about three-quarters of an inch in length, open opposite the middle of the vaginal orifice. The urethra, about one and a quarter inches in length, is directed upwards and backwards to open into the bladder about three-quarters of an inch behind the middle of the symphysis, and has, in front of it, and at the sides, a venous plexus (Santorini). The urethra is sufficiently dilatable as to permit the gradual introduction of the finger. The lymphatics of the external genitals empty into the inguinal glands, whereas, in the neighborhood of the vaginal orifice, there is a neutral territory at which the vaginal and the vulvar lymphatics communicate. The lymphatics of the perineum terminate in the horizontal set of the inguinal glands.

Extravasation of Urine.—When the membranous part of the urethra is ruptured, and urine is extravasated, it will be contained between the super-

ficial and the deep layers of the deep triangular ligament. If pus form it may burrow along, or among the fibres of the levator ani down to the ischio-rectal fossa, or since the deep layer of the ligament is formed by a portion of the pelvic fascia, it may spread into the pelvis along this fascia. Should, however, the urethra be ruptured at the junction of the membranous with the bulbous portion, then the urine is contained between the triangular ligament and the deep layer of the superficial fascia. It cannot pass backwards because of the junction of these two structures immediately behind the transversus perinei muscle. It cannot enter the pelvis because of the obstruction offered by the triangular ligament, nor can it extend laterally into the inner aspects of the thigh, since both the floor and the roof of the space are attached to the rami of the pubes and ischium, so that, the only course available, is for it to pass forwards, and this it does readily, because of the fact that the roof, *i.e.*, the deep layer of the superficial fascia is continuous with the dartos of the scrotum. The urine, therefore, infiltrates the tissues of the scrotum beneath the dartos and then extends on to the abdomen, beneath the deep layer of the superficial fascia, which is continuous with the dartos, and, since the deep layer of the superficial fascia of the abdomen is adherent at both the median line and immediately below Poupart's ligament, to the deep fascia, it follows that the only channel, whereby the urine or pus can reach the abdomen, is the space between the pubic spine and the symphysis.

Rectal Examination in the *Male*.—On inserting the finger into the rectum the opposition offered to it by the external sphincter will be at once noticed. Immediately above this, for the distance of about one inch, the action of the internal sphincter will be manifest. A little over one inch from the anus the lateral edges of the levator ani

can be felt, while about half an inch above the internal sphincter, *i.e.*, from one and a half to two inches above the anus, the prostate gland, about the size of a horse chestnut, can be readily identified. Immediately behind this gland the soft elastic feel of the bladder is evident and the portion that can be felt is the triangular interval, that is bounded, on either side, by the vesiculæ seminales. These vesiculæ seminales extend backwards and outwards, for about two inches, and are about half an inch in thickness. Immediately in front of the apex of the prostate gland, *i.e.*, about one inch above the anus, the membranous part of the urethra, especially if distended with a catheter, or a sound, will be recognized. Posteriorly, the curve of the sacrum and coccyx, and, laterally, the roots of the sacral nerves and the internal iliac vessels may be felt. In the *female*, the uterus can be mapped out, while, on bimanual examination, displacements, especially retro-flexion, will be evident; and, further, any sensitiveness of the ovaries may be elicited, if the hand on the abdomen be pressed down in the semilunar line, about two inches from the iliac spine, as in the examination per vaginam.

As a guide to the situation of the ovary, when examining per rectum, the utero-ovarian ligament may be employed. This is felt as a prominent fold on the posterior surface of the broad ligament just below the cornu uteri and by following this fold outwards for about an inch, the inner border of the ovary may be felt, while the tube above it may be identified and any abnormality of the vagina, in front of the rectum, recognized.

Diseases and Reflex Disturbances of the pelvic viscera.—*Hemorrhoids* may be either external, or internal. In the external variety, the radicles of the inferior hemorrhoidal veins are dilated, whereas, in internal hemorrhoids, the middle and superior hemor-

rhoidal veins are the vessels affected. These two sets of venous radicles, *i.e.*, the inferior hemorrhoidal on the one hand, and the superior and middle on the other, communicate just within the anal margin, and this connection between the portal and caval systems affords an outlet for the rectal vessels that are distended from obstruction of the portal vein. Hence, in "piles," it is advisable to bear in mind the fact that instead of being a purely local affair, the venous distention may be symptomatic of disease of the liver, or of the portal vein itself, whereby resistance is offered to the circulation through the portal channels. Should tenesmus be a symptom of the presence of "piles," it is dependent on the irritation of the sensory nerves of the lower part of the rectum, being referred, through a centre in the lumbar region of the spinal cord, to the plexus mesentericus of the intestine, and causing peristalsis, while at the same time, reflex stimulation of the sphincters causes their contraction.

Fissure in Ano.—In this condition a tear is present in the muco-cutaneous margin of the anus, and hence, the distention of the orifice, that, normally, occurs during the act of defœcation, irritates filaments of the inferior hemorrhoidal nerve that may be exposed in the base of the fissure, with the result, that the reflex act, which, normally, contracts the sphincter for some time after a stool, becomes converted into the pathological condition of persistent contraction. This is probably due to the irritation of the exposed nerve being transferred through the lumbar centre to the branch of the fourth sacral supplying motion to the sphincter ani muscle, and since this spastic condition of the sphincter muscles still further irritates the exposed nerve, it follows, that pain may persist, oftentimes for hours, after the act of defœcation. Again, the effects of this irritation of

the inferior hemorrhoidal nerve are not limited to the sphincter ani muscle, since the inferior hemorrhoidal is a branch of the pudic, and the pudic is derived from the third and fourth sacral nerves, and, since these nerves send branches to the viscera of the pelvis to communicate with the sympathetic system, it follows, that irritation of the inferior hemorrhoidal nerves may be transferred to the bladder and induce vesical tenesmus, or retention of urine; as seen after operations on the anus, or, it may be transferred to the penis, through the pudic itself, thus causing pain in the integument of the penis, or priapism, or neuralgia of the urethra. The pain that is sometimes felt down the inner and back parts of the thigh, or, in the perineum, from affections of the anus, rectum, prostate or bladder, depends on the fact that, while the third and fourth sacral nerves give branches, as above mentioned, to the pelvic viscera, the third helps to form the sciatic, and the fourth forms the pudic, hence, in inflammatory affections of these organs the pain may be referred to the distribution of the sciatic, *i.e.*, to the inner and back parts of the leg, or to that of the pudic, *i.e.*, the perineum and penis. In ischio-rectal abscess, reflex disturbances affecting the bladder and rectum may follow similar paths, and in this disease, the inferior pudendal, a branch of the small sciatic, is especially involved, so that the pain is readily reflected to the other branches of this nerve in the leg.

Stone in the bladder may cause retraction of the testicle, or erection of the penis, or pain, felt in the penis, or at its end. In the first case, *i.e.*, when retraction of the testicle is present, the stone generally rests on the trigone, which is richly supplied with branches from the inferior hypogastric plexus, but this plexus sends branches to the vas deferens, which communicate with the spermatic plexus. Hence, irritation of these plexuses, surround-

ing the vas deferens, may cause reflex contraction of the cremaster muscle through stimulation of the genito-crural which supplies this muscle, so that retraction of the testicle would result. Where the pain is felt in the penis, it is due to projection, or reference of the irritation from that portion of the hypogastric plexus which supplies the bladder, *i.e.*, the vesical plexus, to the cavernous plexus or nerve, which is distributed to the penis.

Stricture of the urethra may cause priapism from the fact that the urethra itself as well as the muscles of the penis are all supplied by the same nerve, *viz.*, by the internal pudic, and hence irritation of the mucous membrane of the urethra may reflexly cause erection of the the penis through stimulation of the erector muscle, since both mucous membrane and muscles are controlled by the one nerve, and for the same reason, the passage of a sound may cause spasmodic stricture, owing to reflex contraction of the compressor urethræ muscle. *Injury to the testicle* may cause shock or collapse, just as a similar injury to the intestine would, since both testicle and intestine receive their nervous supply from the solar plexus—the testicle receiving its supply through the spermatic plexus, an offset from the renal and aortic plexuses, which are derived from the solar plexus. The *ovary* has a somewhat similar nervous connection through the ovarian plexus, with the result, that disease of this organ may cause reflex symptoms through the widespread connection of the solar plexus, already referred to, when dealing with the nervous reflexes of the intestine.

Operations.—*Ischio-rectal abscess* should be opened early, since the blood supply of this region is very poor and suppurative processes rapidly spread and open, either externally, through the skin, or internally, into the rectum, forming what is known as “fistula in ano.” In opening

an ischio-rectal abscess the incision should be made in a longitudinal direction and a little nearer to the ischium than to the rectum so as to avoid wounding the latter.

In *fistulo in ano* the opening in the rectum is, as a rule, within one and a half inches (generally half an inch) from the margin of the anus, because of the slanting position of the levator ani muscle which directs the pus, downwards and inwards, towards the interval between this muscle and the internal sphincter. The fistulous channel may be straight or tortuous, and, should two openings be found externally, it will be advisable to divide the sphincter ani muscles at one point, only, since there is a possibility that permanent loss of function might result were two divisions of the muscles made.

Lateral Lithotomy.—After the patient has been brought into the lithotomy position, a staff is introduced into the bladder and held with the handle well over the patient's abdomen, so that the curve of the staff will push the membranous portion of the urethra towards the surface of the perineum. The first incision is made by inserting the knife a little to the left of the median line and just behind the central tendinous point of the perineum, *i.e.*, the knife should enter about one and a quarter inches in front of the centre of the anus. The knife thrust should be at right angles to the perineum and directed towards the staff, and the incision should be completed by carrying the knife downwards and outwards through the left ischio-rectal fossa, to end at a point between the tuber ischii and the posterior part of the anus, one-third nearer to the tuberosity than to the anus. The incision should be about three inches in length and should gradually become more shallow as it is made backwards. The staff is now drawn upward so that its hollow will rest against the pubic arch, the forefinger of the left hand feels for the groove in its

surface, and, when found, the knife is slipped along the finger until it reaches the groove and is then pushed along it until the bladder is reached. As the knife is withdrawn, its edge is turned downwards and outwards, so as to enlarge, obliquely, the opening made in the neck of the bladder and prostate. The finger now follows the staff into the bladder, the staff is removed, the stone identified, the lithotomy forceps introduced along the finger and the stone seized and withdrawn. The first incision cuts the skin and fasciæ; the transverse perineal artery, nerve and vein; the lower edge of the upper layer of the triangular ligament and the external hemorrhoidal vessels and nerves. The second incision divides the membranous and prostatic portions of the urethra; the posterior portion of the triangular ligament; the compressor urethræ; the levator ani and the left lateral lobe of the prostate.

The following structures may be injured if care be not taken to avoid them: 1. *The artery of the bulb.*—This is avoided by not starting the incision beyond the point mentioned, *i.e.*, beyond a point, one and a quarter inches in front of the centre of the anus, since the artery runs towards the central tendinous point, which is about one and a half inches in front of the centre of the anus. 2. If the incision be carried too far outwards the *internal pudic vessels*, which lie inside the tuberosity of the ischium, might be wounded. 3. *Rectum.*—If the incision be not carried sufficiently outwards, or if the rectal tissues be not guarded with the finger, or if the bowel be distended, then the rectum would be in danger of being wounded.

Prostate.—If the prostate be not incised in a direction downwards and outwards, *i.e.*, if it be cut transversely, then it is probable that the recto-vesical fascia, which passes from the sides of the pelvis to the prostate gland will be opened up, and infiltration of urine into the pelvic cavity occur.

Hydrocele.—Should tapping of the sac be employed, it is advisable to bear in mind that, in the majority of cases, the testicle is situated posteriorly, and hence the trocar and canula should be inserted from the front, and, after penetrating the tunica vaginalis, as evidenced by the cessation of resistance to its passage through the tissues, the point of the trocar should be directed upwards so as to avoid the testicle.

Varicocele.—In the open method of operating for varicocele a transverse incision through the scrotal tissues is better than a longitudinal one, since, when sutured, the edges of the resulting wound are better approximated than in the longitudinal incision because of the direction of the unstriped muscular tissue of the dartos of the scrotum. Before ligating the pampiniform plexus of veins, the vas deferens should be identified by the cord-like feel it imparts to the fingers, and should be carefully avoided, not only for its own sake, but also because the artery of the vas deferens runs along with it. Two or three veins should be left out of the ligature, since otherwise, orchitis or atrophy of the testicle might result, and, lastly, the plexus should be excised between two ligatures, one above, on the cord, and, the other below, near the globus minor of the epididymus.

In *castration*, an incision is made from a point one inch beneath the external ring to the bottom of the scrotum, and when the testicle and cord are exposed, the latter is divided about three-quarters of an inch below a clamp placed upon its upper part. It is better to ligate the blood-vessels separately, rather than to include the whole of the cord in one ligature, since this might slip and permit secondary hemorrhage.

Prostatic Inflammation.—Should pus form, it might burrow up, towards the pelvis, or backwards, and rupture into the rectum, but, in all probability, it will open into the urethra. When the presence of pus is established, an incision should be made in the middle line, about half an inch in front of the anus, while the finger in the rectum protects the bowel and directs the knife towards the prostate gland.

Enlargement of the Prostate.—Should prostatectomy be performed for this condition, it is best done through a suprapubic incision, as in the operation of suprapubic lithotomy. White, of Philadelphia, first suggested castration as a means to induce atrophy of the prostate when this gland is hypertrophied.

CHAPTER XXX.

SCARPA'S TRIANGLE AND FEMORAL HERNIA.

SUPERFICIAL FASCIA.	FEMORAL HERNIA
LYMPHATIC GLANDS.	COVERINGS.
SAPHENOUS OPENING.	OPERATIONS.
SCARPA'S TRIANGLE	

In the *region of Scarpa's triangle* we find that the superficial fascia is divisible into two distinct parts, viz., a superficial or fat-bearing layer and a deep or fibrous layer. The following structures separate these two divisions of the superficial fascia from each other, viz.: The superficial epigastric, the superficial circumflex iliac and the superficial and deep external pudic arteries; the companion veins to these arteries; the long saphenous vein; the crural branch of the genito-crural nerve; the middle cutaneous branch of the anterior crural nerve; twigs from the ilio-inguinal nerve, and, lastly, superficial lymphatic vessels and glands.

The **Lymphatic** Glands are arranged in two sets—a superior and an inferior. The *superior group* is more or less parallel to Poupart's ligament and may be affected in septic wounds, etc., of the buttocks, or of the inner part of the thigh, the lower portion of the superficial structures of the abdomen, the integument of the penis, scrotum and perineum in the male, and the lower portion of the vagina in the female; whereas, the *inferior group*, which is situated at right angles to Poupart's ligament and in the neighborhood of the saphenous opening, may be involved in wounds, etc., of the lower limb. In the

deep fascia, in this region, there is a cleft, termed the **Saphenous Opening** and through this opening the following structures enter or leave the thigh, viz.: The superficial epigastric vessels, the superficial external pudic vessels, the saphenous vein and the lymphatics. But these structures lie between the superficial and deep layers of the superficial fascia, hence they must pierce the deep layer of this fascia which overlies the saphenous opening and is adherent to its margins, so that the numerous perforations, resulting, give this fascia the name of the *cribriform fascia*.

The saphenous opening, spoken of above, is covered in by this cribriform fascia, hence it is not, in reality, an opening. It is one, potentially, only. The existence of this so-called opening is due to a peculiar arrangement of the fascia lata of the thigh, and, in order to understand this arrangement, imagine that no such opening existed, but that the deep fascia was incised for a distance of one and a half inches, beginning at Poupart's ligament, about one and a quarter inches from the pubic spine. Imagine, further, that the upper angles of this incision are stretched so that the inner or pubic portion is drawn outwards, beneath the femoral artery and vein, but above the psoas and iliacus muscles, as far as the capsule of the hip joint, and that the outer or iliac portion is drawn inwards, over the artery and vein, as far as the pubic spine, where it touches the pubic portion; we would, then, have an opening about one inch in length, directed obliquely downwards and outwards, wider below than above, since it tapers to a point, above, owing to the junction of the iliac and the pubic portions of the fascia lata, and with its axis pointing inwards and forwards. The centre of the opening is one inch below a point, which is situated one and a quarter

inches horizontally outwards from the spine of the pubes, *i.e.*, the centre is one and a half inches in a direction, downwards and outwards, from the pubic spine. The saphenous opening overlies the pectineus muscle, and, if the cribriform fascia be removed and the finger inserted into the opening, it will pass in an outward direction and will touch the femoral vein.

Scarpa's Triangle.—On the removal of the fascia lata a muscular triangle is exposed, immediately below Poupart's ligament—Scarpa's triangle. This triangle is bounded, externally, by the sartorius, and, internally, by the adductor longus, and the convergence of these muscles forms the apex, while the base is situated at Poupart's ligament. The floor is composed, from without inwards, of the following muscles, *viz.*: The iliacus, the psoas, the pectineus, a small portion of the adductor brevis and the adductor longus, while the roof is formed by the two layers of the superficial fascia.

Landmarks—The base varies in accordance with the length of Poupart's ligament, while the apex is situated about five inches from the base, and is on a deeper level than it in the extended position of the limb. The relationship of the main structures in the triangle, from within outwards, is femoral vein, femoral artery and anterior crural nerve. The vein lies close to the inner side of the artery, whereas, the nerve is situated about half an inch external to the artery, lying between the psoas and the iliacus muscles. The femoral artery almost bisects this triangle, passing, as it does, to the apex, from a point half an inch internal to the middle of the base. The term, common femoral, is applied to the vessel until it divides into its two branches, *viz.*, the superficial and the deep femoral, and the point, where this division occurs, is variable, although it may be taken, on an average, as about one and a half inches below Poupart's ligament.

Femoral Hernia.—When the deep fascia is removed from Scarpa's triangle and the artery and vein are exposed, there is seen to overlie them, a sheath, that may be picked up with the forceps from the vessels for a distance of about one inch from Poupart's ligament. This sheath entirely surrounds the vessels, the anterior portion of it being formed by the projection downwards, from the abdomen, of the transversalis fascia, while the posterior portion is the downward projection of the iliac fascia.

If we examine the lower quadrant of the abdomen from within, after stripping off the peritoneum, we see, that the transversalis fascia, which lines the anterior wall of the abdomen, and the iliac fascia, that covers the posterior wall, are united where they meet on the posterior surface of Poupart's ligament. This union occurs along the whole length of the ligament, except at the point where the vessels are seen to descend, beneath the ligament, into the thigh. Here, they seem to push the line of union downwards ahead of them, so that the transversalis fascia lies in front and the iliac fascia behind these vessels. But the vessels would appear to have carried down with them an area of this line of union, wider than their calibre would warrant, since, although the sheath is closely applied to the outer surface of the artery, there is an interval of about half an inch in width, left on the inner side of the vein, and, since this fascial sheath is united to the areolar sheath of the vessels about one inch below Poupart's ligament, it follows that the space left on the inner side of the vein must be funnel-shaped.

The wide part of the funnel is directed upwards beneath Poupart's ligament, is half an inch in width, and is termed the *femoral ring*, while the funnel itself is about half an inch in length, and is called the *femoral canal*. The femoral ring is a potential and not an actual opening,

and is filled with areolar tissue, which, according to Cloquet, is condensed to form a septum—the *septum crurale*. On the other hand, Joussel maintains that there is no fascial septum here, that it is merely areolar tissue, and that this areolar tissue, with a gland—Rosenmüller's—protects the ring. The presence of a canal or space alongside the femoral vein proves of great importance in connection with the circulation of the lower extremity, for, if the inner margin of the sheath, formed by the iliac and transversalis fasciæ, were as closely applied to the vein as the outer margin is to the artery, there would be more or less interference with the venous circulation, especially in the different movements of the limb, on account of the sluggish nature of the current of blood in the vein as compared with that in the artery. The tip of the index finger can be readily inserted into this ring in the dead subject, due, no doubt, to the fact that the femoral vein is here collapsed, whereas, in the living subject, it is altogether likely that the distended state of the vein would markedly lessen the size of the ring as found in the dead subject. The presence of the areolar tissue, mentioned above, strengthens what would otherwise be a rather weak part, so that femoral hernia is very infrequent as compared with inguinal hernia. But, when in the old, or in patients after frequent pregnancy, Poupart's ligament becomes more or less lax from repeated over-stretching, this potentially weak spot may, during efforts of straining, become converted into an actual defect, and, yielding to the pressure of the intestine, permit a femoral hernia to occur.

Coverings of Femoral Hernia.—When the bowel protrudes, it pushes in front of it, the peritoneum covering the ring; next, the subserous areolar tissue; the septum crurale, when it exists, and the areolar tissue of the canal;

then the cribriform fascia, and, lastly, the superficial layer of the superficial fascia and the skin. The protruded intestine changes its direction twice—a point to be remembered in the application of the taxis for its reduction. The *first change in direction* occurs as the bowel reaches a point, a little below the middle of the saphenous opening, where it turns forwards so as to distend the cribriform fascia in front of it. One reason for this change in direction is, that the fibrous sheath is here, *i.e.*, one inch below Poupart's ligament, closely adherent to the areolar sheath of the vein, so that the bowel cannot descend along the vein any farther, and another reason is, that the lower margin of the saphenous opening is closely applied to the vein, thus forming a thin partition which separates the long saphenous from the femoral vein, and, therefore, offers an obstruction to the further descent of the bowel. The *second change in direction* is, when the bowel, pushing the cribriform fascia in front of it, arches upwards, towards Poupart's ligament, over the upper or falciform boundary of the saphenous opening. This change may be influenced by the direction and termination of the superficial epigastric, the circumflex iliac and the external pudic veins, since they come from above and pass downwards to the femoral vein through the saphenous opening, and would, therefore, support, cradle-like, the hernia and direct it upwards towards the abdomen. The mesentery may be another factor in this turning upward of the intestine, since the traction exercised by it, while the bowel continues to be forced downwards, would tend to curl the latter upwards. To properly apply the *taxis*, the above path must be borne in mind, so that, the protruded bowel would have to be directed downwards, backwards and upwards, *i.e.*, so as to cause it to retrace the course it took in its descent. In spite of the fact that the

femoral canal is in a more dependent position than the inguinal, and is directed vertically rather than obliquely as the latter is, femoral hernia is not very common, principally because of the small size of the femoral ring. According to Macready, out of one hundred cases of rupture, there would be, in the male, 83.5% of inguinal and 2.1% of femoral, and, in the female, 8.5% inguinal and 5.9% femoral. The greater width of the pelvis in the female and the effect of child-bearing on the length of Poupart's ligament account for the larger number of cases of femoral hernia in the female than in the male. When a femoral hernia is *strangulated*, the seat of stricture may be at the neck of the sac, at the femoral ring, or under the overhanging upper margin of the saphenous opening, and in the **operation** for its relief this seat of stricture may have to be divided. Should the stricture be situated at the femoral ring, it should be divided by nicking its inner border, *i.e.*, Gimbernat's ligament. The femoral vein forms the outer boundary and could hardly escape being wounded if the knife were directed outwards; the vas deferens, in the male, and the round ligament, in the female, lie above Poupart's ligament, and, therefore, are in front of the ring; the bone is behind, while the free crescentic edge of Gimbernat's ligament is situated internally. In one out of one hundred cases the obturator artery is given off from the deep epigastric to wind around the inner border of the ring, so that, under these circumstances, this artery might be wounded during the operation. In the *radical* cure, the margins of the saphenous opening are approximated by interrupted sutures after the sac has been ligated and excised.

CHAPTER XXXI.

THE GLUTEAL REGION.

MUSCLES AND THEIR ACTIONS.

STRUCTURES BENEATH GLUTEUS MAXIMUS.

LANDMARKS.

The superficial fascia in this region is thick and coarse, especially towards the lower part of the buttock, while the deep fascia, termed from its extent the fascia lata, is attached to the crest of the ilium above, to the lower part of the vertebral aponeurosis behind and to the border of the tuberosity and the ascending ramus of the ischium below and internally. The fascia lata invests all the muscles of the thigh.

Muscles.—The *Tensor Vaginæ Femoris* arises from the front of the outer lip of the crest of the ilium and half of the notch between the anterior superior and the anterior inferior spines, and is inserted into the fascia lata below the level of the great trochanter. It may be regarded as an interrupted portion of the gluteus maximus, since it is inserted, like it, into the fascia lata of the thigh. This muscle abducts the thigh and rotates it inward, and is, like the gluteus maximus, a tensor of the fascia lata, thus assisting in the completion of the act of extension of the leg, by drawing upwards the external tuberosity into which the fascial band is inserted. The *Gluteus Maximus*, arising from the posterior fifth of the crest of the ilium and from the outer surface of the bone between the crest and the superior curved line, from the fascia over the erector spinæ muscle and from the posterior surface of the sacrum and coccyx, is inserted into the fascia lata and into the line leading from the great trochanter to the linea aspera—the upper half of the muscle and the superficial

fibres of the lower half going to the fascia lata, while the deeper portion of the lower half is inserted into the femur. *Actions.*—It is an external rotator and an extensor of the thigh, the latter action being pronounced when an extra effort is required for extension, as in climbing a hill, or in jumping, etc.—the ordinary extension that takes place in walking on the level being the result of the action of the hamstring muscles. Acting from below, the gluteus maximus extends the pelvis on the femora, so as to bring the body to an erect position. One of the distinguishing features of lumbago is pain on attempting to assume the erect posture after stooping, and this is due to the fact, that a portion of the gluteus maximus arises from the fascia covering the muscles affected in lumbago, and consequently, when the patient raises his body from the stooping posture, the traction on this fascia by the gluteus maximus causes pain.

Gluteus Medius.—From the anterior four-fifths of the crest of the ilium and from the outer surface of the bone between the superior and the middle curved lines; into the oblique line running downwards and forwards on the outer surface of the great trochanter. The gluteus maximus covers the posterior third of this muscle. *Actions.*—It is an abductor of the thigh, and can rotate the limb, by its anterior fibres, inwards, and, by its posterior fibres, outwards. Acting from below, it balances the pelvis when the opposite limb is raised from the ground, and is, therefore, brought into play in walking, whereas, in fast walking, it rotates the opposite side of the pelvis forward and thus increases the length of the stride.

Gluteus Minimus.—From the outer surface of the ilium between the middle and the inferior curved lines and from the margin of the great sacro-sciatic notch; into the anterior border of the great trochanter. Its *actions* are similar to those of the gluteus medius.

Pyramiformis.—From the anterior surface of the sacrum, between the first, second, third and fourth foramina; from the anterior surface of the sacro-sciatic ligament and from the margin of the great sacro-sciatic foramen; into the inner surface of the anterior portion of the upper border of the great trochanter. *Action*.—It rotates the thigh outwards, and, acting from below, rotates the pelvis towards the opposite side.

Obturator Internus.—From the inner surface of the obturator membrane and a portion of the bony ring surrounding the foramen; into the inner surface of the upper border of the great trochanter near the neck of the femur. *Action*.—It rotates the thigh outwards.

Gemellus Superior and Inferior.—The former from the outer surface of the spine of the ischium; into the upper border of the tendon of the obturator internus about one inch from its insertion; the latter, from the upper part of the inner border of the tuberosity; into the lower border of the above tendon, the same distance from its insertion as the gemellus superior. The *action* of these muscles is similar to that of the obturator internus.

Quadratus Femoris.—From the upper part of the outer border of the tuberosity of the ischium; into the linea quadrata of the femur. *Action*.—External rotation of the thigh.

These muscles, *rotators* in action, are all supplied by the *same nerves*, viz., the lumbo-sacral, and branches from the first and second sacral nerves—the gluteus maximus receiving, in addition, fibres from the third sacral, through the inferior gluteal nerve.

On **removal** of the **gluteus maximus** the following structures are exposed, from above downwards: The posterior portions of the gluteus medius and gluteus minimus muscles; the gluteal artery and its branches; the superior

gluteal nerve; the piriformis muscle; the internal pudic artery, pudic nerve and sciatic artery; small and great sciatic nerves; the inferior gluteal nerve emerging from the pelvis; the obturator internus muscle, with the gemellus superior above and the gemellus inferior below; a small portion of the obturator externus; the quadratus femoris; the upper portion of the adductor magnus, and the origins of the semi-membranosus, semi-tendinosus and the biceps muscles. Besides the above structures, the following also are exposed: A portion of the ilium, the posterior superior and the posterior inferior spines, the greater and lesser sacro-sciatic ligaments, the spinous process and the tuberosity of the ischium; the bursa overlying the latter; the great trochanter with its bursa; the posterior surface of the sacrum and the side of the coccyx covered by ligaments.

Landmarks for the Gluteal Region.—The *posterior superior* spine can be felt by running the finger backwards along the crest of the ilium to its termination. This spine corresponds to the middle of the sacro-iliac joint and to the level of the second sacral spine. The *posterior inferior spine* is about one inch below the posterior superior spine, lies one-quarter of an inch external to the line from the latter spine to the outer border of the ischial tuberosity, and corresponds to the lower limit of the sacro-iliac joint. The *tuberosity of the ischium* lies near the lower border of the gluteus maximus, while the *spine of the ischium* is situated beneath a line drawn from the posterior superior iliac spine to the outer border of the ischial tuberosity and at a point, about two inches above the latter. This spine lies about one and a quarter inches below the top of the great trochanter. The *third sacral spine* may be found after the second spine has been identified, as above described, viz., by its relationship to the posterior superior

spinous process. The third spine corresponds to the lower limit of the spinal membranes, to the exit of the gluteal artery and to the upper border of the sacro-sciatic notch, The lower part of the *last piece* of the *sacrum* is opposite the spine of the ischium.

Landmarks for the *Vessels*.—*Gluteal Artery*.—Rotate the slightly flexed thigh inwards, and draw a line from the posterior superior spinous process to the posterior part of the upper border of the great trochanter. The junction of the upper and middle thirds of this line will correspond to the point of emergence of the gluteal artery above the pyriformis muscle, and is about opposite to the third sacral spine.

The *sciatic and pudic* arteries may be located by identifying the spine of the ischium, in the manner above described, since they emerge from the pelvis immediately above this spine. Landmarks for the *muscles*.—The *gluteal muscles* may be mapped out by remembering their origin and insertion. The *pyriformis* may be represented by a triangle, with its apex at the anterior part of the upper border of the great trochanter, and its base corresponding to the line drawn between the landmark for the gluteal artery, above, and that for the sciatic and pudic arteries, below. The *quadratus femoris*, about two inches broad, is situated between the outer surface of the tuber ischii and the posterior surface of the great trochanter, while the *obturator internus* with the gemelli, above and below it, is situated between these two muscles, *i.e.*, the pyriformis and the quadratus femoris. Landmarks for the *nerves*.—The *superficial nerves* of the *gluteal region* are situated as follows: Below the anterior iliac spine are the branches of the external cutaneous; behind the spine and running towards the great trochanter, the lateral cutaneous of the last dorsal crosses the iliac crest; close

behind this, is the lateral cutaneous branch of the iliohypogastric; between the latter and the posterior superior spine are lateral branches from the posterior divisions of the three upper lumbar nerves. Between the posterior inferior spine and the ischial spine are branches from the posterior divisions of the three upper sacral nerves. Between the ischial spine and the tuberosity of the ischium is the perforating cutaneous branch of the fourth sacral nerve, and, lastly, external to the tuberosity, are branches of the small sciatic curving upwards over the lower border of the gluteus maximus. The *superior gluteal* nerve is situated immediately below the landmark for the gluteal artery; the *small sciatic* and the *inferior gluteal* are about half an inch external to the landmark for the pudic artery, *i.e.*, the spine of the ischium, while the *great sciatic* lies about one inch external to the same landmark, and may be represented by a line drawn downwards from this point, or from a point, a little internal to the middle of the space between the tuber ischii and the great trochanter, to the middle of the lower part of the back of the thigh.

CHAPTER XXXII.

THE HIP JOINT.

ANATOMY.

SYNOVITIS.

MORBUS COXAE.

Symptoms.

DISLOCATION.

Varieties

Reduction by Manipulation

The hip joint is formed by the reception of the rounded head of the femur in a cavity—the acetabulum—which is thickened at its upper part, since it is here that the strain is received in supporting the weight of the body. The hip joint is an enarthrodial, or ball and socket joint, and has in connection with it the following ligaments, viz., the capsular, transverse, ligamentum teres, and the cotyloid cartilage. The *capsular ligament* is attached, above, to the margin of the acetabulum, a little beyond the cotyloid cartilage, and, where the rim is deficient below, to the transverse ligament. To the femur, it is attached along the anterior intertrochanteric line, while behind, the attachment is from one-half to two-thirds of an inch above the posterior intertrochanteric line. Some of the deeper fibres of this ligament spread, from their insertion in the bone, upwards on the neck of the femur towards the head of the bone and are termed “retinacula.” The capsular ligament is sufficiently loose that some portion of it is relaxed in every position of the body. It is thinnest below and anteriorly, but is thickened above and behind by means of the following *auxillary bands*, viz., the ilio-femoral or Y ligament (Biglowe), the ischio-femoral, the pectineo-femoral, the ilio-trochanteric band and the tendino-trochanteric band. The *ilio-femoral* is very strong and is triangular in shape, with the apex attached, above, to the ilium immediately below the anterior inferior spine, and

the base formed by two limbs—one, almost transverse, attached to the anterior edge of the great trochanter, and the other, directed obliquely, to the anterior spiral line. The *ischio-femoral*, situated behind and above the joint, is also triangular in shape, with the base attached to the ischial margin of the acetabulum, and the apex to the digital fossa on the inner aspect of the upper border of the great trochanter. The *pectineo-femoral*, from the anterior border of the pectineal eminence, passes transversely outwards to the neck of the femur behind the lower limb of the Y ligament. The two minor accessory bands, viz., the ilio-trochanteric and the tendino-trochanteric bands, from the rectus tendon to the great trochanter, also assist in strengthening the upper part of the capsule. The *transverse* ligament passes across the cotyloid notch so as to convert it into a foramen, while the *cotyloid* deepens the acetabulum, being superimposed on its margin. The *ligamentum teres*, conoidal in form, with its apex at the head of the femur and its base in the non-articular part of the acetabulum, is about one and a half inches long and is covered by the synovial membrane. The latter, *i.e.*, the *synovial membrane*, lines the interior of the joint, covering the head and neck of the femur and the base of the acetabulum. It is prolonged from the head of the bone to the latter situation over the ligamentum teres and then covers the inner surface of the capsular ligament.

The *arteries*, supplying the hip joint, are derived from the internal and the external circumflex, the sciatic, the gluteal and the obturator. The branch from the latter, after ramifying in the fat at the bottom of the acetabulum, passes down the ligamentum teres to the head of the femur to supply it. The *nerves* are from either the sacral plexus or the great sciatic nerve, from the anterior division of the obturator, the accessory obturator, and the an-

terior crural. *Movement.*—Every movement, viz., flexion, extension, rotation, abduction, adduction and circumduction, with their combinations, is permitted at this joint.

Synovitis.—In this disease the *position* assumed by the limb is that of flexion, eversion and abduction. Treves shows, that it is in this position, that the joint contains the greatest amount of fluid, and, therefore, when the synovial sac is distended with hypersecretion, as in synovitis, the limb is flexed, abducted and rotated outwards, so as to distribute the pressure, as evenly as possible, on the inflamed synovial membrane. It is *flexed* to relax the main portion of the ilio-femoral ligament, *abducted* to further relax the outer arm and *everted* to further lessen the pressure due to the inner arm of this ligament. In synovitis the swelling is rarely appreciable because of the deep situation of the joint, but when it is, its usual situation is behind the great trochanter, or in front, below the middle of the line separating the thigh from the abdomen; or it may be internally, in the angle between the thigh and perineum, behind the adductor longus tendon. It must not be forgotten that there are *three bursæ* in the neighborhood of the joint, which, when distended, might, if not carefully examined, lead one astray in the diagnosis of synovitis with effusion—*one*, beneath the ilio-psoas muscle between it and the capsule of the joint, and extending as far as the lesser trochanter; *a second*, over the great trochanter, between it and the gluteus maximus, and *a third* over the ischial tuberosity. The diagnosis may be assisted by the fact, that, when either of these bursæ is distended, there is neither swelling nor fluctuation present at the other points mentioned above as the possible seats of the swelling in synovitis of the hip joint.

Morbus Coxæ or Tuberculosis of the Hip Joint.—In the *young*, tuberculosis of the hip may start in the base of the acetabulum, or in the femur, either in the head under

the encrusting cartilage, or in the neck, on the distal side of the epiphyseal line. Senn quotes Heberern's statistics to the effect that, the acetabulum alone was affected in fifty and the femur alone in twenty-three out of eighty cases of primary bone disease. Treves states, that exact data with reference to the relative frequency of the appearance of the initial foci are wanting, although he says, "It is generally believed to start most frequently in the femur, next in the synovial membrane, and more rarely in the acetabulum." The knowledge of the reflection of the synovial membrane is of importance in connection with this disease, since the relation of the *synovial membrane* to the head and neck of the femur is such, that, surrounding them as it does, disease in either of these situations may readily involve this membrane, and this it generally does. Rarely, however, the pathogenic process follows down the neck to the great trochanter, and then appears on the surface, or, on the other hand, it may spread along the ligamentum teres to the acetabulum, and, penetrating the latter bone, appear as a pelvic abscess. In the latter instances, the tubercular abscess may be outside the synovial sac, *i.e.*, may not involve this membrane at all.

Symptoms.—In the *first stage* of morbus coxæ the limb is, as a rule, flexed, everted and abducted. This position is likely due to the attempt to lessen the pressure on the inflamed synovial membrane, as explained above, under synovitis. In the *second stage* the limb becomes still more flexed, the abduction changes to adduction, and the eversion to inversion. In the *third or last stage* erosion or loss of substance of the bones occurs at their points of contact, so that the head of the femur may be dislocated, generally on to the dorsum of the ilium. By some, the position of the limb in the first and second stages have been ascribed to neuro-muscular causes, although Barwell,

in speaking of the change from the first to the second, says, "The cause of this change is quite occult. At present we are without any clue even to an inference as to its nature."

With the position of the limb in the first stage there is necessarily associated *apparent lengthening*. This is due to the position of abduction present in this stage, for, should the patient be asked to bring his limbs parallel, when lying down, or to touch the ground with the foot of the diseased side, when standing, he will have to lower down the pelvis on the affected side so as to bring the abducted limb to a parallel or to a vertical position. In the second stage there is *apparent shortening*, because of the adduction present, since here, as in the first stage, the patient alters the transverse axis of the pelvis to make the limbs parallel, and this alteration consists in raising, or tilting up, the side of the pelvis corresponding to the affected limb, so that the latter is apparently shortened. In either stage, a change in the direction of the spinal axis must, also, occur, when the patient attempts to bring the limbs into a parallel position. This is due to the fact that, since the limb is fixed in a flexed position, it is impossible to straighten it by means of any movement at the hip joint, and further, that the amount of movement permitted at the sacro-iliac joint is not sufficient to allow the limb to be straightened, so that, to straighten the limb it will be necessary to extend it by *lordosis*, *i.e.*, by a forward bending of the lumbar vertebræ. *Limping*, in *morbis coxæ*, is dependent, probably, on the fact that "the weight of the body on the femur causes uneasiness, hardly amounting to pain, but sufficient to lead the patient to rest as short a time as possible on the limb, and there is, therefore, a short step and a long one alternately" (Treves).

Pain.—With ordinary passive motion, there is very little pain, in the early stages, in those cases in which the tubercular processes have started in the bone, although pain can be elicited by forced passive movements. The pain, when present, would be due to the action of the ilio-femoral ligament, which, acting as a fulcrum when the limb is over-extended or over-abducted, would tilt the head of the femur up against the upper part of the acetabulum and thus induce pain. To prevent this pain on forced passive movement the limb is instinctively brought into a more or less spastic condition by the patient, especially when the surgeon attempts to over-extend it. This spastic condition is termed “reflex spasm,” and is one of the diagnostic features of the early stage of hip joint disease, especially when the primary disease is situated in the bones. When, however, the disease starts in, or early involves the synovial membrane, any movement at the joint is resisted, since such movement would result in friction of the diseased surfaces and consequent pain. Pain may be felt in children, old enough to localize it, either in the neighborhood of the joint, such as near the apex of Scarpa’s triangle, or over the ilium above the great trochanter, or, more often, at the knee. The explanation of the location of pain at this latter situation, *i.e.*, the knee, is vague. Bell, quoted by Senn, believed it due to a reference of the pain to the cutaneous branches of the obturator nerve, and Coulson explains those cases, in which the pain is felt at points other than the distribution of the branches of the obturator, as being due to inflammation of the fascia of the rectus femoris, which muscle is, at its origin, connected with the capsule of the hip joint, and that the pain is, therefore, conveyed down along this muscle towards the knee. In all probability, however, the reference of the pain to the knee is dependent on the fact, that the nerves

supplying the hip joint, with the exception of the accessory obturator nerve, supply the knee joint as well, viz.: The anterior crural, entering the knee joint, on either side of the patella; the obturator, from behind, through the middle of the posterior ligament; the great sciatic by means of branches that accompany the articular arteries—internal, external and azygos—hence, pain felt in the knee, at either of these situations, is likely due to the involvement of the particular nerve supplying the joint at that point. Barwell draws attention to the sympathy existing between the ends of the bones, so that, when the thigh is pressed upwards, patients often complain of pain, not at the hip joint, but at the knee joint.

Starting pains, inducing *night cries*, are due to a reflex act through an excited spinal cord, just as the child drops asleep, and when, therefore, the controlling power of the cerebrum is withdrawn. A twitching or an involuntary relaxation of the over-fatigued muscles, which have kept the limb fixed while the patient was awake, is developed and causes the ends of the diseased bones to come together with sufficient force as to make the child cry out with pain.

The possibility of hip joint disease should always be kept in mind when examining a patient complaining of pain in the knee joint; and, in addition to the means usually employed to differentiate disease of the one joint from that of the other, it is well to note, that pressure on the knee will increase the pain if the latter be due to local causes only, but, will not affect it, if it be a referred pain. *Abscess* in tuberculosis of the hip joint may appear on the surface at any point. When it presents itself in the gluteal region, it may be and frequently is dependent on disease in the head, or in the head and neck of the femur. If appearing above Poupart's ligament, it is, in all likelihood, due to perforation of the acetabulum.

Dislocation at the hip joint is more frequent in men than in women owing to the greater exposure of the former to the accidents that give rise to these injuries. Of the regular dislocations of the hip there are four varieties—(1) On the dorsum ilii; (2) into the sciatic notch; (3) on the thyroid foramen, and (4) upon the pubes. These occur in the order named, thus, out of the one hundred and four cases collected by Hamilton, fifty-five were on the dorsum, twenty-eight into the sciatic notch, thirteen on the thyroid foramen and eight on the pubes.

1. On the **Dorsum Ilii.**—This form of dislocation generally occurs when the thigh is adducted, flexed and inverted (Hamilton, Andrews); while Treves states, that in the production of this variety of dislocation, the limb, on the receipt of the injury, is, as a rule, in the position of abduction and flexion. Whatever be the position of the limb when the accident happens, the head of the femur rests on the dorsum ilii, under or among the gluteal muscles, while the shaft points towards the upper part of the patella of the uninjured limb, and the toe of the dislocated (2) towards the instep of the sound side. The smaller external rotators are tense, or torn, the glutei muscles are pushed up and stretched, the adductors are tense, while the ilio-femoral or Y ligament is rigid. The limb is in a state of adduction, inward rotation and slight flexion, due, partly, to the bony conformation of the head of the femur and of the dorsum ilii on which the head rests, but chiefly to the tension of the Y ligament (Bigelow), although Gunn of Chicago, considers, as the result of his dissections and experiments, that the Y ligament is entirely without influence in determining the deformity in this form of dislocation, but that the deformity depends on the tension of the anterior and inferior untorn portions of the capsular ligament.

2. Dislocation into the **vicinity of the Sciatic Notch.**—The same kind of accidents may cause this, as are responsible for the dorsal iliac variety, with the exception that the limb at the time of the receipt of the injury is less flexed and less rotated inwards than in the case of the dorsal iliac variety. The condition of the soft parts is much the same in each of these forms of dislocation. The head, however, in this variety, rests in the vicinity of the great sciatic notch (often upon the spine of the ischium), while the great toe of the dislocated limb is generally pointing towards the ball of the great toe of the sound limb. Bigelow describes what he calls a dislocation “below the tendon of the obturator internus,” in which this tendon lies between the head of the femur and the acetabulum.

3. Dislocation **into the Thyroid Foramen** is generally caused by falls or violence received, when the limbs are abducted or widely separated. When, in this form of dislocation, the head of the femur leaves the acetabulum, it slips, generally, forwards, so as to rest on the thyroid foramen. The limb is slightly flexed and abducted, and the foot points forward, or is somewhat everted. There is lengthening of the limb from half an inch to two inches. The psoas, iliacus and the adductors are overstretched and tense, whereas, the posterior external rotators are not much affected. The flexion and abduction are attributed to the influence of the Y ligament by Bigelow, though Gunn states, that it is impossible for the head of the bone to occupy the thyroid foramen without complete rupture of this ligament. The abduction is in all probability due, partly to the head of the femur resting on the inclined plane formed by the ascending ramus of the ischium and the descending ramus of the pubes,

and partly to the tension of the psoas and iliacus muscles, while the flexion is due to the over-stretching of these muscles.

4. Dislocation **on to the Pubes** results from falls on the feet or knees, when the limb is extended or thrown backward behind the centre of gravity. In it, the head of the bone rests in front of the body of the pubes, generally outside of the femoral vessels and under the psoas and iliacus muscles, and, therefore, stretching the anterior crural nerves; the posterior surface of the neck is in contact with the rim of the acetabulum, while the trochanter major sinks into the acetabulum. The shaft of the bone is abducted, slightly flexed and rotated outwards from much the same causes as in the other variety of forward dislocation, *i.e.*, dislocation into the thyroid foramen, and the surrounding soft parts are disturbed to nearly the same degree as in the other form. *The rent in the capsule.*—Hamilton, Gunn and Barwell state that it is the posterior portion of the capsule that is torn. Treves, Tillaux and Morris, on the other hand, believe that, in nearly every case of dislocation, the head of the bone leaves the acetabulum through a rent in the lower and anterior part of the capsule, and that the condition of rotation of the limb, at the time of the receipt of the injury, influences the position the limb will assume, *i.e.*, the form of dislocation. Thus, if the limb be flexed and rotated inwards, or if the pelvis be rotated outwards, the head of the bone will sweep around an axis formed by the untorn part of the capsule, so as to occupy the neighborhood of the sciatic notch, but if the flexion and rotation be more marked, then the head will be carried back on to the dorsum ilii. Should, however, the limb be rotated outwards at the time of the receipt of injury, or should the position of the pelvis be correspondingly altered, then a forward dislocation

will result. In every case, then, there must be a primary downward dislocation, which is later converted into the particular form present, since the structures forming and protecting the joint, viz., the acetabulum and the capsular ligament, are strong and thick above, whereas, below, they are almost wanting in the case of the acetabular margin, and weak in the case of the ligament, and it is on this less protected portion of the joint that the head of the bone, in abduction, rests. Wherever the rent in the capsule be situated, most authorities agree that the untorn part offers a considerable obstacle to reduction, although different reasons have been assigned by different authorities in explaining the opposition to the reduction of a dislocation; thus, Nathan Smith, for instance, considers that the tension of the glutei muscles is responsible; Reid thinks it is due to the abductors and the rotators, etc.

Reduction by Manipulation depends on the fulcrum-like action of the untorn part of the capsule. In the reduction of a *backward dislocation* by manipulation, the leg should be flexed on the thigh to enable the surgeon to use the latter as a lever and for the purpose of relaxing the hamstring muscles. He then, to relax the Y ligament, raises the knee towards the patient's face, *i.e.*, flexes the thigh, with slight adduction until resistance is encountered. The limb is now gently carried outward, *i.e.*, circumducted, until resistance is met with, thus causing the head of the bone to sweep around the acetabulum, through an axis formed by the untorn part of the capsular ligament, and to traverse, therefore, the path it followed in arriving at its abnormal position. While this latter movement is being performed, the thigh should be slightly rotated outwards to relax the tense external rotator muscles. The limb should now be gradually extended. Hamilton says, "I do not know that the whole process should

be expressed in simpler or more intelligent terms than to say that the limb should follow constantly its own inclination." Too powerful manipulatory movements might convert one form of dislocation into another by throwing the head too far forward. In *forward dislocation* the limb is already abducted, and should, therefore, be flexed in this abducted position. It should then be carried inwards, *i.e.*, circumducted, to make the head of the bone follow back its route towards the acetabulum, and, when the knee is opposite the pubes, the thigh should be gently rotated inwards, since the head of the bone would be, with the knee in this situation, about opposite the rent in the capsule. The limb is then extended.

For *amputation at the hip joint*, see page 338.

CHAPTER XXXIII.

THE THIGH.

MUSCLES AND THEIR ACTIONS.

NERVE ASSOCIATIONS. LANDMARKS.

BLOODVESSELS. FRACTURES.

Relations. OPERATIONS.

Muscles.—The *sartorius*, from the anterior superior spinous process of the ilium and from the adjacent part of the notch below it; into the upper part of the inner surface of the tibia and into the fascia of the leg. *Actions.*—(1) It flexes, slightly abducts and rotates outwards the thigh; (2) flexes the knee; (3) acting from below, it flexes the pelvis on the thigh.

The *pectineus*, from the pectineal line between the pubic spine and pectineal eminence, from the surface of bone in front of the line and from the pubic portion of the fascia lata; into the rough line leading from the lesser trochanter to the linea aspera. *Action.*—(1) It flexes and abducts the thigh, as in crossing the legs; (2) it acts as a slight external rotator.

The *adductor brevis*, from the body and descending ramus of the pubes; into the inner lip of the linea aspera, from just below the lesser trochanter to the middle of the back of the femur. *Action.*—It adducts, rotates outwards and slightly flexes the thigh.

The *adductor longus*, from the front of the pubes, at angle of junction of crest and symphysis; into the inner lip of linea aspera, about the middle third of the thigh. *Action.*—It adducts, flexes and rotates outwards the thigh.

The *adductor magnus*, from the outer border of ischial tuberosity, from ascending ramus of ischium and descending ramus of pubes; into the line from the great trochanter

to the linea aspera and into the linea aspera and the upper part of its inner bifurcation, while those fibres from the tuberosity of ischium are inserted, by a rounded tendon, into the adductor tubercle on the inner condyle of femur. *Action*.—It is the most powerful of the adductors and hence it flexes, adducts and rotates the thigh outwards, whereas, that portion from the tuberosity of the ischium slightly extends the femur and rotates it inwards.

The *gracilis*, from the anterior surface of the body and descending ramus of the pubes, *i.e.*, from about the middle of the symphysis down to the junction of the rami of the pubes and ischium; into the inner surface of the tibia below its tuberosity, between the insertions of the sartorius and the semi-tendinosus. *Action*.—To adduct the thigh and flex the knee.

The *obturator externus*, from the inner half of the anterior surface of the obturator membrane, from a portion of the descending ramus of the pubes and the ascending ramus of the ischium; into the digital fossa on the inner surface of the great trochanter. *Action*.—To adduct and rotate outwards the thigh.

The *Hamstring Muscles*.—*Biceps*, from the inner and posterior facet of the ischial tuberosity by the long head, and from the outer lip of the linea aspera from the insertion of the gluteus maximus above, to within two inches of the external condyle below, by the short head. This muscle is inserted into the outer surface of the head of the fibula, sending expansions to the outer tuberosity of the tibia and the deep fascia of the leg. *Action*.—It extends the thigh and flexes the knee; acting from below, it raises the body from the stooping posture.

The *semi-tendinosus*, from the inner and posterior facet of the tuberosity of the ischium; into the upper part of the inner surface of the tibia, below and behind the insertion

of the gracilis. *Actions.*—To extend the hip and flex the knee, and, acting from below, to assist in raising the body from the stooping position.

Semi-membranosus, from the anterior and outer facet of the ischial tuberosity; into the inner and back part of internal tuberosity of the tibia; into the posterior ligament of the knee, and into the fascia over the popliteus muscle. *Action.*—To extend the hip and flex the knee, and, when acting from below, to assist in raising the body from a stooping position. The peculiar arrangement of this penniform muscle, whereby the upper or proximal end is flattened, permits the free action of the biceps muscle which crosses it above, for, if it were not thus flattened, the resultant increased thickness of the muscle, when acting, would interfere with the contraction of the biceps.

Anterior Muscles.—*Rectus femoris*, from the anterior inferior spine of ilium by one head, and from the upper surface of the rim of the acetabulum by the other; into the front of the upper border of the patella. *Action.*—To extend the leg and assist in flexing the thigh.

Vastus externus, from the anterior intertrochanteric line, from the front of the great trochanter, and lower border of same, and from the outer lip of the linea aspera; into the outer half of the upper border of patella and into the upper third of its outer border. *Action.*—The same as the two following muscles.

Vastus internus and crureus, from the lower part of the line from the inner side of the neck to the linea aspera, from the inner lip of the linea aspera and the line leading from this to the internal condyle, from the whole of the external, internal and anterior surfaces of the shaft of femur, to within the lower fourth of that bone; into the posterior aspect of the upper border of the patella and into the upper half of the inner border of that bone. *Action.*

—To extend the knee, and, when acting from below, to support the femur on the tibia.

Since the shaft of the femur is directed somewhat inwards, because of the separation, above, by the pelvis, the quadriceps extensor, excepting that part formed by the vastus internus, would tend, when contracting, to displace outwards the patella, and, this, it would do, were it not for the direction and insertion of the fibres of the vastus internus, which arise lower down on the thigh than the vastus externus (the lower level of the muscular fibres of the latter being opposite a point about one inch above the external condyle, while the lower level of the former, *i.e.*, the vastus internus, is opposite a point about half an inch below the upper level of the internal condyle), and, not only is its origin lower down, but its insertion is, also, since it is inserted into the upper half, whereas, the vastus externus is inserted into the upper third of the corresponding border. It results, therefore, that, when the quadriceps extensor contracts, the inward traction of one of its constituent parts, *viz.*, the vastus internus, counteracts the tendency to outward displacement of the patella, the result of the action of the rest of the muscle.

Nerve Associations.—In connection with the nerve supply of the above muscles it is interesting to note that the adductor muscles, the gracilis and the obturator externus, which all adduct the thigh, are supplied by the third and fourth lumbar nerves through the obturator, and that the pectineus, which also adducts the thigh receives a branch from the obturator and accessory obturator. But the chief action of the pectineus is to flex the limb like the psoas, iliacus, sartorius and the rectus muscles, and, like them, it is supplied by branches from the anterior crural. Thus, muscles having similar actions are controlled by the same nerves. This is seen in the

supply to the hamstring muscles which are governed by the first, second and third sacral nerves through the great sciatic. Since these muscles extend the thigh, we would expect to find other muscles with similar actions having the same nerve supply, and this we do, in the case of the gluteus maximus and the adductor magnus, since the gluteus maximus, which extends the hip, is supplied by branches from the first and second sacral nerves, and the lower part of the adductor magnus by branches from the great sciatic. This similar nerve supply to muscles with similar actions is emphasized in the case of the adductor magnus muscle, for, while its upper fibres which *adduct* the limb are supplied, as mentioned above, from the third and fourth lumbar nerves through the obturator, its lower fibres, which *extend* the limb, are, like the other extensors, supplied by branches from the great sciatic.

Bloodvessels.—The femoral artery, the continuation of the external iliac, terminates below, where it passes through a tendinous opening in the adductor magnus muscle to become the popliteal. The femoral artery lies in front of the head of the femur, above, but at some distance from it, lower down, while, below, owing to the obliquity of the shaft of the bone, which is directed inwards towards the middle line, the artery lies close to the inner side of the bone. It is divided into common, superficial and deep femorals. The *common femoral* begins, above, immediately beneath Poupart's ligament, and ends where the other two begin, generally about one and a half inches below Poupart's ligament. *Relations.*—It lies in Scarpa's triangle, having the integument, the superficial and deep fasciæ, transversalis fascia, the crural branch of the genito-crural nerve, and the superficial circumflex iliac vein, in front; behind, it rests on the psoas tendon, which separates it from the brim of the pelvis and the cap-

sule of the hip joint; lower down, it rests on the pectineus muscle, being separated from it by some fatty tissue. Inside, is the femoral vein, and outside, is the anterior crural nerve. The *superficial femoral* is superficial, only, while contained in Scarpa's triangle, since, below this, it is covered by the sartorius. It has, in front of it, the integument, superficial and deep fasciæ, and a branch of the internal cutaneous nerve crossing it near the apex of the triangle. Behind, it has the pectineus, being separated, near the lower end of Scarpa's triangle, from the muscle, by the following structures in the order named: Femoral vein, profunda vein and profunda artery. Lower down, it lies on the upper part of the adductor longus muscle. On the outer side, is the long saphenous nerve and the nerve to the vastus internus. Inside, is the femoral vein, above, although, as the apex of the triangle is approached, this vein gradually gets behind the artery. This portion of the superficial femoral is about three and a half inches in length, while the rest of the vessel, viz., that contained in Hunter's canal, is about five inches long. *Hunter's canal* is a triangular-shaped space bounded by the vastus internus, externally, the adductor longus and magnus, internally, while, in front, is an aponeurosis, which stretches across from these boundaries and consists of transverse fibres especially marked over the lower part of the canal. The artery has in front of it, in this situation, the integument, superficial and deep fasciæ, the sartorius, the aponeurotic covering of the canal and the long saphenous nerve lying in front and to its outer side. Behind, it rests on the angle of junction of the vastus internus and the adductors, being separated from them by the vein, which gradually becomes a little external to the artery at the lower end of the canal. The *profunda* is the nutrient vessel for the thigh and arises from the outer side of the common femoral.

As it descends it gets behind the superficial femoral, being separated from it, by the veins, above mentioned, and by the adductor longus. Behind, it rests on the iliacus, pectineus, adductor brevis and adductor magnus muscles, while, externally, it is separated from the femur by the vastus internus muscle.

Landmarks.—Landmarks for the *femoral artery*.—With the thigh slightly flexed, abduct and rotate it outwards. Draw a line from midway between the anterior superior spinous process of the ilium and the symphysis pubis, or, from a point, half an inch internal to the middle of Poupert's ligament, to the adductor tubercle on the internal condyle. Another landmark would be a line drawn from the same point, above, to the inner border of the patella, when the limb is extended, *i.e.*, when parallel with its fellow: the upper two-thirds of either of these lines will represent the situation of the vessel.

Landmarks for the *femoral vein*.—A line drawn from a point, one-half inch internal to the line of the artery at the level of Poupert's ligament, to blend with the line of the artery about five inches below the ligament. For the *long saphenous vein*, a line drawn from a point about three-quarters of an inch internal to the line of the artery and about one inch below Poupert's ligament, downwards to a point behind the internal condyle of the femur, thence down the inner aspect of the leg to the dorsum of the foot, crossing the lower end of the tibia about two and a half inches above the tip of the inner malleolus.

Landmarks for the *nerves*.—*Anterior Crural*.—A short trunk, situated about half an inch external to the femoral artery, immediately below Poupert's ligament.

Great Sciatic.—A line drawn from a point a little internal to the middle of the space between the tuberosity of the ischium and the great trochanter, downwards, to the middle of the popliteal space.

Relations of the soft parts at the middle of the thigh.

—This portion of the thigh corresponds (1) to the middle of the insertion of the adductor longus; (2) to the lower limit of insertion of adductor brevis; (3) to the middle of the linea aspera, where the division into its three lips is marked; (4) to where the adductor magnus, at its insertion, crosses over from the upper half of the outer lip to the lower half of the inner lip of the linea aspera; (5) to where the aponeurotic expansion for the tendon of the biceps begins; (6) to about where the sartorius changes the direction of its fibres; (7) to where the third perforating branch of the profunda arises and perforates the adductor magnus; (8) to the origin of the branch from the long saphenous nerve to the plexus at the lower border of the adductor longus; (9) to where the long saphenous nerve reaches the front of the femoral artery; (10) to the middle of the incision for the exposure of the artery in the ligation of the vessel in Hunter's canal.

Fracture of Femur.—The neck of the femur is strengthened by a special arrangement of the cancelli, which consist of two sets—one, running up the inner portion of the shaft and then diverging, so as to end in the great trochanter and in the upper part of neck and head of femur; while the other set passes up the outer side of the shaft and terminates in gradually increasing curves that occupy the great trochanter and neck and that cross the first set at right angles. In addition to this arrangement whereby the neck of the femur is strengthened, thus enabling it to best support the weight of the body, there is present, a vertical plane called the "calcar femorale," which passes upwards towards the digital fossa, from the lower part of the base of the neck, near the lesser trochanter. The posterior wall of the neck is weaker than the anterior, since that, if it be followed from the head outwards, it is found to

split into two planes or laminae which diverge from one another, so that, while one passes in the direction of the centre of the trochanter, the other forms the remaining portion of the posterior wall, and the result of this bifurcation is, that the latter wall is much weaker and more friable than the anterior. *Fracture of the neck* may be intracapsular, extracapsular or mixed, *i.e.*, partly intra and partly extracapsular. *Intracapsular* occurs, generally, in elderly people, because of the relative weakness of the femoral neck that is present in old people, the result of the absorption of the cancelli. Merkel considers the fragility of the neck as due to the disappearance of the "calcar femorale," which, in the newly-born, is absent, but which reaches its maximum development in middle life, to disappear in old persons. Intracapsular fracture occurs, as a rule, from slight injuries, such as tripping, etc., and under these circumstances, may be the result of muscular action rather than from the effects of the fall. *Shortening* is generally present in this variety of fracture and averages about one inch and should be measured with the patient perfectly straight on a level surface and with both limbs exposed. The pelvis should be perfectly transverse and the tape should be accurately applied to the lower edge of the anterior superior spine of the ilium, above, and to the internal or external malleolus, below, and the measurement of the sound should be compared with that of the injured limb. In connection with shortening, it is necessary to consider Nelaton's line and Byrant's ilio-femoral triangle, since these terms indicate methods that are of importance in the diagnosis of certain injuries to the hip joint. The former, *i.e.*, Nelaton's line, is the line drawn from the anterior superior spine to the most prominent part of the tuber ischii. The top of the trochanter is, in every position of the normal limb, in some part of this line,

hence, should it be found that the top of the trochanter is above or below this line, it would then indicate that the great trochanter is not in its normal situation. Bryant's triangle is mapped out as follows, viz.: Drop a vertical line from the anterior superior spine to the level of the surface on which the patient lies. Draw a second line from the top of the trochanter upwards, so as to meet this vertical line at a right angle, and then, for the remaining side of the triangle, join the anterior superior spine to the top of the trochanter by a third line. The first and second lines, in a normal limb, are of equal length. This triangle is utilized, by comparing the distance from the top of the trochanter to the vertical line on the injured side, with the similar line on the sound side. Another symptom is *eversion of the foot*. This may be due to the greater loss of substance of the posterior than of the anterior wall of the neck, or to the natural inclination outwards of the foot and leg, or to the action of the external rotators. Should the foot be inverted, in all likelihood there is impaction of the fragments present, which rotates the limb inwards. In *extracapsular fracture*, the anatomical considerations above dealt with, have nearly the same bearing as in intracapsular fracture. Lastly, it must not be forgotten that a fracture of the neck may be partly intra. and partly extracapsular, since, as already mentioned, the capsule is attached about one-half or three-quarters of an inch from the posterior intertrochanteric line, and, therefore, does not cover the whole of the neck, posteriorly. *Bony union* may, but very rarely does, occur in intracapsular fracture, chiefly on account of the deficient amount of blood supplied to the head of the bone when the fragments are separated, since the circulation of this part of the bone is carried on by means of a branch of the obturator passing down the ligamentum teres to the head. It is true there

are, in addition, branches ascending in the interior of the neck, and others along the retinacula or reflected portions of the capsular ligament, but, in a fracture of the neck, the latter two sources are cut off from the head, and hence, there is not sufficient blood brought to this fragment to promote bony union. Another possible explanation is, that, since the neck is surrounded by synovial membrane, and, since there is always more or less synovitis present in fracture of the neck, it is, therefore, possible for the effused fluid to wash away the exudate necessary for callus formation, and, lastly, the movement, more or less permitted, between the fragments might prevent bony union.

Fracture of the Shaft.—The shaft is most often broken in the middle third and generally in the upper part of this portion of the bone. According to Hamilton, out of 146 cases of fractured femur, thirty belonged to the upper third, eighty to the middle and thirty-six to the lower third. The direction of the obliquity varies, being, generally, downwards and inwards, in the upper and middle thirds of the shaft, and downwards and forwards, in the lower third, and when union occurs, there is, generally, a shortening of from one-half to three-quarters of an inch, excepting in children in whom very little shortening can, as a rule, be detected.

Displacement, when due to muscular action, in fracture of the thigh, may be explained as follows: When the fracture is *near, or at the neck of the bone*, the contraction of the glutei, adductors and pectineus, the rectus, gracilis, sartorius, biceps, semi-tendinosus and semi-membranosus draw up the lower fragment and produce shortening of the limb. When the fracture is situated immediately *below the lesser trochanter*, the upper fragment is flexed by the action of the psoas and iliacus, rotated outwards by the external

rotator muscles along with the glutei, and abducted by the latter muscles. This position of the upper fragment produces a prominence at the upper and outer aspect of the thigh, while the lower fragment is drawn upwards by the adductors, the pectineus, gracilis, rectus, sartorius, biceps and the other hamstring muscles; inwards, by the adductor muscles and pectineus and everted or rotated outwards by the same muscles. A fracture through the *middle of the shaft* would present displacement similar to the above, but, when the break occurs *immediately above the condyles*, then the lower end of the upper fragment is thrust forward, against or through the fibres of the rectus muscle, by the contraction of the psoas, iliacus, pectineus, adductor brevis and adductor longus. This upper fragment is also adducted or drawn inwards by the pectineus and adductor muscles, which are more powerful than the abductor muscles, *i.e.*, the glutei, and is rotated outwards by the pectineus, the adductors, the glutei, and by the direct external rotators. The lower fragment is tilted back by the action of the gastrocnemius and plantaris muscles, and drawn upwards by the muscles referred to above, when speaking of fracture below the lesser trochanter, *viz.*, by the adductors, the pectineus, gracilis, rectus, sartorius, biceps and the other hamstring muscles. In this displacement, it is possible for the popliteal vessels to be wounded, especially the vein, by the upper end of the lower fragment, and further, when the attempt is made to straighten the limb by traction on the leg for the purpose of reducing the fracture, the gastrocnemius tends to draw back the lower fragment still more, hence the need of an inclined plane to relax the gastrocnemius in the treatment of this fracture. Some surgeons divide the tendo Achilles to prevent this backward traction of the gastrocnemius.

Operations.—*Excision of the Hip Joint.*—Unless contraindicated, the best incision for exposing the hip joint is Barker's, whereby the joint is opened from in front. *Operation.*—The incision, about three inches in length, starts about half an inch below and a little outside of the anterior superior spinous process, and is made downwards and slightly inwards, passing between the sartorius and the tensor vaginæ femoris. On separating these muscles the outer edge of the rectus is identified, and the knife passes through a quantity of areolar tissue between this muscle and the gluteus minimus, dividing, generally, a small branch of the external circumflex artery. The capsule of the joint is opened, by this incision, where it overlies the middle of the neck of the femur and the diseased portion of the bone is then removed.

Amputation at the Hip Joint.—Of the different methods of hæmostasis employed in this operation, none can compare with the simplicity and effectiveness of that of Wyeth's. Amputation by this method is performed as follows: Two large mattress needles, each about ten inches in length, are employed; one, introduced one inch below and slightly to the inner side of the anterior superior spinous process, traverses the muscles and fasciæ on the outer side of the hip, to emerge on a level with, and about three inches from the point of entry. The other is inserted about one inch below Poupert's ligament, a little to the inner side of the saphenous opening, and, passing transversely backwards through the adductor muscles, emerges about one inch below the tuberosity of the ischium. The points of the needles are now protected by bits of cork, and a piece of rubber tubing, half an inch in diameter and long enough to go around the thigh five or six times, is wound tightly around the hip above the fixation needles. An incision is then made around the limb

and about six inches below the tourniquet and is joined by a longitudinal one commencing at the tourniquet. The integument and superficial fascia are dissected up as far as the trochanter minor, at which point the remaining soft parts are divided down to the bone. The vessels are ligated, the soft parts separated up to the joint, and the whole limb, being used as a lever, is forcibly flexed, abducted and adducted, to permit the entrance of air into the joint after the capsule has been opened, and to rupture the ligamentum teres, after which the disarticulation is completed.

Operations on *Arteries*.—*Compression*.—Compression of the femoral is best made immediately below Poupart's ligament, since, at this point, the artery is separated from the pubic bone by the psoas muscle, only. The pressure should be directed backwards against the bone. In the middle third of the thigh the pressure should be directed from within outwards, because of the relation of the vessel to the bone in this portion of the thigh, lying as it does, to the inner side.

Ligation of the *common femoral*, is rarely, if ever, done, since there is always an uncertainty as to the height at which this vessel bifurcates. Further, because of the number of branches given off from this artery, it would be unwise to make the attempt, unless extraordinary circumstances would warrant it, since a clot might not form, and secondary hemorrhage, therefore, result. Again, since the common femoral is the main bloodvessel of the limb, gangrene might follow if this vessel were ligated. *The superficial femoral*, therefore, is generally elected, and the best situation at which to apply a ligature to it, is at the apex of Scarpa's triangle. Ligation of this vessel is done for wounds, or for popliteal, or lower femoral aneurism. *Operation*.—An incision is made through the integument and superficial fascia in the line of the vessel and about three

inches in length, so that, its centre shall correspond to the apex of Scarpa's triangle. A large branch of the long saphenous vein, the external femoral cutaneous, will be exposed and may have to be divided between two ligatures, if it cannot be drawn aside. The deep fascia is incised and the sartorius is exposed. This muscle will be identified by the direction of its fibres, running as they do, downwards and inwards. Should fibres be met with, passing downwards and outwards, they are part of the adductor longus muscle and the artery must be sought for, farther outwards. The sartorius is drawn outwards, and the finger seeks for the pulsation of the vessel. Branches of the internal cutaneous nerve will be found in front of the artery while the nerve to the vastus internus and the long saphenous will lie on the outer side of the vessel. The sheath of the vessel is opened and the needle passed from within outwards.

Ligation of the Femoral in Hunter's Canal.—An incision about three inches in length is made along the line of the artery about the middle third of the thigh. After the division of the superficial fascia, in which run, nearly in line with the incision, the anterior branch of the internal cutaneous nerve and the long saphenous vein, the deep fascia is brought into view, and, on being incised, the sartorius is exposed, and, having been identified by the direction of its fibres, which, here, run vertically downwards, is drawn inwards. Should the fibres of the muscle, that presents itself, run, downwards and outwards, it is probably the vastus internus that is exposed, especially if the incision has been made too far outwards, or it may be the adductor longus, if the incision be too far inwards; the situation of the artery as evidenced by the pulsations, will assist in telling whether it be the one or the other muscle, and, in which direction to continue the dissection. After

drawing aside the sartorius, areolar tissue presents itself, and, this being incised, the transversely directed fibres of the aponeurosis, which forms the roof of Hunter's canal, and is especially marked in its lower two-thirds, is recognized. The sheath is opened, well to the inner side of the front of the artery, and the needle passed from without inwards, being closely applied to the artery to avoid the femoral vein, which, here, is adherent to the back and outer side of the vessel. The long saphenous nerve which lies in front and to the outer side of the artery, in the canal, can be easily avoided.

Collateral circulation after ligation of the superficial femoral artery, is carried on, chiefly by means of, (1) the descending branches from the internal and external circumflex anastomosing with the anastomotica magna and the superior articular branches of the popliteal; (2) the perforating and terminal branches of the profunda with the articular branches of the popliteal, and (3) branches of the comes nervi ischiadici communicating, on the popliteal nerves, with branches from the popliteal and posterior tibial arteries.

Ligation of the Gluteal Artery.—This artery is very rarely ligated, but, should it be necessary, an incision is made along the line of the landmarks for the vessel, viz., along a line drawn from the posterior superior spine of the ilium to the posterior superior angle of the great trochanter when the thigh is rotated inwards. The centre of the incision should correspond to the exit of the gluteal, referred to in landmarks for the gluteal region, viz., at the junction of the upper and middle thirds of this line. The gluteus maximus is incised in the direction of the incision, which corresponds also to the direction of the fibres of this muscle. The posterior border of the gluteus medius is separated from the upper border of the pyri-

formis, and the upper margin of the sciatic notch is identified, and the artery sought for, at this point, and ligated.

Operations on the *Nerves*.—The *anterior crural*, as already mentioned, lies about half an inch external to the femoral artery at Poupart's ligament. To expose it, make a vertical incision in the line of the nerve, dividing the superficial circumflex iliac vessels and the crural branch of the genito-crural nerve. The deep fascia is then incised and the nerve sought for, immediately below Poupart's ligament, between the psoas and iliacus muscles. The *great sciatic* is situated on the back of the thigh. It extends from its exit from the pelvis, at the lower border of the pyriformis muscle, to a point, a little below the middle of the thigh, where it generally divides into internal and external popliteal nerves. The great sciatic is covered by the gluteus maximus and the hamstring muscles, and rests on the external rotators and on the adductor magnus. (The small sciatic nerve is in the same line as the great sciatic, but superficial to it.) To expose the great sciatic nerve for the purpose of stretching it, make an incision, a little external to the course of the nerve. After incising the superficial and deep fasciæ, the lower border of the gluteus maximus is exposed and drawn upwards, the hamstring muscles next present themselves and should be drawn inwards, the knee having been previously flexed to relax them, and the nerve will be found lying beneath these muscles.

Amputation of the Thigh.—*General Considerations*.—The integument of the thigh is loosely attached to the subjacent tissues, and hence, retraction of the skin flaps, in amputation, is pronounced. Along the groove between the vastus externus and the hamstring muscles, however, the skin is more firmly united to the deeper parts. In a section through the thigh, at its upper third, the bone is even-

ly covered with muscles. In a transverse section through the middle of the femur, the bone is about the centre of the section and is also evenly surrounded by muscles. The biceps and semi-tendinosus are here separated from the bone, the adductor longus is small and the brevis has disappeared. In a transverse section, at the lower third of the thigh, *i.e.*, about a hand's breadth above the knee, the bone is nearest to the anterior surface of the section. In antero-posterior flaps, the femoral artery is found in the anterior flap if the amputation be above the middle of the limb, but in the posterior, if below that point. The medullary cavity occupies the middle two-fourths of the shaft.

Amputation through the thigh may be performed by means of circular, modified circular or by antero-posterior flaps. In the circular method the flap should be a little longer on the inner and posterior aspects, because of the retraction that takes place, owing to the number of muscles unattached here, and if this precaution be not taken the subsequent contraction will draw the muscular coverings of the bone upwards and backwards, and a conical stump result. The best method, however, for amputation of the thigh is by a long anterior, and a short posterior flap. The anterior flap being equal, in length, to a diameter and a half of the limb at the saw line, and the posterior flap, to a length, one-half of the diameter, at the same level. The flaps are made and retracted, the muscular structures divided from without inwards, and the bone sawn through.

CHAPTER XXXIV.

THE POPLITEAL SPACE.

DESCRIPTION.

RELATIONS OF CONTENTS.

LANDMARKS.

BURSITIS.

ANEURISM,

OPERATIONS.

Description.—This space is bounded, above, by the divergence of the outer and inner hamstring muscles, viz., the biceps on the outer side, and the semi-membranosus, semi-tendinosus, gracilis and sartorius on the inner side. It is bounded, below, on the outer and inner sides by the outer and inner heads of the gastrocnemius respectively. The floor is formed by the lower part of the posterior surface of the femur, by the posterior ligament of the knee joint, by the posterior surface of the upper end of the tibia, and by the fascia covering the popliteus muscle; whereas the roof is formed by the deep fascia of the leg, the superficial fascia and the integument, in which are found cutaneous branches of the small sciatic nerve that supply the superficial structures, and the external or short saphenous vein that pierces the deep fascia at the lower angle of the space to enter the popliteal vein.

Relations of Contents of the Space.—The internal popliteal nerve lies in the middle line of the space, immediately beneath the deep fascia and continues, downwards, the line of the great sciatic nerve. Beneath the internal popliteal nerve is some areolar tissue which contains a lymphatic gland; next to this is the popliteal vein, while, lying internal to the nerve and below and a little internal to the vein is the popliteal artery, with its articular branches, and a lymphatic gland, on either side, embedded in areolar tissue. Occasionally a gland is present, situated beneath the artery, between it and the bone, while

the articular branch of the obturator nerve lies on the artery. On the outer side of the space, under cover of the biceps tendon, is the external popliteal nerve, while, on either side, among the tendons are the different popliteal bursæ. The biceps muscle, forming part of the outer boundary, is readily recognized beneath the skin, by the finger; whereas, on the inner side, the muscular bulk is composed, superficially, of the semi-tendinosus, the long rounded tendon of which may be felt, as a rounded cord, running downwards and inwards, and of the semi-membranosus, which lies beneath and is broader than the semi-tendinosus and which may be felt projecting about half an inch on either side of the latter tendon, while, most internal of all is the gracilis. The *internal popliteal nerve* passes through the middle of the popliteal space and is termed the posterior tibial at the lower extremity of the space. It is separated by areolar tissue from, and lies to the outer side of the vessels above the level of the knee joint, but, below this, it is in close relation with them, and gradually crosses them, so that, at the lower end of the space, it lies internal to the vessels. This nerve sends articular branches, which accompany the internal articular and the azygos articular arteries; muscular, which supply the gastrocnemius, plantaris, soleus and popliteus, and, lastly, a branch which forms, with the corresponding branch from the external popliteal, the short saphenous nerve which accompanies the short saphenous vein. The *external popliteal nerve* lies parallel with and slightly behind the inner border of the biceps muscle. As it descends it diverges from the middle line and is best recognized by the finger on a level with the most prominent part of the posterior surface of the internal condyle. Above this point, it is possible to identify it by the sensation imparted when the nerve is pressed upon, but, below this,

it sinks in between the biceps tendon and the outer head of the gastrocnemius, so that, it is only possible to elicit the sensation peculiar to the nerve when compressed, by sinking the nail of the finger or thumb, deeply, immediately above the styloid process of the fibula. *The lymphatic glands* receive the deep lymphatic vessels, which accompany the bloodvessels of the back of the leg, and, in addition, the superficial lymphatics from the superficial structures of the back of the leg and sole of the foot. The efferent vessels from these popliteal glands terminate in the deep femoral or inguinal glands. *The popliteal vein* is formed by the union of the venæ comites of the anterior and posterior tibials at the lower border of the popliteus muscle. At the lower part of the popliteal space it is a little internal to the artery, but gradually crosses it, being firmly bound down to it by the fascial sheath of the vessel, so that, at the upper end of the space, it lies external to the artery. *The popliteal artery*, the downward continuation of the femoral, ends at the lower border of the popliteus muscle, where it divides into anterior and posterior tibial.

Relations.—In its passage through the popliteal space it rests upon the popliteal surface of the femur, on the posterior ligament of the joint, on the tibia and on the fascia covering the popliteus muscle. Behind; are the semi-membranosus muscle, the popliteal vein, internal popliteal nerve, inner head of the gastrocnemius, the articular branch of the obturator nerve, and a lymphatic gland, with the integument, the superficial and the deep fasciæ overlying them. Inside, are the semi-membranosus, above, and the inner head of the gastrocnemius, and the internal popliteal nerve, below. Outside, are the biceps and the internal popliteal above, with the outer head of the gastrocnemius and the plantaris below.

Landmarks.—For the *Popliteal Artery*.—To represent the upper part of the popliteal artery, draw a line from the outer border of the semi-membranosus at the junction of the middle and lower thirds of the thigh, obliquely downwards to the middle of the popliteal space opposite the line of the knee joint. The lower part of the vessel would be represented by a line joining the lower end of the above line with a point opposite the lower border of the tubercle of the tibia, since this is the landmark for the termination of the vessel. Landmarks for the *superior articular arteries*.—A line passing transversely from the line of the artery, on either side, immediately above the condyles of the femur. For the *inferior internal articular* vessel.—Draw a transverse line inwards from the line of the artery and passing immediately below the inner tuberosity of the tibia, while for the *inferior external articular*, draw a line outwards, from the line of the popliteal, immediately above the head of the fibula. Landmarks for the *internal popliteal nerve*.—Draw a line downwards in the course of the continuation of the great sciatic nerve, already referred to, and crossing the line for the popliteal artery opposite the line of the joint. For the *external popliteal nerve*.—Draw a line from the preceding, starting about opposite the junction of the middle and lower thirds of the thigh, and continue it downwards and outwards to a point, a little in front and outside of the styloid process of the fibula. The lines for the nerve, artery and vein correspond in the middle of the popliteal space opposite the joint line, but, above, the line for the nerve is a little over half an inch external to the commencement of the artery, so that the order of the chief structures found in the upper part of the popliteal space is, both from behind forwards and from without inwards—*nerve, vein and artery*.

Bursitis affecting the *Popliteal Bursæ*.—On the *outer* side of the popliteal space there are four bursæ: (1) One beneath the outer head of the gastrocnemius; (2) one between the biceps tendon and the external lateral ligament of the knee joint; (3) one between this ligament and the popliteus tendon; (4) one between the latter tendon and the outer condyle of the femur. On the *inner* side five are usually found: (1) One beneath the gastrocnemius, sending a projection between it and the semi-membranosus; (2) one beneath the sartorius, gracilis and semi-tendinosus and between them and the internal ligament; (3) one between this ligament and the tendon of the semi-membranosus; (4) one between the latter muscle and the head of the tibia; (5) one between the tendon of the semi-membranosus and that of the semi-tendinosus. Of those on the inner side of the space, the most important is the one beneath the inner head of the gastrocnemius and between it and the semi-membranosus. This was found affected twenty times out of thirty cases of bursitis in this region collected by Foucher; while, of the outer bursæ, the one beneath the biceps tendon is also of practical importance, since it is situated beneath the tendon, just above the head of the fibula, and the external popliteal nerve is stretched over it, so that, symptoms of disturbance of this nerve, such as numbness, pain, etc., may present themselves when this bursa is inflamed.

When the bursa between the gastrocnemius and the semi-membranosus is enlarged, it may be mistaken for a popliteal aneurism. This bursa often communicates with the knee joint, since, as Foucher found, out of twelve cases of inflammation of this bursa, a communication with the joint was present in six of them. When enlarged, it may extend inwards towards the middle line of the space, and, receiving pulsation from the popliteal artery, may simu-

late an aneurism. To assist in differentiating a bursitis in this situation from an aneurism, it is worthy of note, that the pulsations conveyed to the finger are more evident, in bursitis, when the limb is extended, whereas, they are better appreciated, in aneurism, when the limb is flexed. The reason being that, when the limb is extended in bursitis, the popliteal fascia is rendered more tense and, therefore, presses the bursa more firmly upon the artery with the result that the force of the pulsations is increased; whereas, when the limb is flexed, the pressure on the bursa being relieved, the pulsations are less evident. The pulsations of an aneurism, however, are more pronounced, when the limb is flexed, since, the flexion relaxes the popliteal fascia and the finger can, therefore, better appreciate the aneurismal sac and its pulsation. Again, compression of the femoral artery lessens, to a very slight degree, the size of a bursa; whereas, it lessens, to a marked degree, the size of an aneurism. In many cases, this bursa is connected with the joint, and hence, the contents may be gently pressed into the cavity of the joint, when the limb is slightly flexed, since this position enlarges a slit-like opening which communicates with the joint and which is probably closed when the limb is extended. The possibility of many of these bursæ communicating with the joint should always be kept in mind, in operating them, because of the danger of subsequent infection of the articulation.

Aneurism.—There are a number of reasons that influence the production of an *aneurism* of the popliteal artery: (1) The effects of extension or flexion of the leg on the calibre of the vessel. That the position of the limb has an influence on the size of the vessel is evident from the fact, that extreme flexion may entirely occlude the artery, as shown by Maunoir—this is taken advantage of

in the treatment of popliteal aneurism by means of forced flexion. Hence, flexion and extension of the limb may predispose towards popliteal aneurism by frequently altering the size of the vessel. (2) The absence of muscles closely surrounding and, therefore, supporting the artery. (3) The alteration in the current of the blood, the result of the division of the artery, at this point, into two large branches. (4) The curve in the artery—the femoral portion of the popliteal space is deeper than the tibial, hence, it follows, that the vessel must suddenly curve backwards, from the femur, to arrive at the higher plane on the tibia.

Operations.—*Tenotomy* of the hamstring muscles may be performed for pseudo-ankylosis, when these tendons are permanently contracted, and, when this operation is employed, the tendons are generally divided on a level with the most prominent part of the femoral condyles. When the bicipital tendon is to be divided, the sharp tenetome is introduced on the inner side of, and close to the tendon, and the blunt tenetome, following it, is turned towards and divides the tendon. In the insertion of the sharp tenetome it is essential that both this tendon and the external popliteal nerve, that runs along its inner and posterior border, should be clearly identified. As a rule, when the conditions demand a tenotomy of the biceps, the latter is so prominent, that the nerve is left behind, *i.e.*, is more deeply situated, with reference to the tendon, than usual, but, even though this is likely to be the case, yet the normal relation of nerve and tendon should be kept in mind when operating on the latter. When the semi-tendinosus and the semi-membranosus are to be divided, the knife should be introduced at a spot, opposite the site of the incision, employed for the division of the biceps.

Ligation of the popliteal artery, at its upper part, is done through an incision about three inches long just behind the tendon of the adductor longus. The anterior branch of the internal cutaneous nerve and the long saphenous vein may be exposed in the line of the incision and should be avoided; the deep fascia is incised in front of the sartorius muscle, which is then drawn backwards, and the white tendon of the adductor longus is identified and drawn forwards; the semi-membranosus is drawn back and the artery sought for, between this muscle and the bone and close to the latter. By this incision the artery is approached from the inside and is reached without necessarily exposing the popliteal nerve or vein. Care should be exercised in passing the needle around the artery since the vein is very adherent to the vessel and might be wounded.

CHAPTER XXXV.

THE REGION OF THE KNEE JOINT.

MOVEMENTS.	TUBERCULOSIS.
LANDMARKS.	MOVABLE BODIES.
ANTERIOR BURSÆ	PATELLA.
SYNOVITIS.	DISLOCATION.
OPERATIONS.	

One would be led to think, on examining the skeleton, that dislocation at the knee joint would be very common, since this joint is formed by the large, lower extremity of the femur resting upon the tibia, and is not protected, in the same manner, as is the hip or elbow joint; but the great strength imparted to the articulation by the powerful ligaments connected with it, causes displacement to be, relatively, very rare. The space left between the ligamentum patellæ and the lateral ligaments, in front of the joint, is filled up with the capsular ligament, strengthened by lateral prolongations, or accessory bands, from the extensor tendons, while, behind, the posterior ligament is augmented by a number of fasciculi from the semi-membranosus tendon, and, further, the two crucial ligaments in the interior of the joint give additional strength to the articulation and are important factors in preventing dislocation.

The **Movements** permitted at the knee joint are flexion and extension, accompanied by a slight amount of rotation. Flexion and extension result from the gliding of the tibia beneath the femoral condyles, but the character of these movements causes them to differ from the movements permitted in a pure hinge joint, like the humero-ulnar articulation. In the latter joint, the ulna moves on a stationary axis, passing through the trochlear surface

of the humerus; whereas, in the knee joint, the axis, on which the tibia moves, shifts its position, so that, in extension, the anterior part of the articular surface of the tibia is in contact with the femoral condyles, while, in extreme flexion, the posterior portions are in contact. This is brought about by means of the gliding of one bone under the other. If the termination of the movement of extension be closely watched, it will be seen, that just before its completion, the leg and foot are suddenly turned or rotated outward, and, on the commencement of the movement of flexion, the leg and foot move primarily inwards, before flexion is well started. These movements of eversion and inversion are caused by the direction of the anterior articular surface of the internal condyle, which is inclined obliquely outwards. In addition to the above, there are two movements, that might be termed, pronation and supination, and that can occur in the semi-flexed position only, since, in this position, the ligaments are relaxed. These movements take place between the tibia, below, and the interarticular fibro-cartilages, above—the axis being vertical and passing through the spine of the tibia—whereas, the movements of flexion and extension, as well as that of rotation, spoken of above, as occurring at the end of extension and the beginning of flexion, take place between the femur, above, and the interarticular fibro-cartilages, below. In extension, all the ligaments of the joint are on the stretch, with the exception of the ligamentum patellæ and the anterior portion of the capsular, whereas, in ordinary flexion, all are relaxed, excepting the patellar ligament and the front of the capsule. The crucial ligaments strongly bind together the femur and the tibia; the anterior preventing over-extension, and the posterior over-flexion, and, in addition, both assist the lateral ligaments in preventing any lateral bending at the joint.

Landmarks.—In the middle of the anterior aspect of the joint is the patella. Above the patella is a depression which corresponds to the tendon of the quadriceps extensor, while, continued downwards from it, is the ridge formed by the ligamentum patellæ. On either side is a hollow corresponding to the insertion of the vasti muscles and to the anterior part of the capsule of the joint. When the limb is extended, the upper border of the patella is on a level with a point, about three-quarters of an inch above the upper limit of the articular surface of the femur; whereas, the lower border is opposite a point, about a quarter of an inch below the line of the joint. On the inner aspect of the joint, a prominence, which is rounded in form, can be felt. This is the internal condyle of the femur. The summit of this condyle is termed the inner tuberosity and is situated about one and a quarter inches above the line of the articulation. On the upper part of the condyle another prominence is evident—the adductor tubercle, which receives the insertion of the tendon of the adductor magnus. Immediately beneath this condyle is the depression, between the femur and the tibia, which indicates the line of the articulation on the inner side of the joint. The thumb nail, pressed along this line, will elicit tenderness in injury to the internal semilunar cartilage, or will ascertain whether the cartilage be absent or not, from its position, in cases presenting symptoms of a moveable body within the joint. Externally, the finger comes in contact with the prominence formed by the tuberosity of the external condyle, while, below it, is a slight depression from which arises the tendon of the popliteus muscle. Immediately beneath this depression, a thin ledge is evident (the lower margin of the condyle), and below this is the external line of the articulation, with the tuberosity of the tibia and the head of the fibula immediately beneath. The relative situation

of the latter prominences is as follows: The outer tuberosity is about three-quarters of an inch above the line of joint; the anterior portion of the upper border of the fibular head is three-quarters of an inch below the line of the joint, whereas, the styloid process of the fibula is a little less than half an inch below the joint line. The *epiphyseal* line for the lower end of the *femur* runs transversely outwards from the adductor tubercle on the upper part of the internal condyle, and skirts the upper border of the articular surface; that for the *tibia*, runs towards the middle line of the bone immediately below the tibial tuberosities and includes, therefore, the articular facet of the tibia. As these lines approach the middle of the bone, they descend and meet at the lower border of the tubercle of the tibia, so as to include it in the epiphysis. Behind the *upper third* of the ligamentum patellæ is the synovial membrane of the joint, separated from the ligament, however, by a pad of areolar tissue and a portion of the capsular ligament. In the space behind the *middle third* of the patellar ligament, and between it and the anterior surface of the head of the tibia, is areolar tissue; while, behind the *lower third* of the ligament, and between it and the upper part of the tubercle of the tibia, is the pretibial bursa. This bursa, however, frequently extends upwards behind the middle third of the ligament.

Bursæ in the anterior region of the knee joint.—

The following bursæ are found in this situation: (1) *One*, beneath the quadriceps extensor tendon. The upper limit of this bursa is about two inches above the upper border of the patella, while the lower limit is about one inch above that bone. When this bursa is distended, it forms a swelling, which is transverse to the axis of the limb, and is about one inch, or more, in depth. This bursa frequently communicates with the joint through a variable-

sized orifice, so that, inflammatory actions starting in the former will, in the majority of cases, affect the latter, also—a point that should be borne in mind in wounds of the anterior aspect of the lower part of the femur. (2). *A second*, in front of the lower portion of the patella—the prepatellar bursa. This extends over the upper part of the ligamentum patellæ as well, and may be acutely or chronically inflamed, in those whose occupations necessitate frequent kneeling, as stone-masons, housemaids, etc., hence the term “housemaid’s knee.” This prepatellar bursa is occasionally traversed by one or more septa, with the result, that, when inflamed, more or less irregularity in shape is produced. Pain is frequently complained of, in inflammation of this sac, on account of the distention stretching the patellar plexus of nerves, which is composed of branches from the internal, middle and external cutaneous and from the long saphenous nerves. (3) *A third*, beneath the lower third of the ligamentum patellæ and between it and the upper part of the tubercle of the tibia—the pretibial bursa. This bursa is occasionally distended in rapidly growing boys, about the age of puberty, and can be diagnosed by the fact, that the swelling bilobed—the ligamentum patellæ being stretched over it—and hence, fluctuation may be elicited from one side of the ligament to the other in this situation.

Synovitis.—In *synovitis*, the effusion distends the depression, normally present on either side of the tendon of the quadriceps extensor, patella and the ligamentum patellæ, so as to obliterate these depressions, and, since the capsular ligament between the ligamentum patellæ and the lateral ligaments, is the most lax part of the ligamentous structures of the joint, it follows that the swelling is most marked on either side of the patella and of the upper part of

the patellar ligament, and, further, that fluctuation, from one side of these structures to the other is readily elicited. In synovitis, the patella is raised up from the trochlear surface, on which it normally lies, so that, on pressure backwards over it, it feels as though it rested on a "water-bed." When, in synovitis, a constriction appears about one inch above the patella with a swelling immediately above it, it means that there is a communication present between the sub-quadriiceps bursa and the knee joint.

Tuberculosis of the knee joint, in the young, appears first, as a rule, in the bones of the articulation and in the following order, viz.: Femur, tibia and patella; whereas, in the older patient, the disease very often begins in the synovial membrane of the joint. When the bone is affected, movement, in the early stages at least, causes very little pain, but when the synovial membrane is diseased, pain on movement is excessive. When the disease begins in the synovial membrane there is a point of maximum tenderness, according to Barwell, in front of the internal condyle, about half an inch internal to the patella. In the young, the disease may start beneath the encrusting cartilage, or in the neighborhood of the epiphyseal line, causing early enlargement of the epiphysis and tenderness along the epiphyseal line. Abscess was present, according to Gibney, in one hundred and forty out of three hundred cases of tuberculosis of the knee joint, and it must not be forgotten that such abscesses may burrow towards and open upon the skin, without involving the interior of the joint at all, so that, the less severe operation of curetting the diseased bone may save an incision of the joint. In *inflammatory affections* of the knee joint flexion is generally present. This flexion, in synovitis with effusion, may depend on the fact that, when the leg is semi-flexed, the cavity of the joint contains a greater amount of fluid,

than when it is extended, or when, even extremely flexed, or the flexion may be due to the tendency to put the least possible tension on the ligaments, since, when semi-flexed, these, with the exception of the ligamentum patellæ and the anterior part of the capsule, are all relaxed. The cause of the flexion, however, may be the reflex irritation of the nerves supplying the muscles that control the joint, since these muscles are governed by the same nerves that supply the articulation, and hence, when they are reflexly contracted, flexion results, since the hamstring are more powerful than the extensor muscles. When heat, or cold, or blisters, etc., is applied to the knee joint, the beneficial effect that generally follows, may be due to reflex stimulation of the nerves *i.e.*, the plexus patellæ, or, it may be dependent on dilatation of the superficial bloodvessels of this region, and, since these superficial arteries are branches of the deep arteries that supply the interior of the articulation, it follows that dilatation of the former will, to some extent, at least, withdraw the blood from the latter, *i.e.*, will lessen the congestion of the interior of the joint.

Movable Bodies in the joint may be portions of cartilage, or remnants of embryonic tissue which have, later on, developed so as to produce tags projecting into the interior of the articulation, or they may be synovial processes, the result of chronic inflammation of the serous membrane, or, lastly, detached nodules in cases of rheumatoid arthritis. These movable bodies may slip between the contiguous bones and cause a sudden, extreme pain, with fixity of the limb, due to a reflex spasm of the muscles. When the leg is flexed and the biceps strongly contracted; as in the act of kneeling, the inner tuberosity is slightly separated from the femur, and this position favors

the "nipping" of the movable body between the bones. The semilunar cartilages may, very rarely, be "nipped," and of the two, the internal is the one usually affected, since the inner tuberosity of the tibia can be separated from the femur by the action of the biceps, as already mentioned.

The Patella.—The patella protects the front of the joint and increases the leverage of the quadriceps extensor by making it act at a greater angle. Its posterior surface has seven facets: One, the inner, being in contact with the internal condyle in all the movements of the joint; while the others are arranged, in pairs, so that, in extension of the leg, the lower pair rests on the upper portion of the trochlear surface of the femur; in mid-flexion, the middle pair rests on the middle of the trochlear surface while, in flexion, the upper pair rests on the lower part of this surface. Thus the points of contact of the patella with the femur change, just as those of the tibia and femur do, in flexion and extension.

Fracture of the Patella.—Hamilton states that muscular violence, *i.e.*, sudden forcible contraction of the quadriceps extensor is responsible for the break in a transversely fractured patella, and that, when so occurring, the fracture is generally in the lower third of the bone. The explanation of this is, that, in midflexion—the position in which the limb generally is, when fracture occurs—the middle of the patella rests on the middle of the trochlear surface, leaving, therefore, the upper and lower portions of the bone unsupported, and hence, the lower portion, being the weaker, may give way from any sudden, severe strain. Stellate fractures of the patella generally result from the application of direct violence. Bony union in these fractures is very rare, partly from the pre-

patellar aponeurotic structures falling in between the fragments, and thus preventing their proper approximation, and partly because of the separation that results. This separation of the fragments depends on the degree of laceration of the aponeuroses on either side of the bone. As a rule the lesion is confined to the bone, and to its periosteal coverings along with the thin and scattered fibres of the tendon of the quadriceps, that pass in front of the patella to become continuous with the ligamentum patellæ below, and when thus confined to the bone and the fascia over it, the separation is rarely more than half an inch, but, when, in addition, the lateral aponeuroses are extensively torn, the separation may be two inches or more (MacEwen). Occasionally, in fracture, the prepatellar bursa, the posterior wall of which is in direct contact with the fibrous investment of the patella, communicates with the joint cavity, since this wall is torn by the separation of the bony fragments. In the operative treatment of fractured patella, it is always necessary to cut away these aponeurotic structures that overlie the fragments, and to suture the lateral aponeuroses, if torn.

Dislocation at the *knee joint* is very rare, partly because of the breadth of the ends of the bones that enter into the formation of the joint, but, chiefly, on account of the great strength of the ligaments that bind the bones together. When dislocation occurs, the head of the tibia may be displaced backwards, forwards, inwards or outwards. In *backward displacement*, the head of the tibia is felt in the popliteal space, and a depression, immediately below the patella, exists in front of the joint, while the leg is, generally, in a state of extreme extension. *Condition of the soft parts.*—The posterior ligament is torn, the hamstring muscles and the popliteal vessels and

nerves are stretched, while all the ligaments of the joint, with the exception, possibly, of the patellar, are tense or torn. *Forward displacement.*—The condyles of the femur are felt behind, while the patella, the tibia and the fibula are prominent in front, and the soft parts are injured as in the preceding dislocation, the patellar ligament, however, being torn as well as the other ligaments.

Dislocation of the patella is very rare, but, should it occur, the bone is generally displaced outwards. This is due to a sudden, severe strain being put on the quadriceps extensor, and, especially, on the external portion of it, as for instance, in suddenly twisting the thigh, inwards, while the weight of the body rests on the foot. Most frequently, however, the dislocation is only partial, the inner half of the patella resting on the articular surface of the outer condyle.

Operative Work on the knee joint.—**Excision** of the knee joint may be either partial or complete. Partial excision is termed arthrectomy, and may be employed in even the advanced stages of the disease, so that, complete excision of the articulation is very rarely performed. *Partial excision*, or arthrectomy, means the scraping away of all diseased structures, especially the synovial membrane, and the best incision to employ, is one starting on each side of the lower portion of the patella and running towards the respective condyle. Should it be found that more room is required, then a cross incision may be added over the front of the patella, and this bone divided, transversely, so that, after the removal of the diseased tissues, it may be united again—thus preserving the function of the quadriceps extensor muscle. *Complete excision.*—Should it be found advisable to do the complete operation, the above incisions may be utilized if the attempt has first been made to do a par-

tial excision; or, the incision may start at the posterior margin of one condyle and pass, in a convex manner, across the front of the articulation, below the patella, dividing the ligamentum patellæ near its insertion, and terminating at the posterior margin of the outer condyle. The knee is now flexed, the patellar ligament and the anterior parts of the capsule, along with the patella, turned up, the leg still more flexed, the lateral crucial ligaments divided and the lower part of the femur excised. In connection with this step, *i.e.*, sawing the femur, the axes of the two main bones of the leg must be borne in mind. The two bones (femora), which are separated above by the pelvic bones, approach the middle line, below, while the tibiæ, on which the femora rest, are vertical, and hence, when the bones are sawn, it is necessary to preserve this relationship, so that, for the femur, the saw should be applied, in the antero-posterior direction, at right angles to the axis of the shaft, for, if this were not done, then the tibia, uniting with the obliquely sawn femur, would be directed so, that the foot would be much in front of or much behind its normal position. Again, the saw should be applied so that the cut is, in the transverse direction, parallel with the free surface of the condyles, for, were it not, then the leg would point either inwards or outwards as the case might be. The tibia is divided in a direction parallel with its upper surface, *i.e.*, at right angles to the shaft. It must not be forgotten that the epiphyseal lines should not be encroached upon, otherwise arrest of growth would occur, and it may be roughly stated, that, in a child of about eight years of age, half an inch of the femur may be removed; whereas, in a youth of seventeen years of age, one inch is safe, without endangering the epiphyseal line. In the tibia, as already stated, the lower margins of the tuberosities mark the epiphyseal line and these mar-

gins should, therefore, be respected. After the division of the bones, the diseased synovial membrane is removed, the ligamentum patellæ united, the wound sutured and the limb fixed in a suitable splint.

Amputation.—Amputation in the neighborhood of the knee joint may be done immediately above the base of the condyles, by Carden's, or by some modification of Carden's method. In *Carden's operation*, an incision starts over the most prominent part of the tuberosity of one condyle, and sweeps with an easy curve, across the anterior aspect of the limb, crossing the median line, about the middle of the patellar ligament, while the posterior incision is quite horizontal. The tendon of the quadriceps is then divided above the patella, which is removed, and the femur is sawn through at the desired point. Farabœuf's modification consists in making the anterior flap about one inch longer than the antero-posterior diameter of the limb at the saw line, while the posterior is equal to half that diameter. The steps are otherwise the same as in Carden's method. It is much more advisable, however, to disarticulate at the knee joint rather than saw through the femur, and for disarticulation at the knee joint, *Stephen Smith's method* is usually employed. In this, an incision commences in front, in the median line, about one inch below the tubercle of the tibia, and is carried, in a curved manner, across the most prominent part of the outer side of the leg. It then slopes upward to reach the middle line at the posterior aspect of the limb. A second incision begins at the same point in front and is carried in a similar manner across the inner side of the leg to meet the first incision on the posterior aspect. The inner flap should be a little longer than the outer, so as to provide for the longer

and larger internal condyle. The ligamentum patellæ is divided, the knife is inserted between the semilunar cartilages and the tibia, the other ligaments of the joint are severed along with the remaining soft parts, and the leg is removed, the patella being left in the stump.

CHAPTER XXXVI.

THE LEG.

ANTERIOR AND POSTERIOR ASPECTS.

Muscles—Actions.	Ligation.
Bloodvessels.	Fractures.
Landmarks.	Amputation.

Anterior Aspect.—The following nerves are found in the superficial fascia of the anterior aspect of the leg, viz.: The internal or long saphenous, along the inner side, with branches of the external popliteal on the outer side, above, and of the musculo-cutaneous on the same side, below. The latter nerve, *i.e.*, the musculo-cutaneous, pierces the deep fascia to become cutaneous, about the junction of the middle and lower thirds of the leg. The superficial veins on the anterior aspect of the leg, are the long saphenous vein, with its branches.

The **Muscles** of the anterior tibial region are: The *tibialis anticus*.—From the outer tuberosity of the tibia, the upper two-thirds of the external surface of the bone and from the interosseous membrane; into the inner and under surfaces of the internal cuneiform and the basè of the first metatarsal.

Action.—It flexes the ankle joint, draws up the inner border of the foot, *i.e.*, inverts the sole, and adducts the front part of the foot. The two latter movements take place at the calcaneo-astragaloid and the medio-tarsal joints. The flexing action of this muscle is seen in the act of walking, since it is this muscle that lifts up the front of the foot, so as to allow the toes to clear the ground when the leg swings forward. *Extensor proprius hallucis.*—From the middle two-fourths of the anterior surface of

the fibula and from the interosseous membrane; into the ligamentous structures at the back and sides of the metatarso-phalangeal articulation and into the base of the last phalanx of the great toe. *Action*.—To extend the first phalanx of the great toe; to slightly extend the second phalanx; to flex the ankle and at the same time slightly adduct the front of the foot and invert the sole. *Extensor longus digitorum*.—From the upper three-fourths of the anterior surface of the fibula and from the interosseous membrane; into the metatarso-phalangeal joints and the three phalanges of each of the four outer toes. *Action*.—To extend the first phalanges of these toes. It, may, to a very slight degree, extend the second and third phalanges, but the chief extension movement of these phalanges is performed by the lumbricales and the interossei of the sole of the foot, which are inserted into the expansions of this tendon going to these phalanges. This muscle also flexes the ankle joint and slightly everts and abducts the front part of the foot. *Peroneus tertius*.—From the lower fourth of the anterior surface of the fibula and from the interosseous membrane; into the inner side of the base of the metatarsal bone of the little toe. *Action*.—It flexes the ankle joint and abducts the front of the foot, at the same time elevating the outer border of the foot. These muscles have actions somewhat similar (flexion of the foot, especially), and are all supplied by the same nerve, viz., the anterior tibial.

Anterior annular ligament.—The vertical part of this ligament binds down the tendons as they pass to the foot, and is attached, externally, to the lower end of the fibula and, internally, to the tibia. The horizontal part will be considered in connection with the dorsum of the foot. The vertical part contains one synovial sheath, viz., that for the tibialis anticus tendon. The

other tendons, the bloodvessels and the nerve, all pass beneath this ligament without any special sheath of synovial membrane.

The Bloodvessels—The anterior tibial artery begins at the lower border of the popliteus muscle, *i.e.*, at the termination of the popliteal. It passes to the front of the leg and then down this surface to terminate, on the dorsum of the foot, as the *dorsalis pedis*.

Relations.—In front, are the skin, superficial and deep fasciæ, while, in its lower third, it is crossed, from without inwards by the extensor proprius hallucis. The vessel lies in the interval between the tibialis anticus, internally, and the extensor longus digitorum and the extensor hallucis, externally. It has in front, also, the anterior annular ligament of the ankle joint, as well as the anterior tibial nerve in its middle third; behind, it lies, in the upper two-thirds of its course, on the interosseous membrane, and, in its lower third, on the front of the tibia and the ankle joint; externally, in its upper third, it lies in contact with the extensor longus digitorum, and in most of its lower two-thirds, with the extensor proprius hallucis, while, for the distance of about one inch above the ankle joint, the extensor longus digitorum again lies next to it; internally, it has the tibialis anticus, with the exception of the lower portion, where the extensor proprius hallucis lies, for a short distance, in front or on its inner side.

Landmarks.—The course of the artery corresponds to a line drawn from the inner side of the head of the fibula to a point midway between the two malleoli. Since the artery begins about the lower border of the tubercle of the tibia and comes almost directly to the front, the landmark for its upper end, on the anterior surface of the leg, will be indicated by the lower border of the tubercle,

and this corresponds to a point, a little over one inch below the anterior surface of the head of the fibula, or about one and a half inches below the styloid process of the fibula. There are two venæ comites for the artery, one lying in front and the other behind, hence their lines will correspond to the line of the artery. *Long saphenous vein.*—A line drawn from in front of the inner malleolus to the inner and posterior portion of the internal condyle of the femur. This line, in passing upwards, crosses the internal border of the tibia, in the adult, about two and a half inches above the apex of the inner malleolus.

Ligation of the *Anterior Tibial* in the *upper third* of the leg.—The vessel must be looked for between the tibialis anticus, internally, and the extensor longus digitorum, externally, when it is to be ligated in the upper part of the leg, but, since the extensor longus digitorum is a penniform muscle and overlies the artery, the incision should be made a little internal to the line of the artery and should start, above, about the level of the upper border of the tubercle of the tibia. The gap between the above muscles is about one inch from the anterior border of the tibia, and must be sought for, though it may be difficult to find. The surgeon will have to rely, to a great extent, on the feel of the muscular planes, as evidenced in making the tibialis anticus tense by extending and everting the foot, or in putting the extensor longus digitorum on the stretch by strongly flexing the phalanges of the toes. The finger in the wound will recognize the individual muscle brought into play by these movements and will, therefore, be able to identify the interval between them. On separating these muscles by means of the handle of the scalpel or by the finger, the external border of the tibia is the next guide, and, towards it, the finger or the handle of the scalpel should work, when the vessel will be found lying

close to this border. The ligature generally includes the venæ comites, since they are closely connected with the vessel in its course.

Ligation of the artery in the *middle third* of the leg.—An incision a little internal to the line of the vessel is made; the tibialis anticus and the extensor longus digitorum identified in the manner above described; the external border of the tibia is used as a guide and the artery found by keeping close to the tibialis anticus. The nerve, in this situation, lies in front of the vessel and must be avoided. Ligation at the *lower third* of the leg.—An incision is made in the line of the artery on the outer side of the tendon of the tibialis anticus, and on separating this from the extensor proprius hallucis, the vessel will be found lying between them, or beneath the latter muscle. The nerve, in this situation, lies external to the vessel, so that the needle should be passed from the nerve, *i.e.*, from without inwards. *Collateral circulation*, after ligation of the tibial, will be carried on (1) by the anterior peroneal anastomosing with the external malleolar of the anterior tibial, and with the tarsal, a branch of the dorsalis pedis; (2) by the calcanean, from the peroneal, communicating with the external malleolar, tarsal, and with branches of the external plantar; (3) by the external and internal plantar with the branches of the dorsalis pedis; (4) by the internal malleolar of the anterior with the internal malleolar of the posterior tibial, and (5) by muscular branches from both tibials that pierce the interosseous membrane.

Posterior Aspect.—The superficial structures of this region are supplied by branches from the internal or long saphenous nerve and by the external or short saphenous nerve. The latter is formed by the communicans poplitei, which pierces the deep fascia about the middle of the leg and then receives the communicans peronei. The exter-

nal saphenous vein is situated in the superficial fascia and lies internal to the nerve, above, but runs behind it, about two inches above the external malleolus.

The **Muscles** of this region are: The *Gastrocnemius*, which arises by two heads—one, from the upper and back part of the internal condyle, and the other from the upper and back part of the external condyle. These heads unite at the upper part of the middle third of the leg and then terminate in an aponeurosis, which, receiving the soleus, becomes the tendo Achilles. Its *actions* will be considered with those of the soleus. *Soleus*.—From the back of the head of the fibula, from the upper third of the posterior surface of fibula, from the oblique line of the tibia, and the middle third of its internal border and from the fascia between these heads; into an aponeurosis which unites with that of the gastrocnemius. *Tendo Achilles*.—This tendon, nearly six inches in length, commences a little below the middle of the leg and is about five-eighths of an inch in width and three-eighths of an inch in thickness. It is narrowest about one and a half inches above its insertion into the lower part of the posterior surface of the os calcis. A bursa is interposed between the tendon and the upper part of this surface, so that, in case of any swelling occurring in this situation, it is advisable to bear in mind the existence of this synovial sac. *Actions* of these combined muscles.—They extend the foot, so that, when they contract, in the erect position of the body, they act as the power, the body being the weight, and the contact of the anterior parts of the metatarsal bones with the ground, the fulcrum. These muscles are brought into action in such movements as walking, leaping, jumping, etc., and, when acting from below, they support the body—the soleus steadying the tibia on the astragalus, and the gastrocnemius, the femur on the tibia. After they have

completely extended the foot, they tend to slightly adduct it and to invert the sole. The *popliteus*, from the outer side of the external condyle and from the posterior ligament of the knee joint; into the inner two-thirds of the triangular surface above the oblique line of the tibia and into the fascia covering the muscle. *Action*.—It feebly flexes the tibia and at the same time rotates it inward slightly. Its attachment to the posterior ligament tends to draw back this ligament in flexion of the leg and so prevent it from being “nipped” between the bones in that movement. *Plantaris*.—From the lower two inches of the outer bifurcation of the linea aspera and from the posterior ligament of the knee joint; into the os calcis, or the tendo Achilles, or into the plantar fascia. *Action*.—To feebly extend the ankle and to flex the knee like the gastrocnemius, and, like the popliteus, to prevent the posterior synovial membrane from being caught between the bones in flexion of the leg. *Nerves*.—The above muscles, having actions somewhat similar, are all supplied by the same nerve, viz., by the internal popliteal.

Beneath the deep tibial fascia, which is attached to the inner border of the tibia, internally, and to the outer border of the flexor surface of the fibula, externally, and which is thicker below, blending in this situation, with the deep fascia of the leg, are the following muscles: *Flexor longus digitorum*.—From the posterior surface of the tibia below the oblique line, to within three inches of the ankle joint, and from the adjoining deep fascia; into the bases of the last phalanges of the four outer toes. *Action*.—It flexes the last phalanges and assists in the flexion of the second and first phalanges, and of the front part of the foot at the medio-tarsal joint, and, in addition, it assists slightly in extension of the foot at the ankle joint. *Flexor longus hallucis*.—From the lower two-thirds of the

posterior surface of the fibula and from the adjoining interosseous membrane; into the base of the last phalanx of the great toe and by a small slip into that part of the preceding muscle going to the second and third toes. *Action.*—It flexes the last and then the first phalanx of the great toe; flexes, slightly, the anterior part of the foot at the medio-tarsal joint, and, in addition, extends the foot at the ankle. This muscle is of importance in walking, in which action it is strongly contracted so as to press the great toe, which is the last to leave the ground in walking, firmly against the ground. *Tibialis posticus.*—From the tibia, between the upper part of the oblique line, above, and the middle of the external border of the bone, below; from the upper two-thirds of the internal surface of the fibula and from the interosseous membrane between these origins; into the tuberosity of the scaphoid, and, by offsets, into all the other tarsal bones, except the astragalus, and into the bases of the second, third and fourth metatarsal bones. *Action.*—It extends the foot at the ankle joint, inverts or raises its inner border, adducts the front part, and, on account or by means of its tarsal attachments, it assists in maintaining the arches of the foot. *Nerves.*—Since all these muscles extend the foot they are supplied by the same nerve, viz., the posterior tibial.

Bloodvessels.—The posterior tibial artery passes down the leg, beginning, above, at the lower border of the popliteus muscle, and terminating, below, in the fossa between the heel and the inner ankle.

Relations.—It lies on the tibialis posticus, the flexor longus digitorum, the tibia and the back of ankle joint, and is situated beneath the superficial and deep fasciæ and the gastrocnemius and soleus; below, it runs parallel with the inner border of the tendo Achilles. The posterior tibial nerve crosses it, and, therefore, in the upper

third of the course of the vessel, lies to its inner side, whereas, in the lower two-thirds, *i.e.*, after crossing, it lies to its outer side. The branches of this artery are: Muscular, nutrient to the tibia, calcanean communicating with the peroneal, the peroneal itself, which runs along the fibular side of the leg, and the malleolar.

Landmarks.—*Artery.*—A line drawn from the middle of the popliteal space, opposite the knee joint, to a point midway between the centre of the convexity of the heel and the tip of the internal malleolus, corresponds to the direction of the lower two-thirds of the posterior tibial artery, whereas, the upper third is represented by a slightly curved line, with its convexity outwards, drawn downwards, from a point, on the posterior surface of the leg, on a level with the lower part of the tubercle of the tibia, to join the former line about two inches below this point. Landmarks for the *veins.*—The *posterior tibial veins* correspond to the above lines for the artery, since these veins lie one on either side of that vessel. For the *external saphenous vein.*—Draw a line from the centre of the leg, on a level with the styloid process of the fibula, to a point midway between the external malleolus and the heel. This represents the superficial part of the vein, but, at the upper part of the leg, this vessel, after piercing the deep fascia runs for a distance of one and a half inches vertically upwards, before emptying into the popliteal vein. Landmarks for the *nerves.*—The posterior tibial nerve may be represented by a line starting, as in the case of the artery, from the middle of the popliteal space opposite the level of the knee joint and drawn, downwards, to a point about a quarter of an inch external to midway between the centre of the convexity of the heel and the tip of the internal malleolus.

Ligation of the posterior tibial, in the *middle third* of the leg is rarely called for, and, when it is, is done through an incision about four inches long, commencing about half an inch behind the inner margin of the tibia, avoiding the long saphenous vein and exposing the inner margin of the gastrocnemius which is pulled aside, the soleus is now divided, directing the point of the knife towards the tibia, and the deep fascia, which covers the deep muscles and the vessels, is identified. The soleus is retracted and the finger feels for the pulsations of the artery near the outer border of the tibia, and, when found, the ligature is applied. Ligation at the *lower third*.—An incision is made, about two inches long, midway between the inner border of the tendo Achilles and the inner edge of the tibia in the line of the artery. The tendon is retracted and the vessel found lying on the flexor longus digitorum with the nerve to its outer side. The needle is passed from the nerve and the artery ligated. Ligation *behind the malleolus*.—An incision about two inches in length is made, midway between the centre of the convexity of the heel and the tip of the inner malleolus. The internal annular ligament is divided and the vessel found in a gap, felt by the finger, between the flexor longus digitorum and the flexor longus hallucis. The venæ comites are separated from the artery and the latter ligated. *Collateral circulation* after ligation of the posterior tibial; the peroneal anastomoses with the posterior tibial by means of the communicating and muscular branches; the termination of the peroneal, with branches from the external plantar of the foot and with the tarsal; the tarsal and metatarsal from the dorsalis pedis, with the external plantar; internal branches from the same vessel, with the internal plantar; internal malleolar, from the anterior tibial, with branches from the posterior tibial; external malleolar branches of the same artery, with the external plantar.

Fibular Muscles.—*Peroneus longus.*—From the head and upper two-thirds of the outer surface of the fibula. This muscle passes down behind the outer malleolus, then on the outer side of the os calcis, and then, changing its course to the under surface of the cuboid, is inserted into the outer side of the base of the metatarsal bone of the great toe and into the internal cuneiform bone. *Action.*—It extends the foot at the ankle joint; abducts its anterior part, and raises up the outer border, and, in addition, assists in maintaining the arches of the foot. Its action is seen in walking, in which, along with the muscles forming the tendo Achilles, it raises the heel, and, counteracting the tendency of these muscles to invert the inner border of the foot, balances, evenly, the foot in the act of walking.

Peroneus brevis.—From the lower two-thirds of the external surface of the fibula; into the outer side of the base of the metatarsal bone of the little toe. *Action.*—To extend, slightly, the foot; to abduct its anterior part, and to raise up its outer border. *Nerves.*—Having the same action, as the above, it is supplied by the same nerve, viz., the musculo-cutaneous.

Fractures of the bones of the leg.—*Tibia.*—The head of the tibia may be fractured, implicating the joint, or, the epiphysis, which unites with the shaft about the twentieth year, may be separated, or, the tubercle, which, though usually included in the epiphysis, occasionally has a separate centre of ossification, may be torn from the bone. The shaft may be broken from falls on the feet or from direct injury, or the lower epiphysis which unites with the shaft about the eighteenth year, may be torn off. The displacement in fractures of the shaft is very little affected by muscular action, since the unbroken fibula prevents any overriding. *Fibula.*—The head of this bone is

an epiphysis and, uniting, as it does, with the shaft, about the age of twenty-five, may be broken off, either by direct blows or by sudden, forcible contraction of the biceps muscle. When this accident occurs there is a possibility of the external popliteal nerve being injured, or of its being included in the resulting callus, with subsequent paralysis of the muscles supplied by it. *Potts' Fracture.*—Here the fibula breaks at its weakest part, *i.e.*, within two or three inches from the lower extremity. In this fracture, the foot is turned outwards, and the tibia, having lost its support, is forced inwards from off the astragalus, stretching or tearing the internal ligament of the joint, so that, in addition to the fracture, there is a partial dislocation. The foot in this injury is everted, partly from mechanical causes and partly from the action of the peroneus longus; while the muscles of the calf draw up the heel. Since the greater part of the fibula is buried beneath muscles, and, since the head and the external malleolus, along with about three inches of the external surface of the shaft above the malleolus, are the only parts of the bone that can be clearly felt, it follows, that it is often difficult to recognize a fracture of the shaft of the fibula, especially when swelling has occurred. The fact that pressure on these subcutaneous portions of the bone may elicit pain at the seat of fracture when the shaft is broken, may be of assistance in diagnosis. *Fracture of both bones* is generally the result of direct blows or of crushing accidents, and out of two hundred and seventeen fractures of both bones, one hundred and twenty-five belonged to the lower third (Hamilton). Indirect fractures are, as a rule, oblique, the tibia being broken, generally, in a direction downward, forward and inward. Compound fractures are more frequent here than in any other of the bones of the body—no doubt because of the superficial position of these bones

of the leg. *Displacement.*—Of course the direction and obliquity of the fracture affect the position of the fragments. If the obliquity be downwards and forwards, the lower fragments are drawn up behind the upper fragments by the gastrocnemius, assisted slightly by the soleus and plantaris, but, if the obliquity be downwards and backwards, then the lower fragments override the upper, being drawn up by the same muscles. Flexion of the leg on the thigh will relax the gastrocnemius muscle and thus permit freer extension of the bones in endeavoring to coaptate them.

Amputation of the leg.—Amputation, at the “place of election,” *i.e.*, about one hand’s breadth below the knee joint, is best performed by Farabœuf’s method, which consists of an external and an internal flap. The external flap is equal to the diameter of the limb at the level of the saw line, *i.e.*, it is one-third the circumference of the limb at this point. The incision starts in front opposite the saw line and passes down parallel with and internal to the anterior border of the tibia. The posterior incision ends above, opposite the anterior incision, but about one and a half inches below the beginning of that incision. These two incisions are joined by a curved one on the outer side of the leg, while, on the inner side, the incision is carried from the upper end of the posterior incision to a point on the anterior about one and a half inches below its commencement. The anterior tibial artery is in the external flap which must not be separated too high for fear of wounding that vessel where it perforates the intermuscular septum. The soft parts are retracted and the bone divided at the desired line. On looking at the stump in this operation, the anterior tibial nerve is seen to lie on the outer side of the anterior tibial artery. The posterior tibial and the peroneal vessels are found lying

on the tibialis posticus muscle at the same level and about midway between the bones. The posterior tibial nerve lies close to the inner side of the artery. Holden draws attention to the fact, that, in amputations one inch below the head of the fibula, only one main artery is divided. In amputations two inches below it, two main arteries are divided—the anterior and the posterior tibial, while in amputations three inches below the head, three main arteries—the two tibials and the peroneal—are divided. Amputation through the *middle of the leg* may be performed by means of a large posterior flap. The length and breadth of the posterior flap are equal to one-third the circumference, at the level of the saw line, *i.e.*, to the diameter of the leg at this level, whereas, the anterior flap is one-third the length of the posterior. The incisions are commenced about one inch below the point where the bones are to be sawn so as to allow for retraction. The inner limb of the U-shaped posterior flap is just behind the inner border of the tibia, while the outer limb of this flap is posterior to the peronei muscles.

In the stump, after this amputation, the anterior tibial artery lies on the interosseous membrane between the tibialis anticus and the extensor proprius hallucis with the nerve in front of it, the posterior tibial is found lying between the superficial and the deep planes of muscles with the nerve to its outer side, while the peroneal vessels will be close to the fibula lying on the flexor longus hallucis. Amputation through the *lower third* of the leg may be performed by means of the large posterior flap. This large posterior flap, after retraction, which causes it to lose about one-third of its length, should be equal to, in length, the half of the circumference

of the limb at the level of the saw line. The anterior flap is about one-quarter the length of the posterior. The internal vertical incision for the posterior flap descends in front of the inner border of the tibia, while the external lies behind the fibula.

CHAPTER XXXVII.

THE ANKLE JOINT.

DESCRIPTION.	ORDER OF STRUCTURES
MOVEMENTS.	SURROUNDING JOINT.
DISEASES.	TENOTOMY.

The ankle joint is a ginglymus or hinge joint, and is formed by the reception of the astragalus in a cavity, composed of the lower articular end of the tibia and of the malleolus on either side. The *ligaments* of the joint are external and internal, anterior and posterior. The former, *i.e.*, the external lateral, is composed of three parts; one, stretching from the external malleolus to the astragalus; another—the middle fasciculus—from the same malleolus to the peroneal tubercle of the os calcis, and a third, from the posterior border of this malleolus to the astragalus. The internal lateral or deltoid ligament, from the inner malleolus, is attached to the scaphoid in front, the sustentaculum tali below, and the astragalus behind, while the anterior and the posterior ligaments are attached above, to the tibia, and, below, to the astragalus.

Movements.—It is so embraced by the malleoli that movement at this joint is limited to flexion and extension, with the exception, that, in extreme extension, in which position the narrowest portion of the astragalus rests upon the widest part of the joint cavity, there is, in addition, a slight amount of lateral motion permitted. Flexion is limited by the posterior and middle portions of the external lateral ligament, by the posterior ligament of the ankle joint, by most of the fibres of the internal ligament and by the neck of the astragalus abutting on the front of the tibia, whereas, extension is limited by the anterior fibres

of the internal ligament, by the anterior and middle fibres of the external ligament, by the anterior ligament and by the astragalus meeting the tibia behind.

Disease.—*Synovitis.*—In synovitis, the effusion distends the capsule and causes a swelling, slight on either side of the tendo Achilles, but marked over the front of the joint. On the inner aspect of the front of the joint, this swelling is most pronounced between the tendon of the tibialis anticus and the internal lateral ligament; whereas, on the outer side, it is most in evidence between the peroneus brevis and the external lateral ligament. Inflammation of the bursa lying between the lower part of the tendo Achilles and the upper part of the posterior surface of the os calcis might be confounded with the swelling found posteriorly in synovitis of the ankle joint, but may be diagnosed by the fact, that, in bursitis, the fluctuation from one side of the tendon to the other is more superficial and is situated lower down, *i.e.*, nearer the os calcis than in synovitis, and further, that, in the latter disease, the swelling is evident on the front of the articulation as well. *Tubercular disease*, occurring in the ankle joint may begin in either the bone or in the synovial membrane of the joint, and, in connection with tuberculosis of this joint, it is interesting to note the ease with which the disease can spread to most of the surfaces of the astragalus. In tubercular synovitis, Barwell states that a point of special tenderness is located in front of the outer malleolus, just about where the peroneus tertius crosses the joint. *Relative position of the structures surrounding the joint.*—*In front.*—From within outwards, are: (1) The tibialis anticus; (2) the extensor proprius hallucis; (3) the termination of the anterior tibial artery with its venæ comites; (4) the anterior tibial nerve; (5) the extensor communis digitorum, and (6) the peroneus tertius. In the super-

ficial structures and running in front of the inner malleolus, are the long saphenous vein and nerve, while more externally are the branches of the musculo-cutaneous nerve. On the *outer* side are, from before backwards: (1) The peroneus brevis, and (2) the peroneus longus lying behind the outer malleolus and contained in a common synovial sheath; (3) external calcanean branches of the peroneal artery, while superficially, about midway between the outer malleolus and the centre of the heel, are the external saphenous nerve and vein. *Internally* are: (1) The tibialis posticus; (2) flexor longus digitorum; (3) posterior tibial artery with its venæ comites, one on either side; (4) posterior tibial nerve, and (5) flexor longus hallucis. The space occupied behind the inner malleolus, by each of these structures, is as follows: The tibialis posticus, one-quarter of an inch; the flexor longus digitorum, one-quarter of an inch; the vessels and nerve, three-eighths of an inch, and the flexor longus hallucis, including the muscular fibres, which are attached low down to its tendon, one-half inch.

Tenotomy or division of tendons.—Before the days of aseptic surgery, the subcutaneous division of tendons was a very important procedure for the correction of the different varieties of club-foot, and certain situations were selected at which to divide the tendons, so as to avoid their synovial sheaths, and, since the surgeon may occasionally be called upon to divide them, it is, therefore, advisable to briefly refer to the operation. When tenotomy is required in the treatment of club-foot, it may be performed on the individual tendons at the following points: (1) The *tibialis anticus* tendon may be divided as it crosses the scaphoid bone, *i.e.*, about one inch above its insertion, since the synovial sheath for the tendon ends just above this point. This is one of the tendons that need to be

divided, when tenotomy is indicated to correct talipes varus, *i.e.*, the condition in which the inner border of the foot is drawn up and the anterior part adducted, so that the patient walks on the outer side of the sole of the foot. (2) *Extensor longus digitorum*.—To divide the tendons of this muscle, occasionally necessary in talipes calcaneus, in which the patient walks on his heel, the knife should be entered on the inner side of the innermost tendon about the level of the ankle joint, avoiding the artery, which here lies internal to the tendon and between it and the extensor proprius hallucis. (3) The *tibialis posticus* is divided above the upper limit of its synovial sheath, *i.e.*, at a point about one and a half inches above the tip of the malleolus. The long saphenous vein, which crosses the inner border of the tibia, about two inches above the joint, must be avoided. In the infant this tendon should be cut about half an inch above the tip of the malleolus. In the operation, the knife should be entered between the inner margin of the tibia and the tendon, but, should it be impossible to feel this margin of the bone in a very fat infant, the guide to it is a point, midway between the anterior and the posterior borders of the leg, in the situation mentioned (Little). (4) The *peroneus longus* and *brevis* are divided above the level of their common synovial sheath, *viz.*, about one and a half inches above the tip of the outer malleolus. (5) *Tendo Achilles*.—For this, the section is made at the narrowest part of the tendon, *i.e.*, about one inch above its insertion into the os calcis, avoiding the external saphenous vein which, in this situation, lies a little anterior to the outer margin of the tendon.

CHAPTER XXXVIII.

THE FOOT.

DORSAL SURFACE.

Structures Covering.

Landmarks for Arteries.

Landmarks for Bony Prominences.

Arches of Foot.

Amputation.

PLANTAR SURFACE.

Plantar Fascia.

Actions of Muscles.

Landmarks for Arteries

Club Foot.

Dorsal Surface.—In the superficial fascia of the dorsum of the foot the following nerves are found, viz.: The terminations of the internal saphenous, along the inner border; the branches of the musculo-cutaneous over the greater part of the dorsum, and the short saphenous nerve along the outer side of the little toe. Over the toes, the integument is supplied as follows: The adjoining sides of the great and second toes are supplied by the anterior tibial; the outer side of the little toe by the short saphenous and the remaining toes by the musculo-cutaneous.

Anterior annular ligament.—The vertical part has already been described on page 366. The horizontal portion is composed of bands of fascia arranged somewhat like the letter Y. The base or body of the Y is attached to the os calcis in front of the depression for the interosseous ligament and splits to enclose the extensor longus digitorum and the peroneus tertius along with their common synovial membrane. At the inner border of these tendons the upper branch, or limb, passes up towards the inner malleolus, enclosing by a splitting of its fibres, the tibialis anticus and its synovial sheath, but passing over the extensor proprius hallucis, anterior tibial nerve and the bloodvessels. The other or lower limb passes downwards to the

scaphoid and internal cuneiform bones, passing over both the tibialis anticus and the extensor proprius hallucis and the bloodvessels as well. *Muscle.*—*Extensor brevis digitorum.*—From the upper and outer surface of the os calcis; into the dorsal surface of the base of the first phalanx of the great toe by the innermost tendon—the other three blending with the long extensor tendons, from the leg, for the second, third and fourth toes. *Action.*—To extend the four inner toes, and, in the case of the first phalanx of the great toe, to act as an adductor also. The obliquity of the insertion of its three outer tendons counteracts the inward tendency of the long extensor when extending the toes. This muscle is supplied by the anterior tibial nerve.

Bloodvessels.—The *dorsalis pedis* passes forwards to the back part of the space between the first and second metatarsal bones. *Relations.*—It lies beneath the integument, fascia and the anterior annular ligament, and passes under the innermost tendon of the short extensor; on the inner side, is the extensor proprius hallucis; externally, is the extensor longus digitorum and the nerve, while behind, are the astragalus, scaphoid and the internal cuneiform bones.

Landmarks.—The *dorsalis pedis artery* may be represented by a line drawn from a point midway between the two malleoli, to the back of the first metatarsal space. Landmarks for the *tarsal branch.*—Draw a line outwards from the line of the artery on a level with the head of the astragalus. Landmarks for the *metatarsal.*—A line drawn from the line of the artery outwards, commencing opposite the bases of the metatarsal bones. *Ligation.*—An incision about one and a half inches long is made, midway between the tendon of the extensor hallucis and the innermost tendon of the extensor brevis digitorum, avoiding the internal branch of the musculo-cutaneous

nerve which lies in the superficial tissues. In tying the artery, the needle should be passed from the outer side of the vessel to avoid the nerve.

Plantar Surface.—In the sole of the foot the nervous supply of the superficial structures consists in the internal and the external plantar nerves with the plantar cutaneous branches from the posterior tibial. Beneath the superficial fascia is the *plantar fascia*, which is composed of three parts—a central and two lateral. The central portion of this fascia is attached, behind, to the inner tubercle of the os calcis, while, in front, it divides, near the heads of the metatarsal bones, into a process for each toe. This process sends superficial fibres, as in the palmar fascia, to the overlying integument, while the main part of each process blends with the fibrous sheath for the toe, and forms, therefore, a channel for the passage of the flexor tendon to the last phalanx. The outer portion of the fascia is attached to the os calcis behind, and spreads forwards, covering the abductor minimi digiti, to be attached to the base of the fifth metatarsal bone; while the inner portion of the fascia, attached behind to the internal annular ligament, covers the abductor hallucis muscle. Beneath this plantar fascia, the muscles of the sole are arranged in four layers and have actions as follows: *First layer.*—The *abductor hallucis* flexes and abducts the first phalanx of the great toe; the *flexor brevis digitorum* flexes the second phalanges and, in combination with the long flexor, assists in walking, by pressing the toes against the ground; the *abductor minimi digiti* abducts and flexes the little toe. *Second layer.*—The *flexor accessorius* assists in flexing the last phalanges of the four outer toes, at the same time drawing them outwards, thus neutralizing the inward traction exercised by the long flexor. The *lumbricales*, four in number, flex the first phalanges and ex-

tend the second and third phalanges, as seen in walking, where the simultaneous flexion of the first with extension of the second and third phalanges results in the application of the whole length of the toes to the ground. *Third layer.*—The *flexor brevis hallucis* flexes and slightly adducts the first phalanx of the great toe; the *adductor hallucis* adducts and flexes the first phalanx of the same toe. This muscle, *i.e.*, the adductor, with the abductor hallucis and the flexor brevis hallucis causes direct flexion of the first phalanx of the great toe, so that, in walking, while the second phalanx is pressed firmly against the ground by the action of the long flexor, these smaller muscles act similarly on the first phalanx. The *transversus pedis* adducts the first phalanx of the great toe and draws together the heads of the metatarsal bones after they have been separated by the pressure of the weight of the body in walking. The *flexor brevis minimi digiti* flexes and slightly abducts the first phalanx of the little toe. *Fourth layer.*—The *interossei* flex the first and extend the terminal phalanges, being assisted in these actions by the lumbricales, and, lastly, the plantar interossei adduct the three outer toes, while the dorsal ones abduct the second, third and fourth toes.

Bloodvessels.—The *external plantar* artery passes obliquely forwards and outwards across the sole of the foot to the base of the fifth metatarsal bone, where it makes a bend forwards and inwards, to sink deeply into the foot and terminate at the proximal end of the first interosseous space, by anastomosing with the communicating branch from the *dorsalis pedis*. It has two *venæ comites*. The internal calcanean branches of the external plantar arise close to the origin of the vessel (occasionally they are derived from the posterior tibial, close to its bifurcation), and are of great importance in connection with the line of

the incision in Syme's operation. The *internal plantar* passes forwards along the inner side of the sole of the foot to the inner side of the base of the first metatarsal bone where it anastomoses with the *princeps pollicis* from the communicating.

Landmarks of the Foot.—For the *bloodvessels*.—The line for the *external plantar* is drawn from a point, midway between the tip of the inner malleolus and the centre of the convexity of the heel, to about one finger's breadth from the tuberosity of the fifth metatarsal bone. The portion constituting the arch is represented by a slightly curved line drawn from the latter point, *i.e.*, a finger's breadth internal to the tuberosity of the fifth metatarsal bone, inwards to the back of the first interosseous space. The line for the *internal plantar* is drawn, from the same point of origin as for the external, forwards to the middle of the under surface of the great toe.

Bony Prominences.—On the *dorsum*, the bony prominence felt below and about one inch in front of the lower end of the tibia is the *head of the astragalus*. The *longitudinal ridge* forming the highest point of the *dorsum* of the foot is composed, from behind forwards, of the head of the astragalus, the scaphoid, the middle cuneiform, and the second metatarsal bone. On the *inner side* of the foot, there can be felt, from behind forwards, the following prominences: The *internal tuberosity* of the os calcis, the *sustentaculum tali* with the internal malleolus above it, the *tuberosity of the scaphoid*, the *base of the first metatarsal bone* and the *head* of the same with the *base of the first phalanx* immediately in front of it, the latter being increased in depth by the presence of the sesamoid bones beneath it. On the *outer side* is the *external tuberosity* of the os calcis, next, the *peroneal tubercle* some distance in front of this tuberosity and situated be-

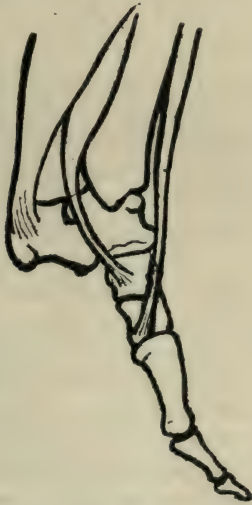low the external malleolus. This peroneal tubercle has the tendon of the peroneus brevis above it and the tendon of the peroneus longus below it. In front of the tubercle is the *base of the fifth metatarsal bone*, while in front of the latter is the *base of the first phalanx* of the little toe. As the result of the measurement of a number of skeletons we found the following to be the average distances between these prominences:

On the inner side.—From the tip of the internal malleolus to the sustentaculum tali, *i.e.*, the ridge lying directly below the malleolus, the average distance was one inch; from the sustentaculum tali to the most prominent part of the tuberosity of the scaphoid, $1\frac{1}{4}$ inches; from the tip of the internal malleolus to the tuberosity of the scaphoid, $1\frac{1}{2}$ inches—in this triangle is a portion of the astragalus, hidden, to some extent, by the internal lateral ligament. From the tuberosity of the scaphoid to the base of the first metatarsal bone, $1\frac{3}{8}$ inches. Immediately behind the tuberosity of the scaphoid is the inner end of the mid-tarsal joint, while, immediately in front of it is the joint between the scaphoid and the internal cuneiform bones.

On the outer side.—From the external malleolus to the peroneal tubercle, $\frac{7}{8}$ of an inch; from the peroneal tubercle to the base of the fifth metatarsal, $1\frac{5}{8}$ inches. Between these prominences, *i.e.*, the peroneal tubercle and the base of the fifth metatarsal bone, is situated the outer extremity of the mid-tarsal joint. This mid-tarsal joint is $\frac{7}{8}$ of an inch from the peroneal tubercle, and $\frac{3}{4}$ of an inch from the base of the metatarsal bone, so that, the joint lies a little nearer to the base of the fifth metatarsal than it does to the tubercle. The tip of the external malleolus projects $1\frac{1}{8}$ inches below the level of the upper border of the ankle joint, while the tip of the internal malleolus is $\frac{5}{8}$ of an inch below the same level; the former, therefore, being half an inch longer than the latter.

The Arches of the Foot, two in number, are the longitudinal and the transverse. The *longitudinal arch* reaches from the posterior part of the os calcis to the heads of the metatarsal bones, while the transverse is best marked along the tarso-metatarsal joints. These arches protect the delicate plantar tissues and give a certain amount of springiness to the gait, thus preventing sudden jars, etc., to the foot, and, being composed, as they are, of a number of bones bound together, they give elasticity to the tread. The particular part of the foot contributing to this elasticity is the portion of the arch formed by the astragalus, the scaphoid and the cuneiform bones, whereas, the os calcis and the cuboid afford solidity and strength, and thereby assist in supporting the more elastic portion of the foot. In a longitudinal section of the foot the os calcis is seen to form one side of this arch—the scaphoid, cuneiform and the metatarsal forming the other, while, superimposed on them, is the astragalus forming the keystone of the arch (Fig. 10). On a transverse section through the cuneiform and cuboid bones, the wedge-shaped middle cuneiform forms the summit or keystone of the transverse arch. These arches are supported by (1) the *plantar fascia* holding together the ends of the longitudinal arch; (2) the *inferior calcaneo-scaphoid ligament*, which, attached to the sustentaculum tali behind and the scaphoid in front, supports the head of the astragalus, and containing, as it does, a considerable amount of elastic tissue, gives, therefore, spring and elasticity to the longitudinal arch; (3) beneath this ligament, the tendon of the *tibialis posticus* passes forward to the scaphoid bone, and, therefore, assists in supporting the head of the astragalus and in maintaining the arch of the foot when the weight of the body is thrown on it in walking, etc. This tendon has a number of processes that pass to the

different tarsal and metatarsal bones and these processes hold together the bones, which, without these bands would otherwise tend to become spread out when the weight of the body is thrown on the foot in the upright position; (4) the *peroneus longus* has an action similar to the above, as far as the transverse arch is concerned, since it assists in maintaining this arch by its traction on the first metatarsal bone, while (5) the *tibialis anticus*, in-



(Fig. 10.)

Diagram illustrating the effect of Muscular Action in throwing up the Arch.

serted into the internal cuneiform, supports the astragalus, since the astragalus rests on the scaphoid, and the scaphoid on the internal cuneiform.

Diseases—*Tuberculosis* of the tarsal bones may arise on account of the large amount of cancellous tissue that enters into their formation, and because of the trau-

matisms to which their situation and functions predispose them, and, since the synovial membranes in connection with these bones are six in number, injuries would, therefore, have a greater chance of inducing tubercular synovitis, which, when started, could readily spread from one bone to another through continuity of the synovial tissue, and, lastly, the distance of this part of the limb from the heart, along with its dependent position, would tend to favor alteration in the circulation through the bones and thus cause them to be less resistant to the action of the bacilli.

Club Foot.—Of the five chief forms of this deformity, *talipes equinus* is nearly always acquired and is generally due to infantile paralysis of the extensor muscles. The heel is drawn up by the tendo Achilles, while the portion of the foot in front of the mid-tarsal joint is bent downwards and backwards so that the patient walks on the balls of the toes. *Talipes varus* is generally congenital and is most commonly seen in the condition described as equino-varus. In the latter form, *i.e.*, equino-varus, the heel is drawn up by the tendo Achilles and the portion of the foot, in front of the mid-tarsal joint, is drawn inwards and upwards by the tibialis anticus and the tibialis posticus, so that, the scaphoid is situated internal to, rather than in front of, the astragalus, with the result, that the anterior part of the foot is adducted and inverted, the inner border being turned upwards, and the outer border downwards, so that the sole looks backward and the dorsum forward—the patient walking, therefore, on the front part of the outer side of the sole. In *talipes calcaneus* the patient walks on the os calcis, and in the congenital form, the anterior part of the foot is drawn up by the extensor muscles. In *talipes valgus*, or flat foot, the two arches of the foot are more or less flattened, the anterior

part of the foot being everted. This variety is very commonly acquired, and is due to a yielding of the ligaments and tendons supporting the arches, so that they become lost, as arches, and the bones forming them come in contact with the ground, while the anterior part of the foot is more or less abducted and everted, leaving the head of the astragalus partly exposed on the inner side of the foot. In *talipes cavus* the sole is arched and the plantar fascia tense. This deformity has been considered as due to paralysis of the interossei muscles, but Walsham states that he has not found these muscles affected. *Hallux valgus* means an inclination outwards of the great toe at the metatarso-phalangeal joint, and it frequently happens that pressure of the boot causes an inflammation of the soft structures overlying the joint, *i.e.*, a bunion. *Hammer toe* is the condition in which the second toe (the one usually affected) is hyperextended at the metatarso-phalangeal joint and flexed at the first interphalangeal joint. This condition is quite frequently caused by hallux valgus, and both, when acquired, are due, as a rule, to the wearing of ill-formed boots. *Metatarsalgia* (Morton's affection) is characterized by intense pain in the neighborhood of the fourth metatarsal bone, and depends on a flattening of the transverse arch which permits the head of the metatarsal bone to compress the contiguous nerve. Whitman advises the building up of the anterior transverse arch by means of a steel support, while Gibney draws attention to the need of specially constructed boots in the treatment of this affection.

Amputation through the foot.—The incision for disarticulation of the *last phalanx of the great toe* is made by entering the knife just over the side of the head of the first phalanx, a little nearer to the dorsal than to the plantar surface, and then cutting along the toe to the

pulp. A dorsal incision joining the ends of the former is made, while the toe is forcibly flexed. In disarticulation of the phalanges, it must not be forgotten that the joint between the first and second phalanges corresponds to the middle of the whole length of the toe, while the metatarsophalangeal articulation is about one inch behind the web of the toe. In disarticulation of the *first* and *second phalanges* of the toes, the usual incision is the oval or racket incision, and, in the case of the second phalanx, is made by entering the knife about two-fifths of an inch above the joint, while in the case of the first phalanx, the incision begins a little below the joint. Continue the incision, then, in the median line, along to the web of the toe in the case of the first phalanx, or to the middle of the phalanx in the case of the second one, and curve it down to the plantar margins and join the ends by means of a transverse incision. In the case of the first phalanx of the great toe, this incision is modified by placing it at the junction of the internal and dorsal surfaces instead of in the median line, so that, when disarticulated, the line of union will be away from the line of pressure. *Lisfranc's operation*, or disarticulation at the tarso-metatarsal joint, is done by an incision on the dorsum, starting about half an inch behind the tuberosity of the fifth metatarsal bone, and continued forwards about half an inch in front of this tuberosity. It then passes across the dorsum of the foot about half an inch in front of the line of the joints, and then, on arriving at the inner border, it is turned backwards, along that border of the foot to end a little over half an inch behind the joint line. The plantar incision is made by entering the knife on the outer side of the foot, in the original incision, and then, following the edge of the fifth metatarsal bone for a short distance, it passes obliquely to the neck of the fourth metatarsal from which

point it sweeps across the sole to the inner border to join the dorsal incision, lying, in its course, just behind the heads of the metatarsal bones. It must be remembered that the joints between the tarsal and the metatarsal bones are not in the same plane, since the joint between the first metatarsal and the internal cuneiform is half an inch in front of the joint between the second metatarsal and the middle cuneiform, and that this latter joint is one-quarter of an inch behind the joint between the third metatarsal and the external cuneiform; and further, that, in this operation, after the dorsal ligaments binding the metatarsal to the tarsal bones have been divided, it will be necessary to insert the knife, held like a trocar, between the bases of the first and second metatarsal bones and then to elevate the handle until it is perpendicular to the dorsum of the foot so as to divide the strong ligament of Lisfranc.

Chopart's Operation.—The dorsal incision in this operation commences at a point about midway between the external malleolus and the tuberosity of the fifth metatarsal bone, and crosses the bases of the metatarsal bones to a point just behind the tuberosity of the scaphoid on the inner side of the foot. The plantar flap follows the main lines of Lisfranc's operation, but crosses the sole about the middle of the metatarsus. In this operation the bones are disarticulated at the medio-tarsal joint, which is composed of two articulations, viz., the calcaneo-cuboid on the outer side, and the astragalo-scaphoid on the inner. These two joints have distinct synovial membranes and lie almost in a transverse line, the astragalo-scaphoid, however, being convex anteriorly, and the calcaneo-cuboid somewhat concave anteriorly, the two somewhat resembling the letter *f*. If this shape of the medio-tarsal joint be not kept in mind, some difficulty may be encountered in the disarticulation.

Syme's Operation, or disarticulation at the ankle joint.—In this, the incision starts from the tip of the outer malleolus, a little nearer to its posterior than to its anterior border, and is carried down the heel at right angles to the long axis of the foot, across the sole, and then, vertically upwards on the inner side, to a point half an inch below the inner malleolus. The flap is cleared from the under surface and the tuberosities of the os calcis and then from its posterior surface. The dorsal incision is made by connecting the ends of the plantar incision by a cut that sweeps across the front of the ankle. In disarticulating, the knife should cut the lateral ligaments from within outwards, as, otherwise, it would be difficult to divide them, and, in the division of the tibia, the saw line should be one-quarter of an inch above the inferior margin of the bone.

It is important that the inner end of the plantar incision should be directly below the internal malleolus and not behind it, since, in the latter case, the posterior tibial or the origin of the plantar arteries would be severed, and, since the blood supply for the heel flap is derived chiefly from the internal calcanean branches of the external plantar, or from the posterior tibial just at its bifurcation, it would necessarily follow that an incision terminating behind the inner malleolus would sever these trunks, and, therefore, seriously impair the nutrition of the heel flap.

CHAPTER XXXIX.

HEAD AND NECK.

THE SCALP.

Structures Forming.
Landmarks for Nerves
and Bloodvessels.
Ligation of Arteries.
Injuries and Diseases.

THE SKULL.

Diploic and Emissary
Veins.
Fractures of the Skull.

The Scalp.—The tissues forming the scalp are, from without inwards: The integument, superficial fascia, occipito-frontalis muscle and its aponeurosis, delicate areolar tissue, and, lastly, pericranium. (1) The *superficial fascia*, like the superficial fascia of the palm of the hand or of the sole of the foot, is composed of a considerable quantity of fibrous tissue which is arranged in bands and connects the integument to the tissues beneath, while in the interstices, so formed, are lodged pellets of fat, hair bulbs, sebaceous glands, nerves and bloodvessels. These fibrous bands firmly unite the overlying skin to the occipito-frontalis muscle and its aponeurosis, and protect the delicate vessels and nerves of the scalp from injury, to which their exposed position and the underlying convex surface of bone would incline them. Besides, the close union of these structures permits much less gaping, in wounds of this portion of the superficial fascia, than is usually found in similar wounds of the superficial fascia elsewhere in the body, and, lastly, in such inflammatory affections of the scalp, as erysipelas, etc., there is very little swelling present (although the pain is severe), because of this intimate connection between the integument and the aponeurosis. The hair bulbs, so numerous in this fascia, are directed, with a forward slant, behind, and, with a backward slant,

in front. (2) The *occipito-frontalis muscle* is composed of two parts, the occipital and the frontal—the former from the outer two-thirds of the superior curved line of the occipital bone and from the ridge on the mastoid; into the epicranial aponeurosis, one and a half inches from its origin—the latter from the front portion of this epicranial aponeurosis, into the deep surface of the skin of the eyebrows and the root of the nose. *Nerve supply.*—The facial, through its posterior auricular branch supplies the occipital portion, while the temporo-facial branch of the same nerve supplies the frontal portion. *Action.*—The occipital part draws back the aponeurosis and with it the scalp, while the frontal portion, when its insertion is fixed by the contraction of the orbicularis palpebrarum, draws forward the scalp. Simultaneous action of the two parts of this muscle elevates the skin of the forehead into ridges, as seen in the expression of horror, etc. Contraction of the frontal portion, alone, produces the wrinkles of the forehead indicative of a more moderate degree of expression, as surprise, etc. (3) *Delicate areolar tissue*, which is almost devoid of fatty particles, loosely connects the epicranial aponeurosis to the pericranium beneath. The laxity of this union between the epicranial aponeurosis and the pericranium allows the former to glide easily over the skull, permitting, therefore, great freedom in the movements of the occipito-frontalis muscle and thus assisting in preventing the effects of such injuries to the skull as result from blows, etc., by causing the instrument inflicting them to glance, the more readily, off the skull. (4) *The pericranium*, or periosteal covering of the bones of the skull, is loosely attached to these bones, excepting at their margins, where it blends with the upper portion of the sutural membrane situated between the bones, and, since the dura mater is adherent

to this sutural membrane on its under surface, there is, therefore, by means of this membrane a certain amount of continuity between the pericranium above and the dura mater below. The pericranium differs from the periosteum that covers the bones elsewhere, in that its osteo-genetic layer is almost wanting; hence, when the pericranium is separated from the bone beneath in injuries, etc., necrosis does not result to the same degree as it does when the periosteum is stripped off a bone, since, in the latter case, the main supply of blood is cut off, whereas, in the former, *i.e.*, in the case of the skull, the main supply of blood is brought by the meningeal vessels of the dura mater and not by the pericranium—nor does any involucre or deposit of bone take place, when the pericranium is inflamed, as it does when the periosteum is affected, because of the almost entire absence of the osteo-genetic or bone forming layer.

Nerves and Bloodvessels of the Scalp.—These structures are contained in the superficial fascia and hence union can occur in very extensive wounds of the scalp in which large portions have been raised from the bones beneath, since these portions, themselves, contain the bloodvessels necessary for their nourishment.

Landmarks for the Nerves of the Scalp.—In front, over the glabella, is the *supratrochlear nerve*; next running upwards from the junction of the inner and middle thirds of the supra-orbital margin is the *supra-orbital nerve*; in the temporal region, near the outer canthus of the eye, and about one inch above the zygoma is the *temporal branch of the orbital* from the superior maxillary; over the temporal fossa are the *temporal branches of the facial nerve* and the *superficial temporal branches of the auriculo-temporal*. Over the posterior portion of the pin-

na is the *auricularis magnus*. Immediately behind the ear is the *posterior auricular* of the facial, and, along the posterior border of the mastoid is the *occipitalis minor*, while farther back, about midway between the mastoid and the inion, is the *occipitalis major*.

Landmarks for the Bloodvessels.--The *frontal artery* supplies the neighborhood of the glabella, the *supra-orbital* emerges from the orbit at the same point as the supra-orbital nerve, above referred to, viz., at the junction of the inner and middle thirds of the supra-orbital margin; the *superficial temporal* ascends over the zygoma to the side of the head, having the superficial temporal vein behind and overlapping it, and the auriculo-temporal nerve behind the vein, so that the order of these structures in the region of the zygoma, from behind forwards, is *nerve, vein, artery*. The superficial temporal divides into two branches, anterior and posterior, about one and a half inches above the zygoma—the anterior division, in its forward sweep, lying about one and a quarter inches above and behind the external angular process. Deeper in the temporal fossa are the *deep temporal vessels* from the internal maxillary, and the *middle temporal* from the superficial temporal artery. Immediately behind the meatus is the *posterior auricular*, while midway between the mastoid process and the inion is the *occipital artery*.

The **Veins** of the scalp follow the lines of the arteries, with the exception of the *supra-orbital* and the *frontal*; the latter, beginning about the level of the coronal suture, and passing downwards along the inner canthus of the eye under the name of the angular vein, continues over the face as the facial; whereas, the former drains the territory above the orbit and, communicating with the ophthalmic, empties into the frontal vein.

Ligation of the *Arteries*.—The *supra-orbital* may be ligated through an incision similar to that for exsection of the supra-orbital nerve, viz., by means of an incision, about one-half or three-quarters of an inch in length, and so placed, that its centre will be opposite to the foramen at the junction of the inner and middle thirds of the supra-orbital margin. After division of the skin, superficial fascia and orbicularis muscle, the supra-orbital artery and nerve are exposed, the nerve lying to the inner side of the artery, when the latter is isolated and ligated. The *superficial temporal* may be ligated just in front of the pinna of the ear, where it crosses the root of the zygoma, and through an incision, about one inch in length, dividing the skin, superficial and deep fasciæ, and, since the order of the structures here is, from behind forwards, nerve, vein and artery, the needle, in ligating the artery, should be passed from behind forwards. The *occipital artery* may be ligated, in the occipital region, through an incision carried upward and backward from the tip of the mastoid process, dividing the skin, superficial fascia and nerves, the sternomastoid and the splenius capitus muscles.

Injuries and Diseases of the Scalp.—*Wounds*.—There is very little *gaping* in wounds of the scalp because of the close union existing between the integument and the epicranial aponeurosis, referred to above. Hæmorrhage is often profuse in scalp wounds, because of the fact that the outer coats of the arteries are intimately adherent to the fibrous tissue of the superficial fascia, so that retraction is prevented and the application of hæmostatic forceps rendered difficult. Should the wound be transverse and involve the aponeurosis of the occipito-frontalis muscle, the gaping is much more marked than if the wound were a longitudinal one, and, when the aponeurosis of this muscle is divided, there is great danger of the inflammatory pro-

ducts spreading beneath it. Should septic processes develop in the wound, the laxity of the attachment of this epicranial aponeurosis to the pericranium, allows the pus to burrow beneath the aponeurosis and thus separate these structures, so that the whole of the scalp may be raised from the skull as though it rested on a water-bed. When this occurs the swelling is especially marked, through the influence of gravity, in front, above the orbits; behind, above the superior curved line of the occipital bone, and, laterally, above the zygoma and the mastoid, and at these points, especially in front and behind, openings for the exit of the purulent collection may be made. It follows then, that, in wounds involving the epicranial aponeurosis, the strictest application of asepsis should, as in all other wounds, not be deviated from. *Cephalhæmatoma*, or blood tumor, may be the result of blows or falls, or may result in the new born from pressure on the head of the child during labor. In it the collection of blood may be present (1) in the superficial tissues of the scalp, *i.e.*, superficial to the aponeurosis; (2) beneath the aponeurosis itself; (3) underneath the pericranium. In some of these cases of cephalhæmatomata, the sensation imparted to the examining finger resembles somewhat that from a depressed fracture, since they both present a hard edge with a central depression, but, in the case of the blood tumor, firm pressure on the edge of the tumor for a moment or two will cause the raised edge to disappear and the bone to be felt underneath, whereas, such pressure in fracture will have no effect. MacEwen's explanation of this peculiar shape of some of the cases of blood tumor is, that the inflicting blow causes disintegration and scattering of the cellular elements at the part struck, with a corresponding heaping up, at the margin of the area, which, along with the infil-

tration of blood that follows, produces the raised edge. When the cephalhæmatoma is beneath the pericranium, *i.e.*, between it and the bone, it is limited to that bone, because of the union of the pericranium to the sutural membrane, around the margins of the bone. When, however, the effused blood is beneath the aponeurosis of the muscle, it may spread over the whole head, as explained above; whereas, if it be confined to the superficial fascia, it may be situated anywhere, but is localized. The danger of erysipelas and other septic affections of the scalp will be dealt with when discussing the venous circulation of the bones of the skull and brain. *Tumors* of the scalp.—Nævi affecting the scalp may be either the capillary form, the cavernous or the mixed. These vascular tumors have special predilection for the tempero-frontal region—probably, as Virchow states, arising from the vascular tissue of the branchial arches. Plexiform angeiomata, or aggregations of dilated and tortuous arteries, generally affect the superficial temporal and the occipital arteries. Sebaceous cysts or wens frequently occur in the scalp, and in their extirpation, it is necessary to remove every vestige of the cyst, since, otherwise, recurrence may take place.

The Skull.—The skull is composed of two tables with an intervening cancellous tissue termed the diploë. The skull averages in thickness one-fifth of an inch, being thinnest over the temporal fossa and thickest in the neighborhood of the external occipital protuberance or inion. The *outer* or compact table of the skull affords strength and elasticity, while the *diploë*, being cancellous, acts as a damper to vibrations that may have been started in the outer table by a blow received on the vault, so that, on reaching the inner table these vibrations would be much diminished in force. The diploë is normally absent in the thinnest parts of the skull, *viz.*, in the squamous portion of

the temporal, in the cerebellar fossæ, in the orbital plates of the frontal, and at the floor of the lateral sinuses as they approach the base of the skull. The *inner table* is thinner, whiter and less regular than the outer and is very inelastic and fragile.

Diploic and Emissary Veins.—In the diploë are numerous venous channels which are of large size but have thin walls composed of endothelium overlying a layer of elastic tissue. These venous channels have no valves but communicate freely with one another in the adult (in the fœtus, however, each system is distinct), and are arranged as follows: (1) The *frontal diploic vein*, situated in the anterior part of the frontal bone, terminates in the supra-orbital, a tributary of the frontal vein of the scalp, *i.e.*, it empties *outwards*. (2) The *fronto-sphenoidal*, in the lateral part of the frontal bone, terminates in the spheno-parietal sinus which empties into the cavernous, *i.e.*, it empties *inwards*. (3) The *anterior temporal*, in the anterior part of the parietal bone ends, after piercing the outer table, in the deep temporal veins externally, and in the superior petrosal sinus, a tributary of the lateral, internally, *i.e.*, it empties both *outwards and inwards*. (4) The *posterior temporal*, in the posterior part of the parietal bone, ends in the lateral sinus, *i.e.*, *inwards*. (5) The *occipital*, in the occipital bone, empties into the occipital vein externally, or into the lateral sinus internally, *i.e.*, *outwards and inwards*.

Thus there is seen to be a direct communication between the venous systems outside of the cavity of the cranium and the sinuses inside the cranium. In addition to the above, there is another communication established with the interior of the skull, *viz.*, that by means of the emissary veins.

These **Emissary Veins** are as follows, viz.: (1) One, occasionally present, passing through the foramen cæcum and connecting the anterior end of the longitudinal sinus with the nasal veins; (2) another, passing through the mastoid foramen between the lateral sinus and the posterior auricular vein; (3) a third, through the parietal foramen between the longitudinal sinus and the veins of the scalp; (4) a fourth, connecting the cavernous sinus, through the ophthalmic vein, with the supra-orbital and the angular veins; (5) veins passing through foramina at the base, viz., one, through the anterior condyloid foramen, connecting the occipital sinus internally, with the deep veins of neck externally; another, through the posterior condyloid connecting the lateral sinus with the deep veins of neck. In addition to these, there are a few small veins passing through the foramen ovale, the foramen lacerum medium and the foramen Vesalii, which connect the cavernous sinus with the pterygoid and the pharyngeal plexuses of veins, and these plexuses communicate with the facial vein in the following manner, viz.: The pterygoid by means of the deep facial, which passes downwards and forwards between the buccinator and the masseter muscles to end in the facial vein; and the pharyngeal by emptying into the termination of the common facial vein. Lastly, there is, to a slight degree, a direct connection between the veins of the pericranium and the venous channels of the diploë by means of minute openings in the outer table of the skull. These emissary veins may possibly serve a useful purpose by permitting a free escape of blood from the sinuses when the latter are over-distended, especially in infancy during fits of passion, etc, but they are of especial importance in connection with pathological processes, offering as they do, direct channels for the spread of septic processes from

the exterior, into the sinuses in the interior of the skull. This secondary cerebral involvement may occasionally be seen in such conditions as erysipelas of the face or head, septic wounds of the scalp, osteomyelitis, etc.

Fractures of the skull are of importance, chiefly in so far as they affect the contents of the cranium, and, in connection with fractures, it is of interest to note some of the means provided for the protection of the brain from injury, and, among these, are the following: (1) The mobility of the scalp which tends to convert a direct into a glancing blow; (2) the dome-like shape of the skull and the mobility of the head on the spine; (3) instead of one uniform bone forming the skull, its division into a number of individual bones, separated, excepting in later life, by the sutural membrane, tends to diffuse the vibrations which might otherwise produce a fracture; (4) the elasticity of the outer table and the power of deadening the vibrations possessed by the cancellous diploë; (5) the pericranium without and the dura mater within, which act, just as a wet washleather covering and lining would to a bell, viz., dampen its vibrations (Nancrede); (6) the arrangement, at some of the sutures, whereby a part of the border of one bone overlaps that of another, as at the upper part of the frontal bone, or on the lower part of the parietal, or where the squamous portion overlaps the inferior border of the parietal. The part this arrangement plays in protecting the brain beneath is shown by the diffusion of the effects of a blow, received on the skull, to distant parts rather than its concentration upon the tissues directly beneath, and this diffusion is seen in instances where pain is felt in the cheek, the result of a blow received on either the upper part of the frontal or parietal bones. In the case of the latter, the upper part of the parietal being depressed by the blow, would force the lower

border of the bone outwards against the squamous portion of the temporal, and then passing through the temporal, the effects of the blow would be conveyed to the zygoma and expend itself in the malar bone, and since this malar articulates with the superior maxillary and the frontal, we can understand the aching present in the region of the face. When the blow has been received on the upper part of the frontal, the same train of events would follow, as in the case of the parietal, since the upper part of the frontal rests on the parietal.

It is claimed that the vibrations set up by the application of violence to the vault are transmitted to the sella turcica through buttresses which diverge from the centre of the vault to converge, beneath, near the sella turcica. These buttresses are: One, in front, the fronto-ethmoid; one, behind, the occipital, and two on either side, viz., the orbito-sphenoid and the petro-mastoid. Fractures of the skull may be either direct or indirect. *Direct fractures* result from the direct application of force to a limited area of the skull, the bone yielding at the point struck. While the great majority of direct fractures are limited to the vertex, occasionally they may occur at the base, as from punctured wounds or from falls on the feet causing fractures in the neighborhood of the foramen magnum, or from falls on the lower jaw fracturing the glenoid fossa. *Indirect fractures* arise from a diffused blow, as in falls on the head, etc. Fractures of the vault may be *fissured*, *punctured*, *depressed*, *star-shaped* and *comminuted*, and, with the exception of the punctured variety, which is necessarily compound, they may be either simple or compound. A *fissure* which is present in a compound fracture may present some difficulty in diagnosis, since it might be mistaken for the line of a suture, but the knowledge of the direction of a suture would assist in the diagnosis, and

besides, in a fracture, no amount of rubbing with a sponge will remove the line of blood (bright red in recent injuries, but darker in color in older ones) effused between the edges of the fractured bone. *Punctured* wounds of the skull may be inflicted with a sharp-pointed instrument such as the blade of a knife, etc., and, if the instrument inflicting the wound, be driven into the bone at right angles, there may be neither splintering nor depression of the inner table; whereas, if the instrument be dull, such as a blunt-pointed nail, the end of a cane, etc., there may be extensive comminuting of the inner table. *Depressed* fractures usually cause a greater degree of splintering of the inner table than one would think, judging from the size of the depression of the outer table. This is probably due to the fact, as pointed out by Teevan, that the bone yields, first, on the side of extension, *i.e.*, that the table exposed to most extension gives way first, just as in breaking a stick over the knee. Possibly the diffusion of the force as it passes through the diploë and the brittle nature of the inner table are contributing factors. The elasticity of the outer table causes a recoil which lessens the depression of this table; whereas, in the case of the inelastic inner table no such recoil occurs and, hence, this table remains more depressed than the outer. The frontal sinuses appear, first, about the age of seven as prolongations from the anterior ethmoidal cells, but do not often attain any great size until after the twenty-fifth year of age. A depressed fracture in the region of these sinuses may not cause any splintering of the inner table, yet these wounds should be carefully examined in every case to ascertain the existence of a sinus, since, even in advanced adult age, the frontal sinus may be undeveloped or may exist on one side only. Attention has already been drawn

to the possibility of mistaking the raised border of a cēphalhæmatoma for a depressed fracture and the means of differentiating the one from the other.

Fractures of the Base are generally parallel to the direction of the force causing them, so that, in blows or falls on the side of the head the direction will be, as a rule, transverse, whereas in injuries received on the frontal or occipital regions, it will be longitudinal. These fractures may result from direct or indirect force—the *direct* being due to thrust wounds implicating the orbit, the cribriform plate of the ethmoid, the sphenoid or rarely the occipital bone, or they may be due, as mentioned above, to falls on the lower jaw, or feet, or to falls in which the head strikes some yielding body such as soft earth, etc. The *indirect* are due, according to Aron's law, to radiation of the fissure, from the point struck, by the nearest way to the base. In those instances in which there occurs a fracture of the base, without one of the vault, the explanation is, that the basal fracture occurs from compression, *i.e.*, that the skull bursts, as it were, at the lower segment. As a rule, force applied to the frontal region produces, when the base is affected, a fracture of the anterior fossa. When applied to the parietal region it produces a fracture of the middle fossa, or to the occipital region, the posterior fossa. Among the *symptoms* of fracture of the base, are: (1) *Ecchymosis*.—Ecchymosis may be due to direct injury to the soft parts without any involvement of the skull whatever, and, when occurring in the region of the orbit, the ecchymosis resulting from a purely local injury must be distinguished from that following a fracture of the base. In the former instance the bruise or "blackeye" appears very shortly after the receipt of the injury, and, besides, if the conjunctiva has been injured at the same time, discoloration of the eyeball, which occurs, almost immediately, in

the substance of the conjunctiva, is of a brighter color on account of the facility of oxidation from its exposed position. In cases of effusion of blood into the conjunctiva from a purely local injury, if the conjunctiva be made to glide over the sclerotic, the discoloration is seen to move with it, since, as already stated, the effusion of blood is into the structures of the conjunctiva, and not under it, as it is in the case of an ecchymosis due to a fracture. In the latter case, *i.e.*, in fracture, not only is the effusion of blood beneath, rather than in the conjunctiva, but it appears here before showing itself in the lower lid, and further, the upper lid is not affected, in fracture of the base, unless the fracture involve the orbital ridge as well as the orbital plate. The total absence of ecchymosis, however, cannot exclude a basal fracture, since Hewett has shown that, out of twenty-three cases of fracture of the frontal bone, in eight there was no evidence whatever of extravasation of blood. (2) *Escape of blood.*—Nor does the escape of blood afford positive proof that a fracture has occurred, for, though in fracture of the anterior fossa, epistaxis may occur, and in injury to the middle fossa, hæmorrhage from the external meatus may result, and though blood may find its way into the pharynx from a lesion involving the posterior fossa and passing through the basilar process; yet, hæmorrhage may occur in either of these situations from injury to the superficial structures, such, for instance, as, from the mucous membrane of the nares, or from, in the case of the ear, laceration of the meatus itself, or from rupture of the membrana tympani, or, lastly, in the case of the pharynx, from the mucous membrane of that cavity, hence escape of blood is only of value when it is persistent and is taken into consideration along with other evidences of serious cranial injury.

It must not be forgotten that a fracture involving the petrous portion of the temporal bone may permit blood to be effused into the tympanum and thence, passing into the pharynx through the Eustachian tube, be swallowed.

(3) *Paralysis of Nerves.*—This will be considered later on.

(4) *Escape of cerebro-spinal fluid* from the ear and nose.—In the case of the ear it would be necessary in order to allow the fluid to escape, that the membrana tympani should be ruptured and that the tympanum should be opened up, and further, that the fracture should traverse the internal auditory meatus, and, lastly, that the meningeal sheath around the auditory and the facial nerves should be torn (the cerebro-spinal fluid lies within this sheath), while, in the case of the nose, the dura mater must be torn, and, in addition, the orbital plates fractured.

Meningeal Arteries.—These vessels are for the purpose of nourishing the dura mater and the bones of the skull, especially the latter, and are derived as follows, viz.: Those in the anterior fossa are from the anterior and the posterior ethmoids; those in the middle fossa are from the ascending pharyngeal, the internal carotid and the internal maxillary; while those belonging to the posterior fossa are from the occipital, the ascending pharyngeal and the vertebral. The chief one of these meningeal vessels is the *middle meningeal artery*, which arises from the internal maxillary and ascends to the interior of the cranium through the foramen spinosum, and then, after passing up the greater wing of the sphenoid, divides into two branches—anterior and posterior. The anterior branch of this middle meningeal artery is lodged in a depression on the greater wing of the sphenoid and on the anterior portion of the parietal (often the groove in the parietal is converted into a canal), and terminates near the superior

longitudinal sinus; whereas, the posterior branch lies on the posterior part of the squamous and then on the corresponding portion of the parietal. This vessel is the principal source of extra-dural hæmorrhage. Hewett found that the middle meningeal was involved in twenty-seven out of thirty-one cases of this condition. Fracture of the skull generally causes injury to the artery from the sharp edge of the bone lacerating the vessel, especially when it is contained in a canal, as above mentioned, although Jacobson showed, that in eight cases out of seventy, in which the middle meningeal was affected, there was no fracture. In these cases it is probable that the sudden alteration in the shape of the skull that results from violent injuries may overstretch and so rupture the vessel without producing a fracture of the bones. It is in extra-dural hæmorrhage that *relapsing unconsciousness* so frequently occurs, since, when the vessel is torn, the patient may recover sufficiently to go about for a few hours, or even longer, before the blood, pouring out from the injured vessel, will compress the brain sufficiently to induce coma, as in a recent case, where the batter in a baseball game struck a man, who was intoxicated, on the head. The latter walked around for an hour or two and then fell asleep, so his friends thought, in which condition he was removed to his home, still under the belief that he was drunk. He died that night, and at the post-mortem fully a half-pint of blood was found between the dura mater and the skull.

CHAPTER XL.

THE MENINGES OF THE BRAIN.

CEREBRAL SINUSES.

LANDMARKS.

Diseases of

The Meninges of the Brain.—The *dura mater* is a tough fibrous membrane which is in contact with the inner surface of the cranial bones, and acts as a periosteal covering for them, and which, in addition, affords support and protection to the brain. In accordance with these functions it is arranged in two layers, viz., a periosteal and a supporting layer. The supporting layer constitutes the projections of the *dura mater* into the cavity of the cranium, termed the *falx cerebri*, the *falx cerebelli* and the *tentorium cerebelli*. The separation of these layers forms also the cranial sinuses which will be considered later on.

The *arachnoid* forms a well defined limiting membrane on the side towards the *dura mater*—the interval between the *dura mater* and this membrane being termed the subdural space—but on its inner surface it fades away, gradually, into what is erroneously termed the subarachnoidean space. This so-called space is, in reality, filled with tissue—the subarachnoidean tissue—formed of fine trabeculæ lined by endothelium. The *arachnoid* does not, like the *pia mater*, dip into the fissures and sulci of the brain, hence, there is left between them, *i.e.*, between the *arachnoid* and the *pia mater*, an interval filled with this subarachnoidean tissue. Posteriorly, between the medulla and the overhanging inferior vermiform process of the cerebellum, this interval or subarachnoidean space is strongly marked, while anteriorly, extending to the commencement of the great longitudinal fissure beneath the pons and crura, and limited laterally, by the tempero-

sphenoidal lobes, is another distinct interval or space, and these two intervals or spaces are connected with one another around the sides of the medulla oblongata.

This subarachnoidean space contains the cerebro-spinal fluid, and the larger divisions of the space, above mentioned, at the base, allow the brain to rest, as it were, on a sort of water-bed, thus minimizing the effects of jars, blows, falls, etc.. The cisterna magna or posterior space, *i.e.*, the portion of the subarachnoid space behind the medulla, communicates, by means of three small openings (the chief one of which is the foramen of Majendie) in the pia mater covering the fourth ventricle. By means of these foramina, the ventricles of the interior of the brain, that are distended in such diseases as hydrocephalus, etc., may unload themselves into the subarachnoid space, and the increased quantity of fluid, passing down into the subarachnoidean space of the coverings of the cord may be better accommodated in the vertebral canal than in the cranium, since the soft tissues joining the vertebræ together permit more or less distention. It is possible that the Pacchionian bodies may act as an outlet for increased pressure in the cerebral sinuses, since they consist of a central core of subarachnoidean tissue and are covered with arachnoid membrane as well as with a layer of dura mater, and, inasmuch as they project into the longitudinal sinus, and, since injections thrown into the subarachnoidean space find their way into the sinus, it is possible that, conversely, they may offer an outlet from the congested venous circulation into the subarachnoid space.

The *pia mater* is a delicate vascular membrane and serves the purpose of conveying to the interior of the brain the finer bloodvessels of the larger trunks which have divided freely in the subarachnoid space.

The Cerebral Sinuses are formed by a separation of the two layers of dura mater. These sinuses convey the blood from the surface and the interior of the brain itself to the outside of the skull. The longitudinal, superior and inferior, the straight, the occipital and the superior petrosal, converge to the internal occipital protuberance and then pass, by means of the lateral (especially the right one), to the jugular foramen, where they meet with the inferior petrosal conveying the blood from the cavernous, the circular, the transverse and the sphenoparietal. The cerebral veins empty into these sinuses, and, in the case of the superior longitudinal and the posterior part of the lateral, these veins run for a little distance in the walls of the sinuses and then open out in a direction opposite to the current of blood in the sinuses. By this arrangement, and because of the presence of trabeculæ in the interior of the sinuses, the velocity of the blood current is diminished and thus the circulation of the blood within the cranium is equalised.

Diseases of the Cerebral Sinuses.—Communicating, as the sinuses do, with the exterior, by means of emissary veins, it follows that infective sinus thrombosis is by no means uncommon (non-infective thrombosis may occur in wasting diseases whereby the current of blood is rendered very slow, so that coagulation results, as seen in cholera infantum, marasmus, etc). The influence of the emissary veins in the production of this serious condition of infective sinus thrombosis is seen in such infections as erysipelas, septic wounds, etc., involving the region of the face, and, under these circumstances, the connection is by means of the ophthalmic vein—a tributary of the cavernous sinus—with the supra-orbital and facial veins. Another instance is where the nasal passages are involved. In this case the disease spreads through the communica-

tion of the superior longitudinal sinus with the venous system of the nose by means of a small vein which passes through the foramen cæcum; or, it may be seen in infective periostitis, the result of dental caries; or in suppurative tonsillitis; or retro-pharyngeal abscess, etc., and in these instances, the infection spreads to the cavernous sinus through the pterygoid plexus of veins. It may result from infective processes which develop in the tympanum and then pass along the small emissary veins that connect this cavity and the petrosal bone with the lateral (sigmoid) sinus; or, it may develop from inflammatory conditions situated in front of the ear and spreading along the superficial temporal vein to the longitudinal sinus through the parietal foramen; or, from those situated behind the ear and passing to the lateral sinus through the mastoid foramen, or, from deep-seated abscesses in the posterior part of the neck affecting the occipital sinus through the anterior condyloid foramen, or the lateral sinus, through the posterior condyloid foramen. Lastly, osteomyelitis affecting the bones of the skull may induce infective disease of the sinuses, since, as already mentioned, some of the diploic veins open into these sinuses. *Conversely*, in sinus phlebitis, there may result distention of these emissary veins, as seen when the cavernous sinus is affected. Here there may be swelling of the eyelids, or of the conjunctiva, etc., or, if the longitudinal be affected, epistaxis may result, or œdema may occur over the temporal region through the parietal foramen; or there may be swelling over the mastoid, through the mastoid foramen, when the lateral sinus is inflamed.

Landmarks for the *middle meningeal artery*.—This vessel begins on a level with a point half an inch in front of the external auditory meatus, and from this point, the posterior branch runs towards the lambda, passing about

half an inch above the auditory meatus, while the anterior branch curves, with convexity forwards, to the anterior inferior angle of the parietal bone, at which point, viz., one and a half inches behind the external angular process and one and a half inches above the zygoma, this artery is usually wounded. The remaining portion of the anterior branch may be indicated by first establishing *Reid's base line* which runs backwards from the lower border of the orbit through the centre of the external auditory meatus. Having mapped out Reid's base line, draw another line from the external angular process of the frontal bone parallel to it. Along this line measure off the distances of one, one and a half, two, two and a half, inches. Through these points draw lines at right angles to Reid's base line from the upper border of the zygoma, and measure the same distances up these vertical lines as they are distant from the external angular process. Join the ends of these vertical lines and the course of the main part of the anterior branch will be indicated. ,

Landmarks for Cerebral Sinuses.—The *longitudinal sinus* may be represented by a line extending from the glabella, *i.e.*, from the root of the nose, to the inion, or external occipital protuberance. This line gradually increases from one-quarter of an inch in width, in front, to half an inch in width at the centre of the vertex. The *lateral sinus* is divided into two parts, viz., the lateral sinus proper, or transverse portion, behind, and the sigmoid portion in front, and of these, the former corresponds to a line about half an inch in width starting from the external occipital protuberance and terminating at the asterion or parieto-occipito-mastoid junction, situated one and a half inches behind and three-quarters of an inch above the centre of

the external meatus ; whereas, the latter or sigmoid sinus, extends with a gentle curve from the asterion towards the apex of the mastoid, so that the anterior border of the sinus is half an inch behind the posterior border of the external auditory meatus.

CHAPTER XLI.
THE CEREBRUM.

FISSURES AND CONVOLUTIONS.	PRESSURE SYMPTOMS OF TUMORS.
CEREBRAL LOCALIZATION.	CEREBRAL HÆMORRHAGE.
INTERNAL CAPSULE.	LANDMARKS.
ARRANGEMENT OF FIBRES.	OPERATIONS.

In connection with the cerebrum it is unnecessary, in a work of this nature, to do more than briefly refer to those portions, the knowledge of which is essential for the proper understanding of cerebral topography and the effects produced by tumors involving the brain.

Fissures and Convolution.—(Fig. 11). Examining the *lateral aspect* of the cerebrum we find a fissure, starting about half an inch behind the middle of the convexity of the cerebrum at the longitudinal fissure, and running downwards and forwards for about three and three-quarter inches. This is the *fissure of Rolando*. Near its termination another prominent fissure is seen, viz., the *fissure of Sylvius*, which, running upwards and backwards, has a vertical limb, about half an inch in front of the lower end of the Rolanderic fissure, and an anterior limb, a little in front of the vertical. The rest of this fissure, *i.e.*, that portion behind the vertical limb, is the horizontal limb. These fissures can always be identified on the lateral aspect of the cerebrum, and are of great importance, since the convolution in front of the fissure of Rolando, viz., the ascending frontal, and that, behind—the ascending parietal—are the chief parts of the brain associated with motion, *i.e.*, in which are situated the motor areas. In front of the fissure of Rolando is the *frontal lobe* with its three fissures—the *precentral*, parallel to the fissure of Rolando and marking off the ascending frontal convolu-

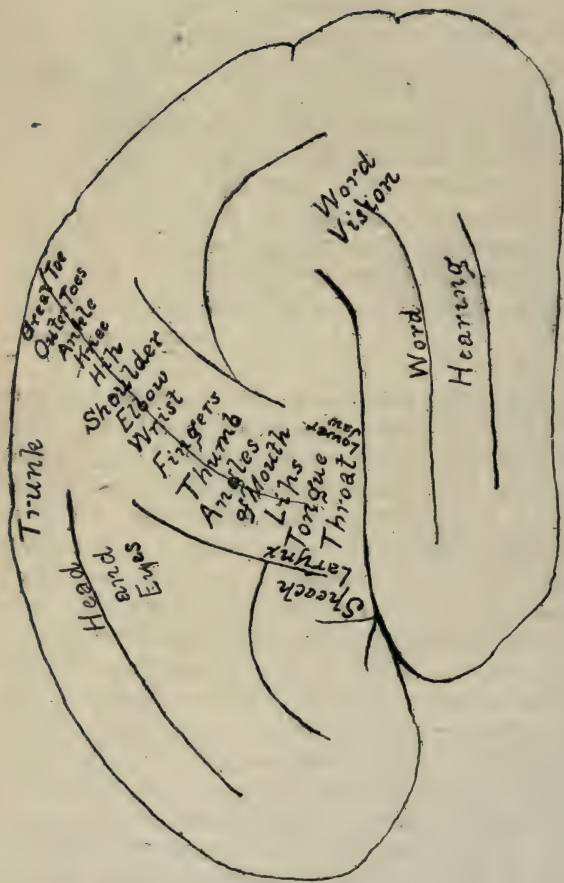
tion, and the *superior* and *inferior frontal*, which form the superior, middle and inferior frontal convolutions. Behind the fissure of Rolando is the intraparietal fissure, which passes upwards and is parallel in its lower part to the fissure of Rolando, and then, curving backwards, is parallel to the longitudinal fissure. The intraparietal fissure terminates near the parieto-occipital fissure, and assists in marking off the ascending parietal convolution, while the portion running parallel to the longitudinal fissure divides the parietal lobe into the superior and the inferior parietal lobules. The latter, *i.e.*, the inferior parietal lobule, is divided into two gyri—one, the anterior, is the supra-marginal and surrounds the termination of the fissure of Sylvius, while the other—the angular—surrounds the posterior end of the superior temporal fissure. The posterior portion of this aspect of the brain is formed by the occipital lobe and is divided, by two fissures, into three convolutions, *viz.*, the superior, the middle and the inferior occipital convolutions. Beneath the fissure of Sylvius is the temporo-sphenoidal lobe which is divided, by means of four fissures, into five convolutions. The fissures are the superior, the middle and the inferior, and, on the mesial or under surface of this lobe, the collateral. The convolutions are the superior, middle and inferior on the lateral aspect and the fusiform and lingual on the mesial surface. On the *mesial surface* of the hemisphere is the calloso-marginal fissure, separating the falciform lobe or gyrus fornicatus which surrounds the corpus callosum, from the mesial surface of the frontal lobe. The conjoined upper ends of the ascending frontal and parietal convolutions are termed the paracentral lobule. Between the hinder end of the calloso-marginal fissure, which curves up to the margin of the cerebrum, and the parieto-occipital fissure, is situated the

mesial surface of the parietal lobe, *i.e.*, the præcuneus, whereas, between the parieto-occipital fissure and the calcarine fissure, is the inner surface of the occipital lobe, *viz.*, the cuneus, and, lastly, beneath the calcarine fissure is the posterior part of the lingual lobe. On drawing the anterior end of the temporo-sphenoidal lobe backwards, and the frontal lobe forwards, and then, on raising up the lower conjoined ends of the ascending frontal and the ascending parietal convolutions, the *island of Reil* is exposed, having been hidden by these conjoined ends, which are, on that account, called the operculum.

The *cerebellum*, situated beneath the tentorium cerebelli, is composed of two lateral lobes united by the vermiform process.

Cerebral Localization.—*Motor centres.*—Experimental research and pathological conditions have shown that the centres which preside over motion are situated in the neighborhood of the fissure of Rolando. In general terms, this region may be divided into fifths—the upper fifth presiding over the leg; the middle two-fifths, over the arm, and the lower two-fifths over the face, speech, etc. The relative position of the leg centres, from above downwards, is as follows, *viz.*, great toe, outer toes, ankle, knee and hip. For the arm centres, the order from above downwards is shoulder, elbow, wrist, fingers, thumb; while, for the face, in the same order, are, elevation and depression of the angles of the mouth, lips, tongue, throat. In front of these centres is that for the larynx, and for speech, the latter centre, being situated in the posterior portion of the third frontal, or Broca's convolution. (Fig. 11.)

Sensation.—Some experimenters place the cerebral centres for sensation in the neighborhood of the motor area of the cortex, but the weight of investigation is



(Fig. 11.)

Motor Centres of Cortex.

rather in favor of the view, that the gyrus fornicatus and the hippocampal region and possibly the postero-parietal convolution are especially concerned with the representation of sensation.

Visual localization.—It is possible that portions of the retina, possibly quadrants, are related to special centres in the brain, but, in general terms, it may be said that the angular gyrus and the occipital lobe preside over vision. Ferrier states that the centre for the macula lutea is situated in the angular gyrus, while Hensechen believes, that the neighborhood of the calcarine fissure has intimate relations with the macula lutea. The centre for *word vision* is situated in the inferior parietal convolution and especially in the neighborhood of the angular gyrus. Whether word blindness is located here or immediately beneath, in the subjacent white tissue, it is impossible to say, since there lies beneath the angular gyrus an association tract connecting the memory picture of words seen, with that of words heard, hence a lesion of the angular gyrus could interrupt this tract. A tumor, therefore, situated at the angular gyrus may cause a loss of power of understanding printed words or of reading aloud.

Auditory localization.—The portion of the cerebrum presiding over hearing is the superior and middle temporal convolutions. Mills quotes an interesting case in which a patient was able to hear sounds such as music, a knock at the door, etc., but she could not understand spoken words, and at the post mortem he found a lesion involving the hinder ends of these convolutions, hence he deduces that the centre for *word hearing* is situated at the posterior thirds of the superior and middle temporal convolutions. The *naming centre* or the *idea centre*, for the grouping of the evidences presented by the different senses and the arrangement of them into ideas, is situated,

in all probability, in the posterior parts of the third and fourth temporal convolutions. The centres for taste and smell are situated in the region of the hippocampal gyrus.

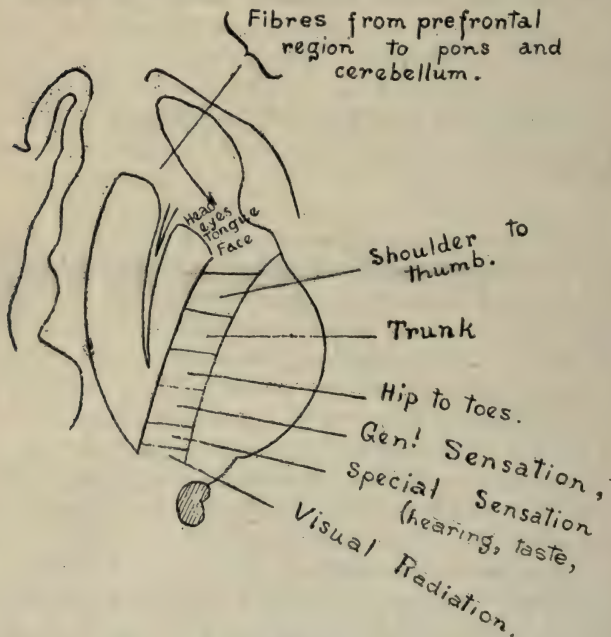
Arrangement of the **Fibres of the Cerebrum, Internal Capsule, etc.**—There are two sets of fibres in the brain—one, commissural or association fibres, and the other, projection fibres. The former, *i.e.*, the *commissural fibres*, unite different convolutions as well as the different parts of one hemisphere together, or they unite the two hemispheres together, as in the case of the corpus callosum and the commissures. These fibres, as their name indicates, no doubt harmonizê and associate the different portions of one hemisphere with each other, or one hemisphere itself with the other.

Projection Fibres.—These are fibres, which run from the cortex or generating portions of the brain to their distribution in the optic thalamus, corpus striatum, pons, medulla and cord. Inasmuch as the outlet or avenue, through which they find exit from the brain, is very narrow as compared with the extent of origin of these projection fibres, it follows, that to pass down to the medulla, cord, etc., they must be collected into as small a bulk as possible where they leave the brain, and the portion of the brain at which this concentration occurs is the *internal capsule*. We might liken the arrangement of these fibres to the household broom, the expanded end of which represents the cortical origin of the projection fibres, and the end of the handle, to which the broom top is affixed, the internal capsule. Some of these projection fibres, in passing downwards to the base of the brain, cut through the corpus striatum, dividing it into two parts, an internal—the caudate nucleus, and an external—the lenticular nucleus, while the remainder of these projection fibres find exit from the cerebrum between the optic thalamus inter-

nally, and the lenticular nucleus externally. After passing down between these bodies, *i.e.*, between the caudate nucleus and the optic thalamus on the inner side and the lenticular nucleus on the outer side, the projection fibres pass under the optic thalamus to the crus cerebri and thence into the pons, medulla and cord. The portion of the internal capsule between the caudate and the lenticular nucleus is shorter than that between the latter and the optic thalamus and the angle at which these two parts join is termed the knee-like bend or genu of the internal capsule.

The **Relative Position of the Fibres** forming the *internal capsule*, is as follows: In front, between the caudate and the lenticular nucleus, *i.e.*, in the *anterior limb*, are the fibres that pass down from the frontal lobe. Some of these fibres terminate in the grey nuclei of the pons, while others pass through the middle peduncle to the cerebellum and associate the latter with the frontal lobe. The *genu* or knee and the *anterior two-thirds of the posterior limb* of the internal capsule contain *motor fibres* for the opposite side of the face, tongue and body. Those for the face, *i.e.*, the facial tract, cross the middle line of the pons to end in the nucleus for the facial nerve in the lower part of the pons; while those for the tongue, *i.e.*, the hypo-glossal tract, terminate in the nuclei for the hypo-glossal nerve in the upper part of the medulla. Both tracts are situated at the genu or knee of the internal capsule, just in front of the motor fibres for the rest of the body. Immediately behind these cranial tracts in the internal capsule, are the motor fibres for the arm, trunk and leg, situated in the order named (Fig. 12). These motor fibres of the projection system pass down, after leaving the internal capsule, beneath the optic thalamus; then in the crus cerebri as a part of the crusta or "foot of the crus" (Fig. 13); then through the pons and medulla to decussate (the ma-

majority of them) in the ventral portion of the latter structure, and to end in arborizations around the cells of the ventral horn of the spinal cord, from which cells, the axis cylinder processes of the lower motor neurones pass out to the muscles on the same side of the cord, but on the side of the body opposite to the cerebral motor area. Im-



(Fig.12.)

Diagram illustrating the relative position of the Tracts in the Internal Capsule.

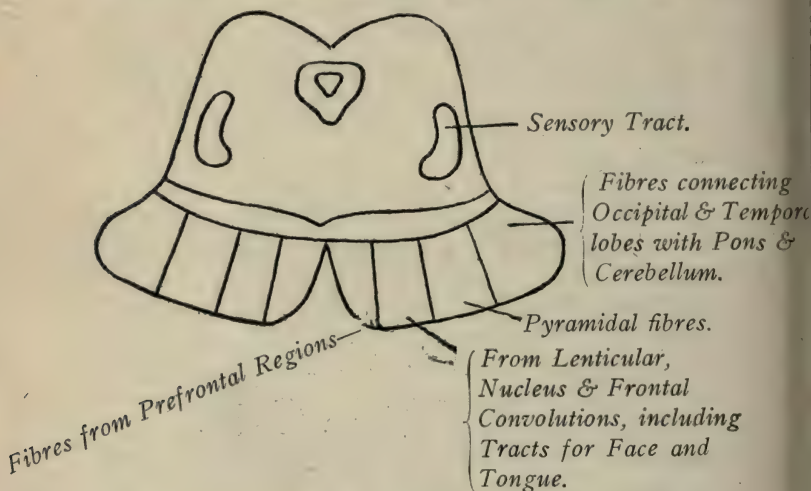
mediately behind these motor fibres of the internal capsule, *i.e.*, in the posterior third of the posterior limb of the capsule, is the *sensory tract*. This tract, beginning in the lower sensory neurones, enters the cord and passes up-

wards, some of the fibres, especially those for pain and temperature, probably decussating at the different levels of the cord, while others—those for common sensibility—decussate at the upper part of the medulla. These pass up in the medial lemniscus to end in the optic thalamus, in which a higher neurone system begins, to end in the cortex. The sensory path passes up through the tegmentum of the crus, and, along with those fibres that have been interrupted in the thalamus, enter the internal capsule, occupying the posterior third of the posterior limb, as mentioned above, to terminate in the gyrus fornicatus or in the hippocampal region. While distinct partitions for motor and sensory fibres would apparently exist from the above description, in the internal capsule, yet it is altogether likely that these tracts are more or less intermixed. Behind the general sensory path in the capsule is the *visual tract*, which connects the optic thalamus with the cortical centres for vision. Next to this visual tract is the acoustic tract for the temporal lobe, and, lastly, behind the latter, the olfactory tract for the hippocampal region. (Fig. 12.) In addition to these tracts, the internal capsule contains projection fibres that go to the caudate and the lenticular nuclei, along with fibres that pass between these bodies, and still others that are connected to the nuclei in and below the optic thalamus.

Pressure Symptoms of Tumors of the Brain.

General symptoms.—Headache is probably due to distention of the dura mater with resultant impression on the fifth nerve that supplies this membrane. It can hardly be caused by pressure on the cerebral tissue itself, since Majendie has shown that the cerebral tissue is non-sensitive. A tumor involving the cerebellum is often accompanied by constant, severe pain because of the limited space this portion of the brain occupies, viz., the posterior

fossa, and because it is bound down by the tentorium cerebelli. The slow pulse and the vomiting, when present in tumor of the brain, are probably dependent on disturbance of the pneumogastric nerve. Convulsions may be the result of the increased cerebral pressure and, so also, is optic neuritis. In the latter case, since the optic nerve is surrounded by two sheaths at its entrance into the



(Fig. 13.)

Diagram showing Tracts in Crus Cerebri.

sclerotic—one, a continuation of the dura mater, and the other, from the pia mater, it follows that, when the pressure in the brain is increased, the cerebro-spinal fluid is forced into and distends these sheaths and thus causes compression and resultant inflammation of the nerve. Double optic neuritis is present in about 80% of cases of cerebral tumor. When the neuritis affects one eye only, it is pos-

sible that the cause is some disease of the optic nerve, itself, in the orbit or in front of the optic chiasm.

Focal Symptoms.—When the lesion is confined to the cortex it may cause such localized symptoms as paralysis of the opposite hand, or arm or leg, etc., and, in addition, when the cortex alone is affected, we may have Jacksonian epilepsy, *i.e.*, spasms limited to one particular part, such as the thumb, hand, etc., or the convulsive seizure may start in some such area and spread to other regions, as, for instance, beginning in the finger, it may spread to the hand, then the arm or leg, thus radiating from the primary focus just as the ripples, that follow a stone thrown on the surface of a pond, radiate from a centre, but if the growth or blood clot affects the internal capsule, then, because of the narrow area through which all of the fibres pass, a very small lesion will likely produce widespread disturbance of motion and sensation.

Tumor of the frontal lobe, or the so-called “silent region,” is associated with changes in the disposition of the patient, such as irritability, stupidity, etc. No motor paralyzes result, at first, unless the posterior part of the third frontal or the ascending frontal convolutions are compressed. When the tumor involves the *third frontal*, or Broca’s convolution, there is motor aphasia and agraphia, *i.e.*, the patient can neither give utterance to his ideas in words or in writing.

Motor Areas.—A tumor situated here may produce symptoms of paralysis of that part of the body presided over by the motor centres, already mentioned, and is generally associated with Jacksonian epilepsy. It is thought that paralysis unassociated with this form of epilepsy is dependent on a lesion situated deeper in the cerebral tissue, *i.e.*, beneath the cortex, and, therefore, affecting the projection fibres from these centres.

Superior parietal lobule.—A tumor, here, interferes with sensation, while one affecting the inferior parietal lobule, and especially the *angular gyrus*, will cause word blindness, particularly when the left gyrus is affected.

A tumor involving the *occipital lobe*, and especially the mesial surface of it, *i.e.*, the *cuneus*, induces disturbance of vision. The *visual tract* passes from the occipital lobe forwards, as the optic radiation, through the posterior part of the internal capsule, to the pulvinar of the optic thalamus and to the geniculate bodies and the corpora quadrigemina, and thence, beneath the crus cerebri as the optic tract, to decussate with the opposite tract at the optic chiasma. Hence the fibres from the right occipital lobe supply the right half of the retina, and, those from the left, the left half of the retina, so that a tumor affecting the right occipital lobe, or its neighborhood, or pressing on the right visual radiation, will destroy the action of the right halves of the retinae, thus causing blindness on the nasal side of the left retina and on the temporal side of the right, *i.e.*, left lateral homonymous hemianopsia.

Tumors of the *temporal lobe* may produce interference with word hearing, especially if the left be affected, or, if on the under surface, according to Ferrier, disturbance of smell and taste.

Tumors in the fissure of Sylvius and upon the *island of Reil* produce numerous symptoms because of their pressure on contiguous structures; thus, on the hinder end of the third frontal they cause motor aphasia and agraphia; on the operculum, facial paralysis; on the superior and middle temporal, word deafness; on the island of Reil and underlying external capsule, paraphasia, *i.e.*, interference with speech due to destruction of the conduction areas for the different regions associated in speech. Interference with speech, like word deafness and word

blindness, is, as a rule, limited to tumors involving the left hemisphere in right-handed persons (or the right hemisphere in the left-handed), possibly because, that in right-handed persons, the left half of the brain is slightly better differentiated, especially the motor part, as shown by the more common use of the right hand.

The *corpus callosum* is a great commissure connecting identical parts of the two hemispheres together, yet the conclusion of Erb and Ferrier is, that almost the entire corpus callosum may be destroyed without producing disturbance of motion or co-ordination, or of sensation, general or special, and without any disturbance of intelligence. Tumors of the *corpus striatum* produce no symptoms of themselves. Mills considers that both the optic thalamus and the corpus striatum preside over the higher automatic acts such as the gait, emotional control, etc., and hence, if diseased, volitional acts may replace these automatic ones so that no apparent ill effects will result from their involvement. Ferrier states that lesions of a stationary character may be found in the grey matter of the corpus striatum without any manifestation of motor symptoms. Several observers, however, have noted a condition of pseudo-bulbar paralysis as present when the lesion was situated in the lenticular nucleus.

Optic thalamus.—The symptoms of a tumor involving the thalamus are nearly as obscure as in the case of the corpus striatum—vision, however, has been found impaired in some cases, although, more often, not, and hemianæsthesia has been occasionally present (likely due to pressure on the posterior limb of the capsule). It is said that paralysis of mimetic movements of the face and the occurrence of post-hemiplegic choreic disorders are in favor of a lesion implicating the opposite thalamus. One

way, however, in which tumors of either the thalamus or the corpus striatum may cause serious trouble is dependent on their relationship to the internal capsule, hence a tumor of these bodies would have to be strictly limited to them alone, as otherwise it would produce symptoms from pressure on the internal capsule.

A tumor of the corpora quadrigemina causes, as a rule, a staggering gait like that of a drunken person, and interference with certain automatic movements of the eyes, such as in following a light with the eyes, etc., hence, irritation of these bodies may cause nystagmus or involuntary movement of the eye from side to side. There is, therefore, in this lesion more or less ophthalmoplegia, or paralysis of most of the muscles of the eye, chiefly because the oculo-motor nuclei are situated here, *i.e.*, beneath the Sylvian aqueduct. In addition, there is some disturbance of hearing since the central tract for the cochlear nerve ascends through the corpora quadrigemina to the internal capsule.

A tumor of the crus cerebri (Fig. 13) may produce paralysis of the opposite side of the face and body, since the motor fibres for these regions lie in the middle two-fourths of the crura. When the tumor involves the lower part of the crus, there is, in addition, paralysis of the third nerve on the same side as the lesion from direct pressure on this nucleus, which is situated in this portion of the crus.

Pons Variolii.—The cranial tracts from the cortex for the facial nerve decussate about the middle of the pons, whereas the pyramidal tract or motor fibres for the limbs passes downwards to decussate in the medulla, hence a lesion in the pons will produce symptoms that differ in accordance with its situation. Thus, in a tumor of the up-

per part of the pons, *i.e.*, above its middle, there will be paralysis of the face and limbs on the side opposite to the lesion, whereas, one situated in the lower half of the pons will press directly on the nucleus of origin of the seventh nerve and cause paralysis of the face on the same side as the lesion, but paralysis of the limbs on the opposite side. The most characteristic symptom, then, of a tumor of the pons, is paralysis of the limbs and tongue on the opposite side, with paralysis of the sixth or seventh nerve on the same side as the lesion—alternate hemiplegia. A tumor of the superficial portion of the pons may cause disturbance of sensation, since the sensory tract passes up through the pons in the *formatio reticularis*. Should the limbs be paralyzed on the opposite side, with the face and tongue paralyzed on the same side as the lesion, then the growth has passed down towards the lowest part of the pons and has affected the nucleus of the hypo-glossal as well as that of the facial. Sudden onset of alternate hemiplegia is characteristic of pontine hæmorrhage, whereas, slow development of the symptoms indicate a tumor.

Lesions of the *medulla* may injure the glosso-pharyngeal, the pneumogastric, the spinal accessory or the hypo-glossal nuclei, and, when so affected, there result such symptoms as impairment or paralysis of deglutition, phonation and articulation—bulbar paralysis. A feature distinguishing true bulbar paralysis from pseudo-bulbar, the result of the implication of the articulatory centres of the cortex, is the fact that in the former there is associated with the usual symptoms, paralysis of the palate as well.

A tumor of the *cerebellum*, especially the middle lobe, may cause difficulty of maintaining the equilibrium and an unsteady reeling gait, while the early appearance of pressure symptoms of the medulla shows that the tumor

involves the inferior surface of the cerebellum and presses secondarily on the medulla. Pressure on the *internal capsule* causes widespread paralysis, since the cortical fibres are here compressed in their passage between the optic thalamus, caudate nucleus and the lenticular nucleus. A glance at the diagram on page 426 will indicate the fibres that would be affected in a lesion in this situation, and the disturbance that would necessarily follow. A small lesion here will cause more extensive distribution than a much larger one involving the cortex of the brain.

Cerebral Haemorrhage.—The arteries that supply the cerebrum are derived from the internal carotid and the vertebral which form the circle of Willis. The middle cerebral, the larger of the two terminal branches of the internal carotid, gives off a number of *central arteries*. These supply the basal ganglia, *i.e.*, the optic thalamus, the lenticular nucleus, the corpus striatum, and the internal capsule which lies between them. One of these central arteries—the lenticulo-striate—supplies the lenticular nucleus and then passes into the internal capsule. This has been called, by Charcot, the artery of “cerebral hæmorrhage,” and, since it supplies the internal capsule, it follows that, when ruptured, symptoms indicative of pressure on the fibres of the capsule result. The left lenticulo-striate artery is said to be more often involved than the right. This may be due to the fact that the axis of the left carotid artery with reference to the thoracic aorta, is such, that the current of blood from each systole of the heart is driven more directly into the left carotid than into the innominate or left subclavian, so that greater strain is thrown on the left carotid than on the right.

These central arteries are terminal, and, when one is plugged, as by an embolus, there is not sufficient collateral circulation established to repair the area damaged by this local withdrawal of the circulation in the vessel.

The *cortical arteries* supplying the cortex of the brain, ramify in the subarachnoid space and then divide into smaller vessels which lie in the pia mater. Leaving the pia mater, at right angles, these cortical arteries dip into the cerebral tissue. There is a slight amount of anastomosis permitted in these terminal branches of the cortical arteries, and it is along the perivascular lymphatic channels of these vessels that pathogenic germs spread from infected foci, and thereby cause localized abscesses of the brain.

Landmarks for the Brain.—The *lower level of the cerebrum* corresponds to a horizontal line drawn across the forehead, through the glabella, to a point half an inch above and behind the external angular process. From this point draw a curved line to a point, one inch behind and half an inch above the external auditory meatus, and thence to the upper part of the external occipital protuberance. The latter portion of this line represents both the *transverse fissure* and the attachment of the tentorium cerebelli to the skull, while the *longitudinal fissure* corresponds to a line drawn over the vertex from the glabella to the occipital protuberance. *Reid's base line* (Fig. 14) is the line drawn backwards from the lower border of the orbit through the middle of the external meatus. The *fissure of Sylvius*.—Draw a line from a point one and a quarter inches behind the external angular process of the frontal bone, to a point three-quarters of an inch below the most prominent part of the parietal eminence. Three-quarters of an inch behind the beginning of this line, *i.e.*, two inches from the external angular process, draw a line, one inch in length, at right angles to the line for the fissure, this represents the ascending limb. The portion of the line in front of this point for the ascending limb is the main fissure, while that behind it, is the horizontal limb.

Fissure of Rolando.—Draw upwards, two parallel and vertical lines from Reid's base line—one immediately in

front of the auditory meatus and the other along the posterior border of the mastoid process. From the junction of this latter or posterior perpendicular line with the longitudinal fissure, draw a line downwards and forwards to the junction of the anterior perpendicular with the line for the Sylvian fissure. This represents the fissure of Rolando. Another method for locating the fissure of Rolando is to draw a line from a point half an inch behind the centre of the longitudinal fissure, downwards and forwards, for about three and three-eighths inches to terminate about half an inch behind the ascending limb of the fissure of Sylvius. *Parieto-occipital fissure.*—Extend the line for the horizontal limb of the fissure of Sylvius backwards to join the longitudinal fissure. The posterior half or three-quarters of an inch of this line represents the parieto-occipital fissure. This fissure is situated about half an inch in front of the lambda, *i.e.*, about two and a half inches above the external occipital protuberance. The *superior frontal fissure* is indicated by a line drawn backwards from the supra-orbital notch to terminate about three-quarters of an inch from the upper end of the fissure of Rolando, while the *inferior frontal fissure* follows the course of the temporal ridge from the external angular process to within three-quarters of an inch of the fissure of Rolando. The *precentral fissure* lies parallel with and about three-quarters of an inch in front of the lower two-thirds of the fissure of Rolando. The *intraparietal fissure* begins about half an inch behind the junction of the middle and lower thirds of the fissure of Rolando; passes upwards parallel to the latter and then curves backwards, midway between the longitudinal fissure and the parietal eminence, to end about midway between the lambda and this eminence.

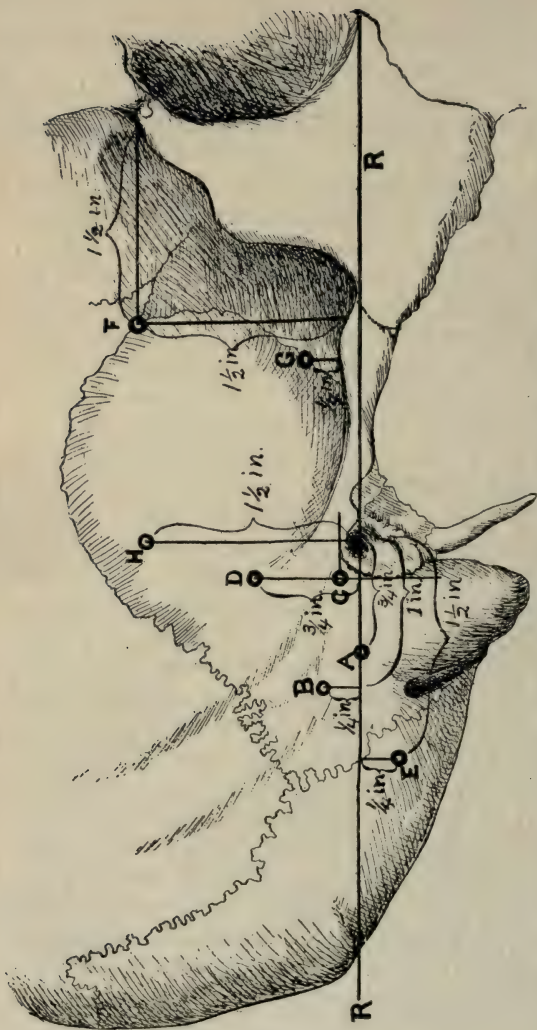
The *superior temporo-sphenoidal fissure* is represented by a line drawn parallel with and one inch below the line

for the Sylvian fissure and terminating about three-quarters of an inch behind and on the same level with the end of the fissure of Sylvius. The *middle temporo-sphenoidal* lies parallel with the latter line and about three-quarters of an inch below it.

Having located the lines for the fissures, the convolutions lying between them can be readily appreciated.

Operations.—*Trephining.*—The skull may be opened by means of the trephine, the saw, or the osteotome, and in turning down the flap for this purpose, it is advisable to bear in mind the general direction, situation and landmarks for the supra-orbital, temporal and the occipital arteries, already referred to, so as to avoid, as far as possible, interference with the circulation in the flap.

Operation on the *sigmoid sinus.*—The incision should extend from the tip of the mastoid process over its prominence to the beginning of the posterior root of the zygoma and the bone should be trephined three-quarters of an inch behind the centre of the external auditory meatus and along Reid's base line. *Lateral sinus.*—One and a quarter inches from the external meatus and about a quarter of an inch above Reid's line. *Temporo-sphenoidal abscess.*—The pin of the trephine should be applied three-quarters of an inch above Reid's line starting from the posterior border of the meatus. For *cerebellar abscess.*—one and a half inches behind the centre of the meatus and a quarter of an inch below the base line. *Middle meningeal artery.*—*Anterior* branch, one and a half inches from the external angular process and the same distance above the zygoma. *Posterior* branch, one and three-quarter inches from the external angular process and one-quarter of an inch above the zygoma. *Tapping the lateral ventricle.*—One and a half inches above the centre of the external meatus. (Fig. 14).



(Fig. 14).—Diagram showing the various Points for Trephining (slightly changed from "Treves' System Surgery").
 R, Reid's base line; A, The sigmoid portion of lateral sinus; B, Transverse portion of the meatus parallel with the base line; C, Mastoid antrum, the point of meeting of two lines—one drawn along the upper margin of the meatus parallel with the base line; the other along the posterior border of the meatus, at right angles to the base line; D, Cerebral abscess; E, Anterior branch, middle meningeal artery; F, Posterior branch, middle meningeal; G, Lateral ventricle.

inches vertically and one and a half inches from side to side. The orbital fat forms a pad for the eyeball and acts as a support for it and for the muscles, nerves and the bloodvessels contained in the cavity of the orbit. The *eyeball* is composed of the cornea, the sclerotic, the choroid and the retina, with the lens, internally, separating the aqueous from the vitreous humor, and having the iris in front of it dividing the space between it and the cornea into two chambers. It, *i.e.*, the eyeball, forms along with the capsule of Tenon, which is a lymphatic space surrounding the posterior two-thirds of the eyeball, a ball and socket joint. The *orbital fascia* receives accessions from the dura mater through the optic canal and the sphenoidal fissure and forms a layer for the bones—the periorbita. This fascia surrounds the individual muscles, nerves and bloodvessels, and, anteriorly, sends a lamina underneath the eyeball as far as the attached margin of the tarsal cartilage of the lower lid, and this layer of fascia, because of its function, is termed the suspensory ligament of the eyeball. From the sheaths formed by the fascia around the muscles, offsets are sent to the margin of the orbit, and these form check ligaments which prevent displacement from muscular action and limit excessive movement of the eyeball. The *nerves* of this region are the third, fourth, ophthalmic division of the fifth, sixth and the optic nerve and their relative position in the different situations is as follows: In the *cavernous sinus*, the third, fourth and the ophthalmic division of the fifth lie along the outer wall of the sinus, which is formed by the dura mater, in the order named, both from above downwards, and from within outwards. Along the inner or bony wall of the sinus, is the carotid artery with the sixth nerve on its outer side; while between them is the venous channel. In the roof of the *sphenoidal fissure*, the rela-

tive position from within outwards, is the fourth, the frontal and the lachrymal; while along the outer wall, from above downwards, are the superior division of the third nerve, next the nasal, then the inferior division of the third, and, lastly, the sixth. The ophthalmic vein lies below, at the angle of junction of the inner and outer walls. *In the orbit*, near its apex, the relative situation of the nerves is, the fourth, the frontal and the lachrymal, and these lie close to the roof of the orbit and in the order named from within outwards; then, the superior division of the third beneath the superior rectus muscle; next, the nasal crossing above the optic nerve; on a lower level, is the inferior division of the third lying below the optic nerve, and, lastly, the sixth nerve, about on the same level as the third and lying near the external rectus muscle.

Effects of Injury to Orbital Nerves.—*Optic nerve.*—In tracing, say, the right optic nerve, backwards from the retina, we find that, as it approaches the chiasma, it divides into two portions; one, the smaller division, continues the course backwards and assists in the formation of the right optic tract, which goes to the right side of the cerebrum; the other portion decussates with a similar division of the left nerve, so that, the right tract contains fibres from the right side of each retina, while the left contains fibres from the left portion of each retina. An injury to the *optic nerve* of one eye will cause loss of vision of that eye; an injury to the *chiasma* or point of decussation, involving the crossed fibres, will cause loss of vision in the nasal halves of the retinae. If the lesion be more extensive and affect the direct or non-decussated fibres as well, then, in addition to the above effects, there will be added loss of vision in the outer half of the eye to which the non-decussated fibres belong. Should the disease be still more extensive and involve all the fibres of

the chiasma then total blindness results. Should the injury be confined to the course of the optic path behind the decussation, then, there will result loss of vision in the temporal half of the retina on the side involved, and, in addition, loss of vision in the nasal half of the other eye.

Third Nerve.—This nerve arises from nuclei in the region of the floor of the aqueduct of Sylvius, and, after passing through the crus, it enters the cavernous sinus on its way to the orbit, where it supplies all the muscles of the eye, with the exception of the superior oblique and the external rectus. It sends filaments to the lenticular ganglion and through the ciliary nerves—branches of this ganglion—it supplies the ciliary muscle, which controls the lens or focussing portion of the eye. It supplies, also, the constricting fibres of the iris. Injury, therefore, to its nucleus, causes (1) ptosis or drooping of the upper eyelid (paralysis of the levator palpebræ). This drooping of the upper lid is not due to contraction of the orbicularis palpebrarum, since, when the lesion is at the nucleus of origin of the third nerve, the orbicularis is also affected. Apparently the facial nerve supplies this muscle, but, in reality, the facial acts merely as a carrier of the fibres, since these fibres arise from the nucleus of the third nerve and pass down in the pons to join the facial at the genu nervi facialis. Further, it will be noticed that the motor oculi supplies not only muscles inside the orbit but also muscles outside of it and protecting it. (2) Divergent strabismus, due to the action of the unopposed sixth nerve; (3) dilatation of the pupil, because of the unopposed action of the dilating fibres of the iris, governed by the sympathetic; (4) loss of accommodation from paralysis of the ciliary muscle, which, therefore, cannot retract the capsule sufficiently so as to alter the convexity of the lens—a necessity in the accommodation for perfect vision. Worms,

dentition, etc., in children may cause by reflex action a form of strabismus—strabismus spasticus—due to a spasm of the muscles, the result of stimulation of this nerve.

The *fourth nerve* arises from the floor of the Sylvian aqueduct near the centre for the third nerve and supplies the superior oblique muscle. This muscle draws the eyeball downwards, and at the same time, rotates it inwards, and hence, when paralyzed, the patient will be unable to move the eyeball in a direction downwards and outwards, so that, when going downstairs, for instance, the axes of the two eyes will not be in the same plane, and diplopia or double vision will result.

Fifth nerve.—When the ophthalmic or sensory division of the fifth nerve is injured, there is loss of sensation in the eyeball itself, since the nasal, a branch of this nerve, supplies the lenticular ganglion with sensory fibres, and branches from this ganglion are distributed to the eyeball. In injury to the ophthalmic, the conjunctiva, with the exception of that portion which covers the lower lid and is supplied by the infraorbital, is insensitive, and, hence, foreign bodies may lodge and remain on the conjunctiva of the eye, without the patient being aware of their presence, until they mechanically cause inflammation and probably ulceration (since the trophic nerves are also affected) of the conjunctiva and cornea. In sensory paralysis, secretion of tears is interfered with, since the lachrymal nerve, a branch of the ophthalmic, would be involved. Sensation is wanting over the forehead (supraorbital and supratrochlear); in the region of the lachrymal sac and side of the nose (infratrochlear); in the mucous membrane of the front part of the nasal fossæ and in the skin over the lower part of the nose itself (nasal branch). Normally, the presence of particles of dirt, etc, on the conjunctiva induce, by reflex action, increased flow of tears

and this flow tends to wash away the offending body, but this action, however, would be interfered with. Another means by which nature attempts to remove an offending body from the conjunctiva is the contraction of the orbicularis palpebrarum, whereby the eyelids, in closing, would mechanically dislodge it, but if there be no warning given on account of the paralysis of the sensory nerves supplying the conjunctiva, there would be no reflex act of winking. The reflex act, in winking, follows a path through the sensory branch of the ophthalmic to the sensory nucleus, thence to the nucleus for the third nerve and from the latter, through the facial, to the orbicularis palpebrarum. Lastly, herpes, also, may develop along the integumentary distribution of this nerve.

Sixth nerve.—Injury to this nerve causes a paralysis of the external rectus muscle and hence there is resultant inability to abduct the eyeball, so that the unopposed internal rectus draws it inwards, *i.e.*, adducts it, producing convergent strabismus and, therefore, double vision. It is interesting to note, in connection with the sixth nerve, that, just as the facial carries fibres belonging to the third nucleus, so the third nerve carries fibres belonging to the sixth nucleus, and these fibres, so carried by the third nerve, are decussatory fibres from the sixth nucleus, which go to the opposite internal rectus muscle. Normally, when a patient is asked to turn his eyes to the right, the right eye is turned by the action of the external rectus and the left eye by the action of the internal rectus, since both these muscles are supplied by the one nucleus, *viz.*, the sixth, and so, in an injury to the right sixth nucleus, the patient could not carry either the right or left eye towards the right, and the same holds good for the left eye.

CHAPTER XLIII.

THE EAR.

THE PINNA.

EXT. AUDITORY MEATUS.

Nerve Reflexes.

Diseases.

THE TYMPANUM.

Otitis Media.

Operations.

The **Pinna** is formed by elastic cartilage, with the exception of its lowest part, which is composed of fibro-areolar and adipose tissue. The integument covering the pinna is so closely attached to the underlying perichondrium that there is very little subcutaneous tissue between them, and the consequence is, that cold may easily affect the circulation in the pinna, as seen in frost-bite, etc. The different fossæ forming the pinna are supposed to concentrate the sound waves on the concha or entrance to the external meatus, but experience has shown that, when the pinna has been removed by operation or accident, the interference with hearing is very slight. The *nerves* supplying the cranial aspect of the pinna are: The auricularis magnus, the posterior auricular, the small occipital, along with Arnold's branch of the pneumogastric, while the auriculo-temporal and the auricularis magnus supply the outer surface. Disease of the upper cervical vertebræ, or irritation of the cervical nerve in the neck from enlarged glands, may cause pain to be felt in the pinna, through the small occipital and the auricularis magnus referring it to their auricular branches.

The **External Auditory Meatus** is about one and a quarter inches long, and consists of a cartilaginous portion about half an inch in length, and an osseous portion about three-quarters of an inch in length. The outer or cartilaginous portion is directed inwards and slightly upwards and backwards, whereas the osseous

portion points forwards and inwards, and consequently, to make the canal sufficiently straight so as to clearly see the membrana tympani, the outer or moveable part must be brought into a straight line with the inner fixed portion and this is done by drawing the pinna upwards and backwards. The angle formed by the junction of these two portions of the external auditory meatus is the narrowest as well as the highest point of the canal. The lining membrane of the meatus is continuous with the skin and is supplied, in its cartilaginous part, with hairs, ceruminous glands and sebaceous glands. The outer end of the canal is oval in shape from above downwards, while the inner end is oval from before backwards, and, since the inner end of the meatus is closed by the membrana tympani and since the latter is directed obliquely downwards, inwards and forwards, it follows that the anterior and the inferior walls of the canal must be longer than the posterior and the superior walls. The nervous supply of the external auditory canal is from the auriculo-temporal and from the pneumogastric through Arnold's branch.

Nerve Reflexes.—Irritation of the branches of either of the divisions of the fifth nerve may induce earache, since the auriculo-temporal, which supplies the auditory canal, is also a branch of the fifth nerve through its inferior maxillary division. This may be seen, clinically, where inflammation of the eye is accompanied by pain in the ear, (ophthalmic), or where caries of the upper teeth (dental branches of the superior maxillary) or of the lower teeth (inferior dental from the inferior maxillary) are associated with earache. When pain in the tongue is referred to the ear it is probably through the lingual branch of the inferior maxillary. Arnold's nerve brings the pneumogastric into connection with the external meatus, so that the introduction of instruments into, or the presence of foreign bodies in the meatus may cause nausea, vomiting, etc.

Diseases.—The dermal or *lining membrane* of the external auditory meatus is closely attached to the underlying structures so that inflammatory action in the canal is attended with considerable pain, as a rule. This is seen, for instance, in furunculosis, when the furuncles or boils are present in the meatus. The anterior wall of the canal is in relation with the parotid gland and with the condyle of the lower jaw—the gland resting against the cartilaginous portion, while the condyle of the jaw is in front of the osseous part. When pus forms in the parotid gland it may burrow into the meatus through two fissures or clefts in the lower portion of the canal—the fissures of Santorini—which are filled with fibrous tissue; or, on the other hand, inflammation of the meatus may spread through these clefts to the parotid gland. Further, since the posterior wall of the canal is separated from the mastoid cells by a thin layer of bone only, inflammation of the wall of this canal may spread to these cells.

The **Tympanum** or middle ear is about half an inch, from above downwards, and the same distance from before backwards, and about one-sixth of an inch in width. The middle ear is separated from the meatus by the *membrana tympani*, which presents a depression about its centre—the *umbo*—caused by the traction of the tip of the handle of the malleus, where it is attached to the membrane. The middle ear is lined with mucous membrane, which is continuous with that of the nasopharynx through the Eustachian tube, and which blends with the mucous covering of the mastoid antrum and cells. The roof of the tympanum separates the middle ear from the cranial cavity, but gives passage to the numerous small veins that empty into the veins of the dura mater from this part of the ear, thereby offering free channels for the passage of septic processes from the tympanum.

num to the brain. In children, under one year of age, there is a suture present in the layer of bone that forms the roof—the petro-squamosal suture. The existence of this suture still further adds to the possibility of cerebral infection developing from disease of the middle ear. The anterior wall of the tympanum has in front of its lower portion, the carotid canal; and in this situation the Eustachian tube opens into the cavity from the pharynx. The opening of this Eustachian tube is about one-sixth of an inch above the floor of the cavity, so that, fluids finding entrance into the tympanum through this tube might remain in it, and induce inflammatory action; and further, the fact of the opening being above the lower level would interfere with proper drainage when pus is present in the middle ear. The floor of the tympanum separates this cavity from the jugular fossa, so that, in fractures of this portion of the tympanic wall, the jugular vein might be wounded, just as in fractures of the anterior wall the carotid artery could be injured. The posterior wall presents the openings that lead into the mastoid antrum and cells. The cavity contains the ossicles, or small bones, which convey the vibrations of the membrane, that have been set up by the sound waves, to the perilymph and endolymph of the internal ear. The chorda tympani nerve passes, from behind forwards, through the tympanum, while the facial nerve is contained in a canal in the upper part of its inner wall. Behind the tympanum is the antrum of the mastoid, which is present at birth, and, in the adult, is about the size of a pea. The antrum is separated by a thin plate of bone from the cranial cavity and communicates with the mastoid cells.

Otitis Media.—Disease of the middle ear may spread to the cerebral sinuses through the venous channels, above mentioned, in the roof of the tympanum, or, in the infant,

through the same channels with, in addition, the petrosquamosal fissure, and thus induce meningitis, or cerebral or cerebellar abscess, or, it may spread, posteriorly, to the mastoid and cause mastoiditis, with, possibly, secondary involvement of the cranial contents through the veins that pass through the roof of that cavity. In mastoiditis, inflammation of the skin and other tissues over the mastoid may develop from the venous communication that exists between the exterior and the cavity. The involvement of these tissues over the mastoid is especially prone to occur in young children, since, in them, the outer wall of the mastoid is exceedingly thin.

The exposed position of the *chorda tympani* renders it liable to injury in otitis media, with the result, that disturbance of taste occurs in the anterior portion of the tongue on the affected side, while caries of the inner wall may cause neuritis of the facial nerve, which runs in a canal in this wall, with resultant facial paralysis.

Possibly otitis media may be reflexly associated with dentition, through irritation proceeding to the tympanic plexus of nerves from the superior and inferior maxillary nerves that supply the teeth. The path, in this case, may be through the superior maxillary to the sphenopalatine ganglion and then through the Vidian nerve, which runs from this ganglion, as a part of the great superficial petrosal nerve, to the tympanic plexus. If the inferior maxillary nerve were involved, then the path might be to the otic ganglion and thence through the small superficial petrosal to the tympanic plexus. In the treatment of otitis media, Politzer's air-bag is used to inflate the middle ear through the Eustachian tube. Normally, this tube is closed except during swallowing, when it is opened by the tensor palati, the levator palati and the salpingo-pharyngeus muscles; hence,

by directing the patient to swallow a mouthful of water, and at the same time forcing air into the nasal passages by means of the air-bag, the orifice of the tube being opened by the act of swallowing, the compressed air enters the middle ear.

Operations.—For *mastoiditis*.—In this, the operation is performed by making an incision about a quarter of an inch behind the insertion of the auricle, extending from the posterior root of the zygoma, above, to the tip of the mastoid, below. The opening through the mastoid process should be made within McEwen's "supra-meatal triangle." This triangle is bounded above by the posterior root of the zygoma, which, together with the upper and the posterior margins of the bony meatus, forms the apex, while an imaginary line joining the ends of these sides forms the base of the triangle. The opening in the bone should be in a direction, forwards and inwards, since, if it were made directly inwards, the sigmoid sinus might be opened. *Paracentesis of the membrana tympani* is best performed through the lower portion of the membrane, since, if it were done above the umbo, there would be danger of injuring the ossicles, or the chorda tympani nerve as it crosses this membrane.

CHAPTER XLIV.

THE NOSE, MOUTH AND PHARYNX.

ANATOMY.

DISEASES.

NERVE REFLEXES.

LANDMARKS.

OPERATIONS.

The **Nose**.—The nose is formed of cartilages united by fibrous tissue and is covered by integument so closely adherent to the underlying structures, that inflammatory affections of the superficial tissues are exceedingly painful. When the integument of this region is inflamed, it may be accompanied by a suffusion of tears through the irritation of the nasal branches of the ophthalmic being conveyed to another branch of the same nerve, viz., the lachrymal, which supplies the lachrymal gland. The skin over the nose, especially in the neighborhood of the tip, has numerous sebaceous glands, so that acne and comedones are not infrequent in this region, while the bloodvessels of the tip are terminal ones, and are liable to be permanently dilated, as in drunkards, etc. The septum of the nose is formed, chiefly, by the nasal spine of the frontal, the septal cartilage, the vertical plate of the ethmoid, and the vomer, and is straight in the majority of children, but, in adult life, it is deflected, more or less, to one or the other side. Within the anterior openings of the nose is the vestibule, and, behind this, are the nasal fossæ, presenting the different *turbinated bones*, viz., the superior, the middle and the inferior. These bones are directed downwards and backwards. The *superior turbinated* extends along the posterior third of the outer wall, and the recess, that lies beneath it—the superior meatus—contains the orifices of the posterior ethmoidal and of the sphenoidal cells. The *middle turbinated* lies along the posterior two-

thirds of the outer wall, and its recess, or middle meatus, has, on its lateral wall, the lower opening of the infundibulum, which connects this meatus with the frontal sinuses, while behind this opening is the orifice of the antrum of Highmore. The *inferior turbinated* bone extends nearly the whole length of the outer wall, and its meatus receives the lower orifice of the nasal duct, which opens about one inch behind the anterior nares and about three-quarters of an inch above the floor of the nose. *Function.*—The olfactory region of the nasal fossæ is limited to the superior and the middle turbinated bones, and to the upper two-thirds of the nasal septum, since it is these portions that contain the branches of the olfactory nerve. The mucous membrane in this situation is thin, whereas, that covering the lower or respiratory portion of the nasal cavities is thick and vascular and is supplied with sensation by branches of the fifth nerves. The veins of the nasal fossæ empty into the cavernous sinus, the pterygoid plexus, the longitudinal sinus and the intracranial veins. The lymphatics are connected with the deep cervical, the parotid and the posterior pharyngeal lymphatic glands.

Diseases.—Inflammation of the mucous membrane of the nose may spread to the adjoining fossæ through the communicating channels, above mentioned. These fossæ are: The frontal sinuses, the ethmoidal and sphenoidal cells and the antrum of Highmore. The frontal sinuses may be occasionally absent, but, when present, they are variable in size, and open into the middle meatus through the infundibulum. When the *frontal sinuses* are inflamed, pain may be felt over the region of the glabella and forehead, since the distention of the sinuses may irritate the pericranial branches of the supra-orbital or supratrochlear nerves from the ophthalmic. Or the pain may be due to compression of the mucous membrane, which is

supplied by the nasal branches of Meckel's ganglion. When the sinuses are distended with pus and the infundibula are not sufficiently patent to provide proper drainage, then it may be necessary to trephine them, and when this operation is indicated, the trephine should be applied just above the inner angle of the orbit, since at this point, the bone, forming the anterior wall of the sinus, is very thin.

When the mucous membrane of the *ethmoidal sinuses* is inflamed and the cells are distended, pain may be felt along the lower frontal region and is then due to irritation of the nasal branches of Meckel's ganglion, which supply the mucous membrane of these sinuses, also. When great distention is present, the pus may make its way along the line of least resistance, *i.e.*, towards the orbit, and cause protrusion of the eyeball. The *antrum of Highmore*, when inflamed, cannot empty itself very readily if fluids be present, since the orifice is situated at the upper and posterior part of the inner wall. To give exit to contained pus it may be necessary to extract a diseased bicuspid or molar tooth that has probably been the cause of the trouble, but, if no such tooth be present, then the drill or trephine should be applied to the wall of the cavity just above the second bicuspid tooth.

Nasal polypi, when present, are found most frequently in the mucous membrane of the superior or middle turbinated bone. Asthma may be dependent, among other reflex causes, on the presence of growths in the nasal fossæ, or in the naso-pharyngeal region, and here, it is possible that the irritation is referred to the pneumogastric nerve through the posterior branches of Meckel's ganglion, which communicate with the pharyngeal branches of this nerve, or, the path may be up through the sensory

branches of the fifth nerve to its centre in the medulla, which communicates with the nucleus of origin of the pneumogastric.

In Fracture of the nasal bones, it is well to remember, that there is a space of about one-sixth of an inch, only, in width at the roof of the nasal fossæ, so that, when using any instrument to replace the fractured bones, it should not be larger than this; in fact, it is desirable to employ even a smaller one, since the swollen mucous membrane would lessen the normal width of this space. Any larger sized instrument would impinge on the nasal process of the superior maxillary bone without coming in contact with the nasal bones at all. The posterior narial orifice, which is about one inch by half an inch in size, may require to be plugged in persistent epistaxis, and, when this operation is necessary, the plug should be a little larger than the dimensions of this orifice. A rough index to the dimensions of the plug required for plugging the posterior nares, is found in the size of the distal phalanx of the thumb.

The **Mouth** —The *lips* are composed, from before backwards, of integument, superficial fascia, orbicularis oris muscle, submucous tissue and mucous membrane. The inferior and the superior coronary arteries, along with the branches of the infraorbital and mental nerves that supply the lips with sensation, are found in the submucous tissue, and, since the lips are richly supplied with blood, wounds of their substance heal rapidly. The lymphatics of the central part of the lower lip converge to a gland above the hyoid bone, while those from the lateral aspects of this lip, along with the lymphatics from the upper lip, go to the submaxillary and the superior deep cervical glands. In hare-lip the defect does not occupy the median line, since the middle portion of the lip, along with

the premaxillary bone, are formed from the fronto-nasal process; whereas, the lateral portion of the lip and the rest of the alveolar process are developed from the maxillary process, and, therefore, in hare-lip, the cleft is generally to the side of the median line.

The Tongue.—The tongue is composed of two halves which are joined together at the septum, and the bulk of it, which is formed by intrinsic muscles, is controlled by the following extrinsic muscles, viz., by the genio-hyo-glossus, the hyo-glossus, the stylo-glossus, the palato-glossus and a part of the superior constrictor of the pharynx. Near the posterior part of the middle line of the dorsum of the tongue is a small pit termed the foramen cæcum, and this depression is the upper extremity of a foetal structure—the thyro-glossal duct—which originally extended from the dorsum of the tongue to the middle portion of the thyroid gland, but which gradually became obliterated. Should, however, this duct not be occluded throughout its whole length, then a dermoid tumor, due to distention of the unobliterated portion might develop. The mucous membrane covering the tongue is continuous with that over the areolar processes and dips in between the tongue and these processes, while, in the middle line, a ridge or duplicature of this membrane is not infrequently present in infants, constituting one form of tongue-tie. On raising the anterior part of the tongue, the ranine vein is seen running towards the tip, and this vein overlies the ranine artery, beneath which is a second or companion vein. These vessels, which are covered by mucous membrane, lie on the lower aspect of the tongue between the genio-hyo-glossus and the inferior lingualis muscles, and are tortuous, so that, when the tongue is protruded, they are not overstretched. The *nerves* of the tongue are as follows: The lingual branch of the inferior

maxillary, which supplies common sensation, and, along with the chorda tympani, the special sense of taste to the fore part and sides of the organ; the glosso-pharyngeal, which is distributed to the base and sides and furnishes this region with the sensation of taste; a few twigs of the superior laryngeal to the root of the tongue near the epiglottis (function doubtful), and, lastly, the hypo-glossal, supplying the muscles of the tongue with motion. Herter considers that the fifth is the special nerve of taste, and that the path for taste reaches this nerve through the chorda tympani and the great superficial petrosal, but, it would seem, rather, that the path is up the chorda tympani to the pars intermedia, which runs on the facial nerve and is derived from the nucleus of the glosso-pharyngeal in the medulla. Uniformity in the nervous supply for the sensation of taste would be marked if this were the case, since the chorda tympani would supply the anterior two-thirds of the tongue, and the glosso-pharyngeal, the posterior third, with the special sense of taste, but, if the chorda tympani be really a portion of the glosso-pharyngeal, then, it follows, that the whole tongue would be supplied with taste by means of the one nerve, viz., the glosso-pharyngeal.

Reflexes.—Ulcer of the tongue often causes pain in the region of the distribution of the other branches of the fifth nerve, viz., in the forehead (subra-orbital); the upper and lower teeth (dental); the side of the head, pinna or external meatus (auriculo-temporal), or in the middle ear (tympanic branch of the glosso-pharyngeal). The lymphatics of the anterior part of the tongue converge to the submaxillary glands, while those of the rest of the organ go, principally, to the deep cervical glands. The tongue is protruded by means of the genio-hyo-glossus and is withdrawn by the hyo-glossus, stylo-glossus, and

by the posterior fibres of the genio-hyo-glossus. These actions are assisted by the muscles steadying the hyoid bone, viz., by the stylo-hyoid, both bellies of the digastric, mylo-hyoid and the genio-hyoid.

Operations.—*Division of the frænum linguæ.*—In this operation the blunt-pointed, curved scissors are directed towards the symphysis, since, if they were directed horizontally towards the tongue, the ranine artery might be wounded.

Division of the lingual branch of the inferior maxillary.—This sensory nerve passes forwards to the side of the tongue, lying below and behind the last molar tooth. It can be divided by making an incision at a point, about half an inch below and behind the tooth, or by incising over the nerve as it lies by the side of the tongue. If the surgeon draw the protruded tongue towards the opposite side, the nerve may be identified, since it causes the mucous membrane to become elevated, ridge-like, opposite the second molar tooth, and, on division of this membrane, the nerve is exposed, when it can be divided or excised if necessary. Its division may be desirable in cancer of the tongue in which the pain is intense. *Excision of the tongue.*—It must be remembered, that in cases of malignant disease of the tongue, in which one side only is involved, this side may be readily removed, and, if there have been preliminary ligation of the lingual artery, hæmorrhage need not be feared, since the anastomosis between the bloodvessels on either side of the septum linguæ is capillary only and very limited at that. Treves is of the opinion that the complete excision is preferable to a partial operation, even though one side, only, is affected, and he advises excision through the mouth, after ligating both linguals. When, however, it is necessary to remove the entire tongue, it will render the prognosis better if the

organ be removed through a curved incision below the jaw, with its convexity touching the hyoid bone, and extending from the angle of the jaw to the symphysis. The object of this external incision is that the submaxillary and the deep cervical glands, which are oftentimes early affected in malignant disease, may be removed at the same time as the tongue.

In *profound anæsthesia*, the relaxation of the tissues permits the tongue to fall backwards and thus depress the epiglottis, thereby obstructing respiration. To relieve this condition the anæsthetist carries the lower jaw forwards by his fingers placed behind the angles of that bone. This procedure puts tension on the genio-hyo-glossus, the genio-hyoid, and the mylo-hyoid, the hypo-glossal membrane, the glosso-epiglottidean folds and the hyo-epiglottidean ligament, thereby drawing forwards the tongue, the epiglottis and the hyoid bone, and opening the superior aperture of the larynx.

Gums.—The gums are formed of dense areolar tissue, covered by mucous membrane. This compact tissue is closely attached to the periosteum of the alveolar processes, and, since the periosteum of the jaw is prolonged into the tooth socket, it follows that inflammatory processes at the root of the tooth may burrow beneath the periosteum of the jaw and form what is known as a gum-boil.

Floor of the Mouth.—Between the tongue and the jaw is a fossa presenting a ridge or elevation on either side of the frænum. This elevation is due to the presence of the underlying sublingual glands, which, touching each other in front near the frænum, extend backwards for about an inch. Opening on the surface of the mucous membrane over these glands are their ducts—the ducts of Rivini—while, on either side of the frænum, is the orifice

of Wharton's duct, the outlet of the submaxillary gland. The ducts of these salivary glands may become obstructed by occlusion of their orifices or by salivary calculi, etc., and when so occluded, there results a tumor which contains a clear gelatinous fluid like the white of an egg. When the tumor is caused by obstruction of the sublingual ducts the swelling is most pronounced in the floor of the mouth and beneath the chin; but, when the submaxillary duct is the one affected, then the swelling appears beneath the jaw at the side of the neck.

The Hard Palate is covered by muco-periosteum, and, when development is arrested, cleft palate results. When operating for this condition, the incision into the muco-periosteum should be made parallel and close to the alveolar process, so as to include the main bloodvessel of the hard palate, *i.e.*, the descending palatine artery, in the flap. When too free hæmorrhage results from a wounded posterior palatine artery, the canal, through which this vessel emerges, may be plugged, if other means fail to check the hæmorrhage. This canal is situated close to and on the inner side of the last molar tooth.

On examining the **fauces**, the anterior pillars, formed by the palato-glossi, are seen passing downwards and forwards to the side of the tongue, while the posterior pillars, passing downwards and backwards, are formed by the palato-pharyngei muscles. In the triangle resulting from the divergence of these elevations, is the tonsil.

The Tonsil is, on an average, about half an inch in diameter and one-third of an inch in thickness. It corresponds to the angle of the jaw externally and is in relation with the ascending pharyngeal and the internal carotid arteries, the former in front of the latter. The tonsil is separated from these vessels by the superior constrictor and the pharyngeal aponeurosis, only, so that they

might be wounded were the knife directed outwards in opening a tonsillar abscess, hence, to avoid this accident, the knife should be directed backwards and inwards. Occasionally, alarming or even fatal hæmorrhage, during excision of a tonsil, may occur from enlarged tonsillar arteries.

The **Soft Palate**.—Hanging down from the hard palate and separating the mouth from the pharynx is the soft palate. This is formed, from before backwards, in the middle line, by the following structures, viz.: (1) Mucous membrane; (2) submucous tissue, with vessels, etc.; (3) palato-glossus; (4) tensor palati; (5) anterior fasciculus of the palato-pharyngeus; (6) levator palati and azygos uvulæ muscles; (7) posterior fasciculus of the palato-pharyngeus; (8) submucous tissue and vessels, nerves, etc., and, lastly, (9) the posterior mucous membrane. The soft palate is about a quarter of an inch in thickness, and, when cleft, the muscles widening the fissure are the tensor and the levator palati, while the superior constrictor closes it during the act of swallowing.

The **Pharynx** is composed of the pharyngeal aponeurosis, lined by mucous membrane, internally, and covered by the constrictor muscles, externally. It extends from the base of the skull, above, to the lower border of the cricoid cartilage, below, and the lower end, *i.e.*, its junction with the œsophagus, corresponds to the lower border of the fifth cervical vertebra. This tube is widest—two inches—opposite the cornua of the hyoid bone, but narrowest—three-quarters of an inch—at its junction with the œsophagus. The upper part of the pharynx is kept patulous by the attachment of the pharyngeal aponeurosis to the basilar portion of the occipital bone; to the apices of the petrous portions of the temporal bones, and to the internal pterygoid plates; while, below, the anterior and

the posterior surfaces are almost touching one another. In addition to the muscles in contact with the lateral aspect of the pharynx, are the following structures, viz.: The parotid gland, the ninth, tenth, eleventh and twelfth cranial nerves, the ascending pharyngeal and internal carotid arteries and the internal jugular vein.

Landmarks.—The anterior arch of the atlas is on the same level as the hard palate; the body of the axis corresponds to the lower edges of the upper teeth, while the lower border of the fifth cervical is opposite the inferior end of the pharynx, and is about six inches distant from the incisor teeth. The Eustachian tube opens into the pharynx on a level with the posterior end of the inferior turbinated bone, *i.e.*, about half an inch above the level of the floor of the nares. In introducing the Eustachian catheter, therefore, it should, after traversing the floor of the nose, be turned, partly outwards, so that the ring on its posterior end shall point to the outer canthus of the eye on the same side as that on which the catheter is being used.

Diseases of the Pharynx.—*Retro-pharyngeal abscess* generally results from an inflamed lymphatic gland, or from caries of the cervical vertebræ, and tends, very rarely, to spontaneous rupture, hence the need of early incision for its evacuation. The pain in retro-pharyngeal abscess is increased by any movements of the head, and, unless evacuated early, there is great danger of spasm of the larynx from reflex action through the pneumogastric, which supplies the larynx as well as the pharynx. There is also danger, in this situation, of the tumor mechanically occluding the windpipe.

Pharyngeal Tonsil.—Near the junction of the posterior wall with the basilar process, and about on a level with the orifices of the Eustachian tubes, is a col-

lection of lymphoid tissue, termed Luschka's tonsil. This tonsil, when hypertrophied, may cause, in time, pronounced symptoms, such as snoring during sleep; mouth breathing; such effects of interference with respiration, as malformation of the chest walls, etc.; mental apathy, etc., and disturbance of hearing from pressure on, or hypertrophy of the mucous membrane of the Eustachian tube. Hence, the need for the early removal of this tissue. The nerves of the pharynx are derived from the pneumogastric (motion); from the glosso-pharyngeal (sensation), and from the sympathetic (trophic and vaso-motor).

CHAPTER XLV.

THE FACE.

MUSCLES AND THEIR ACTIONS.	TRIFACIAL NEURALGIA. OPERATIONS.
LANDMARKS.	FRACTURES AND DISLOCA- TION OF LOWER JAW.
FACIAL PARALYSIS.	

The important muscles of this region are the orbicularis palpebrarum, the orbicularis oris, the temporal, the masseter and the buccinator. In addition to these are the numerous smaller superficial muscles—the risorius, zygomatici, etc.—which are associated with the expression of emotion.

Actions.—The *orbicularis palpebrarum*, by its contraction, protects the eyeball from injury by closing the lids, and, in addition, supports the eyeball in actions associated with a strong respiratory act, such as sneezing, etc. The *orbicularis oris*, surrounding the mouth, brings together the lips, thus opposing the muscles that converge to the mouth. It, therefore, protects the mouth and represses the expression of any emotion. The *temporal*, from the temporal fossa and inserted into the coronoid process of the superior maxilla, closes the jaw; while the *masseter*, from the zygomatic arch, and into the outer surface of the ramus of the jaw bone, has a similar action. The *buccinator*, from the outer surfaces of the alveolar processes of both jaws and from the pterygo-maxillary ligament, into the outer part of the orbicularis oris, draws outwards the corner of the mouth and forces in the cheek, as in blowing on a wind instrument, etc.

The *cheeks* are formed by the integument and superficial fascia, which contains the superficial face mus-

cles, arteries, nerves, etc. This fascia contains a large amount of fatty tissue where it overlies the buccinator muscle—the buccal fat-pad. Beneath this fascia is the bucco-pharyngeal fascia, the buccinator muscle, the buccinator submucous tissue and the mucous membrane.

The *nerves supplying the face* are as follows:—Branches of the fifth or trifacial afford sensation over the whole of the face, with the exception of the region of the ramus and angle of the jaw, which is supplied by the auricularis magnus nerve; the facial, controlling the mobility of the muscles of expression, while the muscles of mastication are supplied by the motor root of the inferior maxillary nerve. The chief bloodvessels of this region are the facial artery and the facial vein.

Landmarks of the face.—The terminal branches of the three sensory divisions of the *fifth nerve* appear on the face in the following situations: The ophthalmic at the supra-orbital foramen; the superior maxillary at the infra-orbital foramen, and the inferior maxillary at the mental foramen. The *supra-orbital foramen* is at the junction of the inner and middle thirds of the supra-orbital ridge; the *infra-orbital* is about two-fifths of an inch below the infra-orbital ridge, while the *mental* is at varying distances from the lower border of the inferior maxillary, depending upon the age of the patient; thus, in infancy, this foramen is situated nearer the lower than the upper border of the jaw; in adult life, it is about midway between the alveolar process and the inferior border; whereas, in old age, it is nearer the alveolar process. These three foramina may be represented by drawing a line, downwards and outwards, from the supra-orbital notch and passing between the two bicuspid teeth. The line will overlie these foramina. The *facial artery* is tortuous, so as to prevent it from being overstretched in

the different degrees of distention of the cheek, and runs, from the junction of the margin of the lower jaw with the anterior border of the masseter muscle, to the inner canthus of the eye. The *facial vein*, less tortuous, is situated close to, but behind the artery, and may be represented by the same line as that for the artery. The *facial nerve* appears on the side of the face at the lower limit of the lobule of the ear. *Stenson's duct* (*parotid*) runs along the side of the face, superficial to the masseter muscle, to penetrate the buccal pad of fat and pierce, at a rather sharp angle, the buccinator muscle, between which and the mucous membrane of the mouth it runs for a short distance to terminate on a papilla opposite the crown of the second upper molar tooth. This duct has the transverse facial artery, above, and the infra-orbital branch of the facial nerve, below, and is situated, about a finger's breadth, below the zygoma, or, to speak more accurately, it corresponds to a line drawn from the lower border of the tragus, to a point opposite the second upper molar tooth, *i.e.*, about midway between the ala of the nose and the red margin of the lip.

Facial Paralysis is said to be *nuclear* when it depends upon injury to the nucleus of origin of the facial nerve beneath the floor of the fourth ventricle; *supra-nuclear* when due to a lesion anywhere in the facial tract above the nucleus, *i.e.*, in the cerebral cortex, the internal capsule, the crus, or in the upper part of the pons, and, lastly, *infra-nuclear* when below the nucleus of origin, *i.e.*, at the base of the brain; in the canal of the petrous bone; at its point of exit from the stylo-mastoid foramen; in its passage through the parotid gland, or at its point of emergence on the side of the face. *Symptoms.*—All voluntary and emotional movements of the face muscles are lost; the eyelids cannot be closed; the lower lid falls

forwards; whistling is impossible or imperfectly performed; the mouth cannot be closed, and in some cases taste is lost on the anterior part of the tongue. *Site of the lesion.*—If *supranuclear*, reflex actions are unchanged, the actions of the eyelids are not interfered with, *i.e.*, the patient can still close the eyelids. The reason that the orbicularis palpebrarum and the anterior part of the occipital-frontalis are not affected, is that, while these muscles are, apparently, supplied by the facial, this nerve, in reality, merely carries fibres, which, derived from the nucleus of the third nerve, join the facial at its knee-like bend in the pons, and, therefore, in a supra-nuclear lesion, this fasciculus is unaffected and the actions of these muscles are not interfered with. Should the lesion be *nuclear*, *i.e.*, in the pons, then there may result crossed paralysis. If at the base of the brain or in the internal auditory meatus, the auditory nerve, which runs in these situations along with the facial, would also be affected, so that deafness would be present along with the paralysis of the face, and there would probably be, in addition, loss of taste for the anterior portion of the tongue, since the nerve for this—the pars intermedia—would likely be affected as it lies between the facial and auditory nerves. Loss of the sense of taste in the anterior two-thirds of the tongue, with paralysis of the face alone, would indicate a lesion of the nerve above the point where the chorda tympani leaves it, *i.e.*, anywhere in the petrous bone above the stylo-mastoid foramen, generally, however, in the Fallopian canal. When the muscles of the face, including the orbicularis palpebrarum and the anterior part of the occipito-frontalis are affected, with no involvement of hearing or taste, the lesion is probably in the trunk of the nerve below its exit from the stylo-mastoid foramen.

Neuralgia of the fifth nerve, or *trifacial neuralgia*, which is a disease of adult life, may be due to a variety of causes, constitutional and local, and may affect one or more of the trunks of this nerve. When the *supra-orbital* is involved, the pain is felt in the distribution of this branch, and tender spots are usually present in the following situations: One, at the exit of the nerve from the supra-orbital foramen; another, occasionally present, in the upper eyelid (palpebral), and a third, on the side of the nose at the junction of the nasal bone with the cartilage (exit of nasal). When the *superior maxillary* is the seat of the pain, a tender spot is generally felt at the infra-orbital foramen, or over the prominence of the cheek (malar). When the *inferior maxillary* is affected, the painful spot is often in front of the ear (auriculo-temporal), or at the mental foramen (exit of inferior dental), or just above the parietal eminence (the auriculo-temporal at its junction with the great occipital).

Operations.—The *facial artery* may be *ligated* through an incision, one inch in length, over the point where it appears on the face, *i.e.*, at the junction of the anterior border of the masseter muscle with the inferior border of the jaw bone.

Nerves.—*Excision* or *stretching* of the facial portions of the trifacial nerve may be performed through incisions over the foramina of exit, above referred to, of the divisions of this nerve. Should it be deemed advisable to remove more of the *superior maxillary* nerve, the floor of the orbit may be chiselled away and the nerve followed backwards, through an incision placed below and parallel with the lower margin of the orbit. If both the superior maxillary and Meckel's ganglion require to be removed, an incision, similar to that in the preceding operation, may be employed, and the nerve, at its exit from the infra-

orbital foramen, identified. The anterior wall of the superior maxillary bone is then trephined, the floor of the orbit is chiselled away, so as to expose the nerve in its canal, and the posterior wall of the antrum having been opened, the ganglion and nerve may be excised. Care should be taken in this operation to avoid the internal maxillary artery that lies just behind the posterior wall of the superior maxillary bone. When the *inferior dental* is the nerve at fault, its termination on the face may be stretched or divided by an incision placed just below the lower border of the jaw, so that the tissues may be raised up, sufficiently, to expose the mental foramen. This incision makes a less conspicuous wound, afterwards, than one over the bone itself. Should the pain still persist, then the nerve may be excised farther back, by means of a trephine opening made through an incision placed below the margin of the lower jaw. The skin is pushed up, the muscles separated from the bone and the trephine applied about one and a quarter inches above the angle, *i.e.*, about opposite the point corresponding to the commencement of the inferior dental foramen on the inner side of the bone, or, the nerve may be exposed through the mouth, by an incision in the mucous membrane opposite the anterior border of the ascending ramus of the jaw; the internal pterygoid muscle is then separated from the bone by the finger, which also feels the bony spine marking the beginning of the dental canal; a sharply curved hook is now employed to draw out the nerve and the latter is excised. Should, however, intense pain still persist in spite of the division of one or more of these branches of the fifth, then the Gasserian ganglion may be removed. *Extirpation of the Gasserian ganglion* is done by means of an Omega-shaped incision, made in the temporal region with the highest part of the curve near the

temporal ridge; the soft tissues are cut through down to the bone, the latter is chiselled along the line of the skin incision; the flap, composed of the bone and soft parts, is laid back, the dura mater and the temporal lobe of the brain raised up, the trunk of the fifth nerve identified and followed back to the apex of the petrous bone on which the ganglion is situated, the dura mater is then incised and the ganglion scraped away, avoiding the cavernous sinus.

Fracture of the *lower jaw*.—In the great majority of instances, the fracture involves the body of the bone, especially in the neighborhood of the mental foramen, since this is the weakest part of the bone. The *deformity* that results is, generally, as follows: The anterior portion is displaced downwards, partly from gravity, and partly from the depressing action of the muscles that connect the lower jaw with the hyoid bone. The posterior fragment is drawn upwards by the action of the temporal, masseter and the internal pterygoid muscles; slightly forwards by the external pterygoid, and outwards by the masseter muscle.

Dislocation of the lower jaw is generally the result of a sudden contraction of the external pterygoid muscle drawing the jaw forwards, when, at the same time, the condyles have already been advanced by widely opening the mouth. This sudden action of the external pterygoid occurs, for instance, in yawning, or in vomiting, etc. When dislocation occurs, the condyles and cartilages are drawn upwards, beneath the zygoma, by the action of the masseter and internal pterygoid muscles, and in its reduction, the thumbs, placed upon the lower molar teeth, press the posterior portion of the jaw, downwards and backwards, so as to disengage the condyles from beneath the zygoma, when the tense elevator muscles will close the teeth with a snap, thus indicating reduction of the dislocation.

Excision of one-half of the lower jaw is performed through an incision starting in the middle line, just below the lip, which is not divided. The incision is continued along and immediately beneath the lower border of the bone, and then upwards, behind the angle, to a point immediately below the lobule of the ear. The integument is pushed up and the muscles separated from the external surface of the bone by means of a periosteal elevator; the buccal mucous membrane is now severed at its junction with the alveolus, the bone is sawn through near the symphysis and the anterior end of the portion to be removed is drawn outwards, the attachment of the mylo-hyoid is then divided, the internal pterygoid is separated by means of an elevator and the inferior dental nerve and artery severed. The jaw is now depressed, thus bringing into view the coronoid process, to which is attached the temporal muscle, and this muscle is cut through with curved scissors. The external pterygoid is next exposed and detached, the articulation is opened and the ligaments divided without any twisting of the bone, since such twisting might bring the internal maxillary artery in contact with the neck of the bone so that it could be wounded. The remaining tissues, *i.e.*, the stylo-maxillary and the pterygo-maxillary ligaments are divided and the jaw removed. The structures in danger of being wounded and which must be avoided during the operation, are: The facial nerve, the internal maxillary artery and temporo-maxillary vein, the auriculo-temporal nerve, the external carotid artery, the gustatory nerve, and the salivary glands.

CHAPTER XLVI.

THE NECK.

CERVICAL FASCIA. TRIANGLES. LANDMARKS.

The Neck.—The following structures are found external to the deep fascia of the neck, viz.: The skin and the superficial fascia, the latter being divisible into two layers—a superficial and a deep—and between which are found the platysma, the external, anterior and the posterior jugular veins, the superficial branches of the cervical plexus of nerves and the inframaxillary branch of the facial nerve.

The Deep Cervical Fascia extends from the ligamentum nuchæ behind and surrounds the trapezius muscle. It then passes across the posterior triangle to the sterno-mastoid muscle, which it embraces, and then, from the anterior border of this muscle, it passes to the median line, to unite with its fellow of the opposite side. At a variable distance above the sternum, this layer divides into two, which are inserted into the anterior and posterior borders of the upper end of the sternum, enclosing fat, one or two lymphatic glands and the anterior jugular veins. Two *transverse portions* are sent off from the under surface of the deep cervical fascia. One, anterior, the *pretracheal fascia*, passes across the neck, from the anterior border of the sterno-mastoid muscle and covers the thyroid gland and the trachea, but lies beneath the sterno-hyoid and the sterno-thyroid muscles. The other, posterior, the *prevertebral fascia*, crosses the neck from the anterior border of the trapezius muscle. This last partition lies behind the carotid artery, jugular vein, pharynx and œsophagus, but in front of the vertebræ and its

muscles, and the subclavian artery. Below, the deep fascia, as already mentioned, is attached to the upper border of the sternum and the clavicle; whereas, the anterior transverse partition, *i.e.*, the pretracheal fascia, follows down in front of the trachea to become continuous with the pericardium, while the posterior partition, or prevertebral fascia, is continued down into the thorax covering the vertebræ and the muscles of the posterior mediastinum, and, where the deep fascia covers the subclavian artery a process of it is prolonged down into the axilla, over the artery. The spaces enclosed between these partitions, communicate with the mediastina in the following manner, *viz.*: The space, bounded in front, by the deep fascia proper, and, behind, by the pretracheal fascia, communicates with the anterior mediastinum. That, between the pretracheal and the prevertebral layers communicates with the middle and posterior mediastina, while the space behind the prevertebral layer communicates with the posterior mediastinum, or properly speaking, lies behind this mediastinum.

Lymphatic Glands.—Some of the *superficial lymphatic glands* of the neck are situated along the course of the external jugular vein, immediately beneath the deep fascia, and receive lymphatic vessels from the neighborhood of the ear and from the occipital region, and hence this chain of glands may be enlarged in inflammatory processes affecting either of these regions. Other superficial glands are situated beneath the ear, or in the submaxillary triangle, and their lymphatics are tributaries of the first set. The *deep lymphatic glands*, which extend along the course of the internal jugular vein, are divided into an upper and a lower set. These deep glands receive lymphatic vessels from the superficial chain and from the glands around the pharynx, and drain, therefore, the re-

gions of the mouth, the interior of the cranium, the pharynx, nose, œsophagus, larynx, etc.

Triangles of the Neck.—The *posterior common triangle* is divided into two triangles, by the posterior belly of the omo-hyoid, viz., into an upper—occipital—and a lower—subclavian. The *anterior common triangle*, separated from the posterior by the sterno-mastoid muscle, is divided, by the anterior belly of the omo-hyoid and the posterior belly of the digastric, into three smaller triangles, viz., the submaxillary, the superior carotid, and the inferior carotid.

The principal contents of the *occipital triangle* which is bounded, in front, by the sterno-mastoid; behind, by the trapezius, and, below, by the posterior belly of the digastric, are: The spinal accessory nerve, the cervical and a portion of the brachial plexuses of nerves, the posterior cervical lymphatic glands, and the transverse cervical artery and vein.

The *subclavian triangle*, bounded, in front, by the sterno-mastoid; above, by the posterior belly of the omo-hyoid, and, below, by the clavicle, contains the supra-scapular and the transverse cervical arteries and veins, the external jugular vein, subclavian artery, subclavian vein and the brachial plexus of nerves.

The *submaxillary*, bounded, above, by the jaw; below, by the posterior belly of the digastric, and in front, by the median line, contains the parotid and the submaxillary glands, the external carotid and its branches, the internal carotid artery and the internal jugular vein, the pneumogastric, glosso-pharyngeal, hypo-glossal and sympathetic nerves and lymphatic glands.

The *superior carotid triangle*, bounded, above, by the posterior belly of the digastric; behind, by the anterior border of the sterno-mastoid, and, below, by the

anterior belly of the omo-hyoid, contains the common carotid, the external carotid with its branches, and the internal carotid arteries, the internal jugular vein, the pneumogastric, hypo-glossal, spinal accessory, superior laryngeal, recurrent laryngeal, descendens hypo-glossi and the sympathetic nerves, the pharynx and a portion of the larynx.

The *inferior carotid triangle*, bounded, in front, by the median line; above, by the anterior belly of the omo-hyoid, and, behind, by the sterno-mastoid, contains the common carotid artery, the internal jugular vein, and the pneumogastric nerve, the descendens and communicans noni, the sympathetic and the recurrent laryngeal nerves, the vertebral artery, the thyroid gland, the larynx and the trachea.

General Landmarks for the neck.—In the *median line*, at the *back* of the neck, immediately beneath the occipital bone, no vertebral spine can be felt, since the atlas has no spine. The first spine that can be recognized by the finger is that belonging to the axis, but, below this, no individual spine can be identified until the finger reaches the seventh, which has the most prominent spinous process of all. In the *median line*, in *front*, is the body of the hyoid bone, which lies a little below the level of the angles of the jaw; about a finger's breadth below this bone is the upper border of the thyroid cartilage, while between them is the thyro-hyoid membrane. In front of the upper part of this membrane and between it and the hyoid bone, there is a small bursa which occasionally becomes inflamed, and, when so inflamed, this bursa causes a transversely-placed swelling to be evident in this situation. Behind the thyro-hyoid membrane is the body of the epiglottis, so that, in cases of cut-throat, if the blade of the instrument inflicting the wound be directed backwards and upwards, im-

mediately below the hyoid bone, it passes between the epiglottis and the base of the tongue, but, if it be directed immediately backwards, the body of the epiglottis itself will be severed. The upper end of the angle of junction of the two halves, or alæ, of the thyroid cartilage, is called the *pomun Adami*. About the centre of this angle of junction is the attachment of the *true vocal cords*, while, one-quarter of an inch above this point, is the attachment of the *epiglottis*. Below the thyroid is the cricoid cartilage, and between them there is stretched a membrane—the crico-thyroid—having the *crico-thyroid artery* running along its anterior surface, near the lower border of the thyroid cartilage. Below the cricoid cartilage is the trachea, with the lateral lobes of the thyroid gland on either side and the isthmus overlying it. The distance from the *cricoid cartilage* to the upper border of the *sternum*, in a child five years of age, is about one and a half inches, but, when the neck is extended, about three-quarters of an inch is gained; whereas, in the adult, the distance from the cricoid to the sternum is about two and a half inches, with a gain of three-quarters of an inch, when the head is extended. There are only seven or eight tracheal cartilages between the cricoid and the sternum, and of these the second and third, and sometimes the fourth, are covered by the isthmus of the thyroid gland. The *cricoid cartilage corresponds* to: (1) The junction of the two bellies of the omo-hyoid; (2) the point where this muscle crosses the common carotid artery; (3) the centre for the incision in ligating the common carotid artery; (4) the junction of the larynx and trachea, and of the pharynx and œsophagus; (5) the narrowest part of the pharynx, and, lastly, (6) the lower border of the fifth cervical vertebra.

Landmarks for the Bloodvessels.—The course of the common, external and internal carotid arteries, when the face is slightly turned to the opposite side, may be represented by a line drawn from the sterno-clavicular articulation, to a point midway between the angle of the jaw and the tip of the mastoid process of the temporal bone. The portion of this line below the level of the upper border of the thyroid cartilage corresponds to the *common carotid artery*; the portion, above this level, agrees with the situation of the *internal carotid*, while the line for the *external carotid* should be drawn slightly in front of that for the internal carotid. *Superior thyroid artery.*—The line for this vessel begins at the line for the external carotid, just below the level of the tip of the greater cornu of the hyoid bone, and passes in a curved direction, with convexity forwards, to the upper part of the thyroid gland. The line for the *lingual* starts from the line for the external carotid, opposite the tip of the greater cornu of the hyoid bone, and, passing above the latter, runs parallel to it for a short distance and then upwards to the junction of the anterior and middle thirds of the lower border of the jaw. *Facial.*—The line for this vessel starts at the line for the external carotid, about one-quarter of an inch above the tip of the greater cornu of the hyoid bone, and runs, in a curved manner, to the junction of the anterior edge of the masseter muscle with the lower border of the jaw. The *occipital* line begins at a point opposite the commencement of the line for the facial and runs to the tip of the mastoid process, and thence to about midway between the occipital protuberance and the posterior border of the mastoid.

The *subclavian* artery may be represented by an arched line, running from the sterno-clavicular articulation to a point, a little to the inner side of the middle of the clavicle,

and with the highest part of its convexity about half an inch above the clavicle. The *suprascapular* and *transverse cervical* arteries run parallel with the clavicle, the former behind this bone and the latter just above it.

Veins.—The *internal jugular* corresponds fairly well with the line for the carotid arteries, although that for the *right* vein is a little external to the line for the right carotid, whereas, that for the *left* somewhat overlies the line for the left carotid. *External jugular.*—A line drawn from the angle of the jaw to the middle of the clavicle. (This vessel pierces the deep fascia at a point a little over an inch above the clavicle.) *Posterior jugular.*—The line for this starts about one inch below and behind the mastoid process and ends in the line for the external jugular on a level with the lower border of the thyroid cartilage. The line for the *anterior jugular* begins at the hyoid bone and runs down the front of the neck to a point half an inch above the sterno-clavicular articulation, thence externally, about the same distance above the clavicle, to end in the line for the external jugular vein.

Nerves.—The *occipitalis minor*; a line drawn from the posterior border of the sterno-mastoid, opposite the hyoid bone, to the posterior border of the mastoid process. *Auricularis magnus.*—A line drawn from the middle of the posterior border of the sterno-mastoid to the lobule of the ear. *Transverse cervical*, from the same point as the above, across the neck, to the upper border of the thyroid cartilage. For the *descending branches* of the cervical plexus, draw a line from a point on the posterior border of the sterno-mastoid, about half an inch below its middle, to the sterno-clavicular articulation, for the sternal branch; to the middle of the clavicle, for the clavicular, and, to the tip of the acromion, for the acromial branch. *Pneumogastric.*—A line corresponding to that for the

carotid arteries represents the course of this nerve. *Hypo-glossal*.—From the upper part of the line for the internal carotid artery, in a curved manner, to the tip of the greater cornu of the hyoid bone, thence, with convexity downwards, to the middle of the lower border of the inferior maxilla. The *spinal accessory* may be represented by a line drawn from the upper end of the carotid line, downwards and backwards, entering the sterno-mastoid muscle, about one inch below the tip of the mastoid process and emerging from the posterior border of this muscle, at its middle, and then, crossing the occipital triangle, to end in the trapezius about three inches above the level of the clavicle. *Phrenic*, from the middle of the sterno-mastoid, opposite the upper border of the thyroid cartilage to the sterno-clavicular articulation.

Operations.—Ligation of Vessels.—(1) *Common Carotid*.—In connection with the ligation of this vessel, it is worth noting, that, about two and a half inches above the clavicle, and in the line of the artery, there is a prominent tubercle, which can be felt on deep pressure. This is termed the *carotid tubercle*, after Chassoignac, who advised compression of the carotid at this point. The common carotid may be ligated, above or below the point where the omo-hyoid muscle crosses the artery, but, on account of the greater depth of the vessel below this point, the upper part of the artery is generally selected for the purpose of ligation. *Operation*.—An incision, three inches in length, is made in the line of the artery with its centre opposite the cricoid cartilage. The skin, superficial fascia and the platysma with branches of the superficial cervical nerves, having been incised, the deep fascia is opened along the anterior border of the sterno-mastoid muscle. This muscle is drawn outwards and the pulsations of the

carotid felt for, and the omo-hyoid; as it crosses the artery, identified. The small artery (sterno-mastoid) and the middle thyroid veins, which cross the vessel are avoided, and so, also, is the descendens noni nerve which lies on its sheath. The latter is opened on its inner side and the aneurism needle introduced from without inwards, taking great care not to injure the pneumogastric nerve or the internal jugular vein. In the operation *below the omo-hyoid* the incision extends from the cricoid cartilage to near the sterno-clavicular articulation; the sterno-mastoid is drawn outwards and the sterno-hyoid and sterno-thyroid muscles, inwards, the inferior thyroid veins are avoided and the sheath opened on its inner side. *Sub-clavian*.—Ligation of the third part, or of that part of the vessel external to the scalenus anticus muscle, alone will be considered. *Operation*.—The external jugular vein pierces the deep fascia, about one inch above the clavicle, and would be in danger of being wounded if the incision were made directly over it, in this region. The skin is, therefore, drawn down on to the clavicle, so that an incision made through it and the superficial fascia and platysma over the clavicle, will avoid this vessel. This incision will extend from the trapezius, behind, to the sterno-mastoid, in front, and its centre will be placed about one inch internal to the middle of the clavicle. The retraction of the skin brings the wound about half an inch above the clavicle, the deep fascia is now divided and the external jugular vein identified and drawn outwards and the edge of the scalenus anticus muscle sought for. This muscle lies behind the sterno-mastoid, and, when found, the finger should follow it down to its tubercle of origin on the first rib. Turning the head repeatedly to the opposite side with one hand, while the finger of the other is in the wound, will often assist in identifying the scalenus

anticus, since this muscle becomes prominent each time the head is turned in this manner. The vessel is sought for, as it lies at the angle of junction of the muscle with the rib, and the needle is introduced from above, downwards, so as to avoid the cord formed by the last cervical and the first dorsal nerves, while the left forefinger, guarding the needle, protects the pleura. *Vertebral.*—An incision three inches long is made from the clavicle, upwards, along the posterior border of the sterno-mastoid muscle, the external jugular vein is avoided, and, with the muscle, is drawn inwards, the transverse process belonging to the sixth cervical vertebra is sought for, and, below it, the operator will find the artery lying between the scalenus anticus and the longus colli muscles. The vertebral vein and the internal jugular will be found lying in front of the vessel and must be avoided. *External carotid.*—This artery is best ligated below the posterior belly of the digastric rather than above it, and may be secured as follows: An incision, reaching from about the angle of the jaw to the middle of the thyroid cartilage, is made, so that its centre will be opposite the tip of the greater cornu of the hyoid bone. The skin, platysma and superficial fascia are divided, the deep fascia is opened, the anterior border of the sterno-mastoid located, and the muscle drawn outwards. The digastric and the hypoglossal nerves should be identified at the upper angle of the wound and the artery exposed opposite the cornu of the hyoid, avoiding, in so doing, the facial and superior thyroid veins which cross the vessel. The artery is ligated between its lingual and superior thyroid branches, by passing the needle from without inwards, carefully avoiding the superior laryngeal nerve, which passes behind the vessel in this situation. *Lingual.*—This artery is best secured at the "Place of Election," *i.e.*, beneath the

hyo-glossus muscle, by a curved incision, with convexity downwards, starting a little below and external to the symphysis of the jaw and ending a little below and to the inner side of where the facial artery crosses the inferior maxilla. The centre of the incision will be opposite the greater cornu of the hyoid bone. After division of the integument, superficial fascia and platysma muscle, the submaxillary gland is identified, the deep fascia overlying it is divided, and the gland elevated and held up by a retractor. The fascia exposed beneath this gland is incised, the mylo-hyoid muscle at the anterior angle of the wound, and the tendon uniting the two bellies of the digastric at the central part of the wound, defined. The hypoglossal nerve is now sought for, where it crosses the hyo-glossus muscle, on which, both it and the digastric rest, and, when found, there is seen a triangle with this nerve as the base and the bellies of the digastric as the sides. Running across this triangle, about midway between apex and base, is the ranine vein, the situation of which corresponds to that of the lingual artery, separated from it, however, by the hyo-glossus muscle. This vein is displaced upwards and the underlying muscle divided, transversely, at the point on which the vein previously rested, when the artery will be exposed, accompanied by two small venæ comites, which will, in all probability, be included in the ligature.

Nerves.—The *facial* has been stretched for the relief of uncontrollable spasms of the muscles of the face, and the incision for this operation starts at the root of the mastoid process and ends near the angle of the jaw. The parotid gland and the anterior edge of the sterno-mastoid muscle are identified. These are separated from each other, the former being drawn forwards, and the latter, backwards, the posterior belly of the digastric is exposed

and the nerve sought for, along the upper margin of this muscle, about opposite to the middle of the mastoid process, and, when found, traction as high as four or five pounds may be employed for the purpose of stretching the nerve. The *spinal accessory* is stretched for the relief of spasmodic torticollis through an incision starting at the tip of the mastoid and extending for about three inches along the anterior border of the sterno-mastoid. On the exposure of this muscle it is drawn forcibly backwards, and the prominent transverse process of the atlas having been identified, the nerve is sought for, as it crosses this process to enter the deep surface of the muscle about one and a half inches below the tip of the mastoid. This nerve may be stretched, as it leaves the posterior border of the sterno-mastoid to cross the posterior triangle, but in this situation, the action of the trapezius alone would be affected, and hence, the operation near the mastoid is preferable. The *brachial plexus* in the neck may be exposed through an incision, which, starting about half an inch above the centre of the clavicle, extends upwards for about three inches. After dividing the integument, fascia and platysma and drawing the external jugular out of the way, the deep fascia is incised, the omo-hyoid drawn downwards, and the plexus exposed with the transversalis colli artery and vein crossing it about its middle. On drawing these aside any particular cord of the plexus may be stretched.

Phlebotomy.—When the *external jugular* is selected, the incision should be made only partly through the vein, *i.e.*, the vessel should not be completely severed, since the flow of blood is freer when the partial incision is employed. Another point in connection with bleeding from this vessel is that the incision should be transverse to the direction of the fibres of the platysma, so that, when

the latter are cut, they will retract and thus give vent to the flow of blood. *Tubercular glands*.—The best incision for the removal of these glands in the upper part of the anterior triangle is a transverse one, which crosses the neck in the crease just over the cornu of the hyoid bone. A similar transverse incision should be employed in the lower part of the posterior triangle, but in the other parts of the neck it should be directed obliquely, *i.e.*, in the direction of the fibres of the sterno-mastoid muscle. While the removal of non-adherent glands is oftentimes a comparatively simple matter, yet the majority of cases in which operative work is undertaken, present glands, which, from inflammatory processes, have become adherent to the adjacent structures, especially the veins, and hence the surgeon, who is not thoroughly conversant with his anatomy, should not undertake this operation, since it is not a case of “cut and tie.” So many structures are grouped within a comparatively limited area in the neck, that important nerves such as the spinal accessory, pneumogastric, phrenic, etc., may be severed, or veins, which in this condition are often enlarged, wounded, with the possibility, among other dangers, of the admission of air into the circulation. *Cervical Abscesses*.—In opening these, Hilton’s method, already referred to when dealing with axillary abscess, should be employed, and the forceps should be inserted in a direction, as far as possible, away from important structures. Souchon advises graduated dilatation by means of canulæ, gradually increasing in size. *Parotid Abscess*.—The opening to relieve this condition should be carefully made, because of the number of important structures in relation to the gland, thus we have: The external carotid, giving off its terminal branches; the trunk, formed by the temporal and internal maxillary veins; the facial nerve; the auriculo-temporal and

the auricularis magnus, while the internal carotid and internal jugular lie close to its under surface. Hence, a careless incision made into this gland might be productive of serious results, but, fortunately, it may be opened by an incision placed in front of the ramus of the jaw, since the gland projects anteriorly, for a variable distance, over the masseter muscle. The opening should not be made within three-quarters of an inch of the zygoma, because of the situation of the artery, duct and nerve which cross the side of the face after leaving the gland.

Tracheotomy.—Although intubation has replaced tracheotomy in many instances, yet occasions arise in which the latter operation may have to be employed, and, of the two operations that may be performed for the purpose of opening the trachea, the “high,” *i.e.*, the one above the isthmus of the thyroid gland, is the better. The following relations of the trachea, below the isthmus, explain the reasons for the selection of the “high” operation; the transverse branches joining the anterior jugular veins are larger, below, than above the isthmus; the muscles are in closer contact, and the presence of the inferior thyroid veins and the thyroidea ima artery add to the dangers of the operation; the great vessels of the neck are nearer one another, and, hence, would be exposed to the danger of being wounded; besides, the left innominate vein often crosses the root of the neck rather than the interior of the thorax, and, lastly, the trachea is more deeply situated and is more mobile in this situation than above. *Operation.*—An incision, about one or one and a half inches in length, is made in the median line and with its upper end about on a level with the upper border of the cricoid cartilage. After dividing the skin, superficial fascia (taking care to avoid the anterior jugular vein while incising the latter) and the deep fascia, the intervals between the two sterno-

hyoid and sterno-thyroid muscles are identified. Separating these muscles with the handle of the scalpel and avoiding any veins that may appear, the trachea, covered with fascia, is reached, the isthmus of the thyroid is displaced downwards, and the trachea, having been steadied by a hook introduced into the cricoid cartilage, is incised with a knife, held with the cutting part towards the patient's chin, and inserted about three rings below the cricoid cartilage so as to cut upwards. The margin of the wound in the trachea is held open with a pair of forceps and the tracheotomy tube introduced. Should the isthmus be in the way, while operating on children, it may be safely divided, as it is very small in these patients.

Laryngotomy may occasionally be performed as a substitute for tracheotomy, but should not be undertaken in children under thirteen, as, in them, the crico-thyroid space, through which the incision is made, is very narrow, since, even in the adult, the height of the space is only about half an inch. An incision is made in the median line over the lower part of the thyroid cartilage, over the crico-thyroid space and the cricoid cartilage; the interval between the muscles is identified and these structures separated, the crico-thyroid space exposed and the membrane divided just above the cricoid cartilage, so as to avoid the crico-thyroid artery that runs across, immediately below the thyroid cartilage.

Diseases of the region of the Neck.—*Burns*.—When a burn is deep enough to affect the platysma, considerable deformity, as a rule, results from its subsequent contraction, because of the extensive surface presented by this muscle and its connection with the muscles of the lower part of the face. *Abscess*.—An abscess, situated outside of the deep fascia, may spread externally, without any special direction being imparted to it, by any arrangement

of the cervical fascia, as would occur if the pus were beneath this fascia. In the latter case, if the abscess be beneath the superficial portion of the deep fascia at the side of the neck, it may, passing beneath the clavicle, burrow into the axilla. Should the collection be beneath the same fascia in the front of the neck, it would, lying between this layer and that covering the depressors of the hyoid bone, be directed into the anterior mediastinum. If it lie beneath the pretracheal layer it would follow this layer downwards, and since the pretracheal is continuous with the fibrous portion of the pericardium, would appear in the middle and posterior mediastina; while, if beneath the posterior or prevertebral layer, it could burrow into the axilla, since a process of this layer surrounds the subclavian artery, or it could gravitate to the posterior mediastinum.

Pressure Effects of Aneurism of the common carotid.—In aneurism involving the arteries of the neck the common carotid is most frequently affected, and, when so, the tumor develops near its bifurcation, as a rule, and any of the following symptoms may be present as the result of pressure by the tumor: (1) On the *internal jugular*—cyanosis of the face, passive congestion of the brain and headache; (2) on the *pneumogastric*—disturbance of the stomach, such as vomiting, etc., or of the lungs, asthmatic attacks; or of the heart, interference with the rhythm, or change of blood pressure. Should the tumor extend higher up the neck than the point of bifurcation, it may compress the *superior laryngeal* branch, with production of cough or spasm or of paralysis of the crico-thyroid muscle; or, if it involve the lower or middle portions of the artery, the *recurrent laryngeal* might be compressed, producing hoarseness and difficulty in speaking; (3) pressure on the *decendens noni* will cause weak-

ness of action of the sterno-hyoid, sterno-thyroid and the omo-hyoid muscles; (4) on the *sympathetic*—symptoms of irritation or of paralysis, such as, in the former condition, *i.e.*, in irritation, there might be dilatation of the pupil, profuse sweating of one side of the face, pallor, disturbance of vision (because of the inability to accommodate for near objects, since the pupil cannot be contracted); whereas, in paralysis of this nerve, there will be active congestion on one side of the face, contraction of the pupil (unopposed third nerve action), sinking of the eyeball (Müller's muscle); (5) on the larynx or trachea there might be interference with respiration, or, on the œsophagus, with swallowing.

CHAPTER XLVII.

THE SPINE.

ANATOMY.

LANDMARKS.

LEVELS OF CENTRES IN SPINAL CORD.

FRACTURES AND DIS- LOCATIONS.

OPERATIONS.

The spine is composed of thirty-three superimposed bones arranged as follows, viz.: Seven cervical, twelve dorsal, five lumbar, five ankylosed to form the sacral, and four, to form the coccyx. Each vertebra consists of a body, two pedicles and two laminæ, which, meeting behind, complete the neural arch and form, posteriorly, the spinous process, while, transverse and articular processes complete the structure of the vertebra. The spinous processes occupy the middle line, posteriorly, whereas, on either side, are the transverse processes. Between these two prominences there is a hollow in the skeleton, which, however, in the body, is filled with the dorsal muscles. The tips of the spinous processes correspond to the lower portions of the bodies of the vertebræ in the following manner, viz.: Each of the cervical, of the three upper and three lower dorsal and of all the lumbar spinous processes is about on the same level as the lower border of the vertebra to which the spinous process belongs; whereas, the dorsal spines, from the third to the ninth, correspond to the lower part of the vertebra, next below the one to which the spine belongs. Within the spinal canal is the *spinal cord* with its membranes, viz., the dura mater, the arachnoid and the pia mater; while, leaving its substance, are the roots of the spinal nerves proceeding to the intervertebral foramina.

Direction of the Spinal Nerve Roots.—The roots of the first cervical ascend slightly to reach the interval between the atlas and the occipital bone. The roots of the second and third nerves pass horizontally outwards; that of the fourth passes obliquely downwards and outwards, while the remaining roots proceed, with increased degrees of obliquity, to their respective foramina.

Landmarks.—The spine measures, from the atlas to the tip of the coccyx, on an average, about twenty-eight inches, of which, the cervical portion is five inches; the dorsal, eleven inches; the lumbar, seven inches, and the sacrum and coccyx, five inches. Viewed in profile, the spinal column presents *four curves*, a cervical, convex anteriorly; a thoracic, concave; a lumbar, convex, and a pelvic, concave. The *spinal cord*, which may be regarded as consisting of thirty-one segments, placed, one on top of the other, like a pile of checkers, measures only seventeen or eighteen inches in length, so that, the spinal canal is nine or ten inches longer than the spinal cord. The spinal cord extends from the foramen magnum to about the lower part of the body of the first lumbar vertebra, the remaining space of the canal being occupied by nerves (the cauda equina), and by the filum terminale, *i.e.*, the prolongation downwards of the pia mater, which contains a very slight amount of nervous tissue. The *cervical enlargement* of the cord, caused by the large size of the nerves given off to supply the arms, extends from the third cervical vertebra to the second dorsal, and is at its maximum at the level of the sixth cervical vertebra; whereas, the lumbar enlargement commences at the level of the ninth dorsal and reaches its maximum at the level of the twelfth dorsal, from which point it diminishes gradually. Each segment of the spinal cord is connected with a pair of nerves, and not only acts as a conductor for the

different neurones, but also contains centres, such as a trophic, a reflex and a vasomotor centre, situated in the H-shaped central grey matter.


Levels of Centres in Spinal Cord.—Peterson states that each separate segment of the cord has its own particular functions, as, for instance, the *reflex centres* for the bladder and rectum are situated in the fourth and fifth sacral segments; that for the ankle clonus, in the fifth lumbar segment; the centre for the knee jerk, in the third lumbar, and those for the wrist and elbow jerks in the sixth cervical, etc. *Motor and trophic functions* are distributed in the same manner, *i.e.*, segmentally, so that, the intrinsic muscles of the foot are represented in the first and second sacral segments; the knee flexors, in the fourth and fifth lumbar segments; the thigh muscles, in the second and third lumbar; the abdominal and spinal muscles, from the second to the twelfth dorsal; the thumb and finger muscles, in the eighth cervical and first dorsal; the forearm muscles, in the sixth and seventh cervical; the shoulder muscles, in the fourth and fifth, and the neck muscles in the second and third cervical segments. The *sensory distribution* is also segmental, thus anæsthesia of the perineum, scrotum, rectum, vagina, and the posterior surface of the penis, is produced by a lesion situated in the fourth and fifth sacral segments. If the lesion be higher up the cord, say at the third sacral segment, the anæsthesia extends farther out on the buttock and downwards over the back of the thigh. If higher still, as at the fifth lumbar segment, the anæsthesia includes, in addition to the preceding areas, the outer sides of both legs. The lower part of the abdomen corresponds to the first lumbar segment; the umbilical region to the tenth dorsal segment, etc., and when the eighth cervical is affected, the anæsthesia is complete, below a girdle about the nipples,

and on the inner sides of the hands, forearms and arms. In a lesion at the level of the seventh cervical, the anæsthesia affects, in addition, the radial sides of the hands, forearms and arms. At the fifth and sixth cervical, the anæsthesia extends to the back of the shoulder and arms in addition to the above. If at the second, third and fourth cervical, the entire surface of the neck and upper part of the shoulder will be affected.

Fractures and Dislocations.—Dislocation of the atlas or axis is, as a rule, rapidly fatal, owing to compression of the cord between the posterior arch of the atlas and the odontoid process of the axis. The dislocation may be produced by a twisting of the neck, whereby the check ligament, first, and then the transverse and other ligaments are ruptured and the atlas displaced forwards on the axis. In children, traction of the head, combined with rotation, is dangerous, since, in young people, the odontoid process is incompletely developed, and, hence, might slip beneath the transverse ligament and permit dislocation. When the cord is crushed at the first or second cervical vertebra, death is usually instantaneous; when at the third, fourth or fifth, death soon occurs from injury to the phrenic, but when below the fifth, breathing may still be carried on by the action of this nerve.

Operations.—*Spinal Drainage.*—For drainage purposes, in cases of increased intra-cranial pressure, the spinal membranes may be punctured, as done by Quincke (1893), who inserted the needle between the third and fourth lumbar vertebræ, and, therefore, below the spinal cord. The depth of the puncture necessary to reach the membrane in infants is about four-fifths of an inch, whereas, in adults, it is about two inches. *Spinal cocainization* was proposed and employed by Corning, of New York, but was popularized by Tuffer at the Thirteenth In-

ternational Medical Congress, held at Paris, 1900. Cocaine in solution, absolutely sterile, is employed to the extent of one-quarter or three-eighths of a grain, and is injected, with all antiseptic precautions, between the third and fourth lumbar vertebræ. The analgesia, resulting, permits operative work below the diaphragm, such as, the removal of the kidney, the radical cure of hernia, operations on the extremities, etc., without the patient experiencing pain to any extent, while labor, also, is said to be almost painless, but at present, the unpleasant and, oftentimes, alarming symptoms, such as vertigo, pallor, nausea, vomiting, etc., as well as some few deaths, that have been reported, prevent it from being ranked as an ideal anæsthetic.



INDEX.

A.	
Abdominal aorta.....	261
Landmarks for.....	262
Abdominal regions.....	265
Abdominal walls.....	170
Landmarks for.....	178
Acromio-clavicular articu- lation.....	13
Aneurism.....	13
Abdominal aorta.....	262
Carotid.....	486
Popliteal.....	349
Thoracic aorta.....	156
Ankle joint.....	380
Anatomy of.....	380
Operations on.....	382
Synovitis of.....	381
Anterior aspect of leg... 365	365
Anterior crural nerve, Landmarks.....	332
Anterior tibial artery, Landmarks.....	367
Ligation of.....	368
Appendix, anatomy of... 223	223
Landmarks.....	228
Appendicitis.....	231
Operation for.....	235
Arches of foot.....	390
Arm, anatomy of.....	50
Landmarks.....	52
Operations on.....	55
Ascending colon.....	225
Anatomy of.....	225
Landmarks for.....	228
Axilla, anatomy of.....	33
Axillary artery operations on.....	45
Axillary fasciæ.....	37
Axillary region, land- marks.....	41
Operations on.....	43
B.	
Bladder, anatomy of.....	270
Landmarks for.....	273
Operations on.....	273
Brachial artery, land- marks.....	52
Ligation of.....	56

Brain, fissures of.....	419
Landmarks.....	435
Meninges.....	413
Bursitis, region of ankle.. 381	381
Region of elbow.....	65
Region of hip.....	316
Region of knee.....	355
Region of popliteal space 348	348
Region of shoulder.....	26

C.

Cæcum, landmarks for.... 227	227
Cardiac neuroses.....	142
Castration.....	299
Cerebrum.....	419
Cerebral fibres, arrange- ment of.....	424
Hæmorrhage.....	434
Localization.....	421
Sinuses, diseases of.... 415	415
Landmarks for.....	417
Cervical fascia.....	471
Clavicle anatomy.....	11
Fractures.....	15
Landmarks.....	11
Clinical examination of	139
Heart and lungs.....	139
Kidney.....	246
Liver.....	203
Spleen.....	252
Club foot.....	392
Colon ascending.....	225
Landmarks.....	228
Colon descending.....	225
Landmarks.....	228
Carotid, aneurism of.... 486	486

D.

Deltoid, muscle.....	31
Diploic, veins.....	404
Dislocation at acromio- clavicular joint.....	15
Elbow.....	70
Hip.....	321
Knee.....	360
Radius downwards.... 70	70
Shoulder.....	27
Sterno-clavicular.....	15
Wrist.....	105

Dorsalis pedis artery.....	385
Duodenum.....	219
Landmarks.....	227

E.

Ear.....	445
Reflexes of.....	446
Elbow joint.....	66
Landmarks for.....	67
Emissary veins.....	404
Extravasation of urine....	291

F.

Face.....	463
Landmarks for.....	464
Operations on.....	467
Facial paralysis.....	465
Fallopian tubes.....	277
Femoral artery, land- marks.....	332
Femoral hernia.....	304
Femur fracture of.....	333
Fibula fracture of.....	375
Fingers.....	89
Landmarks.....	95
Fistula in ano.....	297
Fissures of brain.....	419
Foot, dorsal surface.....	384
Plantar surface.....	386
Bony landmarks.....	388
Forearm.....	73
Landmarks.....	78
Fourth dorsal vertebra....	153
Fractures of clavicle.....	15
Elbow joint.....	68
Femur.....	333
Fibula.....	375
Humerus.....	57
Patella.....	359
Radius.....	82
Scapula.....	19
Skull vertex.....	406
base.....	409
Tibia.....	375
Ulna.....	87

G.

Gall bladder.....	199
Landmarks for.....	200
Operations on.....	204

Gastric ulcer.....	211
Gluteal artery ligation....	341
Landmarks for.....	312
Gluteal region.....	308
Landmarks for.....	311

H.

Hand.....	89
Landmarks for.....	95
Operations on.....	103
Head.....	397
Heart.....	135
Clinical examination of.	139
Landmarks for.....	136
Hernia, femoral.....	304
Operation on.....	307
Hernia, inguinal.....	187
Operations on.....	189
Hip joint.....	314
Diseases of.....	316
Dislocation.....	321
Amputation at.....	338
Humerus fracture.....	57
Hydrocele operation for..	299

I.

Inguinal region.....	182
Hernia.....	187
Internal capsule.....	425
Intestine, small.....	219
Intestine, large.....	222
Landmarks.....	227
Ischio-rectal abscess.....	296

J.

Jaw, lower, fracture of...	469
Dislocation.....	469

K.

Kidney.....	239
Landmarks.....	243
Knee joint.....	352
Amputation.....	363
Bursæ.....	355
Dislocation..	356
Excision.....	361
Landmarks.....	354

L.

- Landmarks for
- Abdominal aorta..... 262
 - Abdominal walls..... 178
 - Anterior crural nerve... 332
 - Anterior tibial artery... 367
 - Appendix 228
 - Arm..... 52
 - Arteries of mediastinum 148
 - Ascending colon..... 228
 - Axillary region..... 41
 - Bladder..... 273
 - Bloodvessels of scalp... 400
 - Bony prominences of foot..... 388
 - Cæcum..... 227
 - Clavicle..... 12
 - Colon..... 228
 - Diaphragm..... 166
 - Dorsalis pedis artery... 385
 - Duodenum 227
 - Elbow joint..... 67
 - External plantar artery. 388
 - Femoral artery and vein 332
 - Fingers.... 95
 - Forearm..... 78
 - Fourth dorsal vertebra.. 153
 - Gall bladder..... 200
 - Gluteal artery..... 312
 - Gluteal region..... 311
 - Great sciatic nerve..... 313
 - Hand..... 95
 - Heart..... 136
 - Kidneys..... 243
 - Knee joint..... 354
 - Liver..... 196
 - Long saphenous vein... 368
 - Lungs..... 127
 - Mediastinum..... 148
 - Middle meningeal artery 416
 - Nerves of scalp..... 399
 - Ovary..... 281
 - Pancreas..... 259
 - Perineum 289
 - Pleura..... 130
 - Popliteal artery..... 347
 - Popliteal nerve..... 347
 - Posterior inf. iliac spine 311
 - Posterior super. iliac spine 311
 - Posterior tibial artery.. 373
 - Roots of lungs..... 130
 - Scarpa's triangle..... 307
 - Sigmoid flexure..... 278
 - Shoulder region..... 25
 - Saphenous opening.... 302
 - Spleen..... 251
 - Stomach..... 209
 - Suprarenal capsules... 257
 - Thigh..... 333
 - Thoracic walls..... 117
 - Transverse colon..... 228
 - Ureter 245
 - Veins of mediastinum.. 150
 - Wrist..... 95
 - Leg amputation..... 377
 - Anterior aspect..... 365
 - Fractures..... 375
 - Landmarks for..... 373
 - Posterior aspect..... 369
 - Ligation of
 - Abdominal aorta..... 264
 - Anterior tibial..... 368
 - Axillary..... 45
 - Brachial..... 56
 - Femoral... 339
 - Gluteal 341
 - Occipital 401
 - Palmar arch..... 104
 - Popliteal..... 351
 - Posterior tibial..... 374
 - Radial..... 81
 - Superficial temporal... 401
 - Supra-orbital 401
 - Linea alba..... 175
 - Lithotomy, lateral..... 297
 - Suprapubic..... 273
 - Liver..... 193
 - Clinical examination... 203
 - Diseases 200
 - Landmarks for..... 196
 - Operations 204
 - Lung..... 126
 - Landmarks for..... 127
- M.**
- Mammary gland..... 114
 - Operations 120
 - Mediastinum..... 145
 - Landmarks for..... 148
 - Mesentery..... 221

- Middle meningeal artery.. 411
 Landmarks 416
 Meninges of brain..... 413
 Morbus coxæ..... 316
 Mouth..... 454
 Movable bodies in knee
 joint..... 358
 Movements permitted at
 Acromio-clavicular joint 13
 Ankle " 380
 Elbow " 67
 Knee " 352
 Sterno-clavicular " 13
 Wrist " 99
 Muscles, action of
 Anterior abdominal... 171
 Anterior aspect of leg.. 365
 Arm..... 51
 Axillary region..... 33
 Diaphragm..... 166
 Fibular 375
 Foot..... 386
 Forearm..... 73
 Gluteal region..... 308
 Hand..... 98
 Occipito-frontalis... 398
 Posterior abdominal... 177
 Shoulder region..... 22
 Thigh 326
 Thoracic walls..... 116
 N.
 Neck..... 471
 Diseases 485
 Landmarks 474
 Operations on..... 478
 Triangles of..... 473
 Nerve reflexes of.....
 Abdominal parietes... 173
 Intestine..... 228
 Kidney..... 245
 Mammary gland..... 115
 Perineum..... 293
 Spleen 253
 Ureter..... 245
 Nerves of scalp..... 399
 Nose..... 451
 Diseases of..... 452
 O.
 Occipital artery, landmarks 400
 Ligation of..... 401
 Oesophagus 151
 Operations on..... 163
 Orbit..... 439
 Injury to nerves of.... 441
 Otitis media..... 448
 P.
 Pancreas..... 258
 Landmark 259
 Paralyses.....
 Erb's..... 108
 Klumpke's 108
 Lower arm type..... 108
 Individual nerves..... 109
 Patella, fracture of..... 359
 Operations on..... 361
 Pelvic fasciæ..... 287
 Suppuration..... 280
 Penis 287
 Pericarditis..... 133
 Operation on..... 133
 Perineum 285
 Landmarks for..... 289
 Pharynx..... 460
 Landmarks for..... 461
 Pleura 122
 Landmarks for..... 130
 Pneumogastric nerve... 154
 Popliteal space..... 344
 Artery, landmarks..... 347
 Ligation of..... 351
 Nerves 347
 Bursæ..... 348
 Posterior inf. iliac spine.. 311
 Posterior sup. iliac spine.. 311
 Posterior tibial artery...
 Landmarks..... 373
 Ligation of..... 374
 R.
 Radical cure hernia..... 190
 Radius, fracture of..... 82
 Rectum..... 282
 Examination of..... 292
 Nerve reflexes..... 293
 Operations on..... 284
 Regions of abdomen..... 265
 Regions of chest..... 112
 Removal of gluteus max-
 imus..... 310

Roots of lungs.....	126
Landmarks.....	130

S.

Saphenous opening.....	302
Scalp.....	397
Landmarks for.....	399
Diseases of.....	401
Scapula, fracture of.....	19
Scarpa's triangle.....	303
Scrotum.....	288
Shoulder region.....	25
Sigmoid flexure.....	282
Sinuses cerebral.....	415
Skull, veins of.....	404
Fractures of.....	405
Spine.....	488
Fractures and dislocations.....	491
Landmarks.....	489
Operations on.....	491
Spinal cord.....	
Levels of centres in.....	490
Spleen.....	250
Landmarks for.....	257
Stomach.....	207
Landmarks for.....	209
Ulcer of.....	211
Structures felt per vaginam.....	281
Subphrenic abscess.....	168
Superficial temporal.....	
Ligation of.....	401
Supra-orbital artery.....	
Ligation of.....	401
Suprarenal capsule.....	257
Synovitis, ankle joint.....	381
Hip joint.....	316
Knee joint.....	356
Shoulder joint.....	25
Sterno-clavicular.....	14

T

Taxis.....	189
Testicle.....	289

Tenotomy, hamstrings....	350
Region of ankle joint...	383
Thigh.....	326
Operations on.....	342
Thoracic aorta, aneurism..	156
Thoracic duct.....	153
Thoracic walls.....	113
Action of muscles.....	116
Landmarks for.....	117
Operations on.....	120
Tibia fracture of.....	375
Tongue.....	455
Reflexes of.....	456
Tonsil.....	459
Tracheal tugging.....	161
Triangles of neck.....	473
Tuberculosis of hip joint..	316
Knee joint.....	357
Wrist joint.....	102
Tumors of brain.....	427

U


Ulna fracture of.....	87
Ulnar artery, landmarks..	79
Ligation of.....	80
Umbilicus.....	175
Ureter.....	242
Landmarks for.....	245
Operations on.....	249
Urethra.....	288
Nerve reflexes.....	296
Urine, extravasation of..	291
Uterus.....	274
Operations on.....	280


V

Vagina.....	277
Veins of mediastinum....	150

W

Wrist joint.....	89
Dislocation.....	105
Landmarks for.....	95
Operations on.....	104
Anatomy of.....	50





Med
Anat

83844

Murdell

Anatomy applied to Med. & Surgery

Author

Title

UNIVERSITY OF TORONTO
LIBRARY

Do not
remove
the card
from this
Pocket.

Acme Library Card Pocket
Under Pat. "Ref. Index File."
Made by LIBRARY BUREAU

