

COLUMBIA LIBRARIES OFFSITE  
HEALTH SCIENCES STANDARD



HX64071022

RK522 lv9 1917 Applied anatomy and

**RECAP**

R.K 522 I v9

1917

Copy 1

Columbia University  
in the City of New York


College of Physicians and Surgeons



Reference Library







Digitized by the Internet Archive  
in 2010 with funding from  
Open Knowledge Commons



# APPLIED ANATOMY AND ORAL SURGERY

*FOR DENTAL STUDENTS*

BY

ROBERT H. IVY, M.D., D.D.S.

ASSOCIATE SURGEON, COLUMBIA HOSPITAL, MILWAUKEE; FORMER ASSISTANT SURGEON, OUT-PATIENT DEPARTMENT, UNIVERSITY HOSPITAL, PHILADELPHIA; FORMER INSTRUCTOR IN ORAL SURGERY, UNIVERSITY OF PENNSYLVANIA

*SECOND EDITION  
THOROUGHLY REVISED*

PHILADELPHIA AND LONDON

W. B. SAUNDERS COMPANY

1917

Copyright, 1911, by W. B. Saunders Company. Reprinted September,  
1914, and January, 1916. Revised, reprinted, and  
recopyrighted July, 1917

---

Copyright, 1917, by W. B. Saunders Company

---

RK 522  
IVS  
1917  
Copy 1

---

PRINTED IN AMERICA

---

PRESS OF  
W. B. SAUNDERS COMPANY  
PHILADELPHIA



## PREFACE TO THE SECOND EDITION

---

IN presenting a second edition the writer has not attempted to enlarge the scope of the work, but has confined himself to making such essential changes and slight additions as would bring the matter of the first edition up to date. The criticisms that applied to the first edition still hold good, therefore, to some extent in regard to the second, which it is hoped, nevertheless, will fulfil the object intended, as set forth in the former Preface.

ROBERT H. IVY.

MILWAUKEE, WIS.,  
FIRST NATIONAL BANK BUILDING

*July, 1917.*



## PREFACE

---

THIS book is an attempt to collect in one place and in a few words the special anatomy and surgery required by the dental student. It is not intended to replace larger works on anatomy and general and oral surgery, but rather to indicate to the student the subjects that require his particular attention. The thanks of the writer are due to Professor M. H. Cryer for valuable aid and suggestions, and also for the use of several illustrations. My thanks are also due Dr. William Francis Campbell, of Brooklyn, N. Y., for kind permission to use ten illustrations from his "Surgical Anatomy," and to Dr. Daniel N. Eisen-drath, of Chicago, Ill., for kind permission to use four illustrations from his "Surgical Diagnosis."

ROBERT H. IVY.



# CONTENTS

## PART I. ANATOMY OF THE FACE, JAWS, AND ANTERIOR PORTION OF THE NECK

	PAGE
CHAPTER I.—BONES.....	17
General Development of the Skull.....	17
Bones of the Skull.....	18
The Sphenoid Bone.....	18
The Ethmoid Bone.....	19
The Maxilla.....	20
The Mandible.....	22
The Hyoid Bone.....	26
The Skull as a Whole: Anterior View. Lateral View.	
Base.....	28
Base of the Skull.....	29
The Orbit.....	32
Bony Roof of the Mouth.....	33
The Nasal Fossæ.....	34
The Maxillary Sinus.....	39
The Frontal Sinuses.....	42
The Sphenoid Sinuses.....	43
The Ethmoid Air-cells.....	43
CHAPTER II.—THE TEMPOROMANDIBULAR ARTICULATION.....	45
CHAPTER III.—MUSCLES AND FASCIÆ.....	47
Cervical Fascia.....	47
Surgical Square and Triangles of the Neck.....	48
Muscles of the Tongue.....	51
Muscles of the Pharynx and Soft Palate.....	53
Muscles of Mastication.....	55
Muscles of Expression About the Mouth.....	59
Muscles Attached to the Mandible.....	61

	PAGE
CHAPTER IV.—BLOOD-VESSELS.....	63
The Internal Carotid Artery.....	63
The External Carotid Artery.....	67
The Vertebral Arteries.....	68
Veins of the Head.....	69
The Internal Jugular Vein.....	70
CHAPTER V.—LYMPHATICS OF THE FACE AND NECK.....	72
CHAPTER VI.—THE CRANIAL NERVES.....	74
Fifth Nerve.....	75
Seventh Nerve.....	83
CHAPTER VII.—GLANDS.....	88
Parotid.....	88
Submaxillary.....	90
Sublingual.....	91
Labial.....	91
Buccal.....	91
Lingual.....	91
Palatal.....	91
CHAPTER VIII.—THE TONSILS AND THE MOUTH.....	92
The Tonsils.....	92
The Mouth.....	94

---

## PART II. SURGERY

### GENERAL CONSIDERATIONS

CHAPTER IX.—ABNORMAL CONDITIONS OF THE CIRCULATION AND COMPOSITION OF THE BLOOD.....	97
Hyperemia.....	97
Anemia.....	97
Leukocytosis.....	98
Leukemia.....	98
CHAPTER X.—INFLAMMATION.....	99
Ulceration.....	104
Gangrene.....	105
Necrosis.....	105
Bacteria Commonly Associated with Surgical Affections.....	106

	PAGE
CHAPTER XI.—CONTUSIONS AND WOUNDS.....	109
Contusions.....	109
Wounds.....	110
Repair of Tissue.....	113
CHAPTER XII.—SURGICAL FEVER.....	115
Septic Surgical Fever.....	115
Sapremia.....	116
Septicemia.....	117
Pyemia.....	118
CHAPTER XIII.—SYNCOPE, SHOCK, COLLAPSE.....	120
Hemorrhage.....	122
Hemophilia.....	126
CHAPTER XIV.—ANESTHESIA.....	130
Spinal.....	130
Local.....	130
General.....	132
Ether.....	133
Nitrous Oxid.....	141
Ethyl Chlorid.....	143
Tracheotomy.....	144
Ligation of Common Carotid Artery and External Carotid Artery.....	145
CHAPTER XV.—PREPARATION FOR OPERATION.....	148
Instruments.....	149
Ligatures, Sutures, etc.....	155
Drainage Materials.....	156
Bandages.....	157

---

### SPECIAL SURGERY

CHAPTER XVI.—HYPERTROPHY; TUMORS.....	159
Neoplasms or Tumors.....	162
Leukoplakia.....	172
CHAPTER XVII.—SYPHILIS OR LUES.....	174
CHAPTER XVIII.—STOMATITIS.....	183

	PAGE
CHAPTER XIX.—ALVEOLAR ABSCESS; OSTEOMYELITIS; NECROSIS; ACTINOMYCOSIS.....	191
CHAPTER XX.—DISEASES OF THE MAXILLARY SINUS.....	200
CHAPTER XXI.—DISEASES OF THE SALIVARY GLANDS AND THEIR DUCTS.....	205
Ludwig's Angina.....	208
CHAPTER XXII.—DISEASES OF THE TONSILS AND OF THE LYMPH- ATIC GLANDS.....	211
Hypertrophy of the Tonsils.....	211
Tonsillitis.....	212
Adenoids.....	213
The Lymphatic Glands.....	213
CHAPTER XXIII.—INJURIES AND DISEASES OF THE TEMPORO- MANDIBULAR ARTICULATION.....	215
Dislocation.....	215
Ankylosis.....	217
CHAPTER XXIV.—IMPACTED TEETH.....	224
Indications for Extraction of Deciduous Teeth.....	229
CHAPTER XXV.—MALFORMATIONS OF THE JAWS.....	231
Cleft-palate.....	231
Harelip.....	237
Injuries During Childbirth.....	239
CHAPTER XXVI.—FRACTURES.....	242
Fractures of the Mandible.....	243
CHAPTER XXVII.—TRIFACIAL NEURALGIA AND FACIAL PARALYSIS.	256
Trifacial Neuralgia.....	256
Facial Paralysis.....	264
—————	
INDEX.....	269



# APPLIED ANATOMY AND ORAL SUR- GERY FOR DENTAL STUDENTS

---

## PART I APPLIED ANATOMY

---

### CHAPTER I

#### BONES

##### GENERAL DEVELOPMENT OF THE SKULL

THE entire bony structure of the head is developed from the mesoblastic layer of the embryo. The bones forming the base of the brain-case are first laid down in cartilage, and those forming the vault of the cranium and the face develop in membrane, with the exception of the mandible. Ossification commences from various centers from the sixth to the eighth week of embryonic life.

The facial bones arise from the under surface of the base of the brain-case by certain processes which push downward. Those in front are termed the frontonasal processes, and those laterally, the maxillary and mandibular. Failure of union on the part of these processes brings about various congenital defects, such as harelip and cleft-palate.

## BONES OF THE SKULL

The skull is composed of 22 bones, of which 8 belong to the cranium and 14 to the face, as follows:

CRANIUM.	FACE.
1 occipital.	2 maxillary.
2 parietal.	2 malar.
2 temporal.	2 palate.
1 frontal.	2 lacrimal.
1 sphenoid.	2 inferior turbinated.
1 ethmoid.	2 nasal.
	1 vomer.
	1 mandible.

The following bones will be described more or less in detail: sphenoid, ethmoid, maxilla, and mandible.

**The Sphenoid Bone.**—The sphenoid bone (Fig. 7) is situated across the base of the skull, between the temporal bones laterally, the ethmoid bone in front, and the occipital bone behind.

The sphenoid bone consists of a body and six processes, three on each side, viz.: the greater wing, the lesser wing, and the pterygoid process. The *body* is cuboid in shape. Its upper and lateral surfaces are within the brain-case. The posterior surface articulates with the occipital bone. The anterior surface forms part of the roof of the nose, and presents the sphenoid turbinated bones and the openings of the sphenoid sinuses, which are situated within the body of the bone. The inferior surface also forms part of the roof of the nose and posterior wall of the nasopharynx.

The *greater wing* presents three surfaces—internal or cerebral, external or temporozygomatic, and orbital, which assists in forming the outer wall of the orbit.

The *lesser wing* extends outwardly from the anterior portion of the body, and has two surfaces. The superior surface assists in forming the anterior fossa of the brain-case, and the inferior surface is part of the roof of the orbit.

The *pterygoid process* projects downward from the junction of the greater wing with the body of the bone. It consists of an internal plate and an external plate, separated by the pterygoid fossa. The lower extremity of the internal pterygoid plate—the hamular process—assists in forming the bony framework of the roof of the mouth.

**The Ethmoid Bone.**—The ethmoid bone (Fig. 1) is situated between the orbits at the anterior part of the brain-case, and forms a portion of the anterior fossa of the skull. It is cuboid in shape, and consists of a vertical or perpendicular plate, a horizontal or cribriform plate, and two lateral masses. The *vertical* or *perpendicular plate* is in the median line, in an anteroposterior direction, and helps to form the septum of the nose.

The *cribriform plate* is placed above the vertical plate, at right angles to it. Its upper surface forms part of

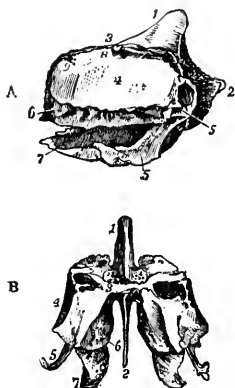


Fig. 1.—Back and side view of the ethmoid bone, showing in B the lateral masses on either side of the vertical septal plate (2), with which they are united by the cribriform plate (3) at the base of the crista (1). Between the nasal meatus and the orbital plate (4) are the cells, the closure of many completed by the frontal and other bones articulating with the ethmoid and projecting downward are the superior (6) and middle (7) turbinates and the uncinat process (5) (Allen).

the anterior fossa of the skull, and its lower surface part of the roof of the nose. It is divided into two lateral halves by the *crista galli*, which projects into the anterior fossa, being a continuation upward of the vertical plate. The cribriform plate is perforated by numerous foramina which transmit the olfactory nerve filaments. The two *lateral masses* are suspended from the cribriform plate on either side of the vertical plate. Each lateral mass is an irregular cube in shape, and is composed of the middle and superior turbinated bones. The lateral surface, known as the *os planum*, is flat and smooth, and forms part of the inner wall of the orbit. The lateral mass contains the middle ethmoid cells. In front, by articulating with the frontal bone, the lateral mass forms the anterior ethmoid cells, and behind, by articulating with the sphenoid and palate bones, the posterior ethmoid cells.

The ethmoid bone assists in forming the anterior fossa of the skull, the nasal chamber, the ethmoid air-cells, the maxillary sinus, and the orbit.

**The Maxilla.**—The maxilla (Fig. 5) is an irregular pyramid in shape, the base toward the median line, and the apex externally. It has four surfaces: the orbital, the nasal, the lateral or facial, and the zygomatic; and four processes: the nasal, the malar, the palatal, and the alveolar.

The orbital or upper surface assists in forming the floor of the orbit. Immediately beneath it runs the infra-orbital canal.

The nasal surface assists in forming the outer wall of the nasal chamber. It presents the large opening of the maxillary sinus.

The lateral or facial surface is concave, and presents a depression behind the root of the canine tooth—the canine fossa—and the infra-orbital foramen.

The posterior or zygomatic surface assists in the formation of the sphenomaxillary and zygomatic fossæ, and presents the tuberosity, a rounded prominence above the third molar tooth.

The body of the maxilla contains the maxillary sinus or antrum of Highmore.

The nasal process runs upward and backward from the anterosuperior angle of the facial surface, and assists in forming the inner wall of the orbit and the outer wall of the nose.

The malar process projects outward and upward to articulate with the malar bone.

The palatal process, with its fellow of the opposite side, forms the anterior three-fourths of the hard palate, the remainder being formed by the horizontal process of the palate bones and the tips of the pterygoid processes of the sphenoid bone. In the anterior portion of the hard palate, in the median line, is seen the anterior palatine fossa. This contains four foramina—the foramina of Stenson, situated laterally, and the foramina of Scarpa, situated anteroposteriorly.

The alveolar process extends forward from the tuberosity along the lower border of the bone, to the outer side of the palatal process, and meets its fellow of the opposite side at the median line in front. This process is composed of cancellated or spongy bone, and contains alveoli for the accommodation of the roots of the teeth. The alveolar process has an inner and an outer plate, which are composed of dense bone. The alveolar

process is developed as the teeth erupt, and undergoes absorption when they are lost.

The maxilla assists in forming the following cavities: the orbit, the nasal chamber, the mouth, the maxillary sinus, the sphenomaxillary fossa, and the zygomatic fossa.

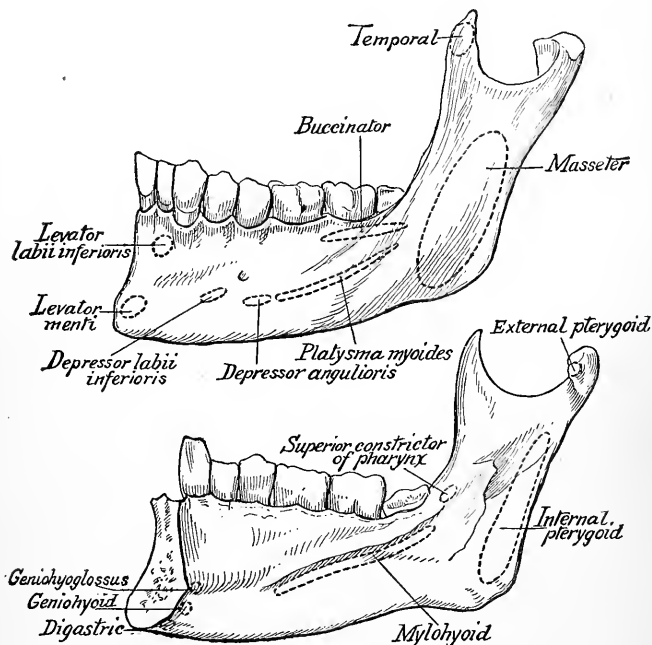


Fig. 2.—The mandible, showing muscular attachments.

**The Mandible.**—The mandible (Fig. 2) is a horseshoe-shaped bone, and consists of a horizontal portion called the body, and two rami. The body extends in a curved manner on either side of the median line, and joins each ramus at about a right angle. The ramus is surmounted by two processes—the coronoid process in front, for the

insertion of the temporal muscle, and the condyloid process behind, the tip of which articulates with the anterior portion of the glenoid fossa of the temporal bone, forming the temporomandibular joint. The two processes are separated by the sigmoid notch. The outer surface of the body of the bone presents the external oblique line for the attachment of the platysma myoides.

In the median line in front, at the symphysis, is the mental process. On the outer surface, below and between the premolar teeth, is the mental foramen. About the middle of the inner surface of the ramus is the inferior dental (mandibular) foramen, transmitting the inferior dental nerve and vessels. On the anterior border of the foramen is a sharp spine, the lingula, to which is attached the internal lateral ligament. From the lower border of the foramen the mylohyoid groove runs forward and downward, transmitting the mylohyoid vessels and nerve. The inner surface of the body of the bone presents an oblique line, the mylohyoid ridge, to which the mylohyoid muscle is attached. Below the ridge posteriorly is the submaxillary fossa, which contains the submaxillary gland, while above it, in front, is the sublingual fossa, for the accommodation of the sublingual gland. In the median line, on the inner surface, are the four genial tubercles—the upper pair for the attachment of the geniohyoglossus muscles, and the lower pair for the geniohyoid muscles; below the genial tubercles is the digastric fossa, for the attachment of the digastric muscle. Just in front of the angle of the mandible, on its lower border, is the facial notch, through which passes the facial artery. The body of the mandible is surmounted by the alveolar process and the teeth.

A transverse section of the body of the mandible shows a U-shaped structure of dense cortical bone, the arms of the U terminating above in the outer and inner plates of the alveolar process. The space between the arms of the U is filled with fine trabeculæ, forming the cancellated structure. The roots of the teeth are embedded within

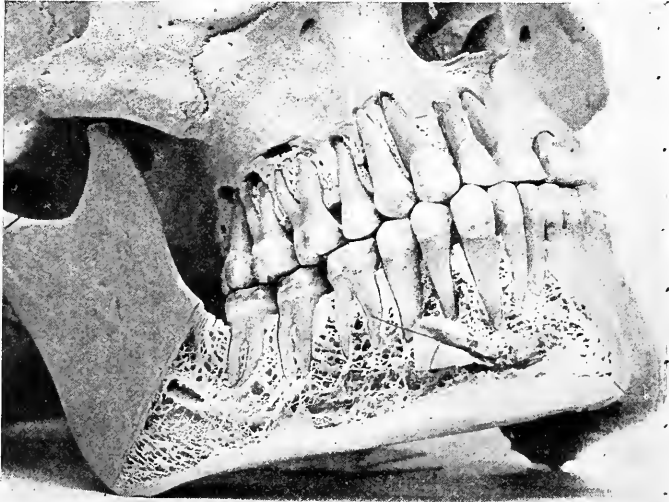


Fig. 3.—Showing cancellated tissue of mandible and inferior dental tube. Wire showing direction of tube from mental foramen (Cryer).

this cancellated tissue. Through the cancellated tissue runs the inferior dental canal or cribriform tube of the mandible, which forms a protective passage (Fig. 3) for the inferior dental nerve and vessels. The cribriform tube passes downward and forward from the inferior dental foramen through the body of the bone to the region of the incisor teeth. From this point a recurrent



branch runs backward to the mental foramen. From the cribriform tube smaller tubules pass upward and forward in a curved direction, and convey individual nerve-fibers and blood-vessels to the roots of the teeth. The tubules to the canine and the first premolar are given off from the recurrent portion of the inferior dental tube.

*Development and Growth of the Mandible.*—The mandible is the second bone in the body to be developed, the clavicle being the first. The mandible is formed from the first pair of branchial folds, called the mandibular plates. These plates, at about the twenty-fifth day of embryonic life, advance from either side and meet in the median line. Soon afterward Meckel's cartilage is formed in the deeper portion of the mandibular plate. The proximal end of the cartilage forms the malleus, one of the middle ear bones, and the distal end joins its fellow of the opposite side in the median line and forms the mandible. About the fortieth day of embryonic life ossification begins around this cartilage from various centers. At birth there is no osseous union between the two halves of the mandible: this takes place during the first year.

The cortical U-shaped portion of the bone is the framework of the jaw. It increases in length and breadth in a different manner from its contents. It is likely that it grows by an interstitial process, each half having three fixed points between which growth occurs—the ramus, the mental foramen, and the symphysis menti. The periods of growth in these regions seem to correspond with the time of development and eruption of the teeth in the localities concerned. Thus, the increase between the mental foramen and the symphysis

menti occurs during the time the incisor, canine, and premolar teeth are developing, while the greatest growth from the mental foramen to the ramus takes place during the development of the molar teeth.

The contents of the U-shaped portion grow forward as the cortical structure increases in length. It is this forward movement that gives the curvature to the various small tubes to the roots of the teeth.

At birth the angle of the mandible is very obtuse, the ramus and body being almost in a straight line. As the teeth erupt the angle changes, until, at the age when all the permanent teeth are in position, it nearly approaches a right angle. The change is due to the gradual separation of the upper and lower jaws by the growth of the teeth and alveolar process. As the teeth are lost with age the angle returns to its former condition, again becoming obtuse. This senile change can be greatly retarded by replacing the lost teeth by artificial dentures.

**The Hyoid Bone.**—The hyoid bone, or *os linguæ*, while not a bone of the skull, is so closely associated with the mouth and jaws by attachment of muscles that it should be described in a study of the regional anatomy of these parts. The hyoid bone is a symmetric, horseshoe-shaped bone, situated in the median line of the upper part of the neck, beneath the floor of the mouth, and above the larynx. It is a floating bone, having no articulation. It consists of a body and four processes, the greater and lesser cornua on each side. The body of the hyoid bone is quadrilateral in shape, compressed from before backward, and extends symmetrically on each side of the median line. It

gives attachment to the geniohyoid, mylohyoid, stylohyoid, digastric, hyoglossus, geniohyoglossus, sternohyoid, omohyoid, and thyrohyoid muscles, and the thyrohyoid membrane.

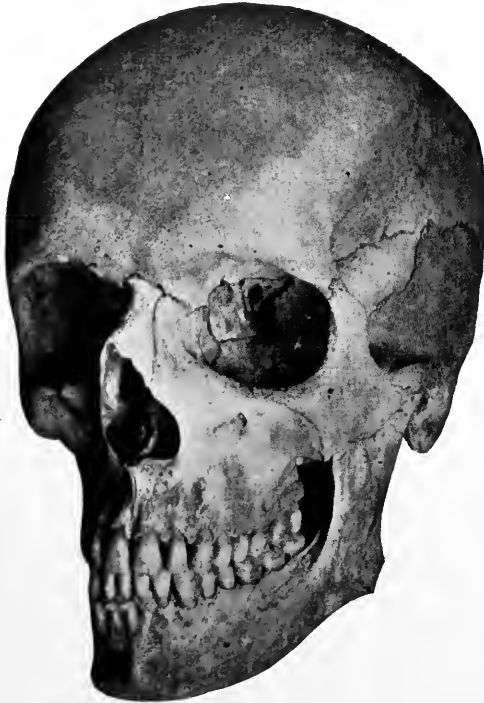

Fig. 4.—Anterolateral view of skull (Cryer).

The greater cornu projects backward from the body of the bone, giving attachment to the superior constrictor of the pharynx, the hyoglossus, and the thyrohyoid muscles.

The lesser cornu is shorter than the greater cornu, and

projects backward and upward from the body of the bone, giving attachment to the stylohyoid ligament.

### THE SKULL AS A WHOLE

**Anterior Region.**—The following prominent landmarks are seen in an anterior view of the skull (Fig. 4): The supra-orbital portion of the frontal bone, the orbit, the nasal fossa, the malar bone, continued laterally as

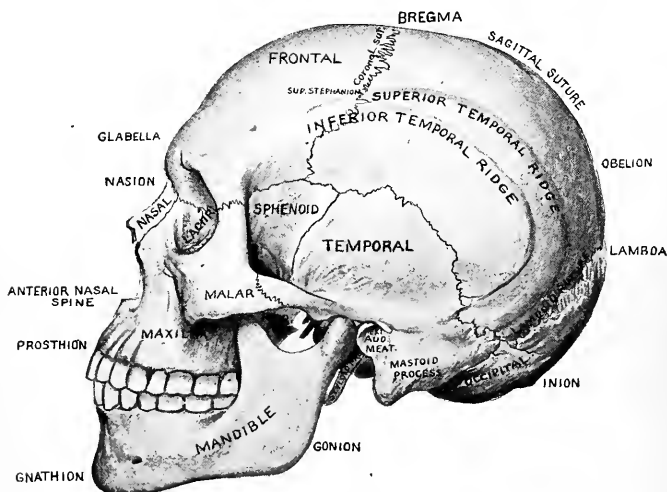


Fig. 5.—Side view of skull (Sobotta and McMurrich).

the zygoma, the maxilla, the teeth, and the anterior portion of the mandible, with the mental process in front. The three most prominent foramina seen are the supra-orbital in the frontal bone, the infra-orbital in the maxilla, and the mental in the mandible. These three foramina are in a vertical straight line.

**Lateral View.**—The lateral aspect of the skull (Fig. 5) presents the mastoid process, the external auditory

meatus, the auditory process, the glenoid fossa, the zygomatic arch, the temporal fossa, the zygomatic fossa, the condyloid and coronoid processes of the mandible. The principal sutures seen are the lambdoid, between the occipital and parietal bones, the squamous, between the temporal and parietal bones, and the coronoid, between the frontal and parietal bones. Certain prominent points of the skull have been given special names for convenience. These are shown in the illustration.

#### BASE OF THE SKULL

**Inferior or External Surface** (Fig. 6).—This surface presents from before backward the hard palate, surrounded by the upper teeth, the zygomatic arch, the pterygoid process of the sphenoid, the posterior nares, the pterygoid fossa, the eminentia articularis, the glenoid fossa, the tympanic plate, the styloid process, the mastoid process, the petrous portion of the temporal bone, the basilar and condyloid processes of the occipital bone, and the external occipital protuberance. The important foramina seen are: the anterior, posterior, and accessory palatine foramina, the foramen ovale, the foramen spinosum, carotid, middle lacerated, stylo-mastoid, posterior lacerated or jugular, anterior and posterior condyloid, and foramen magnum.

The internal or upper surface of the base of the skull is divided into three fossæ—the anterior, middle, and posterior fossæ of the skull (Fig. 7).

The anterior fossa presents the cribriform plate and the crista galli of the ethmoid bone, the orbital plate of the frontal bone, and the body and lesser wing of the sphenoid bone, at the junction of which is the anterior

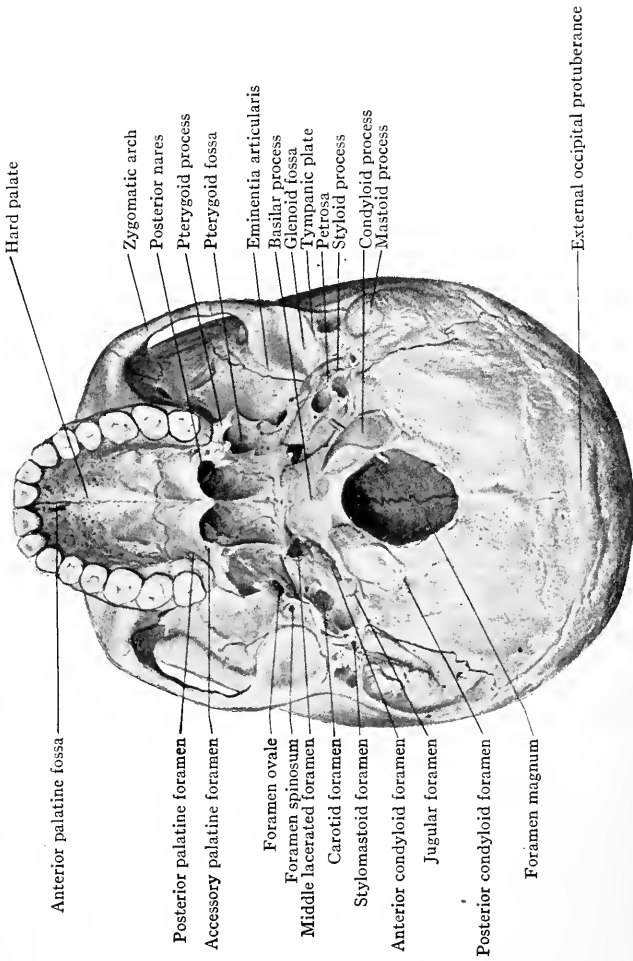


Fig. 6.—The skull seen from below, the outer surface of the base. The mandible has been removed (Sobotta and McMurrich).

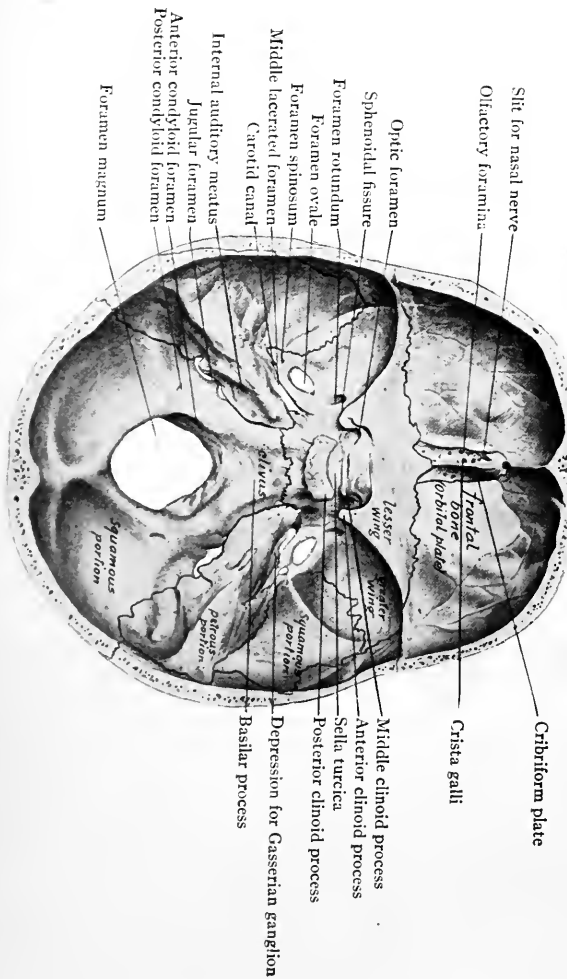


Fig. 7.—The inner surface of the base of the skull (Sobotta and McMurrich).

clinoid process. The middle clinoid process is given off from the side of the body of the sphenoid. The foramina seen are: the orifices for the olfactory nerves, the nasal slit, the anterior and posterior ethmoid foramina, and the optic foramen.

The middle fossa is composed of the body and greater wing of the sphenoid bone, the anterior surface of the petrous portion, and the squamous portion of the temporal bone. In it are seen the sella turcica, the depression for the Gasserian ganglion, the anterior lacerated foramen or sphenoid fissure, the foramen rotundum, the foramen ovale, the foramen spinosum, the middle lacerated foramen, and the orifice of the carotid canal.

The posterior fossa is made up of the basilar process of the occipital, at the anterior end of which is the posterior clinoid process, the horizontal portion of the occipital bone, and the posterior surface of the petrous portion of the temporal bone. It presents the internal auditory meatus, the posterior lacerated or jugular foramen, the anterior and posterior condyloid foramina, and the foramen magnum.

### THE ORBIT

The orbit is a quadrilateral pyramid in shape, its base being directed forward and a little outward. Seven bones enter into its formation, viz.: frontal, sphenoid, ethmoid, palate, malar, maxilla, and lacrimal.

The roof of the orbit is composed of the orbital plate of the frontal bone and part of the lesser wing of the sphenoid bone.

The floor is made up of the orbital surface of the maxilla and the orbital processes of the malar and palate bones.



The outer wall is formed by the orbital surface of the greater wing of the sphenoid and part of the malar bone.

The inner wall is formed by the nasal process of the maxilla, the os planum of the ethmoid, and the lacrimal bone.

The openings into the orbit are ten in number, as follows: Optic foramen, at the apex, transmitting the optic nerve and the ophthalmic artery. Sphenoid fissure, near the apex, transmitting the third, fourth, ophthalmic division of the fifth, and sixth nerves, and the ophthalmic vein. The anterior ethmoid foramen on the inner wall, transmitting the nasal nerve and anterior ethmoid vessels. The posterior ethmoid foramen, on the inner wall, transmitting the posterior ethmoid vessels. The lacrimonasal canal has its opening at the anterior portion of the inner side of the orbit, and communicates with the inferior meatus of the nose. The infra-orbital canal begins in the floor of the orbit, and transmits the infra-orbital nerve and vessels. The sphenomaxillary fissure is in the posterior portion of the orbital cavity, and transmits the infra-orbital nerve and vessels. The malar foramina, two in number, are in the outer wall of the orbit, and transmit nerves and vessels to the cheek.

#### BONY ROOF OF THE MOUTH

The bony roof of the mouth comprises the hard palate; the anterior three-fourths are made up of the palatal processes of the maxillæ, and the posterior one-fourth by the horizontal plates of the palate bones. At the posterior margin of the latter externally are the hamular processes of the sphenoid bone. The palatal processes

of the maxilla are formed from three processes, the wedge-shaped intermaxillary bone in front containing the germs of the incisor teeth, and the two lateral processes or true maxillæ. The intermaxillary bone is formed by the union of the right and left premaxillary bones, which in early life are separated by a suture. The orthodontist in certain cases is able to open this suture in the process of widening the dental arch.

In the anterior portion of the hard palate, at the junction of the palatal processes of the maxillæ and the intermaxillary bone, is the anterior palatine fossa, which contains four openings, two being the foramina of Scarpa, situated anteroposteriorly, and transmitting the nasopalatine nerves, and two situated laterally, the foramina of Stenson, transmitting the anterior palatine vessels. In the suture between the maxilla and the palate bone are the posterior and accessory palatine canals, for the transmission of the posterior palatine nerves and vessels.

#### THE NASAL FOSSAE

The nasal fossæ, two in number, are situated one on either side of the median line of the face, separated by a thin plate of bone—the nasal septum. The nasal fossæ are composed of a roof, a floor, a septum, and outer walls.

The roof of the nasal fossæ consists of three portions—anterior, middle, and posterior. The anterior portion extends upward and backward, and is composed of the under surfaces of the nasal bones and the nasal spine of the frontal bone. The middle portion is horizontal, and is composed of the cribriform plate of the

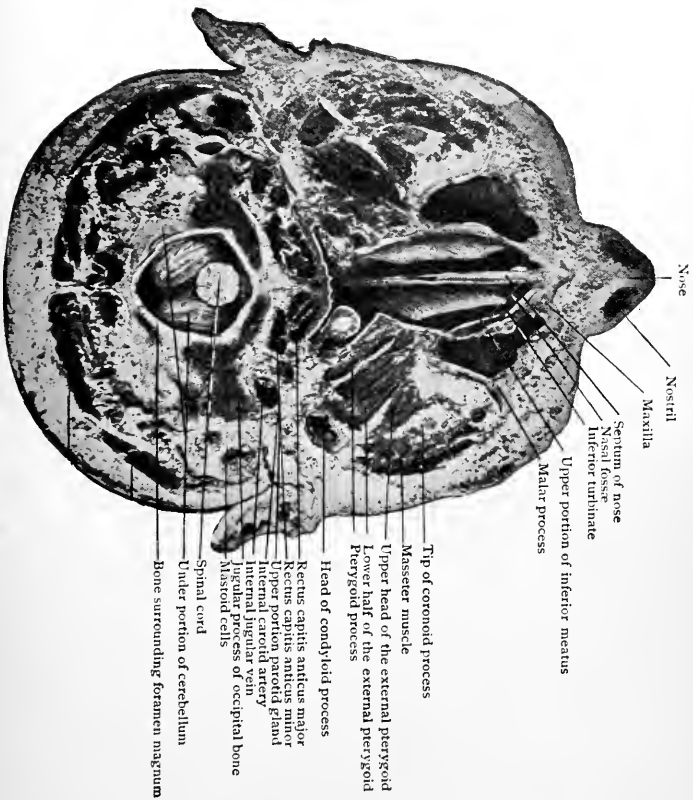


Fig. 8.—Horizontal section of a frozen head (Cryer).

ethmoid bone. The posterior portion slopes downward and backward, and is composed of the body of the sphenoid and the alæ of the vomer.

The floor of the nose is formed by the palatal processes of the maxillæ in front and the horizontal processes of the palate bones behind.

The septum of the nose lies vertically in the median line and runs in an anteroposterior direction. The principal structures forming it are the vomer behind and below, the vertical plate of the ethmoid in front and above, while in the recent state a triangular notch in front is filled in with the triangular cartilage. In addition, the crests of the maxillary and palate bones, the rostrum of the sphenoid, and the nasal spine of the frontal bones assist in forming the nasal septum (Fig. 8).

The bones entering into the formation of the lateral wall of the nasal chamber are: the nasal, the nasal process of the maxillary, the lacrimal, the ethmoid, the inferior turbinated, the palate, and the pterygoid process and body of the sphenoid.

The inferior turbinated bone and the turbinated processes of the ethmoid bone divide the lateral wall of the nasal chamber into several horizontal compartments or meati, three being the number usually described. In the majority of skulls, however, four meati are present, and in a few cases five or even six have been found. The several meati have communications with the maxillary sinus and other pneumatic spaces (Fig. 9).

The inferior meatus is situated between the floor of the nose and the inferior turbinated bone. Into it opens the lacrimonasal duct, which conveys tears from the orbit.

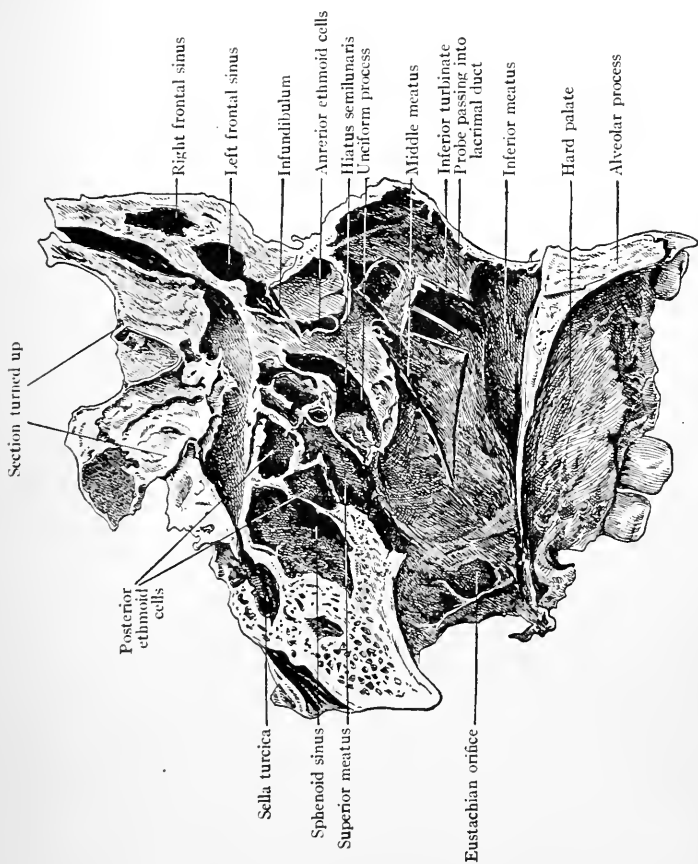


Fig. 9.—An anteroposterior section within the nasal chamber, with the middle turbinate bone and portion of cell walls turned up (Cryer).

The middle meatus is found between the inferior and middle turbinated bones. Into it open the maxillary sinus, the frontal sinus, and the anterior and middle

ethmoid cells. All these air-spaces open into the middle meatus through the hiatus semilunaris, a semi-circular groove continuous with the infundibulum, which is the outlet of the frontal sinus. Many authorities do not regard the infundibulum as distinct from the hiatus semilunaris, the so-called infundibulum being, in their opinion, the upper part of the hiatus. The narrow opening from the frontal sinus into the hiatus semilunaris or infundibulum is sometimes known as the ostium frontale. The hiatus semilunaris is bounded toward the median line by the unciform process of the ethmoid bone, this hook-like projection overlapping the ostium maxillare, which is the opening into the maxillary sinus. Above the unciform process is the bulla ethmoidalis, a rounded prominence of bone formed by the bulging of the middle ethmoid cells. The parts just described, the unciform process, the hiatus semilunaris, and the bulla ethmoidalis, are hidden from view by the middle turbinated bone, and can usually be seen only by removing the latter.

The superior meatus is situated between the middle and superior turbinated bones, which are both parts of the ethmoid. When only three meati are present, the sphenoid sinus, the posterior ethmoid cells, and the cell in the orbital process of the palate bone, all open into this meatus, but when there are four meati, the sphenoid sinus and the posterior ethmoid cells open into the fourth or supreme meatus. The sphenoid cells especially, in the majority of cases, open into the highest meatus, whether three, four, or five meati be present. When more than three meati exist, they are formed by additional turbinated masses on the ethmoid bone.

The nasal chambers are bound in front by the anterior nares, and behind by the posterior nares. The space of the *anterior nares* is inclosed by the nasal bones above, the maxillæ laterally and below, while it is divided into two portions by the triangular cartilage of the nasal septum.

The *posterior nares* is bounded above by the cribriform plate of the ethmoid and body of the sphenoid bones, laterally by the vertical plates of the palate bones, and below by the horizontal plates of the palate bones. The vomer divides the space vertically into two portions.

#### THE MAXILLARY SINUS

The maxillary sinus or antrum of Highmore (Fig. 10) is the largest pneumatic space communicating with the nasal fossa, and is situated in the body of the maxillary bone. In the typical specimen the cavity is somewhat pyramidal in shape, with its base directed toward the nasal fossa, and its apex extending toward and sometimes into the malar bone. Though this may be given as the typical shape, yet the maxillary sinus varies very much in form and size in different individuals, and on the two sides in the same individual. The cavity is lined with mucoperiosteum surmounted by a layer of ciliated columnar epithelium.

The roof of the maxillary sinus is formed by the orbital plate of the maxillary bone, which separates it from the orbit. It presents a ridge of bone inclosing the canal for the passage of the infra-orbital vessels and nerve. The prominence of this ridge varies in different subjects. In the negro race especially, where the bones are very thick, it is scarcely perceptible.

The anterior wall is formed by the facial portion of the maxilla. It contains the anterior dental canal, transmitting nerves and vessels to the incisor teeth.

The floor of the maxillary sinus is composed of the

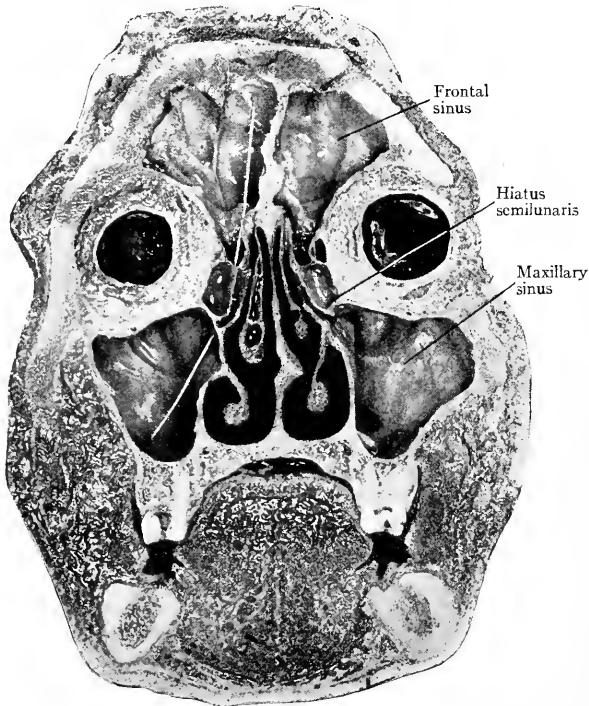


Fig. 10.—Transverse section of face, showing probe passing from maxillary sinus through ostium maxillare and hiatus semilunaris into frontal sinus (Cryer).

alveolar process. It presents conic elevations corresponding to the apices of the roots of the molar and sometimes of the premolar teeth. It may also present partial septa extending transversely. Complete septa are never found in the maxillary sinus.



The posterior wall of the maxillary sinus is formed by the zygomatic plate of the maxilla, which separates it from the sphenomaxillary fossa.

The proximal or nasal wall is formed chiefly by the maxilla, aided by the inferior turbinate, ethmoid, and palate bones (Fig. 11). This partition separates the

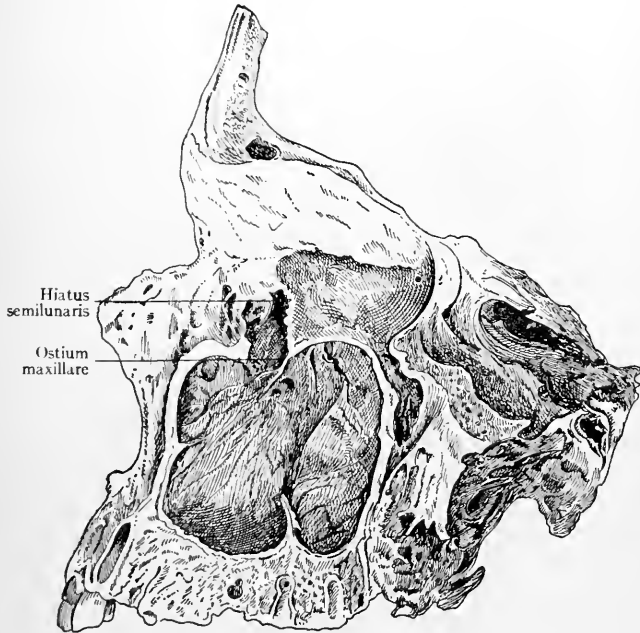

Fig. 11.—Anteroposterior division through the maxillary sinus (Cryer).

maxillary sinus from the nasal fossa. At the upper anterior portion of this wall is found an oval foramen—the ostium maxillare—which affords communication between the maxillary sinus and middle meatus, opening directly into the hiatus semilunaris. This is the only normal

opening of the antrum of Highmore, but in certain pathologic conditions more than one opening may be present, when the normal opening becomes closed by pressure of the engorged mucous membrane covering the

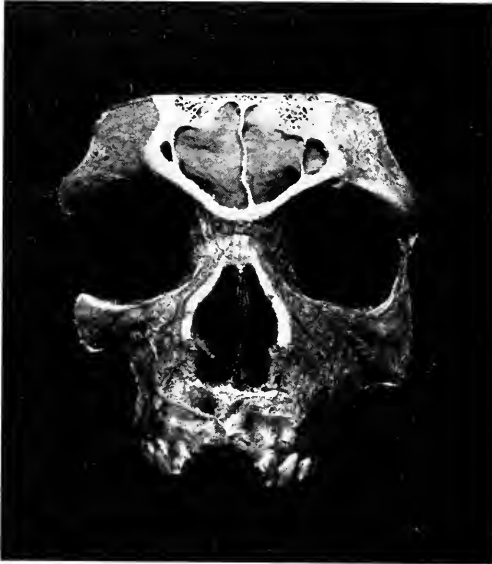


Fig. 12.—Front view of skull with frontal sinuses exposed (Cryer).

bullae ethmoidalis. Under normal conditions there is communication between the maxillary sinus and the frontal sinus through the ostium maxillare, the hiatus semilunaris, and the ostium frontale. By this communication disease from the teeth may spread through the antrum to the frontal sinus and the other pneumatic spaces.

#### THE FRONTAL SINUSES

The frontal sinuses (Fig. 12) are two irregular air-cells situated in the facial portion and the orbital proc-

esses of the frontal bone. They vary greatly in size, shape, and position, and there may be three, four, or five cells, each with a separate opening. Each frontal sinus is separated from its fellow by a bony septum, which may be in the median line or to one side of it. Partial septa also often exist. In typical cases the frontal sinus opens at its lower part into the hiatus semilunaris of the middle meatus of the nose. The opening is known as the ostium frontale. Multiple sinuses may open into one another or into the anterior ethmoid cells.

The **sphenoid sinuses** are two in number, situated in the body of the sphenoid bone. The bony septum between them is often deflected to one side or the other. They empty into the highest meatus of the nose.

The **ethmoid air-cells** occupy the lateral masses of the ethmoid bone, and are divided into three sets—anterior, middle, and posterior. The anterior and middle ethmoid cells open into the middle meatus of the nose through the hiatus semilunaris, while the posterior ethmoid cells empty into the superior meatus.

#### REVIEW QUESTIONS

Name the bones forming the cranium.

Name the bones forming the face.

Describe the principal portions of the sphenoid bone.

Describe the ethmoid bone.

What cavities does the ethmoid bone assist in forming?

Describe the maxilla.

What cavities does the maxilla assist in forming?

Describe the general features of the mandible.

Describe the external surface of the mandible.

Describe the internal surface of the mandible.

Describe the internal structure of the mandible.

Describe in a general way the development and growth of the mandible.

Describe the variations occurring in the angle of the mandible according to the age of the individual.

Describe the hyoid bone.

What prominent landmarks are seen in an anterior view of the skull?

What prominent landmarks are seen in a lateral view of the skull?

What prominent landmarks are seen on the under surface of the base of the skull?

What prominent landmarks are seen on the upper surface of the base of the skull?

Name the bones forming the orbit, giving their relations.

Name the openings into the orbit, giving the structures that pass through each.

Describe the bony roof of the mouth, naming the bones forming it, and giving their relations.

What foramina are found in the roof of the mouth? What structures do they transmit?

Name the teeth which develop in the different formative bones of the upper jaw.

Name the bones forming the roof of the nasal fossæ, giving their relations.

Give the names and position of the bones forming the floor of the nose.

Describe the nasal septum, giving the bones forming it.

Name the bones forming the lateral wall of the nasal chamber.

Describe the various meati of the nose.

Name the openings into the various meati of the nose.

Describe the hiatus semilunaris and the adjacent structures.

What bones bound the anterior nares?

What bones bound the posterior nares?

In what bone is the antrum of Highmore situated?

Describe the shape and boundaries of the maxillary sinus.

Name and give the situation of the outlet of the maxillary sinus.

Trace the course of disease from the maxillary sinus to the frontal sinus.

Give the general situation and outlet of the frontal sinus.

## CHAPTER II

### THE TEMPOROMANDIBULAR ARTICULATION

THE temporomandibular joint is formed by the articulation of the condyle of the mandible with the glenoid fossa of the temporal bone. It is a compound joint, allowing elevation and depression of the mandible, forward and backward gliding, and also lateral motion.

The condyle of the mandible is the rounded prominence surmounting the condyloid process. The condyle is broader in its lateral direction than anteroposteriorly, and is covered with articular cartilage.

The glenoid fossa is a shallow depression in the temporal bone, situated just in front of the ear. It is bounded in front by a ridge—the eminentia articularis—and posteriorly by the tympanic plate of the temporal bone. The fossa is divided into an anterior portion and a posterior portion by the Glaserian fissure, which contains the processus gracilis of the malleus, and transmits the tympanic branch of the internal maxillary artery. The anterior part of the glenoid fossa is the articular portion. The posterior portion contains a process of the parotid gland.

There are four ligaments connected with this joint, and also an interarticular fibrocartilage with two synovial sacs.

The ligaments are as follows:

1. Capsular ligament.
2. External lateral ligament.

3. Internal lateral ligament (sphenomandibular).

4. Stylomandibular ligament.

The capsular ligament surrounds the joint and is attached above to the margins of the glenoid fossa, and below to the neck of the condyle. It also sends fibers in to blend with the interarticular fibrocartilage.

The external lateral ligament is a thickening of the capsular ligament, and extends from the tubercle of the zygoma to the outer side of the neck of the condyle.

The internal lateral ligament runs from the spine of the sphenoid to the lingula of the mandible.

The stylomandibular ligament runs from the tip of the styloid process of the temporal bone to the angle of the mandible.

The interarticular fibrocartilage is an oval disc, convex above and concave below, thicker at its periphery than centrally, placed between the condyle and the glenoid fossa. It is held in place by fibers from the capsular ligament, and also receives a slip from the external pterygoid muscle, which draws it forward on the eminentia articularis when the jaw is protruded.

The synovial sacs, containing synovial fluid, are two in number, situated one above and one below the interarticular fibrocartilage.

#### REVIEW QUESTIONS

Describe the bony surfaces forming the temporomandibular joint.  
Describe the ligaments and other structures of the joint.

## CHAPTER III

### MUSCLES AND FASCIÆ

#### THE CERVICAL FASCIA

THE cervical fascia is divided into the superficial and the deep layers. The superficial cervical fascia lies immediately beneath the skin, and connects the latter with the deeper structures. In its meshes is found the platysma myoides, a broad, thin sheet of muscle extending from the clavicle to the lower border of the mandible, where it blends with the muscles of expression about the mouth. Through the superficial fascia run the external anterior and posterior external jugular veins and the superficial cervical nerves.

The deep cervical fascia or cravat fascia forms a complete investment for the deeper structures of the neck. It is attached behind to the spinous processes of the cervical vertebræ, splits into two layers to invest the trapezius muscle, and forms a single layer at the anterior border of that muscle, to cross the posterior triangle of the neck. When the posterior border of the sternomastoid muscle is reached, the fascia again divides into two layers, one going in front of and one behind the muscle. From the anterior border of the sternomastoid a single layer passes across the anterior triangle to meet the fascia of the opposite side in the median line of

the neck. The cervical fascia is attached below to the clavicle. Above, it is attached to the lower border of the mandible, the zygoma, the mastoid process, and the superior curved line of the occipital bone. This fascia gives off many processes which invest various structures of the neck. Two layers are given off to invest the parotid gland, known as the parotid fascia. The following are the deeper processes: (1) A process comes off near the anterior border of the sternomastoid muscle, which passes behind the depressor muscles of the hyoid bone, invests the thyroid gland, and covers the front of the trachea. (2) A process known as the prevertebral fascia passes behind the trachea and esophagus and in front of the prevertebral muscles. (3) The carotid sheath, enclosing the carotid artery, the internal jugular vein, and the pneumogastric nerve, is derived from layers 1 and 2.

#### THE SURGICAL SQUARE AND TRIANGLES OF THE NECK

The surgical square of the neck is bounded in front by the median line; behind, by the anterior border of the trapezius muscle; above, by the lower border of the mandible and a line drawn from the angle of the mandible to the mastoid process of the temporal bone; below, by the clavicle. The coverings of the square of the neck are the skin, the superficial fascia,—in which lies the *platysma myoides*,—and the deep fascia.

The sternocleidomastoid muscle runs diagonally across the square of the neck, from its posterior superior angle to its anterior inferior angle, dividing it into an anterior and a posterior triangle (Fig. 13).

The *anterior triangle* is divided into three smaller triangles by the anterior and posterior bellies of the



digastric muscle and the anterior belly of the omohyoid muscle, which traverses the square diagonally from its anterosuperior to its postero-inferior angle. The three anterior triangles are the inferior carotid, the superior carotid, and the submaxillary triangles.

The *posterior triangle* of the neck is divided by the posterior belly of the omohyoid muscle into the subclavian and occipital triangles.

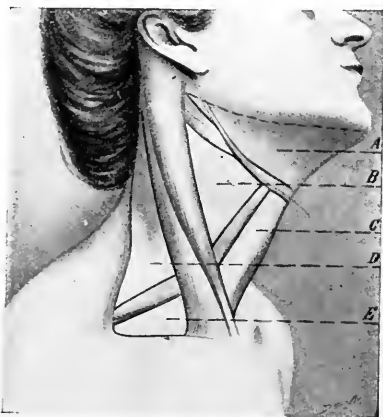


Fig. 13.—Triangles of the neck: A, Submaxillary triangle; B, superior carotid triangle; C, inferior carotid triangle; D, occipital triangle; E, supraclavicular triangle (Campbell).

The *inferior carotid triangle* is bounded in front by the median line, behind by the sternomastoid muscle, and above by the anterior belly of the omohyoid muscle. It contains the common carotid, the inferior thyroid, and the vertebral arteries, the internal jugular and middle and inferior thyroid veins, and the pneumogastric and phrenic nerves.

The superior carotid triangle is bounded in front by

the anterior belly of the omohyoid muscle, above by the posterior belly of the digastric muscle, and behind by the sternomastoid muscle. It contains the common carotid and its bifurcation into the internal and external carotid arteries, the superior thyroid, the ascending pharyngeal, the lingual, the facial, the occipital, and the posterior auricular arteries; the superior thyroid, the ranine, the lingual, the facial, and the internal jugular veins, and the descendens hypoglossi and pneumogastric nerves.

The *submaxillary triangle* is bounded below by the anterior and posterior bellies of the digastric muscle, and above by the lower border of the mandible and a line drawn from the angle of the mandible to the mastoid process. This triangle contains the external carotid, the facial, the lingual, and the posterior auricular arteries; the internal jugular, the lingual, and the facial veins; the pneumogastric, the glossopharyngeal, and the hypoglossal nerves, and the submaxillary gland. The submaxillary triangle is the most important to the oral surgeon and the dentist, because it lies immediately beneath the oral cavity, and is most often affected by diseases of the mouth.

The *occipital triangle* is bounded in front by the sternomastoid muscle, behind by the anterior border of the trapezius, and below by the posterior belly of the omohyoid muscle. It contains the transversalis colli artery and the spinal accessory and cervical plexus of nerves.

The *subclavian triangle* is bounded below by the clavicle, in front, by the sternocleidomastoid muscle, and behind, by the posterior belly of the omohyoid muscle. It contains the subclavian, the vertebral, the thyroid

axis, the internal mammary, and the superior intercostal arteries, the subclavian vein, and the brachial plexus of nerves.

### THE TONGUE

The tongue, when the mouth is closed, "occupies the space from the anterior teeth backward nearly to the postpharyngeal wall, and from the floor of the mouth nearly to the roof. It almost completely fills the space, which is quite different in form from that shown in most text-books. Professor Donder has spoken of the space between the roof of the mouth and the tongue as acting somewhat on the same principle as the vacuum chamber in an upper artificial denture, *i. e.*, when the air is exhausted by the action of the tongue a partial vacuum is created when the tongue is relaxed, by the action of which the weight of the lower jaw, with the tongue, is overcome to a certain extent" (Cryer) (Fig. 14).

The muscles of the tongue are divided into two groups, the extrinsic group and the intrinsic group.

The *extrinsic* muscles of the tongue are: The hyoglossus, the geniohyoglossus, and the styloglossus. The palatoglossus is also attached to the tongue, but will be described with the muscles of the soft palate.

The *hyoglossus* muscle arises from the greater and lesser cornua of the hyoid bone, and is inserted into the posterior and lateral portions of the tongue. It is supplied by the hypoglossal nerve. Its action is to aid in depressing the tongue.

The *geniohyoglossus* is a fan-shaped muscle arising from the superior genial tubercle of the mandible. It spreads out and passes backward, its upper fibers being

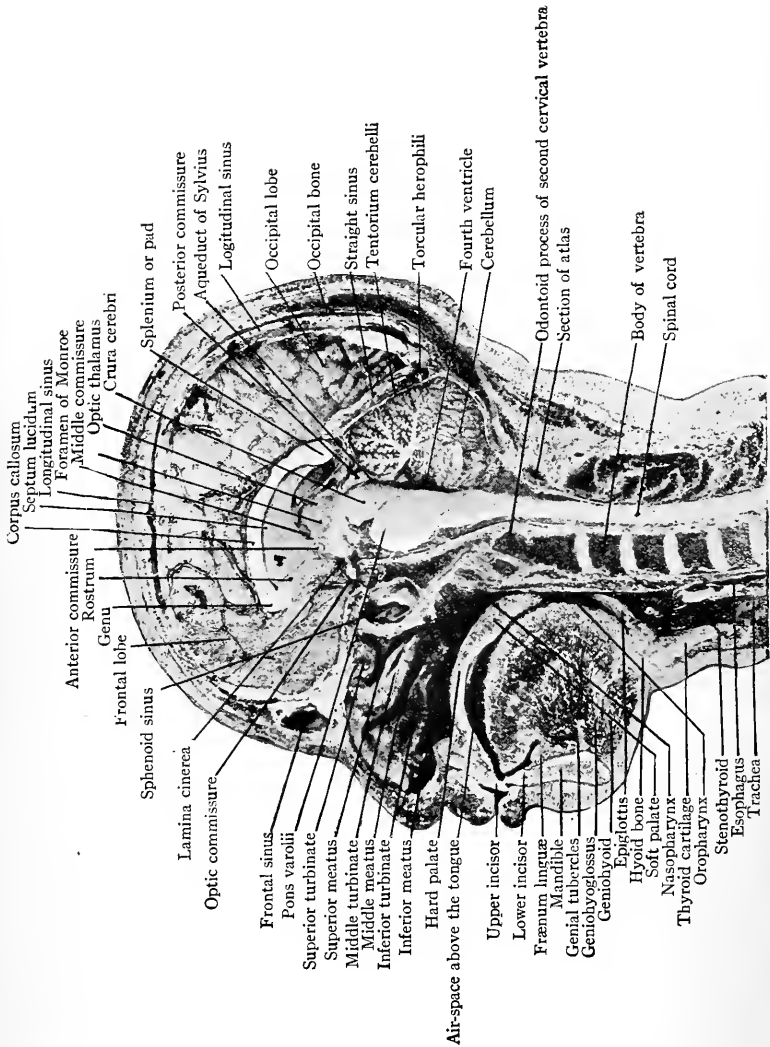


Fig. 14.—Vertical anteroposterior section of a frozen head (Cryer).

inserted into the under surface of the body of the tongue, and its lower fibers running to the hyoid bone. This muscle is supplied by the hypoglossal nerve. Its action is to draw forward and protrude the tongue.

The *styloglossus* muscle arises near the apex of the styloid process and passes forward, downward, and inward to the posterior part of the tongue, where it divides into a longitudinal portion, passing forward, and an oblique portion, passing downward. Its nerve-supply is derived from the hypoglossal. The *styloglossus* assists in retracting and elevating the tongue.

The *intrinsic* muscle of the tongue is the *lingualis*.

The principal bulk of the *lingualis* is a longitudinal set of muscular fibers, arising at the base and extending between the *hyoglossus* and the *geniohyoglossus* muscles to the apex of the tongue. It mingles with the fibers of the extrinsic muscles. The *lingualis* is supplied by the hypoglossal nerve. Its different portions have various complex movements.

#### MUSCLES OF THE PHARYNX AND SOFT PALATE

This group includes the superior, middle, and inferior constrictors of the pharynx, the *stylopharyngeus*, the *palatopharyngeus*, *palatoglossus*, *tensor palati*, *levator palati*, and *azygos uvulæ*.

The *constrictor muscles of the pharynx* are three practically continuous sheets of muscle placed one below the other. They arise from various bony and cartilaginous points in front of the pharynx, and are inserted posteriorly into a median raphé. The superior and middle constrictors receive their nerve supply from the pharyngeal plexus, and the inferior constrictor is supplied by

the pharyngeal plexus and the external laryngeal nerve. These muscles, by contracting one after the other from above downward, are the principal agents in the function of deglutition.

The *stylopharyngeus muscle* arises from the styloid process near its base, passes downward and inward between the superior and middle constrictors of the pharynx, and is inserted into the lateral walls of the pharynx and the posterior border of the thyroid cartilage. It is supplied by the glossopharyngeal nerve and assists in elevating the pharynx.

The *palatopharyngeus* muscle arises from the posterior portion of the soft palate, and is inserted into the lower part of the pharynx and the upper and posterior border of the thyroid cartilage. This muscle and its fellow of the opposite side form the posterior pillars of the fauces. The nerve-supply of this muscle is derived from the sphenopalatine or Meckel's ganglion. Its action is to elevate the pharynx in deglutition, to open the Eustachian tube, and to keep the soft palate in position during respiration.

The *palatoglossus* arises from the under surface of the soft palate near the base of the uvula, and is inserted into the side and base of the tongue. This muscle and its fellow of the opposite side form the anterior pillars of the fauces. Its nerve-supply is from the facial. The action of this muscle is to depress and draw slightly forward the palate and elevate and draw back the tongue.

The *tensor palati* muscle arises from the scaphoid fossa at the root of the pterygoid plates, the spinous process of the sphenoid bone, and the side of the Eus-

tachian tube. Its tendon passes around the hamular process of the sphenoid bone and is inserted into the aponeurosis of the soft palate and transverse ridge on the lower surface of the palate bone. The nerve-supply is derived from the otic ganglion. The muscle renders the palate tense and opens the Eustachian tube.

The *levator palati* muscle arises from the lower surface of the petrous portion of the temporal bone, and is inserted into the soft palate. Its nerve-supply is from the sphenopalatine ganglion. The action of the muscle is to raise the soft palate and to narrow the orifice of the Eustachian tube.

The *azygos uvulae* arises from the posterior spine of the palate bone, and is inserted into the uvula. It is supplied by the facial nerve. The action of the muscle is to contract the uvula.

#### MUSCLES OF MASTICATION

The following are the muscles of mastication. Temporal, masseter, internal pterygoid, external pterygoid. The accessory muscles are buccinator, platysma myoides, digastric, mylohyoid, geniohyoid.

The *temporal* muscle arises from the temporal fossa and from the temporal fascia. It is inserted into the coronoid process of the mandible. It is supplied by a branch of the mandibular division of the trifacial nerve. The function of the temporal muscle is to pull the lower jaw upward and backward.

The *masseter* muscle consists of a superficial portion and a deep portion (Fig. 15). The superficial portion arises from the anterior two-thirds of the lower border of the zygoma. It is inserted into the lower part of the

outer side of the ramus of the mandible. The deep portion arises from the posterior third of the lower border of the zygoma, and from its entire inner surface. It is inserted into the upper portion of the outer side of the ramus of the lower jaw. The nerve-supply of the masseter muscle is derived from the mandibular division of the trifacial. The superficial portion of the

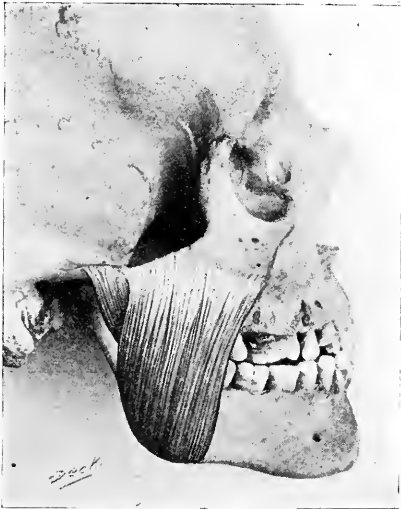

Fig. 15.—Masseter muscle (Campbell).

masseter draws the lower jaw forward and upward. The deep portion draws it backward and upward.

The *internal pterygoid* muscle (Fig. 16) arises from the inner surface of the external pterygoid plate and pterygoid fossa of the sphenoid bone, and from the tuberosities of the palate and maxillary bones. It is inserted into the inner side of the ramus and angle of the mandible.



The nerve-supply of the internal pterygoid is derived from the mandibular division of the trifacial. This muscle elevates the lower jaw.

The *external pterygoid* muscle arises by two heads, one from the outer surface of the external pterygoid plate of the sphenoid and the other from the zygomatic surface of the greater wing of the sphenoid. It is

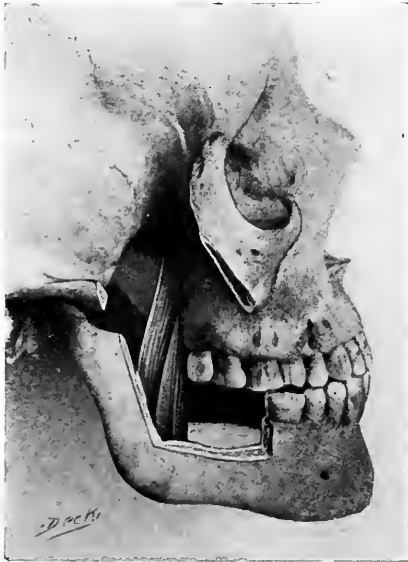


Fig. 16.—Internal pterygoid muscle (Campbell).

inserted into the anterior part of the neck of the condyle of the mandible, and into the interarticular fibrocartilage of the temporomandibular joint. The nerve-supply to this muscle is derived from the mandibular division of the trifacial. The two external pterygoid muscles acting together draw the lower jaw forward. When the mandible is depressed to a certain extent,

it is further depressed by the action of these muscles. Acting separately, the external pterygoids draw the mandible to one side or the other. The slip to the inter-articular fibrocartilage pulls the latter forward on to the eminentia articularis when the condyle moves forward.

The *buccinator* muscle arises from the posterior part of the alveolar processes of the maxilla and mandible, and from the pterygomaxillary ligament. It is inserted into the orbicularis oris muscle, and blends with the other muscles of expression of the face. It is supplied by a branch of the mandibular division of the trifacial nerve, and also by the facial nerve. This muscle compresses the cheek, and assists in keeping the food between the teeth.

The *platysma myoides* is a broad, thin sheet of muscle arising from the clavicle, the acromion, and the superficial fascia of the neck. It runs upward within the meshes of the superficial fascia, and is inserted into the lower border of the mandible, where it blends with the superficial muscles of the face. It is supplied by the facial and superficial cervical nerves. The platysma helps to depress the lower jaw and open the mouth.

The *digastric* is a bi-bellied muscle, which arises from the digastric groove on the mastoid process of the temporal bone, and from the lower border of the mandible near the symphysis. The two heads converge into a tendon, which is attached to the hyoid bone by a fibrous loop from the stylohyoid muscle. The posterior belly of the digastric is supplied by the facial nerve, and the anterior belly by the mylohyoid branch of the trifacial. The digastric muscle aids in depressing the lower jaw.

The *mylohyoid* muscle, with its fellow of the opposite

side, forms the muscular floor of the mouth. It arises from the mylohyoid ridge on the inner surface of the body of the mandible, passes downward and inward to be inserted into the body of the hyoid bone, and into a median raphé in the floor of the mouth. It is supplied by the mylohyoid nerve, a branch of the mandibular division of the trifacial. This muscle slightly assists in depressing the mandible.

The *geniohyoid* muscle arises from the inferior genial tubercle of the mandible, and is inserted into the anterior portion of the hyoid bone. Its nerve-supply is from the hypoglossal. It aids in depressing the lower jaw.

#### MUSCLES OF EXPRESSION ABOUT THE MOUTH

The muscles of expression of the face (Fig. 17) differ from other voluntary muscle in that none of them have bony insertions, and some of them have no bony origin. The oral group consists of the orbicularis oris and those muscles that are inserted into it.

The *orbicularis oris* forms the sphincter of the mouth. It is elliptic, and its fibers interlace with those of the other muscles of expression. The remaining muscles are inserted into the orbicularis oris, and are as follows, beginning at the median line above:

*Levator labii superioris alæque nasi*, arises from the upper and outer part of the nasal process of the maxilla.

*Levator labii superioris*, arises from the maxilla immediately below the orbit.

The *depressor labii superioris* arises from the incisor fossa of the maxilla.

The *zygomaticus minor* arises from the lower surface of the malar bone.

The *zygomaticus major* is just behind the zygomaticus minor, arising from the lower edge of the malar bone, near the zygomatic suture.

The *levator anguli oris* arises from the canine fossa, immediately below the infra-orbital foramen.

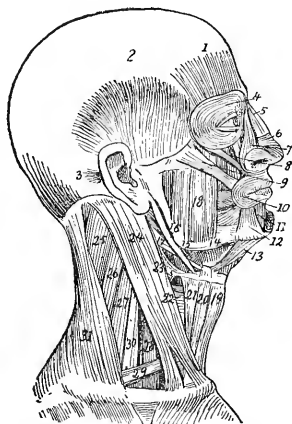


Fig. 17.—Muscles of the right side of the head and neck (*American Illustrated Medical Dictionary*): 1. Frontalis; 2, superior auricular; 3, posterior auricular; 4, orbicularis palpebrarum; 5, pyramidalis nasi; 6, compressor naris; 7, levator labii superioris alæque nasi; 8, levator labii superioris; 9, zygomaticus major; 10, orbicularis oris; 11, depressor labii inferioris; 12, depressor anguli oris; 13, anterior belly of digastric; 14, mylohyoid; 15, hyoglossus; 16, stylohyoid; 17, posterior belly of digastric; 18, the masseter; 19, sternohyoid; 20, anterior belly of omohyoid; 21, thyrohyoid; 22, 23, lower and middle constrictors of pharynx; 24, sternomastoid; 25, 26, splenius; 27, levator scapulæ; 28, anterior scalenus; 29, posterior belly of omohyoid; 30, middle and posterior scalenus; 31, trapezius.

The *risorius* muscle arises from the deep fascia covering the masseter muscle. It is not always present.

The *depressor anguli oris* (*triangularis menti*) arises from the external oblique line of the mandible.

The *depressor labii inferioris* (*quadratus menti*) arises

from the mandible along the line extending from the symphysis to the mental foramen.

The *levator labii inferioris* arises from the upper portion of the incisor fossa of the mandible.

The action of the foregoing muscles is indicated by their names.

The nerve-supply is through branches of the facial.

#### MUSCLES ATTACHED TO THE MANDIBLE (Fig. 2)

##### To the inner surface of the body:

*Geniohyoglossus*, to the superior genial tubercle.

*Geniohyoid*, to the inferior genial tubercle.

*Digastric*, to the digastric fossa.

*Mylohyoid*, to the mylohyoid ridge or internal oblique line.

*Superior constrictor of pharynx*, just behind the third molar tooth.

##### Outer surface of the body of the mandible:

*Platysma myoides*, *depressor anguli oris*, and *depressor labii inferioris*, to external oblique line.

*Levator labii inferioris*, to incisor fossa.

*Levator menti*, to symphysis.

*Buccinator*, to outer surface of alveolar process of molar teeth.

##### Inner surface of ramus:

*Internal pterygoid*.

##### Outer surface of ramus:

*Masseter*.

*Coronoid process: Temporal.*

*Neck of condyle: External pterygoid.*

## REVIEW QUESTIONS

Describe the cervical fasciæ.

Give the boundaries and coverings of the surgical square of the neck.

Name the triangles of the neck, giving their boundaries and the most important structures found in each.

Which triangle is the most important to the oral surgeon, and why?

Give the position of the tongue, and name its extrinsic and intrinsic muscles.

Name the muscles of the soft palate, giving origin, insertion, and nerve-supply.

Name the muscles of mastication.

Name the accessory muscles of mastication.

Give the origin, insertion, nerve-supply, and function of the temporal, masseter, internal pterygoid, and external pterygoid muscles.

Name the muscles inserted into the sphincter of the mouth. Give their function and nerve-supply.

Name and locate the muscles attached to the mandible.

## CHAPTER IV

### BLOOD-VESSELS

THE blood-supply of the head (Fig. 18) is carried mainly by the common carotid and vertebral arteries.

The right common carotid artery is a branch of the innominate artery. The left common carotid comes directly from the arch of the aorta. Apart from this, the arteries of the two sides are similar.

The *surgical line* of the common carotid artery extends from the sternoclavicular articulation to a point midway between the angle of the mandible and the mastoid process of the temporal bone. While this is the direction of the artery in the neck, its upper termination is at the level of the upper edge of the thyroid cartilage. The common carotid artery lies in the carotid sheath, a process of the cervical fascia (p. 48) which also incloses the internal jugular vein and the pneumogastric nerve. The vein lies external to the artery, while the nerve is between and behind the two. The descends hypoglossi nerve, a branch of the hypoglossal, passes down the neck on the front of the carotid sheath. The structures within the carotid sheath lie just beneath the inner edge of the sternocleidomastoid muscle.

At the level of the upper edge of the thyroid cartilage, in the superior carotid triangle, the common carotid bifurcates into the internal and external carotid arteries.

The **internal carotid artery** (Fig. 19) passes upward

to the carotid canal in the petrous portion of the temporal bone. It is divided into four portions—cervical, petrous, cavernous, and intracranial.

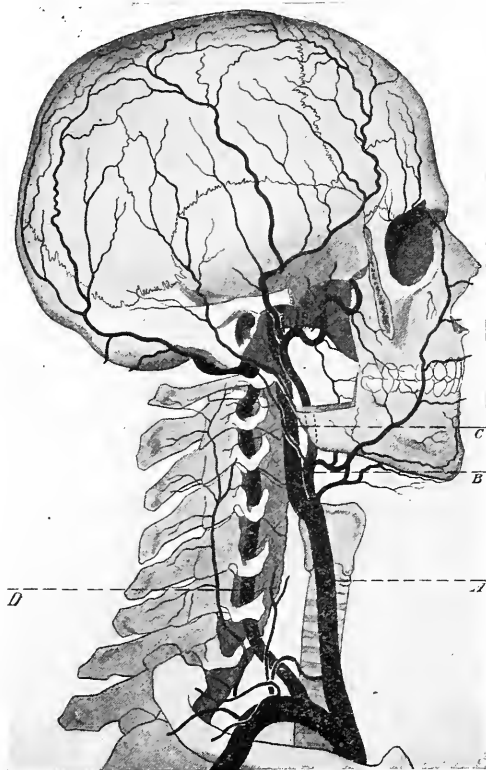


Fig. 18.—The chief arteries of the neck: *A*, Common carotid; *B*, external carotid; *C*, internal carotid; *D*, vertebral (Deaver, modified).

The *cervical* portion is at first more superficial than, and to the outer side of, the external carotid artery. It then passes more deeply, in relation with the superior



constrictor of the pharynx, which separates it from the tonsil, and the transverse processes of the three upper cervical vertebræ. The artery is inclosed in a sheath in company with the internal jugular vein and the pneumogastric nerve.



Fig. 19.—The carotid region and the chief structures (Campbell). Note the relation of the internal jugular vein, the common carotid artery, and the pneumogastric nerve.

The *petrous* portion of the internal carotid is inclosed in the carotid canal in the petrous portion of the temporal bone.

The *cavernous* portion is inclosed by the cavernous sinus, and begins just above the middle lacerated foramen within the brain case.

The *intracranial* portion begins at a point where the artery passes through the upper wall of the cavernous sinus, and gives off the terminal branches.

The cervical portion of the internal carotid artery seldom gives off any branches.

The petrous portion gives off the tympanic branch.

The branches of the cavernous portion are: Meningeal, pituitary, and cavernous.

The branches of the intracranial portion are: Ophthalmic, anterior cerebral, middle cerebral.

The *ophthalmic* artery is the largest branch of the internal carotid. It passes through the optic foramen, and gives off the lacrimal, supra-orbital, central retinal, ciliary, posterior and anterior ethmoid, muscular, palpebral, frontal, and external nasal branches.

The anterior and middle cerebral arteries assist in the formation of the circle of Willis.

#### BRANCHES OF INTERNAL CAROTID ARTERY.

Internal carotid.	Cervical portion. Petrous portion.	Cavernous portion.	Intracranial portion.	None.	
				Tympanic.	
			Meningeal. Pituitary. Cavernous.		
			Ophthalmic.	Lacrimal. Supra-orbital. Central retinal. Ciliary. Posterior ethmoid. Anterior ethmoid. Muscular. Palpebral. Frontal. External nasal.	Anterior cerebral. Middle cerebral.

**The External Carotid Artery.**—The external carotid artery (Fig. 18) is given off from the common carotid in the superior carotid triangle. It passes up the neck to a point opposite the neck of the condyle of the mandible, where it gives off its terminal branches in the substance of the parotid gland.

Most of the branches of the external carotid artery are given off in the superior carotid triangle.

The branches are:

*Ascending pharyngeal*, to the upper part of the pharynx.

*Superior thyroid*, to the thyroid gland, larynx, and various muscles.

*Lingual*, to the tongue.

*Facial*.—This branch runs upward and inward to the angle of the lower jaw, passes over the facial notch in the lower border of the mandible near the angle, thence to the angle of the mouth, the ala of the nose, and the inner canthus of the eye.

The *occipital* artery passes backward and upward and supplies the structures in the region of the occiput.

The *posterior auricular* artery passes upward and backward to supply the region behind the ear.

The *superficial temporal* artery is one of the terminal branches of the external carotid, and is given off in the substance of the parotid gland. It passes upward in front of the ear, accompanied by the auriculotemporal nerve, and is distributed to the temporal region of the scalp.

The *internal maxillary* artery (Fig. 18) is the other terminal branch of the external carotid, and is given off in the substance of the parotid gland. It winds

around the inner side of the neck of the condyle of the mandible, between it and the internal lateral ligament, passes between the two heads of the external pterygoid muscle, and enters the sphenomaxillary fossa, where it breaks up into its terminal branches. The artery may be divided into three portions: (1) The maxillary division, extending from the external carotid to the internal lateral ligament. (2) Pterygoid division, between the two heads of the external pterygoid muscle. (3) Sphenomaxillary division, in the sphenomaxillary fossa.

The branches of the lingual artery are: hyoid, dorsalis linguæ, sublingual, and ranine.

The branches of the facial artery are: (a) On the neck: Ascending palatine, tonsillar, submaxillary, submental. (b) On the face: Inferior labial, inferior coronary, superior coronary, lateralis nasi, angular.

The branches of the internal maxillary artery are as follows: (a) Maxillary portion: Tympanic, middle meningeal, small meningeal, and inferior dental. (b) Pterygoid portion: Deep temporal, pterygoid, masseteric, and buccal. (c) Sphenomaxillary portion: Alveolar to the upper teeth, infra-orbital, descending palatine, vidian, pterygopalatine, and nasopalatine.

The **vertebral arteries** are given off from the subclavian arteries, and pass upward one on either side of the neck, through the foramina in the transverse processes of the cervical vertebræ, entering the skull through the foramen magnum. The arteries of the two sides join at the posterior inferior extremity of the pons Varolii to form the basilar.

The *basilar* artery at the anterior extremity of the pons divides into the posterior cerebral arteries. These

anastomose with the anterior cerebral branches of the internal carotid arteries through the posterior communicating arteries. The *circle of Willis* is completed

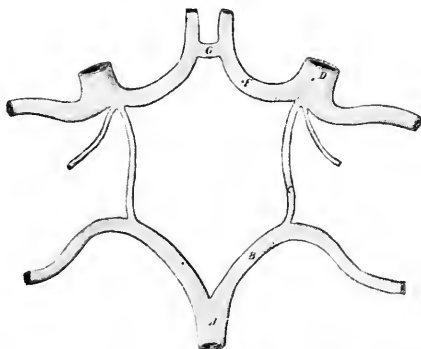


Fig. 20.—Diagram of the circle of Willis: *A*, Basilar artery; *B*, posterior cerebral; *C*, posterior communicating; *D*, internal carotid; *E*, anterior cerebral; *F*, anterior communicating (Campbell).

in front by the anterior communicating artery, which joins the two anterior cerebral arteries (Fig. 20).

#### VEINS OF THE HEAD

The veins of the head may be divided into external and intracranial.

Practically all the venous blood from the head is conveyed by the internal and external jugular veins.

The following table gives the principal veins of the head and their tributaries:

## EXTERNAL VEINS.

Temporal.	} Temporomaxillary.	} External jugular. Subclavian.	
Internal maxillary.			Posterior auricular.
Facial.	} Common facial.	} Internal jugular.	
Anterior division of temporomaxillary.			Lingual.
			Pharyngeal.
			Superior thyroid.
			Middle thyroid.
			Occipital.

The **internal jugular** vein is formed by the union of the lateral and inferior petrosal sinuses at the posterior lacerated or jugular foramen. These sinuses and their tributaries convey venous blood from the structures of the interior of the skull, including the brain and its membranes, orbit, etc.

Venous blood is conveyed from the upper teeth by the alveolar vein into the internal maxillary vein; that from the lower teeth is carried by the inferior dental vein to the internal maxillary vein.

The course of blood from the heart to the right upper teeth and back again to the heart is as follows: Aorta, innominate, right common carotid, external carotid, internal maxillary, and alveolar arteries; alveolar, internal maxillary, temporomaxillary, external jugular, subclavian, and innominate veins, superior vena cava, to heart. In supplying the teeth of the left side the course of blood is the same, except that it passes directly from the aorta into the left common carotid artery, instead of first traversing the innominate. The lower teeth receive blood from the inferior dental instead of the alveolar branch of the internal maxillary.

By *anastomosis* is meant the free communication of blood-vessels. Practically all blood-vessels anastomose with adjacent trunks. The best example of an anastomosis is the circle of Willis at the base of the brain (p. 69), where branches of the internal carotid and vertebral arteries of the two sides communicate to form a complete circle.

A *collateral circulation* is an accessory source of blood-supply to a part by anastomosis of vessels, whereby nutrition is maintained after the main source of blood-supply is cut off. A good example of this in the neck is seen in the anastomosis of the princeps cervicis branch of the occipital with the profunda cervicis branch of the superior intercostal, which comes from the subclavian, so that if the blood-supply to the occipital region through the external carotid artery be cut off from any cause, blood would still be carried to the part by the branch of the subclavian.

### REVIEW QUESTIONS

Give the surgical line of the common carotid artery.

Name and give the relations of the structures within the carotid sheath.

Give the point of bifurcation of the common carotid artery and its branches.

Give the course and branches of the internal carotid artery.

Give the course and branches of the external carotid artery.

Give the course and branches of the facial artery.

Give the course and branches of the internal maxillary artery.

Describe the circle of Willis.

Give a general outline of the veins of the face and neck.

What is meant by anastomosis of blood-vessels.

What is meant by collateral circulation? Give examples.

## CHAPTER V

### LYMPHATICS

THE lymphatic glands of the face are as follows: (*a*) Parotid, of which there are two groups, one placed on the surface of the parotid salivary gland, and the other more deeply in the substance of the gland. (*b*) Zygomatic, beneath the zygoma. (*c*) Buccal, on the surface of the buccinator muscle. (*d*) Internal maxillary, on the inner side of the ramus of the mandible.

The lymphatic glands of the neck are superficial and deep. The superficial groups are: (*a*) Submaxillary, beneath the body of the mandible, in the submaxillary triangle. (*b*) Suprahyoid, in the median line of the neck. (*c*) Cervical, along the course of the external jugular vein.

The deep cervical glands are found along the course of the internal jugular vein, and are divided into an upper and a lower group. Practically all the lymphatics of the head drain into the deep cervical glands, which communicate below with the mediastinal glands.

The following table gives the various structures of the face and neck, and the lymphatic glands connected with them (Treves):

Skin of face and neck.....	Submaxillary, parotid, and superficial cervical glands.
External ear.....	Superficial cervical glands.
Lower lip.....	Submaxillary and suprahyoid glands.



Buccal cavity.....	Submaxillary and upper set of deep cervical glands.
Lower jaw.....	Submaxillary glands.
Anterior portion of tongue.....	Suprahyoid and submaxillary glands.
Posterior portion of tongue.....	Upper set of deep cervical glands.
Tonsils and palate.....	Upper set of deep cervical glands.
Upper part of pharynx.....	Parotid and retropharyngeal glands.
Lower part of pharynx.....	Upper set of deep cervical glands.
Larynx, orbit, roof of mouth....	Upper set of deep cervical glands.
Nasal fossæ.....	Retropharyngeal and upper set of deep cervical glands.

## CHAPTER VI

### THE CRANIAL NERVES

THE cranial nerves, with their foramina of exit from the brain-case, principal distribution, and function, are as follows:

NAME.	FORAMEN.	DISTRIBUTION.	FUNCTION.
First: olfactory.	Olfactory	Nose.	Smell.
Second: optic.	Optic.	Eye.	Sight.
Third: oculo-motor.	Sphenoid fissure.	Orbit.	Motor to muscles of eyeball.
Fourth: trochlear.	Sphenoid fissure.	Superior oblique muscle of eyeball.	Motor.
Fifth: trifacial.	(a) Sphenoid fissure.	Ophthalmic.	Sensory.
	(b) Rotundum.	Maxillary.	Sensory.
	(c) Ovale.	Mandibular.	Sensory. Motor to muscles of mastication.
Sixth: abducens.	Sphenoid fissure.	External rectus muscle.	Motor.
Seventh: facial.	Stylomastoid.	Facial muscles.	Motor.
Eighth: auditory.	Internal auditory meatus.	Internal ear.	Audition and equilibration.
Ninth: glossopharyngeal.	Jugular.	Tongue, pharynx, middle ear. Stylopharyngeus.	Sensory. Taste. Motor.
Tenth: pneumogastric.	Jugular.	Alimentary, respiratory, and circulatory systems.	Sensory and motor.

NAME.	FORAMEN.	DISTRIBUTION.	FUNCTION.
Eleventh: spinal accessory.	Jugular.	Sternomastoid and trapezius muscles.	Motor.
Twelfth: hypoglossal.	Anterior condyloid.	Tongue and muscles of hyoid bone.	Motor.

### THE FIFTH NERVE

The fifth or trifacial nerve (Fig. 21) is the great sensory nerve of the face and head. It also supplies motor fibers to the muscles of mastication. The deep

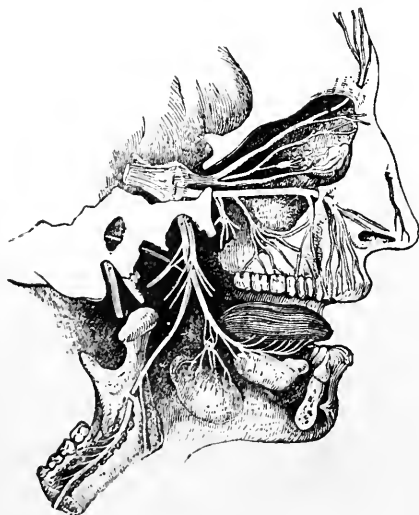

Fig. 21.—The distribution of the three divisions of the fifth nerve (Leidy).

origin of the trifacial nerve is from a sensory nucleus and a motor nucleus in the floor of the fourth ventricle.

The superficial origin is from the side of the pons Varolii, where the nerve emerges as an anterior motor and a posterior sensory root. The sensory root termin-

ates in the Gasserian ganglion, situated at the apex of the petrous portion of the temporal bone, within the brain-case. The motor root passes out through the foramen ovale and joins the sensory portion of the mandibular division immediately outside this foramen.

The *Gasserian* or *semilunar ganglion* is a crescent-shaped structure, with its convexity directed forward, situated in a depression at the apex of the petrous portion of the temporal bone. The ganglion is joined posteriorly by the sensory root of the trifacial nerve. The motor root of this nerve does not enter the ganglion, but passes around it and joins the inferior division from the ganglion outside the foramen ovale to form the mandibular nerve.

The branches of the Gasserian ganglion, three in number, are given off from its anterior portion, and are as follows:

First, or ophthalmic division.

Second, or maxillary division.

Third division, which unites with the motor root to form the mandibular nerve.

The *ophthalmic division* passes forward along the outer wall of the cavernous sinus, passes through the sphenoid fissure, and breaks up into three branches, frontal, lacrimal, and nasal.

The *frontal* nerve passes forward in the orbit, and divides into two branches, the supra-orbital and the supratrochlear. The *supra-orbital* nerve passes through the supra-orbital foramen, and supplies the skin of the forehead. The *supratrochlear* nerve leaves the orbit near its inner angle and supplies the skin of that region.

The *lacrimal* nerve passes forward in the orbit, and

breaks up into branches which supply the lacrimal gland, the conjunctiva, and the upper eyelid.

The *nasal* nerve passes obliquely forward from the sphenoid fissure, between the two heads of the external rectus muscle, to the anterior ethmoid foramen. It divides here into the internal nasal and the infratrochlear nerves.

The branches of the nasal nerve are: Branch to dura mater, branch to ophthalmic ganglion, long ciliary, posterior ethmoid, infratrochlear, internal nasal, and external branches, which are septal, lateral, and anterior.

The internal nasal nerve passes through the anterior ethmoid foramen into the brain-case beside the cribriform plate. It then enters the nasal slit beside the crista galli, passes into the nasal chamber, and breaks up into the terminal branches, septal, lateral, and anterior.

**The Maxillary Division.**—The maxillary division passes forward from the Gasserian ganglion, and leaves the cranium through the foramen rotundum. It crosses the sphenomaxillary fossa, and enters the orbit through the sphenomaxillary fissure. The nerve then becomes the infra-orbital, enters the infra-orbital canal in the floor of the orbit, and runs forward to open on the face at the infra-orbital foramen, where it breaks up into its terminal filaments. The branches of the maxillary nerve are: Meningeal, orbital or temporomalar, sphenopalatine, superior dental, and infra-orbital.

The *meningeal* branch is given off within the cranium and passes to the dura mater.

The *orbital*, or *temporomalar* branch, is given off in the sphenomaxillary fossa. It enters the orbit through the sphenomaxillary fissure, and divides into two branches, the temporal and the malar. The temporal

branch, after giving off a filament which communicates with the lacrimal nerve, passes into the temporal fossa through the sphenomalar canal. It pierces the temporal muscle, and is distributed to the skin of the region. The malar branch passes through the malar canal to supply the skin over the malar bone.

The *sphenopalatine* branches, two in number, are given off in the sphenomaxillary fossa, and pass to Meckel's ganglion, forming its sensory roots.

The *superior dental* branch is given off in the sphenomaxillary fossa, and passes through the posterior dental canals to supply the upper molar and premolar teeth and the gums.

The *infra-orbital* nerve is the terminal branch of the maxillary division of the trifacial. It lies in the infra-orbital canal, and opens on the face at the infra-orbital foramen, where it breaks up into its terminal branches. This nerve sends a branch down in the anterior wall of the maxillary sinus, which supplies sensation to the canine and incisor teeth of the upper jaw and the muco-periosteum of the maxillary sinus.

**The Mandibular Division.**—The third or mandibular division of the trifacial is its largest branch. It is formed by the junction of the third portion of the sensory root from the Gasserian ganglion with the motor root. The two leave the cranium separately through the foramen ovale, and unite immediately afterward to form one trunk. About a quarter of an inch lower down, behind the external pterygoid muscle, the trunk branches into a smaller anterior and a larger posterior division. The branches of the mandibular nerve may be divided into three groups, as follows:

(a) *From the main trunk:* Recurrent branch, and nerve to the internal pterygoid muscle.

The *recurrent* branch enters the cranium through the foramen spinosum, and is distributed to the mastoid cells and the petrous portion of the temporal bone.

The *nerve to the internal pterygoid* is the motor nerve to the muscle named. It also contains sensory fibers which pass to the otic ganglion.

(b) *Branches from the anterior division:* Deep temporal, masseteric, external pterygoid, buccal. These branches supply motor fibers to the muscles named.

(c) *Branches from the posterior division:* Auriculotemporal, lingual, and inferior dental.

The *auriculotemporal* nerve passes up with the superficial temporal artery to supply the skin of the auricle and the temple.

The *lingual* nerve runs downward and forward on the internal pterygoid muscle to the inner side of the lower jaw, near the last molar tooth, where it lies just under the mucous membrane. It then runs forward to the tip of the tongue. The lingual nerve is joined behind the ramus of the jaw by the chorda tympani nerve. The lingual nerve supplies common sensation to the tongue.

The *inferior dental* nerve passes downward and enters the cribriform tube of the mandible through the inferior dental (mandibular) foramen. It passes forward to the symphysis menti, and then recurs to open on the face as the mental nerve at the mental foramen.

The branches of the inferior dental nerve are: Mylohyoid, dental and gingival, and mental.

The *mylohyoid* nerve is given off just before the inferior dental nerve enters the mandibular canal. It

runs along the mylohyoid groove of the mandible with the mylohyoid vessels, and carries motor fibers to the mylohyoid muscle and the anterior belly of the digastric muscle.

The *dental and gingival* branches pass up the tubules coming off from the main tube of the mandible, to supply the teeth and gums.

The *mental* nerve is the terminal branch of the inferior dental. After emerging from the mental foramen, it breaks up into filaments which supply the skin of the chin and lower lip.

**Sympathetic ganglia** associated with the trifacial nerve.

These ganglia are four in number, and are as follows: Ophthalmic, sphenopalatine, otic, and submaxillary.

These ganglia supply sympathetic fibers to the various parts to which their branches are distributed, for example, motor fibers to the ciliary muscle, secretory to the submaxillary gland, etc.

The *ophthalmic*, ciliary, or lenticular ganglion is a small body, about the size of a pin-head, situated in the back of the orbit, between the optic nerve and the external rectus muscle. Its sensory root is derived from the nasal branch of the trifacial nerve. Its motor root is derived from the internal oblique branch of the oculomotor nerve. Its sympathetic root is derived from the cavernous plexus.

The branches of the ophthalmic ganglion are the short ciliary nerves, eight to ten in number, which pass to the ciliary muscle of the eyeball.

The *sphenopalatine*, or *Meckel's ganglion*, is situated in the sphenomaxillary fossa, near the maxillary division of the trifacial nerve. Its sensory roots are two in



number, and are the sphenopalatine branches of the maxillary nerve. The motor and sympathetic roots are combined as the Vidian nerve. This nerve is formed by the great superficial and great deep petrosal nerves.

The great superficial petrosal nerve is the motor root of Meckel's ganglion, and is derived from the facial nerve.<sup>7</sup> The great deep petrosal nerve is the sympathetic root, and is derived from the carotid plexus of the sympathetic.

The branches of Meckel's ganglion are—(a) Ascending, (b) internal, (c) descending, (d) posterior.

The *ascending* branches are small twigs to the periosteum of the orbit and the mucous membrane of the sphenoid and posterior ethmoid sinuses.

The *internal* or *anterior* branches supply the mucous membrane of the nose and roof of the mouth as the nasopalatine nerve, which passes through the anterior palatine canal and foramen of Scarpa.

The *descending* branches are the anterior, posterior, and external palatine nerves. The *anterior palatine* nerve descends through the posterior palatine canal, runs forward on the hard palate to supply the mucous membrane of the mouth, and communicates with the nasopalatine nerve. The *posterior palatine* nerve passes through one of the accessory palatine canals to the uvula, tonsil, and soft palate. The *external palatine* nerve passes through the other accessory palatine canal to supply the tonsil and soft palate.

The *posterior* branches of Meckel's ganglion pass to the nasopharynx.

The *otic* ganglion lies on the mandibular nerve just after it leaves the foramen ovale. Its motor and sensory roots reach it through the nerve to the internal

pterygoid muscle. Its sympathetic root is derived from the plexus around the middle meningeal artery. It sends branches to the parotid gland, motor twigs to the tensor palati and tensor tympani muscles, and a communicating branch to the chorda tympani nerve.

The *submaxillary* or *submandibular* ganglion lies on the submaxillary gland, and is connected with the mandibular division of the trifacial nerve. Its sensory root comes from the trifacial nerve through the lingual branch. Its motor root is derived from the facial through the chorda tympani. Its sympathetic root is derived from the plexus around the facial artery. This ganglion sends branches to the submaxillary gland, Wharton's duct, and the sublingual gland.

TABLE OF SYMPATHETIC GANGLIA, ASSOCIATED WITH FIFTH NERVE

Name.	Division.	Sensory root.	Motor root.	Sympathetic root.	Branches and distribution.
Ophthalmic.	Ophthalmic.	Nasal branch of trifacial.	Internal oblique branch of oculomotor.	Cavernous plexus.	Short ciliary nerves to ciliary muscle.
Sphenopalatine or Meckel's.	Maxillary.	Sphenopalatine branches of maxillary.	Great superficial petrosal branch of seventh, through Vidian.	Great deep petrosal from carotid plexus, through Vidian.	(a) Ascending, to orbit, sphenoid, and ethmoid sinuses. (b) Internal or anterior, to mucous membrane of nose and mouth, as nasopalatine. (c) Descending, as anterior, posterior, and external palatine nerves, to mucous membrane of palate and tonsils. (d) Posterior, to nasopharynx.
Otic.	Mandibular.	Internal pterygoid branch of trifacial.	Internal pterygoid branch of trifacial.	Plexus around middle meningeal artery.	Parotid gland, tensor tympani, and tensor palati muscles.
Submaxillary.	Mandibular.	Lingual branch of trifacial.	Facial through chorda tympani.	Plexus around facial artery.	Submaxillary gland, Wharton's duct, sublingual gland.

TABLE OF THE FIFTH NERVE AND ITS BRANCHES

<i>Ophthalmic.</i>	Frontal . . . . .	{	Supratrochlear.	
			Supra-orbital.	
	Lacrimal . . . . .	{	Superior branch.	
Inferior branch.				
Nasal . . . . .	{	Branch to dura mater.		
		Branch to ophthalmic ganglion.		
		Long ciliary.		
		Internal nasal..	{	Septal.
			{	Lateral.
		{	Anterior.	
<i>Maxillary..</i>	Temporomalar... {	Temporal.		
		Malar.		
	Sphenopalatine.			
	Superior dental.			
	Infra-orbital..... {	Palpebral.		
Nasal.				
Labial.				
<i>Mandibular.</i>	From main trunk. {	Recurrent.		
		Internal pterygoid.		
	Anterior division.. {	Deep temporal.		
		Masseteric.		
		External pterygoid.		
		Buccal.		
		Auriculotemporal.		
	Posterior division. {	Lingual.		
		Inferior dental. {	Mylohyoid.	
			{	Dental.
		{	Mental.	

THE SEVENTH NERVE

The seventh cranial or facial nerve (Fig. 22) is the motor nerve to the muscles of expression of the face, and also supplies the scalp, external ear, platysma myoides, buccinator, posterior belly of the digastric, and stylohyoid muscles.

The deep origin of the facial nerve is in the floor of the fourth ventricle. Its superficial origin is from the medulla, between the olivary and restiform bodies.

The facial nerve enters the internal auditory meatus in company with the auditory nerve. At the end of the

meatus it passes into a narrow bony canal, the aqueductus Fallopii. This canal has a tortuous course through the petrous portion of the temporal bone, and terminates at the stylomastoid foramen, where the facial nerve makes its exit from the skull. It breaks up into its terminal branches in the substance of the parotid gland.

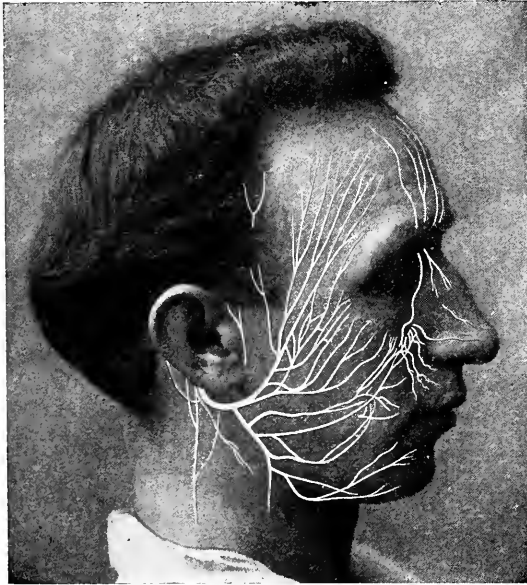


Fig. 22.—Branches of the facial nerve spread over the face like a fan (Campbell).

The branches of the facial nerve are divided into two groups: (a) *Before its exit from the stylomastoid foramen.* Nerve to stapedius muscle, chorda tympani, connecting branches with pneumogastric, branches to glosso-pharyngeal.

The *nerve to the stapedius* passes through a fine bony canal and supplies the muscle named.

The *chorda tympani* nerve passes in a bony canal through the petrous portion of the temporal bone, crosses the tympanic cavity, enters the canal of Huguier at the side of the Glaserian fissure, and unites with the lingual branch of the trifacial nerve, under the lower border of the internal pterygoid muscle. The *chorda tympani* probably originates from the glossopharyngeal, and carries fibers of the special sense of taste. The communicating branches pass to ganglia of the pneumogastric and glossopharyngeal nerves.

(b) *After the exit of the seventh nerve from the stylo-mastoid foramen:* Posterior auricular, stylohyoid, digastric, styloglossal, temporofacial, cervicofacial.

The *posterior auricular* nerve arises near the stylo-mastoid foramen. It passes backward and divides into auricular and occipital branches. The auricular branch supplies the *retrahens aurem*, and the occipital supplies the *occipitalis* muscle.

The *stylohyoid* nerve supplies the muscle named.

The *digastric* branch is distributed to the posterior belly of the digastric muscle.

The *styloglossal* branch supplies the styloglossus and stylopharyngeus muscles.

The *temporofacial* division passes upward and forward in the substance of the parotid gland and breaks up into three branches: (a) *Temporal*, to the muscles of the temple and side of the forehead. (b) *Malar*, to orbicularis palpebrarum and corrugator supercilii. (c) *Infra-orbital*, to the muscles connected with the upper lip.

The *cervicofacial division* passes downward and forward in the substance of the parotid gland, and breaks up into the following branches: (a) *Buccal*, to the buccinator

and orbicularis oris muscles. (b) *Supramaxillary*, to the muscles of the lower lip and chin. (c) *Inframaxillary*, to the platysma myoides.

The *geniculate ganglion* is situated on a bend of the facial nerve in the aqueductus Fallopii. Its branches are as follows:

- (a) Great superficial petrosal nerve.
- (b) Small superficial petrosal nerve.
- (c) Branches to the sympathetic system.
- (d) Branches to the tympanic plexus.
- (e) Branches to the pneumogastric nerve.
- (f) Branches to the glossopharyngeal nerve.

The *great superficial petrosal* nerve passes through the hiatus Fallopii on the anterior surface of the petrous portion of the temporal bone, then inward beneath the Gasserian ganglion to the middle lacerated foramen. Here it joins the great deep petrosal nerve, and with it passes through the Vidian canal in the sphenoid bone as the Vidian nerve, and enters Meckel's ganglion as its motor root.

The *small superficial petrosal* nerve joins the otic ganglion as its motor root.

The *branches to the sympathetic system* pass to the plexus around the middle meningeal artery and tympanic plexus.

It is generally taught that the facial is purely a motor nerve. Studies of cases in which the Gasserian ganglion had been removed or the function of the fifth nerve otherwise completely destroyed, tend to show that sensibility to deep pressure over the facial muscles in these cases is still present to a certain extent. From this it may be assumed that the facial nerve contains fibers of deep sensibility from the muscles supplied by it.

## TABLE OF THE SEVENTH NERVE AND ITS BRANCHES.

Before exit from stylomastoid foramen.....	{	Stapedius.	{	Auricular.
		Chorda tympani.		
		Branch to pneumogastric.		
		Branch to glossopharyngeal.		
After exit from stylomastoid foramen.	{	Posterior auricular.*	{	Occipital.
		Stylohyoid.		
		Digastric.	{	Temporal.
		Styloglossal.		Malar.
		Temporofacial.		Infra-orbital.
		Cervicofacial.	{	Buccal.
				Supramaxillary.
				Inframaxillary.

## REVIEW QUESTIONS

Name the cranial nerves in their regular order, giving their foramina of exit from the brain-case, distribution, and function.

Give the deep and superficial origins of the fifth nerve.

Give the name, position, and branches of the sensory ganglion of the fifth nerve.

Give the course of the motor root of the trifacial nerve.

Name the three divisions of the trifacial nerve, giving their foramina of exit from the skull.

Give the branches of the ophthalmic division of the trifacial nerve.

Give the branches of the maxillary division of the trifacial nerve.

Give the branches of the mandibular division of the trifacial nerve.

What sympathetic ganglia are connected with the fifth nerve? Give their positions, roots, and branches.

What are the functions of the fifth nerve?

Give the deep and superficial origins of the seventh nerve.

Give the course of the seventh nerve from its superficial origin to its terminal branches.

Give the branches of the facial nerve.

Give the name, position, and branches of the ganglion associated with the seventh nerve.

What are the functions of the seventh nerve?

## CHAPTER VII

### GLANDS

THE special mucous and salivary glands associated with the oral cavity are the parotid, submaxillary, sublingual, labial, buccal, lingual, and palatal glands.

#### PAROTID GLAND

The parotid gland (Fig. 23) is the largest of the salivary glands, its weight averaging one ounce. It is




Fig. 23.—The parotid gland (Campbell).

a compound racemose, salivary gland, its principal secretion being ptyalin, an amylolytic ferment.



The parotid gland is situated in the parotid space. This triangular space is bounded in front by the ramus of the mandible; behind, by the mastoid and styloid processes and the tympanic portion of the temporal bone; and below, by a line drawn from the angle of the mandible to the tip of the mastoid process. The gland does not exactly conform to the confines of this space, but overlaps its boundaries. The deep portion of the gland passes inward and comes into relation with the vertebræ and base of the skull. The upper portion passes into the posterior part of the glenoid fossa. The anterior portion overlaps the masseter muscle. The accessory parotid or *socia parotidis*, when present, lies on the masseter muscle below the zygomatic arch. The parotid gland is invested by processes of the deep cervical fascia.

The duct of the parotid gland, or *Stenson's duct*, is about two and a half inches long, and varies in diameter, its orifice being its narrowest part, only permitting the entrance of a small probe. The duct runs forward across the face from the anterior border of the parotid gland, about a finger's breadth below the zygoma, over the masseter muscle, curves inward to pierce the buccinator muscle, and opens in the vestibule of the mouth in a papilla opposite the upper second molar tooth.

The blood-supply of the parotid gland is derived from the external carotid, internal maxillary, superficial temporal, transverse facial, and posterior auricular arteries. The veins follow a similar course to the arteries.

The nerves are derived from the facial, auriculo-temporal, great auricular, and the sympathetic plexus of the external carotid artery.

The external carotid artery and its terminal branches and the facial nerve pass through the substance of the parotid gland.

The parotid lymphatic glands lie upon it and within its substance.

#### THE SUBMAXILLARY GLAND

The submaxillary gland is a compound racemose gland and secretes a mucosalivary fluid. It is, therefore, a mixed gland. It is smaller than the parotid gland, being about the size of a hazel-nut. The submaxillary gland is situated in the submaxillary fossa, on the inner side of the body of the mandible. Above and in front of the gland is the mylohyoid muscle, which separates it from the sublingual gland. Behind, the submaxillary gland is separated from the parotid gland by the stylomandibular ligament. In relation to the neck the submaxillary gland lies in the submaxillary triangle, and is covered by the skin, superficial fascia, platysma myoides, which lies in the superficial fascia, and the deep fascia.

The outlet of the submaxillary gland is known as the *duct of Wharton*. This runs backward under the mylohyoid muscle, around the posterior edge of the muscle, and over its upper surface, to open through the floor of the mouth in a papilla at the base of the tongue.

The blood-supply to the submaxillary gland is derived from the submaxillary branch of the facial artery. Its nerve-supply is from the submaxillary ganglion.

## THE SUBLINGUAL GLAND

The sublingual gland is smaller than the submaxillary gland. It is a compound racemose gland and secretes mucus only. The sublingual gland is situated in the sublingual fossa of the inner surface of the body of the mandible, immediately beneath the mucous membrane of the mouth. Below it is the mylohyoid muscle. The gland consists of several small lobes, which open into the floor of the mouth by separate small ducts, *the ducts of Rivinus*, eight to twenty in number. A larger duct, the *duct of Bartholin*, runs from the posterior lobules and empties into Wharton's duct.

The labial, buccal, lingual, and palatal glands are small racemose or compound tubular glands, situated in the mucous membrane covering the lips, cheeks, tongue, and hard and soft palate, which secrete mucus.

## REVIEW QUESTIONS

Name the mucous and salivary glands which empty into the oral cavity.

Describe the parotid gland, giving its position, relations, duct, and function.

Describe the submaxillary gland, giving its position, relations, duct, and function.

Describe the sublingual gland, giving its position, relations, duct, and function.

What is the function of the lingual, labial, buccal, and palatal glands?

## CHAPTER VIII

### THE TONSILS AND THE MOUTH

#### THE TONSILS

THE tonsils (Fig. 24) are two oval masses of lymphoid tissue, situated one on either side of the tonsillar space. This space is found between the anterior and pos-

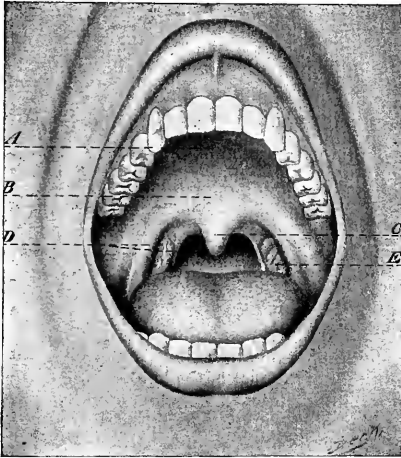


Fig. 24.—Surface markings shown within the mouth: *A*, Hard palate; *B*, soft palate; *C*, uvula; *D*, pillars of fauces; *E*, tonsils (Campbell).

terior pillars of the fauces. The anterior pillars of the fauces are formed by the palatoglossus muscles and the posterior pillars by the palatopharyngeus muscles (Fig. 25). Externally, the tonsil is in relation

with the superior constrictor muscle of the pharynx, which separates it from the internal carotid artery. This artery has been wounded in operations on the tonsil.

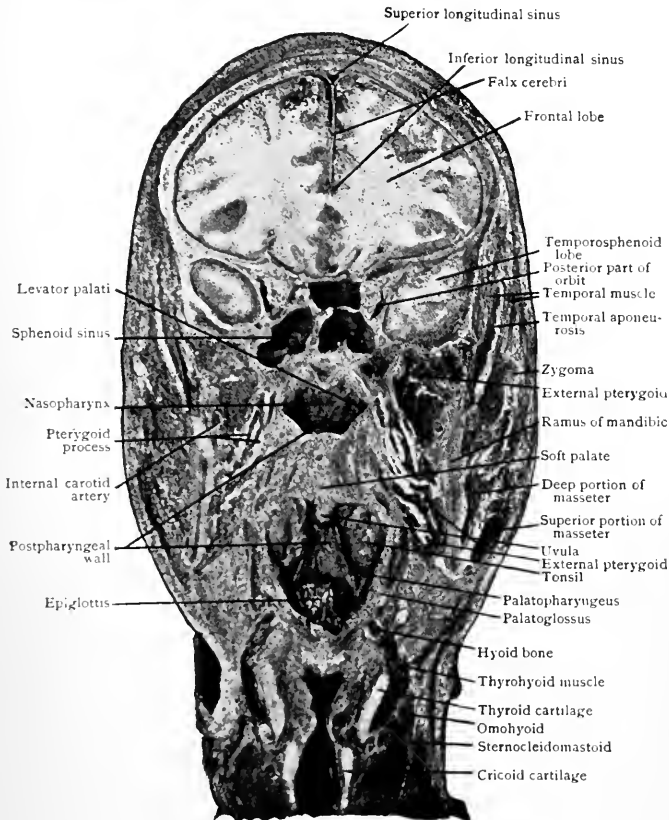


Fig. 25.—Vertical transverse section of a frozen head (after Cryer).

The ascending pharyngeal artery is more likely to be injected, but is a much smaller vessel, and is not likely to give rise to serious hemorrhage if divided. The tonsil is

composed of lymphoid tissue arranged in follicles. It is covered with stratified squamous epithelium. On the proximal surface of the tonsil are several depressions or crypts, lined with squamous epithelium, into which open a number of mucous glands. These crypts sometimes become clogged by secretion, giving rise to inflammation of the tonsil.

The blood-supply of the tonsils is derived from the tonsillar and ascending palatine branches of the facial artery, the descending palatine branch of the internal maxillary artery, and the ascending pharyngeal artery.

The functions of the tonsils are obscure. The fact that they atrophy about puberty unless diseased shows some connection with the growth of the individual. They are believed to act as filters which prevent the absorption of disease germs through the throat. On the other hand, there is abundant evidence to show that many diseases gain entrance through the tonsils.

In addition to the faucial tonsils, there are other masses of lymphoid tissue known as the *lingual* and *pharyngeal* tonsils.

### THE MOUTH

The oral cavity consists of a roof, a floor, lateral walls, vestibule, an inlet, and an outlet.

The *roof* of the mouth is formed by the hard palate in front and the soft palate behind.

“The hard and soft palates should be described as extending from the anterior teeth backward and slightly down in a concave line to near the postpharyngeal wall, leaving scarcely any space. In the normal living subject, when the mouth is closed, the soft palate, the

posterior border of the tongue, and the epiglottis are all in close proximity to the post-pharyngeal wall" (Cryer) (Fig. 14).

The *floor* of the mouth is composed of the two mylohyoid muscles, which join in the median line to form a raphé. Above the mylohyoid muscle is the sublingual gland, while below it is the submaxillary gland. Posteriorly is the base of the tongue, and anteriorly are the alveolar process and the lower anterior teeth.

The mouth is bounded laterally by the cheeks.

The *vestibule* of the mouth is the pocket between the outer side of the alveolar processes and teeth and the inner surface of the cheek.

The *inlet* of the mouth is surrounded by the orbicularis oris muscle, forming the lips. Just within this are the upper and lower anterior teeth.

The *outlet* of the mouth is bounded above by the uvula and posterior edge of the soft palate, laterally by the pillars of the fauces and the tonsils, and below by the dorsum of the tongue.

#### REVIEW QUESTIONS


Give the structure, position, relation, blood supply, and functions of the faucial tonsil.

What other tonsils are there?

Describe the roof of the oral cavity.

Describe the floor of the mouth, giving the structures in close relation to it.

What structures form the outlet of the mouth?





## PART II

### ORAL SURGERY

---

#### GENERAL CONSIDERATIONS

---

#### CHAPTER IX

#### ABNORMAL CONDITIONS OF THE CIRCULATION AND COMPOSITION OF THE BLOOD

By **hyperemia**, or congestion, is meant an excessive supply of blood in a part. It may be *active*, in which case there is an increase in the moving blood, due to dilatation of arterioles and capillaries, or *passive*, in which the blood is stagnant, due to venous obstruction. In hyperemia the elements of the blood remain within the vessels, as distinguished from the further process of inflammation.

By **anemia** is meant a deficient supply of blood to a part, or a defect in the composition of the blood. The degree of anemia is measured by the percentage of hemoglobin as compared with that of normal blood, and by the number of red corpuscles (erythrocytes) in a given quantity of blood as compared to the normal blood. In normal blood the percentage of hemoglobin is taken as 100, and the number of red cells as 5,000,000 per cubic millimeter. Various grades of anemia are recog-

nized by comparison with these standards, and by change in the ratio borne by the percentage of hemoglobin to the number of red cells. Severe anemias are also characterized by alterations in size and shape of the red corpuscles (poikilocytosis), and by the appearance of nucleated red cells and granular degeneration of the cells. Two general classes of anemia are recognized, primary and secondary. Secondary anemia may be due to hemorrhage, various poisons, as lead, phosphorus, etc., wasting diseases, as syphilis, tuberculosis, cancer, and other conditions, as intestinal parasites. Primary anemia is regarded as a disease originating in the blood itself or in the blood-forming organs, though it is probable that ultimate causes will be found for this class also.

The **leukocytes**, or white blood-corpuscles, are normally found in the proportion of about 8000 to the cubic millimeter. An increase in their number is known as *leukocytosis*, which occurs in ordinary acute inflammation, sometimes amounting to 15,000, 20,000, or 50,000.

In inflammatory leukocytosis the increase is chiefly in the polymorphonuclear leukocytes. Certain diseases of the blood and blood-forming organs known as **leukemias**, are also characterized by a tremendous increase in the number of certain varieties of leukocytes, and the appearance in the blood of new forms.

Active hyperemia is the result of mild irritation of some sort. When irritation is more severe or is kept up, a condition of inflammation is induced.

#### REVIEW QUESTION

Define hyperemia, anemia, leukocytosis, leukemia.

## CHAPTER X

### INFLAMMATION

It is impossible to adequately define the term inflammation in a short sentence, owing to the complex nature of the process, and the following definitions are necessarily imperfect.

Inflammation is an expression of the effort on the part of a living tissue to rid itself of or render inert noxious irritants, arising from within or introduced from without. It is the sum of the pathologic changes taking place in a part as the result of injury, and characterized by heat, pain, redness, swelling, and disturbance of function.

Inflammation is a succession of local adaptive changes in a part resulting from direct or referred injury (Adami).

**Etiology.**—Anything that causes local injury to the tissues is a cause of inflammation. These causes are: (a) Mechanical—trauma. (b) Chemical. (c) Physical—heat, cold, electricity. (d) Metabolic—gout, etc. (e) Bacterial.

The presence of bacteria is not essential for inflammation.

There are two grades of inflammation, the *acute*, running a rapid course, characterized by the classic symptoms, and generally due to microbic invasion, and the *chronic*, slow in development and progress, in which cardinal symptoms may be lacking. All grades occur between these two extremes.

**Tissue Changes Occurring in Acute Inflammation.**— These may be studied under the microscope in the web of the living frog's foot or mesentery, and also by preparing sections of tissue in different stages of inflammation. What knowledge we have has been gained by a combination of these methods.

These changes may be summed up as follows:

1. Primary contraction of blood-vessels, and increase in rapidity of the current.
2. Dilatation of the vessels and gradual slowing of the current.
3. Temporary or permanent arrest of the blood current (stasis).
4. Emigration of leukocytes through the vessel-walls into the surrounding tissues.
5. Exudation of blood-serum, and diapedesis of red blood-corpuscles.

There is a primary contraction of the blood-vessels, due to the irritation. This causes a temporary increase in the velocity of the blood-current. The vessels now gradually dilate, and the current becomes slower and slower until it is almost entirely arrested. These phenomena are observed solely in the veins and capillaries. The slowing of the current is believed to be due to changes in the endothelia of the veins. While the current is flowing rapidly, the individual cells of the blood cannot be distinguished, but as it slows down, the leukocytes are observed to accumulate in the outer zone of the current, along the walls of the veins, some of them becoming fixed there. The leukocytes also show a tendency to cling to the walls of the capillaries (margination of leukocytes). After a time the leukocytes

are observed to be making their way through the vessel walls. The first indication of this is the appearance of a small portion of the cell on the outer side of the vessel-wall, gradually followed by the whole cell. This passage of the leukocytes through the walls of the veins and capillaries is known as *emigration*. The white blood-cells are believed to pass through spaces or *stomata* between the endothelial plates lining the vessel-walls. The leukocytes which have left the vessels may pass through the tissue spaces to the seat of the irritation, or may reënter their circulation through the lymph vessels. While the emigration of leukocytes is going on, red cells and blood-serum find their way into the surrounding tissues, principally through the walls of the capillaries. The extravasation of red cells is known as *diapedesis*. The serum extravasated differs somewhat in composition from normal blood plasma, being richer in proteins.

Inflammation may terminate in *resolution* without pus formation, or *suppuration* may supervene before resolution.

In the inflammatory process the leukocytes pass to the point of irritation, which is generally due to bacteria, gather around the infected area, and attempt to neutralize the action of the bacteria and their products. This action of the leukocytes is called *phagocytosis*. The leukocytes can be shown to absorb the bacteria into themselves and digest them. Other body cells and tissues form substances that neutralize the toxic effects of the bacteria and prepare them for ingestion by the leukocytes. In primary resolution after inflammation there is no death of tissue, which returns to a normal

condition by absorption into the circulation of the inflammatory exudates.

Sometimes the resistive powers of the body are not sufficiently powerful to overcome the bacteria, which continue to grow and send out their products, resulting in liquefaction and death of the tissue-cells and leukocytes. This process is known as *suppuration*. Sooner or later, as a rule, the suppurative process becomes localized or walled in by leukocytes. The liquefied necrotic area is known as an *abscess*, and the material contained in it is called pus. Pus is, therefore, composed of fluid containing broken-down leukocytes and tissue-cells, fat globules, albuminous granules, and bacteria. Pus is not, as a rule, absorbed, but gradually makes its way in the direction of least resistance, toward the surface of the tissue and is expelled. The communication of an abscess cavity or area of necrotic tissue with the surface of the body is known as a *sinus*. This term should not be confused with *fistula*, which is a pathologic communication of a normal cavity or hollow viscus with the body surface, or with some other hollow viscus. After evacuation of an abscess, resolution takes place, new tissue being formed to make up for that lost by suppuration. The process of repair of tissues will be considered under Wounds.

**Symptoms of Inflammation.**—The cardinal or classical symptoms of inflammation are heat (*calor*), pain (*dolor*), redness (*rubor*), swelling (*tumor*), and disturbed function (*functio læsa*). These symptoms can all be explained by the pathologic changes which occur in an inflamed tissue.

*Heat.*—An inflamed part is usually both subjectively

and objectively warmer than the surrounding tissues. The temperature, however, is, in reality, no higher than that of the blood. The local sensation of warmth is due to the increased blood-supply and to chemical action.

*Pain* is due to irritation of sensory nerve-endings by the toxins produced. That it is not caused by pressure of the exudate is borne out by the anesthesia produced by injection of subcutaneous tissues with physiologic salt solution.

*Redness* is due to distention of the capillaries of the inflamed part with blood.

*Swelling* is caused in part by the increased amount of blood in the vessels, but is chiefly due to exudation of blood-serum into the tissues.

*Disturbed Function.*—This naturally results from the swelling and pain.

In addition to the classical symptoms, other signs are noted in the various stages of inflammation. Some are purely local, while others are an expression of a general poisoning of the system by absorption of toxins into the circulation.

*Edema*, or pitting on pressure of the skin over the inflamed part, is usually present in microbic inflammation of subcutaneous tissues. It is due to the presence of inflammatory exudate.

*Fluctuation* is a sign of a localized collection of pus or abscess.

*Fever*, or elevation of temperature, is present in all microbic infections in which the products of bacterial growth are absorbed into the general circulation. It is due to increased heat production from the breaking down of tissues by bacterial toxins. The rise of temperature is always accompanied by *increased pulse-rate*.

A *chill* often precedes the formation of pus.

*Leukocytosis* is found in nearly all acute inflammatory conditions, the increase being chiefly in the polymorphonuclear leukocytosis.

Besides these symptoms, we may have muscular weakness, anorexia or distaste for food, headache, delirium, and other disturbances of the nervous system. The liver, kidneys, and other excretory organs may be affected.

**Treatment of Inflammation.**—The general principles of treatment of inflammation consist in removal of the cause, putting the parts at rest, and the application of cold and pressure. When pus forms, it must be evacuated.

*Cellulitis.*—When the leukocytes fail to build a limiting wall to the area of infection, the bacteria spread in the tissue-spaces and along the lymph-channels of the subcutaneous tissues. This process is known as *cellulitis*. It may result in diffuse suppuration, or, in more severe cases, where there is extensive tissue destruction, in phlegmonous or gangrenous inflammation. In the region of the jaws cellulitis may be caused by an infected tooth, from stomatitis, from infection of the salivary glands, or from an impacted third molar. The cellulitis from an abscessed tooth may spread down the neck between the layers of the deep fascia. Where it is caused by an impacted third molar, the inflammation generally passes upward to the temporomandibular articulation, causing acute ankylosis.

#### ULCERATION

An *inflammatory ulcer* is the result of suppuration and tissue destruction in close connection with an epidermal



or mucous surface, causing loss of these layers. The process is identical with that of abscess formation, and repair takes place in the same way.

Tissue surface may be lost by injury of some kind, resulting in the formation of a *traumatic ulcer*. The surface may also break down from lack of nutrition by cutting off of the blood-supply, forming *trophic ulcer*.

### GANGRENE

*Gangrene* is necrosis or death en masse of soft tissue. It is caused by interference with the blood-supply of the part affected, and may be due to virulent microbic infection. It is also seen in disorders of nutrition, in which the arterial supply is gradually shut off. This variety, known as *dry gangrene*, is characterized by a shriveling up of the part affected, which turns black and finally drops off if not previously removed by the surgeon. In *moist gangrene* there is also obstruction to the veins; the part becomes swollen by distention of the tissues with exudation from the vessels, putrefaction sets in, giving rise to a very foul odor, and the patient may die from absorption of the products of putrefaction.

### NECROSIS

The term *necrosis* means death en masse of any tissue, but is usually applied to death of bone. It is produced in the same way as gangrene of the soft tissues, by any agent that destroys its blood-supply, either through the internal portion of the bone or the periosteum covering the bone. It may thus follow trauma,

chemic action, as seen in poisoning of various kinds, and microbic invasion of the bone-marrow (osteomyelitis), or of the periosteum (periostitis).

By *caries* of bone is meant a slow molecular disintegration of the bone.

#### BACTERIA COMMONLY ASSOCIATED WITH SURGICAL AFFECTIONS

In the following brief account only the more important of the micro-organisms will be mentioned, and there will be no consideration of the purely bacteriologic side of the subject, which can be obtained in text-books.

The commonest organisms met with are the pyogenic cocci. These include the staphylococcus aureus, staphylococcus albus, staphylococcus citreus, and the streptococcus pyogenes.

The *staphylococcus aureus* is associated with practically all circumscribed local suppurations, such as abscesses, boils, etc.

The *staphylococcus albus* is present normally in the skin, and is found in suppurative lesions of the skin, such as acne. This organism is responsible for stitch abscesses after operations.

The *staphylococcus citreus* is less common than the foregoing.

The *streptococcus pyogenes* is the commonest cause of spreading infections, cellulitis, erysipelas, etc. It is more liable to cause systemic disturbance than the staphylococci, resulting in grave septicemia.

Other organisms capable of producing pus under favorable conditions are the gonococcus, pneumococcus, bacillus typhosus, bacillus coli communis, bacillus pyocyaneus.

The *gonococcus* is the specific cause of gonorrhoea. In addition to infection of the urethra, it may cause infection of the conjunctiva, lymphatic glands, joints, and serous membranes.

The *pneumococcus* is at times responsible for suppurative lesions of joints and other tissues.

The *typhoid bacillus* may cause suppuration of joints, glands, and other tissues. Abscess of the parotid gland is a frequent sequel of typhoid fever.

The *colon bacillus* is frequently responsible for infections connected with the alimentary and genito-urinary tracts.

The *bacillus pyocyaneus*, or green-pus bacillus, often becomes ingrafted on another infection, particularly in connection with the alimentary canal.

The *bacillus tuberculosis* is of surgical interest by reason of the lesions it causes in bones, joints, and lymphatic glands.

The *bacillus mallei* is the cause of glanders.

The *bacillus anthracis* is the cause of anthrax or malignant pustule, a disease seen in wool-sorters or men engaged in the handling of hides.

The *tetanus bacillus* is the cause of tetanus or lock-jaw. It is especially found in soil, dust, and in sweepings of stables. The organism is anaërobic, and, therefore, deep or punctured wounds are more liable to become infected by it than open ones.

The *spirochetæ pallida*, or, more correctly, the *trep-  
onema pallidum*, is the cause of syphilis.

The *actinomyces*, or ray-fungus, is the cause of actino-  
mycosis.

The *diphtheria bacillus* is occasionally associated with  
surgical conditions.

The *bacillus ærogenes capsulatus* is found in cases of  
emphysematous gangrene.

### REVIEW QUESTIONS

Define inflammation.

Give the etiology of inflammation.

Describe the tissue changes taking place in acute inflammation.

What may be the terminations of inflammation?

Define the terms stasis, diapedesis, phagocytosis, abscess, sinus,  
fistula.

Give the five cardinal symptoms of inflammation, with the explana-  
tion of each.

What other symptoms may be present in inflammation?

What are the principles of treatment of inflammation?

Explain the terms cellulitis, ulcer, gangrene, necrosis.

Name and describe briefly the principal micro-organisms associated  
with surgical affections.

## CHAPTER XI

### CONTUSIONS AND WOUNDS

#### CONTUSIONS

A *contusion* is an injury to an organ or to the subcutaneous tissues, due to a blunt force, in which the surface remains intact, such as falls, kicks, blows, etc.

**Pathology.**—The tissue structure is torn, blood-vessels are ruptured, and there is an effusion of blood and lymph. If a large vessel is ruptured, there may be a considerable extravasation of blood into the tissues (*ecchymosis*), or there may be a distinct cavity in the tissue, containing a collection of blood (*hematoma*). This is usually gradually absorbed, but may undergo suppuration. A *petechia* is a small ecchymosis. As blood is absorbed it undergoes chemic changes, giving rise to a succession of colors, the part being first red, then in turn purple, black, green, and yellow.

**Symptoms** of contusion are swelling, pain, tenderness, and numbness. *Swelling*, due to rupture of a blood-vessel, appears very quickly after the injury, while later swelling is due to the exudation of lymph. Discoloration of the skin appears early in superficial contusions, late in deep ones. A hematoma fluctuates at first, later becomes hard, due to coagulation of the blood. Secondary softening is usually due to suppuration, and is accompanied by the symptoms of inflammation.

**Treatment.**—This in most cases consists in rest, compression, and application of cold to the part. If the swelling increases, due to rupture of a large vessel, an incision must be made, and the vessel sought for and ligated. The only other indications for incision are persistence of the swelling for some weeks, infection, and gangrene.

### WOUNDS

A *wound* is an injury involving a breach in the surface.

Wounds are divided into incised, lacerated, contused, and punctured.

An *incised* wound is a clean cut, made by a sharp-edged instrument, with loss of only a thin film of tissue.

A *lacerated* wound is one in which the tissues and skin-edges are torn, made by a dull instrument.

A *contused* wound is one in which the tissues are crushed, made by a blunt instrument.

A *punctured* wound is one of varying depth, made by a pointed instrument.

When it communicates with a cavity, it is known as a *penetrating* wound.

*Gunshot* wounds may be lacerated, contused, punctured, or penetrating. Any of these varieties may be complicated by the presence of bacteria, resulting in an *infected* wound.

*Hemorrhage* is a symptom of all wounds. *Pain* is, as a rule, not so severe after incised wounds as after other varieties.

In an incised wound the skin-edges gape less if the cut be parallel to the fibers of the underlying muscle. If the muscle-fibers be cut across, the edges usually gape

widely, resulting in a broader scar, and also in greater functional disturbance after healing has taken place. This point should be borne in mind in making incisions at operations.

**General Principles of Treatment of Wounds.**—1. Arrest hemorrhage. 2. Remove foreign bodies. 3. Render aseptic. 4. Drain, and bring edges together. 5. Secure rest.

1. Any but the smallest bleeding vessels are grasped with hemostatic forceps and secured by ligatures. Capillary oozing may be controlled by hot applications or by compression. Bleeding from small vessels in the skin is often arrested by the sutures which bring the edges together.

2. All visible foreign bodies, such as bits of glass, clothing, etc., should be removed with forceps. Devitalized tissue should be trimmed away.

3. To thoroughly cleanse a wound, shave any hair from the immediately surrounding skin, wash the skin with tincture of green soap, followed by alcohol and 5 per cent. solution of iodine. Any wound other than that made by the surgeon should be swabbed out with the last solution. If dirt be ground into a wound, wash first with turpentine, followed by soap and germicidal solution.

4. In superficial wounds, suture the edges together without drainage. Deep wounds require drainage by strands of silkworm-gut, catgut, rubber tubing, or gauze. Bring together divided muscle-fibers or tendons with deep sutures of chromicized catgut. Bring the skin-edges together with interrupted sutures of catgut, silkworm-gut, or horsehair, leaving space for the drain. Infected wounds must invariably be drained. Arrange the drainage material loosely, so that it will not dam back

the fluid. Strips of rubber dam may be used to drain small wounds. Drainage should be employed for at least twenty-four hours. After that time the appearance of the wound is a guide as to drainage. Apply a wet dressing of gauze saturated with equal parts of 1 : 1000 bichlorid solution and alcohol over all infected wounds, or those in which infection is suspected. This stimulates phagocytosis and feels more comfortable than a dry dressing. Cover the wet dressing with waxed paper to retain the moisture as long as possible, or pour on fresh solution from time to time. In badly infected wounds it is well to arrange to keep a constant drip of fresh bichlorid solution, 1 : 10,000, on the dressing, by means of a vessel suspended above the part with a piece of gauze hanging over the side. An infected wound is redressed at least every twenty-four hours. An aseptic wound should be inspected in two days. Skin stitches may be removed from superficial wounds in four or five days. An aseptic wound may be sealed with White-head's varnish after closure with a continuous suture. This is particularly useful in parts of the body which are liable to become bathed with secretions, such as the region of the mouth. It is made up as follows: Iodoform, 1 ounce; compound ethereal solution of benzoin, 5 ounces.

5. Rest. Immobilize the parts by bandaging and splints if necessary.

In punctured wounds where there is a possibility of infection by the tetanus bacillus, the parts are cauterized with pure carbolic acid, followed by the application of alcohol, and a prophylactic dose of 1500 units of tetanus antitoxin should be administered subcutaneously.



*Wounds of mucous membranes* such as the mouth are always infected, but, as a rule, heal remarkably well. In a wound of the mouth the hemorrhage should first of all be arrested, after which steps should be taken to reduce the amount of infection as much as possible. Deposits of decomposing food and tartar should be removed from the teeth, all useless roots extracted, and carious teeth treated. An antiseptic mouth-wash should be employed at frequent intervals. Small wounds of the mouth require no suture, but the edges of large lacerated or incised wounds should be brought together with catgut, which does not have to be removed, or horsehair, which must be taken out after four or five days.

If made by the surgeon in the course of an operation, under approximately aseptic conditions, small incised wounds of the mouth may be closed without drainage, interrupted horsehair sutures being employed. In lacerated or contused wounds, or incisions made in connection with large areas of infection, the raw surfaces should be painted with tincture of iodine, after which partial closure may be made with catgut or horsehair, but an opening should be left for drainage with a strip of rubber dam.

#### REPAIR OF TISSUE

After a wound, there is an exudation of lymph, fibrin, and white blood-corpuscles. The corpuscles become changed into fixed connective-tissue cells, and other connective-tissue cells are formed by proliferation from surrounding tissues. From the walls of neighboring capillaries plugs of endothelial cells, known as fibroblasts, are thrown out, which unite with similar outgrowths from the opposite side of the wound. These

plugs are at first solid, but later become hollowed out, forming new capillaries. The connective-tissue cells elongate until they take on the character of white fibrous tissue. This reparative tissue is known as granulation tissue. In incised wounds whose edges have been brought together, healing by primary *union* or *first intention* takes place. This means that, as there is no loss of substance to be made up, only a thin layer of granulation tissue is formed between the two sides of the wound, leaving a linear scar.

In larger wounds, where a considerable amount of tissue has been lost, healing takes place by *second intention*. Here the space between the edges of the wound is filled in with granulation tissue, and proliferation of epithelium from the edges gradually covers over the surface.

What is known as healing by *third intention* is sometimes brought about by approximation of two granulating surfaces.

Repair of soft tissues after inflammation takes place in the same way as after wounds.

In the case of bones, the lost tissue is replaced by fibrous connective tissue into which lime salts are deposited by the osteoblasts, forming new bone.

#### REVIEW QUESTIONS

What is a contusion? Give its symptoms and treatment.

Define the terms ecchymosis, petechia, hematoma.

Define the term wound. Give the varieties, symptoms, and general principles of treatment of wounds.

Describe healing by first and second intention.

How are bones repaired?

## CHAPTER XII

### SURGICAL FEVER

*Aseptic surgical fever*, first described by Billroth, is the almost invariable sequel of a surgical operation or severe injury, in the absence of infection, and is believed to be due to the absorption of fibrin ferment from the seat of injury. There is no evidence of infection of the wound, and the patient feels well. There is an elevation of temperature, sometimes to  $103^{\circ}$  F., beginning on the evening of the operation, and lasting for twenty-four or forty-eight hours.

Aseptic surgical fever requires no treatment. The symptoms of septicemia should be carefully watched for, and the bowels opened with a purge. The wound should not be disturbed.

### SEPTIC SURGICAL FEVER

Under this general heading are included three conditions due to the entrance into the system of micro-organisms or their products through a wound or breach of surface.

1. *Sapremia* is a constitutional disorder due to chemic poisoning by the products of bacteria, these products having been absorbed from the wound. It is usually the result of putrefaction.

2. *Septicemia* is a disorder caused by the action of the products of living micro-organisms that have gained

entrance into the body, and are undergoing growth and multiplication there. It differs from sapremia in that the poison is being continually produced within the body, while in sapremia the poison is produced in the wound, that is, outside the body.

3. *Pyemia* is a disease produced by the absorption of pyogenic organisms into the blood, and characterized, in addition to other symptoms, by the formation of abscesses in various tissues of the body.

### SAPREMIA

This is usually seen in connection with a putrefying mass of material in a wound, such as a blood-clot. A common cause of sapremia is retention of blood-clot and fetal membranes in the uterus after delivery.

**Symptoms.**—These usually come on suddenly and early in the case. The temperature rises to  $103^{\circ}$  or  $104^{\circ}$  F., and is sometimes associated with a rigor. The skin is flushed, hot, and dry, and the patient complains of headache and thirst. The tongue is coated and persistent vomiting may occur. The pulse is rapid and full, the respirations hurried. Inspection of the wound reveals a foul-smelling discharge.

The **diagnosis** from septicemia depends chiefly on rapid recovery after removal of the putrefying material.

**Prognosis.**—Very favorable if the cause is removed early.

**Treatment.**—Clean out the putrefying blood-clot or other material, taking care to injure the surrounding parts as little as possible. Do not use strong germicidal solutions. In severe cases stimulation may be advisable in the form of alcohol, such as whisky, half an ounce

every four hours by mouth, or strychnin hypodermically. Subcutaneous infusion of normal saline solution, half a pint every three hours, dilutes the poison in the blood. Persistent vomiting is best treated by washing out the stomach. The diet, while marked symptoms persist, should be liquid, in the form of milk or albumin water.

#### SEPTICEMIA

The organisms usually associated with this disease are the pyogenic cocci, which are absorbed from a wound into the surrounding tissues or into the blood, where they grow and liberate their toxins.

**Symptoms.**—As in sapremia, these come on early. There is a rapid rise of temperature to  $103^{\circ}$  or  $105^{\circ}$  F., which remains high and is usually associated with rigors. The pulse is rapid, and in severe cases may be weak and irregular. Respiration is rapid and there may be dyspnea or cyanosis. Vomiting is not so marked as in sapremia. Headache and, later, delirium are usually present. Examination of the blood shows leukocytosis. *Locally*, the tissues surrounding the wound (which may be a very small one) become swollen, reddened, and tender, showing the signs of inflammation, and later there may be suppuration. The neighboring lymphatic glands are enlarged and tender and may suppurate.

**Prognosis.**—This is very grave. The disease is often fatal and recovery is generally very slow.

**Treatment.**—The wound should be thoroughly cleaned out and cauterized with pure carbolic acid if possible. The same general treatment is indicated as in sapremia, but must be given more vigorously, and continued

for a longer time. Tincture of the chlorid of iron in doses of 15 minims four times a day is especially efficacious in septicemia. If the micro-organism causing the disease can be isolated, an antitoxin may be given.

#### PYEMIA

The micro-organism usually present in pyemia is the streptococcus pyogenes, though the micrococcus aureus has also been known to cause it. The constitutional effects are due to the action of the toxins of these bacteria in the blood-stream. The secondary abscesses are formed by the micrococci becoming lodged in the walls of the veins (suppurative phlebitis) and septic thrombi becoming detached from these, and being carried to various organs. Pyemia is frequently a sequel of acute suppurative osteomyelitis. A case of osteomyelitis of the mandible, for instance, may be followed by pyemia, with secondary foci in the lungs, peritoneum, brain, and joints.

**Symptoms.**—Pyemia does not, as a rule, begin as early as the other two forms of surgical fever. Local signs of inflammation appear in the wound, associated with phlebitis of the veins of the region under the red and tender skin. The general symptoms begin with a chill and rapid rise of the temperature to 104° or 105° F. This is followed by profuse sweating and a fall of the temperature two or three degrees. The chills, fever, and sweats occur irregularly throughout the course of the disease. The other general symptoms resemble those of septicemia, but are more severe. The secondary abscesses appear from the sixth to the tenth day, and may be located in the lungs, spleen, kidneys, brain,

peritoneum, and joints, giving rise to special symptoms according to the organ affected.

**Prognosis.**—Recovery from pyemia is extremely rare.

**Treatment.**—The wound or primary seat of the infection must be thoroughly cleaned and drained. Cold sponging may control the fever. Tincture of the chlorid of iron and quinin should be given, and the patient should be stimulated as in septicemia. Morphin may be required to relieve pain. Secondary abscesses, if accessible, must be opened and drained.

#### REVIEW QUESTIONS

Define surgical fever, and give its varieties.

Give the symptoms and differential diagnosis of sapremia, septicemia, and pyemia.

Give the prognosis and treatment of each.

## CHAPTER XIII

### SYNCOPE, SHOCK, COLLAPSE

*Shock* is that state of prostration which may follow any excessive disturbance of the nervous mechanism, as in those who have been severely injured, or whose minds have been shaken by intense emotion (Brodie).

*Collapse* is a condition similar to shock, differing in its mode of causation and rate of onset. The main symptoms are the same.

*Syncope*, or fainting, is a mild degree of shock, produced by a temporary anemia of the brain. It is of sudden onset and short duration. The face suddenly becomes blanched, the pulse small and rapid, and the individual sinks to the ground unconscious for a few moments.

**Etiology.**—*Shock* is usually caused by severe bodily injury, following operation, or associated with intense pain or emotional disturbance. It sometimes follows prolonged anesthesia.

*Collapse* is caused by severe external or internal hemorrhage and loss of body fluid, as through persistent vomiting or diarrhea.

**Pathology.**—*Shock* is due to a depression of function of cerebral nerve-centers, particularly of the vasomotor centers, resulting in dilatation of the splanchnic area and a lowering of blood-pressure.

*Collapse* is brought about by a primary loss of body fluid, resulting in cerebral anemia and consequent de-



pression of the higher nerve-centers, with lowering of blood-pressure.

**Symptoms.**—*Shock* usually comes on suddenly. The skin is pale, cold, and moist. The muscles are relaxed. The patient is apparently unconscious, but can be aroused and will reply to questions. The temperature is subnormal, the pulse weak and rapid, and the respirations shallow. The pupils are dilated. The sensibility is dulled.

In *collapse* the onset is gradual, and the symptoms, which are the same as those of shock, grow progressively worse.

**Treatment.**—*Syncope.*—Loosen the clothing about the neck, place the patient in a recumbent position, or thrust the head down between the knees, douche the head with cold water, and allow the patient to inhale aromatic spirits of ammonia. As the patient recovers consciousness administer one dram of aromatic spirits of ammonia in a little water by the mouth.

*Shock.*—Remove the exciting cause if it is still present, and then restore the circulatory function. Place the patient in the recumbent position, elevating the foot of the bed to assist the return of blood from the lower extremities. This is often aided by bandaging the lower extremities. Administration of saline solution increases the volume of circulating blood. Where a rapid effect is desired, from one to two pints of normal saline solution (a teaspoonful of common salt to a pint of sterile water), at a temperature of  $104^{\circ}$  to  $112^{\circ}$  F., may be injected directly into a vein. In less urgent cases the saline solution may be given through the rectum (enteroclysis) or subcutaneously (hypodermo-

clysis). To prevent loss of body heat the patient is wrapped in hot blankets, surrounded by hot-water bottles. A pint of hot coffee may be given by the rectum. Where the shock is due to pain, give morphin,  $\frac{1}{4}$  grain, with sulphate of atropin,  $\frac{1}{120}$  grain hypodermically, and repeat if necessary. Other valuable stimulants are aromatic spirits of ammonia, 30 minims, camphor in olive oil (camphor, 1 grain, olive oil, 5 minims) in 15-minim doses, strychnin,  $\frac{1}{20}$  grain, atropin,  $\frac{1}{120}$  grain, administered hypodermically, and repeated every three hours if necessary. The most rapid effects are produced by the camphorated oil and the ammonia. Adrenalin chlorid is recommended by some, but its effects are only transitory.

*Crile's Method.*—In cases of sudden heart failure during anesthesia or following injury Crile injects normal saline solution containing adrenalin directly into the common carotid artery toward the heart, combining this with massage of the heart. The abdomen is opened through the left rectus, and the heart massaged through the diaphragm. Cases have been literally brought back to life by this method.

In *collapse*, caused primarily by loss of body fluids, the administration of saline solution by the mouth or by injection is especially valuable, though the general principles of treatment are the same as for shock.

#### HEMORRHAGE

Hemorrhage is the escape of blood from the blood-vessels. It may be either spontaneous or due to traumatism. The blood may either escape from the surface of the body, or into the tissues surrounding the blood-

vessels, when it is known as *extravasation*. A circumscribed collection of extravasated blood is known as a *hematoma*. A hemorrhage is known as *internal* when it escapes into one of the body cavities, such as the peritoneal cavity, but is not met with in the region of the body with which we have to deal.

There are three *anatomic* varieties of hemorrhage—arterial, venous, and capillary.

1. *Arterial hemorrhage* is caused by section or rupture of an artery. There is a flow of bright-red blood, which occurs in spurts coincident with the heart-beat.

2. *Venous hemorrhage* is caused by injury to a vein. There is a continuous flow of dark colored blood.

3. *Capillary hemorrhage* is characterized by a steady oozing of blood from a wound.

The *clinical* varieties of hemorrhage are primary, intermediate, and secondary.

1. *Primary hemorrhage* occurs immediately after the division of a blood-vessel.

2. *Intermediate hemorrhage* occurs after the reaction from shock, due to disturbance of the temporary blood-clot by increased vigor of the circulation. It occurs within twenty-four hours after the injury.

3. *Secondary hemorrhage* occurs after the first twenty-four hours. It may be due to sloughing of the end of the vessel, traumatism, or infection. Certain conditions predispose to it, such as arteriosclerosis and hemophilia.

Certain terms are also used in connection with hemorrhage from particular regions. Thus, *epistaxis* refers to nose-bleed; *hemoptysis*, the coughing up of blood; *hematemesis*, the vomiting of blood; *hematuria*, blood in the urine.

**Constitutional Effects of Hemorrhage.**—When a considerable amount of blood has been lost, the pulse becomes rapid and feeble, the respirations gasping. There is a sense of suffocation or *air hunger* and intense thirst. The skin is cold, pale, and moist. Delirium may be present.

**Spontaneous Arrest of Hemorrhage.**—When an artery is divided, the inner and middle coats curl up within the lumen and occlude the cut end. The blood clots above this in the case of a small vessel and hemorrhage ceases spontaneously. The escaped blood also clots around the cut end of the vessel. Later the clot becomes converted into fibrous tissue by the process of repair.

**Methods of Arresting Hemorrhage.**—*Arterial hemorrhage* is arrested by grasping the bleeding artery with a pair of hemostatic forceps. In the case of a small artery the crushing together of the coats of the vessel by the forceps is often sufficient to stop the bleeding if the forceps are allowed to remain for a few minutes. Before removing the forceps the vessel may be twisted with them. In the case of larger arteries a catgut ligature is tied around the vessel before removing the forceps. Sometimes it is necessary to tie both ends of the cut vessel.

*Venous Hemorrhage.*—Bleeding from large veins is arrested in the same way as arterial hemorrhage. Moderate and slight venous oozing can generally be controlled by gauze packing or compression. Bleeding from a small incised wound is generally stopped after the skin sutures are tied, if they are placed deeply enough to compress the bleeding points.

*Capillary hemorrhage* may be checked by the applica-

tion of hot water to the wound, followed by compression with gauze.

*Hemorrhage Following Tooth Extraction.*—Considering the large number of teeth extracted, this is not a very frequent complication, but it may be a very serious and even fatal one. If undue hemorrhage occurs, the alveolus is to be syringed out with warm water to dislodge any clots. In most cases a little tannic acid on cotton packed into the socket will usually stop the bleeding. If this does not suffice, the socket should be tightly packed with gauze covered with tannic acid. A pad of gauze is now laid over the plug, and the teeth of the two jaws are brought together. The jaws are held together with Barton's bandage. In most cases the packing should not be disturbed for twenty-four hours. The gauze packing in the tooth socket may be held in place by a crossed ligature passed over the socket and secured to teeth on either side of it. Sometimes it is advisable to replace the extracted tooth in the alveolus and allow it to remain for several hours. In severe cases it may become necessary to ligate the external carotid artery.

Persistent capillary hemorrhage is frequently due to a deficiency of substances which bring about coagulation of the blood. These substances may be supplied to a patient in whom bleeding from a tooth socket persists by the injection hypodermically of normal blood-serum. Normal horse-serum may be obtained in convenient syringes for this purpose, and is given in doses of 10 to 20 c.c., which may be repeated in twenty-four hours or less if necessary. Where the normal horse-serum is unobtainable in emergencies, diphtheria antitoxin may be used. Normal serum has also been successfully em-

ployed locally to check hemorrhage, and may be used on the cotton packing in the tooth socket instead of tannic acid.

**Constitutional Treatment Following Hemorrhage.**—

The patient is to be placed in the recumbent position, with the head lowered, and kept perfectly quiet. This is secured, if necessary, with a hypodermic injection of  $\frac{1}{4}$  grain of morphin. The lost blood is replaced with intravenous injection of one to two pints of normal salt solution, and circulatory stimulation is carried out by hypodermic injections of strychnin, atropin, and camphorated oil, in the doses given in the treatment of shock. If the site of the hemorrhage is not absolutely secured from further bleeding, judgment must be exercised in stimulating the circulation on account of the danger of setting up fresh hemorrhage from increased arterial pressure. The thirst present in these cases is relieved by water, either by the mouth or by the bowel. The anemia following severe hemorrhage is to be treated later by tonics, particularly iron.

In some cases the only hope of improvement is by direct transfusion of blood from another person, preferably a blood relation of the patient.

#### HEMOPHILIA

Hemophilia (hemorrhagic diathesis) is a congenital tendency to spontaneous hemorrhage and immoderate hemorrhage after injury. The disease is restricted to the male sex, and is usually hereditary in character, being nearly always transmitted through the female sex.

**Etiology and Pathology.**—The blood in these cases is found to have a subnormal number of leukocytes, par-

ticularly of the polymorphonuclear leukocytes. It is now recognized that the disease is due to a defect in the coagulating power of the blood.

**Symptoms.**—The diathesis shows itself in subcutaneous hemorrhages, hemorrhage into joints, and immoderate spontaneous bleeding from mucous membranes, for example, from the nose and gums. Moreover, severe bleeding follows the slightest injury, and can be arrested only with great difficulty. Death has frequently followed extraction of a tooth in one of these cases, and as extensive dental caries is very often associated with hemophilia, this becomes a serious complication. There is a noticeable tendency for the hemorrhage to come on at night. It may not be severe immediately after infliction of the wound, but will break out again after the patient goes to sleep.

**Prognosis.**—This is especially unfavorable in infancy, but the coagulability of the blood increases as age advances, and while the outlook is never good so far as the traumatic hemorrhages are concerned, yet the patient, as he grows older, becomes careful not to incur these, and the tendency to spontaneous hemorrhage usually is overcome.

**Treatment.**—From the surgical standpoint the chief consideration is the prevention and arrest of traumatic and postoperative hemorrhage. The following measures are on the lines laid down by Sir A. E. Wright.

**Prophylaxis.**—In a patient known to be a bleeder it is well to avoid performing any operations, if possible. If an operation, such as extraction of a tooth, becomes imperative, some attempt may be made to increase the coagulability of the blood by the administration of

drugs by the mouth. The defect in nucleo-albumin may be supplied by the administration of extract of thymus gland, in doses of 5 grains three times a day. The remedies used to increase coagulability are the salts of calcium and magnesium. A mixture of calcium chlorid or lactate and magnesium carbonate may be given in doses of 5 grains of each three times a day. These measures should be carried out for several days preceding the operation.

If, in spite of these precautions, or if bleeding occurs in an unsuspected case of hemophilia, the remedies must be given in larger doses—20 grains three times a day of the thymus extract may be given. An initial dose of 1 dram of calcium chlorid or lactate, or a mixture of equal parts of calcium chlorid and magnesium carbonate, may be given to an adult, followed by 30 grains daily to keep up the effects.

The injection of normal blood-serum in suitable doses, repeated if necessary, is indicated in hemophilic bleeding, as well as a prophylactic, just as in ordinary capillary hemorrhage. Direct blood transfusion may also give successful results.

*Local Treatment.*—This consists in the application of physiologic styptics, which exert their effect by accelerating the coagulation of the blood on the bleeding surface. Wright finds that with such a styptic he can arrest hemorrhage from the cut femoral artery of a dog, provided the artery be compressed for a minute or two to allow consolidation of the clot. This styptic is made from the thymus gland of a calf or lamb. The gland is chopped up finely and placed in a jar with normal salt solution in the proportion of one part of gland to ten



parts of the solution. The extract is filtered off, and 0.5 per cent. of calcium chlorid added to the filtrate with 1 per cent. of carbolic acid. The wound is plugged with cotton or lint soaked in the styptic.

### REVIEW QUESTIONS

Define shock, collapse, syncope.

Give the etiology, symptoms, and treatment of shock.

Define and give the anatomic and clinical varieties of hemorrhage.

Give the constitutional effects or symptoms of hemorrhage.

How is spontaneous arrest of hemorrhage brought about?

Give the methods for controlling arterial, venous, and capillary hemorrhage, respectively.

Give the methods of arresting hemorrhage following tooth extraction.

What is the constitutional treatment of hemorrhage?

Define hemophilia. Give its etiology, pathology, symptoms, prognosis, and treatment.

## CHAPTER XIV

### ANESTHESIA

THREE methods of inducing anesthesia are employed at the present time for the performance of surgical operations. The three forms are spinal, local, and general.

**Spinal anesthesia**, so successfully employed by Jonnesco, of Bucharest, has not met with universal favor in this country, and a limited number of surgeons employ it in operations on the lower extremities and lower part of the trunk. The anesthesia is induced by paralyzing the sensory spinal nerve-roots by injection of a solution of stovain into the spinal canal in the lumbar region. This method is not, as a rule, applicable to operations on the head and neck, so it is only briefly mentioned in passing.

**Local Anesthesia.**—By this is meant the induction of loss of sensibility in a part by the local application or injection of certain drugs. Superficial local anesthesia may be induced by the application of a volatile fluid, such as *ethyl chlorid*. This is applied in the form of a spray, and by its evaporation abstracts heat from the part. The ethyl chlorid spray is suitable for opening small abscesses. Various substances are used to paralyze sensory nerve-endings by injection into the skin. Cocain hydrochlorid, beta-eucain hydrochlorid, and novocain are the most commonly used, in solutions ranging from 1 to 5 per cent. Novocain is just as efficient as cocain,

and is practically never followed by toxic effects. Moreover, the novocain solution can be sterilized by boiling, which is not true of cocain without interference with its anesthetic properties. For most practical purposes a 1 per cent. novocain solution will answer. With this is combined adrenalin chlorid in the proportion of 1 part in 10,000. The adrenalin enhances the anesthetic effect, constricts the blood-vessels of the part, thus lessening hemorrhage, and retards absorption of the anesthetic. This form of local anesthesia is applicable for the removal of small growths from the skin, foreign bodies, etc. It should not be used where there is infection, and extreme care should be employed in thorough sterilization of the needle and the parts to be operated upon. The needle is introduced *into*, not *beneath*, the skin, at one end of the prospective incision, and a drop of the solution injected. The needle is then pushed a little further along the line of incision and another drop injected. This is continued until the whole line of incision is infiltrated by the anesthetic. Before proceeding with the operation, it is well to wait two or three minutes for the anesthetic to take effect.

*Local Anesthesia for Extraction of Teeth and Operations About the Jaw Bones.*—With improvements in technic and the substitution of novocain for cocain, what was formerly condemned as dangerous and unsatisfactory, has in the last few years come to be regarded as one of the most valuable aids in dental and oral surgery. The essentials of success in the employment of local anesthetics are a thorough knowledge of the anatomy of the parts, proper technic, the selection of suitable cases, and, above all, the observance of absolute asepsis. It is dangerous to inject

a local anesthetic into acutely inflamed tissues about a tooth, as the introduction of any fluid under pressure in these circumstances may result in spreading the infection or sloughing of the tissues. The anesthetic effect, too, is not nearly so powerful when the tissues are inflamed. Again, certain people of nervous temperament are not suitable subjects for local anesthesia, their nervous condition causing them to flinch at the sight of instruments, the prick of the needle, etc. This applies also to young children, in whom general anesthesia is more satisfactory. For details of the technic of injection, etc., the reader is referred to special works on this subject, such as those of Fisher-Riethmuller, Thoma, and Allen.

**General Anesthesia.**—General anesthesia is the artificial production of loss of consciousness by the action following inhalation of certain drugs upon the sensory nerve-centers in the brain. In a general way the cranial nerves are affected by general anesthetics in their regular order, beginning with the olfactory.

The general anesthetics in common use are ether, chloroform, and nitrous oxid. Ethyl chlorid is occasionally used.

The choice of an anesthetic depends upon several factors, such as the length of anesthesia required, the nature of the operation, and the condition of the patient.

For prolonged anesthesia, ether and chloroform are used. For the vast majority of cases ether should be selected, as it is very much less dangerous than chloroform. The number of deaths following the inhalation of chloroform is about 1 in 4000, while the number from ether is about 1 in 16,000. Chloroform is more dangerous than ether because it acts more strongly and quickly

upon the circulation and respiration than ether. In its administration there is a progressive fall of blood-pressure. The comparative infrequency, too, with which chloroform is given by anesthetists in this country undoubtedly contributes to the danger. Chloroform is much more pleasant to take than ether, produces less excitement, less irritation of the respiratory passages, its effects are much more quickly produced than those of ether, while there is usually less nausea and vomiting following its administration. All these advantages, however, are counterbalanced by the danger of chloroform and the comparative safety of ether, and there are only a few cases in which the latter is not to be preferred. In chronic bronchitis, asthma, and phthisis pulmonalis, chloroform is preferable to ether, as the latter is a powerful irritant to the respiratory passages. In case of war, chloroform is less bulky, and the patients can be anesthetized much more rapidly, and thus there is the possibility of attending to a greater number of wounded. The secondary effects of chloroform on the tissues are more serious than those of ether.

Ether is said to be unsatisfactory in tropical countries, owing to its great volatility, but it is used here with success in the hottest weather. It is also said that ether is less suitable for children than chloroform, but practical experience shows that it can be employed just as satisfactorily in the case of children as of adults.

#### ETHER NARCOSIS

Ether anesthesia may be divided into four stages, as follows:

1. Stage of primary anesthesia.

2. Stage of excitement.
3. Stage of relaxation.
4. Stage of collapse.

*First Stage.*—On first inhalation of ether there are burning in the throat and a feeling of strangulation, due to local irritation of the ether. In a short time sensibility becomes distinctly lessened, and the patient becomes semiunconscious. In this stage minor operations, such as extraction of a tooth or opening an abscess, can be performed without pain.

*Second Stage.*—The first stage is soon succeeded by the stage of excitement. The patient becomes delirious and often violent. The muscles are rigid; the respirations are rapid, though they may cease through spasm of the glottis; the face is flushed and moist. Reflexes are present and may be exaggerated. The pulse is rapid and full. The pupils are dilated.

*Third Stage.*—In this stage the patient becomes quiet. The muscles are relaxed; the corneal and other reflexes are lost. The pupil is contracted. The breathing is slow, deep, and regular. The pulse is full, strong, and slow. The skin is flushed, warm, and moist. This is the stage during which surgical operations are performed. Production of complete surgical anesthesia requires, as a rule, from ten to fifteen minutes.

*Fourth Stage.*—If anesthesia be carried beyond the third stage, the patient's life is in danger from collapse. The breathing becomes stertorous from paralysis of the muscles of the palate. The respirations then become shallow and irregular, or may cease altogether. The pupil dilates, and will not respond to light. The pulse becomes rapid and weak. The skin is cold, moist, and

dusky. Ether usually produces death by asphyxia, due to depression of the respiratory centers, but may also act fatally by depressing the heart. On the nervous system ether acts as a depressant, first on the cerebrum, then the sensory side, and finally the motor side, of the spinal cord. The first action of ether upon the circulation is as a stimulant to the heart and vasomotor centers, but it finally depresses the heart and vascular system.

Extraction of a tooth, or opening of an abscess, can often be performed during the first stage of ether anesthesia. In these cases little or no previous preparation of the patient is necessary, and they can be done with the patient in the sitting posture. The best way of giving the ether in these cases is by means of a towel folded into the shape of a cone, in which a sponge moistened with warm water is inserted. A considerable quantity of ether is poured on the sponge, and the face of the patient gradually approached with the cone. The patient is instructed to take full breaths and to hold up one arm. In a few minutes the arm drops and the tooth is extracted without pain.

Before the administration of ether for complete anesthesia, the following precautions are to be taken:

No food should be taken by the patient for at least ten or twelve hours before the administration of the ether where a long operation is to be performed. If this precaution be not observed, vomiting is liable to occur, with danger of suffocation and aspiration pneumonia. The bowels should be emptied by a dose of magnesium sulphate the evening before the operation. The patient's heart and lungs should be carefully examined. It is important to know the condition of the kidneys, both as

to presence in the urine of albumin and casts and the quantity excreted. Ether is a powerful irritant to the kidneys, and the minimum amount must be used in the presence of nephritis.

Just before administration of the anesthetic all foreign bodies, such as removable artificial teeth, should be taken from the mouth. The clothing about the neck and chest must be loosened. The horizontal position is preferred in administration of the anesthetic, but the patient can later be placed in any more convenient position for the performance of the operation. In giving the anesthetic it is not necessary to remove the pillow from beneath the patient's head, as is so often done. Respiration is usually much less embarrassed with the pillow. The lips and nostrils of the patient should be anointed with vaselin before giving the ether. Some anesthetists precede the administration of ether by nitrous oxid, and by this means shorten the induction of complete anesthesia. The method is undoubtedly also more agreeable to the patient, and the after-effects are said to be less noticeable. But in the experience of the writer, for prolonged operations, where complete relaxation is necessary, it is best to commence with ether. Patients throughout the operation do not seem to lose the cyanosing effects of the nitrous oxid, thus masking possible cyanosis from the ether, and complete relaxation is not so easily attained. If the ether be given slowly, it is seldom objected to by the patient. I have seen one anesthesia death following the combination of nitrous oxid and ether, probably caused by mistaking the results of too much ether for nitrous oxid cyanosis.



The best way of administering the ether is with the ordinary wire mask (Fig. 26) usually employed in giving chloroform. It is easily handled and removed when necessary in operations about the face, and has the especial advantage that plenty of air is admitted with the ether. This latter is the most important point in ether administration. About four layers of gauze are placed on the mask and a few drops of ether allowed to fall on them. The mask is held at first at some little distance from the patient's face, and gradually made to come nearer, until finally the fumes become tolerable and it can be laid directly in contact with the face. After this the ether can be given more rapidly, but still drop by drop, and, if necessary, a few more layers of gauze temporarily applied, which can be removed when anesthesia is complete. By this open method, with slow administration of the ether and allowing admixture of plenty of air, a longer time is required for anesthesia than by giving the ether in larger quantities and excluding the air, but relaxation becomes more complete, and the general condition of the patient is much better throughout the operation. The patient is instructed to breathe deeply and regularly, but forcible respiration is to be avoided. Any cessation of the respiration dur-

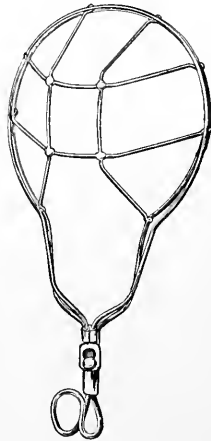


Fig. 26.—Wire frame for holding gauze in ether anesthesia.

ing the early stages is due to local irritation or spasm of the glottis. A full breath of air, followed by an increase in the amount of the anesthetic, is generally successful in restoring natural respiration. The lower jaw should be kept forward by pressure of the fingers behind the angle. This prevents the tongue from falling back and obstructing the glottis. During the stage of excitement the patient may become so violent as to require assistants to hold him. When the patient is quietly resting upon the operating table, the arms should be secured to the sides by a towel passed under the body, the ends being fastened to the wrists with safety-pins. This prevents the arms from hanging over the sides of the table, and consequent risk of musculospiral paralysis from pressure on the nerve by the edge of the table.

The indications that anesthesia is complete are relaxation of the muscles and absence of the corneal reflex. During the operation the anesthetist must from time to time note the condition of the pulse, and report it to the operator. The pulsation of the temporal artery can be conveniently felt immediately in front of the ear. He should remove any mucus which may have collected in the throat by means of a gauze sponge. Respiration may be aided by inserting a mouth-gag, drawing the tongue forward, and holding it with a small piece of gauze in the fingers. This is preferable to the tongue forceps, which crush and wound the tongue unnecessarily. During the operation the patient is kept under with the minimum amount of ether, continually administered drop by drop. The best guide to the depth of anesthesia is the respiration of the patient. A slight break in the regularity of the breathing is an

indication, as a rule, that the patient is coming out, and to push the anesthetic a little. During deep anesthesia the pupil is contracted. As it becomes less profound the pupil dilates, but will respond to light. When the ether is pushed too far, the pupil also dilates, but does not respond to light. The depressant effects of the ether also show themselves in a duskiness of the skin, due to sluggish circulation. This is well seen in the lobe of the ear. Pressure causes the cyanosis to disappear, and it returns slowly when the pressure is released. Cyanosis is accompanied by a *gradual acceleration* in the pulse-rate and a decrease in its volume. These signs call for stimulation and a termination of the operation in as short a time as possible.

Strychnin sulphate,  $\frac{1}{20}$  grain, and atropin sulphate,  $\frac{1}{120}$  grain, and tincture of digitalis, 10 minims, may be given hypodermically, and the first repeated if necessary. In more extreme cases, with the pulse at 160 or higher, especially when the patient has lost a considerable quantity of blood, intravenous infusion of a pint or more of normal saline solution is indicated.

Vomiting during the operation is usually a sign that the anesthesia is not sufficiently deep. Its onset is heralded by retching, and it can often be averted by pushing the ether. If vomiting does occur, remove the mask and turn the head of the patient to one side to prevent inspiration of the vomited material. As soon as possible after the throat has been cleared the administration of the anesthetic is continued.

In case of respiratory failure, remove the anesthetic at once, see that the tongue has not fallen back to obstruct the glottis, and attempt to set up respiratory

movements by pressure on the chest. A piece of gauze saturated with aromatic spirits of ammonia placed over the nostrils will often be of assistance. If these fail, regular artificial respiratory movements should be tried. Administration of oxygen with the ether in all cases that show a tendency to respiratory embarrassment should be a regular procedure.

Sudden heart failure calls for cardiac massage and Crile's method of saline infusion into the carotid artery (see section on Shock).

The anesthetic may be withdrawn several minutes, as a rule, before the operation is completed, and may be replaced with oxygen or aromatic spirits of ammonia. Careful watch should be kept over the patient recovering from the anesthetic, as vomiting almost invariably occurs, and the respiratory passages must be kept clear of vomited material.

Ether vapor is heavier than air, and consequently the fumes during its administration tend to settle in the lower part of the room. As ether is very inflammable, all gas, candle, or lamp lights should be well above the level of the patient. The thermocautery should not be used near the anesthetic. The fact that ether vapor is heavier than air also renders anesthesia most rapid when the mask is held vertically above the face of the patient.

For operations within the mouth various forms of apparatus have been devised for introducing the anesthetic into the respiratory passages without interrupting the operation. The ether may be given in the form of vapor by means of catheters passed into the pharynx through the nose, or directly into the trachea through

the mouth (intratracheal insufflation). In all these methods the ether is vaporized, mixed with air, and pumped in by means of an electric motor, a foot bellows, or a hand bulb.

### NITROUS OXID

For short operations, such as the extraction of teeth, opening abscesses, etc., nitrous oxid gas ( $N_2O$ ) is a suitable anesthetic, though in the practice of the writer its use has become considerably replaced by local anesthetics. It is best given combined with oxygen.

Nitrous oxid has the following advantages over other general anesthetics:

1. It is the safest anesthetic known.
2. It requires very little previous preparation of the patient.
3. The patient can be anesthetized either in a recumbent or a sitting posture.
4. The patient is rapidly anesthetized.
5. Ill after-effects are seldom produced by nitrous oxid.

The disadvantages of nitrous oxid are:

- (1) The appliance required for its administration is very heavy and cumbersome.
- (2) Its effects pass off very rapidly, and it is, therefore, not suitable for operations in the mouth that require more than a few seconds.

By the use of oxygen with the nitrous oxid the period of anesthesia can be lengthened, though the effects pass off as rapidly as with nitrous oxid alone, and with the introduction of the nasal inhaler prolonged operations within the mouth may be successfully undertaken.

The writer, however, reserves nitrous oxid and oxygen for cases in which local anesthesia is contraindicated and unsuitable, and where the operation is not of sufficient consequence to require hospital facilities. But in operations on other parts of the body the combination of oxygen and nitrous oxid is very useful in cases where other anesthetics, such as ether or chloroform, are contraindicated. The writer has had experience with it in operations lasting nearly an hour. By this method the cyanosis induced by nitrous oxid alone is eliminated, and after-effects are more rarely seen. Perfect relaxation of the muscles can be obtained. The time required to anesthetize a patient by this method is rather longer than by nitrous oxid alone. The operator must judge of the amount of oxygen required by watching the face of the patient for cyanosis. The amount of oxygen used ranges from 4 to 10 per cent.

Before administering nitrous oxid, the clothing about the neck of the patient should be loosened, and removable artificial teeth or other foreign bodies taken from the mouth. A cork or rubber prop should be placed between the teeth on the side opposite to that upon which the operation is to be performed. The patient is instructed to take slow full breaths, and is made to go through several respirations of this character with the hood over the face and the air-valve open. When proper breathing has been established, the gas is turned on and air excluded. The time for anesthesia to become complete varies, but averages about a minute and a half. The indications of the onset of the anesthesia are a tremor or shaking of the body, stertorous breathing, and cyanosis. The tremor generally appears first, followed by cyanosis

and stertorous breathing. Stertorous breathing is the surest sign of complete anesthesia, and calls for withdrawal of the anesthetic. The operator usually instructs the patient to hold up one arm, and as soon as this falls to the side, anesthesia is regarded as complete. The effects last about a minute or a minute and a half. After this period has passed the patient gradually regains consciousness, the return often being accompanied by laughing, weeping, and sometimes violence. Consciousness returns in about two minutes, after which no ill effects are felt by the patient, as a rule. The anesthetic effect of nitrous oxid is in part due to deprivation of oxygen, but chiefly to the inherent action of the gas upon the sensory centers. It is unsafe to continue administration of the gas after anesthesia has been induced, and it is, therefore, not available for prolonged operations unless combined with oxygen. The operator must judge of the amount of oxygen required by watching the face of the patient. He can start anesthesia with pure nitrous oxid, and then add oxygen, gradually increasing the percentage as cyanosis appears, just giving enough to eliminate the cyanosis, and yet not enough to counteract the effect of the nitrous oxid.

#### ETHYL CHLORID

Ethyl chlorid, under the names of somnoform, narcotile, etc., is used to a considerable extent for the extraction of teeth and other minor operations. It resembles nitrous oxid in the rapidity of its action and fugaciousness, but several deaths have been reported from its use, so that it is not to be recommended for ordinary practice.

## TRACHEOTOMY

This procedure consists in making an artificial opening in the wall of the trachea to enable respiration to be carried on after obstruction of the larynx. The indication for its performance is occlusion of the respiratory tract above the trachea by inflammation (diphtheria, laryngitis, tuberculosis, etc.), edema of the glottis, tumors, and foreign bodies.

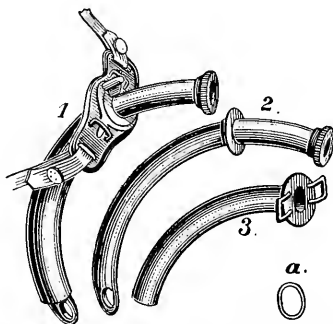


Fig. 27.—Cohen's tracheotomy tubes: 1, Outside tube and obturator; 2, obturator; 3, inside tube; a, cross-section of the tube (Fowler).

The operation is performed as follows: The shoulders are raised and the head thrown back as far as possible, which gives increased room for the operation, brings the trachea near the surface, and puts it on the stretch, thus making it less mobile. A median incision, 3 inches long, is made from the cricoid cartilage downward. The sternohyoid muscles are pulled to either side with retractors, exposing the isthmus of the thyroid gland, which usually lies over the second, third, and fourth



rings of the trachea. Cutting the isthmus should be avoided if possible, owing to its vascularity. The opening in the trachea is made preferably above the isthmus, the latter being pushed down. The trachea is opened by a longitudinal incision large enough to admit the silver tracheotomy tube (Fig. 27), which is then inserted and secured in place. Hemorrhage may occur from division of the inferior thyroid veins, which should be controlled by ligation.

#### LIGATION OF COMMON CAROTID ARTERY AND EXTERNAL CAROTID ARTERY

One of these procedures is carried out as a preliminary to operations on the head and neck where a large portion of tissue is to be removed, as a precaution for the control of hemorrhage, for example, before removal of the upper jaw for sarcoma. It is also done in the treatment of aneurysm of one of these arteries and for arresting hemorrhage which cannot be stopped by the usual methods. The *common carotid artery* is ligated in the superior carotid triangle, just before its bifurcation at the level of the upper border of the thyroid cartilage. An incision 2 inches long is made over the anterior edge of the sternocleidomastoid muscle, through the skin, superficial fascia, platysma myoides, and deep fascia. The pulsation of the artery is now felt for and the carotid sheath opened. The artery lies to the inner side of the internal jugular vein, with the pneumogastric nerve between and behind the vessels. To avoid wounding the vein, the ligature (silk) is passed by means of an aneurysm needle around the artery

from the outer side, care also being taken not to include the pneumogastric nerve in the ligature. If the artery is to be severed, it must be tied in two places and cut between the ligatures.

The *external carotid artery* is also ligated in the superior carotid triangle, just above the level of the upper edge of the thyroid cartilage. After bifurcation of the common carotid, the external carotid lies at first nearer the median line than the internal carotid, for which it must not be mistaken. The branches of the external carotid artery may also be ligated in the superior carotid triangle.

### REVIEW QUESTIONS

Define local anesthesia.

Give some of the local anesthetics in common use, with indications for and mode of administration.

What are the dangers of the hypodermic use of cocaine as a local anesthetic in the region of the jaws?

Define general anesthesia.

Name the three commonest general anesthetics in their order of safety of administration.

Discuss the points to be considered in the selection of ether or chloroform as a general anesthetic.

Describe the stages of ether narcosis.

Give the preliminary measures to be carried out before the administration of ether.

Describe the method of inducing primary ether anesthesia for the extraction of a tooth.

Describe the method of inducing complete ether anesthesia.

What are the most reliable signs that anesthesia is complete?

What are the signs that the patient is coming out of the anesthesia?

What are the signs that the patient is getting too much ether?

What treatment is called for when the depressant effects of the anesthetic begin to show themselves?

What is the treatment of respiratory failure during ether anesthesia?

What is the treatment for sudden heart failure during ether anesthesia?

Give the treatment of vomiting during ether administration.

Is ether vapor heavier or lighter than air? What is the importance of knowing this?

Give the advantages and disadvantages of nitrous oxid as a general anesthetic.

Give the advantages of the use of oxygen in conjunction with nitrous oxid in anesthesia.

What are the indications for the performance of tracheotomy? Describe the operation.

What are the indications for ligating the common carotid or the external carotid artery? Describe the operation.

## CHAPTER XV

### PREPARATION FOR OPERATION

OPERATIONS about the face and jaws should be performed under as aseptic conditions as possible, that is, bacteria should be removed from the field of operation and excluded from it after the operation. In external operations on the face and neck this can be successfully carried out, but within the mouth asepsis is impossible, though even here a satisfactory degree of cleanliness can be approached by removing diseased roots, tartar, etc., and by the use of antiseptic mouth-washes before operation. The skin is prepared by washing with soap and sterile water, followed by alcohol and a 1 : 2000 solution of bichlorid of mercury. A piece of sterile gauze is now applied, and nothing allowed to touch the part until time for the operation. At this time the region of incision may be painted with a 5 per cent. solution of iodine, which destroys any bacteria in the deeper layers of the skin which may have escaped the preliminary cleansing. The hands of the operator and of his assistant, and of any one else who is to handle instruments or dressings that will touch the wound, are sterilized by scrubbing for ten minutes with soap and water, followed by alcohol and the bichlorid solution. The surgeon should preferably wear sterile rubber gloves. It is hardly necessary to add that the instruments, dressings, towels, and, in fact, everything that comes in contact with the wound must be sterile. For opera-

tions within the mouth, these precautions are all carried out, except, of course, that the mouth cavity cannot be rendered sterile. Some degree of asepsis, however, can be attained by painting the mucous membrane in the field of operation with tincture of iodine just before making the incision.

#### INSTRUMENTS COMMONLY REQUIRED IN OPERATIONS

*Knives.*—A *scalpel* (Fig. 28) is a broad-bladed knife for making incisions through the skin and tissues.




Fig. 28.—1, Scalpel; 2, bistoury (Gibbon).

A *bistoury* (Fig. 28) is a narrow, sharp-pointed knife for opening abscesses and making small incisions.




Fig. 29.—A, Scissors curved on the flat; B, straight scissors; C, angular scissors (Fowler).

*Scissors* (Fig. 29), which may be straight or curved, are used for cutting tissue, sutures, ligatures, dressings, etc.

*Dressing forceps* are used to grasp the tissue while dissecting it during the operation, to handle dressings, etc.

*Hemostatic forceps* (Fig. 30) are instruments used to clamp blood-vessels to arrest hemorrhage.

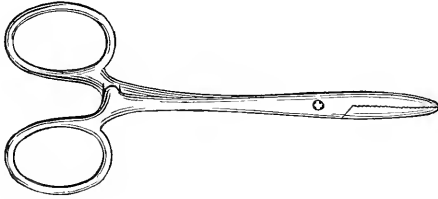


Fig. 30.—Hemostatic forceps (de Nancrede).

A *grooved director* (Fig. 31) is a long, probe-like instrument, which is grooved on one side to act as a guide for the knife-blade.

*Probes* are usually made of silver, and have a ball-like end, which permits them to easily follow the course of sinuses and spaces within the tissue.



Fig. 31.—Grooved director (Fowler).

*Allis' forceps* (Fig. 32) are long toothed forceps which can be clamped, and are useful as retractors and for grasping tissue during dissection.

A *blunt dissector* is a dull-bladed instrument used in dissecting tissues without cutting them.

An *osteotome* is a chisel-shaped instrument used in conjunction with a mallet for cutting bone.

*Retractors* are instruments used to draw back the

skin and other tissues to give a better view of the field of operation.

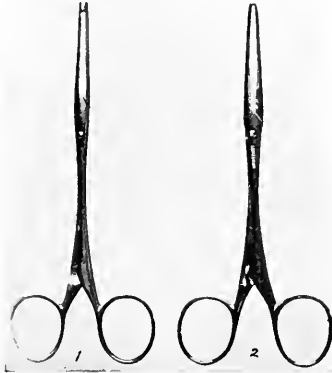


Fig. 32.—Allis' forceps (Gibbon).

The instruments required in an ordinary operation are: Knife, scissors, dressing forceps, several pairs of




Fig. 33.—Rack-and-pinion mouth-gag (Fowler).

hemostatic forceps, grooved director, probe, and retractors.

For operations within the mouth a mouth-mirror, mouth-gag (Fig. 33), and tongue depressor (Fig. 34) are required in addition to the other instruments. In operations on the jaw bone the surgical engine and various burs, drills, etc., are required. For the extraction of teeth dental forceps (Fig. 35) and elevators (Fig. 36) are used.



Fig. 34.—Bosworth's tongue depressor (Keen's Surgery).

The *surgical engine* designed by Cryer (Fig. 37) is indispensable for operations about the jaws, and is to be preferred to the chisel and mallet in general bone surgery. It is adaptable for trephining and osteoplastic operations in brain surgery, drilling holes in the operative treatment of fractures, removal of bone in osteomyelitis, and, in fact, for all the uses to which ordinary bone



instruments are put. The engine is modeled after the cord dental engine, but is larger, and the hand-piece and

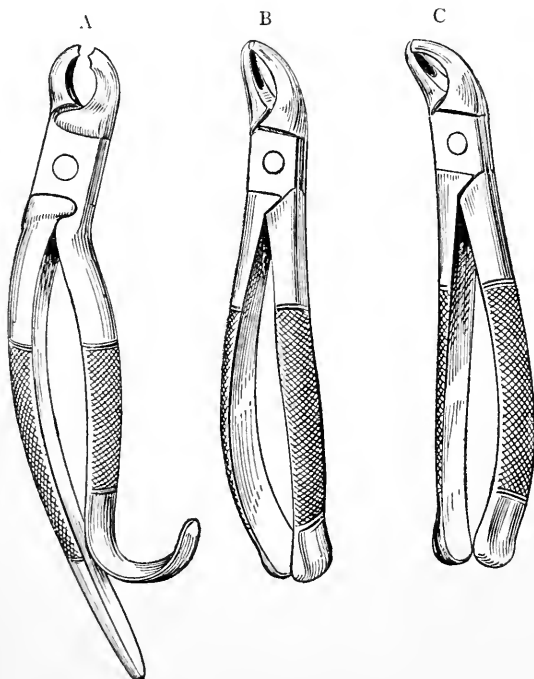


Fig. 35.—A, Lower molar forceps; B, Universal upper forceps (Cryer); C, Universal lower forceps (Cryer).

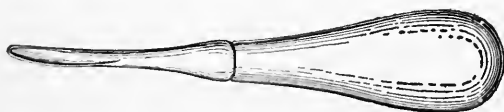

Fig. 36.—No. 3 elevator.

accessories are fitted for heavier work than the dental engine. Saws, trephines, drills, and burs, of various

sizes and shapes, may be obtained to fit the hand-piece. The engine may be driven by hand or by an electric motor.

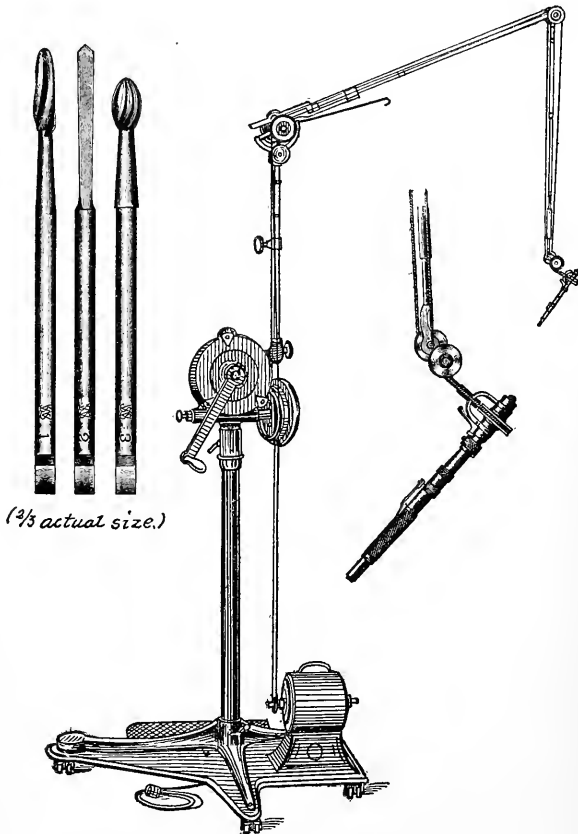


Fig. 37.—Cryer's surgical engine, spiral osteotome, drill, and bur.

The *spiral osteotome* is a useful instrument used for cutting bone with the surgical engine. For brain surgery it is furnished with a special guard, to protect

the dura and cerebrum from its point. With this instrument the bone cutting necessary for an osteoplastic flap can be cut in the skull in less than two minutes.

#### LIGATURES, SUTURES, ETC.

A *ligature* is a thread used to tie around a blood-vessel after the latter has been secured with hemostatic forceps, and also to tie around pedunculated growths. Ligatures are nearly always composed of catgut (No. 1, plain) or silk. In tying ligatures a double square knot should always be used. In the case of a large vessel it is better to secure this with a third knot.

A *suture* is a thread used with a needle to close a wound. Many materials are used for sutures, the commonest being catgut, plain and chromicized, silk, silkworm-gut, horsehair, and silver wire.

Sutures may be *continuous*, a single thread being used to close the wound from one end to the other, or *interrupted*, in which case a series of threads is used at intervals.

Catgut is absorbed by the tissues, and sutures of this material do not have to be removed by the surgeon. Plain catgut usually is absorbed in three or four days, while chromicized catgut remains from ten to twenty days. All other suture materials are non-absorbable, and, therefore, surface sutures of these require removal. In wounds of the skin of the face, where there is little tension, sutures of fine silk or horsehair are least liable to leave a scar. Horsehair is also the least irritating in the mucous membrane of the mouth, and does not swell from absorption of fluid. In larger wounds, where there is considerable tension, interrupted sutures of silkworm-gut are the most satisfactory.

In using non-absorbable material it is better to make interrupted sutures, as it is easier and less painful to remove them, especially in children. Many varieties of *needles* are employed for inserting sutures. For the skin a needle with a cutting-edge is necessary. When possible, it is better to use a straight needle than a curved one, as this does away with the necessity for a needle-holder. A pair of hemostatic forceps makes a convenient needle-holder, but in time this spoils it for any other purpose. Sutures should be tied firmly, but not too tightly. Undue tension causes sloughing of the tissue and cutting out of the sutures. The edges of the tissue should be approximated and not made to overlap or fold in. The suture is tied with a double square knot, with the exception of silkworm-gut, which may be tied with a single surgeon's knot. Silver wire sutures are used in some cleft-palate operations to hold the two halves of the palate in apposition.

#### DRAINAGE MATERIALS

Glass and rubber tubing, rubber dam, gauze, and strands of catgut or silkworm-gut are used among other materials for this purpose. Glass tubes are used practically only after abdominal operations.

Rubber tubing may be used to drain abscess cavities in which the discharge is very free. Holes should be cut in the rubber tube at intervals. It may be sutured to the edge of the wound with silkworm-gut or a safety-pin may be put through it at each end to prevent it from slipping out of the wound.

Strips of gauze may be employed for drainage. They should be packed in lightly, and drainage is considerably

aided by previously moistening the gauze. It is not necessary to use iodoform gauze about the face.

Strips of rubber dam cut with serrated edges are useful for providing drainage, and have the advantage over gauze that that they do not become clogged with secretions from the wound and act as plugs.

Strands of catgut and silkworm-gut are sometimes tied together and used for draining superficial wounds.

*Dressings* for wounds consist of pads of sterile gauze, secured in place by means of adhesive plaster and

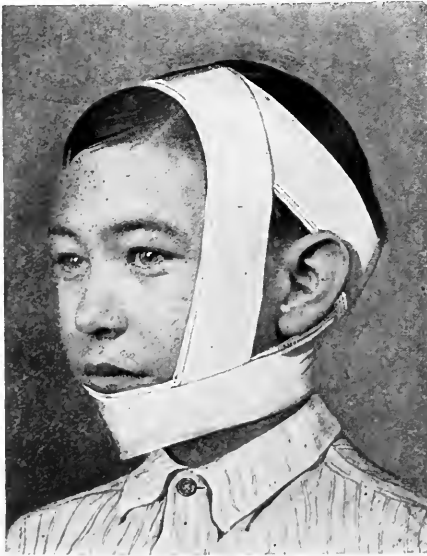

Fig. 38.—Barton's bandage (Fowler).

bandages. Zinc oxid adhesive plaster should always be used in contact with the skin.

*Bandages* are made of muslin or of gauze. Gauze is, as a rule, satisfactory for holding ordinary dressings

in place, but where considerable support and firmness are required, as in the case of fractures, the muslin bandage is preferable.

The *Barton* bandage (Fig. 38), or one of its modifications, is the most useful about the head.

For this bandage muslin or gauze 2 inches in width is used, and is applied as follows: Starting at the occiput, the bandage is carried to the vertex, then beneath the chin, to the vertex, to the occiput, around the *front* of the chin, ending at the occiput. These turns should be repeated three times. When additional stability is required, this may be secured by ending with a turn or two around the forehead. The direction in which the turns are made may vary with the individual case. The Barton bandage is used in dressing fractures of the jaws, and in some cases alone suffices to maintain immobility. In cases of fracture of the angle or ramus the turn in front of the chin would tend to pull the jaw too far back. A modification of the Barton bandage is used in these cases, the bandage passing from the occiput to the vertex, under the chin, to the vertex, to the occiput, *under* the chin, to the vertex, to the occiput, *under* the chin, to the vertex, ending at the occiput. This modification is also useful in holding dressings to the jaw for any purpose.

#### REVIEW QUESTIONS.

Describe the measures for sterilization to be carried out before performing an operation.

Define the following: Grooved director, osteotome, ligature, suture.

Give the suture materials in common use, and the indications for each.

Describe the Barton bandage.

## SPECIAL SURGERY

---

### CHAPTER XVI

#### HYPERTROPHY

By the term *hypertrophy* is meant an overgrowth of tissue in which the individual cells maintain their normal physiologic functions. The overgrowth may be due either to an increase in the size of the individual cells, or to an increase in their number (*hyperplasia*), or both. The term hyperplasia is not confined to hypertrophic conditions alone, but is applied to any increase in number of cellular elements, such as that seen in inflammatory conditions and in neoplasms.

*Hypertrophy* may be inherited or acquired.

In *inherited* hypertrophy, certain portions of the body may be the seat of the overgrowth, *e. g.*, the gums and alveolar process. In cases of this kind the gum tissues may be so redundant as to completely hide the teeth. The lips bulge out, giving the patient the appearance of a receding chin (Figs. 39, 40).

*Acquired* hypertrophy may be the result of increased demand for work on the tissue, mild irritation continued over a long period of time, overnutrition, and other factors. Acquired hypertrophy of the gums is caused by irritation of various kinds. A badly fitting plate may cause the gum tissue in the anterior part of the

mouth to grow down between the plate and the front of the bony ridge, giving the appearance known as "double lip." In the roof of the mouth a deep vacuum chamber with sharp edges will often cause hypertrophy. A badly fitting crown or clasp may set up irritation about the neck of a tooth, thus causing hypertrophy of the

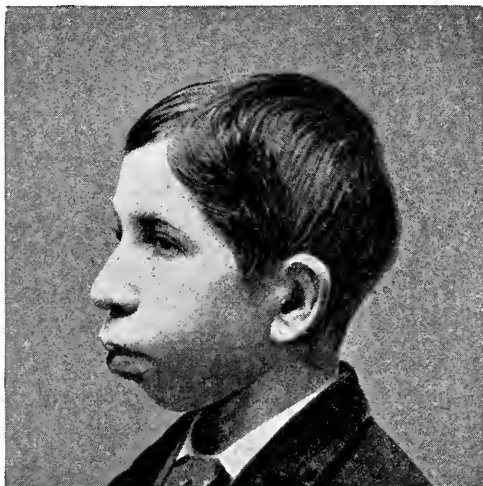


Fig. 39.—From photograph of a lad suffering from hypertrophy of the gums and alveolar process (after Cryer).

gum. In the same way a cavity in a tooth often becomes filled with hypertrophied gum tissue.

**Treatment.**—In inherited hypertrophy this consists in removal of the excess of gum tissue by operation. To do this it may be necessary to enlarge the opening of the lips by an incision on the face. Where the teeth are embedded in the hypertrophied tissue, they often have to be removed. When the parts have healed,



an artificial denture may be put in to replace the lost teeth.

In *acquired* hypertrophy of the gums the first thing to do is to remove the cause, whether it be a badly fitting plate, vacuum chamber, or crown. An overgrowth of gum tissue in a tooth cavity may be removed after cauterizing with trichloroacetic acid. In the case

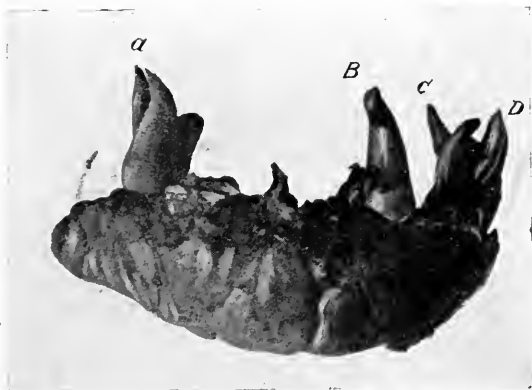


Fig. 40.—Tissue removed from upper jaw of patient shown in Fig. 39 (after Cryer).

of “double lip” under local anesthesia the hypertrophied tissue can be cut away with gum scissors, the base of the growth having been previously ligated, if necessary, to control hemorrhage. If the growth is pedunculated, it can be ligated and cut off. Where the hypertrophy is only slight, removal of the cause and painting the parts with astringents, such as glycerol of tannic acid, will generally be sufficient treatment.

## NEOPLASMS OR TUMORS

A *neoplasm* or *tumor* is a new-growth of cells, resembling in structure, as a rule, the organ or tissue from which it arises, but having an atypical arrangement of cells and no useful function.

**Etiology.**—Certain facts are known as to the etiology of tumors, but we are still in the dark, to large extent, and can only resort to theory—and none of these theories is adequate to explain all tumors.

*Cohnheim's Theory.*—According to this theory, certain cells which, in the course of development, have been displaced from their normal relationship or have failed to grow with the rest of the body, retain their embryonic properties, and later on in life take on renewed growth, resulting in tumor formation. This theory can be applied in part to certain forms of tumors, particularly teratomata and some new-growths of malignant type, but cell displacement cannot account for all tumors.

The *microbic theory* might suffice to explain the cause of cancer, but not of other tumors. It has not yet been found that certain micro-organisms set up certain forms of new-growth.

All that we can say at present is that there is a change in the biologic properties of cells giving origin to tumors, and can only theorize on what brings about this change. *External stimulus* may favor this change, and it is well known that certain forms of tumor are especially apt to follow trauma or irritation, but this factor is not essential.

*Heredity, age, and sex* seem to act as predisposing factors in the causation of certain kinds of tumors.

**Classification.**—Tumors, as a rule, are classified in accordance with their resemblance to normal tissues. Inasmuch as all tissues have a framework of connective tissue holding the cells proper in place, tumors of epithelial type are not composed of epithelial tissue alone, but contain connective tissue as well, though the essential nature of the tumor lies in the epithelial elements. Three great types of tumors are, therefore, recognized, according to the tissues from which they are derived:

- |  |   |  |
|--|---|--|
| I. Epithelial type.....                        | } | Papilloma (warts).<br>Adenoma (glandular tissue).<br>Neuroma (nerve tissue).<br>Carcinoma (embryonic epithelial tissue).<br>Epithelioma (embryonic squamous celled epithelial tissue. Subvariety of carcinoma).  |
| II. Connective-tissue type.                    | } | Fibroma (fibrous tissue).<br>Myoma (muscular tissue).<br>Chondroma (cartilaginous).<br>Osteoma (bony).<br>Angioma (vascular).<br>Lymphoma (lymphatic tissue).<br>Lymphangioma (lymphatic vessel tissue).<br>Myxoma (mucous connective tissue).<br>Lipoma (fatty tissue).<br>Sarcoma (embryonic connective tissue).<br>Myeloma (bone-marrow). |
| III. Mixed type, composed of both tissues..... | } | Teratoma (dermoid cyst, odontoma).   |

Two varieties may be combined, giving rise to compound tumors, such as fibromyoma, adenofibroma, osteochondroma, angiofibroma, osteosarcoma, myelosarcoma, etc. There are also many subvarieties of the different types.

A *cyst* is a hollow tumor, usually lined with epithelium, and with fluid or semifluid contents.

**Clinical Classification of Tumors.**—Clinically, tumors are divided into two types, *benign* and *malignant*. An intermediate class exists, having some of the properties of each.

*Benign* tumors are characterized by their slow growth, the fact that they are usually circumscribed and encapsulated, do not have a deleterious effect on the organism at large, and do not tend to recur after removal. They closely resemble in structure the adult tissues from which they spring, and do not infiltrate surrounding tissues.

*Malignant* tumors are, as a rule, not encapsulated or circumscribed. They rapidly infiltrate the surrounding tissues, are accompanied by pain, have a deleterious effect on the general system, tend to form metastases in other parts of the body, and tend to recur after removal. They resemble embryonic tissue in their structure. Examples of this type are carcinoma and sarcoma. Most of the other tumors are benign, though they may cause ill effects or even death by pressure on vital structures.

To the *intermediate* type belong certain forms of tumors microscopically malignant that infiltrate surrounding tissues very slowly, do not form metastases, and do not tend to recur after removal. Benign growths that tend to undergo malignant change may also be placed in this group.

*Carcinomata*, which are composed of epithelial cells of embryonic type embedded in a stroma of connective tissue, are divided into—(1) scirrhus, or hard cancer, and (2) medullary, encephaloid, or soft cancer, according

as the connective tissue or the epithelial tissue preponderates. Thus a tumor composed of much connective-tissue stroma with few epithelial cells would be *scirrhous*, while one containing many epithelial cells and but little stroma would be medullary. Another variety of carcinoma, composed of flat or squamous epithelium, is known as *epithelioma*. The more cells, in proportion to the connective tissue, the more malignant the tumor.

*Sarcomata* are divided into several varieties according to the types of cells of which they are composed. Thus we have *small round-celled sarcoma*, *large round-celled sarcoma*, *spindle-celled sarcoma*, *giant-celled sarcoma*, etc. The smaller the cells, as a rule, the more malignant the growth. Thus, small round-celled sarcoma is very malignant, while giant-celled sarcoma has comparatively little malignancy.

#### DIFFERENTIAL DIAGNOSIS BETWEEN CARCINOMA AND SARCOMA.

CARCINOMA.	SARCOMA.
Occurs late in life.	Occurs at any age, most commonly early in life.
Not encapsulated.	May be encapsulated and circumscribed.
Grows less rapidly.	Grows more rapidly.
Adjacent lymphatics involved.	Lymphatics, as a rule, not involved.
Forms metastases through the lymphatics.	Forms metastases through the blood-vessels.
More apt to form metastases.	Less apt to form metastases.
Tendency to ulceration.	Does not tend to ulcerate.

Positive diagnosis can generally be made by removing a portion of the growth and examining under the microscope.

NEW-GROWTHS COMMONLY ASSOCIATED WITH THE FACE  
AND JAWS.

I. <i>Epithelial type</i> .....	{	Papilloma (warts).
		Adenoma (salivary glands).
		Carcinoma (epithelioma).
		Sebaceous cysts.
	{	Fibroma (in subcutaneous tissue).
		Lipoma (in subcutaneous tissue).
		Angioma (of skin or gum).
II. <i>Connective-tissue type</i> .	{	Chondroma.
		Osteoma.
		Osteosarcoma.
		Sarcoma.
		Giant-cell myeloma.
III. <i>Mixed type</i> .....	{	Mixed tumor of parotid gland.
		Odontoma.

*Carcinoma* may affect the lip, tongue, cheek, or salivary glands, particularly the parotid. It usually takes the form of epithelioma, and occurs in greatly varying degrees of malignancy (Fig. 41). In some cases it is found as a deep-seated, slowly spreading ulceration of the cheek (rodent ulcer), having apparently no general ill effects, while in others it may rapidly infiltrate the floor of the mouth, the tongue, cervical lymphatics, pharynx, and larynx, resulting shortly in death.

The treatment for carcinoma is removal if seen early enough. The entire growth and some healthy tissue beyond the apparent limits of the disease should be removed. This includes bone and cervical lymphatics if they are involved. Secondary operations sometimes have to be performed to make flaps to cover denuded areas, and prosthetic appliances may be used to replace lost tissue.

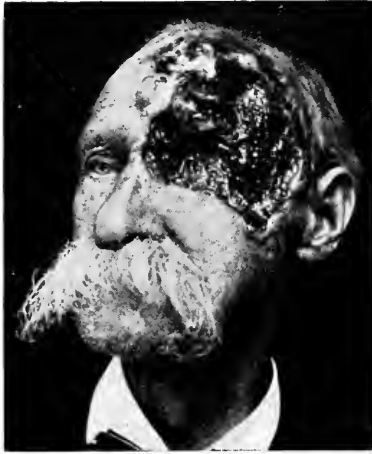

Fig. 41.—Rodent cancer of the face (Fowler).

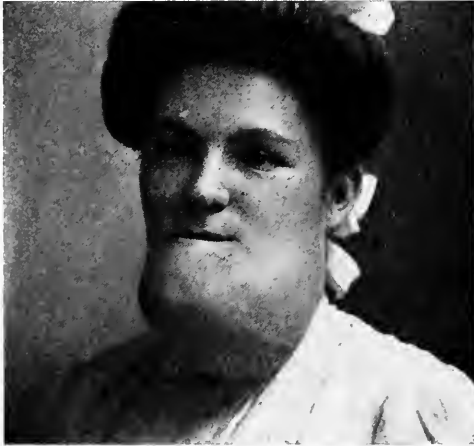

Fig. 42.—Osteosarcoma of the lower jaw (after Cryer).

An *osteoma* is a simple benign tumor of bone, and is rare in this region of the body. Removal of the growth

will not be followed by recurrence. Bony tumors of the jaws are usually malignant, *osteosarcoma* (Fig. 42), and are to be treated as such—*i. e.*, by removal of the whole of the growth and some of the surrounding healthy tissue. Sarcoma frequently affects the upper jaw, involving the maxillary sinus.

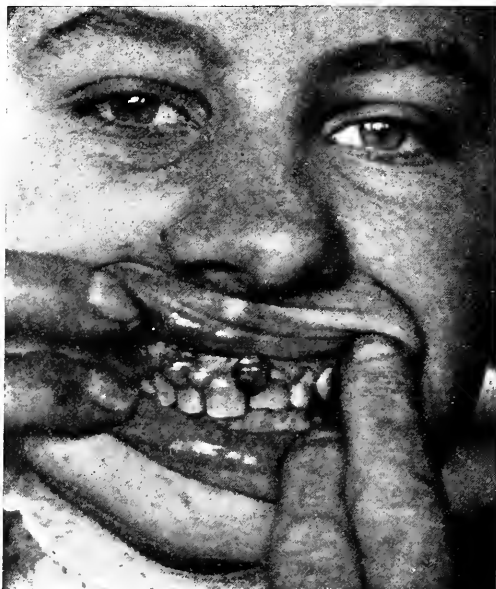

Fig. 43.—Epulis (after Cryer).

*Epulis* is a clinical term applied to the commonest group of tumors in the mouth. From the derivation of the word, it is any growth on the gum, but the name is usually applied to a circumscribed connective-tissue growth from the alveolar ridge, attached with a broad or narrow pedicle, and covered over by normal mucous



membrane, except as the latter may undergo secondary ulceration due to pressure necrosis, infection, etc. From both the clinical and pathologic standpoints several varieties are described. *Fibrous epulis* is hard, grows slowly, gradually displacing teeth in its neighborhood, and microscopically is a fibroma. A second variety is

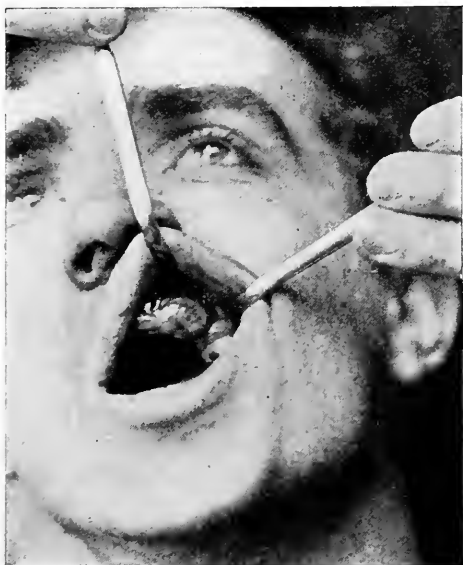

Fig. 44.—Malignant epulis (Binnie).

the *angiofibroma*, in which the microscope shows numerous distorted capillary channels running through the fibrous tissue. This form of epulis presents a bright red, spongy appearance and bleeds easily. The third common variety of epulis is the *giant-cell myeloma*, which consists of a stroma of fibrocellular tissue, with numerous giant-cells scattered throughout. These growths are

dusky red in color and grow with comparative rapidity. All forms of epulis spring from the periosteum or from the bone itself, and, therefore, to prevent recurrence it is important in the treatment not only to remove the apparent growth itself, but also to curet the point of origin or bur away some of the bone from which it arises. Teeth involved in the growth should be extracted. If left they may invite recurrence by interfering with complete removal of the tumor.

The use of the actual cautery is an efficient means of controlling the hemorrhage when operating on such vascular structures.

An *odontoma* or *odontome* is a tumor derived from the special cells concerned in tooth development (James). In general, odontomas may be classified into two great groups, the solid and the cystic. The commonest form of the solid group is the *calcified composite odontoma*, which consists of a conglomerate mass of tooth structure formed of the various component tissues of a tooth massed together without any definite arrangement. It usually takes the place of one of the natural teeth, and in a case of this kind one of the normal teeth is missing from the arch. There is usually a swelling of the jaw in the region involved which may cause no discomfort unless infection takes place. If the latter occurs, the swelling becomes painful, and there may be a discharge of pus either within the mouth or externally through sinuses leading down to the diseased tooth tissue. The *x-ray* is useful in distinguishing a growth of this kind from necrosis of the jaw bone. The treatment consists in removal of the abnormal tooth structure.

The principal forms of *cystic* odontomas are (1) follicular and (2) radicular.

(1) The *follicular cyst* or *odontocoele* is a sac lined with epithelium, filled with fluid, and containing an unerupted normal or abnormal tooth. It is caused by an abnormality in development of the dental follicle. The accumulation of fluid causes a distention of the jaw bone, the bone oftentimes becoming so thin as to give a crackling, parchment-like sensation. The fluid is usually clear and straw colored, but may be converted into pus by infection. The treatment consists in removal of the encysted tooth, evacuation of the fluid, and removal of the epithelial lining of the cavity. This epithelium secretes the fluid, and if not thoroughly removed the operation may be followed by recurrence.

(2) The dental *root cyst* is a growth arising about the apex of an erupted tooth that has usually been devitalized, and is probably the result of infection, whereby the epithelial cells normally found in the peridental membrane are stimulated to grow and secrete fluid. The fluid causes a destruction and sometimes distention of the jaw bone, as in the case of the follicular cyst. Here, too, the fluid is normally clear, but may be converted into pus by secondary infection. The treatment consists usually in removal of the affected tooth, evacuation of the cyst contents, and removal of the lining membrane by curetment.

*Mixed tumors of the parotid* are composed of various tissues, sometimes even containing cartilage and bone.

## LEUKOPLAKIA

Leukoplakia consists of white, slightly raised patches, varying in size and irregular in shape, situated on the mucous membrane of the tongue, cheek, lips, and palate. They are especially apt to be found on the part of the cheek corresponding to the line of occlusion of the molar and premolar teeth. The patches consist of dead epithelium that has not been cast off from the mucous membrane.

**Etiology.**—The cause is not known, but leukoplakia is frequently found in persons with unclean mouths, those who use tobacco and alcohol to excess, or who are fond of hot condiments, pepper, pickles, etc. In some cases the disease apparently has a syphilitic origin.

**Symptoms.**—In addition to the description already given, the patches may be painful, particularly when anything irritating is taken into the mouth. They cannot be scraped off without leaving an ulcerated, bleeding surface.

**Prognosis.**—If all irritation be discontinued after treatment of early cases, the condition is not likely to return. If allowed to continue without treatment, leukoplakia has a tendency to develop into epithelioma.

**Treatment.**—This consists in removal of the patches, either with the knife or, preferably, with the actual cautery. The parts are then to be kept clean. Chemic caustics are not to be used, as they only cause irritation and tend to aggravate the condition.

## REVIEW QUESTIONS

Define hypertrophy, hyperplasia, neoplasm.

Give the etiology, symptoms, and treatment of the various forms of hypertrophy of the gums.

Discuss the etiology of tumors.

Give a classification of tumors.

Give the clinical classification of tumors, and two examples of each variety.

Give the varieties of carcinoma.

Give the varieties of sarcoma.

Give the differential diagnosis between carcinoma and sarcoma.

Name several of the commoner tumors of the face and jaws, giving the tissue from which they spring.

Give the symptoms and treatment of carcinoma of the lower jaw.

Give the pathology, symptoms, and treatment of epulis.

What is an odontoma? Give treatment.

Give the etiology, symptoms, prognosis, and treatment of leukoplakia.

## CHAPTER XVII

### SYPHILIS OR LUES

THE recognition of this disease by the dentist is very important, as he is at any time liable to meet with its oral manifestations, some of which are among the most contagious lesions of the disease.

**Etiology.**—Infection occurs through some break in the surface of the skin or mucous membrane. It may be of genital or of extragenital origin. The commonest mode of infection is through sexual intercourse, but the disease may be acquired innocently through infected drinking-cups or other utensils, a razor, kissing, etc. Surgeons have become infected by wounding their fingers while operating on syphilitic patients. Infection may be transmitted from one patient to another by unclean surgical or dental instruments. The infecting organism is the *spirochæta pallida* or, more correctly, the *treponema pallidum*, discovered by Schaudinn about 1905. The organism can be found in lesions of all stages of syphilis. It is a pale, spiral organism, with from ten to twenty turns, a flagellum at either end, and is endowed with active motility. It can only be stained by special methods. It is taught that the tertiary stage of syphilis is not contagious. In this stage probably the spirochetæ, though they are present, have lost their virulence.

Syphilis is divided into the primary, secondary, and tertiary stages.

(1) **Primary Stage.**—The typical lesion is the *chancre*, which appears at the point of infection about three

weeks after exposure. It begins as a small, slightly raised papule, which slowly grows larger, and finally breaks down, discharging purulent material, leaving a crater-like ulcer, the size of a twenty-five-cent piece, with raised edges and indurated base. The chancre is very rarely painful. At the same time there is an enlargement of the lymphatic glands of the region, which do not coalesce and are not painful.

(2) **Secondary Stage.**—The symptoms of this stage begin to appear about six weeks after the chancre. There is a general adenopathy or lymphatic enlargement, particularly of the postcervical and epitrochlear glands, anemia, slight fever, headache, joint pains, shedding of the hair, iritis, and deafness. The principal secondary symptom is the skin eruption. This begins as the roseolar or macular eruption, which progressively becomes papular, pustular, and even ulcerative. Examples of all these lesions may be found at the same time. They occur symmetrically on the two sides of the body, vary from a pin-head to a split-pea in size, and do not itch. The tubercular syphilid is a large pustule of the secondary stage occurring in severe cases.

*Mucous patches* are papules occurring on moist skin surfaces or on mucous membranes. They are found on the genitalia, under the breasts of women, and on the mucous membrane of the mouth. In the mouth they usually appear first on the tonsils, then at the sides of the tongue, and the inner surface of the cheek and lips. Mucous patches are oval, grayish-white, slightly raised, and moist, and leave a raw, bleeding surface when scraped away. The lesions in the mouth are accompanied by sore throat and hoarseness.

After the secondary stage, if the case has been treated properly, we may have no further symptoms. Otherwise there is an *intermediate period* of eighteen months to three years, followed by the tertiary stage.

(3) **Tertiary Stage.**—Tertiary symptoms manifest themselves in the skin as deep-seated ulcers known as *rupia*, which are less numerous than the secondary eruption and are not symmetric. In other tissues the typical tertiary lesion is known as the *gumma*, which is a deep-seated localized softening, which becomes necrotic, and may liquefy and find its way to the surface of the body, discharging a dirty brown fluid. Gummata may be found in any tissue of the body, muscle, bone, liver, and other abdominal organs, tongue, palate, and brain. When they break down, they cause great loss of tissue, which is not repaired.

**Oral Manifestations of the Different Stages of Syphilis, and the Diagnosis from Other Lesions.**—The initial lesion of syphilis in rare cases may occur on the lip, tongue, palate, or tonsil. This is associated with early enlargement of the submaxillary lymphatic glands. Chancre of the lip is to be diagnosed from epithelioma by the following points:

CHANCRE.	EPITHELIOMA.
May occur at any age after puberty.	Occurs in middle age, as a rule.
Is not painful.	May be very painful.
Early enlargement of submaxillary glands.	Late enlargement of submaxillary glands.
Some induration at base.	Wide-spread induration.
Followed by secondary eruption.	Not followed by skin eruption.
Improves on antisiphilitic treatment.	Not improved by medicinal treatment.
Develops rapidly.	Develops slowly.
Spirochetæ present.	Microscope reveals cancer tissue.



In the *secondary stage* we find *mucous patches*, and the patient complains of sore throat. The postcervical lymphatic glands are enlarged.

Mucous patches are to be differentiated from leukoplakia and from simple ulcers.

## MUCOUS PATCHES.

## LEUKOPLAKIA.

May occur at any age.	Usually occur in middle life.
History of chancre and other lesions of syphilis.	History of excessive smoking or other irritation in the mouth.
Glandular involvement.	No glandular involvement.
Easily scraped off.	Scraped off with difficulty.
Painless.	Painful.
Spirochæta pallida present.	No spirocheta.
Responds to treatment by mercury.	Does not respond to mercury.

*Simple ulcers* are rounded instead of oval, with reddish borders, are painful, and there are no other lesions of syphilis present.

In the *tertiary stage* we may find a *gumma* of the tongue, lip, cheek, soft palate, or hard palate, or its sequel, necrosis of the bones of the roof of the mouth, and cleft palate (Fig. 45).

A gumma of the tongue is differentiated from carcinoma of the tongue as follows:

## GUMMA.

## CARCINOMA.

Not painful.	Painful.
Develops more rapidly.	Develops more slowly.
Very little induration.	Great induration.
History and other signs of syphilis.	Microscope reveals nature of the growth.

Syphilitic ulcer is to be differentiated from tuberculous ulcer.

## SYPHILITIC ULCER.

Not painful.  
 Rough, undermined edges.  
 Spirochetæ may be found.  
 History and other lesions of syphilis.

## TUBERCULOUS ULCER.

Painful.  
 Pale, with smooth edges.  
 Tubercle bacilli found.  
 Other lesions of tuberculosis.

The oral manifestations of **hereditary syphilis** are: **Hutchinson's teeth**, which are typically seen in the permanent central incisors, though the lateral incisors



Fig. 45.—Nasal deformity due to syphilis. In this case the cartilaginous and bony septum was completely destroyed, allowing the nose to fall in and the two nostrils to become fused into one opening. There is scarcely any trace of the *alæ nasi* (Eisendrath).

and other teeth may be poorly developed. The teeth are barrel shaped, with a semilunar notch on the cutting-edge. Cracks or fissures (rhagades) around the mouth

are common in infants with hereditary syphilis, which later in life leave radiating linear scars. The ordinary secondary and tertiary symptoms—mucous patches, glandular enlargement, gumma, necrosis, cleft-palate, etc.—are found just as in acquired syphilis.

**Newer Methods of Diagnosis and Treatment.**—Within the last ten years our ideas as to the diagnosis and treatment of syphilis have been revolutionized by three great advances: (1) The establishment of the *Treponema pallidum* as the cause of syphilis; (2) the application of the serum complement-fixation test or Wassermann reaction; (3) chemotherapy by means of organic arsenical compounds (salvarsan, etc.).

(1) By means of the dark field illuminator microscopic diagnosis may be made early in a large proportion of cases by finding the treponema in the exudate from the primary lesion, where formerly it was frequently necessary to wait until secondary symptoms appeared before a diagnosis of syphilis could be made. We are now in a position, therefore, to commence treatment several weeks earlier in the disease than formerly, and consequently with a greater chance of cure.

(2) The *Wassermann reaction* consists in the detection in the blood of a syphilitic individual of certain substances produced through the action of the *Treponema pallidum*. It is out of the question to attempt a description of the test here, and the reader is referred to works on immunology and laboratory diagnosis. Of far greater importance to the clinician is the method of obtaining the specimen of blood from the patient and the significance of the reaction.

At least 2 c.c. of blood should be obtained from the

patient either by puncturing the end of the finger or by withdrawing it from a vein at the bend of the elbow with a hypodermic syringe. The blood should be placed in a sterile tube and sent to the laboratory as soon as possible for examination. The patient whose blood is to be tested should not have had any antisyphilitic treatment for at least three weeks prior to the removal of the blood. Otherwise a negative reaction may be obtained in a case that should be positive. Alcohol taken within the previous twenty-four hours may have the same effect. A positive Wassermann reaction means the presence of living spirochetes in the body. As a rule the test does not become positive until at least two weeks after the appearance of the chancre, so for positive diagnosis earlier than this we resort to microscopic examination for the *Spirochæta pallida* in the exudate. The Wassermann reaction is strongly positive in practically every case of secondary syphilis, while in tertiary syphilis it is positive in from 80 to 90 per cent. of cases. It may also be positive in cases of latent syphilis presenting no active symptoms. A single negative Wassermann reaction does not rule out syphilis. A strongly positive reaction practically always means syphilis.

(3) For the past five years a synthetic arsenical compound discovered by Ehrlich, dioxydiamidoarsenobenzol, known under the trade name salvarsan, and popularly as "606," has been extensively used in the treatment of syphilis, and has resulted in immense improvement over our old methods.

**Treatment.**—The treatment of syphilis should not be commenced until the diagnosis of the primary lesion is certain. This may be made in the great majority of

cases, especially if no local treatment has been applied, by microscopic examination of the exudate from the chancre for the *Treponema pallidum* (*Spirochæta pallida*). Later a positive Wassermann reaction will be obtained. In cases seen early, therefore, it is seldom necessary to wait until secondary symptoms appear before beginning treatment. It is now recognized that vigorous early treatment with modern remedies will frequently result in a rapid cure, even in the prevention of secondaries or of a positive Wassermann reaction.

Before commencing antisyphilitic treatment the mouth and teeth should be got into the best possible condition. Tartar should be removed, cavities filled, and all useless and unhealthy teeth and roots extracted. The patient should diligently use the tooth-brush and a mouth-wash during the entire period of treatment. Danger of salivation by mercury is thus lessened. Mucous patches may be painted with a solution of chromic acid, 4 grains to the ounce of water.

The most efficient treatment for syphilis consists in the intravenous administration of salvarsan, the average dose being 0.6 gram. One injection frequently suffices to make all symptoms disappear in a very short time, though not permanently. But in the majority of cases two or three injections at intervals of a week or ten days are necessary. The salvarsan should be followed by mercury, for example, 1 to 3 grains of the protiodid per day by mouth for several weeks. The course of treatment should be guided by the Wassermann reaction. A reaction still positive after a full course of treatment, even in the absence of symptoms, calls for more salvarsan and mercury. After cessation of treatment the serum should

be tested every three months or oftener for at least two years, and should be returned negative for this period before the patient may with safety be pronounced cured. As a rule, the later in the course of syphilis that treatment is begun the more difficult it will be to effect a cure, as evidenced by disappearance of symptoms and permanently negative Wassermann reaction. If seen in the early stages we are justified in regarding syphilis as a curable disease.

Mercury may also be given in the form of mercurial ointment as inunctions in the skin, dose, 1 dram daily, or hypodermically in the form of the bichlorid,  $\frac{1}{24}$  grain daily. In late cases of syphilis mixed treatment should be given, *i. e.*, potassium iodid is added to the mercury. It is given in beginning doses of 10 grains, increased up to 1 dram three times a day. The potassium iodid is best given in milk after meals.

### REVIEW QUESTIONS

Give the etiology of syphilis.

Give the period of incubation and the various stages of syphilis, with the duration of each.

Give the principal lesions of the three stages of syphilis.

Describe the oral manifestations of the three stages of syphilis, acquired and hereditary.

Give the differential diagnosis of chancre and epithelioma of the lip.

Give the differential diagnosis of mucous patches and leukoplakia.

Give the differential diagnosis of gumma of the tongue and carcinoma.

What do you know of the serum diagnosis of syphilis?

What is the prophylactic mouth treatment in syphilis? Give the principal reason for carrying it out.

Give the constitutional treatment of syphilis.

Discuss the "salvarsan" treatment of syphilis.

## CHAPTER XVIII

### STOMATITIS

STOMATITIS is inflammation of the mucous membrane of the mouth. There are many varieties of stomatitis—almost as many as the causes that produce it:

1. Simple stomatitis.
2. Aphthous stomatitis.
3. Ulcerative stomatitis.
4. Gangrenous stomatitis.
5. Parasitic stomatitis (thrush).
6. Toxic stomatitis (mercurial, arsenical, etc.).

1. **Simple** or **catarrhal stomatitis** is usually seen in children, and is caused by digestive disturbances, particularly in warm weather, and bad hygienic surroundings.

The *symptoms* are heat and tenderness in the mouth, redness of the mucous membrane, fetor of the breath, and fever.

*Treatment*.—Regulate the bowels, and keep the mouth clean with a solution of boric acid.

2. **Aphthous stomatitis** presents the symptoms of catarrhal stomatitis, with the addition of numerous small, round, yellowish-white vesicles on the lips, cheek, and tongue. These soon break, and leave small shallow ulcers with a red areola.

The *cause* of aphthous stomatitis has not been definitely settled. Aphthæ are liable to appear in the mouths

of children during the digestive disturbance at the time of teething. The general opinion now tends to the belief that the lesions are not bacterial in origin, but have something to do with nervous derangement.

The *treatment* is the same as for catarrhal stomatitis.

3. **Ulcerative stomatitis** occurs both in children and in adults, and is usually the result of bad hygienic surroundings. It sometimes occurs in epidemics.

*Symptoms.*—The mucous membrane of the mouth is very much inflamed, breaks down, and leaves shallow ulcers covered with yellowish exudation. The breath is extremely fetid, and there is excessive flow of saliva. The infection may spread to the sockets of the teeth, causing the latter to loosen and drop out. Fever and digestive disturbances are often associated conditions.

*Treatment*—The internal administration of potassium chlorate in 5-grain doses is beneficial, combined with a mouth-wash of potassium chlorate in the proportion of 10 grains to the ounce of water. The teeth should be cleaned, all cavities filled, and decayed roots removed. The ulcers may be touched with silver nitrate, pure carbolic acid, or trichloroacetic acid. The application of powdered subnitrate of bismuth to the ulcers is often soothing.

4. **Gangrenous stomatitis** is a further stage of ulcerative stomatitis in which the destruction of tissue extends beneath the mucous membrane.

*Causes.*—It is seen in persons whose vitality has been much lowered, as through alcoholism, and who live in poor hygienic surroundings. These factors, in conjunction with lack of attention to cleanliness of the mouth and teeth, are responsible for the disease.



*Symptoms.*—The disease starts as an ulcer, usually in the vestibule of the mouth, which becomes larger, the inflammation spreading to the deeper tissues, which slough, forming a foul, yellow, stringy mass. The teeth become very loose and may be lost. The flow of saliva is increased, and the swelling interferes with speech and mastication. Marked constitutional symptoms sometimes are present, the result of absorption of toxic matter from the mouth. The temperature may be as high as  $103^{\circ}$  F., and the pulse weak and rapid. The gangrenous process may spread through the cheek, or the infection may pass into the deep cellular tissue of the neck and about the glottis, suffocating the patient.

The *prognosis* is unfavorable, probably about 50 per cent. of the cases being fatal.

*Treatment.*—*Local* measures consist in keeping the mouth as clean as possible. The stringy necrotic tissue should be trimmed away with scissors once a day, and after swabbing the surface with cotton soaked in dioxid of hydrogen, it should be touched with pure nitric acid, care being taken not to allow the acid to touch other than the parts desired. The patient should be given a mouth-wash of potassium permanganate 1 : 2000, which should be used frequently throughout the day.

*General Treatment.*—Where constitutional symptoms are marked, the patient should have rest in bed. Stimulants and tonics are indicated. The bowels should be freely opened with calomel in repeated doses of  $\frac{1}{4}$  grain every hour for four doses, followed by half an ounce of magnesium sulphate, if necessary. Ten or fifteen drops of tincture of the chlorid of iron and  $\frac{1}{30}$  grain of strychnin

four times a day are usually sufficient in the way of stimulation. Half an ounce of whisky four times a day is often beneficial, particularly in alcoholic subjects.

The diet should be liquid at first, until the patient can chew and swallow solid food. As soon as possible the patient should be allowed to sit up, as the danger of pneumonia is thereby lessened.

**Noma**, or **cancrum oris** (Fig. 46), is a form of gangrenous stomatitis occurring in infants, sometimes in epi-

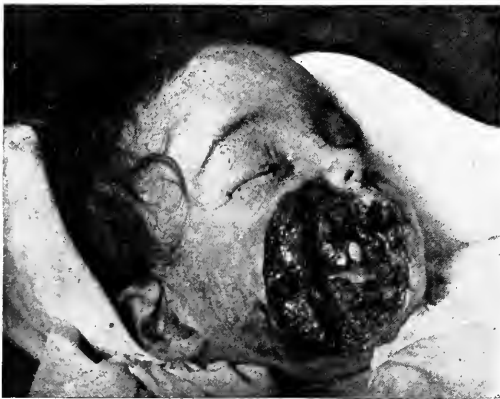

Fig. 46.—Noma (after Schamberg).

demic form. It occasionally follows infectious diseases, such as measles or whooping-cough, and occurs in badly nourished children in poor hygienic surroundings.

Various forms of bacteria have been isolated from cases of the disease, and the spirillum and fusiform bacillus described by Vincent have been found.

*Symptoms.*—The disease commences as a swelling of the cheek, with fetor of the breath and salivation. This is followed by a small ulcer at the buccal margin of the

gum, which rapidly spreads to the cheek and alveolar process. The tissue of the cheek becomes black, and finally sloughs away, exposing the mouth. The disease is, as a rule, unilateral. The effects on the general system are very marked. The temperature is high, the pulse weak and rapid, and the child lies in a semi-comatose condition.

*Prognosis.*—Nearly all cases are fatal.

*Treatment.*—The ulcer should be cauterized with nitric acid on an orange-wood stick, or with the actual cautery. The parts should be frequently washed with a 1 : 4000 solution of potassium permanganate. The gangrenous tissue of the cheek must be removed. If the patient survives, the resulting disfigurement may be corrected, to some extent, by plastic operations. The general condition of the patient requires stimulation in the form of strychnin and brandy. The latter may be given in doses of five to ten drops every three or four hours.

5. **Parasitic Stomatitis.**—The commonest form of stomatitis parasitica is known as *thrush*, and is due to a fungus—the *saccharomyces albicans*. The disease occurs in children and is usually associated with gastro-enteritis.

The mouth presents numerous small white elevations which, on removal, leave a raw surface, with slight bleeding. The disease affects the tongue, cheeks, lips, and hard and soft palate.

*Treatment* consists in removal of the patches by wiping out the mouth with cotton soaked in a solution of boric acid (10 grains to the ounce) every two hours. Attention should also be given to the general condition of the patient.

**Vincent's angina** is an exudative inflammation of the pharynx and the tonsils which occasionally affects the mouth. It is characterized by the formation of a false membrane resembling that of diphtheria. The disease is associated with the presence of a spirillum and a fusiform bacillus, described by Vincent, which are readily stained in smears.

In the mouth the grayish-white patches may appear on the gums about the necks of the decayed teeth. They are easily removed, leaving an eroded surface. Sometimes deeper ulceration occurs.

The *treatment* is the same as for thrush and for ulcerative stomatitis. The local application of salvarsan powder is said to be specific.

*Syphilitic stomatitis* is described under that disease.

**6. Toxic Stomatitis.**—*Mercurial stomatitis* is an inflammation of the mouth due to the continued administration of small doses or the ingestion of large doses of mercury. It is also seen in artisans who work in mercury.

The inflammation is not produced by the direct action of the mercury itself upon the oral mucous membrane, but the drug lowers general vital resistance, thus permitting the growth of pathogenic bacteria within the mouth. Patients taking mercury whose mouths have been previously put in hygienic condition and are kept clean very rarely get mercurial stomatitis.

*Symptoms.*—The disease starts with tenderness of the gums and pain on bringing the upper and lower teeth together. The gums around the necks of the teeth are reddened. There is a metallic taste in the mouth and an increase in saliva (ptyalism). Later, the salivation becomes profuse, there is intense fetor of the breath, and the gums become much swollen and of a purple

color. The teeth loosen and may be lost. In severe cases ulceration of the gums and necrosis of the alveolar process may result.

*Treatment.*—The condition can practically always be prevented by appropriate prophylactic treatment before putting a patient on a course of mercury and by careful watch for the earliest signs of the onset of the disease. Before administering mercury, when the drug is to be given for any length of time, the mouth should be brought into a thoroughly hygienic condition. All deposits should be removed from the teeth, cavities filled, and useless roots extracted. During the entire course of treatment by the mercury a mouth-wash should be used, and the teeth kept thoroughly clean. If the slightest tenderness of the teeth on bringing them together occurs, reduce the dose of mercury to one-half, and if the symptoms do not subside, discontinue the mercury altogether for a time. The mouth must be thoroughly cleaned, as in the case of prophylactic treatment. The inflamed gums may be touched once daily with tincture of iodine. The best mouth-wash is a 1 : 2000 solution of potassium permanganate, used every few hours. A 1 : 6000 solution of bichlorid of mercury sometimes acts well, tending to show that it is not the local action of mercury that causes the stomatitis. Potassium chlorate, 10 grains to the ounce of water, may also be used as a mouth-wash. Potassium iodid in 10-grain doses may be given internally.

*Arsenic* may cause a localized inflammation of the gum about a tooth from carelessness in its use in devitalization of the dental pulp. The inflammation may spread to the deeper tissues and cause necrosis of the bone.

The treatment consists in the immediate application of the antidote—dialyzed iron—if arsenic is accidentally allowed to touch the gum. If inflammation occurs, the gum may be painted with tincture of iodine.

*Lead-poisoning* does not cause stomatitis, but is often manifested in the mouth by a blue line at the margin of the gums around the necks of the teeth. This is due to a deposit of sulphid of lead in the gum tissue, and not on the teeth. Consequently, it cannot be scraped off. The gums are not inflamed. Other symptoms of lead-poisoning are present, including colic, constipation, wrist-drop, etc.

#### REVIEW QUESTIONS

What is meant by stomatitis?

Give the etiology, symptoms, and treatment of ulcerative stomatitis.

Give the etiology, symptoms, and treatment of gangrenous stomatitis.

What is noma? Give the etiology, symptoms, prognosis, and treatment.

What is Vincent's angina?

Give the etiology, symptoms, and treatment of mercurial stomatitis.

What are the oral manifestations of lead-poisoning? How would you diagnose the condition?

## CHAPTER XIX

### ALVEOLAR ABSCESS; OSTEOMYELITIS; NECROSIS; ACTINOMYCOSIS

#### TREATMENT OF ALVEOLAR ABSCESS

THE treatment of acute alveolar abscesses differs in details, but not in principle, according as to whether the offending tooth is to be saved or not. The technic of treatment for preservation of the tooth is discussed fully in works on operative dentistry. While it is possible to preserve and render useful many teeth which have caused alveolar abscesses, it is also undoubtedly true that too many of these teeth are retained and remain as sources of irritation for years. There is also a general hesitancy about extracting a badly decayed tooth that is causing an alveolar abscess. The patient is told to wait until the abscess subsides, as extraction might cause the abscess to spread. The patient consults the family physician, who refers him back to the dentist, and thus the abscess often does "spread," extending to the bone, setting up osteomyelitis and necrosis.

The treatment of an alveolar abscess caused by a tooth too badly decayed to be preserved is extraction of the tooth as soon as possible. Frequently this will be all the treatment necessary, as the pus will be evacuated through the socket. In other cases the pus must be allowed to escape through an incision made in the gum

over the swelling. Where there is too much swelling to render an attempt to extract the tooth certainly successful, this should be first reduced by letting out the pus, but the tooth should be removed as soon as possible. Dioxid of hydrogen should never be used in these cases, either in cleaning out the root-canal when the tooth is to be preserved, or in the abscess cavity. An attempt should always be made to prevent the pus from an alveolar abscess from pointing externally on the face or neck. This may be attained by early incision within the mouth, by the avoidance of hot poultices or hot-water bags on the face, and by the application of cold and pressure externally. Chronic abscesses in which there is necrosis of the end of the root of the tooth are sometimes cured by so-called amputation of the root, but frequently do not heal until the tooth is extracted. It is unwise to attempt to save teeth that have been the cause of abscesses opening into the maxillary sinus or externally on the face or neck. They should be extracted.

#### OSTEOMYELITIS AND NECROSIS OF THE JAW BONES

Osteomyelitis is an inflammation of the marrow of bone.

**Etiology.**—*General diseases*, such as syphilis, tuberculosis, and infectious fevers, interfere with the nourishment of bone, giving opportunity for the entrance and growth of pyogenic micro-organisms.

*Local infections* following alveolar abscess, stomatitis, or fracture of the jaw bone may set up osteomyelitis. The use of dioxid of hydrogen about an infected area



communicating with the bone is one of the commonest causes of osteomyelitis. When this drug comes in contact with organic material free oxygen is given off, and in an inclosed space, such as an alveolar abscess with a small opening, it produces a species of explosion, driving the infected material before it through the cancellated tissue of the bone. The hypodermic injection of cocain or any drug into inflamed tissues to produce anesthesia for the extraction of a tooth may act in a similar manner by carrying infection from around the tooth or from the gum surface into the surrounding tissues and thence to the bone. Osteomyelitis may thus occur quite independently of the toxic action of the drug itself.

*Poisons*, such as mercury, arsenic, cocain, and phosphorus, cause osteomyelitis either by their direct action or by so lowering the resistance of the tissues that pyogenic bacteria gain entrance.

Mercury may cause osteomyelitis in those who work with the metal, or the disease may be a late stage of the stomatitis that follows overdosage of the drug.

Arsenic and cocain may cause a direct poisoning of the tissues when applied locally as therapeutic agents.

*Phosphorus* causes osteomyelitis of the jaws in workers at match-making who pay little or no attention to hygiene of the mouth. The phosphorus in solid form or by its fumes probably gains entrance to the jaw bone through devitalized carious teeth, or through an inflamed periodontal membrane. The white or yellow phosphorus is the poisonous form. The red, amorphous variety is non-poisonous. Since the passage of prohibitive legislation against the use of white phosphorus in match

manufacture necrosis from this source has been eliminated.

Osteomyelitis from any of the foregoing causes usually ends in *necrosis* or death of a portion of the bone *en masse*. Necrosis may also be caused by traumatism, whereby a portion of the bone is cut off from its blood-supply. Bones are nourished through blood-vessels derived from the marrow and from the periosteum, so that necrosis is essentially the result of *starvation* from interference with either of these sources by inflammation or injury, or by derangement of the trophic nerves, which govern the nutrition of the bone.

When necrosis occurs, the dead bone becomes separated in the form of a *sequestrum*. The periosteum, if not destroyed, forms a shell of new bone about the sequestrum, known as the *involucrum*. Between the two the inflammatory process goes on, forming pus, which makes its escape through openings on the surface of the bone.

**Symptoms.**—In osteomyelitis the usual signs of inflammation are present. There are deep-seated pain and tenderness over the bone affected. In the case of the mandible, the side of the face affected becomes greatly swollen. The general symptoms—fever and prostration—are usually greater than those caused by an ordinary alveolar abscess. Grave septicemia and even pyemia, with metastatic abscesses of other parts of the body, may result. The pus eventually makes its way to the surface of the bone, and is evacuated in the mouth or points on the neck, leaving sinuses. When necrosis occurs, the sequestrum can be felt by passing a probe up the sinus. In the mouth, the appearance

of a red papilla through which pus exudes is an indication of dead bone underneath. In the early stages of necrosis the sequestrum is not separated from the rest of the bone, but later it becomes quite loose and may be thrown off spontaneously.

The different causes of necrosis may give rise to variations in the character of the sequestrum. In syphilis, the dead bone is usually black and soft. In tuberculosis it is commonly white and soft. In phosphorus poisoning it is white, hard, and brittle, giving rise to the term "pumice-stone" necrosis.

The necrosis may be slight in extent, or it may involve the entire bone. In the mandible, providing the periosteum is not destroyed, an entire shell of new bone may be formed. Regeneration of bone after necrosis in the upper jaw is rare. The x-ray is a valuable guide in ascertaining the condition of the bone and the extent of the sequestrum.

**Treatment.**—If a cause be present, such as a devitalized tooth, it should be removed. An ice-cap applied to the side of the face will often give relief. When there are indications that pus is present, it should be evacuated, through the mouth if possible, and if not, by as small an external opening as is necessary to give drainage.

When dead bone is felt, the surgeon must be guided by the indications of the individual case and by experience whether to remove it or wait until separation of the sequestrum occurs. It is better to remove small portions from time to time than to do a radical operation too early. In this way the osteogenic cells are more likely to be preserved for the formation of new bone, and less

disfigurement results. If new bone is formed coincidentally with destruction of the old bone, the continuity of the jaw is preserved, and pathologic separation or fracture through the diseased area is not so liable to occur. Some cases, however, on account of the effects on the general system, demand early and thorough eradication of the necrotic area. A cardinal rule is to remove sequestra from within the mouth when possible, thereby avoiding scars on the face and neck.

Loose sequestra should, of course, be removed at once. After scraping away dead bone the walls of the cavity left may be smoothed by the surgical engine. When a loose sequestrum has been taken out, the walls of the cavity will have a smooth and velvety feeling to the finger. After the operation the parts may be lightly packed with a strip of gauze to control any oozing; this should be removed on the following day, and the mouth syringed out with a solution of boric acid several times a day. Dioxid of hydrogen should never be used to irrigate these cases. Sinuses on the neck will close almost immediately if all the dead bone has been removed. They should not be packed with gauze. If some dead bone remains, suppuration will still go on through the sinus, in which case a small gauze or rubber drain may be inserted and covered with a sterile gauze pad held in place by a modified Barton bandage.

The general condition of the patient in osteomyelitis and necrosis of the jaws requires careful attention. If there is much fever, the patient should be kept in bed, on liquid diet, and stimulation given if required.

## ACTINOMYCOSIS OR STREPTOTRICHOSIS

This is a chronic infective disease occurring in cattle, and rarely in man. It is usually due to the actinomyces or ray fungus, but the same symptoms may be caused by other allied organisms belonging to the general streptothrix group, so that the term streptotrichosis is preferable.

The appearance of the lesion varies according to the part affected, and the presence or absence of pyogenic organisms. The head and neck are involved in more than half of the cases. Frequent involvement of the jaw gives rise to the name "lumpy jaw."

**Etiology.**—The ray-fungus, or streptothrix bovis, is the usual cause of the disease. It appears under the microscope as a mass of radiating threads with clubbed ends. Other forms are found, consisting of branching threads, and sometimes with spores. The organism is believed to gain entrance into the body by grain or straw, causing a lesion of the mucous membrane of the digestive or respiratory tract or the skin. The tonsils or carious teeth may be points of entrance. Thus the disease is particularly apt to occur in persons residing in the country.

The disease spreads in the body by a gradual invasion of the tissues surrounding the point of inoculation. It spreads both by continuity and contiguity of tissue—that is, it passes onward without regard to anatomic boundaries. The lymphatics are not apt to be involved except when the disease is associated with an infection by pyogenic organisms. Metastases may take place through the veins.

**Symptoms.**—In cases of superficial infection the disease begins as a small, soft, and tender nodule which

slowly spreads, giving to the skin a purplish mottling. The nodules break down, forming sinuses which discharge a thick pus in which the typical "sulphur granules" are found. These granules are composed of masses of the fungi, which can be demonstrated under the microscope. It is practically impossible to make the diagnosis without the microscopic demonstration of the organism.

The lesions show a tendency to heal in one portion and to break down in another. In healing, much cicatricial tissue is formed. The lesions are tender, but are not, as a rule, accompanied by great pain. The chronic cases rarely present constitutional symptoms. In acute cases complicated by infection with pyogenic organisms, or by the formation of metastases, symptoms of septicemia or of pyemia may be present.

The **prognosis** of chronic and localized cases depends on the situation of the disease. Where vital organs are not involved, the chances for recovery are good. The principal danger of the disease lies in the introduction of pyogenic organisms into the lesions, resulting in septicemia or pyemia. The formation of metastases also renders the prognosis unfavorable. The mortality of superficial lesions is about 10 per cent., and of the deeper tissues about the jaws, 30 per cent.

**Treatment.**—The most successful forms of treatment are the internal administration of potassium iodid, and total excision of the part affected. Potassium iodid may be given in doses of 15 to 60 grains a day. Operative interference, in which all the diseased tissue could not be removed, has been followed by rapid metastases. Tincture of iodine locally may have a beneficial effect.

Injection of killed cultures of the organism has met with some success.

#### REVIEW QUESTIONS

What is the treatment of an abscess caused by a decayed tooth, opening into the maxillary sinus, or externally?

Define osteomyelitis. Give etiology.

What is necrosis? What are the essential factors in its production?

Define sequestrum, involucrum.

Give the symptoms of osteomyelitis and necrosis of the mandible.

Give the treatment of osteomyelitis and necrosis.

Give the etiology, symptoms, prognosis, and treatment of actinomycosis.

## CHAPTER XX

### DISEASES OF THE MAXILLARY SINUS

THE maxillary sinus or antrum of Highmore may be the seat of catarrhal inflammation, empyema or suppurative inflammation, impacted teeth, tumors, and polypi.

**Catarrhal inflammation** is usually the result of extension of catarrh from the nose and associated air-cells. The inflammation extends from the middle meatus of the nose, by way of the hiatus semilunaris and the ostium maxillare. The mucous membrane becomes swollen and secretes mucus. The swelling of the mucous membrane in the region of the ostium maxillare sometimes shuts off that opening, and the accumulation of mucus gives rise to pain from pressure. In simple acute catarrhal inflammation of the antrum it is not, as a rule, necessary to open into the sinus. The inflammation usually subsides by spraying and applications through the nose.

**Suppurative inflammation** or **empyema** of the maxillary sinus may be caused by infection extending from the nose and associated air-cells, or from penetration of bacteria and their products through the floor of the antrum from the teeth. The latter is not so common as might be supposed, because when a tooth becomes diseased, and an abscess from its root threatens to break into the antrum, the floor of that cavity over the



particular root becomes thickened by hyperplasia of the bone tissue, thus protecting the antrum from infection. There are also more cases in which teeth are lost through diseases of the antrum than cases in which the teeth are primarily diseased and cause infection of the antrum. Foreign bodies, such as rubber drainage-tubes, may become lodged within the maxillary sinus and keep up chronic suppuration.

The *symptoms of acute empyema* of the maxillary sinus are pain, swelling, and tenderness over the affected side of the face. There may be a history of a diseased tooth on the affected side and examination may reveal it. Breathing through the nose on that side may be impaired or completely obstructed. A flow of pus from the nostril can usually be obtained by holding the head down and forward with the affected side uppermost. *Transillumination*, by placing a small electric light in the mouth, may show a dark area on the affected side, but the small size of the antrum may make this sign of little value. The *x-ray* is a valuable aid in diagnosis, a cloudiness of one side of the face often indicating maxillary sinus disease. The *x-ray* in a great many cases shows exactly which tooth is involved.

*Chronic* suppuration of the maxillary sinus may be accompanied by little or no pain or swelling, and the only symptom may be a flow of pus from the nostril or an opening into the mouth. A badly decayed tooth may be present, the *x-ray* showing its root discharging into the sinus.

Suppuration of the maxillary sinus may be complicated by infection of the frontal and sphenoid sinuses and the ethmoid cells. If the frontal sinus be involved, the patient

complains of pain in the supra-orbital region, and there will often be a flow of pus from above into the anterior portion of the nose. When the sphenoid and ethmoid cells are affected, the pus passes backward and collects on the posterior wall of the pharynx.

*Treatment.*—This consists in making an opening into the maxillary sinus and draining it. If an abscess from a diseased tooth has opened into the antrum, the tooth should be extracted at once. Conservative treatment of the tooth should not be attempted, as sufficient drainage cannot be obtained through the root. After extraction of the tooth, usually a bicuspid or molar, the opening into the antrum may be made larger by drilling through the socket with the surgical engine.

*Selection of the Place of Opening the Maxillary Sinus when No Tooth-socket is Available.*—There are three places to be considered: (a) Through the canine fossa. (b) Through the nose. (c) Through the alveolar process just above the second bicuspid tooth.

(a) In a great many cases an opening through the canine fossa will give the best access to the antrum, but we often cannot be sure that an opening at this point will not enter the nose instead of the maxillary sinus. The opening through the canine fossa also may not enter the lowest point of the sinus, and drainage will be imperfect.

(b) Drainage through the nose is also often imperfect, and in making an opening in this region we are working in the dark, to a large extent.

(c) The alveolar process over the second bicuspid tooth, or the same region if the tooth has been previously lost, is for most cases the best point to open the antrum,

as we are generally sure to reach the antrum from this position, and drainage is more perfect as the cavity is opened at its lowest point. The bone also is usually thin in this region. Sometimes a counter-opening from the nose is advisable for freer washing out of the cavity.

After the antrum has been opened, it is washed out several times with warm antiseptic solution. The fluid should be forced through the antrum until it runs out from the nostril. This is done every day and kept up until all odor and discharge disappear. Drainage-tubes should not be placed in the opening. If this threatens to close too early, a small plug of cotton may be inserted daily. If the discharge is slow in clearing up, tincture of iodine, a few drops to half a glass of water, may be used in flushing out the cavity. If dead bone is felt, it must be removed, and necrotic mucous membrane must also be scraped away.

*Impacted teeth* are sometimes lodged in the wall of the maxillary sinus. Their position is well shown by the  $x$ -ray. Treatment consists in removal.

**Tumors** of various kinds—carcinoma, sarcoma, osteosarcoma, etc.—may involve the antrum. Their treatment is by early operation, just as in the case of malignant growths of other regions.

*Polypi* are pedunculated growths covered by mucous membrane. They are an overgrowth of the submucous tissue and contain cystic areas filled with mucus. They usually follow chronic inflammatory conditions. Another form of polyp is fibrous in character, springing from the periosteum. Polypi are felt as soft, semisolid masses that bleed easily.

Treatment is by enlarging the opening into the antrum

from the mouth if one already exists; if not, make a new opening with the surgical engine, grasping the polypi with special long-beaked forceps, and twisting or tearing them out. Bleeding after removal is controlled by packing the antrum with gauze, which is changed in twenty-four hours, for three or four days, after which the opening may be allowed to close.

#### REVIEW QUESTIONS

Name the principal diseases of the antrum of Highmore.

Give etiology, symptoms, and treatment of empyema of the antrum of Highmore.

What factors should guide the operator in selecting a place for opening a diseased maxillary sinus when no tooth socket is available?

Give the diagnosis and treatment of polypi of the maxillary sinus.

## CHAPTER XXI

### DISEASES OF THE SALIVARY GLANDS AND THEIR DUCTS

THE salivary glands are subject to inflammation and tumors, while their ducts may be obstructed by inflammation, tumors, calculus, or foreign bodies.

**Inflammation.**—The parotid gland is subject to *epidemic parotitis* or *mumps*, a specific inflammation, the nature of which is not known, and infection by various bacteria. Typhoid fever is sometimes followed by suppuration of the parotid gland.

**Tumors.**—The most common tumors of the parotid gland are the so-called *mixed tumors*, or teratomata, which consist of several varieties of tissue, including fat, fibrous tissue, muscle, glandular tissue, and cartilage.

*Carcinoma* of the parotid gland sometimes occurs, but is rare.

A swelling over the region that may be mistaken for a tumor of the parotid gland is sometimes caused by enlargement of the lymph-node which lies over the gland.

Swelling of the parotid gland, whether due to inflammation or neoplasm, is generally associated with false ankylosis of the temporomandibular joint. The patient has pain and difficulty in opening the mouth. There is also nearly always some facial paralysis on the affected

side, due to pressure on the filaments of the seventh nerve as they pass through the parotid gland.

The **submaxillary gland** may also be affected by inflammation of tumors. These give rise to a swelling in the submaxillary triangle.

*Stenson's duct*, the outlet of the parotid gland, sometimes becomes obstructed by an extension of inflamma-

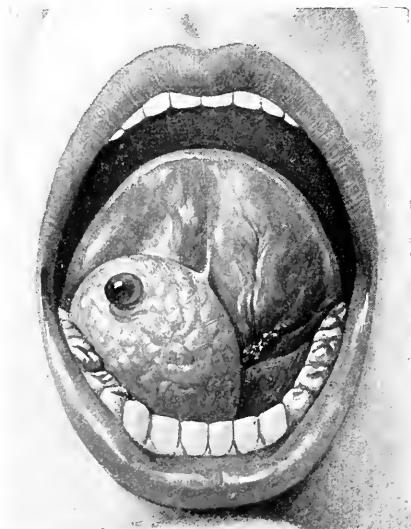


Fig. 47.—Ranula. Note the prominent tumor on right side of floor of the mouth, pushing the tongue upward (Eisendrath).

tion from the mucous membrane of the mouth. It may be relieved by probing.

**Ranula.**—Obstruction of the ducts of the submaxillary, sublingual, or mucous glands gives rise to a swelling in the floor of the mouth caused by retention of the secretion of these glands, known as *ranula* (Fig. 47). A ranula is, therefore, a retention cyst.

*Etiology.*—The obstruction may be caused by salivary calculus or a foreign body, such as a tooth-brush bristle, within one of the ducts, or by inflammation or a tumor involving or causing pressure upon the ducts. The encysted material may be mucus, cheesy matter, or hard calculus.

*Symptoms.*—The floor of the mouth presents a smooth swelling, usually soft, of a grayish color, which pushes the tongue up and interferes with eating and speech. The tongue may protrude from the mouth. There is, as a rule, very little pain associated with the swelling, which slowly increases in size. Puncture of the swelling is followed by a flow of thick mucus, the retained secretion of the gland involved. When the swelling contains calculus, it is hard.

*Treatment.*—This consists in attempting to open the duct of the gland by dislodging the cause of the obstruction and evacuating the fluid. If this cannot be done, a new outlet is to be made. This, in some cases, may be brought about by means of a “seton,” which is a piece of silk ligature passed through the mucous membrane near the duct with a curved needle and tied in place. The silk sloughs off in a few days, leaving a new opening. In other cases a V-shaped flap is cut in the mucous membrane over the swelling, turned in, and sutured. Sometimes the entire sac must be dissected out.

**Salivary fistula** is a communication of one of the salivary glands, usually the parotid, with the surface of the face, through which the saliva is discharged. Salivary fistula is caused by obstruction or injury to Stenson’s duct, which may be due to traumatism, such as a gunshot-wound, carelessness or unavoidable injury in opera-

tions in the region of the duct, obstruction of the duct from calculus or inflammation, or ulceration following malignant disease. The opening on the face is just beneath the zygoma, and is usually very resistant to treatment, owing to retraction of the scar tissue and the constant escape of saliva.

*Treatment.*—Any obstruction to the normal outlet of saliva into the mouth must be first removed, if possible, or a new connection made between the duct and the mouth. After this has been done, the opening on the face must be closed by cutting the scar tissue away from the bone, to which it may be very adherent, freshening the edges of the opening, and bringing them together with sutures. Sometimes, when a large space is to be filled, it is necessary to close the opening with a flap of skin turned up from the neck.

**Ludwig's Angina.**—Ludwig's angina is the name given to a rapidly spreading cellulitis of the tissue beneath the floor of the mouth.

*Etiology and Pathology.*—The infection gains entrance through the roots of decayed teeth, through peridental inflammation, through the tonsils, or through the ducts of the submaxillary glands. The invading organism in the majority of cases is the *Streptococcus pyogenes*. The inflammation first involves the submaxillary lymphatics, and spreads thence into the surrounding cellular tissue, passing sometimes into the region of the glottis.

*Symptoms.*—The disease begins as a swelling in the floor of the mouth, accompanied by pain and increased flow of saliva. Later, the submaxillary region becomes indurated, swollen, and tender. The rapid increase in



the swelling and in the other symptoms is characteristic of the disease, its entire course sometimes not occupying more than twenty-four or forty-eight hours. The mucous membrane of the floor of the mouth may be pushed up to the level of the tops of the lower incisor teeth. The tongue is forced up, causing the mouth to be held open. The disease usually commences on one side, but not infrequently both sides soon become involved. The local symptoms are often accompanied by high temperature and rapid pulse, and the patient may be prostrated by absorption of the toxic products of the infection. The cellulitis may rapidly spread to the glottis, causing suffocation of the patient.

*Prognosis.*—If the case is seen very soon after its onset and proper treatment instituted, recovery generally follows. Cases seen late, or allowed to go without proper treatment, are usually rapidly fatal.

*Treatment.*—This consists in free *external* incision and drainage as soon as possible after the diagnosis has been made. Incision in the floor of the mouth is not sufficient. Two openings should preferably be made, one in the median line of the neck, just beneath the chin, and the other laterally, in the submaxillary triangle. The incisions must be carried beneath the deep fascia, for this is where the inflammation is taking place. The two openings should be connected by passing hemostatic forceps from one to the other, and a rubber drainage-tube inserted between them. Pus usually is not obtained in early cases, but this incision almost invariably checks the spread of the inflammation. The incision in the median line may be carried up to, but should not pass through, the mucous membrane of the mouth. At this

point, as in the case of all median raphés, no blood-vessels are apt to be wounded. These incisions are usually followed by subsidence of the swelling within a few hours, accompanied by a fall of temperature and general improvement in the patient's condition. The opposite state of affairs has been seen so often to follow postponement of free incision that delay is to be severely condemned. If the case is seen late, when the process has begun to occlude the glottis, tracheotomy in addition to the other measures offers the only hope of recovery. The general condition of the patient requires liquid diet and stimulants

#### REVIEW QUESTIONS

Give several causes and the effects of swelling of the parotid gland.

Give the etiology, varieties, symptoms, and treatment of ranula.

Give the etiology and treatment of salivary fistula.

Define and give the etiology, pathology, symptoms, prognosis, and treatment of Ludwig's angina.

## CHAPTER XXII

### DISEASES OF THE TONSILS AND OF THE LYMPHATIC GLANDS

THE tonsils normally undergo atrophy as age advances, but may become hypertrophied, in which case they are subject to attacks of inflammation, form points of entrance for pathogenic bacteria into the system, and give rise to various pathologic conditions.

In **hypertrophy of the tonsils** the organs are enlarged, and either project toward the median line, narrowing the lumen of the oropharynx, or are buried behind the pillars of the fauces. While the former give rise to excessive mouth-breathing and its sequels, it is the latter that act as a constant menace to the health of the individual from the absorption of pathogenic bacteria.

It is doubtful whether hypertrophy of the tonsils causes a narrowing of the bony palatal arch. It certainly narrows the lumen of the oropharynx, thus increasing the mouth-breathing, which is normal in all cases, to a certain extent. In this way irregularity of the teeth may result, because the normal hammering action of the mandible is absent (Fig. 48).

The *treatment* of hypertrophy of the tonsils consists in removal of the organs. This is best done by enucleation by blunt dissection, followed by the use of a snare. It is impossible to completely remove the buried variety of hypertrophied tonsil by cutting with the ordinary tonsillotome, and this is the variety that demands removal most frequently. In operations on the tonsil

care must be taken not to wound the internal carotid artery, which lies externally to it, being separated from the tonsil by the superior constrictor muscle of the pharynx. The ascending pharyngeal artery is more likely to be wounded, but is a much smaller vessel, and is not apt to give rise to serious hemorrhage if divided.



Fig. 48.—Facial expression in hypertrophied tonsils and adenoids (St. Clair Thomson).

**Tonsillitis.**—The tonsils are subject to several varieties of *inflammation*, which will only be mentioned briefly. The two commonest forms are *follicular tonsillitis* and *suppurative tonsillitis*, or *quinsy*. A convenient method of removing pus from the region of the tonsil and without danger of causing undue hemorrhage is by thrusting the end of a grooved director into the abscess.

The tonsils are the most frequent seats of *diphtheric* infection. This produces a grayish-white membrane of

necrotic tissue over the tonsil. Smears and cultures made from this membrane contain diphtheria bacilli.

The secretion of the tonsillar crypts often collects behind the anterior pillar of the fauces, giving a foul odor to the breath. Many of these cases come with the idea that the odor is due to decay of the teeth. Examination reveals no cavities in the teeth, but small, cheesy masses of the tonsillar secretion are found behind the anterior pillar of the fauces, and the removal of this by wiping with cotton gives immediate relief.

**Adenoids.**—Adenoid growths are hypertrophy of the lymphoid tissue which normally lies beneath the mucous membrane of the nasopharynx. These growths obstruct the posterior nares, preventing nasal breathing, thus giving the mouth abnormal respiratory work to do, and causing in this way the same conditions as hypertrophy of the tonsils. Deafness may also result from occlusion of the Eustachian tube. Adenoids are felt by passing the finger up behind the soft palate.

The *treatment* consists in removal of the growths by a special curet.

#### THE LYMPHATIC GLANDS

The lymphatics most frequently affected by lesions of the mouth and jaws are the submaxillary group. When enlarged, these are felt immediately beneath the lower border of the mandible, in the submaxillary triangle of the neck. These glands may be enlarged from inflammation or malignant disease of the region.

**Inflammation.**—The most common inflammatory conditions causing enlargement of the submaxillary lymph-glands are inflammation of the tonsils, inflammation

about the roots of teeth, and osteomyelitis of the mandible. These structures must, therefore, be examined in searching for a cause of the swelling. The glands are also subject to tuberculous infection. Inflammation of the submaxillary lymph-glands (lymphadenitis) may be acute or chronic. In the *acute* form there is a painful tender swelling beneath the lower border of the jaw, which may go on to suppuration. The *treatment* consists in removal of the cause, application of cold or soothing ointment, such as ichthyol, and pressure. If pus forms, the neck must be opened and drained.

*Chronic* lymphadenitis is characterized by nodular swellings in the submaxillary region, which may or may not be tender. The swellings tend to remain about the same size for a long period. The *treatment* is to remove the cause if it can be found, and if this is not followed by subsidence of the swelling, the glands should be dissected out.

**Malignant Disease.**—*Carcinoma* of the tongue, floor of the mouth, or of the mandible is usually accompanied sooner or later by enlargement of the submaxillary lymphatic glands. This enlargement may at first be due to absorption of infectious material from ulceration of the tumor, but is also caused by a growth of tumor-cells in the glands. Hence the glands, if involved, should always be removed at the time of operation on the primary focus.

#### REVIEW QUESTIONS

What pathologic conditions may be caused by hypertrophied tonsils?

What are adenoid growths? Give the symptoms, diagnosis, pathologic effects, and treatment.

What conditions may cause swelling of the submaxillary lymph-glands?

## CHAPTER XXIII

### INJURIES AND DISEASES OF THE TEMPOROMANDIBULAR ARTICULATION

#### DISLOCATION

By dislocation or luxation (Fig. 49) is meant an alteration in the relation of the bony surfaces composing a joint.

One or both temporomandibular joints may be affected, double luxation being more frequent. The dislocation may be complete or incomplete.

*Displacement.*—The condyle of the mandible is always carried forward. It is prevented from passing backward by the tympanic plate of the temporal bone. Hence, posterior dislocation is unknown unless accompanied by fracture of this plate of bone. In complete dislocation the condyle of the mandible passes out of the glenoid fossa, under the eminentia articularis into the zygomatic fossa, accompanied by the interarticular fibrocartilage, and is held there by contraction of the temporal and masseter muscles. The capsular ligament of the joint is torn and other ligaments are put upon the stretch.

In incomplete dislocation or subluxation the condyle of the mandible rests on the eminentia articularis.

**Etiology.**—Dislocation of the jaw is caused by any force which produces an overopening of the mouth. A blow on the chin while the mouth is open, undue

forcing open the mouth in the extraction of a tooth, and yawning are among the numerous causes of dislocation. Some individuals have the power of producing a disarticulation at will, and in them the luxation gives rise to little or no discomfort.

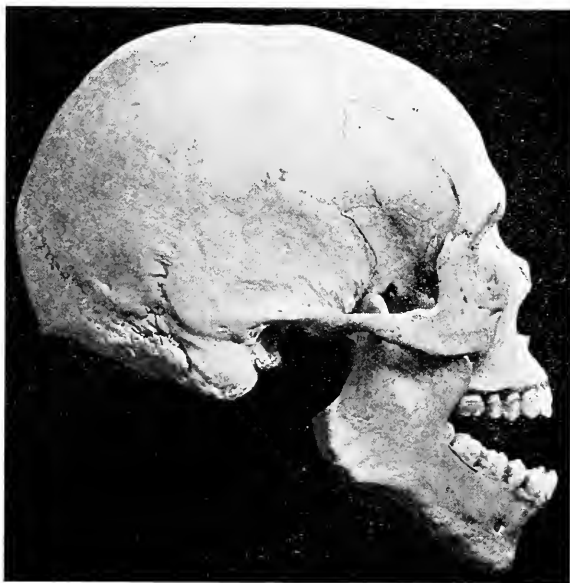

Fig. 49.—Dislocation of temporomandibular joint.

**Symptoms.**—In double luxation the mouth is held wide open and cannot be closed, interfering with mastication and speech. The chin is protruded beyond the normal. There are hollow spaces in front of the ears, where the condyles ought to be. Considerable pain is complained of.

In dislocation of one joint only, the chin is protruded and deflected toward the sound side, and there is a



hollow space in front of the ear on the affected side. Single luxation is not so common as double.

**Treatment.**—When seen early, a case of dislocation of the temporomandibular joint may be difficult to reduce, owing to the rigidity of the temporal and masseter muscles, but in an hour or two, when the muscles have relaxed, the condyle usually slips back into place easily. It may be necessary to anesthetize the patient. Reduction is brought about by covering the thumbs with a towel, and placing them one on each side of the mouth, to the outer side of the molar teeth. The other fingers are placed under the chin. By downward pressure of the thumbs and lifting the chin with the fingers, the condyle is carried under the eminentia articularis into the glenoid fossa. After reduction of the dislocation the Barton bandage should be applied and worn for two weeks. After this time massage and passive motion may be begun.

Old dislocations that resist all attempts at reduction require osteotomy at the angle of the mandible.

#### ANKYLOSIS

By the term ankylosis is meant partial or total immobility of a joint.

The following varieties of ankylosis of the temporomandibular joint are found:

(a) *True Ankylosis.*—Immobility due to disease within the joint itself. This is usually *complete*, owing to a deposit of bone in and around the joint. Ossification may be preceded by fibrous or cartilaginous change in the joint, in which case the ankylosis would be *incomplete*.

*Etiology.*—True ankylosis of the temporomandibular joint is usually found in osteoarthritis, a chronic disease, in which all the joints of the body are progressively affected by ossification of the joint structures. Bony union of the joint surfaces and surrounding parts also occurs after traumatism. After prolonged ankylosis characteristic changes take place in the shape of the mandible. The condyloid process is shortened. This causes an apparent elongation of the coronoid process. The angle of the mandible is elongated, so that it forms a projecting point, and the base of the bone under the mental foramen is thickened. The mental process is much diminished in size by recession. The base of the bone, between the angle and a point vertically under the canine tooth, is deeply concave in outline.

The cause of these changes lies in the activity of the muscles that depress the jaw. The muscles of mastication—*i. e.*, those which elevate the lower jaw—are inactive, while those which assist in depressing the mandible become more and more active in their work in an endeavor to overcome the fixation of the temporomandibular articulation. By their action the lower jaw, from the symphysis to the angle, becomes modified in proportion to the contraction of the depressing muscles of the lower jaw. Anteriorly, there are the geniohyoglossus, the sternohyoid, the sternothyroid, the digastric, the omohyoid, and the platysma myoides, all of which are abnormally active. Their action without the compensating factor of the mandibular motion brings about the changes noted <sup>1</sup> (Figs. 50 and 51).

(b) *False ankylosis* is partial immobility, due to changes

<sup>1</sup> Cryer, "Studies in the Internal Anatomy of the Face."

in structures outside the joint. It may be—(1) chronic, (2) acute.

*Chronic false ankylosis* of the temporomandibular joint may be due to (a) trauma, resulting in thickening of the ligaments, or formation of scar tissue from a wound in the region of the joint.

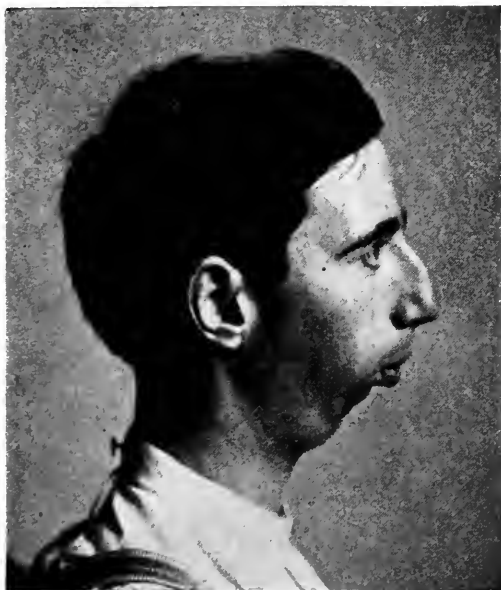


Fig. 50.—Ankylosis of jaw (after Cryer).

(b) Inflammatory conditions, followed by organization of exudate or formation of scar tissue about the joint.

(c) Cicatricial tissue following sloughing within the mouth in the course of acute exanthemata (scarlet fever, etc.).

The changes in the shape of the mandible following prolonged ankylosis of this character are similar to those seen in acute ankylosis.

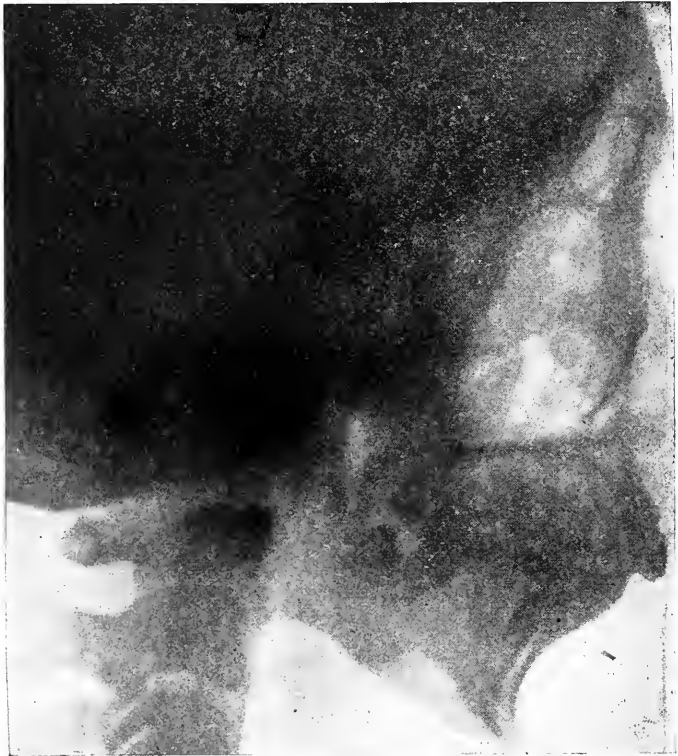

Fig. 51.—Radiograph of ankylosis of temporomandibular joint, showing underdevelopment of mandible and impaction of teeth (after Cryer).

*Acute false ankylosis* is inability to move the jaw, owing to an acute inflammatory exudate in the region of the joint. This is often seen in connection with mumps and other inflammations of the parotid gland. An impacted

third molar tooth or an abscess from a tooth often causes cellulitis, which extends up to the region of the joint.

**Symptoms.**—*Complete True Ankylosis.*—Complete immobility of the temporomandibular joint is rare. There is absolute inability to open the mouth. After a time the chin recedes, the angle of the jaw becomes obtuse, and the muscles below the jaw have the appearance of being tense. If ankylosis dates from childhood, the teeth are found to be irregular and some of them impacted, owing to lack of space for eruption. The x-rays are of great value in these cases in ascertaining the condition of the joint, and also because inability to open the mouth makes examination by the ordinary methods difficult or impossible.

*True ankylosis that has not become complete and chronic false ankylosis* present symptoms that vary only in degree. Here the jaws can be separated to a slight extent. There is no pain, except when force is used to open the mouth. The secondary changes, recession of the chin, impaction of teeth, etc., are found as in the case of bony ankylosis.

*Acute False Ankylosis.*—Here we have the symptoms of acute inflammation—heat, pain, redness, swelling, and *disturbed function*—in the region of the joint. The motion of the lower jaw is limited owing to the pain and exudation, and the patient has difficulty in opening the mouth. The local signs may be accompanied by fever and other general symptoms. In inflammations of the parotid gland the swelling is triangular in shape, behind the ramus of the jaw and in front of the ear. The limitation of jaw movement in these cases is due largely

to inflammation of the process of parotid gland that is found in the glenoid fossa, though it is also brought about by the general swelling behind the ramus. This form of ankylosis often gives rise to great alarm on the part of the patient and family, who fear the onset of tetanus.

*Prognosis and Treatment.*—In *true ankylosis* of the temporomandibular joint the prognosis is unfavorable. Where bony union of the parts has taken place, it is never possible to restore the function of the joint. In this case the only hope of improvement is by making a false joint (pseudo-arthritis). It is best to do this by removing a wedge-shaped piece of bone at the angle of the mandible, rather than section at the neck of the condyle. This may be done by making a section at the neck of the condyle, or by removing a wedge-shaped piece of bone at the angle of the mandible. A flap of soft tissue is interposed between the cut ends of bone, and after the operation motion is begun early to prevent the formation of new bone at the point of section.

In *incomplete ankylosis*, whether true or false, the prognosis is more favorable, and great improvement can sometimes be brought about. Cicatricial tissue or fibrous bands which restrict the movement of the jaw may be cut away by operation, and the jaws gradually spread apart by a special appliance, or they may be gradually stretched without operation. A special wedge is made, the jaws of which are spread wider apart little by little each day. Wedge-shaped pieces of box-wood or ivory may also be introduced between the upper and lower teeth, and the patient instructed to work the jaws with the wedge in position. In this way great progress may be made, the final result obtained depending on the severity of the case.

In *acute ankylosis* the prognosis is good, and the treatment consists in removal of the cause. If it be an impacted or abscessed tooth, this should be removed. Anesthesia is often necessary to get the mouth open. The inflammation is treated by rest, cold, soothing lotions, incision, etc.

#### **Differential Diagnosis of Tetanus and Acute Ankylosis.**

—The muscles of the jaw are those earliest affected in tetanus (lockjaw), and this fact often leads to alarm on the part of the patient suffering from acute ankylosis that he has an attack of lock-jaw. There is no necessity, however, for the surgeon to confuse the two. In the *trismus of tetanus* or *lock-jaw* the inability to open the mouth is purely due to muscular spasm, and is not inflammatory, consequently there is no swelling in the region of the temporomandibular joint. The muscular contractions are intermittent. The convulsions are not confined to the muscles of the jaw, except in the earliest stages, but are general; there are severe constitutional symptoms, and the patient is very much prostrated. Spasm of the muscles of the back causes a marked arching (opisthotonos), so that the patient may be supported by his head and heels. In tetanus there is generally a history of a punctured wound, such as that made by a rusty nail in the foot, a gun-shot wound, etc.

#### **REVIEW QUESTIONS**

Give the displacement, etiology, symptoms, and treatment of luxation of the temporomandibular joint.

What is meant by ankylosis? Give the varieties of ankylosis of the temporomandibular articulation and the causes of each.

Give the symptoms of the different varieties of ankylosis of the temporomandibular joint.

Give the prognosis and treatment of the different varieties of ankylosis.

Give the differential diagnosis of tetanus and acute ankylosis of the temporomandibular joint.

## CHAPTER XXIV

### IMPACTED TEETH

THE term impaction has been used to describe a tooth that is prevented from erupting, being deflected from its normal line of movement so that it impinges on an adjacent tooth. This impingement may permit of partial eruption or entirely prevent it. The same term is also applied to other malpositions, rotations, and inversions of *unerupted* teeth.

*Order of Impaction.*—The tooth most frequently impacted is the lower third molar. This is closely followed by the upper canine and the upper third molar. Other teeth are occasionally impacted, but not so frequently as those mentioned. The explanation is easily seen. The third molar, being the last of the posterior teeth to erupt normally, the space reserved for it is readily filled up by abnormal conditions. The canine, in relation to the anterior teeth, suffers similarly from lack of space when this part of the jaw is affected.

Impacted teeth are found in various positions, shapes, and degrees of impaction. Sometimes they are partially erupted and can be seen, but often they are entirely covered by the gum and the bone. An impacted lower third molar usually lies more or less horizontally, pressing at various angles against the second molar. This tooth may be impacted without pressing against the second molar, and may be rotated in various directions,



pointing back toward the ramus, or it may be completely inverted (Figs. 52 and 53).

The upper third molar is usually impacted with its crown pressing against the second molar. Its roots may apparently pass into the maxillary sinus, as shown by

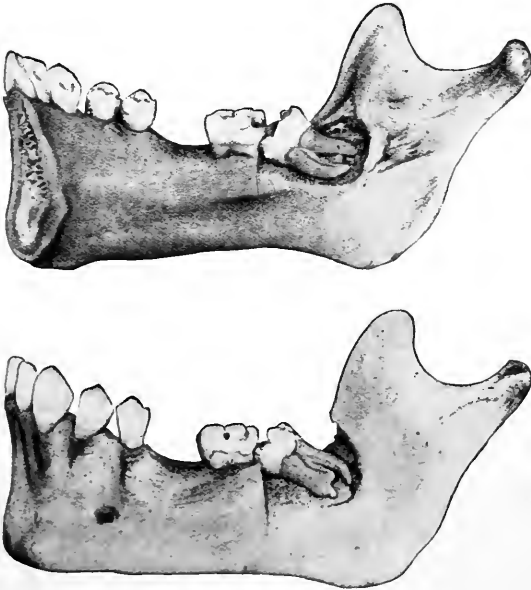


Fig. 52.—Side view of two impacted lower third molars, the bone having been removed in order to expose the roots (after Cryer).

the x-ray, but this occurs very seldom, the roots really being in the wall of the sinus, above the level of the floor.

An impacted canine tooth is usually prevented from eruption by the roots of adjacent incisors or premolars, against which it presses.

The roots of impacted and misplaced teeth are often built into abnormal shapes during their development in order to avoid encroachment upon important structures, such as the maxillary sinus, the inferior dental tube, etc.

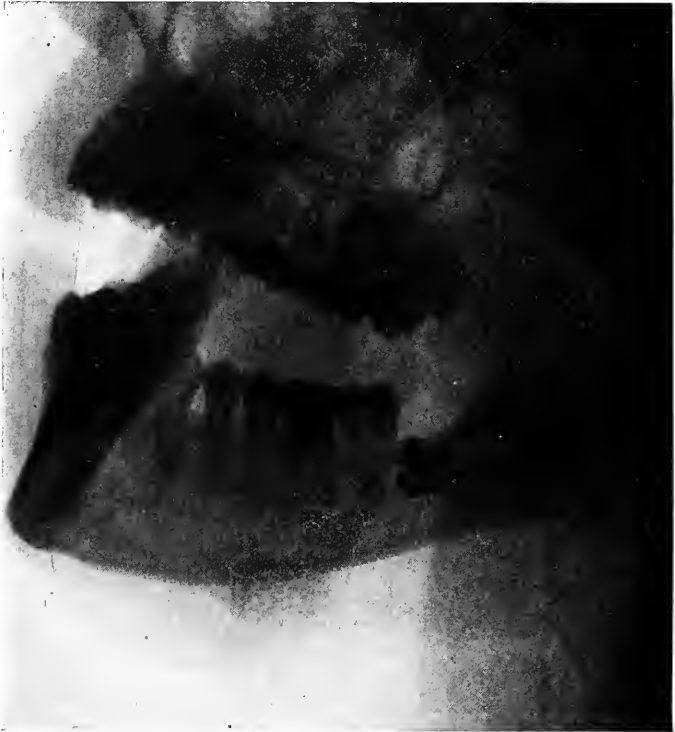

Fig. 53.—Radiograph showing impacted lower third molar tooth, with resorption of root of second molar; also impacted upper third molar (after Cryer).

**Etiology.**—Many pathologic conditions bring about retarded eruption, displacement, and impaction of the teeth.

*General Disturbances.*—Acute infectious fevers of

childhood, such as scarlet fever and measles, and disorders of nutrition, such as scurvy. *Local causes* are inflammations of the jaw bones set up by decayed teeth or other causes, injury, contracted arches produced by excessive mouth-breathing the result of nasal obstruction from adenoids, etc. The growth of the jaws and the movement of the teeth are in a forward direction; consequently, anything which interferes with this forward movement or growth will cause impaction of the teeth. Acute infectious fevers interfere with the forward movement by causing a deposit of dense bone. Local increase in the density of the bone may also be brought about by inflammation of the peridental membrane extending into the alveolar process. The cancellated tissue, instead of being spongy and elastic, becomes hard and solid. This condition following caries of the first permanent molar soon after its eruption is a frequent cause of impaction of the lower third molar.

The effects of contracted arches of constant mouth-breathers on the eruption and position of the teeth are well known. Severe traumatism to the jaws may cause a deposit of lime salts in the cancellated tissue and thus bring about impaction. A heavy blow on the chin in childhood may produce ankylosis of the temporomandibular joint, resulting in arrest of growth of the jaws, leaving insufficient space for the eruption of all the teeth. Too early extraction of deciduous teeth may cause malposition of the permanent teeth, this leading in turn to impaction of unerupted teeth. Failure to lance the gums in retarded eruption of deciduous teeth may bring about an abnormal density of the cancellated tissue, resulting in impaction of permanent teeth. In

addition to injury, disease, and lack of development, it is conceivable that impacted teeth may result from hereditary causes, such as transmission of small jaws from one parent and small teeth from the other. Irregularities are artificially produced in certain animals by breeders, and the same thing occurs in the human race accidentally.

**Symptoms and Diagnosis.**—Impacted teeth may be present without giving rise to any symptoms whatever. Others cause pain, which may be local or neuralgic in character, distributed along the branches of the trifacial nerve. Sometimes, in the case of the lower third molar, cellulitis is set up, which produces false ankylosis of the temporomandibular joint. If the tooth is partly erupted, the diagnosis is at once apparent, but in other cases the diagnosis depends on the absence of the tooth from the denture and the *x*-ray findings.

Impacted teeth are a frequent cause of many serious local and general disturbances.

*Local Effects.*—An impacted third molar may press against the crown of the second molar and cause decay of that tooth, or itself become the seat of caries around the point of contact. Exposure and devitalization of the pulp from this cause may give rise to neuralgia. Neuralgia may be caused in another way by pressure of the roots of the impacted tooth on the inferior dental nerve and its branches. The irritation set up by an impacted tooth may cause condensation of the surrounding bone, with pressure on the nerve and its branches. Infection from a pulp devitalized by pressure of an impacted tooth may pass up into the maxillary sinus and other pneumatic spaces.

*General Effects.*—Impacted teeth can set up functional nervous and possibly mental disease, even though they cause no local symptoms.

*Treatment.*—This, as a general rule, consists in removal, by operation, of the impacted tooth. In some cases it is more advisable, on account of the difficulty in reaching the misplaced tooth, to extract the adjacent tooth that is causing the obstruction. After this has been done the impacted tooth will in many cases erupt in the position of the extracted tooth. This procedure is sometimes advisable even in cases where the third molar could be easily reached, especially where the second molar is badly decayed. It is occasionally necessary to sacrifice both the second and third molars. Sometimes the impacted tooth, a lower third molar, for example, can be turned out of its socket by inserting a No. 3 elevator between it and the second molar, but generally some of the dense bone overlying the tooth must first be cut away with a bur in the surgical engine. The tooth can then be turned out with the elevator or grasped by the forceps. In many cases the extremely dense character of the bone makes removal of a considerable quantity necessary before the tooth can be removed.

**Indications for Extraction of Deciduous Teeth.**—The deciduous teeth should be retained if possible until time for the eruption of the permanent teeth, as they are guides to the correct eruption of the latter. On the other hand, retention of deciduous teeth that are badly decayed is a frequent cause of inflammatory conditions resulting in increase in density of the jaw bones, followed by maleruption and impaction of the permanent teeth.

The deciduous teeth should be extracted, therefore:

(1) When they are so badly decayed as to give rise to continual pain which cannot be relieved.

(2) When they interfere with the correct eruption of the permanent teeth.

(3) When they remain in position after eruption of the corresponding permanent teeth.

#### REVIEW QUESTIONS

Define the term impacted tooth. Give etiology, effects, diagnosis, and treatment of impacted teeth.

Give the indications for extraction of the deciduous teeth.

## CHAPTER XXV.

### MALFORMATIONS OF THE JAWS

#### CLEFT-PALATE

By cleft-palate (Fig. 54) is meant the formation of an opening in the hard or soft palate or both, affording a communication between the oral and nasal cavities.

**Varieties.**—Cleft-palate may be:

1. Acquired.

2. Congenital.

1. **Acquired cleft-palate** may be due to—

(a) Traumatism, as a gunshot wound or blow.

(b) Disease, such as syphilis, which causes necrosis of the bones. Acquired clefts vary very greatly in size. The opening may be merely a small round hole or cleft, it may involve only the soft palate, or it may be so large as to convert the mouth and nose into practically one cavity by destruction of the whole of the hard and soft palates.

*Treatment.*—Acquired cleft-palate is treated by obturators and artificial vela, after the parts have been brought into as healthy a condition as possible by removing necrotic tissue, internal medication, etc. The simplest form of obturator is nothing more than a plate of metal or rubber, covering a break in the hard palate. Obturators which correct breaks in the soft palate, being mobile in construction, are known as *vela*. A velum is

used not only to fill a space, but also to assist in a functional performance. It is designed to take the place of the soft palate in swallowing.

The best method of taking the impression of a cleft-palate is by filling the cleft with absorbent cotton smeared with vaselin. This prevents the plaster from

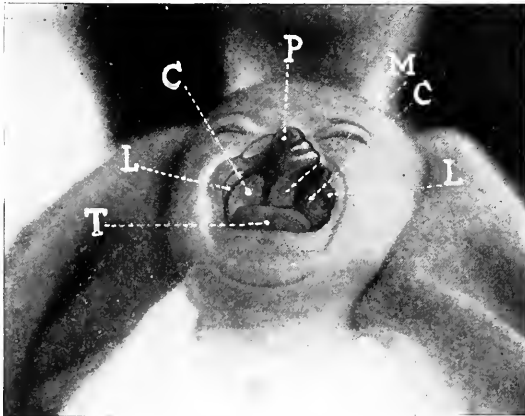


Fig. 54.—Double cleft-palate and harelip. View of interior of mouth: *P*, Skin in median line covering the intermaxillary bone, the projecting portion of the latter being seen immediately below it; *M*, intermaxillary bone; *C, C*, palatal processes of the right and left superior maxillæ respectively; the black space between *C* and *M* on each side of the median line represents the cleft in the palate; *L, L*, right and left lips respectively. Note the cleft between these rudimentary lips and the central portion of the lip, *P*, covering the intermaxillary bone; *T*, tongue. This photograph was taken while the child was crying (Eisendrath).

going up into the nose. Plaster-of-Paris should always be used in taking the impression. From the impression a cast is made, and the obturator constructed just as in the case of a vulcanite or metal denture. The obturator is kept in place in the mouth by means of clasps. In using clasps it is always advisable to attach them



to teeth that are not quite opposite to one another. Thus it is well to clasp a first molar on one side of the mouth, and a second bicuspid on the other. This keeps the piece firm and prevents rocking. Where a cleft in the soft palate is to be filled, the part of the obturator representing the soft palate may be made of hard rubber and attached to the front piece by a hinge, which allows accommodation to the movements of swallowing; or the back piece may be made of soft rubber. This piece is first built on to the anterior portion in wax, and its proper size and shape are obtained by trying it in the mouth several times, trimming it off until perfect adaptation is obtained.

Obtulators are used not only in the treatment of acquired cleft-palate, but are required in cases of inoperable congenital cleft-palate.

2. **Congenital Cleft-palate.**—In order to comprehend the congenital formation of cleft-palate it is necessary to understand something of the development of the maxillary bones. The maxilla is developed from two processes—the lateral process, or true maxilla, and the anterior nasofrontal process, or premaxillary bone. Under normal conditions the premaxillæ of the two sides unite at about the fortieth day of embryonic life to form the intermaxillary bone, which in turn becomes joined to the lateral processes or true maxillæ. These also unite with each other in the median line behind the intermaxillary bone. Under abnormal conditions these processes may fail to unite, resulting in the formation of single or double cleft-palate. In *single* cleft-palate the cleft passes between the intermaxillary bone and one of the true maxillæ, and then is continued backward

between the palatal processes of the maxillæ and the horizontal processes of the palate bones. It may or may not involve the soft palate, but usually does. It is thus seen that the cleft anteriorly is to one side of the median line, while posteriorly it runs in the median line. In rare cases the cleft is due to failure on the part of the two premaxillæ to unite, and here the opening is in the median line anteriorly as well as posteriorly.

In *double* cleft-palate there is a cleft on either side of the intermaxillary bone, the two clefts joining posteriorly to this bone to form a single cleft which passes between the two true maxillæ and between the horizontal processes of the palate bones. From this it will be seen that the opening in double cleft-palate is Y-shaped, the divergent arms of the Y embracing the intermaxillary bone. This description is somewhat diagrammatic, as the small size of the intermaxillary bone and distortion of the parts sometimes make it difficult to follow out the course of the cleft according to the description. Congenital cleft-palate may be complete, that is, embracing both hard and soft palate, or incomplete, involving the hard palate or the soft palate only. It may or may not be associated with harelip.

*Causes of Congenital Cleft-palate.*—There are many theories explaining why the bones do not unite. According to one theory, about the sixth week of embryonic life, through fright to the mother or some other cause, nourishment to the parts is cut off or diminished, which prevents them from uniting. *Mechanical theory:* The lower jaw, being formed first, influences the shape of the upper jaw, and, owing to some undue pressure within the uterus, is forced between the formative processes

of the upper jaw, and thus prevents their union. This theory is borne out by the fact that in cases of cleft-palate the alveolar ridge of the upper jaw is outside that of the lower jaw, while under normal conditions it is inside it. This theory is further borne out by the fact that after operation for cleft-palate the upper jaw, when its two halves are brought together, is not too small, this proving that the cleft is not due to lack of tissue (Cryer).

*Treatment.*—The treatment of congenital cleft-palate is either mechanical or operative. Mechanical treatment is resorted to when operative treatment is not indicated, *i. e.*, when a patient with a wide cleft has been allowed to reach a mature age. The best age for operation is as soon after the birth of the child as it has become used to its surroundings, provided it be well nourished—*i. e.*, before the age of six months. The bones at this early period are not thoroughly calcified, and can, therefore, easily be brought together. The sooner the operation is performed also, the better for the general health and nourishment of the child, as it cannot suck with a cleft-palate. The teeth at this age have not erupted, and the parts are, therefore, more accessible than if the teeth were in position. The child has not yet learned to talk, and has no mispronunciation to correct.

The following is a brief description of the Brophy operation, which is suitable in a large number of cases: The cheek is raised, and a silk suture is inserted into the substance of the bone just behind the malar process and carried out on the opposite side. Care must be taken to place the suture above the palatal plate of the bone. This suture is then replaced by one of silver wire,

which may be doubled, if necessary. Anterior to this wire another silver wire is inserted and carried through the substance of the bone above the palatal plates, and out through the other side, at a position corresponding to the place of entrance. The next step is to take two lead plates molded to fit the parts, one on either side of the outer portion of the upper jaw, each long enough to pass beyond the points of exit of the wire sutures, so that they will pass through it. Each plate is provided with holes through which pass the two ends of the wires as they emerge on each side. The bones are now pressed together and held in position by twisting the ends of the wires. After approximation of the parts, additional sutures, if necessary, are inserted in the median line of the mouth. The abrasions caused by the metal plates are usually very slight, and need not cause any anxiety. They may remain in place six or eight weeks. After closure of the cleft the palate will not, as a rule, be contracted to an abnormal extent. The teeth will also generally be found to erupt and occlude normally with those of the lower jaw. If this does not occur, the irregularity must be corrected.

In some cases of cleft-palate, where the intermaxillary bone is turned up and attached to the septum of the nose in front, it is necessary to remove it altogether. In this case the incisor teeth, both temporary and permanent, will be lost, as their germs are contained in the intermaxillary bone.

The Brophy operation is not, as a rule, suitable for cases over six months old, as the bones by this time are not sufficiently pliable to be pressed together. In cases over this age, and in which the cleft is very wide, a flap oper-

ation is indicated. The Brophy flap operation is made by loosening a flap of mucous membrane from the bone on either side of the cleft, and uniting the free edges in the median line with silver-wire sutures, prevented from cutting out by lead plates. The Lane operation is as follows: A large flap of mucous membrane is dissected from the hard palate on one side of the cleft, being still attached to the bone on the side nearest the cleft. This is turned completely over, with its raw edge downward, and its free edge tucked under the mucous membrane that has been lifted from the bone on the opposite side of the cleft. The flaps are now secured in place by silk sutures. The raw surface in time is covered over with epithelium. In the flap operations no attempt is made to bring the bones together.

In inoperable cases of cleft-palate obturators and vela may be made, just as in cases of acquired cleft-palate.

#### HARELIP

Harelip (Figs. 55 and 56) is a congenital cleft or fissure in the lip, usually the upper. It is due to the same causes as congenital cleft-palate, *i. e.*, a failure to unite on the part of the developmental processes in the embryo. It may occur with or without cleft-palate, and cleft-palate may occur without harelip. The fissure is generally situated at a point opposite the space between the canine and lateral incisor teeth. Harelip may be single, with a cleft only on one side of the lip, or double, in which there is a cleft on both sides of the median line. Occasionally the fissure may be situated in the median line, or between the central and lateral incisors.

*Treatment.*—Where the fissure is only slight, the treat-

ment consists in paring the edges, bringing them together, and holding them in place with interrupted silk or horse-

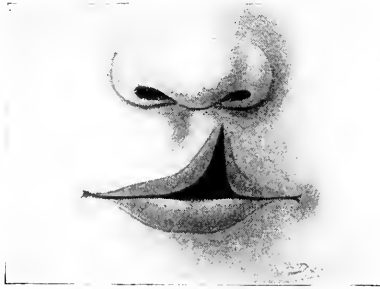


Fig. 55.—Harelip (Campbell).

hair sutures. The sutures should pass down as far only as the mucous membrane, and not through it, thus avoid-



Fig. 56.—Double harelip (before operation) (Grant).

ing infection as much as possible. In applying the dressing, direct pressure must not be brought to bear on the

line of suture. To prevent this, small rolls of gauze are placed one on either side of the cleft, and the dressing of iodoform gauze laid between these. The dressing is secured in place with a strip of adhesive plaster. The chances of infection are greatly lessened by applying Whitehead's varnish to the line of suture, and if this is done a large gauze dressing can be dispensed with. The sutures should remain in five or six days.

When the cleft in the lip is a wide one the operator must use his ingenuity in cutting flaps to obtain sufficient tissue to fill in the space. It is wise, if possible, to get tissue a little in excess of the amount needed, as it usually contracts later.

In a combined case of harelip and cleft-palate the palate should, if possible, be operated upon first. By doing this the operator has better access to the palate than if the fissure in the lip were closed first. Another reason is that it is more important for the nourishment of the patient that the cleft in the palate should be closed than that in the lip. The cleft-palate can be closed only by an operation early in life, while the harelip can be remedied at any time.

#### INJURIES DURING CHILDBIRTH

**Inferior Prognathism.**—By this term is meant a projection of the mandible, causing an overlapping of the lower front teeth in advance of the upper. Observations have shown that this deformity is not always merely a malposition of the teeth, but is often primarily due to a forward position of the entire mandible, and that there is a subluxation of the condyle of the mandible on to the eminentia articularis of the temporal bone, the condyle

assuming this position, instead of being back in the anterior portion of the glenoid fossa. Examination of a skull in which inferior prognathism exists will show this, and the x-rays will show it in living subjects. Many of these cases are known to have been breech presentations at birth. It is estimated that breech presentations occur in about 3 per cent. of all cases of labor. In various methods employed for delivery of the after-coming head in breech presentations the finger of the accoucher is placed in the child's mouth to make strong traction on the chin, and it is reasonable to suppose that subluxation of the mandible may be caused by this procedure, followed by inferior prognathism.

*Treatment.*—The attending physician in a case of labor should examine the jaws of the child, and if the deformity has been produced, recognized by undue projection of the chin, to correct it immediately, pushing the condyles back into position. If allowed to remain, it becomes impossible to reduce the dislocation later. When seen later in life, a case of this kind may be benefited by operation, the rami of the mandible being divided, and the whole bone being carried backward the required distance. Before the operation intermaxillary splints should be made to hold the jaw in its correct relation.

Another deformity of the jaw occasionally seen in adults is absence of the normal angle of the mandible. The ramus in this case is nearly in a straight line with the body of the jaw, and the result is that only the back teeth occlude, leaving a space between the anterior upper and lower teeth when the mouth is shut. Absence of normal acuteness of the angle of the lower jaw may also



be associated with the condition of forward bite of the lower teeth, as just described. It is not an obliteration of the angle so much as some interference with development, because there is scarcely any angle at birth in the normal subject. It has been shown that this deformity followed cases of difficult labor in which the jaws were subjected to undue pressure, or in which the forceps were used. Special care in the application of the forceps may prevent the deformity. When seen in later life, it may be corrected by operation.

#### REVIEW QUESTIONS

Define cleft-palate.

Give the etiology and treatment of acquired cleft-palate.

Describe the different forms of congenital cleft-palate, with theories as to production.

Give the treatment of congenital cleft-palate.

What is the best age for operation on cleft-palate? Give reasons.

Describe the Brophy operation for cleft-palate.

Describe harelip and give treatment.

In a case of harelip combined with cleft-palate, which should be operated upon first? Give reasons.

## CHAPTER XXVI

### FRACTURES

A *fracture* is a solution in the continuity of a bone, the result of trauma, disease, or muscular action.

Fractures are divided into—(1) Greenstick; (2) simple; (3) compound; (4) comminuted.

1. A *greenstick* fracture is an incomplete fracture which occurs in children, in which the fractured ends are joined together by unbroken fibers of bone resembling a broken green stick. The peculiar character of these fractures is due to the incomplete calcification of the bones of children.

2. A *simple* fracture is one in which the break occurs without infliction of an external wound which communicates with the ends of the fractured bone.

3. A *compound* fracture is one in which the fractured bone communicates with the external air through a wound. It is also known as an open fracture.

4. A *comminuted* fracture is one in which the bone is broken into numerous small fragments.

The **general principles of treatment of a fracture** consist in reducing the fracture, *i. e.*, bringing the fractured ends of the bone into correct apposition, and holding them in position by splints and bandages until reunion takes place. In a compound fracture these procedures are to be supplemented by disinfection of the wound.

The special fractures that will be taken up in detail are:

1. Fractures of the upper jaw, comprising the maxilla, and sometimes involving also the palate and malar bones and the zygomatic arch.

2. Fractures of the lower jaw or mandible.

**Fractures of the upper jaw bones** are rare. A frequent method of production when bicycle riding was popular was by sudden arrest of the machine, and projection of the rider over the handle-bars. Cases are on record of complete fracture of the upper jaw through the floor of the orbits on each side. Usually only a portion of the alveolar process is fractured, and this may occur by blows, during the extraction of a tooth, or from a bullet wound. In extraction of the upper third molar the tuberosity may be broken off. A bullet or the end of a blunt instrument may pass through the roof of the mouth, perforating the hard palate. Owing to the absence of attachment of powerful muscles to the upper jaw great displacement of the fragments is uncommon.

#### FRACTURES OF THE MANDIBLE

These make up the great bulk of fractures of the jaw bones. They are usually compound, the fractured ends of the bones communicating with the mouth cavity through a laceration of the mucous membrane.

**Etiology.**—Fractures of the mandible may be caused by kicks, blows, bullet wounds, necrosis of the bone, or muscular action. It is often difficult to obtain a clear history of the injury, as the patient is often intoxicated at the time of its reception.

**Seat of Fracture.**—The most frequent single seat of

fracture is the region of the mental foramen. The bone is weakened here by the mental foramen and by the peculiarly attenuated internal structure of the bone at this place, which is one of the fixed points from which growth extends. At this position also is the middle of the curve in the body of the jaw, and finally the large socket of the canine tooth is situated in this region. Fractures may also occur in the region of the angle, between the angle and the mental foramen, and at the symphysis menti. Fractures of the ramus, the condyloid and coronoid processes, are rare, owing to the protection afforded by overlying muscles. Fracture of the condyloid process is usually produced by a blow on the opposite side of the chin. When a fracture occurs in the region of the angle the direction of the break is anterior from below upward, generally at an angle of about 60 degrees from the horizontal. The lower jaw is often broken in more than one place, the fractures usually occurring on opposite sides. The fractures may occur at corresponding places on the two sides, or at different places, according to the direction of the breaking force. A common double fracture is one in which the bone is broken near the mental foramen on one side and through the angle on the other. Comminution may occur when the trauma is of exceptional severity.

Owing to early ossification, greenstick fractures of the mandible are rare. One case of fracture or separation at the symphysis menti by the obstetric forceps during parturition has been reported.<sup>1</sup>

**Complications.**—Fractures of the mandible being usually compound, the commonest complication is infection of the intramandibular and perimandibular

<sup>1</sup> Ivy, R. H., Univ. of Pa. Med. Bull., 1907.

tissue, which may lead to cellulitis, suppuration and abscess, necrosis of bone, sinus formation, and delayed or non-union. Infection of the tissues after fracture is much less common than one would suppose in view of the fact that the seat of fracture immediately becomes bathed in saliva loaded with many varieties of pathogenic bacteria. From this it is inferred that the saliva exerts some restraining power over the organisms, lessening their virulence. It is generally in neglected cases, in persons of low vitality, and in jaws previously infected by diseased teeth that abscesses occur. Abscesses following infection at the seat of fracture may open directly over the point of injury, or may burrow under the fascia and open on the neck at some distant point. Persistent sinuses often remain, due to the presence of necrosed bone.

In many cases teeth become loosened at the seat of fracture either by the traumatism or by subsequent infection, or roots of teeth may be fractured. In repair of the fractured bone filaments of the inferior dental nerve may be caught in the callus or the main trunk pressed upon, causing neuralgia. Fracture is frequently followed by anesthesia or numbness of the lips and skin covering the chin, owing to rupture or laceration of the inferior dental nerve, which supplies the region through its mental branch. The interference with sensation is only temporary, however, as regeneration nearly always follows. Delayed and non-union are common in neglected cases. Infection and abscess formation are undoubtedly a cause of delayed and non-union of fractures of the mandible, but a far more common cause lies in imperfect reduction and fixation of the fragments.

Delayed union is more frequently seen in double fractures, in which immobilization is more difficult than in single fracture. Among possible complications is pneumonia due to inhalation of septic material from the mouth. T. T. Thomas reports a case of Ludwig's angina following fracture due to a gunshot wound.<sup>1</sup>

Fracture or solution of continuity of the lower jaw may result from a primary weakening of the bone by disease, followed by necrosis. In other long bones of the body experience shows that while new bone may be formed to replace necrotic bone, union after necrosis with fracture practically never takes place. This applies only to cases in which fracture was primarily due to disease and not to trauma. In the mandible this rule does not hold good. There are several instances recorded in which regeneration of new bone in the place of that lost by necrosis occurred after a complete solution of continuity; the result was perfect union and subsequent restoration of function.

**Symptoms and Diagnosis.**—Fracture of the mandible has the symptoms common to fractures of other bones, viz., *sharp pain, crepitus*, or grating on rubbing the ends together, *preternatural mobility, deformity*, indicated by malocclusion of the teeth, *swelling*, and *impaired function*. The pain and tenderness are much greater than any lesser injury. When the fracture occurs in the portion of the jaw occupied by teeth, the line of the teeth may be irregular, the teeth anterior to the break lying on a lower level than those posterior to it. This is due to the fact that the posterior fragment is held up in position by the elevator muscles, while the depressor

<sup>1</sup> Annals of Surgery.

muscles and gravity cause the anterior fragment to drop. By grasping one of the fragments in each hand they can be made to move up and down one upon the other, which is indicated by the adjacent teeth interchanging

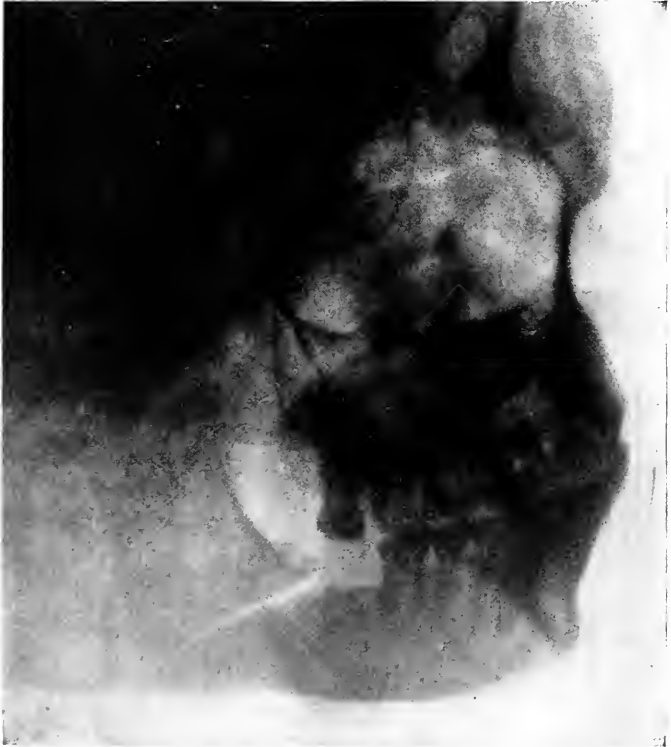

Fig. 57.—Radiograph showing fracture at angle of mandible (after Cryer).

levels. Crepitus is also elicited in this way. In fractures of the angle or ramus behind the insertion of the masseter little or no deformity occurs, as the anterior fragment is then held up by this muscle, making diagnosis

difficult. In these cases the *x*-ray is useful in deciding the nature of the injury. In all cases the *x*-ray is valuable in determining the direction of the fracture, injuries to roots of teeth, involvement of teeth in the fracture, and position of the fragments after reduction (Fig. 57).

Fracture of the condyloid process may be diagnosed by history of a blow on the opposite side of the chin, swelling and pain in front of the ear, limitation of motion, and deviation of the chin toward the affected side when the mouth is closed. It is sometimes difficult to obtain a good *x*-ray picture showing the injury. Fracture at this point is sometimes followed by ankylosis, though in the experience of the writer the fragments in untreated cases usually unite in malposition, leaving deformity without ankylosis. (Annals of Surgery, May, 1915.

**Treatment.**—Fractures of the mandible will be dealt with first.

The rules for treatment of fractures in general apply to fractures of the mandible, namely, reduction and fixation of the fragments until firm union takes place. But the peculiar shape and position of the bone, and its close relation to the bacteria-laden mouth, render necessary important modifications and special methods of treatment. Thus the danger of infection is greatly increased in cases in which no attention is paid to the hygiene of the oral cavity. Therefore, whenever possible before inserting splints or applying bandages, tartar should be removed from the teeth, suppurating roots extracted, and the mouth well washed out with an antiseptic solution. A very satisfactory antiseptic and deodorant is a 1 : 2000 solution of potassium permanganate. Throughout the period of treatment the



mouth should be syringed with this twice a day. Having got the mouth as clean as possible, the fragments are to be reduced and fixed in position. The method used depends on the seat of fracture, accessibility of suitable appliances, the presence or absence and the number of teeth, the amount of displacement of the fragments, and the presence of complications. In many cases where the teeth are good and the upper and lower teeth occlude well, and particularly where no appliances are at hand for making splints, good results are obtained by bringing the lower teeth in correct occlusion with the upper, and holding them there with a firm Barton bandage. Additional stability may be given to the dressing by a pasteboard cup molded to fit the chin, and padded with cotton before being applied.

It is better not to reduce the fracture completely by bringing the upper and lower teeth into absolute occlusion, but to wait one or two days until the swelling and extreme tenderness of the face pass away. After that, however, the teeth must be held together by the bandage. The bandage is liable to work loose by stretching after a few days. To avoid displacement of the fragments by removing it, the bandage may be tightened by placing pads of muslin between it and the vertex of the skull. The bandages used in these dressings should always be of muslin and not of gauze, and they should have been previously stretched, if possible. In applying the Barton bandage, great care must be used to see that the fragments are in good position and that the teeth occlude correctly, as it is very easy to exert too much pressure upon one particular region, drawing the bone out of position at this place. To feed the patient

it is not necessary to extract a tooth, as recommended by some authors. He can in every case be fed on liquids through a tube, the food passing in between the teeth, and through the spaces behind the third molars. In uncomplicated cases treated by this method firm union between the fragments takes place in from four to five weeks.

In some cases of this character a very satisfactory way of adding stability to the dressing is by placing over the Barton bandage another of gauze incorporated with plaster-of-Paris. When the plaster sets, the dressing can be cut through on each side, and the free ends trimmed off until it fits snugly. The dressing can then be fastened securely with strips of adhesive plaster. This dressing has the advantage of being easily removed when necessary.

*Gilmer's Method.*—In other cases, where the teeth and occlusion are good, after removing deposits and getting the mouth as clean as possible, the fragments may be maintained in proper apposition by holding the lower teeth in correct relation to the upper by means of brass wire ligatures passed around two or three teeth on each side of the fracture, these ligatures being fastened to similar ones applied to corresponding teeth of the upper jaw. After twisting the wires together and cutting them off the sharp ends may be covered with softened gutta-percha to prevent irritation. This method may sometimes be employed to advantage in maintaining correct occlusion of the teeth in fracture of the angle or ramus.

*Splints.*—Many splints have been devised for these fractures, including interdental vulcanite splints, metal maxillomandibular splints, metal caps fitting over the

teeth adjacent to the fracture, metal bands around the teeth, and silver plates attached to the bone by screws. Metal bands about the teeth, as advocated by Angle, can be used successfully in certain cases. Operative treatment by wiring the bone or attaching silver plates by screws has not been successful, as a rule, as the parts cannot be sufficiently immobilized, and the wires or plates through infection or mobility nearly always work loose before union of the bone has taken place. The vulcanite interdental splint, which fixes the jaws with a space between the upper and lower teeth, is sometimes used in fractures occurring in the portion of the mandible occupied by teeth. This splint is particularly contraindicated in fracture posterior to the teeth, as the "open-bite" position produced by it does not maintain the fragments in correct relation, a V-shaped space being formed at the seat of fracture, which fills up by the process of repair, thus preventing the front teeth from coming together after removal of the splint. Vulcanite splints are also uncleanly and cumbersome, and should be relegated to the museum. For any fracture occurring in the region of the teeth by far the most comfortable, hygienic, and least cumbersome splint is one made of a metal cap or bridge fitting over several teeth adjacent to the seat of fracture. The chief advantage of his device is that it firmly fixes the fragments and at the same time allows the patient to open and close his mouth. It is made as follows: A plaster-of-Paris impression is taken of the teeth of the fractured jaw before reduction, and also one of the upper teeth, and casts made from these. The lower cast will represent the teeth in their relation after fracture. The cast is

now cut through with a saw at the place corresponding to the fracture, and the two portions arranged so that the teeth will occlude correctly with those of the upper jaw, *i. e.*, will be as they were before fracture occurred. The two portions of the cast are cemented together, zinc dies are made, and a cap of German silver or of gold is swaged. The cap should take in two or three teeth on each side of the fracture. The fragments can now be reduced, and the splint cemented in place over the teeth. It is wise to reinforce the splint with a Barton bandage until the cement thoroughly hardens. This splint is suitable in cases where there are several firm teeth immediately on each side of the seat of fracture.

The *mandibulomaxillary metal splint* consists of two portions, one covering the lower and the other the upper teeth, the two parts being soldered together. By this splint the jaws are fixed together with the bite closed, in contrast to the vulcanite interdental splint. Thus it can be used in fractures of the angle of the mandible without producing a V-shaped space at the seat of fracture, which is formed when the jaws are fixed with the bite open. In these fractures at or behind the angle the essential point is to fix the anterior fragment in its normal relation with the upper jaw. The posterior fragment will take care of itself, as it is not displaced to any great degree. The mandibulomaxillary splint is made of gold or of German silver in the same way as the metallic splint for the lower teeth, except that a cap is also made to fit over the upper teeth and the two soldered together after grinding the occluding surfaces of the metal to obtain close apposition of the upper and

lower teeth. The patient receives nourishment through the spaces behind the third molar teeth. This splint can be used in any case of fracture where there is a sufficient number of sound teeth, and is far superior to the vulcanite splint, being more cleanly and less bulky. Before inserting any splint the same precautions of cleansing the mouth must be observed as in cases treated by the bandage alone. Many cases occur in which the teeth are very poor, and naturally they are the most difficult to treat. Sometimes a satisfactory splint cannot be made owing to absence or poor quality of the teeth, and we have to rely on the bandage and external pasteboard cup. In edentulous mouths mandibulomaxillary splints, made from impressions of the gums, sometimes bring about good results.

Cases of fracture that are not seen until some time after the injury are often very difficult to reduce at once, owing to muscular spasm or swelling from infection. Then it is necessary to resort to slow reduction by bandages. Sometimes a mandibulomaxillary splint can be inserted, the maxillary portion fitting over the upper teeth, and the lower teeth being brought up into position by gradual pressure with bandages. Often after two or three days of the application of this double-inclined plane principle the lower teeth will be found to have gained their normal position and the splint can be firmly cemented in place.

If abscesses form on the face or neck, they must be opened and drained. If sinuses persist, they indicate necrosed bone. The sinuses must be kept clean by irrigation with a germicidal solution, such as bichlorid of mercury 1 : 2000. Dioxid of hydrogen must not be

used for irrigation, as it tends to spread the infection through the bone. When sequestra become loosened they should be removed. Teeth loosened at the seat of fracture should usually be extracted before applying the dressing, as they eventually will be lost, and are a source of danger of infection if allowed to remain. When only slightly loose the teeth may sometimes be left in place.

When neuralgia is caused by pressure of callus upon the inferior dental nerve or its branches, it may become necessary to remove the redundant bone, or even to resect a portion of the nerve-trunk. Any rough spurs of bone can easily be smoothed away with the surgical engine.

In treating recent cases of *fracture of the condyloid process* absolute fixation of the lower to the upper jaw by means of interdental splints is inadvisable, owing to the proximity of the fracture to the joint, with consequent danger of ankylosis. Ordinarily all that is necessary is restriction of movement by means of a modified Barton bandage not too tightly applied, with instructions to the patient to use the jaw with moderation. After five weeks, as a rule, the bandage may be removed. Where there is extreme displacement of the upper fragment, or excessive deformity from deviation of the chin, or where ankylosis seems unavoidable, excision of the condyle followed by arthroplasty is probably advisable.

In the treatment of **fractures of the upper jaw** much depends upon the position and extent of the injury. In most cases splints are not required, as there is very little displacement. When the tuberosity is broken off, as in extraction of a third molar, an attempt should be

made to obtain union by bringing the upper and lower teeth together with a Barton bandage. If the parts fail to unite after a reasonable time, the fragment should be removed. The same care must be paid in regard to cleanliness and extraction of loosened and diseased teeth as in fracture of the mandible. Sometimes, after gunshot wounds, or perforation of the hard palate by a blunt instrument, a permanent opening into the nose remains, which requires closure with an obturator.

### REVIEW QUESTIONS

Give the four principal varieties of fracture and the general principles of treatment.

Give the etiology and commonest seats of fracture of the mandible.

Give reasons for its common occurrence in the region of the mental foramen.

Give the complications of fracture of the mandible.

Give the symptoms and diagnosis of fracture of the mandible.

Give the prophylactic treatment of fracture of the mandible. Give the simplest form of treatment in which the occlusion of the teeth is good.

What is the best splint to use in cases where there are several good teeth on each side of the fracture?

What is the best splint when the teeth are poor or where the fracture is behind the region of the teeth?

Describe the making of a mandibulomaxillary splint of metal.

## CHAPTER XXVII

### TRIFACIAL NEURALGIA AND FACIAL PARALYSIS

#### TRIFACIAL NEURALGIA

THE word neuralgia signifies a pain along the course of a nerve. It is applied to any pain that shoots along the course of a nerve, that is not due to organic disease of the nervous system, or the cause of which is not immediately evident. But the more our knowledge advances, the more is trifacial neuralgia regarded as a symptom, rather than a disease itself.

Trifacial or trigeminal neuralgia may be broadly classified into two forms: (1) In which no cause can be found, and presenting a definite course and clinical picture—the so-called neuralgia quinti major, or tic douloureux; (2) in which the pain is caused by some irritative lesion along the course of the fifth nerve—neuralgia minor. Some authorities make other subdivisions of the disease, for example, neuralgia secondary to disease of the nerves of the head, general diseases, etc. But for practical purposes the classification given, viz., neuralgia in which a cause can be found and that in which no cause can be found, is sufficient. With the advance of our methods of diagnosis, such as by the *x*-rays, and a better knowledge of pathologic lesions of the teeth and jaws, the latter group is growing smaller.

**Etiology.**—*Central Lesions.*—Tumors of the brain or



meninges, or of the roots of the nerve itself, may give rise to neuralgia. Syphilitic gummata of these regions or fracture of the base of the skull may cause neuralgia by pressure on the roots of the fifth nerve. These causes nearly always produce anesthesia of the areas supplied by the nerve, especially noted in the intervals between the attacks of pain.

*Peripheral Causes.*—The following causes may result in trifacial neuralgia: an exposed pulp of a tooth, periodontitis, an impacted tooth; inflammatory conditions of the jaw-bones causing increased density from deposit of lime salts, resulting in pressure on the nerve filaments; tumors pressing on the nerve-trunks; pyorrhœa alveolaris; eye-strain; middle-ear disease; inflammation of the maxillary, frontal, and sphenoid sinuses and the ethmoid air-cells.

*General diseases* or conditions of the blood, such as anemia, diabetes, and malaria, may result in trigeminal neuralgia. No cause may be discoverable.

**Symptoms.**—These vary greatly in intensity according to the cause and extent of the area supplied by the fifth nerve that is involved. In some cases the pain is confined to one or two divisions of the nerve, the maxillary and mandibular divisions being most frequently involved. The pain is not always confined to the division of the nerve supplying the seat of the lesion, but may be referred to other parts of the face. In the so-called neuralgia minor, due to an obvious cause, the symptoms consist usually of sharp, shooting pains along the course of the nerve, beginning at the seat of the lesion. These pains may come without provocation, and as suddenly disappear. Cases of this form frequently occur in which

the character of the attacks cannot be distinguished from that of the more severe form, and this leads one to suppose that all cases of trifacial neuralgia have an original cause in irritation somewhere along the course of the fifth nerve. This is further borne out by the discovery and removal of local causes, followed by cure, in cases previously diagnosed by neurologists as neuralgia major. It is obvious that when a cause has been found, the condition of the patient should not be referred to as neuralgia, but classified according to the particular lesion of which the neuralgia is merely a symptom. Thus a case of brain tumor pressing upon the roots of the fifth nerve would not be called neuralgia after diagnosis of the cause was made. The pain of neuralgia is accompanied by more or less tenderness of certain points, particularly over the supra-orbital, infra-orbital, and mental foramina, the peripheral points of exit of the branches of the nerve.

In the severe form of the disease, neuralgia quinti major, or tic douloureux, the case begins as one of simple neuralgia, but does not respond to treatment, and search for a cause proves fruitless. The attacks of sharp shooting pain increase in frequency and severity, and often interfere with any kind of work on the part of the patient. They often come on without any obvious cause, but are sometimes apparently induced by sudden shock, exposure to cold, or even talking. The attacks may last for a few seconds or for several minutes, and depart as suddenly as they come. During the paroxysms the patient may scream and roll on the floor in agony, and life becomes unbearable. The pain is accompanied by twitching of the facial muscles (tic), and

thus it is seen that the seventh nerve is involved in the disease as well as the fifth. The skin on the side of the face affected is flushed, and trophic changes, such as falling out of the hair, sometimes occur.

**Diagnosis.**—It is of the highest importance that cases due to a local irritation of the fifth nerve be distinguished from those in which no cause can be found. The character of the attacks of pain and its location will often lead easily to the source of the trouble. A careful examination of the mouth, teeth, accessory sinuses, etc., should be made in all cases. The *x*-ray is the most valuable means of diagnosis of obscure lesions of the face and jaws that we possess, and no case of trigeminal neuralgia should be allowed to go without careful examination of a good *x*-ray picture that includes the entire facial region. By neglect of this precaution many hidden causes are overlooked and the case placed in the class of neuralgia major.

**Prognosis.**—This depends upon the removal of the cause and the duration of the trouble. If the cause can be located and removed and the symptoms have not existed for too long a period, a cure can be expected. In cases of long standing, however, the pains may continue after the cause has been removed. When the cause cannot be determined, resection of portions of the nerve is frequently followed by recurrence, and even extirpation of the Gasserian ganglion may not effect a cure.

**Treatment.**—This consists in removing the cause, if it can be found. Extraction of an impacted tooth, excision of a tumor pressing on the fifth nerve or its branches, drainage of suppurating accessory sinuses,

in short, removal of any irritation to the nerve, will in most cases effect a cure. When the neuralgia is due to general diseases, such as malaria, anemia, etc., these diseases are to be treated, and the neuralgia will disappear as soon as they are cured. The systemic treatment consists in building up the health of the patient with nutritious food, tonics, exercise, etc.

When no cause, either systemic or local, can be discovered and during the attacks of pain palliative measures must be used. This consists in the local application of hot cloths, blisters, liniments, etc., and the administration of analgesics, such as antipyrin or phenacetin. *Cannabis indica* often affords great relief, and may be given as follows:

R. Codein. sulph..... gr. viij;  
 Ext. cannabis ind..... gr. iv.—M.  
 Ft. capsul. No. xvi.  
 Sig.—One capsule every four hours.

It is not wise to use opium except as a last resort, because of the danger of habit formation. The value of palliative treatment lies only in relief of the patient until an operation can be performed, or in cases in which an operation is contraindicated.

In cases of neuralgia in which the pain is confined to one division of the fifth nerve the operation of resection of a portion of the nerve may be tried. The object is to sever the nerve at a point between the point of irritation and the nerve-centers. These peripheral operations are usually performed in the region of exit of the nerve from the skull on to the face. The ophthalmic division is reached at the supra-orbital foramen, where the supra-orbital nerve emerges on the face.

*Resection of the Infra-orbital Branch.*—This is best performed by an incision in the vestibule of the mouth, as scarring of the face is thereby avoided. General anesthesia is required. The upper lip is raised and held up with a retractor. The tissue of the cheek is divided by an incision upward from the top of the vestibule of the mouth, the knife keeping close to the bone until the nerve is found as it emerges from the infra-orbital foramen. The nerve is grasped with a tenaculum or pair of hemostatic forceps and divided. The distal portion of the nerve is first pulled upon, and as much of it removed as possible by this means (avulsion). The portion emerging from the foramen is then treated in the same way. By this means it is sometimes possible to remove the nerve as far back as Meckel's ganglion. If the infra-orbital artery is divided, it must be ligated. After avulsion of the nerve the wound is lightly packed with gauze. If the incision has been large, one or two silk sutures may be inserted, but the wound should never be entirely closed, as there is always some infection. This rarely amounts to much, however, and is treated by keeping the mouth as clean as possible, the use of mouth-washes, etc.; the gauze drain should be changed twice a day, a smaller piece being inserted each time, until the wound presents no pockets that could hold pus.

*Resection of the Mental Branch at the Mental Foramen.*—This is done through an incision in the vestibule of the mouth over the mental foramen, which lies below and between the two lower premolar teeth. The nerve is grasped as it emerges from the foramen, and a portion removed, as in the case of the infra-orbital branch. Sometimes it is of advantage to cut away a portion of

bone surrounding the nerve before it emerges with the surgical engine, and in this connection it must be remembered that the nerve at this position is recurrent, running backward to the foramen, so that the bur must cut in a direction toward the symphysis' menti.

*Resection of the Inferior Dental Branch.*—This operation is usually performed near the point of entrance of the nerve into the inferior dental tube. The skin behind the ramus of the lower jaw is drawn forward, so that the scar left by the operation will be hidden behind the ramus. A vertical incision, parallel to the fibers of the masseter muscle, about three-quarters of an inch in length, is made over the middle of the ramus down to the bone, the skin, superficial fascia, deep or masseteric fascia, masseter muscle, and periosteum being cut through. Peripheral fibers of the facial nerve running to the muscles of expression about the lower lip are also unavoidably divided by this incision, thus accounting for the temporary paralysis of the muscles mentioned following this operation, the paralysis disappearing eventually when regeneration of the nerve-fibers takes place. After the incision is made, the periosteum is lifted away from the bone. A hole is now trephined with the surgical engine on the outer side of the ramus corresponding to the position of the inferior dental foramen on its inner side. This point is situated in the center of the ramus, *i. e.*, between its anterior and posterior edges, and midway between the bottom of the sigmoid notch and the angle of the mandible. The trephine is made to pass through the whole thickness of the ramus, and the hole may then be prolonged downward with a surgical bur. This exposes the inferior dental

nerve as it enters the mandibular tube. The nerve is grasped with a pair of hemostatic forceps and divided, about half an inch of it being removed. Sometimes the entrance to the bony canal is packed with silver foil to prevent reunion of the cut ends of the nerve. The button of bone removed by the trephine may now be replaced in the opening, the edges of the masseter muscle brought together with buried sutures of chromicized catgut, and the skin sutured with silk or silkworm-gut.

In making the primary incision one must avoid dividing Stenson's duct, which crosses the ramus of the mandible about half an inch below and parallel to the zygoma. Division of this results in a salivary fistula.

The lingual nerve must not be mistaken for the inferior dental, the former lying in front of and above the latter.

Care must be taken not to wound the inferior dental artery in dividing the nerve, as serious hemorrhage might ensue.

In the more severe cases of neuralgia in which no cause has been found and in which two or more divisions of the fifth nerve are involved, removal of the Gasserian ganglion, or division of the sensory root of the nerve as it enters the ganglion, gives the only hope of cure. This operation is one of the most dangerous known to surgery, the mortality being largely due to hemorrhage. It is followed by complete anæsthesia of the face on the side operated on. Owing to loss of sensibility of the cornea, ulceration from foreign particles is liable to occur unless the eye is protected by a watch-glass.

Of recent years brilliant results have been reported following the injection of alcohol in trigeminal neuralgia. By means of a special syringe the alcohol can be injected

directly into the nerve as it emerges through the foramen rotundum, or the foramen ovale, or into the Gasserian ganglion itself. It is possible to locate these foramina with considerable accuracy by means of certain landmarks and measurements. With this method relief from the attacks can be hoped for in many cases, often lasting for several years, if not permanently.

#### FACIAL PARALYSIS

This is a loss of function of the muscles of expression of the face due to a lesion of the seventh or facial nerve.

**Etiology.**—Facial paralysis may be caused by—(a) General diseases; (b) lesions of the cortical facial center or of the seventh nerve nuclei at the base of the brain; (c) lesions of the nerve within the aqueductus Fallopii; (d) lesions of the nerve after its exit from the stylo-mastoid foramen.

(a) By far the most common form of facial paralysis is the so-called “rheumatic type,” which is usually due to exposure to cold. Other general diseases with which facial paralysis is sometimes associated are alcoholic, lead, and diphtheritic neuritis, malaria, and uremia.

(b) Among central lesions are cerebral hemorrhage (apoplexy), embolism, tumor, or gumma, affecting the cortical area for the face, basal meningitis, gumma, or tumor, causing pressure upon or destruction of the nuclei at the base of the brain.

(c) Middle-ear disease, fracture of the base of the skull, tumors involving the aqueductus Fallopii.

(d) *Peripheral Causes.*—Pressure of tumors and inflammation of the parotid gland, through which the nerve and its branches pass after leaving the skull.



Section of branches of the nerve by injury or operation.  
Pressure by the obstetric forceps.

**Symptoms.**—The muscles of expression on the side of the face affected are paralyzed. There is no loss of sensation. The side of the face affected, including the forehead, is smooth. The angle of the mouth droops, allowing the escape of saliva. The muscles of the



Fig. 58.—Left-sided facial paralysis, involving all three groups of muscles supplied by the seventh cranial nerve, namely, the eye, nasal and labial groups. Note the obliteration of the nasolabial fold on the side of paralysis, the drooping of the left angle of the mouth, the inability to close the left eyelid, and loss of action of the muscles of the eyebrows (Eisendrath).

unaffected side draw the mouth toward the healthy side (Fig. 58). The cornea is dry. This is explained by the fact that the facial nerve supplies the orbicularis palpebrarum, and when this is paralyzed there is no distribution of tears. The tears tend to flow over on to the cheek, instead of being carried to the lacrimonasal duct. As a result of this olfaction is interfered with.

Owing to partial paralysis of the buccinator muscle, mastication is affected. If the individual laughs or indulges in vigorous speech, the cheek is puffed out with each expiratory effort. Speech is affected, owing to lack of proper movements of the lips. Sweating on the side of the face ceases or is lessened, as a rule. The tongue when protruded goes to the affected side, being pushed over by the geniohyoglossus muscle of the opposite side.

The position of the lesion causes variations in these symptoms. When it is central, the upper part of the face may escape paralysis or be only slightly affected, because this part receives its nerve-supply from both sides of the brain. Other cranial nerves are also liable to be affected by central lesions.

*Bell's palsy* is facial paralysis associated with loss of sensation of taste in the anterior portion of the tongue. It is caused by a lesion in the aquæductus Fallopii after the chorda tympani joins the seventh nerve and before it leaves it.

In lesions of the nerve behind the point at which the nerve to the stapedius is given off, sensitiveness to sounds may be increased owing to paralysis of this muscle. The soft palate may be affected, causing interference with swallowing and speech. Deafness is often associated with the paralysis when the cause is middle-ear disease.

*Prognosis.*—This depends, first, upon the seat of the lesion; second, upon the nature of the lesion; third, upon the damage that has been done to the nerve, ascertained by electric reactions.

In central lesions the prognosis for recovery is unfavor-

able, though in syphilitic cases marked improvement may sometimes occur.

Paralysis secondary to middle-ear disease very rarely shows marked improvement.

In the peripheral forms and those due to general disease the electric reaction is a good guide to the prognosis. It is not favorable if reactions of degeneration are present. The loss of excitability to the faradic current may be followed by recovery in about three months. In traumatic cases the prognosis is most favorable.

*Treatment.*—The cause should be determined and, if possible, removed. In syphilitic lesions, mercury, potassium iodid, or salvarsan (606) may be beneficial. Very little can be done in other central lesions. Middle-ear disease, if present, should be treated. Tumors pressing upon the nerve should be removed if possible. In the rheumatic type, when slight, a small blister behind the ear or a mustard plaster and prevention of fresh exposure to cold are all that is necessary. Potassium iodid may be of some benefit in lead neuritis. Massage is of value in all cases of facial paralysis. Electricity should also be used. The variety selected should be that to which the muscles respond. In cases incurable by other means, an operation uniting the distal end of the facial nerve with the hypoglossal has been attempted.

### REVIEW QUESTIONS

Give the definition, etiology, symptoms, diagnosis, prognosis, and treatment of trifacial neuralgia.

Give the operative treatment of trifacial neuralgia.

Give the systemic treatment of trifacial neuralgia.

Define, and give the etiology, symptoms, prognosis, and treatment of facial paralysis.



# INDEX

---

- ABDUCENS nerve, 74
- Abscess, 102  
  alveolar, acute, treatment of, 191  
    and necrosis, 191  
    dioxid of hydrogen in, 192  
    opening externally, 192  
    into maxillary sinus, 192  
    treatment of, 191
- Actinomyces, 108
- Actinomycosis, 197  
  etiology, 197  
  metastases in, 197  
  prognosis, 198  
  symptoms, 197  
  treatment, 198
- Adenofibroma, 163
- Adenoids, 213  
  mouth-breathing and, 213
- Adenoma, 163, 166
- Adhesive plaster, 157
- Adrenalin chlorid, 131  
  and novocain, 131
- Air hunger, 124
- Alcohol, injection of, for neuralgia,  
  263
- Alveolar abscess. See *Abscess, al-  
  veolar.*  
  process, development of, 22  
    maxilla, 21
- Anastomosis, 71
- Anemia, 97  
  and trifacial neuralgia, 257
- Anemia in syphilis, 175  
  primary, 98  
  secondary, 98
- Anesthesia, beta-eucain hydrochlor-  
  id, 130  
  cocain hydrochlorid, 130  
  ether, 133, 140  
  ethyl chlorid, 130, 143  
  general, 132  
  intratracheal insufflation, 141  
  local, 130  
    dangers of, 131, 132  
    for extraction of teeth and  
      operations about jaw bones,  
      131  
    superficial, 130  
    technic, 131  
  nitrous oxid, 141  
    and oxygen, 141  
  novocain, 130  
    and adrenalin chlorid, 131  
  spinal, 130  
  stovain in, 130
- Anesthetic, choice of, 132  
  general, 132
- Aneurysm needle, 145
- Angina, Ludwig's, 208  
  Vincent's, 188
- Angiofibroma, 163, 169
- Angioma, 163, 166
- Angle of mandible, changes in, 26
- Ankylosis, acute, 104

- Ankylosis, acute, and impacted  
 tooth, 221  
 false, 220  
 symptoms, 221  
 treatment, 223  
 and change in shape of mandible;  
 218  
 and tetanus, 223  
 false, 218  
 chronic, 219  
 symptoms, 221  
 treatment, 222  
 of temporomandibular joint, 217  
 and swelling of parotid  
 gland, 205  
 true, 217  
 etiology, 218  
 symptoms, 221  
 treatment, 220  
 x-ray and, 221
- Anorexia, 104
- Anthrax, 107
- Antitoxin in septicemia, 118  
 in tetanus, 112
- Antrum of Highmore, 21, 39. See  
*Maxillary sinus*.  
 diseases of, 200
- Aorta, 63, 70
- Aphthous stomatitis, 183
- Aqueductus Fallopii, 84, 86
- Artery, alveolar, 68  
 ascending pharyngeal, 50, 67, 93  
 wound of, 212  
 basilar, 68  
 common carotid, 49, 50, 63  
 branches, 63  
 ligation of, 145  
 relations of, 63  
 surgical line of, 63  
 external carotid, 50  
 branches, 68  
 course, 67
- Artery, external carotid, ligation  
 of, 146  
 facial, 50  
 branches of, 68  
 course of, 67  
 inferior dental, 68, 263  
 thyroid, 49  
 internal carotid, 50  
 branches of, 66  
 cavernous portion, 65  
 cervical portion, 64  
 course, 63  
 intracranial portion, 66  
 petrous portion, 65  
 wound of, 93, 212  
 mammary, 51  
 maxillary, branches of, 68  
 course of, 67  
 divisions of, 68  
 lingual, 50, 67  
 branches of, 68  
 occipital, 50, 67, 71  
 ophthalmic, 33, 66  
 posterior auricular, 50, 67  
 princeps cervicis, 71  
 profunda cervicis, 71  
 ranine, 68  
 subclavian, 50, 71  
 superficial temporal, 67  
 superior intercostal, 51, 71  
 thyroid, 50, 67  
 thyroid axis, 50  
 transversalis colli, 50  
 vertebral, 49, 50, 63  
 course of, 68
- Auditory meatus, internal, 32  
 nerve, 74
- Avulsion, 261
- Azygos uvulæ, 55
- BACILLUS *aërogenes capsulatus*, 108  
 anthracis, 107

- Bacillus coli communis, 107  
   diphtheriæ, 108  
   mallei, 107  
   pyocyaneus, 107  
   tuberculosis, 107  
   typhosus, 107  
 Bacteria in surgical affections, 106  
   pyogenic, 106  
 Bandage, Barton, 125, 158  
   gauze, 157  
   muslin, 157  
 Bartholin, duct of, 91  
 Barton bandage, 125, 158  
   in fracture of mandible, 240  
   modification, 158  
 Base of skull, inferior surface, 29  
   internal surface, 29  
 Basilar process, 32  
   of occipital bone, 29  
 Bell's palsy, 266  
 Benign tumors, 164  
 Beta-eucain hydrochlorid, 130  
 Bistoury, 149  
 Blood in anemia, 98  
   red corpuscles, 97  
     granular degeneration of, 98  
     nucleated, 98  
   supply of head, 63  
   of teeth, 68, 70  
   transfusion in hemorrhage, 128  
   white corpuscles, 98  
 Blunt dissector, 150  
 Bone, ethmoid, 19  
   frontal, 28  
   hyoid, 26  
   inferior turbinated, 36  
   intermaxillary, 34, 233  
   lacrimal, 36  
   malar, 28  
   mandible, 22  
   maxilla, 20, 28  
   middle turbinated, 37  
   palate, 36  
   premaxilla, 233  
   repair of, 114  
   sphenoid, 18  
   superior turbinated, 38  
 Bones, nasal, 34, 36  
   of face, development of, 17  
   of skull, 18  
 Brachial plexus, 51  
 Branchial folds, 25  
 Brophy's operation for cleft-palate, 235  
 Bulla ethmoidalis, 38, 42  
   Burs. 152  
  
 CALCULUS and ranula, 207  
 Camphorated oil, 122  
 Canal, accessory palatine, 34  
   anterior dental, 40  
   carotid, 32  
   inferior dental, 24  
   infra-orbital, 33  
   lacrimonasal, 33  
   of Huguier, 85  
   posterior palatine, 34  
 Cancellated tissue of mandible, 24  
 Cancer. See *Carcinoma*.  
 Cancrum oris, 186  
 Cannabis indica, 260  
 Carcinoma, 163, 166  
   diagnosis from sarcoma, 164  
   encephaloid, 164  
   hard, 164  
   medullary, 164  
   of cheek, 166  
   of lip, 166  
   of mouth and submaxillary  
     lymph-glands, 214  
   of parotid gland, 205  
   of tongue, 166  
     diagnosis from gumma, 177

- Carcinoma, scirrhus, 164  
 soft, 164  
 treatment of, 166
- Cardiac massage, 140
- Caries of bone, 106
- Carotid canal, 32  
 foramen, 29  
 sheath, 48, 63
- Cartilage, thyroid, 63  
 triangular, 36
- Catgut, 155  
 chromicized, 155
- Cautery, actual, 170
- Cavernous sinus, 65
- Cavity, oral, 94
- Cellulitis, 104, 208  
 and streptococci, 106
- Cervical fascia, 47  
 deep, 47  
 superficial, 47  
 glands, deep, 72  
 superficial, 72  
 lymphatics, 72  
 plexus, 50
- Chancre, 174  
 of lip, diagnosis from epithelioma,  
 176
- Cheek, carcinoma of, 166
- Childbirth, injuries during, 239
- Chill, 104  
 in pyemia, 118
- Chloroform, 132  
 action of, 132  
 anesthesia, mortality from, 132
- Chondroma, 163, 166
- Circle of Willis, 69, 71
- Circulation, collateral, 71
- Cleft palate, acquired, 231  
 causes of, 231  
 treatment of, 231  
 vela in, 231  
 age for operation, 235
- Cleft palate, Brophy's operation  
 for, 235  
 combined with harelip, 239  
 complete, 234  
 congenital, 233  
 causes of, 234  
 double, 234  
 incomplete, 234  
 Lane's operation, 237  
 obturator in, 231  
 operator treatment, 235  
 single, 233  
 syphilis and, 231  
 syphilitic, 177, 179  
 taking impression in, 232
- Clinoid process, anterior, 29  
 middle, 32  
 posterior, 32
- Cocain and osteomyelitis, 194  
 hydrochlorid, 130
- Cohnheim's theory, 162
- Collapse, 120  
 in ether anesthesia, 135  
 pathology of, 120  
 symptoms of, 121  
 treatment of, 122
- Collateral circulation, 71
- Colon bacillus, 107
- Condyle of mandible, 43
- Condylod process of mandible, 23,  
 29  
 fracture of, 248  
 treatment, 254  
 of occipital bone, 29
- Congestion, 97
- Conjunctiva, nerve supply, 77
- Contusion, definition, 109  
 pathology, 109  
 symptoms, 109  
 treatment, 110
- Cornea, ulceration of, 263
- Corneal reflex, 138



- Coronoid process of mandible, 22,  
     29  
     suture, 29  
 Cranial nerves, 74  
 Cranium, bones of, 18  
 Cravat fascia, 47  
 Cribriform plate, 20, 34  
     of ethmoid, 19  
     tube of mandible, 24  
         recurrent portion, 25  
 Crista galli, 20, 29  
 Cyanosis in ether anesthesia, 139  
     in nitrous oxid anesthesia, 143  
 Cyst, 164  
     dentigerous, 172  
     follicular, 171  
     root, 171  
     sebaceous, 166
- DEGLUTITION, 54**  
 Dental arch, process of widening, 34  
 Dentigerous cyst, 172  
 Development of mandible, 25  
 Diabetes and trifacial neuralgia,  
     257  
 Digastric fossa of mandible, 23  
 Dioxid of hydrogen and necrosis,  
     196  
     and osteomyelitis, 192  
 Diphtheria, 212  
     antitoxin in hemorrhage, 125  
     bacillus, 107  
 Dislocation of temporomandibular  
     joint, displacement, 215  
     etiology, 215  
     symptoms, 216  
     treatment, 217  
 Double lip, 160  
 Drainage, 111, 112  
     materials, 156  
 Dressing forceps, 150  
 Dressings, 157
- Drills, 152  
 Drop-method in anesthesia, 137  
 Duct of Bartholin, 91  
     of Rivinus, 91  
     of Stenson, 80, 263  
         obstruction of, 206  
     of Wharton, 90
- ECCHYMOSES, 109**  
 Edema, 103  
 Elevator, 152  
 Eminentia articularis, 27, 45  
 Empyema of maxillary sinus, 200  
 Engine, Cryer's surgical, 154  
 Enteroclysis, 121  
 Epiglottis, 95  
 Epistaxis, 123  
 Epithelioma, 163, 165, 166  
     diagnosis from chancre of lip, 176  
     of face, 166  
 Epulis, 168  
     fibrous, 169  
     treatment of, 170  
 Erysipelas, 106  
 Erythrocytes, 97  
 Ether, 132, 140  
     action of, 135  
     anesthesia, 133  
         cardiac failure in, 140  
         massage in, 140  
         circulatory failure in, 139  
         color in, 139  
         cyanosis in, 139  
         drop-method, 137  
         fourth stage, 134  
         method of administration, 137  
         minor operations under, 135  
         mortality from, 132  
         musculospiral paralysis in, 138  
         oxygen in, 140  
         position of patient, 136  
         precautions, 135

- Ether anesthesia, preparation for,  
 135, 136  
 primary stage, 133, 134  
 pupil in, 139  
 respiration in, 138  
 respiratory failure in, 139  
 second stage, 134  
 stage of excitement, 134  
   of relaxation, 134  
 stages of, 133  
 stimulants in, 139  
 third stage, 134  
 vomiting in, 139  
 wire mask for, 137  
 with nitrous oxid, 136  
 cause of death by, 135  
 comparison with chloroform,  
 132  
 contraindications to, 133  
 effect on kidneys, 136  
 inflammability of, 140  
 narcosis, 133  
 vapor and air, 140
- Ethmoid bone, 19  
 cribriform plate, 19  
 crista galli, 20  
 laterla masses, 20  
 os planum, 20  
 perpendicular plate, 19  
 vertical plate, 19  
 cells, anterior, 37, 43  
   middle, 20, 37, 43  
   outlets, 43  
   posterior, 38, 43  
 cribriform plate, 34  
 turbinated processes, 36  
 unciform process, 38  
 vertical plate, 36
- Ethyl chlorid, 130, 132, 143  
 Eustachian tube, 54, 55  
 External auditory meatus, 28  
 Extravasation, 109, 123
- FACE, bones of, 18  
 epithelioma of, 166  
 lymphatics of, 72  
 motor nerve, supply of, 83  
 nerve supply of, 75  
 tumors of, 166  
 wounds of, 155
- Facial nerve, 74, 83  
 notch, 23  
 paralysis, 264  
   and swelling of parotid gland,  
   205  
 central lesions and, 264  
 electrical reaction and, 267  
 etiology, 264  
 general diseases and, 264  
 middle-ear disease and, 264  
 parotid gland and, 264  
 peripheral, causes, 264  
 prognosis, 266  
 rheumatic type, 264  
 symptoms, 265  
 treatment, 267
- Fascia, cervical, 47  
 parotid, 48  
 prevertebral, 48
- Fauces, pillars of, 54, 92, 95  
 Fever in inflammation, 103  
   surgical, 115
- Fibrin ferment, 115  
 Fibroblasts, 113  
 Fibroma, 163, 166  
 Fibromyoma, 163  
 Fibrous epulis, 169  
 Fissure, Glaserian, 45, 85  
   sphenoid, 32, 33, 76  
   sphenomaxillary, 33, 77, 78
- Fistula, 102  
 salivary, 207, 263
- Floor of mouth, 59, 95  
 of nose, 36
- Fluctuation, 103

- Foramen, accessory palatine, 29  
 anterior condyloid, 29, 32  
   ethmoid, 32, 33  
   lacerated, 32  
   palatine, 29  
 carotid, 29  
 for nasal nerve, 32  
 inferior dental (mandibular), 23,  
   24, 79  
 infra-orbital, 28, 77  
 jugular, 29, 32  
 magnum, 29, 32  
 malar, 33  
 mental, 23, 25, 28, 79  
 middle lacerated, 29, 32  
 of Scarpa, 21, 34  
 of Stenson, 21, 34  
 olfactory, 32  
 optic, 32, 33  
 ovale, 29, 32, 76, 78  
 posterior condyloid, 29, 32  
   ethmoid, 32, 33  
   lacerated, 29, 32  
   palatine, 29  
 rotundum, 32, 77  
 spinosum, 29, 32  
 stylomastoid, 29, 84  
 supra-orbital, 28
- Forceps, Allis', 150  
 dental, 152  
 dressing, 150  
 hemostatic, 150
- Fossa, anterior palatine, 34  
 glenoid, 29, 42  
 nasal, 28, 34  
 of skull, anterior, 29  
   middle, 29, 32  
   posterior, 29, 32  
 pterygoid, 29  
 scaphoid, 54  
 sphenomaxillary, 41, 77, 78, 81
- Fracture, 242
- Fracture, classification, 242  
 comminuted, 242  
 compound, 242  
 general principles of treatment,  
   242  
 greenstick, 242  
 of condyloid process of mandible,  
   244, 248  
   treatment of, 254  
 of mandible, 243  
   abscess and, 245  
   and anesthesia of lip, 245  
   at angle, 244  
   at mental foramen, 244  
   Barton bandage in, 249  
   bilateral, 244  
   bone plates in, 251  
   cellulitis and, 245  
   complications of, 244  
   delayed union, 245  
   disinfection of mouth in, 248  
   during delivery, 244  
   etiology, 243  
   feeding patient in, 249  
   following necrosis, 246  
   Gilmer's treatment, 250  
   impressions and casts for  
     splint, 251  
   in edentulous mouth, 253  
   infection, 245  
   involvement of teeth, 245  
   Ludwig's angina and, 246  
   mandibulomaxillary metal  
     splint, 252  
   metal bands in, 251  
     splint, 252  
   necrosis and, 245  
   neuralgia and, 245, 254  
   non-union, 245  
   plaster-of-Paris bandage in,  
     250  
   seat of fracture, 243

- Fracture of mandible, slow reduction of, 253  
 splints in, 250  
 symptoms and diagnosis, 246  
 treatment of, 248  
   of infection, 253  
   of loose teeth, 254  
 vulcanite interdental splint in, 251  
 x-ray in diagnosis, 248  
 of upper jaw, 243  
   treatment, 254  
 simple, 242
- Frontal bone, 28  
 nasal spine, 36  
 orbital plate, 29  
 process, 42  
 sinus, 37, 42  
   infection of, 201  
   variations, 43
- GANGLION, ciliary, 80  
 Gasserian, 76, 77, 263  
 geniculate, 86  
 lenticular, 80  
 Meckel's, 54, 81  
   branches of, 81  
 ophthalmic, 77, 80  
   branches, 80  
 otic, 55, 82  
   branches, 82  
 sphenopalatine, 81  
 submaxillary, 82
- Gangrene, dry, 105  
 emphysematous, 108  
 moist, 105
- Gasserian ganglion, 76, 77  
   depression for, 32  
   removal of, 263
- Gauze dressing, 157  
 for drainage, 156
- Genial tubercles, 23
- Geniculate ganglion, 86
- Giant-cell myeloma, 166, 169
- Gilmer's treatment of fracture of mandible, 250
- Gland, parotid, 67, 84, 88  
   accessory, 89  
   anatomic relations, 89  
   blood supply, 89  
   diseases of, 205  
   duct of, 89  
   function, 88  
   lymphatics of, 90  
   nerve supply, 89  
   secretion, 88  
   situation, 89  
   structures found in, 90  
   tumors of, 170
- sublingual, 91  
 anatomic relations, 91  
   ducts of, 91  
   nerve supply, 82  
   secretion, 91
- submaxillary, 50, 90  
 anatomic relations, 90  
 blood supply, 90  
 coverings of, 90  
 duct of, 90  
 nerve supply, 82, 90  
 secretion, 90
- Glanders, 107
- Glands, buccal, 91  
 labial, 91  
 lingual, 91  
 mucous, 91  
 palatal, 91  
 salivary, 88  
   diseases of, 205
- Glaserian fissure, 45, 85
- Glenoid fossa, 29, 42
- Glossopharyngeal nerve, 74
- Gonococcus, 107
- Granulation tissue, 114

- Grooved director, 150
- Growth, new, 162  
of mandible, 25
- Gumma, 176, 179  
of hard palate, 177  
of tongue, 177  
diagnosis, from carcinoma, 177
- Gums, hypertrophy of, 159
- HAMULAR process, 19, 33, 55
- Hard palate, 21, 29  
gumma of, 177
- Harelip, 237  
combined with cleft palate, 239  
treatment of, 237
- Head, blood supply, 63  
veins of, 69
- Healing by first intention, 114  
by primary union, 114  
by second intention, 114  
by third intention, 114
- Hematemesis, 123
- Hematoma, 109, 123
- Hematuria, 123
- Hemoglobin, 97  
normal percentage, 97
- Hemophilia, 126  
blood in, 126  
etiology, 126  
pathology, 126  
prognosis, 127  
symptoms, 127  
treatment, 127
- Hemoptysis, 123
- Hemorrhage, 122  
anatomic varieties, 123  
arrest of, 111, 124  
arterial, 123  
blood transfusion in, 128  
capillary, 123  
persistent, 125  
clinical classification, 123
- Hemorrhage, constitutional effects  
of, 124  
treatment following, 126  
following tooth extraction, 125  
from particular regions, 123  
intermediate, 123  
internal, 123  
primary, 123  
secondary, 123  
serum treatment, 125, 128  
spontaneous arrest of, 124  
treatment of, 124  
venous, 123, 124
- Hemorrhagic diathesis, 126
- Hemostatic forceps, 150
- Hiatus semilunaris, 38, 41
- Highmore, antrum of, 39. See also  
*Maxillary sinus.*
- Horsehair, 155
- Huguier, canal of, 85
- Hutchinson's teeth, 178
- Hyoid bone, 26  
muscular attachments, 27
- Hyperemia, active, 97  
passive, 97
- Hyperplasia, 159
- Hypertrophy, 159  
acquired, 159  
inherited, 159  
of gums, 159
- Hypodermoclysis, 121
- Hypoglossal nerve, 75
- IMPACTED teeth, 224  
acute exanthemata and, 226  
and trifacial neuralgia, 257  
canine, 225  
diagnosis of, 228  
etiology, 226  
general effects, 229  
heredity and, 228  
in maxillary sinus, 203

- Impacted teeth, local effects, 228  
     order of impaction, 224  
     symptoms, 228  
     third molar, 225  
     treatment of, 229  
     x-rays and, 228
- Incisor teeth, germs of, 34
- Inflammation, acute, 99  
     bacteria and, 99  
     causes, 99  
     chronic, 99  
     definition of, 99  
     diapedesis, 100, 101  
     edema in, 103  
     emigration of leukocytes, 100,  
         101  
     etiology, 99  
     fever in, 103  
     gangrenous, 104  
     leukocytosis in, 104  
     margination of leukocytes, 100  
     pathology of, 100  
     phagocytosis, 101  
     phlegmonous, 104  
     resolution, 101  
     stasis, 100  
     suppuration, 101, 102  
     symptoms of, 102  
     terminations of, 101  
     tissue changes in, 100  
     treatment of, 104
- Inframaxillary branch of facial  
     nerve, 86
- Infra-orbital canal, 20, 33  
     foramen, 28  
     nerve, 33, 77  
     vessels, 33
- Infundibulum, 38
- Instruments, 149  
     for operation within the mouth,  
         152
- Interarticular fibrocartilage, 46
- Interarticular fibrocartilage, muscle  
     to, 57
- Intermaxillary bone, 34, 233  
     suture, opening of, 34
- Intratracheal insufflation anesthe-  
     sia, 141
- Intravenous injection of normal  
     saline, 139
- Involucrum, 194
- Iodin in sterilization, 111, 148
- Iritis in syphilis, 175
- JAW BONES, osteomyelitis of, 192  
     operations about, local anesthesia  
         for, 131  
     sarcoma of, 168  
     tumors of, 166
- Joint, temporomandibular, 45
- Jugular foramen, 29, 32
- KNIVES, 149
- Knot, square, 156  
     surgeon's, 156
- LABOR and deformity of jaws, 241
- Lacrimal bone, 36
- Lacrimonasal canal, 33  
     duct, 36
- Lambdoid suture, 29
- Lane's operation for cleft palate,  
     237
- Lateral wall of nose, 36
- Lead poisoning, 190
- Leukemia, 98
- Leukocytes, 98  
     emigration of, 100, 101  
     margination of, 100  
     polymorphonuclear, 98
- Leukocytosis, 98, 104
- Leukoplakia, 172

- Leukoplakia, diagnosis from mucous patches, 177  
 etiology, 172  
 prognosis, 173  
 symptoms, 172  
 syphilis and, 172  
 treatment, 172
- Ligament, capsular, 46  
 external lateral, 46  
 internal lateral, 46  
 sphenomandibular, 46  
 stylomandibular, 46, 88
- Ligation of common carotid artery, 145  
 of external carotid artery, 146
- Ligature, 155  
 catgut, 155  
 silk, 155
- Lingualis muscle, 53
- Lip, carcinoma of, 166
- Lipoma, 163, 166
- Lock-jaw, 107, 223
- Ludwig's angina, 208  
 and fracture of mandible, 246  
 etiology and pathology, 208  
 prognosis, 209  
 symptoms, 208  
 treatment, 209
- Lues, 174
- Lymph-glands, affections of, 213  
 parotid, 72  
 submaxillary, 72
- Lymphangioma, 163
- Lymphatics, cervical carcinoma and, 166  
 epitrochlear, 175  
 in syphilis, 175  
 of face, 72  
 of neck, 72  
 postcervical, 175  
 submaxillary, in syphilis, 176
- Lymphoma, 163
- MACULAR eruption in syphilis, 175
- Magnum, foramen, 32
- Malar bone, 28  
 foramina, 33
- Malaria and trifacial neuralgia, 257
- Malignant pustule, 107  
 tumors, 164
- Malleus, processus gracilis, 45
- Mandible, 22  
 alveolar process, 23  
 angle, 26  
 body, 22  
 cancellated tissue, 24  
 changes in shape following ankylosis, 218  
 condyle, 43  
 condyloid process, 23, 29  
 fractures of, 248  
 treatment, 254  
 coronoid process, 22, 29  
 cribriform tube, 24, 79  
 development and growth of, 25  
 digastric fossa, 23  
 external oblique line, 23  
 facial notch, 23  
 fracture of, 243  
 Gilmer's treatment, 250  
 genial tubercles, 23  
 inferior dental (mandibular) foramen, 23, 24  
 internal structure, 24  
 lingula, 23  
 mental foramen, 23, 25  
 process, 23  
 muscles attached to, 61  
 mylohyoid groove, 23  
 ridge, 23  
 ramus, 22  
 sigmoid notch, 23  
 sublingual fossa, 23  
 submaxillary fossa, 23  
 symphysis, 23

- Mandible, transverse section, 24  
 Massage and facial paralysis, 267  
 Masseter muscle, 55  
 Mastication, accessory muscles of, 55  
   muscles of, 55  
 Mastoid process, 28, 29  
 Maxilla, 20, 28  
   alveolar process, 21  
   anterior palatine fossa, 21  
   cavities formed by, 22  
   development of, 233  
   facial surface, 21  
   foramen of Scarpa, 21  
     of Stenson, 21  
   fractures of, 243  
   lateral processes, 34  
   malar process, 21  
   nasal process, 36  
     surface, 20  
   orbital surface, 20  
   palatal process, 20, 33  
   treatment of fracture of, 254  
   tuberosity, 21  
   zygomatic surface, 21  
 Maxillary sinus, 21, 37, 38  
   acute empyema of, 201  
   anterior wall, 40  
   catarrhal inflammation of, 200  
   chronic suppuration, 201  
   communication with frontal  
     sinus, 42  
   diseases of, 200  
   drainage of, 202  
   empyema of, 200  
   floor, 40  
   impacted teeth in, 203  
   nasal wall, 41  
   outlet, 41  
   pathologic outlet, 42  
   polypi of, 203  
   posterior wall, 41  
 Maxillary sinus, proximal wall, 41  
   roof, 39  
   selection of opening, 212  
   septa, 40  
   shape, 39  
   suppurative inflammation of, 200  
   transillumination and, 201  
   treatment of empyema of, 202  
   tumors of, 203  
   variations in, 39  
   x-ray and, 201  
 Meati of nose, number of, 36  
 Meatus, fifth, 38  
   fourth, 38  
   inferior, 36  
     opening into, 37  
   internal auditory, 32  
   middle, 37, 41  
     cells communicating with, 37  
   superior, 38  
     cells communicating with, 38  
   supreme, 38  
 Meckel's cartilage, 25  
   ganglion, 54, 81  
 Mental foramen, 23, 25, 28  
   and fracture of mandible, 244  
 Mercurial stomatitis, 188  
 Mercury in syphilis, 181  
 Metastasis of tumors, 164  
 Mouth, 94  
   breathing and adenoids, 213  
   and hypertrophy of tonsils, 211  
   disinfection in fracture of mandible, 248  
   floor of, 59, 95  
   glands of, 88  
   inlet of, 95  
   manifestations of lead-poisoning in, 190  
   outlet of, 95  
   preparation for operation, 148



- Mouth, roof of, 33, 94  
 syphilitic lesions of, 176  
 treatment of, in syphilis, 181  
 vestibule of, 95  
 wounds of, 113
- Mouth-gag, 152
- Mouth-mirror, 152
- Mucous membranes, wounds of, 113  
 cleansing of, 113  
 closure of, 113  
 drainage of, 113  
 hemorrhage of, 113  
 infection of, 113  
 made by surgeon, 113  
 suture of, 113  
 tincture of iodine in, 113  
 treatment, 113
- patches, 175  
 diagnosis from leukoplakia, 177  
 from simple ulcers, 177
- Mumps, 205
- Muscle or muscles attached to  
 mandible, 61  
 azygos uvulæ, 55  
 buccinator, 58, 61, 83  
 depressor anguli oris, 60, 61  
 labii inferioris, 60, 61  
 superioris, 59  
 digastric, 49, 50, 58, 61, 83  
 external pterygoid, 57, 61  
 geniohyoglossus, 51, 61  
 geniohyoid, 59, 61  
 hyoglossus, 51  
 inferior constriction of pharynx,  
 53  
 internal pterygoid, 56, 61  
 levator anguli oris, 60  
 labii inferioris, 61  
 superioris, 59  
 alæque nasi, 59  
 menti, 61  
 lingualis, 53
- Muscle, masseter, 55, 61  
 middle constriction of pharynx,  
 53  
 mylohyoid, 58, 60, 61, 95  
 of expression, 59  
 nerve supply of, 83  
 of mastication, 55  
 accessory, 55  
 nerve supply, 79  
 of pharynx, 53  
 of soft palate, 53  
 of tongue, 51  
 omohyoid, 49, 50  
 orbicularis oris, 59, 95  
 palatoglossus, 51, 54, 92  
 platysma myoides, 58, 61, 83  
 quadratus menti, 60  
 risorius, 60  
 sternocleidomastoid, 48  
 sternomastoid, 49, 50  
 styloglossus, 53  
 stylohyoid, 83  
 stylopharyngeus, 54  
 superior constrictor of pharynx,  
 53, 61  
 temporal, 55, 61  
 tensor palati, 54  
 trapezius, 50  
 triangularis menti, 60  
 zygomaticus major, 60  
 minor, 59
- Myeloma, 163, 169
- Myelosarcoma, 163
- Myxoma, 163
- NARES, anterior, 39  
 posterior, 29, 39
- Nasal bones, 35  
 chamber, lateral wall, 36  
 fossa, 28, 34  
 meati, 36  
 nerve, 33

- Nasal process of maxilla, 36  
 septum, 36  
 spine, 36
- Nasopalatine nerve, 34
- Neck, lymphatics of, 72  
 surgical square of, 48  
 triangles of, 48
- Necrosis, 105, 194  
 and dioxid of hydrogen, 196  
 causes, 194  
 followed by fracture of mandible,  
 246  
 involucrum, 194  
 phosphorus, 195  
 sequestrum, 194  
 syphilitic, 177, 179, 195  
 treatment, 195  
 tuberculous, 195  
 x-ray and, 195
- Needle-holder, 156
- Needles, 156
- Neoplasm, 162  
 hyperplasia in, 159
- Nerve, abducens, 74  
 anterior palatine, 81  
 auditory, 74, 84  
 auriculotemporal, 67, 79  
 chorda tympani, 85  
 cranial, action of anesthetics on,  
 132  
 table of, 74  
 descendens hypoglossi, 50, 63  
 digastric, 85  
 external laryngeal, 54  
 palatine, 81  
 facial, 54, 60, 61, 74, 83  
 branches, 84  
 course of, 84  
 deep, origin, 83  
 paralysis of, 264  
 superficial, origin, 83  
 temporofacial division, 85
- Nerve, fifth, 33, 75  
 fourth, 33  
 frontal, 76  
 glossopharyngeal, 50, 54, 74, 85  
 great superficial petrosal, 86  
 hypoglossal, 50, 51, 53, 75  
 inferior dental, 78  
 branches of, 80  
 resection of, 262  
 infra-orbital, 33, 77, 78  
 resection of, 261  
 lacrimal, 77  
 lingual, 79, 263  
 mandibular, 78  
 auriculotemporal branch, 79  
 branches, 79  
 inferior dental branch, 79  
 internal pterygoid branch, 79  
 lingual branch, 79  
 recurrent branch, 79  
 maxillary, branches, 77  
 course, 77  
 infra-orbital branch, 78  
 malar branch, 78  
 meningeal branch, 77  
 orbital branch, 77  
 sphenopalatine, branches, 78  
 superior dental branch, 78  
 temporal branch, 77, 78  
 temporomalar branch, 77  
 mental, 79, 80  
 resection of, 261  
 mylohyoid, 80  
 nasal, 33, 77  
 nasopalatine, 34, 81  
 oculomotor, 74  
 olfactory, 74  
 optic, 33, 74  
 phrenic, 49  
 pneumogastric, 49, 50, 63, 74, 145  
 posterior auricular, 85  
 palatine, 34, 81

- Nerve, seventh cervicofacial division, 85  
 short ciliary, 80  
 sixth, 33  
 small superficial petrosal, 86  
 spinal accessory, 50, 75  
 styloglossal, 85  
 stylohyoid, 85  
   superficial cervical, 47, 58  
   superior dental, 77  
 third, 33  
 to stapedius muscle, 85  
 trifacial, 74, 75  
   deep origin, 75  
   divisions, 76  
   function, 75  
   Gasserian ganglion, 76  
   mandibular division, 78  
   maxillary division, 77  
   motor root, 76  
   ophthalmic division, 76  
   superficial origin, 75  
   sympathetic ganglia, 80  
   union of motor and sensory roots, 78  
 trochlear, 74  
 vidian, 81, 86
- Neuralgic and fracture of mandible, 245, 254  
 minor, 256  
 quinti major, 256  
 trifacial, 256
- Neuroma, 163
- New growth, 162
- Nitrous oxid, 132  
 action of, 143  
 advantages of, 141  
 and ether anesthesia, 136  
 and oxygen, 141, 142  
 anesthesia, 141  
   cyanosis, 142, 143  
   indications for, 141
- Nitrous oxid anesthesia, method of administration, 142  
 preparation for, 142  
 stertorous breathing in, 143  
 disadvantages, 141
- Noma, 186
- Nose, floor of, 36  
 lateral wall, 36  
 meati of, 36  
 roof of, 35  
 septum, 36
- Novocain, 130  
 and adrenalin chlorid, 131
- OCCIPITAL bone, basilar process, 29, 32  
 condyloid process, 29  
 horizontal portion, 32  
 protuberance, external, 29
- Oculomotor nerve, 74
- Odontocoele, 171
- Odontoma, 166, 170
- Olfactory foramina, 32  
 nerve, 74
- Operation, preparation of field, 148  
 of mouth, 148
- Ophthalmic artery, 33  
 ganglion, 80  
 nerve, branches, 76  
 vein, 33
- Opisthotonos, 223
- Optic foramen, 32, 33  
 nerve, 33, 74
- Oral cavity, 94
- Orbicularis oris, 59
- Orbit, 28, 32  
 bones forming, 32  
 floor, 32  
 inner wall, 33  
 openings into, 33  
 outer wall, 33  
 roof, 32

- Orbital plate of frontal bone, 29, 42  
 process of palate bone, 38  
 Os linguæ, 26  
 planum, 20  
 Osteoblasts, 114  
 Osteochondroma, 163  
 Osteoma, 163, 166, 167  
 Osteomyelitis, 106, 192  
 and pyemia, 118  
 cocain and, 193  
 dioxide of hydrogen and, 192  
 etiology, 192  
 mercury and, 193  
 phosphorus and, 193  
 septicemia and, 194  
 symptoms, 194  
 treatment, 195  
 Osteoplastic flap, 155  
 Osteosarcoma, 163, 166, 168  
 Osteotome, 159  
 spiral, 154  
 Ostium frontale, 38, 43  
 maxillare, 38, 41  
 Otic ganglion, 55, 82  
 Otitis media and facial paralysis,  
 264  
 Ovale, foramen, 29, 32  
 Oxygen in ether anesthesia, 140  
 with nitrous oxid, 141
- PAIN, cause of, in inflammation, 103  
 Palatal process of maxilla, 33  
 Palate bone, 36  
 cell in orbital process of, 38  
 horizontal plate, 33  
 hard, 33, 94  
 soft, 94  
 Palatine fossa, anterior, 21  
 Papilloma, 163, 166  
 Papular eruption in syphilis, 175  
 Paralysis, facial, 264  
 musculospiral, 138  
 Parotid fascia, 48  
 gland, 67, 88  
 and typhoid fever, 205  
 carcinoma of, 166, 205  
 inflammation, 166, 171, 205  
 mixed tumor of, 205  
 swelling of, and ankylosis of  
 temporomandibular joint,  
 205  
 and facial paralysis, 205  
 teratoma of, 205  
 tumors of, 205  
 lymph-glands, 72  
 lymph-node, swelling of, 205  
 mixed tumor of, 166, 171  
 space, 89  
 Parotitis, 205  
 Periostitis, 106  
 Perpendicular plate of ethmoid, 19  
 Petechia, 109  
 Petrous portion of temporal bone,  
 29, 32  
 Pharyngeal plexus, 53  
 Pharynx, muscles of, 53  
 posterior wall of, 94  
 Phlebitis, 118  
 Phosphorus and osteomyelitis, 193  
 necrosis, 194  
 Pillars of fauces, 92  
 Plaster, adhesive, 157  
 Platysma myoides, 47  
 Plexus, brachial, 51  
 cervical, 50  
 pharyngeal, 53  
 Pneumococcus, 107  
 Pneumogastric nerve, 74  
 Poikilocytosis, 98  
 Polypi of maxillary sinus, 203  
 Potassium iodid in syphilis, 182  
 Premaxillary bone, 34, 233  
 Prevertebral fascia, 48  
 Probe, 150

- Process of widening dental arch, 34  
 Processus gracilis of malleus, 45  
 Prognathism, inferior, 239  
 Pterygoid fossa, 29  
   process, 19, 29, 36  
 Ptyalin, 88  
 Pulse in ether anesthesia, 134  
 Pupil in ether anesthesia, 134  
 Pus, 102  
 Pustular eruption in syphilis, 175  
 Putrefaction, 115  
 Pyemia, cause of, 118  
   definition of, 116  
   prognosis of, 119  
   secondary abscesses in, 118  
   symptoms, 118  
   treatment, 119
- QUINSY, 212
- RANULA, 206  
   calculus and, 207  
   etiology, 207  
   seton in, 207  
   symptoms, 207  
   treatment, 207  
   varieties, 207
- Raphé of floor of the mouth, 95  
 Ray-fungus, 108, 197  
 Reactions of degeneration, 267  
 Reflex, corneal, 138  
 Repair of bone, 114  
   of tissue, 113  
     by first intention, 114  
     by second intention, 114  
     by third intention, 114
- Resection of inferior dental nerve,  
 262  
   of infra-orbital nerve, 261  
   of mental nerve, 261
- Resolution, 101  
 Retractors, 150
- Rhagades, 178  
 Rigor, 116  
 Rivinus, ducts of, 91  
 Rodent ulcer, 166  
 Roof of mouth, 33  
   syphilitic necrosis of, 177  
     of nose, 34
- Root cyst, 171  
 Roseola in syphilis, 175  
 Rostrum of sphenoid, 36  
 Rotundum, foramen, 32  
 Rubber dam for drainage, 112, 157  
   tubing, 156  
 Rupia, 176
- SALIVARY fistula, 207, 263  
   treatment, 208  
   glands, adenoma, 166  
   diseases of, 205
- Salivation, 181  
 Salvarsan, 181  
   powder in Vincent's angina, 188
- Sapremia, causes, 116  
   definition, 115  
   differential diagnosis, 116  
   prognosis, 116  
   symptoms, 116  
   treatment, 116
- Sarcoma, 163, 165, 166, 168  
   diagnosis, from carcinoma, 165  
   giant-celled, 165  
   small round-celled, 165  
   spindle-celled, 165
- Scalpel, 149  
 Scarpa, foramen of, 21, 34  
 Scissors, 149  
 Sella turcica, 32  
 Septicemia, bacteria in, 117  
   definition of, 115  
   prognosis, 117  
   symptoms, 117  
   treatment, 117

- Septum of nose, 36  
 Sequestrum, 194  
 Serum diagnosis of syphilis, 179  
   treatment in hemorrhage, 125,  
   128  
 Seton, 207  
 Shock, Crile's method of treatment,  
   122  
   definition, 120  
   pathology of, 120  
   symptoms, 121  
   treatment of, 121  
 Sigmoid notch, 23  
 Silk, 155  
 Silkworm gut, 155  
 Silver wire, 155  
 Sinus, cavernous, 65  
   frontal, 37, 42  
   maxillary, 37, 39  
   pathologic, 102  
   sphenoid, 38, 43  
 Skin, sterilization of, 148  
 Skull, anterior region of, 28  
   as a whole, 28  
   base of, 29  
   bones of, 18  
   general development, 17  
   lateral aspect, 28  
 Socia parotidis, 89  
 Soft palate, muscles of, 53  
 Spasm of glottis, 138  
 Sphenoid body, 32, 36  
   bone, 18  
   anterior clinoid process, 29  
   greater wing, 18, 29  
   hamular process, 33  
   lesser wing, 19, 29  
   pterygoid process, 19, 29, 36  
   fissure, 32, 33  
   greater wing, 32  
   middle clinoid process, 32  
   rostrum of, 36  
 Sphenoid sinus, 38, 43  
   outlet, 43  
 Sphenomaxillary fissure, 33  
   fossa, 41  
 Sphenopalatine ganglion, 81  
 Spinal accessory nerve, 75  
 Spinosum, foramen, 29, 32  
 Spiral osteotome, 154  
 Spirochæta pallida, 108, 174, 179  
 Splints, 112  
 Squamous suture, 29  
 Square knot, 155  
   of neck, surgical, 48  
 Staphylococci, 106  
 Stasis, 100  
 Stenson, duct of, 89, 263  
   obstruction of, 206  
   foramen of, 21, 34  
 Sterilization, iodine in, 148  
   of skin, 148  
 Stomata, 101  
 Stomatitis, 183  
   aphthous, 183  
   arsenical, 189  
   catarrhal, 183  
   gangrenous, 184, 187  
   mercurial, 188  
   symptoms, 188  
   treatment, 189  
   simple, 183  
   toxic, 188  
   ulcerative, 184  
 Stovain, 130  
 Streptococcus and cellulitis, 106  
   pyogenes, 106  
   in pyemia, 118  
 Streptothrix bovis, 197  
 Streptotrichosis, 197  
   etiology, 197  
   prognosis, 198  
   symptoms, 197  
   treatment, 198

- Styloid process, 29  
 Stylomastoid foramen, 29  
 Styptic, physiologic, 128  
 Sublingual fossa, 23  
     gland, 91  
 Subluxation of temporomandibular joint, 239  
 Submaxillary fossa, 23  
     ganglion, 82  
     gland, 50, 85  
         inflammation of, 206  
         tumors of, 206  
     lymph-glands and carcinoma, 214  
         inflammation of, 213  
 Sulphur granules, 198  
 Suppuration, 101, 102  
 Supramaxillary branch of facial nerve, 86  
 Supra-orbital foramen, 28  
 Surgical engine, 152, 262  
     fever, 115  
         aseptic, 115  
         septic, 115  
         varieties, 115  
     line of common carotid artery, 63  
 Suture, 155  
     catgut, 155  
     continuous, 155  
     coronoid, 29  
     horsehair, 155  
     intermaxillary, opening of, 34  
     interrupted, 155, 156  
     lambdoid, 29  
     method of tying, 156  
     silk, 155  
     silkworm gut, 155  
     silver wire, 155  
     squamous, 29  
 Swelling, cause of, in inflammation, 103  
 Sympathetic ganglia, 80  
 Syncope, 120  
 Syncope, treatment, 121  
 Synovial sacs, 46  
 Syphilid, tubercular, 175  
 Syphilis, 174  
     adenopathy in, 175  
     and cleft palate, 231  
     and leukoplakia, 173  
     cause of, 108  
     chancre, 174  
     diagnosis of, newer methods, 179  
     etiology, 168, 174  
     gumma, 176, 177, 179  
     hereditary, 178  
     Hutchinson's teeth, 178  
     "606" in, 181  
     in the mouth, 176  
     incubation period, 174  
     intermediate period, 176  
     macular eruption, 175  
     mercurial salivation in, 181  
     mercury in, 181  
     mucous patches in, 175, 177  
     necrosis, 177, 179  
     papular eruption in, 175  
     potassium iodid in, 182  
     primary stage, 174  
     pustular eruption in, 175  
     rhagades, 178  
     roseola, 175  
     rupia, 176  
     salvarsan in, 181  
     secondary stage, 175  
     skin eruption, 175  
     sore throat in, 175  
     spirochæta pallida, 174  
     stages of, 174  
     tertiary stage, 176  
     treatment of, 180  
         in late cases, 182  
         of mouth in, 181  
     treponema pallidum as cause, 179  
     ulcers in, 175

- Syphilis, Wassermann reaction, 179  
 Syphilitic ulcer, diagnosis from  
   tuberculous ulcer, 178
- TANNIC acid, 125
- Taste, sense of, 85
- Teeth and diseases of maxillary  
   sinus, 201  
   and fractures of mandible, 245  
   and trifacial neuralgia, 257  
   blood supply of, 68, 70  
   course of blood to and from, 70  
   deciduous, extraction of, 229  
   extraction and local anesthesia,  
     131  
   Hutchinson's, 178  
   impacted, 224  
   lower, nerve supply, 80  
   upper, nerve supply, 78  
   veins from, 70
- Temporal bone, glenoid fossa, 42  
   petrous portion, 29, 32  
   squamous portion, 32  
   tympanic plate, 45  
   muscle, 55
- Temporomandibular articulation,  
   42  
   joint, 42  
     ankylosis of, 217  
     dislocation of, 215  
       interarticular fibrocartilage,  
       46  
     ligaments of, 45  
     luxation of, 215  
     subluxation of, 239  
     synovial sacs, 46
- Teratoma, 163
- Tetanus, 112  
   and ankylosis, 223  
   bacillus, 107
- Thermocautery, 171
- Thrush, 187
- Thyrohyoid membrane, 27
- Thyroid cartilage, 63
- Tic douloureux, 256  
   nerves involved in, 258
- Tissue, granulation, 114  
   repair of, 113
- Tongue, 51  
   carcinoma of, 166  
   depressor, 152  
   dorsum of, 95  
   extrinsic muscles, 51  
   gumma of, 177  
   muscles of, 51  
   nerve supply, 79  
   relation to roof of mouth, 93
- Tonsillar crypts, secretion of, 213  
   space, 92
- Tonsillitis, follicular, 212  
   suppurative, 212
- Tonsils, 92, 95  
   blood supply, 94  
   diphtheric infection of, 212  
   diseases of, 211  
   effects of hypertrophy of, 211  
   faucial, 94  
   functions, 94  
   hypertrophy of, 211  
     treatment of, 211  
   lingual, 94  
   pharyngeal, 94  
   relations of, 92  
   structure, 94
- Tooth extraction and ether anes-  
   thesia, 135  
     hemorrhage following, 125
- Tracheotomy, 144
- Transfusion, 126
- Transillumination, 201
- Trephining, 152
- Treponema pallidum, 108, 174, 179
- Triangle, inferior carotid, 49  
   occipital, 50



- Triangle of neck, 48  
 anterior, 48  
 posterior, 49  
 subclavian, 50  
 submaxillary, 50, 90  
 superior carotid, 49
- Triangular cartilage, 36
- Trifacial nerve, 74, 75  
 ophthalmic division, 33  
 neuralgia, 256  
 alcohol injection, 263  
 anesthesia and, 257  
 central lesions and, 256  
 classification, 256  
 diagnosis, 259  
 etiology, 256  
 general diseases and, 257  
 palliative treatment, 260  
 peripheral causes of, 257  
 prognosis, 259  
 removal of Gasserian ganglion,  
 263  
 resection for, 260  
 symptoms, 257  
 teeth and, 257  
 treatment of, 259  
 x-ray in, 259
- Trismus of tetanus, 223
- Trochlear nerve, 74
- Tube, Eustachian, 54, 55
- Tubercle bacillus, 107
- Tubercular syphilis, 175
- Tuberculous ulcer, diagnosis from  
 syphilitic ulcer, 178
- Tumors, 162  
 adenofibroma, 163  
 adenoma, 163, 166  
 angiofibroma, 163, 166, 169  
 associated with face and jaws,  
 166  
 benign, 164  
 carcinoma, 163, 164, 166
- Tumors, clinical classification, 164  
 chondroma, 163, 166  
 classification of, 163, 166  
 Cohnheim's theory, 162  
 connective-tissue type, 163, 166  
 cystic, 164  
 epithelial type, 163, 166  
 epithelioma, 163, 166  
 epulis, 168  
 etiology of, 162  
 fibroma, 163, 166  
 fibromyoma, 163  
 giant-cell myeloma, 169  
 intermediate type, 164  
 lipoma, 163, 166  
 lymphangioma, 163  
 lymphoma, 163  
 malignant, 164  
 metastasis of, 164  
 microbic theory, 162  
 mixed, of parotid gland, 205  
 type, 163, 166  
 myeloma, 163  
 myelosarcoma, 163, 166  
 myoma, 163  
 neuroma, 163  
 odontocele, 171  
 odontoma, 166, 170  
 of maxillary sinus, 203  
 of parotid, mixed, 166, 171  
 osteochondroma, 163  
 osteoma, 163, 166, 167  
 osteosarcoma, 163, 166, 168  
 papilloma, 163, 166  
 root cyst, 171  
 sarcoma, 163, 166, 168  
 teratoma, 163
- Turbinated bone, inferior, 36  
 middle, 37  
 superior, 38  
 processes of ethmoid, 36
- Tympanic plate, 29, 45

- Typhoid bacillus, 107  
fever, parotid gland in, 205
- ULCER, inflammatory, 104  
of cornea, 263  
rodent, 166  
syphilitic, 175  
traumatic, 105  
trophic, 105
- Ulceration, 104
- Unciform process, 38
- Uvula, 54, 55, 95
- VEIN, anterior external jugular, 47  
external jugular, 69  
facial, 50  
inferior thyroid, 49  
internal jugular, 49, 50, 63, 69,  
70, 145  
lingual, 50  
middle thyroid, 49  
of head, 69  
ophthalmic, 33  
posterior external jugular, 47  
ranine, 50  
subclavian, 51  
superior thyroid, 50
- Vertical plate of ethmoid, 19, 36
- Vessels, anterior ethmoid, 33  
palatine, 34  
infra-orbital, 33  
posterior ethmoid, 33  
palatine, 34
- Vestibule of mouth, 95
- Vidian nerve, 81
- Vincent's angina, 188
- Vomer, 36  
alæ of, 36
- Vomiting during anesthesia, 139  
treatment of, 117
- WASSERMANN reaction, 179
- Wharton, duct of, 90
- Whitehead's varnish, 112
- Willis, circle of, 69, 71
- Wound and tetanus, 112  
cleansing of, 111  
contused, 110  
definition, 110  
drainage of, 111  
dressing of, 111  
gunshot, 110  
incised, 110  
infected, 110  
lacerated, 110  
of face, 155  
of mouth, 113  
of mucous membranes, 113  
cleansing of, 113  
closure of, 113  
drainage of, 113  
hemorrhage of, 113  
infection of, 113  
made by surgeon, 113  
suture of, 113  
tincture of iodine in, 113  
treatment, 113  
penetrating, 110  
punctured, 110  
suture of, 111  
symptoms, 110  
treatment of, 111
- X-RAY and ankylosis, 221  
and empyema of maxillary sinus,  
201  
and impacted teeth, 228  
and necrosis, 195  
in fracture of mandible, 248  
in trifacial neuralgia, 259
- ZYGOMA, 28, 29





---

---

SAUNDERS' BOOKS

on

**Nervous and Mental  
Diseases, Children,  
Hygiene, and Medical  
Jurisprudence**

---

**W. B. SAUNDERS COMPANY**

West Washington Square

Philadelphia

9, Henrietta Street

Covent Garden, London

---

*Our Handsome Complete Catalogue will be Sent on Request*

---

**Dercum's Mental Diseases**

**Mental Diseases.** A Clinical Manual. By FRANCIS X. DERCUM, M. D., Ph. D., Professor of Nervous and Mental Diseases at Jefferson Medical College, Philadelphia. Octavo of 479 pages. Cloth, \$3.50 net. Second Edition published November, 1917

**TWO PRINTINGS IN FIVE MONTHS**

Dr. Dercum's work is along entirely new lines. It is *strictly clinical*. It is a book on mental diseases *really useful* to the *family physician*—a book that tells you how to diagnose, how to treat—either at home or in an institution—all classes of mental diseases; tells you in a clear, simple way.

---

---

**Our books are revised frequently, so that the editions you find here may not be the latest. Write us about any books in which you are interested**

# Church and Peterson's Nervous and Mental Diseases

**Nervous and Mental Diseases.** By ARCHIBALD CHURCH, M.D., Professor of Nervous and Mental Diseases and Head of Neurologic Department, Northwestern University Medical School, Chicago; and FREDERICK PETERSON, M. D., formerly Professor of Psychiatry in Columbia University, New York. Octavo of 940 pages, with 350 illustrations. Cloth, \$5.00 net.

Published October, 1914

## EIGHTH EDITION

For this new eighth edition the entire work has been most thoroughly revised. To show with what thoroughness the authors have revised their work, we point out that in the nervous section alone over one hundred and fifty interpolations have been made, and, in addition, well over three hundred minor corrections. The section on Mental Diseases has been wholly re-arranged to conform to the latest classification, some obsolete matter struck out, and much new matter added.

### American Journal of the Medical Sciences

"This edition has been revised, new illustrations added, and some new matter, and really is two books. . . . The descriptions of disease are clear, directions as to treatment definite, and disputed matters and theories are omitted. Altogether it is a most useful text-book."

# Herrick's Neurology

**Introduction to Neurology.** By C. JUDSON HERRICK, PH. D., Professor of Neurology in the University of Chicago. 12mo of 360 pages, illustrated. Cloth, \$1.75 net.

## A KEY TO NEUROLOGY

Professor Herrick's new work will aid the student to organize his knowledge and appreciate the significance of the nervous system as a mechanism right at the beginning of his study. It is sufficiently elementary to be used by students of elementary psychology in colleges and normal schools, by students of general zoölogy and comparative anatomy in college classes, and by medical students as a guide and key to the interpretation of the larger works on neurology.

Published September, 1915

# Kaplan's Serology of Nervous and Mental Diseases

**Serology of Nervous and Mental Diseases.** By D. M. KAPLAN, M. D., Director of Clinical and Research Laboratories, Neurological Institute, New York City. Octavo of 346 pages, illustrated. Published June, 1914. Cloth, \$3.50 net.

## ILLUSTRATED

This is an entirely new work on this subject. Here you get the newest technic—the application of serology in practice. You get the indications, contra-indications, preparation of patients, technic, after-phenomena, after-care, and disposal of the fluids obtained by lumbar puncture. You get the physical, chemical and cytologic properties of normal and pathologic fluids discussed in *detail*, including the interpretation of findings and bacteriology. You get a full discussion of the serology of all nervous and mental diseases of *non-luetic* etiology—meningeal affections (infectious and non-infectious), brain diseases, cord diseases, nerve affections (including disorders of *internal secretion*), the psychoses, and the intoxications. The serology of every type of *luetic* nervous and mental disease is next presented to you, giving the *Wassermann reaction in detail*, the use of *salvarsan* and *neo-salvarsan*.

---

# Elsberg's Surgery of Spinal Cord

**Surgery of the Spinal Cord.** By CHARLES A. ELSBERG, M. D., Professor of Clinical Surgery, New York University and Bellevue Hospital Medical School. Octavo of 330 pages, with 153 illustrations. Cloth, \$5.00 net.

## ORIGINAL ILLUSTRATIONS

(Published July, 1916)

There is no other book published like this by Dr. Elsberg. It gives you in clear definite language the diagnosis and treatment of all surgical diseases of the spinal cord and its membranes, illustrating each operation with original pictures. Because it goes so thoroughly into symptomatology, diagnosis, and indications for operation this work appears as strongly to the general practitioner and neurologist as to the surgeon. The first part of the work is devoted to anatomy and physiology of the spinal cord, and to the symptomatology of surgical spinal diseases. The second part takes up operations upon the spine, the cord, and nerve-roots. The third part is given over to surgical diseases of the cord and its membranes—their diagnosis and treatment. Included also are chapters on hematomyelia and spinal gliosis, because in these diseases much harm is done to the fiber tracts by compression. There is also a chapter on x-rays in spinal diseases.

## Abt's Preparation of Infants' Foods

A PRACTICAL GUIDE FOR THE PREPARATION OF INFANTS' AND CHILDREN'S FOODS. By ISAAC A. ABT, M. D., Professor of Diseases of Children, Northwestern University Medical School. 12mo of 143 pages. Cloth, \$1.25 net. Published July, 1917

In this book Dr. Abt gives to young mothers, nurses, and those who care for infants and children minute directions on the preparation of every kind of food that has value in infant feeding. Included also is such practical material as diet-lists for constipation, an outline of a plan for feeding babies, care of nipples and bottles, etc. You are given weights and measures; the mineral constituents and caloric values of foods; and a wealth of recipes for foods of all kinds and purposes.

## Hill and Gerstley's Infant Feeding

CLINICAL LECTURES ON INFANT FEEDING. By LEWIS WEBB HILL, M. D., Alumni Assistant in Pediatrics, Harvard Medical School; and JESSE R. GERSTLEY, M. D., Instructor in Pediatrics, Northwestern University Medical School. 12mo of 377 pages, illustrated. Cloth, \$2.75 net. Published October, 1917

In these clinics you are given the full details of the Boston method of infant feeding as developed by Dr. Rotch, and of the Chicago method. You are given the theory, use in both normal and abnormal cases, exact quantities and percentages, and concrete clinical examples. The book is equivalent to a postgraduate course in infant feeding. It brings these two systems right to your door.

## Herrick and Crosby's Laboratory Neurology

LABORATORY OUTLINES OF NEUROLOGY. By C. JUDSON HERRICK, PH. D., and ELIZABETH CROSBY, PH. D., of the Anatomical Laboratory of the University of Chicago. 12mo of 120 pages, illustrated. Published January, 1918

## Hecker, Trumpp, and Abt on Children

ATLAS AND EPITOME OF DISEASES OF CHILDREN. By Dr. R. HECKER and Dr. J. TRUMPP, of Munich. Edited, with additions, by ISAAC A. ABT, M. D. With 48 colored plates, 144 text-cuts, and 453 pages of text. Cloth, \$5.00 net. Published April, 1907



# Ruhrah's Diseases of Children

**A Manual of Diseases of Children.** By JOHN RUHRAH, M. D., Professor of Diseases of Children, College of Physicians and Surgeons, Baltimore. 12mo of 552 pages, fully illustrated. Cloth, \$2.75 net. Published September, 1914

## FOURTH EDITION

The fourth edition makes this work more than ever the ideal desk book for the general practitioner. Although there have been added over one hundred pages of new matter and some sixty new illustrations, the book remains of a handy size and is still flexible.

### American Journal of the Medical Sciences

"Treatment has been satisfactorily covered, being quite in accord with the best teaching, yet withal broadly general and free from stock prescriptions."

---

# Griffith's Care of the Baby

**The Care of the Baby.** By J. P. CRÖZER GRIFFITH, M. D., Professor of Pediatrics at the University of Pennsylvania. 12mo of 455 pages, illustrated. Cloth, \$1.50 net. Published June, 1915

## SIXTH EDITION

### New York Medical Journal

"We are confident if this little work could find its way into the hands of every trained nurse and of every mother, infant mortality would be lessened by at least fifty per cent."

# Bandler's The Expectant Mother

This is decidedly a book for the woman preparing for childbirth. It has chapters on menstruation, nourishment of mother during pregnancy, nausea, care of breasts, examination of urine, preparations for labor, care of mother and child after delivery, twilight sleep, and dozens of other matters of great interest to the expectant mother. Published August, 1916

12mo of 213 pages, illustrated. By S. WYLLIS BANDLER, M. D., Professor of Diseases of Women, New York Post-Graduate Medical School and Hospital. Cloth, \$1.25 net.

## Kerley's New Pediatrics

**Practice of Pediatrics.** By CHARLES GILMORE KERLEY, M. D., Professor of Diseases of Children, New York Polyclinic Medical School and Hospital. Octavo of 913 pages, illustrated.

Published January, 1918

### SECOND EDITION

This is an entirely new work—not a revision of Dr. Kerley's earlier work. It is not a cut-and-dried treatise—but the *practice* of pediatrics, giving, of course, fullest attention to *diagnosis* and *treatment*. The chapters on the newborn and its diseases, the feeding and the growth of baby, the care of the mother's breasts, artificial feeding, milk modification and sterilization, diet for older children—form a monograph of 125 pages. Then are discussed in detail every disease of childhood, *telling just what measures should be instituted*, what drugs given, *60 valuable prescriptions* being included. The chapter on *vaccine therapy* is right down to the minute, including every new method of proved value—with the exact technic. There is an excellent chapter on *Gymnastic Therapeutics*, giving explicit directions for the correction of certain abnormalities in which gymnastics have proved efficacious. Another feature consists of *the 165 illustrative cases—case teaching* of the most practical sort.

## Grulee's Infant Feeding

**Infant Feeding.** By CLIFFORD G. GRULEE, M. D., Assistant Professor of Pediatrics at Rush Medical College. Octavo of 326 pages, illustrated, including 8 in colors. Cloth, \$3.25 net.

Published September, 1917

### THIRD EDITION

Dr. Grulee tells you *how* to feed the infant. He tells you—and *shows* you by clear illustrations—the *technic* of giving the child the breast. Then artificial feeding is thoughtfully presented, including a number of simple formulas. The colored illustrations showing the actual shapes and appearances of stools are extremely valuable.

## Kerr's Diagnostics of Diseases of Children

DIAGNOSTICS OF THE DISEASES OF CHILDREN. By LEGRAND KERR, M. D., Professor of Diseases of Children, Brooklyn Postgraduate Medical School, Brooklyn. Octavo of 542 pages, fully illustrated. Cloth, \$5.00 net.

Published February, 1907

## Hoxie and Laptad's Medicine for Nurses **Second Edition**

MEDICINE FOR NURSES AND HOUSEMOHHERS. By GEORGE HOWARD HOXIE, M. D., Physician to the German Hospital, Kansas City; and PEARL L. LAPTAD, formerly Principal of Training-School, University of Kansas. 12mo of 351 pages, illustrated. Cloth, \$1.50 net.

Published April, 1913

The purpose of this book is to provide enough information about the nature, cause, and cure of disease to enable you to carry out the doctor's orders intelligently, to know when home treatment is sufficient, and how and what to apply, to recognize when professional advice should be sought, and how to render first aid in emergencies. It is just the manual you need in caring for illness and preventing its spread in your home.

## Aikens' Home Nurse's Hand-Book **New (2d) Edition**

HOME NURSE'S HAND-BOOK. By CHARLOTTE A. AIKENS. 12mo of 303 pages, illustrated. Cloth, \$1.50 net. Published March, 1917

You will find the entire realm of *home* nursing very completely presented here. The author *knows*, from long active experience, just how to meet emergencies, how to improvise, how to *manage*. She shows you what to have ready in times of sickness, how to make the bed, how to care for, feed, and bathe the patient, how to give home treatments, and what they are; how to disinfect, how to make and apply bandages, how to render first aid in emergencies.

"Several books have been written upon home nursing, but none has been so clear, so simply put, so easy to learn, so easy to teach, so free from matter not to the point, so all-comprehensive."—*Trained Nurse and Hospital Review*.

## Galbraith's Personal Hygiene and Physical Training **for Women** **Second Edition, January, 1917**

PERSONAL HYGIENE AND PHYSICAL TRAINING FOR WOMEN. By ANNA M. GALBRAITH, M.D., Fellow New York Academy of Medicine. 12mo of 393 pages, with original illustrations. Cloth, \$2.25 net.

This is a book for every woman. It tells you how to train your physical powers to their fullest development. For home study and as a text-book this manual has no equal.

"Just the information that every woman should possess. It gives more valuable and practical help than we have ever seen in any other one volume."—*Health Culture*.

## Galbraith's Four Epochs of Woman's Life **Third Edition**

THE FOUR EPOCHS OF WOMAN'S LIFE. By ANNA M. GALBRAITH, M. D. With an Introductory Note by JOHN H. MUSSEY, M. D. 12mo of 296 pages. Cloth, \$1.50 net. Published March, 1917

Women have at last awakened to a sense of the penalties they have paid for their ignorance of those laws of nature which govern their physical being. Maidenhood, marriage, maternity, and menopause—these are the periods of a woman's life fraught with the greatest dangers. Well-ordered education in these subjects lessens suffering and is essential to prevention of disease. Dr. Galbraith discusses the subject in a modest and conclusive manner. *Sex Instruction* is handled most admirably. There is a valuable chapter on *eugenics* and a glossary of medical terms.

"These truths should be known by every woman, and I gladly commend the essay to their thoughtful consideration."—*Dr. John H. Mussey, University of Pennsylvania*.

## Winslow's Prevention of Disease

PREVENTION OF DISEASE. By KENELM WINSLOW, M. D., formerly Assistant Professor of Comparative Therapeutics, Harvard University. 12mo of 348 pages, illustrated. Cloth, \$1.75 net. November, 1916

This book is a practical guide for the layman, giving him briefly the means to avoid the various diseases described. The chapters on diet, exercise, tea, coffee, and alcohol are of special interest, as is that on the prevention of cancer. There are chapters on the prevention of malaria, colds, constipation, obesity, nervous disorders, tuberculosis, etc. The work is a record of 25 years' active practice.

## Brady's Personal Health

PERSONAL HEALTH, A Doctor Book for Discriminating People. By WILLIAM BRADY, M. D., Elmira, N. Y. 12mo of 405 pages. Cloth, \$1.50 net. Published September, 1916

Knowledge is the only protection against sickness: This book will make you more efficient in preventing illness and in caring for those who are ill when you cannot get a doctor, and in co-operating with him when you can get one. It is written in a clear, concise, and simple style. It is wholly understandable. All the mystery in medicine is swept aside and you are told what is most worth while in modern medicine—your personal health and how to maintain it. It is written by a doctor unusually well qualified to present medicine to the lay reader. It is an instructive book, indeed.

## Keefe's Military Hygiene

MILITARY HYGIENE AND SANITATION. By LIEUT.-COL. FRANK R. KEEFER, Professor of Military Hygiene, United States Military Academy, West Point. 12mo of 305 pages, illustrated. Cloth, \$1.50 net.

This is a concise though complete text-book on this subject, containing chapters on the care of troops, recruits and recruiting, personal hygiene, physical training, preventable diseases, clothing, equipment, water supply, foods and their preparation, hygiene and sanitation of posts and barracks, the troopship, hygiene and sanitation of marches, camps and battlefields, disposal of wastes, tropical and arctic service, venereal diseases, alcohol and other narcotics, and a glossary. July, 1914

## Bergey's Hygiene

Fifth Edition

THE PRINCIPLES OF HYGIENE. By D. H. BERGEY, A. M., M. D., Assistant Professor of Bacteriology, University of Pennsylvania. Octavo of 529 pages, illustrated. Cloth, \$3.00 net. Published September, 1914

"It will be found of value to the practitioner of medicine and the practical sanitarian; and students of architecture, who need to consider problems of heating, lighting, ventilation, water supply, and sewage disposal, may consult it with profit."

*Buffalo Medical Journal.*

## Owen's Treatment of Emergencies

THE TREATMENT OF EMERGENCIES. By HUBLEY R. OWEN, M. D., Surgeon to the Philadelphia General Hospital. 12mo of 350 pages, with 249 illustrations. Cloth, \$2.00 net. Published June, 1917

Dr. Owen's book is a complete treatment of emergencies. It gives you not only the *actual technic* of the procedures, but, what is equally important, the underlying principles of the treatments, and the reason *why* a particular method is advised. This makes for correctness. You get chapters on fractures of all kinds, going fully into symptoms, treatments, and complications. You get treatments of contusions, of wounds, both lacerated and incised. Particularly strong is the chapter on *gun-shot wounds*, which gives the new treatments that the great European War has developed. You get the principles of hemorrhage—arterial, venous, and capillary—together with its constitutional and local treatments. You get chapters on sprains, strains, dislocations, burns and scalds, treatment of sunburn, chillblain, asphyxiation, convulsions, hysteria, apoplexy, exhaustion, opium poisoning, uremia, and electric shock. You get sections on the making and applying of bandages, varieties, and precautions; and a complete discussion of the various kinds of artificial respiration, including mechanical devices. You are told what equipment is necessary for emergency work, and what household remedies should be always on hand.

## Morrow's Immediate Care of Injured

Third Edition

IMMEDIATE CARE OF THE INJURED. By ALBERT S. MORROW, M. D., Major, Medical Reserve Corps, U. S. Army. Octavo of 356 pages, with 242 illustrations. Cloth, \$2.75 net. Published November, 1917

## Pyle's Personal Hygiene

The New (7th) Edition

A MANUAL OF PERSONAL HYGIENE: Proper Living upon a Physiologic Basis. By Eminent Specialists. Edited by WALTER L. PYLE, A. M., M. D., Assistant Surgeon to Wills Eye Hospital, Philadelphia. 555 pages, illustrated. Cloth, \$1.75 net. Published August, 1917

To this new edition there have been added, and fully illustrated, chapters on Domestic Hygiene and Home Gymnastics, besides an Appendix containing methods of Hydrotherapy, Mechanotherapy, and First Aid Measures. There is also a Glossary of the mechanical terms used.

"The work has been excellently done, there is no undue repetition, and the writers have succeeded unusually well in presenting facts of practical significance based on sound knowledge."—*Boston Medical and Surgical Journal*.

## American Pocket Dictionary

New (10th) Edition

AMERICAN POCKET MEDICAL DICTIONARY. Edited by W. A. NEWMAN DORLAND, M. D. Containing the pronunciation and definition of the principal words used in medicine and kindred sciences, with 64 extensive tables. With 707 pages. Flexible leather, with gold edges. \$1.25 net; with patent thumb index, \$1.50 net. September, 1917

## Brill's Psychanalysis

Second Edition

PSYCHANALYSIS: Its Theories and Practical Application. By A. A. BRILL, Ph. B., M. D., Clinical Assistant in Neurology at Columbia University Medical School. Octavo of 392 pages. Cloth, \$1.25 net. Published May, 1914

## Shaw on Nervous Diseases and Insanity

Fifth Edition, published October, 1913

ESSENTIALS OF NERVOUS DISEASES AND INSANITY: Their Symptoms and Treatment. A Manual for Students and Practitioners. By the late JOHN C. SHAW, M. D., Clinical Professor of Diseases of the Mind and Nervous System, Long Island College Hospital, New York. 12mo of 204 pages, illustrated. Cloth, \$1.25 net. *Saunders' Compendis.*

## Golebiewski and Bailey's Accident Diseases

ATLAS AND EPITOME OF DISEASES CAUSED BY ACCIDENTS. By DR. ED. GOLEBIEWSKI, of Berlin. Edited, with additions, by PEARCE BAILEY, M. D., Consulting Neurologist to St. Luke's Hospital, New York. With 71 colored illustrations on 40 plates, 143 text-illustrations, and 549 pages. Cloth, \$4.00 net. *Saunders' Hand-Atlases.* Published 1901

## Bass and Johns' Alveolodental Pyorrhea

ALVEOLODENTAL PYORRHEA. By CHARLES C. BASS, M. D., Professor of Experimental Medicine, and FOSTER M. JOHNS, M. D., Instructor in the Laboratories of Clinical Medicine, Tulane Medical College. Octavo, 168 pages, illustrated. Cloth, \$2.50 net. Published June, 1915

## Spear's Nervous Diseases

A MANUAL OF NERVOUS DISEASES. By IRVING SPEAR, M. D., Professor of Neurology at the University of Maryland, Baltimore. 12mo of 660 pages, with 172 illustrations. Cloth, \$2.75 net. November, 1916

## Jakob and Fisher's Nervous System

**Saunders'  
Hand-Atlases**

ATLAS AND EPITOME OF THE NERVOUS SYSTEM AND ITS DISEASES. By PROFESSOR DR. CHR. JAKOB, of Erlangen. Edited, with additions, by EDWARD D. FISHER, M. D., University and Bellevue Hospital Medical College, New York. With 83 plates and copious text. Cloth, \$3.50 net. Published 1901

## Hunt's Diagnostic Symptoms of Nervous Diseases

DIAGNOSTIC SYMPTOMS OF NERVOUS DISEASES. By EDWARD L. HUNT, M. D., formerly Instructor in Neurology and Assistant Chief of Clinic, College of Physicians and Surgeons, New York. 12mo of 292 pages, illustrated. Cloth, \$2.00 net. Second Edition, June, 1917









COLUMBIA UNIVERSITY

This book is due on the date indicated below or at the expiration as provided in the original arrangement

R. K 522

1917 Inv 9 Copy 1

DATE BORROWED

July

W. H. H. Fraxson, Oral Surgery

5/23/29

3/31/30 8/11/30

OCT 8 '38

Joe Myers

APR 11 '40 H. H. Shapiro (Anat)

DEC 16 1942 L. E. Sina

MAR 6 1943 L. E. Sina

APR 2 1943 L. E. Sina

JUL 19 1943 Beck & Heller

JUL 3 1918

COLUMBIA UNIVERSITY LIBRARIES (hsl.stx)

**RK 522 Iv9 1917 C.1**

Applied anatomy and oral surgery for den



2002398737

