





THE LIBRARY
OF
THE UNIVERSITY
OF CALIFORNIA
LOS ANGELES

GIFT OF

SAN FRANCISCO
COUNTY MEDICAL SOCIETY

ATLAS
OF
APPLIED (TOPOGRAPHICAL)
HUMAN ANATOMY

FOR
STUDENTS AND PRACTITIONERS

BY
DR. KARL VON BARDELEBEN AND PROF. DR. HEINR. HAECKEL

IN COLLABORATION WITH
DR. FRITZ FROHSE
AND
PROFESSOR DR. THEODORE ZIEHEN

Only Authorised English Adaptation from the Third German Edition

CONTAINING 204 WOODCUTS IN SEVERAL COLOURS AND DESCRIPTIVE TEXT

BY
J. HOWELL EVANS M.A., M.B.

M. CH., OXON., F.R.C.S., ENGLAND

LATE SENIOR DEMONSTRATOR OF HUMAN ANATOMY AT ST. GEORGE'S HOSPITAL LONDON
DEMONSTRATOR OF OPERATIVE SURGERY ST. GEORGE'S HOSPITAL, LONDON
ASSISTANT SURGEON TO THE CANCER HOSPITAL, LONDON



LONDON
REBMAN LIMITED
129 SHAFTESBURY AVENUE

NEW YORK
REBMAN COMPANY
1123 BROADWAY

1906

ALL RIGHTS RESERVED

Entered at Stationer's Hall

1906.

Biomedical
Library

Q5
17
E235a
1906

Preface.

Nearly every Student of Anatomy and every Practitioner feels the need of some book which shall, for the former, serve as a supplement to dissection and assist in the study of prepared anatomical specimens and which, for the latter who cannot spare the time for the study of specimens or whose work will not countenance any contact with the cadaver, shall present the regional important structures.

Such a book must present Anatomical data by numerous and good illustrations, the important details depicted must be presented in a systematic, clear, and practical manner. For such merits and to meet these requirements this English Version has been prepared; it is hoped, therefore, that this book will serve as a means of revision among Students, as a valuable reference both of applied Anatomy to the Practitioner, and as a means of quickening the weakening memories of the Surgeon.

The selection of the Plates and their extent has been determined by their relative clinical importance; special attention has been directed to those regions which have, of recent years, become of increased interest to the Physician and Surgeon; so that those portions of Anatomy which are likely to be of actual service to the Student in his subsequent study, and to the Practitioner in his clinical work, form the basis of each plate.

Lithographic Plates for the finer and Wood-cuts for the coarser detail, when coloured, are undoubtedly the best means of illustrating Anatomy and Histology; because by these methods the exact relations and distinctness of different structures in the various planes are most admirably shewn.

This book cannot replace, and is not intended to replace, the Textbook of Anatomy, but is of great use with the more comprehensive Anatomical Works and Atlases.

Here

C24061

There is as yet, no Universal Anatomical Nomenclature — in the original German work the B. N. A. nomenclature is employed, but among English Anatomists the nomenclature is very variable, at one time purely classical at another purely English, frequently a mixture. I have endeavoured to give the terms most frequently employed in England, with a further inclination whenever possible, to an English rather than a Classical term.

In connection with the question of nomenclature, the reader is advised to peruse TOLDT'S Atlas, wherein all synonyms are well explained.

London, W.

J. Howell Evans.

Contents.

I. Head.

- Fig. 1. Median Section through the Head.
" 2. Frontal Section through the Head passing through the Orbits.
" 3. Outer Surface of the Cerebrum — Centres of Localization.
" 4. Outer Surface of the Cerebrum — Convolution and Sulci.
" 5. Inner Surface of the Cerebrum.
" 6. Dorsal Aspect of the 4th Ventricle.
" 7. Course of Fibres in the Internal Capsule.
" 8. Course of Fibres from Cortex to Spinal Cord.
" 9. Course of Fibres in the Crura Cerebri — Frontal Section.
" 10. Convolution and Bony Sutures (in the newborn).
" 11. Convolution and Bony Sutures (in the child).
" 12. Convolution and Bony Sutures (in the adult).
" 13. Base of Brain with Arteries and Cranial Nerves.
" 14. Base of Skull; from above.
" 15. Base of Skull, with Arteries, Nerves and Venous Sinuses.
" 16. Base of Skull, with the soft parts, after partial removal of the bones.
" 17. Projection of the Lateral Ventricle, Middle Ear and Lateral Sinus on to the outer surface of the Skull.
" 18. Projection of the Middle Meningeal Artery on to the outer surface of the Skull.
" 19. Cranio-Cerebral Topography.
" 20. Exposure of the Cerebellum.
" 21. From a horizontal section — Auditory Apparatus and its relations.
" 22. Part of Fig. 21 — Tympanic Cavity and its relations.
" 23. Vertical section through the Left Temporal Bone, passing through the Axis of the Petrous portion.
" 24. Horizontal Section through the Left Temporal Bone.
" 25. Mastoid Process of child, opened.
" 26. Mastoid Process of adult, opened.
" 27 and 28. Tympanic Cavity and its relations; opened from behind.
" 29. Superficial Vessels and Nerves of the Head.
" 30. Side View of the Face — Superficial layer.
" 31. Side View of the Face — Deep layer.
" 32. Exposure of the GASSERIAN Ganglion.
" 33 to 38. Areas of Distribution of the Sensory Cranial Nerves.
" 39. Nasal Cavity with openings of Accessory Cavities.
" 40. Antrum of HIGHMORE and Roots of Teeth.
" 41. Frontal Sinus, Nasal Duct.
" 42. Orbit and its relations — Horizontal Section.
" 43. Orbit and Nasal Cavities in a child — Frontal Section.
" 44. Orbit and its relations in a child — Vertical Section through the Axis of the Optic Nerves.
" 45. Frontal Section through the posterior part of the Nasal Cavity.
" 46. Frontal Section through the Sphenoidal Sinus and Nasal Cavity.
" 47. Frontal Section through the Anterior part of the Cavernous Sinus.
" 48. Frontal Section through the Posterior part of the Cavernous Sinus.

- Fig. 49. Inner region of the Eye — Lachrymal Apparatus — Superficial layer.
„ 50. Lachrymal Passages — Deep layer.
„ 51. Floor of the Mouth.
„ 52. Occipital Region.
„ 53. Horizontal Section through the Head at the level of the Axis.

II. Spinal Cord.

- Fig. 54. Position of the Cord in the Vertebral Canal.
„ 55. Lower End of the Spinal Canal in the Adult.
„ 56. Diagrammatic Cross-Section through the Spinal Cord.

III. Neck.

- Fig. 57. Regions of the Neck — from in front.
„ 58. Regions of the Neck — from the side.
„ 59. Transverse section through the Neck passing through the Upper part of the 5th Cervical Vertebra.
„ 60. Neck, from in front, Superficial layer, in the adult.
„ 61. Neck, from in front, Deep layer, in the adult.
„ 62. Neck, from in front, Deep layer, in the child.
„ 63. Superior Triangle of the Neck, with Lymphatics.
„ 64. Ligature of the Lingual Artery.
„ 65. Larynx — opened from in front.
„ 66. Side View of the Anterior Region of the Neck. Oesophagus.
„ 67. Side of the Neck, lower triangle.
„ 68. Side of the Neck — Superior Cervical Ganglion of the Sympathetic.
„ 69. Larynx, seen from behind.
„ 70. Apex of the Pleura.
„ 71. Course of the Large Vessels and Nerves to the Upper Limbs.

IV. Arm.

- Fig. 72. Axilla.
„ 73. Frontal Section through the Right Shoulder of a Boy.
„ 74. Horizontal Section through the Left Shoulder of a Boy.
„ 75. Anterior Region of the Shoulder-Joint.
„ 76. MOHRENHEIM'S FOSSA — (Infra-Clavicular Fossa).
„ 77. Posterior Region of the Shoulder-Joint.
„ 78. Right Arm — seen from the inner side.
„ 79. Left Arm — seen from the outer side and behind.
„ 80. Transverse Section through the middle of the right arm.
„ 81. Transverse Section through the lower third of the right arm.
„ 82. Left Antecubital Space, superficial layer.
„ 83. Right Antecubital Space, deep layer.
„ 84. Region of Right Elbow.
„ 85. Transverse Section through the right Elbow-Joint.
„ 86. Longitudinal Section through the left Elbow-Joint.
„ 87. Frontal Section through the right Elbow-Joint (aet. 19 yrs.).
„ 88. Sagittal Section through the left Elbow-Joint (aet. 8 yrs.).
„ 89. Right Forearm, deep layer, from in front.
„ 90. Transverse Section through upper third of right forearm.
„ 91. Transverse Section through lower third of right forearm.
„ 92. Region of Right Wrist, outer side. (Snuff-Box.)
„ 93. Nerves and Veins of the Dorsum of the Right Hand.
„ 94. Tendon-Sheaths of the Dorsum of the Right Hand.
„ 95. Palm of Left Hand; Superficial layer.
„ 96. Palm of Left Hand; Deep layer.
„ 97. Tendon-Sheaths, and Large Arteries of the Palm of the Right hand.
„ 98 to 101. Tendon-Sheaths of Palm of Hand. Left side.

- Fig. 102. Horizontal Section through Dorsum of Hand.
" 103. Transverse Section through Carpus.
" 104. Transverse Section through Palm of Hand.
" 105 and 106. Cutaneous Areae of the Nerves of the Upper limb.
" 107 and 108. Cutaneous Areae of the Nerves of the Upper limb according to their spinal segmental origin.
" 109 and 110. Segmental Innervation of the Muscles of the upper limb.

V. Thorax.

- Fig. 111. Regions of the Thorax and Abdomen.
" 112. Frontal Section through the Trunk.
" 113. Superior Aperture of the Thorax.
" 114. Lymphatic Glands of the Breast in the Adult.
" 115. Lymphatic Glands and Vessels of the Head, Neck, Thorax and Arm in a child one year old.
" 116. Boundaries of the Lung and Pleura, from in front — Area of Absolute Cardiac Dulness.
" 117. Boundaries of the Lung and Pleura from behind.
" 118. Anterior Wall of the Thorax and Heart in the New-born.
" 119. Anterior Wall of the Thorax and Heart in the Adult.
" 120. Heart of Adult — Ventricle opened.
" 121. Transverse section through the Trunk; at level of 1st and 2nd Dorsal Vertebra.
" 122. Transverse section through the Thorax; at level of 9th Dorsal Vertebra.
" 123. Transverse section through the Thorax; at level of 5th Dorsal Vertebra.

VI. Abdomen.

- Fig. 124. Position of Viscera, from in front.
" 125. Position of Viscera, from behind.
" 126. Left Lung and Spleen, side view.
" 127. Position of Viscera — Peritoneal Cavity in the Child.
" 128. Liver, Stomach, Pancreas, Omental Sac.
" 129. Liver, Spleen, Pancreas, Duodenum, after removal of Stomach.
" 130. Position of Viscera (Extraperitoneal), Female.
" 131. Gall-Bladder, Bile-ducts, relations, Female.
" 132. Gall-Bladder, Bile-ducts, relations, Male.
" 133. Subphrenic Space, Pelvis of Kidney, Hilum of Liver, Bile-ducts.
" 134. Right Kidney, exposed from behind.
" 135. Portal Vein, Umbilical and Renal Vessels.
" 136. Position of Abdominal Viscera, seen from behind, lines of the Peritoneum.
" 137. Vermiform Appendix and Caecum.
" 138. Sigmoid Flexure and Inguinal Canal.
" 139. Transverse Section through the Trunk at level of 11th Dorsal Vertebra.
" 140. Transverse Section through the Trunk at level of 1st Lumbar Vertebra.
" 141. Retroperitoneal Lymphatics.
" 142. Anterior Abdominal Wall, seen from behind.
" 143. Anterior Abdominal Wall, Region of Appendix with Nerves. Bladder moderately distended.
" 144. Anterior Abdominal Wall, Hypogastric Region with Nerves. Bladder much distended.
" 145. Back, with Nerves, Arteries and Lymphatic Glands.

VII. Pelvis.

- Fig. 146. Median Section through Female Pelvis — Bladder and Rectum empty.
" 147. Female pelvic organs, seen from above and behind.
" 148. Vulva, Vestibule.
" 149. Female pelvic organs, seen from in front and above; Ureter.
" 150. Male pelvic organs exposed from behind.
" 151. Median Section through Male Pelvis.
" 152. Median Section through Male Pelvis; Urethra, Pelvic Fasciae.
" 153. Frontal Section through Male Pelvis; Levator Ani.

- Fig. 154. Male Perinaeum, I. Superficial layer.
 „ 155. Male Perinaeum; II. Recto-Urethral Muscle; Prostate.
 „ 156. Male Perinaeum; III. COWPER'S Glands with their Ducts.
 „ 157. Male Perinaeum; IV. Urogenital Triangle, Ampulla of Rectum.
 „ 158. Male Perinaeum; V. Prostate, Seminal Vesicles, Course of Urethra through the triangular ligament.
 „ 159. Male Perinaeum; VI. Pubic Region Levator Ani.
 „ 160. Female Perinaeum.
 „ 161. Male Pelvic Organs, from behind. Arteries to Seminal Vesicles.
 „ 162. Male Pelvic Organs, from left side. Nerves to Seminal Vesicles.
 „ 163. Gluteal Region.
 „ 164. Lymphatic Glands and Vessels of Female Pelvis, child.
 „ 165. Frontal Section through the Right Hip.
 „ 166. Inguinal Region, 1st layer, Superficial Lymphatic Vessels and Veins.
 „ 167. Inguinal Region, 2nd layer, Fossa Ovalis.
 „ 168. Inguinal Region, 3rd layer, Spermatic Cord, SCARPA'S Triangle.
 „ 169. Inguinal Region, 4th layer, Hernial Orifices, Iliac Bursa.
 „ 170. Inguinal Region, 5th layer, Subperitoneal Hernial Orifices. Hip-joint. Obturator Region.
 „ 171. Frontal Section through Left Hip-joint of boy aged 8 years.
 „ 172. NÉLATON'S Line.

VIII. Leg.

- Fig. 173. HUNTER'S Canal and Popliteal Space, seen from the inner side (JOBERT'S Fossa).
 „ 174. Transverse Section through the right thigh at junction of middle and upper thirds.
 „ 175. Transverse Section through the right thigh at junction of middle and lower thirds.
 „ 176. Left Knee-joint.
 „ 177. Sagittal Section through the left knee-joint (extended).
 „ 178. Sagittal Section through the left knee-joint (flexed).
 „ 179. Sagittal Section through the right knee-joint, boy aged 16 years.
 „ 180. Frontal Section through the right knee-joint, boy aged 8 years.
 „ 181. Transverse Section through the right knee-joint.
 „ 182 and 183. Lymphatics of the Popliteal Space.
 „ 184. Right Popliteal Space.
 „ 185. Transverse Section through the right leg, junction of upper and middle thirds.
 „ 186. Transverse Section through the right leg, near the ankle.
 „ 187. Right Leg, from the outer side. External Popliteal Nerve.
 „ 188. Right Leg, from behind. Internal Popliteal Nerve.
 „ 189. Tendon-Sheaths behind Internal Malleolus.
 „ 190. Region behind Internal Malleolus.
 „ 191. Sole of Right Foot, superficial layer.
 „ 192. Sole of Right Foot, deep layer.
 „ 193. Ankle and Dorsum of Foot, left side.
 „ 194. Outer side of Left Foot.
 „ 195. Dorsum of left foot with Muscles and Tendon-Sheaths.
 „ 196. Dorsum of left foot with Tendon-sheaths, Arteries and Bones projected on to surface.
 „ 197. Frontal Section through the right Ankle-joint.
 „ 198. Frontal Section through the Anterior part of Tarsus.
 „ 199. Sagittal Section through the right foot.
 „ 200. Horizontal Section through the right foot (near the sole).
 „ 201. Tarsal Joints, exposed from above, Right side.
 „ 202 and 203. Areas of the Cutaneous Nerves of the Lower Limb, Right side.
 „ 204. Nerve supply of Skin and Muscles of the Lower Limb according to their Segmental Origin — Anterior Surface.
 „ 205. Nerve supply of Skin and Muscles of the Lower Limb according to their Segmental Origin — Posterior Surface.

ATLAS

OF

TOPOGRAPHICAL ANATOMY.

Fig. 1. Median Section through the Head.

Right half of a frozen-section through the Head and Neck of a girl aged 15. In front the plane of section is carried accurately through the middle line, but posteriorly it deviates about $\frac{2}{5}$ th inch to the left. The bones are left intact, as is shewn by the bisected Odontoid Process; the soft parts (particularly brain-substance) have been carefully cleared away as far as the middle line.

A median section gives the best general idea of the relations and positions of the structures of the head, and in particular of the topographical relations of the brain to the face; it clearly shows how the brain extends further down posteriorly than in front. That portion of the skull cap under which the Cerebrum lies is only covered by a thin layer of soft parts — skin and epicranial aponeurosis (the latter is blue in the figure).

The Hemispheres, therefore, are easily injured in fracture of the vault of the skull. The Cerebellum is better protected. The thickness of the skull cap varies considerably at different points, and in different people — it is normally at the vertex $\frac{1}{10}$ th inch. On either side of the middle line the bone may be very thin, because for a distance of $\frac{4}{5}$ th inch from the middle line Pacchionian bodies may be present, and only covered by a very thin lamina of bone.

The Superior Longitudinal Sinus is exhibited throughout its whole length (the other Venous Sinuses are shewn in Figs. 15 and 16), beginning at the Foramen Caecum and increasing in width as it extends backwards and receives more blood it finally forms by junction with the Straight Sinus the Torcular Herophyli at the level of the External Occipital Protuberance (or somewhat higher up) and unites with each lateral Sinus, especially with the right.

Its position is very exposed; as it can be easily injured it demands consideration during trephining.

The Nasal Septum is usually asymmetrical, being bent to one side (left in this case). Dense connective-tissue is found at the anterior surface of the base of the skull and is continued downwards as the Anterior Common Spinous Ligament which covers the anterior surfaces of the bodies of the vertebrae. A thick mass of lymphoid tissue lies under the mucous membrane of the posterior wall of the pharynx (i. e. the Pharyngeal Tonsil); lower down between the Oesophagus and the Vertebral Column there is only a thin layer of connective tissue in which pus may easily spread downwards (Retropharyngeal Abscess).

When the mouth is closed, the Tongue lies against the Palate (in this figure, depending upon the form of death, suicide by drowning, the tongue is seen pushed between the Canine teeth).

On the posterior surface of the Hyoid Bone the Hyoid Bursa is seen lying between the Hyoid Bone and the Thyreohyoid Membrane which is attached to the upper border of the bone.

The Larynx is here seen at a higher level than usual; the Glottis, as a rule, is situated at the level of the 5th Cervical Vertebra or of the disc between the 5th and 6th Cervical Vertebrae.

The Pyramidal Process of the Thyreoid Gland (Pyramid of Lalouette), in this figure extends almost up to the Hyoid Bone whereas the usual height to which the Isthmus of the Gland reaches is the 1st Tracheal ring.

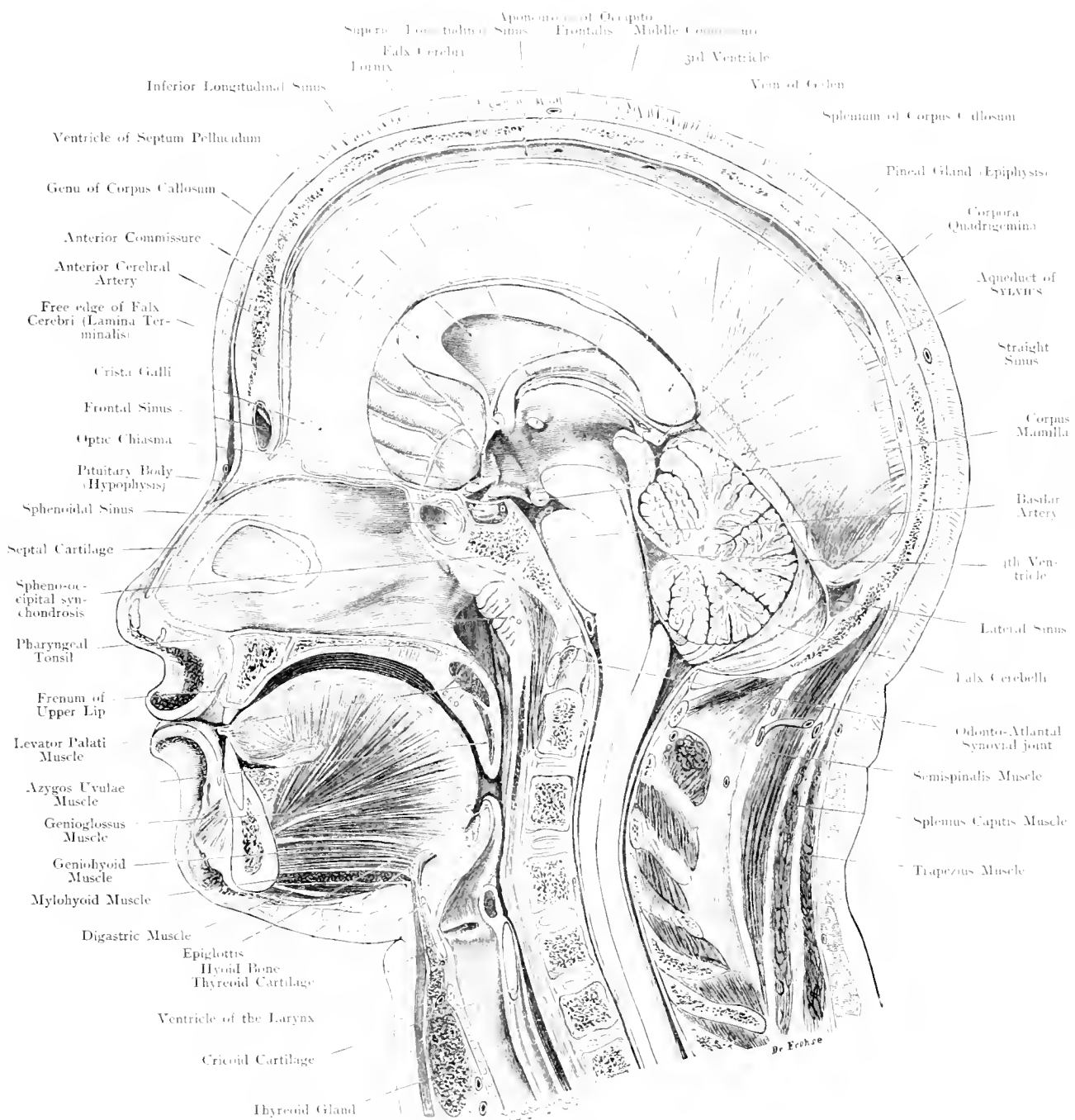


Fig. 1. Mesial (Sagittal) Section through the Head.

$\frac{2}{3}$ Nat. Size.

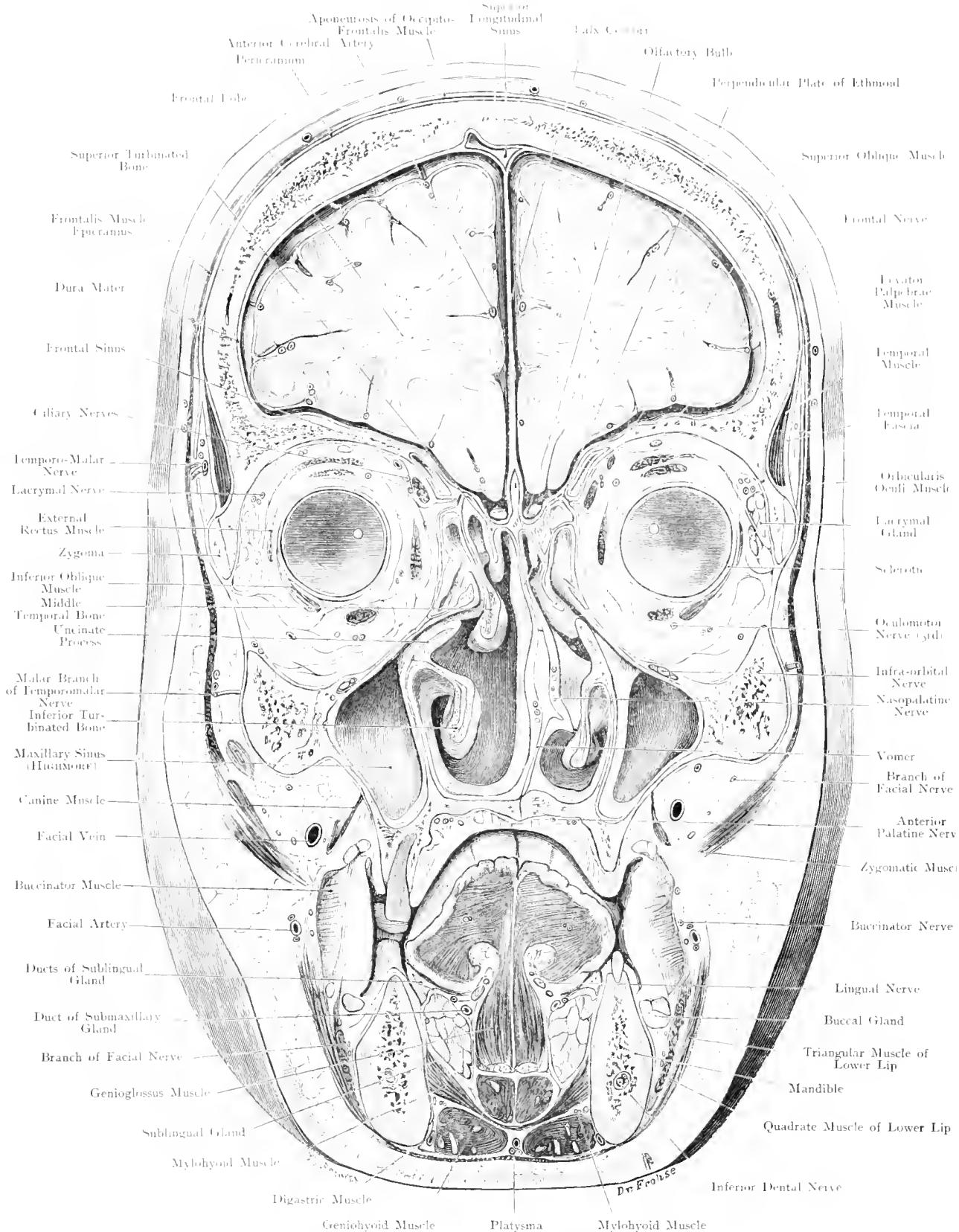


Fig. 2. Frontal Section of Head through the Orbits.
View from in front. - Nat. Size.

Fig. 2. Frontal Section of the Head through the Orbits.

Frozen section through the middle of the eye-balls. The slender nerves and vessels as well as the articulations of the bones have been determined by careful dissection.

The frontal bones are very thick owing to the obliquity of the section.

The Superior Longitudinal Sinus bulges to the right, owing to one of the "Lacunae Laterales"—accessory dilatations of the Sinus which are of frequent occurrence at the Vertex, and may extend $\frac{1}{3}$ ths inch from the middle line.

The Temporal Muscle is observed to be covered by the Temporal Fascia, which extends from the Superior Temporal Ridge to the Zygoma. At the upper border of the Zygoma it splits into 2 laminae (which may reunite), between which some fatty tissue becomes collected.

The Cavity of the Orbit (into the inner and upper portion of its roof the posterior extremity of the Frontal Sinus protrudes) is only partially filled by the eye-ball; the greater space is taken up by fat in which the eye muscles run.

Closely applied to the outer wall of the orbit is the Lacrimal Gland. The point at which the Optic Nerve enters the eye-ball is marked in yellow.

The figure shews the very large space occupied by the Nasal Cavity and its Accessory Cavities. The Nasal Cavity which is only separated from the Cranial Cavity by the thin cribriform plate of the Ethmoid Bone, presents 3 turbinated bones. On the left side the Sphenoidal Turbinated Bone was so short as to nearly escape the section.

Between the Middle and Inferior Turbinated Bones, the communication between the Nasal Cavity and the Frontal Sinus — the Infundibulum — is visible.

Directly below this orifice lies the aperture of the Antrum of HIGHMORE. This aperture situated almost at the top of the Antrum, is necessarily most unfavourable to drainage. The Nasal Septum is deviated from the middle line (cf. Fig. 1).

The Antrum is separated from the Orbit by the thin floor of the Orbit in which along the Infra-Orbital Canal the nerve and vessels of the same name pass. For the relations of the Alveoli of the Teeth to the Antrum vide Fig. 40. The wall between the Antrum and the Nasal Cavity is thin so that perforation can be easily carried out from the nasal cavity (if better drainage be sought by this route).

The Buccal Cavity is closed below by the Mylohyoid Muscle, which extends from the inner surface of the lower jaw downwards and inwards to meet its fellow in the middle line (Diaphragma Oris).

At the junction of the mucous membrane of the Cheek and the Gums, groups of mucous glands are found — buccal glands.

Figs. 3 and 4. Lateral Convex Surface of the Cerebrum.

Fig. 3 is purely diagrammatic, all shallow and inconstant sulci being omitted. From the Physiological standpoint the outer surface of the Cerebral Hemispheres may be divided into 2 parts by the posterior limb of the Fissure of SYLVIUS and the Post-Central Sulcus.

The Anterior part is the Motor Area so-called because from the Cortical Cells in this region arise the nerve fibres which compose the Pyramidal tract — the path of voluntary movements — so that stimulation Evokes involuntary movements or even Jacksonian Epilepsy while destruction produces paralysis of the opposite half of the body. — If then, for example, a tumour becomes formed in the region marked "Leg" on the left side, the pressure produced by this tumour will at first be irritating and bring about involuntary movements of the right leg.

With the extension of pressure, neighbouring centres will be irritated so that the right arm, then the muscles of the mouth on the right side will evidence involuntary movements, a "Progressive Epileptic Fit" being produced. As the tumour increases in size, stimulation will be replaced more and more by inhibition and an increasing paralysis of the right leg will result.

Destruction of the area marked "Writing" will produce only "Agraphia" whereas other movements of the upper extremity will be preserved. Similarly destruction of BROCA'S area will abolish the finer movements of the lips, palate, tongue and larynx, so that motor aphasia is produced, while the coarser movements of these structures remain intact. The centre for the course movements of the lips is situated in the area marked "Facial Expression", for the tongue in the area marked "Tongue".

(Continuation next page.)

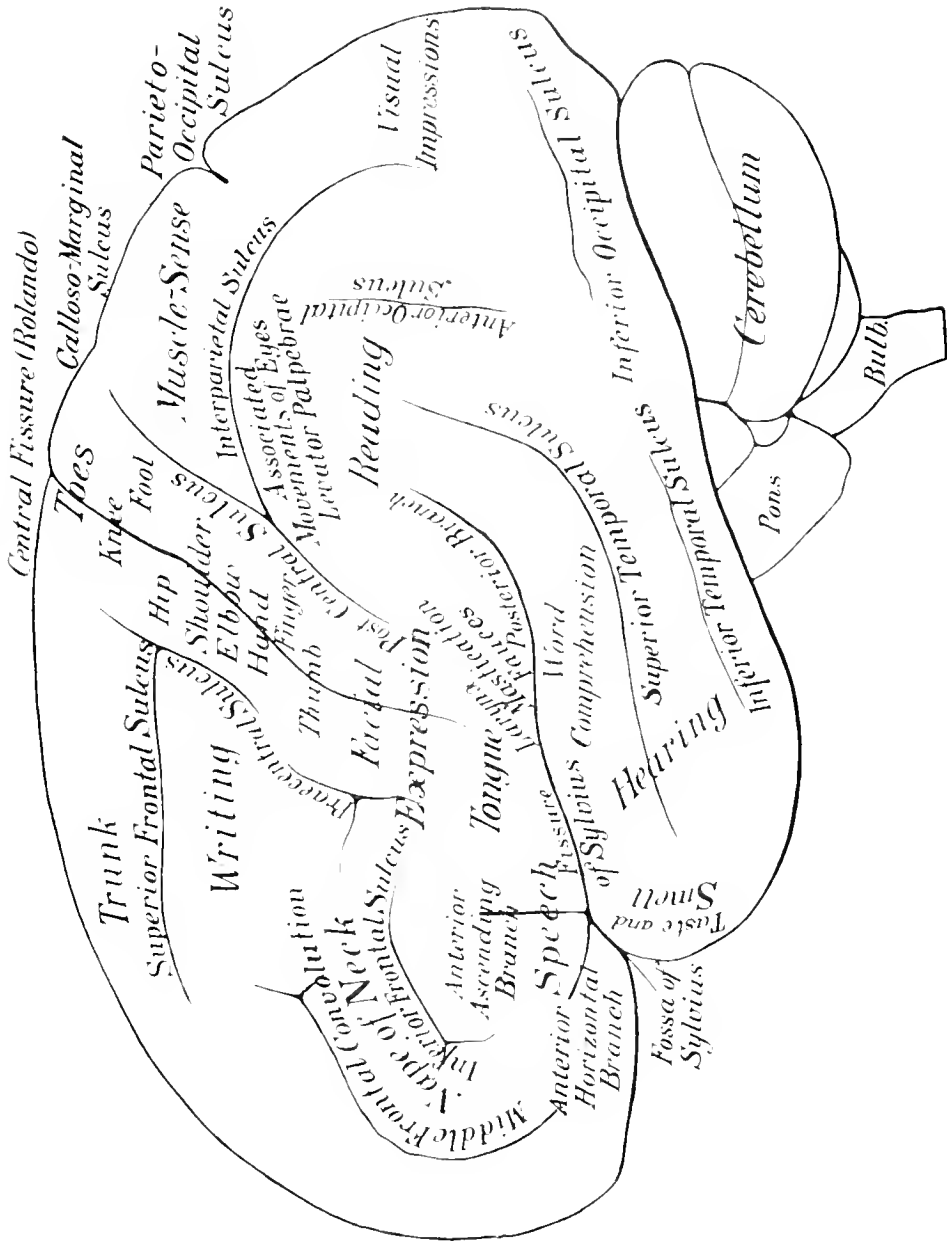


Fig. 3. Lateral Surface of the Great Brain: Centres.

Nat. Size. — By Prof. ZAHLEN.

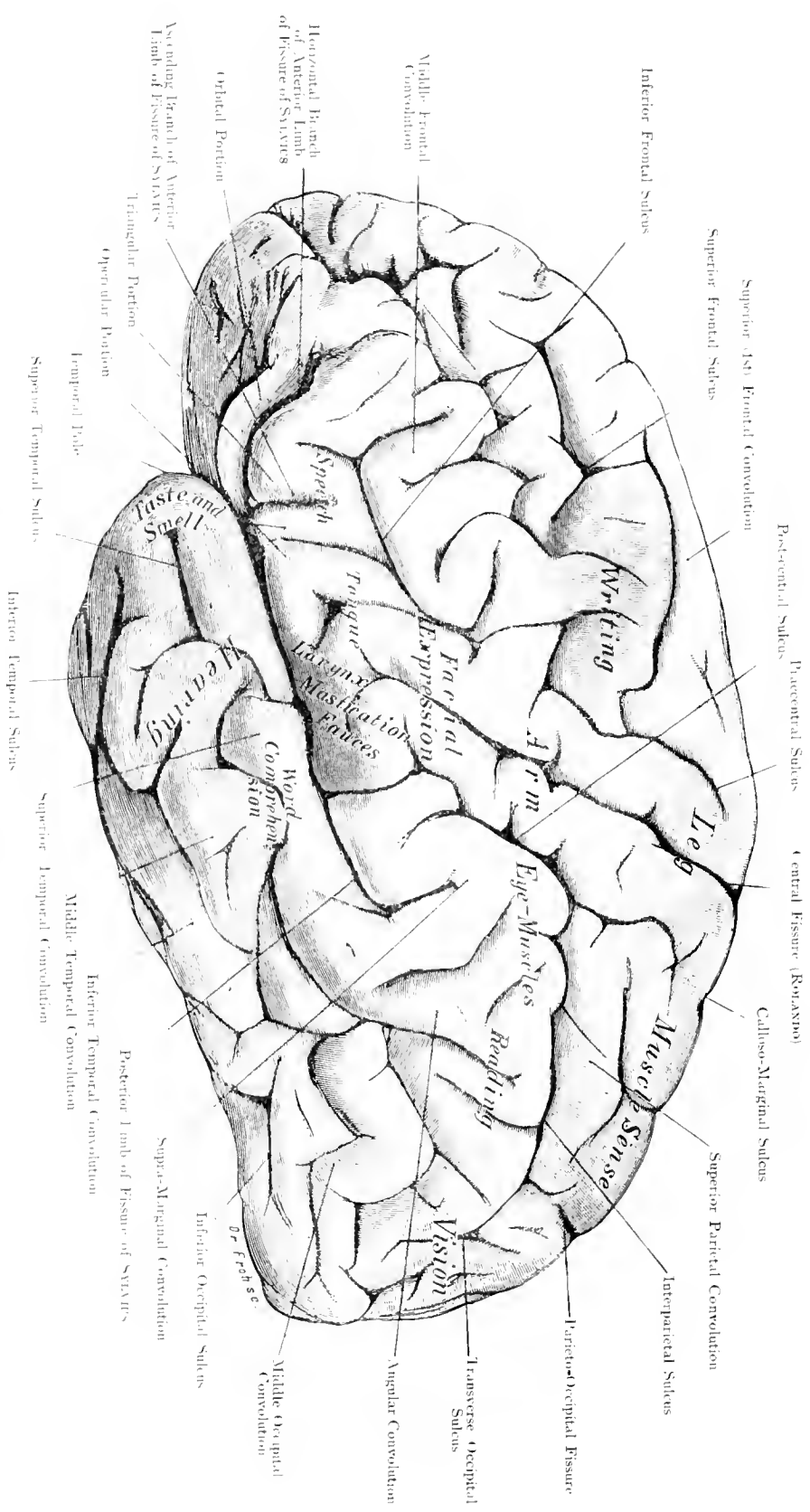


Fig. 4. Lateral Aspect of Cerebrum-Sulci and Convolutions.

Nat. Size. — By Prof. ZIEHEN.

(Continuation of the text of Figs. 3 and 4.)

In right-handed individuals the motor centres for Speech and Writing are situated on the Left (Cerebral Hemisphere, as yet the function of the corresponding area on the Right Hemisphere have not yet been defined. The majority of motor centres are only connected with muscles on the opposite side of the body; exception occurs in the centres for the trunk and the muscles of the eye as both centres have, in accordance with their symmetrical and synergetic innervation, both crossed and direct communications. Stress must be laid upon the fact that in all probably the centres are not acutely defined but overlap to the same extent. The sensory area on the outer surface of the hemispheres may be divided into 3 parts:

1. Area of "Muscle-Sense", in the Superior Parietal Convolution. When this area on the left side is injured the patient is unable to appreciate, with closed eyes, any altered position or passive movements of his right limbs.

2. The "Visual Area", behind the Parieto-Occipital Fissure. It is probable that this portion of the cortex localizes chiefly "Visual Impressions", having nothing to do with vision proper. When this area is destroyed "Psychical Blindness" is produced i. e. the patient sees well enough but cannot recognise objects he has seen before. The area marked "Reading" also belongs to this Visual Area because after destruction of this region the patient can see but cannot recognise letters.

3. Area of Hearing, Taste and Smell in the Temporal Lobe. Destruction of the regions marked "Hearing, Taste and Smell" disturbs these functions. Hearing and Taste are chiefly crossed, but Smell is chiefly direct. Destruction of the area marked "Word Comprehension" is followed by "Word Deafness" (Sensory Aphasia), the patient hears every word but does not recognise them and consequently fails to understand.

ZIEHEN.

Fig. 5. Median Section through the Brain.

The functions of the Anterior Portion of the inner surface of the Hemispheres is as yet unknown. The Convolutions above the Calloso-Marginal Sulcus belong probably to the Motor Area; the anterior parts are held to belong to the Superior Frontal Convolution and to form part of the motor-centre for the trunk; the posterior part is the Paracentral Lobe and forms part of the motor-centre for the Leg. The function of the Callosal Convolution is quite unknown. The Quadrate Lobe (Præcuneus) is probably a centre for "Muscle-Sense" like the Superior Parietal Convolution.

The Cuneus, i. e. the portion which lies between the Internal Parieto-occipital Fissure and the Calcarine Fissure is the area for "Vision" in the strict sense of the word; the portion of Cortex below the Calcarine Fissure probably also belongs to the visual area. Bilateral destruction of this part and the Cuneus produces complete Blindness (Cortical Blindness), unilateral crossed Hemianopsia.

Irritative lesions in this region produce visual hallucinations. The Corpus Callosum which is chiefly composed of Commissural Fibres between the Hemispheres has been divided in the middle line.

The Central Canal of the Cord opens into the tent-shaped 4th Ventricle and again becomes narrow (Aqueduct of SYLVIVS) before it opens into the 3rd Ventricle; the Superior and Inferior Choroid Membranes are incompletely represented. As the posterior tracts pass laterally and dorsally to the Cerebellum so that no

fibres are left between them, the Central Canal opens out into the 4th Ventricle while the delicate epithelium which forms the roof of this Ventricle blends with the Meninges and pushed downwards by the Choroid Plexus becomes the Inferior Choroid Membrane or Tela Choroidea Inferior. This lid or roof is perforated in the middle line by the Foramen of MAGENDIE and bilaterally by the Foramina of LUSCHKA (Foramen of KEY and RETZIUS).

The Epithelial roof of the 3rd Ventricle in all probability undergoes a similar change without the formation of the Foramina.

The lateral walls of the 3rd Ventricle are chiefly formed by the Thalami; connecting these across the cavity is the middle or gray commissure. The Foramina of MONRO lead from this Ventricle into the Lateral Ventricles. The Lamina Terminalis forms the Anterior boundary to this Ventricle which extends downwards to the Pituitary Body and the Optic Chiasma. In front lie two white strands, the Pillars of the Fornix, which can be traced into the Mammillary Bodies and shew through the Ependyma of the Ventricle. Between the Fornix and Corpus Callosum a thin membrane (Septum Lucidum) is stretched across, this membrane is double and often encloses a space which has been called the 5th Ventricle.

Between the Fornix and the Rostrum of the Corpus Callosum the Anterior Commissure has been cut, this probably only contains fibres associated with the Olfactory Apparatus.

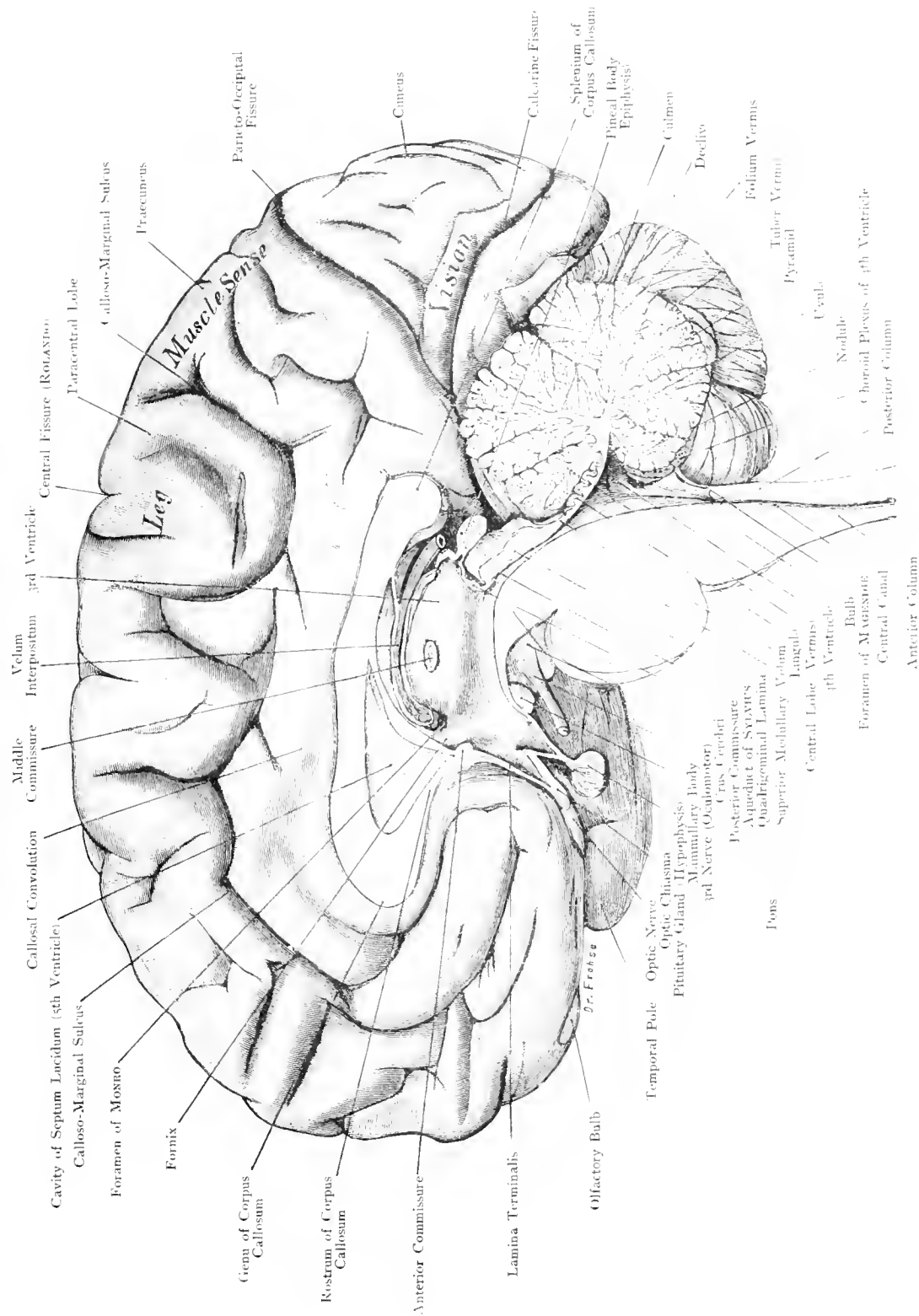


Fig. 5. Median Surface of the Brain.

Nat. Size. By Prof. ZIEHEN.

Cavity of Septum Lucidum (4th Ventricle)
 Callosal Convolution
 Middle Commissure
 Velum Interpositum
 3rd Ventricle
 Central Fissure (ROLANDI)
 Paracentral Lobe
 Callosal-Marginal Sulcus
 Praecuneus
 Parieto-Occipital Fissure
 Cuneus
 Calcarine Fissure
 Splenium of Corpus Callosum
 Pineal Body Epiphysis
 Culmen
 Decliv.
 Folium Vermis
 Tuberculum Vermis
 Pyramid
 Ventr.
 Nodule
 Choroid Plexus of 4th Ventricle
 Posterior Column
 Anterior Column
 Central Canal
 Foramen of Monro
 Fornix
 Rostrum of Corpus Callosum
 Anterior Commissure
 Lamina Terminalis
 Olfactory Bulb
 Temporal Pole
 Optic Nerve
 Optic Chiasma
 Pituitary Gland
 Mamillary Body
 3rd Nerve (Oculomotor)
 Crus Cerebri
 Posterior Commissure
 Aqueduct of Sylvius
 Quadrigeminal Lamina
 Superior Medullary Velum
 Pons
 Central Lobe (Vermis)
 4th Ventricle
 Bulb
 Foramen of Monro
 Central Canal
 Anterior Column
 Muscle-Sarpe
 Fissura
 Leg
 Dr. Freese

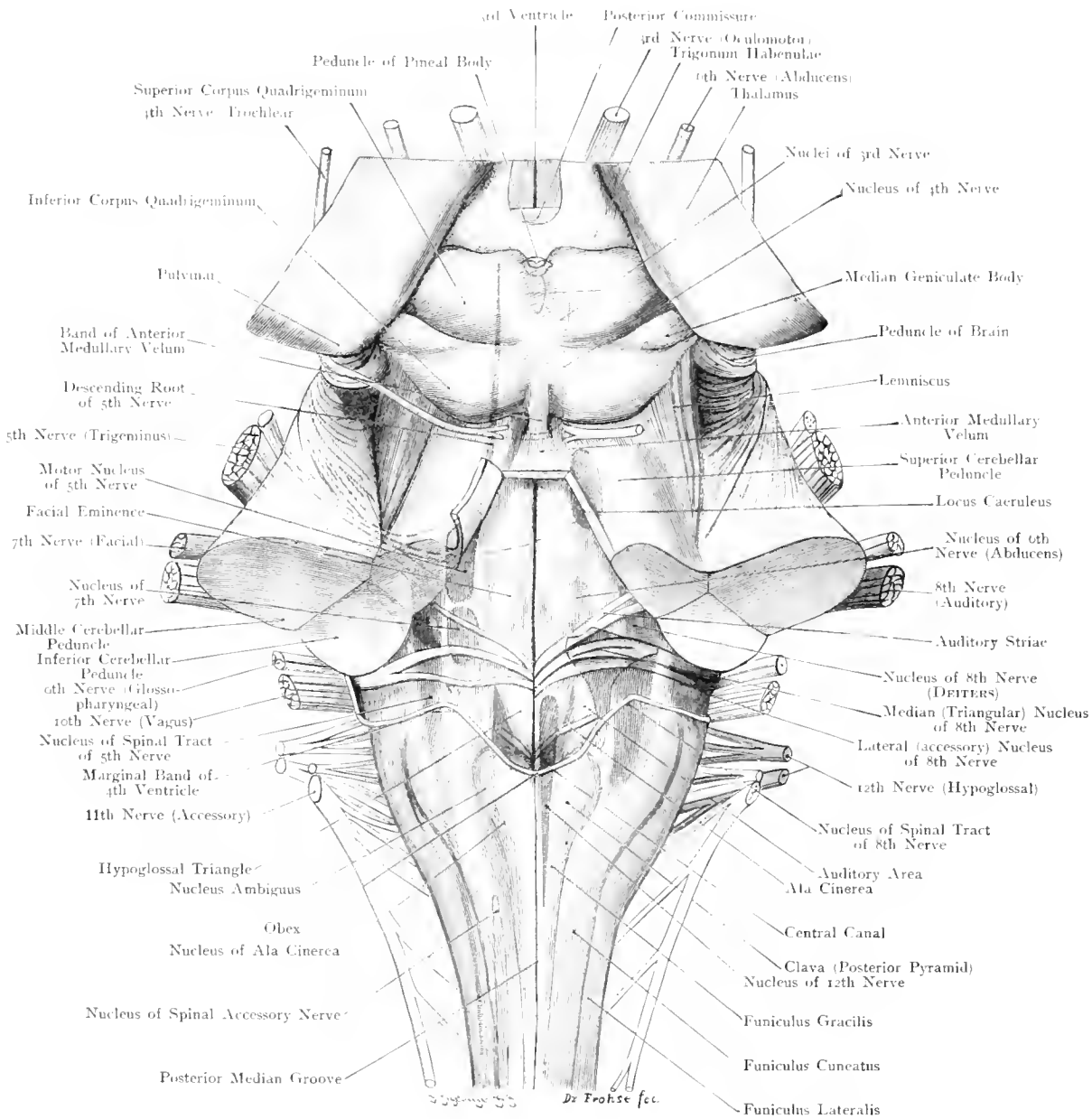


Fig. 6. Dorsal Aspect of Fourth Ventricle.

Twice Nat. Size. — By Prof. ZIEHEN.

Fig. 6. Dorsal Aspect of Fourth Ventricle.

The Cerebellum has been removed by a section parallel with the floor of the 4th Ventricle, so that the 3 Cerebellar Peduncles, strands which connect the Cerebellum with the rest of the Central Nervous System, are seen on both sides in transverse section.

1) Superior Peduncle conducting fibres chiefly to the Dentate Nucleus of the Cerebellum.

2) Middle Cerebellar Peduncle, connecting the Nuclei of the Pons with the Cerebellar Hemispheres.

3) Inferior Cerebellar Peduncle (Restiform Body) chiefly conducts to the Columns of the Spinal Cord those fibres which passed to the Dentate Nucleus through the Superior Peduncle.

The Valve of VIEUSSENS which lies across, between the Superior Cerebellar Peduncles, has been cut and thrown to the left.

The Facial Eminence (Colliculus Facialis) is produced by fibres of the Facial Nerve which, after emerging from their cells, pass towards the floor of the 4th Ventricle and bend at a right angle again, alter a course of $\frac{1}{10}$ th inch, to run backwards towards their nucleus of origin.

As the Nucleus of the Facial Nerve lies deep in the substance of the Pons and Bulb, with many groups of cells extending upwards and downwards, it must be remembered that this Nucleus is not at the floor of the 4th Ventricle and is accordingly represented diagrammatically.

The Nuclei of the other Cranial Nerves lie near the surface. The anterior part of the Oculomotor Nucleus contains the fibres for the Sphincter of the Iris and the Ciliary Muscles; the posterior part contains the Fibres for the Extrinsic Muscles of the Eye. Immediately behind is the Nucleus of the IVth Nerve (Pathetic), the fibres from this pass to the Valve of VIEUSSENS where they decussate and on emerging wind round the Crura to reach the base of the brain. The Nuclei of the Vth Nerve (blue) are partly sensory and partly motor; the chief sensory Nucleus (pale blue) extends as far caudally as the 2nd Cervical Segment (Descending root of the Fifth Nerve), it is club-shaped with its broader end above. The chief Motor Nucleus (dark blue) which is generally connected with the minor Motor Nucleus extends upward into the region of the Anterior Corpora Quadrigemina. Although the shape of the cells of this Nucleus are peculiar, it is probably motor.

The function of the Locus Coeruleus is doubtful, its cells previously considered to be sensory are now viewed as motor.

The Nucleus of the VIth Nerve lies directly under the floor of the 4th Ventricle in the bend of the Facial Fibres described above.

In the posterior part of the 4th Ventricle, which is separated from the anterior part by the Striae Acusticae, a median grey and two lateral white triangular areas can be delineated on either side. The grey area (Ala Cinerea) contains the Sensory Nucleus of IXth, Xth and XIth Nerves. The Motor Nucleus of these nerves (Nucleus Ambiguus) is marked yellow; the Nucleus of their ascending root (Solitary Bundle of MEYNERT) which is not indicated occupies a ventrolateral situation in relation to the Sensory Nucleus.

The Sensory Nucleus is situated internal and at a deeper plane than the descending root of the Vth Nerve. The inner white triangle corresponds to the Hypoglossal Nucleus and the outer to the Dorsal Nucleus of the VIIIth Nerve (Cochlear Portion). This Cochlear Portion has another Nucleus (the Ventral Nucleus) situated along the outer border of the Inferior Cerebellar Peduncle. For the Vestibular Portion of the VIIIth Nerve there are two Nuclei shown in the figure (DEITERS' Nucleus and the Nucleus of the Descending Root of the VIIIth Nerve) [Nucleus Tractus Spiralis Nervi Acustici].

ZIEHEN.

Fig. 7. Arrangement of Fibres in the Internal Capsule.

All the fibres from one hemisphere pass together through the Crus at the Base of the Brain. In their course from the Cortex to the Crus these fibres pass between the large Basal Ganglia (Thalamic, Caudate and Lenticular Nuclei), as shewn in the figure. Leaving the outermost and external capsules out of consideration these fibres have but one course open to them, viz: between the Caudate and Lenticular Nuclei and between the Thalamic and Lenticular Nuclei. This is the Internal Capsule with its Anterior and Posterior limbs and an intervening bend (genu). The arrangement of the fibres in the Internal Capsule is as follows: — The pyramidal tract, the path of voluntary movements, occupies the anterior $\frac{2}{3}$ rds of the posterior limb in such a manner that the Facial and Hypoglossal Fibres lie in the genu, next in order come the fibres to the upper Limb and lastly those to the lower limb. In the posterior $\frac{1}{3}$ rd of the posterior limb of the internal capsule lies the great sensory path for "Common sensibility" and the occipito-temporal cortico-pontic tract which passes from the occipital and temporal lobes to the Pons. Furthermore, fibres pass to and from the Cortex and Thalamus. Close behind the posterior limb is the so-called "Carrefour sensitif" (CHARCOT'S Sensory Tract), through which the paths of the higher senses (Olfactory excepted) pass. In the figure, only the fibres connected with the Optic Nerve are depicted in their passage from this point to the Occipital Lobe.

Disease of this "Carrefour" produces mixed Hemianaesthesia i. e. patients feel, taste and hear less definitely or not at all on the opposite side, and do not see with the Nasal half of the Eye on the same side and Temporal half of the opposite eye, whereas disease of the posterior part of the posterior limb of the Internal Capsule produces motor paralysis of the opposite side.

The Anterior Limb contains chiefly fibres derived from the Frontal Lobe and Caudate Nucleus; their course and function is unknown. The Caudate Nucleus and its tail curl over the Internal Capsule to terminate by blending with the Hippocampal Convolution and the Amygdaloid Nucleus; so that in this section the Caudate Nucleus has twice been cut — at its body internal to the anterior horn of the lateral Ventricle and at its tail near the descending horn.

The lateral and 3rd ventricles communicate through the Foramina of MONRO. The pillars of the fornix are cut near their point of junction. The posterior horn of the lateral ventricle is cut at the point where the inferior horn begins.

The white fibres of the Corona Radiata between the Cortex and the Corpus Striatum is called the Centrum Semi-Ovale of VICQ D'AZYR. ZIEHEN.

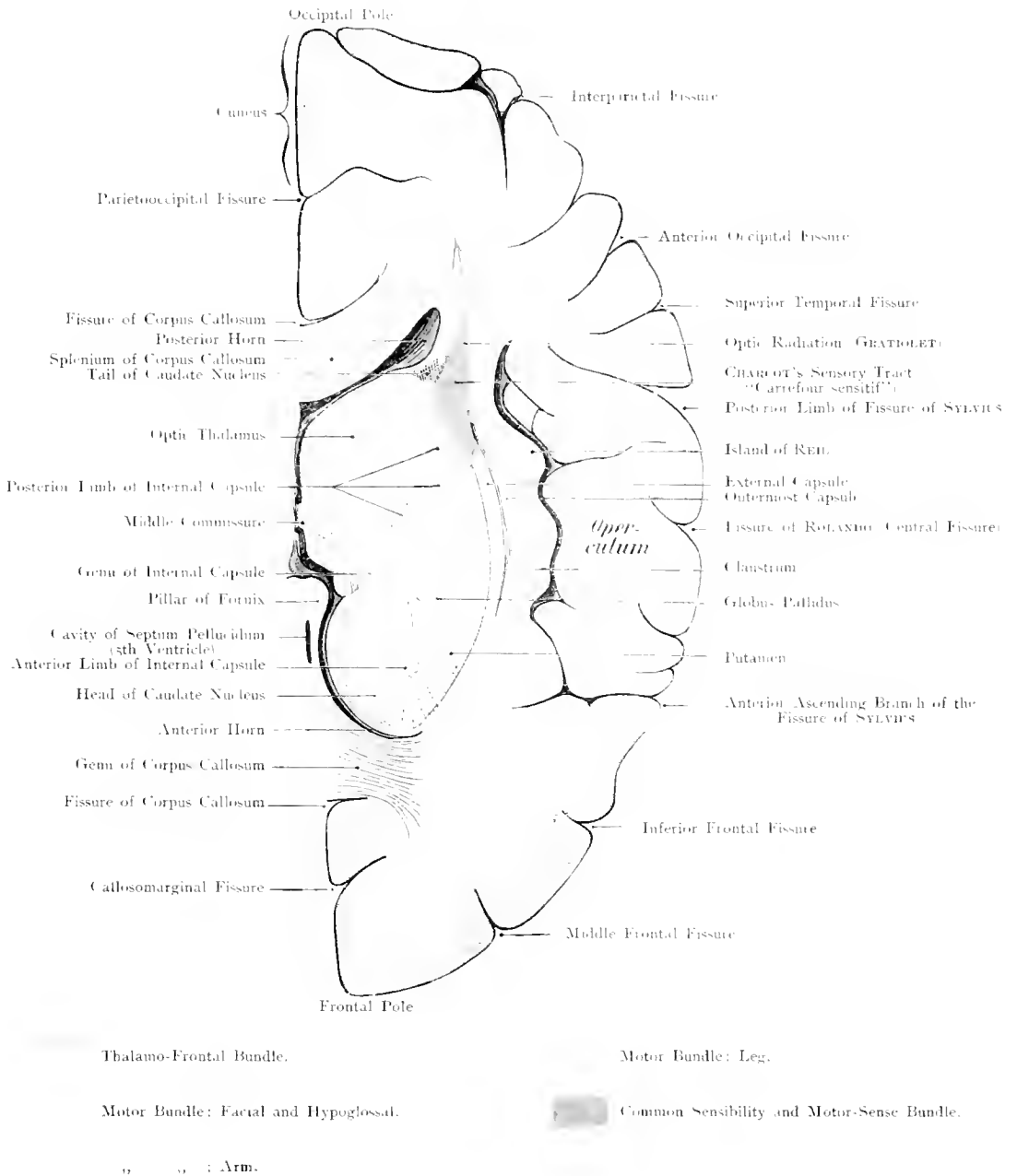


Fig. 7. Direction of Fibres in the Internal Capsule.

Seen from above. — Nat. Size. — By Prof. ZIEHEN.

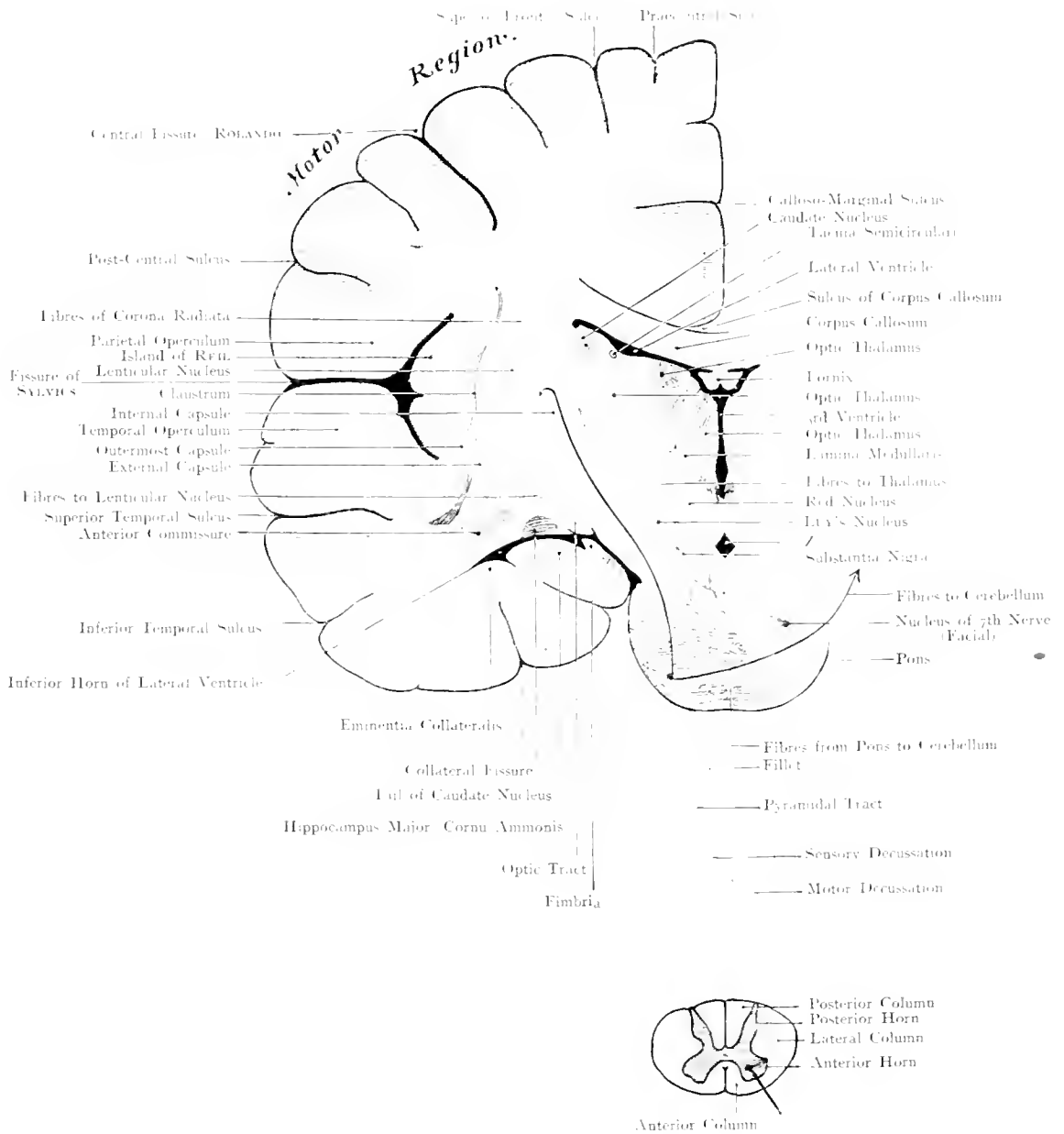


Fig. 8. Course of Fibres from Cortex to Spinal Cord.

Nat. Size. -- By Prof. ZIEHEN.

Fig. 8. Course of Fibres from Cortex to Spinal Cord.

This section is not accurately in the Frontal plane but is directed somewhat obliquely so that above it passes through the Prae-central Convolution and below through the middle of the Pons. At the Point marked *Z* it passes through the Posterior Perforated Spot. A transverse section of the cord has been added in order to shew the topographical relations of the long cerebral tracts to the columns of the spinal cord. The posterior limb of the internal capsule is divided and the pyramidal tract is seen running from the motor area, through the posterior limb, to the middle third of the ventral portion of the Pons; at the Bulb (Decussation of the Pyramids) these fibres cross the middle line and continue their course in the Lateral Columns of the Cord, whence they pass to arborize around the Anterior Cornual Cells which give off the fibres of the peripheral nerve.

The fibres of the pyramidal tract which arborise around the Nucleus of the Facial Nerve of the opposite side cross the middle line in the Pons. The course of the Facial Fibres and the Facial Nucleus is schematic. (Cf. Fig. 6 Text.)

The Posterior Columns of the Spinal Cord contain the path of the "Muscle-Sense". Probably the fibres from the lower extremity lie in the tract of GOLL in the cervical region and those from the upper limb in the tract of BURDACH. These tracts decussate in the Bulb, practically opposite the Decussation of the Pyramids. The further course of this path is known as the "mesial fillet"; the fibres end partly in the Corpora Quadrigemina, partly in the Thalamus and partly, after tracking through the posterior limb of the internal capsule, in the cortex of the Parietal Lobe.

The Occipito-temporal cortico-pontic tract (previously mentioned in Fig. 7), appears again in the outer $\frac{1}{3}$ rd of the base of the Pons, arborising around the Nuclei of the Pons whence new fibres cross the middle line to reach the Cerebellum through the Middle Cerebellar Peduncles. The Optic Tract is cut transversely; the anterior commissure obliquely — its fibres pass to the Olfactory Area, to the Hippocampal convolution.

The Caudate Nucleus is again cut in 2 places, at the commencement of its tail near the Thalamus and at its termination in the descending horn. The Fimbria represents the termination of the Fornix which in its course along the lower aspect of the Corpus Callosum has 2 (posterior) columns which, after diverging, ascend in the form of an arch with its convexity backwards to finally (this is the part called the Fimbria) join the floor of the ventricle. The gray matter situated between the Cortex and the Fimbria is the Fascia Dentata; above these structures (Fimbria and Fascia Dentata) is the Lateral Choroid Plexus. This is not indicated in the figure. It is probable that the Lateral Choroid Plexus does not close in the descending horn of the Lateral Ventricle completely but allows the intra-ventricular cerebro-spinal fluid to communicate with that of the basal sub-arachnoid spaces.

ZIEHEN.

Fig. 9. Frontal Section through the Crus Cerebri at the level of the Posterior Corpora Quadrigemina.

The Mesencephalon (Crura) containing all the Projection Fibres from the Cerebral Hemispheres is divided into 2 layers, an upper the "tegmentum", a lower the "crusta"; these are separated by the "substantia nigra". The Tegmentum chiefly contains: —

1. Fibres from Thalamus and Corpora Quadrigemina. To these belongs the so-called posterior commissure which represents the connection of the Tegmentum with the Thalamus of the opposite side.
2. Fibres from Lenticular Nucleus. Cf. Explanation to Fig. 8.
3. Fibres from Cortex. To these belongs the path of "Muscle-Sense". Cf. Text to Fig. 7. It moreover contains 3 Nuclei.
 - a) Nucleus of Descending Root of Vth Nerve on either side of the Aqueduct of SYLVIVS.
 - b) Nucleus of the IIIrd (Oculomotor) Nerve, on either side of the Aqueduct of SYLVIVS.
 - c) Nucleus of the IVth Nerve which lies posterior to the IIIrd Nucleus at the posterior end of the Aqueduct of SYLVIVS.

The Internal Geniculate Body probably belongs to the auditory path. The posterior longitudinal bundle is derived partly from the anterior column of the spinal cord and possibly connects the nuclei of the motor nerves of the eye.

A large number of the fibres in the tegmentum stop in the "Red Nucleus" where new fibres arise to cross the middle line and leave the tegmentum by passing to the Cerebellum through the Superior Cerebellar Peduncle. (Cf. Fig. 6 Text.)

The Crusta chiefly contains: —

1. Cortico-crustal Fibres — Geniculate Bundle (MEYNERT).
2. Frontal Cortico-pontic Tract which passes from the Frontal Lobe and Caudate Nucleus to the Pontine Nuclei, whence fibres cross the middle line and pass to the Cerebellum through the Middle Cerebellar Peduncle.
3. Pyramidal Tracts. Cf. Fig. 7 Text.
4. Occipito-temporal cortico-pontic Tract which passes from the Temporal and Occipital lobes to the Pontine Nuclei. Course of these fibres as in 2.

The course and function of the fibres in close proximity to the Substantia Nigra is unknown.

Fig. 10. Convolution of the Brain and Sutures of the Skull in the New-Born.

The detailed description of the convolutions is given in the text accompanying the following figures. We only desire to lay stress upon, the high position of the Fissure of SYLVIVS, and the Fontanelles.

The smaller fontanelles (Sphenoidal and Mastoid) may be very small at birth; whereas the largest, the Frontal, remains open till the end of the first year of life.

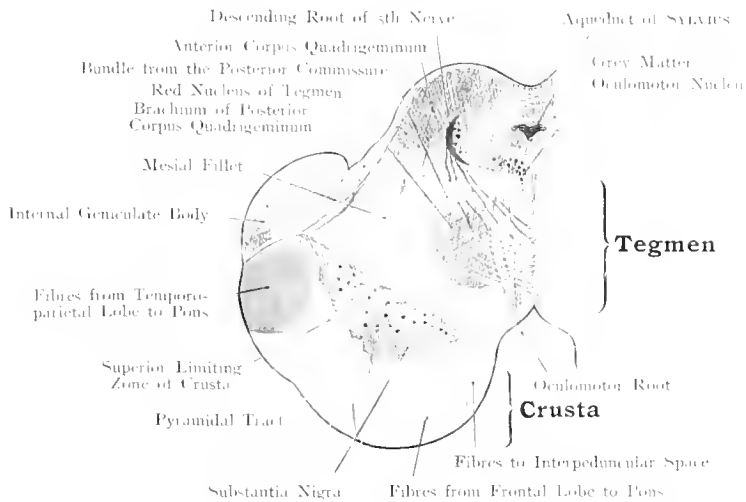


Fig. 9. Direction of Fibres in the Crus Cerebri — Frontal Section.
 Nat. Size $\times 2$. — By Prof. ZIEHEN.

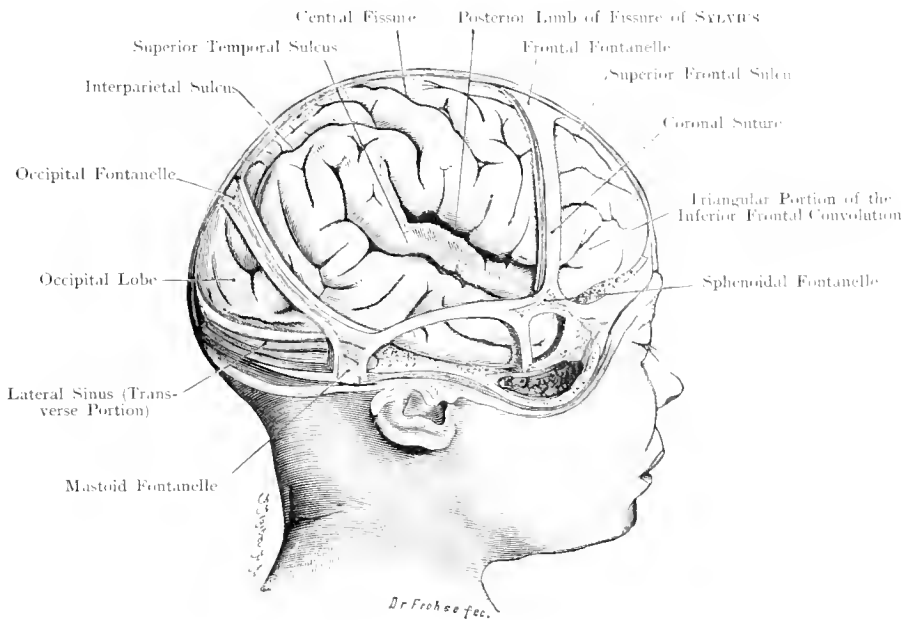


Fig. 10. Convolution of the Brain and Sutures of the Skull in the Newborn.
 $\frac{1}{2}$ Nat. Size. — After Prof. CUNNINGHAM.

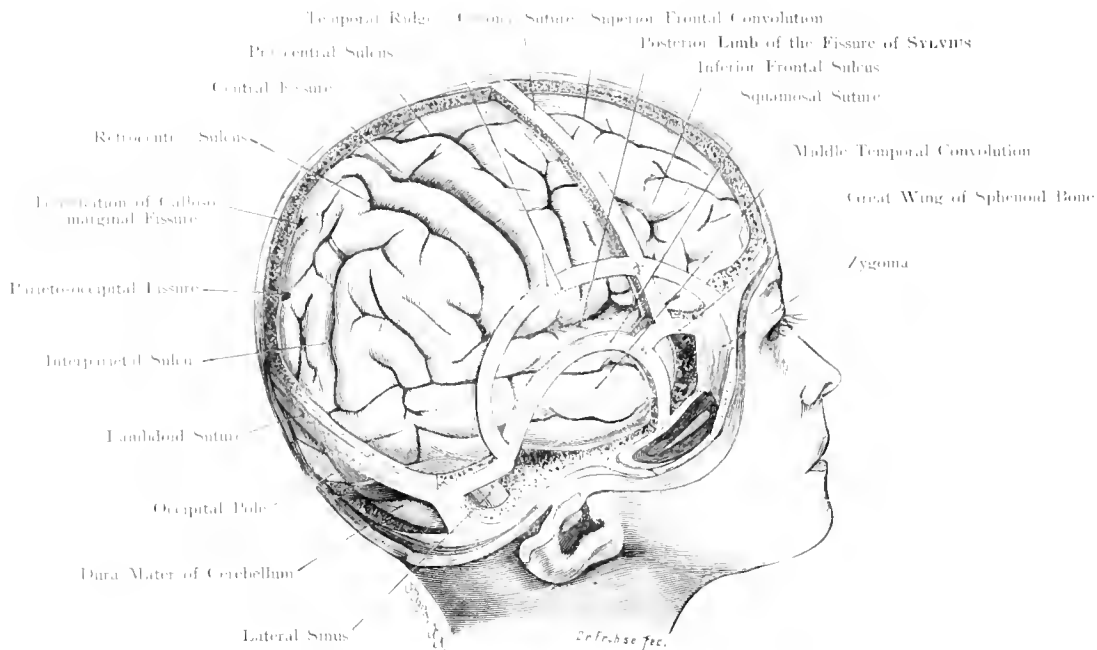


Fig. 11. Convolution of the Brain and Sutures of the Skull in the Child.

$\frac{1}{2}$ Nat. Size. After Prof. CUNNINGHAM.

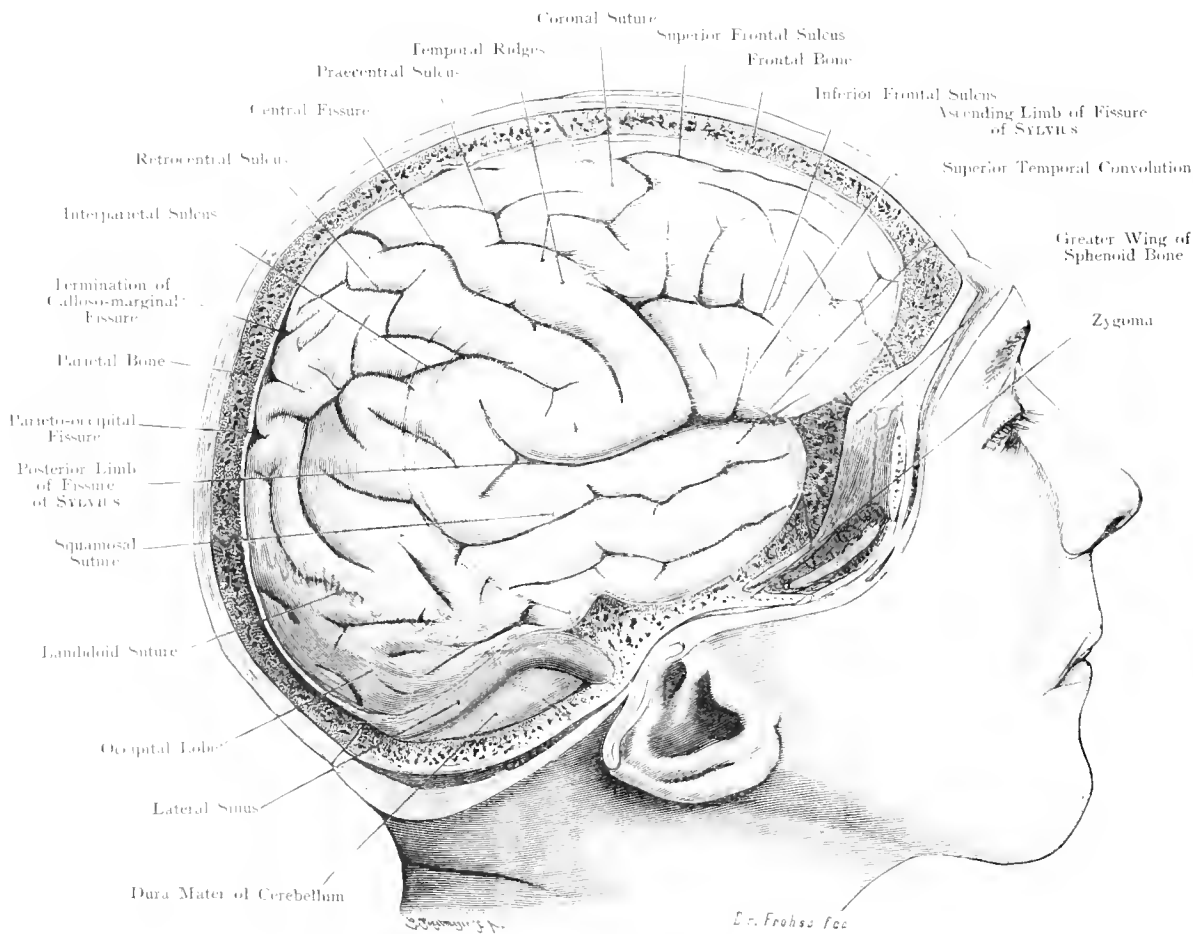


Fig. 12. Convolution of the Brain and Sutures of the Skull in the Adult.

$\frac{2}{3}$ Nat. Size. - After Prof. CUNNINGHAM.

**Fig. 11. Convolution of the Brain and Sutures of the Skull
in the child.**

**Fig. 12. Convolution of the Brain and Sutures of the Skull
in the Adult.**

CUNNINGHAM'S Method of removing the Skull Bones, except narrow bars at the sutures, affords an excellent method of shewing the relations of the Cerebral Convolution to the Cranial Sutures. (Skeletotomy of the Brain, WALDEYER.) It is advantageous to consider the fissures and sulci rather than the convolutions. In the removal of the skull bones in the infant it should be remembered that they become attenuated at the regions farther away from their ossific centres; this diminution in the thickness of the Bone is replaced by a corresponding thickening of the Dura Mater and Pericranium. This close union of the fibrous skull-cap checks the spreading of subdural and subperiosteal Haematomata within the limiting area of any one bone. Moreover, it follows, that Bone and Dura Mater are removed in one piece during this dissection in the new-born. In later childhood and adult life the bones are, as a rule, easily separated from the dura mater, difficulties only occurring at the following points: near the Superior Longitudinal Sinus because PACCHIONIAN bodies may be present, and at the Parietal Foramen (SANTORINI). The Mastoid Emissary Vein may be a point for dangerous haemorrhage because of the proximity of the Lateral Sinus. The Emissary Veins favour the spread of inflammation (cf. Erysipelas complicated by Meningitis).

At the Sphenoparietal Sinus there is danger of Haemorrhage from laceration of the Anterior Branch of the Middle Meningeal Artery which may be embedded in a partial or complete canal near to it. (Cf. Fig. 32.)

In connection with the position of the Sulci and Fissures it should be noted that in the new-born (Fig. 10) the Fissure of SYLVIVS lies at a higher level than the Squamosal Suture, and that the Central Fissure (ROLANDO) is placed more anteriorly than in the adult. In the child (Fig. 11) the squamous portion of the Temporal Bone grows upwards and the temporal ridges become more definite (blue in the figure in order to distinguish them from the sutures [red]).

In the adult the Fossa of SYLVIVS corresponds closely to the Squamosal Suture. (Cf. Fig. 19.)

Accordingly, with certain individual variations, the relation of the Fossa of SYLVIVS to the skull bones gradually alters with the bony development. The most important central convolutions, however, lie at all ages in the middle third of the Parietal Bone, being slightly further forward in the new-born. To the surgeon interest is attached to the sutures, because certain anthropometric markings are employed (Fig. 18).

Nasion, at base of nose, and Inion, at external occipital protuberance, both points are employed in connection with the determination of the upper extremity of the Central Fissure (ROLANDO).

Lambda, in middle line, where the Sagittal and Lambdoid Sutures meet, is employed for the determination of the Parieto-occipital Fissure.

Obelion, a point above the former, less irregular in shape, corresponds to the Parietal Foramen.

Bregma, junction of Sagittal and Coronal Sutures, is at the anterior border of the Parietal Bones.

On the lateral aspect of the Skull, the Asterion, is the postero-inferior angle of the Parietal Bone, where the lateral sinus turns downwards.

Stephanion, the crossing of the coronal suture and the temporal ridges (near the Spheno-parietal Sinus).

Pterion, the point of meeting of the Sphenoid, Parietal and Temporal Bones; this is the site for ligation of the Anterior Branch of the Middle Meningeal Artery; underneath lies the Fossa of SYLVIVS.

Fig. 13. Base of Brain with Arteries and Superficial Origin of Cranial Nerves.

The Pia Mater has been removed. Unimportant branches of the Arteries have been cut away; the Pituitary Body has been removed. (Names of Arteries cf. Fig. 25.)

The vertical and lateral surfaces of the Cerebrum are of importance in connection with Motor and Sensory Centres while the Base of the Cerebrum demands consideration in connection with the position of the Cranial Nerves and the Arteries.

Functional disturbance of a single nerve or of a group of nerves will guide us to the seat of a tumour or any other pathological basal lesion which brings about the particular disturbances. It is a remarkable fact that, with the exception of the Olfactory and Optic Tracts which are really outgrowths from the Brain, all Cranial Nerves emerge from the Brain between the upper border of the Pons and the lower end of the Bulb.

The Superficial (apparent) Origin of the VIth and XIIth nerves are very close to each other at the posterior border of the Pons and side of the Bulb.

The course of the nerves after leaving the Brain until they reach their foramina of exit varies in length. The IVth nerve has the longest intra-cranial course, arising on the dorsum of the Mid-Brain (Mesencephalon), near the valve of VIEUSSENS (cf. Fig. 6), it winds round the Crus to reach the Ventral aspect of the Brain. A portion of the roots of the Spinal Accessory also has a long course arising as it does low in the Cervical portion of the Spinal Cord.

The brain is supplied with blood from its base through the Internal Carotid and Vertebral Arteries. The two Vertebral Arteries unite to form the Basilar which gives off the Postero-Inferior Cerebellar (this is more often a branch from the Vertebral), the Auditory, the Antero-Inferior Cerebellar, and the Superior Cerebellar Arteries. At the inferior border of the Pons the Basilar Artery divides into Right and Left Posterior Cerebral Arteries each of which communicates (posterior communicating) with the Internal Carotid. The Internal Carotid gives off the large Middle Cerebral (SYLVIAN) Artery, the smaller Choroidal Branches and the Anterior Cerebral Artery. As the two Anterior Cerebral Arteries are connected by the Anterior Communicating in front of the Optic Chiasma a large circular anastomosis is formed round the Sella Turcica (Circle of WILLIS).

All the vessels pass to and ramify in the Pia Mater, and give off small branches, which enter the brain and supply it with blood.

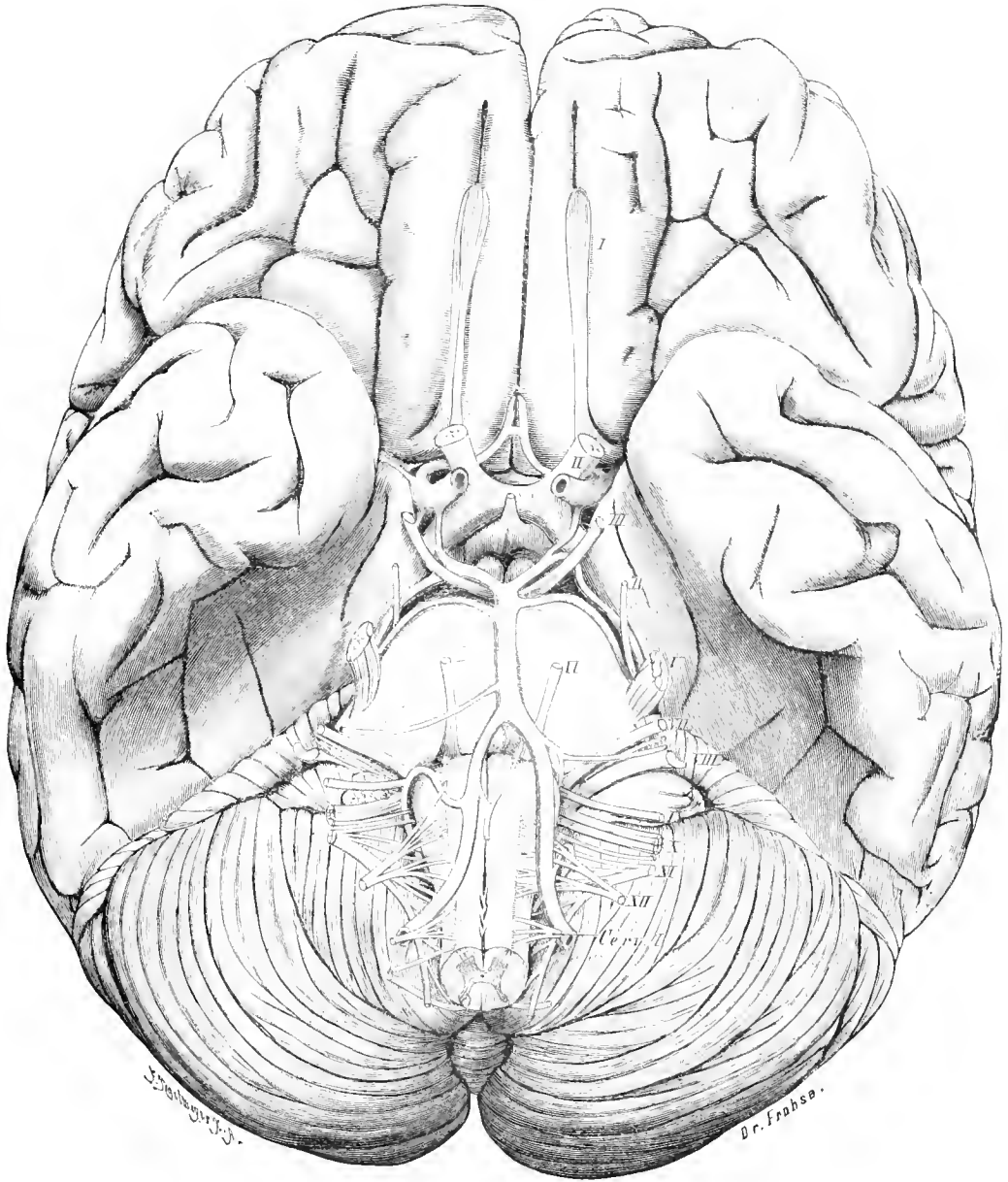


Fig. 13. Base of Brain with Arteries and Superficial Origin of Cranial Nerves.

Nat. Size.

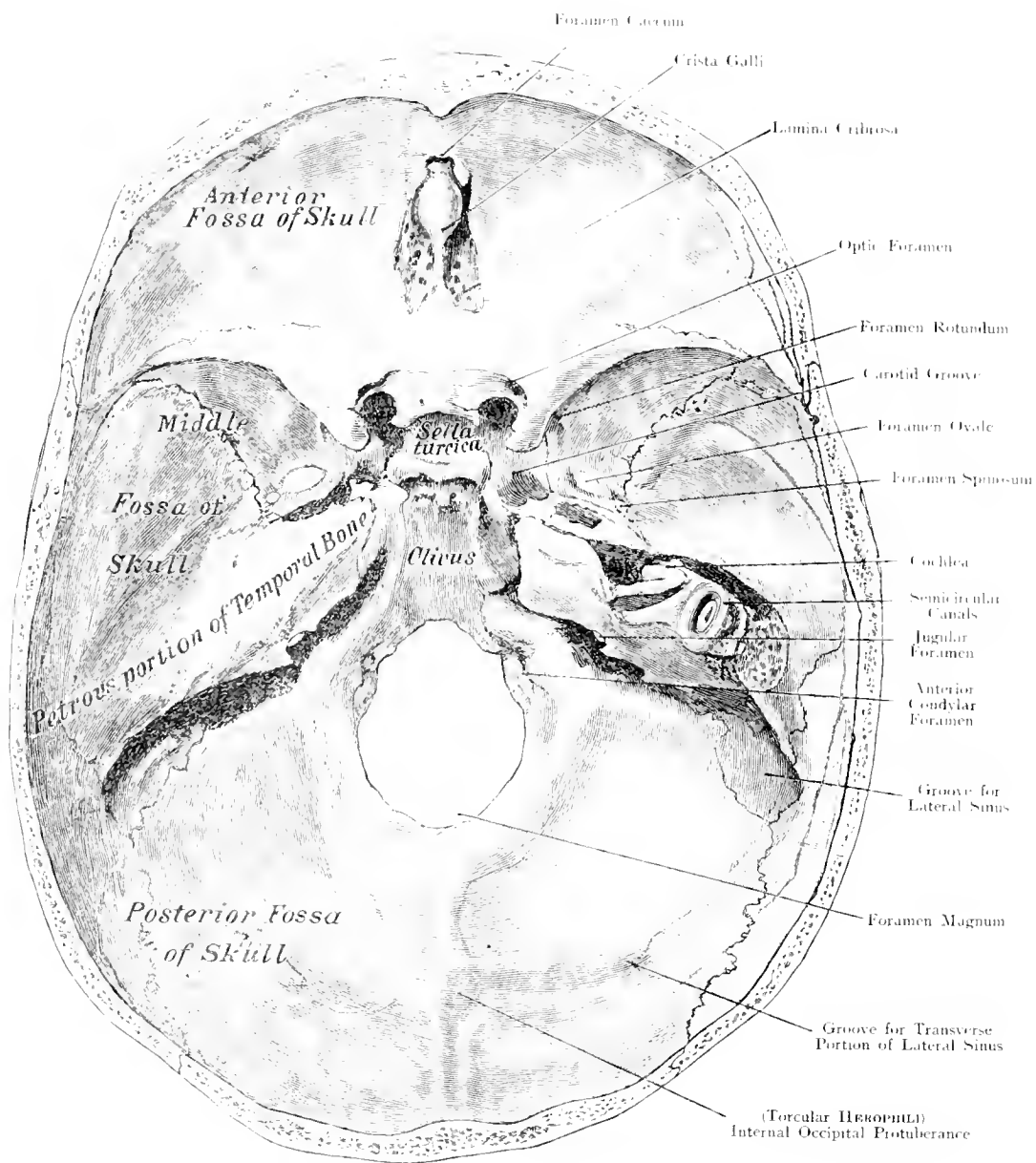


Fig. 14. Base of Skull — seen from above.

$\frac{4}{5}$ Nat. Size.

Fig. 14. Base of Skull seen from above.

Cochlea and Semicircular Canals, on the right side, exposed.

The base of the Skull is more complicated and irregular than the Vertex. Three Fossae are recognised, the anterior bounded behind by the sharp border of the lesser wing of the sphenoid, in this lies the Frontal Lobe, in the middle line are found the Crista Galli and the Cribriform Plate of the Ethmoid through which the Olfactory Nerves pass.

The Middle Fossa extends from the Sella Turcica on either side being limited by the upper border of the Petrous portion of the Temporal Bone. This Fossa contains the Temporal Lobe and many Foramina through which the vessels and nerves pass.

Optic Foramen for Optic Nerve and Ophthalmic Artery.

Sphenoidal Fissure for Superior Ophthalmic Vein, VIth, IVth and IIIrd and Ophthalmic Division of Vth Nerve.

Foramen Rotundum for 2nd Division of Vth Nerve.

Foramen Ovale for 3rd Division of the Vth Nerve.

Foramen Spinosum for Middle Meningeal Artery.

The Middle Lacerated Foramen is closed by fibro-cartilage, a remnant of the primary cartilaginous skull. The Posterior Fossa contains the Cerebellum and Bulb; its boundaries are the Petrous Bones and the Lateral Sinus. The Facial and Auditory Nerves leave the skull by passing through the Internal Auditory Meatus; the Internal Jugular Vein, Glossopharyngeal, Vagus and Spinal Accessory Nerves by passing through the Jugular Foramen and the Hypoglossal Nerve through the Anterior Condylar Foramen.

When the base of the skull is held up to the light, the bones are seen to vary much in thickness. The stoutest portions are: great wing of Sphenoid, Basisphenoid, Basisocciput and Middle $\frac{1}{3}$ rd of Petrous Bone. The thinnest are: Cribriform Plate, Sella Turcica (because the Sphenoidal Sinuses are beneath), lateral parts of middle fossa, Tegmen Tympani, region over Temporo-maxillary articulation and floor of the Posterior Fossa. Violence, broadly speaking, can only affect the base indirectly in as much as it is everywhere protected by the parts covering it. At a few places only is it exposed to trauma: at the Cribriform plate if foreign bodies are pushed into the Nasal Cavities, at the roof of the orbit if foreign bodies are pushed upwards into the orbital cavity.

The excavated right petrous bone shews the Internal Ear, Cochlea, Internal Auditory Meatus, and 2 Semicircular Canals (the Anterior, Vertical; and the Internal, Horizontal). The 3rd or Posterior Canal is not shewn.

Fig. 15. Base of skull with Arteries, Emerging Nerves and Sinuses of Dura Mater.

The Brain has been cut away layer by layer to preserve the Basal Arteries in position and as much as possible of the Nerves. The Spinal Cord, has not been cut at the level of the 2nd Cervical Nerve as usual, but the Bulb has been divided through the Olivary Body. On the left side, the Tentorium has been removed from the Apex of the Petrous Bone to the Torcular Herophili, the Superior Petrosal and Lateral Sinuses being opened (the right middle meningeal artery has been drawn double by mistake).

The Venous Blood returning from the Brain runs into the Sinuses which are found in the Dura Mater. The Blood from all the Sinuses eventually passes into the Lateral Sinus and thence into the Internal Jugular Vein which commences below the Jugular Foramen.

The most important Sinuses are those which lie against the Skull and are liable to be affected in injury or disease of the bone, especially the Superior Longitudinal Sinus and the Lateral Sinus. Cf. Fig. 1. As the Superior Longitudinal Sinus usually opens into the right Lateral Sinus, this Sinus and the Internal Jugular Vein on the right side are usually larger than on the left.

The Lateral Sinus extends from the Torcular Herophili, (or either side) horizontally outwards (cf. Fig. 17) and then descends behind the Mastoid Process, forming two curves towards the Jugular Foramen. In this last portion of its course it gradually leaves the outer surface of the skull and is hardly liable to injury from without.

The course of the Cranial Nerves from the Brain to their foramina varies; in the Anterior and Middle Fossa the Nerves pass directly to their foramina; but in the Middle Fossa the Vth Nerve runs under the Dura Mater for some distance, when it forms the GASSERIAN Ganglion and divides into its 3 Divisions, which again run separately under the Dura Mater to leave the Skull by the Sphenoidal Fissure, Foramen Rotundum and Foramen Ovale respectively. The IIIrd and IVth Nerves run in the outer wall of the Cavernous Sinus to the Sphenoidal Fissure; the Internal Carotid Artery and the VIth Nerve run in the Cavernous Sinus.

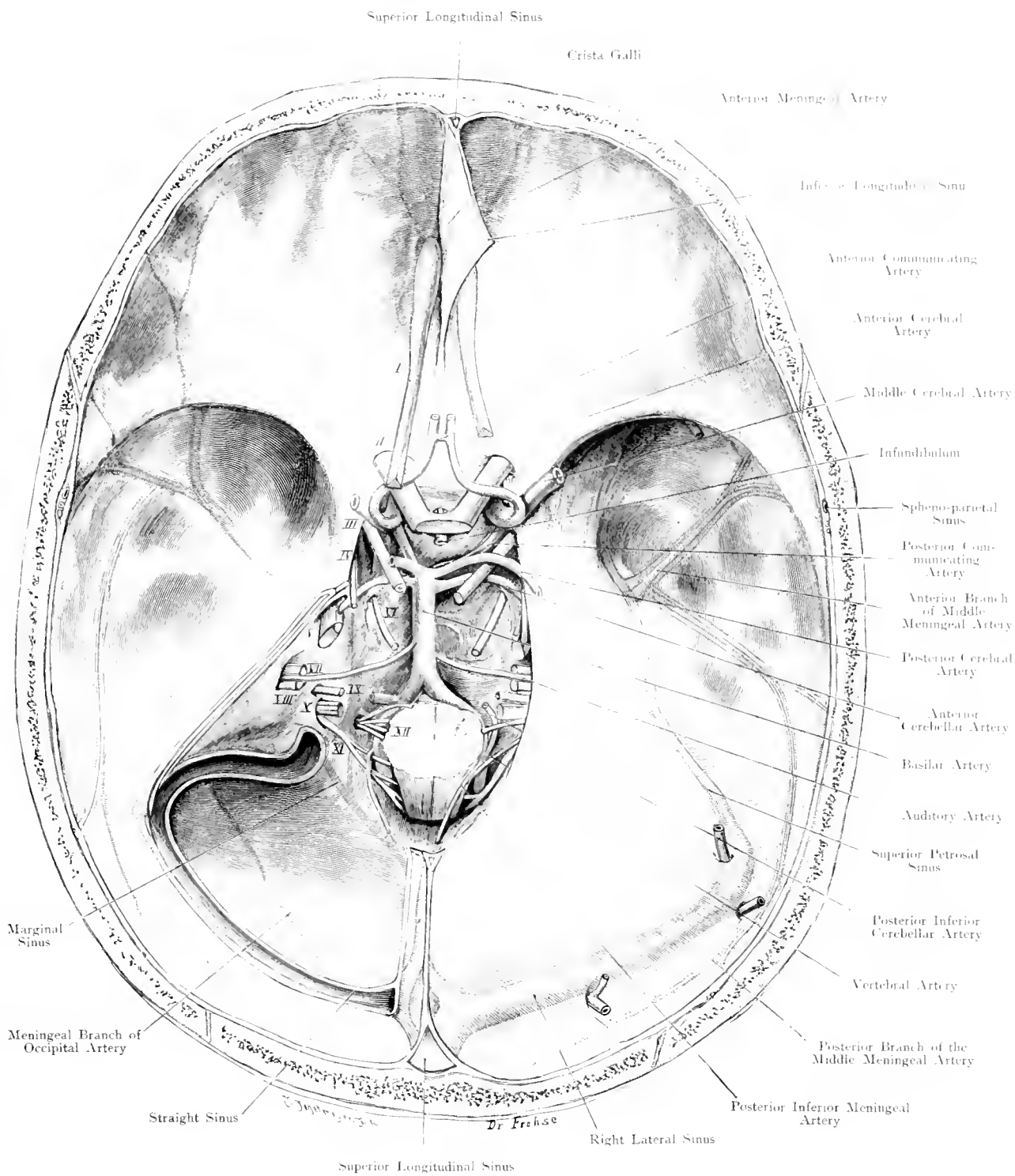


Fig. 15. Base of Skull with Arteries, Emerging Nerves and Sinuses of Dura Mater.
Nat. Size.

Fig. 16. Base of the Skull and Soft Parts after partial removal of the Bones.

This complete fissure is constructed from eight dissections made after hardening in formol and removing various parts of the Brain in successive layers. After decalcifying the bones considerable portions were easily removed by the knife.

On the left side the part of the Occiput forming the Posterior Fossa was removed, the Cavernous Sinus opened and the GASSERIAN Ganglion with its three divisions dissected out. The roof of the Orbit was removed and the structures occupying the upper part of this cavity exposed to view. By cutting away the Cribriform Plate of the Ethmoid, the Accessory Sinuses of the Nasal Cavity were opened up — Mucous Membrane is coloured pink.

On the right side a more extensive area of the base of the Skull has been removed, only a few thin bars being left (Tympanic Cavity pink, Membranous part of Meatus brown). In the lower part of the Orbital Cavity, — the eye-ball having been cut across horizontally and supposed to be transparent, — all the structures including the nerves and muscles are shewn.

The Nerves of the Special Senses are green (Optic Nerve light green; Auditory Nerve and apparatus, dark green).

Sensory Nerves, yellow. Motor, dark blue (Veins being light blue), so that the Motor Root of the Vth Nerve is definitely shewn.

The Vagus Group IX, X, XI, being mixed nerves, are yellow, like the sensory. GASSERIAN, Ciliary and Geniculate Ganglia are orange; on the left, the air-cells of the Auditory apparatus, the EUSTACHIAN Tube and the unusually large Lateral Recess of the Sphenoidal Sinuses extending into the greater wings of the Bone are projected upwards (pink).

This figure — probably the first of this kind — gives, by shewing the vessels and muscles under the base of the Skull in their natural position, an idea of the Topography of this region unattainable from below because in this manner their relations remain undisturbed by dissection.

The figure shews the topographical relations of the 3 great organs of special sense: e. g. Eye, Ear and Nose, moreover, it gives a good view of the course of the Nerves which have a primary intra-, and a subsequent extra-cranial course.

Lastly connections are exhibited which could scarcely be appreciated by other methods.

Fig. 17. Projection of Lateral Ventricle, Middle Ear and Lateral Sinus on the outer surface of the Skull.

To SPITZKA'S figure which shews the projection of the Lateral Ventricle on to the outer region of the Skull, we have added the projection of the Lateral Sinus (violet) and of the Middle Ear with its Accessory Cavities (red) while retaining our own Specimens and the indications by FRIEDRICH MÜLLER.

Puncture of the Lateral Ventricle is performed (a) to empty it of accumulated fluid (Hydrocephalus, Serous Meningitis etc.), or (b) to inject drugs into the Ventricle when not dilated (e. g. Tetanus).

VON BERGMANN trephines the Skull in front, directly above and mesial to the Frontal Eminence and pushes a long hollow needle in a slightly downward and inward direction.

KEEN finds a point on the outer surface of the Skull 31 mm. above a line connecting the lower border of the Orbit with the External Occipital Protuberance and 32 mm. behind the External Auditory Meatus.

The shape of the Lateral Ventricle does not vary much except in the Posterior Horn. The "Trigone" i. e. where the Body, the Posterior and Descending Horns meet, is the largest part and consequently the most suitable for the operation.

Fig. 18. Projection of the Middle Meningeal Artery on the outer surface of the Skull.

After KRÖNLEIN. The Middle Meningeal Artery is red.

To determine certain important Cerebral points and lines, as well as the Middle Meningeal Artery, KRÖNLEIN's landmarks are the most convenient.

1) The "German Horizontal Line" runs through the Infra-Orbital margin, and the upper border of the External Auditory Meatus. 2) The "Upper Horizontal Line" runs through the Supra-Orbital margin, parallel with the former. 3) The "Anterior Vertical Line" passes upward from the middle of the Zygoma at right angles to 1). 4) The "Middle Vertical Line" passes from the Condyle of the Lower Jaw at right angles to 1). 5) The "Posterior Vertical Line" from the posterior margin of the Base of the Mastoid Process at right angles to 1).

A line connecting (a) the point where the "Anterior Vertical Line" and the upper Horizontal Line cross each other with (b) the point where the "Posterior Vertical Line" cuts the Vertex, represents the Central Fissure (ROLANDI). When the angle formed by this line and the upper Horizontal line is bisected by a line drawn to meet the posterior vertical line, the oblique line represents the Fissure of SYLVIIUS.

A and B are the points for trephining to evacuate the blood extravasated from a ruptured Middle Meningeal Artery.

The square marked in thick lines is the region in which VON BERGMANN resects the Skull cap for drainage of Otitic Abscess and Abscess of the Temporal Lobe.

The Black Circles indicate the following points which are often made use of (cf. Text Figs. 11 and 12):

Nasion at root of Nose. Bregma at Vertex; further back, Obelion, Lambda; and Inion at the External Occipital Protuberance.

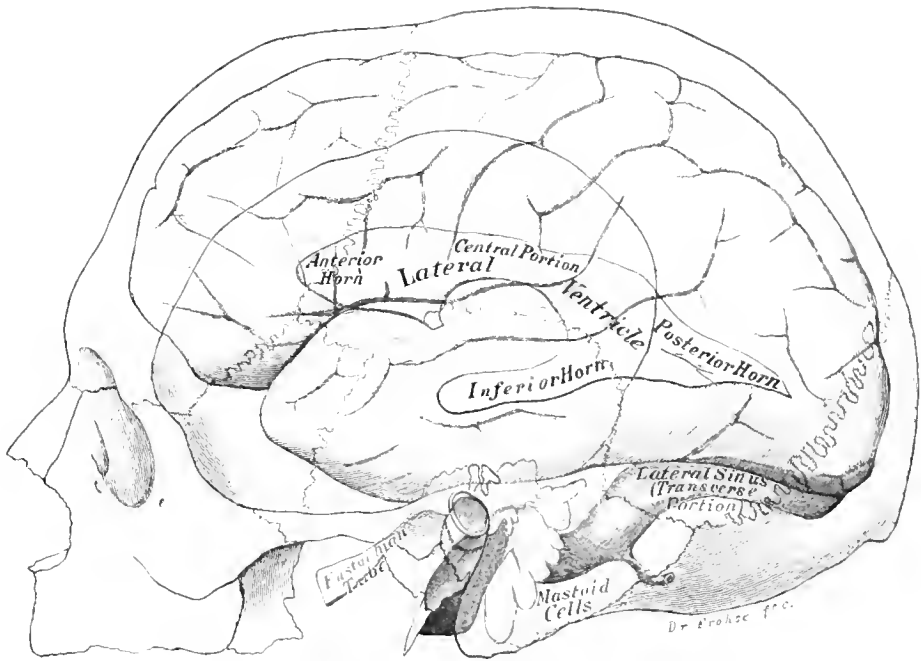


Fig. 17. Projection of Lateral Ventricle, Middle Ear and Lateral Sinus on to the Outer Surface of the Skull.
 $\frac{1}{4}$ Nat. Size.

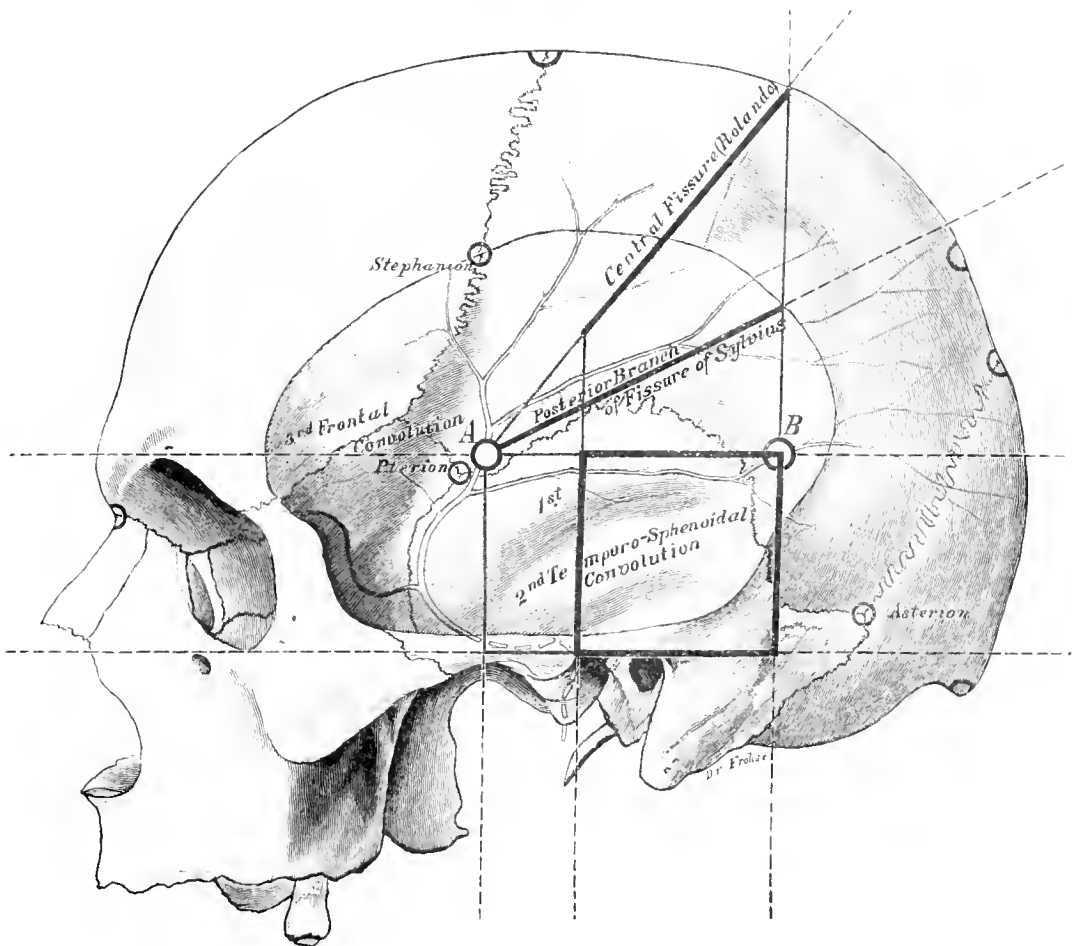


Fig. 18. Projection of Middle Meningeal Artery on to the Outer Surface of the Skull.
 $\frac{3}{4}$ Nat. Size.

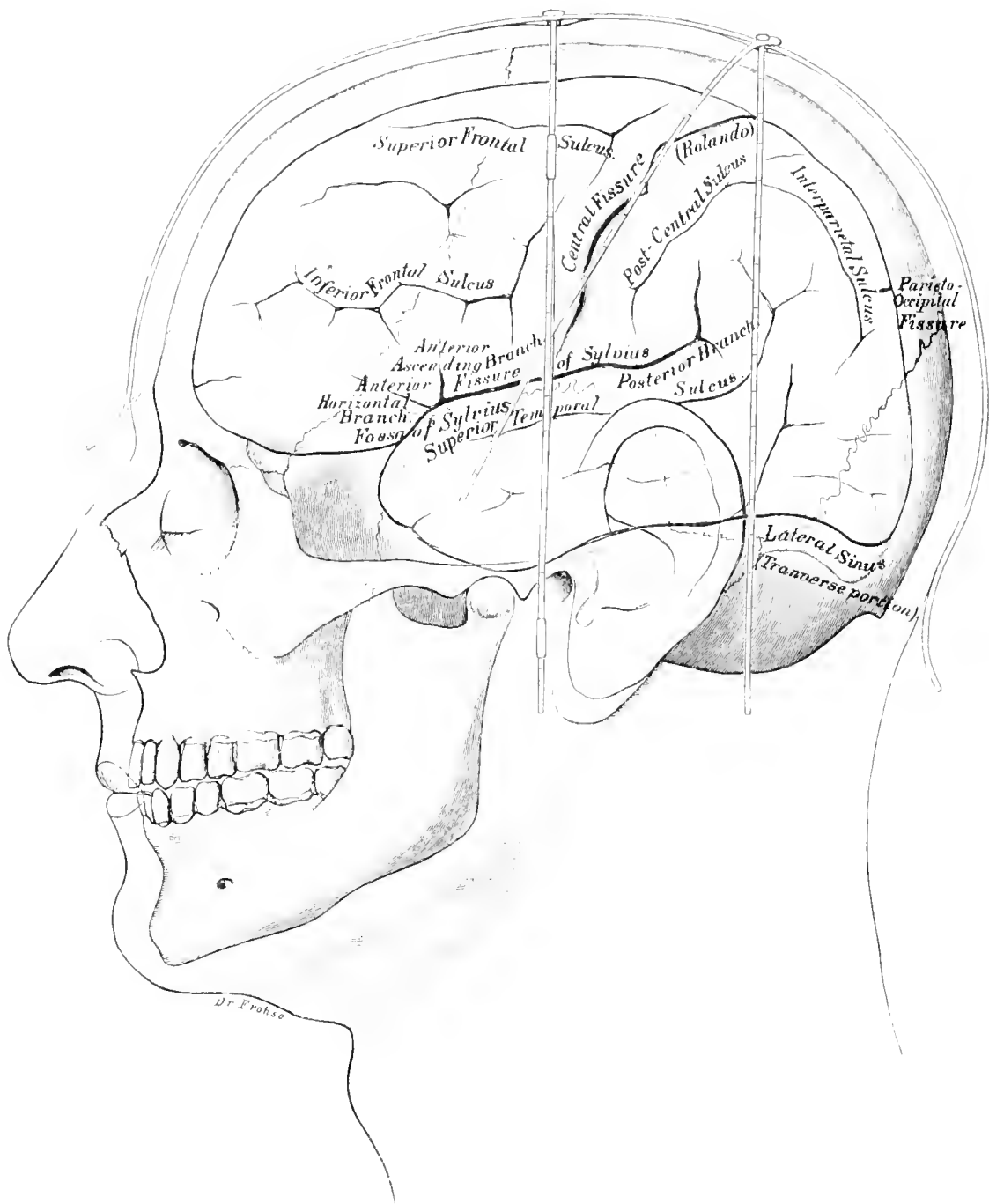


Fig. 19. Cranio-Cerebral Topography.

$\frac{4}{5}$ Nat. Size.

Fig. 19. Cranio-Cerebral Topography.

The bars of A. KOEHLER'S "Cranioencephalometer" are dark red; Brain pink, diagrammatic.

For practical purposes it is very important to know the surface markings for the different parts of the hemisphere. By such knowledge a diagnosis can be made of: "Which cortical region is affected in any particular injury of the Skull?" On the other hand, functional disturbances may indicate disease of a certain part of the Cortex which may require operation; by this knowledge of surface markings the surgeon is enabled to find the seat of the lesion.

Generally speaking it is sufficient to determine the position of the Fissures of ROLANDO and SYLVIVS because the most important centres are situated in the neighbourhood of these fissures (cf. Fig. 3, 5) further with these landmarks other sulci and fissures can be easily marked out.

Many methods have been devised, some requiring special instruments. KOEHLER'S method is simple and reliable.

Cf. Fig. Three lines are necessary.

1. A Sagittal line extending from the root of the nose to the External Occipital Protuberance.
2. A Vertical line through the Anterior Border of the External Auditory Meatus.
3. A second Vertical line parallel to the former through the Posterior Border of the Mastoid Process.

From the point where the last mentioned line meets the Sagittal line another line is drawn downwards and forwards to a point situated midway between the junction of the middle with the lower thirds and the mid-point of the first Vertical Line.

This point corresponds to the lower end of the ROLANDIC Fissure, the upper end of which lies at the junction of the line drawn from the Sagittal Line.

The Fissure of SYLVIVS lies $\frac{1}{2}$ inch below the inferior end of the Fissure of ROLANDO. About $2\frac{1}{2}$ inches above the Zygoma the Short Anterior and Long Posterior Limbs of this fissure begin. Another excellent method of marking out the Fissures of ROLANDO and SYLVIVS, devised by KROENLEIN, is described in Fig. 18.

Fig. 20. Exposure of the Cerebellum.

On the left side an incision has been made from the External Occipital Protuberance horizontally outwards as far as the Ear. From either extremity vertical incisions have been made downwards and the muscle-skin flap thrown downwards. The muscles were subsequently dissected out. A large window was chiselled out of the Bone. The Lateral Sinus has been slit open, the Cerebellum is kept inwards by a broad spatula.

The Cerebellum is much more protected than the Cerebrum. Only a very small surface area comes in contact with the Bone in a region well protected by thick muscles.

Injury to the Cerebellum is accordingly very rare, but operations in this part are far more difficult owing to its position. A glance at the figure shews that suppuration of middle-ear origin may extend from the Lateral Sinus, Posterior Semicircular Canal or Saccus Endolymphaticus and so give rise to an abscess between the posterior surface of the Petrous portion of the Temporal Bone and the Cerebellum or to a Cerebellar Abscess.

These purulent collections may be evacuated by an enlargement of the opening made for the exposure of the Lateral Sinus, backwards. If a Temporal abscess has been looked for by opening the skull in VON BERGMANN'S Rectangular Area (cf. Fig. 18) then further procedure entails enlargement of the osseous opening and incision of the Tentorium Cerebelli in order to compare the superior aspect of the Cerebellum.

A large opening is necessary for Cerebellar Tumours. When the Lateral Sinus gets in the operator's way, he should push the Dura Mater away from the Bone ligature the Sinus with a double ligature and divide it. Upon the further removal of bone the Cerebellum can be well exposed.

We desire to draw particular attention to a vein which runs from the lowest part of the Lateral Sinus or from the Jugular Bulb to the Vertebral Vein through the Posterior Condylar Foramen. Its further course is horizontal between the Occipital Bone and the Atlas.

The vein is of great importance in Ligature of the Internal Jugular in cases of Thrombophlebitis of the Lateral Sinus. Cf. Figs. 27 and 28.

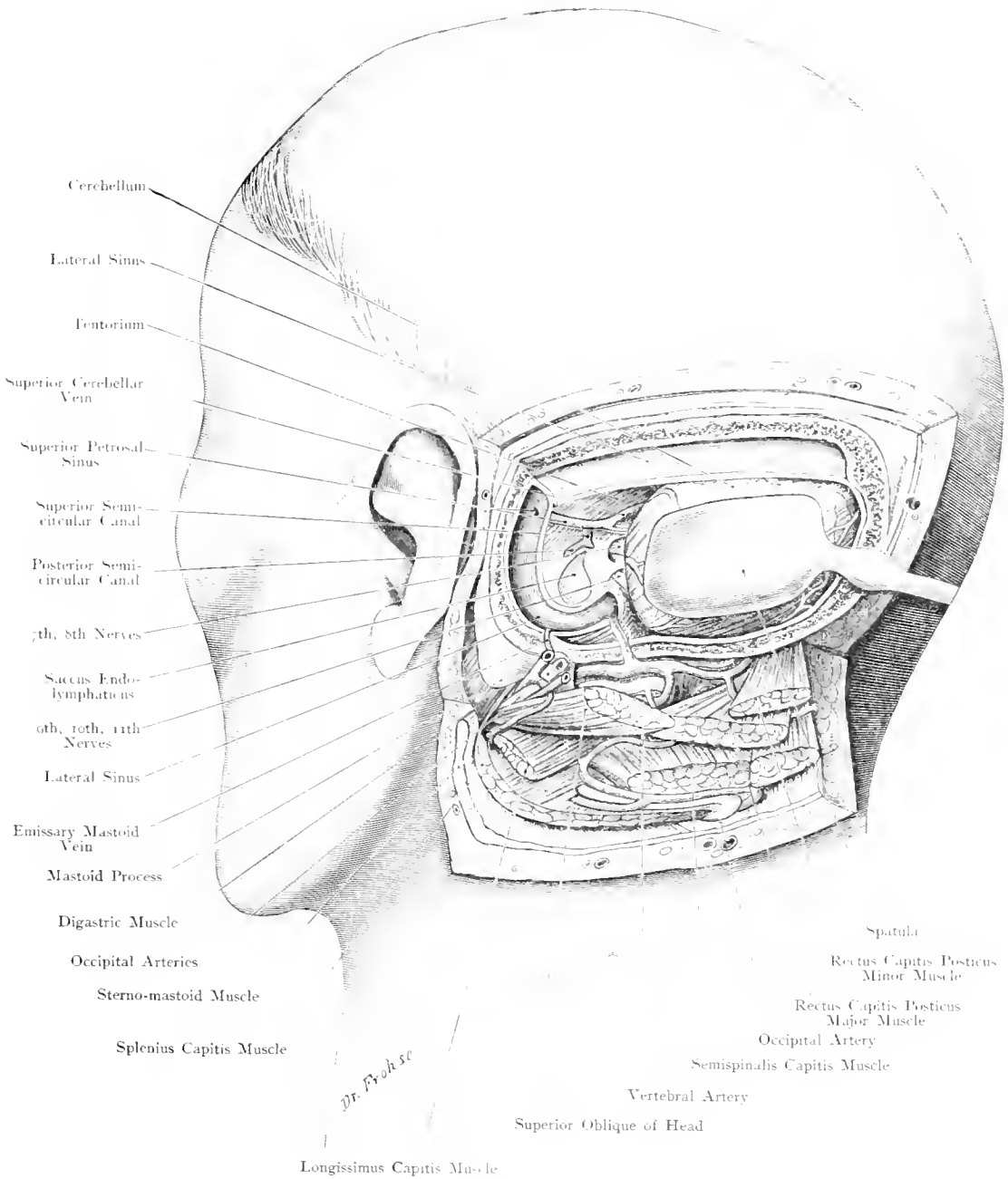


Fig. 20. Exposure of the Cerebellum.

$\frac{1}{5}$ Nat. Size.

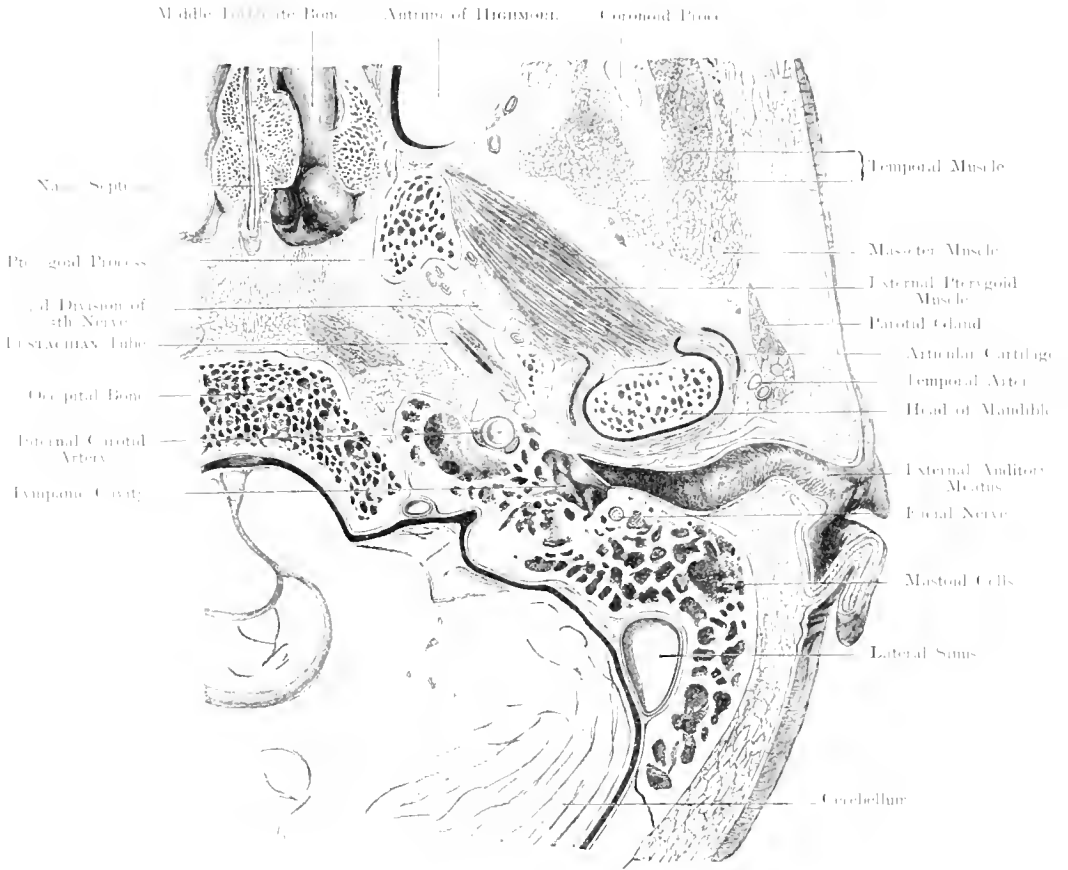


Fig. 21. Horizontal Section of the Head. Organ of Hearing and surrounding Parts. Left side, viewed from below. — Nat. Size.

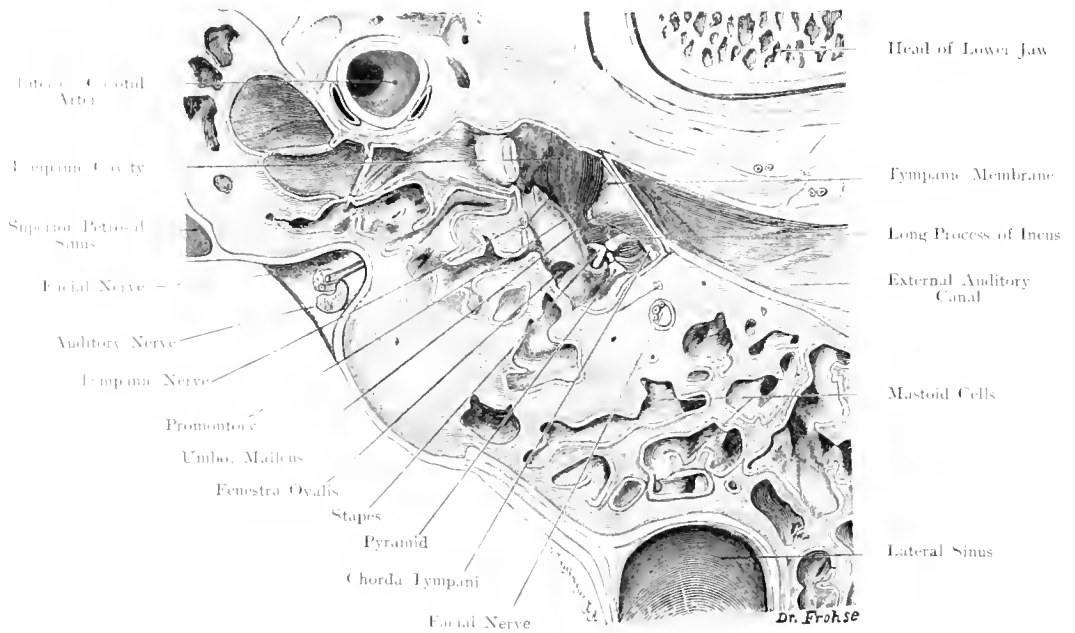


Fig. 22. Part of Fig. 21: Tympanic Cavity and surrounding Parts. $\times 2\frac{1}{2}$.

Fig. 21. Horizontal Section of the Head: Organ of Hearing and Surrounding Parts.

Fig. 22. Tympanic Cavity and Surrounding Parts.

× 2½.

Part of a frozen section from a series of Horizontal sections through the Head.

The two curves described by the External Auditory Canal in the Horizontal plane are well shewn: a 3rd curve is recognisable in the Vertical plane, so that it is not possible to distinctly see the Tympanic Membrane without traction upon the Cartilaginous portion of the Ear.

From the practical point of view the relations which the Auditory Apparatus bears to neighbouring structures and especially to the Lateral Sinus and Dura Mater are most important.

The Dura Mater which covers the posterior aspect of the Petrous Bone is only separated from the numerous air-cells by a thin lamina of bone, so that pus within these cells may easily give rise to a subdural abscess. The Lateral Sinus bears a similar relation to the Mastoid Process so that injury to it may result during operations upon the Mastoid; pus within the Mastoid Cells may extend to the Lateral Sinus and produce Thrombophlebitis.

Around the Internal Carotid Artery which incompletely fills the Carotid Canal, are Venous Spaces, continuations of the Cavernous Sinus. The Facial Nerve is seen cut across in its vertical course to the Stylomastoid Foramen. In the Facial Canal accompanying the Facial Nerve (Fig. 22) are shewn the Stylomastoid Artery with its 2 Venae Comites. In Fig. 22 are further shewn the structures in the Tympanic Cavity: Ear-ossicles, Chorda Tympani and Tympanic Nerve. The EUSTACHIAN Tube, extending obliquely forwards, inwards and downwards from the Tympanic Cavity to open into the Pharynx has been divided obliquely so that it appears larger than if it had been cut transversely to its axis. Between the Condyle of the Lower Jaw and the External Auditory Meatus there is only a very thin layer of bone. The Articular Fibrocartilage is seen almost completely surrounding the Condyle. Internal to the External Pterygoid Muscle is seen the 3rd Division of the Vth Nerve directly after its emergence through the Foramen Ovale; behind and to its outer side is the Middle Meningeal Artery.

The Lymphoid Tissue beneath the Pharyngeal Mucous Membrane — the Pharyngeal Tonsil — which appears very large in a horizontal section deserves notice. This has been cut obliquely because the upper wall of the Pharynx is not horizontal but directed obliquely backwards and downwards.

Fig. 23. Vertical Section through the Left Temporal Bone in the plane of the Axis of the Petrous Portion.

Frozen Section. Mucous Membrane of Tympanic Cavity, Antrum and Mastoid Cells in red. The lower part of the Tympanic Cavity has been carried away in the section so that the External Auditory Canal is exposed.

Fig. 24. Horizontal Section through the Left Temporal Bone.

Section through a macerated bone. The axis of the Mucous Membrane lining the EUSTACHIAN Tube and the Mastoid Antrum is indicated by a red line. The axis through the External and Internal Auditory Meatus, "Sensory Axis", is indicated by a yellow line. The Cartilage of the Temporo-Mandibular Articulation is coloured blue.

The middle ear is surrounded by numerous air-cells which are lined by a continuation of the same mucous membrane and communicate directly or indirectly with the Tympanic Cavity. Pus spreads readily from the Tympanic Cavity to these Accessory Cells. Fig. 23 shews how the cells lie below the plane of the opening into the Tympanic Cavity and consequently drainage is very efficient. The size of these air-cells varies not only on the same side but on either side in the same individual. These cells may extend far into the Petrous Bone, even into the Occipital Condyle and the root of the Zygoma. The chief Accessory Cavity is the Mastoid Antrum (as large as a French Bean) with its long axis ($\frac{2}{5}$ th inch) corresponding to the axis of the EUSTACHIAN Tube and opens into the Tympanic Cavity on the posterior wall, directly below the Tegmen Tympani which forms the roof of the Antrum. The Mastoid Cells, which vary considerably in number, either few or large, numerous or small open into the Antrum. The cells extending into the Squamous Portion are known as Squamosal Cells, but these never extend higher than the temporal ridge. The lamina of bone covering the Mastoid Process is so variable in thickness that, like the Tegmen it is deficient at some points on its outer wall as well as on its inner wall, which is in relation to the Lateral Sinus. These points of deficiency are merely covered by connective tissue.

Pus can spread easily through the thin Tegmen Tympani and cause Meningitis or a Temporal Abscess. Fig. 23 shews the Vth Cranial Nerve in MECKEL'S Cavity, i. e. the depression on the superior surface of the Petrous Bone covered in by Dura Mater.

In Fig. 24 the red line indicates the "mucous membrane axis", i. e. EUSTACHIAN Tube, Tympanic Cavity, Antrum and Mastoid Cells on a line which runs backwards and outwards.

The yellow line is the "sensory axis" which passes through the External Auditory Meatus, Tympanic Membrane and Cavity, Vestibule and Internal Auditory Meatus. These axes cross in the Tympanic Cavity; the first passes through all organs of accessory importance for hearing; the second passes through the organs of hearing proper.

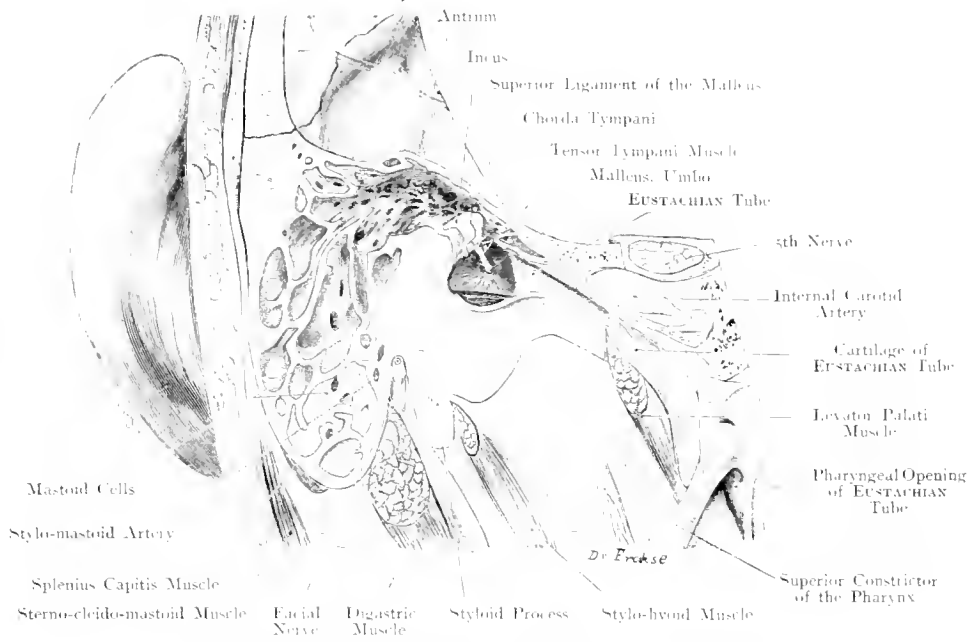


Fig. 23. Vertical Section through left Temporal Bone in the plane of the axis of the Petrous Portion.
 Seen from behind. — Nat. Size.

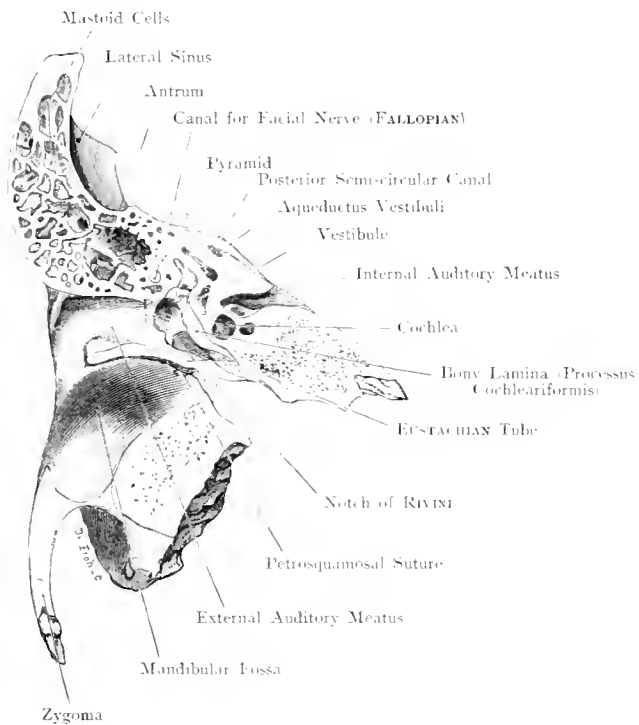


Fig. 24. Horizontal Section through the Left Temporal Bone.
 Seen from below. — Nat. Size.

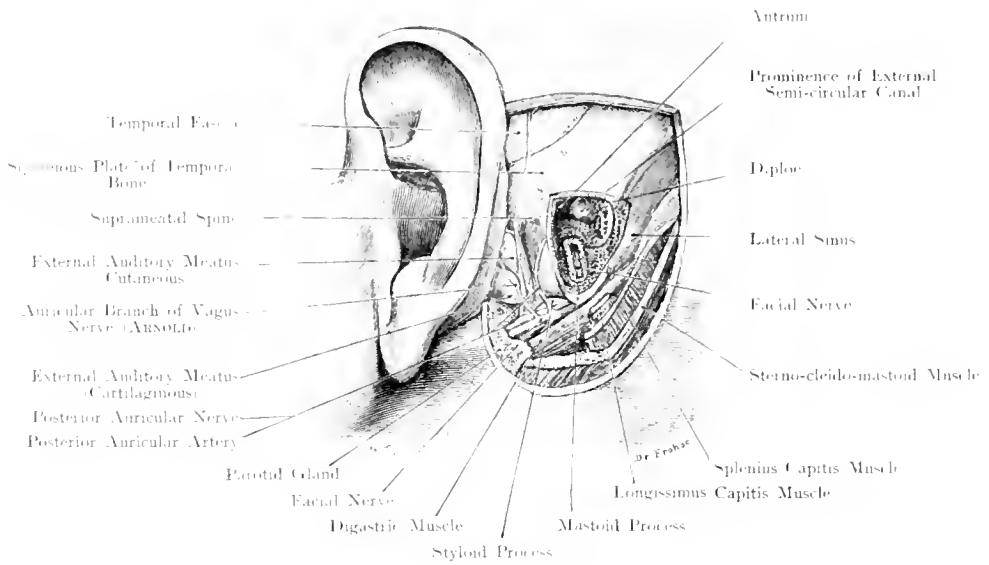


Fig. 25. Mastoid Process of Child opened.
 Nat. Size.

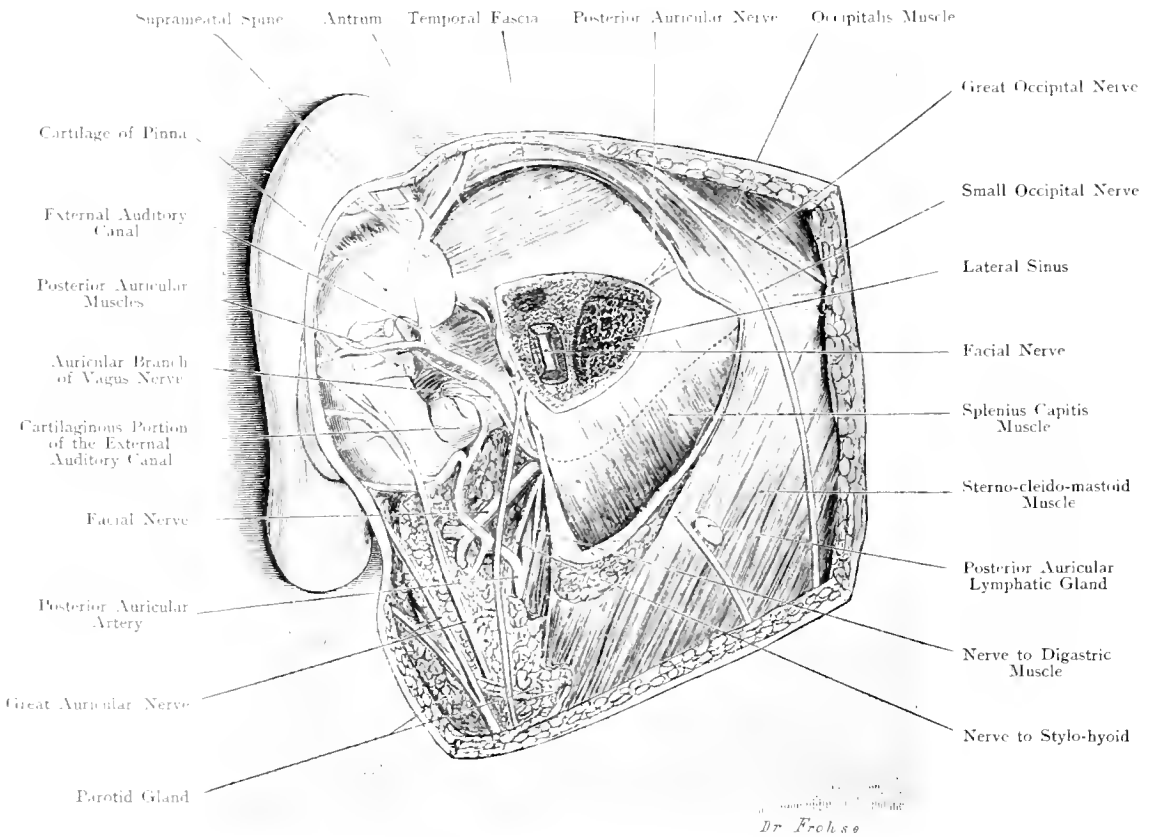


Fig. 26. Mastoid Process of Adult opened.
 Nat. Size.

Fig. 25. Mastoid Process of Child, opened.

Fig. 26. Mastoid Process in Adult, opened.

Fig. 25. The various layers of the Mastoid region in a child, aged two years, have been exposed, and the Mastoid Process chiselled open. Air-cells, red. - In Fig. 26 the Mastoid region of an adult has been more extensively dissected but only that portion of the Mastoid Process containing air-cells has been opened by chisel. The periphery of the Mastoid Process is indicated by a dotted line. By removal of a portion of the Parotid Gland the Facial Nerve has been exhibited as it emerges from the Stylomastoid Foramen.

The Antrum is well marked in the New-Born though the Mastoid Process is scarcely discernible; its posterior and external portion becoming formed during the first years of life; it grows downwards as the formation of air-cells slowly progresses. Even in the adult there are not necessarily any air-cells at the tip of the Mastoid Process. The Facial Nerve after emerging from the Stylomastoid Foramen runs forward at a right angle in the infant, at an obtuse angle in the adult.

The groove of the Lateral Sinus is shallow in the child, deep in the adult. The Antrum and Mastoid Cells are easily accessible for operative purposes from the outer surface of the Mastoid Process. Subcutaneously in the angle between the Pinna and the Skull the Posterior Auricular Artery takes its course. The Periosteum is intimately connected with the tendinous fibres of origin of the Sternocleidomastoid Muscle which gradually become lost in the Temporal Fascia. About $\frac{2}{5}$ th inch behind the Suprameatal Spine is situated the Antrum at a depth of $\frac{2}{5}$ th of an inch from the surface. Below this are the Mastoid Cells.

The structures in relation with the Antrum are of great importance.

The thin Tegmen Tympani alone separates the Antrum from the Cranial Cavity, so that search for an Epidural or Temporal Abscess is easy after perforation of the Tegmen Tympani. If projected on to the surface the floor of the middle Fossa of the Skull lies in the region of the attachment of the pinna either above or on the level of the Temporal line. Posteriorly and internally is the Lateral Sinus which should be avoided when the air-cells are opened. The position of the Lateral Sinus varies, it may lie in a shallow groove on the Mastoid Process, or in a deep furrow in both Mastoid and Petrous portions.

According to BEZOLD the most marked outward curve of the Sinus is $\frac{3}{5}$ inch behind the Suprameatal Spine. At this point the bone is usually 0.3 inch thick (0.1 to 0.7). The Facial Nerve may be injured as it lies below the External Semicircular Canal on the inner wall of the Tympanic Cavity close to the opening into the Antrum (Aditus ad Antrum). The wall of the Facial Canal is very thin so that by a careless use of the chisel this nerve may be divided.

Lower down the Mastoid Cells are in relation with the Facial Canal: this portion has been laid free in both figures.

Fig. 27 and 28. Tympanic Cavity and Surrounding Parts opened from behind.

In Fig. 27, the outer wall of the Mastoid Process, Antrum and Attic have been removed, the Mastoid Cells gouged out so that only the inner wall of the Mastoid Process remains: Facial Nerve, Posterior and External Semicircular Canals and Lateral Sinus are still covered by bone. Facial Nerve and Semicircular Canals (yellow) are represented as showing through the bone.

In Fig. 28, the skin incision has been extended downwards, the tip of the Mastoid Process removed, the Digastric Muscle divided and the Attic more freely exposed, the Facial Canal opened, the bony wall of the Sinus removed and the Saccus Endolymphaticus exposed.

The Posterior portion of the Tympanic Membrane, the Posterior and Superior wall of the Bony External Auditory Canal have been removed and the skin which lines this portion slit open. The bar of bone behind the Stylo-mastoid Foramen has been sawn through in order to expose the Jugular Bulb. These figures give the relations which are of importance in radical operations.

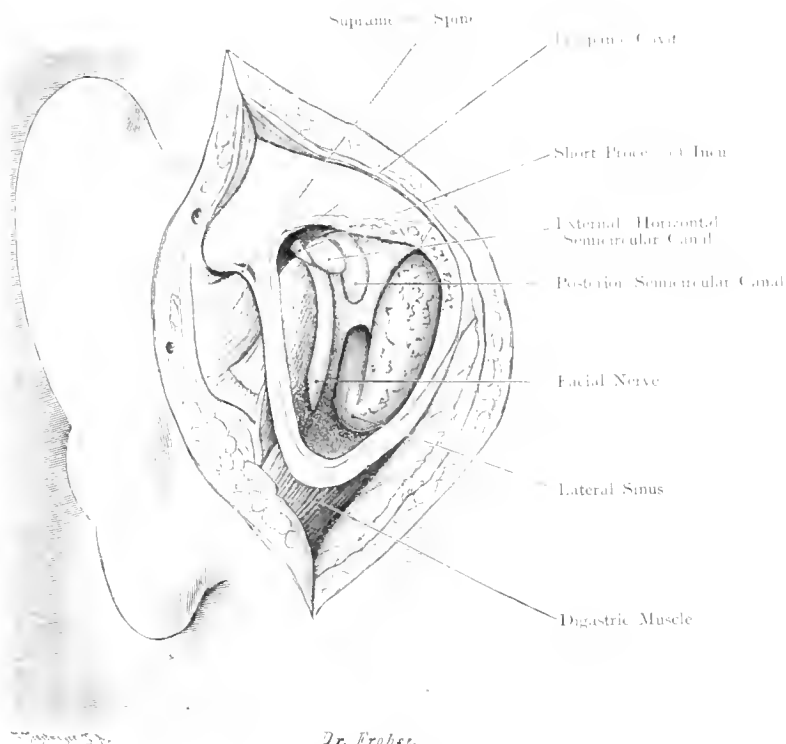
In cases of chronic suppuration and Cholesteomata of the Middle Ear, it is important to expose all the cavities by removing their outer wall and bony septa so that the inner wall of the Tympanic Cavity, Antrum and Mastoid becomes continuous with the Inferior and Anterior Wall of the External Auditory Canal. The bony canal for the Facial Nerve, the External Semicircular Canal and the Stapes must be carefully avoided. The black area below the Incus represents the Fenestra Rotunda.

Fig. 28 shews the whole of the oblique part of the Lateral Sinus to its termination in the Jugular Bulb. After reaching the Temporal Bone its direction changes vertically downwards, embedded to varying depths in the inner wall of the Mastoid Process, thence its course is at first horizontally inwards (occasionally with a sharp upward curve), then directly downwards to pass through the Jugular Foramen and form the Jugular Bulb. Suppurative Thrombo-phlebitis usually affects this last vertical portion, in many such cases the Sinus must be opened throughout its whole length.

Many ways may be employed to expose the Jugular Bulb: GRUNERT removes the tip of the Mastoid Process and proceeds towards the Jugular Foramen at the base of the skull where he divides the bone encircling it. As shewn in the figure the Facial Nerve is in the way. PANSE therefore recommends that the nerve be freed and drawn forward. If the Transverse Process of the Atlas is in the way it should be carefully removed, avoiding any injury to the Vertebral Artery. Owing to anatomical variations, this may be impossible so that GRUNERT's method (as practiced by PIFFL), of removing the floor of the Auditory Meatus and Tympanic Ring, under which the Jugular Bulb lies, may be necessary. (Cf. Fig. 17.)

By this method the Facial Nerve lies behind the field of operation; the structure to be avoided in front is the Internal Carotid Artery. Will ligature of the Internal Jugular Vein in Septic Thrombophlebitis prevent the spread of infection?

This question demands a consideration of the many Venous Channels which open into the Lateral Sinus (Superior Petrosal Sinus, Figs. 15, 16, 20), Mastoid Emissary Vein (Figs. 20 and 28), Posterior Condylar Emissary Vein (Fig. 20), Marginal Sinus (Fig. 15), Inferior Petrosal Sinus (Fig. 15), Anterior Condylar Vein which accompanies the Hypoglossal Nerve and passes to the Jugular Bulb from the Vertebral Plexus. The figure shews the close proximity of Facial and Spinal Accessory Nerves so that in cases of Facial Paralysis the Surgeon may be tempted to suture the central portion of the Spinal Accessory to the Peripheral portion of the Facial Nerve.



Dr. Erohee.

Fig. 27. Superficial Layer.

Malleus

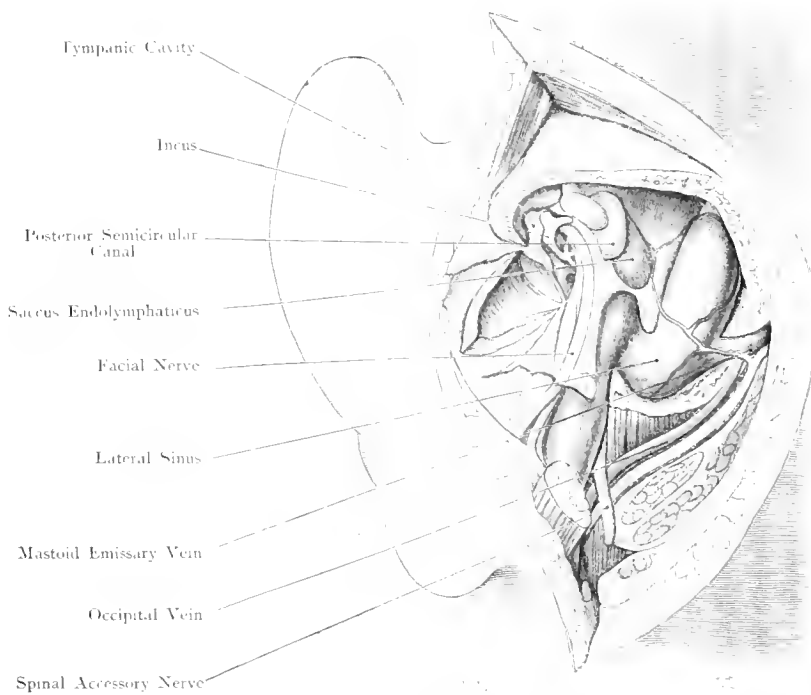


Fig. 28. Deep Layer.

Figs. 27 and 28. Tympanic Cavity and surrounding Parts opened from behind.

Nat. Size.

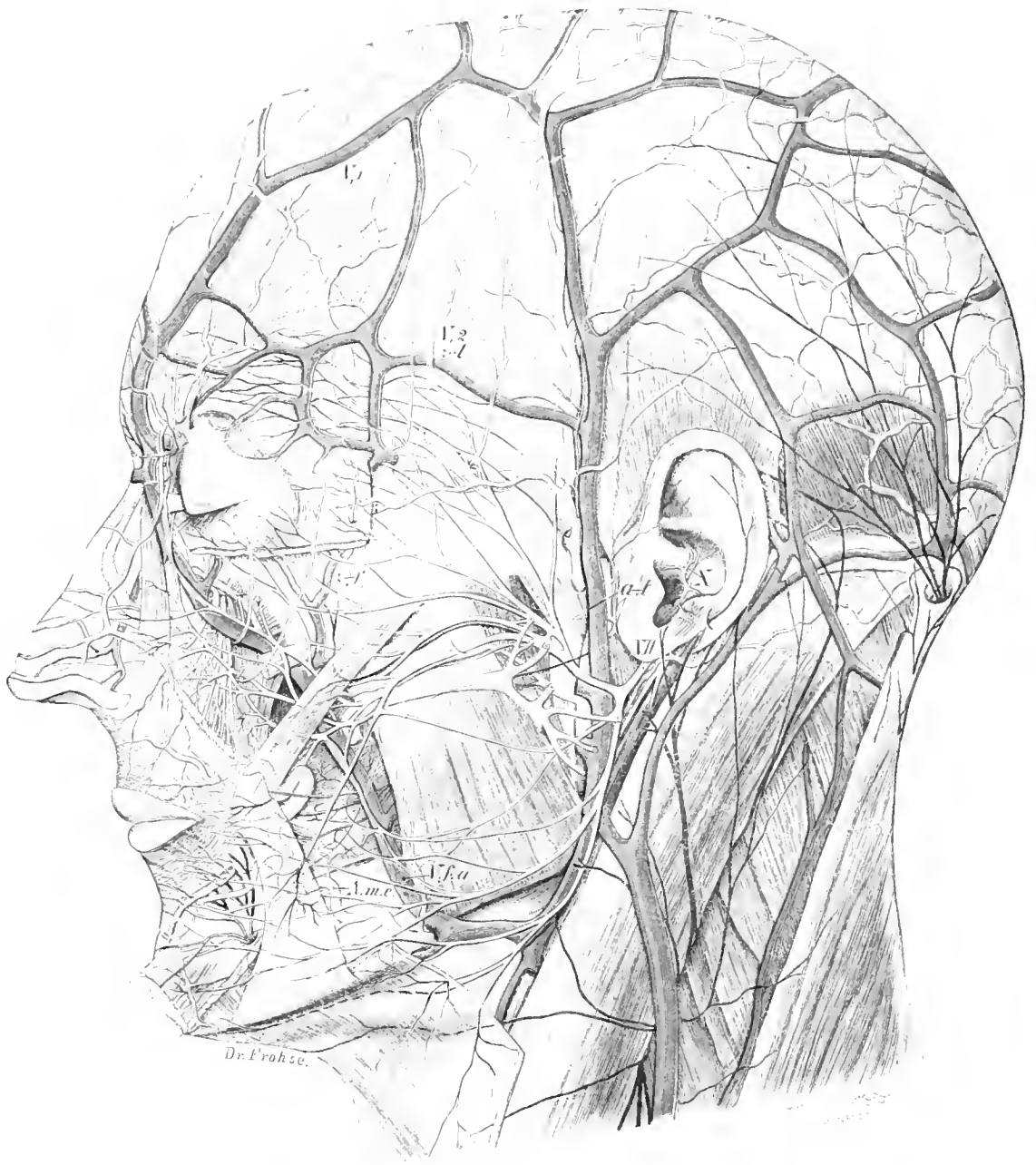


Fig. 29. Superficial Vessels and Nerves of the Head.

2/3 Nat. Size.

Fig. 29. Superficial Vessels and Nerves of the Head.

Skin, Parotid Gland, portion of the Orbicularis Palpebrarum and Square Muscle of the Upper Lip (Quadratus Labii Superioris), have been removed. The Superficial Arteries, Veins, Nerves and Muscles have been exposed by dissection.

Light red, Arteries. Passing upward over the lower jaw is the Facial Artery which shews through the Muscles as it is covered by them: in front of the Ear the Temporal Artery gives off the Transverse Facial Artery. At the upper border of the Orbit the Frontal Artery (a branch of the Ophthalmic Artery which comes off the Internal Carotid) is seen and at the back is the Occipital Artery.

Violet, Veins. The Facial Vein (anastomosing, at the Naso-frontal Angle, with the Frontal Vein and indirectly with the Intracranial Venous System) is seen communicating with the Temporal Vein which lies in front of the Pinna. Posteriorly the Occipital Vein is seen.

The Facial Nerve and its branches are white. (Cf. Figs. 33—38.)

The other nerves are coloured in accordance with their area of distribution. (Cf. Figs. 33—38.)

Dark red — Ophthalmic Division of Vth Nerve. (I', 1).

Yellow — Superior Maxillary Division of Vth Nerve (I', 2). (*z-t* indicates Zygomatico-Temporal, and *z-f* Temporal-Facial Branches).

Blue — Inferior Maxillary Division of Vth Nerve (I', 3). This gives off the Auriculo-Temporal Nerve (*a-l*) before the Inferior Dental enters its Foramen.

Orange — Auricular Branches of Vagus (X) to the Pinna (ARNOLD).

Black — Cervical Nerves: Great Auricular, Great and Small Occipital and Superficial Cervical Nerves.

The Duct of the Parotid Gland (STENSON'S Duct) and its small tributaries are coloured light brown.

Fig. 30. Side View of Face. Superficial Layer.

The Parotid Region has been dissected on the Left Side and a window made in the Parotid Gland to show the formation of STENSON'S Duct, Branches of the Facial Nerve and the main vessels (all very carefully dissected).

Broadly speaking the Vessels and Nerves of the Face are subcutaneous with the exception of the area covered by the Parotid Gland.

The Parotid Gland is covered by a thick fascia; its outer surface is triangular in shape with the base directed upwards and the Apex at the angle of the Lower Jaw. The base extends from the posterior extremity of the Zygoma to the Cartilaginous portion of the External Auditory Canal and to the Anterior border of the Sternomastoid Muscle. The posterior border runs parallel to the Sternomastoid Muscle; at the angle of the Jaw, this is met by the Anterior border which crosses the Masseter Muscle. The greater part of the Gland lies behind the Ramus of the Jaw and extends inwards to the Digastric (i. e. close to the Carotid and Jugular Vessels Fig. 53). STENSON'S Duct runs almost horizontally forwards $\frac{2}{5}$ th inch below the Zygoma and turns inwards at the Anterior border of the Masseter to perforate the Buccinator obliquely and terminate within the Buccal Cavity opposite the 2nd upper molar tooth (cf. Fig. 57). There is often present an Accessory Parotid (Socia Parotidis) attached to the Duct (cf. Fig. 30).

The Facial Nerve bears a close relation to the Gland. After emerging out of the Stylomastoid Foramen this nerve enters the substance of the Gland at the level of the lobule of the Ear. Here it divides, and its branches run in the substance of the gland, to emerge at the Anterior border and be distributed to all the muscles of Facial Expression. Consequently it is impossible to remove the whole of the Parotid Gland without injury to the Facial Nerve, but removal of the lower part in no way leads to interference with the Nerve; in this case the Mandibular Branch, which supplies the muscles of the angle of the mouth, is chiefly damaged. The branches of the Facial Nerve form an anastomosis with each other (Pes Anserina) and with the Fifth.

The Auriculo-Temporal Nerve (from I, 3) runs through the Parotid Gland as well as the Superficial Temporal Artery (continuation of External Carotid Artery); this vessel in its course through the gland gives off the Transverse Facial Artery which takes a horizontal course. The Superficial Temporal Artery then passes upwards in front of the ear dividing into an Anterior (Frontal) and a Posterior (Parietal) branch to supply the Frontal and Parietal Regions of the Scalp as far as the Vertex. The Temporal Vein, accompanying the Artery, receives blood from the Temporal Region and the Ear. In the substance of the Parotid Gland are embedded a few lymphatic glands which are of practical importance; rarely, a cutaneous lymphatic gland, superficial to the Parotid, is found.

Temporo-Facial Branches
of Facial Nerve

Auriculo-Temporal
Nerve

Superficial Temporal Artery

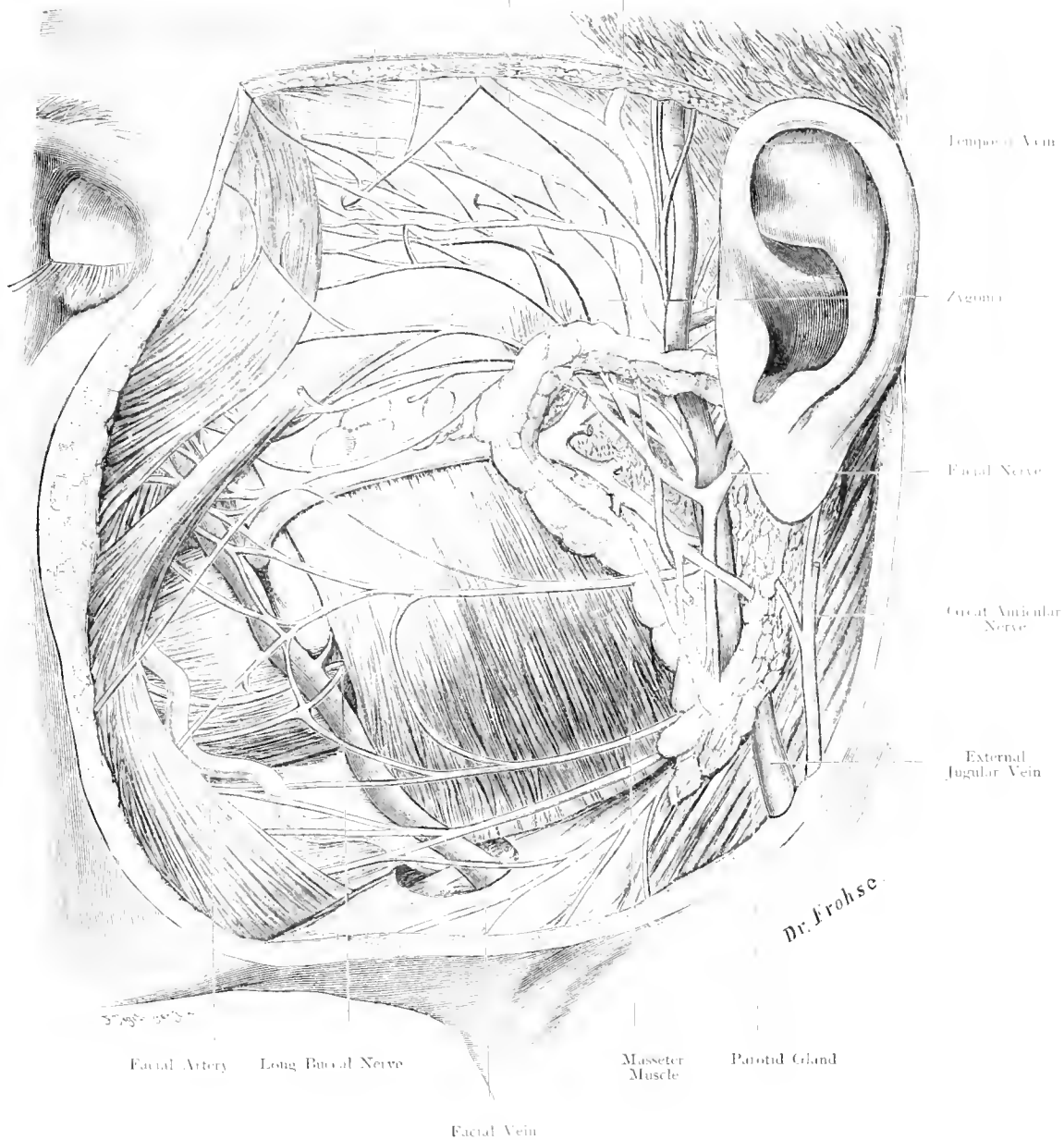


Fig. 30. Side View of Face. Superficial Layer.

Nat. Size.

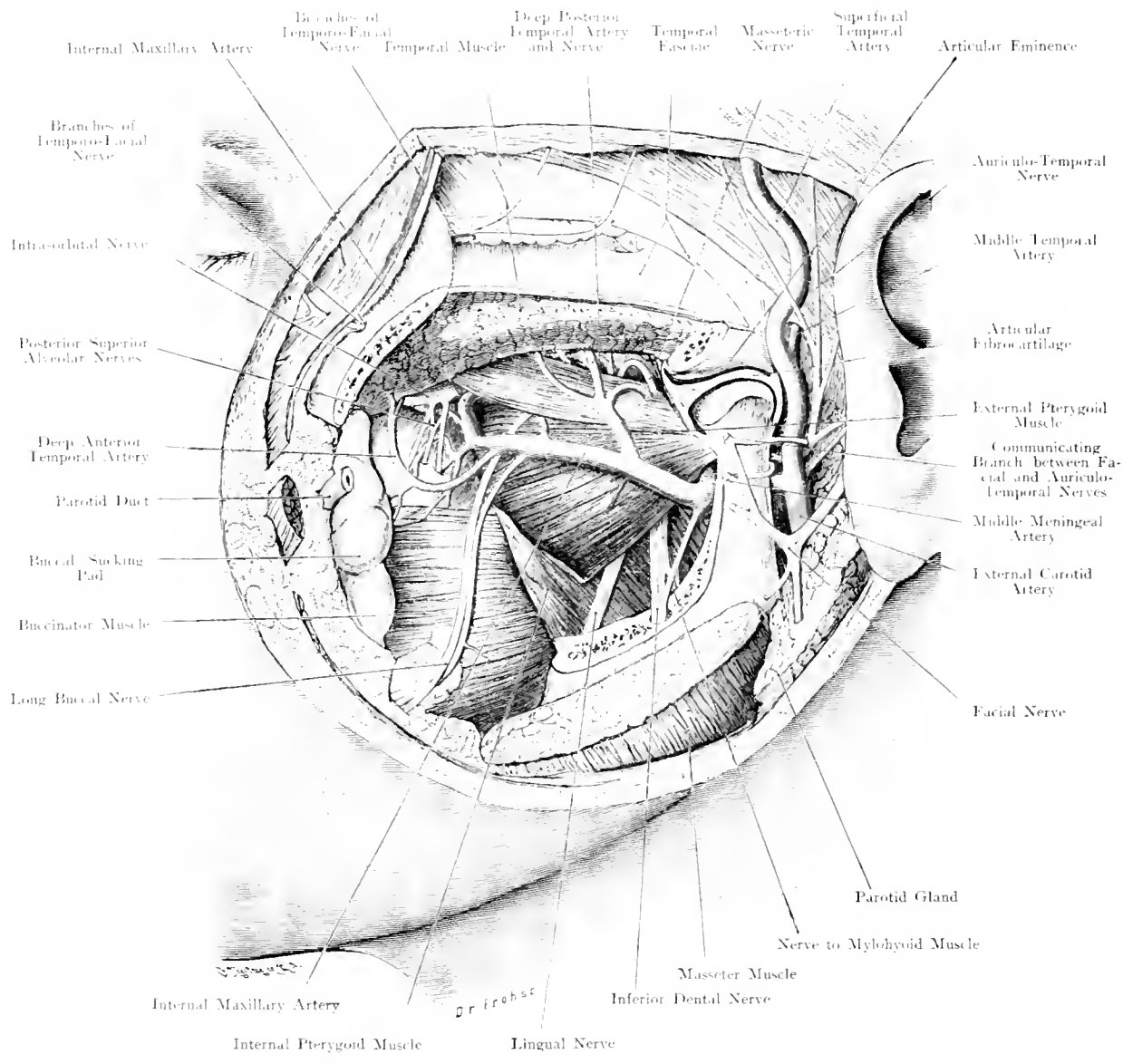


Fig. 31. Side View of Face. Deep Layer.
Nat. Size.

Fig. 31. Side View of Face, deep layer.

The branches of the Facial Nerve have been cut off but its communications with the Auriculo-Temporal Nerve have been exposed to view: the Zygoma has been sawn through and removed together with the upper part of the Masseter Muscle, (in a similar manner, the Coronoid Process with the attached Temporal Muscle). All the chief branches of the 2nd and 3rd divisions of the Vth Cranial Nerve and the branches of the Internal Maxillary Artery are exhibited.

Under cover of the Coronoid Process of the Lower Jaw and the Temporal Muscle attached to it, the structures of the Zygomatic Fossa are covered with fat. After the removal of this fat the External Pterygoid Muscle is seen extending from the Pterygoid Process to the Condyle of the Lower Jaw. The relation of the Internal Maxillary Artery (terminal branch of External Carotid Artery) to this muscle varies as it runs, either superficial or deep to the muscle, to gain the Spheno-Maxillary Fossa. This vessel gives off the Middle Meningeal Artery which runs upwards to the Foramen Spinosum and the Inferior Dental Artery which enters the Inferior Dental Foramen. After removal of the External Pterygoid Muscle the 3rd or Inferior Maxillary-Division of the Vth Nerve is visible.

After passing through the Foramen Ovale this breaks up into numerous diverging branches. The Auriculo-Temporal Nerve passing backwards emerges behind the Temporo-Maxillary Articulation and supplies the skin of the temporal region with common sensibility, this nerve generally forms a loop through which the Middle Meningeal Artery passes. The other branches are partly motor and supply the Muscles of Mastication (Internal and External Pterygoids, Masseter and Temporal), and partly sensory, long Buccal to the skin and Mucous Membrane of the Cheek. The two largest branches, Inferior Dental and Lingual, pass downwards on the Internal Pterygoid Muscle; the former, the larger nerve, is the more posterior.

In the Spheno-Maxillary Fossa but situated anteriorly, is the posterior surface of the Superior Maxilla. The Infra-orbital Artery, a branch of the Internal Maxillary Artery, enters the Infra-orbital Canal, while close above this vessel lies the 2nd division of the Vth Nerve which in its course from the Foramen Rotundum to enter the Infra-orbital Canal inclines outward. In its short course it gives off the Spheno-Palatine Nerves to the Spheno-Palatine Ganglion (MECKEL'S, cf. Fig. 44) and through the Pterygo-Maxillary Fossa the Zygomatic, Superior Dental and Sphenopalatine Nerves.

Operations in this region — for removal of tumours, resection of the 2nd or 3rd divisions of the Vth Nerve for Acute Neuralgia — are rendered difficult by the diffuse Venous Plexus (Pterygoid Plexus) which replaces the Venae Comites of the Internal Maxillary Artery. This plexus which has been removed in the dissection, extends from the Infra-orbital Canal and Spheno-Maxillary Fissure between the Pterygoid Muscles as far as the Temporo-Mandibular Joint.

Fig. 32. Exposure of the Gasserian Ganglion. Natural Size.

On the right side an incision, curvilinear with its base at the Zygoma, has been carried through the soft parts. The bone has been chiselled through and the osteoplastic flap, broken at its base, is turned downwards. The Dura Mater of the Middle Fossa and the Temporal Lobe are raised so that after division of the Middle Meningeal Artery, the GASSERIAN Ganglion and the 3rd division of the Vth Nerve are exposed outside the Dura Mater. (As the bone was removed the Anterior Division of the Middle Meningeal Artery was lacerated in its bony canal.)

Persistent Facial Neuralgia which is unrelieved even by extensive resection of the peripheral branches of the Vth Nerve as they emerge from the skull and which is unrelieved by medicaments has recently been dealt with by removal of the GASSERIAN Ganglion. Two methods may be adopted either (ROSE) the Zygoma may be temporarily resected, when after exposure of the Foramen Ovale from below the base of the skull is opened up; or the skull may be opened in the Temporal region (HARTLEY, KRAUSE) and the Ganglion with its branches exposed. This latter method is perhaps the better one; moreover, it may be employed for removing tumours of the Middle Fossa or for ligation of the Middle Meningeal Artery. After turning down an osteoplastic flap as described above, the Dura Mater covering the Temporal Lobe is lifted away from the Skull. Considerable haemorrhage follows from the laceration of numerous small veins. At a depth of one inch from the Squamous portion of the Temporal Bone, just above the root of the Zygoma lies the Middle Meningeal Artery. This vessel is divided between two ligatures in order to expose the Foramen Ovale which lies $\frac{1}{10}$ th inch internal and in front of the Foramen Spinosum; $\frac{2}{5}$ th inch forwards and nearer to the middle line than the Foramen Ovale is situated the Foramen Rotundum through which the 2nd division of the Vth Nerve passes; $\frac{1}{5}$ th inch from the Foramen Ovale and $\frac{2}{5}$ th inch from the Foramen Rotundum is the Convex margin of the GASSERIAN Ganglion. It lies in an impression on the upper surface of the petrous bone and covered by Dura Mater in MECKEL'S Cave (cf. Fig. 23).

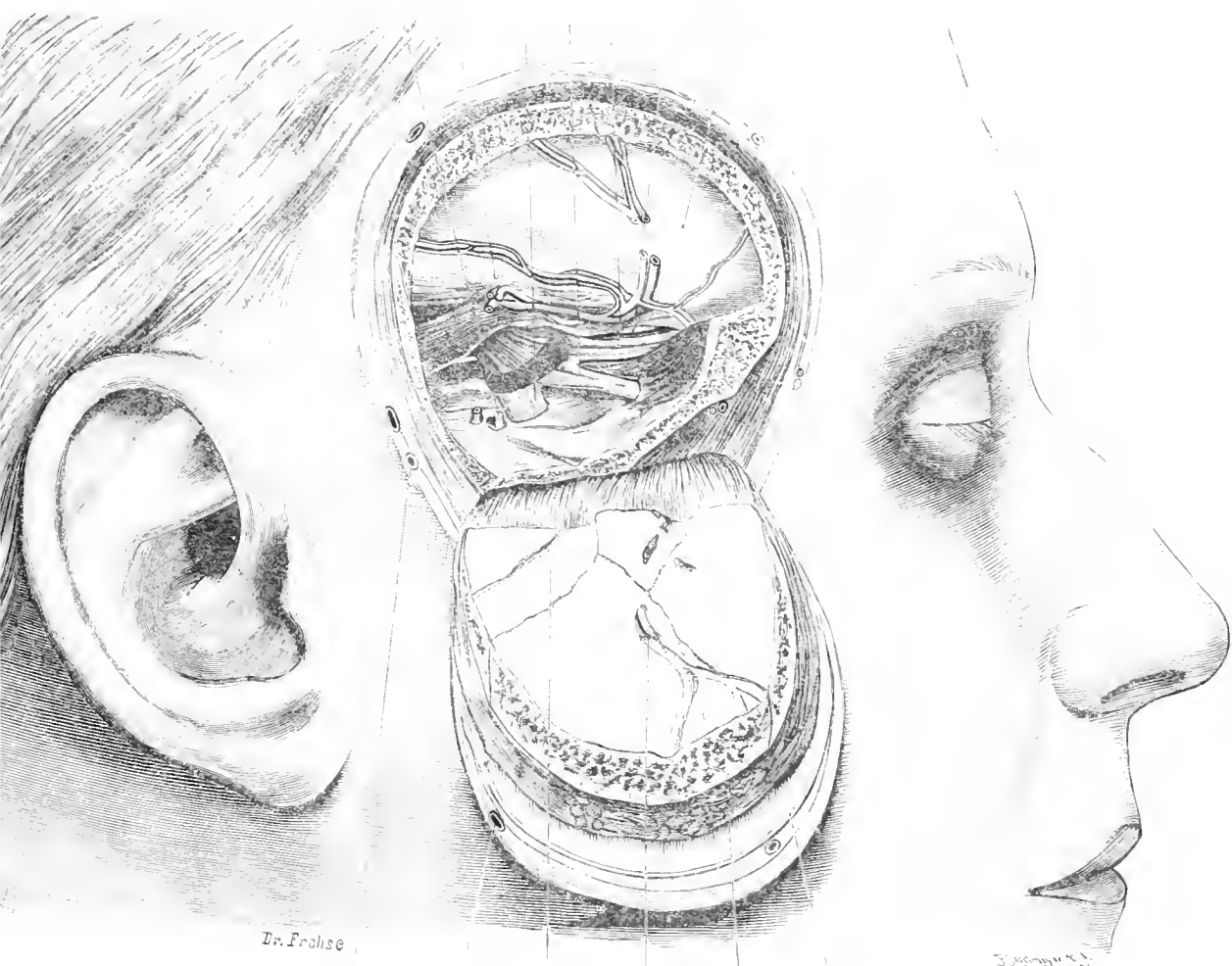
The trunk of the Vth Nerve enters its Dural Sac by passing through a slit in the Dura Mater at the attachment of the Tentorium Cerebelli to the superior border of the petrous bone. The GASSERIAN Ganglion and its three divisions are outside the Dura Mater and can be operated upon without opening the meninges or exposing the brain.

Particular attention should be paid to the first division of the Vth Nerve, as it lies in the outer wall of the Cavernous Sinus; so that in freeing this division the Sinus is necessarily injured. (Cf. Fig. 17.)

Another method, devised by LEXER, is still less liable to injure the brain whereas it gives a good exposure of the Ganglion. LEXER makes a smaller temporal flap but enlarges the area of operation downwards by temporarily resecting the Zygoma and removing the base of the skull as far as the Foramen Ovale.

Dura Mater of Temporal Lobe
V
Trochlear Nerve
Dura Mater of Frontal Lobe

3
2
1



Dr. Frohse
Superficial Temporal Artery
Superficial Temporal Vein
Posterior Branch of Middle Meningeal Artery
Anterior Branch of Middle Meningeal Artery
Muscle Temporal
Fascia

Fig. 32. Exposure of the GASSERIAN Ganglion.
 Nat. Size.



Fig. 33.

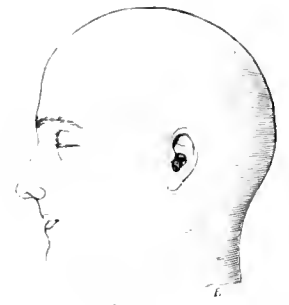

Fig. 35.

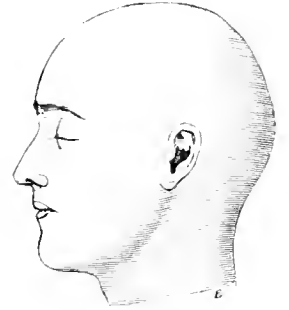


Fig. 36.

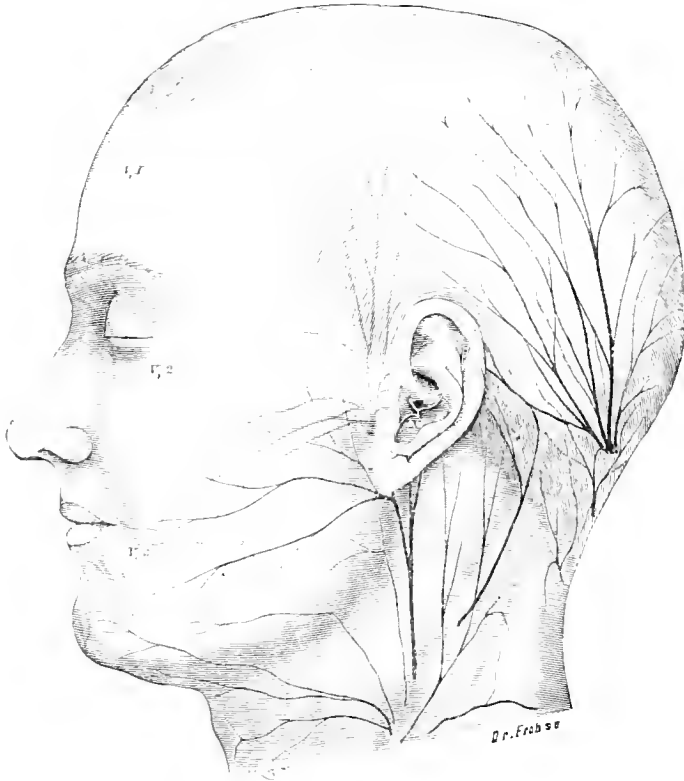

Fig. 34.

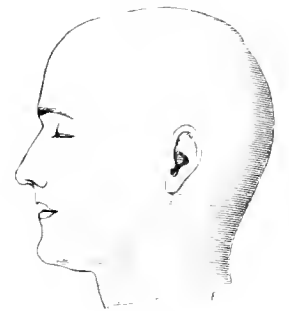


Fig. 37.

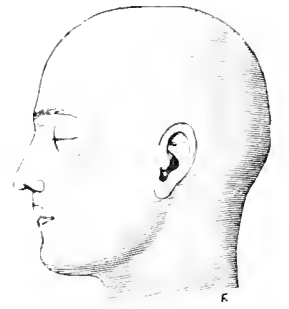


Fig. 38.

Fig. 33—38. Area of Distribution of the Sensory Cranial Nerves:
 Fig. 33 Front View, Fig. 34 Side View, $\frac{1}{2}$ Nat. Size.
 Fig. 35—38. Variations, Side View. $\frac{1}{5}$ Nat. Size.

Fig. 33—38. Area of Distribution of the Sensory Nerves of the Head.

These diagrams have been made in accordance with FROISE's investigations and ZANDER's data. In fig. 33 the foramina of exit of the chief branches of the Vth Nerve have been indicated by black Dots.

A characteristic feature of the Cranial Nerves is that they are either pure Motor or pure Sensory nerves; when they contain fibres of the other variety they do not represent true mixed nerves like the Spinal Nerves. The anterior half of the head is supplied by the Vth Cranial Nerve, the posterior half by the Cervical Nerves, a very small portion only of the Pinna being supplied by the Auricular Branch of the Vagus (cf. the black area in Figs. 35—38, and in Fig. 34 the white nerve marked X).

The 1st division of the Vth Nerve (red) supplies the forehead and vertex of the skull as far back as a vertical line drawn upwards from the posterior border of the Pinna, the middle portion of the upper Eyelid and the Lateral aspect of the Dorsum of the Nose. A branch of the Nasal Nerve supplies the anterior part of the nasal mucous membrane whereas its outer branch only becomes superficial between the Nasal Bone and the Nasal Cartilage (cf. Fig. 50).

The 2nd Division (yellow) covers the smallest cutaneous area supplying the teeth of the upper jaw (Superior Dental Nerves), the nasal mucous membrane (Nasopalatine Branches) and through the Infra-orbital Nerve the lower eyelid and the upper lip.

The 3rd Division (blue) gives off Motor Branches to the muscles of mastication and to the Mylohyoid Muscle. Its Sensory Branches are the Auriculo-Temporal, Long Buccal and Mental Nerves.

Cervical Nerves. The Great Auricular plays an important part in the Nerve supply of the Face by supplying the region over the Parotid and the Masseter.

One of its branches ascends between the Helix and Antihelix. The outer side of the Pinna is accordingly supplied by 3 nerves: — Auriculo-Temporal, Auricular Branch of Vagus and Great Auricular.

The foramina of the 3 branches of the Vth Nerve viz. the Supra-orbital Foramen (notch), Infra-orbital and Mental Foramina lie almost in a vertical line (K. v. BARDELEBEN). In Neuralgia these points are exceedingly tender. A glance at Figs. 35 to 38 indicates the enormous variations in the cutaneous supply. Thus (cf. Fig. 36) the Infra-orbital Nerve may supply the whole of the middle portion of the Dorsum of the Nose and eliminate the Outer Branch of the Nasal Nerve from the Tip of the Nose. Fig. 38 shews a very considerable extension of the Cervical Area. Variations not only occur in different individuals but even in the same individual, so that the cutaneous supply is different in each lateral half of the face. Frequent anastomoses occur so that one area may be supplied by several nerves. Stress should be laid on the fact that the nerves cross the middle line to the opposite side (cf. Fig. 33).

Fig. 39. The Nasal Cavity with the Opening of its Accessory Sinuses.

The Sagittal Section has been made a little to the right of the Nasal Septum, Sphenoidal and Frontal Septum. Portions have been removed from the Turbinated Bones in order to exhibit the orifices of the accessory Cavities. Into some of these directors have been introduced. The Tongue has been almost completely removed to shew the Tonsil.

The Accessory Cavities of the Nose may be considered Embryologically as Ethmoidal Cells which have grown beyond the area of the Labyrinth. They become formed by the resorption of the bony walls of the Nasal Cavity. The mucous membrane follows this process and grows into the accessory cavities. The Nasal Duct opens, covered by the inferior turbinated bone, into the inferior nasal meatus. This meatus readily allows the introduction of a canula into the opening of the EUSTACHIAN Tube which lies in the Outer Wall of the Pharynx. At this opening is the EUSTACHIAN Cushion, behind it the Fossa of ROSENMÜLLER. Under the Mucous Membrane covering the roof and back of the Pharynx is a mass of lymphoid tissue (Pharyngeal Tonsil) which in the middle line exhibits a recess of variable shape, grooved, saccular or double (Pharyngeal Bursa).

Into the middle meatus, at the Anterior part of a ridge, is the opening of the Frontal Sinus (Infundibulum), at the posterior part the aperture of the Antrum of HIGHMORE. The communication between the Antrum and the Nose is not always single, it may be double.

We have already stated (in Fig. 2 Text) that the opening of the Antrum is in a most unfavourable position for drainage, because it is situated at the top of the cavity. The Anterior Ethmoidal Cells also open into the Middle Meatus (cf. Fig. 2) directly above the aperture of the Antrum. The Superior Meatus contains the opening for the Posterior Ethmoidal Cells. Above the Superior Turbinated Bone is the aperture for the Sphenoidal Sinus into which guided by a mirror one can introduce a canula through the Anterior nares. The aperture of the Sphenoidal Sinus is not situated at the lowest part of the cavity and is consequently not favourable for drainage. All the accessory nasal cavities are lined with mucous membrane.

The figure shews the Tonsil situated between the two pillars of the Fauces. About one inch long and composed of Lymphoid Tissue it only becomes distinctly visible when the tongue is depressed. (Cf. Fig. 53.)

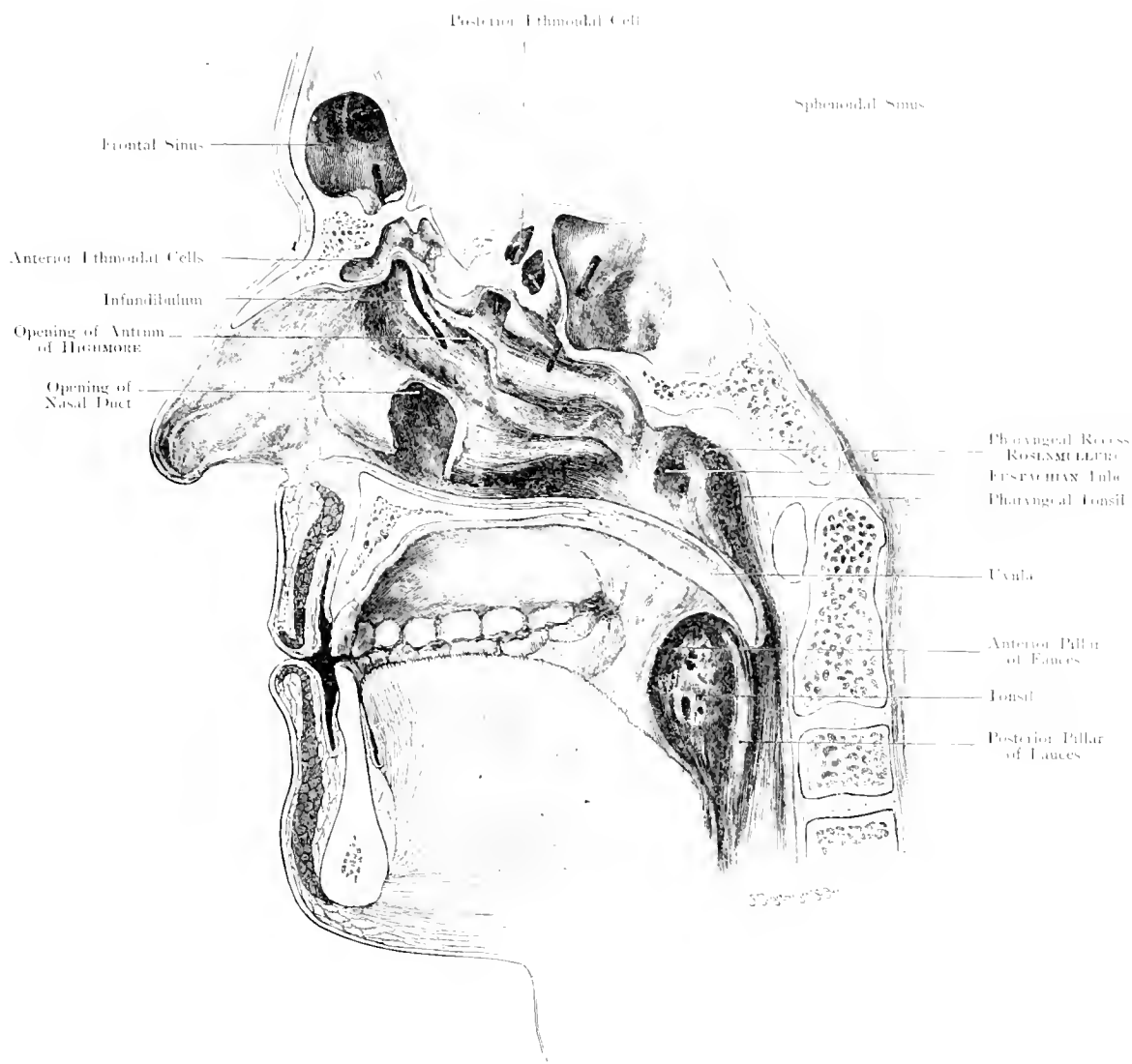


Fig. 39. Nasal Cavity with Openings of Accessory Sinuses.

$\frac{1}{2}$ Nat. Size.

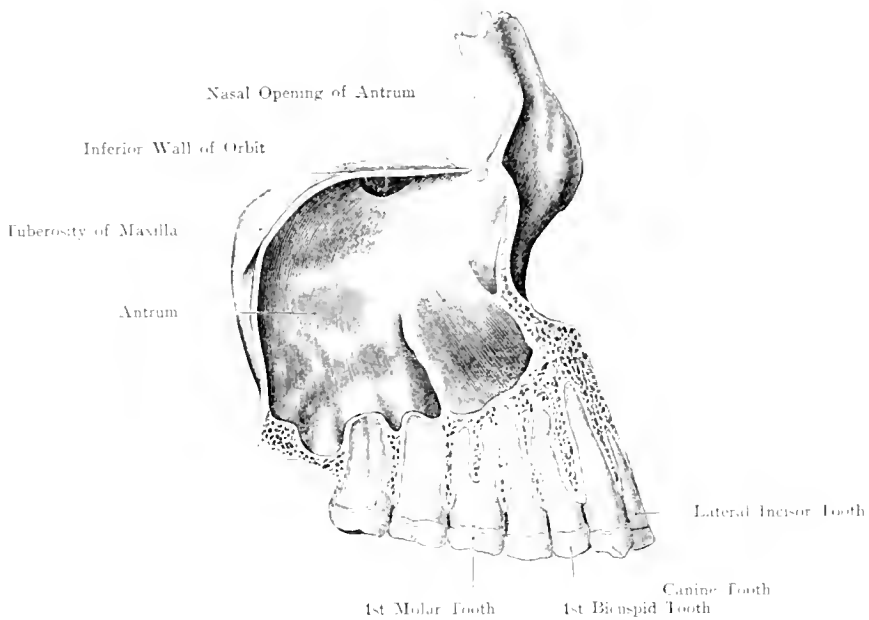


Fig. 40. Antrum of HIGHMORE with Roots of Teeth.
Nat. Size.

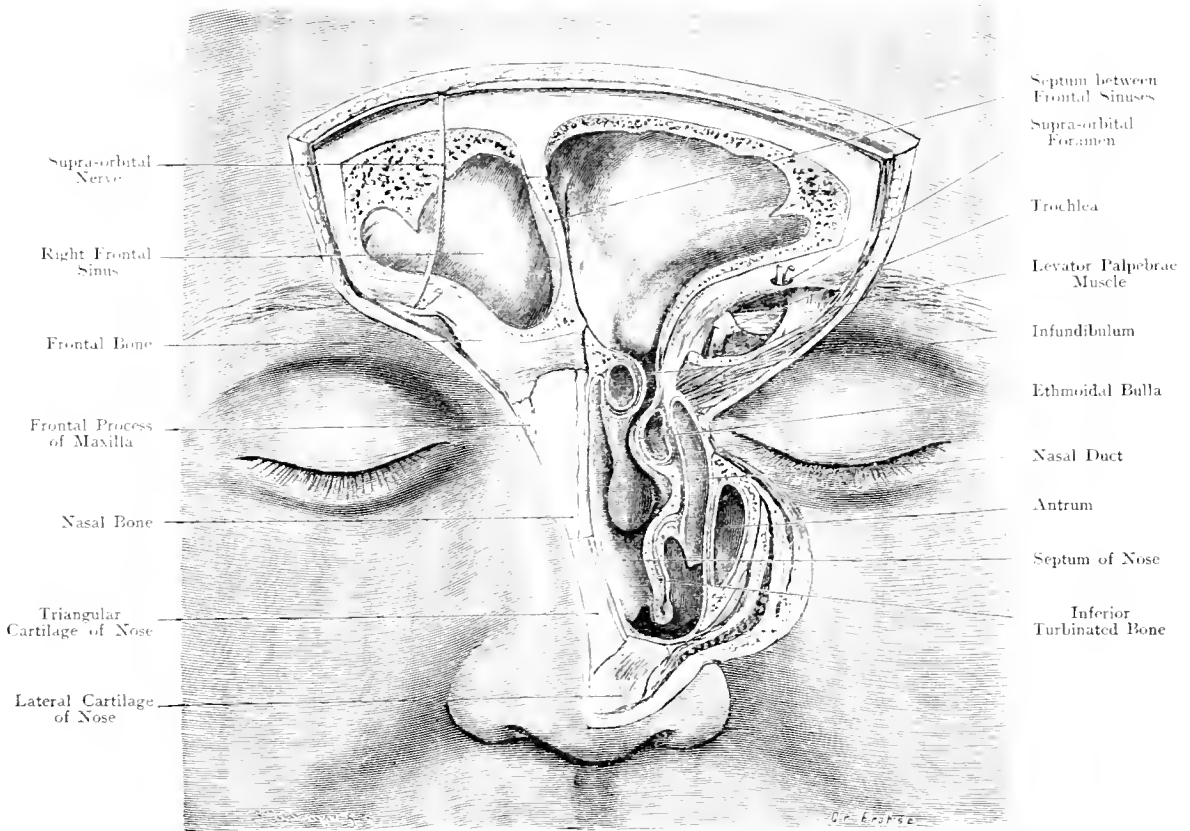


Fig. 41. Frontal Sinus. Nasal Duct.
Nat. Size.

Fig. 40. Antrum of HIGHMORE with Roots of Teeth.

The Alveolar Process and Teeth were ground off until the Antrum of HIGHMORE was well exposed; its Anterior wall was removed.

The Incisor Teeth are in no relation with the Antrum. The Canine and first Bicuspid Teeth are closely related to this cavity, but separated from it by a thick layer of bone. The 2nd Bicuspid and the 3 Molar Teeth are in closer relation to it. The roots of the Molars frequently project upwards as conical processes, separated from it only by a thin layer of bone. Thus disease of the roots of the last four teeth may lead to suppuration in the Antrum. On the other hand, an empyaema of the Antrum of HIGHMORE may be drained by extracting one of the teeth mentioned and perforating the thin layer of bone.

Fig. 41. Frontal Sinuses. Nasal Ducts.

Both Frontal Sinuses are chiselled open from the front. On the right, the bones and sutures at the root of the nose are laid bare; on the left, the outer wall of the Nose has been removed, as far as necessary to expose the duct which leads from the Frontal Sinus to the Nasal Cavity. Mucous membrane is coloured pink.

The Frontal Sinuses lie directly above the root of the nose, they extend towards the forehead and over the orbital cavities from which they are separated by the thin roof of the Orbit. Their greatest depth is above the nose; externally they gradually become more flattened. Their size and shape vary enormously in different people. Their utmost limits are laterally the fronto-malar suture and superiorly half-way to the Summit of the vertical portion of the frontal bone. They are separated from each other by a thin lamina of bone, which practically always deviates from the middle line.

They are to be considered as ethmoidal cells which have been pushed into the frontal bone, in this way, the external table and diploë lie in front, and the internal table behind them. This explains the strength of the anterior wall and its resistance to external violence.

Their inner surface is irregular and may present recesses resembling diverticula. They are, as their origin explains, lined by mucous membrane.

They always communicate with the nasal cavity; the opening of this communication lies invariably in the middle nasal meatus (infundibulum), into which the Antrum of HIGHMORE also opens (cf. Fig. 39). The Frontal Sinus may reach as far as the anterior end of the Ethmoidal turbinated bone and open by means of a simple slit, or the anterior ethmoidal cell may be very large and thus cause constriction of the lower part of the Sinus; in this case a Canal is formed: — the naso-frontal duct —.

These deviations explain why it is very easy in some cases, and difficult in others — or even impossible — to introduce a canula into the Frontal Sinus through the nose.

Fig. 42. Orbit and surrounding Structures — Horizontal Section.

From a frozen section which passes horizontally through the middle of the eye of a male body, 45 years old, the brain is removed; middle Meningeal Artery and GASSERLIN Ganglion dissected. Mucous membrane of Nasal and Accessory Cavities, red. TENON'S Capsule and Periosteum blue. Lachrymal apparatus orange.

This section shews the conical shape of the orbital cavity which has also been compared with a pyramid. The inner wall is chiefly formed by the Os Planum of the Ethmoid; it is very thin, and separates the orbit from the accessory nasal cavities. Pus may thus easily spread from them into the orbit. The centre of the eyeball does not lie in the axis of the orbit, but slightly external to it. The orbit is filled with fat through which the muscles, vessels and nerves to the eyeball run. (The Ciliary Ganglion is shewn in Fig. 16.) The Optic Nerve, flattened in the skull, leaves its foramen as a round cord, runs forwards and outwards — then inwards — and just before reaching the eyeball again slightly outwards. It thus describes an S-shaped curve (cf. Fig. 44).

The connective tissue of the orbital fat forms near the eyeball a strong membrane — TENON'S Capsule —. The eyeball moves in this membrane, as if this were a ball- and socket-joint. There is, however, no free space between the eyeball and capsule, as the space is filled up by a delicate scaffold-like tissue. TENON'S Capsule ends behind at the Optic Nerve, in front at the Fornix of the conjunctiva; the eye muscles pass through slits in the capsule, which sends at these points sheaths to surround the muscles; these sheaths blend with the aponeurosis of the muscles. Internal to the Inner Rectus, TENON'S Capsule forms a triangular cushion and thus blends with the fascia of HORNER'S Muscle, the lachrymal sac and the puncta lacrimalia

At that point it is only indirectly — through the internal tarsal ligament — attached to the wall of the orbit. At the outer angle of the eye the Capsule is in relation with the walls of the recess which lodges the lower portion of the Lachrymal Gland and with the external tarsal ligament by which means it becomes attached to the bone.

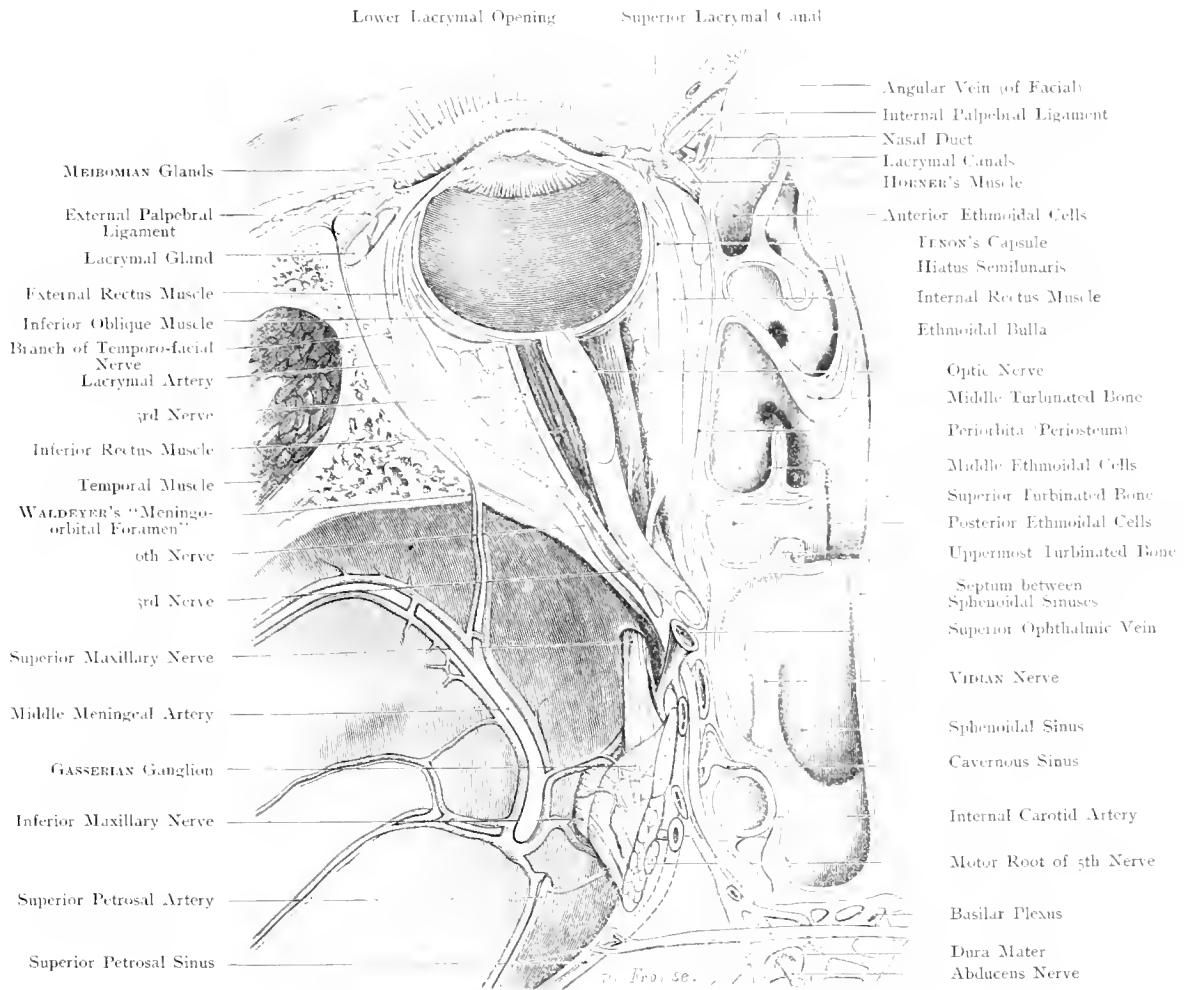


Fig. 42. Orbit and surrounding Structures — Horizontal Section.

$\frac{1}{2}$ Nat. Size.

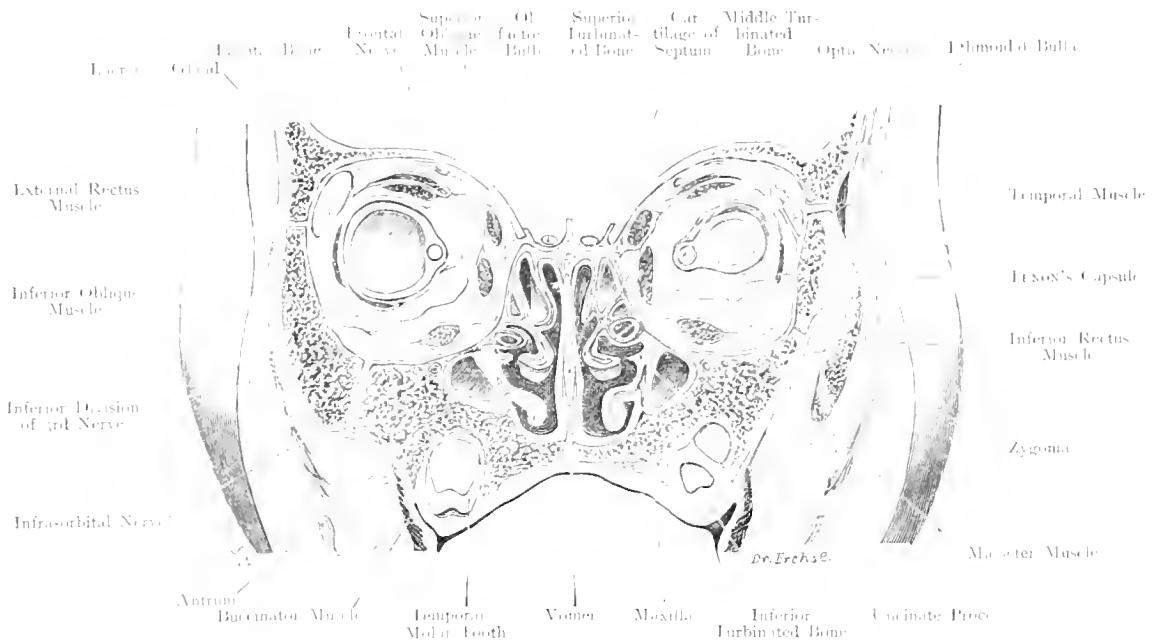


Fig. 43. Orbital and Nasal Cavities in a Child. Frontal Section.
Nat. Size.

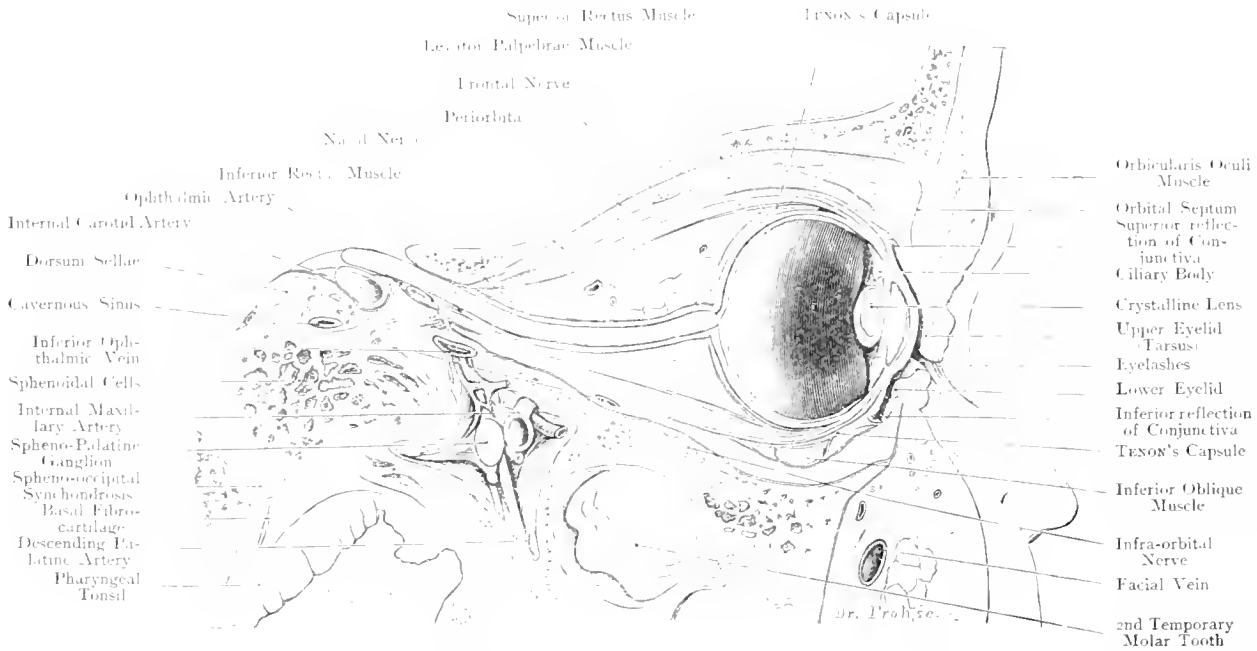


Fig. 44. Orbital Cavity and surrounding Structures in the Child. Vertical Section through Axis of Optic Nerve.

$\frac{2}{3}$ Nat. Size.

Fig. 43. Orbital and Nasal Cavities in a Child. Frontal Section.

Portion of a frozen section through the head of a girl, 1½ years old.

A comparison with Fig. 1 shews, how different the accessory cavities of the Nose and Upper Jaw are in the child when compared with those in the adult. The Frontal Sinuses are formed at the end of the first year by ethmoidal cells growing into the diploë of the Frontal Bone. They attain the size of a pea at the 6th or 7th year; they are fully developed when the nose and frontal bone cease growing — about the 20th year —. The Antrum of HIGHMORE is virtually present before the middle of Intra-uterine life; in the newborn it appears as a bulging of the middle nasal meatus the upper jaw being almost completely filled with developing teeth. With the beginning of the 2nd dentition, it increases rapidly in size. The Infraorbital Nerve is still external to the Antrum in our figure. The Outer Rectus Muscles of the Eye were so contracted on both sides, in our body, that the posterior segment of the eyeball was markedly directed inwards: this explains why the Optic Nerve has been divided by this section.

Fig. 44. Orbital Cavity and surrounding Structures in the Child. Vertical Section through Axis of Optic Nerve.

From a frozen section through the head of a child, 1½ years old. TENON'S Capsule, Periosteum, and Orbital Septum, blue.

This figure shews that the upper eyelid covers a greater portion of the cornea than the lower. The rima palpebrarum therefore lies, when the eyes are closed, below the middle of the cornea.

The Orbital Septum (cf. figure) is a plate of connective-tissue which runs from the margin of the orbit, downwards; behind the Orbicularis Palpebrarum, in the upper eyelid, it blends with the anterior slip of the Levator Palpebrae Superioris Muscle and is separated from the tarsal plate by loose connective tissue. In the lower lid, it enters the subtarsal connective tissue. It is a structure of no particular value; it is merely the Aponeurosis of the Orbicularis palpebrarum Muscle.

This figure also shews the termination of TENON'S Capsule at the Conjunctiva. It splits into 2 layers, and blends with the Tunica Propria of the Conjunctiva lining the eyeball and of the palpebral conjunctiva.

Very complicated is the arrangement of TENON'S Capsule, where it is crossed by the Inferior Oblique. From the under surface of the capsular portion of the fascia of the Inferior Rectus a lamina — "the Accessory Fascia" — runs forwards under the Inferior Oblique, blends with its sheath, and terminates in the subtarsal connective tissue of the lower eyelid, where the capsule proper also ends.

Above the Pharyngeal Tonsil lies the basilar fibrocartilage, above this again lies the Spheno-Occipital Synchrondrosis which may be injured in the too-energetic scraping of adenoids.

Fig. 45. Frontal Section through Posterior Part of Nasal Cavity.

Fig. 46. Frontal Section through Sphenoidal Sinuses and Nasal Cavity.

A section from a skull was hardened, together with its soft parts, in formalin, and decalcified before further division into frontal sections. The section shewn in Fig. 46 passed about $\frac{3}{10}$ th inch behind Fig. 45.

In Fig. 45, the posterior part of the Antrum of HIGHMORE has been cut on both sides; the 3 turbinated bones are well shewn. The great variations met with in the sinuses accessory to the nasal cavity, are well shewn by the fact, that, on the left, the most Posterior Ethmoidal Cell has been cut by the section, whilst, on the right, the Ethmoidal Cells did not extend so far back. The posterior part of the orbit has also been divided by this section. The numerous Vessels and Nerves which lie close together in the Cavernous Sinus, diverge and divide into groups; the origin of the Ocular Muscles near them, are shewn in cross-section. The Optic Nerve which has left the skull-cavity, in company with the Ophthalmic Artery through the Optic Foramen, lies, enclosed by Dura Mater, to the inner side of these structures.

In Fig. 46 the Sphenoidal Sinuses (their openings into the nose are shewn in Fig. 45) are laid open. They are separated from each other by a median septum and occupy the body of the Sphenoid Bone. They often extend as far (cf. Fig. 47) as the Sella in which lies the Pituitary Body; in fact, they may reach the Spheno-Occipital Synchronosis. They form the most posterior part of the inner wall of the Orbit (cf. Fig. 42) and may in some cases extend into the Greater Wings of the Sphenoid Bone (cf. Fig. 16 Lateral Recess of the Sphenoidal Sinus). In chronic inflammation of the nose, these may become the seat of suppuration, and have to be opened, because their natural narrow opening into the nose affords insufficient drainage.

In most cases, it will be possible to open them from the Nasal Cavity; they are also accessible from in front, after having well exposed the Ethmoidal Cells from the Orbit (cf. Fig. 42).

The Optic Nerve is cut as it enters the Optic Foramen. The Nerves from the Cavernous Sinus lie close to each other in the Sphenoidal Fissure; below them at some distance, is the 2nd division of the Vth Cranial Nerve.

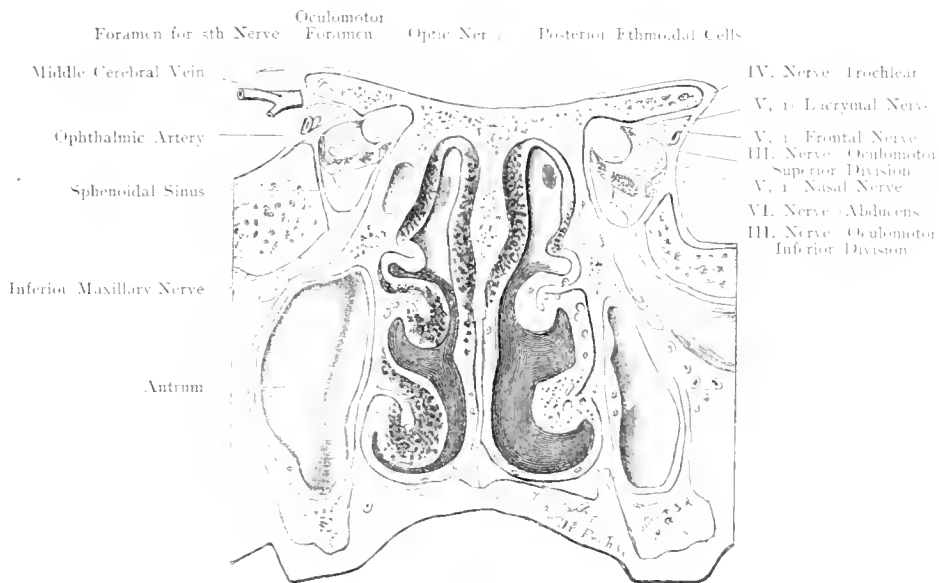


Fig. 45. Frontal Section through Posterior Part of Nasal Cavity.
Nat. Size.

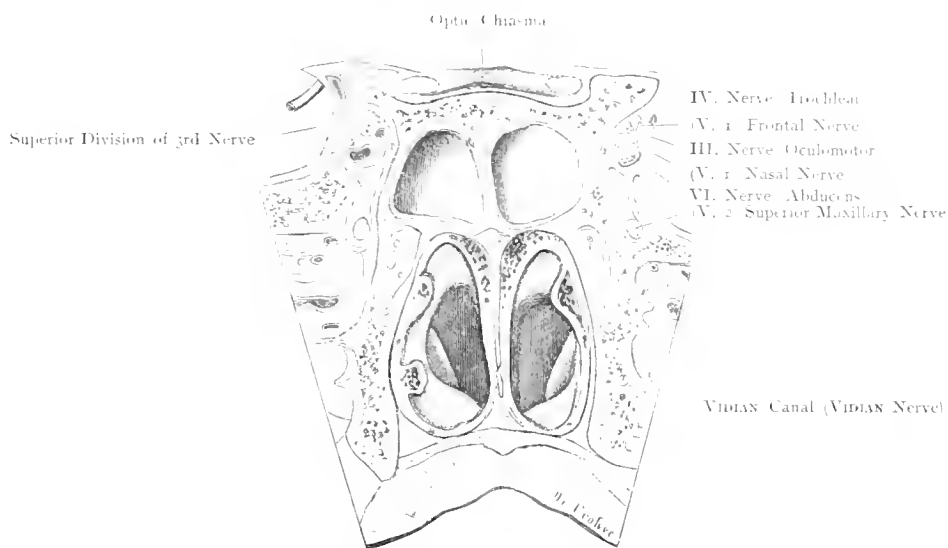


Fig. 46. Frontal Section through Sphenoidal Sinus and Nasal Cavity.
Nat. Size.

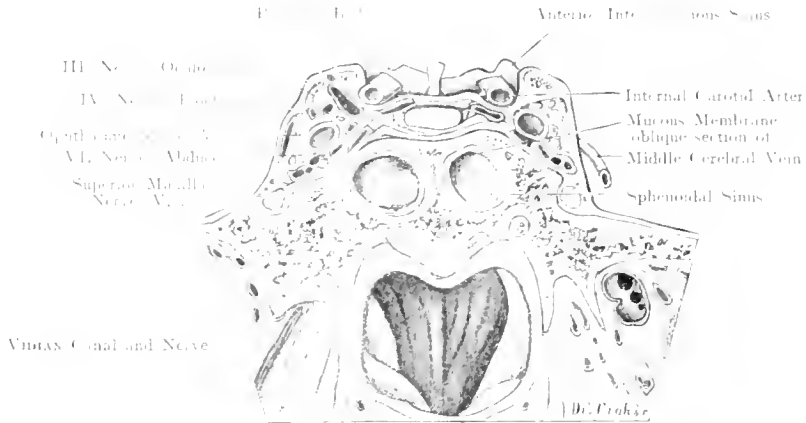


Fig. 47. Frontal Section through Anterior Portion of Cavernous Sinus.
Nat. Size.

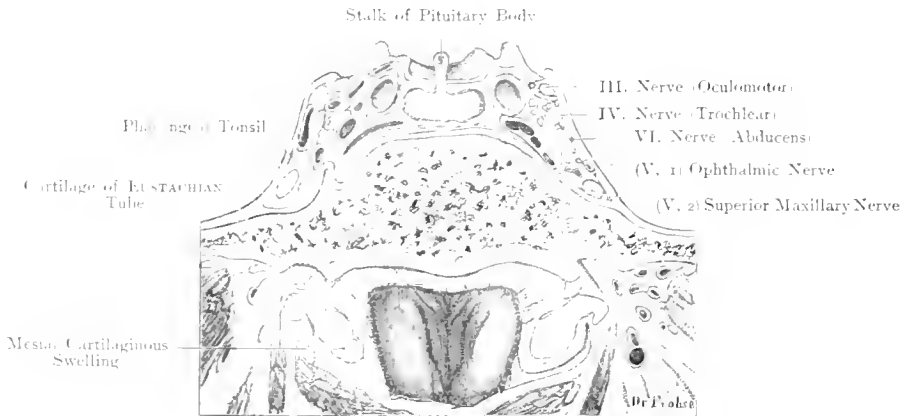


Fig. 48. Frontal Section through the Posterior Part of the Cavernous Sinus.
Nat. Size.

Fig. 47. Frontal Section through Anterior Portion of Cavernous Sinus.

Fig. 48. Frontal Section through Posterior Part of Cavernous Sinus.

Sections of the same series as those shewn in Fig. 45 and 46. Section 47 passed 0.3 inch behind section 46, and 48 passed 0.3 inch behind 47.

On either side of the Sella Turcica is the Cavernous Sinus the most complicated of all the sinuses formed by the Dura Mater. It contains the Internal Carotid Artery, the 3rd, 4th and 6th Cranial Nerves, and is in close relation with the 1st division of the 5th Nerve. The Dura Mater is at some distance from the bone, and thus forms with it a space which contains the structures mentioned amid numerous veins. These veins are partly plexiform in character. This sinus is, therefore, unlike the others, not a large venous channel, but a mass of freely anastomosing veins. Both cavernous sinuses are joined to one another by two transverse veins which pass respectively in front of and behind the Pituitary Body. Thus a venous ring, the Circular Sinus (or Sinus of RIDLEY) is formed.

Primary thrombosis of the Cavernous Sinus is rare; thrombosis usually occurs secondary to the Lateral Sinus with which it communicates through the Superior Petrosal Sinus, or by the spreading of a thrombus along the Ophthalmic Vein. Empyema of the Sphenoidal Sinus may also give rise to this thrombosis, as the intervening bone is very thin; this process is absolutely analogous with the thrombosis of the Lateral Sinus due to pus in the Mastoid Process. The anatomical relations explain why thrombosis of the Cavernous Sinus may produce Neuralgia of the first division of 5th C. N., Paralysis of 3rd, 4th and 6th Nerves, and why congestion or thrombosis of the Ophthalmic Vein can be followed by Oedema of the Eyelids, Retro-bulbar Oedema and Exophthalmos.

Surgical treatment for thrombosis of the Cavernous Sinus has hitherto only once been attempted with success. The diseased sinus was reached by removing the petrous portion of the temporal bone, attacking it from the ear. It can also be got at by the channel made for the removal of the GASSERIAN Ganglion.

Should the Internal Carotid Artery be injured where it lies in the Cavernous Sinus, with a sharp instrument entering the Orbit, or by a piece of bone (fracture), or through a shot, or should the vessel burst spontaneously (calcified arteries in old people), an abnormal communication may be formed between the artery and the sinus (Aneurysm by Anastomosis), the consequence is a pulsating Exophthalmos which is a rather curious condition.

A glance at the figures shews that dangerous haemorrhage may follow the tearing of the 1st division of the 5th C. N. in the removal of the GASSERIAN Ganglion. Externally to this nerve lies a venous space, which was unequally developed on the two sides in our specimen.

Fig. 49. Inner Part of Eye. Lachrymal Apparatus, Superficial Layer.

Fig. 50. Lachrymal (Nasal) Duct, Deep Layer.

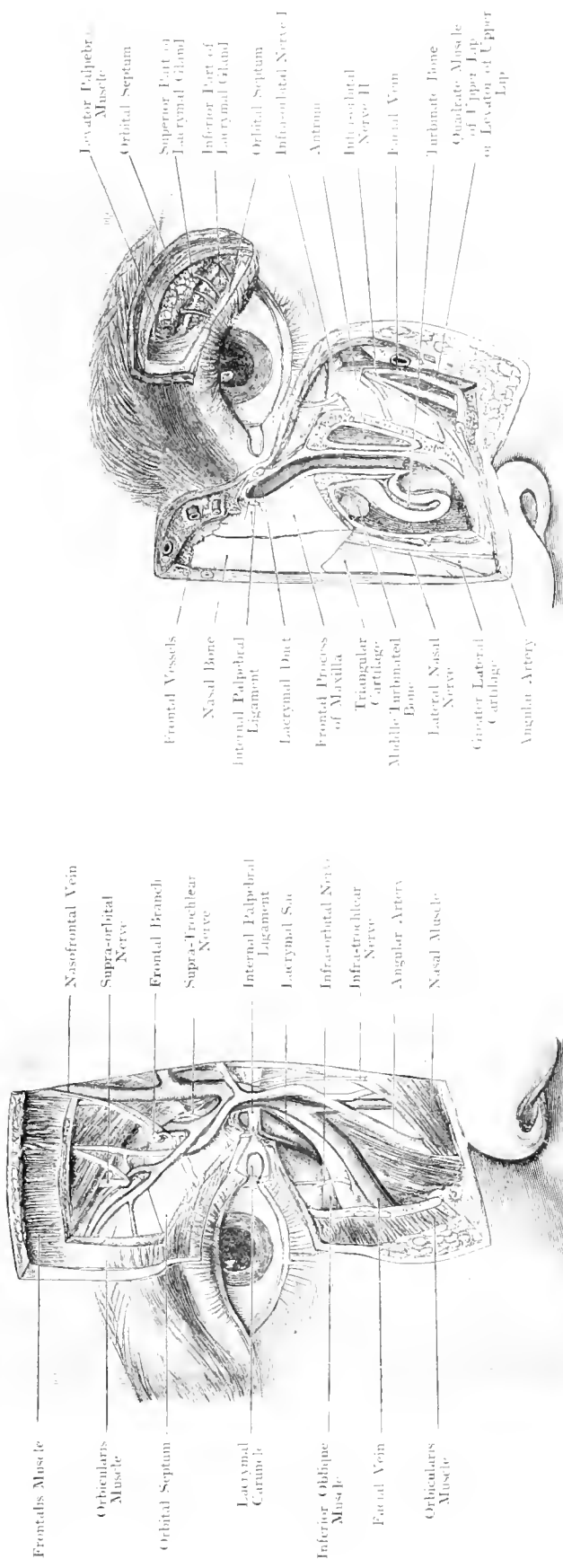
Fig. 49. After partial removal of the Orbicularis Palpebrarum Muscle, all the important vessels and nerves of the inner region of the eye and the superficial layer of the lachrymal apparatus have been exposed.

Fig. 50. The Nasal Duct has been opened in its entire length, as well as the Adrium of HERTMÖRE. The anterior portion of the inferior turbinated bone has been cut away. In the outer and upper part, the lachrymal gland, its ducts and the fasciæ are shown.

The region of the inner canthus is very vascular. After having incised skin and Orbicularis Palpebrarum one comes across the Angular Artery and the Facial Vein; the latter receives at this point the Frontal and superior Palpebral Veins and anastomosis with the Upper Ophthalmic Vein. The Lachrymal Gland lies in the Lachrymal Fossa on the Frontal bone, where the roof and outer wall of the orbit meet, under the margin of the orbit. It is covered by the skin of the upper eyelid and Orbital Septum (described in Fig. 44, text). The Lachrymal Gland may conveniently be divided into 2 portions, a larger upper portion, and a smaller inferior portion, separated from each other by a thin fascia, a variable number of ducts carries the secretion to the conjunctival sac; the tears leave this sac again through the Puncta lachrymalia which lie at the inner angle of the lids. Thence they pass through the Lachrymal Ducts which are about $\frac{2}{3}$ inch long (blue in the figure). The upper lachrymal duct has been given too sharp a curve in the figure; as a matter of fact, its course is similar to the lower one, into the lachrymal sac. This structure lies in the lachrymal fossa, and is covered by the Internal Tarsal

Ligament, where it is not enclosed by bone. Between the lower border of the Ligament mentioned and the commencement of the bony nasal duct, it is merely covered by skin and a few fibres of the Orbicularis Palpebrarum Muscle; when distended by secretion, it may bulge forwards at this point. The Canal-de-sac is just visible above the upper border of the ligament. The Lachrymal Sac is about $\frac{2}{3}$ inch long and continuous below with the Nasal Duct. This channel is $\frac{3}{8}$ — $\frac{1}{2}$ inch long according to the arrangement of the mucous membrane lining it. If the latter ends at the bony orifice below the Inferior Turbinated Bone (cf. Fig. 39), it is short; but becomes longer if the mucous membrane is continued as a tube for some distance in the mucous membrane of the nose. The direction of the Nasal Duct is downwards and backwards; it may run somewhat inwards, if the aperture is small.

Where the Lachrymal Sac and Nasal Duct join, there is usually a narrowing, or even a valve (Valve of BERKAMP). At the nasal aperture HASNER has described a valve, which, however, is no valve.



Dr. Frazer

35 11 57

Dr. Frazer

35 11 57

Fig. 49. Inner Part of Eye. Lacrimal Apparatus, Superficial Layer. Nat. Size.

Fig. 50. Lacrimal (Nasal) Duct Deep Layer. Nat. Size.

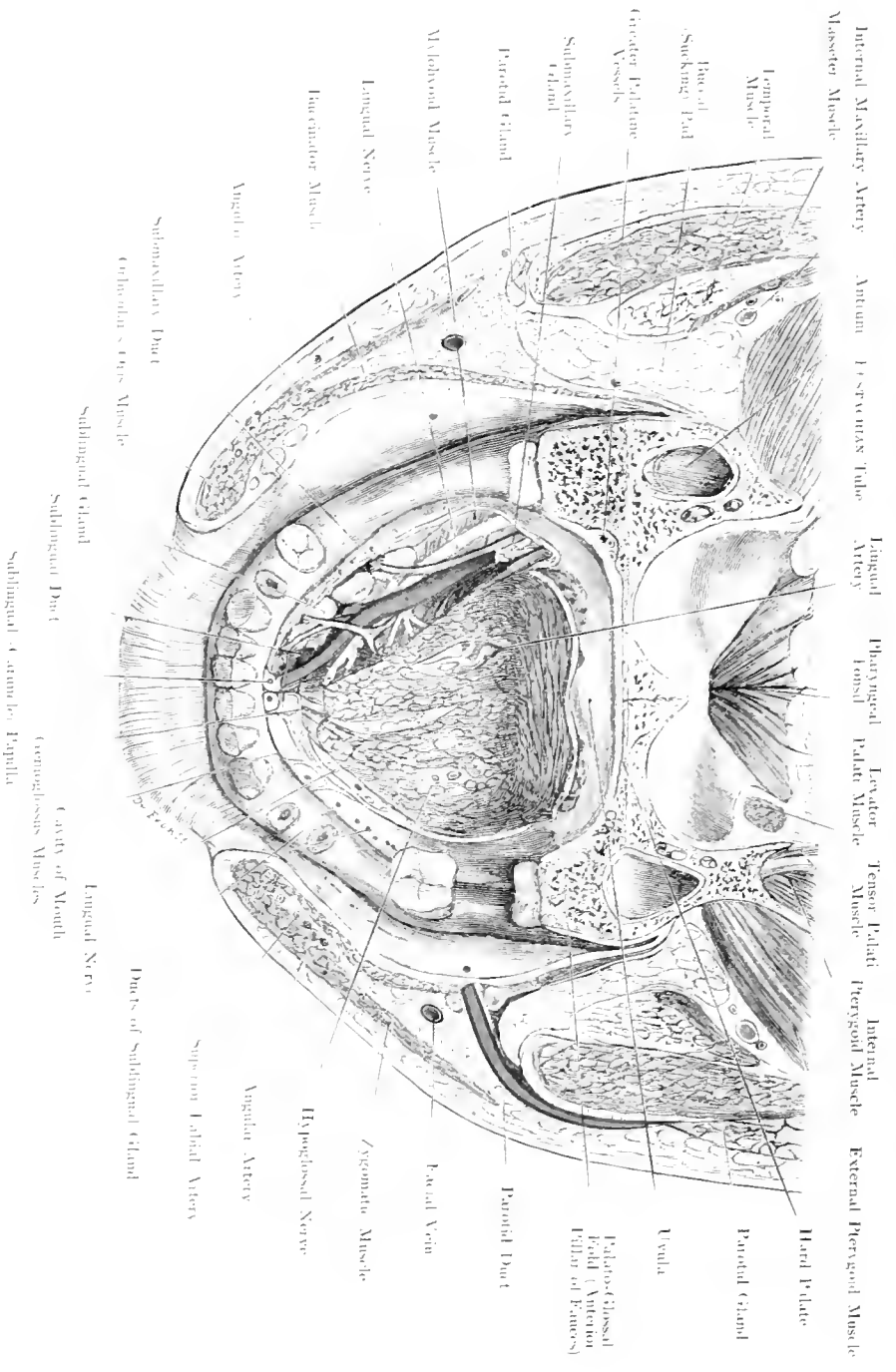


Fig. 51. Floor of Mouth.

Nat. Size.

Fig. 51. Floor of Mouth.

The Head of a man 58 years old has been seen through the line from the external auditory meatus to the angle of the mouth. The Hard Palate has been removed by a section, vertical to the above and passing in front of the 3rd molar tooth, in order to expose the Tongue. This organ was removed by a section parallel to the first, a little distance above the origin of the Genio-glossus Muscles; the vessels, ducts and nerves were then dissected from above, on the right side.

While Fig. 51 shews the floor of the mouth from below this upper surface of the Mylohyoid Muscle to the Caruncle and figure shews the structures of this region from above. The floor carries the saliva from the Submaxillary Gland. The Lingual of the mouth is of great surgical importance because operations are frequently performed in this region for suppuration, calculus in the salivary ducts, ranula, removal of the tongue and lower jaw, temporary division of the jaw for removing tumours of the tonsils, &c.

If the tip of the tongue is raised, or, as is shewn in our figure, the tongue is removed at the level of the floor of the mouth, 2 small elevations will be seen in the middle line, sublingual carunculae, at which WHARLTON'S duct opens. (Close to these is a blunt projection gradually disappearing behind, which is produced by the Sublingual gland. Its accessory ducts open by junctioniform apertures on the elevated crest of the mucous membrane, which is caused by the projection of the gland, whilst the main duct opens into WHARLTON'S duct, or very near it into the mouth.

After removal of the mucous membrane, the Sublingual Gland lying in its depression on the lower jaw, and, internal to this, WHARLTON'S duct, are exposed. This duct runs forwards on the

upper surface of the Mylohyoid Muscle to the Caruncle and carries the saliva from the Submaxillary Gland. The Lingual Nerve crosses this duct at an acute angle; at first this nerve lies behind and outside the duct which it crosses in order to reach and innervate the anterior portion of the tongue. — This nerve contains fibres of Common Sensibility and fibres of Taste, having received the latter from the Chorda tympani.

Next to WHARLTON'S duct are branches of the Sublingual Vein, under this duct lies the Sublingual Artery, a branch of the Lingual Artery which runs forwards, external to the Genio-glossus Muscle. This anastomoses with the Submental branch of the Facial Artery, and may be replaced by it. The structures mentioned, lie on the Diaphragma oris, the Mylohyoid Muscle, which arises from the Mylohyoid ridge on the lower jaw: a part of its origin is shewn in the figure.

The trunk of the Lingual Artery — the Ravine Artery — lies embedded in the substance of the tongue, near the middle line.

An incision into the muscle of the tongue has exposed a part of its ramifications.

Fig. 52. Occipital Region.

On the right, the superficial vessels and nerves, on the left, the deep layer, after partial removal of Sternocleidomastoid, Splenius and Semispinalis capitis Muscles, have been exposed. The Inferior Oblique has been pushed upwards in order to make the 2nd Spinal Root Ganglion visible.

While the anterior region of the neck contains structures of vital importance, which connect the head with the thorax and abdomen, the posterior region of the neck is chiefly occupied by large muscles; here we only find the necessary neural and vascular supply to these large muscles with the skin over this region, and a few vessels and nerves in their passage through this part. These powerful muscles are necessary to hold the head up, because without such the anterior portion of the head which is much heavier would sink forwards.

The skin over the back of the neck is much thicker and the superficial fascia much stronger than the thin mobile corresponding structures on the anterior and lateral aspect. This skin is transitory to the skin over the back, which is the strongest of the entire body. The aponeuroses are closely connected with the superficial fascia and prevent any great mobility of the nape of the neck. The most important point of this region is the point where the Occipital Artery and Vein and the Great Occipital Nerve become superficial. This point is at the middle of a line connecting the external occipital protuberance with the posterior border of the Mastoid Process. These vessels and nerves which take a different course, meet at this point. The Occipital Artery

coming off the External Carotid opposite the origin of the Facial Artery runs backwards in its groove at the base of the Mastoid Process, covered more posteriorly by the Sternocleidomastoid, Splenius Capitis, and Longissimus Capitis Muscles. It becomes superficial at the outer border of the Trapezius, or when this muscle is very broad, by piercing the same. It has 2 Venae Comites. The Great Occipital Nerve is the largest branch of the posterior division of the 2nd Cervical Nerve. It winds round the lower border of the Inferior Oblique Muscle of the Head, pierces the Semispinalis Capitis and passes upwards to become superficial at the same point as the artery.

At a deep level the Vertebral Artery passes. After having removed the Semispinalis Capitis Muscle, a small Δ is exposed, formed by the Superior Oblique, Inferior Oblique and Rectus Posticus Major Muscles. In this Δ is the horizontal portion of the artery after it has emerged from the foramen in the transverse process of the Atlas (cf. Fig. 51).

A small group of lymphatic glands (Occipital Glands) lie on the origin of the Trapezius Muscle and slightly above it; if enlarged by disease, they can be distinctly felt through the skin.

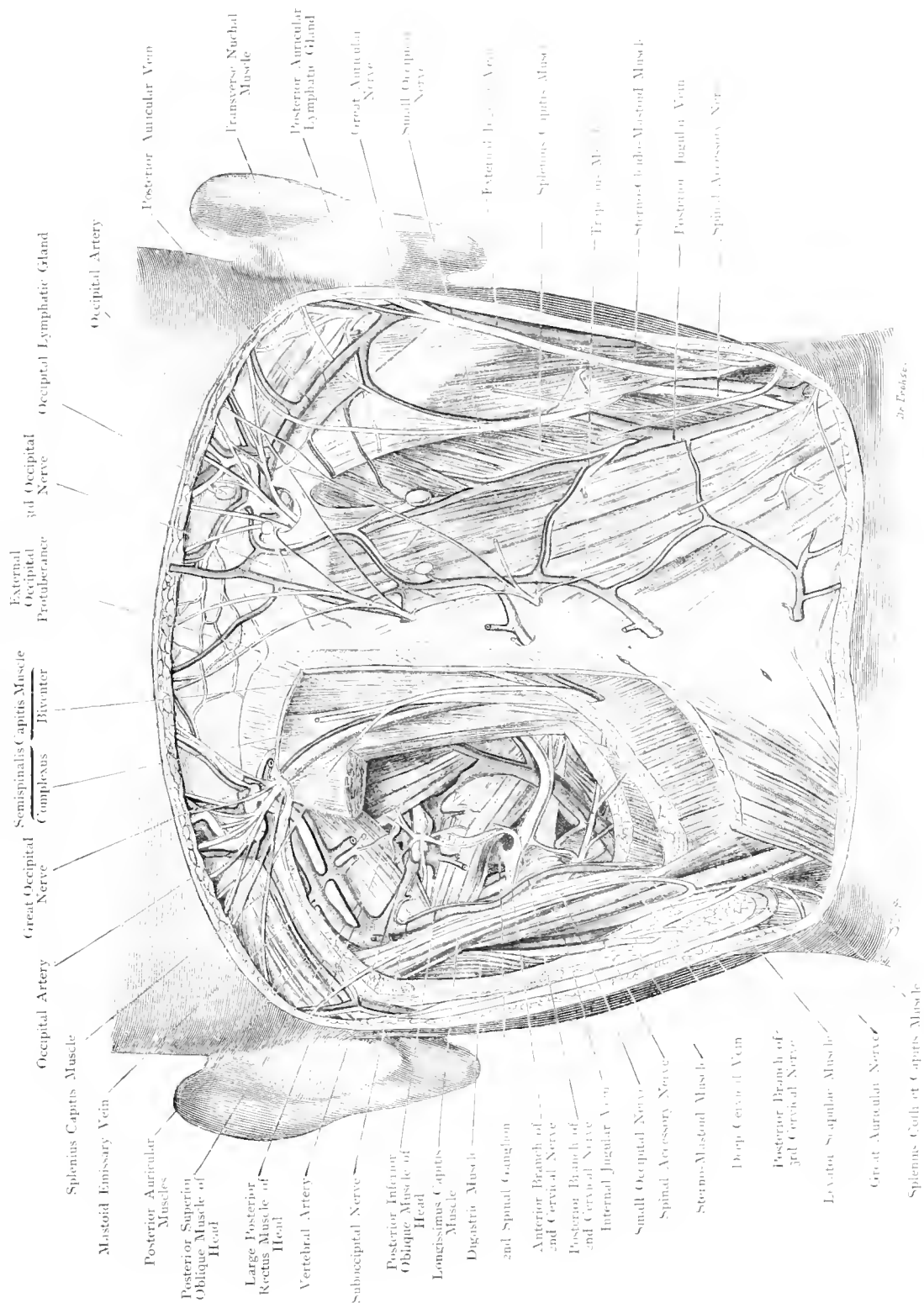

Fig. 52. Occipital Region.

1/6 Nat. Size.

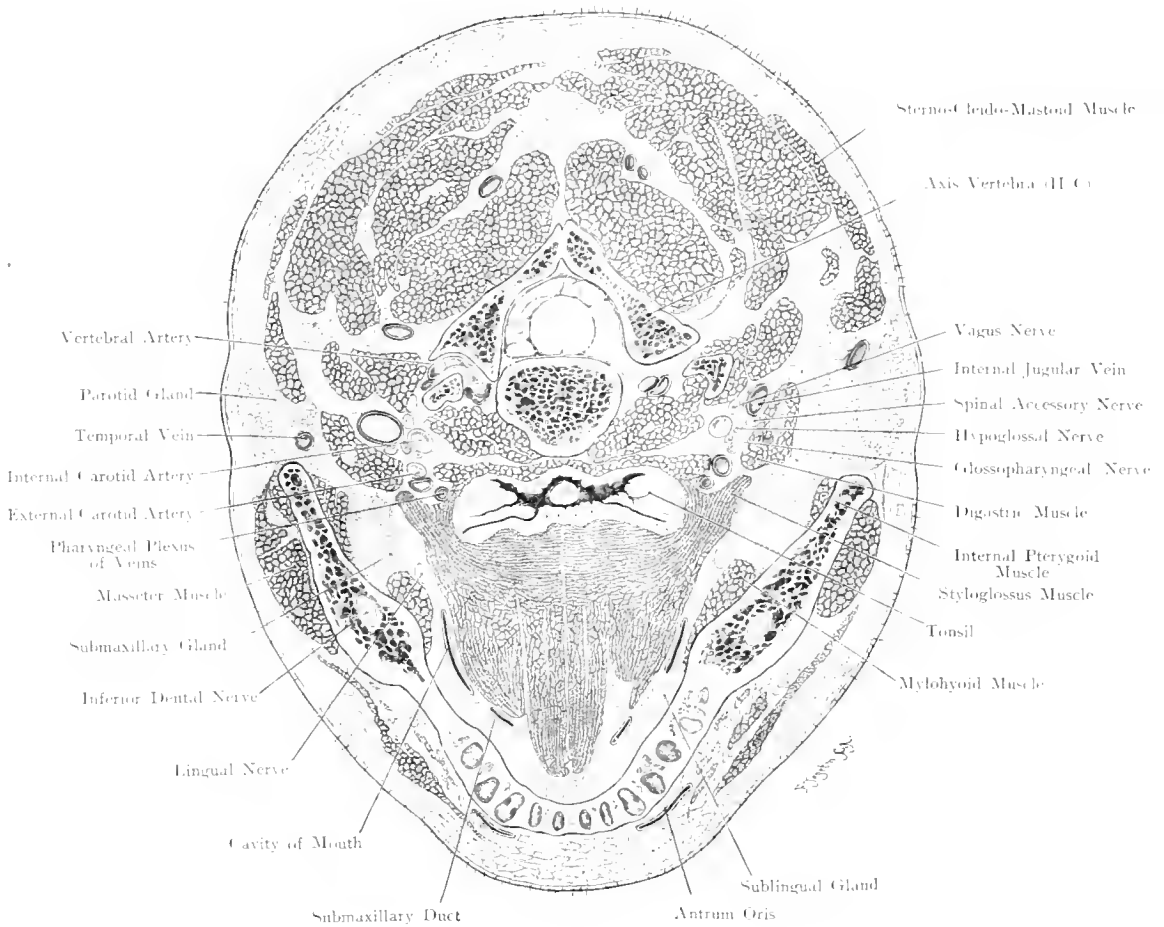


Fig. 53. Horizontal Section through the Head at the level of the Axis.

Seen from below. $\frac{2}{13}$ Nat. Size.

Fig. 53. Horizontal Section through the Head at the level of the Axis.

One of a series of frozen sections through the head

The Vestibule of the Mouth and the Buccal Cavity have only been cut at their lowest points, where the tongue is adherent to the floor of the mouth. Of the 3 salivary glands (Sublingual, Submaxillary and Parotid) the last is of interest because it extends far inwards, and, on the left side of the figure, even forwards under cover of the lower jaw. The tip of the Uvula was cut by this section.

The Tonsil is divided below its middle: it lies in a capsule which is closely connected with the muscles of the Pharynx. Very important are the parts around the tonsil, in deciding the question of the source of furious hæmorrhage in some cases of tonsillotomy? We mentioned that the Tonsillar Branch of the Ascending Palatine Artery is far too small to cause serious hæmorrhage. Of the large vessels, the Internal Carotid which is said to have been wounded during the operation, lies $\frac{3}{4}$ inch away from the tonsil. It could only be injured when a particularly clumsy surgeon cuts very deeply. This statement also holds good for the External Carotid. It is the Facial Artery which lies very near the tonsil and may be injured (MERKEL). This vessel arises from the External Carotid at the level of the lower end of the tonsil, passes between the muscles coming from the Styloid Process, describes an S-shaped curve and runs along the circumference of the tonsil. Serious hæmorrhage may also be due to injury of the Pharyngeal Venous Plexus.

Externally and behind the Tonsil the following structures are in close relation: Internal Carotid Artery, Internal Jugular Vein, 9th, 10th, 11th. Cranial Nerves and Hypoglossal Nerve, all lying in one sheath which is attached above to the fibro-cartilage of the posterior lacerated foramen.

The Vertebral Artery having arisen from the Subclavian runs upwards, passing through the foramen in the transverse processes of the upper 6 Cervical Vertebrae. Then curving horizontally backwards — this part of its course is shewn on the left side of our figure — it comes to lie under the Dura Mater which it pierces. (Cf. Fig. 15.) It now lies in the cranial cavity on the side of the bulb, and after running inwards it joins with its fellow to form the Basilar Artery.

General Remarks on the Jugular Veins.

A large share of the venous blood is carried from the Head and the Neck to the Heart by Veins which have a separate course and do not correspond exactly to any artery. These veins are termed Jugular Veins. To the Internal Carotid corresponds more or less the Internal Jugular; to the External Carotid, the External Jugular, formed by the union of Temporal and Facial Veins. The Facial Vein may also be continued downwards as the Anterior Jugular Vein. There may further be a Posterior Jugular Vein (cf. Fig. 67) at the anterior border of the Trapezius Muscle.

The relation of these veins to the Sterno-Cleido-Mastoid is as follows: the External Jugular crosses the outer surface of the muscle which, with its inner surface, covers the Internal. Along the Anterior border runs the Anterior Jugular. The Posterior Jugular is the least constant of these vessels.

All these veins end under cover of the Sternomastoid, where the large Lymphatic Channels open into the Venous System. The Anterior Jugular Veins communicate just above the clavicle by a transverse anastomotic branch.

Fig. 54. Position of Spinal Cord and Spinal Nerves in the Spinal Canal.

The Skull and the Spinal Canal of a female child, a few months old, have been opened from behind; the Dura Mater slit open; and the ribs with the transverse processes of the vertebrae dissected out.

The spinal cord, is, as a whole, very well protected. Anteriorly, it lies at a great distance from the surface of the body; behind, a very thick mass of muscles fills the space between the vertebrae and the prominent spinous processes (cf. the transverse section through neck, thorax and abdomen). The spinal canal, in which the cord lies, is closed completely in front by the bodies of the Vertebrae and the Intervertebral Discs; behind there is a space between the neural arches through which a knife, dagger or other sharp instrument (e. g. for Lumbar Puncture) may enter. These interlaminar spaces are widest in the cervical region where the neural arches are furthest apart; this explains why the spinal cord is more frequently injured by sharp weapons in this region than in any other part. In the upper dorsal region, the neural arches overlap each other and thus almost close the spinal canal posteriorly. In the lumbar region the arches are very broad and thus afford protection to the cord.

The close relation of the cord to the column accounts for the frequent injury to the Cord in fractures of the Spinal Column. These fractures are usually indirect, and occur chiefly where a comparatively movable portion joins a more fixed portion; i. e. at the 5th and 6th Cervical and at the 12th Dorsal and 1st Lumbar Vertebrae.

The Dura Mater does not lie on the wall of the Spinal canal; a cushion, formed by fat, and a large venous plexus lie between the bone and the meninges. Between the Dura Mater and the Cord lies the Arachnoid Sac filled with cerebro-spinal fluid; these arrangements allow the cord to follow the movements of the Column, without friction against the bone.

As the upper limit of the spinal cord, the upper border of the posterior arch of the Atlas, is usually taken, i. e. the point where the first Cervical Nerve emerges. The cord shews two fusiform enlargements in the regions where the nerves to the extremities leave it. The direction of these enlargements is more in the transverse than in the antero-posterior diameter. The upper or Cervical enlargement is most marked between the 5th and 6th Cervical Vertebrae, the lower or Lumbar is most marked at the 11th Dorsal Vertebra. The cord then becomes more slender, ending in the Conus Terminalis which lies at the level of the 1st or 2nd Lumbar Vertebra. A filiform continuation of the Conus Terminalis, called the Filum Terminale, runs vertically downwards to the periosteum of the Coccyx.

The 31 pairs of Spinal Nerves leave the Spinal Canal through the Subvertebral Foramina, ensheathed in processes of Dura Mater. This explains why



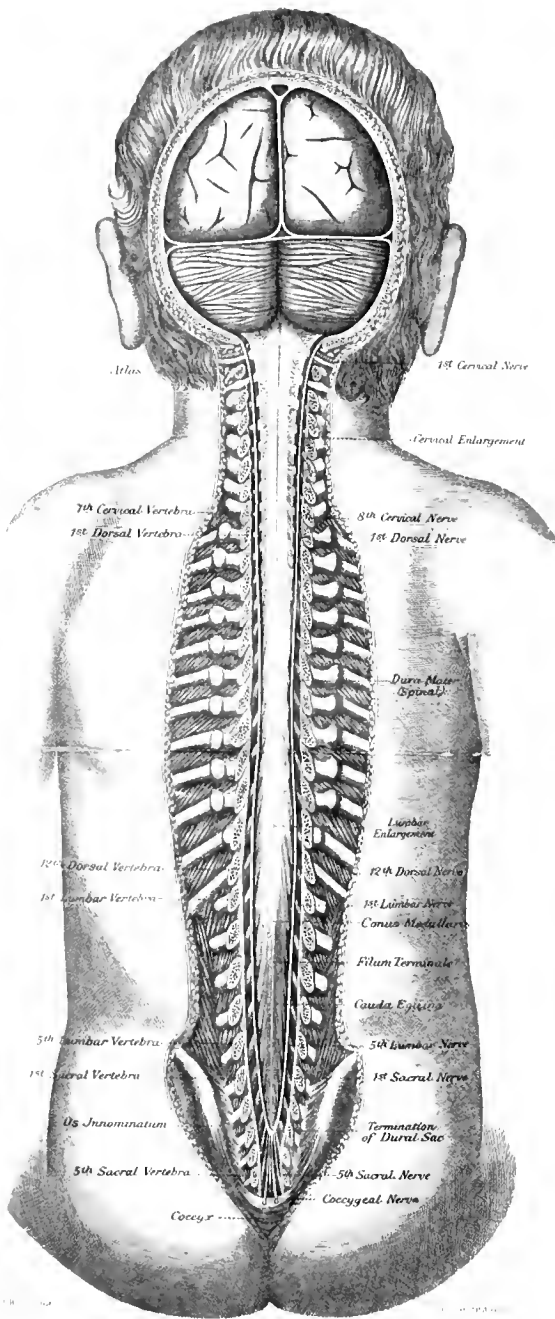


Fig. 54 Position of Spinal Cord in the Vertebral Canal
Natural Size

(Continuation of the text of Fig. 54.)

in our figure, the nerves appear thicker outside than inside the dorsal sac. As the spinal cord ends at the 1st or 2nd Lumbar Vertebra, the course of the spinal Nerves inside the caudal becomes longer the lower their origin. Thus the first Cervical Nerve runs horizontally outwards, the course of the next nerve is more oblique etc; the lowest nerves run almost vertically downwards, parallel to the Filum Terminale. They form with this last mentioned structure and the Conus Terminalis, the so-called Cauda Equina. Injury below the second Lumbar Vertebra, therefore, only involves the Cauda Equina, not the spinal cord.

The spinal nerves arise by 2 roots, anterior and posterior; these roots leave the cord as root-fibres. As a rule, the posterior roots are thicker than the anterior; an exception is, however, found in the 1st Cervical Nerve — as shewn in our figure —. Its posterior root-fibres are very slender; they may even be absent.

On every posterior root is a spinal ganglion, which lies in the intervertebral foramen; the posterior and anterior roots join outside. Just above the 1st Cervical Nerve our figure shews the Vertebral Artery leaving the foramen in the transverse process of the Atlas and running horizontally inwards. It then pierces the Dura Mater and enters the cranial cavity. The Dura Mater does not extend further down in the Spinal Canal than to the level of the 2nd Sacral Vertebra in the adult, and to the 3rd Sacral Vertebra in the child (cf. figure). It ends in a blind sac (cf. Fig. 55). These levels are of great importance, because injury or operation above will necessarily open the dural sac and may be followed by purulent Meningitis which is usually fatal. Below there is no danger of Meningitis. This fact is taken advantage of in operations (KRASKE'S) in which portions of the Sacrum are removed, in order to expose pelvic organs. Of course, when removing portions of this bone, temporarily or permanently, one has to consider the important nerves which should not be damaged. The Coccygeal Nerve which emerges between the 1st and 2nd piece of the Coccyx forms with a branch of the 5th Sacral Nerve the Coccygeal Plexus which innervates the Skin over the Coccyx. The 4th and 5th Sacral Nerves enter into the formation of the Sacral Plexus, the former supplying the Levator Ani and Coccygeus Muscles is more important than the latter. Damage to the Sacral Plexus means damage to the floor of the Pelvis. Twigs from it also go to the Bladder and Rectum. The higher up one goes, the more important are the nerves for the innervation of the pelvic muscles, pelvic organs, and lower limbs (Great Sciatic Nerve).

Fig. 55. Lower End of Spinal Canal in the Adult.

A Figure combined after a specimen from a man of 18, and several skeletons. On the right, bones only, on the left, ligaments and nerves have been drawn diagrammatically.

The anatomical relations make it possible to introduce a trocar or a hollow needle from behind, between 2 neural arches, into the dorsal sac, thus enabling one to increase the pressure of the cerebrospinal fluid in the sac, and to draw off some of the fluid for chemical and microscopical examination. This operation — lumbar puncture — has become of vast importance for diagnostic purposes in recent years.

Not only does it yield information as to the condition of the fluid around the spinal cord, but also as to the intra-ventricular pressure, the pathological changes and the presence of bacteria in the cerebral fluid, because these fluids communicate through the Foramen of MAGENDIE at the floor of the 4th Ventricle.

The lowest portion of the dural sac is selected for lumbar puncture, because the needle cannot, at that point, injure the spinal cord; it meets the Cauda Equina which gets pushed out of the way. The needle should be introduced below the 3rd or 4th Lumbar Vertebra. The vertebra may be found by counting the spinous processes downwards from the 7th Cervical Vertebra, or by counting downwards from the attachment of the 12th rib. A far more simple method — (cf. figure) — consists in drawing a line connecting the highest points of the Iliac Crests. This line crosses the middle of the 4th Lumbar Vertebra. Slightly above it, therefore, is the spinous process of the 3rd. In children, the needle may be introduced exactly in the middle line at the lower border of the spinous process; in adults, it should be introduced $\frac{2}{3}$ ths inch outside the middle line, because the strong median ligaments offer considerable resistance.

If one follows the usual rule, introducing the needle at the level of the lower border of the spinous process and then pushing it forwards, upwards, and inwards, one may come on to bone, especially when the spinous process is short, (this was the case in our specimen). It is infinitely better to introduce the needle horizontally inwards.

In the figure, "Point for Lumbar Puncture" indicates the spot on the skin, at which the needle should be introduced and then pushed inwards.

In children the needle has to enter about one inch, in adults $1\frac{1}{5}$ to $2\frac{1}{5}$ inches.

This figure also shews the Dural Cul-de-sac at the 2nd Sacral Vertebra. The importance of this level has been discussed in Fig. 54, Text.

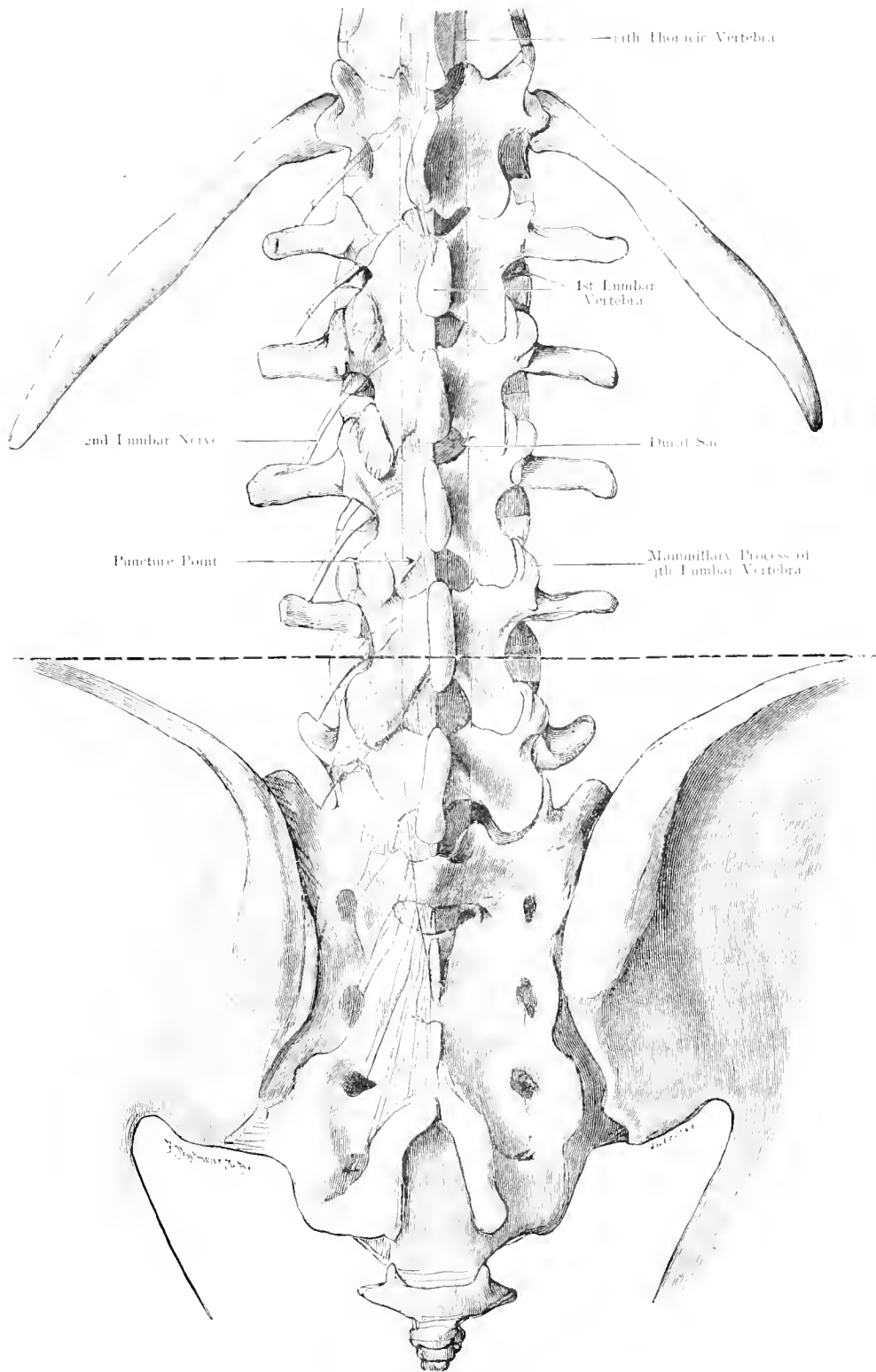


Fig. 55. Lower End of Spinal Canal in the Adult.

$\frac{2}{3}$ Nat. Size.

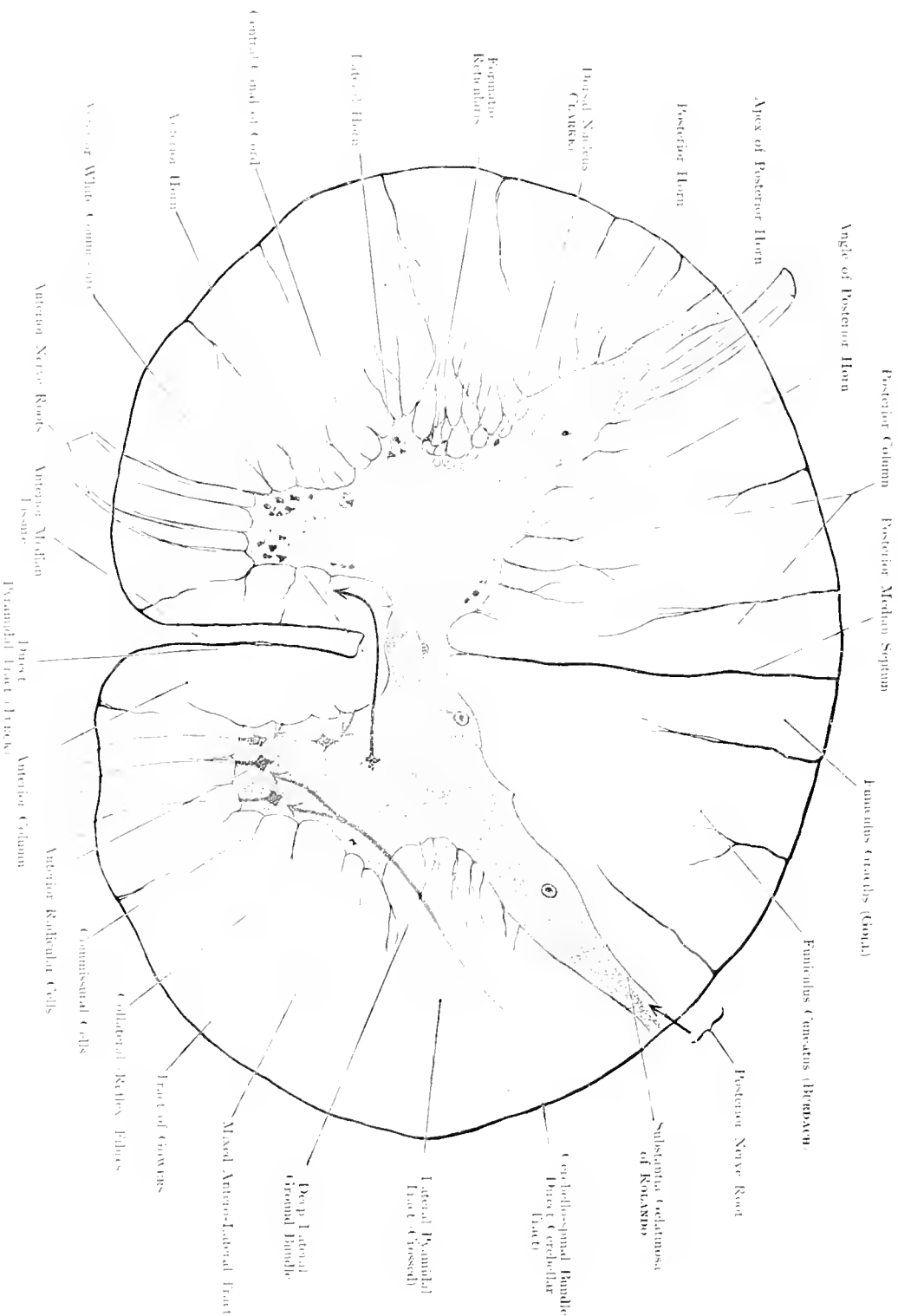


Fig. 56. Diagram of Transverse Section of the Spinal Cord.

Enlarged 13 times. — By Prof. ZIMMERN.

Fig. 56. Diagram of Transverse Section of the Spinal Cord.

This figure shows a transverse section through the dorsal region of the spinal cord. In the anterior median fissure lies a continuation of the Spinal Vira Mater. At the entrance into this fissure lies the Anterior Spinal Artery which sends many branches into the fissure in order to supply the central portions of the cord, there is no corresponding fissure on the dorsal aspect; only in the upper cervical region, lumbar enlargement, and conus terminalis there may be an indication of a fissure. The Anterior root-fibres are Motor and arise exclusively from the anterior-root cells of the anterior horn of the same side. The Posterior root-fibres are Sensory; the greater part enter the cord internal to the apex of the posterior horn; whence they run either

- a) in the posterior column of the same side as far as the bulb, (these are the long fibres (red);
 - b) to CLARKE'S column of the same side, i. e. a group of cells at the base of the posterior horn, where they arborize around the neurons of this column (orange);
 - c) to anterior root-cells either of the same or of the opposite side (reflex fibres, yellow);
 - d) to posterior root-cells around which they arborize.
- The following main tracts can be distinguished in the white matter of the cord:

- 1) Path of Voluntary Movement, the Pyramidal Tract, which arises from the Motor Area of the Cortex, the majority of fibres decussate in the bulb and run downwards in the lateral column of the opposite side (Crossed Pyramidal Tract). The minority descend in an anterior column of the same side (Direct Pyramidal Tract). It is probable that the crossed tract chiefly innervates the extremities, and the direct the trunk. This would explain why the direct tract is frequently much diminished or even absent above the lumbar enlargement. Both Pyramidal Tracts finally arborize around the neurons of the anterior horn — some of the direct pyramidal fibres after having crossed the middle line —. The anterior root-fibres are thus the physiological continuation of the Pyramidal Tracts. They have therefore all been coloured blue.

- 2) Path of Muscular Sense (Sense of Position and Movement), this occupies the greatest portion of the posterior column. Only the ventral zone of this column and the area adjacent to the posterior median septum, seem to contain other fibres, which are not indicated in the figure. The Path of Muscular Sense is the direct continuation of the posterior root fibres (vide supra). These fibres enter the Tract of BURDACH, but become pushed, by new fibres entering at a higher level, to the inner side and thus into the Tract of GOLL. In the upper Cervical region, the Tract of GOLL therefore contains chiefly fibres from the lower, and the Tract of BURDACH fibres from the upper extremity. These tracts do not decussate; they end in the bulb in the Gracile and Cuneate Nuclei.

- 3) Path of Conscious Cutaneous Sensation, arises probably from the cells of the posterior horn and runs partly on the same side, partly crosses the middle line. It is yellow in the figure and lies probably in the deep lateral ground bundle as indicated by FLETCHER; for embryological reasons, and perhaps also in the mixed Antero-Lateral Tract. It is highly probable that this path is interrupted at various places in its course to the brain.

- 4) The Direct Cerebellar Tract, also centripetal, comes from CLARKE'S Column. Its fibres run through the Lateral Column transversely, and become collected at its postero-external border. They pass upwards, without decussation or interruption, to the Cerebellum.

- 5) GOWERS' Tract lies at the anterior margin of the lateral column and appears to be very similar to the direct cerebellar, these fibres are also centripetal passing to the Cerebellum, its origin is unknown.

The white commissure contains, apart from the fibres of the Direct Pyramidal Tract, which cross the middle line, fibres which come from the so-called Commissural Cells of the Anterior Horn and go to the anterior column of the opposite side. Their termination and their field of junction are not yet definitely known; this statement also holds good for the lateral horn.

Fig. 57. Region of the Neck, from in front.

Fig. 58. Region of the Neck, from the Side.

The Neck, which extends from the lower border of the lower jaw to the clavicle, and from the external occipital protuberance to the 7th Cervical Vertebra, may be divided into 3 regions, 1 paired and 2 unpaired: Anterior, Posterior and 2 Lateral regions. The anterior region of the Neck lies between the 2 Sterno-Cleido-Mastoid Muscles; the lateral regions, between these muscles and the Trapezius; the posterior corresponds to the area covered by the Trapezius, as far down as the spinous process of the 7th Cervical Vertebra (Vertebra Prominens).

The anterior cervical region extends from the lower jaw to the upper border of the Sternum. This region may be subdivided into Submaxillary, Hyoid, Sub-hyoid (between the hyoid bone and the upper border of the thyreoid cartilage), Laryngeal, Tracheal (which the B. N. A. subdivided into Thyreoid and Suprasternal) regions and Suprasternal notch. The area between the lower jaw, Omohyoid and Sterno-mastoid Muscles forms a Δ which may be subdivided into a Digastric Δ and a Carotid Δ . (The small space between the ramus of the lower jaw and the origin of Sterno-Mastoid Muscle belongs to the head.)

Anatomists' opinions differ as to whether the broad Sterno-Mastoid should be regarded as a boundary line or as a special (Sterno-Cleido-Mastoid) region. In any case the parts described in the regions bounded by this muscle lie deep to it (vide infra). Between the Sternal and Clavicular heads of this muscle there may be a little fossa (Fossa supraclavicularis minor).

From the lateral cervical region a Δ is cut off by the inferior belly of the Omohyoid (Inferior Δ of the neck). The boundaries of this Δ are formed by the Clavicle, Sterno-Mastoid and Omohyoid Muscles. When the Sterno-Mastoid is very broad, or present as Sterno-Cleido-Mastoid, if the Trapezius extends far forwards (in some cases touching the Sterno-Cleido-Mastoid), then this Δ will be very small or even absent.

This Δ is made larger — e. g. for ligaturing the Subclavian Artery —, by pressing the Clavicle (arm) downward and (if necessary), cutting the Omohyoid.

A portion of the posterior Cervical Region may be termed, Regio-Nuchae.

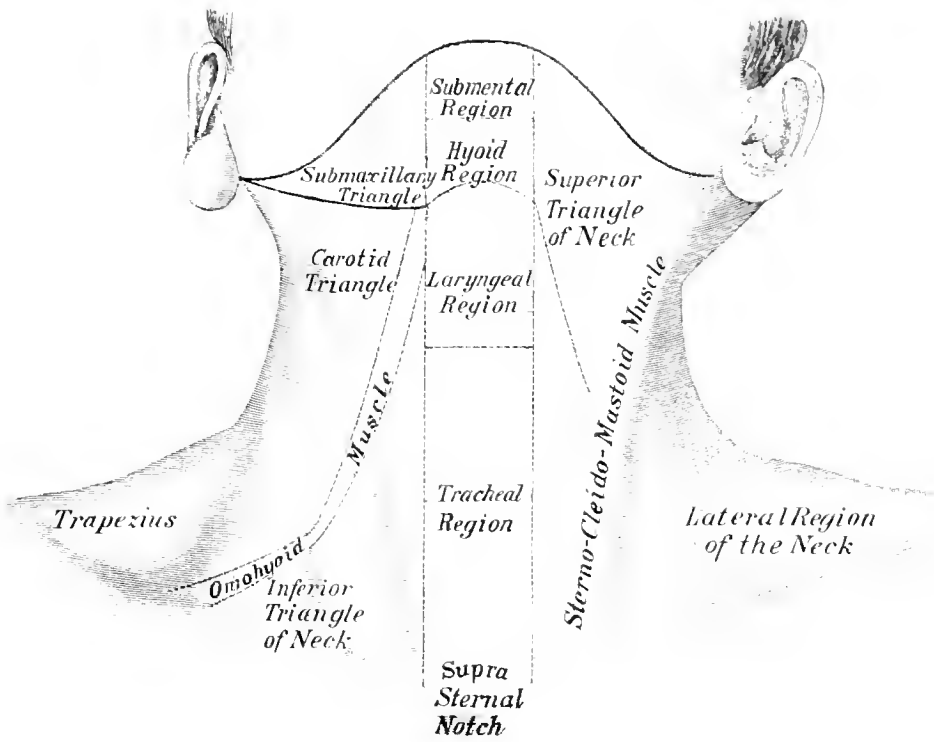


Fig. 57. Region of the Neck, from in front.
 1/2 Nat. Size.

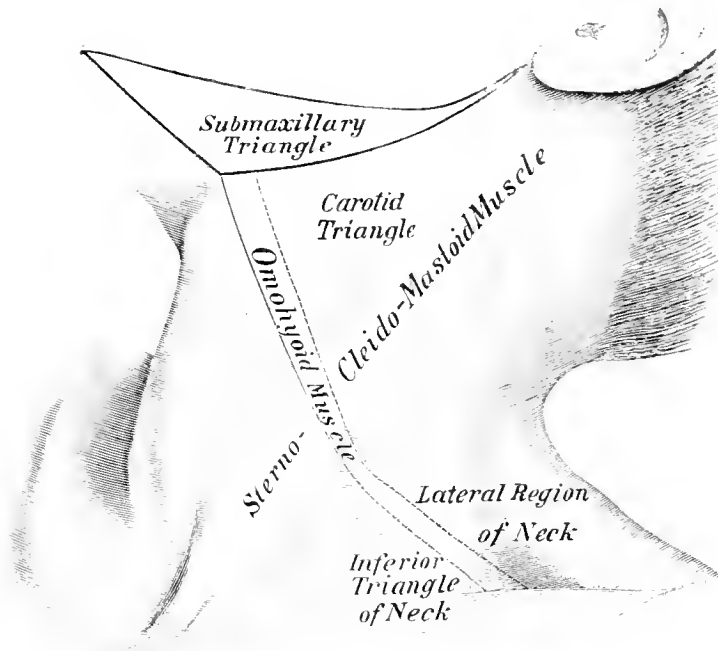


Fig. 58. Region of the Neck, from the Side.
 1/2 Nat. Size.

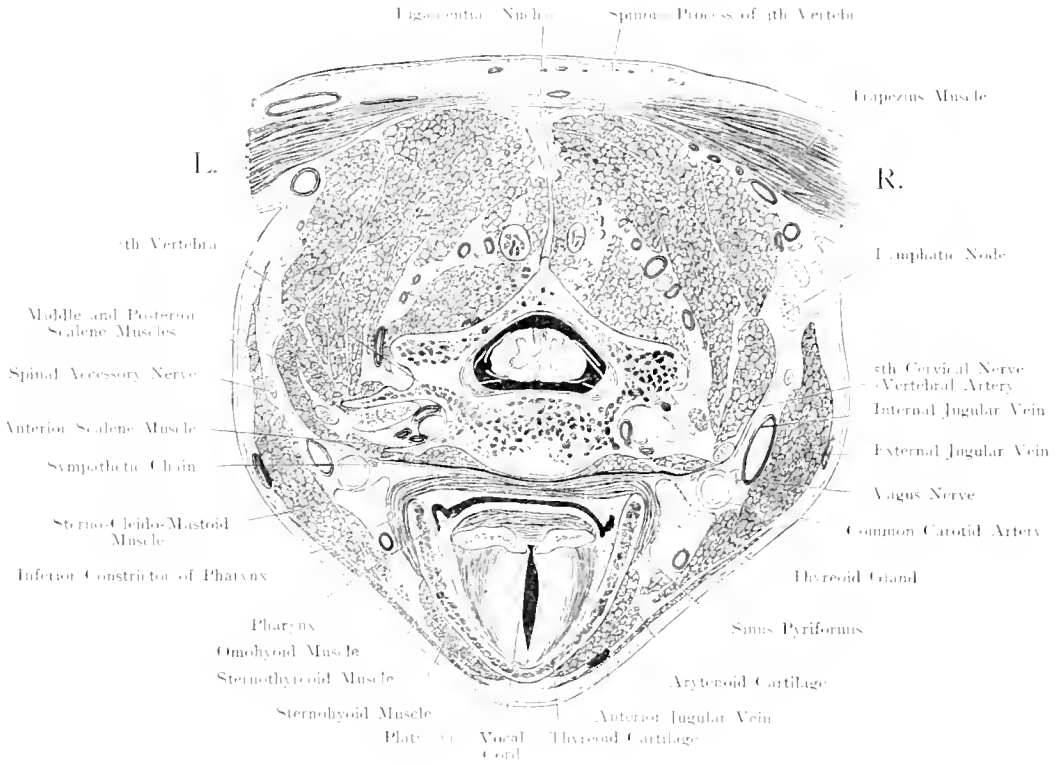


Fig. 59. Transverse Section through the Neck at the level of the Fifth Cervical Vertebra.

Seen from below. — $\frac{1}{4}$ Nat. Size.

Fig. 59. Transverse Section through the Neck at the level of the Fifth Cervical Vertebra.

Frozen Section.

This figure shews that all the important structures, Large Vessels, Nerves, Thyroid Gland, Food and Respiratory passages are in close apposition in the anterior part of the neck whereas the largest spaces, external and posterior to the vertebral column, are almost completely occupied by powerful muscles.

In front lies the Larynx with the Subcutaneous Pomum Adami. Its position can, therefore, easily be made out. This section passes exactly through the Vocal Cords; between these the Glottis is continued backwards to a certain extent between the vocal processes of the Arytenoid Cartilages. These cartilages are joined by the Aryteno-Arytenoideus Muscle; immediately behind and below this muscle lies the lowest portion of the Pharynx which presents here the Recessus Pyriformis on either side. These recesses extend forward for some distance under cover of the thyreoid cartilage. In a cross-section, the Pharynx, and its continuation, the Oesophagus, which is usually taken as commencing at the 5th Cervical Vertebra, appear as a transverse slit, when empty.

In front of the Vertebral Column and the Longus Colli Muscle which lies upon it, is the strong Prevertebral Fascia. This fascia is separated from the muscles of the Pharynx and Oesophagus by loose connective tissue in the meshes of which Retropharyngeal Abscesses readily spread downwards.

External to the larynx is shewn the apex of the lateral lobe of the Thyreoid Gland with the large Superior Thyreoid Artery which has just entered the substance of the gland. The Thyreoid Gland lies on the Common Carotid Artery, which at the point of section is covered completely by the Sterno-Cleido-Mastoid Muscle (cf. Fig. 60, text). External to the Carotid Artery, and somewhat posterior lies the Internal Jugular Vein (the right vein is usually larger than the left, cf. Fig. 15, text, Explanation of Lateral Sinus). Between the Artery and Vein and somewhat posterior runs the Vagus Nerve. The Cervical Sympathetic Trunk is in apposition with the posterior part of the inner wall of the Common Carotid Artery.

The foramen in the transverse process has been cut in such a way that it does not appear as a closed ring. In it run the Vertebral Artery and its Venae Comites. The 3rd Cervical Nerve which has just left its intervertebral Foramen appears very thick, owing to the obliquity of its section.

Between the posterior border of the Sterno-Cleido-Mastoid and the Anterior border of the Trapezius, lie the superficial cervical lymphatic glands.

Fig. 60. Anterior Aspect of the Neck, Superficial Layer. Adult.

The Head is strongly inclined backwards. Platysma and part of the superficial cervical fascia covering the right Sterno-Mastoid Muscle have been removed. The right Sterno-Mastoid Muscle has therefore dropped backwards.

Under the skin lies the Platysma, which, converging from both sides, only reaches the middle line at the chin; it therefore does not cover the anterior cervical region. Deep to it is the superficial layer of the cervical fascia which is important because it pulls the Sterno-Mastoid Muscles towards the Middle line. When the fascia is divided, — as necessary for dissecting purposes — these muscles drop backwards and outwards. They cover, as is well seen, in Fig. 59, when in their natural position, the large vessels of the neck at a much higher level, than after division of the fascia.

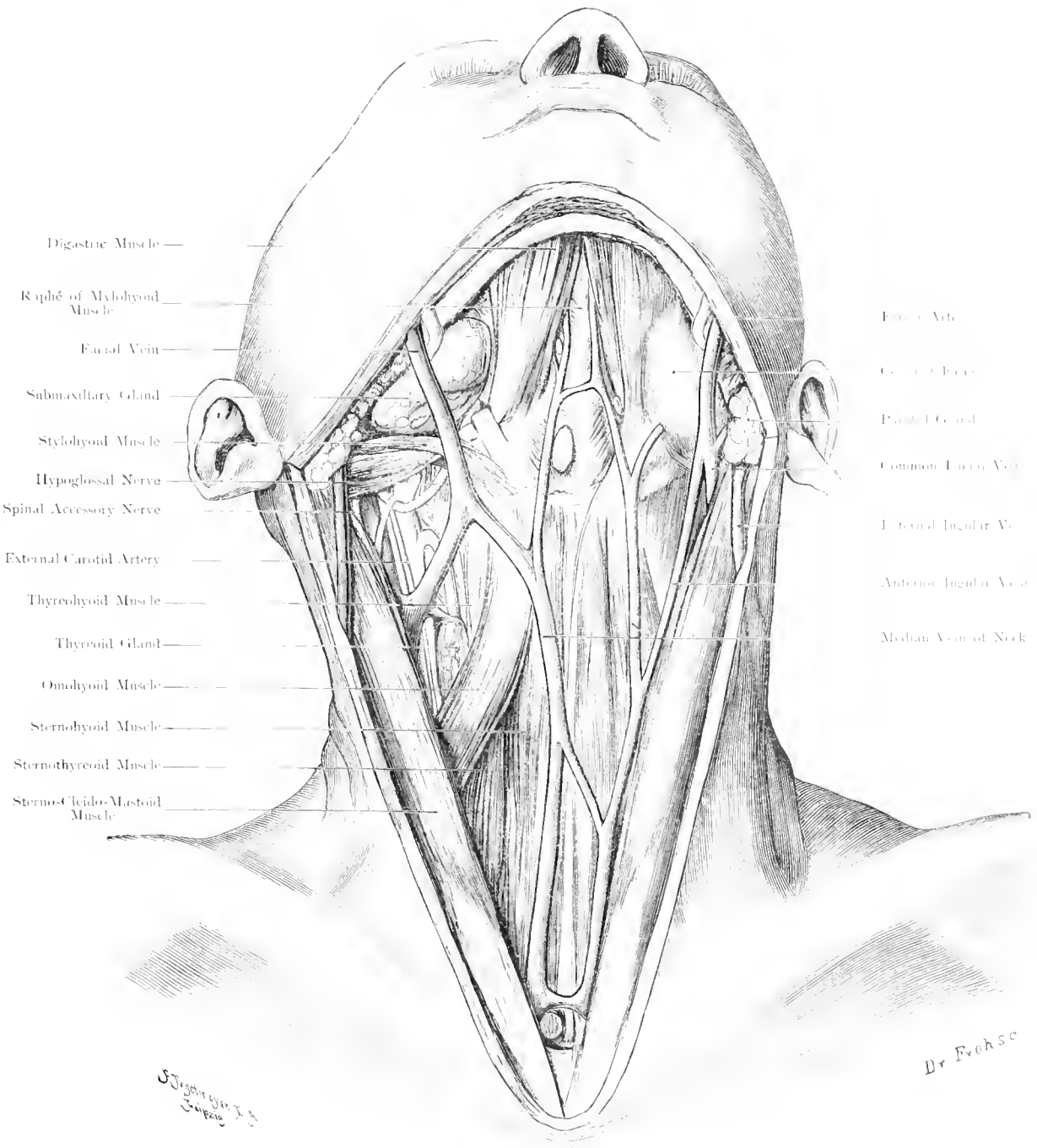
The Anterior Jugular Veins, anastomosing above with the Facial Vein, end below in the jugular venous arch which connects the 2 External Jugular Veins. This communication usually passes behind the Sterno-Cleido-Mastoid Muscles. In some cases, the Anterior Jugular Veins terminate by joining one of the Jugular Veins.

The next layer comprises the Infrahyoid Muscles; the Sterno-Hyoid converging above, the Sterno-Thyreoid, converging below. Thus, in the middle line a space is formed which is broadest ($\frac{3}{5}$ inch) at the mid-point between the Hyoid Bone and Sternum. The deep cervical fascia envelopes these muscles and covers in this space. When this fascia is divided, the muscles mentioned sink downwards and outwards, thus exposing Larynx, Isthmus of Thyreoid Gland and Trachea.

In the Submaxillary Region the anterior bellies of the Digastric Muscles converge towards the chin; between these the Mylo-Hyoid Muscles and their median raphé are visible; our figure shews a lymphatic gland in this region, which is not uncommon. The attachment of the intermediate Tendon of the Digastric to the Hyoid Bone varies; it is either bound down by an aponeurotic continuation of the Fascia of the muscle which is fixed to the hyoid bone, or the anterior belly arises partly from the hyoid bone, either in a tendinous or in a muscular origin.

The distance between the intermediate tendon and the hyoid bone also varies; thus the distance is much greater in this figure than in Fig. 63.

Bursae are met with occasionally over the Pomum Adami and the space between the Thyreoid Cartilage and the Hyoid Bone.



Digastric Muscle —
 Raphe of Mylohyoid Muscle —
 Facial Vein —
 Submaxillary Gland —
 Stylohyoid Muscle —
 Hypoglossal Nerve —
 Spinal Accessory Nerve —
 External Carotid Artery —
 Thyrohyoid Muscle —
 Thyroid Gland —
 Omohyoid Muscle —
 Sternohyoid Muscle —
 Sternothyroid Muscle —
 Sternal-Cleido-Mastoid Muscle —

Facial Artery —
 Common Carotid Artery —
 Internal Carotid Artery —
 Common Facial Vein —
 Internal Jugular Vein —
 Anterior Jugular Vein —
 Median Vein of Neck —

Fig. 60. Anterior Aspect of the Neck, Superficial Layer. Adult.
 $\frac{3}{4}$ Nat. Size.

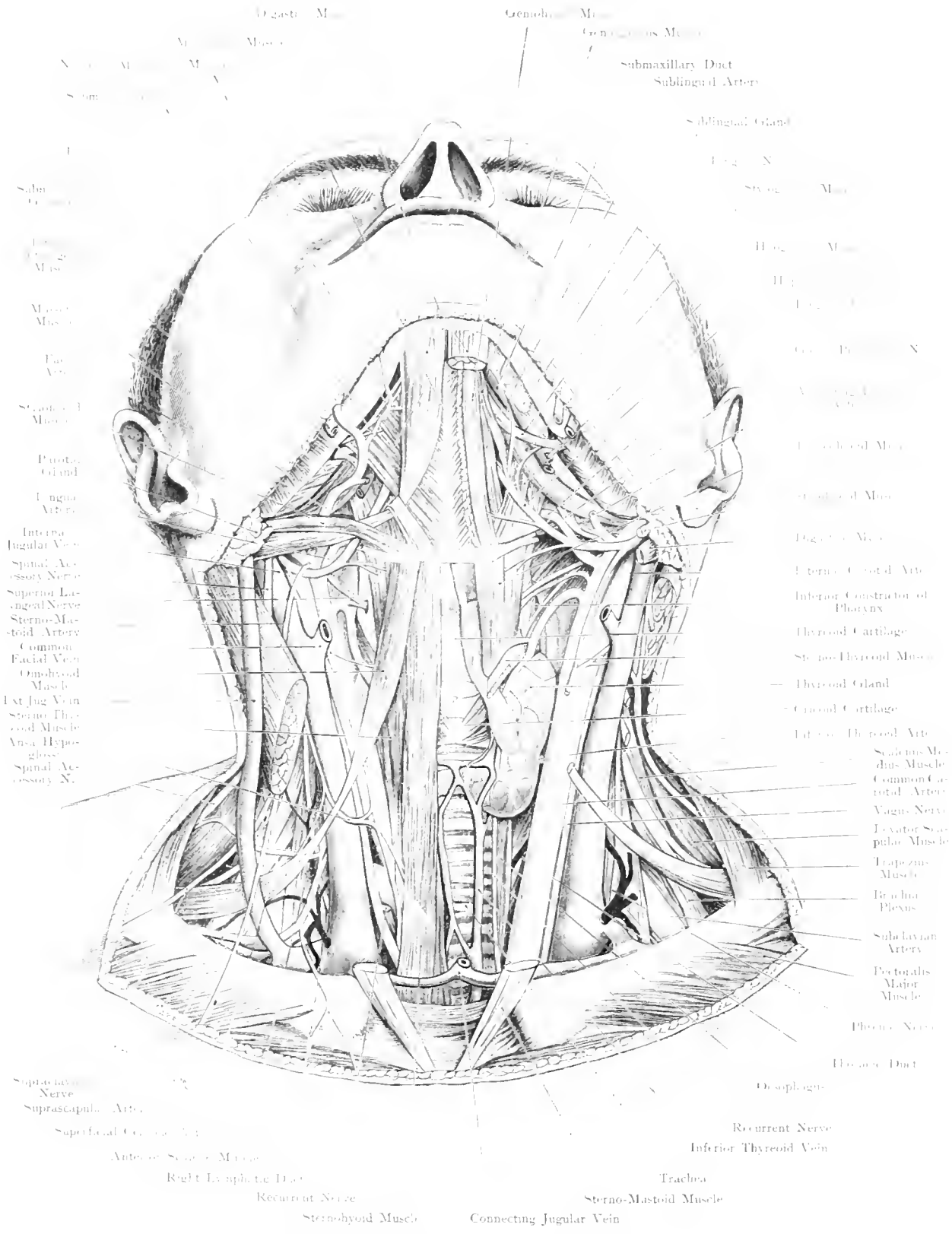


Fig. 61. Anterior Aspect of the Neck, Deep Layer. Adult.

1/4 Nat. Size.

Fig. 6r. Anterior Aspect of the Neck, Deep Layer. Adult.

Position of the head as in last figure. The Superficial Veins are left as stumps, both Sterno-Cleido-Mastoid Muscles are cut off near their attachments; on the left side, Sterno-Hyoid, Sterno-Thyreoid and upper belly of Omo-Hyoid Muscles have been removed. Both Submaxillary Glands have been taken away: removal of the right Digastric Stylo-Hyoid and Mylo-Hyoid Muscles has given a good exposure of the floor of the mouth from below.

The Common Carotid Artery enters the neck behind the Sterno-clavicular articulation, externally to Trachea and Oesophagus. Slightly inclined outwards at first, it soon runs vertically upwards, without giving off any branches. At the level of the upper border of the Thyreoid Cartilage, it divides into External and Internal Carotid (just below the bifurcation, is the most suitable spot for ligaturing the Common Carotid, because it lies superficially here being covered only by skin, Platysma and Superficial Cervical Fascia). When the fascia is incised, the Sterno-Cleido-Mastoid Muscle drops backwards. External to the Artery lies the Internal Jugular Vein, which, when filled, covers the outer aspect of the Artery. It receives the Superior Thyreoid Vein and, above the bifurcation of the Carotid, the Facial Vein; the Carotid Artery and Jugular Vein are enclosed in a common fascial sheath (Carotid sheath); they are crossed by the Omo-Hyoid which runs downwards and outwards. In front of them lies the Descendens Hypoglossi. Between the Artery and Vein, somewhat posteriorly above, but more anteriorly below runs the Vagus Nerve. External to the Jugular Vein, the Phrenic Nerve descends on the Scalenus Anticus Muscle.

The size of the Thyreoid Gland varies considerably according to the frequency of Goitre in certain districts. The isthmus connecting the 2 lobes lies on the trachea, covering the 2nd, 3rd and 4th rings. It may, however, extend higher up or lower down (cf. Fig. 62). It often gives off a process upwards, the Pyramidal Lobe (Pyramid of LALOUETTE); this lobe, as shewn in our figure, may also arise from one of the lateral lobes; it often runs to the Hyoid bone. The isthmus, being fixed to the trachea by connective tissue, follows the movements of that organ. This is of importance in the diagnosis of tumours of the Neck. The lateral lobes are covered by the Sterno-Hyoid, Sterno-Thyreoid and Omo-Hyoid Muscles. Their size varies markedly. They receive blood from the Superior Thyreoid Artery a branch of the External Carotid and from the Inferior Thyreoid Artery, which arises from the Subclavian and runs upwards behind the Common Carotid.

The Larynx is subcutaneous, the Trachea lies under the skin at its commencement but runs to a deeper level the nearer it approaches the Thorax. In front of its upper portion is the Thyreoid Gland; lower down, fatty tissue; at this point the Thymus is just visible above the sternum in children.

Fig. 62. Front View of the Neck, Deep Layer. Child.

Child a few months old; head inclined backwards. On the left side, the superficial structures are displayed after removal of the Platysma; on the right side, the Sterno-Cleido-Mastoid has been cut off near its attachment. The Sternum has been removed between the middle of the Manubrium and the base of the Xiphoid, and with it the 2nd, 3rd, 4th, 5th, 6th Costal Cartilages.

The chief difference in this part between the adult and the child, is the Thymus which is large in the latter. This gland continues its development till the 2nd year, then degenerates or remains stationary till puberty. After puberty, it disappears rapidly; its lobes undergo fatty degeneration; there are, however, always masses of fat containing a few remains of this glandular tissue present even in the adult. The shape of the gland varies much. There are usually 2 longitudinally placed lobes which are pointed above. The limits of the gland are: the level of the 3rd rib, and the lower border of the Thyreoid Gland. Below the Thymus is in relation with the Pericardium, its middle portion is covered by the Sternum; between its outer portion and the thoracic wall, the pleural cavity and the lungs find their way. Above the pericardium, this gland is an anterior relation of the Arch of the Aorta, Superior Vena Cava and Innominate Veins. At a still higher level, it lies on the Trachea, being separated from the skin by Sterno-Hyoid and Sterno-Thyreoid Muscles; at this point it becomes an internal relation to the Innominate Artery, Carotid Artery and Internal Jugular Vein.

This figure also shews some of the Lymphatic glands of the Neck and Thorax.

The chief lymphatic channel, the Thoracic Duct, commences in the abdomen, usually opposite the 1st Lumbar Vertebra (Receptaculum Chyli, cf. Fig. 141). It runs vertically upwards on the right of the Aorta, passing through the Diaphragm, and lying in the Thorax between the Aorta and Great Azygos Vein. Opposite the body of the 7th Cervical Vertebra it arches over the left Subclavian Artery and opens into the left Subclavian Vein (cf. Fig. 67). The corresponding structure on the right is the short right Lymphatic Duct which opens into the right Subclavian Vein. The great lymphatic channel on the right side is formed by the junction of the Bronchial, Mediastinal, Jugular and Subclavian Lymphatics; on the left, the Thoracic Duct receives the left Jugular and Subclavian Lymphatics which carry the lymph from the head and upper extremity. These last mentioned channels may open separately into the veins.

Between the 2 bellies of the Digastric the Submental Glands are shewn; on the Submaxillary Gland, the Submaxillary Lymphatic Glands are visible; at a lower level on the Internal Jugular Vein the Superficial Cervical Glands are seen (more about this group in Fig. 63, text).

On the left side, some of the Inferior Deep Cervical Glands (cf. Fig. 115, text), and finally the Sternal Glands are shewn. These lie near the Internal Mammary Artery and its Venae Comites but are not found in all the interspaces. Their efferent vessels go to the mediastinal glands, to the great lymphatic ducts and to the lymphatics of the neck (cf. Fig. 115).

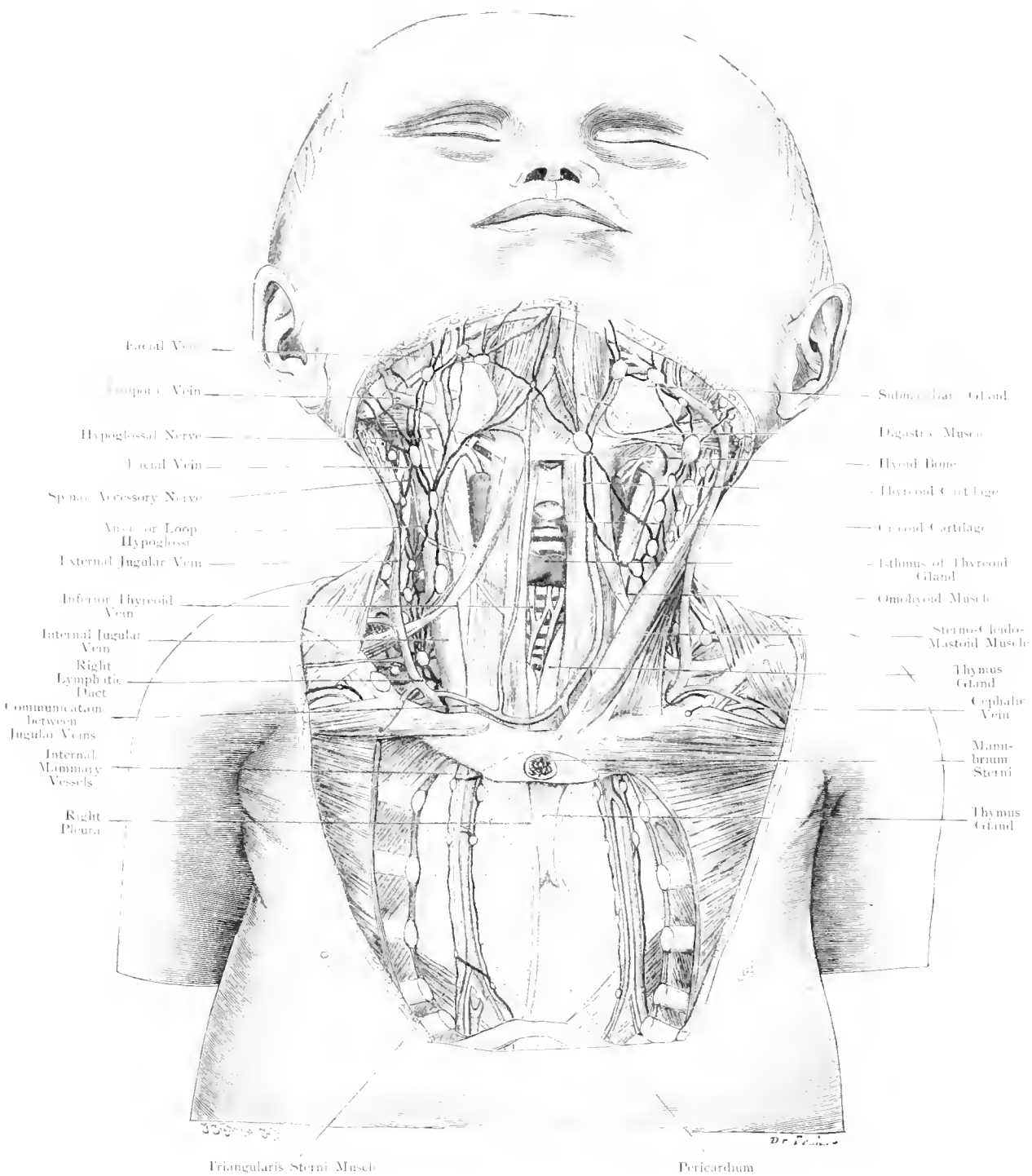


Fig. 62. Front view of Neck, Deep Layer. Child.
Nat. Size.

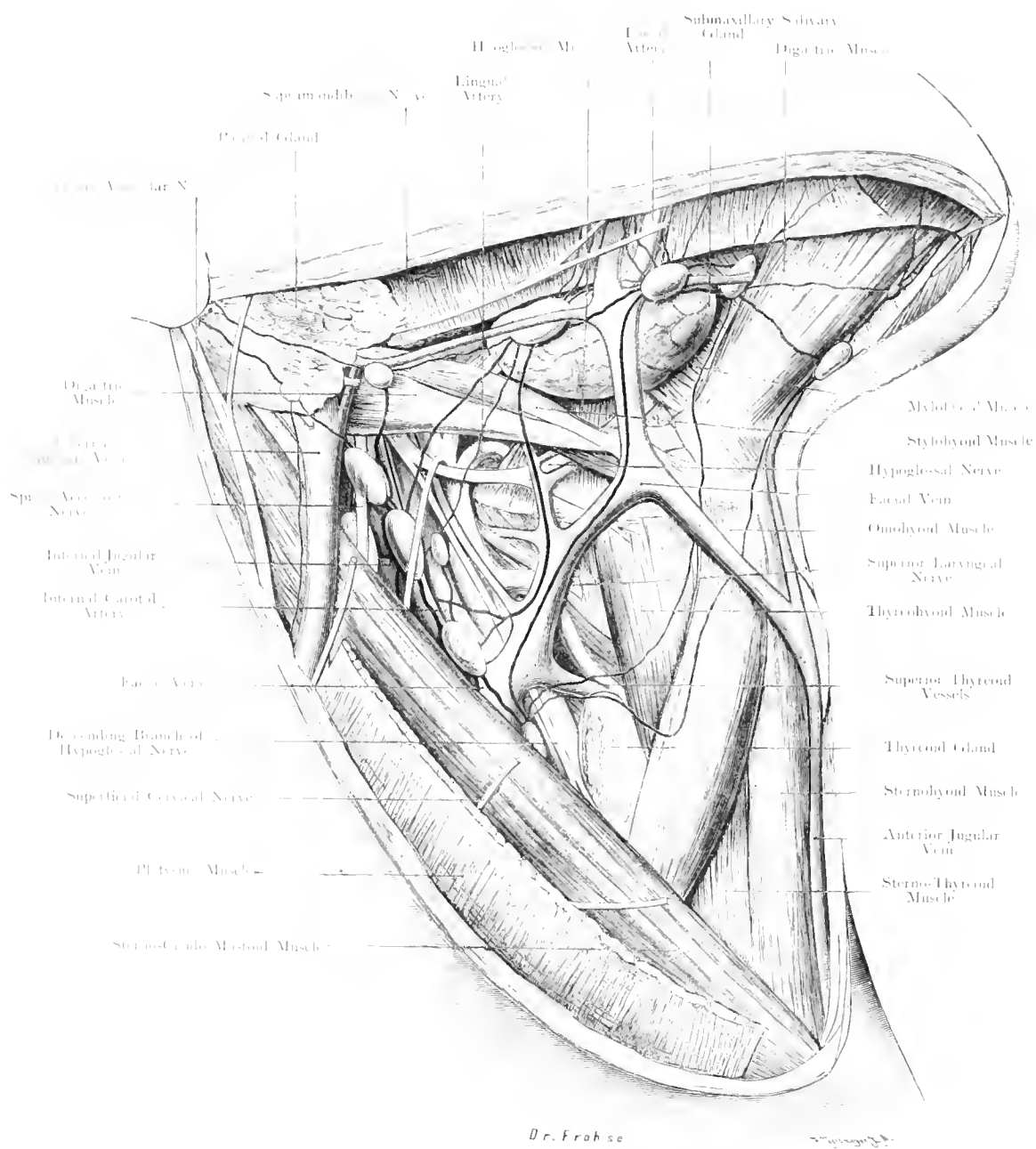


Fig. 63. Upper Triangle of Neck: Lymphatics.

Nat. Size.

Fig. 63. Upper Triangle of Neck: Lymphatics.

The Platysma is almost completely removed. The Cervico-Facial and Cervical Nerves are cut short. The lymphatic glands have been drawn accurately from the specimen (an old man), the lymphatic vessels with the aid of STAHR'S investigations.

Recent investigations have shewn that the number and the position of the lymphatic glands in the submaxillary region do not vary as much as in the other parts of the body (e. g. Axilla and Groin). There are usually only 3 glands, which we call anterior, middle and posterior. They all lie above the submaxillary gland. The anterior is usually the smallest and lies next to the Submental Vein on the Mylo-Hyoid Muscle; the middle is nearer the border of the jaw and usually touches the Facial Artery: the posterior lies near the Facial Vein, either immediately behind it, or nearer the angle of the jaw.

A second group of glands lies between the anterior bellies of the Digastric Muscles. Their number is less constant; but one can make out a superior set (small glands, the upper submental glands) and an inferior set (the lower submental glands) often consisting of only one large gland (cf. Fig. 62).

The efferent vessels from the upper submental set go partly to the lower set, partly to the anterior submaxillary gland. From the lower set the lymph travels to the Anterior Submaxillary Gland and partly to the deep Cervical Glands. The typical arrangement for the submaxillary lymphatics is as follows: lymph goes from the anterior gland to the middle, thence to the posterior. Only in a few cases, does it go directly to the deep cervical glands. Of the efferent vessels from the posterior submaxillary gland, our figure shews the superficial channels running to the cervical glands, but also one vessel going to an Inferior Parotid Gland.

A portion of the superior deep cervical glands along the Internal Jugular Vein and the Carotid Artery is shewn in the figure. They receive lymph from the Submental, Submaxillary, Lingual and Parotidean Glands, i. e. indirectly from the whole Face, from the Skull Cavity, Larynx, Pharynx and Thyreoid Gland; this explains why they become enlarged so very frequently in disease.

The lymphatics of the lips (cf. Fig. 115) are important, in consideration of the frequent occurrence of epithelioma. We need to distinguish between the lymphatics of the skin, and the lymphatics of the mucous membrane. The vessels from the mucous membrane of the lower lip (2—3 inches) usually go to the middle submaxillary gland, into which the vessels from the upper lip (1 to 2 inches) frequently open, the latter may also pass to the posterior submaxillary gland.

The subcutaneous lymphatics vary more widely; these entered beyond the middle line to a greater extent than the submucous vessels (2—4 subcutaneous vessels go from the lower lip to the submental glands). The lymphatics of the upper lip usually go to the middle submaxillary gland; in a few cases to an inferior parotid gland or even to a superficial cervical gland on the Sterno-Mastoid. As epithelioma of the lip usually starts at the junction of the skin and mucous membrane, and as the lymphatic areae meet here, all glands and also those of the opposite side demand consideration.

Fig. 64. Situation for Ligature of the Lingual Artery.

The Submaxillary Region and the surrounding parts are exposed by removal of Platysma, Lymphatic Glands, small Nerves and Fasciae. The Submaxillary Gland has been thrown upwards and appears to be composed of 2 portions, because the Facial Artery holds the deep portion in position. A piece has been taken out of the Facial Vein; this enables one to throw the gland upwards more easily, and gives a better view of the deep structures. Specimen from a man aged 40.

The Lingual Artery soon disappears, after its origin from the External Carotid, under cover of the Hyoglossus Muscle and runs forwards parallel with the hyoid bone accompanied by two Venae Comites. The course of the Hypoglossal Nerve is similar; the nerve being, however, at a higher level and superficial to the Hyoglossus Muscle. The Sublingual Vein accompanies the nerve. This nerve forms a small Δ together with the border of the Mylo-Hyoid Muscle and the posterior belly of the Digastric. In this Δ , the Lingual Artery can be tied, after division or separation of the fibres of the Hyoglossus Muscle, as shewn in our figure.

Another point is suitable for ligaturing this artery, which is so frequently tied in operations for removal of the tongue. The vessel may be ligatured in its course between the External Carotid Artery and the border of the Hyoglossus Muscle below the posterior belly of the Digastric. The place first mentioned is more superficial and more accessible, and would be preferable, if the artery had not given off its main branches as is frequently the case.

The Facial Artery runs — in a tortuous course —, behind the submaxillary gland, emerging between the gland and the border of the lower jaw (cf. Fig. 63) and extending on to the face along the anterior border of the Masseter. The artery is frequently embedded in the gland and ensheathed by the fascia of the gland. This accounts for the fact, that in removing the submaxillary gland, the Facial Artery is so often damaged. The Facial Vein passes in front of the gland.

The Common Carotid Artery bifurcates into Internal and External at the level of the upper border of the Thyroid Cartilage. On it rests the Descendens Hypoglossi Nerve. Behind the External Carotid, the Superior Laryngeal Nerve (from the Vagus) emerges; this nerve divides into an outer and an inner branch, the former to supply the Cricothyroid Muscle, the latter sensation inside the larynx.

Fig. 65. Larynx opened from in front.

The Laryngeal Region in a man (aged 38) has been exposed, and the Larynx slit open in the middle line between the thyrohyoid ligament and the upper border of the cricoid cartilage, a wedge placed between the 2 halves of the thyroid cartilage keeps the larynx open. (This has not been drawn in the figure.)

This figure shews the aspect seen in Laryngo-fissure or Laryngotomy, an operation which is performed for the removal of Laryngeal Tumours, when the neoplasm cannot be extirpated by the transbuccal endolaryngeal method.

The middle of the laryngeal region is not covered by muscles. Under the skin, is seen the cervical fascia in its intimate connection with the larynx. Immediately, under the fascia, is the Thyroid Cartilage. In some cases, there may be a bursa over it. The Anterior Jugular Vein is sometimes very large. There are no other important structures within the area of operation.

This figure also shews that High Tracheotomy is only possible, owing to the position of the thyroid gland, after the Isthmus of the Thyroid Gland has been divided or pushed downwards.

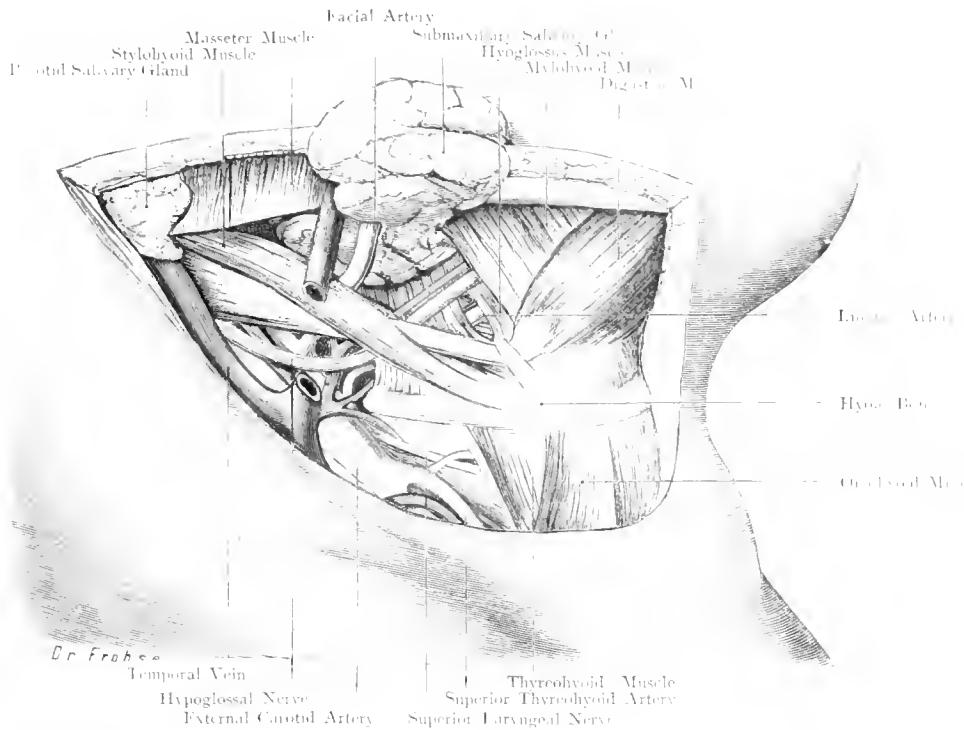


Fig. 64. Situation for Ligature of Lingual Artery. Nat. Size.

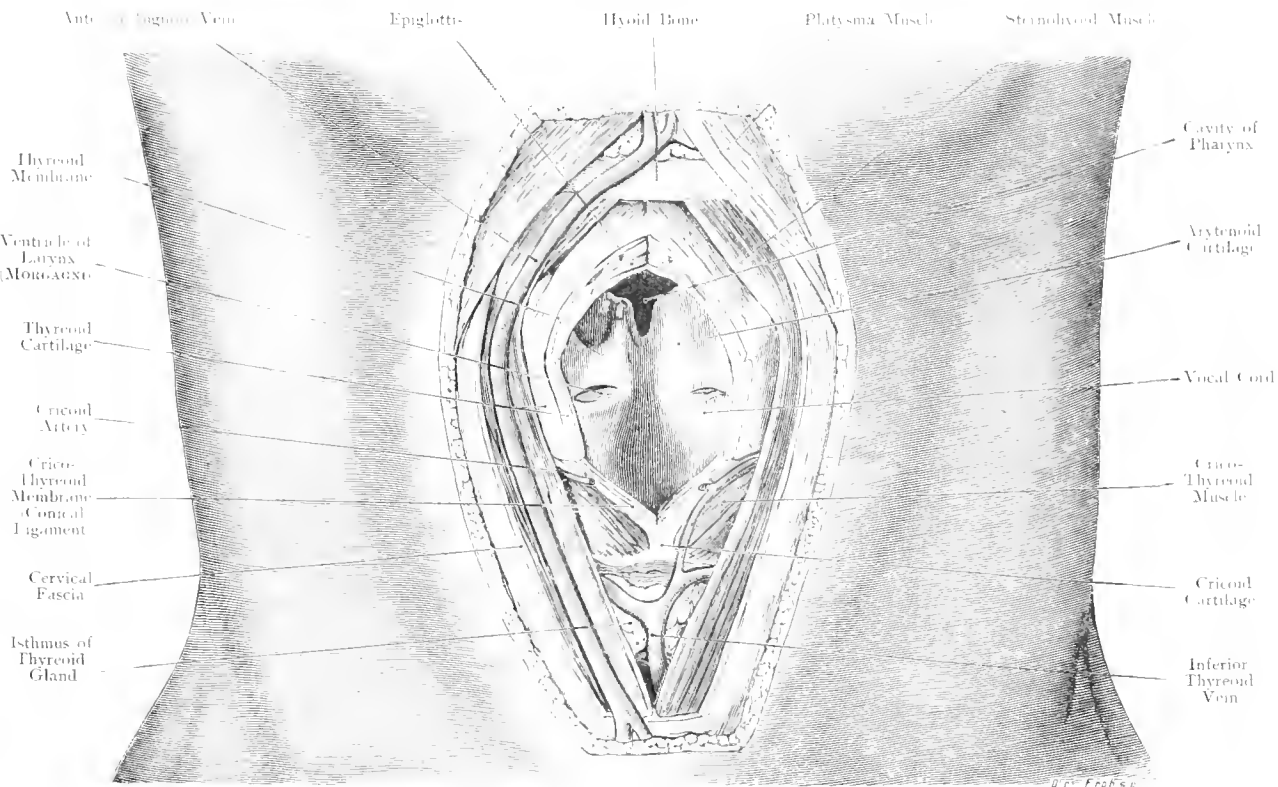
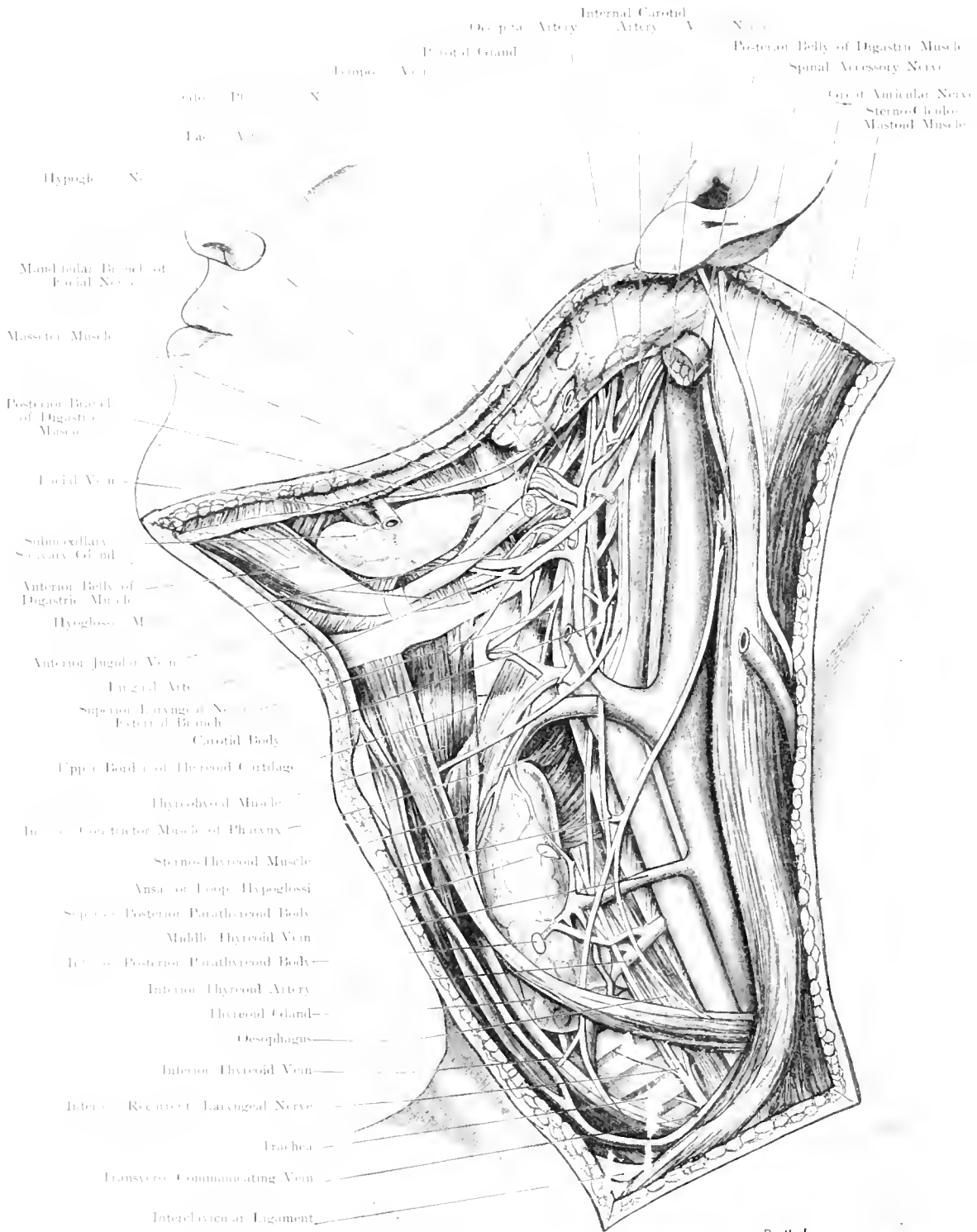


Fig. 65. Larynx opened from in front. Nat. Size.



Dr. Froese.

Fig. 66. Lateral Aspect of the Neck. Oesophagus.

$\frac{4}{16}$ Nat. Size.

Fig. 66. Lateral Aspect of the Neck. Oesophagus.

The outer region of the neck in a man, aged 30, was exposed by a large window-section. Platysma, Superficial Nerves, Facial Vein and lymphatic glands were removed. The Sterno-Cleido-Mastoid Muscle was drawn backwards, the Thyreoid Gland and the muscles near it forwards, in order to show the Oesophagus (red). The Sympathetic is white; the head is rotated to the right and inclined backwards.

The Oesophagus lies between the Trachea and the Vertebral Column, surrounded by loose connective tissue which allows its dilatation and movement upwards and downwards. It begins at the 6th Cervical Vertebra (cf. Fig. 1) and passes downwards behind the Trachea, deviating somewhat to the left. This is the reason why the left side is usually chosen for operating. An incision is made along the Anterior border of the left Sterno-Mastoid Muscle between the level of the Cricoid Cartilage and the Suprasternal Notch; after division of the Platysma and Superficial Cervical Fascia, the Sterno-Mastoid is drawn outwards, and the Omo-Hyoid Fascia divided. — also the Omo-Hyoid Muscle if it cannot be drawn downwards. One now proceeds between the Carotid Artery, which is pulled outwards and the Thyreoid Gland and the Sterno-Hyoid Muscle which cover it. When the gland is very large, it may be necessary to remove the left lobe, in order to have sufficient room. Deep in the wound, the Oesophagus can be recognised, by its longitudinal pale red muscle fibres, in front of the vertebral column and Longus Colli Muscle. The Oesophagus can be opened between the Superior and Inferior Thyreoid Arteries; if it is desirable to open the Oesophagus at a lower point, the Inferior Thyreoid Vessels are divided between a double ligature. In order to avoid the Recurrent Laryngeal Nerve, the canal is opened along its outer wall; the cervical portion of the Oesophagus can thus be exposed, a stricture or cancer removed, and an oesophageal fistula made by sewing the edges of the lumen of the Oesophagus to the skin.

The anatomy for the operation of removal of the Thyreoid Gland is similar (cf. Fig. 67).

At the bifurcation of the Common Carotid Artery lies the Carotid Body, composed of a delicate plexus of blood vessels and sympathetic nervous tissue.

Its functions are not known.

Fig. 67. Outer Region of the Neck. Subclavian Triangle.

The head is rotated to the right. Platysma and a portion of the Supraclavicular Nerves have been removed, the lymphatic glands have been removed in order to simplify the figure; the course of the chief lymphatic tracts has been indicated.

Under the skin we distinguish a Superficial and Deep Cervical Fascia, separated from each other by loose connective tissue, which stretches across the space between Sterno-Mastoid and Trapezius Muscles. The Supraclavicular Nerves become subcutaneous by piercing this fascia.

For the removal of tumours and especially, for the removal of diseased lymphatic glands, a longitudinal incision is made along the posterior border of the Sterno-Mastoid Muscle, the External Jugular Vein is divided. This vein runs downwards from the lower end of the Parotid Gland across the Sterno-Mastoid and Omo-hyoid, to pierce the Omo-hyoid Fascia and open into the Subclavian Vein. Of more importance is the Spinal Accessory Nerve. Emerging at the posterior border of the Sterno-Mastoid, this nerve runs obliquely downwards to the Trapezius.

As it crosses the area of operation, it cannot always be avoided: injury to it may cause paralysis of the Sterno-Mastoid and Trapezius Muscles; but not in every case as both muscles receive fibres from the 2nd, 3rd, and 4th Cervical Nerves which may run separately to the muscles and independent of the Spinal Accessory.

The Brachial Plexus emerges through the slit between the Scalenus Anticus and Scalenus Medius Muscles. Of particular importance is the position of the Phrenic Nerve. Deriving its fibres from the 4th Cervical Nerve, as well as from the 3rd and 5th, it runs obliquely inwards, superficial to the Scalenus Anticus Muscle. At this point, behind the posterior border of the Sterno-Mastoid Muscle, it can be best stimulated electrically.

When the clavicular portion of the Sterno-Cleido-Mastoid does not extend far backwards (as in our figure) the Internal Jugular Vein is visible at its posterior border. The Suprascapular Artery which either comes from the first, or from the 3rd part of the Subclavian Artery, takes a rather high course in this specimen; as a rule, it lies behind the clavicle (cf. Fig. 68). On the other hand, the Transversalis Colli Artery runs usually at a higher level than in our figure.

The most important point, just above the Clavicle, is where the Subclavian Artery and Vein leave the Thorax. Ascending out of that cavity, they form an arch over the first rib on their way to the axilla. The Vein is in front of, the Artery behind the Scalenus Anticus Muscle. The Vein is fixed to the first rib and to the clavicle by tense connective tissue; it cannot, therefore, collapse, when punctured (danger of air embolism). Just above the clavicle, it receives the Suprascapular Vein. The Clavicle and first Rib form the gate through which the Neurovascular Bundle passes into the arm, most external and posterior (highest-up) being the nerves; then comes the artery, and on the inner side and most anterior, the vein.

The large Lymphatic Tracts are in black; the Thoracic Duct opens at the junction of the left Subclavian and Internal Jugular Veins. This Duct receives the Jugular and Subclavian Lymphatic Trunks. When removing the deep cervical glands, which are so very frequently diseased (cf. Fig. 115), there is always a danger of damage to this most important lymphatic tract of the body.

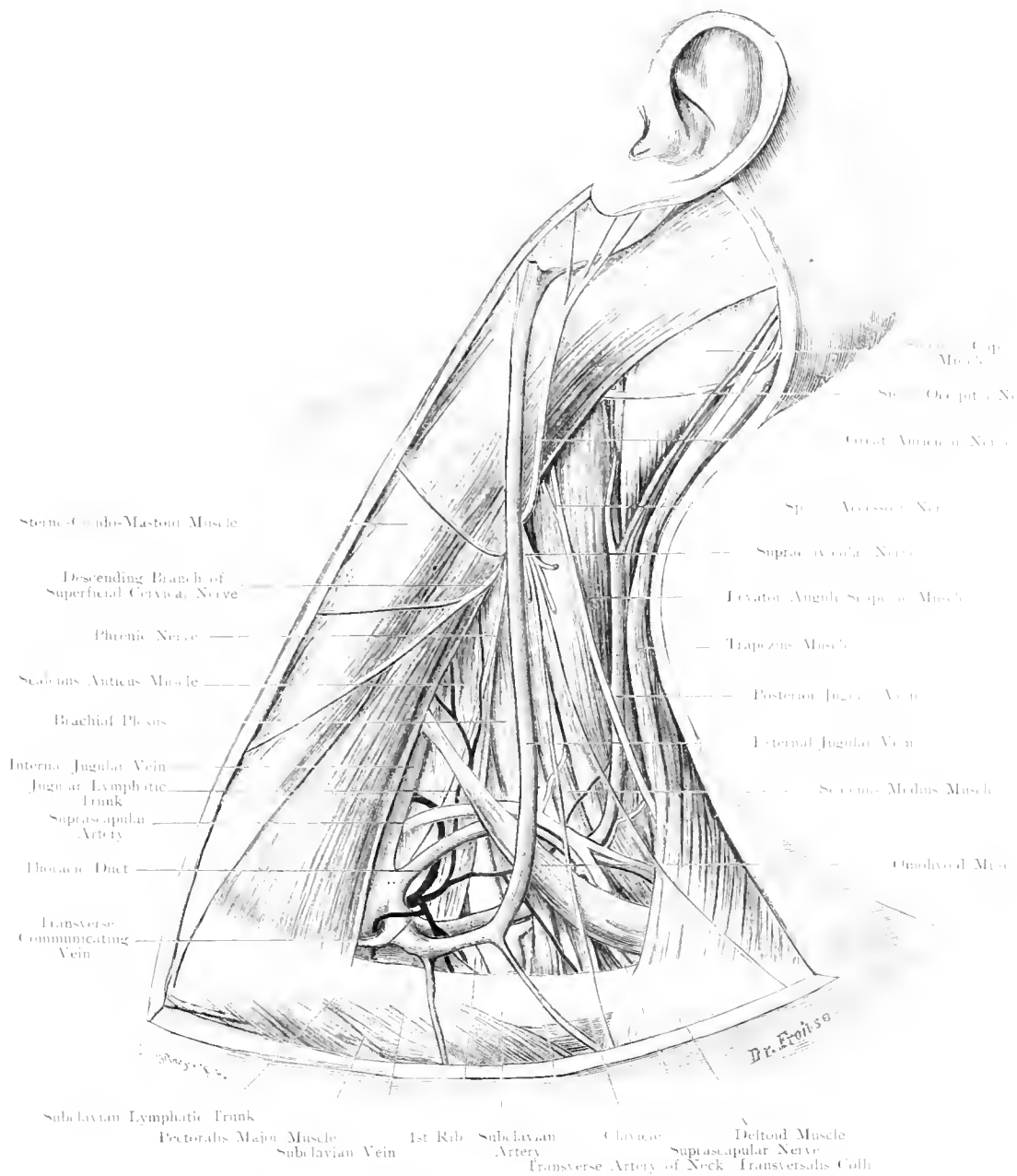


Fig. 67. Outer Region of Neck. Subclavian Triangle.

Nat. Size.

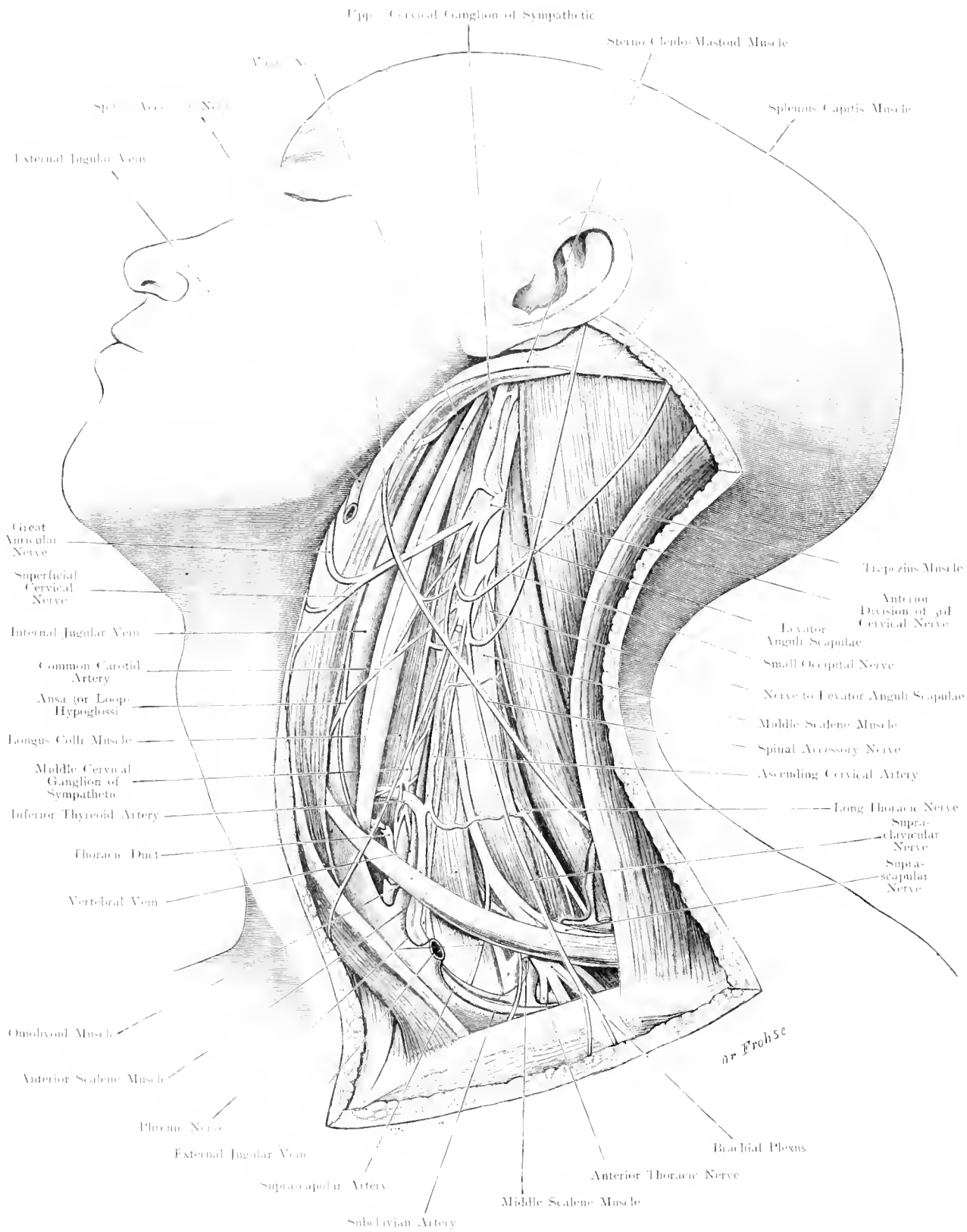


Fig. 68. Outer Region of Neck. Upper Cervical Ganglia of Sympathetic.

$\frac{2}{3}$ Nat. Size.

Fig. 68. Outer Region of the Neck. Upper Cervical Ganglia of Sympathetic.

The head of a male, aged 30, is turned to the right, and drawn backwards. A large window has been made in the skin, the Platysma and External Jugular Vein have been removed, the Sterno-Cleido-Mastoid Muscle and Internal Jugular Vein drawn forwards, and the Trapezius pulled backwards. The Thoracic Duct is white, the Sympathetic Chain and, its Ganglia are orange (by mistake, the Spinal Accessory Nerve has been drawn superficial to the Great Auricular Nerve: it should be the reverse).

In Fig. 67, the parts are in their natural position; in this figure, the deeper structures have been exposed by drawing the superficial muscles apart; the Internal Jugular Vein, which really lies external to the Carotid Artery, has been pulled inwards, the Sympathetic Chain begins with the Upper Cervical Ganglion which is $\frac{1}{5}$ th inch. long, and 0.3 inch. broad; its upper end lies opposite the transverse process of the 2nd or 3rd Cervical Vertebra; its lower end, opposite the 4th, 5th or 6th Cervical Vertebra. At its lower end is seen the sympathetic chain which goes to the Inferior Cervical Ganglion (cf. Fig. 70). This Ganglion varies in size and may form one mass with the 1st Dorsal Ganglion, it lies on the head of the 1st rib at its point of articulation with the body of the 1st Dorsal Vertebra. The sympathetic chain frequently forms a loop around the Subclavian Artery (Ansa of VIEUSSENS). Between the Upper and Lower Cervical Ganglia lies the middle Cervical Ganglion in front of the Inferior Thyreoid Artery, which may also be surrounded by a loop of sympathetic fibres. The Sympathetic Chain lies behind the Carotid Artery, and is fixed to the Vertebral Column and the Pre-vertebral Muscles. It therefore does not move with the Carotid Sheath, in the same way as the Vagus. When ligaturing the Carotid Artery, there is no need to trouble about the Sympathetic but one has to take care not to include the Vagus in the ligature with the Artery.

The Sympathetic is, therefore, in a well protected position, and rarely damaged in accidents, or during operations (removal of tumours). In recent years, the Sympathetic has been divided and more or less removed (Superior Cervical Ganglion etc.) for Epilepsy, Glaucoma and GRAVE'S disease. The Sympathetic can be exposed by a longitudinal incision along the anterior border of the Sterno-Mastoid Muscle; the Carotid Artery, Internal Jugular Vein and Vagus are drawn aside. This proceeding is inconvenient, because the thin-walled much distended vein is held by the retractor. If one operated along the posterior border of the Sterno-Mastoid drawing the muscle with the vein inwards, more room is obtained; if the incision has been continued downwards on to the clavicle, the lower Cervical Ganglion can also be removed, after having freed the clavicular head of the Sterno-Mastoid from its attachment. The latter operation, however, is difficult, because the Vertebral Vessels may lie up against the Ganglion near the Apex of the Pleura (cf. Fig. 70). This should on no account be injured.

This incision is the best for ligaturing the Vertebral Artery before it enters the foramen in the transverse processes of the Cervical Vertebrae.

Fig. 69. Larynx from behind – Goitre.

From the body of an old woman, the enlarged Thyreoid Gland (Goitre) was removed with the Larynx and the Trachea, and hardened in Formalin; only a small portion of the Oesophagus remains; the posterior wall of the Larynx is dissected. The Parathyroids are orange, the lymphatic glands, red. The larger left lobe of the Thyreoid Gland caused the Trachea to rotate around its axis. The Recurrent Laryngeal Nerve has been drawn aside, on both sides, in order to more clearly show its branches.

The topographical position of the Thyreoid Gland is shewn in Fig. 6. Fig. 60 indicates those structures which must be divided in exposure of the gland. The topographical relations at the point where the Superior Thyreoid Artery enters the gland, are most important (cf. Fig. 66). The difficulty in removal of the Thyreoid Gland is to avoid the Recurrent Laryngeal Nerve, injury to which causes paralysis of the Vocal Cords. This nerve ascends in the groove between the Trachea and Oesophagus, supplies these structures and enters into the formation of the Oesophageal Plexus (Plexus Gulae). It then follows the Inferior Thyreoid Artery, in some cases running upwards in front of the Artery, or — more often —, it passes between its branches at the point of bifurcation; it only lies in a few cases behind this vessel, always closely applied to the Thyreoid Gland. For the removal of the gland, the nerve must be freed, and great care taken, to avoid inclusion with the ligature for the Artery. It then passes under the Inferior Constrictor Muscle and ends at the Crico-Thyreoid articulation by dividing into its terminal branches; one of these joins the descending branch of the Superior Laryngeal Nerve, thus forming the loop of GALEN — Ansa GALENI —, the other supplies the muscles of the Larynx, except the Crico-Thyreoid. This muscle is supplied by the External branch of the Superior Laryngeal Nerve (cf. Fig. 66), whilst the bulk of that nerve pierces (internal branch) the Thyreo-hyoid Membrane together with the Superior Thyreoid Artery and supplies the laryngeal mucous membrane with sensation.

Of great practical importance are the Parathyreoid Glands. When enlarged or the seat of a tumour, they may cause great diagnostic difficulties.

Usually, their position is as shewn in the figure near the Thyreoid Gland; but there may be Parathyroids anywhere between the frenum of the tongue and the hyoid bone, and between the lower border of the Mandible, the Clavicle and the Trapezius Muscle.

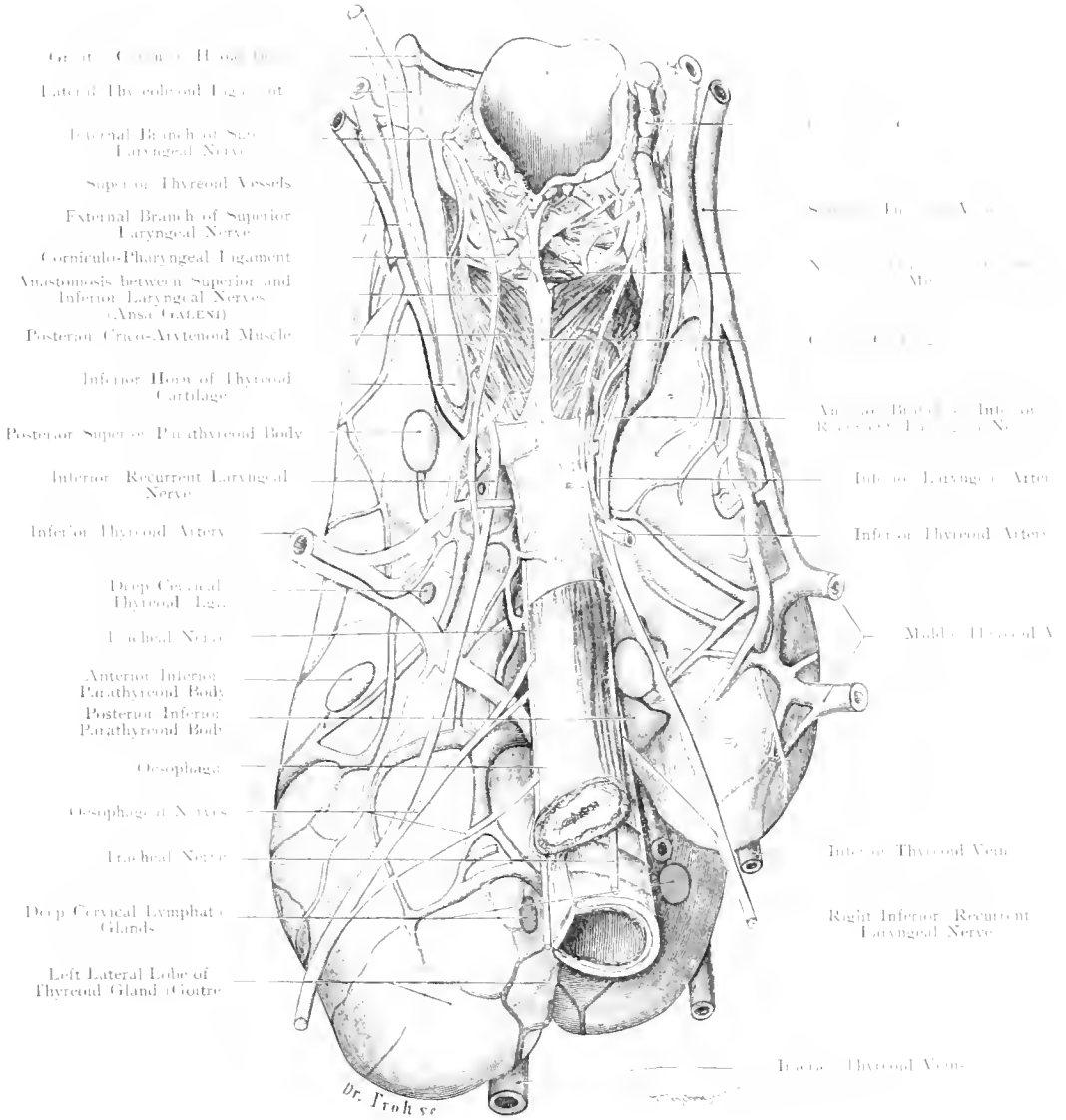


Fig. 69. Larynx from behind — Goitre —.

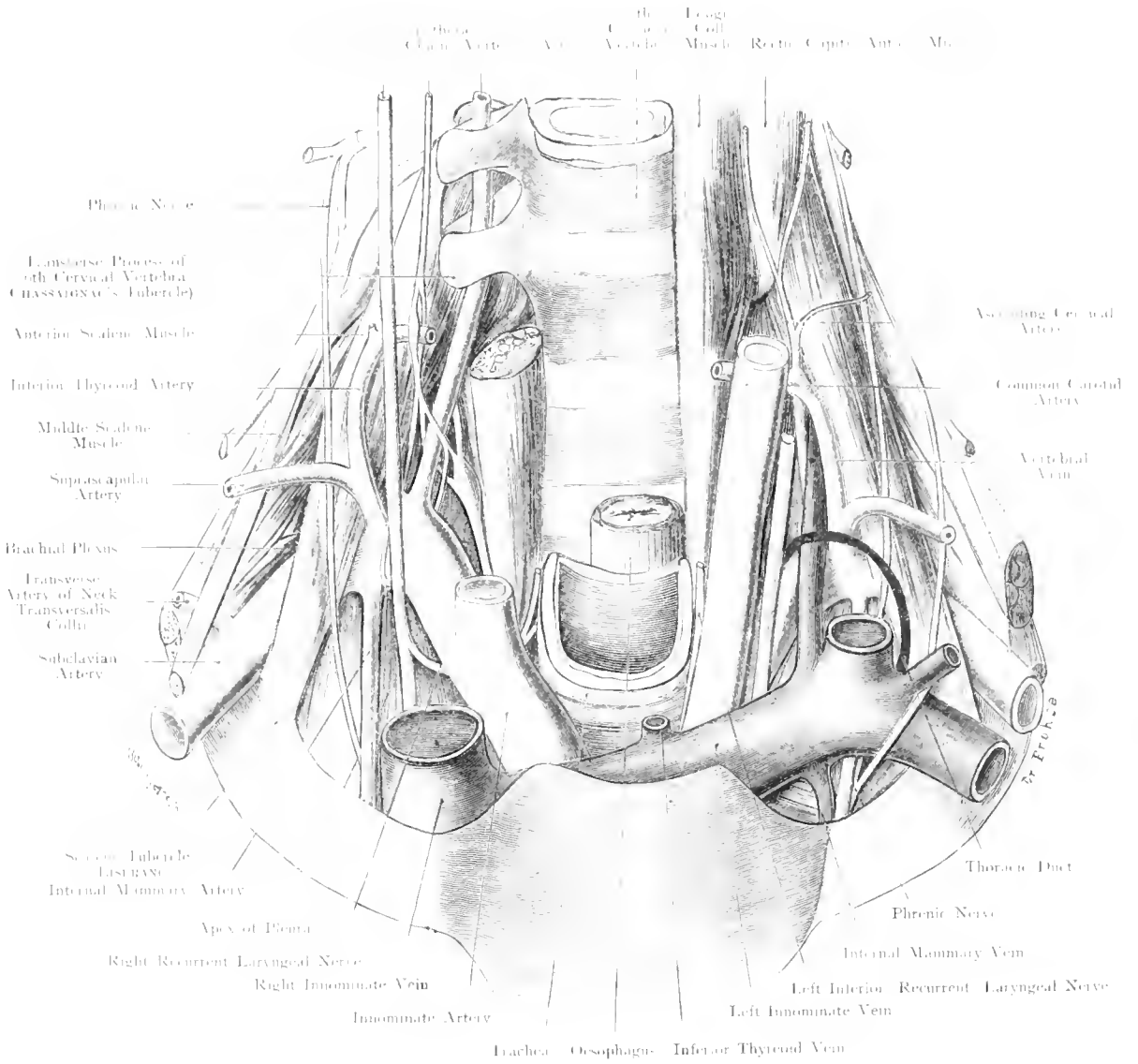


Fig. 70. Apex of the Pleura.

Nat. Size.

Fig. 70. Apex of the Pleura.

From the neck of a man, aged 40, both clavicles have been removed, Trachea and Oesophagus cut off, and the important vessels and nerves displayed in their relation to the apex of the pleura (which is coloured light blue). On the left side, special attention has been paid to the Veins and the Thoracic Duct; on the right side to the Arteries and the Nerves, in particular, to the Sympathetic.

The apex of the Pleura ends exactly at the level of the 1st rib. This rib which forms with the Sternum and 1st Dorsal Vertebra the upper aperture of the Thorax, ascends behind, in an oblique direction. The slope of the apex of the pleura, and the lung within it, corresponds to that of the rib mentioned. An instrument, introduced immediately above the first rib, horizontally backwards, will therefore open the pleura. By percussion, one can also prove the presence of resonant lung about one inch above the clavicle. Despite all this, it is wrong to say that the pleural cavity extends everywhere beyond the upper aperture of the thorax. Normally, it passes above the level of that inclined plane only at one spot, at the middle of the 1st rib, and only to the extent of $\frac{1}{2}$ inch. Strands of connective tissue keep the apex of the pleura in position; this fascia runs from the Cervical Vertebrae and the neck of the first rib to the apical pleura.

The large vessels and nerves which pass through the upper aperture of the Thorax to the head and the upper limb, and the Nerves which go from the neck to the arm are in close relation with the apex of the Pleura. Internal to the latter, on the right side, the Innominate Artery, on the left, the Subclavian Artery passes. The Innominate Artery bifurcates into Common Carotid and Subclavian either behind the Sterno-Clavicular articulation or at a higher level. The Subclavian Artery arches over the apex of the Pleura, leaving it at the Scalene Tubercle on the first rib. The Internal Mammary Artery which arises from the Subclavian, before it passes between the Scalenus Anticus and Medius Muscles, is also in relation to the Apex of the Pleura; external to it is the Phrenic Nerve. The Inferior Cervical Ganglion (cf. right side of the figure) lies on the apex, between the Longus Colli Muscle and the arch of the Subclavian Artery, in front of which the Vagus descends (also in relation with the apex of the Pleura). Both Innominate Veins, formed by the Internal Jugular and Subclavian Veins are also relations of the apical pleura, on which the Brachial Plexus, — external to the Subclavian Artery —, rests. Lastly, the Pleura lines the inner border of the Scalenus Anticus Muscle where it is attached to the first rib.

Disease of the Pleura can, especially on the right side, affect the Recurrent Laryngeal Nerve.

The fact that so many structures of vital importance are in close apposition within a small space renders removal of tumours, growing in that region, and ligature of the vessels very difficult and even dangerous. Apart from the possibility of injury to the vessels and nerves in the neighbourhood, there is danger of opening the Pleura.

Fig. 71. Course of the Main Vessels and Nerves to the Arm.

The head is turned to the left, the arm drawn downwards, slightly abducted and rotated outwards. The Platysma and the clavicular portion of the Pectoralis Major have been removed. A piece has been excised from its sternal portion, its origin and insertion being thrown inwards and outwards respectively.

Between the clavicular portion of the Pectoralis Major which usually arises from the inner half of the Clavicle, and the origin of the Deltoid from the outer third of that bone, a Δ space is left in which the Cephalic Vein disappears to join the Subclavian Vein (for further details cf. Fig. 76, text).

The Subclavian Vein, Artery and Brachial Plexus pass under the Clavicle (as if it were a bridge!) from the neck into the Axilla. The Vein, separated from its Artery on the 1st rib by the Scalenus Anticus Muscle, lies on its inner aspect, lower down. Externally, and partly behind the artery is the Brachial Plexus which soon surrounds this vessel. The Neuro-Vascular bundle is almost completely covered by muscles, even when the latter are ill-developed. Proceeding directly backwards, without interfering with the muscles, separation of the clavicular portion of the Pectoralis Major from its origin, is necessary.

The following surface marking can be used for ligature of the Subclavian Artery in this region. Take the midpoint of the Clavicle; the artery lies at a finger's breadth interval from this point.

Above the upper border of the Pectoralis Minor, the Subclavian Artery gives off two branches which are not shewn in our figure: the Acromio-Thoracic and the minute Alar Thoracic (Thoracica Suprema). The anterior Thoracic Nerves which supply the 2 Pectoral Muscles run with the former vessel. They perforate the costo-coracoid membrane.

Lastly, we mention that in our figure — and this is not uncommon — there is a gap between the sternal and the clavicular portions of the Sterno-Cleido-Mastoid Muscle in which the Internal Jugular Vein is visible.

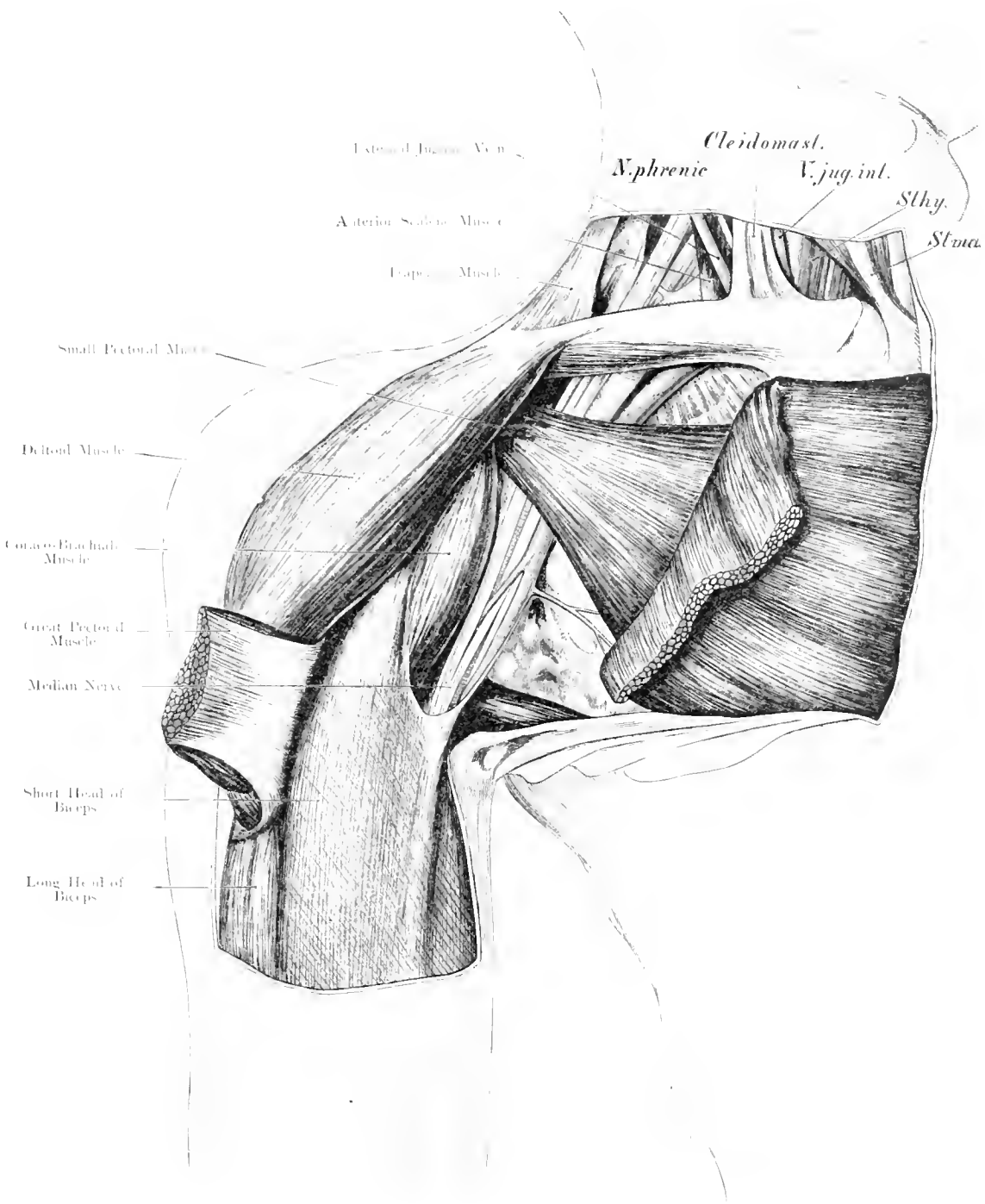
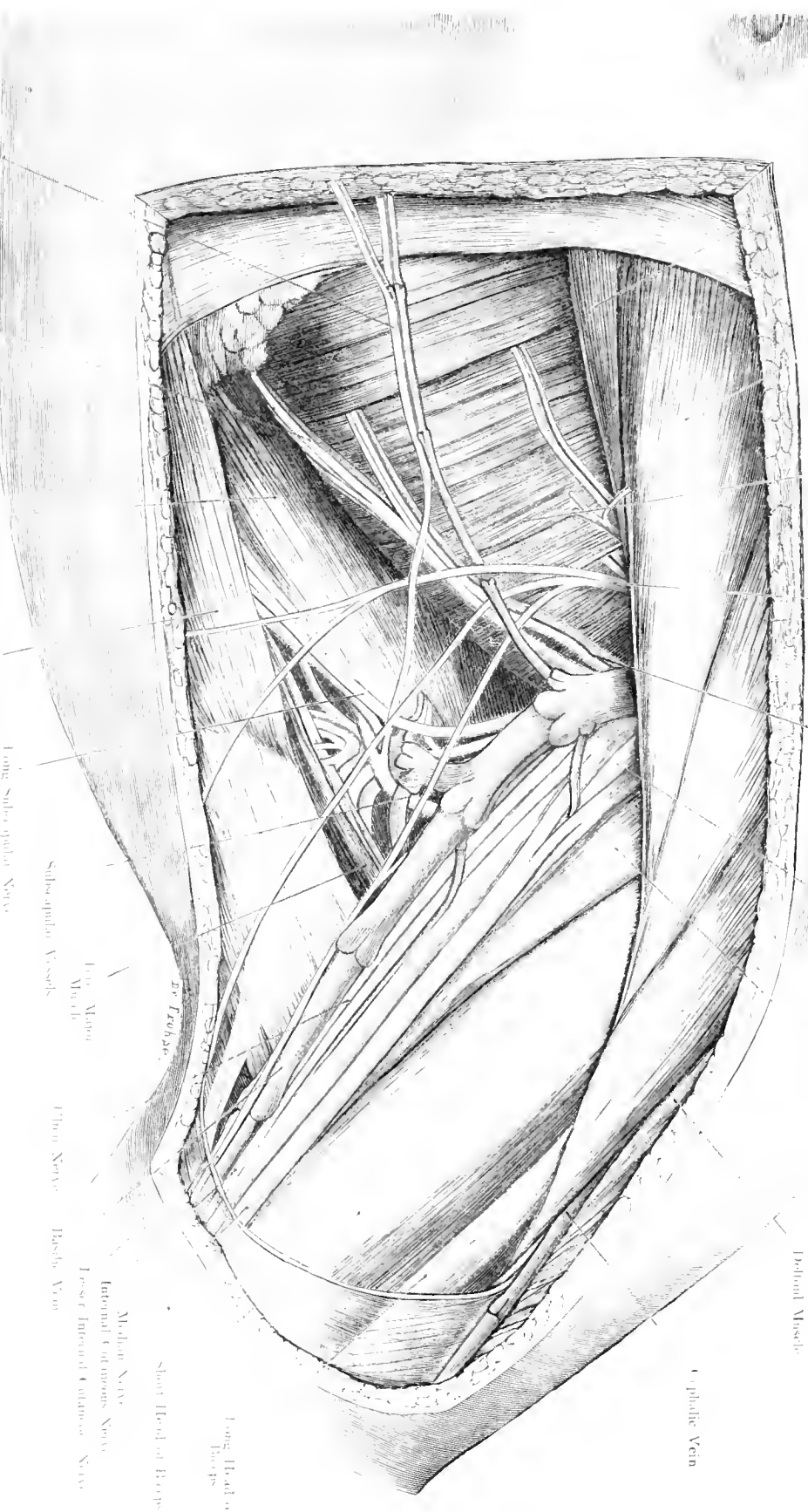


Fig. 71. Course of Main Vessels and Nerves to the Arm.

$\frac{2}{3}$ Nat. Size.

Small Pectoral Muscle
 Great Pectoral Muscle
 Anterior Serratus Muscle
 Intercostal Humeral Nerve
 Long Thoracic Nerve
 Axillary Artery
 Coraco Brachialis Muscle
 Pectoral Muscle
 Cephalic Vein



Small Pectoral Muscle
 Great Pectoral Muscle
 Anterior Serratus Muscle
 Intercostal Humeral Nerve
 Long Thoracic Nerve
 Axillary Artery
 Coraco Brachialis Muscle
 Pectoral Muscle
 Cephalic Vein

Small Pectoral Muscle
 Great Pectoral Muscle
 Anterior Serratus Muscle
 Intercostal Humeral Nerve
 Long Thoracic Nerve
 Axillary Artery
 Coraco Brachialis Muscle
 Pectoral Muscle
 Cephalic Vein

Small Pectoral Muscle
 Great Pectoral Muscle
 Anterior Serratus Muscle
 Intercostal Humeral Nerve
 Long Thoracic Nerve
 Axillary Artery
 Coraco Brachialis Muscle
 Pectoral Muscle
 Cephalic Vein

Fig. 72. Axilla. - Nat. Size.

Fig. 72. Left Axilla.

The arm has been strongly abducted to an angle of 135.5°; Skin, Subcutaneous Tissue, Fascia and Lymphatics have been removed.

The boundaries of the Axilla are: on the inside, the Thorax; externally and above, the Shoulder and the Arm; in front, the Pectoralis Major; behind, the Teres Major and Latissimus Dorsi. In the small triangular space between the Subscapularis, Triceps, Latissimus Dorsi and Teres Major Muscles, the large vessels and nerves run. Internally, the Axilla is continued by means of loose connective tissue (Lymphatics!) under cover of the Pectoralis Major and Minor Muscles, nearly as far as the Sternum; above, it is continuous, behind the clavicle, with the connective tissue of the Neck.

When the arm is abducted, the position, form, size and boundaries of the axilla become altered. The anterior wall, formed by the Pectoralis Major, recedes inwards; the posterior wall, formed by the Latissimus Dorsi, Teres Major, Scapula and Subscapularis Muscle, bulges outwards. The fossa is thus rendered more shallow and more easily accessible from in front.

We distinguish two layers of the Axillary Fascia. The fascia covering the anterior surface of the Pectoralis Major (Pectoral Fascia) forms at the lower border of that muscle, a fibrous aponeurosis which stretches across to the Latissimus Dorsi and often describes an arch at the outer boundary of the Axilla (Axillary Arch; LANGER'S Muscle). The second fascia, is more deeply placed and connected with the Pectoralis Minor Muscle. It attaches this muscle, above to the Clavicle (Costo-Coracoid Membrane), externally to the muscles arising from the Coracoid Process, and to the Superficial Layer. An Axillary Fascia, as an independent and a proper fascia of the Axilla does not exist. But as the fascia is thin and perforated by the vessels, it is comparable to the Cribriform Fascia of the Saphenous Opening. The Axillary Lymphatic Glands which receive lymph from the upper extremity and the greater part of the Thoracic Wall, and those of the Breast, have been removed in this specimen.

The following Vessels and Nerves are seen in the Axilla:

- 1) Axillary Artery.
 - 2) Axillary Vein, formed by the junction of the Basilic Vein and the Venae Comites of the Brachial Artery (cf. Fig. 32). The Vein is the most superficial and most internal of the important structures in the Axilla (according to whether the Venae Comites immediately join the Basilic Vein, there may be one, two, or three Veins in the Axilla). The Cephalic Vein opens, above the Pectoralis Minor, in the Fossa Deltoideo-Pectoralis, — between the Clavicle, Pectoralis Major and Deltoid Muscles — into the Axillary Vein.
 - 3) The Long Thoracic and Subscapular vessels, branches of the Axillary.
 - 4) The Cords of the Brachial Plexus. At first (cf. Fig. 69, 71) they bear a supero-external relation to the Artery. Nextly they surround it, especially the 2 roots of the Median Nerve which diverge above like a fork, and thus leave a space for ligaturing the Vessel. The External Cord divides into the Outer Head of the Median Nerve and the Musculo-Cutaneous (supplying Coraco-Brachialis etc.); the Internal Cord forms the inner head of the Median and the Ulnar Nerve. The Median Nerve is usually in front and external to the Artery (in 15% of all cases it lies between it and the Coraco-Brachialis). Between the Median and Ulnar Nerves the Internal and the lesser Internal Cutaneous Nerves pass. (The former may be mistaken for the Median or Ulnar.) More posterior is the Musculo-Spiral Nerve disappearing between the heads of the Triceps; at a still deeper level is situated the Circumflex Nerve (cf. Fig. 79).
- Important, and not uncommon, is the high division of the Main Artery of the limb, which may occur as the high bifurcation of the Brachial, or even as a bifurcation of the Axillary Artery.

Figs. 73 and 74. Relation of the Capsule of the Shoulder-Joint to the Upper Epiphyseal Line. After VON BRUNN.

Fig. 73. Frontal Section through the right Shoulder-Joint of a boy aged 8 years. Arm abducted to a right angle.

Arm placed horizontally. Seen from in front.

Above, on the outer side, the Capsule of the Shoulder-Joint does not extend as far as the Epiphyseal Line, but on the lower aspect the Capsule passes beyond the Epiphyseal Line on to the inner side of the neck of the Humerus. At the point marked *, the thin dark line shews how the Capsule is reflected so that Separation of the Epiphysis does not necessarily open the Joint-Cavity.

Fig. 74. Horizontal Section through the left Shoulder-Joint of a boy aged 8 years. Arm abducted to a right angle.

Arm placed horizontally. Seen from above. The section passed directly below the Spine of the Scapula and touched the lower border of the Acromion Process.

The relation of the Capsule to the Epiphyseal Line is the same on the anterior and posterior aspects, as it is below (cf. Fig. 13). It is true that the Joint-Cavity extends beyond this boundary (only because the Capsule, arising from the Articular Cartilage, is attached for some distance to the Cartilage or to the Bone).

The Epiphyseal Lines, Epiphyseal Boundaries or Epiphyseal Cartilaginous Discs are of great importance for many reasons. The longitudinal growth of the long bones takes place chiefly, if not exclusively, at these lines, i. e. at the Residual Cartilage between the Diaphysis (shaft) and the Epiphysis. This growing process is especially marked at puberty, but on the other hand, it is especially liable to be interfered with during the same period, by inflammation, which may result in the Separation of Diaphysis and Epiphysis.

Traumatic Separation of the Epiphysis is not so frequent as Inflammatory Separation. Fractures usually occur near, but not (in) along the Epiphyseal Lines. Excision of joints in children should only be performed with due consideration of the Epiphyseal Lines.

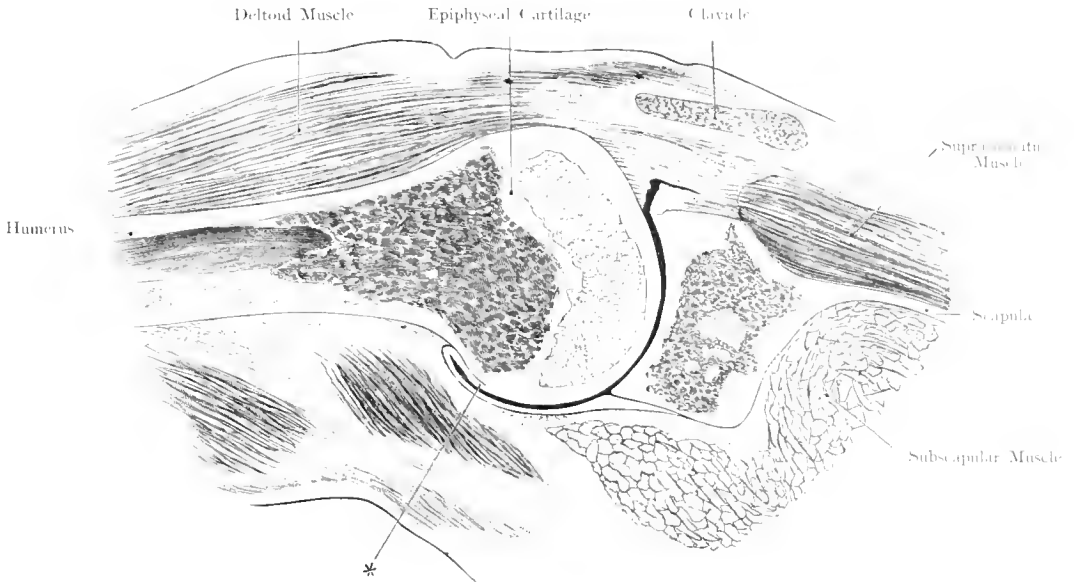


Fig. 73. Frontal Section through the right Shoulder-Joint of a boy aged 8 years.
Arm abducted to a right angle.
 Nat. Size. — After VON BRUNN.

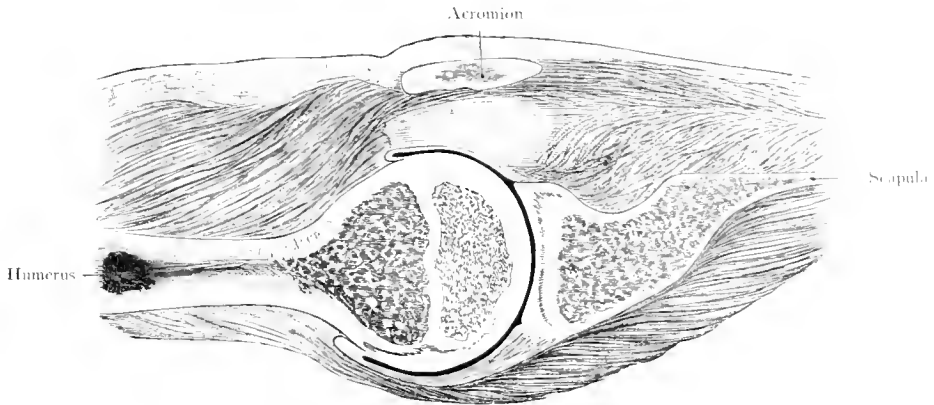


Fig. 74. Horizontal Section through the left Shoulder-Joint of a boy aged 8 years.
Arm abducted to a right angle.
 Nat. Size. — After VON BRUNN.

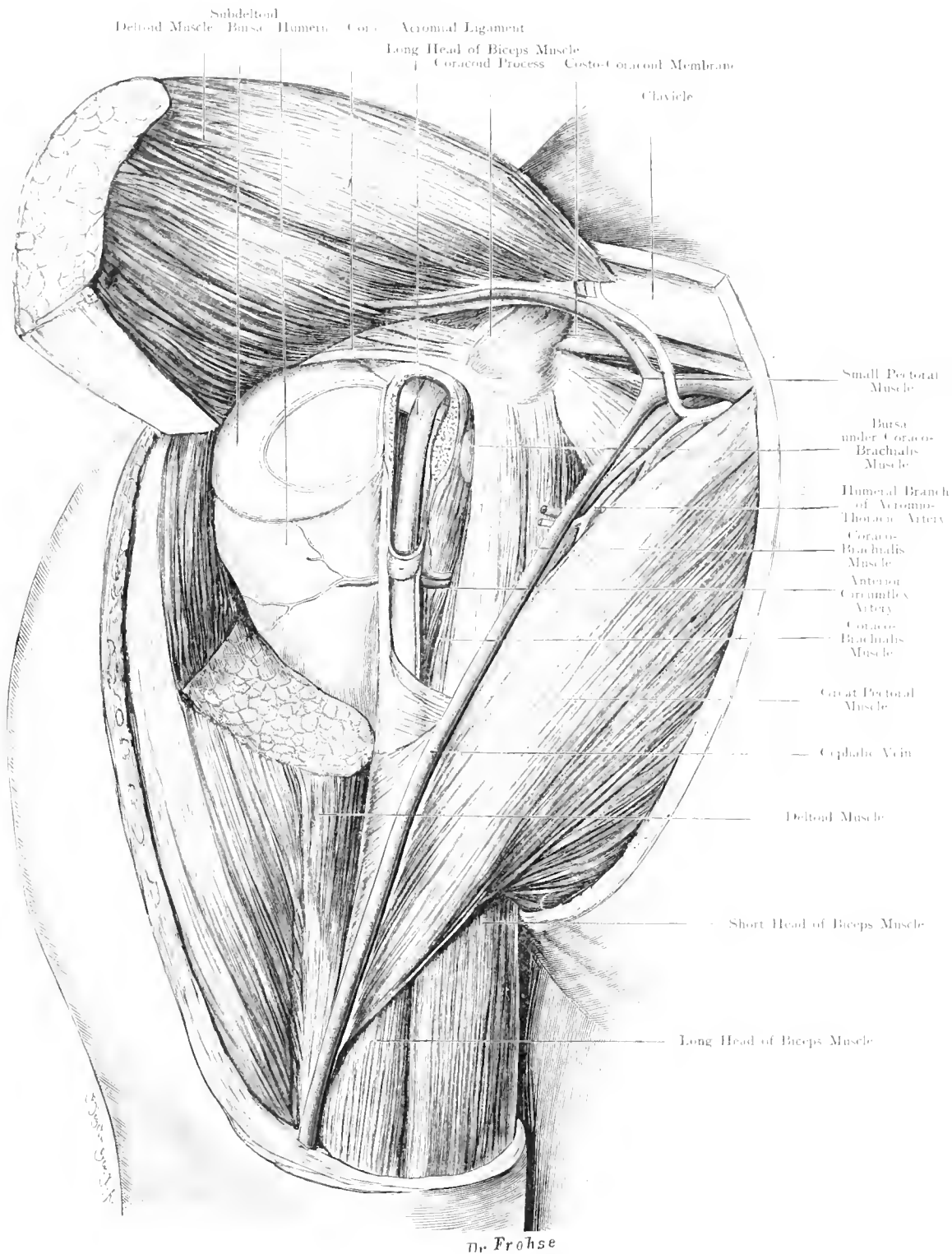


Fig. 75. Anterior Relations of the Shoulder-Joint.

Nat. Size.

Fig. 75. Anterior Relations of the Right Shoulder-Joint.

Skin and Superficial Fascia over the anterior portion of the Deltoid and the outer portion of the Pectoralis Major have been removed; the Deltoid has been cut below the Shoulder-Joint and thrown upwards and outwards. The Subdeltoid Bursa (pink), the Joint, and the Sheath of the Biceps (light blue) have been opened.

The middle third of the Clavicle and Subclavius Muscle, the Coracoid Process with the insertion of Pectoralis Minor Muscle and the common origin of the Coraco-Brachialis and Short Head of the Biceps are shewn. The Long Head runs through the Shoulder-Joint over the Head of the Humerus into the Bicipital Groove. Its synovial sheath always communicates with the Joint. Effusion and Pus in the Joint often extend into this sheath.

Between the Capsule of the Shoulder-Joint and the Deltoid Muscle lies the Subdeltoid Bursa, which, as a rule, does not communicate with the Joint. Distension of this Bursa may easily stimulate fluid in the Shoulder-Joint. The fibrous strands running from the Coracoid Process to the Capsule and the wall of the Subdeltoid Bursa are called the Coraco-Humeral Ligament. They are covered in the figure by the much-distended Bursa.

Between the Capsule and the Coraco-Acromial Ligament which forms a kind of protective roof for the Joint an important bursa, the Subacromial Bursa, is found.

A third large bursa lies between the Scapula and the Subscapularis Muscle: the Bursa Subscapularis usually communicates with the Joint (cf. Fig. 121).

The Capsule of the Shoulder-Joint is wide and loose; it allows the Head of the Humerus to leave the Glenoid Cavity of the Scapula for a distance of as much as one inch. Above, this Capsule is attached to the neck of the Scapula; for the greater part, it is attached to the fibrous ring which deepens the Glenoid Cavity (Glenoid Ligament). The Long Head of the Biceps arises from the upper part of the Glenoid Ligament.

The Glenoid Cavity is not directed exactly outward, but somewhat upwards and forwards.

When the arm hangs vertically downwards, only the lower portion of the Head of the Humerus touches the Glenoid Cavity articular surface of the Scapula, at least in dead bodies. The highest point of the Head of the Humerus lies at a distance of 0.15—0.25 inch from the highest point of the Joint Cavity.

Fig. 76. Infraclavicular Fossa – MOHRENHEIM'S Fossa – Right Side. Natural Size.

The Clavicle has been well-drawn upwards. Skin, Fascia and Platysma over the Clavicular Portion, over the upper part of the Sternal Portion of the Pectoralis Major, and over the anterior portion of the Deltoid Muscle have been removed, as well as above the Clavicle. The Clavicular Portion of the Pectoralis Major has been cut off near the Clavicle. The Costo-Coracoid Membrane has been partly removed.

The term "Infra-clavicular Fossa" (MOHRENHEIM'S Fossa) is often given to the gap between the Deltoid and the Pectoralis Major, as far as it lies above the upper border of the Pectoralis Minor (cf. Fig. 53 text). We prefer the name Deltoido-Pectoralis Fossa or Triangle. The Pectoralis Major and the Deltoid which represent embryologically one mass, vary in size; there may, therefore, be only a narrow slit between them in which the Cephalic Vein runs. Moreover, the Subclavian Artery is sought for below the Clavicle in the space between this bone (or the Subclavius) and the Pectoralis Minor Muscle, and, thirdly, the Clavicular Portion of the Pectoralis Major may be absent. For all these reasons we describe the Triangle between the Deltoid, Clavicle and Sternal Portion of Pectoralis Major as Fossa Infra-clavicularis or MOHRENHEIM'S Fossa. The upper border of the Pectoralis Minor removes a quadrilateral space from this triangle. In this quadrangle all the important structures run (deep to the Costo-Coracoid Membrane which is removed in the figure).

These structures are:

1) Most superficial and most inferior: The Subclavian Vein.

2) Deepest and highest: The Brachial Plexus from which Nerves run forward to supply the Pectoralis Major and Minor Muscles.

3) Between the Nerves and the Vein: The Subclavian Artery which at this point becomes the Axillary, and gives off numerous branches running upwards or outwards and downwards.

4) The Cephalic Vein which opens into the Subclavian or into the Axillary Vein; in some cases, it passes, over the Clavicle to join the External Jugular Vein, at times even forming a Venous Ring around that bone.

5) The Veins are accompanied by large lymphatic trunks (green in the figures). Above the Clavicle, the External Jugular Vein is seen in the figure.

In connection with ligature of the Subclavian Artery below the Clavicle, cf. Fig. 71 text: The Costo-Coracoid Membrane is pierced above the Pectoralis Minor Muscle by the Cephalic Vein, by the Acromio-Thoracic Artery, by the Internal and External Anterior Thoracic Nerves.

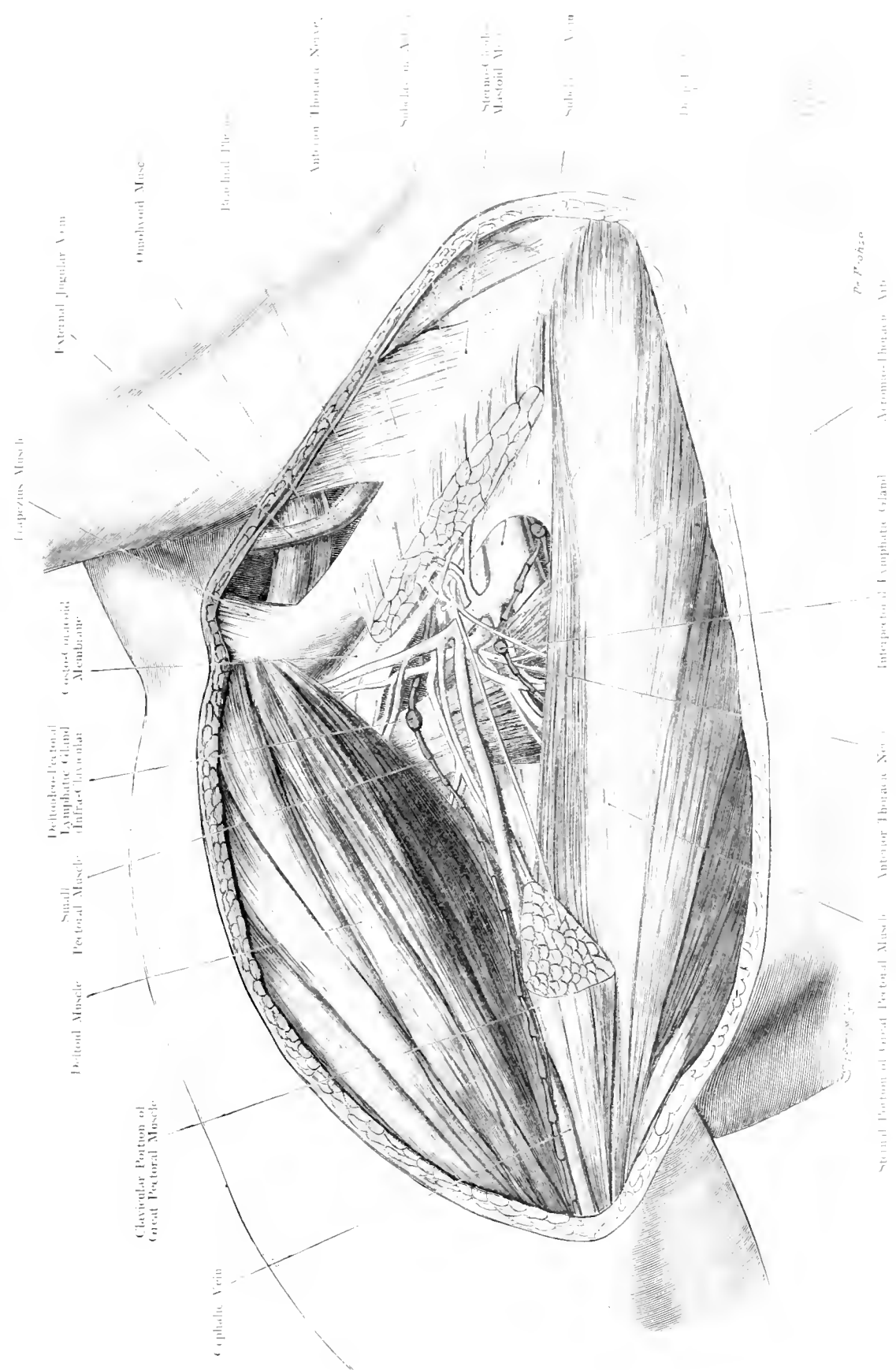
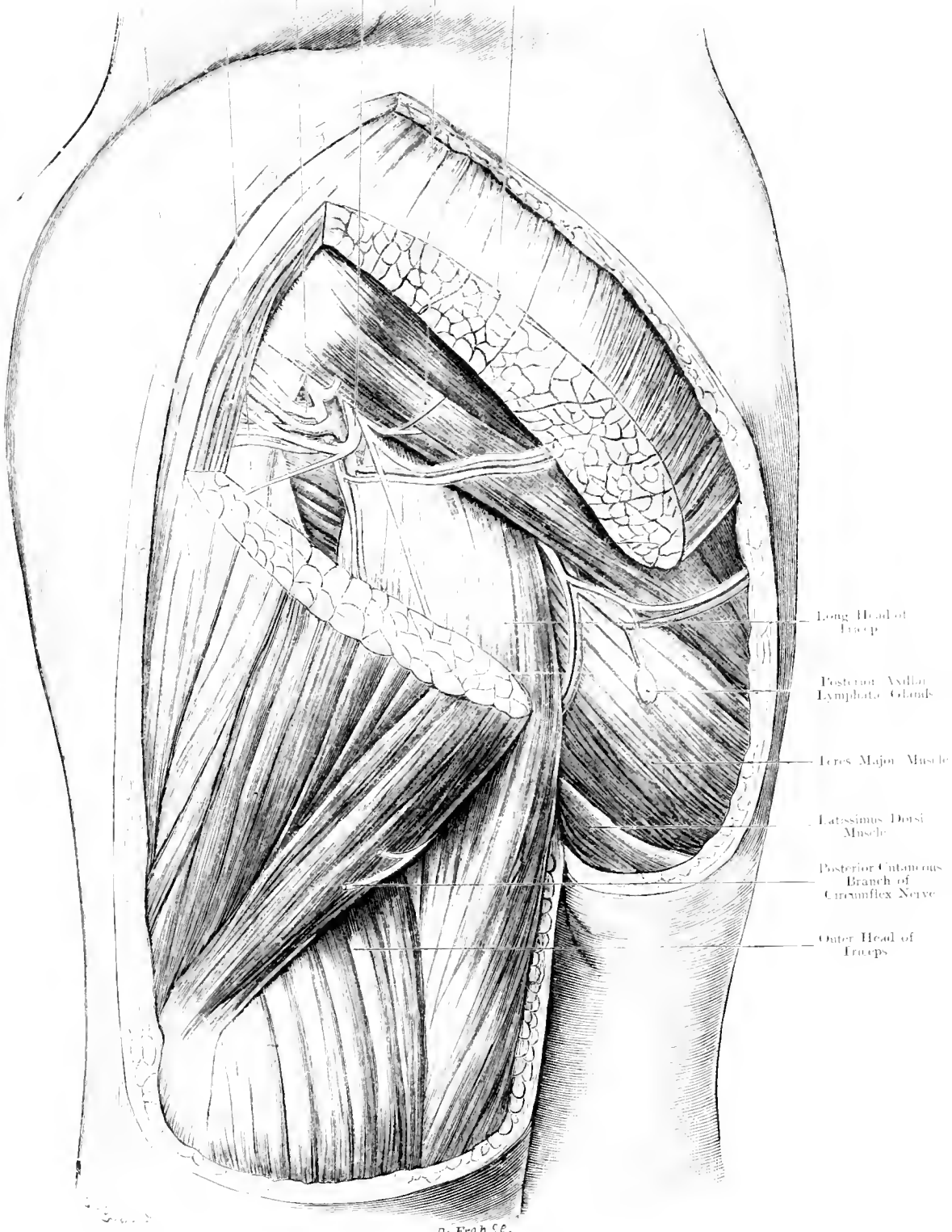


Fig. 76. Infra-Clavicular Fossa (Mohrenheim's Fossa).
 Nat. Size.



- Long Head of Triceps
- Posterior Axillary Lymphatic Glands
- Teres Major Muscle
- Latissimus Dorsi Muscle
- Posterior Cutaneous Branch of Circumflex Nerve
- Outer Head of Triceps

Fig. 77. Posterior Relations of the Shoulder-Joint.
 Nat. Size.

Fig. 77. Posterior Relations of the Shoulder-Joint.

Skin and Fascia have been removed over the posterior half of the Deltoid, of which a large portion has also been cut away.

The Anterior and the Posterior Circumflex Arteries arise, opposite each other, from the last part of the Axillary Artery and wind round the Surgical Neck of the Humerus, the former from in front, the latter from behind. The Posterior Circumflex Artery passes through the Quadrilateral Space formed by the Teres Minor (above), the Teres Major (below), the Humerus (anteriorly) and the Long Head of the Triceps (posteriorly). It supplies the Teres Minor, Deltoid etc., and ends by anastomosing with the Anterior Circumflex. With it run its 2 Venae Comites of which only the larger is shewn in the figure. Taking a similar course, but somewhat posterior, the Circumflex Nerve passes to innervate the Deltoid and Teres Minor Muscles and the skin over this region. Its large cutaneous branch emerges at the posterior border of the Deltoid Muscle and divides into an ascending and a descending branch.

On the Teres Major, below the Deltoid is a lymphatic gland which is probably constant, — the Posterior Axillary Gland (FRÖHSE) —, it is usually subcutaneous; in pathological cases, we have also found deep glands which lie on the blood vessels. Their efferent vessels pass through the triangular space, between the Teres Major, Minor, and Long Head of the Triceps, forwards to the Axilla.

On the dorsal aspect of the trunk there are other subcutaneous lymphatic glands which are neither constant in position nor in number (cf. Fig. 145 and text).

The Superficial Glands of the Thorax and Abdomen may be divided into Anterior, Posterior and External, according to their position.

Anterior Glands: Clavicular Glands lying on the Clavicle, above the Deltoideo-Pectoral Fossa, sometimes also on the origin of the Sterno-Cleido-Mastoid Muscle. (Cf. Fig. 115.)

Internal Pectoral Glands, usually at the level of the 2nd rib, along the inner border of the Breast (the blue gland in Fig. 114).

The Niphoid Gland, at the base of the Niphoid Process (cf. Fig. 114).

External Glands (i. e. external to the nipple line):

External Pectoral or Paramammary Glands, outside the Nipple, and along the outer border of the Breast. They are intermediate glands for the lymphatics of the nipple (cf. Figs. 114 and 115).

Thoraco-epigastric Glands (1—4) along the External Mammary Vessels. One of these glands is nearly always palpable and sometimes visible through the skin.

The most important of these glands are the Thoraco-epigastric, Paramammary and Posterior Axillary. The subcutaneous position of the first mentioned is especially well noticeable when LANGER'S Muscle (i. e. a muscular connection between Latissimus Dorsi and Pectoralis Major) is present. Their efferent vessels run in this case along the free border of the Axillary Fascia, where it is bounded by that muscle, before they open into the Axillary Glands.

The Shoulder-Joint is accessible for (operations) surgical measures from in front, and from behind. The Circumflex Nerve has, however, to be avoided on the posterior aspect, because injury would produce paralysis and atrophy of the Deltoid Muscle.

Fig. 78. Inner Side of the Right Arm. Natural Size.

The Skin has been completely removed between the Axilla and Antecubital Space; the deep Fascia has also been removed as far as it covers the Biceps and the upper portion of the Long Head of the Triceps Muscle.

The large vessels and nerves of the upper extremity run, in the arm, in the furrow along the inner border of the Biceps, which is discernible through the skin. This furrow is continuous above with the Axilla, and is lost below in the Antecubital Space. Below the Axilla, the Nerves and Vessels form an uniform, thick, visible and palpable cord. In the upper third of the arm, the Musculo-Spiral Nerve and the Superior Profunda Artery run backwards; the figure only shows their small branches supplying the Long Head of the Triceps. In the middle third, the Ulnar Nerve and the Inferior Profunda Artery leave the Neuro-Vascular Bundle, pierce the Internal Intermuscular Septum and appear on the posterior aspect of the limb. In the lower third, the Vessels and Nerves are grouped in 2 layers: the Superficial Layer comprising the large Basilic Vein and the Internal Cutaneous Nerve (cf. Figs. 81 and 82), the Deep Layer, separated from the former by fascia, consisting of the Brachial Artery with its Venae Comites, the Median Nerve and the Anastomotica Magna Artery.

The Brachial Artery runs, at first, along the Coraco-Brachialis, then along the Short Head of the Biceps (or the Biceps), being more or less overlapped by this muscle, according to its size. Its relation to the Median Nerve which crosses the artery at an acute angle is most important. In the upper part of the arm, the Nerve is antero-external to the Artery; in the middle part it lies in front

of and in the lower part to the inner side of the artery. In our figure, the Nerve is nearer the inner border of the Biceps than in most cases, thus leaving a greater part of the artery than usual uncovered.

At the usual point for ligature of the Brachial Artery in the middle of the arm, the Nerve generally lies in front of the vessel. It may, however, be posterior. Lower down, the Internal Cutaneous Nerve and the Basilic Vein are internal relations to the Median Nerve. (These have been mistaken for the Nerve and Brachial Artery when no attention was paid to the inner border of the Biceps. VON BERGMANN-ROCHS.) To the inner side, our figure shows the Ulnar Nerve, now embedded in the Inner Head of the Triceps.

The Brachial Artery sometimes divides into Radial and Ulnar Arteries at this level (high division) or even higher up. In such cases, one artery is usually in front and the other behind the Median Nerve. It should always be remembered that when an artery is found in front of the Median Nerve whilst ligaturing the Brachial Artery, a second artery should be sought deep to the Nerve, especially if the Superficial Vessel is small. This is rendered still more important by the fact that in a "high division", there is frequently a large communication between the 2 arteries at the Antecubital Space.

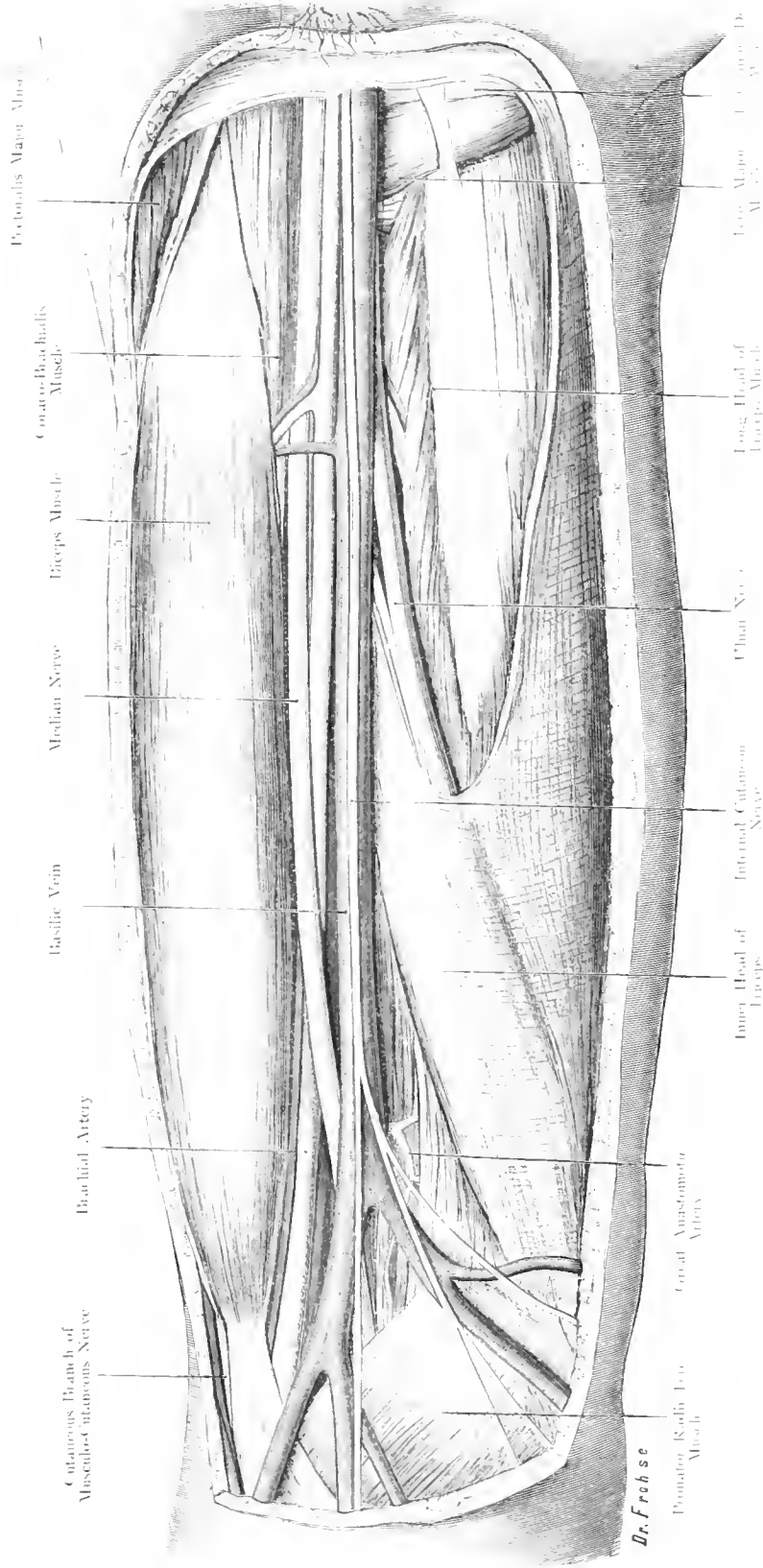


Fig. 78. Right Arm — Inner Side.

Nat. Size.

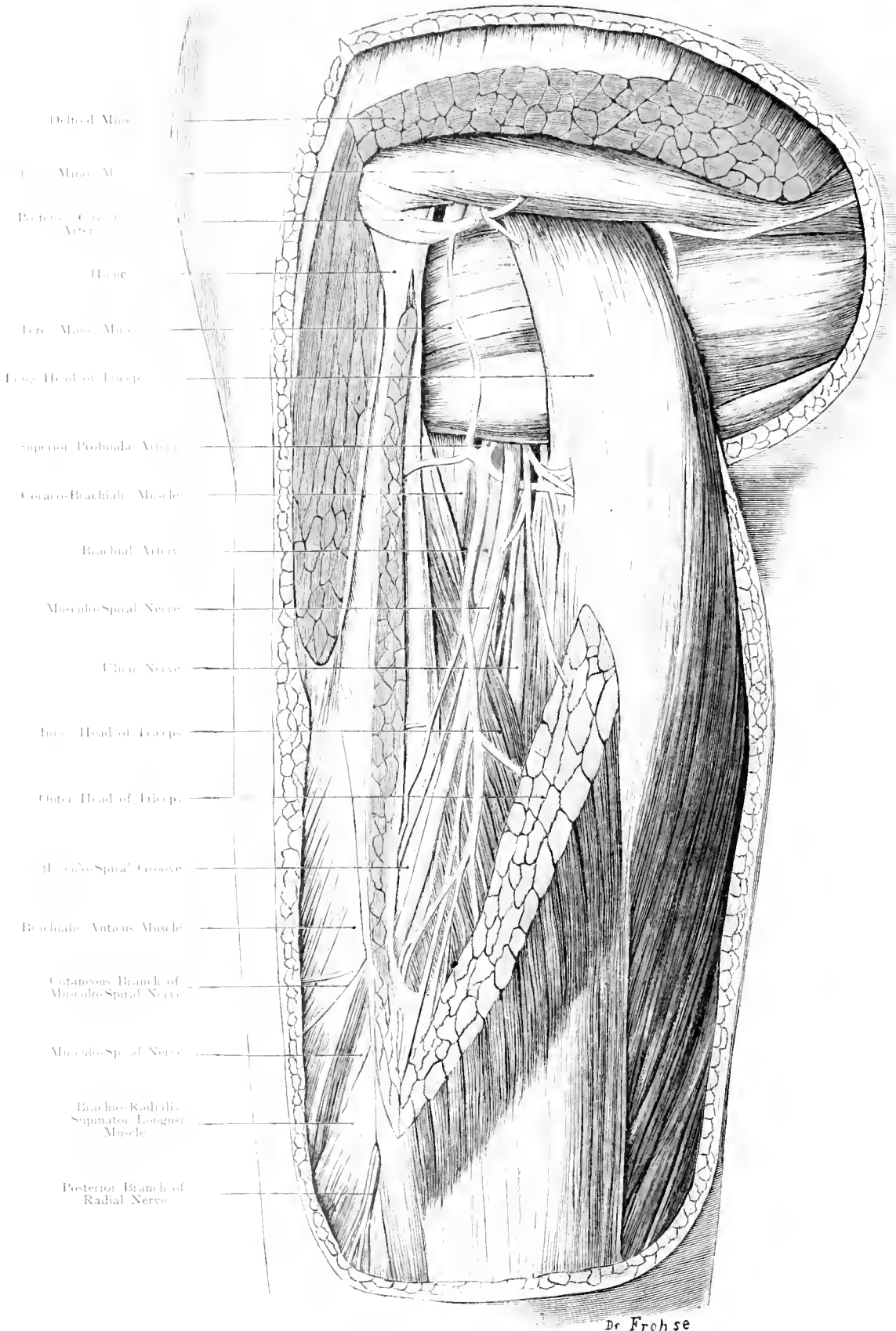


Fig. 79. Outer and Posterior Aspect of Left Arm. — Nat. Size.

Fig. 79. Left Arm, Outer and Posterior Aspect.

Skin and Fascia have been completely removed; a large piece of the Outer Head of the Triceps, and the posterior portion of the Deltoid Muscle below its origin have been cut away. The Long Head of the Triceps has been drawn downwards and backwards. The Venae Comites have been removed.

Below the Shoulder-Joint, from the anterior aspect backwards, around the Surgical Neck of the Humerus, between the Teres Minor and Teres Major, the Posterior Circumflex Vessels pass (the Artery being a branch of the Axillary and having 2 Venae Comites). The Circumflex Nerve accompanies them; it supplies the Deltoid and Teres Minor Muscles (cf. Fig. 77).

Behind the outer border of the Humerus emerge the Musculo-Spiral Nerve and the Superior Profunda Artery, as they wind around the bone in the Musculo-Spiral Groove (cf. Fig. 80). The Nerve pierces the External Intermuscular Septum and runs downwards to the forearm, between the Brachialis Anticus and the Brachio-Radialis Muscles (cf. Fig. 81). This spiral course of the nerve is a serious obstacle in extensive operations on the arm (e. g. extensive scraping of the Humerus for Osteomyelitis). The Anterior and Internal surfaces are not favourable for operations, owing to the large vessels; on the Posterior surface the Musculo-Spiral Nerve is in the way, because its course is not a straight one, like that of the nerves in the thigh. Its close proximity to the bone explains why it is so often injured in fractures, and why it may be pressed upon by or be embedded in Callus-formation.

The Ulnar Nerve runs for a short distance parallel to the Long Head of the Triceps.

The Superior Profunda Artery anastomosing, by means of a Recurrent Branch, with the Posterior Circumflex Artery, supplies the Triceps and the Humerus (nutrient artery) and divides into an Anterior and a Posterior Division. The former accompanies the Musculo-Spiral Nerve and ends by anastomosing with the Radial Recurrent Artery. The latter runs in the substance of the Inner Head of the Triceps downwards to the Olecranon where it anastomoses with the Interosseous Recurrent Artery.

Fig. 80. Transverse Section through the Middle of the Right Arm.

A specimen from a series of sections taken from a frozen body. This section shows the under surface of a right upper stump, or the upper surface of a left arm. For practical purposes, the former interpretation is to be preferred.

Note: The relation of the Median Nerve to the Brachial Artery; the Ulnar Nerve and the Musculo-Spiral Nerve winding round the bone. The External Intermuscular Septum is well displayed; the Internal is not distinctly visible in this section.

The Flexors (Brachialis Anticus, Biceps and Coraco-Brachialis), are separated from the Extensors (Triceps) by the Intermuscular Septa. The Internal Septum runs along the inner border of the Humerus to the Internal Condyle. The External Septum extends from the insertion of the Deltoid Muscle downwards along the outer border of the shaft of the Humerus to the External Condyle. The Internal Septum is really the fibrous continuation of the Coraco-Brachialis (which passes in some animals to the Internal Condyle). The enormous Triceps presses these Septa forwards; in this section they are shewn to describe a curve with its convexity directed forwards. Both groups of Muscles thus lie in fibrous sheaths, formed by the Fascia of the arm, the Intermuscular Septa and the Periosteum.

Fig. 81. Transverse Section through the Lower Third of the Right Arm.

Section through a right arm hardened in formalin. Interpretation similar to that of the section above (Fig. 80).

Note the differences in shape, size, and position of the various structures, as compared with Fig. 80. Shape of the Humerus, of the Biceps, of the Brachialis Anticus, of the Triceps. -- Change in the position of the Musculo-Spiral Nerve which has left the bone, of the Ulnar Nerve which has reached the Internal Intermuscular Septum etc. In this figure, all the Fasciae are coloured blue. Thus the continuity of the Intermuscular Septa with the Periosteum, at the outer and at the inner border of the Humerus, and with the Deep Fascia is shewn. The latter binds down the muscles and forms thin fascial septa between them; i. e. between Biceps, Brachialis Anticus, Coraco-brachialis, and between the 3 heads of the Triceps.

The whole arm is enclosed in the Superficial Fascia which is especially strong on the extensor aspect. On the Deep Fascia run, covered by the superficial fascia, the Superficial Veins and Nerves.

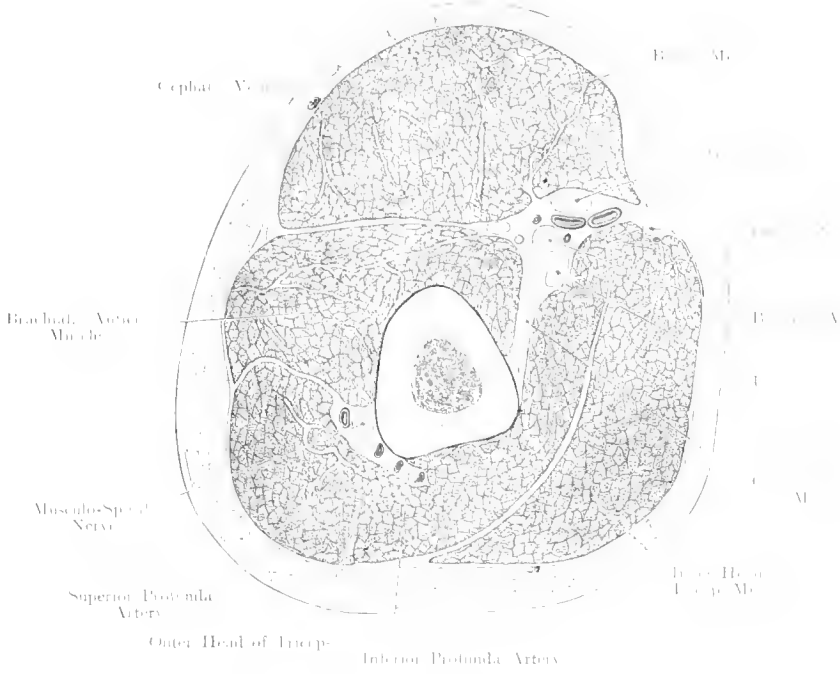


Fig. 80. Transverse Section through the Middle of the (right) Arm.
View from below. Nat. Size.

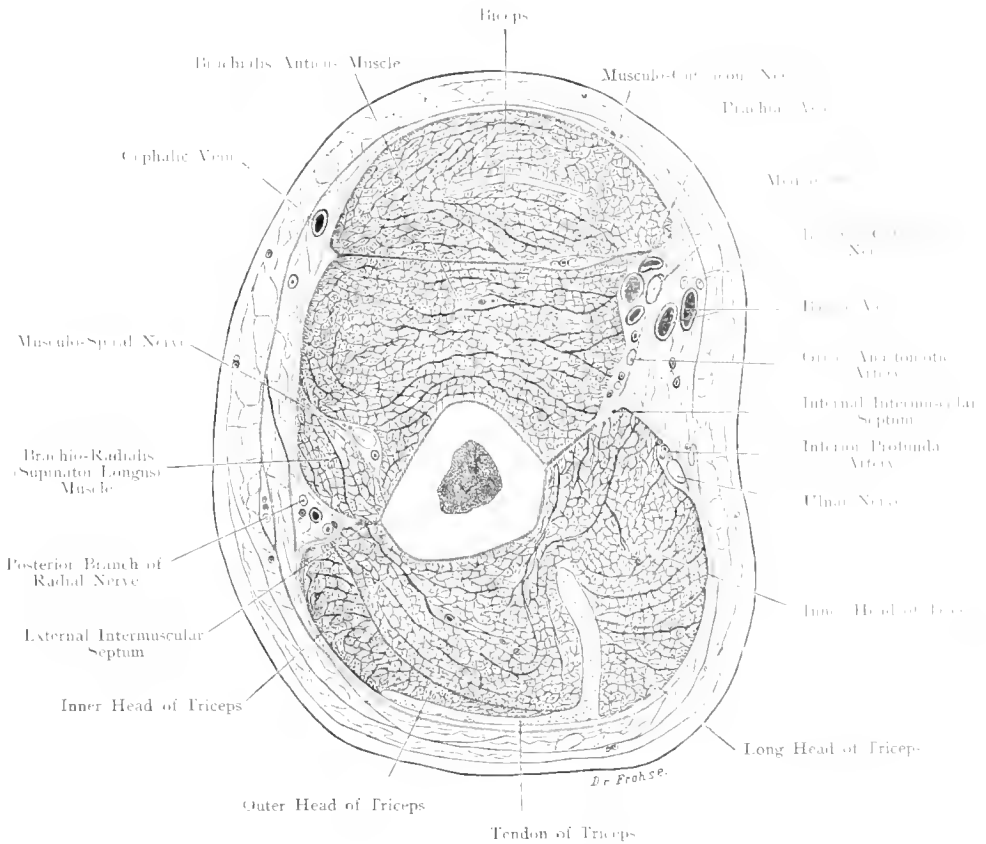


Fig. 81. Transverse Section through the Lower Third of the Right Arm.
Nat. Size.

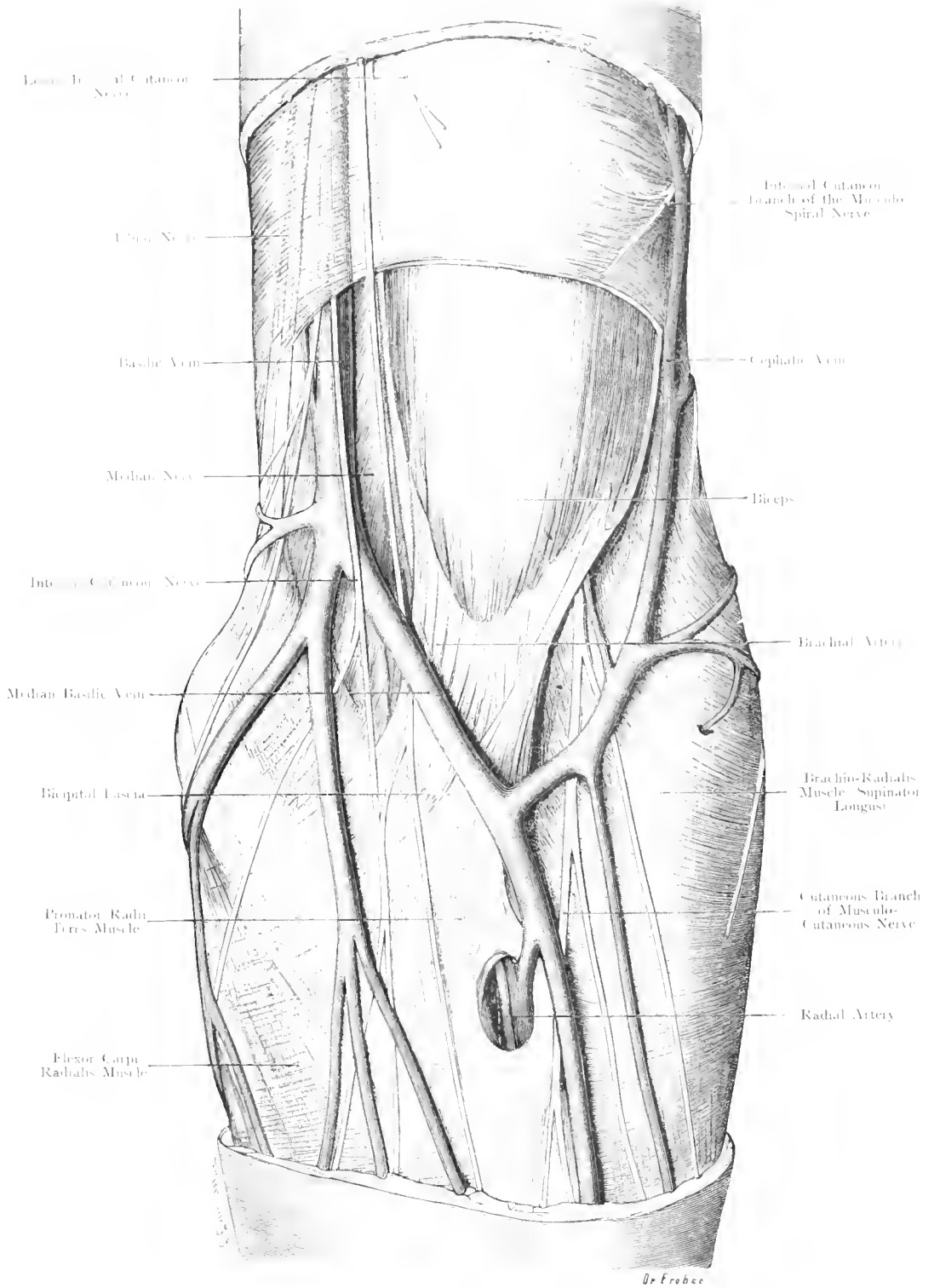


Fig. 82. Left Antecubital Space — Superficial Layer.
Nat. Size.

Fig. 82. Left Antecubital Space. Superficial Layer.

The Skin over the lower part of the arm, and over the upper part of the forearm has been removed. The Superficial Fascia covering the Biceps and the Superficial Veins and Nerves have also been taken away, but the Bicipital Fascia and its expansions in the forearm are left intact.

The superficial and broad Bicipital Fascia ends by an expansion into the Deep Fascia of the forearm and by blending with the Periosteum of the Ulna. The true Tendon of the Biceps is inserted into the Radius. The Superficial Muscles which arise from the Internal Condyle are intimately connected with the Deep Fascia and the Bicipital Fascia in the upper part of the forearm.

Superficial Veins. At the upper end of the forearm 2 constant and one not-constant Veins are found: the Ulnar and Radial Veins, and the Median Vein. The latter vein divides into the Median Basilic, and the Median Cephalic Veins, the former joining the Ulnar forms the Basilic Vein, the latter joining the Radial forms the Cephalic Vein. These veins vary. As a rule, the Median Basilic Vein is the largest vein in the Antecubital Space, and the most suitable for Phlebotomy.

The Cephalic Vein runs upwards in the arm and disappears between the Pectoralis Major and Deltoid Muscles, to join the Axillary Vein (cf. Fig. 75 and 76). It thus forms a collateral venous channel. The Basilic Vein joins the Venae Comites of the Brachial Artery and then forms the Axillary Vein, which, higher up, becomes the Subclavian (cf. Axilla).

The Median Basilic Vein is separated from the Brachial Artery by the Bicipital Fascia. The Artery can therefore be injured in Phlebotomy, and this injury may be followed by an Arterio-venous Aneurysm.

The 2 chief Cutaneous Nerves of the forearm, the Cutaneous Branch of the Musculo-Cutaneous Nerve and the Internal Cutaneous Nerve become superficial at the Antecubital Space. The latter nerve runs with the Basilic and Ulnar Veins. Its trunk and its branches lie in $\frac{7}{8}$ th of all cases at a slightly deeper level than the veins. The nerve may have divided into 2 large branches, where it pierces the fascia of the arm.

Fig. 83. Right Antecubital Space. Deep Layer.

Skin, Superficial, and Deep Fasciae have been removed. The following muscles are exposed: Biceps with Bicipital Fascia, Brachialis Anticus, as far as it is not-covered by Vessels and Nerves, the upper portion of the Superficial Flexors which arise from the Internal Condyle, especially the Pronator Radii Teres. The Brachio-Radialis which has at its upper portion been drawn outwards, is also displayed.

(As to the superficial nerves and veins which have been left in this specimen, see Fig. 82 text.)

The Brachial Artery runs, accompanied by its Venae Comites, along the inner border of the Biceps, towards the acute angle formed by the Pronator Radii Teres and the Brachio-Radialis Muscles. In its course, — in front of the line of the joint — it divides into the more superficial and smaller Radial, and the more deeply placed and larger Ulnar Artery. Internal to the Brachial Artery (or rather to its Internal Vena Comes) runs the Median Nerve which may, however, lie more than $\frac{2}{16}$ th inch internal to the vessel. This nerve pierces the Pronator Radii Teres and supplies the Superficial and the Deep Flexors of the forearm, except the Flexor Carpi Ulnaris and the inner portion of the Flexor Profundus Digitorum (cf. Fig. 89).

Along the outer border of the Biceps runs, at a deeper level, the Musculo-Spiral Nerve; this Nerve lies between the Brachio-Radialis and Brachialis Anticus Muscles (cf. Fig. 89).

The mass of muscles arising from the Internal Condyle of the Humerus and the portion of bone above it, and from the deep fascia of the forearm, separates lower down into the Pronator Radii Teres which is inserted at the middle of the outer border of the Radius, into the Flexor Carpi Radialis going to the base of the 2nd Metacarpal Bone, into the Palmaris Longus, which is not always present, and into the Flexor Carpi Ulnaris, which arises also from the Ulna.

The lymphatic glands are described in Figs. 89 and 115 text.

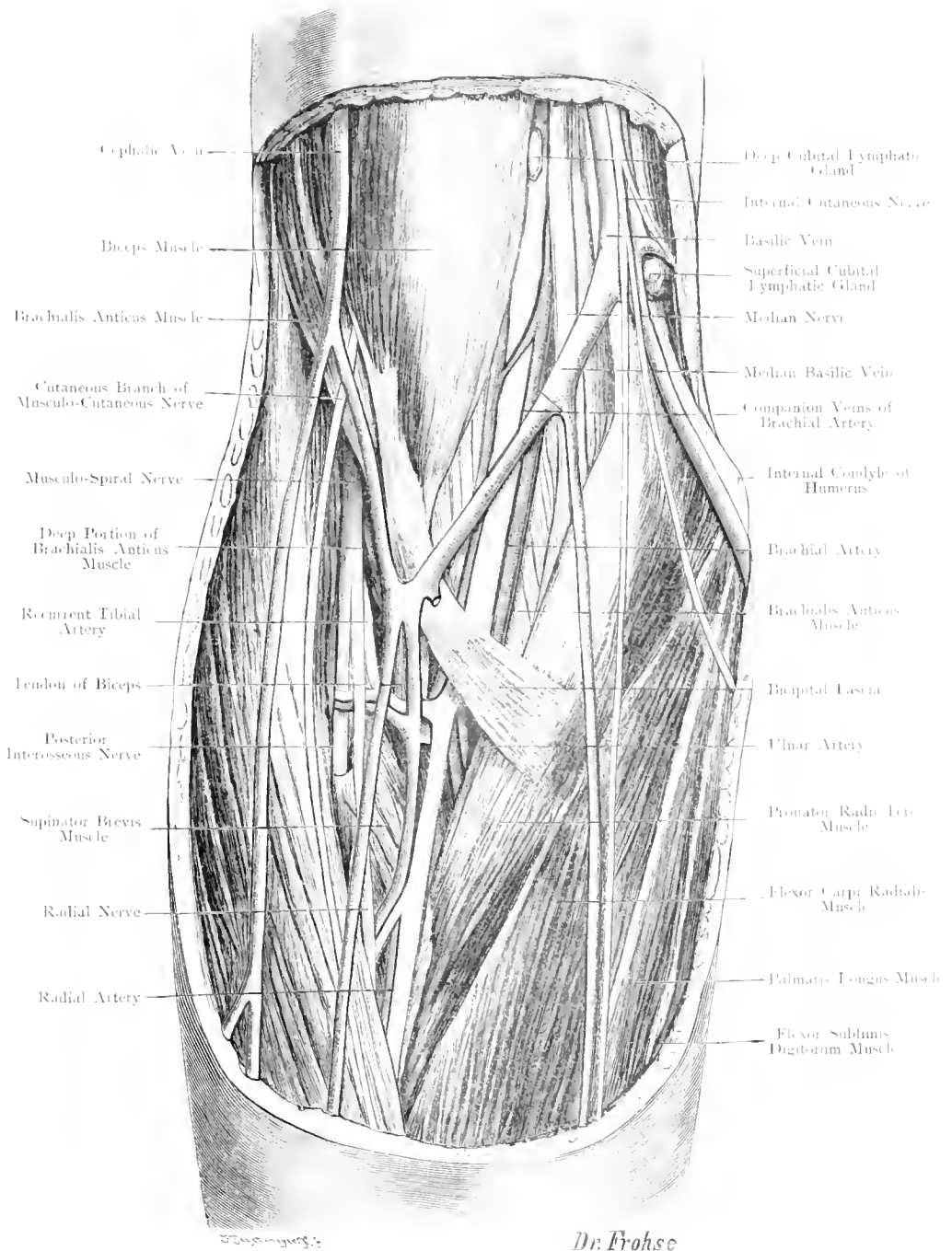


Fig. 83. Right Antecubital Space: Deep Layer.

Nat. Size.

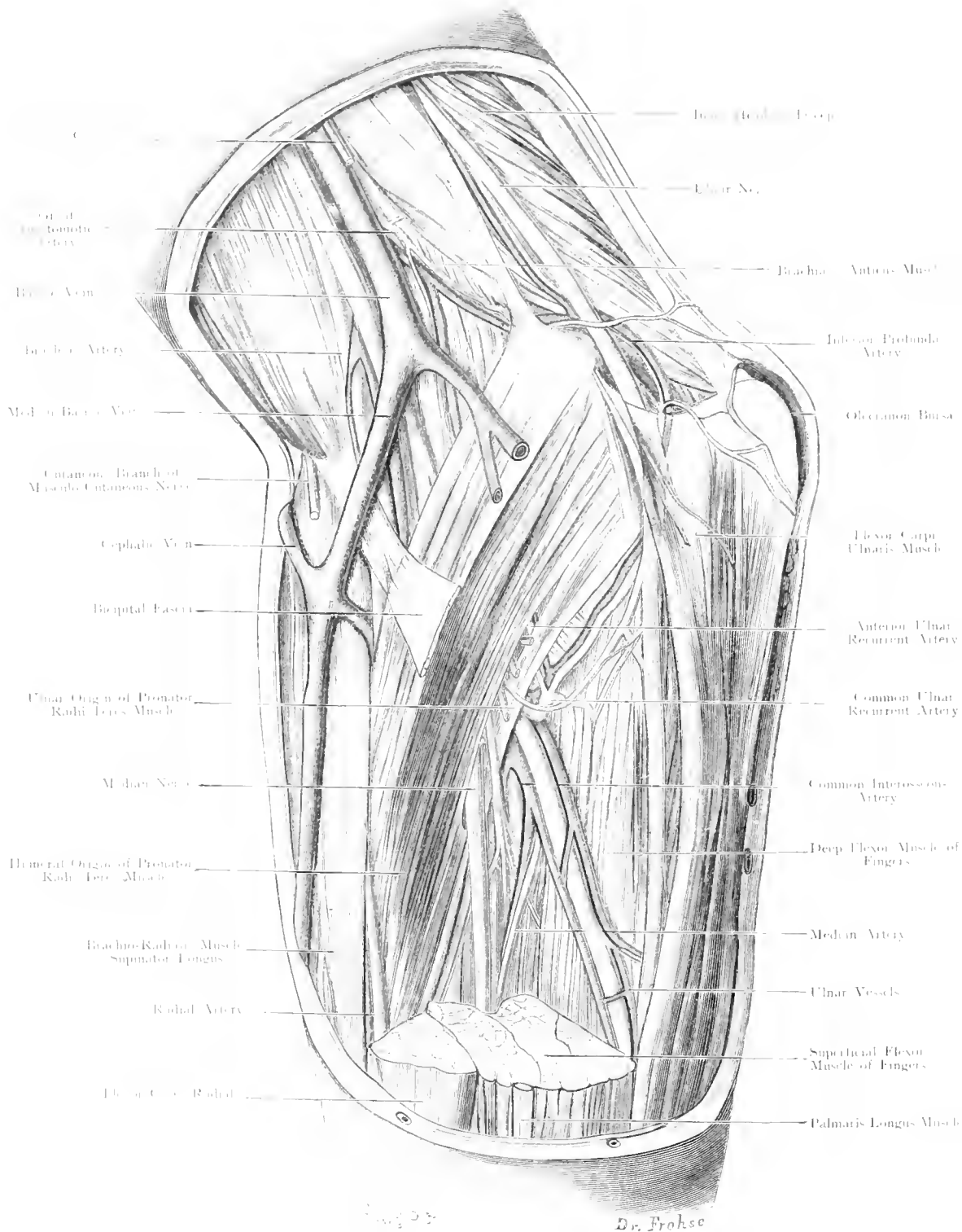


Fig. 84. Region of Elbow — Right Side.
Nat. Size.

Fig. 84. Region of Elbow - Right Side.

Skin, Superficial Fascia (except the Bicipital Fascia) and the upper portions of the Superficial Muscles arising from the Internal Condyle have been removed; the Pronator Radii Teres, however, is left intact.

This figure shews the region of the Elbow, the deep layer of the Antecubital Space and the upper third of the Forearm, from the inner side.

The course of the Ulnar Nerve behind and below the Internal Condyle is well displayed. The nerve having pierced the Internal Intermuscular Septum, comes to lie behind this Septum, often embedded in the Triceps Muscle; then, passing behind the Internal Condyle, it runs between the Humeral and the Ulnar Origins of the Flexor Carpi Ulnaris Muscle. The Ulnar Nerve supplies the Inner Head of the Triceps, and both Heads of the Flexor Carpi Ulnaris, giving off an anastomotic branch to the Median Nerve. In man, only a portion of the Flexor Profundus Digitorum, the slips to the 4th and 5th fingers, are supplied by the Ulnar Nerve.

Behind the Olecranon is the subcutaneous bursa which is the bursa most frequently diseased, with the exception of the Patellar Bursa (Miner's Elbow). Cf. Fig. 86.

There may be a Common Ulnar Recurrent Artery (branch of the Ulnar Artery) which divides into Anterior and Posterior Ulnar Recurrent Arteries, or these vessels may come off directly from the Ulnar Artery. The Anterior Ulnar Recurrent Artery anastomoses with the anterior division of the Inferior Profunda and the Anastomotica Magna, both from the Brachial Artery, and the posterior branch with the posterior division of the Inferior Profunda.

Remarks on the Mechanics of the Elbow-Joint.

The articular surfaces correspond to the type of hinge-surfaces, but not exactly. It has been suggested that they are analogous to screw surfaces. As a matter of fact, they correspond to neither type, although the Trochlea of the Humerus has the shape of a screw surface shewing an inclination of 0.15 inch, a lateral movement of the Ulna does not take place during flexion and extension. Careful investigation shews that the axis of rotation varies constantly during movement, and that the change in direction is much greater than a simple screw movement would account for. — If the movement were a simple rotation, the Ulna should move on the Humerus with as equal freedom as the Humerus on the Ulna; this is not the case according to OTTO FISCHER.

This joint has, therefore, been described as a loose-joint, but FISCHER has shewn that during life the cartilaginous coverings of the joint continuously change their position and shape during movement owing to the action of the muscles which press them firmly together, and that the joint is no "loose-joint".

Fig. 85. Transverse Section through the Right Elbow-Joint.

The section (through a frozen body) has passed, transversely to the axis of the Humerus, through the Trochlea and Radial Head of the bone, through the base of the Olecranon, and the tip of the Coronoid Process of the Ulna.

The reader looks at a right forearm from above. The Head of the Radius with its elevated border lies free; the deeper middle portion is taken up by the radial head of the Humerus. The strength of the Internal and External Lateral Ligaments, the Bursa over the Olecranon, the position of the Ulnar Nerve behind the Internal Condyle, and the positions of Median Nerve, Brachial Artery and Musculo-Spiral Nerve on the flexor aspect are all worthy of observation. The Brachial Artery divides, as a rule, at the level of the line of the joint (i. e. the level of this figure) into Radial and Ulnar Arteries. Below this level, the lumina of these 2 arteries, one superficial (Radial Artery), and one deep (Ulnar Artery), would appear in a transverse section.

When the forearm is extended, the tip of the Olecranon Process (cf. Fig. 86), lies immediately below a line connecting the 2 Condyles of the Humerus. In flexion, it lies at a considerable distance below this line. Dislocation of the Ulna or fracture of the Olecranon Process is present, if the Olecranon lies above this line during flexion of the Forearm.

— — — —

Fig. 86. Longitudinal Section through the Left Elbow-Joint.

The Forearm is in the position of almost complete extension. The section passed through the Trochlea of the Humerus, the Greater Sigmoid Cavity of the Ulna and through a portion of the Radius; it is, therefore, intermediate between a frontal and a sagittal section.

Note:

- 1) The Subcutaneous Bursa over the Olecranon Process.
- 2) The Deep Bursa, above the Olecranon Process, situated in front (under cover) of the Triceps, or in the muscle substance, just above the upper recess of the Capsule of the Joint.
- 3) The Bursa at the Insertion of the Biceps (Bicipital Bursa).

The insertion of the Capsule of the Elbow-Joint on to the Humerus runs along the upper borders of the 3 fossae which receive the Olecranon (posterior) Coronoid Process (anterior larger) and Head of Radius (anterior smaller). These three fossae are therefore intracapsular. — On the Ulna, the Capsule is attached to the border of the cartilage of the Sigmoid Fossa or very near that border. — On the Radius, the attachment is in the middle between the lower border of the Head, and the Bicipital Tuberosity, extending lower down on the outer side than on the inner.

The Capsule itself is very thin, but it is strengthened by anterior and posterior longitudinal and oblique fibres, and especially by the Lateral Ligaments, an Internal and an External Ligament (cf. Fig. 85). The External Lateral Ligament blends with the Orbicular Ligament, of the Radius, which surrounds the Head of that bone and is attached to the Ulna.

(Continuation next page.)

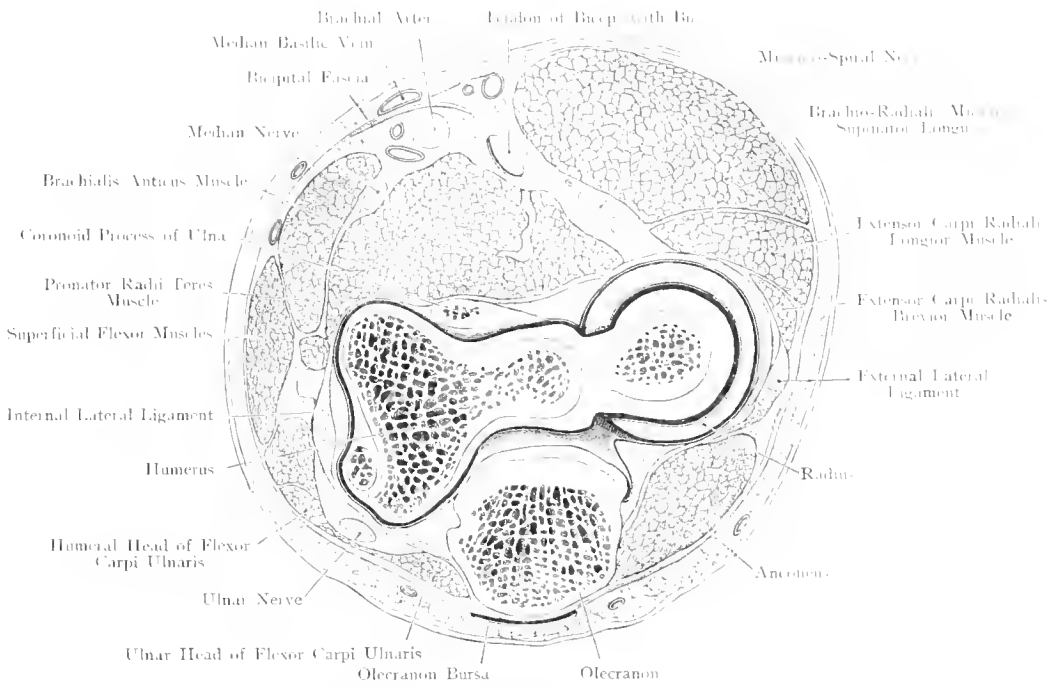


Fig. 85. Transverse Section through Right Elbow-Joint.
 Seen from above. — Nat. Size.

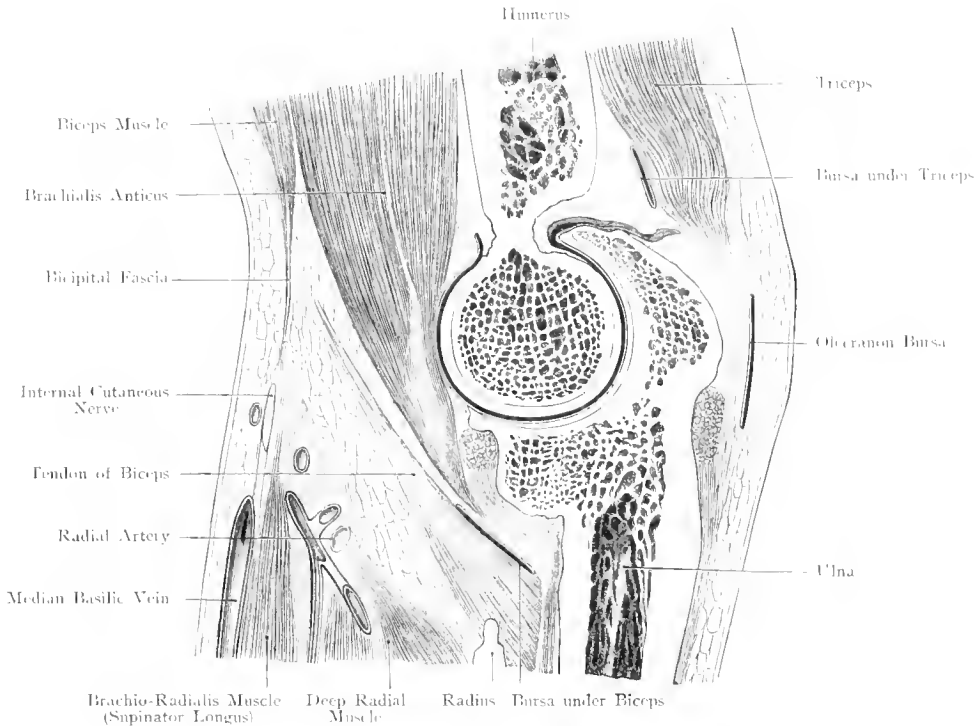


Fig. 86. Longitudinal Section through (left) Elbow-Joint.
 View from outer Side. — Nat. Size.

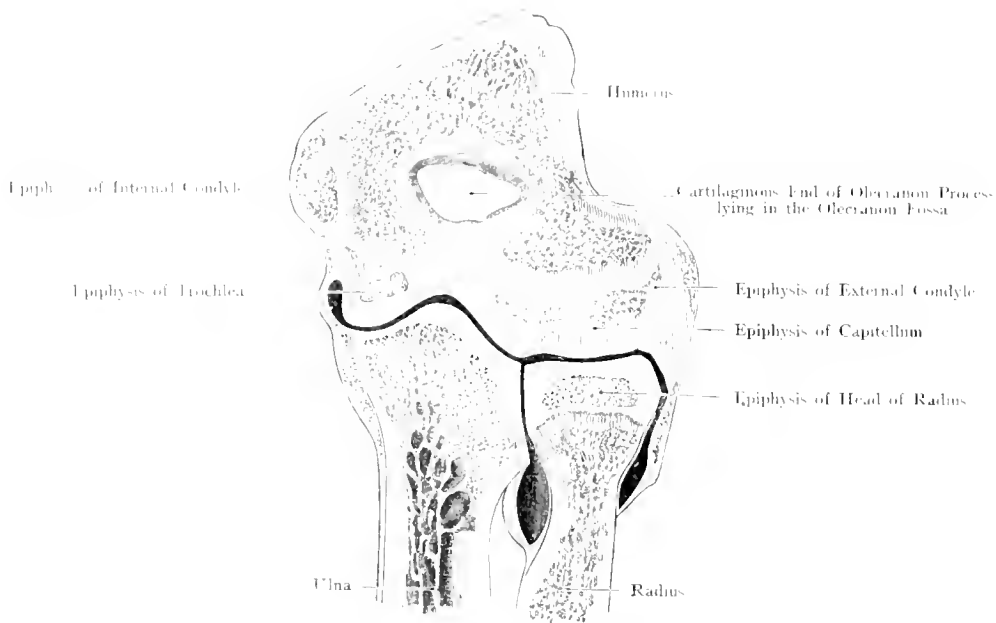


Fig. 87. Frontal Section through (right) Elbow-Joint of a person aged 19 years.
Nat. Size. -- After VON BRUNN.

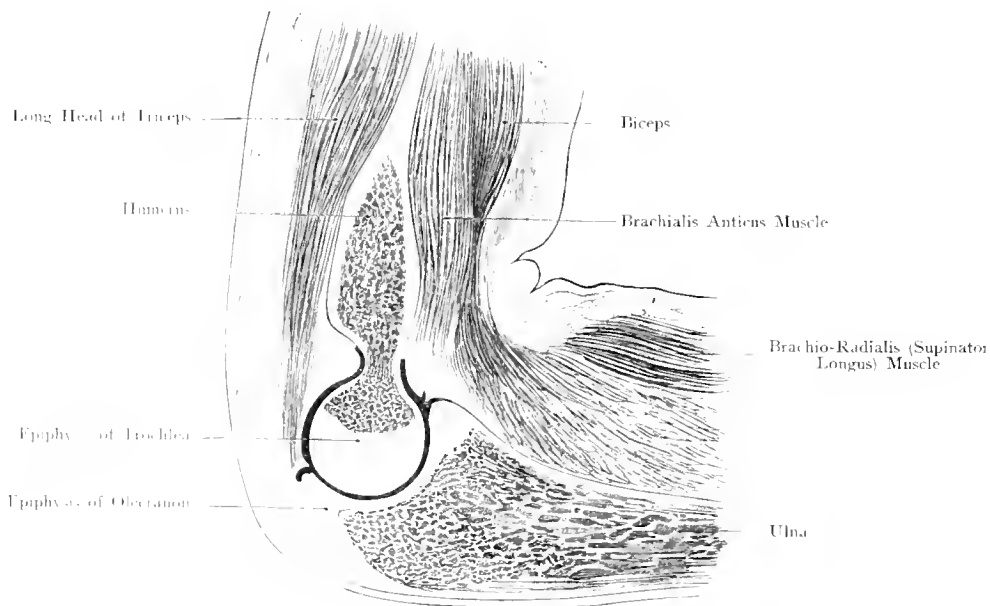


Fig. 88. Sagittal Section through (left) Elbow-Joint of a child aged 8 years.
Nat. Size. -- After VON BRUNN.

(To Fig. 86, former page.)

The lateral ligaments are very important in relation to the movements of the joint. They become tense in marked flexion and extension.

Synovial continuations corresponding to the 3 fossae (vide supra) are formed by the wall of the Capsule: a large posterior, and 2 smaller anterior continuations. The one first mentioned is drawn upwards and backwards, during extension, thus coming to lie above the Olecranon, between this bone and the Triceps (cf. figure). During flexion, it fills the Olecranon Fossa; — the 2 anterior processes present an opposite movement; thus the Anterior Ulnar Synovial Continuation (cf. figure) lies in the greater anterior fossa in front of the Trochlea of the Humerus, during extension.

During extension a recess of the Capsule—analogue to the one above the Patella in the knee-joint — is formed above and behind the Olecranon. This cul-de-sac extends higher in the living subject than is shewn in our figure, which, necessarily, was drawn after death.

The Joint is most readily accessible from behind; in front there are powerful muscles, and large vessels and nerves to be avoided, behind there is only the Ulnar Nerve. Effusion into the joint bulges most at either side of the Olecranon.

Fig. 87 and 88. Relation of the Capsule of the Elbow-Joint to the Epiphysial Lines. (After VON BRUNN.)

Fig. 87. Frontal Section through the Right Elbow-Joint of a person aged 19 years.

View from behind.

The Joint-Cavity extends far beyond the Epiphysial Line of the Head of the Radius; but even here, the Capsule arises (cf. Shoulder-Joint) from the Articular Cartilage, and is loosely attached to the Radius as far as the lower end of the cavity.

Disconnection of the united Epiphyses of the External Condyle and the Radial Head of the Humerus from the rest of the bone will involve the Joint-Cavity; the latter would also be affected if the Epiphysis of the Trochlea were separated at the place where the Trochlea and the Radial Head meet.

Fig. 88. Sagittal Section through the Left Elbow-Joint of a child aged 8 years.

View from the inner side.

The boundary line between the Diaphysis of the Ulna and the Epiphysis of the Olecranon passes across the Joint-Cartilage. — The Capsule also extends above the line of the Diaphysis of the Humerus: Though fairly strong in front and readily removed as far as the Joint-Cartilage it is firmly attached to the Olecranon Fossa, and very thin, thus defying dissection.

Separation of the Epiphyses, — both of Humerus and Ulna —, will therefore affect the Joint-Cavity.

Fig. 89. Right Forearm, Deep Layer: Anterior Aspect.

The Fasciae of the Antecubital Space and of the anterior aspect of the forearm are removed, including the Bicipital Fascia, e. g. of the Superficial Flexors, only their origin and insertion are left. The Deep Head of the Pronator Radii Teres is intact, and the Brachio-Radialis is drawn outwards.

The Brachial Artery divides into Radial and Ulnar usually in front of the line of the Joint. The Ulnar Artery runs downwards and inwards, under cover of the muscles which arise from the Inner Condyle of the Humerus; below the middle (or near the middle) of the forearm, it meets the Ulnar Nerve, which runs along its inner (ulnar) side.

The Median Nerve, as a rule, leaves the vessels in the antecubital space, pierces the Pronator Radii Teres and runs downwards between the Superficial and Deep Flexors. Near the wrist, the Nerve emerges at the outer border of the Flexor Sublimis Digitorum (or Palmaris Longus, if present), and comes to lie just under the Fascia.

The Musculo-Spiral Nerve lies at the inner border of the Brachio-Radialis, and divides into (1) the Posterior Interosseous, which supplies the Extensors of the forearm (cf. Fig. 90) and (2) the Radial Nerve, which accompanies the Radial Artery in the upper $\frac{2}{3}$ of the forearm, and then passes to the posterior aspect (cf. Fig. 93).

The Ulnar Nerve having pierced the Flexor Carpi Ulnaris, runs, to the hand, along that muscle. At the junction of the middle and lower $\frac{1}{3}$ of the forearm, it gives off the Dorsal Cutaneous Branch for the hand (cf. Fig. 93). The Ulnar Artery and Nerve only accompany each other in the lower $\frac{1}{3}$ of the forearm.

The Anterior Interosseous Artery, the Radial and Ulnar Recurrent Arteries are shown in the figure; these latter are important for carrying on the collateral circulation on the outer and inner sides of the arm respectively.

We make special mention of the Lymphatic Glands in this region about which so little is known; in the Antecubital Space: Superficial, Deep, Posterior Cubital Glands; on the forearm: Radial and Ulnar Glands.

When the Palmaris Longus is absent — and in some cases also where it is present — one can make the following observation. When the hand is flexed upon the forearm, the tendons recede, and thus the Median Nerve comes to lie directly under the fascia, where it can be seen, felt and rolled about. The Ulnar Artery becomes at the same time more deeply placed, owing to the relaxation of the Flexor Carpi Ulnaris Muscle. When the hand is extended (dorsiflexed) the Median Nerve slides back into position and the Flexor Carpi Ulnaris presses the Ulnar Artery to the surface. The pulse can now be readily felt by placing the finger on the outer side of the tendon of that muscle.

The position of the hand and the fingers at the moment of injury, traumatism, etc. is therefore most important. In Flexion, there is more danger for the Median Nerve. In Extension the Ulnar Artery (and even the Ulnar Nerve) is in greater peril, even when no muscle or tendon is injured.

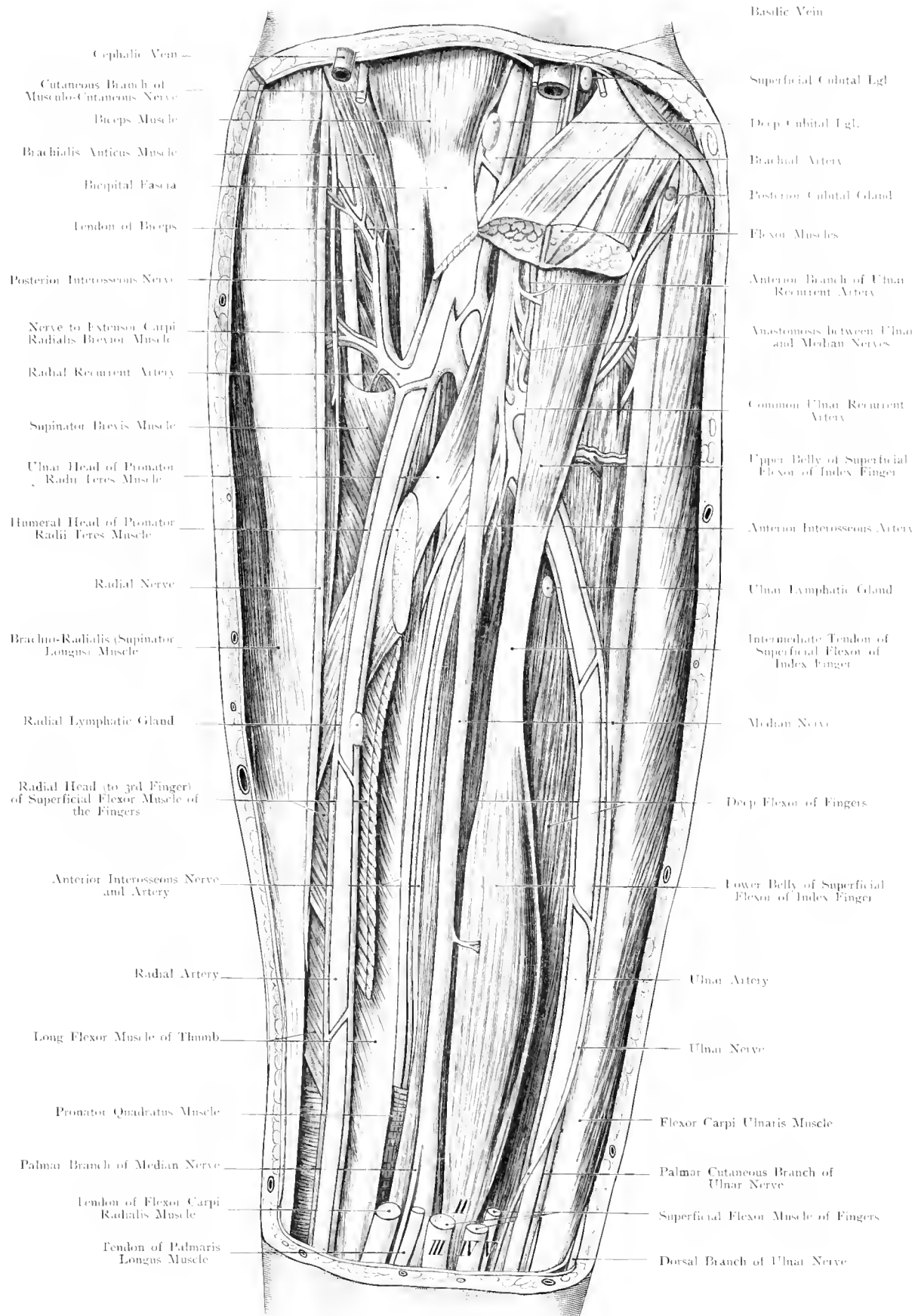


Fig. 89. Right Forearm: Deep Layer. Anterior Aspect. - Nat. Size.

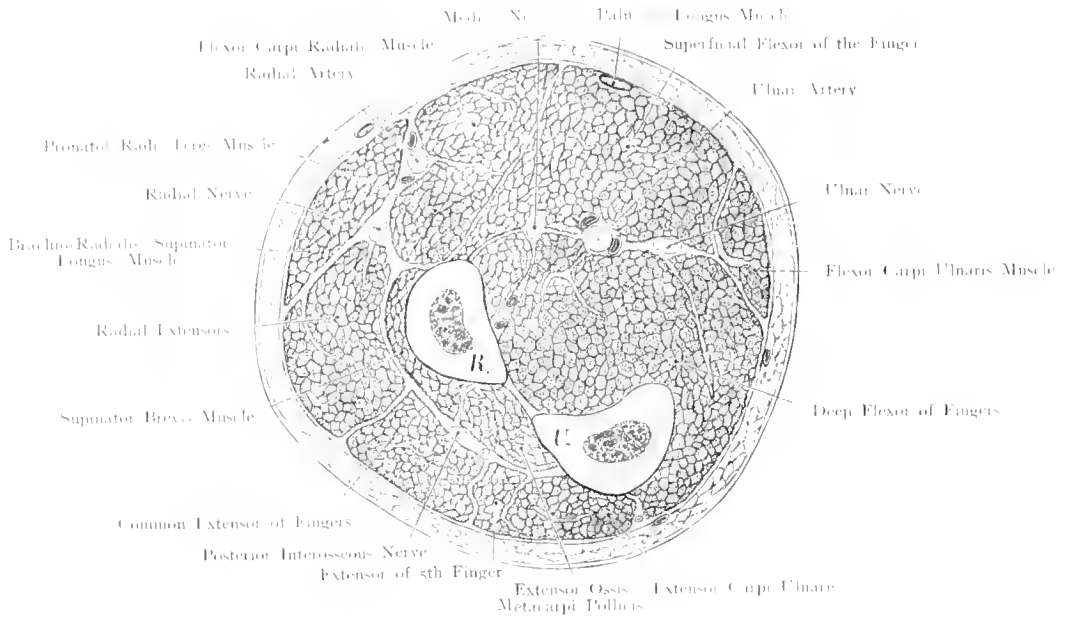


Fig. 90. Transverse Section at the Junction of the Upper and Middle Thirds of the (right) Forearm.

Nat. Size.

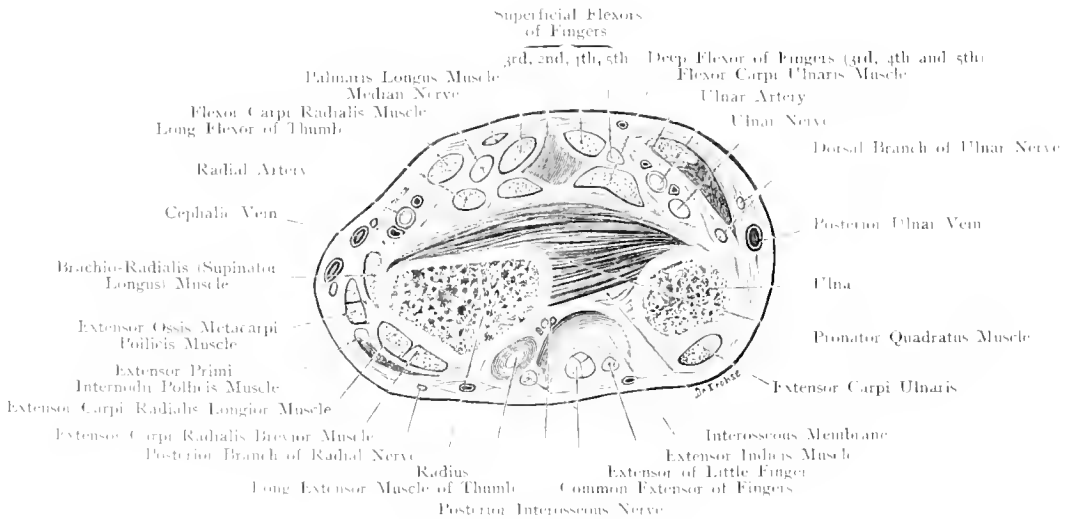


Fig. 91. Transverse Section through Lower End of (right) Forearm.

Nat. Size.

Fig. 90. Transverse Section through the Right Forearm at the junction of the Upper and Middle Thirds.

Frozen section. View of a Right Arm from below, or a Left Arm from above.

On the Flexor Aspect are to be noted: Position of the Palmar Branch of the Radial Nerve (too large in the figure) under cover of the Brachio-Radialis; position of the Radial Artery between this muscle and the Pronator Radii Teres, about $\frac{2}{5}$ ths inch from the fascia. Median nerve in the middle between the Radial and Ulnar Nerves, both deeply embedded in the muscles. Between the Median and Ulnar Nerves is the Ulnar Artery; the Anterior Interosseous Artery runs very near the Radius. Intermuscular Septa are seen between the superficial and the deep flexors, and between the flexor and the extensor muscles.

Dorsal aspect: Posterior Interosseous Nerve and Artery between the Supinator Brevis and the Extensors. Near the condyles of the Humerus the special Fasciae blend with the Deep Fascia of the forearm; at the middle $\frac{1}{3}$ rd they are separate, thus forming the "Lymph spaces" in which inflammation — simple and suppurative — rapidly spreads.

Fig. 91. Transverse Section through the Right Forearm at the lower end.

Frozen section. View of a Right Arm from below, or of a Left Arm from above.

Note: Portion of the Radial Artery, where the pulse can be felt and where the artery is generally ligatured, between the skin and the bone, separated from the latter by fibres of the Pronator Quadratus. — Ulnar Artery usually covered by the Tendon of the Flexor Carpi Ulnaris; at a deeper level, and more towards the inner (ulnar) side lies the Ulnar Nerve — Median Nerve, between the Flexor Carpi Radialis and Flexor Sublimis Digitorum, usually somewhat covered by the Palmaris Longus (cf. Fig. 95), if this muscle is present and normally developed.

Fasciae and Septa are coloured blue in the figure which is a supplement to Figs. 94, 97 and 98 in which the tendon sheaths at the wrist are shown.

The separation of the special fasciae and the fascia of the forearm (cf. Fig. 90) is also well carried out here, although there are no synovial sheaths. The fascia forms on the flexor aspect special compartments for the Flexor Carpi Radialis, Flexor Carpi Ulnaris and Palmaris Longus. This explains why there are 2 Fasciae in front of the Ulnar Artery, whilst the Radial Artery lies immediately under the fascia of the forearm. An incision for ligaturing the Ulnar Artery, carried along the border of the Flexor Carpi Ulnaris, divides not only the fascia of the forearm, but a second fascia which becomes thicker lower down. This fascia forms the posterior wall of the fascial canal, in which the muscle runs.

The Pronator Quadratus is covered by a fascia of its own. It is true that the other Flexor Muscles and the Median Nerve also have their own fasciae, but they are of no practical importance, and one should regard these muscles as lying in a common "Lymph Space" which ends below at the upper limits of the Tendon Sheaths and is bounded on either side by the Septa forming the canals for the 3 muscles mentioned above. Above, this Lymph Space is continued into the arm, along the Vessels and Nerves. This explains the danger (and also the necessity of making deep incisions) of deep suppuration in the forearm.

Fig. 92. Region of the Right Wrist, Outer Surface ("Snuff-Box").

The Skin and Superficial Fascia have been removed. The Posterior Annular Ligament is intact, its relation to the Anterior Annular Ligament is shown. The Radial Artery has been dissected out.

From the posterior aspect of the forearm, the tendons of the following muscles pass under the Posterior Annular Ligament to the Thumb: Extensor Ossis Metacarpi Pollicis, Extensor Primi and Extensor Secundi Internodii (their tendon sheaths are described Fig. 94, text). The Radial Artery runs over the outer (radial) border of the Carpus (Scaphoid, Trapezium) to the first interosseous space, where it passes forwards on to the palmar aspect to join the Deep Branch of the Ulnar Artery, thus forming the Deep Palmar Arch. On the dorsum of the hand, it is crossed by the tendons of the Extensor Muscles of the thumb, the Radial Vein and the Radial Nerve, all the structures being superficial to it. The Radial Vein collects blood from the Thumb, Index and usually from the outer (radial) side of the 3rd Finger. When the thumb is abducted, a triangle can be made out between the Extensor Secundi Internodii and the other muscles of the thumb, the apex of which points towards that finger. In this triangular groove, the "snuff-box", the Radial Artery can be ligatured. It should, however, be noted that in it, the Radial Vein crosses the Artery. The cutaneous branches of the Radial Nerve, innervating the thumb, usually follow the veins more or less closely (cf. Fig. 93); they anastomose with the Cutaneous Branch of the Musculo-Cutaneous and may be partly replaced by it.

The palmar continuation of the Radial Artery is the Superficial Volae Artery which joins the Ulnar Artery, and thus completes the Superficial Palmar Arch. This anastomosis, however, is not constant. In very many cases (cf. Fig. 95) the Superficialis Volae does not complete the arch which is chiefly, if not exclusively, formed by the Ulnar Artery.

The arrangement of the important structures on the dorsum of the hand is similar to that in the foot. Veins and Lymphatics are the most superficial; then come the Cutaneous Nerves; these lie on the deep fascia which is strengthened by accessory fibres ("ligaments"). Under the fascia run the Tendons in their Synovial Sheaths, still deeper are the Arteries and their Venae Comites, and directly under them the bones and joints. At the Metatarsus and Metacarpus a special Dorsal Interosseous Fascia is developed which covers the Interossei and the Small Arteries. This fascia is perforated by a large branch going to the plantar and palmar surfaces, thus completing the Plantar and Deep Palmar Arches.

There are no definite upper and lower borders of the Posterior Annular Ligament, because it is continuous with the deep fascia of the limb partly attached to the bones of the forearm and because its fibres are not (regularly) evenly distributed (cf. Fig. 94).

Fig. 93. Nerves and Veins on the Dorsum of the Right Hand.

A fresh specimen, in which only the skin has been removed. (The Veins and Nerves on the 3rd finger have been drawn after RÜDIGER'S Atlas of the Nervous System.)

Nerves: The Dorsum of the hand is supplied by Sensory Branches of the Radial and of the Ulnar Nerve. Their areas of distribution are not constant; moreover, there is, nearly always, at least one anastomosis, and thus an exchange of fibres occurs between these 2 nerves; this explains why in injury, paralysis etc., the loss of sensation may be very slight. In most cases they divide the Dorsum of the hand equally between them; the axis of the middle finger being the boundary between the 2 areas.

The dorsal surfaces of the distal phalanges (2nd and 3rd) of the 4 inner fingers (2—5), and of the terminal phalanx of the thumb are innervated by nerves running on the palmar surface, thus the Median supplies the 2nd and 3rd phalanges of 3rd fingers completely, and the outer half of those of the 4th finger.

The dorsal surface of the terminal phalanx of the thumb may, however, be innervated only by the Radial Nerve; there may also be PACCINIAN Corpuscles here, although these bodies are usually found on the palmar surface along the branches of Median and Ulnar Nerve (cf. Fig. 95 middle finger).

There are no Motor Nerves on the Dorsum of the hand, because the Dorsal Interossei are supplied, like the Palmar Interossei, by the Deep Ulnar Nerve.

Veins: The blood flows from the fingers on the dorsum through several (as many as to 4) Superficial Veins which begin at the first phalanges into larger venous channels, the Radial and Posterior Ulnar Veins. The former crosses the Tendons of the Extensor Primi Internodii, Extensor Secundi Internodii, and Extensor Ossis Metacarpi Pollicis (cf. Fig. 92) and then runs upwards on the anterior surface of the limb.

The Veins and Nerves are quite superficial, i. e. they lie between the skin and the Tendons of the Extensors. The Posterior Annular Ligament (cf. figure) is formed by transverse and oblique fibres which strengthen the fascia of the forearm. This fascia becomes very thin in the dorsum of the hand (cf. Fig. 92, text).

Fig. 94. Tendon Sheaths on the Dorsal Aspect of the Right Hand.

Skin, Superficial Fascia, Vessels, except the Radial Artery, and Nerves have been removed. The Posterior Annular Ligament is intact, but supposed to be transparent.

The tendon or synovial sheaths of the Extensor Tendons lie in special compartments between the Periostium of the bones of the forearm and the wrists on one hand, and the Posterior Annular Ligament on the other hand; they extend upwards as far as this ligament, i. e. as far as transverse fibres are present; below, they extend $1-1\frac{3}{4}$ inch beyond the ligament.

The synovial sheaths may, however, extend higher ($\frac{2}{5}$ ths inch or more above the highest transverse fibres, vide infra).

Starting at the outer (radial) side, and going inwards, we find 6 Compartments and Sheaths for the Tendons of the following muscles:

1. Extensor Ossis Metacarpi Pollicis, and Extensor Primi Internodii; the sheath for the latter muscle is about $\frac{1}{2}$ inch longer than the sheath for the former.
2. Extensor Carpi Radialis Longior, and Extensor Carpi Radialis Brevior.
3. Extensor Secundi Internodii. The latter crosses the Radial Extensors at an acute angle, lying on them, i. e. posterior to them. These three sheaths usually communicate, and are to be considered as forming practically one sheath.
4. Extensor Communis Digitorum and Extensor Indicis. The two tendons for the index finger lie in one sheath which communicates with the common sheath for the 3rd, 4th and 5th fingers. The index sheath is, however, shorter.
5. Extensor Minimi Digniti. The sheath of this muscle, which sometimes has two tendons (cf. figure) is usually longer than the others mentioned above.
6. Extensor Carpi Ulnaris, this sheath is quite short, because the muscle ends at the base of the 5th Metacarpal Bone.

The broad tendinous slips which connect the tendons to the 2nd, 3rd and 4th fingers are remarkable. Morphologically, they probably represent the formation of one broad aponeurosis, analogous to the one on the palmar aspect which is fully developed.

Subcutaneous Bursae are shewn (cf. figure) on the 2nd and 3rd fingers. They are due to continuous pressure (professional bursae).

The Tendon Sheaths accompany the movements of their tendons. The distal ends of those sheaths which belong to tendons inserted into the metacarpal bones, are easily determined. In order to find the distal ends of the others, the fingers should be completely flexed and hardened with injections of Formalin.

The proximal ends were determined, from another specimen, in the dorsi-flexed position with extended fingers (cf. the black and red lines above the posterior annular ligament).

The length of the Tendon Sheaths varies according to the size of the hand. Those of the Extensors of the Carpus are the shortest and of about equal length ($\frac{1}{15}-\frac{4}{15}$ inch). The sheath of the Extensor Communis Digitorum which often contains several compartments, varies most ($3\frac{1}{5}-3\frac{3}{5}$ inches). It is sometimes longer in small hands than in large ones. The weakest tendons have the largest sheaths, Extensor Secundi Internodii, Extensor Primi Internodii, and Extensor Minimi Digniti; their respective lengths are: $2\frac{1}{5}-2\frac{3}{5}$; $2\frac{2}{5}-2\frac{4}{5}$; $2\frac{3}{5}-3\frac{1}{5}$ inches.

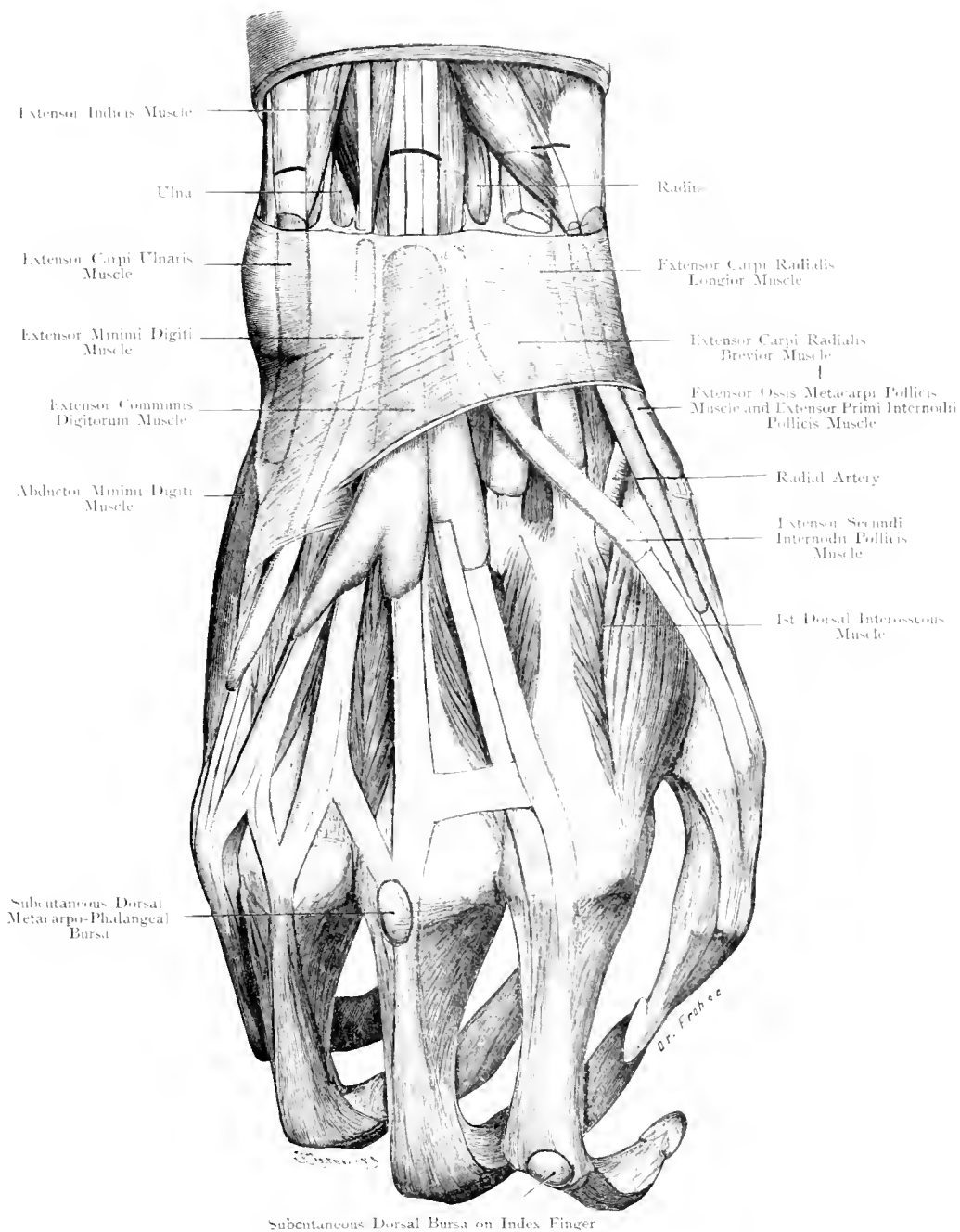


Fig. 94. Tendon-Sheaths on Dorsal Aspect of Right Hand.

Nat. Size.

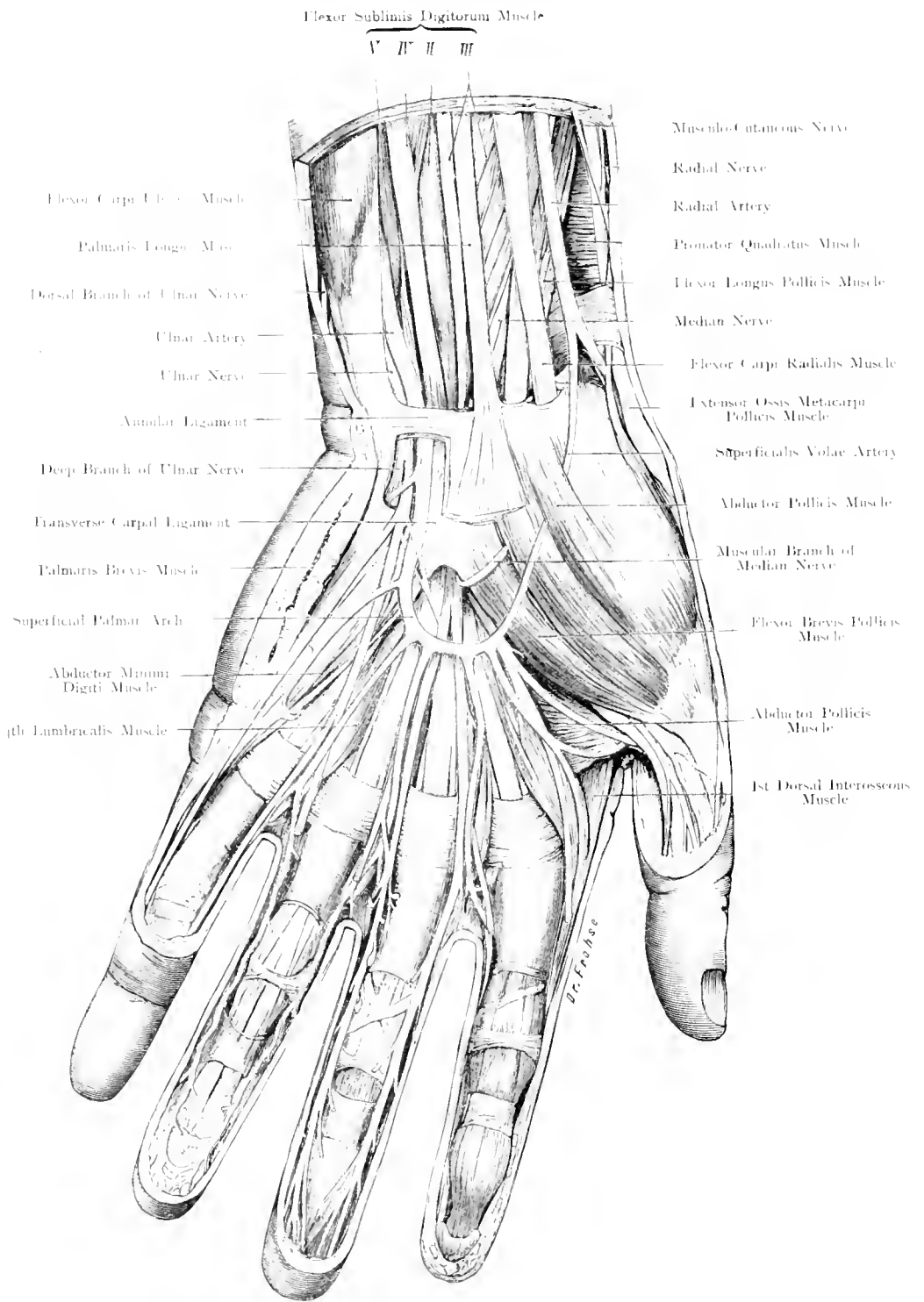


Fig. 95. Palm of Hand (left): Superficial Layer.

Nat. Size.

Fig. 95. Palm of Hand (Left); Superficial Layer.

The Palmar Fascia has been removed almost completely, the Annular Ligament partly, and all the veins have been cut away.

Arteries. At the wrist the Ulnar Artery lies between the Annular Ligament and the Transverse Carpal Ligament; it may, at this point — in contiguity with the Pisiform Bone — give off the branch which joins the deep palmar arch, passing to the deeper layers in association with the deep branch of the Ulnar Nerve (Fig. 96).

In the palm of the hand, covered only by the palmar fascia, lies the Superficial Palmar Arch. This arch is formed by the continuation of the trunk of the Ulnar Artery, and is often completed by an anastomosing branch from the Radial Artery. (Cf. text, Fig. 92.)

Nerves. In the lower part of the forearm the Median Nerve lies on the outer aspect of the Palmaris Longus Muscle, or in the case of absence of this muscle on the outer side of the Flexor Sublimis Digitorum Muscle. In the palm of the hand the nerve is more superficial than the tendons. (Cf. Figs. 103, 104.) The Median Nerve supplies the palmar (flexor) aspect of the three outer fingers and the outer border of the fourth finger whereas the Ulnar Nerve supplies the palmar aspect of the fifth finger and the inner border of the fourth finger.

The Median Nerve supplies

- a) all the short muscles of the thumb except the Adductor Transversus Muscle and the Adductor Obliquus Muscle;
- b) the two Outer Lumbricalis Muscles, and a part of the third (which also derives a supply from the Ulnar Nerve — BARDELEBEN and FROHSE).

The Ulnar Nerve supplies

- a) a part of the third Lumbricalis Muscle as well as the fourth;
- b) all the muscles of the little finger;
- c) all the interosseous muscles;
- d) the Adductor Transversus Muscle and the Adductor Obliquus Muscle of the Thumb.

When the hand is slightly dorsiflexed (cf. text, Fig. 89) the Ulnar Artery and a part of the Ulnar Nerve are shown above the Annular Ligament. The Tendons of the Flexor Sublimis Digitorum Muscle are arranged in two layers — those to the 3rd and 4th fingers are situated more superficial (cf. Fig. 91), those to the 2nd and 5th fingers at a deeper plane. The Median Nerve is contiguous to the tendon of the 3rd finger.

The sheath of the Flexor Carpi Radialis Tendon is laid open at its proximal end; the Extensor Ossis Metacarpi Pollicis sends a slip to the Abductor Pollicis Muscle. The Thenar Eminence is chiefly composed of muscles whereas upon the Hypothenar Eminence is a thick layer of fat containing a cutaneous muscle — the Palmaris Brevis Muscle.

The Palmar Fascia is of great practical importance, — it is very tense and strong, bridging over the space between the Thenar and Hypothenar Eminences; its intimate connection with the skin explains why the latter cannot be picked up and why cellulitis of the hand is dangerous. This dense fascia prevents the infective process from spreading towards the surface while the delicate tendon-sheaths and the loose tissue which surrounds them affords a favourable means of extension. Injury is well known to produce very free haemorrhage due to the abundant anastomosis in this region.

The nerve supply is most complete, numerous Pacinian Corpuscles are observed (cf. Fig. 93).

Fig. 96. Palm of Hand (Left); Deep Layer.

In addition to those structures removed in Fig. 95, the distal portions of the Flexor Sublimis Digitorum and the Flexor Profundus Digitorum (except in connection with the little finger) muscles, the Palmaris Longus Muscle, the Superficial Palmar Arch and the deep fascia of the hand have been cut away. A piece of the Abductor Pollicis Muscle has been excised, and the Pronator Quadratus Muscle exposed.

The Deep Palmar Arch formed by the junction of the deep branch of the Ulnar Artery with the deep division of the Radial Artery lies at a deeper plane than the flexor tendons and the deep fascia, practically, in the middle between the superficial arch and the distal border of the carpal bones, on the bases of the metacarpal bones nearer the dorsal than the palmar aspect of the hand (cf. Figs. 97—104).

The deep division of the Ulnar Nerve accompanies the deep arch as far as the Adductor Transversus Pollicis Muscle and the 1st Dorsal Inter-osseous Muscle, passing on to supply all the Interosseous muscles, having given off, in its course, the fibres to the Hypothenar Group of Muscles and the two inner Lumbricalis muscles.

The tendons and their sheaths run in an Osseo-Aponeurotic Canal (cf. Figs. 98—101). Most important is the relation which the flexor tendons bear to the phalanges. When these tendons are divided near the base of the terminal phalanx no suture is required, as it is quite sufficient to fix the finger in the position of flexion; but if the division should occur at the intermediate phalanx, suture of the cut ends of the tendon is necessary.

The Flexor Profundus perforates the Flexor Sublimis tendon at the first interphalangeal articulation; accordingly at this point there are three tendinous strands. At the base of the first Phalanx (proximal phalanx) there are only two tendons to be sewn together. The flexor tendons are enclosed within a fascial canal and often retract considerably towards the muscular portion when divided. The distal end retracts to a marked extent when the injury occurs in extreme flexion (e. g. when a bottle breaks in the hand).

Under such conditions it may be necessary to open up the tendon-sheath which is relatively thin at the joints (where it is reinforced by a few delicate transverse and oblique fibres) but dense opposite the shaft of the first and second phalanges.

In addition to the sensory communication shown in Fig. 95 as a loop around the Ulnar Artery and the motor communication in the 3rd Lumbrical Muscle, others occur. One inconstant communication occurs between the dorsal branch of the Ulnar Nerve and the branch to the inner aspect of the little finger. Another of greater constancy passes through the Adductor Transversus Pollicis Muscle where becoming more superficial it winds round the Flexor Longus Pollicis Muscle and joins the Muscular branch of the Median Nerve.

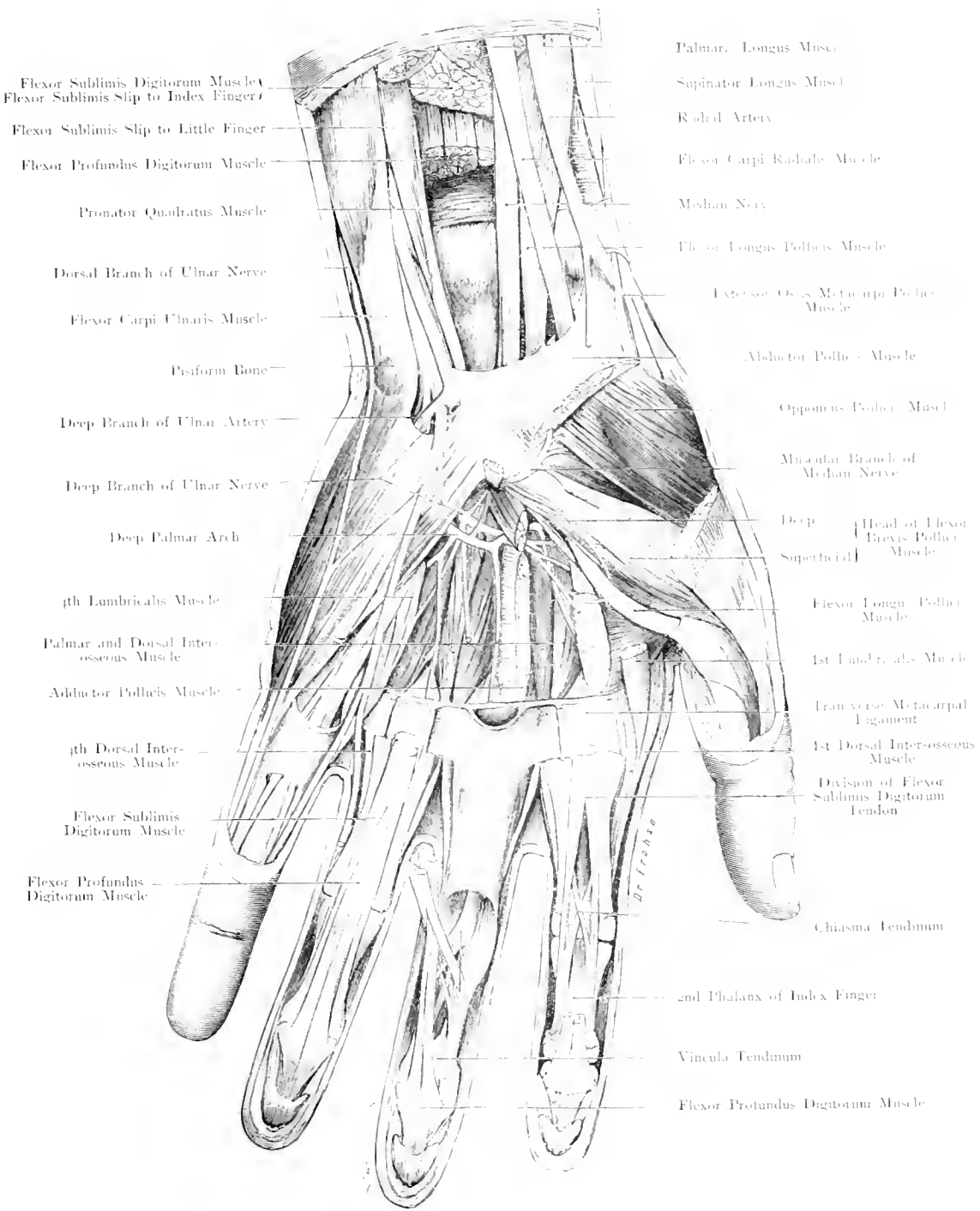


Fig. 96. Palm of Hand (Left): Deep Layer.

Nat. Size.

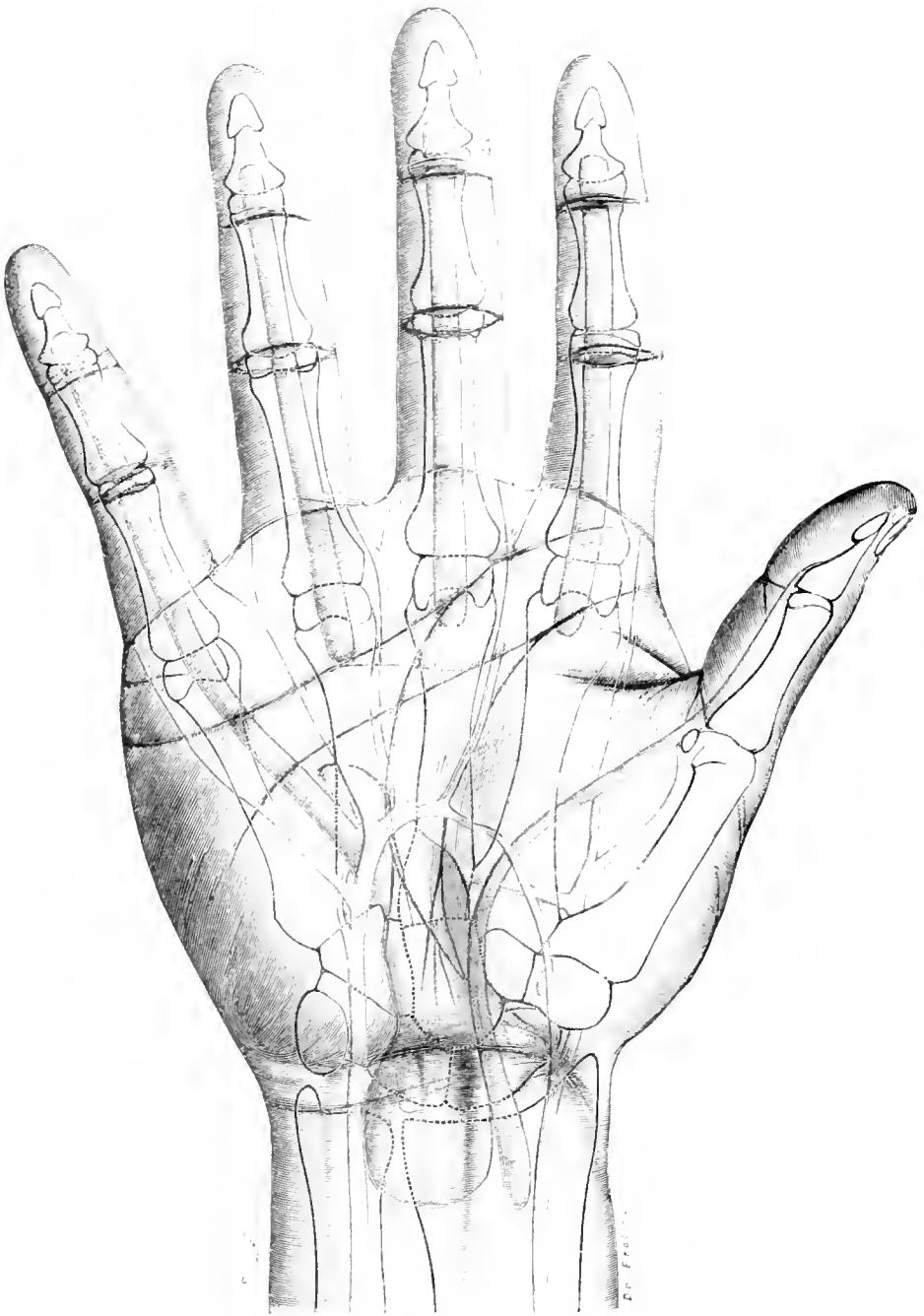


Fig. 97. Palm of Hand (Right): Tendon-Sheaths and Large Arteries.

$\frac{1}{2}$, Nat. Size.

Fig. 97. Palm of Hand (Right); Tendon-sheaths and large Arteries.

This diagram illustrates the Flexor Tendon-sheaths, the large Palmar arteries, the more definite furrows of the skin of the palm, in addition to the outlines of the bones of the hand, as shewn in a skiagram.

The more definite furrows of the Palm of the hand present the appearance of *M* or *W* according to whether they are viewed from the inner or outer aspect of the limb.

The initial upstroke of the *M* curves around the balls of the 3rd, 4th and 5th fingers; the second upstroke (or third line) runs almost transversely across from the ulnar to the radial side of the hand.

The second line, or initial downstroke joins the two upstrokes (1st and 3rd lines) of the *M*, and is variable in its continuity. The last stroke of the *M* skirts the Thenar Eminence.

The third line is the most important guide for the superficial Palmar arch, whereas the first and third lines combined approximately mark the proximal limitation of the tendon-sheaths of the 2nd, 3rd and 4th fingers.

A further description of these tendon-sheaths is found in the text (Figs. 98—101).

The Tendon-sheaths become of great importance in inflammatory conditions. A whitlow originating at the proximal phalanx may invade the tendon-sheath at the base of this phalanx and extend to the palm, thus endangering the whole hand.

At the Osseo-aponeurotic canal completed by the anterior Annular Ligament there is formed a constriction of the tendon-sheaths so that in such pathological conditions as Tuberculosis of the Tendon-sheath and Tenosynovitis the swelling presents a constriction at the Annular Ligament with an enlargement both above and below this structure.

The fold between the hand and the forearm corresponds roughly to the wrist-joint which extends higher into the forearm with its convexity upwards.

The groove between the first (proximal) and second (intermediate) phalanges corresponds to the joint, but the joint between second and third (distal) phalanges is situated $\frac{1}{10}$ to $\frac{1}{6}$ inch distal to the groove.

Figs. 98—101. Palm of Hand (Left); Tendon-sheaths.

After JOESSEL and VON ROSTHORN.

(Cf. Fig. 97.)

The tendon-sheaths of the Flexor Muscles (Flexor Sublimis Digitorum and Flexor Profundus Digitorum; Flexor Longus Pollicis) extend from a distance of a little less than an inch above the Annular ligament far into the palm of the hand.

There are generally two tendon-sheaths — one for the Flexor Sublimis and Flexor Profundus Digitorum Muscles, another for the Flexor Longus Pollicis Muscle — which are frequently in communication.

The sheath of the Flexor Carpi Radialis Muscle extending from the trapezium to the 2nd Metacarpal bone is of but little practical importance. The large flexor tendon-sheath shews after inflation a bulging above the constriction caused by the annular ligament. On the inner side of the hand the sheath extends lower down, and invariably communicates with the sheath for the tendons of the little finger.

In a similar manner the Sheath of the Flexor Longus Pollicis extends as far as the Distal phalanx.

This is a very important point of practical application because suppuration of the sheath of the thumb or of the little finger always extends into the main sheaths; this does not occur in the case of the 2nd, 3rd or 4th digits.

Moreover, we have herein an explanation of the extension of Suppuration from the thumb to the little finger and vice versa — the inflammatory process passing from the thumb to the main flexor sheath and into the sheath of the little finger owing to the free communication.

The Median Nerve is situated between the main Sheaths and the Annular Ligament whereas the Ulnar Nerve lies superficial to the ligament so that it only comes in close relation with the main sheaths above and below this structure.

The Ulnar Artery, not shewn in the figure, lies nearer the Sheaths than the Ulnar Nerve.

The Tendons of the Flexor Sublimis and Flexor Profundus muscles lie in common sheaths as they extend down upon the fingers from the metacarpophalangeal joints as far as the bases of the terminal phalanges, i. e. the insertion of the Profundus tendons.

Injury, therefore, to the terminal phalanges distal to these points would not involve the sheaths.

Figs. 99 and 100 depict variations which are described by some authors as normal — a third sheath being inserted as a wedge, between the two main sheaths at their proximal end —. When this third sheath becomes markedly developed (Fig. 100) the tendon of the Flexor Profundus passing to the Index finger is transmitted through it.

The somewhat complicated arrangement of the tendons of the long flexor muscles is schematically represented in Fig. 101.

The "Mesotendina" analogous to the Mesenteric folds, are shewn in the cross-section.

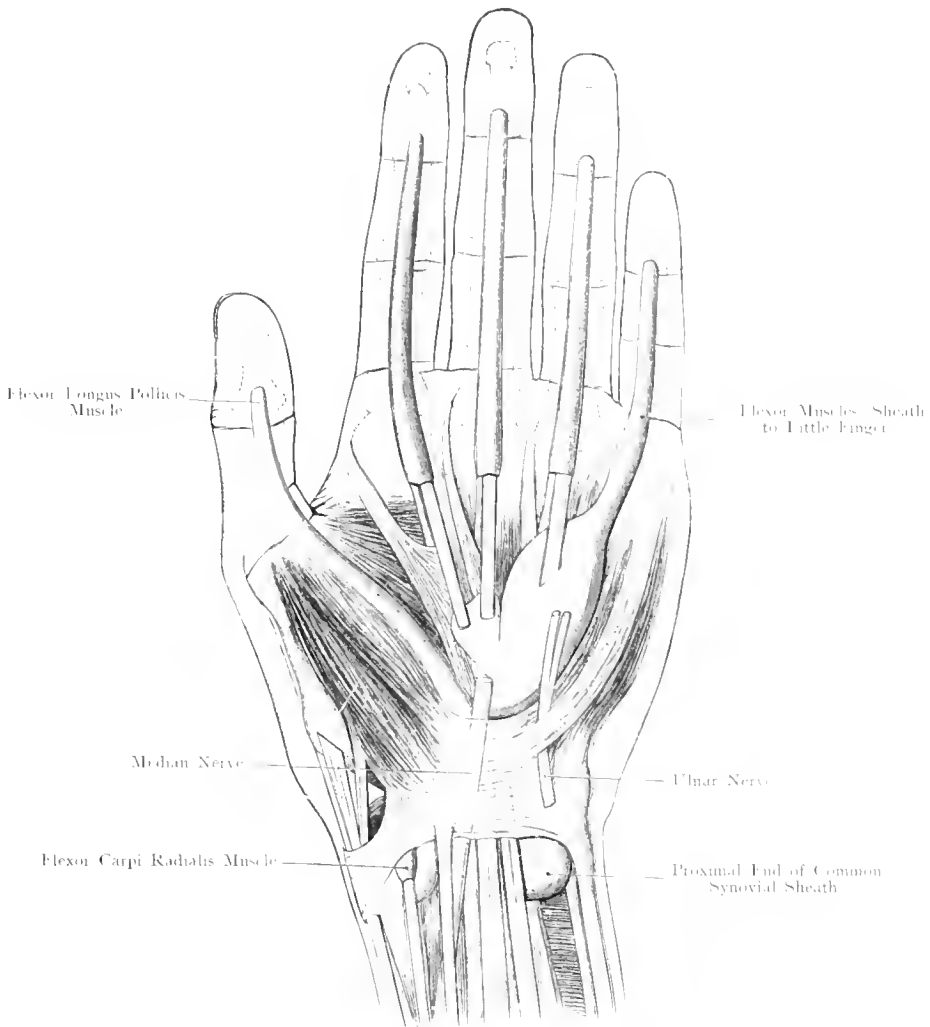


Fig. 98.




Fig. 99.

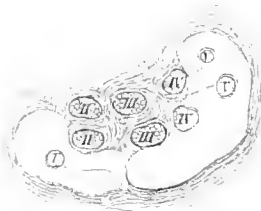

Fig. 101.

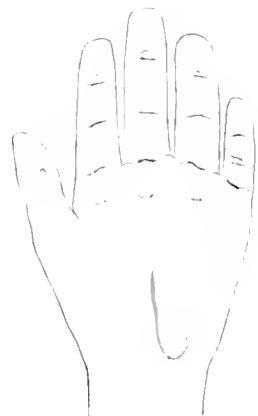

Fig. 100.

Fig. 98—101. Palm of Hand (Left); Tendon-Sheaths.

Fig. 98 and 101 $\frac{1}{2}$ Nat. Size, Fig. 99 and 100 $\frac{1}{4}$ Nat. Size.

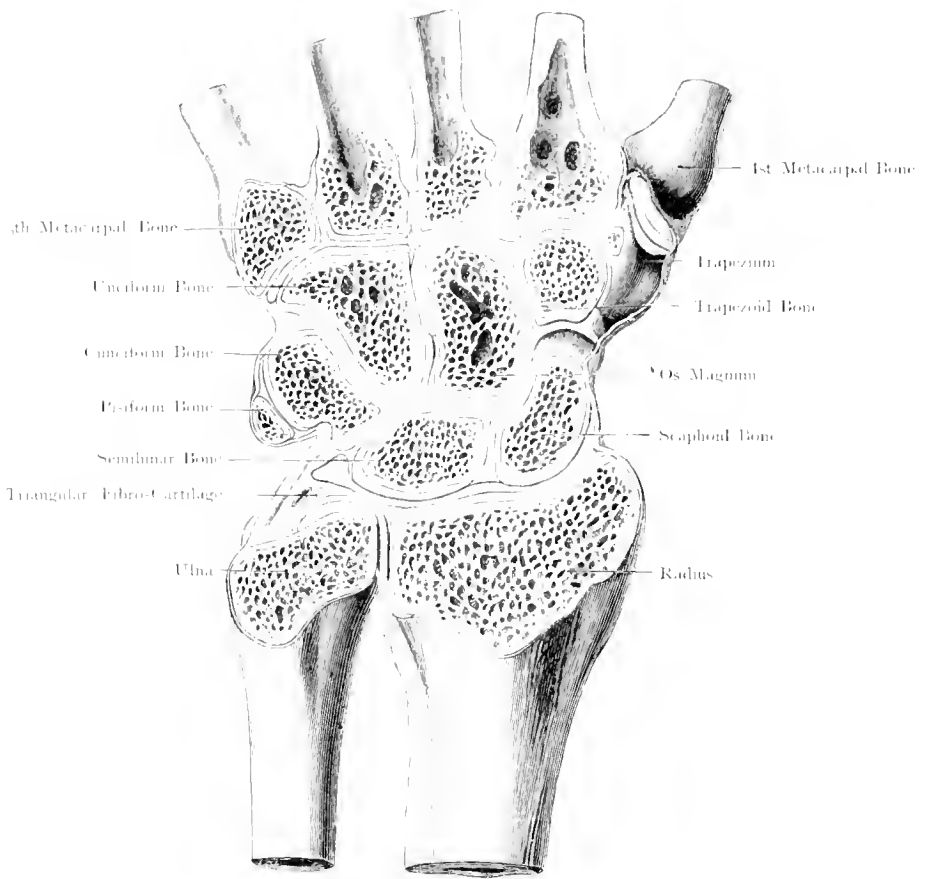


Fig. 102. Horizontal Section through the Dorsum of the Right Hand.
 Articulations. — Nat. Size.

Fig. 102. Horizontal Section through the Dorsum of the Right Hand; Articulations.

A horizontal section has exposed to view from the dorsal aspect all the articulations which lie between the forearm above and the Metacarpal bones below, but those joints which do not lie in the plane of the section have been opened independently, viz: a) Cuneiform — Pisiform. b) Trapezium — 1st Metacarpal.

The following Joint Cavities or combination of Joint Cavities are found in the hand:—

- 1) Joint between Radius, Scaphoid & Semilunar extending almost to the Cuneiform but separated from the following joint by the Triangular Articular Fibro-Cartilage, "the Radio-Carpal Articulation", the Wrist Joint Proper.
- 2) Joint between Head of Ulna, Radius and Inter-articular Fibro-Cartilage, "the Inferior Radio-Ulnar Articulation".
- 3) Joint between the Cuneiform and Pisiform Bones.
- 4) Joint between the Trapezium and the 1st Metacarpal Bone.
- 5) Joint between the Unciform Bone and the bases of the 4th and 5th Metacarpal Bones; this may communicate with the following (6).
- 6) Combination of the joint cavities between the distal surfaces of the Scaphoid, Semilunar and Cuneiform Bones, the proximal surface of the Unciform Bone, all the articular surfaces of the Os Magnum and the Trapezoid, the inner surface of the Trapezium and the bases of the 2nd and 3rd Metacarpal Bones. "Intercarpal and Carpo-Metacarpal Articulation".

The wide extension of No. 6 forms an important point in the spreading of pathological processes.

The Dorsal and Palmar ligaments of the Carpal Joints are very strong so that extreme Dorsiflexion (e. g. as in a fall on the hand) is more likely to result in a fracture of the lower end of the radius than in a rupture of these ligaments. (LECOMTE; cf. the behaviour of the malleoli, in particular the external or fibular.)

Fig. 103. Transverse Section through Carpus.

Frozen section viewed from the Fingers. The second row of Carpal Bones and the Styloid Process of the 3rd Metacarpal Bone have been sawn through.

On the back of the hand the Extensor Tendons, on the outer side the Extensor Ossis Metacarpi and the Extensor Primi Internodii Pollicis, in the palm of the hand the Flexor Tendons are shewn in their relations to each other and to the Bones of the Hand.

The Concavity of the Carpus with the tunnel completed by the Anterior Annular Ligament are well shewn.

Note: Radial Artery; Ulnar Artery, and Nerve. The Median Nerve becoming more superficial at the wrist, lies in close approximation to the Flexor Sheath, and directly under the Palmar Fascia.

(Vide Figs. 98 and 101.)

Fig. 104. Transverse Section through Palm of Hand.

Frozen Section. Left Hand, seen from the fingers.

The Flexor and Extensor Tendons have diverged towards either the inner (ulnar) or outer (radial) side. The median nerve has divided into many branches. The fleshy muscles of the Thenar and Hypothenar Eminences are evident. The Radial and Ulnar Arteries have divided so that the smaller branches of the Radial, with the exception of the Princeps Pollicis artery, are scarcely visible; the branches of the Ulnar Artery are readily found accompanying the nerves on the Palmar aspect near the 4th Metacarpal Bone.

The Palmar Fascia which bridges over the space between the Thenar and Hypothenar Eminences is of great practical importance, because the skin is bound firmly to it so that suppuration deep to the fascia, i. e. around the Tendons or their sheath, becomes pent up, and deep incisions become necessary for the evacuation of the pus.

The concavity of the hand is well shewn. (Cf. Foot.)

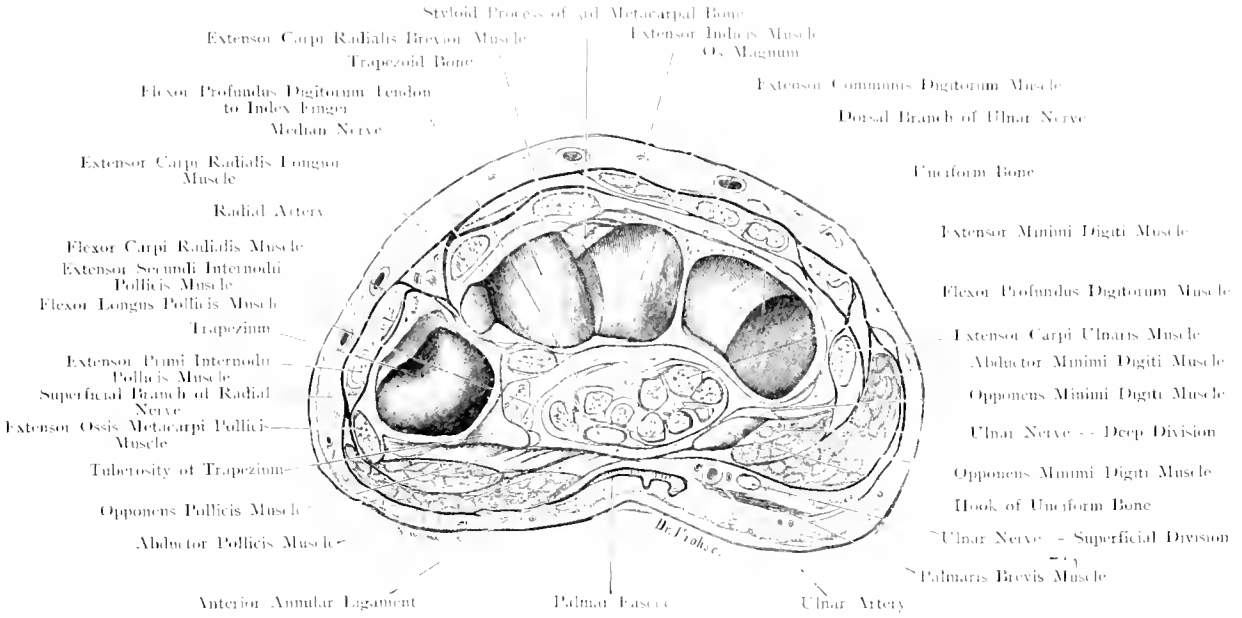


Fig. 103. Transverse Section through Carpus (Left): Distal Aspect.

Nat. Size.

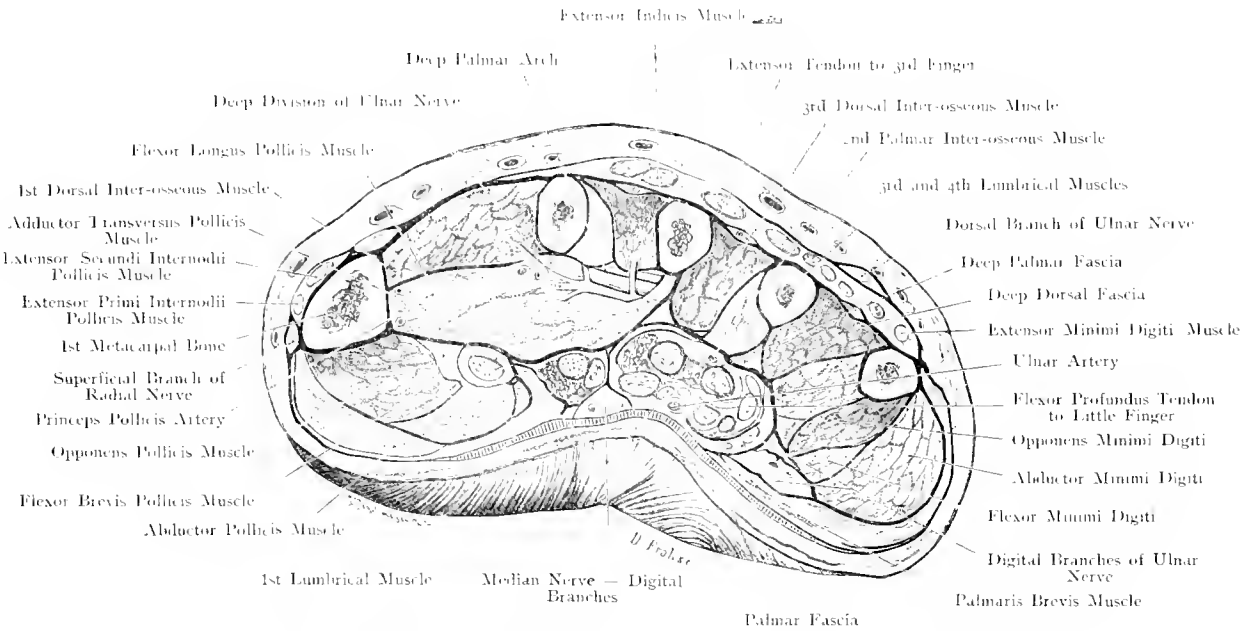


Fig. 104. Transverse Section through Palm of Hand (Left): Distal Aspect.

Nat. Size.

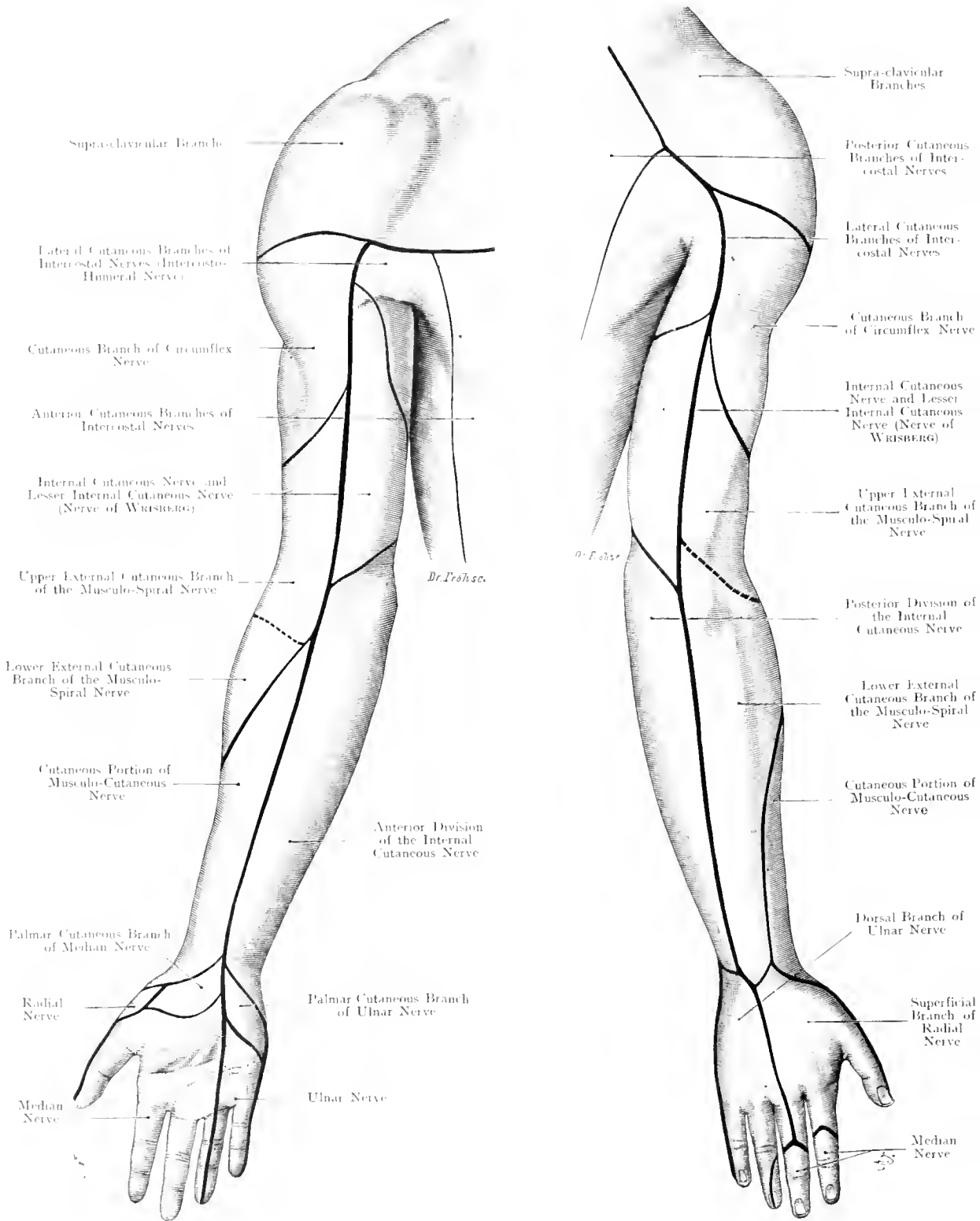


Fig. 105 and 106. Areae of Distribution of Cutaneous Nerves of the Upper Extremity (Right).

**Fig. 105 and 106. Areae of distribution of Cutaneous Nerves
of Upper Extremity, (right).**

*Outlines of Figs. after FAY's Atlas. Colours correspond to those employed for
the spinal segments in the subsequent figures.*

Unfortunately the areae of distribution of the nerves of the limb and their variations have not been completely worked out, as in the case of the Head and the Trunk by FROISE and ZANDER. For practical purposes the diagrams will probably suffice.

The upper part of the shoulder (green) is supplied from the Cervical Nerves. The front of the chest is supplied by the Anterior Branches of the Intercostal Nerves (yellow), the back by the Posterior Branches. The Lateral Branches supply the Axilla and even the upper part of the inner aspect of the arm.

When the arm is supinated the anterior boundary between adjacent areae of distribution extends down the middle of the anterior aspect of the arm to the tip of the 4th finger. But the posterior boundary line runs down the middle of the arm to the 3rd finger.

The following points should be observed:—

The upper part of the shoulder is supplied by the Supra-Clavicular and Supra-Acromial Branches of the Cervical Plexus.

The lower part of the shoulder by the Circumflex.

Below this level the Musculo-Spiral supplies the skin on the outer aspect of the arm corresponding to the area supplied by the Internal Cutaneous (red) and Lesser Internal Cutaneous Nerves on the inner aspect. (A further internal branch from the Musculo-Spiral Nerve GEGENBAUR — may assist in completing the supply of this region.)

On the inner part of the anterior (flexor) surface of the forearm is to be found the Internal Cutaneous Nerve, the dorsal branch of which supplies the inner aspect of the posterior (extensor) surface; on the outer aspect of the back of the forearm the chief nerve is the Radial, only a very small area being supplied by the Musculo-cutaneous Nerve.

In the palm of the hand the cutaneous distribution of the Median (violet) and Ulnar (brown) is divided by a line which runs along the axis of the 4th finger. Special branches from the Median and Ulnar Nerves supply small areae in the upper part of the Palm. On the outer side a small area of the Thenar eminence is supplied by the Radial Nerve.

The Dorsum of the hand is supplied equally by Radial and Ulnar Nerves, but where these become wanting in the case of the 2nd, 3rd and 4th fingers, their deficiency is made up by the Median Nerve. (Cf. Fig. 106.)

Figs. 107 and 108. Cutaneous Nerves, according to their Segmental (Spinal) Origin.

The nerves distributed to the upper extremity are derived from the segments 4th Cervical and 2nd Dorsal inclusive. The distribution is such that the upper segments pass to the outer side and the lower the origin of the nerves, the more internal is their distribution. The thick black lines situated on the Anterior and Posterior aspects of the arm indicate the boundary between the rostral and caudal parts of the limb, the correct continuation of this line on to the forearm and hand is not yet defined.

WICHMANN is of opinion that it should continue between the dark-blue and violet areas to the distal end of the 1st Metacarpal bone on both the anterior and posterior aspects.

The segmentary distribution over the attachment of the limb to the trunk differs in front and behind. The posterior divisions of the Cervical Nerves ramify over the posterior aspect: VIII. C and 1. D have, as a rule, no posterior division, so that 2. D follows VII. C; again, 1. D has not usually even an anterior division, so that the 2nd intercostal nerve follows directly upon the Supraclavicular branches distributed to the chest.

The boundaries between the intercostal nerves are diagrammatic in the figure inasmuch as only the middle $\frac{1}{3}$ of a colour accurately represents the nerve indicated, the upper and lower thirds being the upper and lower association areas of the nerves.

In the limb the limitations are much less definite than indicated; moreover there are many variations particularly on the inner side where the red area may be far more extensive and with the brown may pass even as far as the 4th finger.

The following segments correspond to the different nerves.

IV. C:— the supra-clavicular nerves.

V. C (VI. C):— the cutaneous branches of the circumflex.

(V. C) VI. C, VII. C (VIII. C):— the cutaneous branches of the Musculo-Spiral.

VI. C:— the cutaneous branches of the Musculo-Cutaneous.

On the inner aspect of the limb the Dorsal Nerves enter at the upper part, the Cervical Nerves at the lower. The Intercosto-humeral belongs to the Cervical Plexus if one takes the 2nd Dorsal segment as belonging to this Plexus.

The Internal cutaneous is chiefly derived from 1. D and VIII. C. The violet band (VII. C) gives the boundary between VI. C and VIII. C as these nerves ramify over this area.

The area of the Median and Ulnar Nerves in the hand are not accurately defined. The dorsal branch of the Ulnar Nerve chiefly contains VII. C, the palmar branch VII. C (only represented in the figure) and 1. D.

The Palmar branches of the Median Nerve correspond to VI. C and VII. C, the digital branches to VI. C, VII. C, VIII. C (the nearer to the inner side, the lower is the origin of the fibres in the cord). The outer side of the 4th finger may even be partially supplied by 1. D.

Figs. 109 and 110. Nerve-Supply of the Muscles of the Upper Extremity, according to their Segmental (Spinal) Origin.

The segments are given partly according to WICHMANN and BOLK, partly after ZIEHEN. In the text, Arabic figures represent the Cervical Segments, the first Dorsal is indicated by a Roman I. Colours as in Figs. 107 and 108.

The ventral muscles of the superficial layer of the shoulder-girdle are the Sterno-Mastoid and Pectoralis Major; those of the deep layer the Subclavius and Pectoralis Minor.

That portion of the Spinal Accessory Nerve which supplies the Sterno-Mastoid Muscle contains 2. C. and 3. C. The Anterior Thoracic Nerves divide into several branches; the upper segments are for the Pectoralis Major 5. C., 6. C., 7. C. (Clavicular portion 5. C.), the lower segments are for the Pectoralis Minor 7. C., 8. C.; 8. C. in some cases also supplies the lowest fibres of the Pectoralis Major.

The Nerve to the Subclavius Muscle is composed of fibres derived from 5. C. and 6. C.

The superficial layer of the Extensor Muscles of the Shoulder-Girdle is composed of the Trapezius and Latissimus Dorsi; in the majority of cases the Spinal Accessory Nerve to the Trapezius Muscle contains 2., 3. and 4. C., the long Subscapular Nerve to the Latissimus Dorsi Muscle 6., 7. and 8. C. The other Subscapular Nerves to the Teres Major Muscle 5., 6. (and 7.) C.; to the Subscapularis Muscle 5. and 6. C., the Suprascapular Nerve to the Supraspinatus Muscle 5. C., to the Infraspinatus Muscle 5. and 6. C.

The deep layer is composed of the Serratus Magnus with BELL'S Nerve 5., 6. and 7. C.; Levator Scapulae (3.) 4. and 5. C. and the Rhomboideus Muscles 5. C., possibly further fibres from 4. C. to the Rhomboideus Minor Muscle.

Of the mixed nerves, the Median contains fibres derived from each segment, 5., 6., 7., 8. C. and I. D. — (though 5. C. probably contains Sensory fibres only). — The motor part of the Musculo-Cutaneous Nerve contains fibres from 5., 6. and 7. C.; the Ulnar Nerve usually 7. and 8. C. and I. D. or 8. C. and I. D. only. The motor part of the Circumflex 5. and 6. C. The motor part of the Musculo-Spiral (5. C.) 6., 7. and 8. C.

Musculo-Cutaneous Nerve: Coraco-Brachialis Muscle 6. and 7. C.; Biceps Muscle 5. and 6. C.; Brachialis Anticus Muscle 5. and 6. C. This last named muscle has a double Nerve-supply as it also receives fibres from the Musculo-Spiral Nerve (derived from the same segments).

Median Nerve: Pronator Radii Teres Muscle 6. and 7. C.; Flexor Carpi Radialis 6. and 7. (and 8.) C.; Palmaris Longus 7. and 8. C. and I. D.; Flexor Sublimis Digitorum 7. and 8. C. and I. D.; Flexor Longus Pollicis 6., 7. (and 8.) C.; Pronator Quadratus (6.) 7. and 8. C. and I. D.; Muscles of the Thenar Eminence 6. and 7. C. The two outer Lumbrical Muscles are usually considered to be supplied from 8. C. and I. D. segments.

Ulnar Nerve: Flexor Carpi Ulnaris Muscle (7.) 8. C. and I. D.; the outer (radial) portion may also be supplied by the Median Nerve (FROHSE) thus having a double Nerve-supply, like the following muscle; Flexor Profundus Digitorum (Ulnar and Median) 7., 8. C. and I. D. The deep portion of the Ulnar contains 8. C. and I. D., but chiefly 8. C.; at the Hypothenar Eminence even the 7. C. may take part (BOLK).

For the Motor Anastomosis between the Ulnar and Median Nerves cf. Figs. 84 and 90.

The Circumflex Nerve contains fibres from the 5th and 6th Cervical Segments. The small area of Deltoid Muscle coloured green denotes the probability, as evidenced by clinical observations, that fibres from 4. C. supply this portion (ZIEHEN). The Anterior part of the Deltoid may be supplied by the Anterior Thoracic Nerves (Anastomosis with the Circumflex, FROHSE). The nerve to the Teres Minor Muscle usually only contains 5. C.

Musculo-Spiral Nerve:	}	for Long Head of Triceps	6., 7. and 8. C.
		for Outer Head of Triceps	6., 7. (and 8.) C.
		for Inner Head of Triceps	(6.), 7. and 8. C.
		for Anconeus	7. and 8. C.

Brachio-Radialis (Supinator Longus) 5. and 6. C. Extensor Carpi Radialis Longior and Brevior (5.) 6. and 7. C. Supinator Brevis 5., 6. (and 7.) C. Extensor Communis Digitorum and Extensor Minimi Digiti 6., 7. and 8. C.

Extensor Primi Internodii Pollicis 6., 7. (and 8.) C. Extensor Indicis 6., 7. and 8. C. Extensor Secundi Internodii Pollicis 6., 7. (and 8.) C. (in BOLK'S case 7. C. only)

Fig. III. Thorax and Abdomen.

The Trunk is divided into two chief divisions; the upper is the Thorax (Chest) and the lower is the Abdomen (Belly).

The superficial line of separation between these two regions follows the lower margin of the bones and cartilages which comprise the thoracic cage, but this surface marking by no means indicates the relative size of these cavities.

This curved line only shews the attachment of the base of the diaphragm which is in constant movement so that the capacity of these cavities is ever varying and the position of the more movable viscera alter accordingly.

Certain points and connecting lines are employed in order to subdivide these regions and thereby endeavours are made to traverse or map out certain important viscera or visceral domains.

The most important lines and regions are marked in the figure: to the black lines have been added red lines in order that the most important Continental and English guides may be pictured.

The reader is however strongly recommended to appreciate the multiplicity of visceral surface markings by reference to the following authorities:

Atlas of Human Anatomy, TOLDT.

Textbook of Anatomy, CUNNINGHAM.

QUAIN's Anatomy.

Surgical Anatomy, DEEVER.

Fig. 112. Frontal Section through the Trunk.

Frozen Section. The anterior surface of the second section of a series of Vertical Frontal Sections seen from in front. The Thoracic and Abdominal Viscera are in their position at extreme expiration which is never reached during life. Atmospheric pressure has driven the intercostal spaces inwards so that the outlines of Pleura and Lung are undulating.

A frontal section shews much better than a transverse section the different cavities derived from the general (Coelomic) Cavity of the Embryo.

The formation of the Diaphragm results in a division into Thoracic and Abdominal Cavities. There is really no Thoracic Cavity but a Thoracic Bony Cage. As the pericardium is pushed downwards from the neck into the Coelom, 3 completely independent cavities are established:

- 1) Pericardial Cavity, containing the Heart and a part of the large vessels.
- 2) Left Pleural Cavity with the Lung.
- 3) Right Pleural Cavity with the Lung.

It is the practice of many anatomists to call the space between the Left and Right Pleural Cavities the Mediastinum, — according to this the Heart would be in the Mediastinum (Middle). But if three independent cavities are recognized there remain two spaces communicating above, one in front of and one behind the heart — the Anterior Mediastinum and the Posterior Mediastinum —.

The Anterior Mediastinum is further divided by the overlapping right and left pleurae (cf. Fig. 116) between the 2nd and 4th ribs into an upper and lower compartment with free communication. Above the Mediastina communicate freely with the spaces between the structures of the neck.

The complementary spaces shewn in the figure between the Thoracic Wall and the Diaphragm are only occupied by the Lung during inspiration.

The Pericardium is a closed sac consisting of a visceral layer closely enveloping the heart and the roots of the large vessels and a parietal layer directly continuous with the former but blending with the Mediastinal Pleura, the Diaphragm and the Anterior Thoracic Wall.

The Pleural Sacs are two closed cavities, consisting of a visceral layer which at the root of the lung blends with the parietal layer. This parietal layer lines the thoracic wall — (Costal pleura) — the pericardium — (Pericardial pleura) — the diaphragm — (Diaphragmatic pleura) — and the mediastinum — (Mediastinal pleura) —.

The uppermost part of the pleura which reaches from $\frac{1}{2}$ to $\frac{4}{5}$ ths inch above the first rib is the Apical Pleura (this is not shewn in the figure because it lies behind the plane of section). (Vide Figs. 70, 121, 126.)

Fig. 113. Upper Aperture of Thorax.

The upper part of the Sternum, the 1st and 2nd Costal Cartilages and the muscles attached to these have been removed. The Clavicles and Ribs have been pushed down to their full extent. The Pericardium is exposed. The Thymus and Thyroid Glands have been cut away, together with the Bronchial Lymphatic Glands. The Inferior Thyroid Vessels are divided and the cervical fascia dissected away.

The following structures pass upwards or downwards through the superior aperture of the Thorax.

Vessels. The right Common Carotid Artery rising from the Innominate Artery. The Left Common Carotid a direct branch of the Arch of the Aorta.

The Subclavian Arteries at first pass upwards into the neck and then to the Axilla.

To the right of the Arch of the Aorta lies the Superior Vena Cava formed by the junction of the Right and Left Innominate Veins, which pass behind the Sterno-Clavicular Articulation and the Manubrium Sterni. The Innominate Veins are formed by the junction of the Internal Jugular and Subclavian Veins. The large veins are situated to the outer side and in front of the main arteries.

The Lymphatic Duct (the chief lymphatic channel) after passing upwards in the posterior mediastinum where it is situated between the Aorta, Large Azygos Vein and Oesophagus directs its course away from the Vertebral Column obliquely upwards and to the left side of the neck; here, under cover of the deep cervical fascia it forms an arch and finally opens into the Left Subclavian Vein (cf. Fig. 67).

Nerves. The Phrenic Nerve derived from the 3rd, 4th and 5th Cervical Nerves (chiefly the 4th) runs obliquely across the Scalenus Anticus Muscle to the outer side of the Internal Jugular Vein, then behind this vessel between the Subclavian Vein and Artery (Figs. 67 and 70).

The Right Phrenic Nerve runs to the outer and anterior aspect of the Vena Cava Superior, between the Pericardium and Mediastinal Pleura, along the right border of the Pericardium to the Diaphragm. (Coronary Ligament of Liver, Liver and Abdominal Wall.)

The Left Phrenic Nerve takes a greater curve in its passage from the Neck into the Thorax owing to the asymmetry of the large vessels and is situated on a deeper plane than the right, owing to the rotation of the heart to the left, in its course between the Pericardium and Pleura to the Diaphragm (cf. course of Phrenics in Fig. 122).

The Vagus or Tenth Cranial Nerve running between the Carotid Artery and Internal Jugular Vein at first passes downwards and slightly backwards but soon inclines forwards to the right and in front of the Right Subclavian Artery, on the left side in front of the Subclavian Artery and Aortic Arch.

Both Vagi accompany the Oesophagus in its lower part and through the Oesophageal Opening into the Abdomen on to the walls of the Stomach. The left Vagus merges gradually to the Anterior Aspect whereas the right Vagus becomes directed to the Posterior Aspect of the Stomach; this results from the developmental rotation of the Viscus to the right.

From each Vagus is given off a Recurrent Laryngeal Nerve (Motor Nerve to Muscles of the Larynx); the right recurrent nerve looping around the Subclavian Artery whereas the left recurrent nerve winds round the Ductus Arteriosus at its connection with the Arch of the Aorta; each nerve ascends upwards by the side of the Trachea (cf. Fig. 69).

Viscera: The Trachea bifurcates opposite the 4th or 5th Dorsal Vertebra into Right and Left Bronchus under cover of the large vessels. The Oesophagus is shewn in the figure to the left of the Trachea.

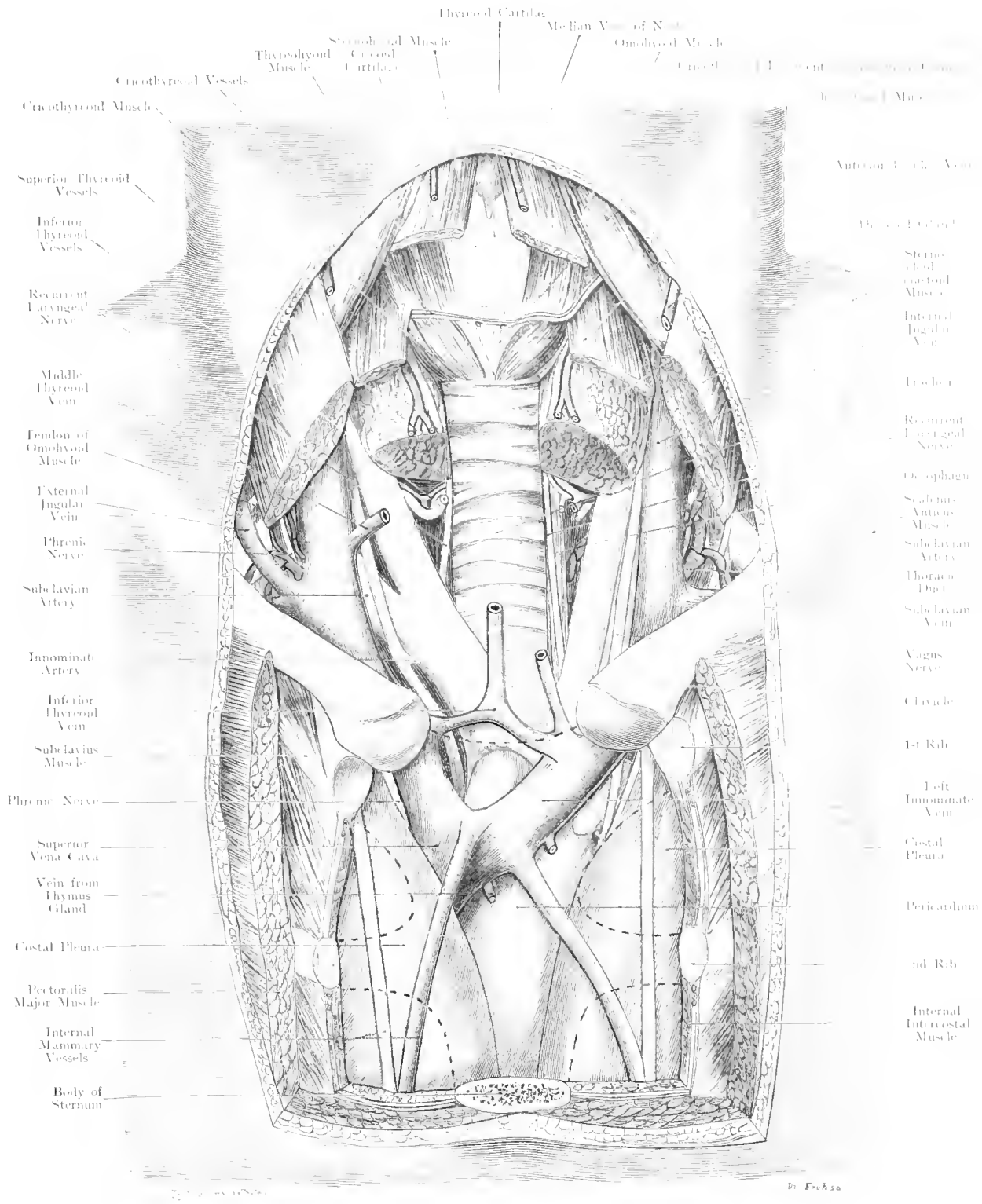


Fig. 113. Upper Aperture of Thorax.

1/4 Nat. Size.

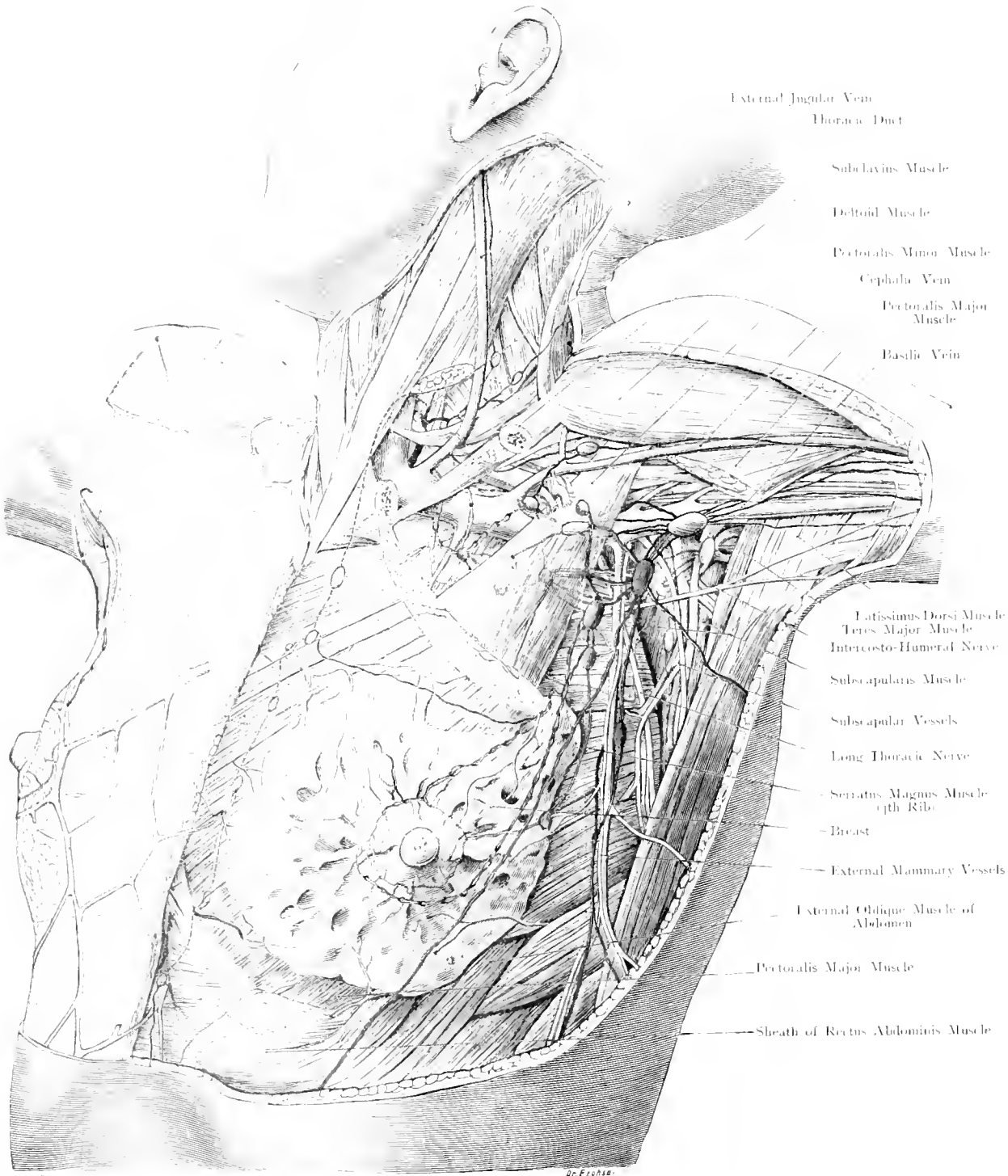


Fig. 114. Lymphatic Glands connected with the Mamma in an Adult.

¹/₂ Nat. Size.

Fig. 114. Lymphatic Glands connected with the Mamma in an Adult.

This figure is not drawn from a dissection but is a diagram constructed from many sources. (Essay by Fröhse on the Axillary Lymphatic Glands.) — On the right side the superficial layer, on the left side the deeper layer and the breast with its bloodvessels and lymphatics are shown. A large part of the Pectoralis Major Muscle and the Clavicle have been removed. — The internal set of glands are coloured blue, the external not coloured, the intermediate green and the deep red.

It is absolutely necessary to adopt a definite and universally applicable classification of the Axillary Lymphatics in order to readily comprehend their distribution. The number of Glands varies enormously (8 to 43) and into these enter the afferent Lymphatic Vessels from the Thorax and Arm.

Of the afferent lymphatics which come from the Thorax, those from the Mammary Gland have the greater practical importance. A superficial and a deep set, separated by the Intercosto-Humeral Nerve and the External Mammary Vessels can be made out.

The first regional gland for the lymphatics of the Breast lies, when the arm is abducted to a right angle, just below the free border of the Pectoralis Major Muscle at the level of the 3rd rib. An inconstant deep gland is sometimes present; this Paramammary Gland is depicted in the figure at the outer border of the breast. By Lesser enlargement of this gland is considered characteristic of Syphilis.

Usually from the Breast the Lymph passes through 1 to 4 glands which lie under cover of the Pectoralis Minor Muscle, parallel to the inner side of the Axillary Vein.

Thus it passes through several smaller glands — Subpectoral and Subclavian Glands.

In rare cases, which one should always bear in mind, lymphatic vessels pass between the two pectoral muscles and are associated with an Interpectoral Gland. But the more usual connection lies with the neighbouring External Gland called the Intermediate. Fortunately there seldom exists a direct communication with the deep glands, the Subscapular Glands and thence along the nerve to the Latissimus Dorsi Muscle. When this group becomes affected, the Neuro-Vascular bundle cannot well be left untouched in the course of a operation inasmuch as it is very frequently surrounded by the lymphatics (v. Origin of Subscapular Artery).

The lymph from the arm passes usually with the superficial vessels to a gland which lies (cf. Fig.) on the Axillary Vein; thence under cover of the Pectoralis Minor Muscle along the outer side of the vein.

A lymphatic channel may accompany the Cephalic Vein and disappear in the Infraclavicular Fossa, between the Deltoid and Pectoralis Major Muscles, to enter a Deltoideo-Pectoral (Infraclavicular) Gland.

The Deep Lymphatics lie partly on the Subscapularis Muscle, partly along the outer Thoracic Wall — the Subscapular and Thoracic Glands.

Accordingly it becomes advisable to classify the glands of the Axilla in the following way:

A. Superficial Glands.

Pectoral, Intermediate, Brachial, Infraclavicular (Deltoideo-Pectoral).

B. Deep Glands.

Subscapular.

To these regional sets of glands the following intermediate glands have to be added: Subpectoral, Subclavian and Thoracic.

An important variation in the Pectoral Glands is the presence of an Interpectoral Gland.

Apart from the usual lymphatic channels leading to the Axilla there are two (blue) other important lymphatic vessels which in obstruction or removal of the former carry lymph from the lower border of the breast to the Umbilicus, or to the Internal Mammary Artery.

From the supero-internal part of the Breast, lymphatics run into the Superficial Internal Pectoral Gland whence the lymph may travel into deeper regions. On the other hand, lymphatics may emerge towards the surface and connect the Internal Mammary Lymphatic Glands with the Superficial Glands of the Axilla. (Cf. the transverse black line at the upper border of the Mamma.)

Fig. 115. Lymphatics of Head, Neck, Chest and Arm. Child aged 1 year.

On the right side the Sternomastoid and Pectoralis Major Muscles together with the outer-half of the Clavicle have been removed in order to expose, to its full extent, the Right Lymphatic Duct. The large vessels and nerves have also been dissected out.

The Lymphatic Glands of the Head are chiefly found at the boundary between the head and neck, only in the neighbourhood of the lower jaw do they occur on the face — (Facial and Marginal Glands, FROESE).

Superficial and Deep (not constant) Facial Glands occur; the former (1 to 4) lie over the Parotid Salivary Gland; — Anterior, Superior, and Inferior Auricular Glands. — The Deep Glands (which often give rise to difficulty in diagnosis) lie in the substance of the Parotid Salivary Gland, on the Buccinator Muscle (Buccinator Gland), on the outer wall of the Pharynx or on the lower jaw (Deep Anterior Facial Gland), near the Facial Vein.

The Marginal Glands of the Head may be divided into, Submental, Submandibular, Parotid, Posterior Auricular (Mastoid) and Occipital.

There are, in all, 3 to 7 Submental Lymphatic Glands lying between the two bellies of the Digastric Muscles and receiving afferent lymphatic vessels from the Lower Lip and Chin.

There are 3 to 6 Submandibular Glands, situated around the Submaxillary Salivary Gland chiefly between this gland and the lower jaw; these receive lymph from the Lip, Gums, Floor of Mouth and the Salivary Glands which open here — (a detailed description is given in connection with Figs. 62 and 63).

There are 1 to 3 Posterior Auricular Glands (Mastoid Glands) situated at the attachment of the Sterno-Mastoid Muscle and are not limited to the Mastoid Process.

There are 1 to 4 Occipital Glands at the attachment of the Trapezius. In Fig. 52 an upper and a lower group are shown.

Superficial Cervical Glands (not constant) are found along the course of the External Jugular Vein between the Platysma and the Sterno-Mastoid Muscles.

Of the Deep Cervical Glands (25 to 70) the upper group lies at the bifurcation of the Carotid Artery along the Internal Jugular Vein as far as the base of the skull, around the XIIth Cranial Nerve, in the neighbourhood of the Thyreoid and the Vertebral Column; the lower group lies in the Suprasternal Notch, around the Brachial Plexus, in the angle between the Internal Jugular and the Subclavian Veins.

The Superior Group of Deep Cervical Glands form the secondary glands to those described above — Cephalic, Facial and Marginal but are the regional glands for the Skull Cavity, Pharynx, Tongue and Upper Part of the Larynx.

The Inferior Group of the Deep Cervical Glands form the secondary glands to the Superior Group and the regional glands for the lower part of the Larynx, Pharynx, and the Thyreoid Gland, also secondary to the Anterior Mediastinal (connected with the Subclavian Trunk).

This Subclavian Trunk, which is the chief vessel carrying lymph from the Axilla, sometimes has an independent opening into the Subclavian Vein (cf. Fig.).

For the Axillary Glands cf. Fig. 114.

The Thoracic Glands (not constant) are the continuation of the Subscapular Glands and lie against the Thoracic Wall (cf. Gland over 2nd rib at the upper border of the Pectoralis Minor Muscle). In a few cases they follow for a variable distance the nerve to the Serratus Magnus (BELL'S Nerve).

Of the Cubital Glands the superficial ones are the larger and more constant especially the one lying over the Ulnar Epicondyle (this is often enlarged in Syphils). The deep glands, usually small (1 to 2), are situated near the artery in the internal bicipital sulcus. The Brachial Gland is almost always constantly situated near the origin of the Inferior Profunda Artery.

The Lymphatics of the Nose (after KÜRTNER) and of the Pinna (after STAHR) are well shown.

From the roof of the nose two lymphatic channels extend backwards along the upper margin of the orbit and descend vertically over the Parotid Salivary Gland to a superficial Anterior Auricular Gland, a Deep Parotid and a Superficial Parotid Lymphatic Gland. From the middle region of the nose the lymphatics run partly over the Masseter Muscle, partly in company with the Facial Vein to the lower border of the lower jaw, — here they join the Parotid Lymphatic Gland, — also to the Posterior Submandibular Gland with the intervention, in their course, of a Buccinator Gland.

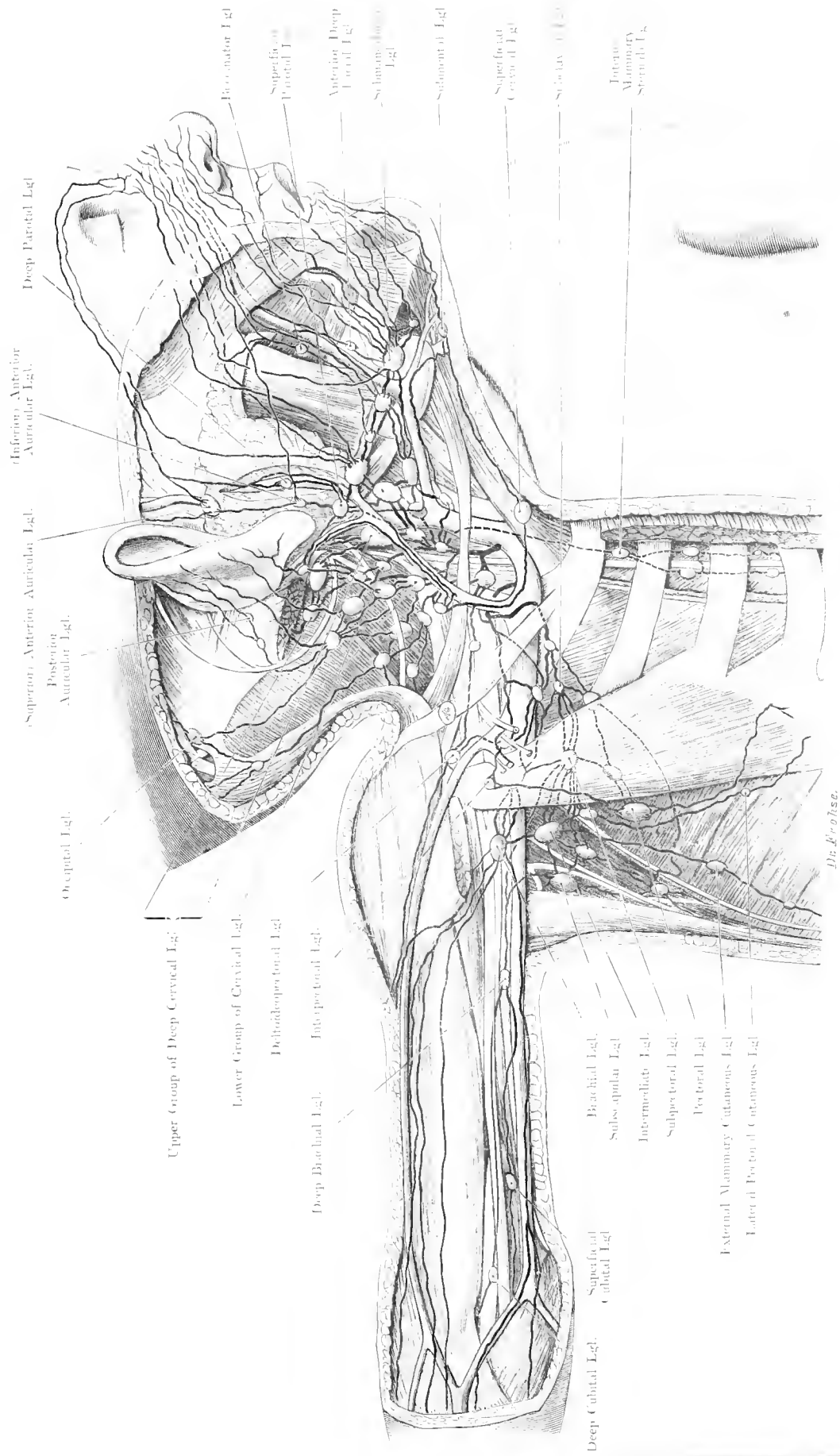


Fig. 115. Lymphatics of Head, Neck, Chest and Arm. — Child aged 1 year.
 1/10 Nat. Size. — Lgl. Lymphatic Gland.

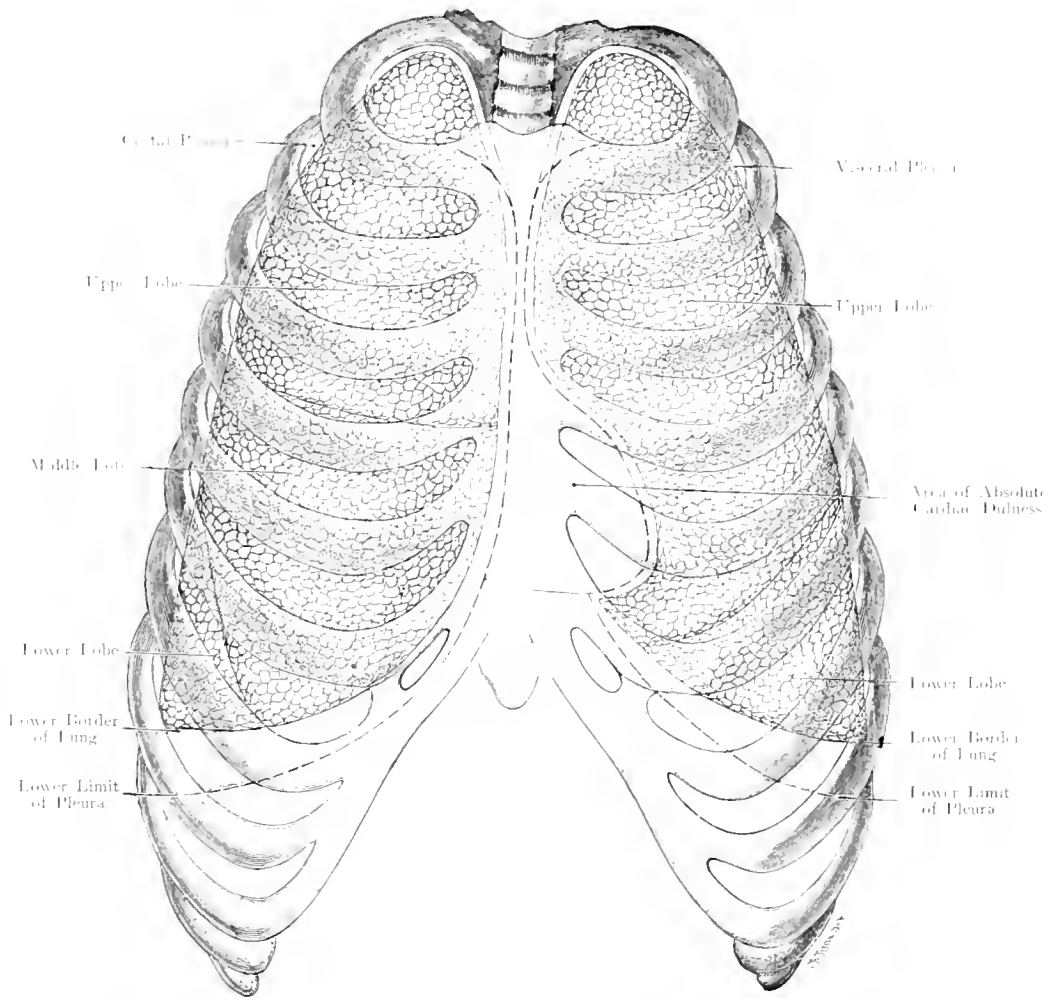


Fig. 116. Boundaries of the Lungs and Pleurae as seen from in Front.
 Area of Absolute Cardiac Dulness.

Nat. Size. — After JOESSEL (modified).

**Fig. 116. Boundaries of the Lungs and Pleurae as seen from in front.
Area of Absolute Cardiac Dulness.**

The Parietal Pleura consists of the Costal Pleura, the Diaphragmatic Pleura, the Mediastinal (including the Pericardial) Pleura and the Apical Pleura.

The knowledge of the reflections of the Pleura, i. e. the lines upon the Anterior Thoracic Wall at which the Costal Pleura becomes the Diaphragmatic and the Mediastinal Pleura — cf. dotted lines in the figure — is important.

The Anterior (Median) Boundary of the right costal pleura extends from the upper margin of the 1st costal cartilage at an angle of 45° downwards and inwards to a point $\frac{1}{10}$ th to 1 inch to the left of the middle line at the angle of the Sternum (Junction of Manubrium and Body of Sternum). From this point it continues downwards in a vertical direction, gradually approaching the middle line at the level of the 5th Costo-Sternal Articulation; from this point its course is slightly downwards along the lower border of the 6th costal cartilage in the 6th intercostal space or along the upper border of the 7th costal cartilage, the lower border of which it reaches about $\frac{3}{5}$ th of an inch mesial to its costo-chondral junction.

The costal cartilage of the 7th rib, like the lower costal cartilages, is almost entirely devoid of Pleura. This also applies to an increasing surface of the ribs themselves as we get lower in the series ($2\frac{1}{4}$ inches). The limit of the Pleura crosses the right nipple line (cf. Fig. 111) at the lower margin of the 6th costal cartilage or slightly lower down, and the axillary line at the lower border of the 9th Costal Cartilage.

In the upper part, the left costal pleura takes a similar course; it crosses the Sternal Angle (LUDWIG'S Angle) a little further to the left; from this point it passes so as to often reach the middle line, becoming, to some degree, adherent to the pleura of the opposite side; for the distance of 2 inches it extends vertically downwards until it reaches the level of the 4th costal cartilage; at this level the margin of the pleura extends obliquely downwards and outwards to the upper border of the 5th Costochondral Articulation whence it curves with its concavity inwards to the upper border of the 7th Costal Cartilage; from this point it again follows a similar course to the Right Pleura downwards and outwards; though mesially it does not reach the 7th Costal Cartilage it may extend lower down externally. The left pleura crosses the axillary line at the 10th rib or in the 9th interspace (cf. Fig. 126). The pink area indicates Absolute Cardiac Dulness which under normal conditions is not encroached upon by lung tissue and which area serves for the exposure of the Pericardium in Pericardiotomy. Cf. Figs. 70 and 121 for a description of the Apical Pleurae.

The boundaries between the different lobes are shewn in the figure.

The Right Lung has three lobes — the superior and middle lobes are separated anteriorly by a fissure which extends to the level of the 4th rib or $\frac{1}{2}$ inch lower. The boundary between the middle and inferior lobes lies opposite the 6th intercostal space and extends behind the anterior extremity of the 7th rib obliquely downwards to the lower border of the lung.

The Left Lung consists of 2 lobes and the fissure which separates them extends from the posterior end of the 4th interspace to the region behind the 7th costal cartilage.

Fig. 117. Boundaries of Lungs and Pleurae from behind.

The Median Boundaries of the Pleurae posteriorly, i. e. the lines at which the Costal Pleurae become continuous with the Mediastinal Pleurae, run along the bodies of the Vertebrae. The lower limit, i. e. where the Costal Pleura becomes continuous with the Diaphragmatic Pleura, is very important. From the lower border of the 12th Dorsal Vertebra this line runs horizontally outwards so that not only the lower rib cartilages but also the bony ribs are free. The 12th rib, which varies much in length and may even be absent, is usually bisected by this line.

The difference on the two sides in the Axillary Line has been mentioned in Fig. 116.

The Apices of the Pleurae are not visible from behind, because they never pass up as high as the upper surface of the 1st Dorsal Vertebra.

The fissures between the Upper and Lower Lobes are indicated by black lines, beginning behind in the 3rd intercostal space they run obliquely outwards and downwards.

But on the right side a small fissure arises from the main fissure and divides the upper lobe into two — (the Superior and Middle Lobes).

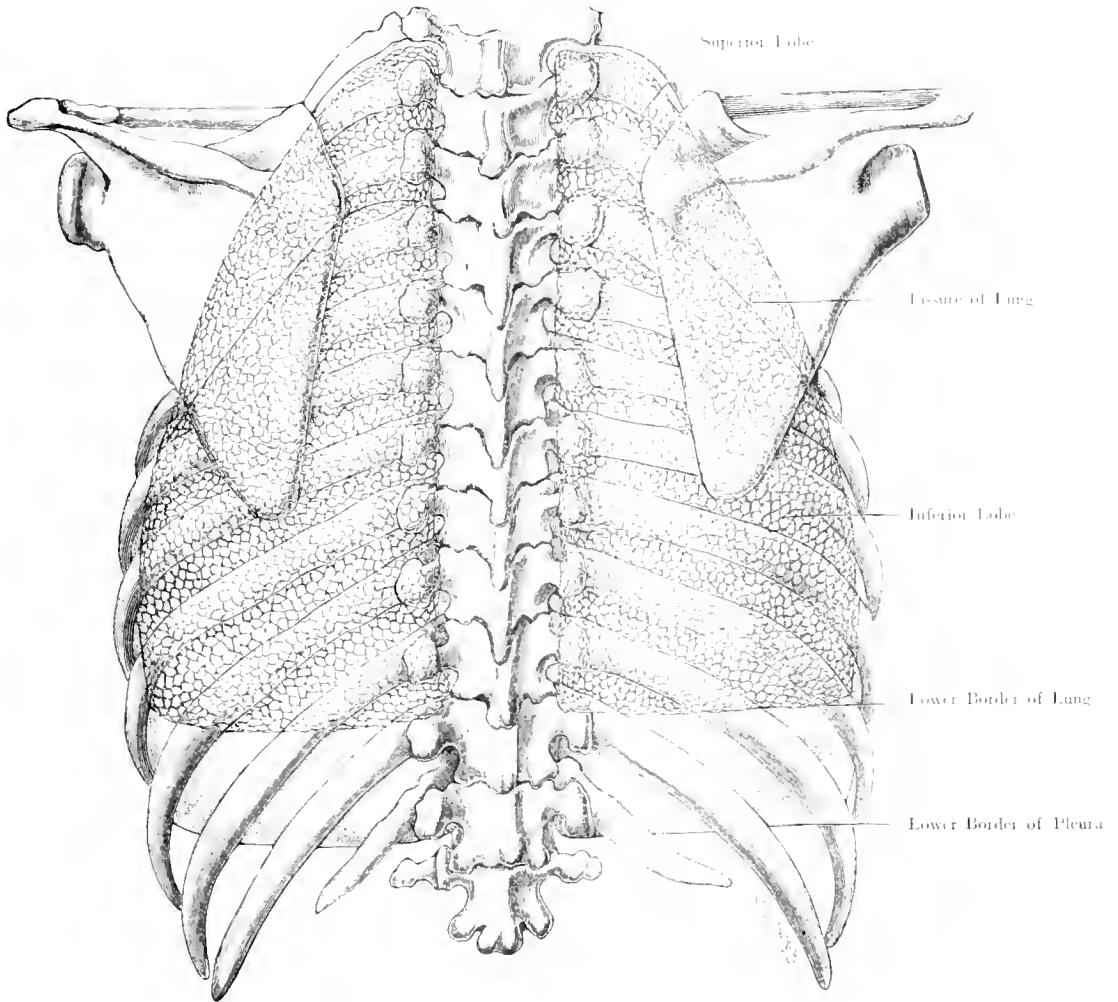


Fig. 117. Boundaries of Lungs and Pleurae, from behind.

$\frac{2}{3}$ Nat. Size. - Modified after JOESSEL.

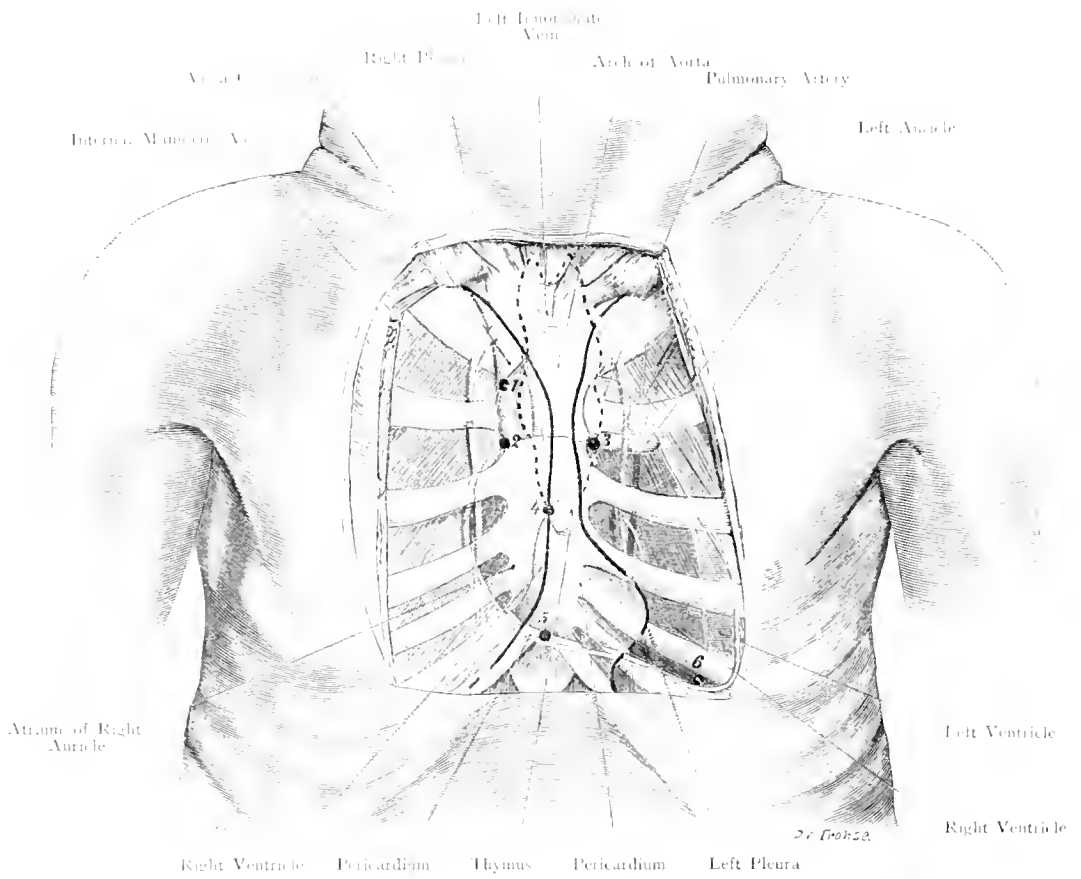


Fig. 118. Anterior Thoracic Wall and Heart in the New-Born.
Nat. Size.

Fig. 118. Anterior Thoracic Wall and Heart in the New-Born.

From the fresh corpse of a normal Foetus the soft parts, of the Anterior Thoracic Wall over the Sternum and Costal Cartilages have been removed. The position of the heart and its important parts has been determined by LUSCHKA'S method, (by the introduction of 6 needles). The heart and the great vessels are fully shewn in the figure, the bones and muscles being imagined as transparent. The outline of the Pericardium and the area of Absolute Cardiac Dulness are yellow.

The six points — indicated by Arabic figures — employed to determine the position of the heart are:

1. Internal angle of the first intercostal space on the right side close to the Sternum; Right Pleura, Right Phrenic Nerve, Reflection of Pericardium, Superior Vena Cava close to the right margin of the Arch of Aorta (this last-named structure may be pierced by inserting the needle obliquely); in the adult the Internal Mammary vessels would be injured, but not so in the child. Cf. Fig. 119.

2. Internal angle of the 2nd intercostal space on the right side close to the Sternum; Right Pleura, Superior Vena Cava, upper border of Right Auricle. Aperture of Pericardium.

3. Internal angle of 2nd intercostal space on the left side close to the Sternum; Region of Pulmonary and Aortic Valves (the pulmonary valves being anterior, above and to the left; the Aortic posterior, below and to the right) Cf. Fig. 120. The left pleura is opened by the needle.

4. Middle line of Sternum at the level of the 4th Chondro-sternal articulations or at a slightly higher level in the new-born; Border of Right Pleura, Boundary between right auricle and right ventricle; Tricuspid Valve.

5. Middle line of Sternum at the junction of the Manubrium with the Xiphisternum; Lower border of right ventricle or of pericardium, and of the area of Absolute Cardiac Dulness.

6. Lower border of 5th rib on the left side at its costo-chondral junction about $\frac{3}{5}$ th inch internal to the mammary line: Apex of Heart, or more accurately the limit between the left (red) and the right (blue) Ventricle. This needle passed exactly through the Interventricular Septum without entering either chamber of the Heart.

The upper and lower parts of the Anterior Mediastinum are continuous in the child; the Thymus which lies in front of the Pericardium reaches downwards between the Parietal pleurae as far as the area of Absolute Cardiac Dulness.

The Anterior Mediastinum is filled up by Thymus, loose connective tissue, fat, lymphatics and small vessels.

Fig. 119. Anterior Thoracic Wall and Heart in the Adult.

In addition to the soft parts covering the Thorax, the 3rd, 4th, 5th Costal Cartilages and the junction of the last named with the 6th Costal Cartilage together with the Intercostal muscles have been removed.

Between the slips of the Triangularis Sterni Muscle the parietal pleura (blue) is visible; its lines of reflection behind the Sternum are also delineated in blue.

Between the 3rd and 4th Costal Cartilages (cf. Fig. 116) the right and left pleurae are in contact with each other, as in the adult the Thymus has contracted upwards. The right pleura may extend considerably beyond the middle line, often as far as the left border of the Sternum.

Parallel with the borders of the Sternum, at a distance which varies with the width of the bone, the Internal Mammary Artery, a branch of the Subclavian, takes its course accompanied by 2 Venae Comites except in the two upper intercostal spaces where there is only one vein. Around the artery lie lymphatic glands, (Sternal and Anterior Mediastinal Glands) more numerous above than below. The Heart in the Adult is more deeply situated than in the Newborn and its apex is further to the left.

The distance from the Apex (Left Ventricle) to the nipple is $2\frac{2}{5}$ ths to $2\frac{1}{2}$ ths inch in the vertical line, and $\frac{1}{5}$ ths to $1\frac{1}{3}$ th inch in the horizontal direction. (As the Figure is $\frac{2}{5}$ ths nat. size, actual measurements according to the Figure will require multiplication by five thirds.)

An irregularity in the Costal Cartilage which may even involve the rib is shewn in the 4th Costal Cartilage on the right side.

The following data connected with the bony Thorax and in particular the costal cartilages have been made out by BARDELEBEN.

In about 10% the 8th Costal Cartilage, on both sides, articulates with the Sternum. The 6th and 7th Costal Cartilages usually articulate with each other; in 60% on the left side and in 40% on the right side, articulations exist between the 5th and 6th Costal Cartilages. The arrangement, together with the close apposition of the cartilages, convert the intercostal spaces in front of the pericardium into narrow slits.

The position of the Apex of the Heart, the Pulmonary and Aortic Valves is not absolutely constant — quite apart from physiological variations in form and position of the Heart.

The Pulmonary Valves usually lie opposite the 2nd left interspace or behind the 3rd left costal cartilage, rarely in the 3rd interspace.

For operations upon the Pericardium the most suitable site is a small area where the pericardium is uncovered by pleura. The entrance may be made through the 4th or 5th intercostal space, close to the Sternum, without wounding the pleura; the Internal Mammary Artery must always be borne in mind. Removal of a part of the 4th and 5th Costal Cartilages with a small portion of the left Sternum, allows a fair extent of the pericardium to be exposed.

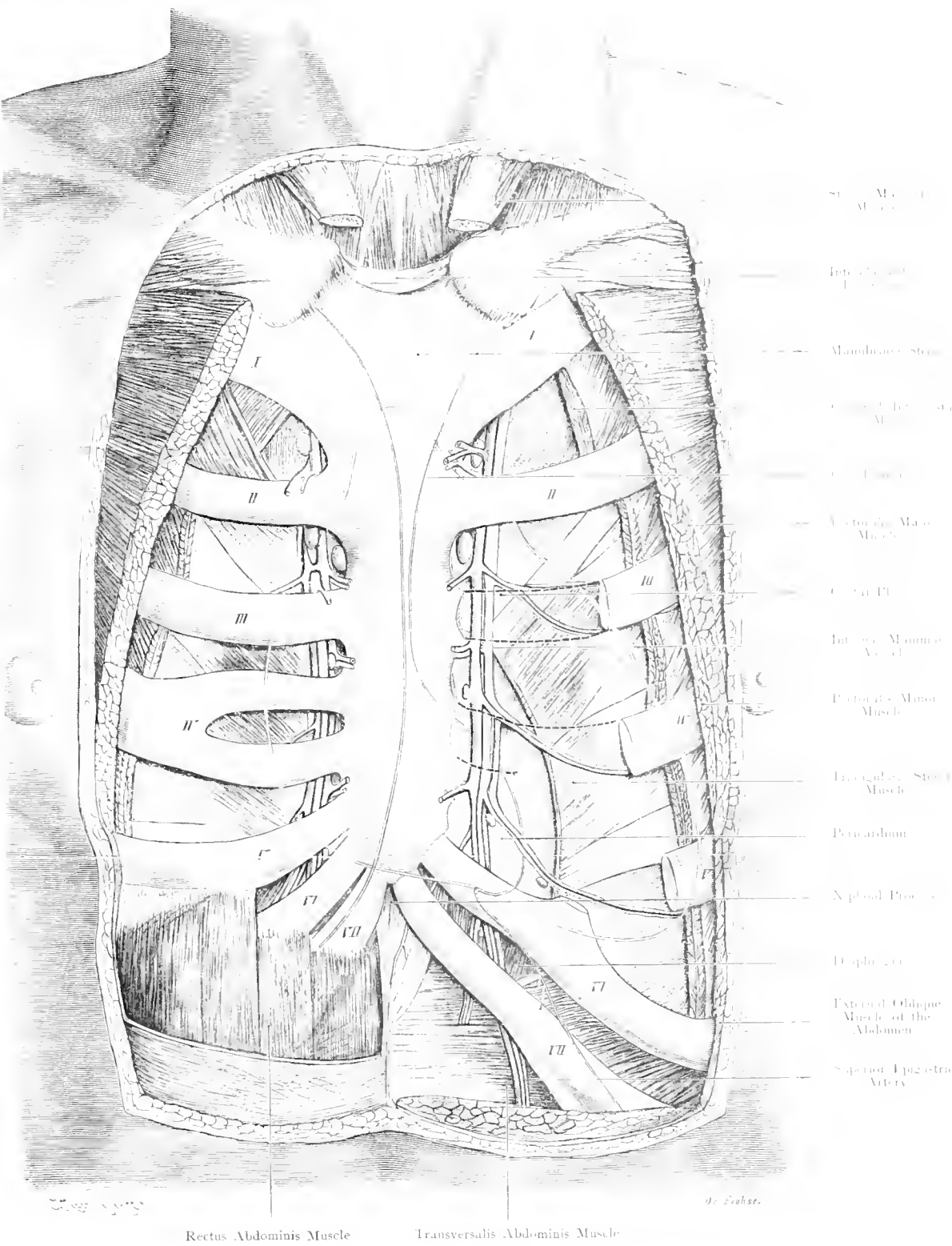


Fig. 119. Anterior Wall of Thorax and Heart in the Adult.
 Nat. Size.

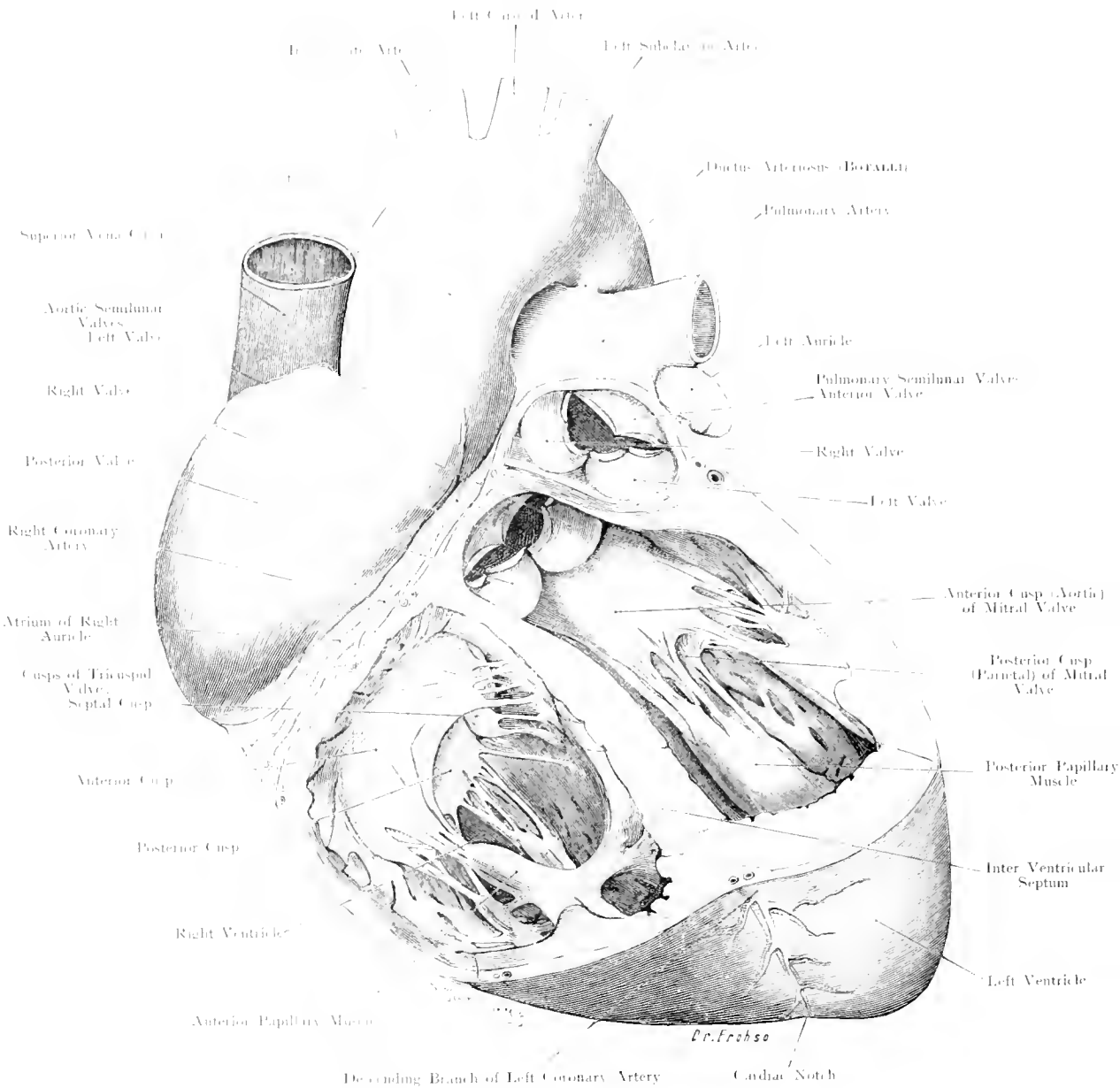


Fig. 120. Heart of Adult. — Ventricles opened.

Nat. Size.

Fig. 120. Heart of Adult, Ventricles Opened.

Normal adult heart hardened in formol; the ventricle is opened so as to show the Aortic and Pulmonary semilunar valves, the heart is rotated so that the Left Ventricle is more to the front.

The figure is semi-diagrammatic in order to demonstrate more clearly all the valves of the heart and their relative positions.

The figure shows the outer and anterior aspects of the Right Auricle, the Right Auricular appendage and the opening of the Superior Vena Cava.

Right Ventricle: Papillary Muscles, Anterior, Posterior and Septal. Chordae Tendineae, 3 Cusps of the Tricuspid valve, one large Anterior, a large Posterior and a small Septal Cusp; between the two Ventricles the Inter-Ventricular Septum; on the Anterior aspect of the Heart the inter-ventricular groove, terminating in the Cardiac Notch, and the Descending Branch of the Left Coronary Artery.

As the continuation of the Right Ventricle upwards (the Conus Arteriosus) has been widely opened and its left wall removed, the pulmonary semilunar valves appear to be completely disconnected from the Right Ventricle, but their relative positions are well shewn, one anterior, one right and one left.

Left Ventricle: Papillary Muscles, anterior or left and posterior or right with chordae tendineae attached to the two cusps of the mitral valve (right or aortic cusp and posterior or left cusp), the right one extending up into the Aorta and almost in continuity with the semilunar valve.

The Aortic Valves are three in number, like the pulmonary, one is posterior, two are anterior or right and left, this is due to the common developmental origin of the Aorta and Pulmonary Artery.

The Aortic Valves lie (cf. Fig. 119) more to the right, at a lower level and posterior to the Pulmonary Valves.

Because the Aortic Valves are situated deeply and at a considerable distance from the Anterior Thoracic Wall, to obviate the obliterating effect of the Pulmonary Valves the Stethoscope is applied over the 2nd right Intercostal space close to the Sternum, i. e. the point where the Aorta lies close to the Anterior Thoracic Wall.

The Mitral Valvular sound is listened for at the apex of the Heart.

Fig. 121. Transverse Section through the Trunk, at the level of the 1st and 2nd Dorsal Vertebra.

Frozen Section. The section passes through the 2nd Dorsal Vertebra and the Disc between the 1st and 2nd Dorsal Vertebrae, also through the 1st and 2nd Ribs, through the lower part of the Trachea, Thyroid Gland and Clavicle; the shoulder-joint on either side and Scapula with their muscles have been cut through. The shoulder is rather elevated.

The important details are:

- 1) Apices of Pleurae as seen from below are unequal because the section is not absolutely horizontal (Difference $\frac{1}{16}$ th inch). The Apices of the Lungs separated by the section have been removed. The Subclavian Artery on the left side arching over the Apex of the Lung, and its intimate relation to the 1st rib and the Scalene Muscles is noticed.
- 2) Course of the Trachea and Oesophagus; the former deviates a little to the right probably owing to the asymmetry of the Thyroid Gland whereas the Oesophagus normally deviates to the left.
- 3) When the Thyroid Gland is much enlarged (as in the inhabitants of the Saxony Mountain Districts) it not only surrounds the Trachea, but also touches the Oesophagus and exerts pressure on the Carotid Artery and thin-walled Jugular Vein — both vessels being pushed backwards and outwards.
- 4) The Brachial Plexus, on either side, has been cut through.
- 5) The Vagus Nerve is situated between the Carotid and Jugular Vessels (cf. Figs. 59, 61, and 113). Recurrent Laryngeal Nerve between the Trachea and Oesophagus (cf. Figs. 69 and 113).

The space between the Vertebral Column and the front of the neck is remarkably small for the passage of the important Cervical Structures.

Finally, the Tendon of the Long Head of the Biceps is seen in its groove and the subscapular bursa between the Subscapularis Muscle and the scapular or shoulder-joint is shewn.

Fig. 122. Transverse Section through the Thorax, at the level of 9th Dorsal Vertebra.

Frozen Section. The section is made through the 9th Dorsal Vertebra, the 4th to 9th ribs; in front the Sternum is divided just below the articulation of the 5th rib. As the man had died from Pneumonia the lungs are fully expanded and not in the cadaveric expiratory position.

This figure shews clearly how the Thorax is occupied by the 3 cavities (Pericardium containing the Heart, Pleurae containing the Lungs) and the spaces or Mediastina (cf. Fig. 112. Text).

The Anterior Mediastinum presents a very small space occupied by loose connective-tissue, fat and lymphatic glands, and shews that the pericardium is not completely covered by Pleura.

In the Posterior Mediastinum at some distance to the left of the Vertebral Column the descending Aorta is seen, on the right side the Oesophagus with both Vagus Nerves, whereas between the Great and Small Azygos Veins the Thoracic Duct is cut across, posteriorly is the sympathetic cord, and behind the right Vagus nerve is a small lymphatic gland.

This figure instinctively shews the position of the Phrenic Nerves between the Pericardium and Parietal Pleurae which is a point of considerable practical importance in Pleurisy.

On either side at the 7th rib in the Axillary line the Interlobar Pulmonary fissure is seen.

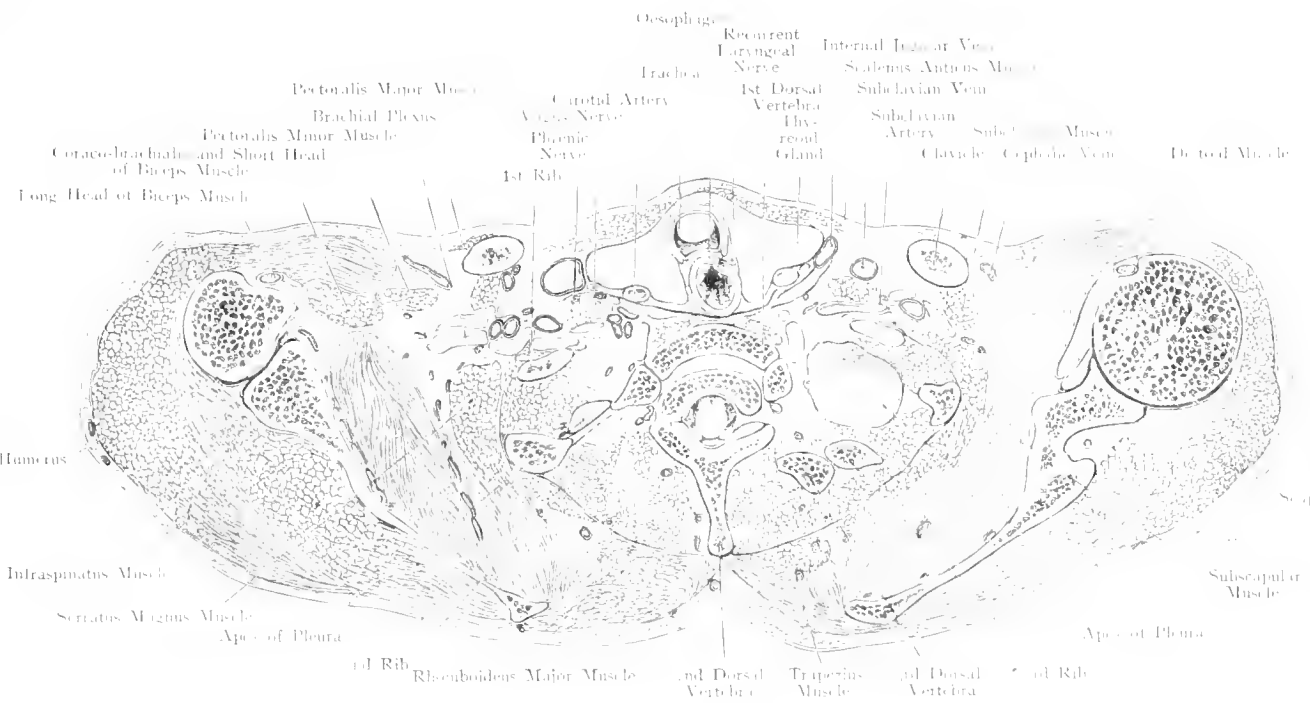


Fig. 121. Transverse Section through the Trunk at the level of the 1st and 2nd Dorsal Vertebra.
 Seen from below. — Nat. Size.

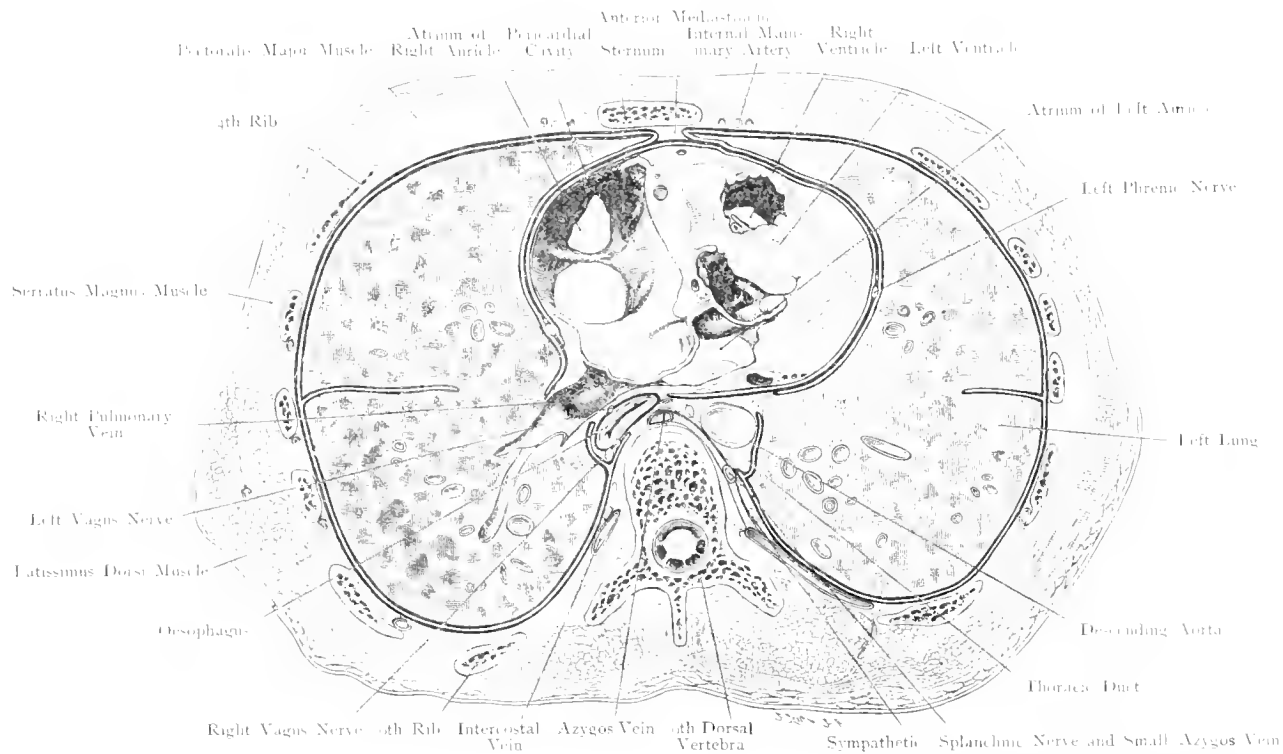


Fig. 122. Transverse Section through the Thorax at the level of the 9th Dorsal Vertebra.
 Seen from below. — $\frac{2}{3}$ Nat. Size.

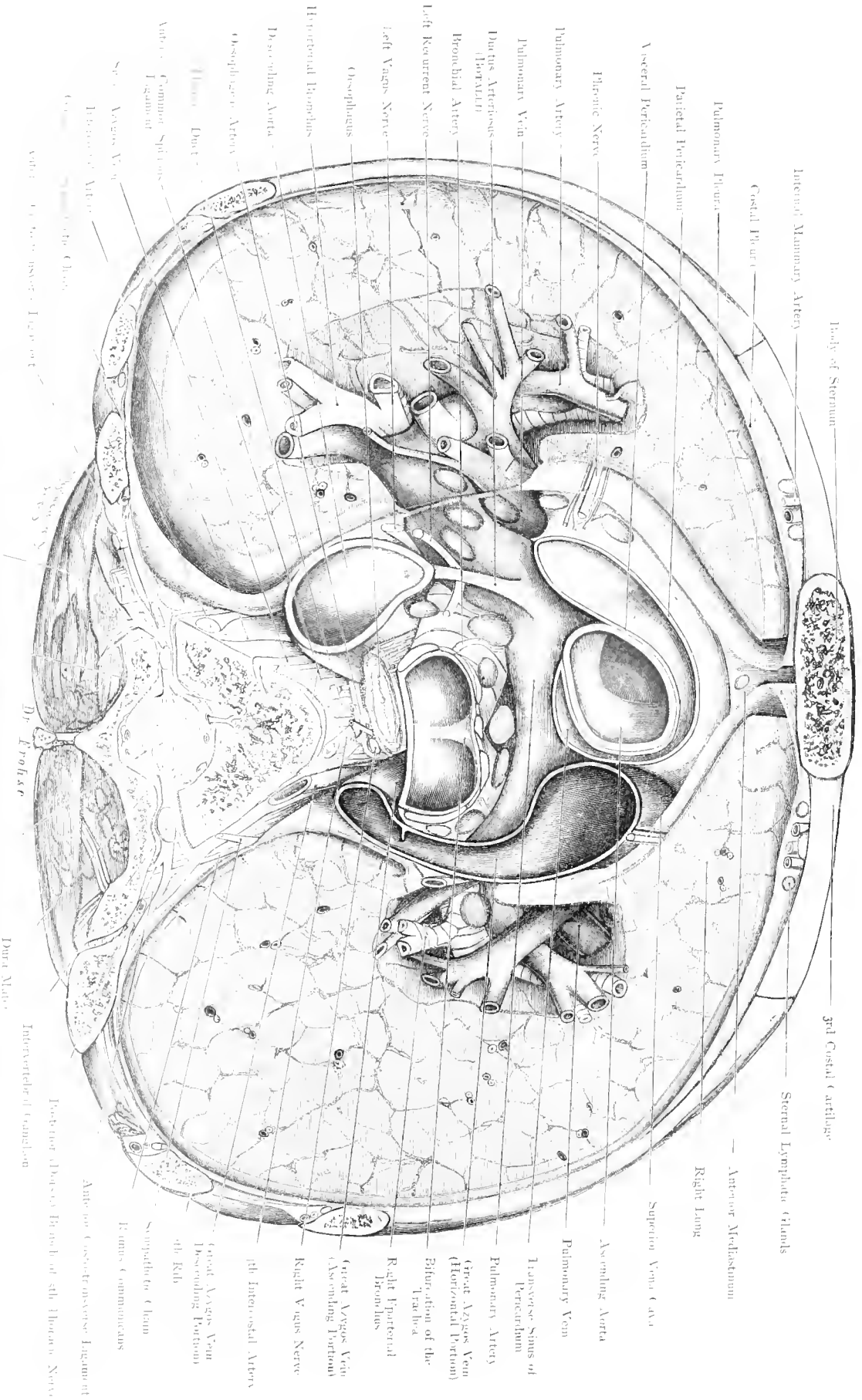


Fig. 123. Transverse Section through Thorax at the level of the 5th Dorsal Vertebra.

Seen from above. — Nat. Size.

Fig. 123. Transverse Section through the Thorax at the level of the 5th Dorsal Vertebra. Seen from above.

After hardening in formal a transverse section was made slanting downwards and forwards through the symmetrical thorax. The 5th Dorsal Vertebra, 3rd, 4th and 5th ribs were divided, obliquely; the section shows the greater part of the 3rd rib with its costal cartilage; by careful dissection structures below the plane of section have been exposed, e. g. the vessels and bronchi at the root of the lung, by removal of lung tissue.

Attention is directed to the following details.

Thoracic Wall: all the soft structures down to the bone have been removed except the deep muscles of the back.

Skeleton. a) Vertebral Column with Nerves; Body; Spinous Process, Neural Arch, Right Transverse Process of 5th Dorsal Vertebra, Spinal Canal containing Cord, Meninges, Large Veins with Spinal nerves emerging on either side through the Intervertebral Foramina, 5th Dorsal Nerve, ganglion, anterior and posterior divisions and Rami Communicantes to the Sympathetic on the right side.

b) Ribs. Close to the 5th Dorsal Vertebra is seen the 5th rib and by following the oblique section forward the 4th and 3rd ribs in sequence. If the section had been horizontal a portion of the 2nd rib would be in view.

c) Sternum. The body of the Sternum is divided close above the 3rd Chondro-Sternal articulation.

Behind the 3rd Costal Cartilage on both sides the Internal Mammary Artery, (a branch of the Subclavian) is seen, together with its accompanying Veins and associated lymphatics (Sternal glands).

Costal Pleura, Mediastinal Pleura, Pleural Cavity, Visceral Pleura, both Lungs with their roots (Hilum).

The Pulmonary Artery and its branches — greyish pink — the trunks of the Pulmonary veins — greyish violet. Bronchi and Bronchioles — white.

These structures are found in the following relative positions at the root of the Lungs, Veins Anterior, Artery in the Middle,

Bronchi posteriorly, but owing to free ramification in all directions such relations soon become altered.

Anteriorly in the middle line and for its greater part covered by Visceral Pericardium the Aorta (dark red) passes upwards and later passes downwards on the left side of the Vertebral column. The Arch (Transverse portion) of the Aorta lies above the plane of this section. Connecting the Pulmonary Artery with the Aorta is the Ductus Arteriosus (the remains of the 4th primary branchial artery); it is around this structure that the Recurrent Laryngeal Branch of the Vagus Nerve winds on the left side. To the right of the descending Thoracic Aorta and in front of the Vertebral column lies the Oesophagus accompanied by both Vagus Nerves, in front of the (Oesophagus the Trachea (pink) bifurcating into right and left Bronchus, into the open mouths of which the reader looks.

On the Anterior and lateral aspects of the Trachea and Bronchi as well as along the branches of the Pulmonary artery are seen a great number of lymphatic glands (the Bronchial glands, grey).

Between the parietal pericardium and the pericardial (mediastinal) pleura, though not symmetrically placed on both sides are the Phrenic Nerves with their companion arteries (Arteria Comes Nervi Phrenici) and Veins.

Behind the Oesophagus, practically in the middle line, is found the Thoracic Duct (red): to the right and left respectively of the bodies of the Vertebrae lie the great and small Azygos Veins. The Great Azygos Vein opens into the Superior Vena Cava.

Fig. 124. Position of Abdominal Viscera, from in front.

Cf. Fig. 111 for Topography.

In the right hypochondrium lies the Liver which even extends further (however, the 12th rib, costal cartilages of 9th, 10th, 11th ribs should be excepted). The liver lies in contact with the diaphragm, and indirectly with the Thoracic wall, the lower border of the viscus varies with its size and shape — this depends upon the shape of the Thorax — and with respiration. In the nipple line it may correspond to the costal arch or extend below it $\frac{1}{3}$ ths to $1\frac{2}{3}$ ths inch. In the Axillary line it reaches to the 10th intercostal space or extends $\frac{1}{3}$ ths to $1\frac{3}{5}$ ths inch lower down. The lower concave surface of the Viscus is in relation with the right kidney, right supra-renal body (cf. Renal Impression Fig. 136) and hepatic flexure of Colon.

In the left Hypochondrium lie the Kidney, Suprarenal body, Stomach, Spleen, Splenic Flexure of Colon, Tail of the Pancreas and usually a part of the left lobe of the Liver. This region is occupied by about $\frac{2}{3}$ ths of the Stomach i. e. Cardia and Fundus. The Cardia lies behind the outer end of the 7th Costal Cartilage, the inner concave surface of the Spleen is in relation with the upper part of the left kidney, its outer convex surface with the Diaphragm (Phrenico-Splenic ligament), cf. Figs. 125, 126, 136. As a rule the liver does not extend further to the left than the inner half of the 7th Costal Cartilage. The Splenic flexure is anchored by the Phrenico-colic fold to the 10th and 11th ribs. This fold also forms a platform upon which the spleen reposes, but this fold becomes stretched when the spleen is enlarged and any alteration occurs in the position of the Colon.

The form and size of the Epigastric regions vary with the individual and the sex; the subcostal angle varies widely between 30° and 70° . The shape of the Xiphoid Process offers many variations, it may be directed forwards, backwards or laterally, presenting an opening, or be bifurcated, curved or crooked.

In the Epigastric region are found a part of the Liver, Gall-Bladder, Stomach, Duodenum and Transverse Colon.

The lower border of the Liver extends at the 8th costal cartilage beyond the right costal arch and often reaches to a point midway between the Umbilicus and the top of the Xiphoid Process. At the lower border of the Liver near the 9th and 10th costal cartilages is situated the gall-bladder (cf. Figs. 131 and 132).

Behind the Liver are situated: Lesser Curvature of Stomach, Small Omentum, Omental Sac, Aorta, Coeliac Plexus of Sympathetic; a part of the Stomach, (Antrum Pylori) touches the Abdominal Wall.

To the right of the Middle line, normally, Transverse Colon as well as Duodenum lie in this region. The former is often curved and extends downwards into the Umbilical region. In some cases it lies wholly outside the Epigastrium.

The Umbilical Region contains a great portion of small intestine (mostly Ileum) which is usually covered by the Great Omentum. The Iliac Region contains the ascending (right) and descending (left) Colon with Small Intestine.

The Hypogastric region lodges in its middle, small intestine, bladder (when distended) and uterus (when pregnant) — on the right the Appendix and on the left the Sigmoid Flexure. The greater part of the anterior wall of the Bladder is uncovered by Peritoneum (cf. Fig. B): when the bladder is much distended this region corresponds to a Δ $\frac{1}{3}$ ths to 2 ins. high with a base corresponding to the interval between the 2 pubic spines (about $1\frac{3}{5}$ th inch). Cf. Figs. 143, 144.

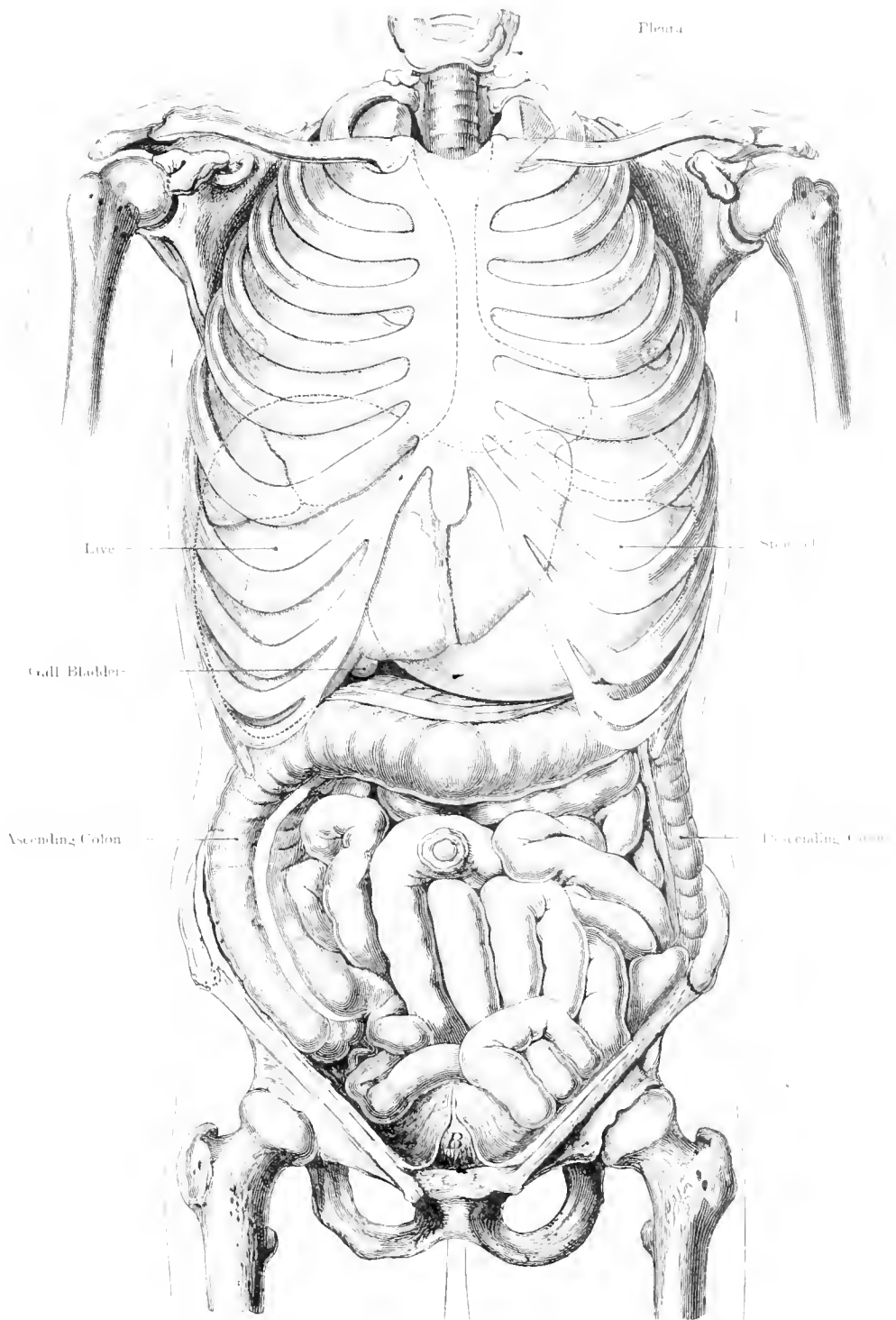


Fig. 124. Position of Abdominal Viscera, from in front.

$\frac{1}{2}$ Nat. Size. — After LUSCHKA.

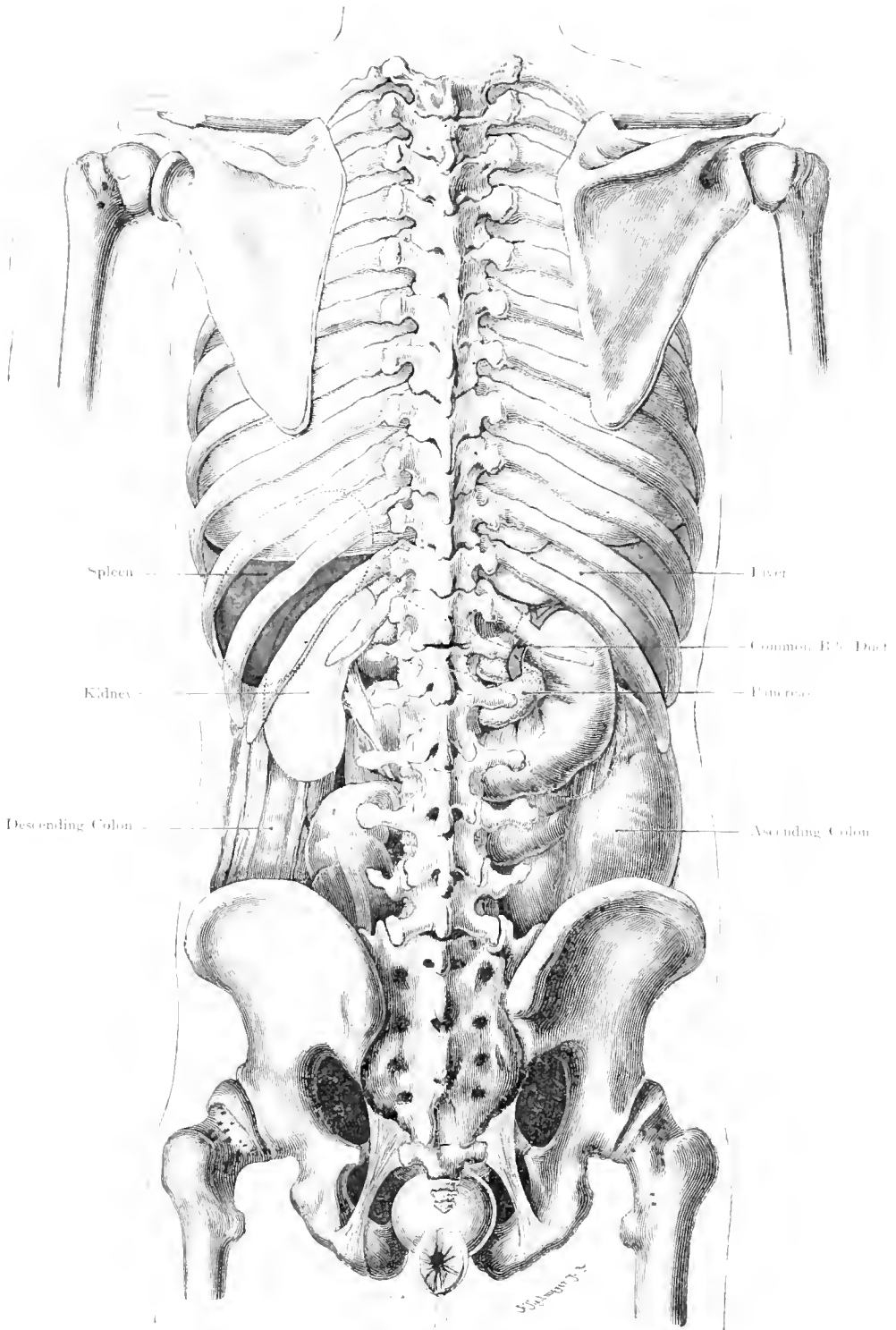


Fig. 125. Position of Abdominal Viscera, from behind.

1 Nat. Size. After LUSCHKA.

Fig. 125. Position of Abdominal Viscera from behind.

Between the level of the 9th and 11th ribs on the left side is situated the Spleen which lies in relation with the Diaphragm above, and the left kidney below (cf. Figs. 126 and 136).

The Kidneys lie opposite the 12th Dorsal and the 1st and 2nd Lumbar Vertebrae and in front of the 12th rib, on the left side also in front of the 11th rib. The right kidney, due to the size of the Liver, is mostly found at a lower level. Sometimes both kidneys are at the same level, but rarely is the right higher. Both kidneys are occasionally situated at a considerably lower level without any evidence of undue mobility. A horseshoe-shaped kidney, i. e. when the lower ends of the two viscera are joined in front of the Vertebral Column, is no great rarity. (Cf. Fig. 127.)

The descending colon lies to the outer side of the left Kidney whereas the ascending colon with its Mesocolon lies in front of the right kidney with the duodenum above (for further details, cf. Fig. 135).

The Pancreas — in front of the 1st Lumbar Vertebra — extends to the left as far as the Kidney and Spleen; its upper part may touch the Suprarenal Gland. In the figure it is visible on either side of the Vertebral Column (yellow) the intermediate part being indicated by dotted lines. Its head is almost completely encircled by the Duodenum; into the Vertical portion of the Duodenum which is closely applied to the posterior abdominal wall, the Duct of the Pancreas (Duct of WIRSUNG) which is usually joined by an accessory Duct (Duct of SANTORINI) (cf. Fig. 130, text), and the Common Bile Duct open.

These relations are shewn in the figure, which also depicts the left ureter coming from the left kidney (cf. Figs. 120, 129 and 133).

The ascending Colon is seen on the right, the descending on the left (next in continuity the Sigmoid Flexure) between the Costal Arch and the Crest of the Ilium.

The relations of the Peritoneum to the Viscera are described in Fig. 136.

The last portion of the gut shews the Ampulla of the Rectum against which the Coccyx lies. Below the tip of that bone, the Rectum passes backward (Perineal Curve) and opens in the slit-like laterally compressed Anus.

Fig. 126. Left Lung and Spleen. — Side View.

The figure shews the diaphragm during extreme expiration (cadaveric expiration); the vault extends as high as the 4th left intercostal space and the left lung to the same degree. The fissure of the Lung — the left boundary of the pleura, cf. Figs. 116 and 117 — and especially the normal position of a normal spleen are shewn.

The inner concave surface of the spleen lies against the Fundus of the Stomach and the upper part of the left kidney (cf. Fig. 135), the convexity is in relation with the Diaphragm connected with it by the Phrenico-Splenic Ligament. The spleen extends from (cf. Fig. 125) the 9th to the 11th rib with its long axis corresponding to the long axis of the 10th rib, in a downward and forward direction, so that the inferior pole points towards the Umbilicus. A normal spleen does not extend beyond the costo-chondral line — i. e. a line drawn from the left Sterno-clavicular articulation to the top of the 11th rib.

Through the Sacro-Sciatic Foramen the lower part of the Sigmoid Flexure and the Rectum are visible.

The convex diaphragmatic surface of the spleen is shewn; as the spleen is a viscus subject to many forms of enlargement, it is desirable to learn the direction in which its increase in size must extend.

The upper concave surface is in relation with the fundus of the Stomach; this frequently prevents a permanent enlargement upwards. The lower surface rests upon solid viscera — left kidney, Pancreas and left Supra-renal glands — which under normal conditions cannot easily be pushed aside.

The Phrenico-Splenic Ligament prevents expansion vertically downwards, but it affords a gliding surface along which the spleen may when enlarged slide forwards and downwards. It is thus that the anterior pole of an enlarged spleen is most readily felt at the anterior border of the 10th rib.

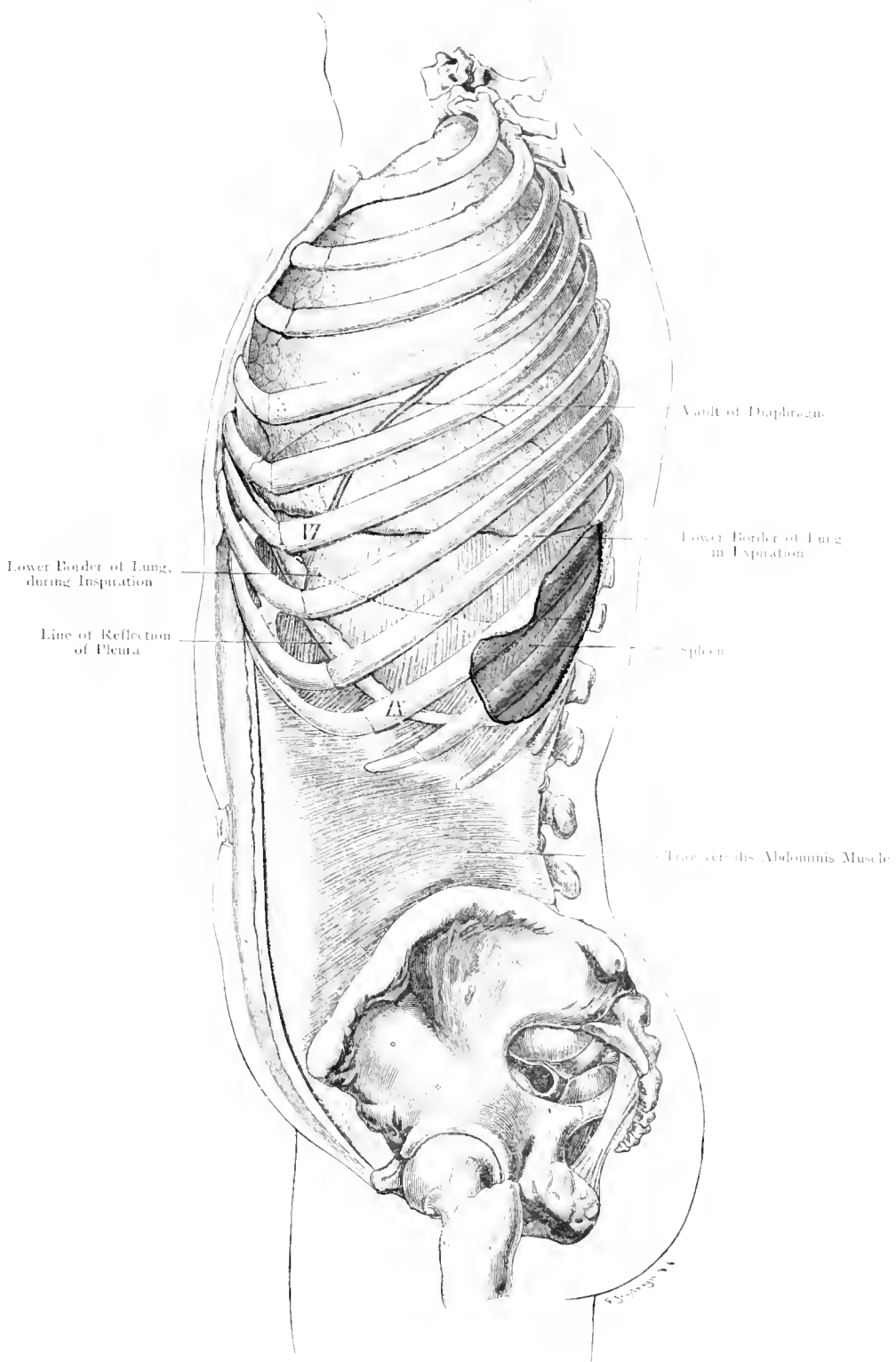


Fig. 126. Left Lung and Spleen, lateral view.

$\frac{1}{2}$ Nat. Size. — After LUSCHKA.

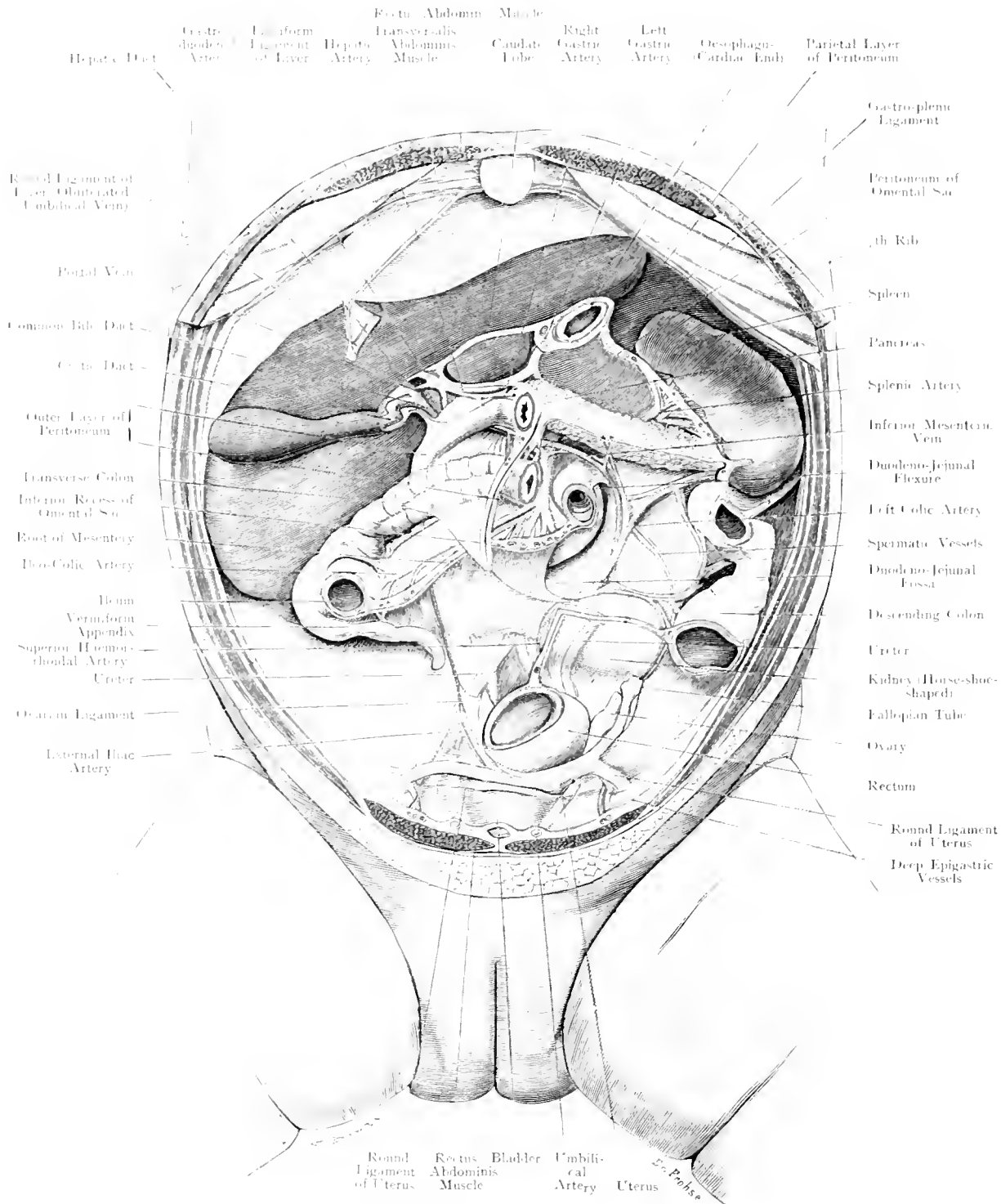


Fig. 127. Position of Viscera covered by Peritoneum — Child.

1/4 Nat. Size.

Fig. 127. Position of Viscera covered by Peritoneum – Child.

Child under one year of age. Anterior abdominal wall, Stomach, Jejunum, Ileum, Left portion of Transverse Colon, Sigmoid Flexure, Mesenteries and wall of Omental Sac, Transverse Mesocolon have been removed. Peritoneum, blue. Inner layer of Omental Sac, yellow.

This figure shews the Abdominal and part of the Pelvic Viscera in situ after removal of those mentioned above. The Liver is large, its anterior surface passing beyond the right costal arch throughout its whole extent (remining one of the arrangement in the Foetus). Of the Viscera the following parts are shewn. Cardiac end of Stomach cut across transversely. Pylorus joining the Duodenum, of which, by removal of the Anterior layer of the lesser Omentum, the horizontal and commencement of the descending portion with the opening of the Common Bile Duct are shewn.

The remaining part is covered by the Transverse Colon. The lumen of the intestine is visible at the Duodeno-jejunal Flexure, below and posterior to which is found the Duodeno-jejunal Fossa.

The Ileo-caecal junction and the Vermiform Appendix are seen in their usual position at a higher level in the child than in the adult.

The Ascending Colon which appears rather short in the figure, the right half of the Transverse Colon (lumen owing to line of section), on the left the Splenic Flexure, Descending Colon, and two openings through which the upper and lower extremities of the Sigmoid Flexure are also visible.

On the lower surface of the Liver we find the Gall Bladder and vessels entering the Hilum of the Liver, the Bile Ducts and further to the left the Spleen. Forming the left inferior boundary of the Fossa Duodeno-jejunalis is the Left Colic Artery.

In this instance the Kidney is horseshoe-shaped, but the Ureters are normal and occupy normal positions, crossing the External Iliac vessels (cf. Figs. 131, 134, 136, 137, 149, 150) and disappearing behind the much distended Rectum.

By the side of the left Ureter runs the Superior Haemorrhoidal Artery (a branch of the Inferior Mesenteric) to the Rectum.

In front of the Rectum is the Uterus, of which the fundus is visible; from either side the round ligament passes to the Inguinal Canal crossing in their course the Deep Epigastric Vessels. The Fallopian Tubes and Ovaries lie on the right side in the true pelvis, on the left side in the false pelvis, either because they have not completely descended, or, more probably, because the much distended Rectum had pushed them upwards. This latter view is supported by the fact that the Fundus Uteri is squeezed in between the Bladder and the left wall of the pelvis.

In front of the Uterus lies the Bladder, bounded anteriorly by the slightly opened Cave of RETZIUS; in this region the Bladder is uncovered by Peritoneum.

The Peritoneum which lines all these organs, and encloses them to a greater or lesser degree, has been cut off at the root of the mesentery. (Cf. Fig. 136.)

Fig. 128. Liver, Stomach, Pancreas, Omental Sac.

In the fresh adult cadaver with the shoulders pushed forcibly backwards a large window has been made in the Anterior Abdominal wall. A window has also been made in the Small Omentum, whereas the right segment of the Gastro-Colic fold has also been opened up. Through the Foramen of WINSLOW has been passed a director with three diverging limbs, one disappears behind the Curvate Lobe lying in the Atrium of the Omental Sac which extends upwards along the Vena Cava to the central tendon of the Diaphragm (cf. Fig. 139), the second passing around the Gastro-pancreatic fold divides so that one branch goes upwards to the Splenic recess, the other downwards over the Pancreas and behind the Stomach into the inferior recess of the Omental Sac.

Liver drawn upwards to the right. Lymphatic gland, orange. The Cardiac end of the Stomach is its most fixed part, because the Oesophagus is fixed; the Pylorus is slightly movable. The body of the Stomach between these two points varies in position according to its distension and frequent pathological conditions (dilatation, varying size of Liver etc.). When moderately full the greater curvature lies three or four fingers' breadth above the Umbilicus. The Oesophagus extends about one inch below the Diaphragm, so that the Stomach may be completely removed. The Cardiac end lies to the left of the 11th Dorsal Vertebra from which it is separated by the Descending Aorta, its projection on to the Anterior Abdominal Wall touches the 7th Costo-sternal articulation. The Pylorus lies a little to the right of the Vertebral column at the level of the disc between the 12th Dorsal and the 1st Lumbar Vertebra; this moves a little to the right when the Stomach contains food. To gain access to this region in surgical operations a median incision should be made between the Umbilicus and Xiphoid Process.

The Fundus of the Stomach is better exposed by an incision carried downwards from the left costal arch through the Rectus Abdominis, or parallel with the arch just below its margin.

The Stomach receives its blood supply from the Coeliac Axis which gives off the Gastric (Coronary) Artery running along the lesser

curvature; this vessel anastomoses with the Pyloric Artery from the Hepatic. Along the greater curvature run the left Gastro-Epiploic from the Splenic (another branch of the Coeliac Axis) and the right Gastro-Epiploic, a branch of the Gastro-duodenal from the Hepatic.

Of importance in connection with the spread of Carcinoma is the arrangement of the lymphatic glands. The bulk of the lymph from the Stomach passes along the lesser curvature and to the Cardiac end where there are many glands situated along the Gastric Artery and around the Cardiac branch (Superior Gastric Glands).

A lesser number of lymphatic glands lie at the right half of the greater curvature near to the Pylorus (Inferior Gastric Glands). The smallest area corresponding to the fundus portion of the greater curvature has its lymph drained to the Splenic glands. From these 3 groups the lymph is directed to the Pancreatic and Splenic glands as they lie along the upper border of the Pancreas, and to the Coeliac Glands which are grouped around the Coeliac Axis.

If these last-named are implicated a radical operation would be hardly possible.

The Small Omentum, in the removal of the Stomach, should not be cut at too great a distance from the lower curvature because the branch of the left Vagus distributed to the Stomach and the Liver would be injured (cf. Figure) and the function of the Liver be damaged.

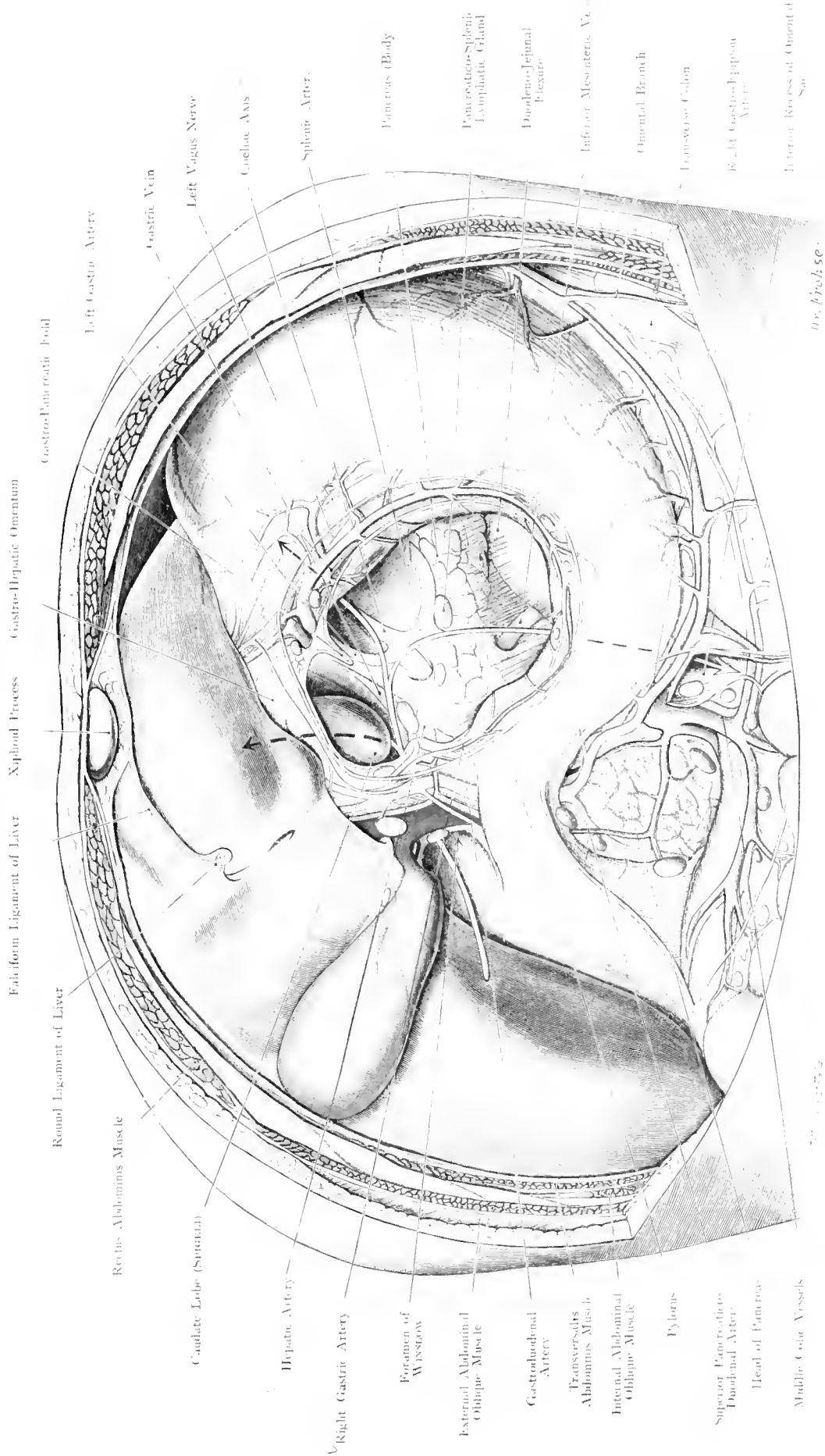


Fig. 128. Liver, Stomach, Pancreas, Omental Sac.
 Seen from in front and below. $\frac{1}{2}$ Nat. Size.

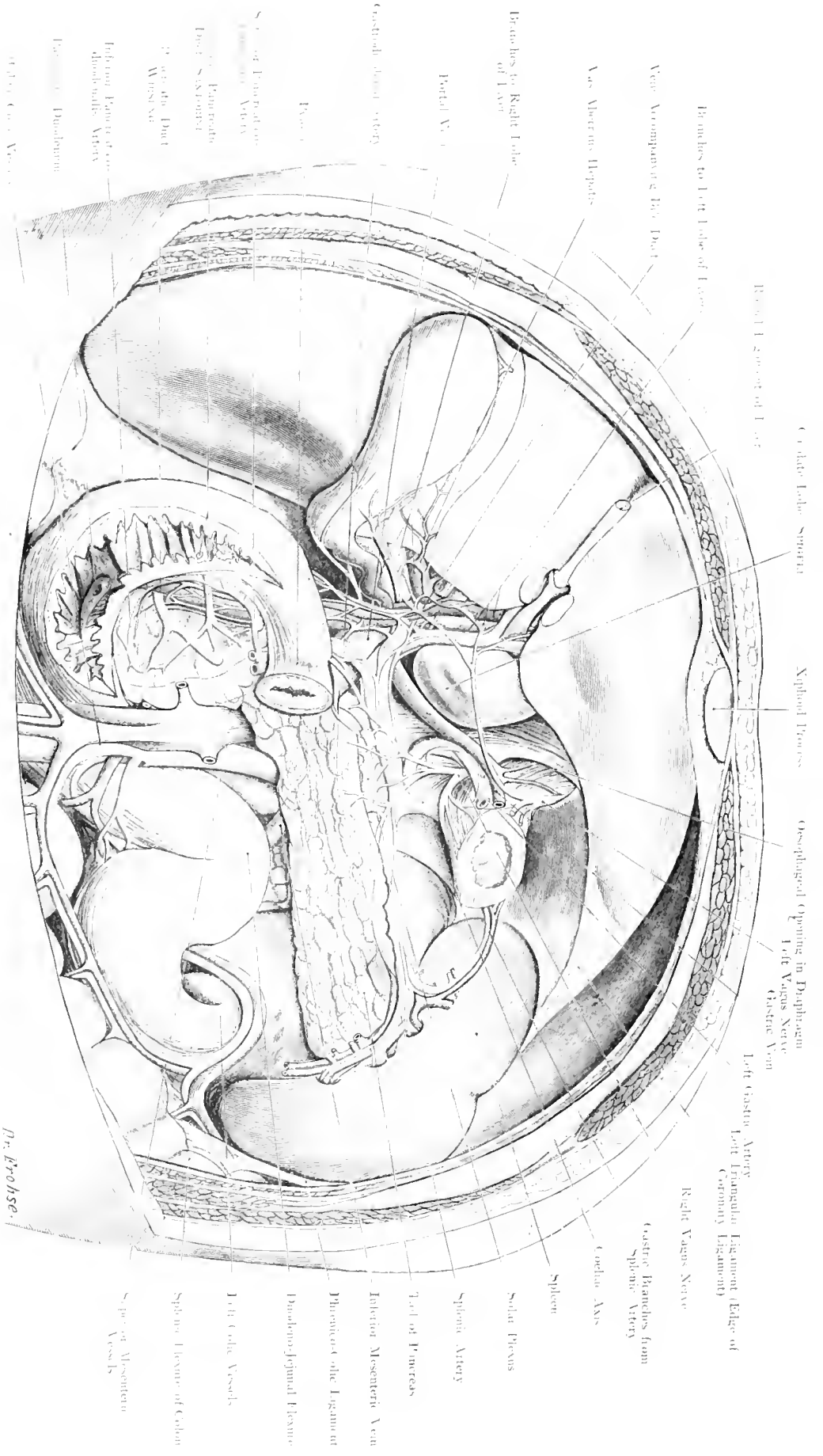


Fig. 129. Liver, Spleen, Pancreas, Duodenum: after removal of Stomach.

Seen from in front and below. — Nat. Size.

Fig. 129. Liver, Spleen, Pancreas, Duodenum, the Stomach having been removed.

The position is the same as in Fig. 128, but the Stomach has been removed with the exception of the Cardiac and Pyloric ends. Small Omentum, Gastro Colic Fold, and Mesocolon have also been cut away together with the posterior layer of the peritoneum. Vessels, Nerves, Ducts of Pancreas and the Biliary Ducts have been exposed by dissection. The Descending portion and lower part of the Duodenum are laid open.

The Pancreas, 6 to 7 inches in length, extends to the left inclining upwards across the 1st and upper part of the 2nd Lumbar Vertebra; its head lies in the curve of the Duodenum, its tail ends at the under surface of the Spleen. The upper border frequently shows a Tubercle (mentale) and extends upwards above the lesser curvature of the Stomach.

Its anterior surface is covered by Peritoneum, the chief duct (the Duct of WIRSTUNG) runs behind the Common Bile Duct and opens in common with it, at the Ampulla of VALLER, into the Duodenum. The upper part of the head often has an accessory duct (Duct of SANCTORINI) which opens separately into the Duodenum but anastomoses with the chief duct.

The region of the Pancreas is much interfered with from the operative view owing to the great number of blood-vessels. Directly behind it are the Aorta and Inferior Vena Cava which give off and receive in this region the Renal Vessels; just above the gland is the origin of the Coeliac Axis the chief branches of which — Hepatic and Splenic Arteries — run along its upper border. The Gastro-duodenal Artery passes in front of the Pancreas, the Superior Mesenteric Artery runs downwards behind this viscus.

The Middle Colic Branch deserves especial attention because gangrene of the Transverse Colon has followed injury to this vessel in the course of an operation on the Pancreas. Behind the neck of the Pancreas the Mesenteric and Splenic Veins unite to form the Portal Vein. (Fig. 135 most clearly shews this complexity of vessels.)

The Pancreas is most easily accessible between the greater curvature of the Stomach and the Transverse Colon after transverse division of the Gastrocolic Fold; by dividing the Gastro-Hepatic Omentum along the lesser curvature of the Stomach a small part of the Pancreas can be exposed to view, whereas by proceeding from below after lifting up the Transverse Colon considerable danger is involved in the necessary division of the Mesocolon.

Access to the head of the Pancreas is obtained by pushing to the left the detached Duodenum; the Head and Tail can be reached retro-peritoneally from the Lumbar region. We desire to point out most clearly that the right Vagus Nerve supplies the Right Lobe of the Liver and the Spleen, although this organ lies on the left side.

Fig. 130. Position of the Viscera which lie outside the Peritoneum.

Woman aged 30. The Intestines have been removed from the Cardiac end of the Stomach down to the Rectum. Pancreas and Spleen in normal position. Parietal peritoneum has been removed in the Abdominal but left in the Pelvic Cavity.

The Peritoneal Cavity has been opened in the following way. The median incision extends from the Xiphoid to the left side of the Umbilicus below which part the incisions diverge towards the right and left Anterior Superior Iliac Spines. The two large upper flaps are further divided into two smaller ones by incisions running towards the 10th ribs.

The two Kidneys (practically at the same level, though the left is usually the higher, cf. Fig. 125) together with their large arteries from the Aorta are shewn with their veins which enter into the Inferior Vena Cava. At the hilum the Vein is situated in front of the Artery, which has divided into many branches, whereas the Ureter is situated behind.

The left Renal Vein passes in front of the Aorta to join the Inferior Vena Cava; the termination of this left renal vein and the right vessels are covered by the head of the Pancreas.

The Pancreas extends across at the level of the 1st Lumbar Vertebra from the Right Kidney to the Left, terminating in relation with the Spleen and lying in front of the Aorta and Inferior Vena Cava.

Above the Pancreas the Coeliac Axis with its three diverging branches is shewn; below the Superior Mesenteric Artery, (the origin of which lies under cover of the gland), at a lower level and to the right is the Middle Colic Artery. To the right of this Artery is the Superior Mesenteric Vein whereas further to the left is the Inferior Mesenteric Vein. Above the Pancreas the Portal Vein can be seen, cut off at the hilum of the Liver. This vein is formed by the union of the Splenic and the Superior Mesenteric Veins.

The Ureters passing downwards on the Psoas Muscles cross the Iliac Vessels — on the left $\frac{1}{2}$ inch above, on the right $\frac{1}{2}$ inch below the origin of the Internal Iliac Artery — and course along the outer wall of the true pelvis to the Trigone of the Bladder. In the Male the Ureter crosses the Vas Deferens, passing below this duct; in the Female the Ureter passes below the Uterine Artery.

To the right of the Aorta lies the Inferior Vena Cava, between these large vessels and to the left of the Aorta are large lymphatic glands.

The Aorta bifurcates into the Common Iliac Arteries at the lower border of the 4th Lumbar Vertebra.

The inlet of the true pelvis is almost completely filled up by the much distended Rectum (ligatured) and the Uterus (in this instance enlarged) which overlies the Bladder. (Cf. Figs. 146 and 147.)

Fig. 131. Gall-Bladder, Bile Ducts, and Surrounding Structures — Female.

On the body of a woman, aged 55, a large window, $5\frac{1}{2}$ inches long by 4 inches wide was made through the skin of the right hypochondriac region. The window aperture is diminished through the deeper layers. The Liver and Gall-Bladder have been drawn upwards and to the right while the Stomach and Duodenum have been drawn downwards. By removal of a part of the Anterior layer of the Hepato-duodenal fold the structures at the hilum of the Liver have been exposed.

This figure shews the window with its inner boundary situated $\frac{1}{5}$ th inch from the middle line. At the margin of the window, especially at the outer margin, the various layers of the abdominal wall are to be seen: External Oblique Muscle, Internal Oblique Muscle, Transversalis Muscle; at the upper and lower margins — the Rectus Muscle and its sheath together with the lumina of the severed vessels which run behind the muscles: Superior Epigastric Branch of the Internal Mammary Artery (cf. Fig. 119) and the Deep Epigastric from the External Iliac Artery.

In this figure the Liver and Gall-bladder have been drawn upwards and to the right in order to shew the structures in the Hepato-Duodenal Fold, but the natural position of the Gall-bladder is shewn in Fig. 124.

The fundus of this organ, which is normal, extends a little way beyond the lower border of the Liver at the point where this viscus leaves the Costal Arch (8th or 9th Costal cartilage) and runs obliquely upwards into the epigastric region. The fundus is $1\frac{1}{5}$ th to 2 inches from the middle line so that access is gained to it by a longitudinal incision from the costal arch through or along the outer border of the Rectus Muscle.

In pathological conditions, the gall-bladder may be so shrunken as to be hidden under cover of the liver, but when distended or the seat of a neoplasm, it may be easily palpated and even become of such a size as to be mistaken for an ovarian cyst.

The size of the Gall-bladder varies greatly from $1\frac{3}{5}$ th inches (as in this instance) to $5\frac{1}{2}$ inches long. It is covered by peritoneum on its free surface only (cf. Fig. 133). The Gall-bladder is directed backwards and inwards. Its duct ($1\frac{1}{5}$ th to $1\frac{3}{5}$ ths inches long) has always an acute S curve and it joins the hepatic duct at an acute angle (the length of the hepatic duct is one inch).

The Hepato-Duodenal Fold forms the Anterior boundary of the Foramen of WINSLOW: the arrangement of the structures in this fold are: —

- To the Right: Common Bile Duct.
- To the Left: Hepatic Artery.
- Behind: Portal Vein.

**Fig. 132. Gall-Bladder. Bile Ducts and Surrounding Structures
Male.**

As in Fig. 131 a large window, 6 inches long and 5 inches wide, was cut out of the right Hypo-chondriac region of the corpse of a robust male. (Other details as in Fig. 131.)

The Fundus of the Gall-Bladder lies more to the side than in Fig. 131. No difference dependent on sex could be made out in the position of the organ.

All the structures are shewn of normal size, more distinctly, and somewhat differently arranged from Fig. 131 e. g. the position of the Gall-Bladder is more transverse, the Pylorus is at a higher level, the Hepato-duodenal fold extends further on to the Duodenum (cf. Fig. 131 where it does not go beyond the Cystic Duct), consequently the Foramen of WINSLOW is in a somewhat different position.

The two lymphatic glands seen, e. g. a smaller Cystic at the neck of the Gall-Bladder, and a larger Gland of the Portal Vein on the anterior aspect of the Portal Vein near the Hepatic Duct, are constant. Another gland may be found lower down near the Common Bile Duct at the upper border of the Duodenum. It is right to know of these glands, because they become enlarged in chronic inflammation of the Biliary passages and may become so hard as to be mistaken for gall-stones.

The Gall-Bladder is supplied by the Cystic Artery (a branch of the Hepatic) which divides into two branches, one running along the free surface of, the other running between, the Gall-bladder and the Liver. (Both branches need a ligature in Cholecystectomy.) Considerable importance is attached to a small but constant artery (cf. Figs. 131 and 132) which, derived from the Hepatic or Gastro-duodenal, runs across the anterior aspect of the Common Bile-Duct and ramifies on it, on the Duodenum and on the Pancreas. It sends a branch upwards to the Gall-Bladder which we call the Accessory Cystic Artery. It reasonably follows that in performing Choledochotomy the operator should look out for this artery.

Both figures shew that, when the Liver is pushed upwards, the Duodenum and Pylorus drawn downwards, the Bile passages are easily accessible; thus removal of the Gall-Bladder, opening of the Cystic Duct, and other operations are rendered possible.

The Common Bile-Duct lies for a short part of its course in the Supra-duodenal portion and favourable for surgical measures. Its further course behind the Duodenum is covered by the Pancreas. (Cf. Fig. 133.)

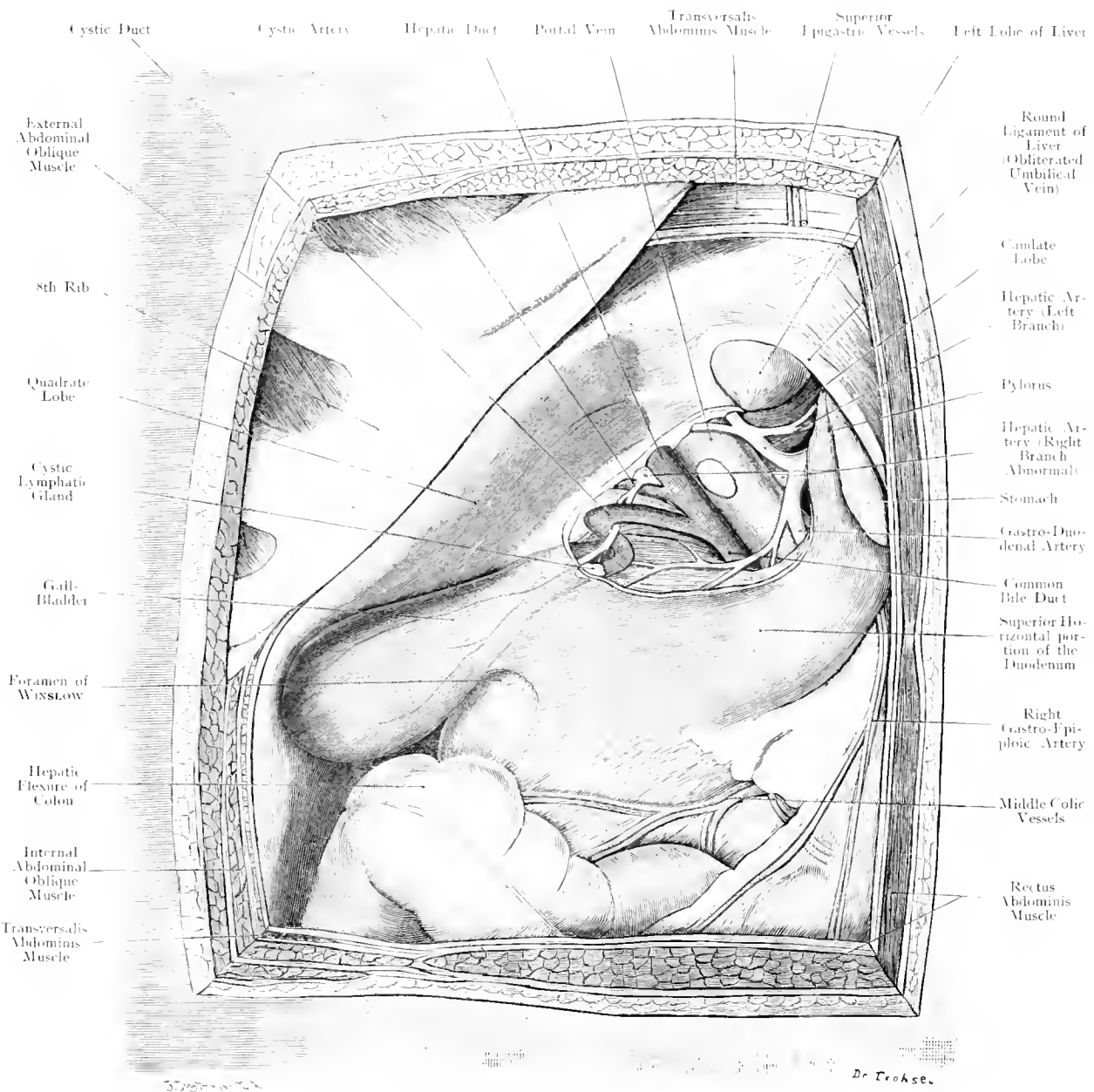


Fig. 132. Gall-Bladder, Bile-Ducts and Surrounding Structures - Male.

Seen from in front. — Nat. Size.

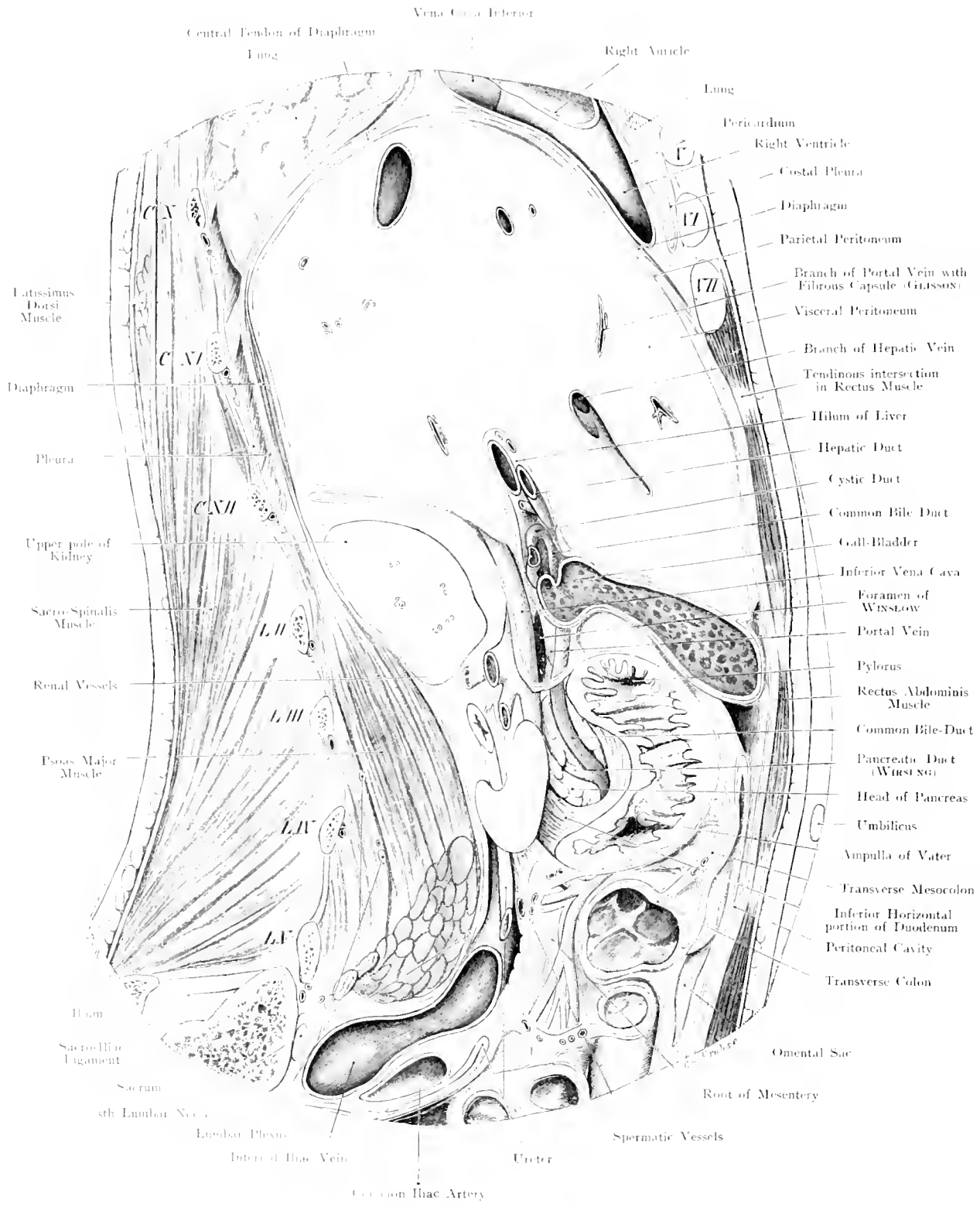


Fig. 133. Subphrenic Space; Pelvis of Ureter, Hilum of Liver, Bile-Ducts. Sagittal Section, seen from the right. — 2/3 Nat. Size.

**Fig. 133. Sub-Phrenic Space: Pelvis of Ureter, Hilum of Liver;
Bile Ducts.**

Sagittal Section passing $1\frac{3}{5}$ th inches to the right of the middle line of a frozen female body. The Common Bile Duct was exposed in its course behind the Duodenum and Pancreas. The Peritoneum is in red.

This figure shews with great accuracy the course of the Common Bile Duct which is usually 3 to 4 inches long. Its upper portion — Supra-Duodenal Portion — lies within the Peritoneum of the Hepato-Duodenal fold, and is $1\frac{1}{5}$ th inch long.

The Duct next passes behind the upper part of the Duodenum and crosses it — Retro-Duodenal Portion 1 inch long.

The last portion — Pancreatic Portion — $1\frac{1}{5}$ th inch in length, runs either through the substance of the Pancreas or in a groove on this gland to the left side of the descending portion of the Duodenum where it opens into the Ampulla of VATER close to the Pancreatic Duct, or together with it in some cases. The Retro-Duodenal and Pancreatic portions are both retro-peritoneal. (Cf. Fig. 130.)

This is of importance in operations on the Bile Duct (gall-stones); the most easily accessible part is the Supra Duodenal portion. (Cf. Fig. 132, text.)

To expose the Retro-Duodenal portion the Gastro-Hepatic Omentum must be divided at the upper portion of the Duodenum, and this structure drawn downwards. When the upper and descending parts of the Duodenum have been freed and drawn to the left, the Pancreatic portion of the Duct is accessible (Trans-duodenal Choledochotomy). Cf. Fig. 129. Exposure of the Retro-peritoneal portion of the Duct from the back, as practised by TUFFIER, is less commendable. Rupture of this portion of the Duct leads to extensive retro-peritoneal exudation of Bile.

The organs below the Diaphragm, viz. Liver, Spleen, Stomach, are separated by a narrow space from the Diaphragm, which is lined by Peritoneum, and communicates with the Abdominal Cavity: this does not apply to those parts of the Liver (cf. Fig. 131) which are not covered by Peritoneum but connected with the Diaphragm by loose connective tissue. When pus spreads into this space from neighbouring organs; Stomach, Gall-Bladder, Appendix, Kidney, or in general Peritonitis, a Subphrenic abscess is formed.

Accordingly, a Subphrenic abscess may be either Intra- or Extra-peritoneal; the latter variety is very likely to occur if suppuration extends along the perinephric connective-tissue. (Cf. Figs. 133 and 130.)

Fig. 134. Right Kidney, exposed from behind.

On the right side of a male corpse a window-section has been made by removing skin, part of the Latissimus Dorsi, two digitations of the Serratus Posticus Inferior, the tendinous origin of the Transversalis Muscle and the fatty tissue behind the Kidney.

The Kidney is tilted forward to exhibit the hilum.

The Left Kidney extends from the upper border of the 12th Dorsal Vertebra to the lower border of the 2nd or to the middle of the 3rd Lumbar Vertebra. The Right Kidney is usually about the space of $\frac{1}{2}$ a vertebra lower. The upper half of the Kidneys lie very near the pleural cavities from which they are only separated by the Diaphragm.

The distance from the lower end of the Kidney to the crest of the Ilium varies considerably ($1\frac{1}{5}$ th inch in the male, 1 inch in the female, on the right side; $1\frac{3}{5}$ ths inch in the male and $1\frac{1}{5}$ th inch in the female on the left side).

Access to the kidney is obtained by two routes, either from in front (transperitoneally — cf. Fig. 135, text) or from behind (from the Lumbar region). By the latter route the surgeon has the advantage that in operations upon the kidney the peritoneum is not opened. The route followed is at the border of the Sacro-Spinalis Muscle after division of the lower border of the Latissimus Dorsi, the deep layer of the lumbar fascia is then divided. After division of the Fascia Transversalis and the Renal Fat the lower end of the Viscus is exposed. In extending the incision upwards as far as the 12th rib the Pleura may be slightly injured, as its line of reflection runs from the lower border of the 12th Dorsal Vertebra in a horizontal direction outwards across the 12th rib if this bone be of some length; in this case the anterior part of the rib lies below the pleura. If the bone is very short the 11th rib may easily be mistaken and thus an incision carried forward may open into the pleura.

For operations near the Pelvis of the Kidney the situation of the Artery and Vein anteriorly affords a great advantage in rendering the Pelvis easily accessible from behind: the same advantage applies to the upper part of the Ureter.

The lower part of the Ureter is reached by "an Oblique lateral incision" as for ligature of the Common Iliac Artery. This incision is carried from the upper border of the 12th rib obliquely downwards and forwards to the junction of the outer and middle third of POUPART'S ligament. The peritoneum is pushed aside without opening. The lowest part of the Ureter below where it crosses the Common Iliac Artery can also be reached extra-peritoneally by an incision made parallel with and directly above POUPART'S ligament.

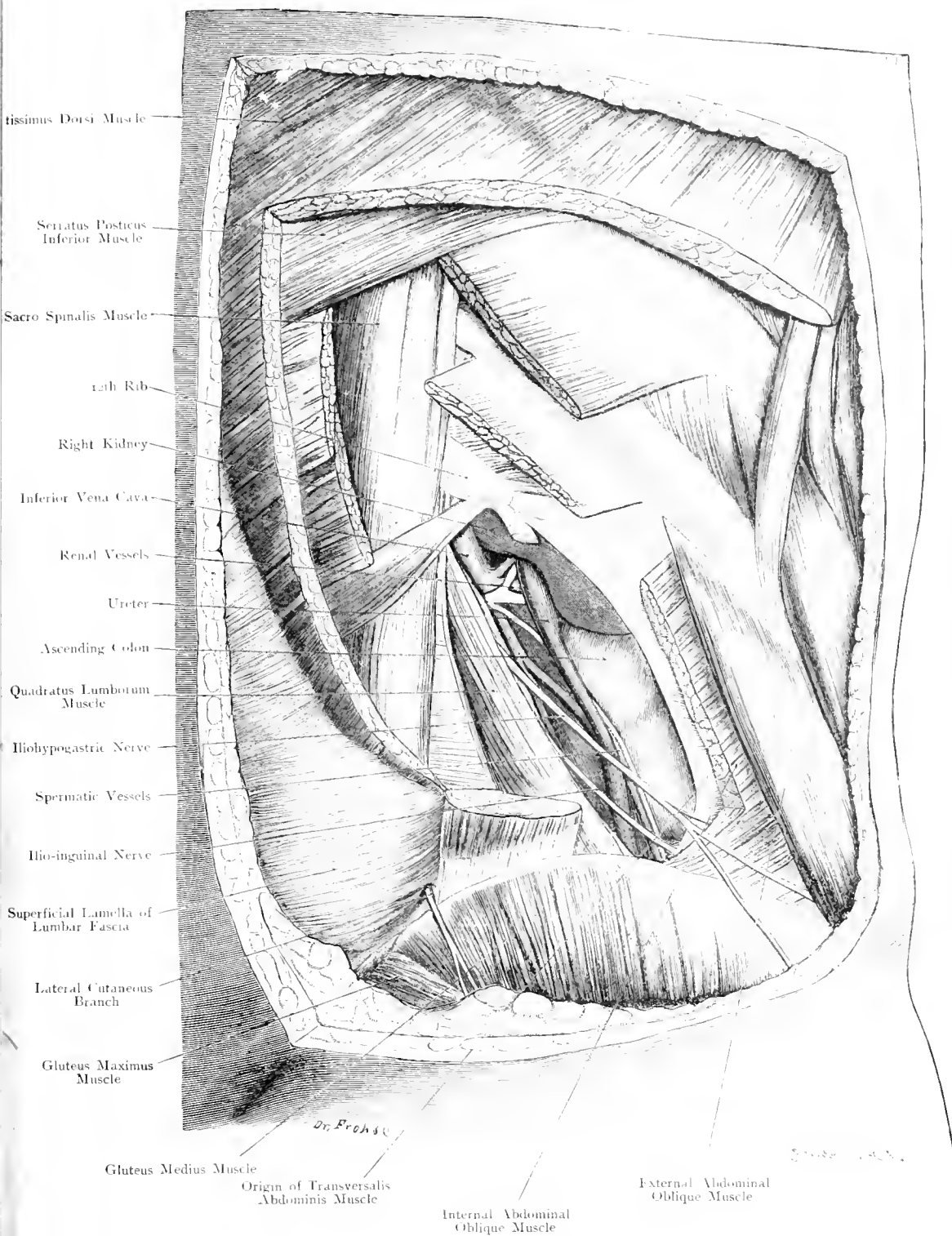
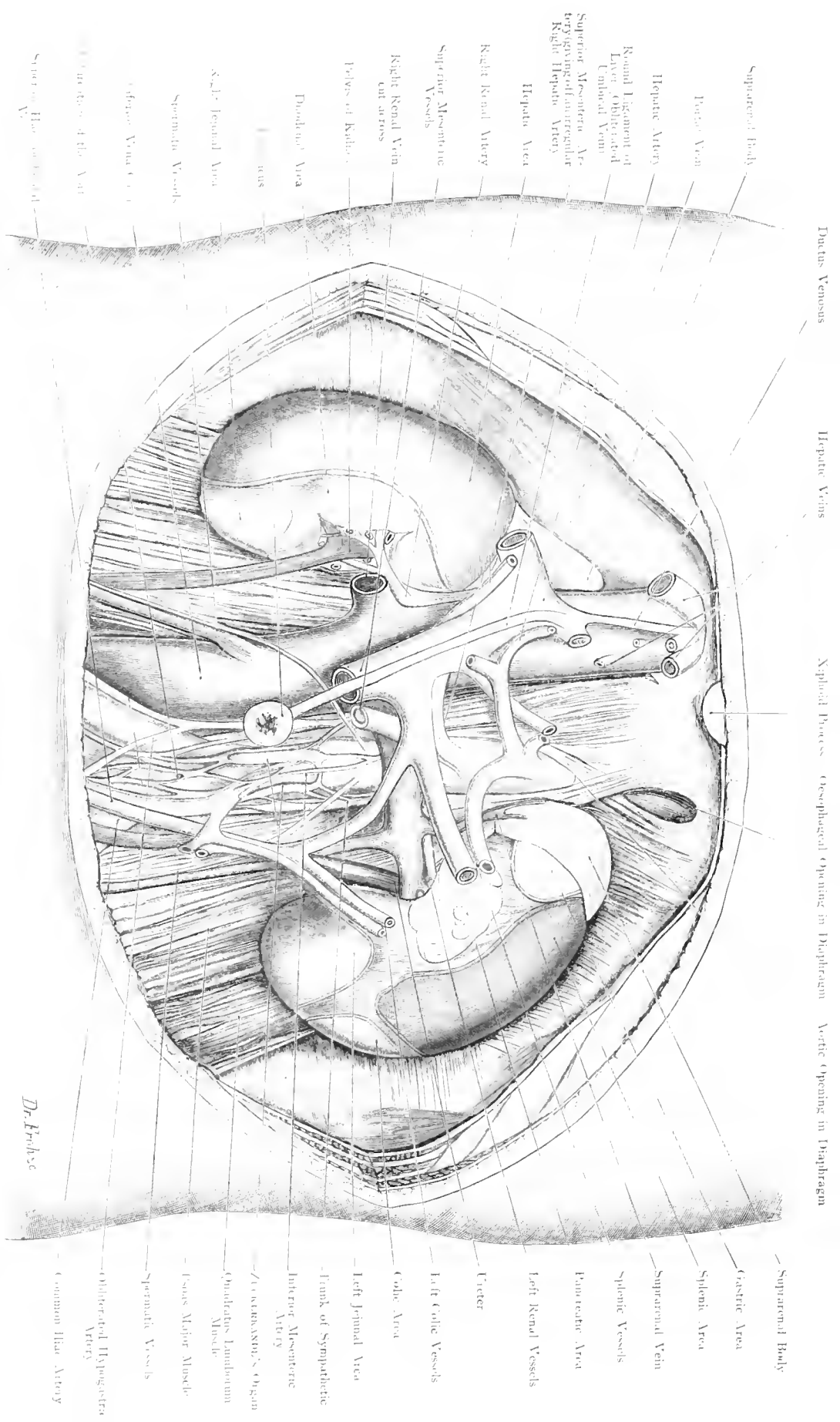


Fig. 134. Right Kidney, Exposed from behind.

$\frac{1}{5}$ Nat. Size.



Ductus Venosus Hepatic Veins Esophageal Opening in Diaphragm Aortic Opening in Diaphragm

Suprarenal Body
 Portal Vein
 Hepatic Artery
 Round Ligament of Liver, Obliterated Umbilical Vein
 Superior Mesenteric Artery giving off an irregular Right Hepatic Artery
 Hepatic Vein
 Right Renal Artery
 Superior Mesenteric Vessels
 Right Renal Vein cut across
 Pelvis of Kidney
 Duodenal Area
 Uterus
 Left Jeminal Area
 Spermatic Vessels
 Inferior Vena Cava
 Esophageal Opening of the Vein
 Superior Mesenteric Vein

—Suprarenal Body
 Gastric Area
 Splenic Area
 Suprarenal Vein
 Splenic Vessels
 Pancreatic Area
 Left Renal Vessels
 Uterus
 Left Colic Vessels
 Colic Area
 Left Jeminal Area
 Trunk of Sympathetic
 Inferior Mesenteric Artery
 —Zosteriform Organ
 Ovarian Ligamentum Muscular
 —Fascia Major Muscle
 Spermatic Vessels
 Oblique Lateral Hypogastric Artery
 —Common Iliac Artery

Dr. Phelps

Fig. 135. Portal Vein, Umbilical and Renal Vessels. "Renal Area".

Seen from in front - 1/2 Nat. Size.

Fig. 135. Portal Vein. Umbilical and Renal Vessels. "Renal Areae".

Out of the Anterior Wall of a recent male corpse an oval window extending from the Xiphoid Process to $1\frac{3}{4}$ ths inch below the Umbilicus, has been cut. — The Umbilicus and the Round Ligament have been preserved and replaced in their normal position. The Viscera, with the exception of the kidneys and suprarenal bodies, have been removed. The radicles of the Portal Vein, excepting the Superior Haemorrhoidal Vein and its branches to the Liver, have been cut away. Of the branches of the Vena Cava Inferior only the Right Renal Vein has been preserved. — Portal System in light blue; Umbilical Veins white; Arteries red.

Whereas the posterior surfaces of the Kidneys are extra-peritoneal as they rest upon the muscles of the posterior abdominal wall, their anterior surfaces are partially covered by Peritoneum, and are in relation with other Viscera. These various surfaces of contact "renal areae" are shewn in the figure, those covered by peritoneum are in different colours. The double line at the margins of the areae indicates the cross-section of the peritoneal reflections from the kidney; the areae uncovered by peritoneum are white.

The Right Kidney, to a large extent, upper $\frac{2}{3}$ rds or even more, is in contact with the Liver, the peritoneal covering of which passes on to the kidney. The Colon either passes around the lower end of the Kidney when its area is usurped by the Jejunum or, as is more frequently the case, passes over it.

Between the jejunal and the hepatic areae two folds of Peritoneum, forming the Ascending Meso-colon, are found. A distended colon may push aside the jejunum and occupy the "Jejunal Area"; again in turn a distended jejunum may push the colon away from the kidney. Many variations are encountered.

The inner border of the Kidney is covered by the vertical portion of the Duodenum. The relations of the Left Kidney are

quite different, its upper end is, to a small extent, in contact with the Fundus of the Stomach and is covered by Peritoneum (Omental Sac); the convex border and a considerable part of the anterior surface are in relation with the Spleen; the hilum is in contact with the tail of the Pancreas; the lower end is partly covered by Jejunum partly by Descending Colon. Large Renal Tumours are frequently removed; by the Anterior or Transperitoneal route, when an incision is made vertically in the middle line or along the outer border of the Rectus Muscle, or obliquely from the Anterior Axillary Line, directly below the costal arch to the Spine of the Pubis. The outer layer of the Meso-colon over the kidney is divided and the intestine pushed inwards so as to expose the kidney.

In front of the Aorta are the "Organs of ZUCKERKANDL" (yellowish-brown); these are connected with the Sympathetic (yellow with pink ganglia) and are here depicted in order to give an idea of their position, size and shape as met with in the Foetus and Child. In the adult they are rudimentary. In the new-born they are $\frac{2}{5}$ th to $\frac{4}{5}$ ths inch long on the right, $\frac{1}{5}$ th to $\frac{3}{5}$ ths on the left, while their upper extremities are oftentimes joined together in the shape of a horse-shoe.

Fig. 136. Position of the Abdominal Viscera seen from behind: lines of Peritoneal Reflection.

The plaster model by Hts which has been made from nature (cf. *Archiv. f. Anat. u. Phys., Anat. Abt.*, 1878) shews when taken to pieces and put together again the form and position of the Abdominal Organs in a beautiful manner; further this model shews the individual relations of the various organs, the lines of reflection of the Peritoneum, and the relations of intra- and extra-peritoneal areas.

Our figure varies slightly from the model by Hts (cf. Fig. 130).

Uncovered by Peritoneum: A considerable area of the posterior surface of the Liver, posterior surface of the Pancreas, of the Duodenum and of both kidneys, the anterior surface of the Kidneys in contact with the Pancreas (cf. Fig. 135 and 139). The large vessels are also extra-peritoneal: — Aorta and Inferior Vena Cava, the posterior wall of the greater part of the Ascending Colon and Descending Colon. The posterior aspect of the middle portion and the whole of the lower portion of the Rectum. The Caecum is also uncovered by the peritoneum except where the Ileum opens into its posterior aspect as it becomes closely applied to the wall of the False Pelvis.

On rare occasions only does the Caecum possess a Mesentery whereas the Vermiform Appendix is enveloped in Peritoneum and has its own Mesentery — Mesenteriolum —.

The extra-peritoneal position of the Kidneys, Ascending and Descending Colon afford an important means of operating upon these Viscera without opening the peritoneal cavity (cf. Fig. 134). Moreover, as the peritoneum is only loosely attached to the anterior surface of the kidney, it can be easily detached, and thus the kidney removed without opening the peritoneal cavity.

Formerly, Lumbar Colostomy was frequently performed for disease of the Sigmoid and Rectum.

The absence of Peritoneum on the posterior surface of the Rectum bears an important relation to the spread of inflammation. This absence of peritoneum is unfavourable for circular enterorrhaphy after removal of Rectal Carcinoma because gut surrounded by Peritoneum heals more readily.

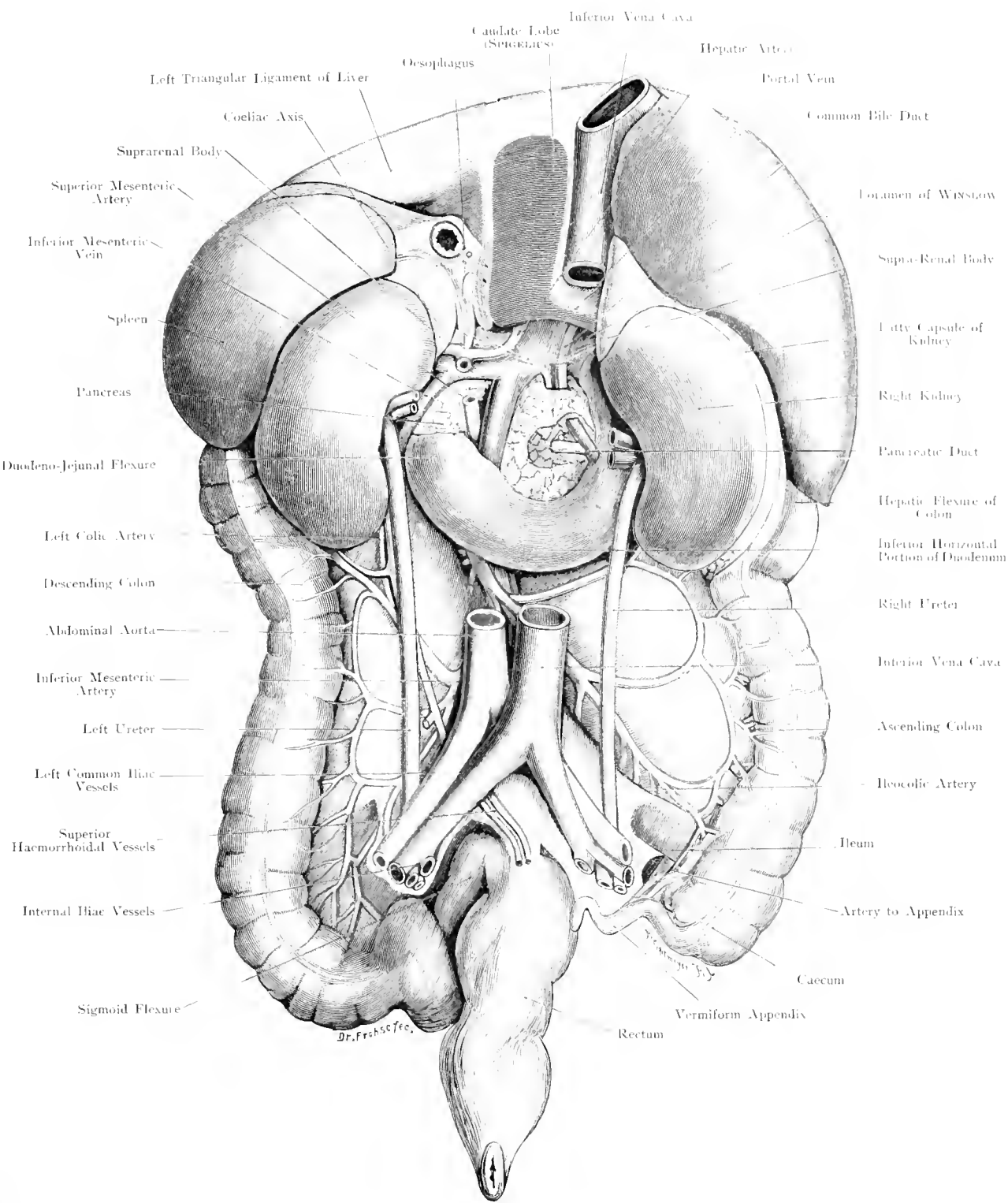
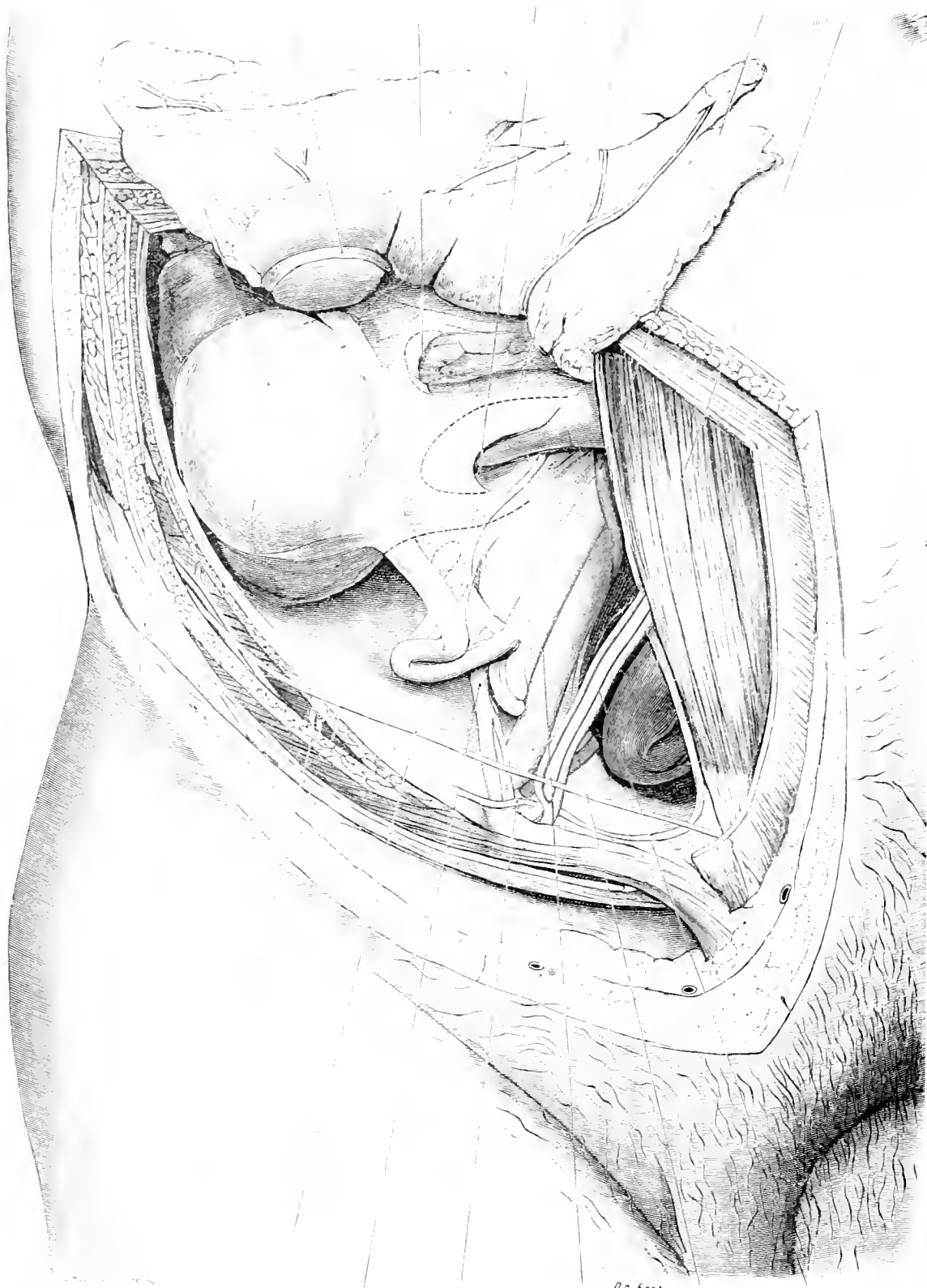


Fig. 136. Position of Abdominal Viscera, seen from behind; Lines of Peritoneal Reflections.

Model made in Plaster of Paris by STAGER, Leipzig. According to W. HIS. — $\frac{2}{5}$ Nat. Size.



Dr. Froese

Anterior Superior Iliac Spine Superficial Epigastric Vessels Deep Epigastric Artery
 Ilio-hypogastric Nerve Vas Deferens External Iliac Vessels
 Spermatic Vessels Plica Epigastrica

Fig. 137. Vermiform Appendix and Caecum.
 Nat. Size.

Fig. 137. Vermiform Appendix and Caecum.

In a robust male corpse, a lozenge-shaped window has been made 5 inches by 4 inches through the skin but of a smaller area through the deeper layers of the right Hypogastric and Iliac Regions; Omentum and Transverse Colon are thrown upwards.

The Appendix is at a higher level, and more laterally situated than usual; its position varies with the degree of distension of the neighbouring intestines. As the Appendix is completely enveloped in Peritoneum, its mobility is very marked in contrast to the commencement of the Ascending Colon which is only covered anteriorly whereas posteriorly it remains fixed to the posterior abdominal wall (cf. Fig. 136).

The Caecum, usually $2\frac{1}{5}$ ths inch long, is situated in the Right Iliac Fossa on the Fascia Iliaca above the outer $\frac{1}{2}$ of POUPART'S Ligament; when moderately distended and the neighbouring coils of intestine empty or only slightly distended it lies against the Anterior Abdominal Wall, but if more movable it may lie bent upwards upon the Ascending Colon.

Coming off the lower end of the Caecum near the Ileo-Caecal Junction and in possession of its own mesentery the position of the Vermiform Appendix is very variable; in length it varies from 1 to 10 inches (usual length 3 to 4 inches); in shape it may be straight, serpiginous, spiral or bent upon itself; in position it may come in contact with the Bladder or Ovary in the true Pelvis, it may lie behind the Ileum or extend up behind the Caecum, Kidney or even the Liver, or Stomach, and extending beyond the middle line.

Its base corresponds to Mc BURNEY'S point — midway between the right Anterior Superior Iliac Spine and the Umbilicus.

The Arteries to the Ileum, Caecum and Appendix produce folds of Peritoneum in relation with which small recesses are formed, e. g. Superior and Inferior Ileo-Caecal Fossae.

As Appendicitis is of frequent occurrence, operations upon the Vermiform Appendix are often necessary. The usual incision is made directly above and parallel to the outer $\frac{1}{2}$ of POUPART'S Ligament; — though the viscus can be reached by an incision along the outer border of the Rectus Abdominis Muscle at the level of the Anterior Superior Iliac Spine.

Fig. 138. Sigmoid Flexure and Inguinal Canal.

The Hypogastric and Iliac Regions are exposed on the left side of a normal male cadaver — (act. 38). The upper portion of the Abdominal Wall in this region has been removed, and the Inguinal Canal dissected out, the Sigmoid thrown upwards and inwards, after accurately determining its position (dotted lines).

The Sigmoid Flexure which, variable in length, extends between the Descending Colon — attached to the posterior Abdominal Wall — and the Rectum — attached to the posterior Pelvic Wall — is the most movable portion of the large intestine.

The Sigmoid Flexure usually possesses a lower (left) curve with its convexity downwards, and an upper (right) curve with its convexity upwards. Such are indicated by the dotted lines. When the Sigmoid is turned upwards, as in the figure, a small peritoneal pouch over the left psoas becomes evident — the Fossa Sigmoidea.

Lying internal to the Psoas Muscle are seen (cf. Fig. 137) the Iliac Vessels; above the divided Rectus Muscle is seen the Obliterated Hypogastric Artery passing upwards towards the Umbilicus as the lateral vesico-umbilical ligament in the Plica Umbilicalis.

The fibres of the External Oblique Muscle of the Abdomen diverge in the Inguinal Region forming the two pillars of the External Inguinal Ring, so that the upper or inner pillar ends in the middle line at the Symphysis and the Suspensory Ligament of the Penis or even extends beyond the middle line to the opposite side, whereas the inferior or outer pillar terminates at the Spine of the Pubis. The upper sharp angle of the External Abdominal Ring, and the anterior surface of the cord are covered by the Intercolumnar Fibres (removed in the figure), the function of which is to prevent a wide divergence of the pillars.

These intercolumnar fibres are derived from the External Oblique Muscle of the opposite side and terminate by blending with POUPART'S Ligament.

Accordingly this ligament is formed by the External Oblique Muscles of both sides and represents a tendon which most authors view as a band of connection between two bony points or as the lower border of the External Oblique Muscle. This latter view is probably the more correct but it fails to take into consideration the connection of this ligament with the Fascia Lata of the Thigh.

Several small ligaments, of which some have been named are connected with POUPART'S Ligament.

There exists, occupying a horizontal position between the Pubis and POUPART'S Ligament, a triangular-shaped ligament, with its base directed outwards, which is named GIMBERNAT'S Ligament. When this structure is looked at from above and behind it receives the name of COLLES' Ligament.

Its sharp outer edge is sometimes called the Falx Inguinalis (Ligament of HENLE).

Internal and external to the Deep Epigastric Vessels lie respectively the Internal and External Abdominal Rings; between these is HESSELBACH'S Ligament.

Obturator
Hypogastric Artery

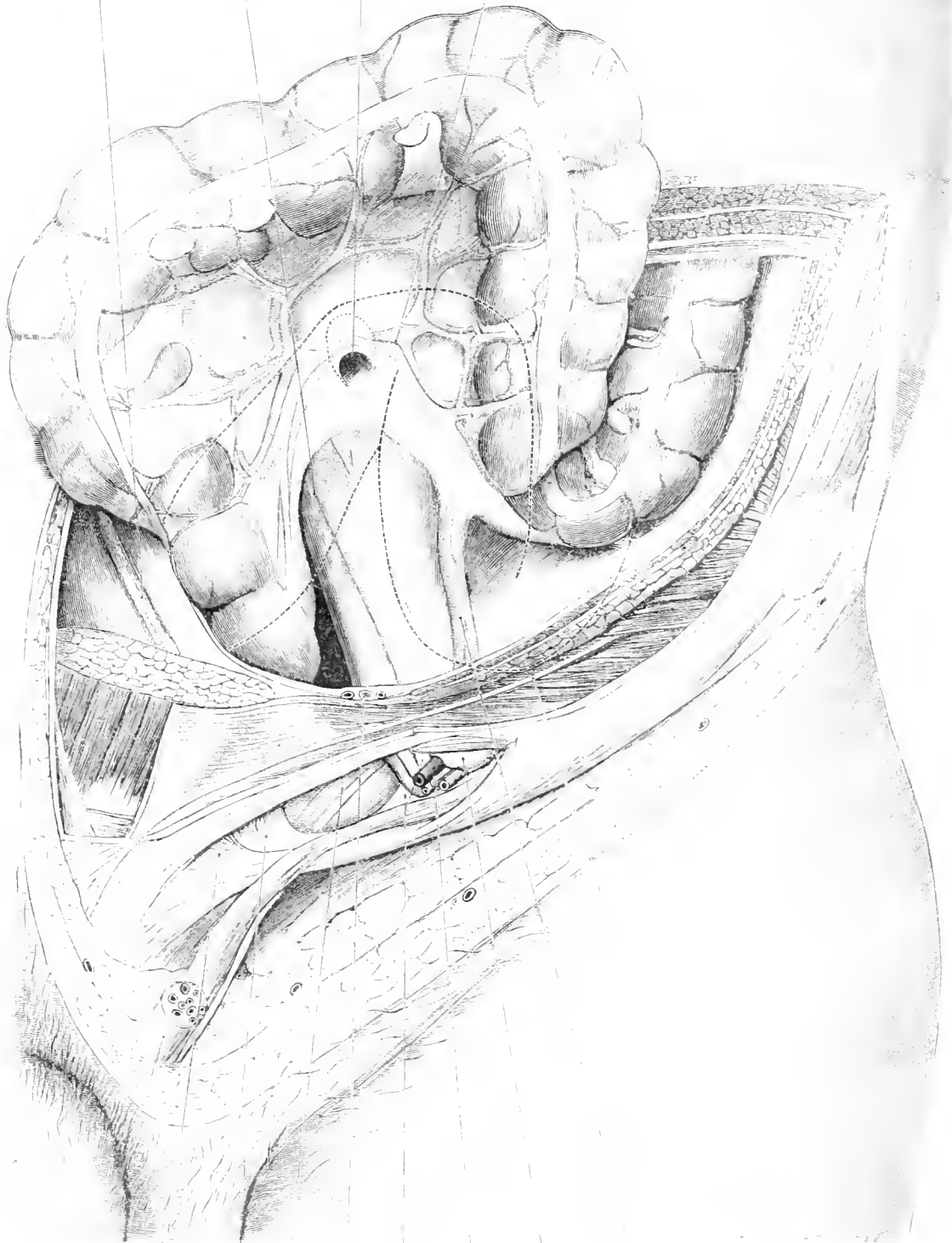
External
Iliac Vessels

Fossa
Intersigmoidea

Left Ovarian Artery

Sigmoid Flexure

Ascending Colon



Spermatic Cord
Ilio-pubic Band (COLLES)

Free Edge of GIMBERNAT'S Ligament

External Abdominal Ring

Deep Epigastric Artery

HESSELBACH'S Ligament

Vas Deferens

Internal Abdominal Ring

Spermatic Vessels

POU PART'S Ligament

PH. L. COLLES'S Nerve

Fig. 138. Sigmoid Flexure and Inguinal Canal.

Nat. Size.

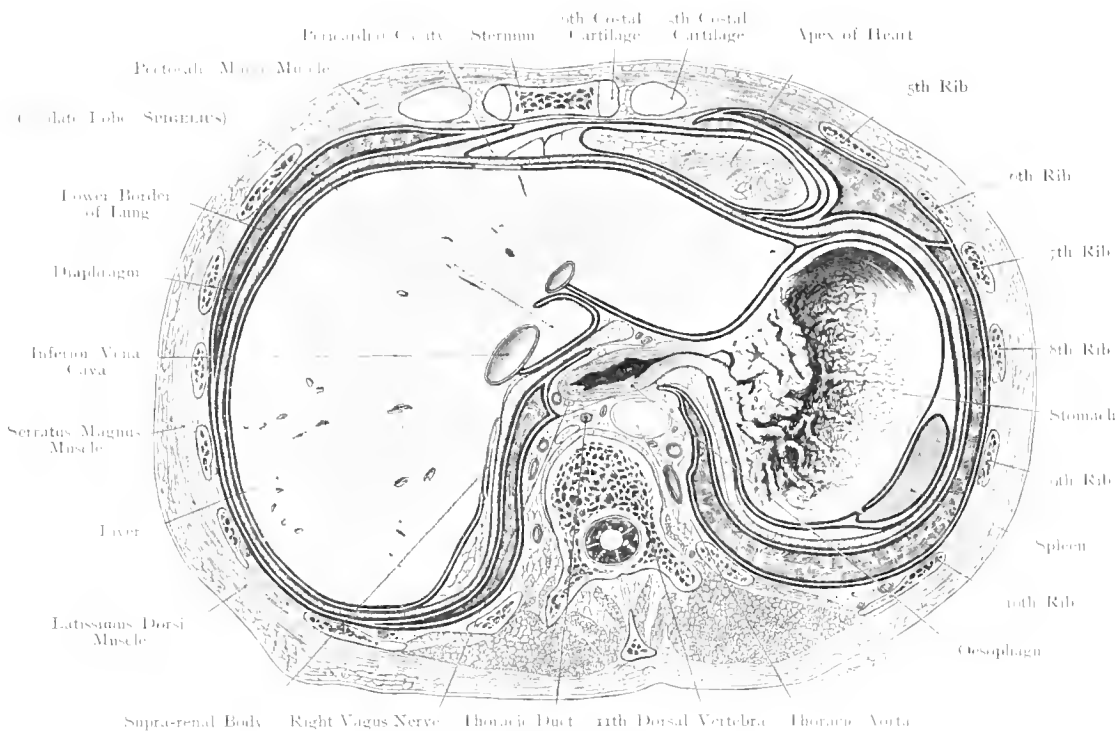


Fig. 139. Transverse Section through the Trunk at the level of the 11th Dorsal Vertebra. Seen from below. $\frac{2}{3}$ Nat. Size.

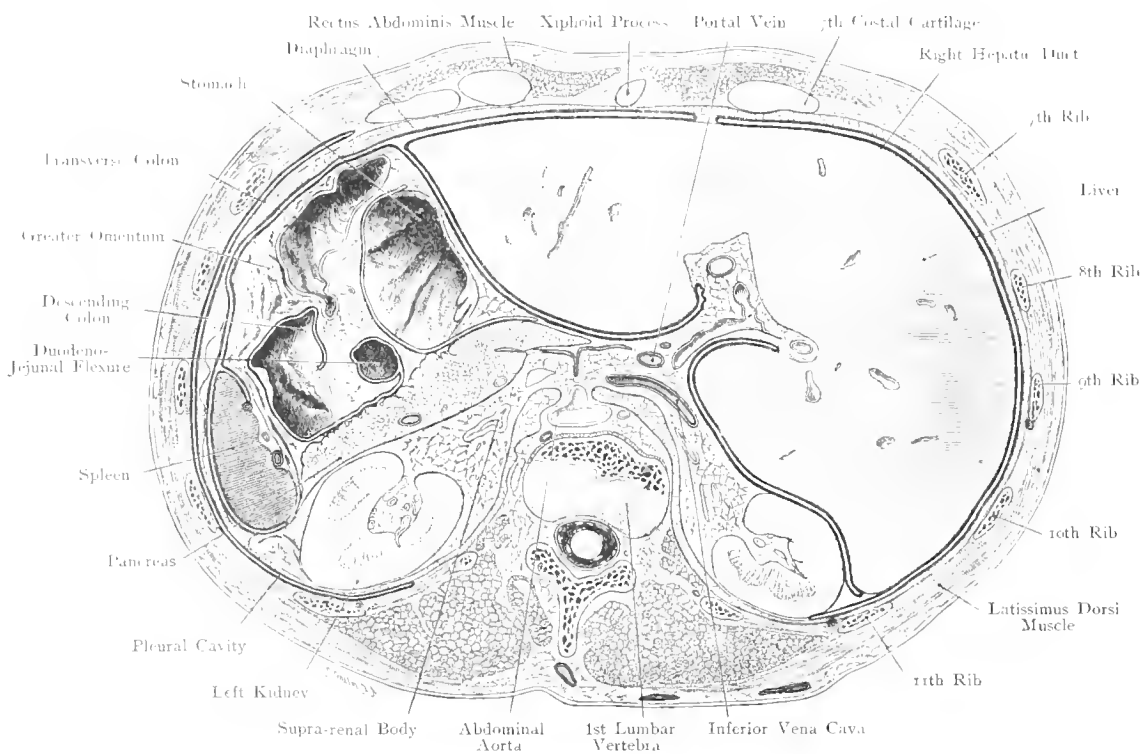


Fig. 140. Transverse Section through the Trunk at the level of the 1st Lumbar Vertebra. Seen from above. $\frac{2}{3}$ Nat. Size.

Fig. 139. Transverse Section through the Trunk at the level of the 11th Dorsal Vertebra, from below.

Frozen section of the same body as in Figs. 121 and 122. In front the 6th Chondro-Sternal Articulation is cut through, also the 5th, 6th, 7th, 8th, 9th, 10th and 11th ribs; the vertebral column is slightly deviated to the right.

In this section the lowest portions of the Thoracic Viscera, Heart and Lungs (in the condition of inspiration as in Fig. 122) and the Abdominal Viscera, Liver, Stomach and Spleen are shewn in transverse section; between these two groups of viscera lies the diaphragm. The Liver occupies the greatest space, the remaining space is chiefly occupied by the Stomach, a small area is left by the Liver for the Apex of the Heart, and by the Stomach for the Spleen.

The Lungs in their position during inspiration are seen at the periphery.

The entrance of the Oesophagus into the Stomach and the numerous broad plications of the Gastric Mucous Membrane are well shewn.

Behind the Oesophagus lies the Aorta; at a higher level the Oesophagus occupies the more posterior position while in close relation behind it and in contact with the Vertebral Column are found the large and small Azygos Veins, the Thoracic Duct and the Sympathetic System.

Fig. 140. Transverse Section through the Trunk at the level of the 1st Lumbar Vertebra. Seen from above.

Frozen section as in Fig. 139 passing through the disc between the 12th Dorsal and 1st Lumbar Vertebra.

The Liver occupies almost as much space as in Fig. 139, now taking up the space previously occupied by the heart whereas, behind, room is made for the right kidney. To the left is the Stomach. Between this Viscus and the Spleen, the Splenic Flexure has introduced itself extending upwards beyond the plane of the section so that only sections of the Transverse and Descending Colon are seen.

Between the Colon and Stomach a lumen of small intestine is visible and between the Colon and Abdominal Wall the Great Omentum.

The Pancreas has been cut almost throughout its whole length as it extends horizontally across from Liver to Spleen. The Oblique position of the kidneys is also seen; on either side a "Pleural Space" is found between their upper half and the posterior abdominal wall.

The space between the Pancreas and the posterior abdominal wall is occupied by the Left Kidney which has been cut through at its greatest diameter whereas the Right, situated at a lower level, was divided nearer its upper pole.

The peculiar shape of the transverse section of the Aorta is due to the origin of the Superior Mesenteric Artery.

Fig. 141. Retroperitoneal Lymphatic Glands and Vessels.

The whole of the Anterior Abdominal Wall and the lower part of the Anterior Thoracic Wall have been removed in a male infant, 4 weeks old. A small area of peritoneum has been left over the right kidney; the Receptaculum Chyli has been exposed to view by cutting away a short piece of the Aorta. The renal lymphatics are described after Stahr; the lymphatics of the testicle partly after Most and partly after Bruhns whose description has been adopted for the deep inguinal glands.

Apart from the glands above the fascia lata of the thigh described in Fig. 166, deep glands demand consideration both as regional and as intermediate to the deep lymphatic vessels of the lower limb. As a rule, they are small and only 1-4 in number; their efferent vessels run, as shewn in the figure, along the inner border of the Femoral Vein and along the outer and anterior surfaces of the vessels of the thigh into the Pelvis. The former path leads to CLOQUET'S Gland, the outer tract to a (usually) very large gland just above POUPART'S Ligament.

The large lymphatic vessels (4 to 6) of the testicle have a very long course before they arrive at their regional glands (the lumbar glands; occasionally, there is an intermediate gland on the course of the Spermatic Vessels (black spot on the right side at the level of the Rectum). The regional glands on the right side are usually at a lower level than on the left side; with the Vas Deferens lymphatic vessels run to the base of the bladder. The lymphatics of the inferior half of the Ureter pass to a Pelvic Gland, those of the superior half to a Lumbar Gland.

The Lymphatics of the Kidney form on its surface a network quite distinct from the Stellate Veins of VERHEYEN.

The efferent vessels (2-4) pass with the renal blood-vessels either directly or through an intermediate gland to the group of lymphatic glands situated at the angle formed by the Renal Veins and the Inferior Vena Cava. When accessory renal vessels are present (cf. Fig. 164) lymphatic vessels with a special regional gland usually accompany them (FROHSE).

As the Peritoneum gives a covering to all the abdominal viscera its lymphatics do not correspond to the limitations of each viscus (cf. peritoneum over right kidney after STAHR who has kindly allowed us to make use of his hitherto unpublished figures).

All the lymphatics referred to, as well as those from the Intestine which convey the Chyle, directly or indirectly pass into the Receptaculum which lies behind the Abdominal Aorta and from which the Thoracic Duct leads. The Aorta and Inferior Vena Cava are surrounded by a network of lymphatics and glands.

General Remarks on Lymphatic Glands.

As many regional glands are secondary to other organs it remains that only a few intermediate glands (a collection of lymphoid tissue on the course of a lymphatic vessel) are purely regional.

From pathological observations, lymph nodes or small collections of lymphoid tissue are frequently found on the course of lymphatic vessels; FROHSE and HEIN have seen in a case of Arterio-Venous Aneurysm (the injected specimen of an amputated arm) 6 large glands situated along the radial and ulnar arteries.

HEIN has further observed in an apparently healthy arm a small gland near the ulnar nerve, just below the Elbow-Joint. FROHSE found in a case of Carcinoma Mammae with obstructed axillary lymphatics 4 newly formed glands on the clavicle and in yet another pathological case 14 axillary glands on the healthy side and 31 on the diseased side; — to sum up: pathological conditions favour the new-formation and development of lymphatic glands. In some cases the lymphatic glands are not visible to the naked eye but when injected with mercury even a gland of the size of a pin's head can be recognized because it becomes distended by preventing the passage of mercury.

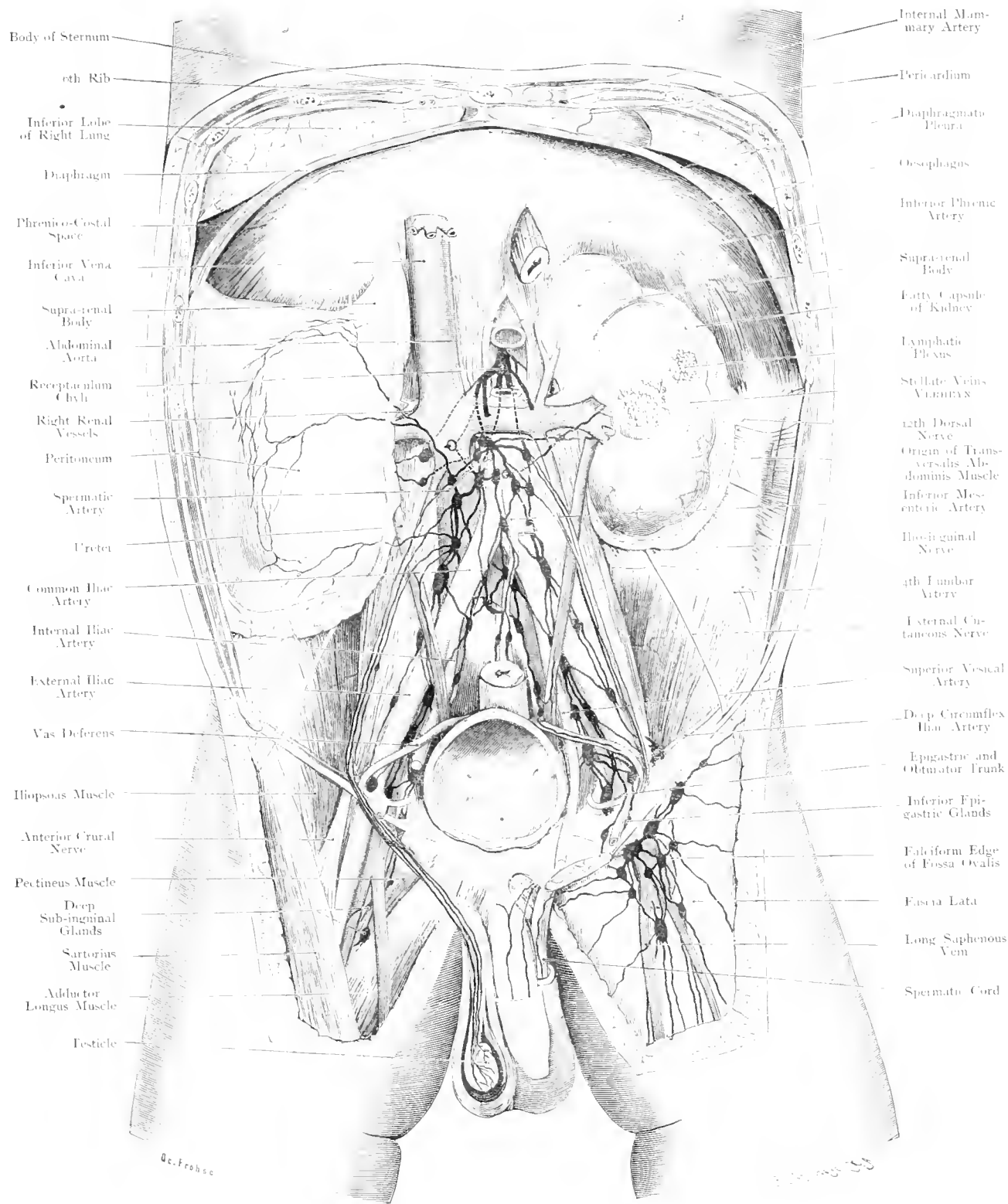


Fig. 141. Retroperitoneal Lymphatic Glands and Vessels.
Newborn male Child. — Nat. Size.

Oblique External Hypogastric Artery
Plica Embryonalis Lateralis

A. F. B. D. S.

Transversalis Fascia

Semilunar Fold of Ductus

Deep Epigastric Artery

Rectus Abdominis Muscle

Oblique External Hypogastric Artery

Trace of White Line

Transversalis Abdominis Muscle

Superfornal Lymphatic Gland

Trochanteral Nerve

Fascia Iliaca Covering Iliacus Muscle

Iliacus Muscle

Obturator Vessels and Nerve

Ilium

Gluteus Minimus Muscle

Gluteus Medius Muscle

Gluteus Maximus Muscle

White Line (Origin of Levator Ani Muscle)

Seminal Vesicle

Peritoneal Muscle

Small Sarcosstatic Ligament

Levator Ani

Great Sarcosstatic Ligament

Ischio-Rectal Fossa

Vas Deferens Ampulla

Middle Sacral Artery

Prostate

17th Piece of Coccyx

Posterior

Deep Epigastric Artery

Forca Supracostalis

Lower Iliacal Ligament

Upper Iliacal Ligament

Potter's Ligament

Forca Embryonalis Cervical Ring

Vas Deferens

Spermatic Vessels

External Iliac Vessels

Anterior Crural Nerve

Finger

Internal Iliac Artery

Ureteric Artery

Inferior Vesical Artery

Gluteal Artery

Great Sciatic Nerve

Middle Haemorrhoidal Artery

Recto-Vesical Fascia

Small Artery

Internal Pubic Artery

Ischio-Pubic Artery

Ischio-Pubic Artery

Superior Haemorrhoidal Artery

Prostate

17th Piece of Coccyx

Posterior

Rehman Limited, London.

Rehman Company, New York.

Fig. 142. Anterior Abdominal Wall seen from behind. 2/3 Nat. Size.

Fig. 142. Anterior Abdominal Wall, from behind.

The Fossae of the Iliac Bones have been seen through obliquely in a plane slightly posterior to the Anterior Superior Iliac Spines and inclined towards the Spines of the Ischia. The Sacrum and Coccyx, with the exception of the last piece of the Coccyx, have been removed. The Peritoneum has been taken away and the Hernial Orifices exposed on the right side, a piece of the Vas Deferens has been removed in order to exhibit the Obturator Canal. The vessels of the Gluteal Region are removed on the right side, but preserved on the left where the Great Sciatic Nerve is to be seen.

Midway between the Xiphoid Process and the Symphysis Pubis lies the Umbilicus which in the adult forms a little fossa varying in depth with the thickness of the Panniculus Adiposus; its margin corresponds to the Annulus Umbilicalis. The gap formed in the fibrous Linea Alba and the subcutaneous fat may be circular, fusiform or lozenge-shaped. From the bottom of the Umbilical Fossa rises a small, usually dimpled, flat, cylindrical or conical process, the Umbilical Papilla (the remains of the umbilical cord).

The Zone between the Papilla and the Annulus is, especially in children, a point of diminished resistance (Umbilical Hernia). The thick parietal layer of Peritoneum is distinguished in the umbilical region by peculiar appendages containing fat which remind one of the Appendices Epiploicae of the Colon. Four cords run to or from the Umbilicus in the adult; they represent canals, patent in the foetus and even later in life they may not be obliterated completely. Upwards and towards the right to the Hilum of the Liver passes the Round Ligament which represents the Umbilical Vein.

From below three cords in their passage to the Umbilicus produce three folds.

1. Utrachus, in the middle line (formerly the stalk of Allantois) extends from the summit of the Bladder to the Umbilicus — Plicae Utrachi.

2. Obliterated Hypogastric Arteries on either side — Plicae Umbilicales.

3. Deep Epigastric Artery (from the External Iliac Artery) on either side (Plicae Epigastricae).

Externally and internally to the Plicae Epigastricae are fossae viz: the External and the Internal Inguinal Fossae. In the outer fossa lies the Internal Abdominal Ring from which point the inguinal canal runs obliquely inwards, forwards and downwards. This canal is occupied by the Spermatic Cord, the contents of which come together at the Internal Abdominal Ring. Separated from the External Abdominal Ring by POTT-PAART'S Ligament is the (rural) Ring.

An Oblique or Indirect Hernia protrudes above POTT-PAART'S Ligament external to the Deep Epigastric Artery; a Direct Hernia internal to this Artery. Femoral Herniae make their appearance below POTT-PAART'S Ligament.

Fig. 143. Anterior Abdominal Wall shewing the Nerves in the region of the Appendix — Bladder moderately distended.

A large window has been cut in the Anterior Abdominal Wall through Skin and Superficial Fascia; through the External Oblique Muscle the opening is smaller and through the Internal Oblique Muscle of yet smaller area. A window has also been made in the Lower Segment of the Left Rectus. The Intramuscular Nerve Twigs are black, the Caecum red, the Peritoneum blue and its line of reflection off the bladder is indicated by a dotted line.

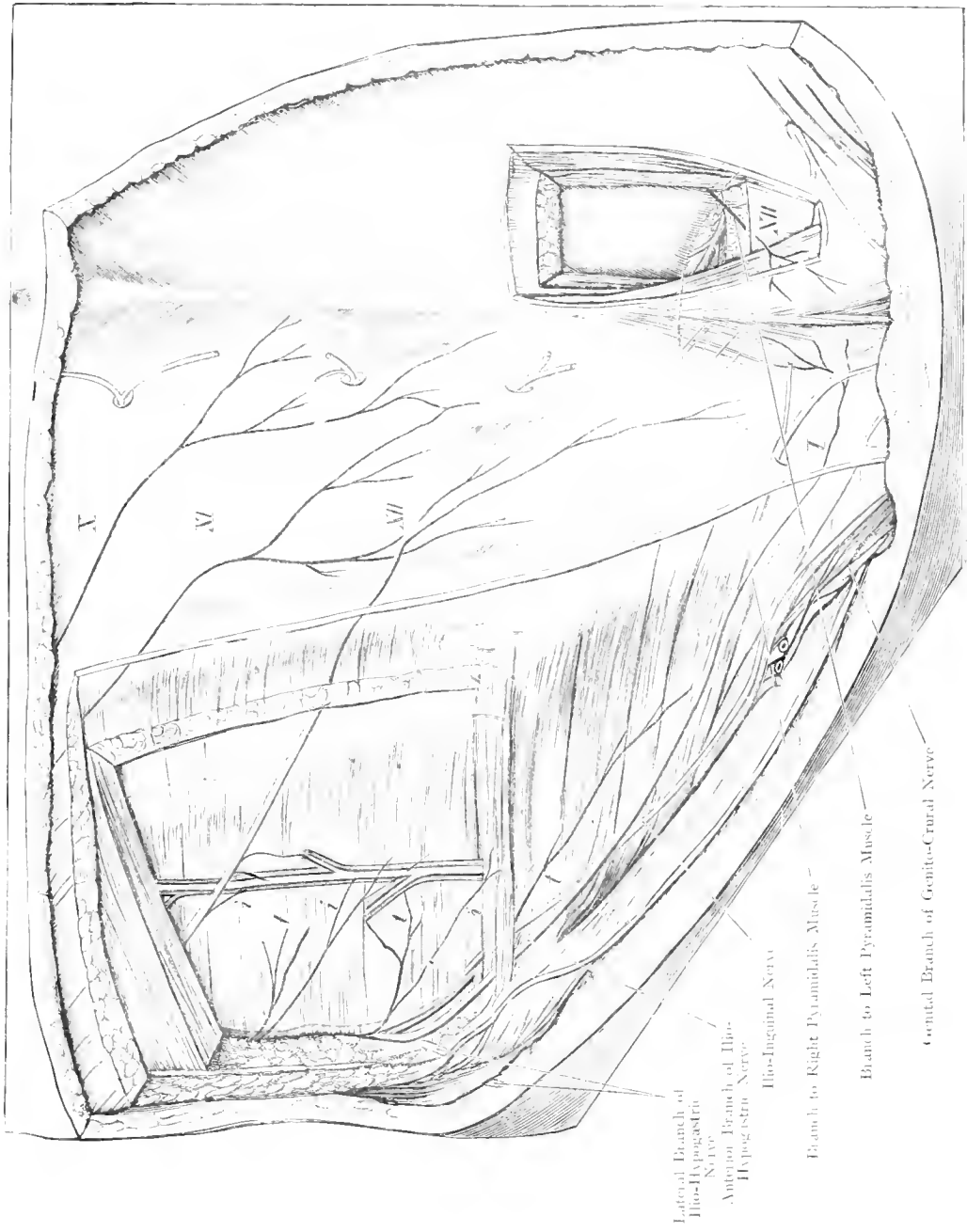
In Laparotomy, of great frequency nowadays, haemorrhage is an unimportant factor; nevertheless, it is a fact to be grasped that an incision through the linea alba which is poor in vessels is attended by very little loss of blood.

The next important vessels met with in the lower part of the Abdominal Wall are the Deep Epigastric and Deep Circumflex Iliac Arteries (branches of the External Iliac Artery). The former vessel arches around the Vas Deferens from below and passes upwards and inwards (Fig. 142) along the posterior surface of the Rectus Muscle to enter its sheath at the Semilunar Fold of DOUGLAS and anastomose with the Superior Epigastric, a branch of the Internal Mammary Artery, which runs vertically downwards.

The Deep Circumflex Iliac Artery runs along the upper border of POUPART'S Ligament towards the crest of the Ilium. The Superficial Epigastric Artery passes upwards and is frequently injured with profuse haemorrhage in incisions which are

made about midway between the Anterior Superior Iliac Spine and the Umbilicus.

In Abdominal incisions consideration of the nerves is more important. Divided and sutured muscle fibres readily atrophy so that Scar-Herniae may occur. Incisions along the Linea Alba or along the outer border of the Rectus Muscle (Linea Semilunaris) avoid injury to muscle fibres. Division of motor-nerves produces paralysis of the different muscle segments which they supply; this paralysis is generally permanent and favours Herniae. If incisions are made parallel to the nerves then fewer nerves will be divided. As the nerves supplying the Abdominal Muscles, Lower Intercostal, Ilio-Hypogastric and Ilio-Inguinal Nerves run obliquely downwards and forwards it is necessary to make oblique incisions wherever possible when the position of Abscess, Tumour etc., renders a median incision undesirable. This figure shows that the Pyramidalis is supplied by the 12th Intercostal Nerve.



H. Fr. 1896

Fig. 143. Anterior Abdominal Wall showing the Nerves in the region of the Appendix;
Bladder moderately distended. — $\frac{2}{3}$ Nat. Size.

- Lateral Branch of Ilio-Hypogastric Nerve
- Anterior Branch of Ilio-Hypogastric Nerve
- Ilio-Inguinal Nerve
- Branch to Right Pyramidalis Muscle
- Branch to Left Pyramidalis Muscle
- Genital Branch of Genito-Crural Nerve

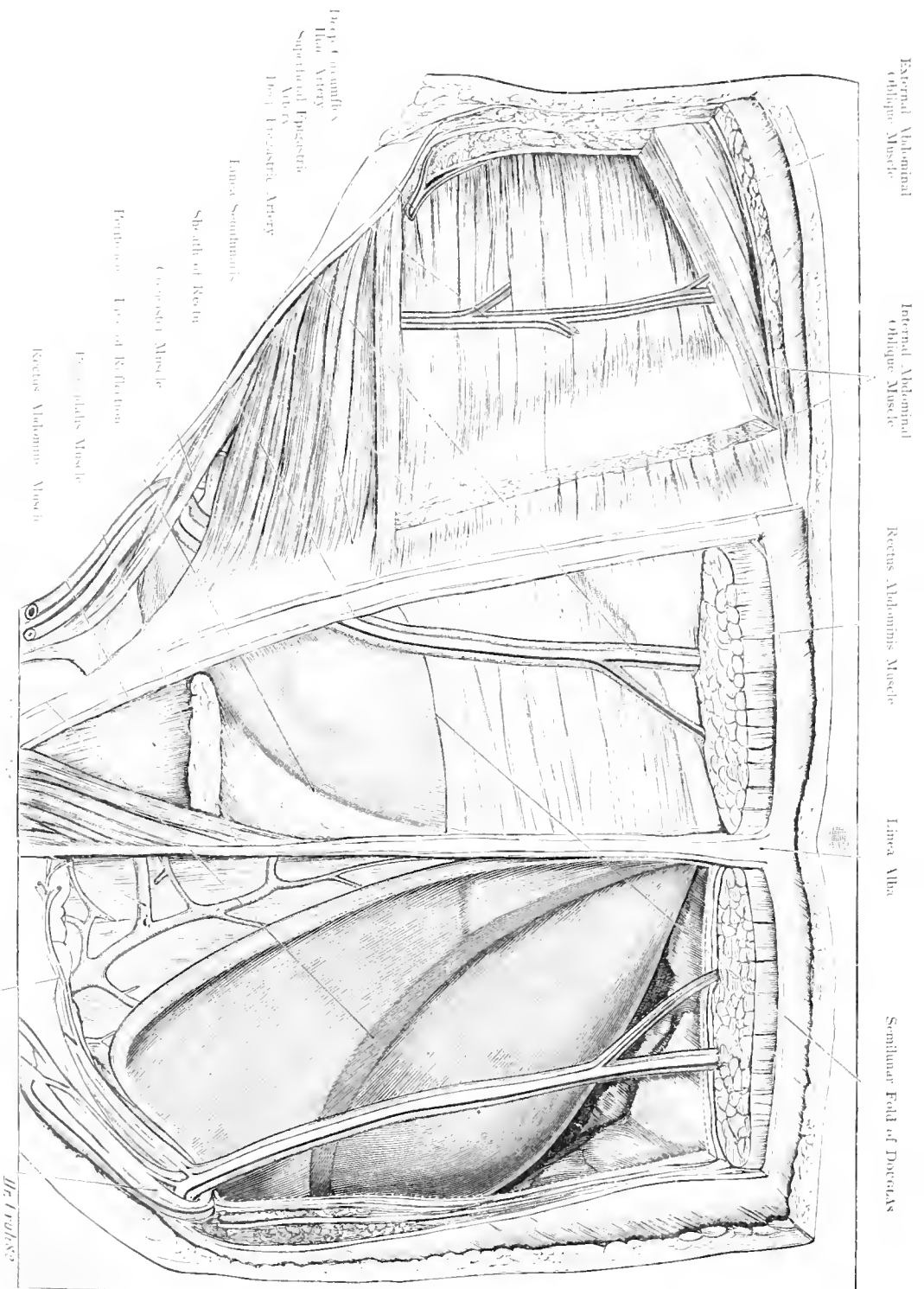


Fig. 144. Anterior Abdominal Wall shewing Vessels in the Hypogastric Region: Bladder much distended.

Fig. 144. Anterior Abdominal Wall; Hypogastric Region with Vessels, Bladder much distended.

A large window has been made in the Anterior Abdominal Wall of a young male body in which the bladder was much distended with urine. On the right side a window section of the Abdominal Muscles has been made as in Fig. 143 with the further removal of a piece of the right Rectus Abdominis; on the left side the posterior sheath of this muscle, its lower portion, the Pyramidalis, Fascia Transversalis and parietal layer of Peritoneum have been cut away with preservation of the Deep Epigastric Vessels.

The figure shows the line of reflection of the Peritoneum, on the right side the parietal peritoneum can be seen behind the Rectus (light blue) while on the left the peritoneal covering of the Bladder is shewn.

This figure shows the important anatomical relations in connection with the operation of Suprapubic Cystotomy.

When empty the Bladder lies completely within the true pelvis and does not reach as far as the upper border of the symphysis pubis; however, with increasing distension it passes upwards out of the pelvis; its position varies much with the degree of distension of the Rectum which by pressure upon the Prostate indirectly affects the Bladder. It is for the purpose of making use of this mechanical effect that a Procteurmyter is employed in operations upon the bladder. Again considerable advantage is gained by the ascent of the Peritoneum coincident with the ascent of the Bladder; as the line of reflection ascends a space is formed above the Symphysis through which the Bladder can be opened without interfering with the Peritoneum. (One is entitled to assume that, with distension of the bladder and rectum,

the line of reflection will be $\frac{1}{2}$ th to $1\frac{3}{4}$ th inch above the symphysis, as this can be pushed still further the bladder wall may be exposed to the extent of $2\frac{2}{5}$ th inches without opening the peritoneum so that an aperture may be obtained large enough to allow of the removal of the largest stone and vesical tumour. Only by over-distension does the line of reflection extend still further (as far as $3\frac{3}{8}$ th inches). The space between the Bladder and Symphysis (Fig. 152) is occupied by fat, — one mass between Rectus and Fascia Transversalis, another between Fascia Transversalis and Bladder — the so-called retrofascial suprapubic space; below the latter is continuous with the prevesical space and together they form the Pre-peritoneal Space of RETZLUS. In the spread of a purulent infection this space becomes of great importance. Over the bladder walls are seen numerous veins.

The arrangement of the posterior sheath of the Rectus is shewn in this figure; at the semilunar fold of DOUTRIAS its firm consistency is lost, so that below this line which allows the Deep Epigastric Artery to enter the Muscle Sheath the Rectus is only separated from Peritoneum by Fascia Transversalis.

Fig. 145. Back shewing Nerves, Arteries and Lymphatic Glands.

The Skin and Superficial Fascia have been removed from the whole dorsal aspect, extending from Occiput to Sacrum. On the right side the Trapezius, Latissimus Dorsi, Superficial Layer of Lumbar Aponeurosis, Supra- and Infra-Spinatus Fascia with the attachment of the Splenius Capitis Muscle have been cleared away.

This figure is purposed to shew those lymphatic glands of the back which are little known and which receive but scant attention.

1. **Muscles and Nerves.** Trapezius Muscle with Spinal Accessory (XIth Cranial) Nerve running almost vertically downwards, Latissimus Dorsi Muscle with its nerve running obliquely downwards and inwards, Levator Anguli Scapulae and Rhomboid Muscles with branches from the Posterior Thoracic Nerve, Supra- and Infra-spinatus Muscles with the Supra-scapular Nerve, Teres Minor and Deltoid Muscles with the Circumflex Nerve, Teres Major Muscle, Subscapular Nerve, Serratus Magnus Muscle, Long Thoracic Nerve (of BELL) (v. Figs. 109 and 110).

2. **Arteries.** The Occipital Artery (a branch of the External Carotid) becomes visible, at the attachment of the Sterno-Mastoid and Trapezius, and ramifies over the Occiput. The Posterior Auricular Artery (External Carotid) passes behind the pinna to anastomose with the former. The Transversalis Colli Artery from the Subclavian Artery appears in the space between the Levator Anguli Scapulae and Rhomboid Muscles. The Supra-scapular Artery either a direct branch of the Subclavian or a radicle of the Thyreoid Axis or Inferior Thyreoid Artery, accompanies the Supra-scapular Nerve to the Supra- and Infra-spinous Fossae where it anastomoses with the Subscapular Artery from the Axillary.

More externally the Posterior Circumflex Artery accompanies the Circumflex Nerve as it winds around the Surgical Neck of the Humerus. In close contiguity to BELL'S Nerve is found the Long Thoracic Artery (inconstant). Upon the Dorsum of the Trunk proper only small arteries are found because the Dorsum of the Trunk like the extensor aspects of the limbs receives its blood from the ventral or flexor aspect.

3. **Lymphatic Glands.** At the point of emergence of the Occipital Artery a few Occipital Glands are found. Behind the Pinna accompanying the Posterior Auricular Artery and lying over the tendinous attachment of the Sterno-Cleido-Mastoid is a posterior Auricular Gland which should be called the Superior Posterior Auricular Gland so as to distinguish it from a deeper gland which lies in contact with the Muscle itself. Deeply situated behind the Mastoid Process, and under cover of the Splenius and close to the Occipital Artery lies a deep Mastoid Gland (cf. Fig.).

The subcutaneous glands along the upper border of the Trapezius and near the Vertebral Column are not particularly marked in the figure. They may be called the Superior and Inferior Subcutaneous Nuchal Glands. At the level of the 7th Cervical Vertebra lies the Superior Superficial Dorsal Gland; the Inferior Superficial Dorsal Gland lies along the outer border of the Latissimus Dorsi at the level of the 1st or 2nd Lumbar Vertebra. At the Clavicular Origin of the Deltoid is the Superficial Clavicular Gland, whereas more deeply situated near the Supra-scapular Artery and at the upper border of the Scapula is the Supra-scapular Gland.

Deep Dorsal Glands are situated at the upper border of the Rhomboid Muscles; on the Teres Major Muscle is seen the posterior superficial Axillary Gland; a deep gland is situated between the Teres Major, Teres Minor and Tri-ceps Muscles.

These glands are not all constant; they may only be found in pathological conditions; such occurrence does not exclude their normal presence as merely elementary.

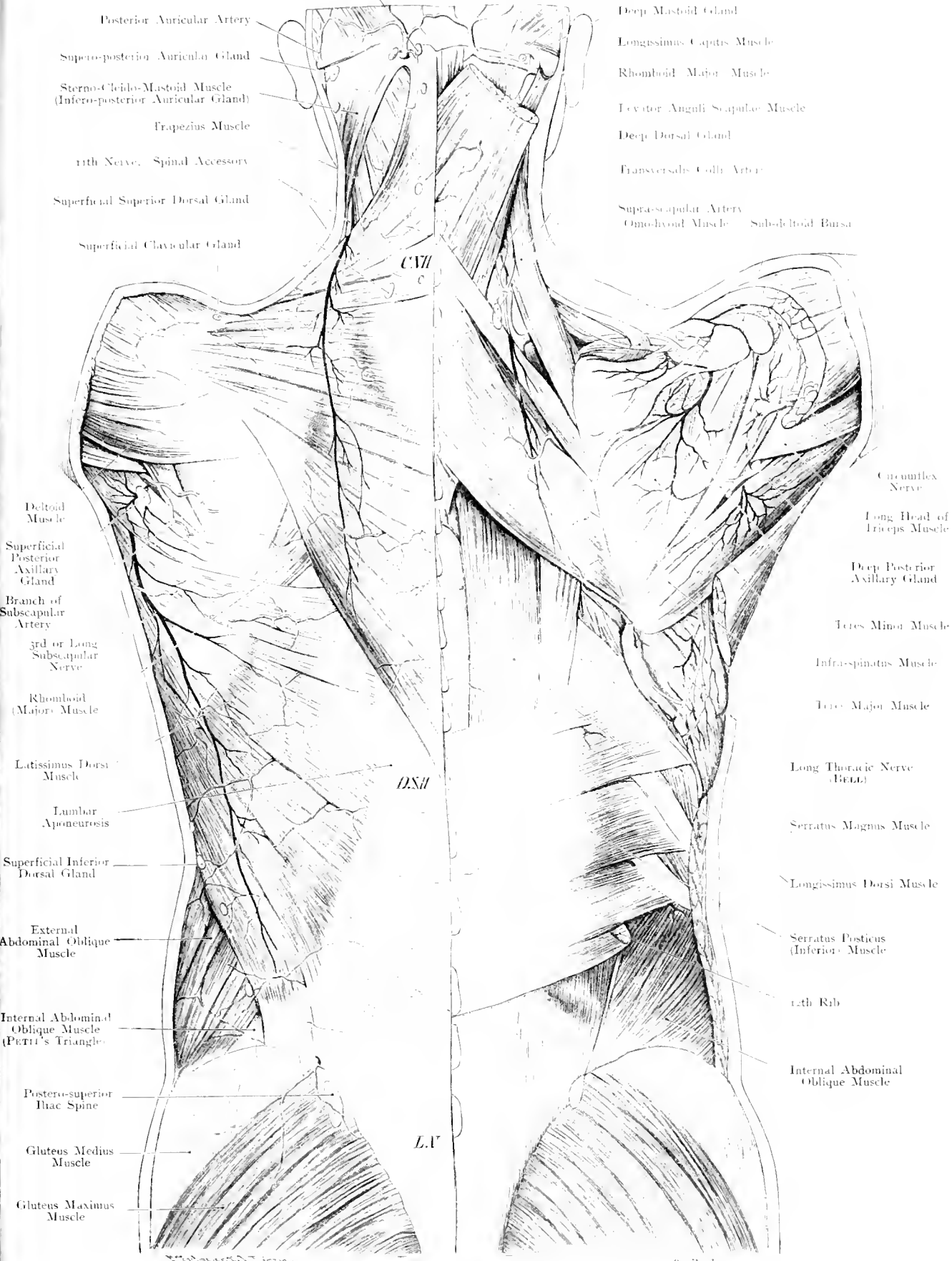


Fig. 145. Back, shewing Nerves, Arteries and Lymphatics.

$\frac{2}{3}$ Nat. Size.

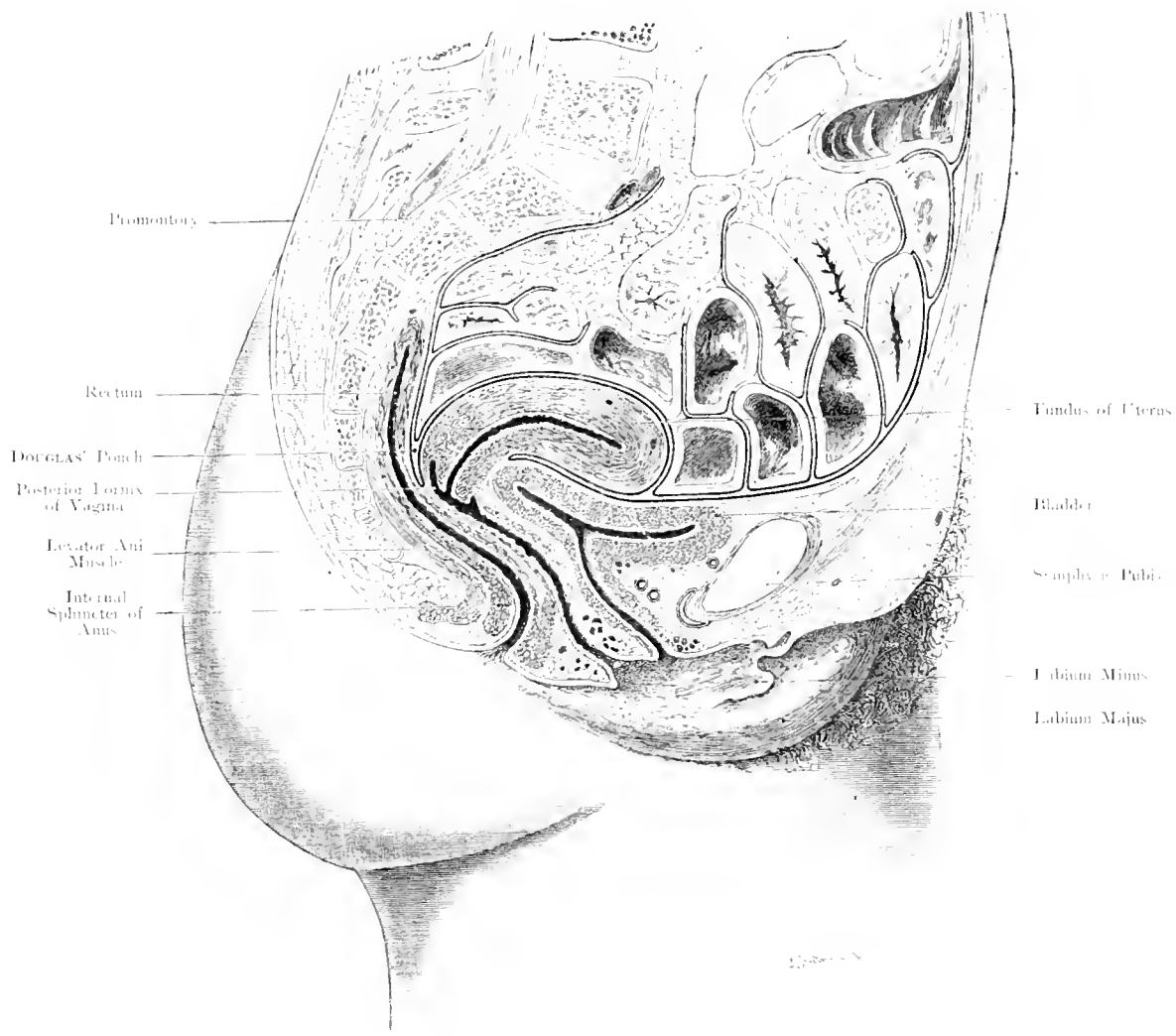


Fig. 146. Median Section through a Female Pelvis (Bladder and Rectum empty).

$\frac{1}{2}$ Nat. Size.

Fig. 146. Median Section through Female Pelvis; Bladder and Rectum being empty.

Median section through the body of a woman aged 30. In this instance, owing either to pathological adhesions or post-mortem changes, the Uterus did not lie directly on the Bladder, it has, therefore, been drawn forward into the position of anteversion and anteflexion in accordance with the general investigations upon living subjects.

When the bladder is empty the normal position of the uterus during life is anteverted (virgins) and anteflexed (women) i. e. the Uterus lies on the postero-superior aspect of the bladder (B. SCHULTZE). Whether coils of small intestine lie between the Uterus and Bladder or whether other varieties normally exist we have not definitely decided.

As the bladder becomes distended the Uterus is pushed upwards and backwards.

The course of the Vagina is S-shaped, like the Rectum and Urethra. Into its upper cul-de-sac the Cervix Uteri protrudes, thus forming an Anterior and Posterior Fornix of which the latter is separated from the Pouch of DOUGLAS by $\frac{1}{25}$ th inch. (Operation route.)

The empty bladder evidences a slight impression due to the body of the Uterus. An "uterine impression" can also be recognized on the distended bladder. The S-shaped Urethra ($1\frac{3}{5}$ th inch long) enters the bladder at an acute angle.

The Peritoneum does not extend so far down on the posterior aspect of the Rectum (3rd Sacral Segment) as upon its Anterior Aspect (1st Segment of Coccyx). Levator Ani, External and Internal Anal Sphincter Muscles are shewn in the figure.

Lastly the extremity of the Dural Sac of the Spinal Cord is seen terminating at the level of the 2nd Segment of the Sacrum.

Fig. 147. Female Pelvic Organs, seen from above and behind.

Body of a Virgin, aged 15 years, with well developed genital organs has been injected with 10% Formol. Large intestine preserved: The retroperitoneal structures have only been exposed at the root of the Mesentery.

By combining this figure with the median section (Fig. 146) and by the further assistance of Fig. 149 a complete and accurate idea of the position of the pelvic organs in the female, can be obtained. Fig. 147 is useful in the consideration of those operations in which the pelvis is approached from above.

A survey of the pelvis from above and behind is the best regional study because the true pelvis is seen as well as the important relations of the Anterior Abdominal Wall in the proximity of the Bladder, the posterior openings of the Inguinal Canals and DOUGLAS' Pouch.

On the lateral aspect of the Lumbar Vertebrae is the Psoas, posterior to this the Quadratus Lumborum and the muscles of the back. In front and slightly to the left is the Aorta and Common Iliac Artery, on the right the Inferior Vena Cava, and on both sides the Sympathetic Chain. To the left of the Psoas lies the Sigmoid Flexure (Fig. 138). The commencement of the Rectum lies in front of the Promontory; anterior to this and more to the right is seen the lumen of the Ileum with the Superior Ileo-Caecal Fossa situated posteriorly, the Appendix anteriorly and the transversely divided ascending colon to the right.

On the Anterior Abdominal Wall (Fig. 142) are to be seen: Urachus (Stalk of Allantois), Obliterated Hypogastric Arteries; Deep Epigastric Arteries, Internal Abdominal Ring, through which pass the Canal of Nuck (Peritoneal Process) and Round Ligament of Uterus. The Uterus lying on the bladder is antverted and, in this case, inclined to the left so that the right broad Ligament is more tense than the left.

The Ovaries attached to the Uterus by the Utero-Ovarian Ligaments (Ligament of Ovary) are situated almost vertically against the lateral wall of the true pelvis when the uterus is anteverted and in the middle line. The Tubes surround and almost completely cover the Ovaries (Left side). In woman and mammals both Ovaries lie in a peritoneal pouch (Bursa Ovarica) which is somewhat shut off from the rest of the peritoneal cavity and becomes of importance when an Ovum wanders from the Ovary into the Abdominal Opening of the Fallopian Tube.

The Recto-Uterine Folds, especially on the right side of the figure, are well marked; these folds form the upper lateral boundaries of the Pouch of DOUGLAS which, in this figure, is almost completely filled by the distended rectum (Fig. 142, 146, 149, 151).

Fig. 148. External Female Genital Organs. (Vulva.) Vestibule.

The Labia have been drawn apart in order to shew the Vestibule and, in particular, the openings of the ducts of BARTHOLINI'S Glands.

The Labia Majora corresponding to the Scrotum of the male limit the Rima Pudendi which is closed in Virgins when the thighs are adducted; in front these Labia meet, but behind they are lost near the Anus. They are folds of skin usually well-covered with hair and large sebaceous glands, and contain large Veins.

The Labia Minora are separated by a sulcus from the Labia Majora; their outer surfaces are covered with skin, their inner surfaces with mucous membrane continuous with that of the Vestibule. In front the Labia Minora bifurcate, the outer portions of either side unite to form the Prepuce of the Clitoris, the inner join below the Clitoris and form the Frenum. The Clitoris which corresponds to the Penis of the Male is usually rudimentary, its extremity (Glans Clitoridis) alone being visible. The posterior ends of the Labia Minora vary much, they may merge into the Labia Majora, or may unite together and form an arch which limits the Vestibule posteriorly. At the posterior junction of the Labia Minora is situated the Fossa Navicularis.

In the angle between the Labium Minus and the Hymen is situated the opening of the duct of BARTHOLINI'S or DUVERNEY'S Gland. In front of the Hymen and about midway between the posterior limit of the Vaginal Orifice and the Clitoris is situated the Urethral Orifice which may be of different shapes: — a vertical slit, semilunar or \wedge -shaped.

The projection of mucous membrane behind this — Lingula Urethrae VON BARDELEBEN — is correspondingly pointed or rounded off.

The Hymen a reduplication of the mucous membrane at the entrance of the Vagina varies much in shape though generally crescentic from side to side with the broad part of the crescent posterior in situation (prior to Defloration); it may be annular, or fimbriated, even double or fenestrated. During "Defloration" the hymen is usually torn and heals with cicatrices. Fresh lacerations occur during the first labour, these lead to the formation of Carunculæ Myrtiformes.

**Fig. 149. Pelvic Organs of Female seen from above and in front.
Ureter.**

Woman aged 50. Intestines removed as far as the Rectum, Uterus retroverted; Left Appendages of Uterus removed. The Right Fallopian Tube is drawn upwards and its fimbriated extremity thrown upwards over the brim of the true pelvis. The Abdominal Opening of the Fallopian Tube and the Ovarian Fossa are thus exposed; the ovary is somewhat drawn upwards by the tube. On the left side the peritoneum covering the important vessels and nerves has been removed, but the portion forming the posterior layer of the Broad Ligament has been preserved intact and the round ligament retained in situ. On the left side the Lymphatic Glands are exposed and their corresponding imaginary situations on the right side are depicted through the transparent peritoneum.

By WALDEYER the lateral wall of the true pelvis has been divided into the following fossae: Paravesical, Obturator, Hypogastric (Para-Iliac) bounded by the Round Ligament (in the Male — Vas Deferens) and the Ureter.

When the Bladder is empty the Paravesical Fossa is divided into an anterior and posterior part by the Transverse Vesical Fold; the anterior part belongs more to the Anterior Abdominal Wall, the posterior part can be fully seen when the Uterus is retroverted. The Obturator Fossa in the depth of which the Obturator Vessels and Nerve run over the surface of the Obturator Internus Muscle contains the Ovarian Fossa which may be a simple groove or a deep alcove against which the lateral half of the Ovary lies while its posterior border remains free and rounded.

The Ovary lies on the Uterine Artery touching the Ureter; according to the size of this organ and the position of the Internal Iliac Vessels it reaches or extends beyond the Internal Iliac Vessels, as far as the lower border of the External Iliac Vein.

The most posterior fossa is the Hypogastric (Para-Iliac) Fossa in which the Piriformis Muscle and on this muscle the Sacral Plexus are found.

The Ureter generally enters the True Pelvis at the bifurcation of the Common Iliac Artery passing over the External Iliac Vessels and the Umbilico-Vesical Trunk to lie between the Internal Iliac Vessels and the Uterine Artery and covered for some distance by the broad ligament and the Vessels to the Appendages. In this part of its course the Ureter lies directly under the Peritoneum. Further forwards, in front of the Broad Ligament, the Uterine Artery crosses over and in front of the Ureter as it leaves the pelvic wall and approaches the Vaginal Portion of the Uterus. It is at the level of the Internal Os (where the Uterine Artery bifurcates — WALDEYER) that the Uterine Artery crosses the Ureter. The Ureter comes very near the Vaginal Portion of the Uterus (cf. dotted line) as it curves round it laterally to open into the bladder.

The Ureter is only separated from the Vaginal Portion of the Uterus by the vessels in the cellular tissue of the Parametrium (Branches of the Uterine Artery and Utero-Vaginal Venous Plexus). On its outer side lies the Vesico-Vaginal Venous Plexus. These Plexuses communicate freely so that the Ureter is embedded in a venous plexus.

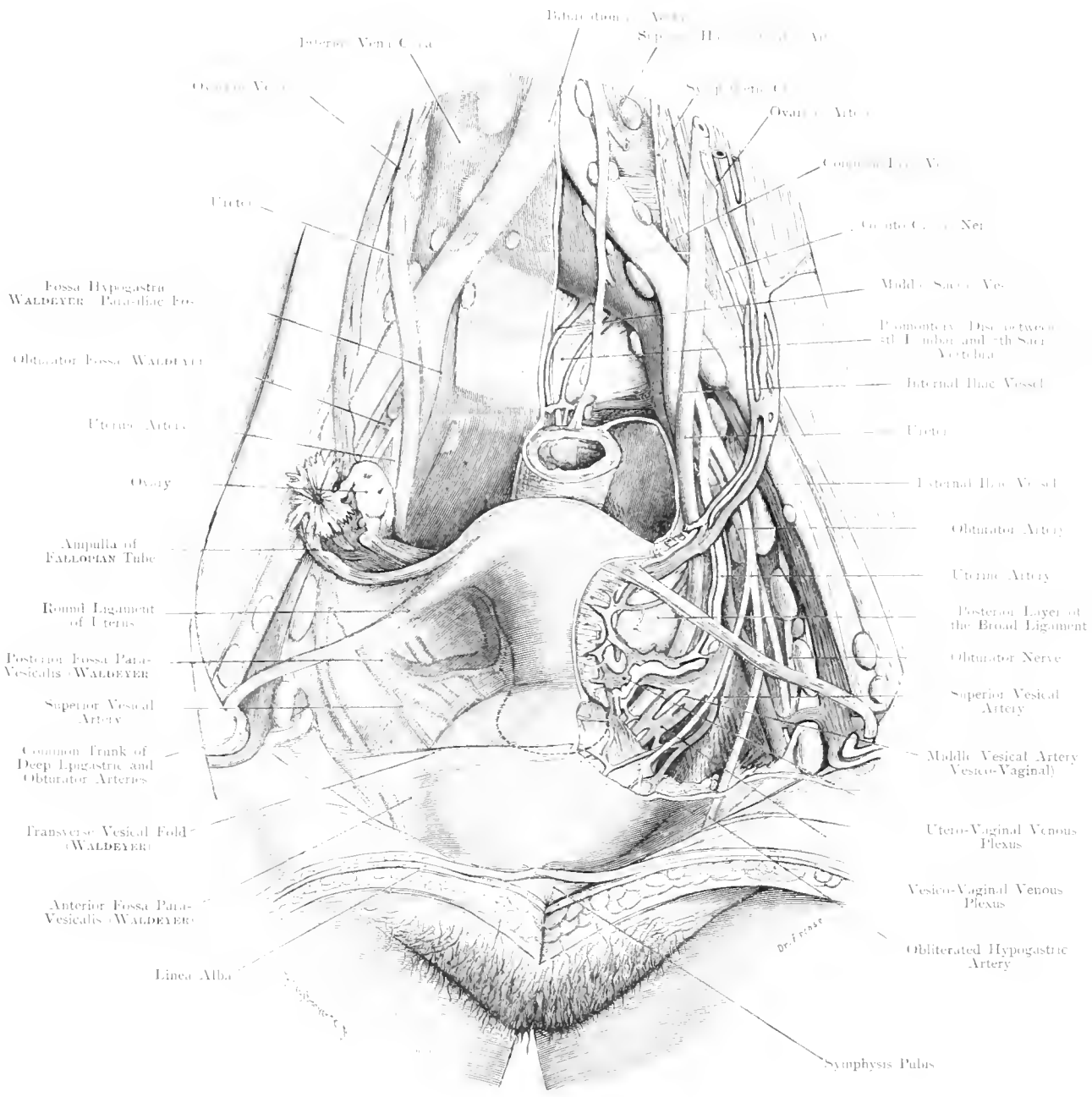
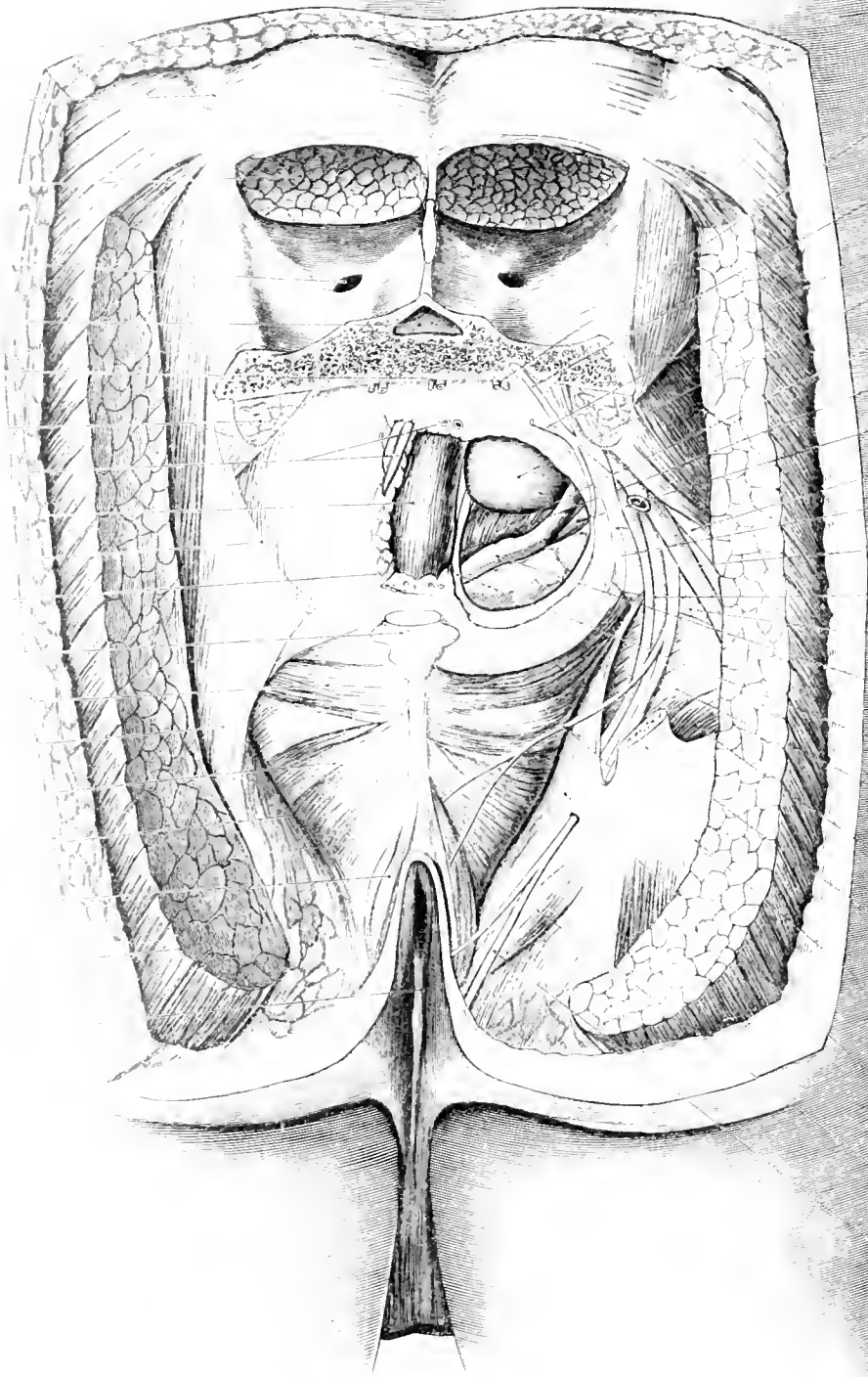


Fig. 149. Pelvic Organs of Female, seen from above and in front Ureter.

$\frac{2}{3}$ Nat. Size.



Can.
 3d Sacral
 P. Musc.
 4th Sacral
 Rectum
 P. Musc.
 Rectum
 and Segment
 of Colon
 Coccygeal
 Musc.
 Sacro-
 Spinous
 Ligament
 Levator Ani
 Musc.
 Levator Prostat.
 Ligament
 Levator Ani
 Sphincter
 Gluteus
 Maximus
 Musc.
 Perineal R. Raphé

Lateral Sacral
 Artery
 Anterior Branch
 of 3d Sacral
 Nerve
 Anterior Branch
 of 4th Sacral
 Nerve
 Peritoneum
 Pouch of
 Douglas
 Bladder
 Recto-Vesical
 Fascia
 Ureter
 Great Sacral
 Nerve
 Small Sacro-
 Spinal Ligament
 Sciatic Vessel
 Internal Pudic
 Vessels
 Gemellus
 Superior Muscle
 Vas Deferens
 Ampulla
 Recto-Vesical
 Fascia
 Obturator
 Internus Muscle
 Gemellus
 Inferior Muscle
 Great Sacro-
 Spinal Ligament
 Inferior
 Haemorrhoidal
 Nerve
 Obturator Fascia
 Ischio-
 Cavosus
 Muscle
 Posterior Sciatic
 Branch of the
 Perinaei Nerve
 of Internal
 Pudic

Fig. 150. Pelvic Organs of Male, exposed from behind.

3/4 Nat. Size.

Fig. 150. Male Pelvic Organs, exposed from behind.

Male aged 33. The Gluteus Maximus is detached from the Posterior Inferior Iliac Spine downwards and the Erector Spinae divided transversely at this level. The Sacrum has been sawn through between the 2nd and 3rd Sacral Foramina, the Coccyx between the 1st and 2nd Segments; the different layers have then been successively exposed: Rectum, Bladder, Peritoneum, Vas Deferens, Seminal Vesicle and Ureter. On the right side the Great Sacro-Sciatic Ligament has been cut short and the Ischio-rectal Fossae cleared out on both sides.

The figure particularly shews the different layers through which the Surgeon cuts in order to reach the Rectum or deeper parts.

Removal of the lower part of the Sacrum can be carried out, as shewn in the figure, without any great damage. The nerve supply of the Rectum and Bladder is chiefly derived from the 3rd Sacral Nerve. There is no risk of opening the Dural Sac which usually terminates at the lower part of the 2nd segment of the Sacrum. Deep to the Sacrum lie the middle and lateral Sacral Vessels; next the Rectal Fascia (yellow) and before reaching the longitudinal muscles of the Rectum a thick layer of fat, in which lie the Superior Haemorrhoidal Vessels and the Lymphatic Glands of the Meso-Rectum, has to be divided. According to the degree of distension the Rectum may occupy the whole of the Recto-Vesical Pouch or leave on either side a peritoneal space (light-blue). The lower boundary at which the peritoneum is reflected on the Rectum is about 3 inches above the Anus. Below this level operations on the Rectum can be performed without opening the Peritoneum.

In front of the Rectum merely separated by Recto-Vesical Fascia is the Bladder, the base of which is laterally and inferiorly covered by the Ampulla of the Vas Deferens and the Seminal Vesicles. In the angle between these structures lies the Ureter (green), this can be exposed by removing a layer of fatty tissue rich in the vascular anastomoses of the numerous branches of the Inferior Vesical Vessels (cf. Fig. 161).

The arrangement of the muscles bounding the Ischio-Rectal Fossa is to be seen as well as their relation to the lesser Sacro-Sciatic Ligament and the Coccygeus Muscle; a small gap engages one's attention (through which a Hernia of the Floor of the Pelvis may occur), next the Levator Ani Muscle and finally the External Anal Sphincter (cf. Fig. 153).

The Internal Pudic Vessels and Nerve wind round the Spine of the Ischium and run under cover of the Obturator Fascia forwards and downwards. These structures therefore do not re-enter the pelvis through the Sciatic Foramen as usually stated but remain separated by the muscular floor of the pelvis. Neither do these structures pass into the Ischio-Rectal Fossa but remain in ALCOCK'S Canal which is a re-duplication of the Fascia covering the Obturator Internus Muscle on the outer wall of this fossa.

Fig. 151. Median Section through Male Pelvis.

Frozen section through the body of a robust elderly man. The Rectum was much distended by faeces which were removed after the section had been hardened; the Bladder contained frozen urine which melted as the section thawed.

The parietal layer of Peritoneum lining the Anterior Abdominal Wall can be traced over the summit and posterior aspect of the Bladder to be reflected on to the anterior surface of the Rectum at the level of the lower border of the 4th segment of the Sacrum. This point, of great surgical importance (for the removal of Tumours) is situated 3 inches above the Anus (length of Index Finger). The Peritoneum now continues upwards as far as the 2nd or 1st segment of the Sacrum. Between the Anterior Abdominal Wall and the Peritoneum a space is formed when the Bladder is distended (Space of RETZIUS) because the peritoneum being adherent to the Bladder is pushed upwards as this organ rises out of the Pelvis (Fig. 144). Between the Rectum and the Bladder, close to the middle line, is situated the Ampulla of the Vas Deferens — this is partly shewn in the section. The Rectum when filled with faeces is chiefly distended above the 3rd or Anal portion (Ampulla Recti) so that the organs which lie in front of this part are pushed upwards.

Below the Ampulla of the Vas Deferens lies the posterior portion of the Prostate; the remainder of this gland lies in front of the Urethra, and is surrounded by the Prostatic Venous Plexus.

In this specimen the Bladder Wall is thickened and presents marked rugae on its inner surface. The Urethra on emerging from the Bladder passes through the Prostatic portion — Prostatic Sinus or Verumontanum — this portion is usually one inch or a little more in length, though in cases of Hypertrophy of the Prostate or a greatly distended Rectum this may be exceeded. The next segment of the Urethra is known as the Membranous portion — according to WALDEYER the upper and larger part of this should be called the Muscular portion because it is surrounded by muscles from which it derives both circular and longitudinal fibres. The length of this segment is almost one inch. The Urethra at this situation forms a curve at an angle of 90 degrees which often obstructs the passage of the point of a catheter. The distal segment is 6 to 8 inches long and extends from the Anterior layer of the triangular ligament to the end of the Penis, lying between the Corpora Cavernosa it is surrounded by a delicate erectile tissue (the Corpus Spongiosum) which is enlarged posteriorly to form the Bulb and anteriorly to form the Glans Penis. The Corpora Cavernosa arise on either side of the ascending Ramus of the Pubis and terminate as cones at the level of the Coronary Sulcus of the Glans Penis by which they are covered. Slightly posterior to the slit-like external urinary orifice the Urethra widens into the Fossa Navicularis. The Glans may or may not be covered by a Prepuce according to size, age, habits, etc. (Phimosis, Paraphimosis, Circumcision — cf. Fig. 152 and Text).

As the position of the testicles is not quite symmetrical, the Septum of the Scrotum has not been divided but the left testicle within its Tunica Vaginalis has been cut obliquely.

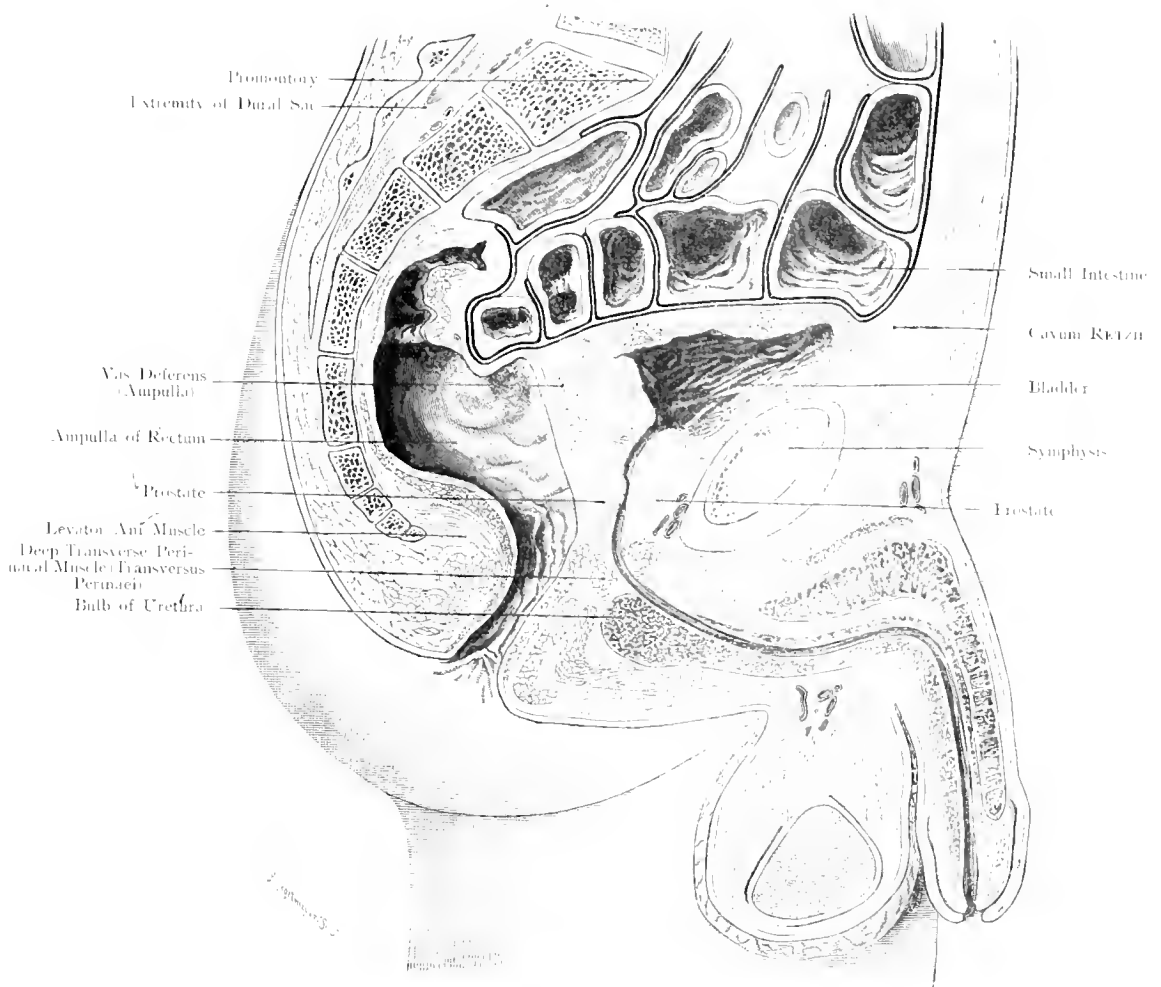
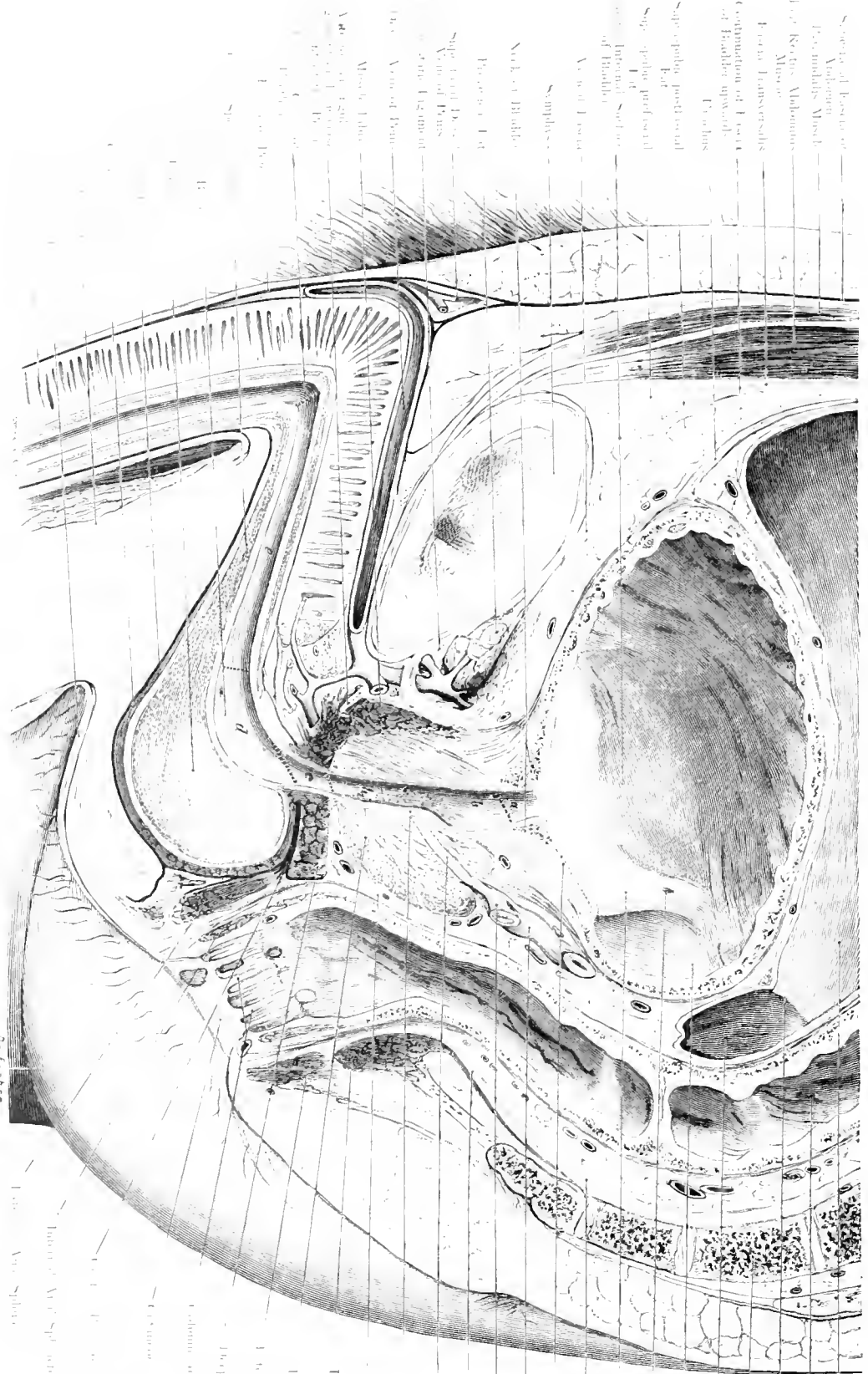


Fig. 151. Median Section through Male Pelvis.

$\frac{1}{2}$ Nat. Size.



- Peritoneal Cavity
- Rectum
- Recto-Vesical Folds
- 5th Sacral Vertebra
- Recto-Vesical Pouch
- Retromental Fossa
- Orifice of Ureter
- Interarterial Folds (Merrill's Gap)
- Rectal Fascia
- Trigone of Bladder
- Left Vas Deferens (Ampulla)
- Seminal Vesicle
- Peripetal Layer of Pelvic Fascia
- Hiatalary Forl
- Vermiformium
- Recto-Vesical Folds
- Pyostide Layer
- Erector Ani Muscle
- Posture
- Internal Anal Sphincter
- Deep Layer of Perineal Muscle
- Canal of Rectum-Mid-vent.
- Cricoid Muscle
- Internal Anal Sphincter
- External Anal Sphincter

- Sphincter of External Urethral Orifice
- Anal Muscles:
 - 1. Levator Ani Muscle
 - 2. External Anal Sphincter
 - 3. Internal Anal Sphincter
 - 4. Pubo-Rectal Muscle
 - 5. Perineal Muscles
 - 6. Transverse Perineal Muscle
 - 7. External Anal Sphincter
 - 8. External Anal Sphincter
 - 9. External Anal Sphincter
 - 10. External Anal Sphincter
 - 11. External Anal Sphincter
 - 12. External Anal Sphincter
 - 13. External Anal Sphincter
 - 14. External Anal Sphincter
 - 15. External Anal Sphincter
 - 16. External Anal Sphincter
 - 17. External Anal Sphincter
 - 18. External Anal Sphincter
 - 19. External Anal Sphincter
 - 20. External Anal Sphincter
 - 21. External Anal Sphincter
 - 22. External Anal Sphincter
 - 23. External Anal Sphincter
 - 24. External Anal Sphincter
 - 25. External Anal Sphincter
 - 26. External Anal Sphincter
 - 27. External Anal Sphincter
 - 28. External Anal Sphincter
 - 29. External Anal Sphincter
 - 30. External Anal Sphincter
 - 31. External Anal Sphincter
 - 32. External Anal Sphincter
 - 33. External Anal Sphincter
 - 34. External Anal Sphincter
 - 35. External Anal Sphincter
 - 36. External Anal Sphincter
 - 37. External Anal Sphincter
 - 38. External Anal Sphincter
 - 39. External Anal Sphincter
 - 40. External Anal Sphincter
 - 41. External Anal Sphincter
 - 42. External Anal Sphincter
 - 43. External Anal Sphincter
 - 44. External Anal Sphincter
 - 45. External Anal Sphincter
 - 46. External Anal Sphincter
 - 47. External Anal Sphincter
 - 48. External Anal Sphincter
 - 49. External Anal Sphincter
 - 50. External Anal Sphincter
 - 51. External Anal Sphincter
 - 52. External Anal Sphincter
 - 53. External Anal Sphincter
 - 54. External Anal Sphincter
 - 55. External Anal Sphincter
 - 56. External Anal Sphincter
 - 57. External Anal Sphincter
 - 58. External Anal Sphincter
 - 59. External Anal Sphincter
 - 60. External Anal Sphincter
 - 61. External Anal Sphincter
 - 62. External Anal Sphincter
 - 63. External Anal Sphincter
 - 64. External Anal Sphincter
 - 65. External Anal Sphincter
 - 66. External Anal Sphincter
 - 67. External Anal Sphincter
 - 68. External Anal Sphincter
 - 69. External Anal Sphincter
 - 70. External Anal Sphincter
 - 71. External Anal Sphincter
 - 72. External Anal Sphincter
 - 73. External Anal Sphincter
 - 74. External Anal Sphincter
 - 75. External Anal Sphincter
 - 76. External Anal Sphincter
 - 77. External Anal Sphincter
 - 78. External Anal Sphincter
 - 79. External Anal Sphincter
 - 80. External Anal Sphincter
 - 81. External Anal Sphincter
 - 82. External Anal Sphincter
 - 83. External Anal Sphincter
 - 84. External Anal Sphincter
 - 85. External Anal Sphincter
 - 86. External Anal Sphincter
 - 87. External Anal Sphincter
 - 88. External Anal Sphincter
 - 89. External Anal Sphincter
 - 90. External Anal Sphincter
 - 91. External Anal Sphincter
 - 92. External Anal Sphincter
 - 93. External Anal Sphincter
 - 94. External Anal Sphincter
 - 95. External Anal Sphincter
 - 96. External Anal Sphincter
 - 97. External Anal Sphincter
 - 98. External Anal Sphincter
 - 99. External Anal Sphincter
 - 100. External Anal Sphincter

Fig. 152. Median Section through Male Pelvis, Urethra. Pelvic Fasciae.

Nat. Size.

Fig. 152. Median Section through Male Pelvis — Urethra.

Male aged 40. Urethra distended and divided into Segments, after WALDEYER (Sitzungsber. d. Akad. d. Wiss. Berlin, 1880). The pubic curve is extraordinarily marked because the penis was frozen with the legs abducted and the penis pendant.

WALDEYER distinguishes 5 segments the limits of which are not vertical to the lumen of the Urethra:

- a) Intra-urethral portion, within the Bladder-Wall — Neck of Bladder.
- b) Prostatic portion, the upper and smaller part of which is exclusively an urinary passage, the lower part both an Urinary and Sexual passage.
- c) Muscular portion, the narrowest part of the Urethra which lies within the (Tro-gential triangle), triangular ligament.
- d) Fossa of the Bulb, corresponding to the Bulb, the upper wall of which is the shorter. This corresponds to the membranous portion proper in as much as it shows neither erectile nor muscular tissue. Into this portion opens (a small slit) the Duct of COWPER'S Gland.
- e) Part corresponding to the attachments of the Corpora Cavernosa (Pars Cavernosa Fixa).

There are two important points of dilatation in the Urethra:

1. The region of the Verumontanum at the posterior part of the Prostatic portion (the Prostatic Sinus in which the Prostatic Secretion mingles with the Semen proper).
2. The Fossa of the Bulb below the Triangular Ligament.

The latter is of great importance in catheterization because the instrument may distend the Fossa posteriorly without entering the Isthmus of the muscular portion. The other point of importance is the (Pre-Urethral Ligament of WALDEYER) Anterior Triangular Ligament against which the catheter may impinge when the Penis is drawn upwards on to the Abdomen.

The Sacral and Perinaeal Curves of the Rectum are shewn. The Epiblastic portion extends as far as the upper border of the

Columns of the Rectum in the folds of which foreign bodies are sometimes retained.

According to the investigations of KALLISCHNER (1906) the Compressor Urethrae with its circular fibres (Urino-gential Sphincter) is not limited to the triangular ligament but can be traced to the bladder where it becomes much attenuated. The muscles of the trigone of the bladder are continued obliquely downwards on to the Anterior wall of the Urethra. These fibres have been called by KALLISCHNER, Sphincter Trigonalis, by others the Internal Sphincter of the Bladder. This muscle does not encircle the neck of the Bladder but its upper crescent lies in the Bladder. The Trigone of the bladder (Triangle of LAFREYTRIE) should therefore be regarded as a portion of the Urethra pushed into the Bladder. The lower crescent lies in front of the Anterior wall of the Urethra.

The Sphincter Trigonalis is, in this way, regarded as an obliquely situated Sphincter.

The greater portion of the Prostate is situated laterally and posteriorly to the Urethra; only a small part — the isthmus — is situated anteriorly.

The parietal layers of the Pelvic Fascia (blue) are reflected on to the floor of the Pelvis as visceral layers (yellow) — behind as Rectal Fascia, in front as Vesical and Umbilico-Vesical Fasciae. Between the Bladder and Seminal Vesicles, the Vasa Deferentia and Prostate on the one hand and the Rectum on the other is stretched the Recto-Vesical Fascia.

In considering the most superficial fasciae (black) it must be remembered that the Superficial fascia of the Abdomen is directly continuous with that of the Penis and Scrotum (Dartos). Diffuse Cellulitis of this region spreads into the Perinaeum as far as the central point.

Fig. 153. Frontal Section through Male Pelvis. Levator Ani Muscle.

Frozen section. Through the body of a Male of middle age a section has been made almost parallel with the pelvic axis, so that the plane of section is not accurately frontal.

This figure is intended to complete the series Figs. 151 and 152; only a short description is necessary.

The Bladder *B* with its overlying peritoneum is, in front of the plane of section, visible above the black lines which delineate the peritoneum.

All other structures except the Rectum and the folds of the buttocks and parts of the thigh lie in a frontal plane, i. e. lower part of the Bladder, Ampullae of Vasa Deferentia, external to these (cf. Fig. 151) the Seminal Vesicles and directly below the last mentioned the Rectal Wall.

Very instructive is the divided Obturator Internus Muscle, which can be felt bulging on examination of the Female Pelvis, and especially the direction of the Levator Ani which arises at the upper border of the Obturator Internus from the White line and approaches the Rectum in a funnel-shaped manner to surround it and terminate in the External Anal Sphincter. This muscle may be considered to consist of many parts. At the commencement of the funnel it is markedly thickened (Constrictor of the Vagina).

Near the Obturator Internus Muscle are situated the Internal Pudic Vessels and Nerve (cf. Fig. 154) covered by Fascia (not seen in the figure). On either side of the Rectum are seen the Ischio-Rectal Fossae filled with fat.

The last part of the Rectum only as it runs obliquely downwards and backwards has been cut through; the upper part lies in front of the plane of section as viewed from behind.

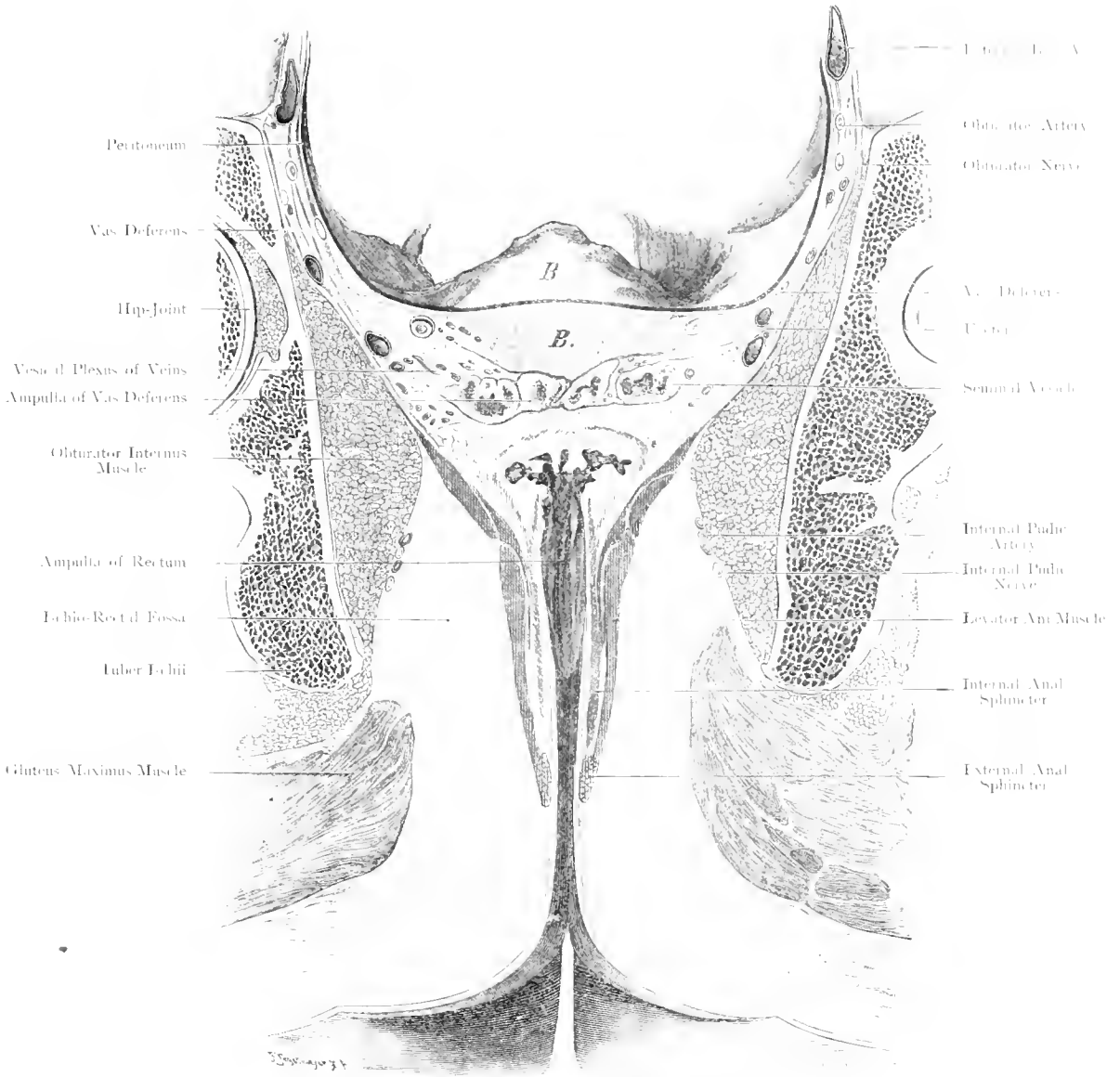


Fig. 153. Frontal Section through Male Pelvis – Levator Ani Muscle.

Seen from behind. — $\frac{2}{3}$ Nat. Size.

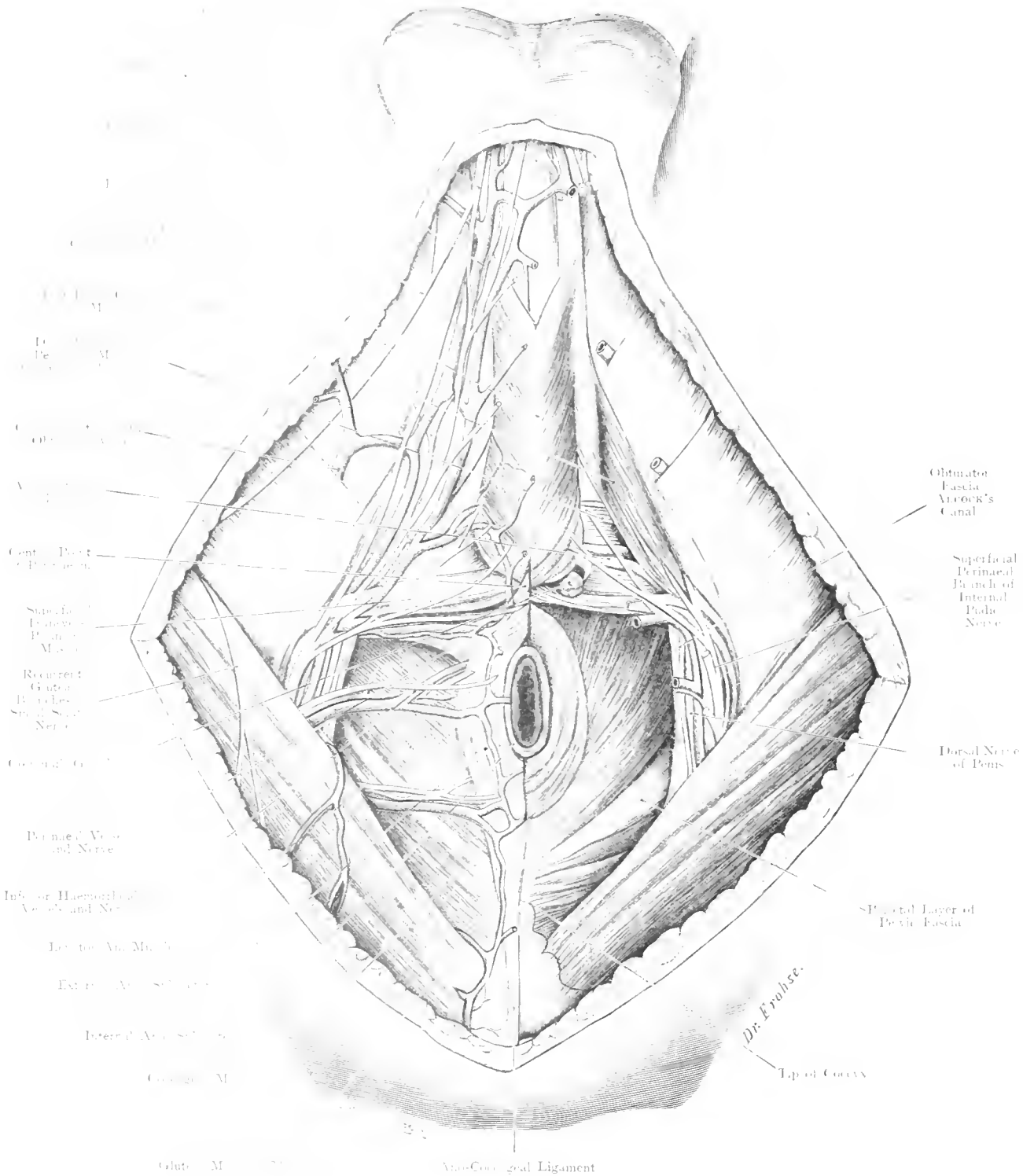


Fig. 154. Male Perinaeum, Superficial Layer.
Nat. Size.

Fig. 154. Male Perineum. I. Superficial Layer.

The Superficial Fascia and Vessels of the Perineum with the Ischio-Rectal fat have been removed. The Superficial Fibres of the External Sphincter Ani have been cut away in order to shew more distinctly the Levator Ani Muscle. On the right side the nerves and vessels have been dissected out; on the left side a deeper dissection, with exposure of COWPER'S Gland, has been carried out after partial removal of Vessels and Nerves.

The connection of the Sphincter Ani and Bulbo-Cavernosus Muscles shews the crossing over of the anterior fibres in the middle line. At the central point of the Perineum, where these muscles join, the Transverse Perineal Muscle is attached. The connection between the Sphincter and Levator Ani Muscles is merely indicated in this figure (cf. Fig. 153).

The Ischio-Cavernosus Muscles arising from the descending rami of the Pubis envelop the Corpora Cavernosa; the Bulbo-Cavernosus Muscles, united by a median raphé, lie in contact with the Corpus Spongiosum.

The Superficial Fascia of the Perineum (as far as it exists) and the Fascia covering the Levator Ani Muscles (Anal Fascia) have been removed. The Fascia covering the Obturator Internus Muscle is shewn in Sagittal Section (cf. Fig. 153).

The Superficial Arteries of the Perineum arise from the Internal Pudic (the terminal Branch of the Internal Iliac Artery):

1. Inferior Haemorrhoidal 1—3 small branches to Anus.
2. Superficial Perineal, runs transversely across either superficial or deep to the Transversus Perinaei.

Both these arteries are direct branches of the Internal Pudic Artery.

3. Terminal Branches of the Internal Pudic Artery:
 - a) Artery to Bulb, giving off the Transverse Perineal Artery and the Artery to COWPER'S Gland.
 - b) Dorsal Artery of the Penis (or Clitoris).

The Nerves of the Perineum are branches of the Internal Pudic Nerve (IIth, IIIth, IVth Sacral) which divide into 2 main branches, the Superficial Perineal and a Deep Branch. Both nerves are mixed, the Deep Branch is continued as the Dorsal Nerve of the Penis.

Fig. 155. Male Perineum. II. Recto-Urethral Muscle. Prostate.

The Perineum is exposed by a triangular window section. The Vessels and Nerves have been completely removed. By dividing and throwing back the Anal Sphincter the Recto-Urethral Muscle has been exposed to view and the Prostate exhibited by separation of some of the thin fibres of the Levator Ani.

In front of the Anus the divided Superficial Anal Sphincter fibres are shewn, anteriorly in the narrow space between them deeper fibres which pass transversely, further forward the retracted fibres of the Levator Ani Muscle; and between these fibres and the Central point stretches the Recto-Urethral Muscle which blends, posteriorly, with the Levator Ani Muscle and the Rectal Wall, anteriorly, with the Transverse Perineal Muscle, the Raphé and the fibres of the Bulbo-Cavernosus Muscles as well as the Membranous Portion (WALDEYER) of the Urethra. On either side of the Recto-Urethral Muscle the Prostate is exposed to view. (This dissection can be carried out in the course of operations.)

In the triangle between the Superficial Transverse Perineal Muscle and the Pubic Angle, the superficial fascia of the Perineum which covers the Ischio- and Bulbo-Cavernosus Muscles is seen on the right side. On the left side the fascia has been removed so that the muscles mentioned and the superficial layer of the triangular ligament are exposed.

The Superficial Fascia is a true superficial fascia, but the triangular ligament is an Aponeurosis (V. BARDELEBEN).

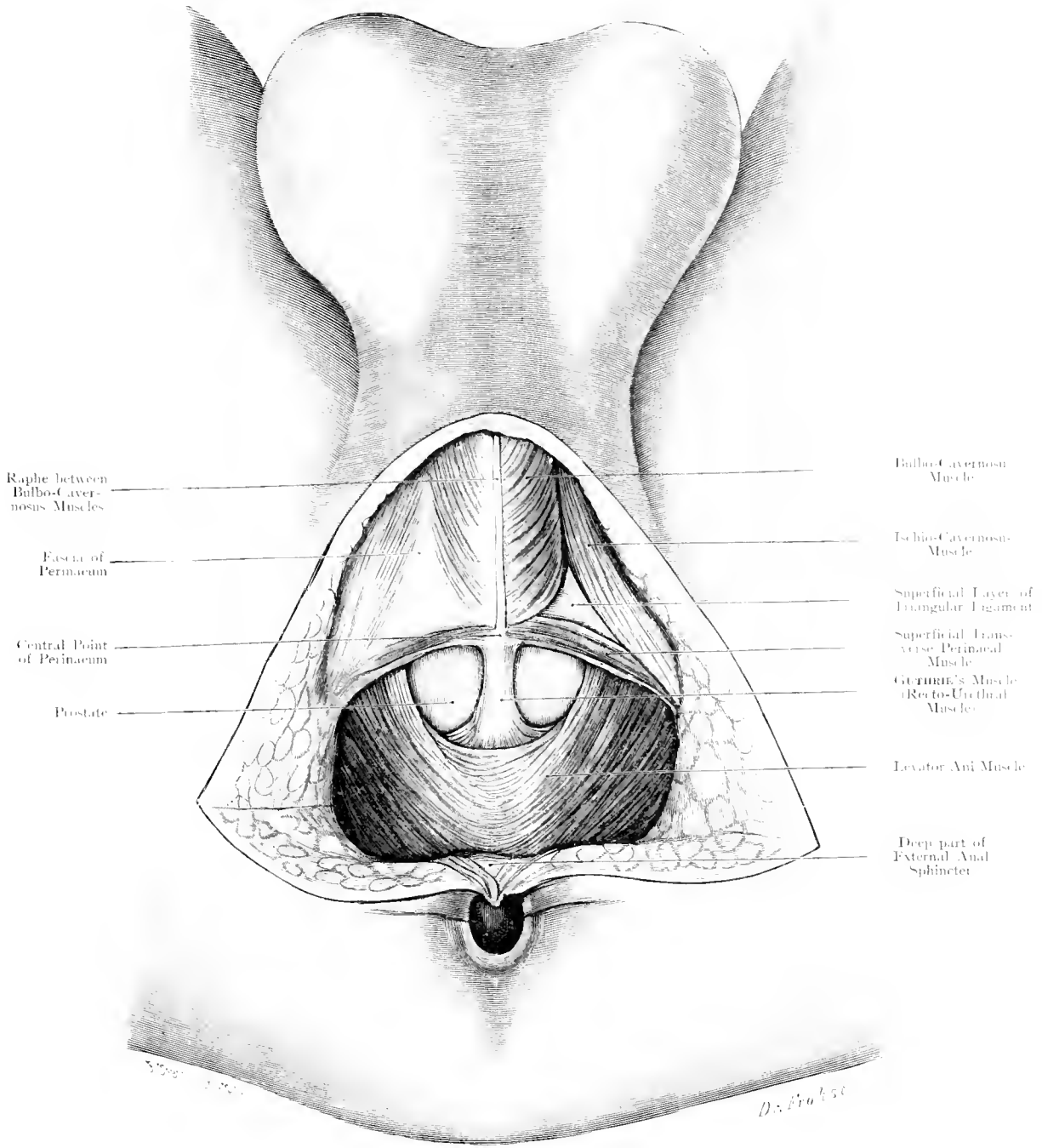
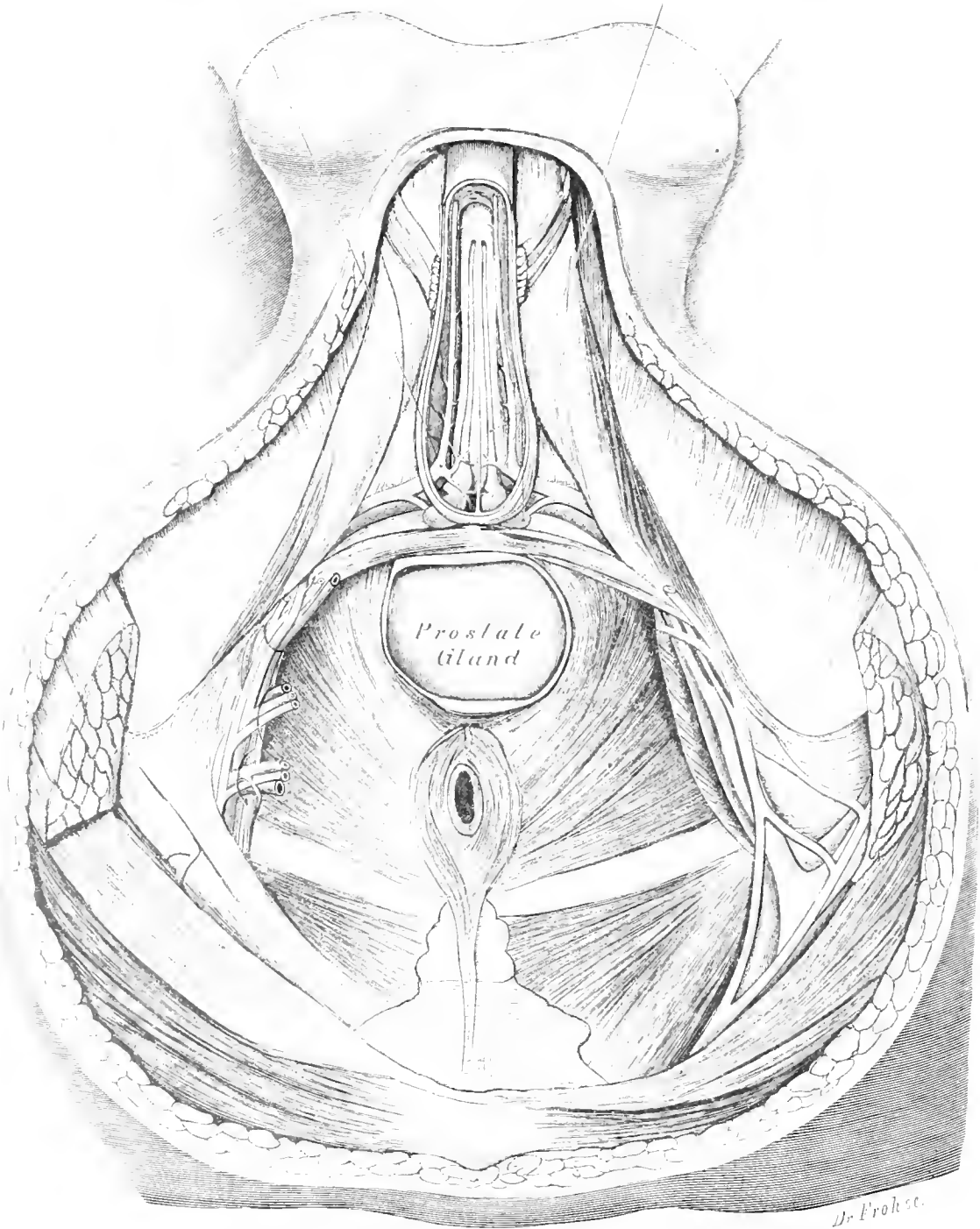


Fig. 155. Male Perinaeum. II. Recto-Urethral Muscle. Prostate.
 Nat. Size.



Prostate
Gland

Dr. Froese.

Fig. 156. Male Perinaeum. III. COWPER'S GLANDS WITH THEIR DUCTS.

Nat. Size.

Fig. 156. Male Perineum. III. Prostate. COWPER's Gland with Ducts. Terminal Branches of Internal Pudic Artery.

The Vessels and Nerves have been cut away in the posterior part of the Perineum. The Corpus Spongiosum has been denuded of its muscles and laid open so as to exhibit the course of the Artery to the Bulb and the Ducts of COWPER's Glands. The Prostate has been exposed by removal of the fibres of the Levator Ani and Sphincter Ani Muscles which cover it.

This figure is given for the demonstration of the position of COWPER's Glands and their ducts which vary from $1\frac{1}{5}$ th to $3\frac{1}{5}$ ths inches in length; whereas their diameter is 0.02 inch and their lumen 0.01 inch.

The Glands themselves, not always symmetrical, are situated about $\frac{1}{5}$ inch from the middle line on either side of the membranous portion of the Urethra between the 2 layers of the triangular ligament, near its posterior border and between the fibres of the Compressor Urethrae. These glands are lobulated or mulberry-shaped, hard, almost white in colour, about $\frac{1}{8}$ to $\frac{2}{5}$ inch long. They belong to the racemose type of glands and vary according to the individual and age but are frequently unobserved owing to incomplete dissection.

The Artery to the Bulb (a branch of the Internal Pudic) consisting of two vessels (cf. Fig. 154), supplies the Bulb, Prostate and the structures which lie between the 2 layers of the triangular ligament, e. g. Compressor Urethrae Muscle, Membranous Portion of Urethra, COWPER's Gland and Corpus Spongiosum as far as the Glans Penis. At this point it anastomoses with the Dorsal Artery of the Penis and through this with the Arteries of the Corpora Caverosa.

Fig. 157. Male Perineum. IV. Urogenital Triangle. Ampulla of Rectum.

The deep layer of the triangular ligament is exposed on the left side by removing the superficial layer of the triangular ligament and the Corpus Spongiosum as far as the middle line; the Urethra, COWPER's Gland, the left Corpus Cavernosum and the Dorsal Artery of the Penis have, however, been preserved.

In front of the Transverse Perineal Muscle, the Compressor Urethrae Muscle (the Muscle of the Urogenital Triangle of WALDEYER) is shewn. This muscle arising from the bony margin of the Pelvis (Ischium and Pubis) and the fibrous portion of the Ischio-Cavernosus Muscle, passes to join its fellow of the opposite side in the middle line. The outlines of the Bulb are delineated in blue; COWPER's Glands and Duct which are not exposed by the dissection (cf. Fig. 156) are also indicated.

Anteriorly the Compressor Urethrae Muscle is connected with the Transverse Pelvic Ligament which may be looked upon as an aponeurotic covering of the muscle or as a blending together of the superficial and deep layers of the triangular ligament. WALDEYER has named this the Preurethral Ligament; emerging through the fibres near the anterior border of the Compressor Urethrae Muscle, the Dorsal Artery of the Penis is seen; this vessel a branch of the Internal Pudic soon gives off the artery to the Corpus Cavernosum. The chief object of this figure is to give an idea of the position and size of the Ampulla of the Rectum when distended (red). In this part of the Rectum which lies above the Anus and which is capable of considerable distension faeces may, and frequently do, accumulate if the bowel is not emptied. On the right side an abnormal Muscle the Ischio-Bulbosus is shewn between the Ischio- and Bulbo-Cavernosus Muscles.

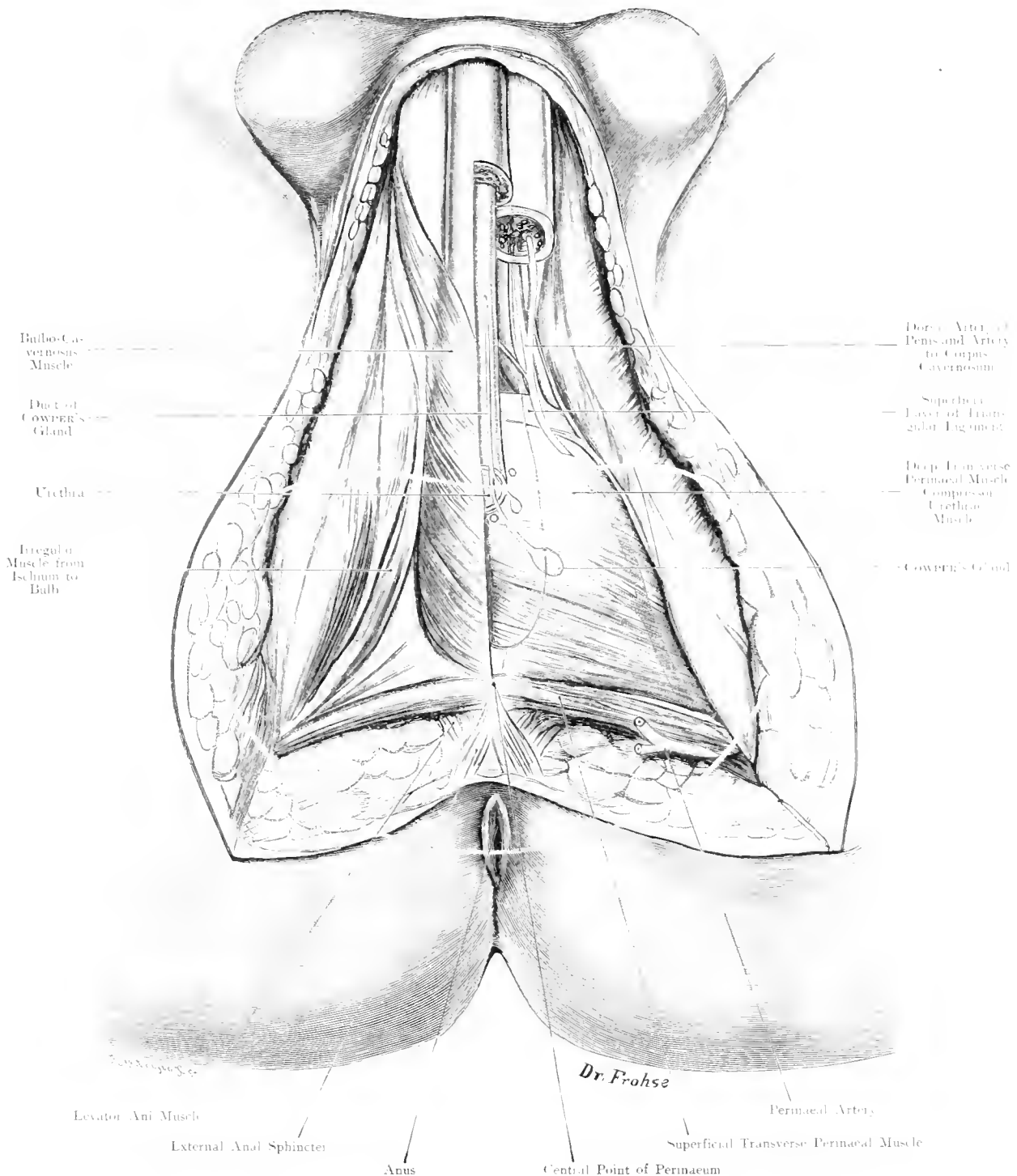


Fig. 157. Male Perinaeum. IV. Uro-Genital Triangle. Ampulla of Rectum.
 Nat. Size.

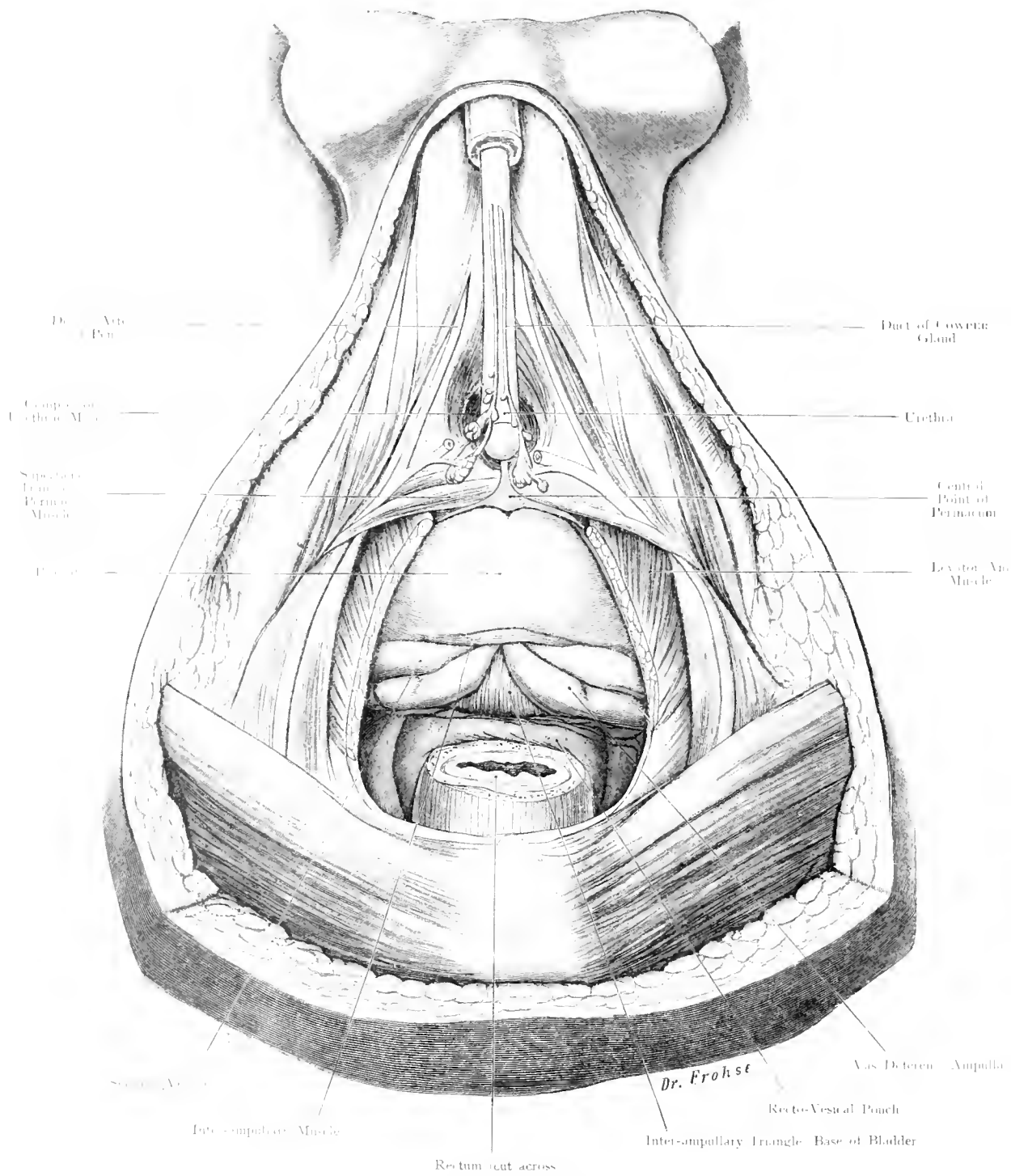


Fig. 158. Male Perinaeum. V. Prostate, Seminal Vesicles, Urethra in its course through the Uro-Genital Triangle.

Nat. Size.

Fig. 158. Male Perineum. V. Prostate, Seminal Vesicles, COWPER's Glands, Urethra passing through the Urogenital Triangle.

Anus and surrounding parts — the Sphincter Ani completely and the Levator Ani Muscle partially (window-section) — have been removed; Prostate, Seminal Vesicles, Bladder and DOUGLAS' Pouch are partly exposed from below and in front, also the central point of the Perineum in front of the Prostate Gland.

Passing from the Tip of the Coccyx forwards to the anterior margin of the cut Levator Ani Muscle the following parts are seen in order: — Transverse Section through the Rectum, Peritoneum of DOUGLAS' Pouch, WALDEYER's Interampullary Triangle with the base of the Bladder; on either side lie the Ampullae of the Vasa Deferentia with the Seminal Vesicles anteriorly. Between the last named and the Prostate the Interampullary Muscle runs transversely.

Next in order is the Prostate Gland with the central point of the Perineum directly in front, whereas further forward are exhibited to view the Urethra and the accessory glands entering the Ducts of COWPER's Glands.

Special attention is called to KALISCHER's Urogenital Sphincter Muscle which is very variable, yet possesses many anatomical and physiological relations. At various times this has been described by JOHANNES MÜLLER as the Constrictor of the Membranous portion of the Urethra, by FR. ARNOLD as the Urethral Muscle; as GUTHRIE's muscle; by CRUVEILHIER as the Transverse Urethral and Ischio-Urethral Muscle; by KRAUSE and KOHLRAUSCH as the Transverse Urethral Muscle; J. HENLE associates it with the Deep Transverse Perineal Muscle (Compressor Urethrae). Cf. the next figure.

Fig. 159. Male Perineum. VI. Pubic Region. Levator Ani Muscle.

The Levator Ani Muscle has been exposed, a part of the Urethra below the point at which it traverses the Triangular Ligament has been removed. The vessels are preserved but the nerves, except the Dorsal Nerve of the Penis, have been cut away.

This figure shews almost the complete surface of the Levator Ani Muscle with its different parts and the incomplete gap anteriorly. Some of the veins which traverse it have been preserved on the left side. Posteriorly the close relation which the Coccygeus bears to this muscle (of which it really should be regarded as a part) is seen.

Furthermore through the gap in the anterior part of the Levator Ani, the Recto-Urethral Muscle (cf. Fig. 155), the Compressor Urethrae Muscle encircling the Urethra by some of its fibres whereas others pass transversely across in front of it can be seen. The Transverse Pelvic Ligament (or the Pre-urethrae Ligament of WALDEYER) runs across in front of a gap (for the transmission of veins). Between this ligament and the Suspensory Ligament of the Penis which is attached to the lower border of the Symphysis, is situated the gap for the passage of the superficial vessels of the Penis.

The Dorsal Arteries of the Penis are seen anastomosing in this figure, and the Dorsal Vein is seen to have bifurcated into Left and Right branches. The lumen of the Urethra, where it passes through the triangular ligament is almost circular if the mucous folds, which become obliterated during the passage of urine or of an instrument, be neglected. In this Distal portion of the Urethra as it is embedded in the Corpus Spongiosum the Lumen is more oval. Here the separation between the Corpus Spongiosum and Corpora Caverosa is most distinct.

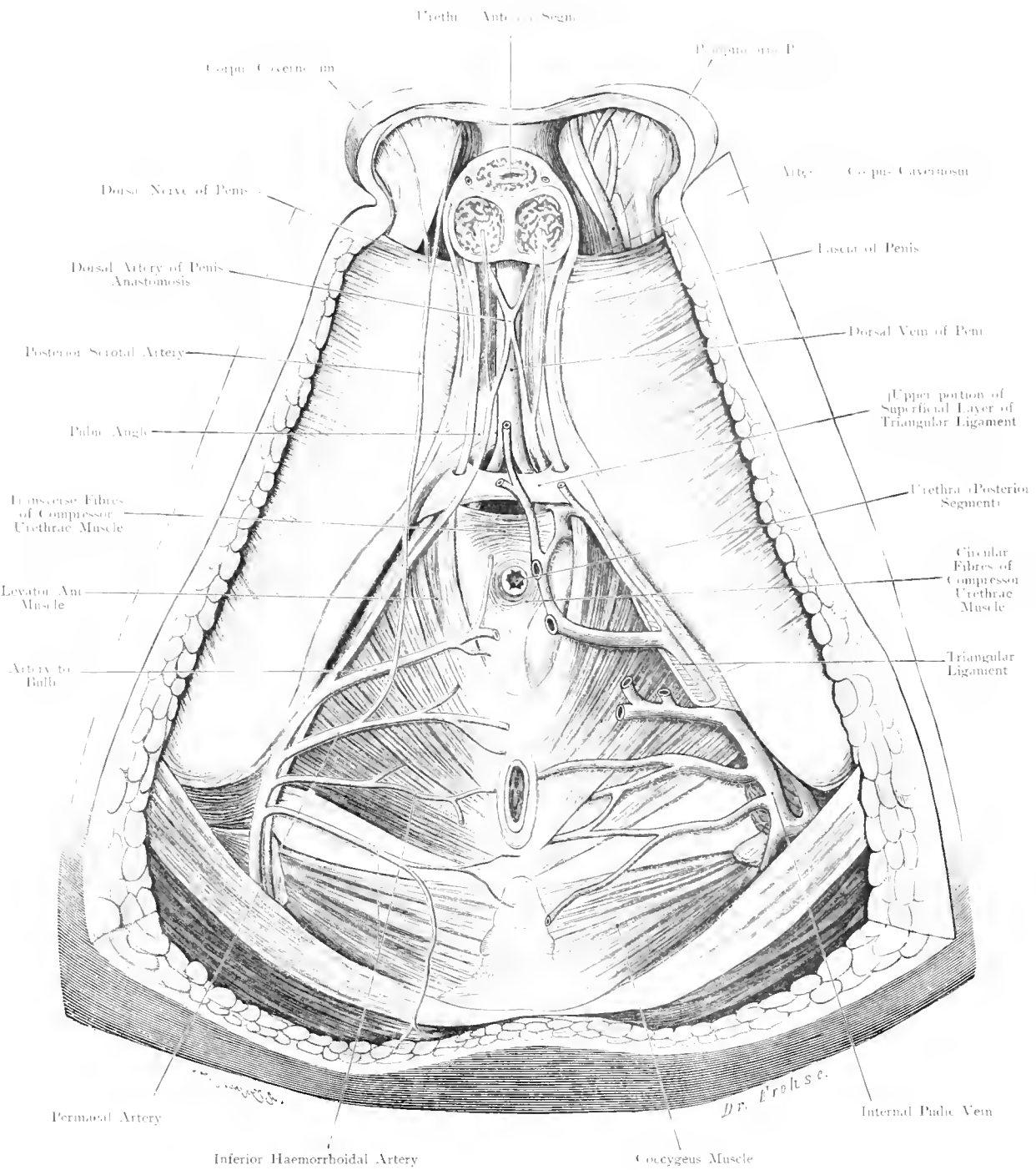


Fig. 159. Male Perinaeum. VI. Pubic Region. Levator Ani Muscle.
 Nat. Size.

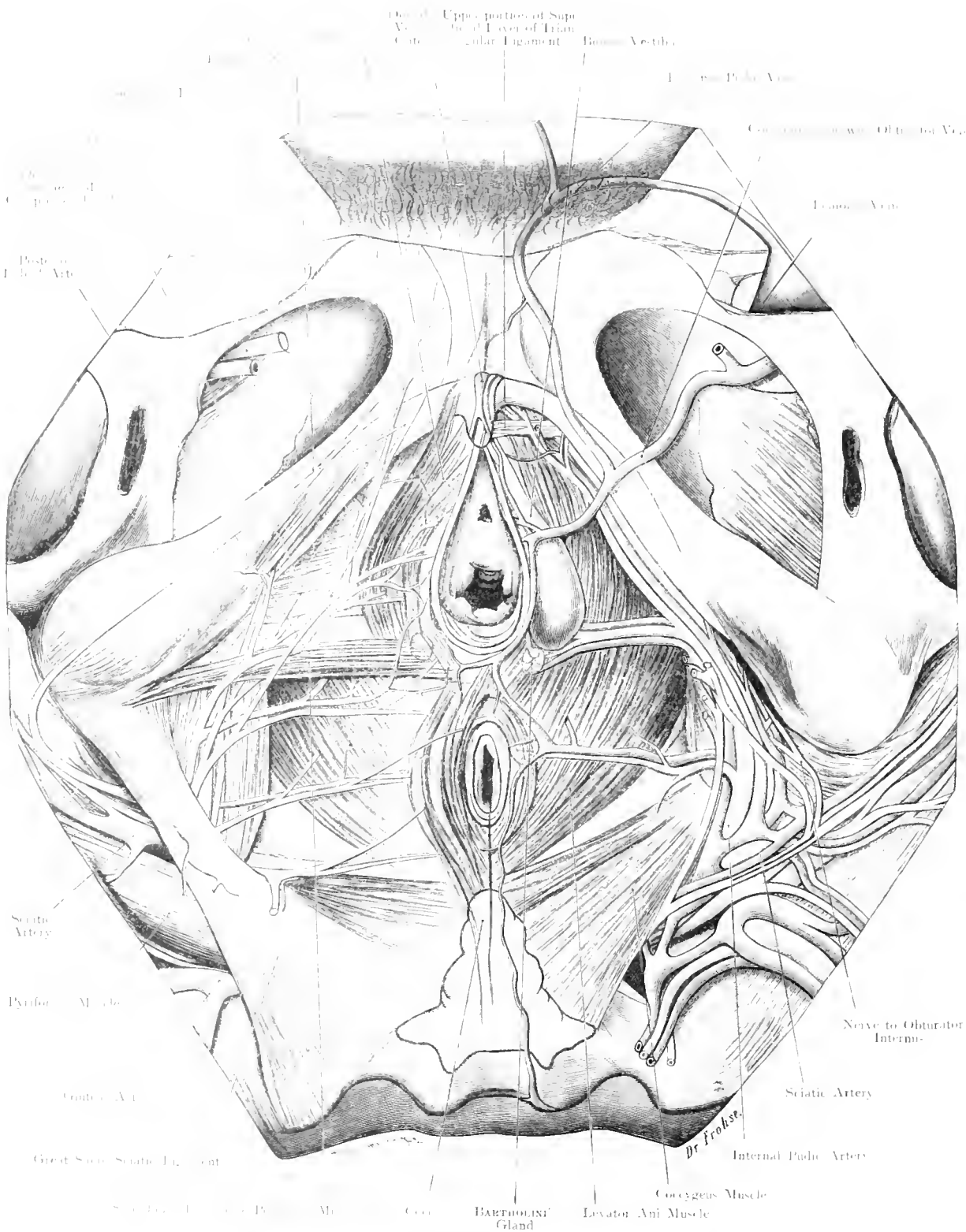


Fig. 160. Female Perinaeum.

Nat. Size.

Fig. 160. Female Perineum.

Body of a Young Female. The skin and Superficial Fascia, except of the Mons Veneris, have been removed. On the right side the superficial, on the left side the deep layer of the Perineum is shown: on both sides the Os Innominatum is exposed: on the right the Great Sacro-Sciatic Ligament is preserved. Vessels and Nerves are entirely preserved on the right side, but only partly on the left.

The chief difference between the Male and Female Perineum consists in the following:—

Instead of the small urethral aperture in the triangular ligament of the Male, there exists in the Female, a much wider opening for the Vestible. Whereas the Corpora Spongiosa are joined in the Male to form the Corpus Spongiosum, the corresponding parts in the Female remain distinct, as the Bulb of the Vestible. So that the Bulbo-cavernosus Muscles in the Female remain distinct on either side: whereas in the Male, they come together in a median raphé. A connection of the superficial fibres of the Bulbo-Cavernosus, with the Sphincter Ani (like a figure 8), is likewise present in the Female. The Bulbs lie on either side of the Vestible at the base of the Labia Minora. These Bulbs of the Vestible contain large quantities of Blood, so that injury to them (e. g. during labour), may produce serious hæmorrhage. From these there extends forwards a Venous Plexus which, near the Frenum of the Clitoris, passes into the deeper tissues at the side of the Clitoris communicating at its mesial aspect with the Veins of the Clitoris (particularly those of the Glans of the Clitoris). The Corpora Cavernosa of the Clitoris are much smaller than the Bulbs of the Vestible or of the corresponding parts in the Male. They arise from the descending Ramus of the Pubis on either side, and unite under the Suspensory Ligament to form one shaft (divided by an imperfect septum); the Clitoris is curved with its concavity downwards and backwards, so that its extremity, the Glans, points towards the Vestible. Many minute veins of the Glans unite to form the Dorsal Vein of the Clitoris, which opens under the Suspensory Ligament into the Pubic Plexus. (Cf. Male.)

The Bulb of the Vestible having a position different from the corresponding parts in the male, the glands, corresponding to COWPER'S Glands, i. e. BARTHOLINI'S Glands lie internally and behind the Bulbus Vestibuli.

The Pubic Arch being much wider, and the Ischio-Cavernosus Muscle less developed in the Female, the Urogenital Triangle is larger than in the Male. In Virgins, the muscles in the subpubic region are well developed. During labour, the Vestible and surrounding parts are stretched to a maximum and even frequently torn, so that a perfect restitution to the normal state never occurs. The Vestible and neighbouring parts remain stretched after labour, so that the muscles become smaller and degenerated, or replaced by connective tissue and fat.

The "True Perineum" which lies between the Vestible and Vagina in front, the Anus and Rectum behind, is neither broad nor strong. "Rupture of the Perineum" is therefore a frequent occurrence during labour. It falls to the duty of the Obstetrician and Gynaecologist, to prevent this rupture by appropriate mechanical intervention, to detect injuries and to suture them, and to cure Recto-Vaginal Fistulae.

Fig. 16r. Organs of Male Pelvis, seen from behind: Arteries to the Seminal Vesicles.

AFTER MAX FRÄNKEL (modified).

A Frontal Section has been carried through the Pelvis which is here viewed from behind. The Pelvic Fascia and Coccygens Muscle have been preserved. The Rectum has been cut across at the level of the upper border of the Prostate and its upper portion removed, while the lower portion is thrown downwards and backwards. The anterior abdominal wall is preserved as far as the Umbilicus; the Peritonæum at the point of junction of the Visceral with the Parietal Portion is cut off, so that not only the Rectum and Prostate but also the Seminal Vesicles and a part of the Bladder are exposed. The soft parts of the Gluteal region are only removed on the left side.

The object of this figure is twofold, firstly, to complete the conception of the Male Pelvic Organs (cf. Fig. 162), and secondly, to exhibit the branches of the Internal Iliac Artery, the inner terminal branch of the Common Iliac Artery.

The Ureter passes into the true pelvis in front of the Internal Iliac Artery, which gives off its Ureteric branch to the posterior aspect of this Duct. The next branch in order is the "Umbilico-Vesical Trunk" (Umbilical Artery), which gives off from its patent first portion, one or several branches (e. g. Superior Vesical, to the upper part of the Bladder, which anastomoses with the Inferior Vesical).

The 3rd branch is generally the Artery to the Vas (Uterine in the Female); this artery reaches the Vas at a point midway between the Internal Abdominal Ring and the Fundus of the Bladder, and divides into an ascending branch which accompanies the Vas through the Inguinal Canal to the Scrotum and anastomoses with the Spermatic Artery, and a descending branch which is distributed to the Ampulla of the Vas and the Seminal Vesicle and anastomoses with branches of the Inferior Vesical and Middle Haemorrhoidal Arteries.

The 4th branch is usually the Inferior Vesical which may be replaced by numerous small branches ramifying over the Bladder and supplying the Prostate and Seminal Vesicle.

The branches which pass to the Seminal Vesicles from above are called by MAX FRÄNKEL (Die Samenblasen des Menschen, mit 4 Taf., Berlin 1901) Vasa posteriora superiora Vesicularum Seminalium: the lower anastomosis he calls Vasa posteriora inferiora Vesicularum Seminalium. An irregular vessel, the Inferior Accessory Vesical Artery may take part in this anastomosis.

The Vasa posteriora superiora are derived from the Middle Haemorrhoidal and the Artery to the Vas. The Vasa posteriora inferiora from the Middle, Haemorrhoidal, Accessory Inferior Vesical and the Superior Haemorrhoidal. The Vasa anteriora from the Inferior Vesical (Accessory Vesical if present) and the Artery to the Vas.

The Vessels to the Ampulla are derived from the Artery to the Vas, the Middle Haemorrhoidal and the Inferior Vesical.

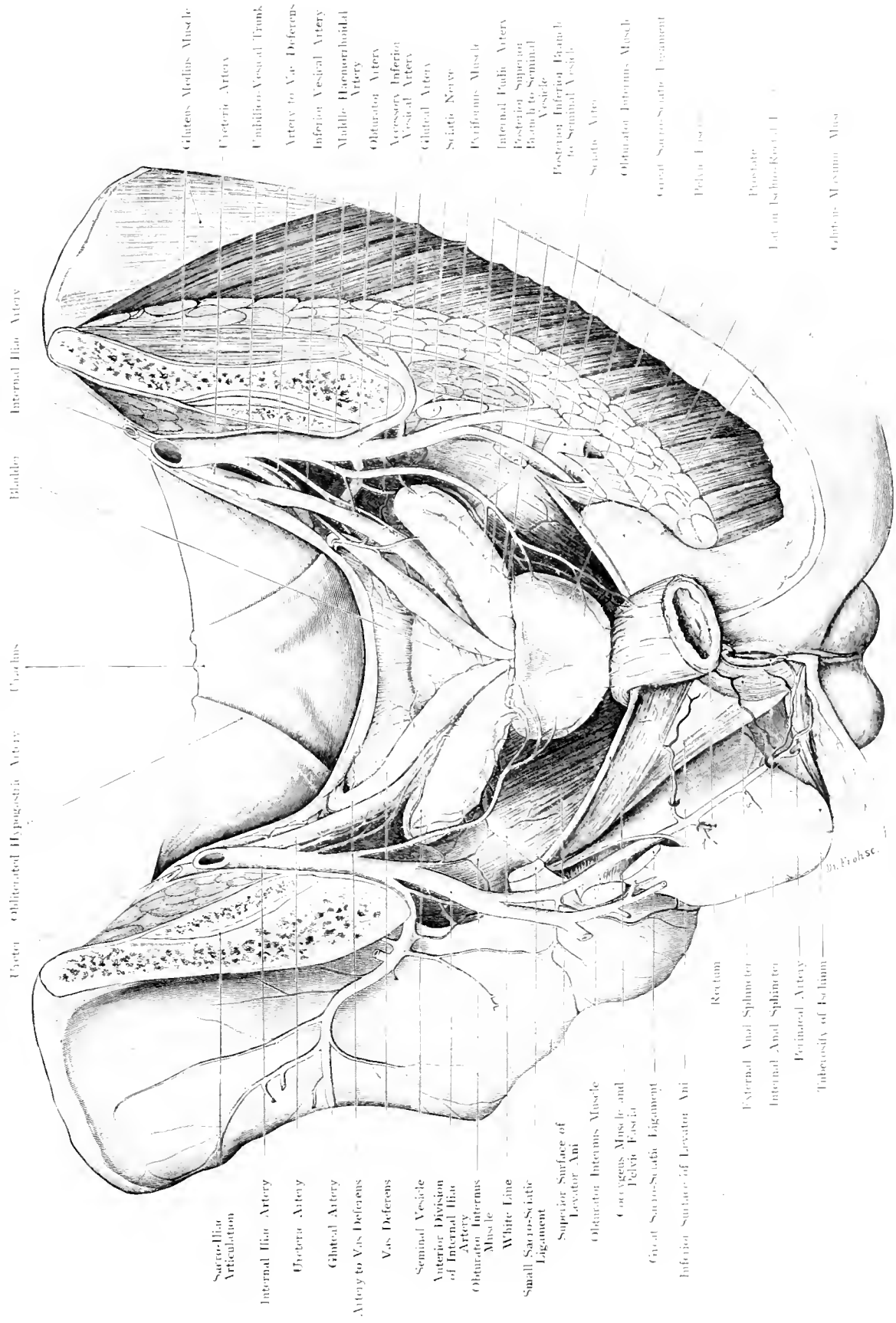
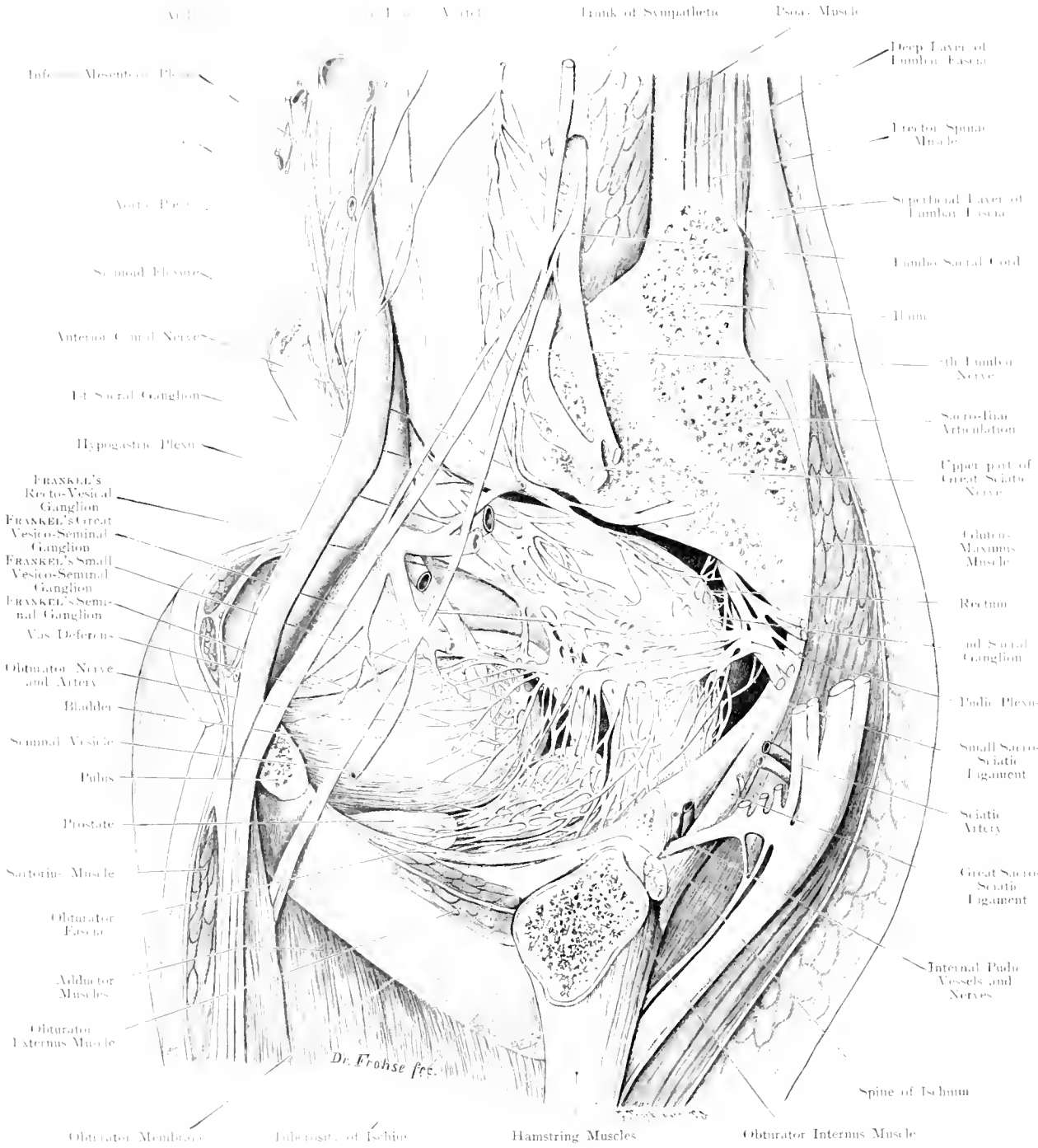


Fig. 161. Organs of Male Pelvis, seen from behind; Arteries to the Seminal Vesicles.
 After MAN FRANKEL (modified). — ^a Nat. Size.



Dr. Frohse fec.

Fig. 162. Organs of the Male Pelvis, seen from the left side. Nerves to the Seminal Vesicles.
 Modified after MAX FRÄNKEL. — $\frac{2}{3}$ Nat. Size.

Fig. 162. Organs of Male Pelvis, seen from the left side. Nerves to the Seminal Vesicles. Modified after MAX FRÄNKEL.

A sagittal section has been made through the left half of a male pelvis. The section passes through Sacro-Iliac Articulation, Tuberosity of the Ischium and Horizontal Ramus of the Pubis; this gives a view from the left side of the Pelvis, — its Viscera and Nerves —. Most of the Blood Vessels have been removed.

The Inferior Mesenteric Sympathetic Plexus runs from the Artery of this name to the Aorta around which it forms the Abdominal Aortic Plexus, this is continued into the Hypogastric Plexus lying in front of the upper part of the Rectum. A little lower down lies the large Recto-Vesical Ganglion of FRÄNKEL which is connected with the 1st Sacral Ganglion by a large nerve. From this 2 or 3 branches pass to a yet larger Ganglion (Great Vesico-Seminal Ganglion). Some of the branches of the Recto-Vesical Ganglion go to the Plexus surrounding the Rectum. Several small branches pass from the Pudic Plexus to the Great Vesico-Seminal Ganglion and a delicate twig to the Seminal Vesicle directly.

Several large and small branches pass from the Great Vesico Seminal Ganglion, one group runs in front of the Ureter, supplying it and terminating in the Posterior Wall of the Bladder, where they either run superficially for some distance, or penetrate at once into the Muscular Coats; another group runs directly downwards; it contains filaments to the Bladder and the Upper Border of the Seminal Vesicle, amongst these is a thicker branch which ramifies around the Vesical Orifice of the Ureter. The bulk of the fibres which leave the Ganglion pass to the Upper pole of the Seminal Vesicle and form a large plexus around it.

Below the Great Vesico-Seminal Ganglion lies the Small Vesico-Seminal Ganglion, directly behind and internal to the Vesical Orifice of the Ureter. The roots of this Ganglion are derived directly from the Recto-Vesical Ganglion but there also exists a connection with the Great Vesico-Seminal Ganglion. Fibres are distributed directly to the Ureter and Vas Deferens, a few run behind the Ureter to the Fundus of the Bladder, while 2 or 3 larger branches go to the upper pole of the Seminal Vesicle, here they anastomose with the fibres from the Great Vesico-Seminal Ganglion.

A very careful dissection exposes two strata of nerves (not seen in the figure), an upper going directly to the Prostate, and a lower lying on the Seminal Vesicle. Both layers anastomose with each other. In this lower stratum, FRÄNKEL found 2 other small ganglia which he calls Seminal Ganglia. From the lower part of the Hypogastric Plexus fibres also run directly to the Seminal Vesicles.

JOHANNES MÜLLER called (in 1835) this part of the Plexus "the Inferior Hypogastric Plexus". MAX FRÄNKEL proposes to divide this into a Superior, a Middle and an Inferior Haemorrhoidal Plexus. The latter would be applied to the Plexus on the Rectum below the Levator Ani.

Fig. 163. Gluteal Region.

A large window has been cut out of the Gluteus Maximus Muscle; from the Gluteus Medius and the Piriformis Muscles, smaller pieces have been removed.

Under an extremely thick layer of superficial fascia, lies the Gluteus Maximus Muscle, which covers nearly the whole of the Gluteal Region. The following bony prominences can be felt: the Crest of the Ilium, the Great Trochanter and with less ease, because covered by the Gluteus Maximus, the Tuberosity of the Ischium. The upper and outer part of this muscle passes over the posterior and outer aspect of the Great Trochanter and is inserted into the Fascia Lata. A Superficial Trochanteric Bursa placed within the superficial fascia is rare. The Gluteus Maximus covers important vessels and nerves; at the upper border of the Piriformis Muscle, emerging with it through the Great Sacro-Sciatic Foramen, is the Gluteal Artery, a branch of the Internal Iliac. Outside the Pelvis, the trunk of this vessel is short, and soon divides into 5—7 branches to the Glutei Muscles. A large branch (Superficial Branch) becomes more superficial by emerging between the Gluteus Medius and Piriformis Muscle, to run under cover of the Gluteus Maximus. Another large branch (Deep Branch), runs between the Gluteus Medius and the Gluteus Minimus, this divides into a Superior and an Inferior Branch, the former of which follows the middle curved line. Deep to these vessels lies the Superior Gluteal Nerve. At this point a variety of Sciatic Hernia may occur.

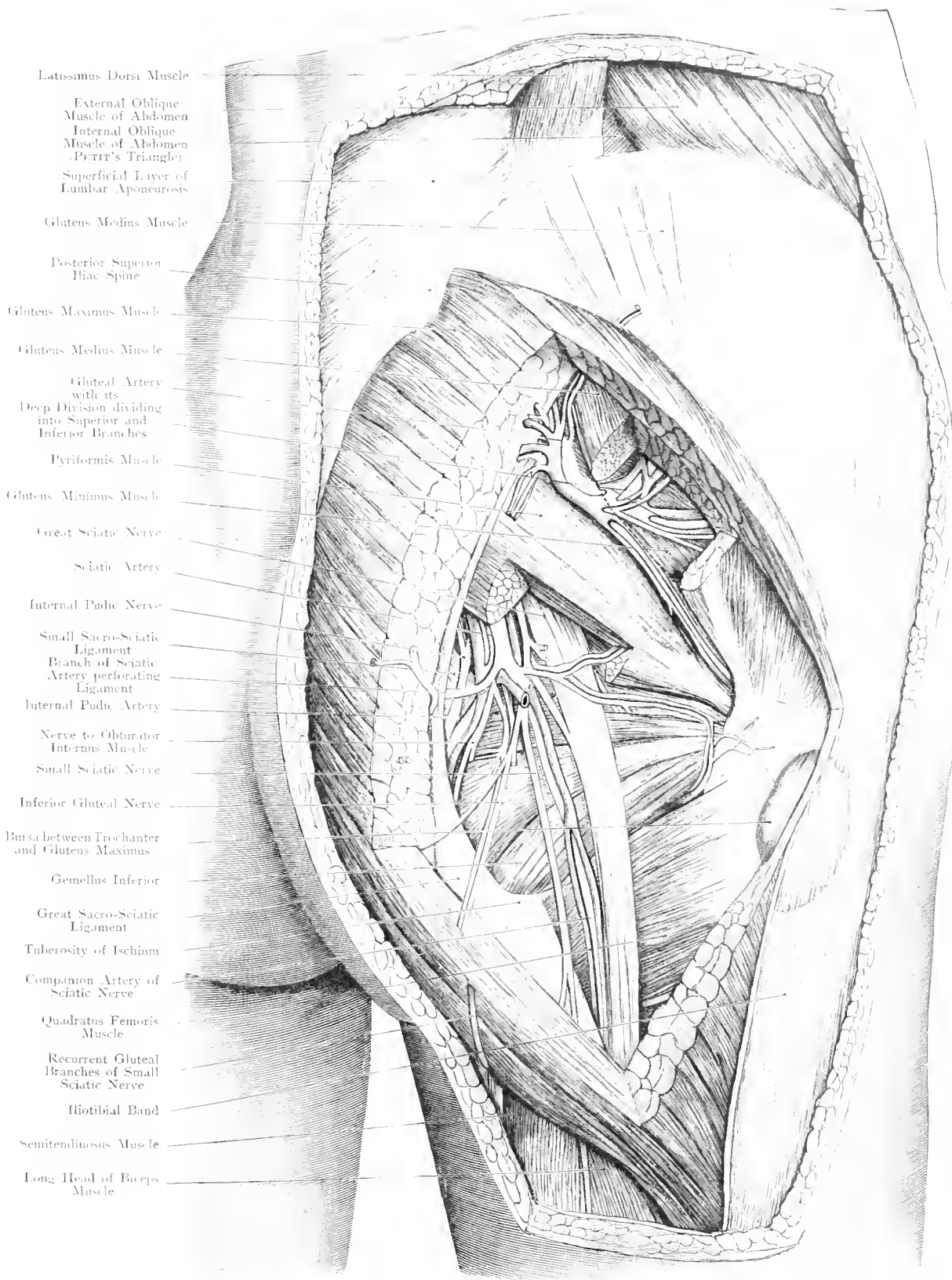
At the lower border of the Piriformis Muscle, the Great Sciatic Nerve emerges at a point corresponding to the junction of the inner and middle thirds of a line drawn from the Great Trochanter of the Femur to the Tuberosity of the Ischium. At the lower border of the Gluteus Maximus Muscle, the Great Sciatic Nerve is easily exposed, because at this point, it is only covered by skin and superficial fascia; at a lower level it is covered by the long head of the Biceps Muscle.

Internal to the Great Sciatic Nerve, lies the Sciatic Artery, a slightly smaller vessel than the Gluteal Artery. This vessel gives off the Companion Artery to the Sciatic Nerve. Between the Sciatic Artery and the Great Sciatic Nerve lies the Nerve to the Gluteus Maximus Muscle, — the Inferior Gluteal Nerve —.

Most internally, the Internal Pubic Artery emerges at the lower border of the Piriformis Muscle, and after crossing the Spine of the Ischium or the smaller Sacro-Sciatic Ligament re-enters the Pelvis through the Sacro-Sciatic Foramen, but does not enter the Pelvic Cavity (cf. Fig. 150).

A second variety of Sciatic Hernia may protrude below the Piriformis Muscle, where the structures mentioned leave the Pelvis; a third variety may occur at the Lesser Sacro-Sciatic Foramen.

The Hip-Joint lies under cover of the Piriformis Muscle in front of the Obturator Internus and Externus Muscles, and in consequence is scarcely accessible from behind. An important Bursa lies between the Tuberosity of the Ischium and the soft parts over it, e. g. the Sciatic Bursa.



- Latissimus Dorsi Muscle
- External Oblique Muscle of Abdomen
- Internal Oblique Muscle of Abdomen (Perrin's Triangle)
- Superficial Layer of Lumbar Aponeurosis
- Gluteus Medius Muscle
- Posterior Superior Iliac Spine
- Gluteus Maximus Muscle
- Gluteus Medius Muscle
- Gluteal Artery with its Deep Division dividing into Superior and Inferior Branches
- Piriformis Muscle
- Gluteus Minimus Muscle
- Great Sciatic Nerve
- Sciatic Artery
- Internal Pudic Nerve
- Small Sacro-Sciatic Ligament
- Branch of Sciatic Artery perforating Ligament
- Internal Pudic Artery
- Nerve to Obturator Internus Muscle
- Small Sciatic Nerve
- Inferior Gluteal Nerve
- Bursa between Trochanter and Gluteus Maximus
- Gemellus Inferior
- Great Sacro-Sciatic Ligament
- Tuberosity of Ischium
- Companion Artery of Sciatic Nerve
- Quadratus Femoris Muscle
- Recurrent Gluteal Branches of Small Sciatic Nerve
- Iliotibial Band
- Semitendinosus Muscle
- Long Head of Biceps Muscle

Fig. 163. Gluteal Region.

$\frac{3}{4}$ Nat. Size.

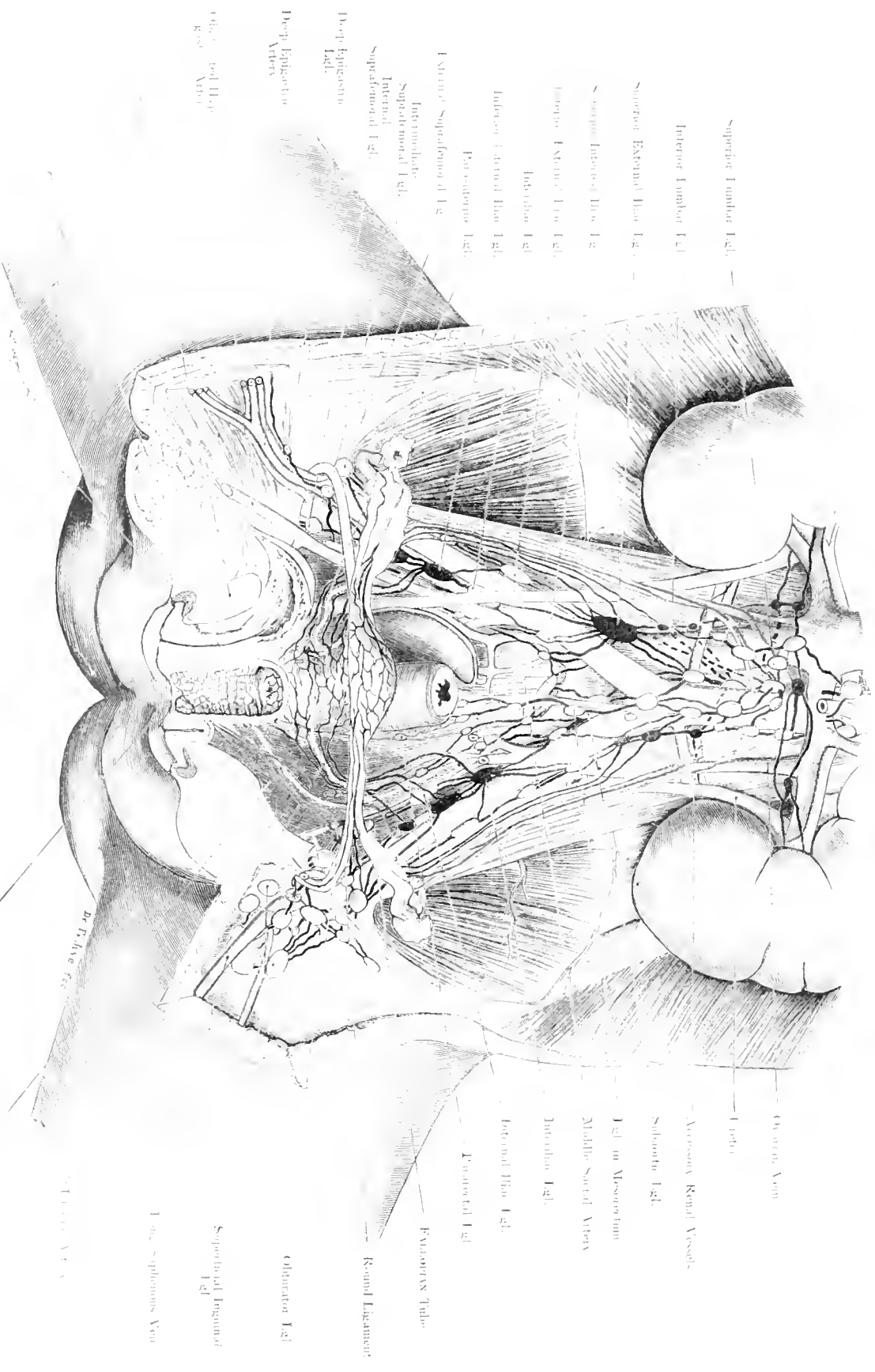


Fig. 164. Lymphatic Channels and Glands of the Female Pelvis. Child. Modified after C. HERGENROTTER. Nat. Size. Lg., Lymphatic Channel.

Fig. 164. Lymphatic Channels and Glands of the Female Pelvis. (Child)

Female Infant, aged 1 year. The Bladder and Vaginal Wall are slit open in the middle line. On the Left: Half of the Bladder, the lower portion of the Uterus, and a part of the Vagina have been removed (Lymphatics after C. Brunns). Lymphatic Vessels and Regional Glands of the Uterus and Kidneys, black; of the Ovary, red; of the Vagina, blue; of the External genitalia, yellow; glands unconnected with the genital organs, not coloured.

The best nomenclature of the Pelvic Lymphatic Glands is derived after the vessels around which they are found. Of the Pelvic Viscera, it is only in the neighbourhood of the Rectum, that large lymphatic glands are found; those near the Bladder and Uterus are small and very inconstant. Distinction is made between the glands of the False Pelvis and the glands of the True Pelvis. One group of the former lies directly above POUPART'S Ligament, receiving the lymph from the lower limb (Suprafemoral); this group may be subdivided into two sets, Internal and External. The External set receives the lymphatics which accompany the Femoral Vessels; the Internal set receives the efferent lymphatics from CROQUET'S Gland; between these two sets, a gland is occasionally found receiving the lymphatics which accompany the Deep Epigastric Vessels. The glands along the Iliac Vessels are called Iliac Glands, the gland along the outer border of the External Iliac Artery is called the External Inferior Iliac Gland, and that along the inner border of the Common Iliac Artery, the Internal Superior Iliac Gland.

Above the bifurcation of the Aorta on the posterior Abdominal Wall, Superior and Inferior Lumbar Glands are distinguished, although there is no definite demarcation between them. At a lower level, a large gland, the Subaortic Gland is sometimes found.

Owing to great variation in position, number and size, it is difficult to classify the glands of the True Pelvis. Internal and External groups are recognised according to their relations to the Internal Iliac Artery. Particular mention is here made of the Inter-iliac Glands at the bifurcation of the Common Iliac Artery, the Gluteal Glands, around the Gluteal Artery, the Pubo-Sciatic Glands around the Sciatic and Internal Pudic Arteries,

and the Obturator Glands at the Obturator Foramen. The lymphatics of the External Genitals as far as the Hymen, pass chiefly to the Superior Internal Inguinal group, thence to the Internal Suprafemoral set, and onwards partly to the Inferior Internal Iliac Glands, partly to the Obturator Gland. This gland is also regional for the lower lymphatics of the Vagina (coloured blue). The upper lymphatics of the Vagina pass to the Internal Group of glands of the True Pelvis, rarely some pass along the floor of the Pelvis to the Para-rectal Gland. The Regional Lymphatic Glands (black) of the Uterus are: for the Cervix, the Inferior Internal Iliac Glands; for the Body, the same glands and the Inter-iliac Groups; at the Fundus there are connections with the lymphatics of the *Fallopian Tube* and the Round Ligament, these are especially important because they lead to the Superficial Inguinal Glands. The most important lymphatics do not follow the Uterine Artery, but the Ovarian Artery and thus pass to the Inferior Lumbar Glands. A Para-uterine Gland may be present in the Parametrium where the cervix and body meet at the bifurcation of the Uterine Artery (WALDEYER). The large lymphatics of the Ovary (red) go to the Superior Lumbar Glands, and there meet the Renal Lymphatics. (On the left side, however, there is an intermediate lymphatic gland.) The lymphatics accompanying the Accessory renal vessels go to the Inferior Lumbar Glands.

The lymphatic system of the Female Genitals accordingly comprises nearly the entire lymphatic chain from the Inguinal region upwards in the Abdominal Cavity, as far as the lower border of the Renal Veins, so that the further up towards the Fundus Uteri the disease may have spread, the smaller is the chance of operating on the Regional Lymphatic Glands.

Fig. 165. Frontal Section through the (Right) Hip-joint.

This section is not quite vertical, but is directed obliquely from above and in front, downwards and backwards. The Hip-joint is the most deeply situated of all the large joints in the body, and is covered on all sides by thick muscles.

Access is obtained more easily from the outer side over the Great Trochanter, because in this situation there are fewer Vessels and Nerves. The Socket of the joint is incompletely covered by cartilage at the Fossa Acetabuli which is filled with fat. At this point, the bony wall is very thin, and easily allows of perforation by disease, which may subsequently extend in the Pelvis. The Socket is deepened by a dense fibrous ring, the Glenoid Ligament. The Capsule of the joint extends on to the Femur, — to a varying extent at different parts —. In front it reaches the Intertrochanteric Line, behind it is inserted on to the Neck of the Femur, about $\frac{2}{3}$ th inch below the middle of the neck, so that a considerable part of the Neck lies within the Capsule and fractures of the Femur may consequently be completely Intra-Capsular. The Capsule is strongest in front, owing to the Ilio-Femoral Ligament (BERTINI, BIGELOW) which passes, from the Antero-Inferior Iliac Spine and the bone internal to this, over the Capsule with which it blends, to the Intertrochanteric Line. Superficial to BIGELOW'S Ligament, lie the 2 Tendons of origin of the Rectus Femoris Muscle which arise from the Antero-inferior Spine and the brim of the Acetabulum. The angle between the axis of the shaft and the axis of the neck (Angle of inclination of the Neck) of the Femur varies from 116° to 138° (MIKULICZ) but is usually about 120° to 133° , the average being 125° . As a rule the longer the neck, the greater the angle.

The architecture of the cancellous tissue is briefly as follows: A pressure system of Cancelli converges from the surface, commencing at right angles to the surface on the inner side; a traction system crosses the former at right angles, forming arches, which run from the outer compact tissue with their convexity directed upwards to the middle and lower parts of the head, and the adjacent portions of the neck. The third (muscular traction) system begins at the Great Trochanter at right angles with the insertion of muscles into it, and passes inwards forming arches with their convexity directed upwards: this system crosses the former at an angle of 45° , together with the first set, this forms the strong vertical plane of compact bone which MERKEL calls the Femoral Spur (Calcar Femorale).

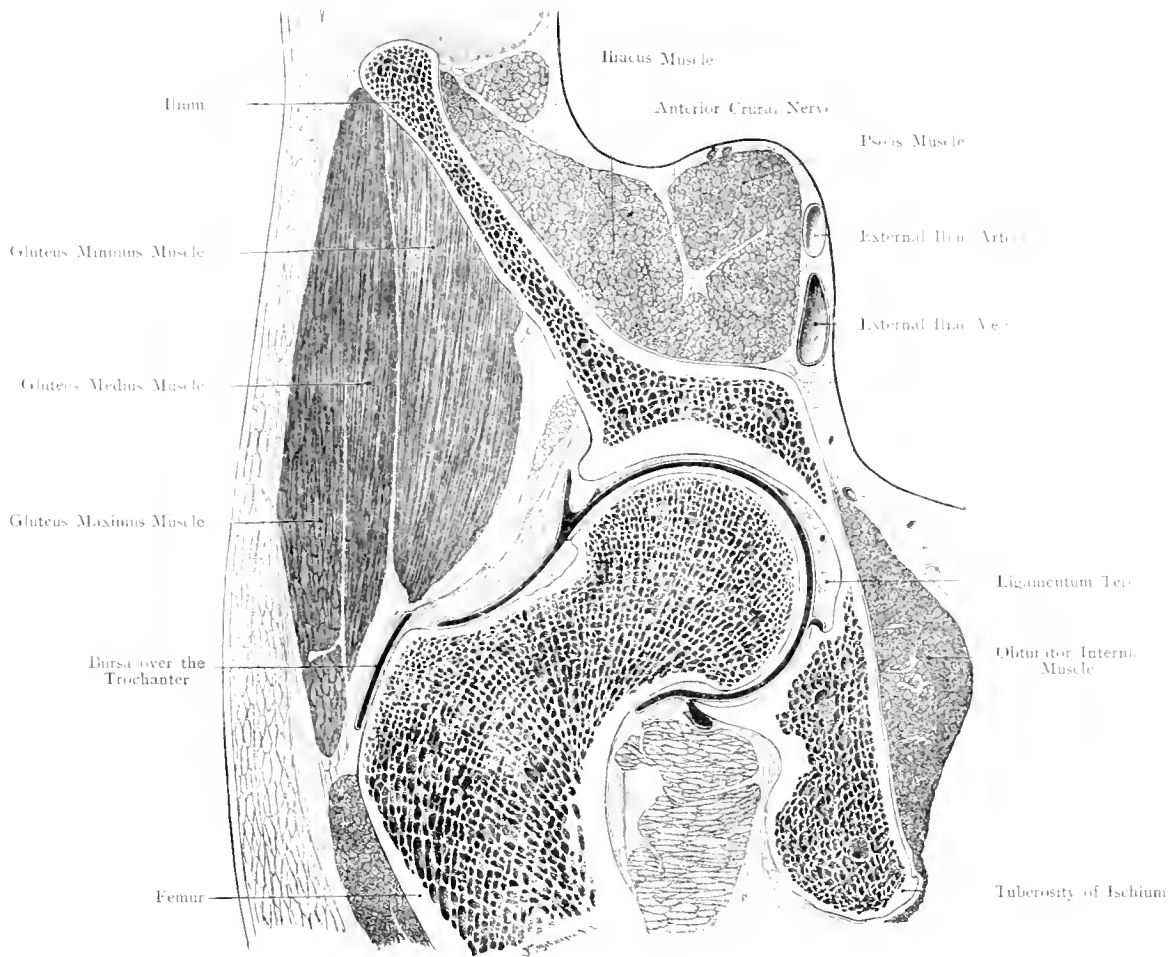
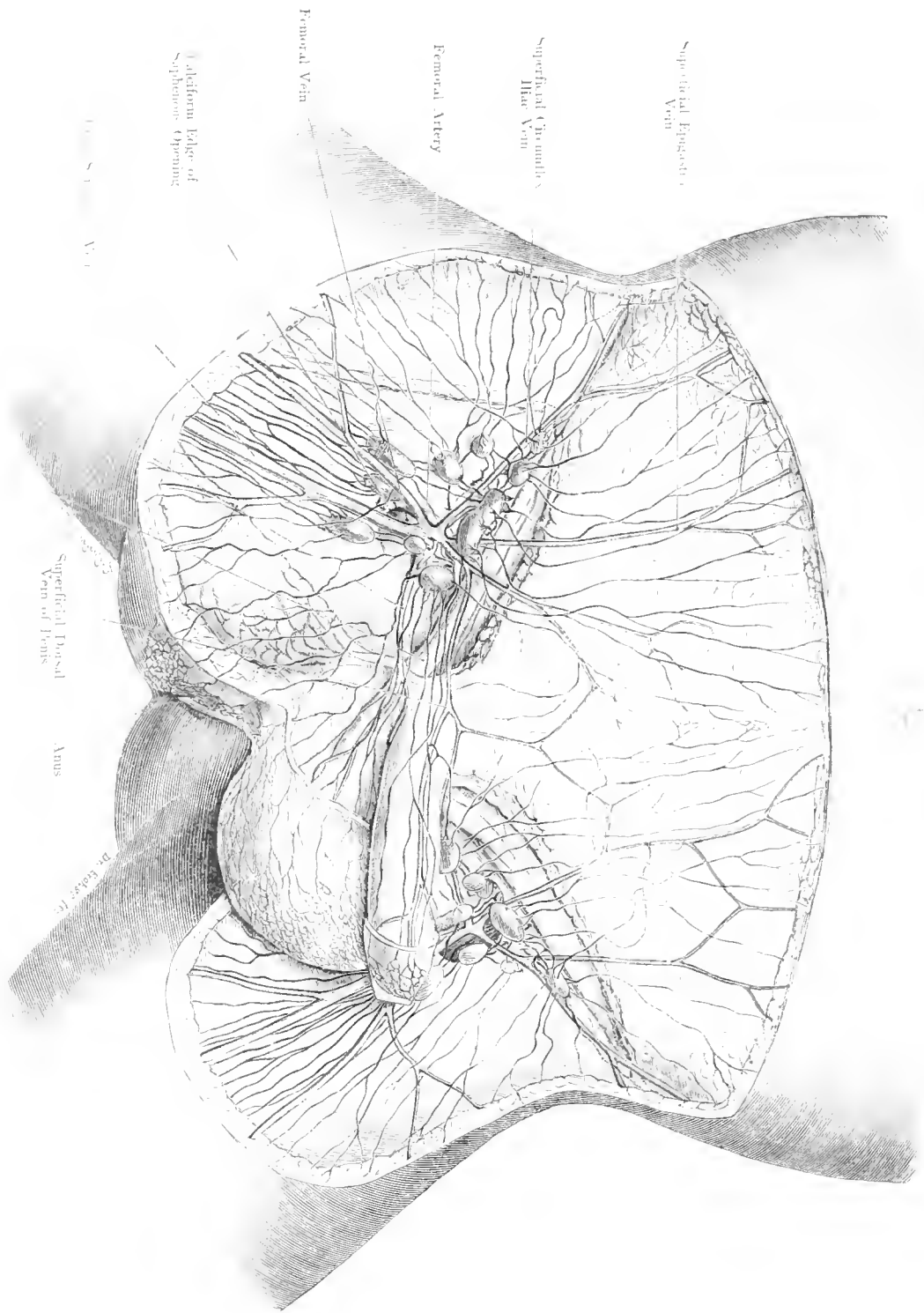


Fig. 165. Frontal Section through the Hip-Joint; Right side.

Seen from in front. — $\frac{2}{3}$ Nat. Size.



Superficial Psoas Vein

Superficial Circumflex Iliac Vein

Femoral Artery

Femoral Vein

Aliform tube of Saphenous Vein

Superficial Psoas Vein of Penis

Anus

Superficial Psoas Vein

Fig. 166. Inguinal Region, 1st Layer. Superficial Lymphatic Vessels and Glands; Veins.

Child. Nat. Size. - Modified after CARL BRUNS.

Keegan Limited, London.

Keegan Company, New York.

Fig. 166. Inguinal Region — 1st Layer — Superficial Lymphatic Glands.

Outlines. Veins. Position of lymphatic glands after a specimen from a new-born male infant. Penis and Scrotum are drawn to the left. The subcutaneous tissue in Scarpaa's Triangle, has been removed down to the fascia. The Veins are preserved and the trunk of the Arteries shown on the right side. Lymphatic Vessels after a drawing by Franz Frohse for C. Brunhs (modified).

The Inguinal Lymphatic Glands lie in the deeper layers of the Subcutaneous fat, less separated from each other in the child, than in the adult, when the External Glands may lie close to the Anterior Superior Iliac Spine. No glands are found above POUPART'S Ligament, but below, they extend as far as the apex of SCARPA'S Triangle. In this figure only the Superficial Inguinal Glands are shown. These number 8 to 15; in pathological conditions they may be more. These may be divided into groups according to their relation to the Long Saphenous Vein: Firstly, a Superior and an Inferior Group. In children these glands are almost circular, in adults, oval. — The longitudinal axis of the Superior group lies parallel with POUPART'S Ligament; the longitudinal axis of those belonging to the Inferior group lies parallel to the long axis of the thigh. Each of these groups is divided into an Inner and an Outer group; the glands close to the Saphenous opening are considered as a 5th group. None of these 5 groups contain more than 3 or 4 glands (cf. Fig. 141). The Superficial Glands are the Regional Glands for the skin of the Trunk below the Umbilicus, they receive the Lymphatics from the lower part of the Abdominal Wall, Gluteal Region, External Genitals, Perineum, Anus, Skin and deeper part of the Lower Limb (cf. Figs. 182, 183). The Subcutaneous Lymphatics of the Penis and Glans run (very frequently to both sides) to the Superior Internal Group; those of the Scrotum, chiefly to the Inferior Internal Group, but also to the former. In this figure the gland which receives these lymphatics has to be considered as belonging to the 5th group. The Lymphatics of the Perineum also pass to this gland, but they are further connected with the Superior Internal Group.

The Superior External Group contain the regional glands for the Abdominal Wall and upper part of the Gluteal Region; the Lymphatics of the lower part of the Gluteal Region pass to the Inferior External Group. The chief lymphatics of the lower limb do not lie, at this stage, within the Superficial Fascia, but on the Deep Fascia, on either side of the Long Saphenous Vein, especially on the outer side.

A circular arrangement of the superficial lymphatics may be spoken of, e. g. Internal parts have an Internal Group; Upper parts have a Superior Group, etc., although variations occur. It should be borne in mind that lymphatics branch and anastomose freely, so that a lymphatic vessel may communicate with 2 or 3 different glands. As the parts spoken of are often affected with disease, the lymphatics become affected and demand operative procedures. They are associated with the gland which is most frequently affected in the whole body: Ulcers on the Genitals, Inflammation on the Lower Limb etc., produce Suppuration in these Glands (Bubo); in cases of Epithelioma of the Penis, Vulva, Anus, the poisons extend to these glands where metastatic foci occur. Tuberculosis of the Joints of the Lower Extremity often involves these glands.

Operations on these glands are usually accompanied by free hæmorrhage, because of the confluence of many superficial vessels in this region. These vessels are only separated from the large vessels by the Crithiform Fascia, so that precautions are necessary in making incisions into or for removing these glands.

The Efferent Lymphatics pass to the Iliac Glands; only a small portion goes to the Deep Inguinal Glands (cf. Fig. 141).

Fig. 167. Inguinal Region; 2nd Layer. Fossa Ovalis (Saphenous Opening).

Specimen from a man aged 33. Skin, Subcutaneous Tissue and Lymphatic Glands have been removed. The Lymphatic Vessels which perforate the Deep Fascia in one region – the Cribriform Fascia – have also been removed. The Fossa ovalis (Saphenous Opening), and above the Femoral Vein, the “Infundibuliform Process” (WALDEYER) derived from the Transversalis Fascia are shewn.

Not only the Aponeurosis proper of the External Abdominal Oblique Muscle but also the Fascia Lata and the Fascia covering the Pectineus Muscle etc., may be looked upon as tendinous expansions of this Muscle. Not only in animals, but also in man, this muscle extends directly or indirectly on to the Thigh. The Fascia Lata can be made tense in all bodies by pulling on the External Oblique Muscle. Below POUPART'S Ligament, special arrangements occur which have been produced by the passage of the Vessels through the Fascia.

The usual description given is: The Fascia Lata which envelopes the thigh, like a tense membrane, divides below the inner part of POUPART'S Ligament into 2 layers. The Deep Layer blends with the Ilio-Pectineal Fascia, and passes upwards behind the Vessels. The Superficial Layer is attached to POUPART'S Ligament; over the Femoral Vein and internal to it, this fascia is perforated at many points, through which Superficial Vessels enter the deep layers (Cribriform Fascia). When this fascia is removed together with the subjacent fat, a groove is exposed; Fossa Ovalis or Saphenous Opening. The lower margin of this opening is always sharp (the Falciform Margin); over this the Long Saphenous Vein passes to open into the Femoral Vein. The upper and outer margin which can be dissected out is attached above to POUPART'S Ligament, and partly to GIMBERNAT'S Ligament. The Saphenous Opening is merely intended for the transmission of vessels comparable to many other openings in superficial fasciae, through which veins pass; with this difference that the opening is too large for the vein.

The Superficial Vessels which pierce this Fascia are:— on the inner side, External Pudic Vessels; above, Superficial Epigastric Vessels; on the outer side, the Superficial Circumflex Iliac Vessels. Like all vessels situated close to their origin from a large artery or near their opening into a large vein, these small vessels bleed furiously when cut.

Fig. 168. Inguinal Region, 3rd Layer. Spermatic Cord. SCARPA'S Triangle.

Male, aged 37. The Fascia Lata and the Lymphatics of the Groin have been removed. The Aponurosis of the External Abdominal Oblique Muscle (and the External Abdominal Ring) has been slit up and the chief constituents of the Spermatic Cord dissected out.

When the Fascia Lata which stretches across the Inguinal Region has been removed, a triangular space with its base directed upwards, and its apex downwards — SCARPA'S Triangle — is exposed. The upper boundary of this area is POUPART'S Ligament; the internal, Adductor Longus Muscle, which arising from the bone below the Pubic Spine, runs outwards and downwards, to be inserted into the middle third of the middle lip of the Linea Aspera; the external, Sartorius Muscle, which arising below the Antero-Superior Spine of the Ilium descends obliquely inwards and downwards, over the Internal Condyle of the Femur, to be inserted on the inner surface of the Tibia as far down as the Crest of the Tibia.

In this Triangle, the Anterior Crural Nerve and the main vessels are exposed. The Femoral Artery lies directly under POUPART'S Ligament, at the mid-point between the Anterior Superior Iliac Spine, and the Symphysis Pubis, and passes almost vertically downwards. At the ligament, the Femoral Artery can be readily compressed by digital pressure against the horizontal ramus of the Pubis. In SCARPA'S Triangle, the Femoral Artery gives off posteriorly, the Deep Femoral Artery, apart from the smaller branches, Fig. 167 — Superficial Epigastric, Superficial External Pudic and Superficial Circumflex Iliac Arteries —. As the Deep Femoral Artery is a branch of large size, there occurs at its origin, $1\frac{1}{2}$ inch below POUPART'S Ligament, a sudden diminution in the calibre of the Superficial Femoral Artery.

The Femoral Vein lies to the inner side of the Artery and is enclosed in its sheath, but soon passes behind the Artery. This Vein receives the Long Saphenous Vein, which passes over the margin of the Fascia (see Fig. 167). Internal to the Vein, is situated the Crural Ring (see Fig. 170). The space below the ring, — between the Adductor Longus, Femoral Vein, and Pectineus Muscle — is filled up with fat and deep lymphatic glands. The Anterior Crural Nerve appears in the Muscular Compartment under POUPART'S Ligament, and lies about $\frac{2}{5}$ th inch external to the Artery in SCARPA'S Triangle. This nerve disappears under cover of the Sartorius Muscle and divides into branches which supply the skin on the Anterior Aspect of the thigh, the Sartorius and the Quadriceps Extensor. Deep to the Vessels and the Nerve lie the Ilio-Psoas and Pectineus Muscles.

At the Apex of SCARPA'S Triangle, the Sartorius passes obliquely over the vessels. This muscle has, therefore, to be drawn aside in order to expose the further course of both Artery and Vein.

The figure also shows the constituents of the Spermatic Cord: Vas Deferens with the Vessels to the Vas, Spermatic Artery and the Pampiniform Plexus of Veins, Cremasteric Vessels to the coverings of the Cords.

The Cremasteric Vein is of importance because it always communicates with the Pampiniform Plexus, though it opens into the Deep Epigastric Vein (Collateral Venous Channel).

Fig. 169. Inguinal Region, 4th Layer. Hernial Orifices, Iliac Bursa.

Male aged 60. The Spermatic Cord has been drawn out of the Inguinal Canal and cut off. Vas Deferens (blue). Fascia of Penis is opened up and the Dorsal Vessels and Nerves are exposed. External part of Fascia Lata has been removed. Anterior Crural and External Cutaneous Nerves have been lopped off short. A piece has been cut out of the Ilio-Psoas to expose the Iliac Bursa (pink). The Pelvis and Head of the Femur are indicated in dotted lines. The dotted ellipse over the Head of the Femur indicates the position and size of the communication between the Iliac Bursa and the Hip-Joint (in this case).

Immediately external to the Common Femoral Artery, but on a slightly deeper plane, are the Ilio-Psoas Muscle and the Anterior Crural Nerve.

A very large bursa (Iliac Bursa) separates the Ilio-Psoas Muscle from the Horizontal Ramus of the Pubis and the Capsule of the Hip-Joint whereby the Muscle plays over the edge of the bone without friction. The Capsule of the Hip-Joint is weak at its point of contact with the Iliac Bursa, and in some cases (1 in 10) there exists a communication between these 2 cavities.

This Bursa may extend some distance into the Pelvis which occurrence is of practical importance in connection with primary disease of this Bursa. When swollen the difficulty of diagnosis arises between enlarged lymphatic glands, aneurysm of the Femoral Artery, or disease of the Hip. An accurate anatomical knowledge of this bursa is the only clue to a correct diagnosis. Again inflammation may spread from the Hip-Joint into the Bursa, via a direct communication, by piercing the thin septum, and further extend into the Pelvis.

The figure also shews the important relations of the Hernial Orifices. The fibres of the External Abdominal Oblique Muscle diverge at an acute angle, and form the 2 pillars of the External Abdominal Ring. The Internal Pillar ends in the middle line (or reaches to the opposite side) at the Symphysis Pubis by sending fibres into the Suspensory Ligament of the Penis. The Outer Pillar is chiefly inserted into the Pubic Spine. The angle between the diverging fibres and the anterior aspect of the cord are covered by intercolumnar fibres which hold the two pillars together. POUPART'S Ligament is a thickened fibrous cord or rather a tendon or tendinous cord (the lower border of the External Abdominal Oblique Muscle).

From the External Pillar and POUPART'S Ligament which are blended together, many fibres spread in various directions, and to some of these names have been applied. The fibrous mass which stretches across to the Fascia covering the Pectineus Muscle, near the Spine of the Pubis, and forming a triangular ligament with the base pointing outwards has been called GIMBERNAT'S Ligament (Fig. 170). The fibres directed upwards and backwards to reach the bone, have been called the Ilio-Pubic band. Both ligaments are usually blended together. These structures are not constant, and their descriptions are most variable.

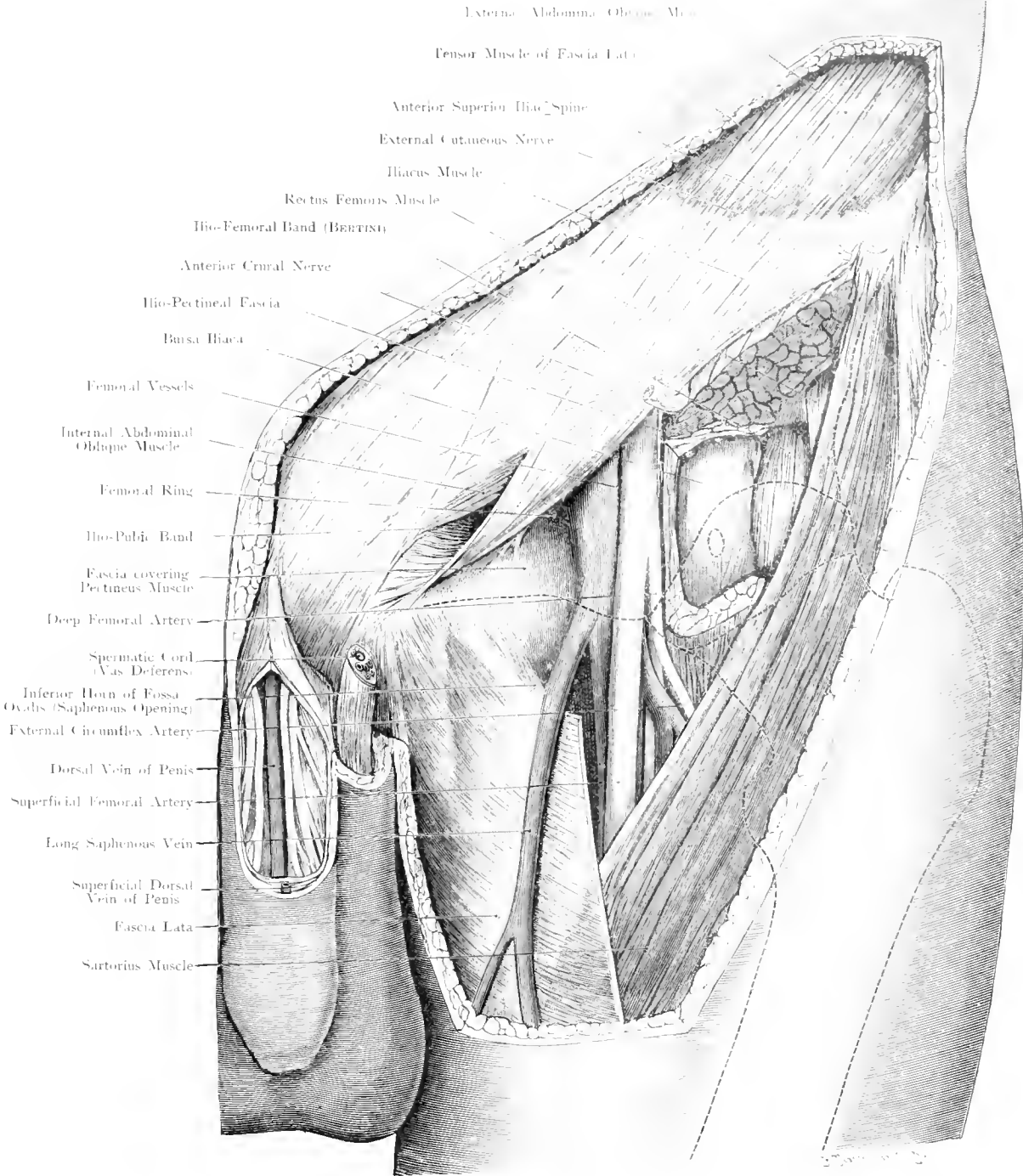


Fig. 169. Inguinal Region, left side, 4th Layer. Hernial Orifices. Bursa Iliaca.
 $\frac{3}{4}$ Nat. Size.

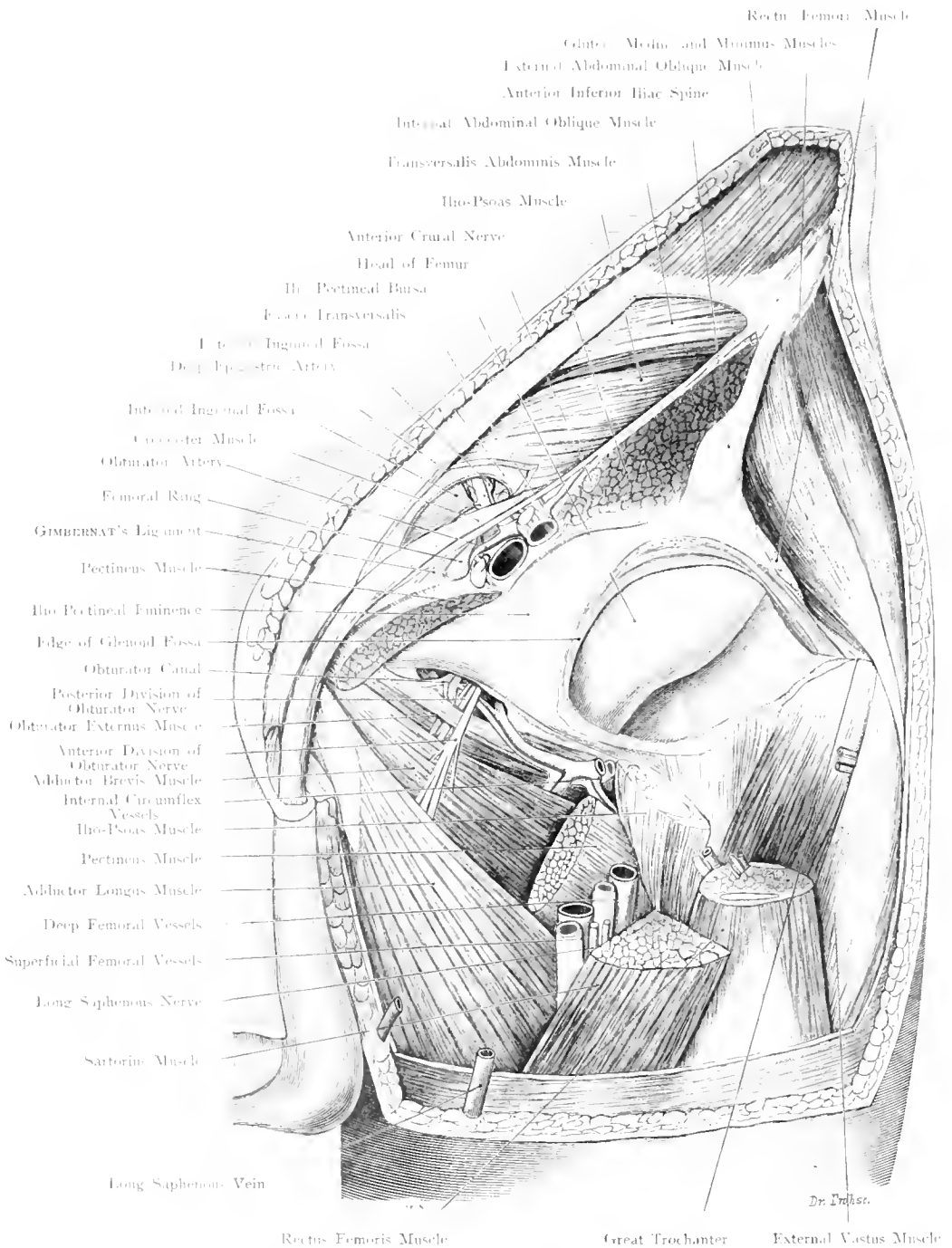


Fig. 170. Inguinal Region, left side, 5th Layer. Subperitoneal Hernial Orifices. Hip-joint. Obturator Region.

Nat. Size.

Fig. 170. Inguinal Region, left side, 5th layer. Subperitoneal Hernial Orifices. Hip-Joint. Obturator Region.

The Inguinal Region and neighbouring parts have been exposed layer by layer in an adult male; above POUPART'S Ligament the Subperitoneal Hernial Orifices are exposed. At the level of POUPART'S Ligament Muscles and Vessels are cut across so that the Muscular Compartment and the Vascular Compartment (opening for Femoral Hernia) are seen. Below the Ligament on the inner side a piece of the Pectineus has been cut out so that the opening of the Obturator Canal (external opening of Obturator Hernia) is shewn; on the outer side the Hip-Joint has been exposed and the joint cavity widely opened.

The Hip-Joint lies immediately external to the Artery but on a much deeper plane. The Anterior Crural Nerve lies almost over the middle of the Head of the Femur. The Head of the Femur can only be felt from in-front, in very thin people. So that owing to its deep situation and its proximity to the large vessels, the Hip-Joint is not very easily accessible from in front.

The Internal and External Circumflex Arteries, of considerable size, are given off from the Deep Femoral Artery, but one of them, occasionally both, may come off from the Common or Superficial Femoral Artery.

Internal to the vessels is a landmark of some importance. If the Pectineus Muscle be removed the External Obturator Muscle is exposed as it arises from the outer surface of the Obturator Foramen and the Obturator Membrane, and runs outwards to the Digital Fossa. The Membrane closes the Obturator Foramen except at its anterior and external angle; here a small gap hardly $\frac{1}{5}$ th inch in diameter allows the Obturator Vessels and Nerve to pass. A hernia may protrude through the orifice - Obturator Hernia - its position proves the difficulty of diagnosis, and its close proximity to the Obturator Nerve sometimes causes pain in the area of distribution of the nerve owing to pressure by the Hernia. The figure also shews structures passing under POUPART'S Ligament which together with the upper border of the Pelvis forms a large slit-like space divided into two compartments by the Ilio-Pectineal Fascia. This fascia, which is derived from the Fascia covering the Iliacus Muscle and accompanied the Ilio-Psoas down to the Lesser Trochanter of the Femur, is firmly attached to the Ilio-Pectineal Eminence. In the outer compartment is the Ilio-Psoas Muscle with the Anterior Crural Nerve embedded in its anterior surface. In the inner compartment are the Large Vessels and the Pectineus Muscle. Between the Femoral Vein and the outer margin of GIMBERNAT'S Ligament there remains a small space filled by loose connective-tissue; this is the Femoral Ring, the most important spot at which the Peritoneum can readily be pushed forward and give rise to a Femoral Hernia. Here we find situated the Deep Inguinal Lymphatic Glands, one of which goes by the name of CLOQUET'S Gland.

A Femoral Canal does not exist (as a preformed Canal) in normal subjects. It is the result of the descent of a Femoral Hernia.

Fig. 171. Frontal Section through the Hip-Joint of a boy 8 years old. After VON BRUNN.

Frozen Section.

The Synovial Membrane extends on all sides beyond the Epiphyseal Line on to the Neck of the Femur. The capsule is generally opened when the Epiphysis is torn off provided sufficient violence be acting to tear the capsule at the point at which it leaves the Head to pass on to the Neck of the Femur; but as the capsule can easily be separated from the Neck the joint may remain intact if the Diaphysis separates easily from the Cartilage to which the Synovial Membrane is intimately adherent. Inflammation of the Epiphysis extending into the neighbouring parts must necessarily perforate the hip-joint, provided it does not spread exclusively downwards towards the Diaphysis.

The distance of the Epiphyseal Line from the surface of the Head of the Femur is very short. The removal of the articular surface, in cases of excision of the Hip-Joint therefore brings

about destruction of the Epiphyseal Line, thus the longitudinal growth of the Femur to a considerable extent in young individuals is impaired.

Fig. 172. ROSER-NÉLATON Line.

The outlines of the Bours are projected on to the surface.

The Head of the Femur is so covered by a thick layer of soft tissues on all sides that palpation is defied. In order, therefore, to ascertain its position, the Great Trochanter which is subcutaneous and can be easily felt, is taken as a landmark. The distance between the Trochanter and the Head of the Femur is merely the length of the Neck of the Femur. When semi-flexed, the most external and prominent part of the Great Trochanter, when flexed to a right angle, the tip of the trochanter just touches a line drawn from the Anterior Superior Iliac Spine to the Tuberosity of the Ischium.

If the Head of the Femur is dislocated upwards the Trochanter must also be above NÉLATON'S Line.

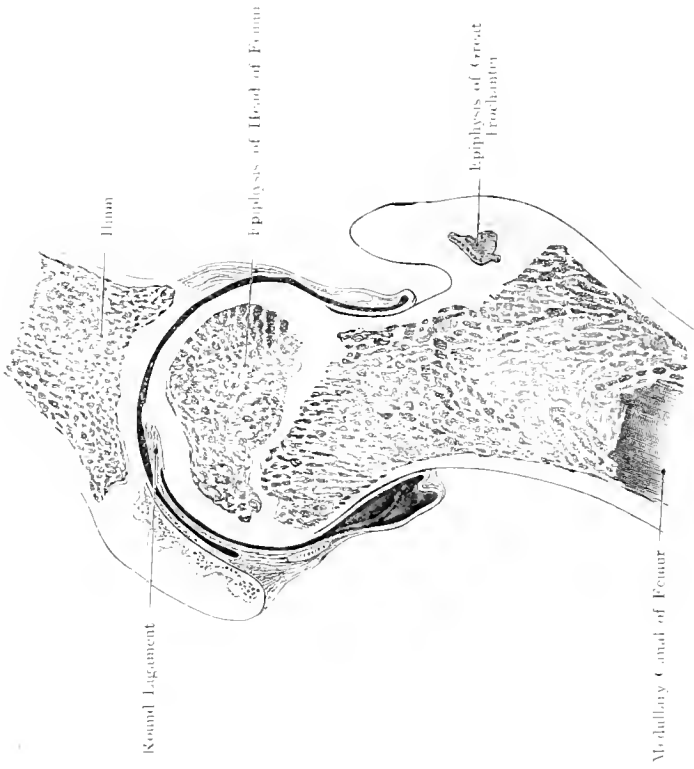


Fig. 171. Frontal Section through (left) Hip-joint in Boy aged 8. Front view.

After von BRUNN. — Nat. Size.

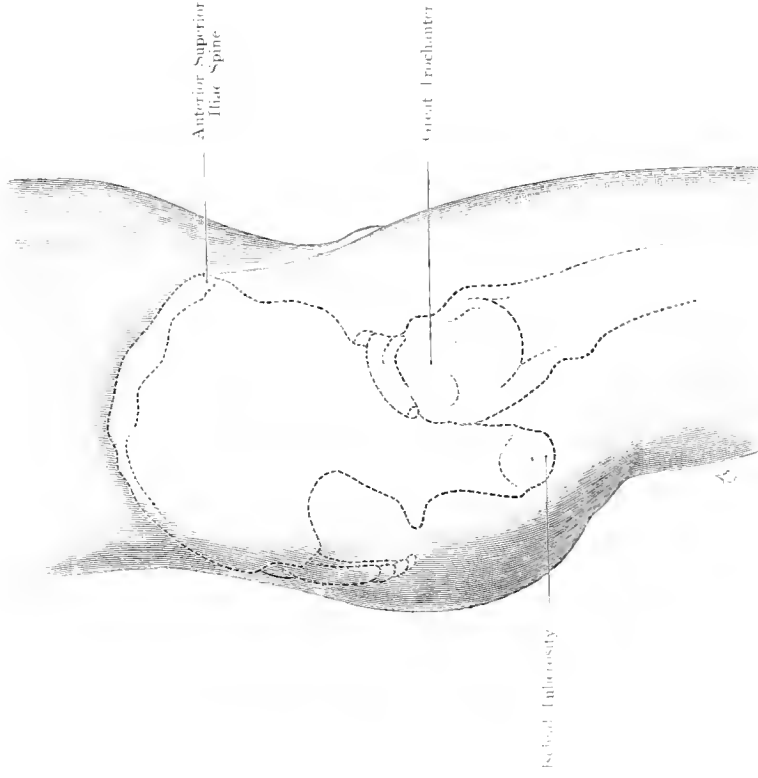


Fig. 172. NELATON'S LINE.

$\frac{1}{4}$ Nat. Size.

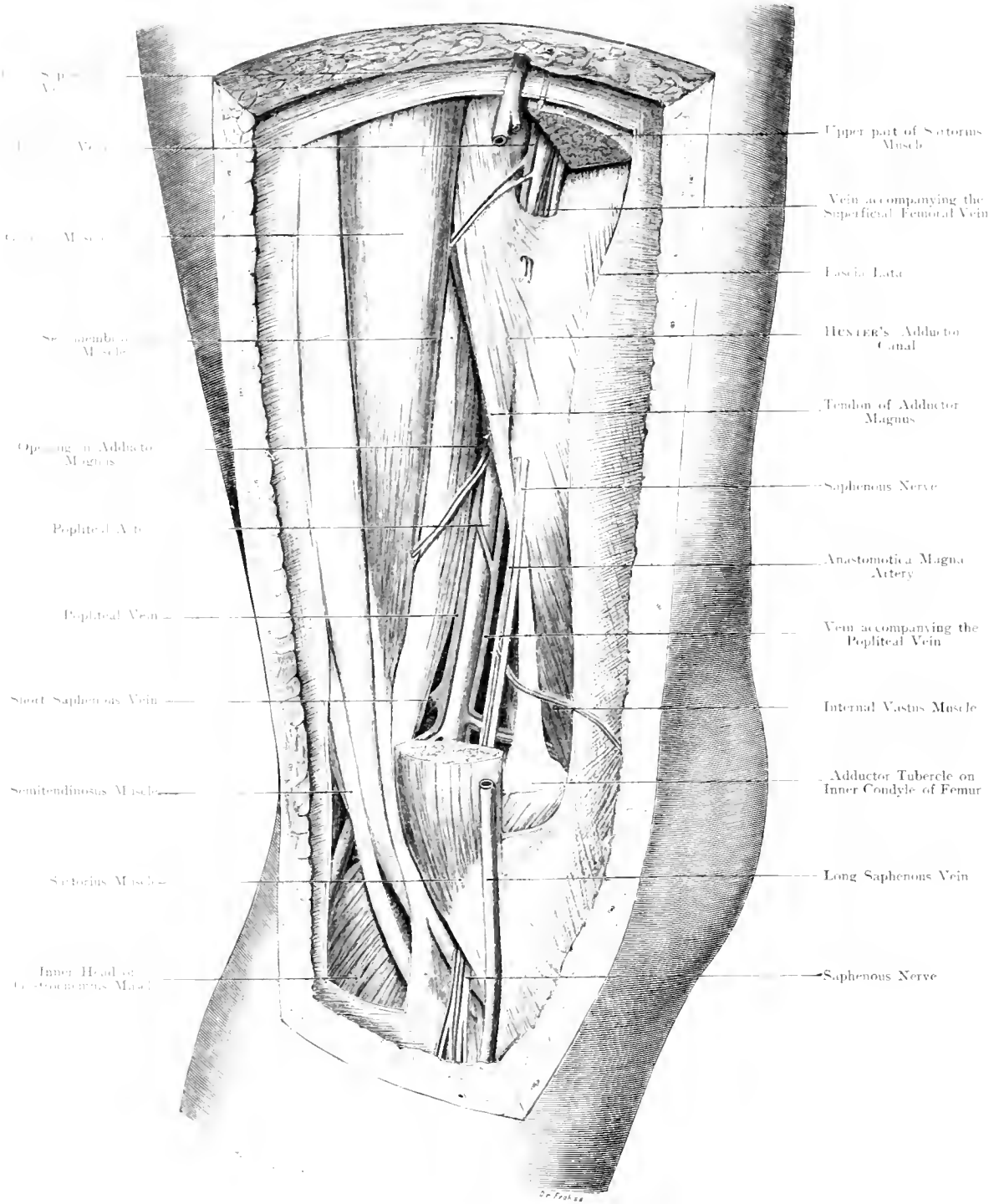


Fig. 173. HUNTER'S Canal and Popliteal Space, left side, seen from the inner side. (JOBERT'S FOSSA.)
Nat. Size.

Fig. 173. HUNTER's Canal and Popliteal Space seen from the inner side. (JOBERT's Fossa.)

Left Leg of a girl aged 15 years. A piece has been cut out of the Sartorius Muscle.

In the upper part of the thigh the Femoral Artery lies on the anterior aspect of the limb, lower down it is on the inner side and finally on its posterior aspect. In its course the Artery crosses the Femur at an acute angle. Above the Artery lies internal and superficial to the head of the bone but subsequently it approaches the inner side of the shaft, and gets on to its posterior surface. The course of the Artery is almost in a line drawn vertically downwards whereas the axis of the Femur is oblique, thus the crossing is brought about.

Above the Artery is in front of the Adductors but as these muscles, e. g. Pectineus, Adductor Longus and Adductor Magnus, are inserted by a broad membranous tendon along the entire length of the Linea Aspera from the Lesser Trochanter as far down as the Inner Condyle, the Artery must pierce this tendon in order to reach the posterior surface. This occurs in the Adductor or HUNTER's Canal. Below the apex of SCARPA's Triangle the Artery is covered by the Sartorius Muscle and rests upon the Adductor Longus Muscle. About the middle of the thigh it reaches HUNTER's Canal which is formed by a strong Aponeurosis spreading from the Adductor Longus and Magnus Muscles over the Vastus Internus Muscle. At the end of this canal the artery pierces the Adductor Tendon. This canal bounded in front by the Aponeurosis mentioned, behind by the Adductor Longus and Magnus is about 2 inches long and terminates at the junction of the middle and lower thirds of the thigh. The Long Saphenous Nerve enters the canal with the Artery but perforates, in conjunction with the Great Anastomotic Artery, the Anterior wall of this Canal about its middle. Two accompanying Veins pass through the Canal with the Artery: of these veins, one is usually very diminutive. The 3 Perforating Branches of the Deep Femoral Artery perforate the insertion of the Adductors in a similar way, to gain the posterior aspect of the Thigh.

For operations — e. g. in cases of Acute Osteomyelitis — which require exposure of the Femur throughout its extent, the outer side is chosen because internally and anteriorly the large vessels are in the way; on the anterior aspect the upper cul-de-sac of the Knee-joint may be injured, posteriorly the Sciatic Nerve and lower down the vessels. On the outer side there are no important Vessels or Nerves.

Figs. 174 and 175. Transverse Sections through the Thigh at the end of the upper and middle thirds.

Frozen Section.

Three powerful groups of muscles surround the thigh and enclose it so completely that the Great Trochanter and the Condyles alone remain subcutaneous. In front, the Quadriceps Extensor (Rectus arising from the Anterior Inferior Spine and brim of the Acetabulum, Vastus Internus, Vastus Externus and between these the Crureus arising from the Femur); internally, the Adductors (Adductor Brevis, Adductor Longus, Adductor Magnus, Pectineus and Gracilis) arising from the Pelvis; behind, the Flexors (Biceps, Semimembranosus, Semitendinosus) arising from the Tuberosity of the Ischium with the exception of the Short Head of the Biceps.

The Extensors increase in mass as far as the lower third because they receive fibres from the Femur. The Adductors diminish regularly until they merely form a tendon at the Knee-joint. The Flexors are reinforced by the Short Head of the Biceps and diverge at the Popliteal Space to the outer and inner sides respectively.

A very strong fascia surrounds the muscles of the thigh enclosing them so tightly that after division of the fascia the muscles protrude through the slit, like a hernia. The fascia is strongest on the outer side because it receives the tendinous expansion of the Tensor of the Fascia of the Thigh, and of the Gluteus Maximus. From the Fascia two membranous Septa stretch to the bone, thus dividing the muscles into 2 groups: the External Septum extending from the great Trochanter along the outer lip of the Linea Aspera down to the External Condyle; the Internal Septum from the Lesser Trochanter along the inner lip to the Tendon of the Adductor Magnus. The figures shew the different positions of the Femoral Artery. In Fig. 174 it lies just above the slit in the Adductor on the inner side, and slightly anterior to the Bone. In Fig. 175 it has already reached the posterior aspect of the Bone. The Deep Femoral Artery is still visible as a large vessel in Fig. 174 between the Adductor Longus and Adductor Magnus. It diminishes rapidly in size by giving off the Perforating Arteries.

While the Anterior Crural Nerve divides rapidly into its branches so much so that the main trunk is no longer evident in our figures, the Sciatic Nerve remains distinct on the back of the thigh, being well surrounded by fat and lying in the triangular space between the Adductors and the already diverging Flexors. In Fig. 175 the nerve has already divided into External and Internal Popliteal Nerves, which, however, lie in close apposition.

The Adductors and Flexors are less distinctly separated from each other than they are from the Extensors. The Sartorius has throughout its course a special canal, formed by the splitting of the Superficial layer of the Fascia. This statement holds good also for the Gracilis and Rectus in the upper part of the thigh.

The thin special fasciae of the Flexors and Adductors are easily perforated by pus. They are practically lymph spaces between the muscles and their neighbouring parts.

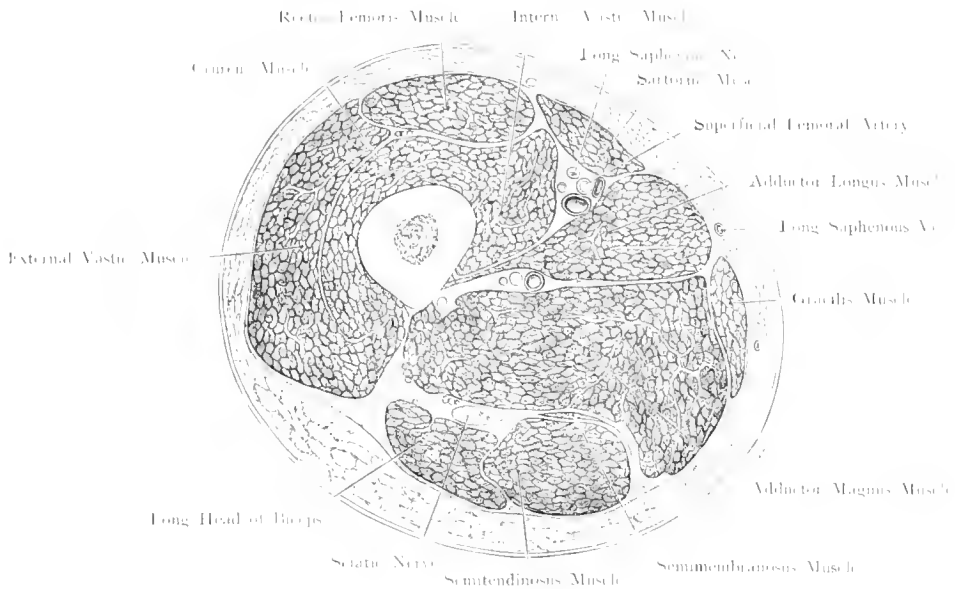


Fig. 174. Transverse Section through the Junction of Upper and Middle thirds of the (right) Thigh.
 Seen from below. $\frac{2}{13}$ Nat. Size.

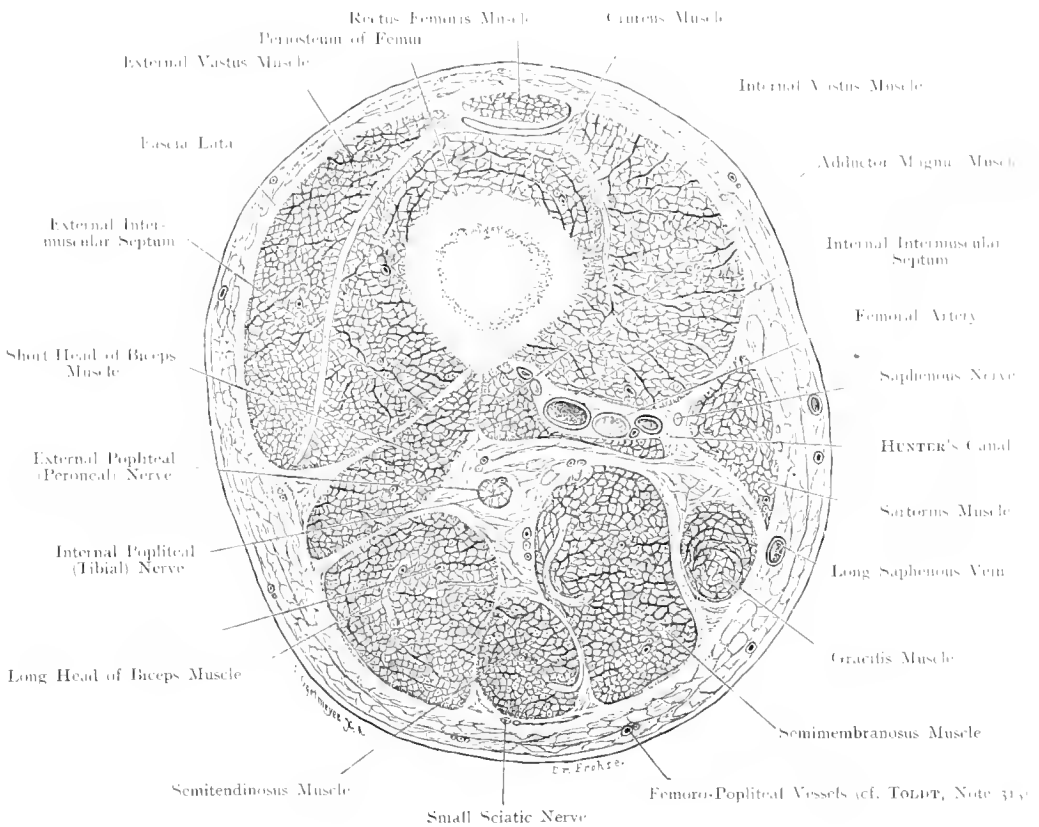


Fig. 175. Transverse Section through the Junction of Lower and Middle thirds of the (right) Thigh.
 $\frac{1}{6}$ Nat. Size.

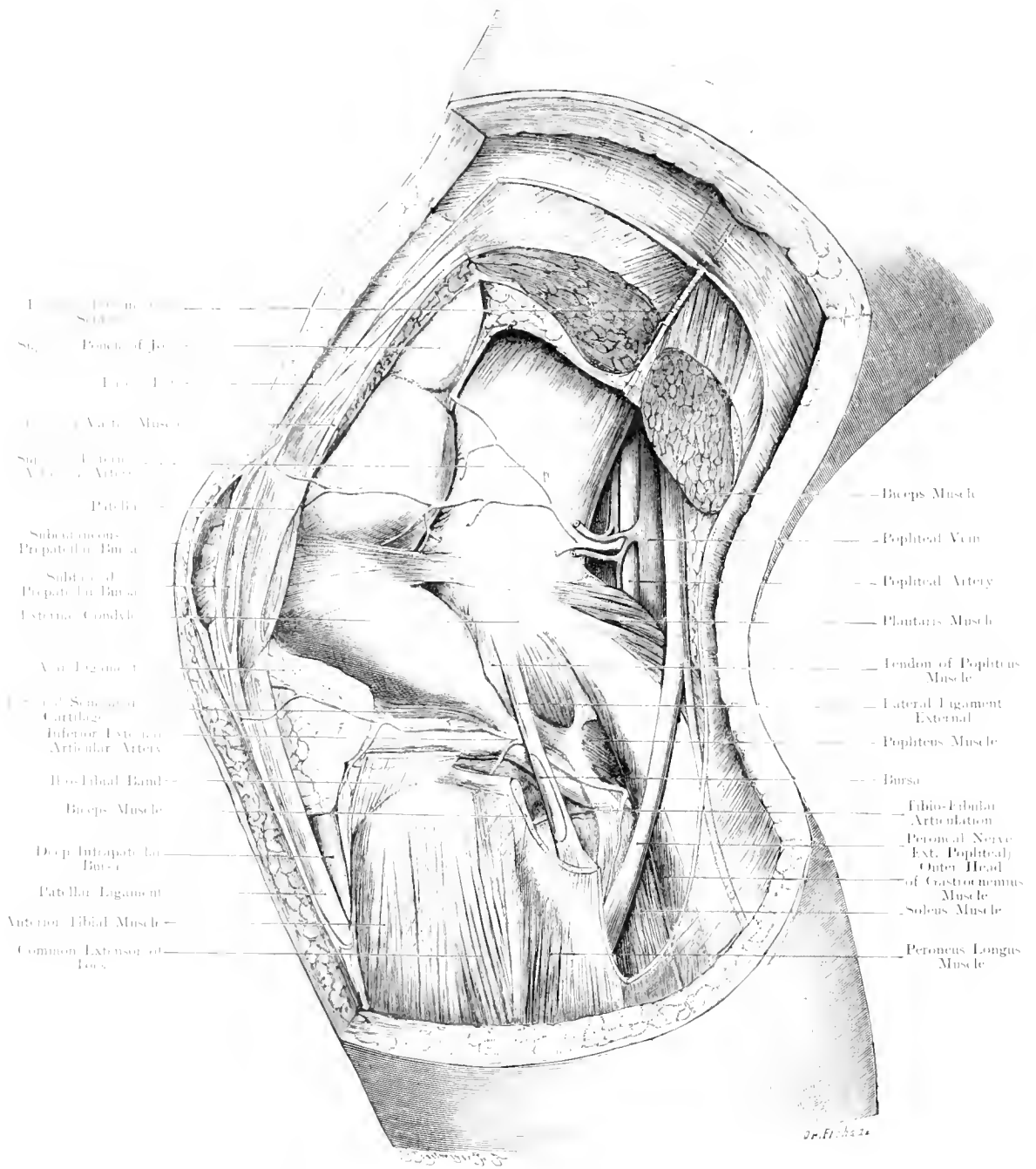


Fig. 176. Left Knee-Joint and Surrounding Structures.

Seen from the outer (left) side. — $\frac{1}{4}$ Nat. Size.

Fig. 176. Left Knee-Joint and Surrounding Parts. Seen from the outer side.

Preparation made from a female aged 15 years. Plaster of Paris had been injected into the Knee-Joint. Boundaries of the Joint-Cavity (pink); the Tibia-Fibular Articulation which does not communicate with the knee-joint, dark red. The independent bursae around the knee-joint (blue). The lower parts of the Vastus Externus and Biceps Muscles have been removed; the attachment of the Ilio-Tibial Band and the insertion of the Biceps into the Head of the Fibula and into the Tibia are preserved.

The Fascia Lata of the thigh is continuous with the Fascia enclosing the leg, and is reinforced by a broad strand of fibres the Ilio-Tibial Band of MAISSIAT, which is derived from the Tensor of the Fascia of the Thigh and some fibres of the Gluteus Maximus Muscle; this Band runs down to the Tibia, and blends with the Capsule of the Knee-Joint. It checks Adduction of the Thigh. The figure shews the extent of the Knee-Joint Cavity and of the upper cul-de-sac, which practically always communicates with it, distended as is the case in serous, purulent or haemorrhagic exudations. One observes that the greatest extension of the joint is possible in the forward direction. A tense effusion pushes the Patella and the Common Extensor Tendon away from the bones, so that, under these conditions, the Patella is not in contact with the underlying bones but rides or dances on the fluid. Laterally no great degree of bulging is possible, firstly, because the Synovial Cavity does not reach far either upwards or downwards over the joint-slit; secondly, because the extremely strong lateral ligaments are tightly stretched. Posteriorly around the Condyles of the Femur, the capsule is more extensible.

In addition to the Prepatellar Bursa (cf. explanation to Fig. 181), and the deep Infrapatellar Bursa, which lies between the Tibia and the Ligament of the Patella, the almost constant External Inferior Bicipital Bursa is shewn lying between the Biceps Tendon and the External Lateral Ligament. Like the bursa above mentioned, this never communicates with the Knee-Joint.

Further, the vessels which take part in the anastomosis on the outer side of the knee-joint are visible.

The blood-supply of the Anterior Aspect of the Joint which has to bear much pressure (e. g. in kneeling) is abundant.

On the inner side, the Superior and Inferior Internal Articular Arteries, on the outer side, the Superior and Inferior External Articular Arteries, form the Anastomosis which is reinforced by the Great Anastomotic Artery, and the Recurrent Tibial Artery.

The Anastomosis is partly superficial between the Patella and the Skin, partly deep between the Tendons and the Ligaments.

Fig. 177. Sagittal Section through the Knee-Joint during Extension.

Frozen Section through the External Condyle of the Femur and the Tibia; the Patella is not cut along its greatest longitudinal axis.

The Knee-Joint is easily accessible from in front or either side, only on its posterior surface, do we find large muscles and between them important Nerves and Vessels. This Synovial Cavity is the largest in the body; moreover, it is the most complex joint on account of its various Intrinsic Ligaments.

The insertion of the Capsule is different on all sides. The joint-cavity extends highest in front, as far as $1\frac{3}{4}$ to $2\frac{1}{4}$ inch, above the margin of the Patella, if we take into account the Suberureal Bursa, which nearly always communicates with the Joint. On both sides (cf. Fig. 180), the insertion of the Capsule reaches close to the line of the joint, posteriorly, it extends upwards as far as the upper limit of the Condyles of the Femur, below it follows the Tibia to a lesser extent. Thus the anterior and posterior surfaces of the Femoral Condyles are within the Synovial Sac, but not so their lateral surfaces.

The anterior wall of the Capsule is formed above by the Tendon of the Quadriceps; between this tendon and the anterior surface of the Femur there is always a Bursa which is of importance because it communicates, occasionally in children, but invariably in adults (98 %), by a more or less wide opening (cf. course of a director in the figure), with the Joint-Cavity. This Bursa may, therefore, be regarded as a part of the Joint-Cavity, and be called the upper cul-de-sac of the Knee-joint. Accumulations of fluid within the Knee-joint cause bulging at this spot. Below the point of insertion of the Quadriceps Extensor to the upper border of the Patella, the wall of the joint is formed by the cartilaginous covering of the posterior surface of this bone. The Ligamentum Patellae attaches the lower border of this bone to the Tubercle of the Tibia. Between it and the Tibia lies the deep Infra-patellar Bursa which does not communicate with the Joint on account of its being separated by a large Synovial-fold — Plica Synovialis Patellaris. This is attached to the Intercondylar Fossa (Crucial Ligaments) by sagittal fibres.

Between the Tibia and the Femur, the External Semilunar Cartilage is seen in the figure, its inner concave margin is sharp, its external convex margin is firmly connected with the capsule of the joint.

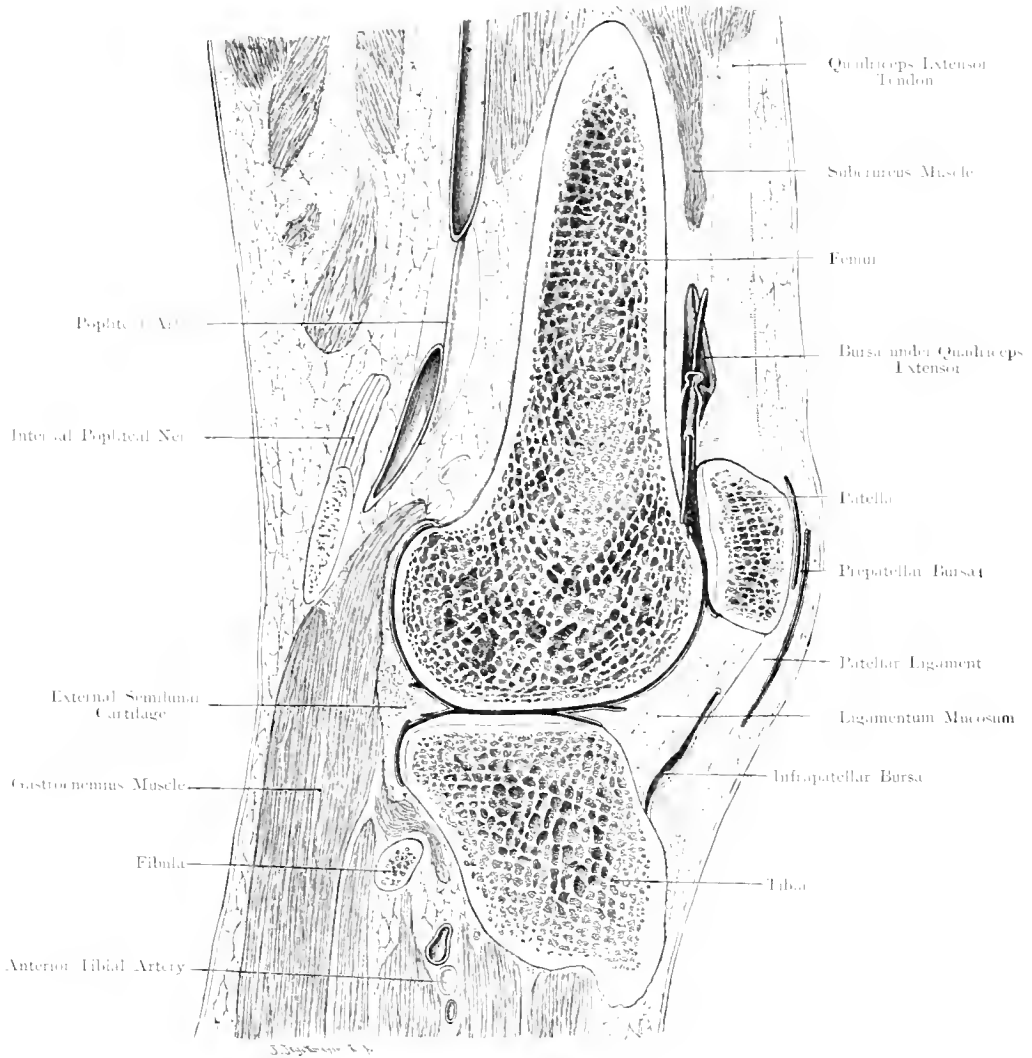


Fig. 177. Sagittal Section through the (left) Knee-Joint during extension.
 Seen from the inner (right) side. — 2 Nat. Size.

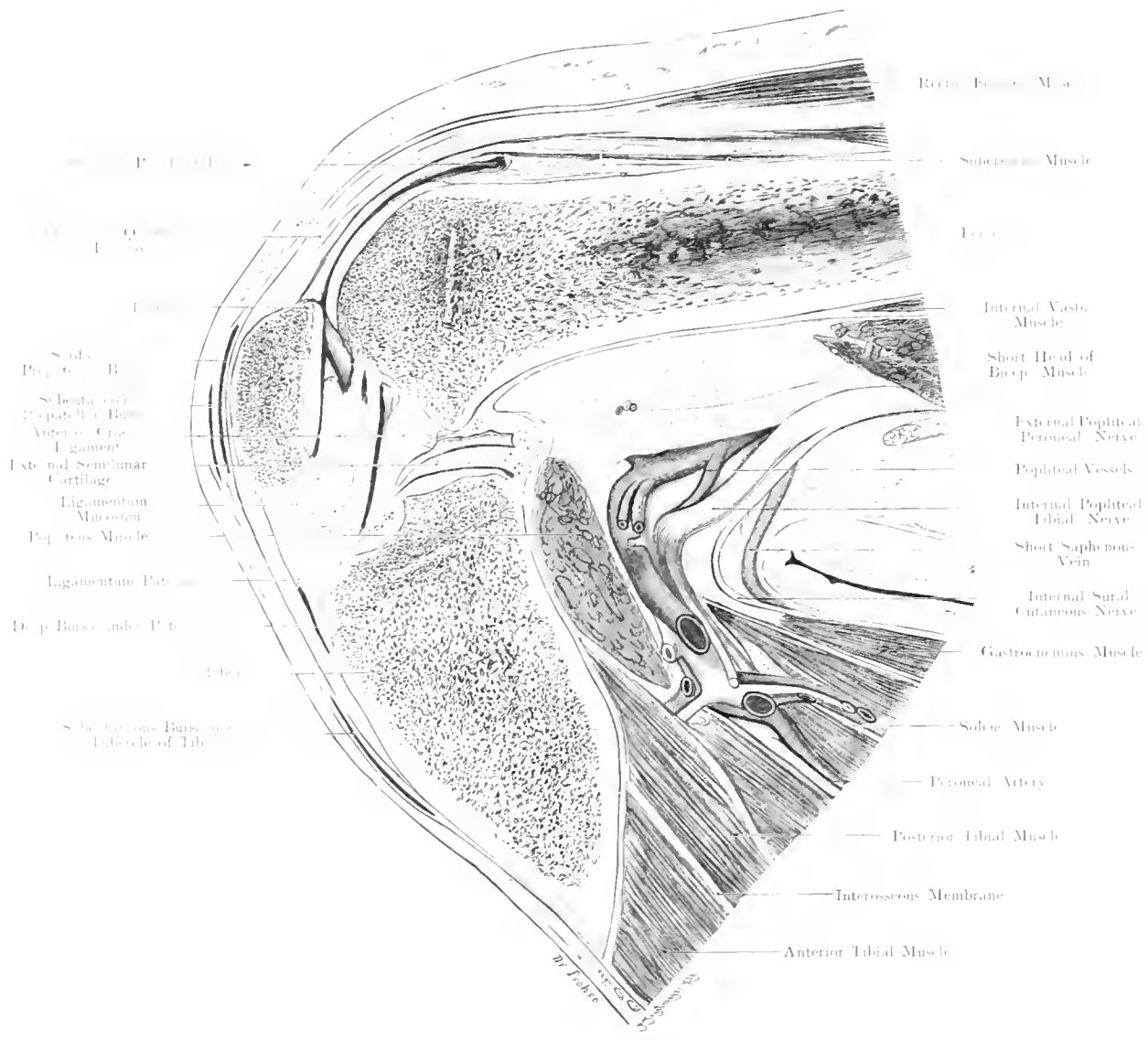


Fig. 178. Sagittal Section through the (left) Knee-Joint during flexion.

Seen from the outer (left) side. — $\frac{1}{4}$ Nat. Size.

Fig. 178. Sagittal Section through the Left Knee-Joint during Flexion.

This preparation was made from a man aged 82 years. Formol was injected into the limb, and the knee, forthwith, flexed to its utmost limit, was kept in that position. On the following day the section was made without freezing. In spite of advanced age and a high amputation through the right leg this joint was quite normal.

In contrast with the extended position (Fig. 177) this figure indicates the relations during extreme flexion. As the section has been carried almost through the middle of the joint, a larger part of the Intrinsic Ligaments is shewn than in Fig. 177.

As the Patella is fixed by the Ligament of the Patella to the Tibia, the Patella leaves the Anterior Surface of the Femur during flexion, and comes to lie in front of the Joint-slit, which it does not cover during extension. The Capsule is folded backwards, and the Vessels and Nerves are extremely bent. To such frequent bendings of an imperfect elastic arterial tube, is attributed the main cause of the not-uncommon aneurysm of the Popliteal Artery. Of the 2 Crucial Ligaments, the figure exhibits the Anterior: this extends from the depression in front of the Spine of the Tibia (Anterior Intercondylar Fossa) upwards, outwards and backwards to the inner side of the External Condyle; its function, like the Posterior Crucial Ligament, is to check excessive rotatory movements. The Plica Synovialis Patellaris fills up the space between the Patella, Articular Surface of the Tibia, and the Crucial Ligaments.

One of the most striking changes which occurs in this joint during flexion, is relaxation of the External Lateral Ligament — this is not seen in the figure —. Attached to the Femur eccentric to the axis of flexion, this ligament becomes tense during extension and prevents rotation, but during flexion it is relaxed and allows inward rotation of the leg. These movements, however, are limited by the Crucial Ligaments. A glance at the figure shews its complexity. Contrary to the other large joints, which either have a free joint cavity or are at the outset traversed by one tendon (e. g. Shoulder, by tendon of biceps, Hip-joint by Ligamentum Teres), the interior of this joint contains a complicated arrangement of ligaments which lead to the formation of numerous pouches. In cases of suppuration in the Knee-joint, the purulent products, therefore, tend to remain in these recesses and clefts, and are only removed with difficulty.

Figs. 179 and 180. Relation of the Epiphyseal Lines at the Knee-Joint to the Capsule of the Joint.

After VON BRUNN.

Fig. 179. Frozen Section (sagittal) through the Knee-joint (passing through the Internal Condyle), of a boy aged 16 years.
Fig. 180. Frozen Section (frontal) through the Knee-joint of a boy aged 8 years.

On to no part of the Tibia beyond the Epiphyseal Line does the capsule of the joint extend, so that separation of the upper Epiphysis of the Tibia could only open the Tibio-Fibular Articulation.

On the Femur, the Capsule does not quite reach the Epiphyseal Line, so that opening into the joint with separation of the Epiphysis, could only occur on the Anterior Aspect where a thick cushion of adipose tissue protects the capsule from laceration. It is true that the Subcureal Bursa which usually communicates with the joint and really represents its upper cul-de-sac (cf. Fig. 177), extends far beyond the Epiphyseal Line, but being well-protected from the bone, by a thick layer of fatty tissue, it can get out of the way and avoid injury.

The lower Epiphysis of the Femur is twice as long as the Upper Epiphysis of the Tibia; this point is important in connection with Excision of the Knee-joint in young persons, because for the growth of the Femur in length preservation of this Epiphyseal Cartilage is indispensable. A thicker piece can, therefore, be

removed from the Femur than from the Tibia without interference with the growth in length of the bone.

These figures, moreover, shew the relations of the Epiphyses to the Capsule on the different aspects of the joint. As the Capsule (Fig. 177) reaches in front and behind as far as the Epiphyseal Line, but only covers a small part of the Epiphysis laterally, disease commencing in the Epiphysis of the Femur (Tuberculosis, Acute Osteomyelitis) would behave differently according to the direction in which it spreads. If the disease extends forwards or backwards, it may perforate the joint; on the inner or outer side, it would become subcutaneous without affecting the joint. For the same reason the operator may work much lower down on either side than in front or behind the knee without risk of opening the joint.

Lastly, the figure shews the communication of the Bursa under the Semimembranosus Muscle with the joint cavity (cf. Fig. 183 and Fig. 184, Text).

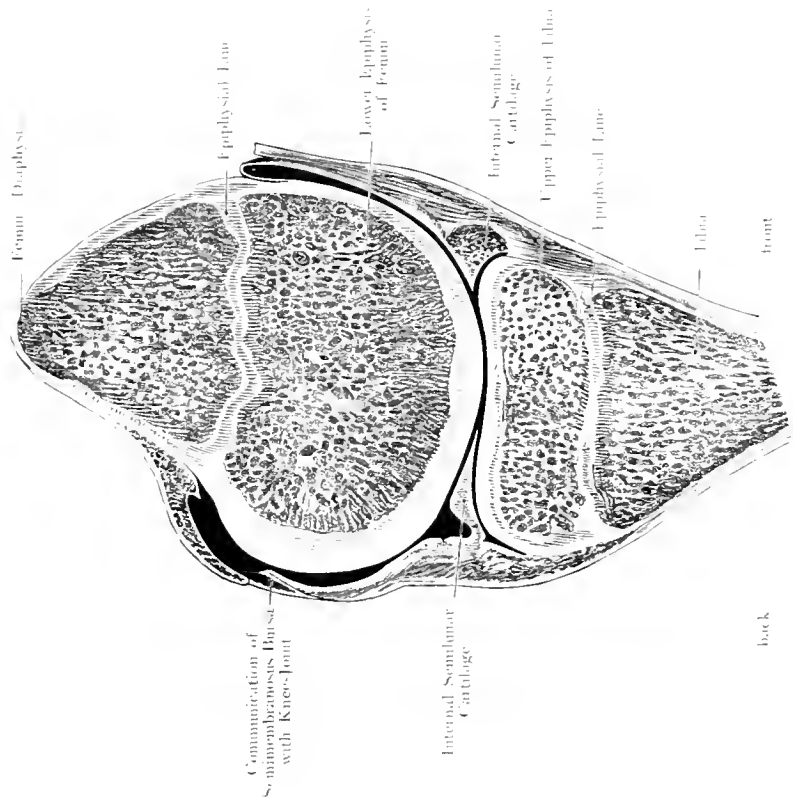


Fig. 179. Sagittal Section through the (right) Knee-Joint of a Boy aged 16.
 Seen from the outer side. — After VON BRUNN.

Rehman Limited, London.

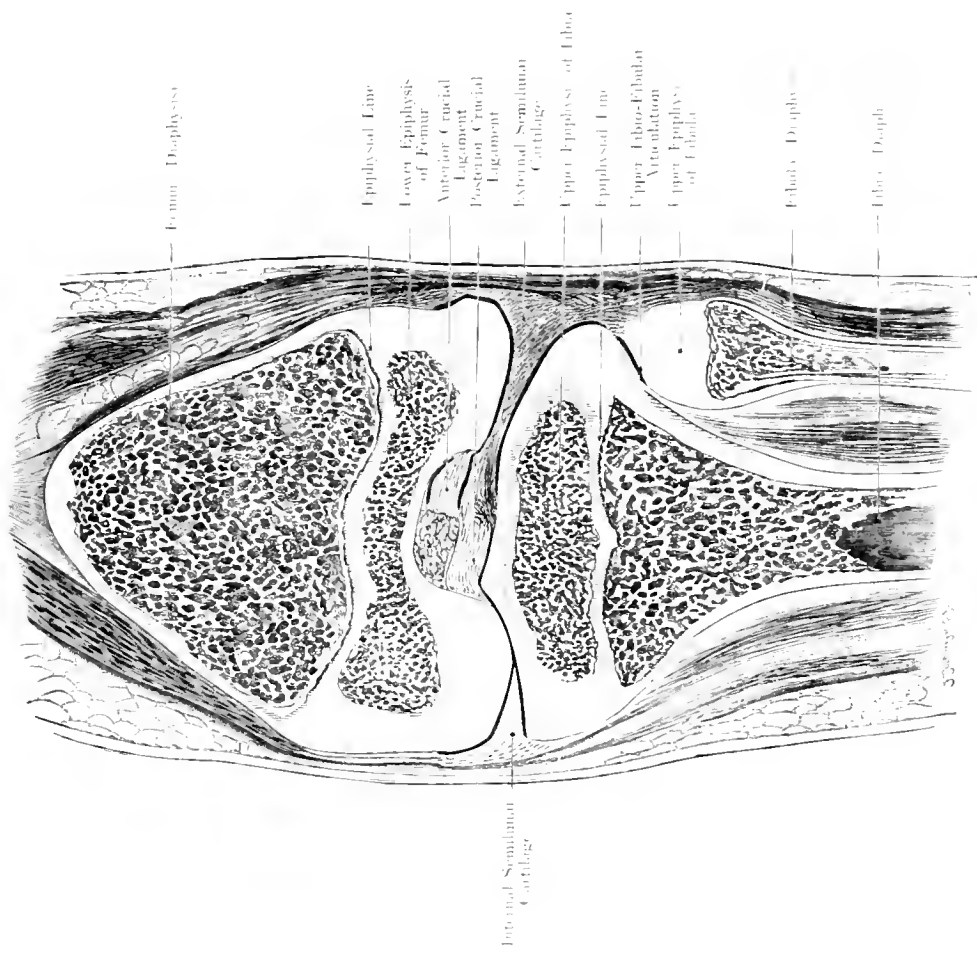


Fig. 180. Frontal Section through the (right) Knee-Joint of a Boy aged 8.
 Seen from behind. — After VON BRUNN.

Rehman Company, New York.

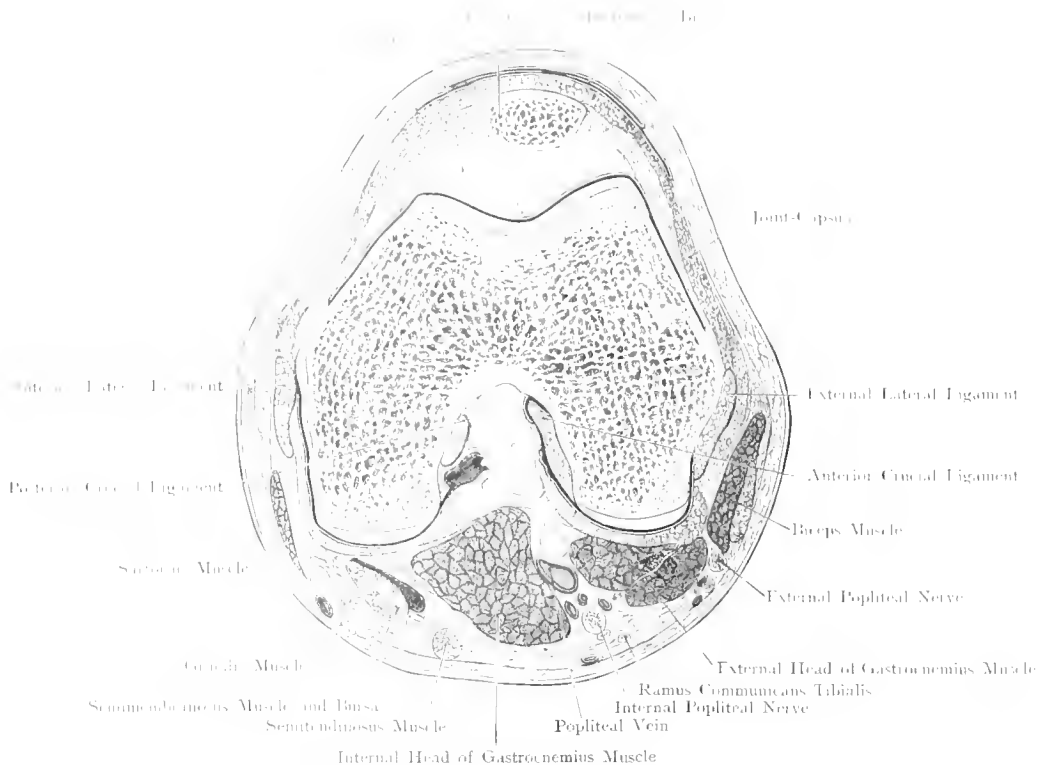
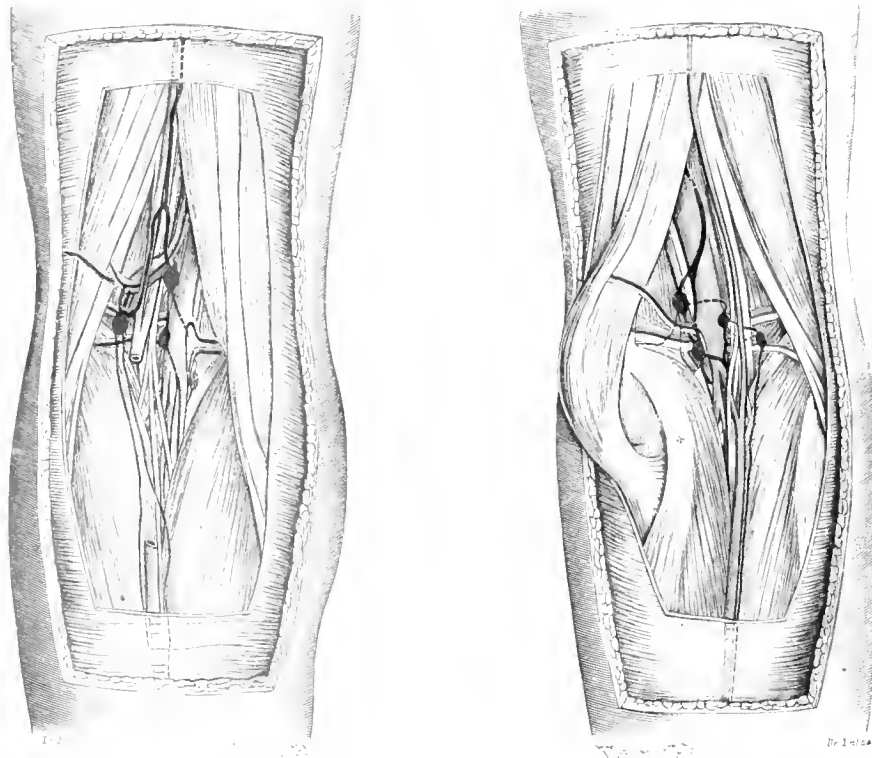


Fig. 181. Transverse Section through the right Knee-Joint.
 Seen from above. -- $\frac{2}{10}$ Nat. Size.



Figs. 182 and 183. Lymphatics of the Popliteal Space. $\frac{1}{2}$ Nat. Size.

Fig. 181. Transverse Section through the Knee-Joint.

Frozen Section.

This frozen section shews the Prepatellar Bursa (Subcutaneous and Subfascial Compartments), the lateral ligaments and anterior to these, the Retinacula of the Patella, which strengthen the Capsule. These Retinacula become of importance in Fracture of the Patella. When the Patella is broken transversely, the functional impairment of the Extensor Apparatus will depend on the extent of the destruction of these Retinacula.

Figs. 182 and 183. Lymphatics of the Popliteal Space.

Fig. 182. From a man aged 41 years. — Fig. 183. From a woman aged 60 years.

Normally there occur in the Popliteal Space more Lymphatic Glands than are usually stated (3—5); they are easily overlooked on account of their small size and the difficulty of their dissection in fat subjects. They may be divided into three groups (of at least one gland each): a Superficial group between the External Saphenous Vein and External Popliteal Nerve, separated from the latter by a thin fascia — the Superficial Popliteal Gland. The greater number lie close to the Popliteal Vessels under cover of the Internal Popliteal Nerve — the Deep Popliteal Glands. Variable in position is a gland below the vessels which receives the bulk of the lymphatics of this space; whereas the Afferent Lymphatic Vessels to the different groups of glands are fairly constant, there is much variation in the Efferent Vessels. Therefore different cases are depicted.

In Fig. 182, large Lymphatics, accompanying the Short Saphenous Vein, join the Superficial Gland; one Efferent Lymphatic extends upwards with the Femoro-popliteal Vein, another Efferent Lymphatic divides and joins the Articular Gland, which thus becomes a secondary gland to the Superficial as well as to the Deep Gland and the Lymphatics of the Joint. The large Efferent Vessel opened, in this instance, into the Efferent Tract (first mentioned), of the Superficial Gland and extended upwards as a stray vessel, to 4 inches beyond the figure, under cover of the fascia. After piercing the fascia it divided into 5 branches, and after a curved course opened into the Lower Internal Group of the Superficial Inguinal Glands.

The arrangement of the Lymphatics in Fig. 183 is similar. The Afferent Vessels join, in this case, to form a thick trunk which passes with the Popliteal Vein through the opening in the Adductor Magnus. Between these two extremes there are endless variations, both paths being used in equal or unequal proportions at the same time. We are not satisfied of the presence of a third path; if such were employed it would, theoretically, lead along the Great Sciatic Nerve to the Pelvic Glands. The Lymphatics of the lower extremity begin at the foot and follow, in front and on the inner side, the Long Saphenous Vein; on the posterior aspect they partly pass over the Popliteal Space and go to the inner side; partly, as shewn in the figure, to the Popliteal Space, under the fascia, accompanying the Short Saphenous Vein.

So that these Lymphatics may reach the Deep Inguinal Gland by following the Popliteal and Femoral Vessels, or join the Superficial Inguinal Glands after having pierced the fascia.

In Fig. 183, the Bursa in connection with the Semimembranosus Muscle has been opened and the Bursa under the Inner Head of the Gastrocnemius is shewn projected through that Muscle. Both communicate at the red spot which is marked by a †. We were unable in these cases and in 8 others, to shew any communication between these Bursae and the Knee-joint.

It, therefore, seems doubtful whether this Bursa communicates (in $\frac{2}{3}$ rd or $\frac{1}{2}$ of all cases), with the Joint as is stated in the books.

Weak spots in the Capsule favour the perforation backwards in pathological cases; in the removal of Hygromata, the joint is frequently opened on account of the tenuity of its wall.

Fig. 184. Popliteal Space.

The immediate continuation of the Fascia Lata is known as the Popliteal Fascia which, after covering the Popliteal Space, becomes directly continuous with the Fascia of the leg. On this lies the Short Saphenous Vein which sinks into the Popliteal Space and opens into one of the Popliteal Veins. After removal of this fascia, the Popliteal Space is exposed. This space is formed by the diverging Flexors of the leg (Biceps on the outer side inserted into the Head of the Fibula, Semimembranosus and Semitendinosus on the inner side inserted into the Crest of the Tibia), while out of the depth of the space, emerge the two converging heads of the Gastrocnemius. In this way a lozenge-shaped space is formed (void of muscles), which contains, well surrounded by fat, the Large Vessels and Nerves. The most superficial structure is the Internal Popliteal Nerve which traverses the space almost vertically, to disappear, after giving off its Communicating Tibial Branch, under cover of the Gastrocnemius Muscle. The division of the Great Sciatic Nerve into Internal and External Popliteal Nerves, has occurred at about or above the middle of the thigh. While the Internal Popliteal Nerve passes almost vertically downwards in the middle line, the External runs downwards and outwards along the inner border of the Biceps Muscle.

Somewhat internal and on a deeper plane is situated the Popliteal Vein, i. e. the largest of the 2 or 3 Veins which accompany the Artery; this vein is closely bound down to the Artery by connective-tissue. The Artery lies at a still deeper plane and more towards the middle of the space, it is here separated by a layer of fat, $\frac{1}{2}$ inch thick, from the Femur; near the articular surfaces of the Tibia it is closely applied to the capsule of the joint. Now the artery, having left the middle line, lies somewhat to the outer side (cf. Fig. 181). In cases of Excision of the Knee-joint, it could only be wounded at this spot. Its branches are the Superior and Inferior Internal and External Articular Arteries and the Azygos Articular Artery which pierces the posterior wall of the Capsule.

Close to the Internal Popliteal Nerve, is a small Lymphatic Gland; another may lie subcutaneously on the fascia, but there are rarely ever more than 4 (cf. Figs. 182, 183).

This figure also shews the Bursa under the Inner Head of the Gastrocnemius Muscle, which may communicate with the Knee-joint (Fig. 179). (Cf. Figs. 182 and 183, Text.)

This is of importance, because this Bursa may be the seat of a Hygroma which needs removal. It is, therefore, possible to infect the Knee-joint during an operation on this Bursa.

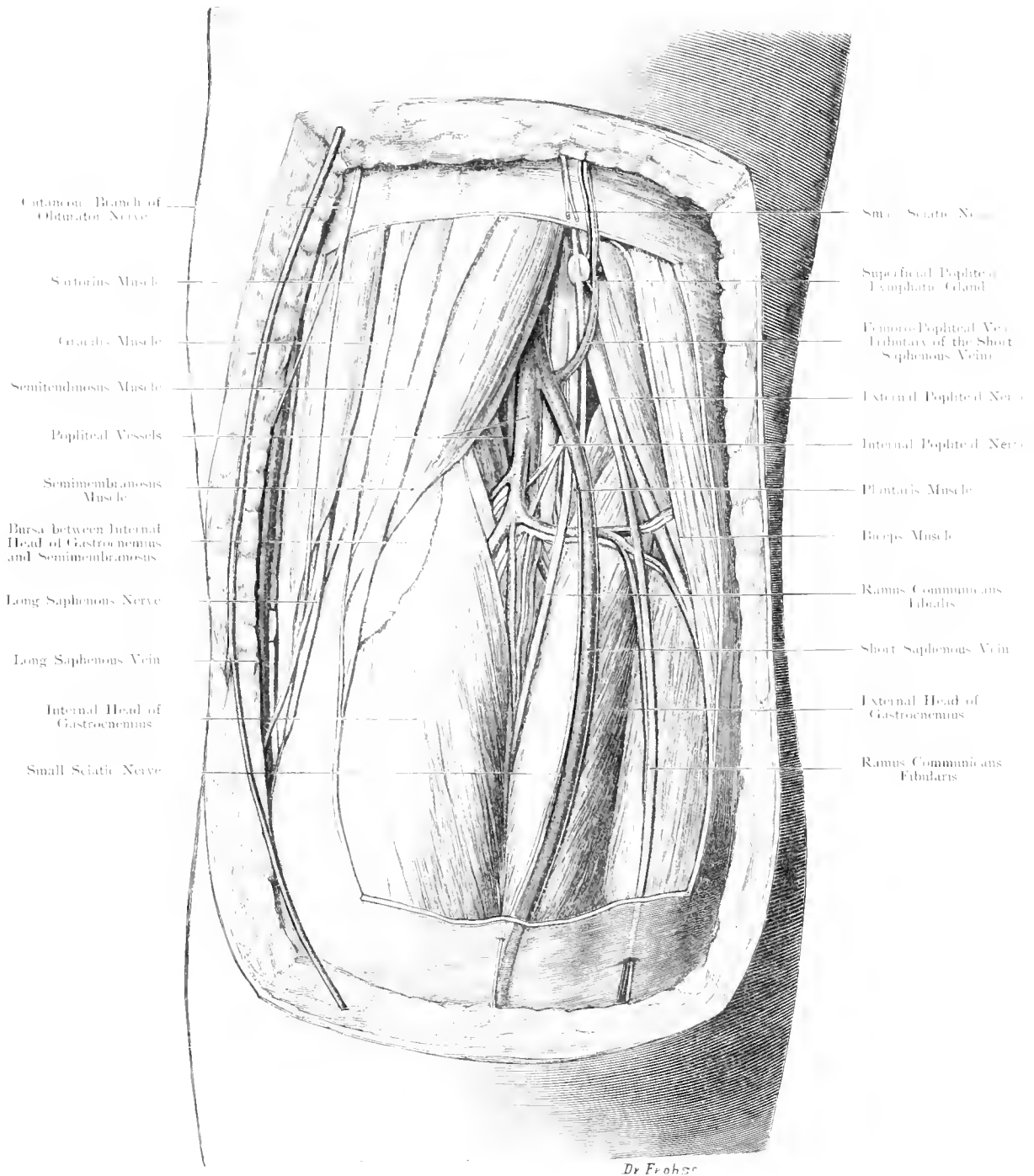


Fig. 184. Popliteal Space on the right side.

$\frac{7}{16}$ Nat. Size.

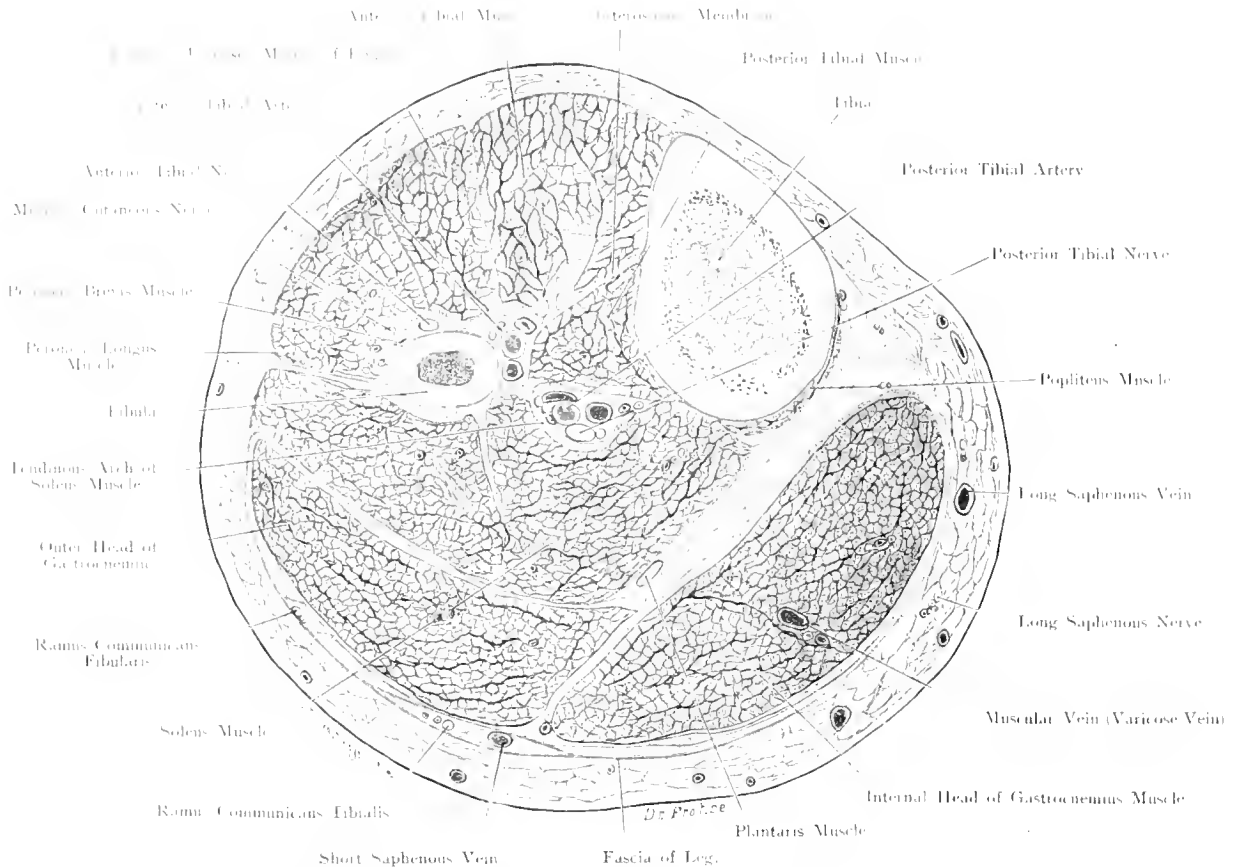


Fig. 185. Transverse Section through the right Leg at the Junction of Upper and Middle thirds.
 Seen from below. - Nat. Size.

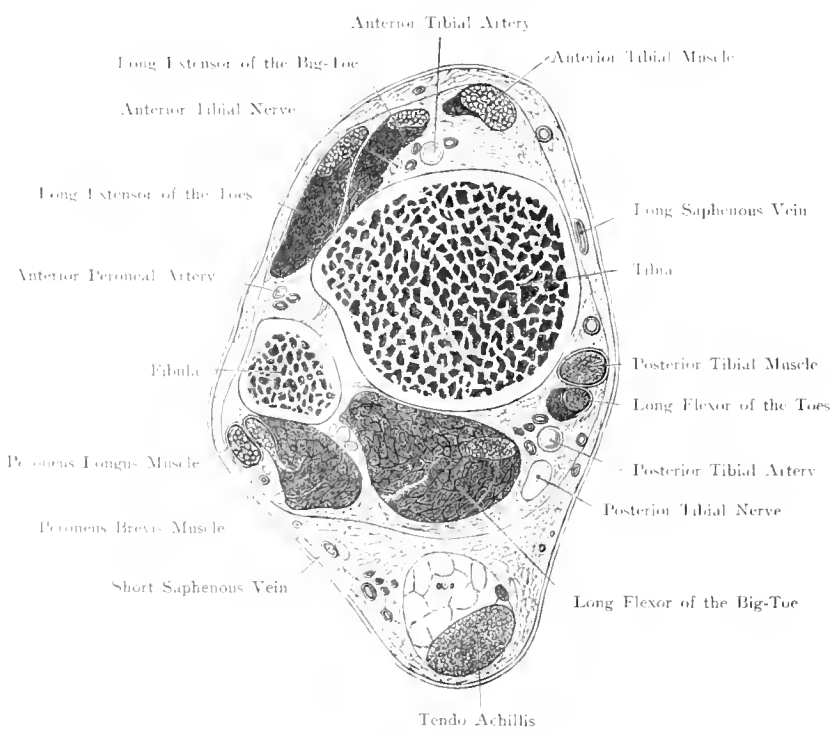


Fig. 186. Transverse Section through the right Leg near the Ankle.
 Seen from below. - Nat. Size.

Figs. 185 and 186. Transverse Sections through the Leg at the beginning of the middle third and near the ankle.

Frozen Sections.

The Fasciae (blue) in Fig. 185, shew that on the Anterior aspect of the limb, the Extensor Group of Muscles arise from fascia; on the Posterior aspect from the Fascia enveloping the limb, and forming a special canal for the Short Saphenous Vein; the particular Fasciae of the Muscles are represented.

At a higher level this Fascia is continuous on the flexor aspect with muscular attachments: on the outer side, with the expansion of the Biceps Tendon internally with the expansion of the Sartorius, Gracilis and Semitendinosus Tendons.

The circumference of the leg diminishes below the middle as the muscles become tendinous, thus near the ankle there are practically only tendons and bones.

In the subcutaneous tissue, the Long Saphenous Vein on the inner, and the Short Saphenous Vein on the posterior surface are observed. The Fascia, which is a continuation of the Fascia Lata, is only interrupted by the Anterior Surface of the Tibia as it becomes intimately blended with the Periosteum. On the Antero-external aspect the Fascia sends a septum to the Fibula, which separates the Peroneal Muscles from the Extensors. A deep layer passes transversely across from the Posterior Surface of the Tibia to the outer surface of the Fascia, this layer lies deep to the Soleus and Gastrocnemius Muscles, which it separates from the still more deeply situated Flexors. Above the ankle this layer is very strong and binds the Flexors down to the Bone; the Tendo Achillis becomes more prominent near the Os Calcis. The space formed in this way is filled by large pads of fat. The Internal Surface of the Tibia is palpable throughout its whole extent being only covered by skin and thin superficial fascia. The other surfaces of this triangular prism of bone are covered by muscles. The Fibula is completely surrounded by muscles except the Head and a triangular surface above the External Malleolus which are subcutaneous.

The bond of union between the Tibia and Fibula is very firm. The upper Tibio-Fibular Articulation allows of scarcely any movement; this joint may communicate with the Bursa under the Popliteus Muscle and indirectly with the Knee-joint. Lower down these two bones are held together by a very strong Interosseous Membrane, whereas in the lower third, the union is yet more firm.

Near the ankle, so firmly are these bones held together, that they may be viewed as one while the Inferior Tibio-Fibular Articulation is rather to be considered as an excavation of the Ankle-joint, than as an independent joint.

In the upper third of the leg, of the 2 most important vessels which require ligation, the Anterior Tibial Artery is easily found on the Posterior Surface of the Posterior Tibial Muscle in the Neuro-Vascular Bundle; external to this is the Peroneal Artery.

Fig. 187. Outer Aspect of Leg. External Popliteal Nerve.

On the outer side a larger window has been cut out of the fascia; portions have been removed from the following muscles: Anterior Tibial, Long Extensor of the Toes, Long Extensor of the Big Toe, Long and Short Peroneal Muscles, so that portions of the Tibia and Fibula have been exposed.

The Anterior Aspect of the Leg is occupied by the Extensor Muscles of the Foot; the External Surface of the Tibia is covered by the Anterior Tibial Muscle and the Long Extensor of the Toes. About the middle of the leg, the Long Extensor of the Big Toe appears between these two muscles and in these relations the Tendons pass under the Annular Ligament, on to the Dorsum of the Foot.

On the outer side, the 2 Peroneal Muscles which arise from the Fibula pass down, as tendons, behind the Outer Malleolus. The large Vessels and Nerves are on the Flexor Aspect (cf. all large joints). Their branches to supply the anterior aspect of the leg pass to the front from the Popliteal Space by various routes. The Anterior Tibial Artery passes directly forwards over the upper margin of the Interosseous Membrane, and runs downwards upon this Membrane lying at first between the Anterior Tibial Muscle and Long Extensor Muscle of the Toes, then between the former and the Long Extensor Muscle of the Big Toe. In the lower third this tendon crosses the Artery obliquely, so that finally the Artery reaches the Dorsum of the Foot by passing below the Anterior Annular Ligament between the Long Extensor Muscles of the Toes and Big Toe.

The External Popliteal Nerve takes quite a different course, coming off the Great Sciatic Nerve at or above the middle of the thigh this nerve passes towards the outer boundary of the Popliteal Space and perforating the Long Peroneal Muscle winds around the head of the Fibula and appears on the anterior aspect of the Leg. In its course this nerve divides into a Superficial and a Deep branch; the former — Musculo-Cutaneous Nerve supplies the Peroneal Muscles and pierces the deep fascia at the junction of the middle and lower thirds of the Leg, whence it runs down to the Dorsum of the Foot as a Cutaneous Nerve. The Anterior Tibial Nerve passes obliquely through the Origin of the Long Extensor Muscle of the Toes, and runs downwards on the outer side of the Artery; lower down the Nerve crosses in front of the Artery and lies antero-internal to it at the ankle-joint. In its course it supplies the three Extensors on the front of the Leg.

The position of the External Popliteal Nerve passing round the head of the Fibula requires great care in operations on the upper end of the Fibula because a deep longitudinal incision would divide the nerve.

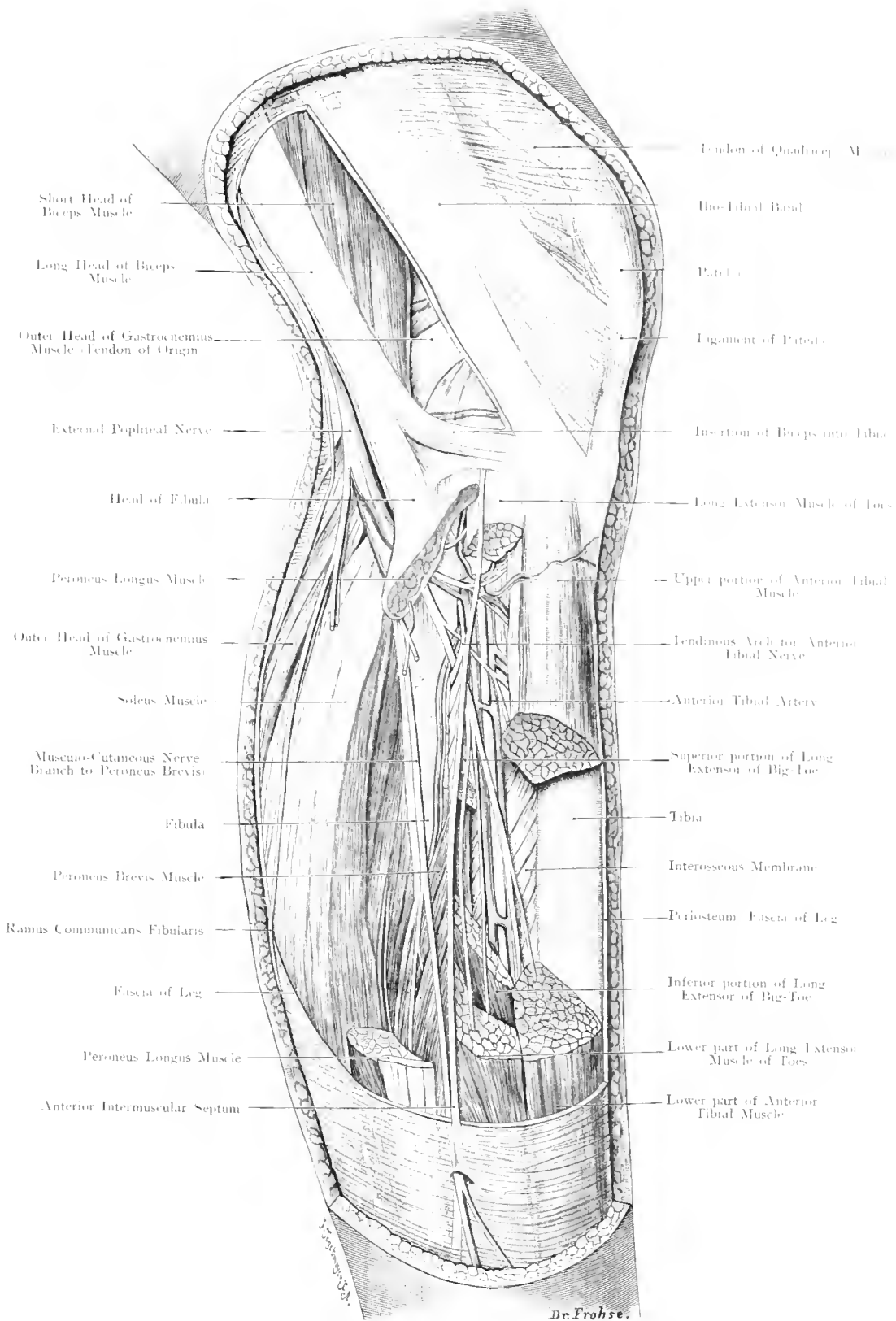
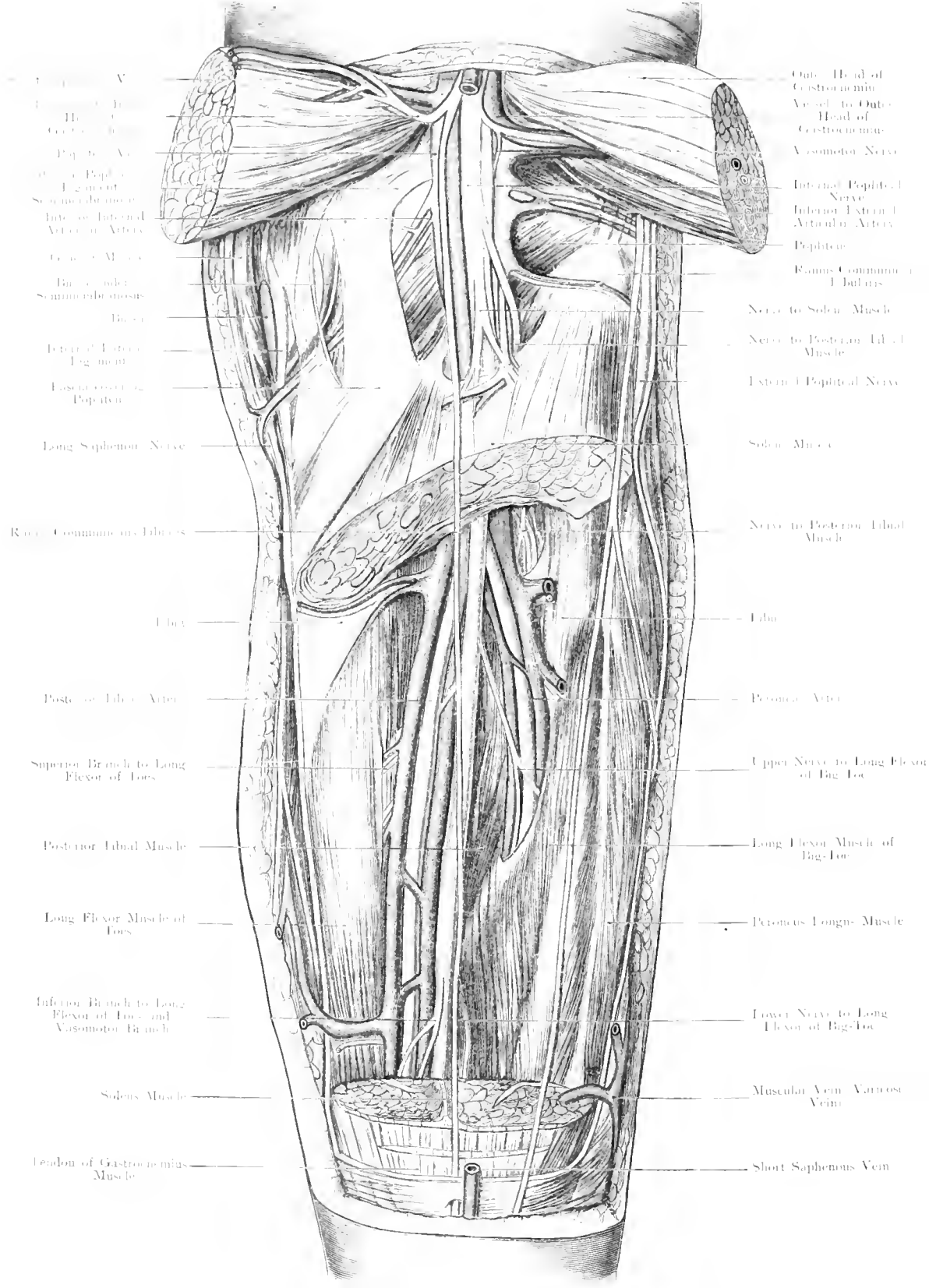


Fig. 187. Right Leg. Outer Side. External Popliteal Nerve.

$\frac{2}{3}$ Nat. Size.



1. Head of Gastrocnemius
 2. Vessel to Outer Head of Gastrocnemius
 3. Popliteal Vein
 4. Outer Popliteal Nerve
 5. Sciatic Nerve
 6. Internal Popliteal Artery
 7. External Popliteal Artery
 8. Gastrocnemius
 9. Branches of Sciatic Nerve
 10. Branches of Sciatic Nerve
 11. External Popliteal Nerve
 12. Long Saphenous Nerve
 13. Rami Communica. Fibrosi
 14. Tibia
 15. Posterior Tibial Artery
 16. Superior Branch to Long Flexor of Toes
 17. Posterior Tibial Muscle
 18. Long Flexor Muscle of Toes
 19. Inferior Branch to Long Flexor of Toes and Vasomotor Branch
 20. Soleus Muscle
 21.endon of Gastrocnemius Muscle

22. Outer Head of Gastrocnemius
 23. Vessel to Outer Head of Gastrocnemius
 24. Vasomotor Nerve
 25. Internal Popliteal Nerve
 26. Internal External Articular Artery
 27. Popliteus
 28. Rami Communica. Fibrosi
 29. Nerve to Soleus Muscle
 30. Nerve to Posterior Tibial Muscle
 31. External Popliteal Nerve
 32. Soleus Muscle
 33. Nerve to Posterior Tibial Muscle
 34. Tibia
 35. Posterior Artery
 36. Upper Nerve to Long Flexor of Big Toe
 37. Long Flexor Muscle of Big Toe
 38. Peroneus Longus Muscle
 39. Lower Nerve to Long Flexor of Big Toe
 40. Muscular Vein Vasomotor Vein
 41. Short Saphenous Vein

H. Frause.

Fig. 188. Right Leg from behind: Deep Layer. Internal Popliteal Nerve.

1/2 Nat. Size.

Fig. 188. Posterior Aspect of Leg. Deep Layer, Internal Popliteal Nerve.

After removal of the Superficial Fascia, a large piece has been cut out of the Gastrocnemius and Soleus Muscles, the heads of origin of the Gastrocnemius have been thrown outwards. By further removal of the Deep Fascia, the large Vessels and Nerves have been exposed. An incision through the fascia covering the Popliteus Muscle has exposed the Bursa under the Semimembranosus Muscle.

The arrangement of the muscles on the back of the leg is very simple: a Superficial Layer formed by the Gastrocnemius, Soleus and the slender Plantaris; a Deep Layer formed by the Posterior Tibial, Long Flexor of Toes and Long Flexor of Big-Toe. On this latter group lie the important Nerves and Arteries, which are quite separated from the Superficial Layer of muscles by the Deep Fascia of the Leg (v. Figs. 185, 186). Between the Deep Fascia of the leg and the Superficial Muscles, loose connective tissue, favourable to the spread of Cellulitis is found.

In order to allow the vessels and nerves, leaving the Popliteal Space, to reach the deep aspect of the superficial muscles an aponeurotic opening is formed by the Soleus i. e. an arch is thrown across from its Tibial to its Fibular Origin under which the above mentioned structures pass.

At the lower border of the Popliteus Muscle, the Popliteal Artery divides into Anterior and Posterior Tibial Arteries (occasionally this division takes place at a higher level). The Anterior Tibial Artery (the smaller branch), passes directly over the upper border of the Interosseous Membrane to the Anterior Aspect of the Leg; the Posterior Tibial Artery passes under the arch of the Soleus, approaches the inner side of the limb and lies in its outer third under the skin between the Tendons on the Long Flexor of the Big-Toe and the Long Flexor of the Toes; together with these tendons it passes behind the Internal Malleolus into the sole of the foot. The chief branch from this vessel is the Peroneal Artery which runs outwards through the arch of the Soleus, under cover of the Fibular origin and the muscular belly of the Long Flexor of the Big Toe, to near the ankle where it emerges and terminates by giving off a Perforating Branch to the Anterior Tibial Artery and a large Communicating Branch (sometimes double) to the Posterior Tibial Artery or the outer side of the heel.

The Posterior Tibial Nerve runs along the outer side of the Artery, and after giving off numerous branches, passes with it under the Internal Annular Ligament to the sole of the foot.

Deeply situated on the Interosseous Membrane lies the Posterior Tibial Muscle. As the Tibia is subcutaneous throughout its whole length, the structure of the leg is convenient for extensive operations. The Fibula is readily exposed after removal of the Soleus Muscle, but care must be taken in the neighbourhood of its head to avoid injury to the External Popliteal Nerve.

Fig. 189. Synovial Sheaths of the Tendons behind the Internal Malleolus.

The Tendo Achillis, Plantar Fascia, a large part of the Abductor Muscle of the Big Toe, the Short Flexor of the Toes and the Deep Fascia of the Leg have been removed. The Annular Ligament has been dissected out and the Tendon-sheaths distended with Gelatin.

Strong Septa extend from the Internal Annular Ligament to the posterior surface of the Tibia, so that the Tendons run in Osteo-aponeurotic Canals, enclosed by synovial sheaths. The Sheath of the Posterior Tibial Tendon commences two inches above the tip of the Internal Malleolus and reaches as far as the insertion of this Tendon into the Scaphoid Bone, so as to extend a little further downwards on the bony aspect of the tendon. Immediately behind this sheath and rarely communicating with its upper end lies the Sheath of the Long Flexor Muscle of the Foot. This sheath extends to a higher level up the leg than the former and is inserted obliquely on the tendon, leaving its posterior border free as long as muscle fibres are inserted into it.

The sheath ends at the level of the Astragalo-Scaphoid Joint. Still nearer the Os Calcis is the Sheath of the Long Flexor of the Big-Toe separated from the Long Flexor of the Toes by a space occupied by the Posterior Tibial Nerve and Vessels on their way to the sole of the foot. This sheath commences one inch above the Tip of the Malleolus and may reach as far as the base of the first Metatarsal Bone. At the point where the Tendon of the Long Flexor of the Big-Toe crosses the Long Flexor of the Toes and has a band of communication with the latter, the Tendons still remain within their proper sheaths, but these sheaths communicate with each other; in many cases the Long Flexor of the Big-Toe is without synovial covering at the point of crossing.

Like the tendon-sheaths in the hand, these sheaths are of importance in connection with the spreading of inflammatory processes from the foot to the leg and vice versa. Moreover, as they pass over the Capsule of the Ankle-joint disease may perforate these Sheaths and extend to the Ankle-joint or in the reverse direction.

At the toes the Flexor Tendons, like those of the Hand, have sheaths with one important difference; at the toes they never communicate with the Central Synovial Sheaths.

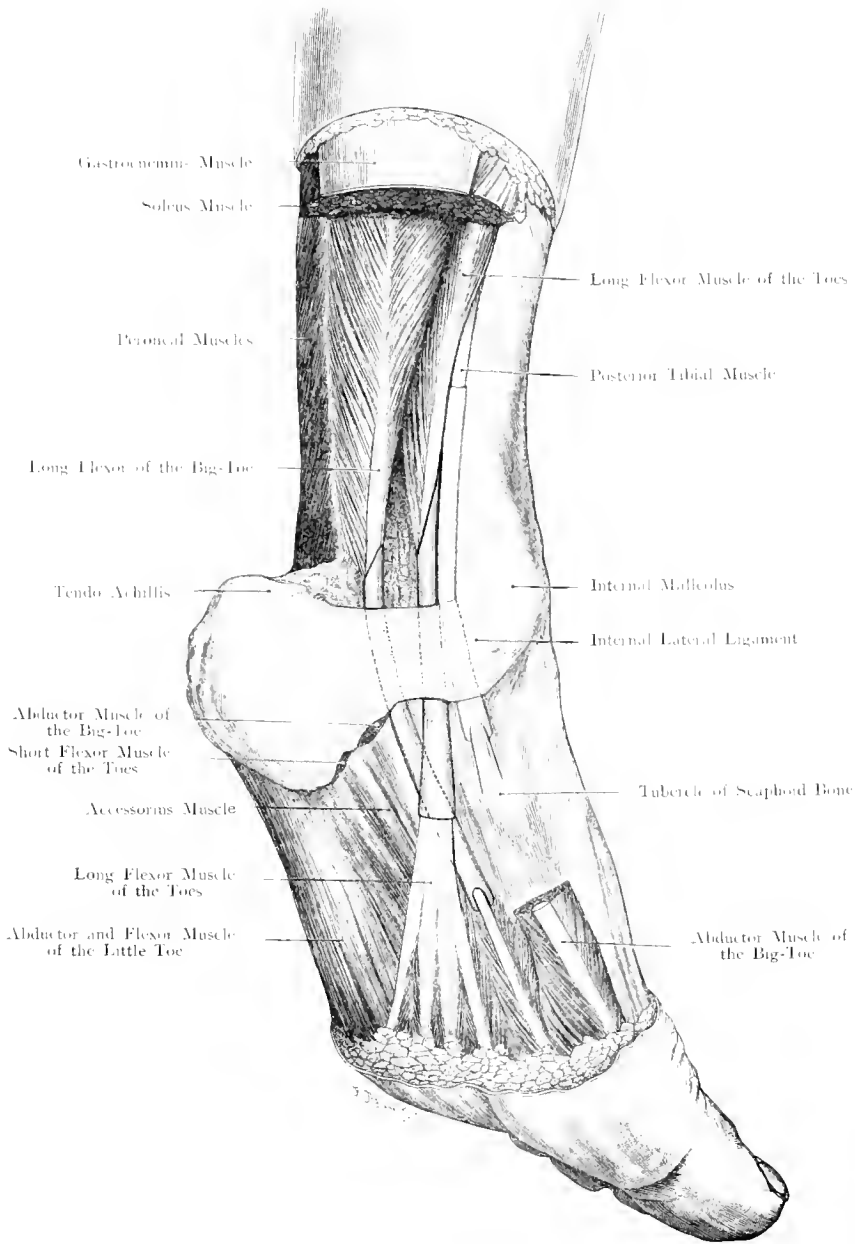


Fig. 189. Tendon Sheaths behind the Internal Malleolus.

$\frac{1}{2}$ Nat. Size.

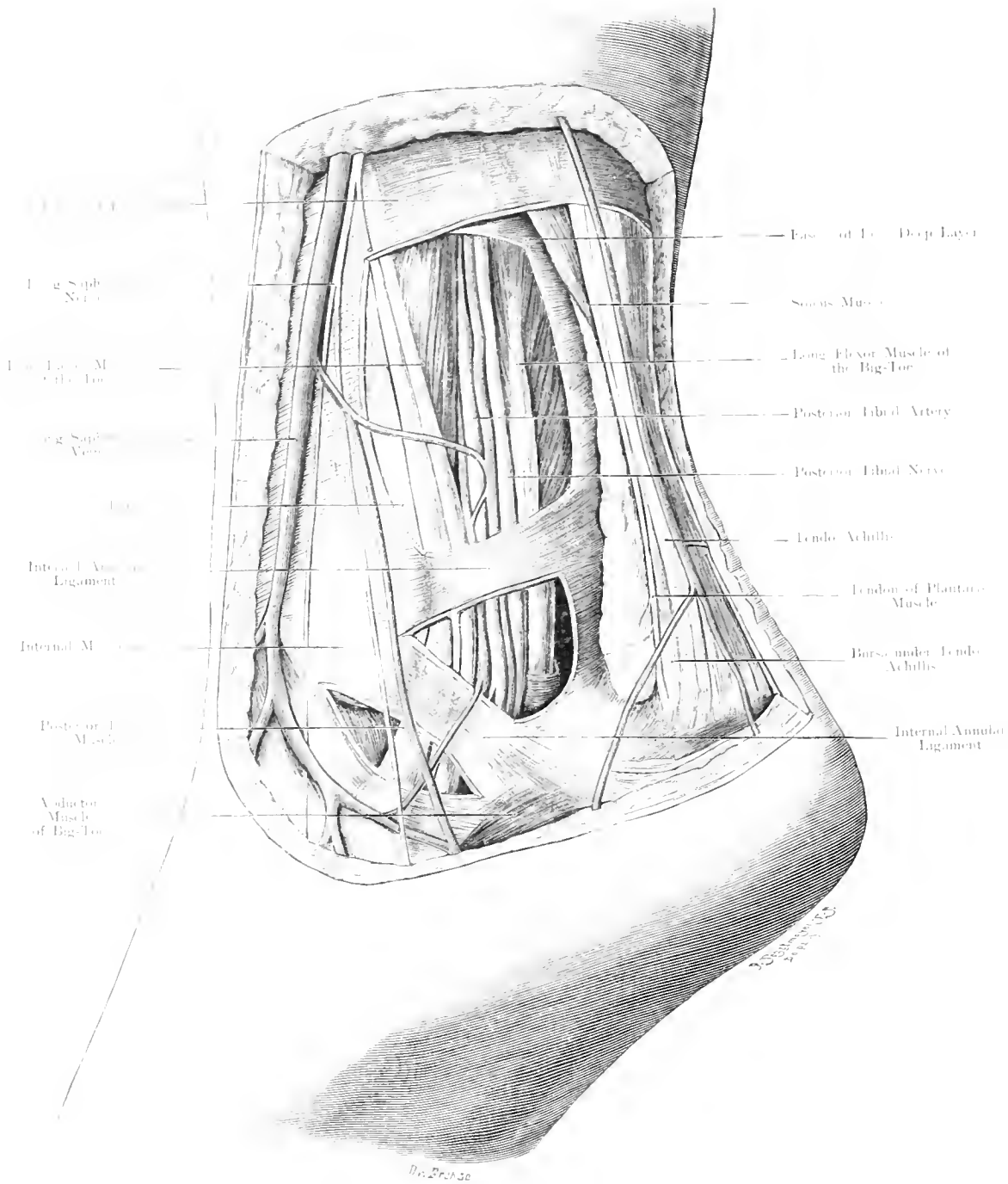


Fig. 190. Region of (right) Internal Malleolus from behind.
Nat. Size.

Fig. 190. Region behind the Internal Malleolus.

Right Leg of a girl aged 15 years. The region around the Internal Malleolus is exposed in layers. 3 windows have been made in the Deep Fascia and Internal Annular Ligament.

The Long Saphenous Vein runs in the Superficial Fascia as far as the Internal Malleolus accompanied by the Long Saphenous Nerve. The Fascia of the Leg is strengthened behind the Internal Malleolus by thick bands of fibres which radiate from the Malleolus towards the inner surface of the Os Calcis and Plantar Fascia — the Internal Annular Ligament. This Ligament forms a bridge under which the Flexor Tendons, Nerves and Vessels pass to the sole of the foot.

Nearest to the Internal Malleolus under this fascia and in a strong Aponeurotic Canal the Tendon of the Posterior Tibial Muscle passes, next to this the Tendon of the Long Flexor of the Toes. The Tendon of this muscle crosses the Posterior Tibial Muscle in the Leg from within outwards.

Nextly, the Posterior Tibial Vessels lie between the Long Flexor of the Toes and the Long Flexor of the Big Toe so that, for ligature of this vessel, the mid-point between Internal Malleolus and Tendo Achillis serves as the landmark.

Directly posterior to the Artery is the Posterior Tibial Nerve or its terminal branches. — Internal and External Plantar Nerves. — The space posterior to this and extending as far back as the Tendo Achillis is occupied by fat; in this is found the Tendon of the Plantaris which is inserted into the posterior part of the Os Calcis, along side of the Tendo Achillis.

By pushing the Vessels and Nerves forwards, the posterior segment of the Ankle-joint can be reached. The Long Flexor of the Big Toe passes over the middle of the joint. Between this and the other tendons, posterior to the Inner Malleolus on the one side and the Peroneal Tendons behind the outer Malleolus on the other side, the Capsule of the Joint may bulge in cases of effusion into the joint, because it is not strengthened at these points. For operations, such as Extirpation of the Capsule in Tuberculosis, the joint is accessible from behind. The arrangement is analogous with that on the Anterior Aspect of the joint near the Extensor Tendons (cf. Fig. 193), there is, however, the difference that, owing to its deeper position, the swelling of the joint is only noticed posteriorly when extensive. It becomes visible when the hollow next to the Tendo Achillis is filled out.

Fig. 191. Sole of (Right) Foot. Superficial Layer.

The Plantar Fascia has been removed. The Short Flexor of the Toes except its origin and tendinous insertion has been cut out.

As in the palm of the hand, the fat of the sole of the foot is firm, lobulated and compressed within the fine meshes of a fine connective tissue which is intimately connected superficially with the skin, and deeply with the Plantar Fascia. The skin is consequently not movable — mobility would be inconvenient —. The Plantar Fascia arises as a strong aponeurosis from the inner tubercle of the Os Calcis and diminishing in thickness, as it extends forwards, divides into 5 processes, one for each toe. Arising in part from the deep surface of this fascia are seen in the middle third the Short Flexor of the Toes, on the inner side, the powerful Abductor Muscle of the Big-Toe, and on the outer side, the Abductor Muscle for the little Toe. Deep to the Short Flexor of the Toes, lies the Accessory Muscle, this by its insertion into the Tendon of the Long Flexor of the Toes changes the oblique pull of that Tendon into a longitudinal force.

The Posterior Tibial Artery and Nerve divide behind the Internal Malleolus into Internal and External Plantar Arteries and Nerves, and pass under the Internal Annular Ligament and the Abductor Muscle of the Big Toe, which extends like a bridge from the Os Calcis to the first phalanx of the Big Toe. The smaller Internal Plantar Artery runs forwards along the inner border of the Big Toe, accompanied by the Internal Plantar Nerve — somewhat like the Median in the hand — to supply the 3 inner Toes and the inner side of the 4th Toe with common sensibility. The External Plantar Artery, the larger of the two, arches outwards, forming the Plantar Arch, and disappears by passing deep into the middle of the sole; with this vessel runs the External Plantar Nerve — like the Ulnar in the hand — giving off a Superficial Branch to supply the 5th Toe and the outside of the 4th Toe and a Deep Branch to accompany the Plantar Arch.

Fig. 192. Sole of (Right) Foot. Deep Layer.

The Superficial Layers have been removed as in Fig. 191. A large piece has been cut out of the Accessory Muscle together with the Tendon of the Long Flexor Muscle of the Toes, and the Oblique Adductor of the Big Toe. Deep to the Tendons of the Long Flexor of the Toes and the Lumbrical Muscles are placed the Transverse and Oblique Adductor of the Big Toe.

Still deeper, the spaces between the Metatarsal Bones are filled by the Interosseous Muscles. The External Plantar Artery disappears at the base of the fifth Metatarsal Bone under the Oblique Adductor of the Big Toe, and supplies the toes, anastomosing in the first interosseous space with the termination of the Dorsal Artery of the Foot. (The Anterior and Posterior Tibial Arteries can thus replace each other.) The arrangement of the Arteries in the Foot differs from those in the Hand; there is no Superficial Arch in the Foot. The Digital Arteries must, therefore, arise deeply because superficial vessels would be pressed upon too much. The External Plantar Nerve is analogous to the Ulnar Nerve in the Hand; its Deep Branch accompanies the Arch. The Nerve disappears under the Oblique Adductor and supplies the 2 outer Lumbrical Muscles, a part of the 3rd, the Interossei, and the Oblique and Transverse Adductors of the Big Toe. The Tendon of the Long Peroneal Muscle extends from the outer side obliquely across the foot to be inserted into the base of the first Metatarsal Bone. In its course, it is enclosed by a fibrous sheath which does not communicate with the Common Peroneal Sheath behind the External Malleolus (Fig. 191). The Oblique Adductor of the Big Toe arises partly from this sheath.

Fig. 197. Frontal Section through the (Right) Ankle-Joint.

Frozen Section. As the section did not pass directly through the tip of the External Malleolus some tissue was removed in order to expose this prominence.

The Tibia and Fibula by means of their Malleoli form a socket which grips the Astragalus. The External Malleolus extends to a lower level than the Internal; the joint cavity extends upwards between the lower ends of these bones forming a recess called the Inferior Tibio-Fibular Articulation. To the Tibia and Astragalus the Capsule is attached along the border of the articular cartilages (on the anterior surface only does the Capsule extend to the neck of the Astragalus). By this arrangement a considerable portion of the Neck of the Astragalus may enter the joint cavity in extreme dorsi-flexion of the foot. Corresponding to the free movements in Dorsal and Plantar Flexion, the capsule is loose in front and behind, so as to form folds (vide Fig. 199) but on either side strong tense ligaments attach the Malleoli to the Astragalus and Os Calcis; the Deltoid Ligament extending from the Internal Malleolus to the Astragalus and Sustentaculum Tali, the Anterior and Posterior Astragalo-Fibular Ligaments and the Calcaneo-Fibular Ligaments extending from the External Malleolus to the Astragalus and Os Calcis respectively.

The ankle-joint is therefore not easily accessible from the side; behind, it lies at a considerable depth under the Tendo Achillis, but can be reached (cf. Fig. 190). Its anterior aspect, on either side of the Extensor Tendons, is the most accessible (cf. Fig. 193).

This figure also shews the position of the Peroneal Muscles enveloped in their sheaths below the Outer Malleolus and the position of the Flexors on the inner side. The Posterior Tibial Artery and Nerve have already divided into Internal and External Plantar Branches which are now lying in a well-protected position between muscles. Between the Astragalus and the Os Calcis, the Posterior Calcaneo-Astragaloid Articulation can be seen; this lies at a slightly higher level than the tip of the External Malleolus.

The Anterior Calcaneo-Astragaloid Joint which is separated from the Posterior by the Interosseus Ligament (v. Fig. 199) is not an independent joint but is a part of the Astragalo-Scaphoid Articulation, whereas the Posterior Calcaneo-Astragaloid Articulation is quite independent and liable to independent affections. If swollen it bulges forwards and outwards to point anteriorly at the Tip of the External Malleolus.

The movements of Abduction and Adduction are limited at this joint.

The inner border of the foot is arched and does not touch the ground.

Fig. 198. Transverse (Frontal) Section through the Anterior Part of the Tarsus.

Frozen Section.

The Foot is arched both Antero-posteriorly and Transversely. The Transverse Arch, shewn in the figure, begins posteriorly where the Os Calcis with its Sustentaculum Tali forms a semicircle (v. Fig. 197).

A little further forward the Scaphoid and Cuboid Bones form an arch, whereas in front of these the arch becomes more definite as the Cuneiform Bones with their broad Dorsal and narrow Plantar Surfaces closely resemble the stones of an arch.

The Longitudinal Arch is still more pronounced in the Metacarpal Bones. The Plantar Vessels and Nerves run forward under cover of this arch which serves to protect them from pressure (due to the weight of the body).

Fig. 199. Longitudinal (Sagittal) Section through the Foot.

Frozen Section carried through the middle of the Tibia and the outer part of the 2nd Toe.

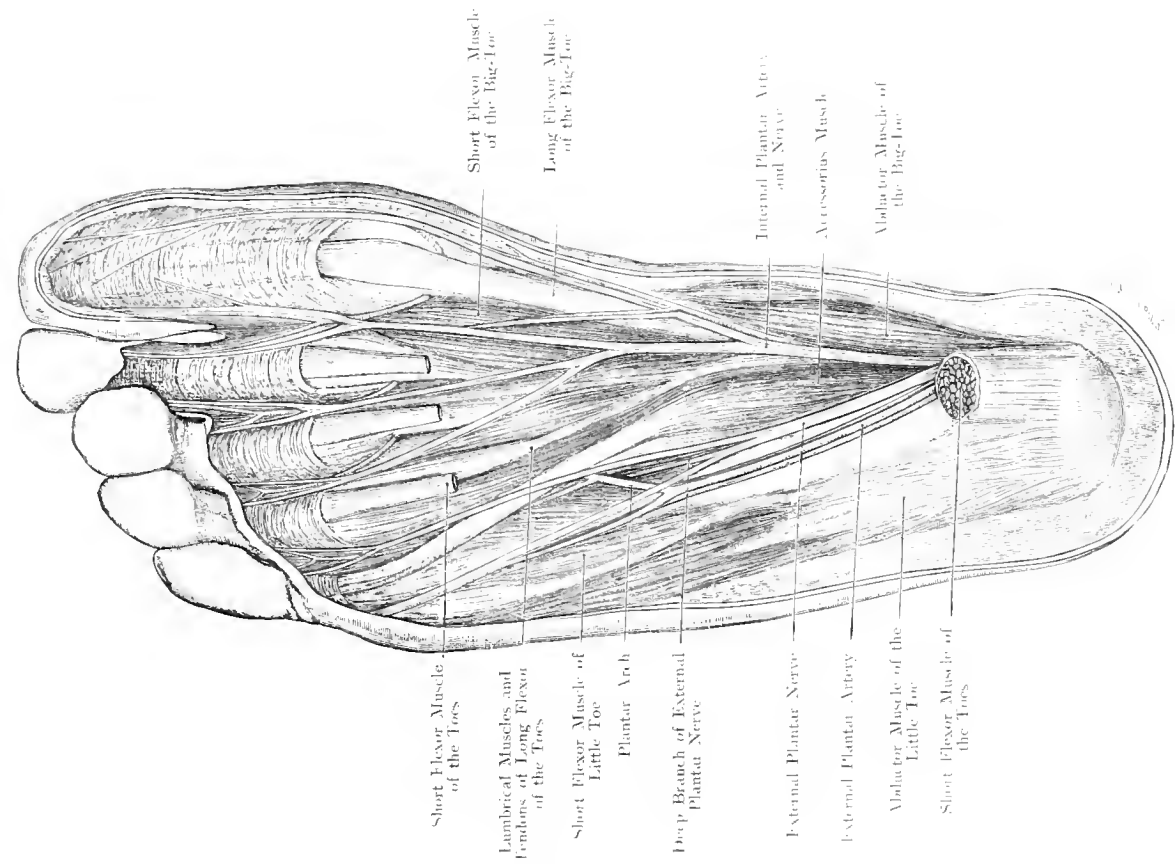
This figure shows the Longitudinal Arch which is most marked on the inner side. The inner tubercle of the Os Calcis and the head of the 1st Metatarsal Bone form the Pillars of this Arch. On the outer side of the Foot the arch is less curved; here its Anterior Pillar is formed by the base of the 5th Metatarsal Bone. The Astragalus forms the Keystone of this Arch. Strong ligaments bind together the bones on their Plantar Aspect and firmly brace up the arch; the Plantar Fascia stretched across from the Inner Tubercle of the Os Calcis to the Heads of the Metatarsal Bones acts like a bowstring.

Mention must also be made of the assistance rendered by the Tendon of the Posterior Tibial and other Muscles in keeping up the Arch.

This figure further shews: a Bursa (always present) between the Os Calcis and Tendo Achillis. (A Bursa between the Tendo Achillis and the Superficial Fascia is rarely met with.)

The cavity of the ankle-joint extends backwards nearly as far as the Posterior Calcaneo-Astragaloid Articulation. In front it is $\frac{3}{5}$ ths inch distant from the Astragalo-Scaphoid Joint. This explains why inexperienced persons, when performing CHOPART'S disarticulation, easily open the ankle-joint instead of the Astragalo-Scaphoid Articulation.

The figure shews also that the Posterior Calcaneo-Astragaloid Articulation is a complete joint, whereas the anterior is merely a part of the Astragalo-Scaphoid Articulation.



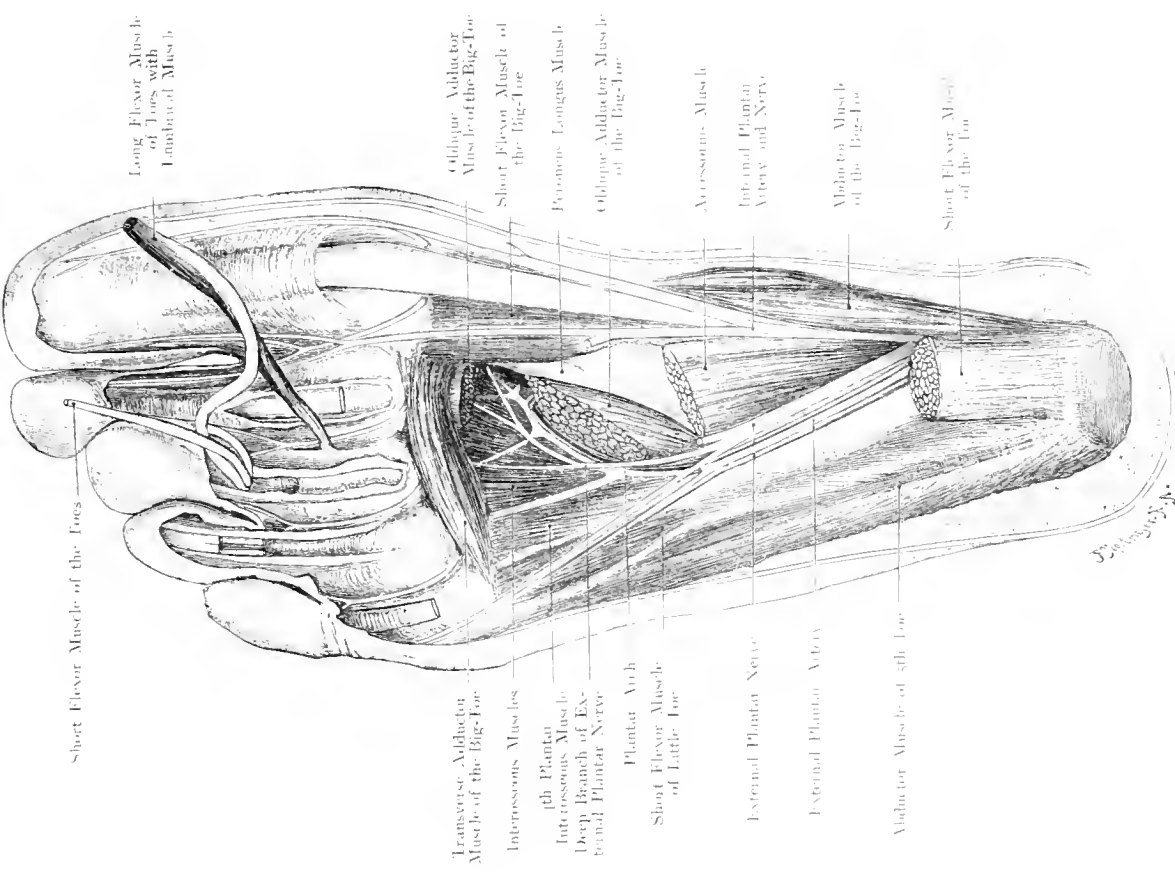
Short Flexor Muscle of the Toes
 Lumbrical Muscles and Tendons of Long Flexor of the Toes
 Short Flexor Muscle of Little Toe
 Plantar Arch
 Deep Branch of External Plantar Nerve
 External Plantar Nerve
 External Plantar Artery
 Abductor Muscle of Little Toe
 Short Flexor Muscle of the Toes

Short Flexor Muscle of the Big Toe
 Long Flexor Muscle of the Big Toe
 Internal Plantar Artery and Nerve
 Accessorius Muscle
 Abductor Muscle of the Big Toe

Fig. 191. Sole of (right) Foot. Superficial Layer.

7/8 Nat. Size.

Rehman Limited, London.



Short Flexor Muscle of the Toes
 Transverse Adductor Muscle of the Big Toe
 Interosseous Muscles
 4th Plantar Interosseous Muscle
 Deep Branch of External Plantar Nerve
 Plantar Arch
 Short Flexor Muscle of Little Toe
 External Plantar Nerve
 External Plantar Artery
 Abductor Muscle of 5th Toe
 Short Flexor Muscle of the Toes

Long Flexor Muscle of Toes with Lumbrical Muscle
 Oblique Adductor Muscle of the Big Toe
 Short Flexor Muscle of the Big Toe
 Promiens Longus Muscle
 Oblique Adductor Muscle of the Big Toe
 Accessorius Muscle
 Internal Plantar Artery and Nerve
 Abductor Muscle of the Big Toe
 Short Flexor Muscle of the Toes

Fig. 192. Sole of (right) Foot. Deep Layer.

7/8 Nat. Size.

Rehman Company, New York.

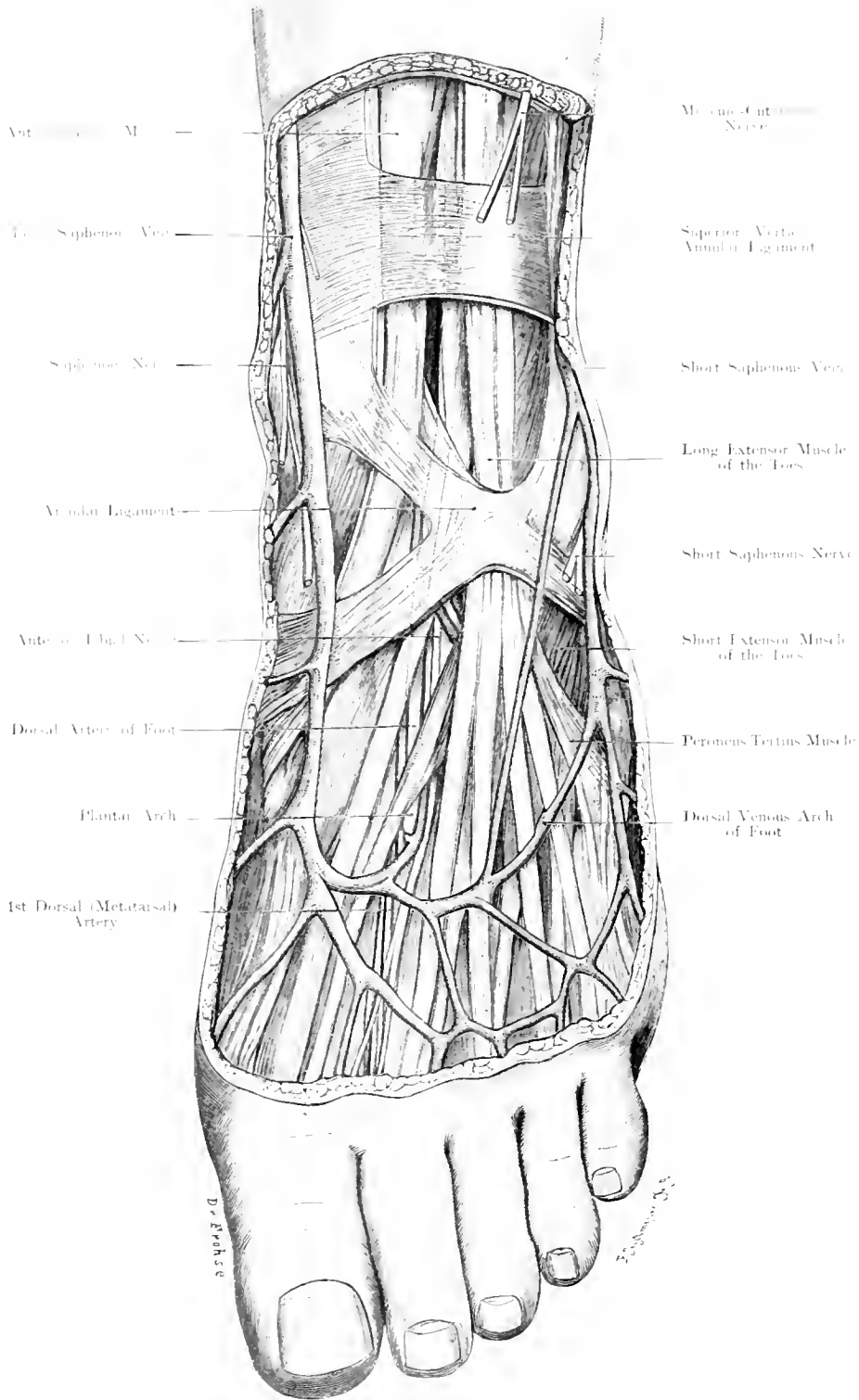


Fig. 193. Region of Ankle and Dorsum of Foot.

Nat. Size.

Fig. 193. Region of the Ankle and Dorsum of Foot. Left.

Preparation from a girl aged 15 years. The Fascia of the Leg and Dorsum of the Foot has been removed, but the Superficial Veins and the Anterior Annular Ligament have been preserved.

The open network of superficial fascia which occurs in this situation, contains little fat, but is rich in a Venous Plexus which terminates on the inner side in the Long Saphenous Vein, and on the outer side in the Short Saphenous Vein. The Fascia extending from the leg to the foot is considerably strengthened above and over the ankle by the Superior and Anterior Annular Ligaments. The latter is formed by a series of fibres which run from the Internal Malleolus outwards and downwards to the outer border of the foot, these fibres are crossed by another series of fibres which run from the inner border of the External Malleolus. These fibres are no independent structures but thickenings of the Fascia; they can only be displayed artificially (cf. Fig. 193).

The Extensor Muscles present the same relations as in the Leg. On the inner side, the Anterior Tibial Muscle is inserted into the Scaphoid and base of the first Metatarsal Bone, externally to this the Long Extensor of the Big Toe runs to the terminal phalanx of the Big Toe, next the Long Extensor of the Toes to the 4 outer Toes, and lastly the Peroneus Tertius (Third Peroneal) Muscle to the Tubercle of the 5th Metatarsal Bone. Arising from the first part of the upper and outer surface of the Os Calcis, deep to the Tendon of the Long Extensor of the Toes, lies the Short Extensor of the Toes, with its obliquely directed tendons which blend with the Long Extensor Tendons to form the dorsal aponeurosis of the toes. Between the Metatarsal Bones appear the Dorsal Interosseous Muscles.

At the mid-point between the 2 Malleoli and between the tendons of the Long Extensors of the Toes and Big Toe is situated the Anterior Tibial Artery; in its continuation below the Anterior Annular Ligament it is called the Dorsal Artery of the Foot which runs over the middle Cuneiform Bone onwards into the 1st interosseous space, where it anastomoses with the External Plantar Artery.

The Anterior Tibial Artery gives off to each Malleolus — a Malleolar Branch —, the Dorsal Artery of the Foot, to both inner and outer sides of the Foot a Tarsal Artery.

The Anterior Tibial Nerve generally on the inner side of the Dorsal Artery of the Foot, supplies the Short Extensor Muscle of the Toes and gives a Cutaneous Nerve to the contiguous sides of the Big Toe and the 2nd Toe.

On either side of the Extensor Tendons and between the tendinous bundle and each Malleolus is a space of considerable importance, because at these points the Capsule of the Joint is only covered by Skin and Superficial Fascia without any accessory strengthening fibres.

At no other place is the joint so exposed or so readily accessible. Moreover by a bulging of these spaces an effusion into the joint will be first observed.

Fig. 194. Outer Side of (Left) Foot.

Preparation from a girl aged 15 years. The Fascia over the Dorsum of the Foot has been removed with preservation of the Annular Ligament, Superficial Veins and Nerves. Fascial Bands which bind down the Peroneal Muscles are shown (Retinacula Peroneorum). Synovial Sheaths of Peroneal Muscles pink.

The Superficial Fascia behind the External Malleolus contains the Short Saphenous Vein and Nerve. Over the External Malleolus, (in $\frac{1}{2}$ to $\frac{1}{3}$ cases), there is a small Subcutaneous Bursa. The Peroneal Tendons are held within their grooves behind the External Malleolus by strong bands similar to those on the inner side which are derived from the Anterior Annular Ligament. Without these ligaments a displacement of these tendons over the Malleoli would be of frequent occurrence. These bands, the Superior and Inferior Peroneal Bands are thickenings of the fascia. The Superior Band runs from the outer side of the Malleolus to the lower part of the outer surface of the Os Calcis and has under it the tendon of the Long Peroneal and deep to this the tendon of the Short Peroneal Muscle.

The Inferior Peroneal Band, more distally situated, runs from the Tip of the Malleolus to the outer surface of the Os Calcis: a Septum separates these two muscles, of which the Short Peroneal lies anteriorly.

Both the Peroneal Tendons are enclosed in a common sheath while in the groove directly behind the External Malleolus, but above and below this point, the sheath is bifurcated: the upper bifurcation lies under cover of the Superior Peroneal Band and the lower bifurcation comes into relation with the posterior border of the Inferior Peroneal Band. The upper end of the sheath enclosing the Long Peroneal Muscle, extends $1\frac{3}{4}$ inches above the tip of the Malleolus; the sheath for the Short Peroneal to a less height. The lower end of the sheath of the Short Peroneal Muscle extends to CHOPART'S Joint but the sheath of the Long Peroneal passes beyond as far as the groove on the Cuboid Bone, here it receives a new sheath which comes almost into contact with the first sheath; a communication between them never occurs. Nevertheless, the intervening septum is so thin that it is easily perforated by pus.

By this route an Abscess of the sole of the foot may easily spread up into the leg. Again; the relation of the Peroneal Sheaths to CHOPART'S Joint allows, for example, tuberculosis of this joint to extend up the leg after perforating the tendon sheaths.

At the Ankle such easy means for extension are not found, although the Tendons are closely applied to the joint behind the External Malleolus. The reason of this is explained by the definite separation which the strong Calcaneo-Scaphoid Ligament secures.

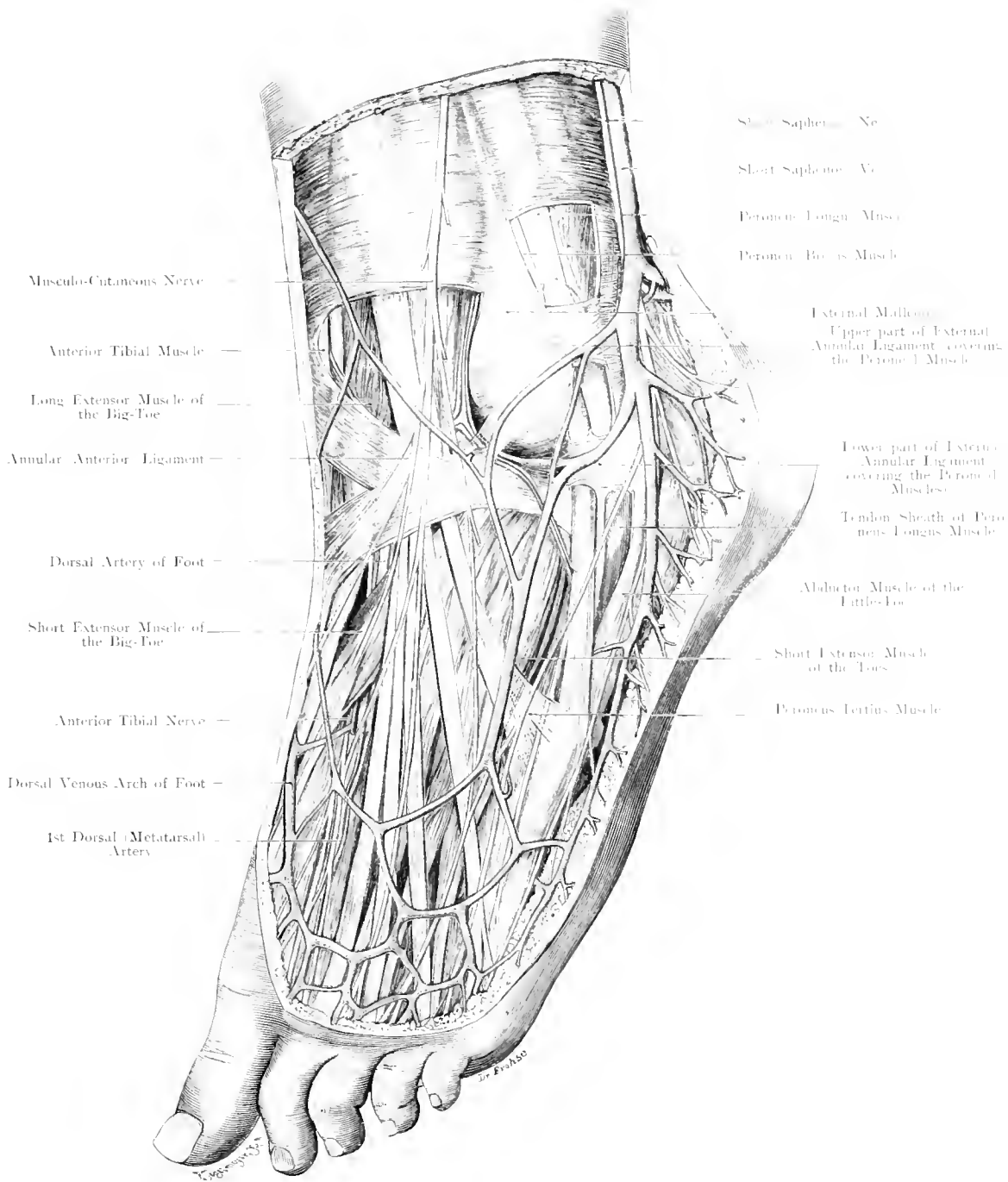


Fig. 194. Outer side of the (left) Foot.
Nat. Size.

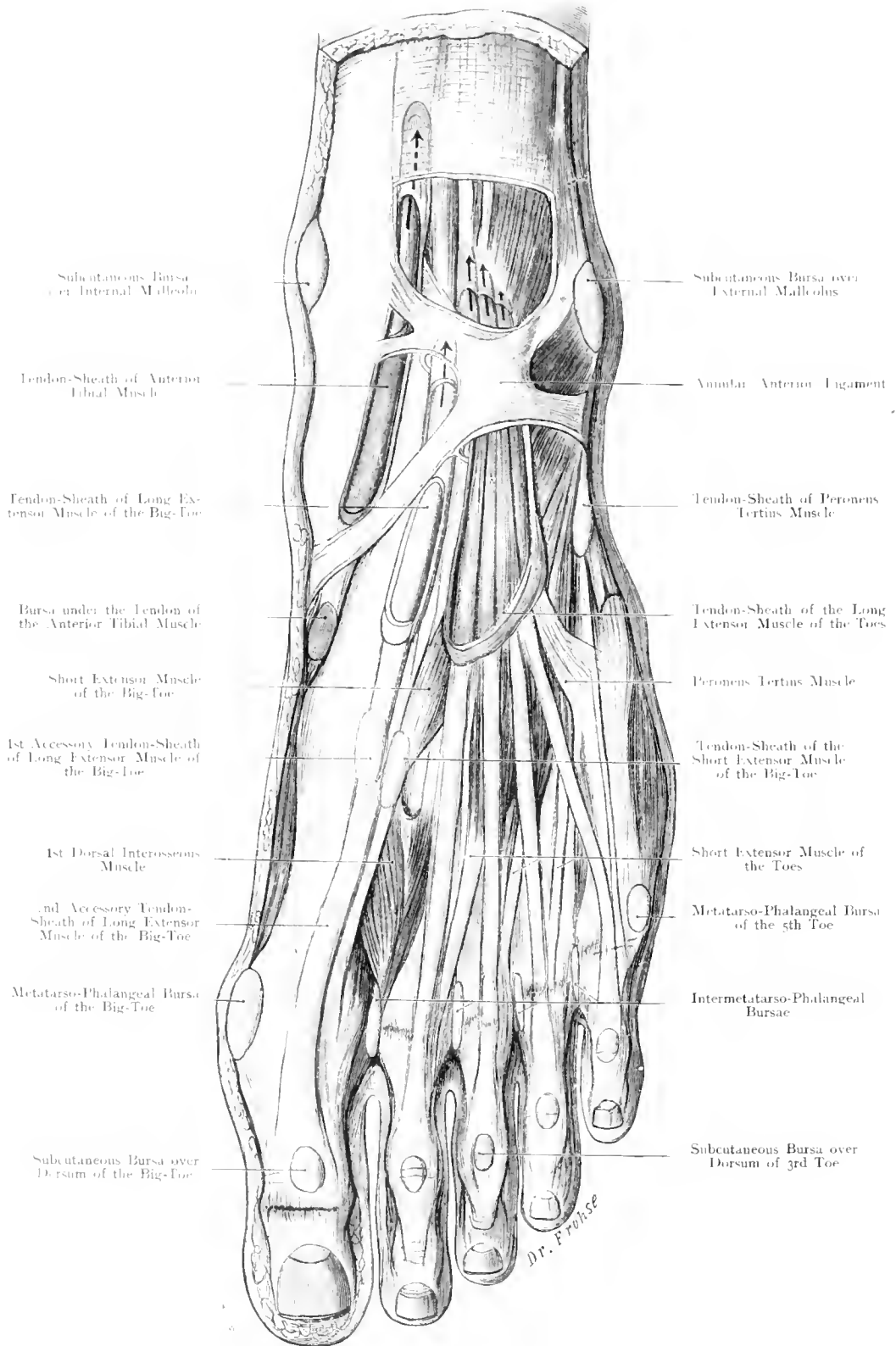


Fig. 195. Dorsum of (left) Foot shewing Muscles and Tendon-Sheaths.

1/2 Nat. Size.

Fig. 195. Dorsum of (Left) Foot with Muscles and Tendon-sheaths.

The Fascia of the Dorsum of the Foot has been removed except the Superior and Anterior Annular Ligaments. The Tendon-sheaths have been opened except the eul-de-sac at their extremities, the length of which is indicated by an arrow.

The Superior and Anterior Annular Ligaments keep the Extensor-Tendons in position during movements at the ankle; this arrangement is perfected by a separate compartment for each tendon with its own special sheath in order to avoid any friction.

The Sheath of the Anterior Tibial Muscle commences $2\frac{1}{2}$ inches above the Intermalleolar-Line (between the tips of the Malleoli) and ends usually at CHOPART'S Joint. The Sheath of the Long Extensor of the Big Toe begins $\frac{3}{4}$ inch above the Intermalleolar-Line and extends down to LISFRANC'S Joint. A second and even a third Synovial Sheath may be present (Fig. 195) in connection with this tendon.

The Long Extensor of the Toes and the Third Peroneal Muscle occupy a common sheath which commences lower down than the sheath of the Anterior Tibial and extends to the middle of the External Cuneiform Bone.

A sling-like ligament which arises in the Sinus Tarsi assists in keeping these tendons in place under the Annular Ligament. Sometimes an extensive Bursa is found between this Ligament and the Neck of the Astragalus.

Many other Synovial Sacs may be present: those between the heads of the Metatarsal Bones (Intermetatarso-phalangeal Bursa) are quite frequent. Whenever tendons pass over bony prominences, small synovial sacs are placed to act like cushions; even where the Lumbrical Muscle winds around the shaft of the first phalanx these are found. Again Subcutaneous Bursae occur whenever there is pressure of skin against bone especially under "Corns". The Bursae over the Malleoli are fairly constant as well as those on the lateral aspect of the Heads of the 1st and 5th Metatarsal Bones, and those over the Heads of the 1st Phalanges.

Fig. 196. Dorsum of (Left) Foot, with Tendon-sheaths. Arteries and Bones projected on to the Skin.

This is a reconstructed figure: The outlines are taken from a young individual; the bones are of a corresponding size; moreover in comparison with several other specimens the position of the Arteries and Tendon-sheaths have been relatively determined.

This figure (cf. Fig. 97) has been constructed to shew the relation of Arteries and Tendon-sheaths to Bones and Joints. In the Hand furrows and folds indicate the position of deeper structures, but in the Foot bony prominences are to be taken as the reliable points. Along the inner border, the Tubercle of the Scaphoid, on the outer side the Tuberosity of the 5th Metatarsal Bone are plainly evident. The Tarso-Metatarsal Articulation (LISFRANC'S Joint) is determined thus: Immediately proximal to the tuberosity of the 5th Metatarsal Bone is the one point, the other point lies $1\frac{1}{2}$ inches distal to the tubercle of the Scaphoid. A curved line joining these 2 points indicates the line of the joint. (Cf. Fig. 20.)

The Mid-Tarsal Joint is determined by connecting on the inner border a point $\frac{2}{3}$ rd inch proximal to the Tubercle of the Scaphoid, on the outer border $\frac{1}{5}$ inch proximal to the Tuberosity of the 5th Metatarsal. The figure shews the relations which the extremities of the Tendon-sheaths bear to these lines. The joint space can be made out directly in most cases by feeling at $\frac{2}{3}$ rds to $\frac{3}{5}$ th inch above the tip of the Inner Malleolus the Anterior Border of the Articular Surface of the Tibia where it is only covered by skin and tendons. (For certain Synovial Bursae see Fig. 197.)

Frequently a Bursa is placed between a tendon and its insertion into the bone where it acts as a cushion when pressed against the bone by the opposing muscles. Consider, from this point of view, the bursa over the Internal Cuneiform Bone, which lies under the Anterior Tibial Muscle close to its point of insertion into the Internal Cuneiform and the 1st Metatarsal Bones.

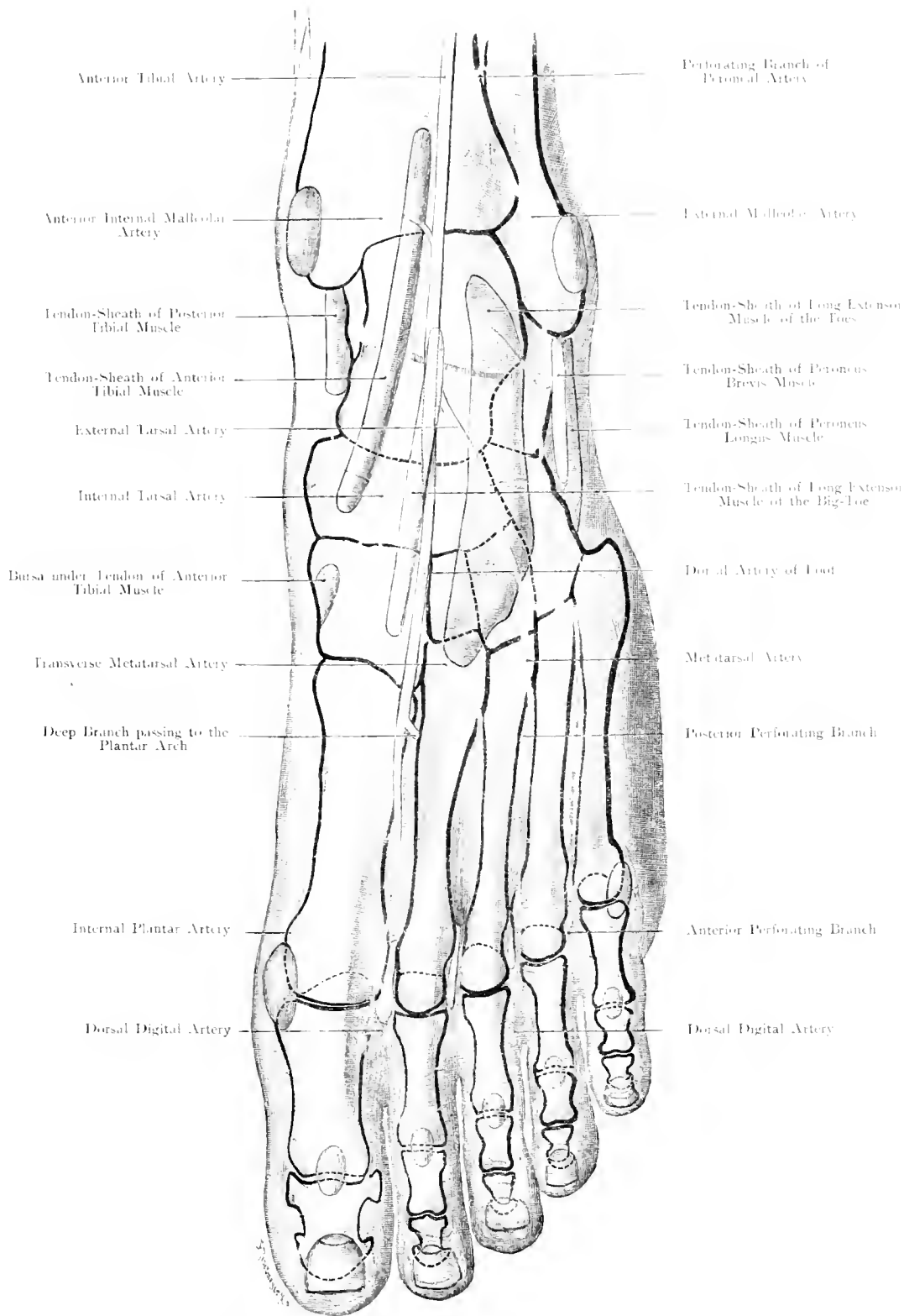


Fig. 196. Dorsum of Foot with Tendon-Sheaths, Arteries and Bones.
 (Projection on to the surface.) Left side.

1/2 Nat. Size.

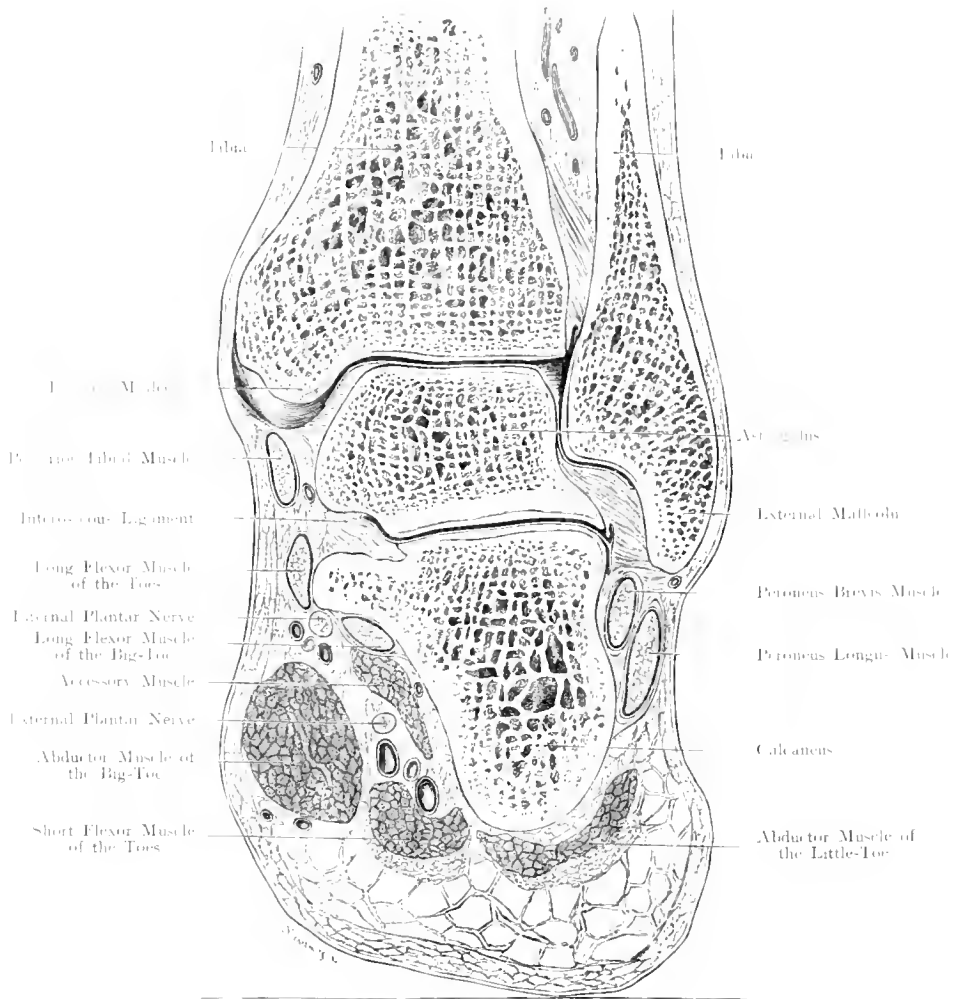


Fig. 197. Frontal Section through the (right) Ankle-Joint.

Seen from behind. — Nat. Size.

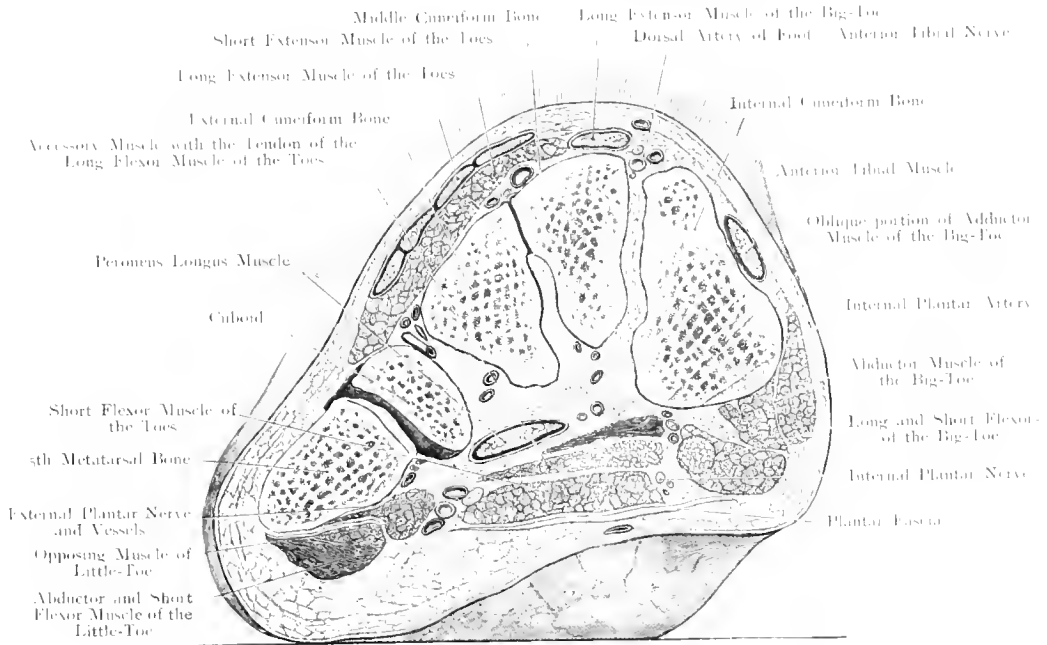


Fig. 198. Frontal Section through the Anterior Part of the Tarsus.
 Seen from in front. - - Nat. Size.

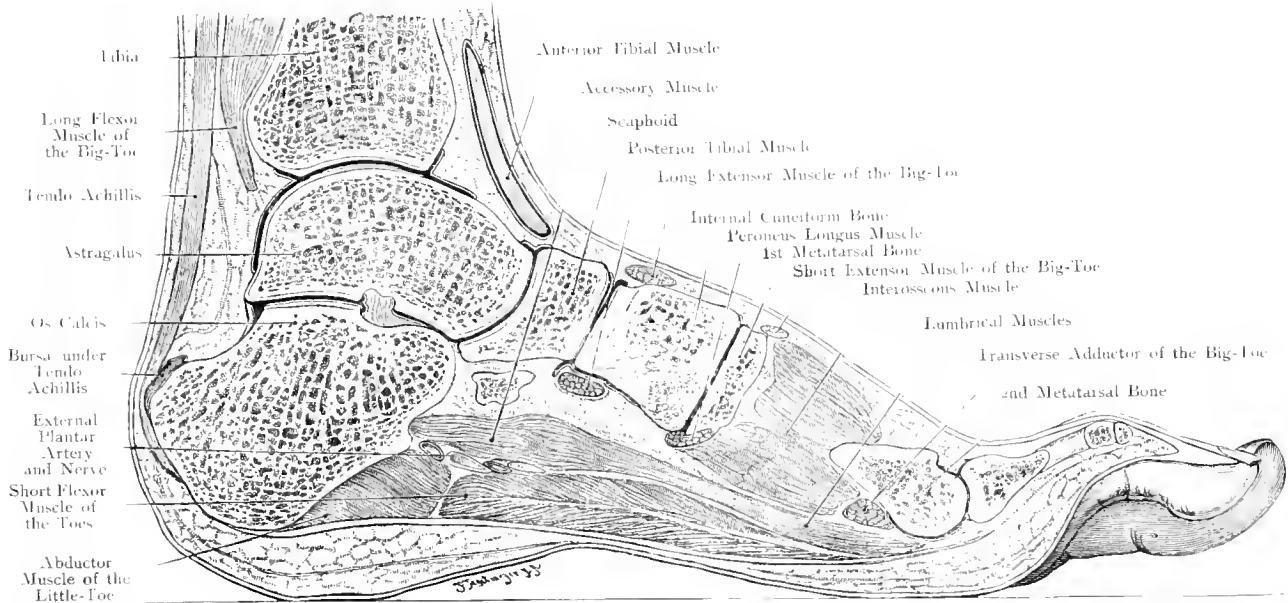


Fig. 199. Sagittal Section through the (right) Foot.
 Seen from the outer side. - $\frac{1}{2}$ Nat. Size.

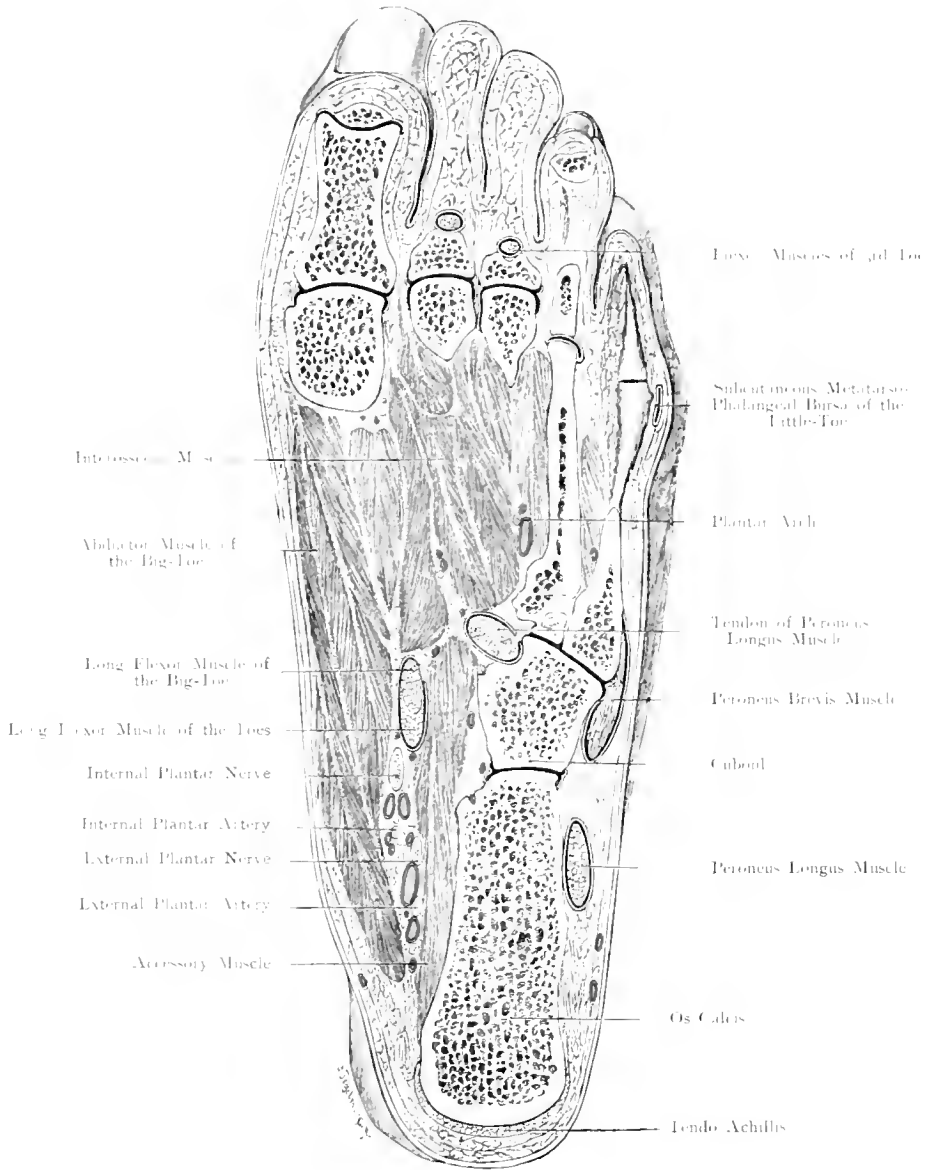


Fig. 200. Horizontal Section through the (right) Foot, near the sole.
 Nat. Size.

Fig. 200. Horizontal Section through the (Right) Foot near the Sole.

Frozen Section. The distal half of the 5th Metatarsal Bone has been freed by dissection.

The result of the arching of the foot is that the body-weight is received only by a few points of the skeleton of the foot, namely: behind; the Inner Tubercle of the Os Calcis; in front on the outer side; the Head, also the base of the 5th Metatarsal Bone; on the inner side; the Head of the 1st Metatarsal Bone though many consider that owing to the mobility of this bone the head of the 2nd Metatarsal Bone should be looked upon as the supporting point. According to H. VON MEYER the 3rd Metatarsal Bone should be viewed as the point of support as the other bones only serve for the purpose of preventing the foot from capsizing to either side. However this may be, foot-prints teach us that only the heel, outer margin of foot, balls of toes and toes themselves, touch the ground normally; when the inner margin meets the ground we have to deal with: Flat-Foot,

The section shews definitely the share taken by the different bones in this arrangement. The Metatarsal Bones lie at different levels; the heads of the inner three have been divided by the section which passes throughout the length of the 4th and only through the base of the 5th Metatarsal (of which its distal half has been freed by dissection).

In the figure is seen the Bursa on the outer aspect of the Little Toe opposite the Metatarso-phalangeal Articulation; this the most prominent point on the outer margin of the foot is frequently the seat of a corn produced by pressure from the boot.

Inflammation readily reaches this Bursa whence it spreads to the joint which is often in communication with the Bursa.

Fig. 201. Tarsal and Metatarsal Articulations. Right Side.

The preparation is of a frozen foot in extreme plantar flexion; the minimum of tissue necessary to thoroughly expose the joints has been removed with a chisel.

The Tarsal Bones articulate with each other, with the Bones of the Leg and with the Metatarsal Bones, forming as a rule 8 separate joint-cavities of which some are very simple (where only two articular surfaces take part in the joint), others are very complicated (where several joint-spaces combine to form one joint-cavity by communication). In the latter case, disease spreads rapidly from one articulation into the communicating joints whereas disease of a simple cavity may remain localized.

The separate joint-cavities are:

1. Ankle-joint, between the Astragalus, Tibia and Fibula with an upward recess between the Tibia and Fibula.

2. Posterior Calcaneo-Astragaloid Joint (Fig. 199).

3. Articulation between the Astragalus on the one hand with the Scaphoid and Os Calcis on the other hand (Fig. 199). The Head of the Astragalus lies in a socket formed by the Scaphoid, Calcaneo-Scaphoid Ligament and the Anterior Part of the Os Calcis.

4. Joint between Os Calcis and Cuboid; the inner extremity of this joint lies exactly opposite the outer end of the former (3) separated only by the Calcaneo-Cuboid Ligament. The foot can be easily disarticulated at this S-shaped articulation the Astragalus and Os Calcis being left behind. (Disarticulation after CHOPART.) It is to be noticed that this joint consists of 2 separate joint-cavities so that, in disease, one may be affected without the other.

5. Small Articulation between the Cuboid and External Cuneiform.

6. Very complex Joint-cavity between Scaphoid and the 3 Cuneiforms, between the contiguous Cuneiforms, between the Middle and External Cuneiforms and the bases of the 2nd and 3rd Metatarsals and between the bases of these Metatarsals.

7. Joint between 1st Metatarsal and the Internal Cuneiform.

8. Joint between the Cuboid and the 4th and 5th Metatarsals.

The joints between the 5 Metatarsals on the one hand and the 3 Cuneiforms and the Cuboid on the other form a curved line which is only interrupted by the proximal projection of the 2nd Metatarsal to the extent of $\frac{2}{5}$ th inch. Disarticulation of the Metatarsals after LISFRANC can be performed at this line.

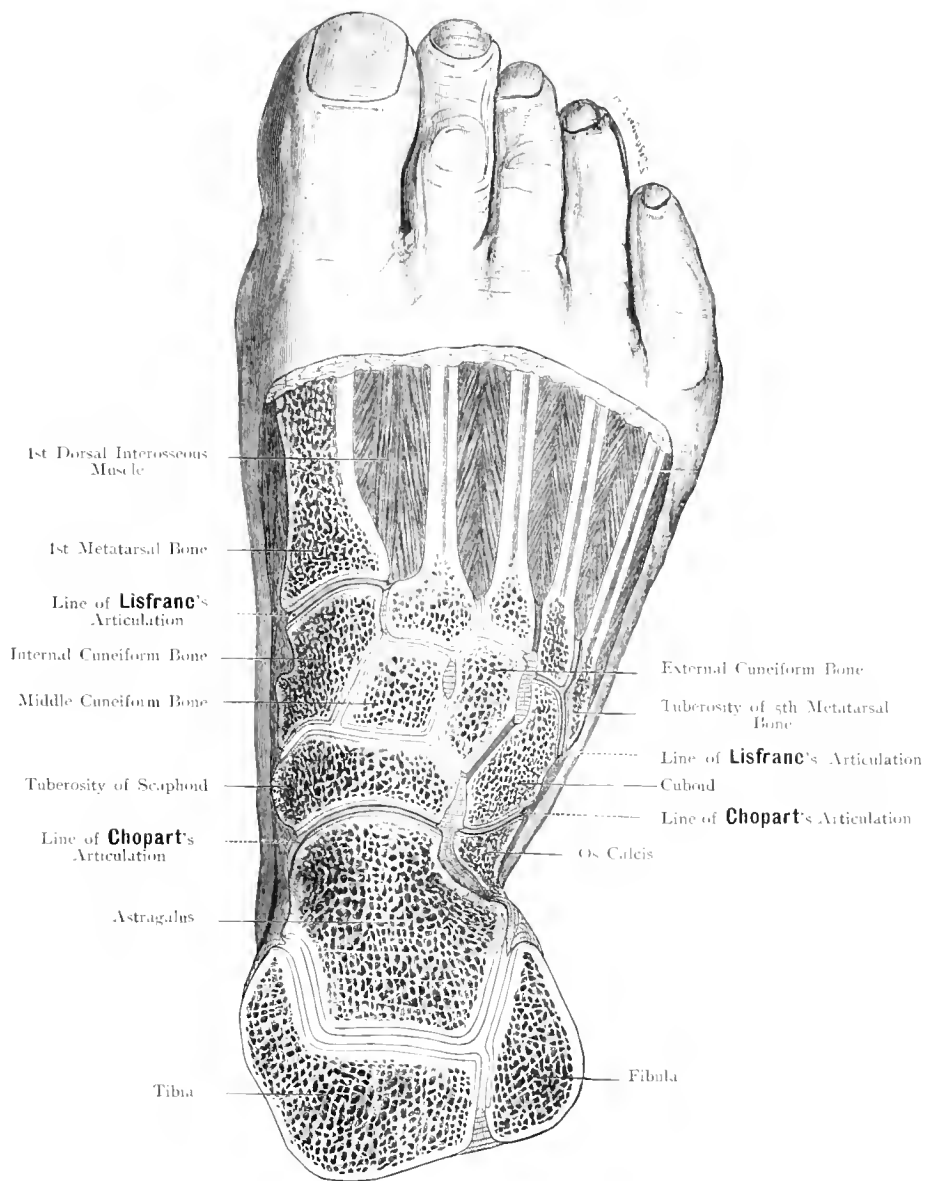


Fig. 201. Tarsal and Metatarsal Joints exposed from above on the right side.

$\frac{2}{3}$ Nat. Size.

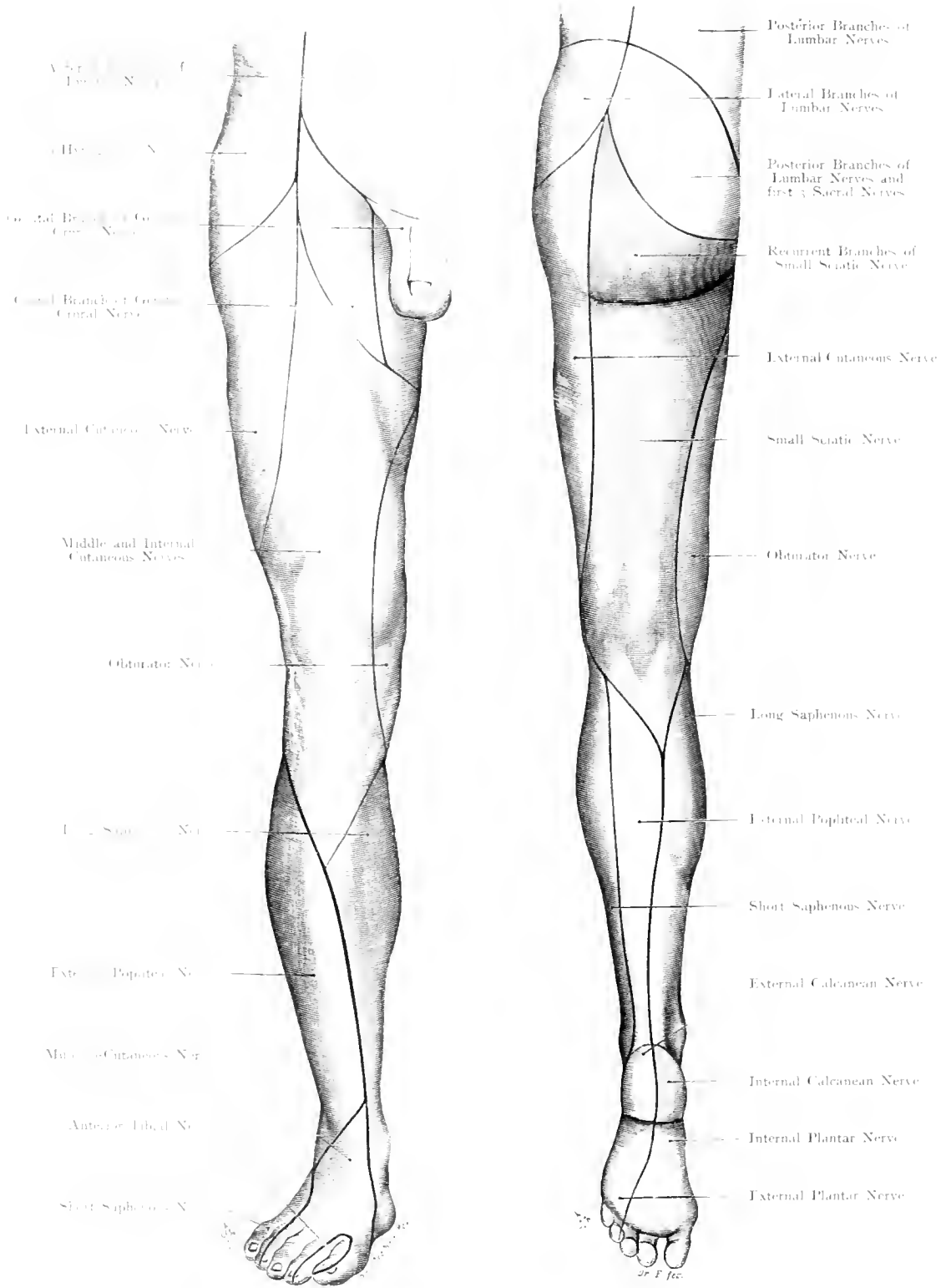


Fig. 202 and Fig. 203. Areas of Distribution of the Cutaneous Nerves of the lower Extremity. Right side.

$\frac{1}{2}$ Nat. Size.

Figs. 202 and 203. Areae of distribution of the Cutaneous Nerves of the Lower Extremity. Right Side.

Outlines partly after FAU's Atlas. Areae of Nerves are partly diagrammatic. Colours are chosen in the order of segmentation: those for the Lumbar Plexus are in accord with the colours used, in the two following figures, for the segments of the cord.

The Cutaneous Nerves of the Lower Extremity require thorough re-investigation, far more than those of the Upper Limb. The upper quarter of the thigh is supplied by the following Cutaneo-sensory Nerves:— Outer third, Ilio-hypogastric (red); Middle, Crural Branch of Genito-Crural; Inner third, Genital Branch of Genito-Crural. These 2 areae, supplied by the same nerve, are yellow; only a small area near the Scrotum (visible on separation of the thighs) is supplied by the Perineal Branch of the Small Sciatic. The remainder of the Anterior Surface is supplied in its outer third, by the External Cutaneous, internal to this, by the Middle and Internal Cutaneous; at its innermost part, by the Obturator Nerve.

The two Lateral Nerves extend on to the posterior aspect which is chiefly supplied by the Small Sciatic Nerve.

The Gracilis is not often perforated by the Cutaneous Branch of the Obturator; this Nerve usually winds round the border of the Adductor Longus Muscle and thus comes to the surface at the Anterior Border of the Gracilis. It nearly always anastomoses with the Internal Cutaneous Nerve and comes to lie near the Long Saphenous Nerve after piercing the fascia, so that this Nerve is composed of fibres from the Internal Cutaneous as well as from the Obturator Nerve.

The inner surface of the Leg is entirely supplied by the Terminal Sensory Branches of the Anterior Crural Nerve, namely, the Long Saphenous Nerve which reaches down as far as the inner border of the foot, and so becomes the longest nerve in the body. All other parts of the Foot and Leg are supplied by the Great Sciatic Nerve and its branches.

In the Leg, the Internal and External Popliteal Nerves apportion the skin between each other, the former taking the middle of the calf, the latter the outer side. In the Foot, the Dorsum belongs to the External Popliteal, the Sole to the Internal Popliteal.

At the Heel, the Internal and External Calcanean Branches should be mentioned. The area of the Internal Plantar corresponds to the distribution of the Median, that of the External Plantar to the Ulnar in the hand.

The supply of the Dorsum of the Foot exhibits no similarity to that of the Hand. Besides the Superficial Nerves a Deep Branch from the Anterior Tibial Nerve has to be considered in its supply to the contiguous margins of the Big and 2nd Toes.

Fig. 204. Innervation of the Skin and Muscles of the Lower Limb according to their Segmental Origin from the Cord: Anterior Aspect.

Outlines modified after FAU's Atlas; Nerve-supply after WICHMANN with modifications suggested by ZIEHEN. In the text Arabic figures indicate the Lumbar, Roman the Sacral Segments. As each plexus has only 5 segments the fundamental colours of the Spectrum Red, Orange, Yellow, Blue and Green are employed. Black lines represent the boundary between trunk and limb and the so-called Axial Line which, invisible in the thigh, appears at the outer side of the leg running obliquely downwards to the Internal Malleolus and encircling the latter.

The Segmental Distribution of the Nerves in the Lower Extremity is more complicated than in the Upper Limb. In man the distribution of both Motor and Sensory Nerves has not been properly determined. This figure is intended to contrast the Cutaneous Supply with the Muscular.

Naturally the Nerves are to be divided into Dorsal or Extensor Nerves, and Ventral or Flexor Nerves, the former being the Anterior Crural and External Popliteal, the latter the Obturator and Internal Popliteal. Apart from these, special branches for the Muscles of the Pelvic Girdle will (as well as the Flexor Nerves) be considered in the next figure. In this figure only the Extensor Nerves will be described.

The Anterior Crural Nerve corresponds more to the Musculo-Cutaneous than to the Radial; this divides into a branch to the Iliacus (cf. Fig. 105), the Anterior Division (mixed) which supplies the Sartorius and Pectineus, and the Posterior Division (also mixed) which supplies the Quadriceps Extensor Group of Muscles.

These muscles correspond to the following spinal segments, Pectineus 2 and 3; Sartorius 2 and 3; Rectus Femoris 2, 3 and 4; Vastus Internus 2 and 3 (and 4), Crureus (2) 3 and 4; Subcrureus 3 and 4; Vastus Externus 3 and 4.

The Sensory Portion of the Nerve is formed by the Middle and Internal Cutaneous (Anterior Divisions) and its communication to the Obturator Nerve, by the Long Saphenous Nerve (Posterior Division). Of these, the former supply the thigh chiefly from 2 and 3, the latter supplies the Leg and is formed from 3 and particularly 4.

The External Cutaneous Nerve (a modified lateral branch of the Lumbar Nerves) contains 1, 2 and 3; its Posterior Branch may be a trochanteric branch; occasionally its Anterior Branch contains the Crural Branch of the Genito-Crural (the internal twigs of which also contain ventral elements). This nerve is not constant, neither is there any constant relation between the fibres which it receives from 2, 3 and 4.

The following remarks are made in connection with the incompletely studied External Popliteal Nerve: — Motor part: Short Head of Biceps 5. I. (II). Long Peroneal Muscle (4) 5. I. Short Peroneal Muscle 5. I. Long Extensor of the Toes 4. 5. I. Long Extensor of the Big Toe (4) 5. I. Anterior Tibial 4. 5. (I) Short Extensor of the Toes 4. 5. I; The slip from the muscle to the Big Toe 4. 5. I.

Sensory part: On the outer side of the leg from above and in front, downwards and backward, 5. I and II.

At the foot (Musculo-Cutaneous and Anterior Tibial Nerve) 5. I and II. The whole of the Dorsum of the Foot contains: on the inner side, according to PATERSON, 3 and 4; on the Dorsum proper 4. 5. I; on the outer side, I and II.

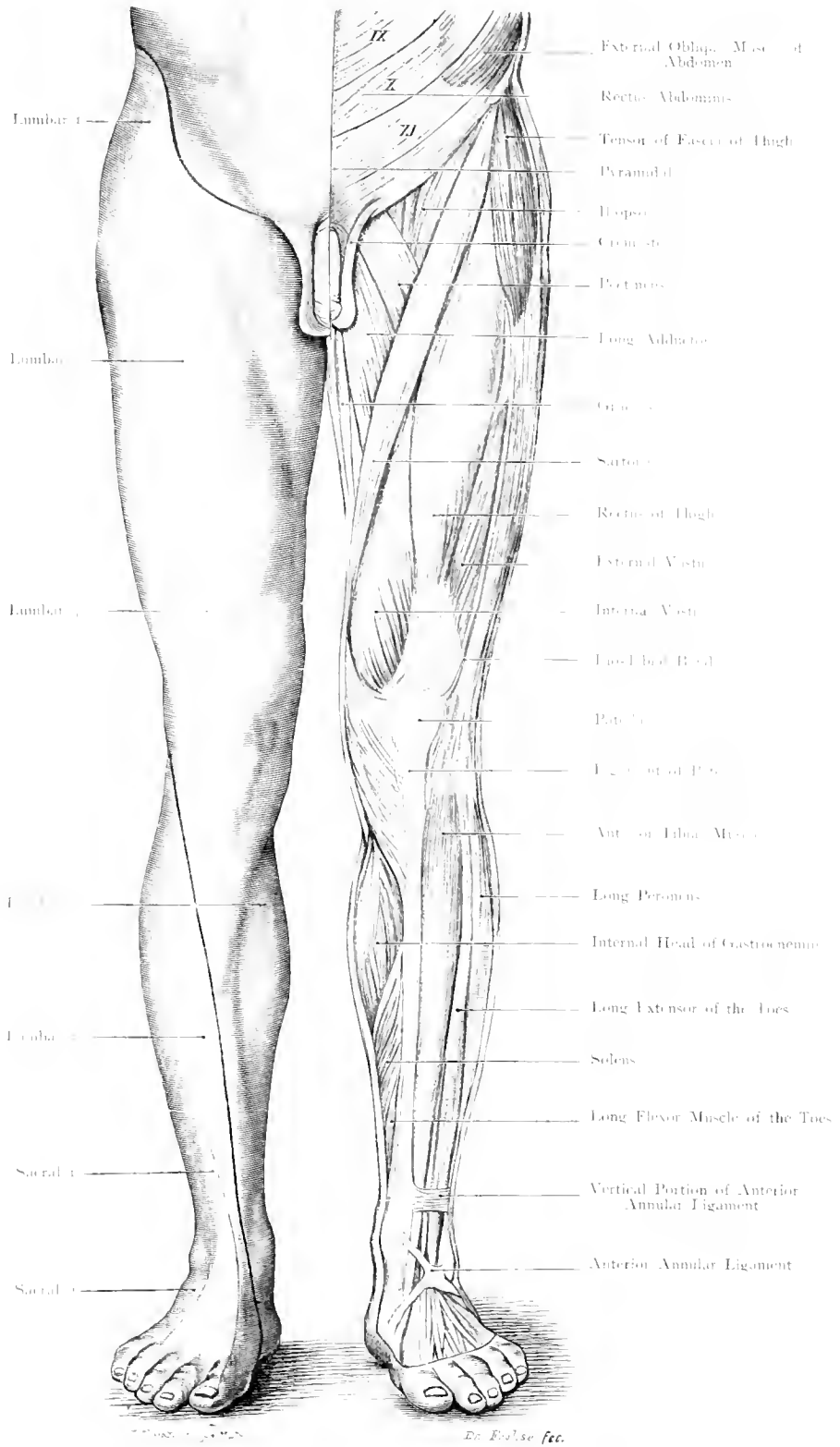


Fig. 204. Nerve-Supply of the Skin and Muscles of the Lower Limb according to their Segmental (Spinal) Origin. Anterior Aspect.

$\frac{1}{6}$ Nat. Size

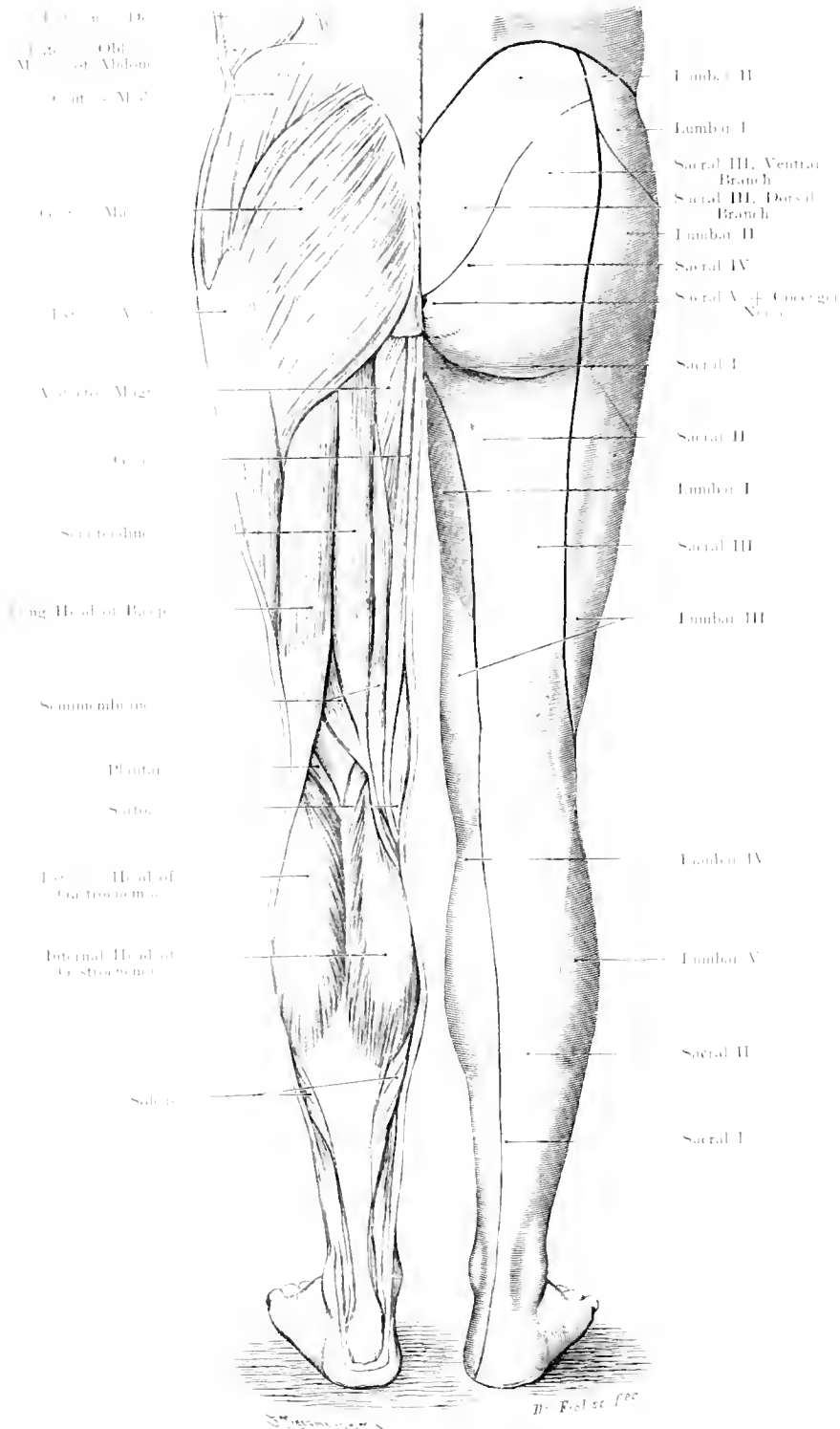


Fig. 205. Nerve-Supply of the Skin and Muscles of the Lower Limb according to their Segmental (Spinal) Origin. Posterior Aspect.

1/3 Nat. Size.

Fig. 205. Innervation of the Skin and Muscles of the Lower Limb according to their Segmental Origin from the Cord: Posterior Aspect.

The preliminary remarks made in connection with Fig. 204 apply to this figure. The boundary line (difficult to define) between the Trunk and the Limb has not been especially indicated but the continuation of the Axial Line is shown in this figure. This line runs upwards on the back of the thigh to the Crest of the Ilium and below, after encircling the Inner Malleolus, it runs on the posterior aspect of the leg to reach the inner side of the thigh. On the back of the limb the distribution is still more complicated than on the anterior aspect, because the dorsal nerves of the Plexus enter in, and the nerves of the muscles of the Gluteal Region have to be divided into a Dorsal and a Ventral Group.

Obturator Internus Muscle, Gemelli and Quadratus Femoris Muscles belong to the Flexor Group; to the Extensor Group belong, in front the Psoas Group, behind the Gluteal Muscles, Tensor of the Fascia of the Thigh and the Piriformis.

The following is the segmental relation:

Obturator Internus 5. I. II. (III), Gemellus Superior 5. I. II. (III), Quadratus 4. 5. I. Gemellus Inferior 4. 5. I. (so that the first two and the last two go together).

Psoas and Psoas Minor 1. 2. 3. (4), Iliacus 2. 3. 4. belong to the Extensor Group.

Gluteus Maximus is supplied by 4. 5. I. II. Medius and Minimus by 4. 5. I. Tensor of the Fascia of the Thigh 4. 5. I. Iliac Portion of the Quadratus Lumborum 1. 2. 3. (4).

The Motor part of the Internal Popliteal supplies the Muscles of the Thigh, Leg and Foot: Long Head of Biceps 4. 5. I (or according to BÖLK I and II); Semitendinosus and Semimembranosus 4. 5. I; Adductor Magnus (hamstring portion) (3) 4. (and 5). To the Superficial Muscles of the Calf and the Popliteus 4. 5. I (II) are generally accepted: for the deep Flexors 5. I. (II). The terminal branches contain 5. I. II, the Internal Plantar chiefly 5. I, the External mostly I and II.

The motor fibres of the Obturator Nerve (2. 3. 4.) are divided as follows:— Obturator Externus 3 and 4. Adductor Magnus (2) 3 and 4. Adductor Brevis 2. 3. 4. Adductor Longus 2 and 3. Pectineus (exceptionally) 2. 3. Gracilis 2. 3. (and 4).

Sensory part:— the Small Sciatic Nerve is composed of I. II and III; Internal Popliteal Nerve I and II and its continuation also I and II, on the sole of the foot the Internal Plantar 5 and I, the External I and II. The Cutaneous Fibres of the Obturator Nerve are like the motor fibres derived from 2. 3 and 4.

Over the Sacrum the Dorsal Branches of the Sacral Nerves and the Coccygeal Nerve must be mentioned. They are chiefly derived from II and III (yellow). As other nerves take part in the supply of this area, the other colours Green, Blue and Red for the Coccygeal Nerve should have been put in.

The red colour (indicative of the 1st segment of a new plexus) has been omitted to avoid complexity in the figure.

On the outer side of the Hip it is necessary to remember the Ilio-hypogastric superficial to the Fascia covering the Gluteus Medius Muscle (SCHWALBE).

Printed by Hermann Pohle, Jena, Germany. — 233.

2

UNIVERSITY OF CALIFORNIA LIBRARY
Los Angeles

This book is DUE on the last date stamped below.

JUN 1 1981	
JUN 1 1981	
BIO MED JUN 2 1981	



3 1158 00822 3306

1977-1978