CONTRIBUTIONS TO EMBRYOLOGY

Volume XIV, Nos. 65-71.

Published by the Carnegie Institution of Washington
Washington, 1922

CARNEGIE INSTITUTION OF WASHINGTON
Publication No. 277

TECHNICAL PRESS
WASHINGTON

CONTENTS.

CONTRIBUTIONS TO EMBRYOLOGY, No. 65.

DIRECT GROWTH OF VEINS BY SPROUTING.

By Florence R. Sabin,

Anatomical Laboratory, Johns Hopkins Medical School.

With one plate.

DIRECT GROWTH OF VEINS BY SPROUTING.

In the chapter on the development of the vascular system in Keibel and Mall's Manual of Human Embryology, published in 1911 and 1912, Evans gave an analysis of the progress of embryology in connection with this system up to that time. By his own work he then demonstrated in a series of beautiful studies that the method of injection, as applied to the embryo, had made possible a great advance in the phase of the subject concerned with the spread of vessels over the body. In the introduction he said:

> "The two fundamental questions involved in the development of the vascular system are—(1) What is the origin of the blood-vessels in the body of the embryo? (2) What is the primitive form of the vessels in any area, and the manner of change from this to that of the adult? These two aspects of the subject thus concern themselves with the problem of the cellular antecedents of the endothelium, on the one hand, and with the principles governing the architecture of the vascular system, on the other. To the former problem it is still impossible to give any decisive answer, but to the latter I trust the reader will see that a flood of new light has come."

It is now possible, I think, to give a definite answer to the first question; we know just how blood-vessels begin, and it is therefore possible to show that this knowledge of the fundamental genesis of the vascular system calls for certain extensions and modifications of the prevailing views on the second question.

A more careful examination of the old problem of angiogenesis, opened up by the early embryologists, Wolff, Pander, von Baer, and others, in their studies on blood-islands, has shown that blood-vessels begin by the differentiation of a new type of cell, the angioblast of His or vasoformative cell of Ranvier. The final proof that vessels are formed intracellularly was not obtained until the methods of tissue-culture permitted the process to be actually watched in a living specimen. The angioblast has certain characteristics. When it divides it forms syncytial masses, which have two essential properties: (1) the power of liquefying in the center, with the formation of plasma and vesicles; (2) the power of sprouting, by which these groups of cells join similar groups, forming vessels or plexuses. Both of these processes are necessary for the formation of the vascular system. It has thus become clear that the most fundamental concept, in connection with the vascular system, is that its essential tissue, endothelium, differentiates from mesenchyme. This means that the processes by which vessels form are essentially different from the processes by which the great tissue spaces (such as the arachnoidal spaces and periotic spaces) form. Weed (1917) has followed the development of the spaces of the arachnoid, Streeter (1917) the periotic spaces, and Shields, in a paper now in preparation, the tendon-sheaths; in all of these structures the formation or differentiation of a mesothelial lining is the last stage in the process, while in the formation of the blood-vessels the differentiation of the lining-cell, endothelium, is the first stage in the process.

Having determined that the primary point about the vascular system is that it starts by the differentiation of a new cell, which increases by division and by sprouting, it is of first importance to determine whether the differentiation of new angioblasts is limited in time or whether it continues throughout life, either generally or in certain specific places. This question was tested by restudying the regeneration of blood-vessels, after intestinal anastomoses made in adult dogs, in conjunction with Dr. Halsted and Dr. Holman (1920), who performed the operations. No evidence could be found of a differentiation of new angioblasts; rather, the vascular system was restored by an active division of preexisting endothelium of small arteries, veins, and capillaries, involving a return of this endothelium to its embryonic angioblastic condition. Thus in these studies the new vessels, when first formed, were connected with the old, but showed a lumen as irregular as the lumen of embryonic vessels during their transformation from solid angioblastic masses. It thus seems likely that we must look for a phase in embryonic or fetal development when the differentiation of new angioblasts ceases, all subsequent new growth of vessels being accounted for by the division of preexisting endothelium. Thus the complete story of the development of the vascular system must take into consideration how far each vessel arises by the differentiation of angioblasts and how far by division and sprouting, and when, for each organ or area of the body, the differentiation of new vasoformative cells ceases.

As far as we have gone in this study, it has been found that throughout the first 7 days of incubation in the chick there is a differentiation of new angioblasts to be made out in the area pellucida. This differentiation of new angioblasts is extremely extensive during the whole of the second day; from the third day on it becomes relatively greatly diminished; but almost any blastoderm up to the seventh day of incubation, which is as far as the process has yet been followed, will show one or two small vesicles unconnected with the main plexus. It is an interesting point that the solid masses of angioblasts are much rarer than the vesicles, only one or two masses of angioblasts having been found in about 80 specimens, while most of the specimens show one or two vesicles. The reason for this is that the liquefaction takes place in a short time, only one or two hours being required to transform a solid mass into a hollow vesicle, while it takes a long time for the vesicles to join the main plexus. One only rarely sees the process during the time of observation of a single specimen, representing on an average 5 hours. This difference in duration in the two processes explains why the isolated vesicles are so much more common in sections than the solid masses of angioblasts.

Concerning the primary vessels of the embryo, it was first noted that a large part of the dorsal aorta of the chick could be seen in the living blastoderm to differentiate *in situ* from angioblasts. In this volume is a study of the origin of the pulmonary vessels in the chick, by Buell. He has demonstrated that the period in which the vessels begin, *i. e.*, on the second day of incubation, is a stage in which the vessels are represented by a mass of solid angioblasts. These angioblasts first appear as a solid mass of cells connected with the wall of the sinus venosus and are readily distinguishable by their structure from undifferentiated mesenchyme. Buell was unable to find any clumps of angioblasts unconnected with the main mass, so he had no evidence of a direct differentiation of these cells from mesenchyme; rather, they seem to come directly from the wall of the sinus venosus; but he had abundant evidence that the period of origin of the pulmonary vessels falls well within the angioblastic stage of the vascular system. This mass of angioblasts forms at a stage when the lung-bud lies directly dorsal to the sinus venosus. The cells spread over the surface of the gut, making a plexus which connects with the dorsal aorta, the ventral aorta, and both cardinal veins. By the liquefaction of their cytoplasm the plexus of angioblasts becomes a plexus of vessels. The pulmonary veins form in the angioblasts that are directly connected with the sinus venosus, while the arteries form in the more dorsal loops of the post-branchial plexus, the formation of the pulmonary artery slightly preceding the completion of the pulmonary arch. Thus the fundamental morphology of the vascular system of the lung in the chick is established.

This volume also contains a study by Miss Finley of another phase of this problem. She has studied the invasion of the subcutaneous tissue of the head of the human embryo by the vascular system. In the head there are two primary vascular plexuses: One in the meninges, the forerunner of the vessels of the central nervous system, the meninges and the skull, which begins very early; the other the subcutaneous plexus, which develops late. Its late appearance makes this subcutaneous plexus a favorable place to study the problem of the differentiation of angioblasts in a late embryonic or early fetal stage. Miss Finley has found evidence of a progressive differentiation of angioblasts in front of an invading zone of vessels. There are four zones, beginning at the periphery: (1) An avascular area, with undifferentiated mesenchyme. (2) A zone in which the vascular system consists of a massive plexus of cells. This vascular plexus, interestingly enough, consists very largely of masses of red cells, with a somewhat incomplete endothelial border, so that the observations have a very important bearing on the method of origin of the red blood-cells in the mammal. The process is clearly an intermediate one between the condition found in the chick, where the red cells arise within vessels, and a process of a diffuse origin of red cells which would subsequently have to migrate into vessels. These observations will be of especial value in the restudy of mammalian bone-marrow, where the question of the relation of the origin of red cells to endothelium has not been satisfactorily cleared up. Along the edge of this angioblastic zone are a very few isolated masses or chains of angioblasts. Miss Finley has studied the tissue, first in place and then in total preparations, stripped from the head of the embryo, so that she is sure of the very small number of such isolated clumps. (3) The third zone, which is formed from the second, consists of capillaries, some of which are empty, while some contain red cells. This zone probably does not have any circulation. (4) The fourth zone, leading to the neck, has definite vessels in which one can make out a pattern that may persist. Thus she has demonstrated an advancing zone in the angioblastic phase, definitely related to the formation of red cells, in human embryos about 30 mm. long, corresponding to the end of the second month of pregnancy.

It thus becomes clear that in the study of the development of the vascular system as a whole there are three great stages: First, a primary stage before the circulation begins, when there is a differentiation of angioblasts and the formation of a very primitive vascular system, including the heart, aorta, and primary veins; second, a long stage of invasion of the entire body by the vascular system, a process accomplished by both a progressive differentiation of new vessels and the continued division and growth of the vessels already formed; and third, the final stage, in which new growth or repair of the system is from preexisting endothelium.

An exceedingly valuable analysis of these recent modifications on the subject of the development of the vascular system was given by Streeter in 1918, in a study on the developmental alterations in the vascular system of the brain of the human embryo. He divided the development of the vessels of the brain into five successive periods: First, a stage of differentiation of primordial endothelial blood-containing channels, in which there are neither arteries nor veins and in which it is practically impossible to make out a vascular pattern that is even a forerunner of the pattern of the adult. This is the more strictly angioblastic phase. Second, a stage characterized by the formation of certain primitive arteries and veins and a capillary bed, through which blood circulates; the pattern is related to the existing functional needs of the tissues and yet is not to be interpreted too closely with reference to the adult pattern. Third and fourth, stages involved in the adaptation of the vascular pattern to changes in the general region, and later to changes in the specific developing organ, the vessels always conforming to alterations in structure and to the immediate functional requirements of the organ. Fifth, a period of the final histological differentiation of the ultimate, permanent arteries and veins. It is clear that the entire vascular system must be restudied with some such outline.

These new concepts, in connection with the blood-vascular system as a whole, apply with equal force to the subject of the lymphatic system. It has, I think, become clear that the fundamental concept that the lymphatic system is a part of the blood-vascular system, subject to the same laws of development, has been strengthened rather than weakened by these new studies; that is to say, all the observations that have gradually accumulated in connection with the development of the lymphatic system fall into line with the idea that the lymphatics also differentiate from angioblasts and develop as do the veins. In 1911 Huntington discussed the development of the lymphatic system from the standpoint of the two processes of differentiation and growth and has throughout believed that the Meyer-Lewis primordia—that is, the isolated vesicles shown by Lewis (1906) to characterize the pathway of developing lymphatic vessels—arise locally. That these isolated vesicles of Lewis do arise locally in the origin of the main lymphatic trunks is undoubtedly true, since the time of their development corresponds with periods during which blood-vessels themselves have been proved to be increasing by a differentiation of angioblasts *in loco*. Their method of origin, however, has proved to be the most important point. In connection with the origin of blood-vessels it has been proved that these isolated vesicles of Lewis arise by a liquefaction of the center of a solid mass of cells, so that they form, not secondary to a collection of fluid in mesenchymal spaces, but by a transformation of mesenchyme cells into angioblasts which then produce both the fluid and the endothelial boundary.

It is interesting to note that all of the facts brought forward by Kampmeier (1922), in his recent restudy of the origin of the lymphatic system in amphibia, are virtually an account of the origin of the lymphatic system by the differentiation of angioblasts, their transformation into vessels, and their uniting to make lymphatic plexuses. When the subject is restudied, it will be found, I am sure, that the same sequence of events can be demonstrated in any of the zones in which lymphatics are differentiating; that is to say, the fundamental principles of the origin of the entire vascular system, including lymphatics, are known. It is, of course, clear that we are as far as ever from analyzing the cause of this differentiation and are stating merely a sequence of events, that the cell precedes the formation of the fluid of the blood or of the lymph rather than that fluid collects and causes a flattening out of cells to line a space. If the third hypothesis of Thoma, namely, that in the spread of vessels into organs it is, in the last analysis, the organs themselves that determine vessels, proves to be the most fundamental law in connection with the growth of the vascular system, certain factors in the environment of developing vessels are not beyond the range of experimentation. Indeed, such studies have already been started by Stockard (1915) and, if carried farther, might throw great light on the extent to which the vascular system is determined by its environment.

In the early studies of the spread of vessels over the embryo, as developed by the method of injection, there grew up the theory that the growth of vessels is wholly within the capillary bed. This was a natural deduction from the fact that during the stages in which vessels are spreading over the embryo the wall of the vessel is almost everywhere limited to a lining of endothelium, so that the idea was correlated with the fact that the entire vascular system started on the basis of the structure of the capillary. In fact, the aorta begins as a vessel with a lining of endothelium only and remains without either muscle or adventitia for a long time after the circulation has begun. Indeed, the heart is the only part of the vascular system in which the musculature begins to differentiate at the same time the endothelial lining is itself forming from angioblasts. It appears, then, that in the spreading of the vascular system the capillary plexus precedes the artery and vein. There are, however, exceptions to the general rule that each vessel comes from a preliminary plexus, since the aorta itself, certainly in a part of its course, forms from chains of angioblasts rather than from any very complicated plexus.

In the present paper are presented certain observations concerning the growth of veins, which have a bearing on these fundamental relations. In the study of the vessels in the area vasculosa of the living chick it has been found possible to make preparations of the area pellucida throughout the period of incubation. The embryo itself can be kept attached only through the early part of the fourth day, because it then becomes too heavy to remain against the cover-slip in the reversed position of the hanging drop preparation, and as it sags away from the cover-slip it drags the membranes with it. The area pellucida, however, with a rim of the opaca, can be mounted; and although the circulation stops when the embryo is cut away, the cells continue to divide for a short period, so that certain processes can be watched. In such a preparation it was first noted that the granulocytes which develop outside the vessels could wander into the veins, even after a considerable thickness of the adventitia had developed, with just as great ease as they enter the capillaries; that is to say, the adventitia is no barrier whatever to the wandering of the leucocytes. It was then found that the same was true with regard to sprouting. Sprouts put out from the walls of a vein could push their way between the adventitial cells as easily as through the looser tissue that surrounds a capillary.

Plate 1 shows examples of such sprouting from veins of the area pellucida in a chick of the fourth day of incubation which was grown for two hours on a cover-slip. In figure A is a long sprout consisting of endothelial cells, for the most part solid, which were growing out from the side of a large vein. It is clear that at the base of the sprout the adventitia is represented by two cells, one on each side, that are growing out with the endothelium; that is to say, the vessel is growing as a vein, not as a capillary that is to be transformed later into a vein. Toward the end of the outer endothelial cell is a tiny vesicle, which I think is the beginning of the lumen-forming process. It seems difficult to accept the idea that the lumen of a vessel may develop within the cytoplasm of a single cell, but the process has now been so frequently observed that there is no escape from the fact.

In figure B is another long sprout from a smaller vein, which shows even more clearly that sprouts grow as veins, for the adventitial cells have wandered even farther along the growing sprout. In this case the lumen of the vein has opened widely into the base of the sprout. On the margin of the main vein there is a considerable heaping up of adventitial cells and several are also seen along the new sprout. The last adventitial nucleus is on the upper side and is the third nucleus from the tip. The branch of the sprout which passes upward has already joined another vein not shown in the drawing. In the new growth of veins one often finds rather large blunt swellings on the side of vessels, like the zone at the base of the sprout in this figure. Such a swelling represents a proliferation of endothelium from which a sprout will eventually form a connection with a neighboring vessel. The beginning of this process is shown in figure C, where a group of three endothelial nuclei is to be seen at the base of a short endothelial sprout. This is also a vein, as can be seen from the adventitial nucleus at the right of the base of the sprout.

Thus from the living specimens is established the fact that not only do the preliminary angioblasts make plexuses by the process of sprouting, but that the resulting capillaries and the veins likewise have this property. The importance of the point concerns (1) the story of how the vessels of each organ develop originally and (2) how to visualize the processes of repair of vessels after injury. If veins can regenerate as veins, it means that we have a much more rational accounting for the rapidity with which vessels are repaired in wound-healing. In the case of the healing of the vessels in intestinal anastomosis, we know that vessels from one of the apposed surfaces of the intestine can be injected from the other surface on the fourth day after the operation. If veins can grow as veins, the reestablishment of the circulation can doubtless be more rapid than by a process of the preliminary development of a capillary bed out of which the larger vessels must subsequently form.

Along with the processes of growth in these living specimens, it is possible also to follow the important subject of the destruction of vessels. In the area vasculosa there are regions in which one finds an extensive plexus of capillaries followed a short time later by a stage in which the same area has only one or two large vessels. A most interesting place to follow such a change is in the origin of the main vein, which develops to accompany the primary stem of the omphalo-mesenteric artery. Such a transition must involve a destruction of vessels and one should be able to follow this process in a living specimen. Figure D is taken from the same blastoderm as the other figures, but shows veins which were disappearing rather than growing at the time the specimen was fixed. All of the other figures were near together in a growing zone, while this figure is taken farther along the course of the same veins, where branches were degenerating. The main large vein at the right of the figure is normal. From this vein are two branches in which both the endothelial and the adventitial cells are to be seen in a stage of advanced degeneration. The cells are full of vacuoles and granular detritus and lead over to another smaller vein on the left side. The specimen shows clearly that the first stage in the degeneration of a vessel is a preliminary collapse of the endothelium which obliterates the lumen of the vessel. The evidence for this is a solid core of endothelium in a structure that was a vein. This is probably an important step in preventing hemorrhage during the degeneration of vessels. In this specimen the next stage is the death of the cells, both endothelial and adventitial. It seems to me possible that in some cases there may be a retraction of the endothelial sprouts, after the collapsing of the lumen, instead of actual death of the cells, making the process the reverse of the sprouting which characterises the growth of vessels. If this takes place, it should be possible to find it in a living blastoderm, but so far it has not been observed. As a matter of fact, the methods of destruction of vessels in a growing zone are second in interest only to the methods of spreading of vessels, so often are the vessels formed and re-formed before the final pattern is reached.

It seems to me clear that the work of the past twenty years on the development of the vascular system has established its fundamental genesis and has given us the broad outlines on which the story of the spread of the vascular system over the body has become a feasible problem. Instead of lessening the interest in the problem, as one for which we can now see a conclusion, the whole subject has rather been opened up to a new experimental attack by which we may hope to analyze more deeply some of the factors in development that control and modify the system.

BIBLIOGRAPHY.

BUELL, C. E., 1922. Origin of the pulmonary vessels in the chick. Contributions to Embryology (this volume).

FINLEY, E. B., 1922. The development of the subcutaneous vascular plexus in the head of the human embryo. Contributions to Embryology (this volume).

HOLMAN, E., 1920. End-to-end anastomosis of the intestine by presection sutures. An experimental study. Johns Hopkins Hosp. Bull., vol. 31, p. 300.

HUNTINGTON, G. S., 1911. The anatomy and development of the systemic lymphatic vessels in the domestic cat. Memoirs of the Wistar Institute of Anatomy and Biology, Philadelphia, No. 1.

KAMPMEIER, O. F., 1922. The development of the anterior lymphatics and lymph hearts in anuran embryos. Amer. Jour. Anat., vol. 30, p. 61.

LEWIS, F. T., 1906. The development of the lymphatic system in rabbits. Amer. Jour. Anat., vol. 5, p. 95.

SABIN, F. R., 1920. Studies on the origin of blood-vessels and of red blood-corpuscles as seen in the living blastoderm of chicks during the second day of incubation. Contributions to Embryology, vol. 9, Carnegie Inst. Wash. Pub. No. 272.

STOCKARD, C. R., 1915. The origin of blood and vascular endothelium in embryos without a circulation of the blood and in the normal embryo. Amer. Jour. Anat., vol. 18, p. 227.

STREETER, G. L., 1917. The development of the scala tympani, scali vestibuli, and perioticular cistern in the human embryo. Amer. Jour. Anat., vol. 21, p.299.

———, 1918. The developmental alteration in the vascular system of the brain of the human embryo. Contributions to Embryology, vol. 8, Carnegie Inst. Wash. Pub. No. 271.

WEED, L. H., 1917. The development of the cerebro-spinal spaces in pig and in man. Contributions to Embryology, vol. 5, Carnegie Inst. Wash. Pub. No. 225.

DESCRIPTION OF PLATE.

FIG. A. Endothelial sprout from wall of median anterior vein of the area pellucida of the yolk-sac of a chick (No. 312) on the fourth day of incubation. The specimen was grown on a cover-slip for 2 hours in Locke-Lewis solution and then fixed in Bouin's solution, stained in hematoxylin and counterstained in eosin and orange G. × 525.

FIG. B. Branched endothelial sprout from the wall of a smaller vein from the same specimen. The reticular structure of the red blood-cells is an artefact due to the fixation. × 525.

FIG. C. Small sprout from a vein, taken from the same specimen, showing a heaping up of endothelial nuclei at its base. × 525.

FIG. D. View of degenerating veins along the course of the same vein as figure 1, but closer to the embryo. The large vein at the right is normal. The specimen shows the preliminary collapsing of the endothelium as evidenced by the solid core of endothelium, followed by the death of both endothelial and adventitial cells. × 525.

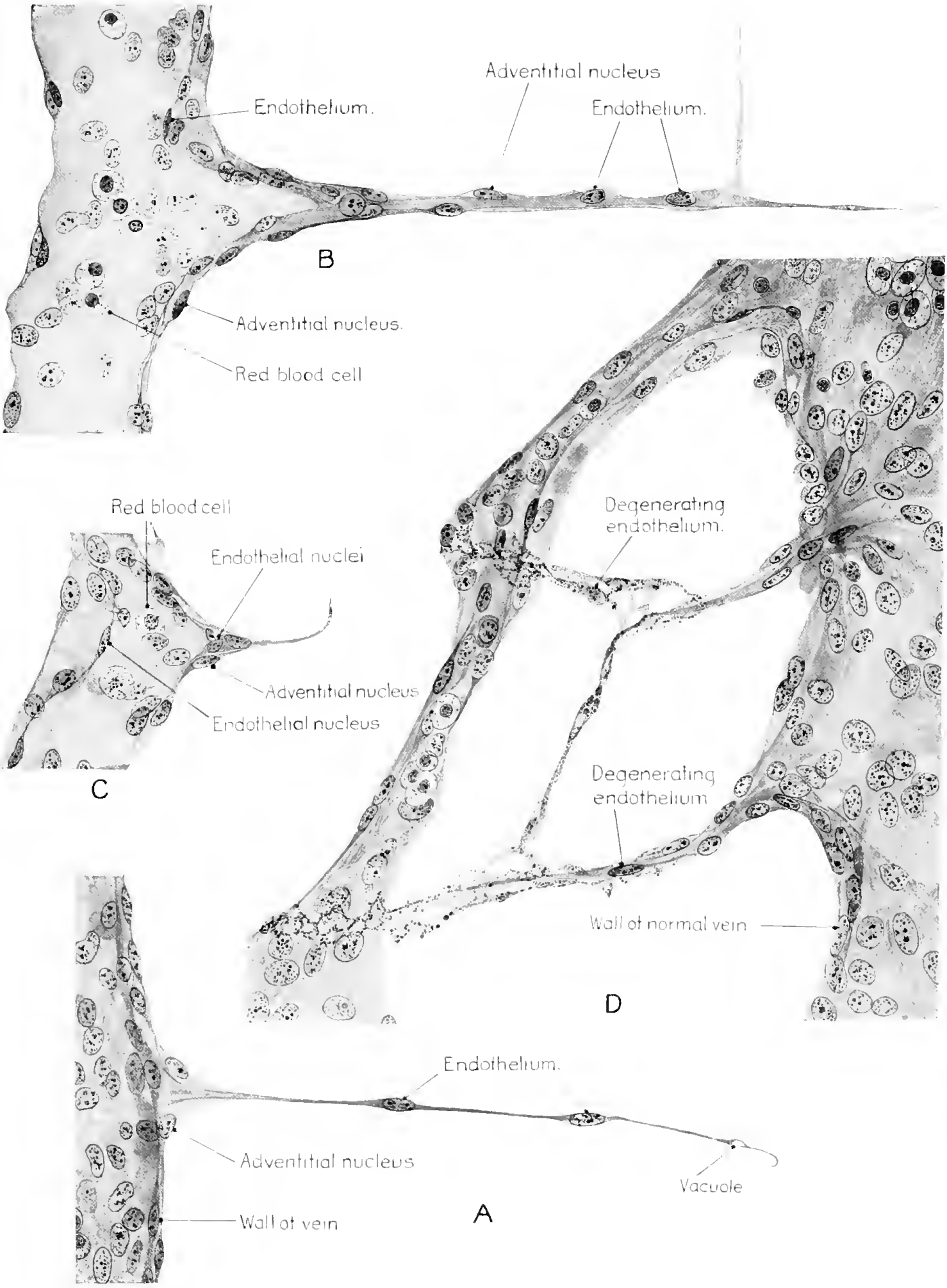

J. F. DIDUSCH FECIT

CONTRIBUTIONS TO EMBRYOLOGY, No. 66.

ORIGIN OF THE PULMONARY VESSELS IN THE CHICK.

By Charles Elbert Buell Jr.,
Anatomical Laboratory of The Johns Hopkins University.

With two plates.

ORIGIN OF THE PULMONARY VESSELS IN THE CHICK.

INTRODUCTION.

This paper deals with the origin and early stages of the pulmonary vessels of the chick, as demonstrated by stained serial sagittal and cross-sections of fixed specimens and by injecting living embryos with dilute india ink. The serial sections begin at the stage of 20 somites, in which the first evidence of a pulmonary system is seen in the proliferation of angioblasts from endothelial walls of established vessels, although it is possible that a few of these cells may differentiate from mesothelium. From these sections I have been able to show that this proliferation of angioblasts gives rise to both the common pulmonary vein and the left valve of the sinus venosus. The angioblasts spread over the ventral surface of the gut, acquire a lumen, and form a capillary mesh from which the vessels of the lung are evolved. After this plexus is patent and connected to the systemic vessels, the changes leading to the formation of the earliest pulmonary system may be followed by injections. By means of a modified technique for injection I have been able to demonstrate earlier stages in these vessels than have heretofore been shown and to trace the metamorphosis which this capillary plexus undergoes in forming the rudimentary pulmonary vessels. The study ends at the stage of 85 hours' incubation, at which time the pulmonary system is definitely laid down in its earliest complete form.

Concerning the origin of the pulmonary vessels, not only is our present knowledge meager, but the views are conflicting and based on observations of embryos of different forms, made with varying technique. Wax reconstruction of small blood-vessels, while a valuable asset to the embryologist, is open to manifold errors, and where possible should be checked up by injections. Confusion has arisen from the efforts to prove or disprove the probable course of events in one embryonic form from observations on another embryonic form. In recent studies of the pulmonary vessels, guinea-pig, rabbit, cat, and chick embryos have been represented. The finer details in the development of separate structures might follow quite different courses in these several forms. Although it is to be remembered that any attempt to draw conclusions for one on the basis of another is open to error, this study is presented in the hope that demonstrating the developmental steps of the vessels of the lung in the chick may by comparison prove of value in working out the embryology of similar structures in other forms.

In an investigation of this kind some obstacles are sure to be encountered, even in so simple an embryo as the chick. In mammalian embryos these are harder to overcome and offer a possible explanation for our present inadequate knowledge of the origin of these vessels. The period of origin, from the beginning of the proliferation of the angioblasts until the establishment of a lumen in the pre-pulmonic capillaries, represents a relatively short period of incubation and exact stages are not easily defined. The delicate collapsing capillaries are difficult to make out in serial sections unless they are injected. Wax reconstruction of such minute vessels is more or less impracticable because there are no blood-corpuscles in the small capillaries. Angioblast and mesenchyme cells are not easily differentiated and hence interpretation is often difficult. The location and continuity of angioblastic cells with endothelium or other angioblasts are of great value in their identification. The angioblast is larger than the mesenchyme cell, the cytoplasm contains more basophilic substance, and the nucleus is more oval, larger, and more vesicular. In injected specimens mounted *in toto* the small capillaries are concealed by large systemic vessels packed with granules of ink. This drawback has been overcome by a simple method of paraffin dissection for the younger embryos and direct dissection of the older ones.

METHODS.

Three methods were used in this study: (1) Injecting living embryos and clearing, by the Spalteholz technique, for dissection in oil of wintergreen; (2) embedding injected chicks in paraffin for dissection; (3) cutting serial sagittal and cross-sections (10 to 15 microns) for staining. A summary of the development of the technique of injections is found in the work of Sabin (1915). The injection method used in this work is a modification of that devised by Popoff. The injections were made by blowing ink into the vitelline vein of the living embryo by means of a fine glass canula. Popoff (1894) first described this method of injecting small vessels. In his work on the yolk-sac he found that injections of prussian blue greatly facilitated the study of the capillaries. He did not apply the method to vessels within the embryo proper, but used it for the vessels of the yolk-sac by injections made into the marginal sinus. At that time he noted the influence of the heart and the direction of the blood-flow upon the completeness of his injections.

My injections were made into the right vitelline vein, which lies over the artery and lends itself readily to injection. The tributaries of this vein join at an angle just before entering the body of the embryo. The point of the canula was introduced into the vein at the vertex of this angle, which acts as a guide and offers sufficient resistance to allow the entry of the needle into the vein. The tip of the canula is visible and the extent of the injection under perfect control. MacCallum simplified the injection of small vessels by following its course under a compound microscope. A binocular microscope is of great help in making very dilute injections where danger lies in blowing too much ink into the blood-stream. A small amount of ink diluted with physiological saline does not embarrass the circulation. The heart action mixes the ink thoroughly with blood plasma and gives a complete injection. The ink granules adhere to the endothelium of the vessels, due either to the sticky surface of the endothelium or to direct phagocytosis. Care should be observed that no vessels are torn in preparation for the injection.

To make a suitable glass canula, select a piece of soft glass tubing 12 cm. long and 5 cm. in diameter. Using a Bunsen flame, mold the tubing into the shape of a U. Hold an arm of the U in each hand and draw out quickly until the base measures 5 cm.; now substitute a small flame (1 cm.) for the Bunsen burner. Gently heat the base of the U near either arm, and as it softens a quick drawing motion completes the canula. A second one can be made from the other arm. Trim the tip to the desired size with a pair of small scissors and the canula is ready for use. Equip with a piece of rubber tubing of convenient length and a glass mouthpiece.

Injection Mass.—It has been found that india ink is more suitable for injection than prussian blue, because of its finer granulation. At first I diluted the ink 1 to 1 with water. This was freshly filtered and used at once. These injections, however, were too intense and seemed to embarrass the circulation. Better injections were obtained by diluting the ink 1 to 5 with physiological saline and filtering several times through the same paper; the ink is still further diluted in the blood-stream. This gives excellent injections of the capillaries and at the same time renders the large overlying veins transparent, so that they do not obscure the lung-vessels.

To inject a chick, draw up a small quantity of freshly filtered dilute ink into the canula, followed by a drop of physiological saline to prevent soiling of the field of injection. Prepare a dish of warm Locke's solution, about 37° C., and another dish containing 10 per cent nitric acid for fixation. Place the egg in a shallow glass jar packed with cotton. Remove a sufficient quantity of shell to expose the embryo and permit free access to it. Add a few cubic centimeters of warm Locke's solution to prevent drying. Place the preparation under a low-power binocular microscope and remove the vitelline membrane over the site of the proposed injection. Introduce the tip of the canula into the angle formed by the tributaries of the right vitelline vein and blow the ink into the vein. The heart action completes the injection. In fixing, add the 10 per cent nitric acid first directly to the embryo, then remove the embryo from the shell and place it for 5 minutes in a cover-glass containing the acid solution. The acid fixative makes the tissues more transparent and prevents diffusion of the ink through the vessel-walls. The fixed specimens are washed in several changes of water to remove the excess acid. Some of my specimens were given a light lavender tint with Ehrlich's haematoxylin, but this is not necessary. The embryos are dehydrated with graded alcohols—absolute alcohol, absolute alcohol and xylol, xylol—then (on an electric stove) through xylol and paraffin, and finally paraffin for embedding and dissection. The larger embryos are not embedded, but are put through benzine into oil of wintergreen for direct dissection.

Paraffin Dissection.—In using whole mounts of injected embryos for the study of the early lung vessels, a difficulty is encountered in the large overlying cardinal veins that obscure the delicate vessels beneath. This difficulty increases with older stages and more complete injections. In efforts to overcome it I have had good results with the following simple method of dissection: The embedded embryo is trimmed into a block so that the broad surface is parallel to the sagittal plane of the embryo. With gentle heat the block is fixed upon a glass slide. In good light, under the high power of a binocular microscope, holding a sharp scalpel lightly in the fingers of the right hand, successive layers of paraffin are shaved off until the overlying injected vessels are removed. The block is then reversed, exposing the other side of the embryo, and the procedure repeated. The block is then removed, the paraffin dissolved off in xylol, and the block mounted in balsam. By this method the early pulmonary capillaries are brought out clearly and their development can be readily followed. Figures 7 and 8 were drawn from dissections of this sort.

Direct Dissection.—This method was more practical with the older embryos. The chick was injected as above described, dehydrated in graded alcohols, and passed through benzine into oil of wintergreen. The preparation was then placed under the high power of a binocular microscope, and held in position with a fine camel's-hair brush. With needle-pointed forceps the large limb-buds on both sides were carefully removed before attempting the more delicate structures. The cardinal veins, duct of Cuvier, and sinus venosus were opened and brushed free of ink granules. This procedure exposes the pulmonary vessels *in situ* while preserving their anatomical relations. Such a technique was used for specimens shown in figures 9 and 10.

Serial Sections.—In the early stages in which the splanchnic plexus can not be injected, *i. e.*, before the pre-pulmonary capillaries are patent, I resorted to serial sections. The embryos were fixed with Bouin's mixture (75 parts picric acid, 20 parts 40 per cent formalin, and 5 parts glacial acetic acid). After removal from the shell the chick was fixed for one hour in this mixture, then passed directly through several changes of 60 per cent alcohol to remove the excess of the fixative, and finally through the graded alcohols to paraffin, as above described. Sections 10 to 15 μ in thickness were cut by the water-knife method of Huber and stained in hematoxylin and erythrosin. Both sagittal and cross sections were used, so as to serve as a check in either series and to give a more exact localization of the anatomical structures. By using both types of sections the left valve of the sinus venosus can be assigned to its correct position in relation to the mass of cells giving rise to the common pulmonary vein. Sagittal sections have a close relation to the injected specimens, which are used as guides. Erythrosin is used as a cytoplasmic stain, although in the early stages the cells show a marked affinity for basic dyes. Cochineal carmine may be used alone after cells have been identified.

PULMONARY VEIN.

The present status of our knowledge of the origin of the pulmonary vein is embodied in the seemingly opposed views of Fedorow and Brown. The former holds that the vein is derived from an endothelial proliferation of the dorsal wall of the sinus venosus, while Brown thinks that it is a part of an indifferent plexus originally present in this region.

Fedorow (1910), studying embryos of four orders (amphibian, reptile, bird, and mammal), reports the origin of the vein as an outgrowth of endothelium from the dorsal wall of the sinus venosus. The cavity of the sinus extends into this proliferation for a short distance, forming the pulmonary vein, then breaks up into two vessels which in turn ramify into capillaries that unite with a similar capillary outgrowth formed by the pulmonary arteries.

Brown (1913), from his observations on embryos of the domestic cat, together with reference to sections of chick embryos, questions the work of Fedorow. He states that the pulmonary system is simply a specially developed part of an indifferent plexus originally present in this region, and that the proliferation of endothelium described by Fedorow is the left valve of the sinus venosus, which occupies that position.

In considering these two views it must be remembered that the investigators were using embryos of different forms and that the course of development may vary in these types. My work on the chick can do no more than establish the process as it occurs in that embryo and is designed only for that end. At the same time I feel that this paper tends to show that the views of Brown and Fedorow are mutually exclusive only so far as their interpretations are concerned, not in any actual differences in the mode of development of the pulmonary vein in their respective embryos. That there is a proliferation of endothelium from the dorsal wall of the sinus venosus is apparent. Equally so is the fact that the pulmonary vein is not established at that time. In slightly older stages the pulmonary vein is seen opening into the sinus venosus at that point, and yet in the same section is a mass of endothelium readily recognizable as the left valve of the sinus venosus. Fedorow did not recognize the left valve of the sinus venosus or the dual character of the mass of endothelium giving rise to both the endothelial lip of the left valve and the common pulmonary vein. Brown, from his cat-embryo material, does not exclude the possibility of this origin of the pulmonary vein. He says:

> "It is the purpose of this paper to follow the development of the pulmonary vein of the domestic cat from the early stage in which it empties into the cephalic portion of the sinus venosus in the median line to the stage in which it attains its definitive connections with the left auricle."

From his work it is clear that in his earliest stage the pulmonary vein is already established and that, instead of offering proof as to the origin of the vein, he is merely describing a stage in its development. Earlier stages might show that in the formation of the pulmonary vein the cat follows the same process as the chick. At least Brown's observations do not exclude such a probability and suggest further work on the cat embryo.

Brown raised a legitimate objection to Fedorow's work so far as the left valve of the sinus venosus is concerned, in that the latter observer did not recognize the left valve as such nor show its relation to or origin with the common pulmonary vein. On the other hand, Brown is in error in rejecting Fedorow's work upon the origin of the pulmonary vein, since he based his contention upon findings in a different embryo and at stages that are plainly older than those described by Fedorow. Brown probably saw the endothelial lip of the left valve of the sinus (fig. 5) and the pulmonary vein opening into the sinus and concluded that this was what Fedorow described.

COMMON PULMONARY VEIN AND ITS TRIBUTARIES.

The first indication of the common pulmonary vein is a proliferation of angioblasts from the dorsal wall of the sinus venosus extending dorsally toward the gut at the level of the lung-bud. This occurs in the chick at the stage of 20 somites and is best seen in sagittal section (fig. 1). There is no venous opening into the sinus at this time, indicating that the pulmonary vein is not established. This primary proliferation of angioblasts soon shows a differentiation into a right and left portion having distinct histological differences (figs. 2 to 5). The right two-thirds forms a compact mass of endothelium of the lip of the left valve of the sinus venosus (fig. 5), into which the mesothelium of the dorsal mesocardium extends. On the left the angioblasts are larger and more loosely connected; they extend dorsally to the surface of the gut and spread out in all directions over its ventral surface in the plane of tissue between the endoderm of the gut and the dorsal mesocardium. At the same time, angioblasts can be seen to differentiate from both sides of the dorsal aorta and from the bulbus of the ventral aorta, until the whole ventral surface of the gut is covered with a plexus of angioblasts which have not yet formed the capillaries. It is possible that some of the angioblasts may differentiate *in situ* from mesoderm, but I have not found any isolated clumps of these cells that would indicate that this does actually occur. At this stage the thickness of the embryo precludes the study of living cells in this region, which is necessary for direct proof of such a process. The loosely meshed clump of angioblasts lying between the tip of the lung-bud and the sinus venosus on the left side (figs. 2 and 3) undergoes central liquefaction and opens secondarily into the sinus venosus. This is the common pulmonary vein, which at this stage is a blind pouch, as the plexus of angioblasts covering the ventral surface of the gut is not patent but is merely a network of cells connecting the common pulmonary vein with the ventral and dorsal aortæ. This plexus of angioblasts acquires a lumen and forms a capillary net, the splanchnic plexus, which connects the lumen of the sinus venosus, through the common pulmonary vein, to the dorsal and ventral aortæ and cardinal veins.

I am not prepared to state whether the lumen of this plexus of capillaries is an extension of the lumen of the common pulmonary vein or of the ventral or dorsal aortæ, or whether, as in the case of the common pulmonary vein, it is produced by central liquefaction. In the case of the pulmonic arches (sixth) there is definitely an extension of the lumen through a cord of angioblasts, while the common pulmonary vein is formed by central liquefaction. Both processes occur in early blood-vessel formation and are probably dependent upon the hydrodynamics of circulation in any given area. This would explain the different processes seen in the case of the pulmonic arches in contrast to the common pulmonary vein. Fedorow thought that the lumen of the sinus venosus extended into this endothelial proliferation. In my sections the reverse seems to be true; the mass of endothelial cells undergoes central liquefaction, forming a lumen that opens secondarily into the sinus venosus. Figure 3 shows a stage in which central liquefaction has occurred but there is no opening into the sinus. Figure 5 shows this process slightly older and there is now an opening into the sinus at that point.

That this outgrowth of endothelium or angioblasts is the first indication of the common pulmonary vein is supported by the following facts: (1) There is no venous opening into the sinus at this point, either before or during the proliferation of angioblasts from the dorsal wall of the sinus venosus. (2) This mass of cells occupies the exact position at which, in a later stage, the common vein opens into the sinus venosus. (3) Liquefaction can be seen in this mass of angioblasts before the vein has opened into the sinus. (4) The orifice of the common pulmonary vein in later stages can be seen at this point, the mass of cells having disappeared. (5) The lip of the left valve of the sinus venosus is also derived from these cells and is present throughout the process, having distinct histological differences that render its identification a simple matter (figs. 4, 5).

Some confusion may arise from the fact that the pulmonary vein opens into the sinus at the left of the left valve of the sinus; in other words, the left valve lies to the right of the opening of the vein. A study of the early development of the heart shows this to be the case. Later, however, when the left valve fuses with the dorsocaudal extremity of the septum superius (Brown), the opening of the vein is assigned to its final position in the left auricle.

The pulmonary circulation goes through two phases of development, ascending and retrograde. The former reaches its maximum at the stage of 90 hours' incubation. At this time the system consists of two pulmonary arches, two pulmonary arteries, and a common pulmonary vein with four main branches plus connections to both anterior cardinal veins. From this time on, the system may be said to undergo retrograde changes leading to the adult structure. It is beyond the scope of this paper to consider more than the origin of these vessels and the first step in their retrogression, *i. e.*, the loss of two of the branches of the common vein.

With the formation of the common pulmonary vein and its connection with a patent splanchnic plexus of capillaries over the ventral surface of the gut, a new path of blood-flow is established between the arterial and venous portions of the heart through this plexus. The axis of the common vein is perpendicular to that of the plexus and divides the plexus into two portions, the cephalic and post-caval, both of which drain into the common vein. A change occurs, due to dynamics of circulation and growth, in which the capillaries in each of the four directions about the common vein are replaced by individual vessels that take over the function of the plexus. On the right and left sides of the gut, at the level of the lung-bud, the right and left lateral branches are formed. These are the true pulmonic branches, in that each drains its respective artery in the right and left lung rudiment. They persist and develop with the lungs.

The capillaries caudal to the common vein begin to disappear early, decreasing in size, number, and importance. They are merely the connections between the cephalic and post-caval portions of the splanchnic plexus. At the stage of 90 hours of incubation they are represented by only one or two small twigs which soon disappear. It is of interest to note that the persistence of one of these vessels may give rise to a very unusual anomaly of the pulmonary circulation. Brown gives an excellent description of such a case.

A most interesting vessel is derived from the capillaries cephalad to the common vein, *i. e.*, the cranial tributary of the pulmonary vein. This lies in the midline of the ventral surface of the gut and drains a system of anastomoses between the two pulmonary arteries, receiving also small twigs from the pulmonary arches. Figure 10 shows this vessel at the height of its development. It, also, is a temporary structure and begins to degenerate at the stage of 100 hours. Squier has shown a later stage in which it has lost its rich arterial connections and stands out like a dead branch of a tree, finally disappearing. Squier used a method of wax reconstruction and described a stage 10 hours older than that shown in figure 10. During this period several changes take place. The cranial tributary loses its connections with the pulmonary arteries and disappears. The distal communications with the post-caval plexus have disappeared. The lung rudiments begin to show definite signs of lobulation and the vascular picture has accommodated itself to that change.

In summary, then, the formation of the pulmonary circuit falls into three main periods:

(1) *Precirculatory.*—A proliferation of angioblastic cells from established embryonic endothelium, with the possibility also that some of the vasoformative cells may differentiate from mesoderm and join in the process. This mesh of angioblasts undergoes cytoplasmic liquefaction, forming a capillary net over the surface of the primitive gut. From this plexus the pulmonary vessels are evolved.

(2) *Circulatory.*—After the capillary plexus is patent, a new route is established between the arterial and venous portions of the heart. The plexus undergoes a change in pattern with the establishment of new lines of blood-flow and the formation of definite vessels, such as the pulmonary arches, arteries, capillaries, and veins.

(3) *Adaptive.*—With the development of the lung, new patterns of vessels are evolved to accommodate the circulation to this change. This leads to the formation of a true pulmonary circulation. The arteries increase in length, the capillaries over the lung rudiments increase in number, and the remnants of the indifferent plexiform stage disappear. The cranial tributary has reached its highest development and is about ready to disappear. The post-caval connections have already disappeared except for one or two small remaining twigs.

Streeter (1915), in a study of the vascular system of the brain of the human embryo, divides the stages of development of the brain-vessels into five periods, showing the various adaptive changes which the circulation goes through in accommodating itself to the ever-changing environment of embryonic development.

PULMONARY ARTERY.

The recent views on the origin of the pulmonary artery have undergone a complete change from the old concepts that still dominate the text-books, based on the works of His, Zimmermann, Rathke, and others. The old idea that the pulmonary artery is derived as a branch from the pulmonary arch was the accepted one until the recent work of Fedorow, Bremer, and Huntington. Even Bremer (1902, 1909) adhered to this conception in his first two articles, but corrected it in a third paper on the rabbit embryo. He describes the origin as a blind extension of a capillary net from the ventral aorta. Unknown to Bremer, Fedorow, in a Russian publication, antedated the former's work by a similar description of the origin of the pulmonary artery in the embryo of the guinea-pig. Bremer (1912*b*), in a fourth paper, generously acknowledged the priority of Fedorow's work.

Huntington, basing his observations on reconstructions from the cat embryo, holds that the artery is formed by the "organization of a distinct arterial channel in the ventral portion of the post-branchial plexus." Thus far his observations coincide with my own on the chick. Concerning the origin of the original plexus, he states that it is derived from the dorsal aorta and links up secondarily with the ventral aorta:

> "The so-called outgrowth from the pulmonary sixth arch serves merely as the point of junction, at which after coalescence with the pulmonary plexus, the blood is carried from the ventral segment of the sixth arch into this prepared channel of the pulmonary artery. The outgrowth would be more correctly defined as the pulmonary arterial tap or approach of the sixth arch."

Huntington's description of the origin of the splanchnic plexus in the cat is quite different from the condition met with in embryos of the guinea-pig, rabbit, and chick. It may be possible that the cat is individual in this respect. Fedorow, using guinea-pig embryos, described an extension of capillaries from the ventral aorta. A similar observation is made by Bremer in rabbit embryos. My chick embryos show an extension of angioblasts from the ventral aorta. However, this is but a part of the whole process and there are other factors which contribute to the formation of the splanchnic plexus. In considering this we must realize that the splanchnic plexus consists of more than merely that portion giving rise to the pulmonary arteries; it lies caudal to the fourth aortic arch and includes the developing hepatic system as well. In the chick the different parts of the plexus are derived from different structures. The cephalic (pre-pulmonic or post-branchial) portion of the plexus is formed from angioblasts derived from the endothelium of the dorsal aorta, ventral aorta, and sinus venosus. The post-caval portion is largely from the dorsal aorta and partially from the sinus venosus. The cardinal veins may also contribute to both parts of the plexus, although I have not seen any direct proliferation from them. They are joined to the plexus at a very early stage, namely, at 35 somites. It is also possible that certain of the angioblasts may differentiate from mesenchyme and contribute to this formation.

In order to understand the origin of the pulmonary artery, it is necessary to consider that portion of the splanchnic plexus lying between the fourth aortic arch and the sinus venosus at the level of the lung-bud. The pulmonary artery, and the pulmonary arch (sixth) as well, are persisting channels in this capillary bed.

As to the origin of the capillary plexus, it is derived from angioblasts that proliferate from endothelium of established vessels. From the dorsal aorta angioblasts spread out ventrally over the surface of the gut. From the ventral aorta they extend caudally under the surface of the gut. From the sinus venosus, as a part of the common pulmonary vein, the angioblasts spread laterally, caudally, and cranially, so that the ventral surface of the primitive gut is covered with a network of angioblasts. This sheet of angioblasts later forms a network of capillaries connecting the dorsal and ventral aortæ to the sinus venosus through the common pulmonary vein. There are also connections to anterior and posterior cardinal veins.

This capillary plexus, meeting the fate of all embryonic capillary meshes, is changed into individual vessels, certain ones of which increase in size and take over the function of the smaller capillaries, leading to the atrophy and loss of the latter. This process is followed in the splanchnic plexus. I have already shown how the tributaries of the pulmonary vein are evolved in this manner. In a similar way the arteries are formed. In figure 8, along the junction of the lateral and ventral surface of the gut on each side, is a capillary vessel which arises from the ventral aorta, extends caudalward, following a diagonal course to the laterodorsal surface of the lung rudiment, where it connects with other capillary vessels, the forerunners of the corresponding branches of the common pulmonary vein. It is possible to inject the vessel at 60 hours' incubation (35 somites).

It is interesting to note that the lumen of the artery can be injected before the pulmonary arch is patent, showing that the artery antedates the arch. This does not agree with the observations of Huntington in cat embryos, in which he states the arches are formed before the arteries.

PULMONARY ARCHES.

The pulmonary arches (sixth) arise in a manner slightly different from that of the other aortic arches. The difference is largely chronological. The fact that the arches are formed in conjunction with the splanchnic plexus and hence may be regarded as a part of that capillary net does not cover the whole process, as there are certain differences in origin that must be considered. The arches are formed later than the pulmonary artery and vein and other capillaries in the splanchnic plexus. It is possible to inject these vessels before a lumen is established in the arches, although the dorsal and ventral primordia can be seen. Figure 7 shows such a stage.

The pulmonary arch on each side arises from two sources. The first or dorsal rudiment often has a double origin, part from the dorsal aorta and part from the fourth aortic arch at the angle formed by the union of these two vessels. This is the most constant relation, although some injections show it coming almost entirely from the fourth arch near its junction with the dorsal aorta. It curves ventrally around the last pharyngeal pouch and is connected with a similar process extending dorsally from the ventral aorta. The lumina of the dorsal aorta and fourth arch penetrate the dorsal angioblastic cord from above, often separately for a short distance, then uniting and extending ventrally. In a similar manner the lumen of the ventral aorta extends dorsally into the ventral angioblastic cord. The two lumina meet behind in the fourth pharyngeal pouch, completing the pulmonary arch. This occurs in chicks of 35 somites.

It is possible to inject both the dorsal and ventral primordia before the arch is complete (fig. 7). In embryos a few hours older it is possible to inject the whole arch, the large, pouch-like lumina of the two rudiments being connected by a delicate capillary filament. I have injected such a stage, which is earlier than that shown in figure 8, and in which there is a complete arch, in the form of an extremely fine capillary, connecting the large dorsal and ventral pouches of the arch. This is the earliest stage at which it is possible to inject the arch by this method. The specimen was not used for illustration because other structures, due to faulty dissection, did not show clearly.

As soon as the arch is complete it undergoes a rapid increase in size until it is equal in importance to the other arches. Its position, connecting the ventral aorta to the dorsal aorta, puts it in the direct line of arterial blood-flow. The dynamics of increased pressure, rate of flow, and action of the heart are undoubtedly responsible for this rapid increase in size. The pulmonary artery, lying in an indirect path connected with the venous circulation, has no such stimulus to growth and remains a small, unimportant-looking vessel. The early connection of the pulmonary artery with the ventral aorta, adjacent to the pulmonary arch, is soon altered. The arch during its rapid growth actually carries the small artery along with it, until in later stages the artery is seen to come off at the junction of the ventral and middle third of the arch. This early disproportion in size, together with the relation of the artery to the arch at this stage, gave rise to the former erroneous view that the pulmonary artery arises as a small branch from the arch. In reality the two arise independently of each other, the artery actually antedating the arch.

I wish to take advantage of this opportunity to acknowledge the generous assistance and encouragement of Dr. F. R. Sabin, under whose supervision this work was done.

SUMMARY.

1. The first phase of the vascular system of the lung consists of masses of solid angioblasts, rather than of a plexus of vessels, but although the origin of the pulmonary system falls well within the period in which vasoformative cells are seen to differentiate out of mesoderm, I have in my material no positive evidence that the angioblasts giving rise to this system do actually differentiate *in situ* from mesenchyme. No isolated clumps of these cells indicating such a process are seen in my sections. A study of the cells of this region in a living blastoderm is impracticable because of the dense intervening tissues. The angioblasts seen are connected to other angioblasts, and the earliest cells are in continuity with and lie near the endothelium of established vessels, and the zone between the gut and the dorsal mesocardium is almost acellular before the spread of angioblasts into that area.

2. The first indication of the common pulmonary vein is a proliferation of angioblastic cells from the dorsal endothelial wall of the sinus venosus at the level of the developing lung-bud, seen in chicks of 20 somites.

3. This mass of cells extends between the folds of the dorsal mesocardium until the solid wall of the ventral surface of the gut is encountered. They then grow out in all directions over the ventral surface of the gut, contributing to the formation of the splanchnic plexus (20 to 30 somites).

4. The core of angioblasts between the primitive gut and the sinus venosus becomes differentiated into two parts. The right two-thirds is a compact mass of endothelium forming the left valve of the sinus venosus; the left third undergoes central liquefaction and opens into the lumen of the sinus venosus. This is the common pulmonary vein in the form of a blind pouch connecting the sinus venosus with the angioblasts on the surface of the gut (24 somites).

5. The angioblasts on the ventral surface of the gut in the region of the developing lung-bud acquire a lumen and form the splanchnic plexus (30 to 35 somites). The four tributaries of the pulmonary vein are surviving vessels in this plexus of capillaries. The veins from the right and left lobes persist and develop with the lungs. The post-caval connections disappear at about 90 hours of incubation. The cranial tributary loses its arterial connections and disappears at about 100 hours of incubation.

6. The pulmonary arteries are persisting longitudinal vessels in the cephalic portion of the splanchnic plexus of capillaries. The angioblasts giving rise to these capillaries begin as a caudal extension of angioblasts from the endothelium of the ventral aorta.

7. The pulmonary arches (sixth) arise in the cephalic portion of the splanchnic plexus at the stage of 35 somites. The angioblastic precursors of the arches are derived from two sources, the dorsal rudiment from the junction of the dorsal aorta and fourth aortic arch, the ventral rudiment from the ventral aorta.

8. The pulmonary arches and arteries arise in the same plexus of capillaries, but independently of each other. The arteries are patent before the arches are complete. As a result of unequal rates of growth, the arch increases more rapidly in size than the artery and includes the mouth of the artery within its wall. This relation and early disproportion between the arteries and arches led to the former erroneous view that the artery is derived as a small branch from the arch.

BIBLIOGRAPHY.

Bremer, J. L., 1902. On the origin of the pulmonary arteries in mammals. Amer. Jour. Anat., vol.1, pp. 137–144.

——— 1909. On the origin of the pulmonary arteries in mammals. Anat. Record, vol. 3, pp. 334–340.

——— 1912*a*. The development of the aorta and aortic arches in rabbits. Amer. Jour. Anat., vol. 13, pp. 111–128.

——— 1912*b*. An acknowledgment of Fedorow's work on the pulmonary arteries. Anat. Record, vol. 6, pp. 491–493.

Brown, A. J., 1913. The development of the pulmonary vein in the domestic cat. Anat. Record, vol. 7, pp. 299–329.

Duval, M., 1889. Atlas d'Embryologie. Paris, G. Masson.

Evans, H. M., 1909. On the development of the aorta, cardinal, and umbilical veins, and other blood-vessels of vertebrate embryos from capillaries. Anat. Record, vol. 3, pp. 498–518.

Fedorow, V., 1910. Über die Entwickelung der Lungenvene. Anat. Hefte, Erste Abth., Bd. 40, pp. 529–607.

——— 1911. Communications of the Military Med. Acad., St. Petersburg, Russia, vol. 22. (After Bremer, 1912*b*.)

Flint, J. M., 1906–07. The development of the lungs. Amer. Jour. Anat., vol. 6, pp. 1–137.

Huntington, G. S., 1919. The morphology of the pulmonary artery in the mammalia. Anat. Record, vol. 17, pp. 165–201.

Lillie, F. R., 1919. The Development of the Chick. Henry Holt and Co.

Mall, F. P., 1906. A study of the structural unit of the liver. Amer. Jour. Anat., vol. 5, pp. 227–308.

MacCallum, W. G., 1902. Die Beziehung der Lymphgefässe zum Bindegewebe. Arch. f. Anat. u. Physiol., Anat. Abth., pp. 273–291. Also translated in Johns Hopkins Hosp. Bull., Baltimore, 1903, vol. 14, pp. 1–9.

Popoff, D., 1894. Die Dottersack-Gefässe des Huhnes. C. W. Kreidel's Verlag.

Sabin, F. R., 1915. On the fate of the posterior cardinal veins and their relation to the development of the vena cava and azygos in the embryo pig. Contributions to Embryology, vol. 3, Carnegie Inst. Wash. Pub. No. 223, pp. 5–32.

——— 1917. Origin and development of the primitive vessels of the chick and of the pig. Contributions to Embryology, vol. 6, Carnegie Inst. Wash. Pub. No. 225, pp. 61–124.

Squier, T. L., 1916. On the development of the pulmonary circulation in the chick. Anat. Record, vol. 10, pp. 425–438.

Streeter, G. L., 1915. The developmental alterations in the vascular system of the brain of the human embryo. Contributions to Embryology, vol. 8, Carnegie Inst. Wash. Pub. No. 271, pp. 5–38.

DESCRIPTION OF PLATES.

PLATE 1.

FIG. 1. Median-sagittal section (10 μ in thickness) through tip of lung-bud of a 20-somite chick, 40 hours' incubation; hematoxylin and eosin stain, series B. Angioblasts, forerunners of pulmonary system, are seen proliferating from and near dorsal endothelial wall of sinus venosus. They extend dorsally toward the ventral surface of the gut, which shows a slight ventral swelling—the primary lung rudiment. This is about the earliest stage in which there is any evidence of the formation of a pulmonary vascular system.

FIG. 2. Cross-section (10 μ) through tip of primary lung rudiment of a 21-somite chick, 48 hours' incubation; carmine stain, series O. A slightly later stage in the angioblastic proliferation from the dorsal sinus wall. The right portion of the cell-mass has begun to form a matted group of cells, the tip of the left valve of the sinus venosus. The left portion of the proliferation shows signs of liquefaction by which the common pulmonary vein is formed.

FIG. 3. Sagittal section (10 μ) through left third of proliferation of angioblasts, to show process of liquefaction extending toward sinus venosus. It is about to open into the sinus, thus forming the common pulmonary vein. Hematoxylin and eosin stain; chick of 23 somites, 48 hours' incubation, series D.

FIG. 4. Median-sagittal section (10 μ) through right two-thirds of mass of angioblasts, to show matting together of cells to form left sinus valve tip. The pulmonary vein is not established. This embryo (22 somites, 44 hours' incubation) is slightly younger than that shown in figure 3. Hematoxylin and eosin stain; series H.

FIG. 5. Cross-section (10 μ) through tip of primary lung rudiment of a chick of 24 somites, 48 hours' incubation; carmine stain, series E. The right two-thirds of the mass of angioblasts has formed the tip of the left valve of the sinus. The common pulmonary vein is now established, opening into the sinus to the left of the valve. Angioblasts can be seen spreading over the ventral surface of the gut. This is the earliest stage in which the common vein is complete.

FIG. 6. Sagittal section (15 μ) through plane of common pulmonary vein, showing it complete, from the sinus venosus to tip of lung rudiment. There is no pulmonary circulation at this stage. Angioblasts can be seen over the surface of the lung-bud. Embryo of 31 somites, 50 hours' incubation; hematoxylin and eosin stain; series X.

PLATE 2.

FIG. 7. From an injected embryo of 35 somites, 55 hours' incubation, dissected by the paraffin method. The lung consists of a simple ventral diverticulum beginning to show lateral swellings into right and left primary buds. The common pulmonary vein opens into the sinus at the level of the lung rudiment. It drains the capillaries of both cephalic and post-caval portions of the splanchnic plexus. The anastomoses between the plexus and the cardinal veins are established. The pulmonary arches are not formed, although the dorsal and ventral primordia of the arch are indicated by the blind pouches. The cranial end of the pulmonary artery is now easily recognized in the capillary plexus.

FIG. 8. A 36-somite chick of 60 hours' incubation, injected with ink and dissected by the paraffin method. Only the right half of the vascular tree is shown. This stage is but slightly older than that in figure 7. The pulmonary arch is now complete but still retains a capillary appearance. The pulmonary artery can be recognized in the cephalic portion of the plexus. The right lobar tributary of the common vein is formed and is connected with its corresponding artery on the dorsal surface of the lung-bud. The cranial tributary of the common vein is plainly seen. The wall of the sinus venosus has been removed to show the opening of the common pulmonary vein into the sinus.

FIGS. 9–10. Dissections of injected chick embryos of 85 hours' incubation. Figure 9 shows the right side of the pulmonary system. In figure 10 the spinal cord, dorsal aorta, and dorsal surface of the gut have been removed, exposing the pulmonary system in a coronal plane from a dorsal view. The lung is in a simple stage of right and left primary buds which do not show further lobulation. The left bud is more ventral than the right and is parallel to the gut. The right bud tends more toward a horizontal position in relation to the plane of the gut. The pulmonary vessels bear a constant relation to the bronchi of the buds, even at this early stage. The artery lies dorsal and lateral to the bronchus; the vein, ventral and medial to the bronchus, the lung capillaries lying between the two on the dorsal surface of the buds. The pulmonary artery comes off from the arch at the junction of its middle and proximal third, and passes directly back to the tip of the lung-bud, where it joins freely, in a capillary net, with the corresponding tributary of the pulmonary vein. Very near the arch a capillary connection is given off to the anterior cardinal vein. The two arteries extend parallel to each other and in their proximal third are joined by numerous capillary anastomoses which are drained by the cranial tributary of the common vein. The middle third of the artery has no branches. The entire distal third is connected with the vein by a rich plexus of capillaries over the dorsal surface of the lung-bud. A few twigs are still present, connecting with the post-caval portion of the plexus. The pulmonary vein is made up of several tributaries which unite in a common trunk; this in turn empties into the sinus venosus. Considerable variation is encountered in the pattern of these branches in different specimens. The right and left lobar branches to the lung-buds drain their respective arteries. In figure 9 a vessel connects the right lobar vein to the cranial tributary. This is not constant and is absent in figure 10. A few small branches to the post-caval plexus are seen caudal to the lobar branches. The cranial tributary of the common vein drains the anastomotic vessels between the two pulmonary arteries and arches. It extends directly caudad on the ventral surface of the gut and, with the other tributaries, empties into the common vein. It may have but one opening into the common vein, as in figure 10. This stage is about the oldest in which the cranial tributary is seen complete and represents its highest development. In a later stage, as described by Squier, the cranial tributary loses its arterial connections and disappears. The pulmonary arches (sixth) have undergone rapid growth and have included the arteries within their walls.

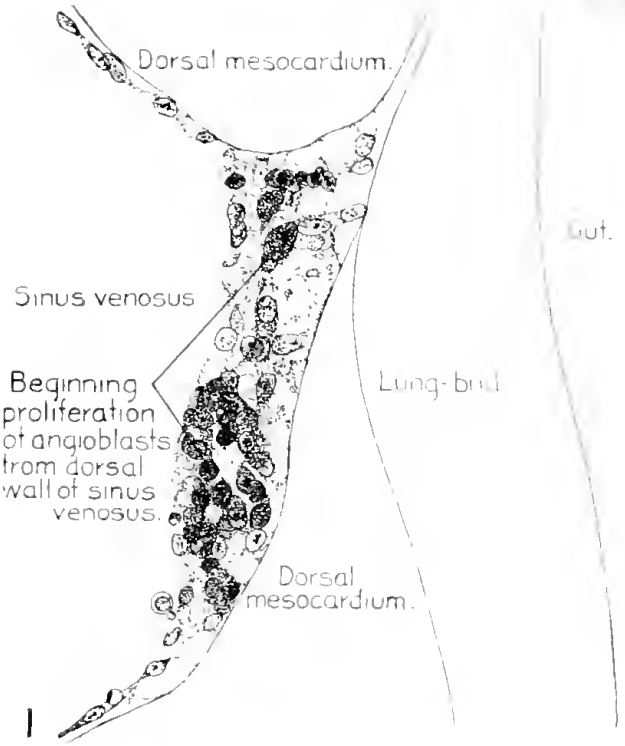
Dorsal mesocardium.
Gut.
Sinus venosus
Lung-bud
Beginning proliferation of angioblasts from dorsal wall of sinus venosus.
Dorsal mesocardium.

1

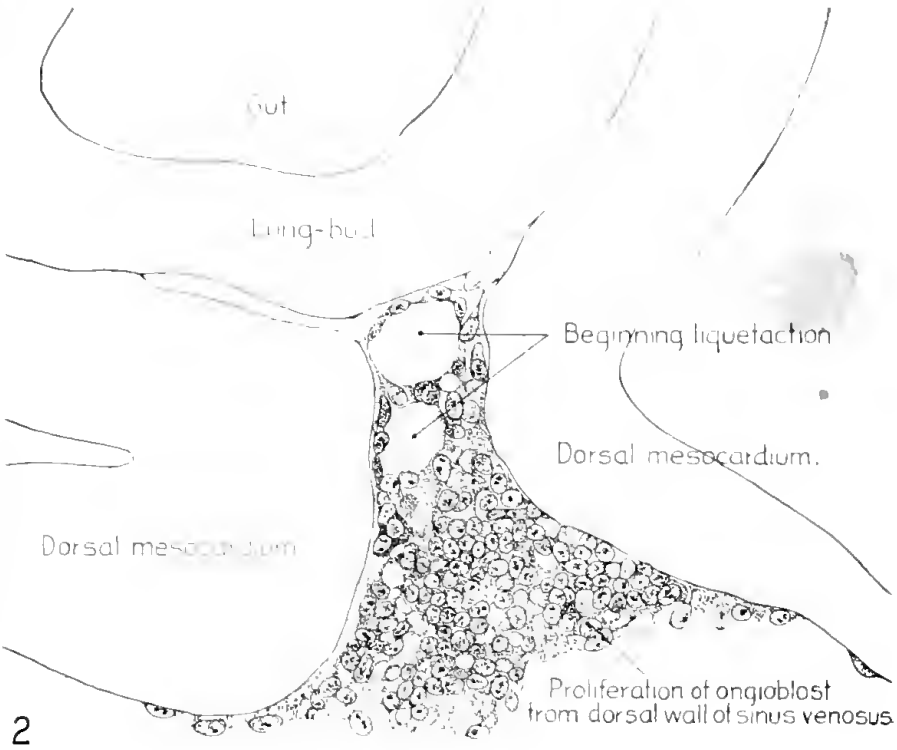
Gut
Lung-bud
Beginning liquefaction
Dorsal mesocardium.
Dorsal mesocardium
Proliferation of angioblast from dorsal wall of sinus venosus.

2

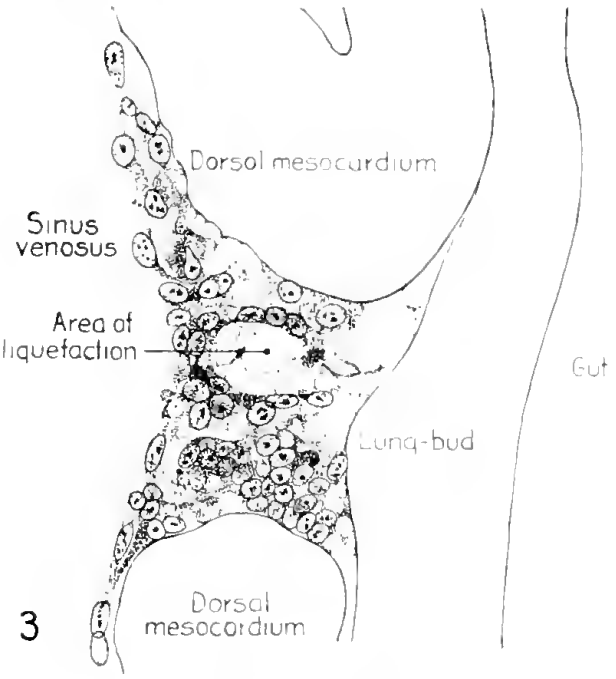
Dorsal mesocardium
Sinus venosus
Area of liquefaction
Gut
Lung-bud
Dorsal mesocardium

3

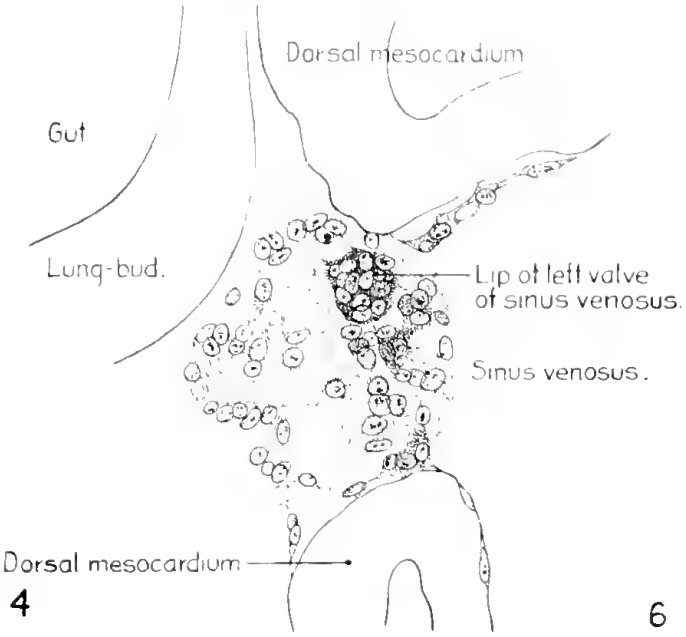
Dorsal mesocardium
Gut
Lung-bud.
Lip of left valve of sinus venosus.
Sinus venosus.
Dorsal mesocardium

4

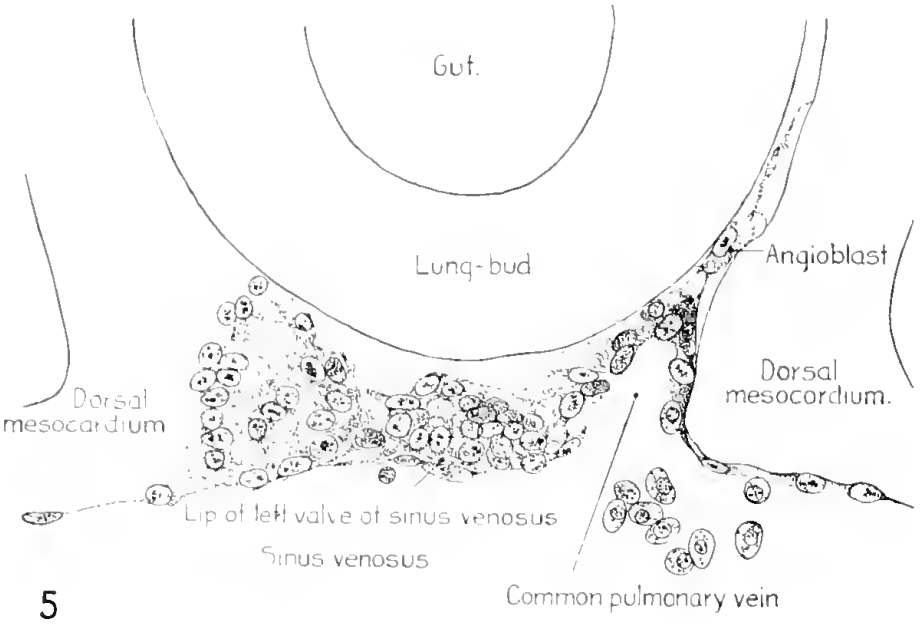
Gut.
Lung-bud
Angioblast
Dorsal mesocardium.
Dorsal mesocardium
Lip of left valve of sinus venosus
Sinus venosus
Common pulmonary vein

5

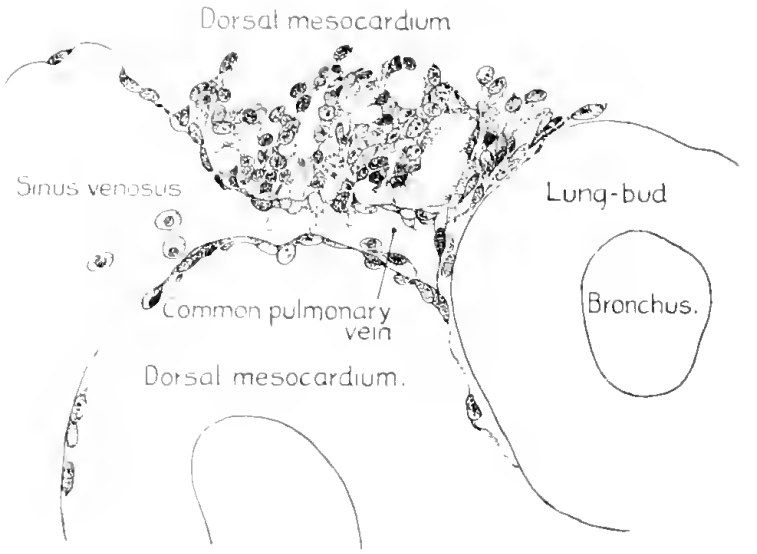
Dorsal mesocardium
Sinus venosus
Lung-bud
Bronchus.
Common pulmonary vein
Dorsal mesocardium.

6

CONTRIBUTIONS TO EMBRYOLOGY, No. 67.

THE CIRCULATION OF THE BONE-MARROW.

By Charles A. Doan,
Anatomical Laboratory of the Johns Hopkins University,

With one plate and three text-figures.

THE CIRCULATION OF THE BONE-MARROW.

In considering the varied functions of the vascular system of the body, attention has been riveted in the past almost solely on the grosser arterio-venous circulation and the observable changes associated with these vessels in health and disease. Only comparatively recently has the tendency to overlook the connecting link between afferent and efferent systems been noticeably changing, and from many different sources there are now various evidences of an awakening realization of the importance of the capillaries, the real structural medium of body nutritive exchange. As has been strikingly stated by a recent writer, the cardio-vascular system exists only to regulate the blood-flow through the capillaries, for here takes place the exchange of gases necessary for internal respiration and the exchange of materials necessary for metabolism.

This failure to devote more direct consideration to the function of the capillaries has probably been due in large part to their unobtrusive and rather obscure existence in the larger functioning unit and to the technical difficulties which observations on these, the smallest vessels of the circulation, involve. Especially has the latter factor operated in reference to the circulation in the marrow of the bone. The methods of direct observation, recently so ingeniously evolved for a study of the capillary circulation in many of the other tissues of the body, are manifestly incapable of application when it comes to a study of the tissues inclosed within a thick, bony shell. Still another factor has hitherto influenced the lack of interest in a careful analysis of the circulation of the marrow, viz, the fascination which investigators have found in attempts to classify and relate the various precursors of the different circulating blood-cell elements known to have their origin and development in the red marrow of the long and flat bones. The result has been a most thorough morphological study of the cells of the marrow. Ehrlich (1891), Pappenheim (1919), Maximow (1909), Bunting (1906), Danchakoff (1908), Dickson (1908), Ferrata (1918), and many others have studied minutely the cytology of the hemopoietic tissues, leaving little to be desired so far as gross morphological description is concerned. There are fundamental points of difference, however, in the theories as to the original or parent cell type or types. This difference of opinion among investigators has led to the formation of two schools—the monophyletic school, with strong adherents in Dominici, Pappenheim, Weidenreich, Maximow, Danchakoff, and Ferrata, and the dualistic or polyphyletic school, supported notably by Ehrlich, Naegeli, Schridde, and Morawitz. Both the monophyletic and the polyphyletic interpretations have arisen out of a study of normal and pathological tissues fixed and stained with identical methods in an identical manner, but by different investigators. From the careful analysis of fixed tissues we have gained much in our understanding of the blood and its formation, but it has become increasingly evident that the problem of the original type or types of parent blood-cells still remains, with a necessity for the development of further methods of attack. Until further progress toward this fundamental comprehension of first principles has been made, by means of studies along different lines of approach than hitherto employed, we shall still be without the basis for a rational therapy.

Within the past two decades exceedingly valuable contributions toward solving the problem of the origin and development of individual types of blood-cells have been made through embryological studies. The most representative work on the embryology of the blood is that carried out by Danchakoff (1908, 1909) and Sabin (1920, 1921) on birds and by Maximow (1909, 1910) on the mammal. Both Maximow and Danchakoff recognized the relationship between endothelium and blood-cells, not only in the stage of the primitive blood-islands but also in somewhat later stages; both have thought, however, that endothelium gives rise only to indifferent blood-cells. Schridde (1907), on the other hand, has described the direct transformation of endothelium into erythroblasts in early human embryos. Maximow believed that although the early erythroblasts of mammalian embryos are intravascular in origin and derived indirectly from endothelium, the ultimate erythroblasts of the adult are a group of cells extra-vascular in origin. This may be said to be the prevailing view to-day. The question has been reopened recently, however, by the work of Sabin (1920, 1921). It was not until she had actually seen, by direct observation on living chick embryos during the second day of incubation, the differentiation of the red cell from early endothelium and later the origin of the monocyte cell-series and clasmatocytes from the same source in chicks of the third and fourth days, that the etiological importance of the endothelium, and hence the significance of the exact pattern of the vessels of the marrow in the mature organism, was fully understood. Thus the whole blood problem receives a new impetus in a different direction. This work places an emphasis upon the importance, not hitherto adequately appreciated, of a more comprehensive and exact knowledge of the endothelial content of adult marrow. It is not a purely morphological standpoint to which the importance attaches now, nor are we interested in it solely as a means by which the blood-cells gain entrance into the circulation. The important question, stimulated by the work of Sabin, is the very suggestive one as to the possible direct relationship between the endothelium of the hemopoietic tissues and the blood-cells of the mature organism.

Obviously, before attempting to determine this relationship, a thoroughly comprehensive understanding of the extent and distribution of the endothelium in the marrow of the long and flat bones is essential. But here again we find in the literature a wide difference of recorded observation on the part of various workers. The views held may be classified into three groups, together with their respective supporters. (1) The earliest observations followed close upon the first recognition of the bone-marrow as a hemopoietic tissue. Hoyer (1869) could detect no endothelial walls in the so-called capillaries or blood-channels in observations on the marrow of injected rabbits. Rindfleisch (1880), using a gelatin injection mass, interpreted the regularly outlined channels in his sections of bone-marrow (very well illustrated in one of his plates) as indicative of tissue spaces filled with blood and limited only by the medullary parenchyma, that is to say, entirely devoid of endothelial lining. This earlier view, however, has been quite clearly shown to have been based upon erroneous observations, and the later conceptions, while being divided by two different interpretations, nevertheless agree on the presence of endothelium-lined blood-vessels as the essential basis of the circulation. (2) Langer (1877) was among the first to advance the opinion that the vascular system of the bone-marrow is a closed system lined throughout with a continuous endothelial layer. Bizzozero (1891), a few years later, after more extensive investigations than had hitherto been made, reported as follows:

> "In the marrow of birds one is able to affirm that the venous capillaries are limited by a thin nucleated membrane, consequently they are not the simple hollow spaces in the tissue of the marrow as so many have maintained."

On the other hand, Bizzozero was not so positive about the circulation in mammals and was rather prone to doubt the completeness everywhere of the vascular walls in mammalian marrow. Denys (1887–1888), also drawing his conclusions from experiments on the bird, concurred in the observation that the vascularization of the marrow is that of a single closed system of vessels lined with endothelium. Again, Van der Stricht (1892) differentiated between avian and mammalian marrows, in the former observing only closed venous capillaries possessing an endothelial wall throughout their extent, in the latter describing non-continuous vascular walls. Minot (1912) questioned the adequacy of proof for the contention that there are direct openings into the parenchyma from the blood-vessels. Schäfer (1912) contented himself with stating that there were two theories, frankly withholding any opinion in the controversy.

Finally, Drinker, Drinker, and Lund (1922), in a recent analysis of a very extensive series of splendidly controlled injections of marrow, state their belief that the "capillaries conducting blood in the bone-marrow of the mammal in a condition of normal blood formation are closed structures lined throughout with endothelium and not in communication with the marrow parenchyma." (This coincides with my own [1922] observations on mammalian marrow.) They further advance a most interesting explanation of the marrow condition during active hyperplasia.

> "Under conditions of active red-blood-cell formation the extremely delicate walls of these capillaries [venus sinusoids] are grown through by irregularly placed red cells in varying stages of maturity. The capillaries are thus, for a period of varying length, open structures, but the opening presented does not result in flooding the marrow parenchyma with blood, because of the packing of the immature blood-cells, which is an essential phase in the process of encroachment upon the capillary wall."

(3) As has been suggested above, the third view is that there is an incomplete endothelial lining to the venus sinuses with openings directly into the parenchyma for the exit of blood plasma and the entrance of mature cells. Weidenreich (1903, 1904), in his researches on the marrow as a hemopoietic organ, found that so-called "cell-nests" constitute the blood-forming tissue, that they are appendages of the venous capillaries, and that the endothelium of the latter is deficient in the region of these "cell-nests." Venzlaff (1911) maintained that erythrocytic differentiation takes place within the venous sinuses of avian marrow from lymphocytes that have passed out of the "Leukoblastershaufen" (the "cell-nests" of Weidenreich), in the

region of which he also believed the endothelium of the sinuses to be lacking. Brinckerhoff and Tyzzer (1902), in studies on the uninjected marrow of rabbits, described places in which the blood-stream is not confined within endothelial walls but wanders through channels in the reticulum and the masses of cells. More recently, Bunting (1919) describes the marrow vascularization as follows:

> "The circulation as revealed by natural injections of the rabbit's marrow is unlike that of any other organ but resembles superficially that of the spleen pulp."[1]

He further states that there is no capillary network and describes slender arterioles originating near the center of the marrow and proceeding, without capillary side branches or anastomoses, to the periphery, where they open directly into wide, thin-walled sinuses.

Desiring to investigate the relationship which endothelium might bear to the supply of red blood-cells in the mature organism, it became necessary to know its distribution at first hand. The interesting results which have attended these studies are presented with the belief that they open up a new field of possibilities, only vaguely hinted at heretofore, but now having a definite basis in anatomical structure.

MATERIALS AND METHOD.

The conclusions reached in this paper are based largely on a series of investigations on about forty adult pigeons. Further experiments of a similar character, conducted on the dog, cat, rabbit, and white rat, seem to substantiate and corroborate the gross findings in the pigeon, so far as I have been able to observe in a limited series. A larger number of observations on mammals will be necessary before a complete report can be made.

An attempt has been made to get complete injections of the vascular system of the bone-marrow. This has not been easy, the difficulties being fourfold: (1) to secure a satisfactory medium for injection, (2) to keep the pigeons alive sufficiently long during the preliminary insertion of the cannula, etc., (3) to secure and maintain just the right pressure for perfusing, and (4) to wash out and inject under conditions as nearly physiological as possible and for the optimum length of time.

It has been found, in general, that pigeons are peculiarly susceptible to chloroform. All operations have been done on anesthetized birds, and a light ether anesthetization has been found entirely satisfactory. It is desirable to have the animal alive during the first stage of the washing-out process.

My most successful injections were made with a pressure of 130 mm. of mercury for both saline and ink. When the pressure was materially increased above this point, rupture and extravasation frequently occurred, whereas with pressures below this level an incomplete injection was apt to result. Both the injection material and the physiological saline were previously warmed to a degree somewhat above body-temperature to insure their reaching the vessels at body-temperature. With a free flow this saline should not be run longer than 8 minutes, preferably a shorter period, judging by the clarity of the venus outflow. The injection mass

---

[1] Mollier (1909) has demonstrated openings into the splenic pulp, *i. e.*, fenestrated vessel-walls.

should be run for about 10 minutes. However, experience only can give one competent judgment in this, as there are many indications, not reducible to writing, which one learns to recognize and be governed by in individual instances. One may get a complete injection of the superficial vessels of the skin and muscle with practically no penetration of the marrow cavities. The optimum condition is to stop as soon as possible after the maximum complete injection of the smallest capillaries of the bone-marrow, which, being manifestly impossible of direct observation, must be a matter of experience.

Several injecting solutions were tried. A silver-nitrate solution permeates the vessel walls and, while outlining the larger vessels quite clearly, masks the smaller capillaries completely. Freshly precipitated carmine, even under the best conditions, forms flocculi too large to be carried into the smallest vessels for a complete injection. The best results were obtained from a freshly filtered solution of one part of Higgins india ink diluted with three parts of physiological saline. Very satisfactory injections, which I feel are relatively complete, were secured with this injection mass under the conditions stated above.

The cannula was placed directly into the heart, into the subclavian artery (making ventral incisions), or into one of the iliacs or the abdominal aorta (with a dorsal incision). This latter procedure was used almost exclusively in the later experiments. The antero-posterior incision was made just to the side of the mid-line; a lateral exposure of the ribs was made and, after removing a section of four ribs, the lung was carefully laid back by blunt dissection, after which the abdominal aorta or common iliac was easily located. The auricle or inferior vena cava was opened for the return-flow outlet. No injections were attempted via the nutrient arteries direct.

After many methods for fixation had been tried, the best results were found to be obtainable by fixing the "marrow pencils" in Helly's fluid at 38° for from 2 to 6 hours and the whole bones in 10 per cent formalin for 24 hours. The former were fixed in the routine manner, dehydrated, cleared, and embedded either in celloidin or paraffin, the celloidin proving better for the study of individual cells when stained. The whole bones were cleared by the Spalteholz (1914) method. As a routine procedure the radius and ulna of one side were fixed and treated for clearing *in situ* and the "marrow-pencils" of the opposite side were taken out and fixed in Helly's fluid for embedding.[2] It is desirable to fix when fresh and to maintain the "marrow-pencils" in as perfect form as possible. With reasonable care the fresh marrow may be removed intact, and, except in rare instances, there are no spicules of bone in the marrow calling for decalcification. Danchakoff's (1908) modification for the mounting of celloidin sections was used in making serial sections.

For staining sections we have used Giemsa's stain, Wright's blood-stain, methylene-blue-eosin, hematoxylin and eosin, and hematoxylin and carmine. The sharpest differentiation was obtained with a slight modification of the ordinary hematoxylin and eosin stain. A two-minute period in a freshly filtered 1 per cent solution of Ehrlich's hematoxylin, diluted one-half, alkalinization in $Ba\ (OH)_2$

---

[2] The humerus in the pigeon contains no blood-forming marrow.

solution, and then counterstaining for 2 to 3 minutes in a 5 per cent aqueous eosin, gave a beautiful contrast to the cellular elements. Dr. Sabin found that the addition of orange G to the eosin increased the effectiveness of this combination in the staining of embryonic blood-cells.

OBSERVATIONS.

In the earlier incomplete injections the gross architecture of the bone-marrow was plainly evident in the cleared specimens. Figure 4 (plate 1) shows the medullary artery entering the marrow cavity near the center of the diaphasis, perforating the compact tissue obliquely. It divides immediately into two main branches which diverge abruptly, one extending toward each epiphysis. These two main arterial trunks in turn divide about a third of the way to the epiphyses and extend from their point of origin to the limits of the marrow at either end, anastomosing with the vessels entering there. Several small arteries were usually seen at the epiphyses, entering the marrow cavity through the bone, anastomosing with the medullary vessels, and helping to furnish the additional blood-supply to the actively functioning red marrow of these regions.

In addition to this main arterial supply there could be seen numerous small vessels entering along the shaft of the bone (fig. 6), primarily to nourish the cancellous and compact tissue, but anastomosing at the periphery with the arterioles of the central vessels. There was frequent and intimate intercommunication along the entire shaft between the nutrient vessels of the Haversian canals and the circumferential end arterioles and venules of the medulla of the bone. These anastomoses formed a very striking picture in cleared specimens and gave a new insight into the delicacy of the vascular interlacings and the extent of their ramifications. We are not dealing with two more or less separate and distinct systems, one to nourish the marrow, the other the cancellous and compact tissues, but with one interdependent and communicating whole. The subject of the vascular supply of the bone-substance itself has been treated in a recent monograph by Foote (1921) in a most admirable manner, with extensive illustrations.

There were three groups of veins in the long bone. (1) The central medullary veins could be seen accompanying the central artery (fig. 4). From one to four parallel veins accompanied the artery and traversed the shaft from each end to unite near the center in a single efferent vein which occupied the nutrient foramen, together with the entering artery. (2) Several large veins emerged near the vascular area of red marrow, always more prominent toward the epiphyses. (3) There were numerous small veins along the diaphysis (fig. 6) which drained the compact tissue and the peripheral area of the marrow and, with the small nutrient arterioles of the shaft, formed the abundant vascular network of the periosteum (not shown in the diagram). This general vascular pattern held for both the radius and the ulna of the pigeon, the individual bones differing only in the number of their central vessels, in direct relation to their relative size, and in the extent of bone-marrow to be supplied. In relatively complete injections, the central vessels could not be seen from the surface, even in the most perfectly cleared specimens, so dense was the network of carbon-filled vessels, as will be shown later.

In figure 6, which shows the next stage of a partially complete injection, the gross picture observed in figure 4 is again illustrated in the cleared specimen with the marrow *in situ.* The central vessels are still visible and smaller branches may be seen coming off at an angle from the main artery and extending toward the circumference. These begin almost at the center of the shaft but become more numerous and dense toward the ends. At each epiphysis there is a veritable spray-like shower of fine vessels which ramify to every part of the marrow and supply the epiphysis as well, but which stop abruptly at the line of cartilage forming the articulation of the joint (fig. 1). The characteristic vessels of embryonic cartilage have disappeared in the mature state.

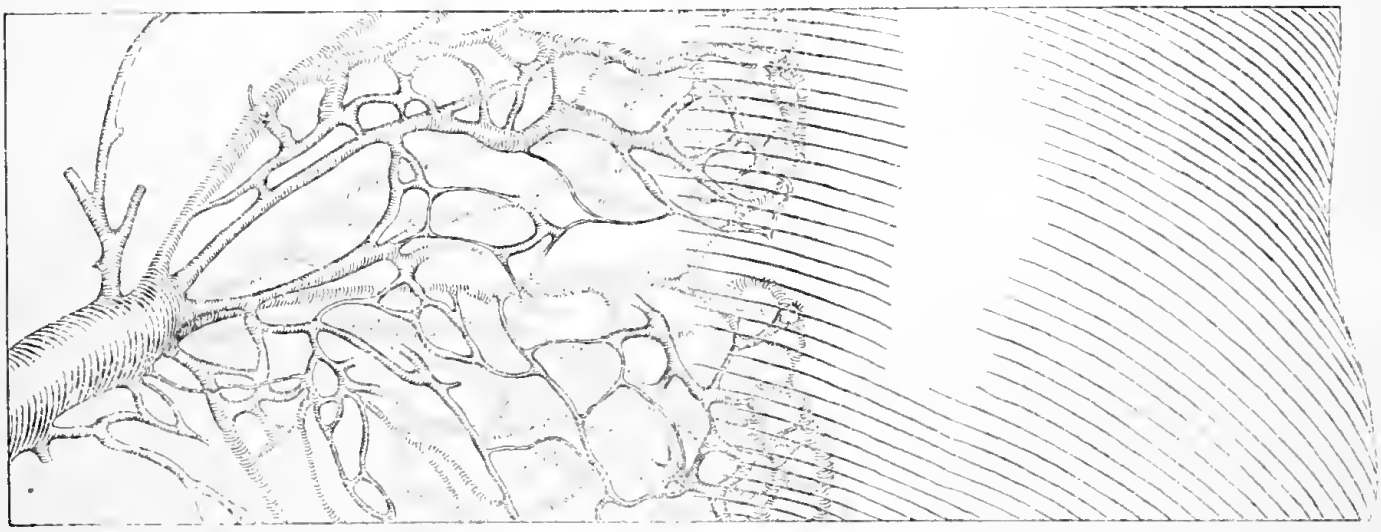

FIG. 1.—A detail drawing of a part of the epiphysial end of specimen shown in figure 4 (plate 1). There is a most extensive ramification of the vessels at the epiphysis, radiation stopping abruptly, however, at the line of cartilage. × 140.

The artery and its branches were easily distinguished from the veins by virtue of their smaller caliber, firmer walls, and less tortuous course; also by the fact that the lumen was more closely packed with particles of carbon. The divisions of the artery were characteristic, the branches came off at an acute angle, and the subdivisions were much less numerous than those of the corresponding veins. The arterioles at the periphery were characteristic in their delicacy, scarcity, and apparently limited distribution.

Figure 6 illustrates very graphically the "tuft-like" character of the venous branchings. Coming off from the central vessel, almost at right angles, are the large distended veins which at once branch outward toward the circumference in an ever-widening balloon-shaped bed, to anastomose eventually with branches from tufts on either side. The large caliber of the vessels is strikingly maintained; and though there is some decrease in the lumen toward the periphery, it is not commensurate with the extent of the branching. The most apparent and striking thing about the entire vascular system of the bone-marrow, both in gross and in microscopic view, is this extensive venous ramification and its very evident capacity for large quantities of blood.

A still better comprehension of these venous and arterial tufts and the means by which they become continuous with each other is obtained from a study of a third more complete injection (sections 100 to 150 micra thick). Figure 5 gives such a picture. In this preparation can be plainly seen what I have termed the "transitional capillaries" leading directly from the arterioles to the venous sinusoids and with apparently very little true arterial capillary bed. This patent capillary link connecting arterioles and venules is extremely circumscribed, and it is not until the venous sinusoidal anastomoses are reached that the blood spreads out in lacing and interlacing vessel tufts, thence to be directed from the tuft-like branchings into larger and larger vessels, eventually to enter the central longitudinal vein almost at right angles or to find egress by way of one of the other venous outlets. It will be seen that the marrow assumes almost the appearance of a segmentally or lobularly divided organ, dependent upon the structural circulatory distribution of these venous tufts, so completely do they ramify in definite areas, yet anastomosing on all sides with the ramifications of bordering tufts. The relationship of the arterial tree to the venous tufts on either side and the capillary transitions from one to the other, even though not extensive, were easily distinguished and were very characteristic in sections of injected marrow. There is little doubt, however, that the extensively distributed, spacious, thin-walled venous sinusoids form normally the principal functioning vascular bed for the actively circulating blood in the marrow; *i. e.*, they correspond largely to the capillaries of other organs. These are the vessels that have been seen and described as the fundamental units of the bone-marrow by those who have worked in this field; and, while being the most outstanding structures in injected marrow, by virtue of their caliber they are quite as easily seen and followed in the uninjected state. By most writers they are termed the *venous capillaries.* It would seem that *venous sinus* or *venous sinusoid* might be more appropriate and desirable terminology, inasmuch as there are already two types of true capillaries in the marrow, as recognized and interpreted in these observations.

All of the vessels thus far described were plainly apparent, either grossly or with the aid of the binocular microscope. The analysis of the circulation up to this point had been comparatively simple through the study of injected material; when an attempt was made, however, to study, under an oil-immersion lens, the detailed ramifications of the smaller vessels and the extent and continuity of the individual endothelial cell distribution, difficulties were at once encountered. It was found that analysis of these finer points in normal marrow is extremely unsatisfactory, if not quite impracticable. In order to analyze with any certainty the finer ramifications of the vascular pattern, *i. e.*, the cytological relationships, it is essential, in the first instance at least, to have a marrow depleted as far as possible of all the free cells. An attempt was therefore made to produce experimentally a hypoplastic bone-marrow in the pigeon. The desired condition was secured through simple starvation for periods varying from 10 to 18 days.

PROTOCOL, PIGEON 19 A.

January 29. Pigeon in excellent condition, weight 475 grams. Diet restricted to fresh water every morning. Condition remained excellent up to February 7. February 10, condition good. February 15, pigeon in fair condition but emaciated; weight 340 grams. Operation same date.

3.15 p.m., ether anesthetization; posterior incision, cannula inserted. 3.25 p.m., warm physiological salt solution started at 130 mm. Hg. 3.31 p.m., salt stopped. 3.32 p.m., warm india-ink (1-4) at 85 mm. Hg. 3.39 p.m., ink stopped.

One radius and ulna fixed in 10 per cent formalin and cleared. Marrow from opposite radius and ulna fixed in Helly's fluid (Zenker-formol). Imbedded and cut in serial sections.

In such an experimentally produced hypoplastic marrow (fig. 2) three types of cells were observed, fat-cells, reticular cells, and endothelial cells. In order to analyze the relations of these three cell-types the vessels of the marrow were washed out with physiological salt-solution and then injected with india ink. The fat-cells, together with their nuclei, were readily distinguishable and quite characteristic. They were more numerous in the hypoplastic marrow, having apparently replaced to a large extent the depleted cellular areas. In the fixed tissue these cells appeared as empty spaces, limited by a thin but distinct membrane. Each contained a more or less flattened oval nucleus, eccentrically placed and but faintly stained, owing to the small amount of chromatin. Such cells made an easily discernible network. Frozen sections of the fresh tissue, stained with Sudan III, indicated the increased extent of these deposits of fat in the cytologically depleted marrow.

Reticular elements which conformed to all of the known criteria were to be seen. They were large pentagonal or hexagonal cells with large, round, vesicular nuclei; the cytoplasm took a faint eosin stain, the nuclei showed moderate chromatin content.

The endothelial cells, in the main, conformed to certain standards and were recognized through various characteristics. In the areas where the endothelium could be seen lining the venules and the capillaries connecting them with arterioles there was no difficulty in its identification; but there were capillaries in the bone-marrow where, even after taking all the histological characteristics of endothelium into consideration, certain cells could not be definitely classified. This was especially true in normal uninjected marrow. Unfortunately, a specific stain for identifying endothelium in sections has not been developed up to the present time, and such characteristics as size, morphology, and peculiarities of the nuclei are not always adequate criteria. The methods developed by McJunkin (1919), Foot (1921), Wislocki (1921), and others, dependent on the specific phagocytic function of endothelium for various colloidal suspensions and vital dyes, were all tried in the bone-marrow with indifferent success, but it is possible that additional experiments, now being carried out, will give us at least some valuable leads in further finer differential data applicable to the problem. It must not be forgotten, however, that such methods depend upon direct contact between the phagocytizable particles and the endothelial cell; therefore, assuming that the capillaries described below are probably normally non-patent to the circulating blood, we still have left the need for further means of differentiating endothelium. Realizing fully, then, the limitations of our present methods and the difficulties for final determination in the case of a certain few individual cells, I have tried to analyze the picture presented by these injections on the basis of data available at this time for their interpretation.

As stated in a preliminary communication (Doan, 1922), it is not until sections as thin as 5 micra (fig. 2), from a relatively complete injection of a hypoplastic marrow, are seen under an oil-immersion lens that the full import of the nature and extent of the bone-marrow circulation begins to be realized and perhaps partially understood. First of all, the gross structures—the main longitudinal vessels, transverse smaller branches, arterioles, a few transition capillaries, and the venous sinusoids described above—were easily verified in the serial sections. But in addition to these I have found, appearing between the fat spaces in well-outlined and clearly defined channels, a most extensive system of capillaries, hitherto unsuspected. Many of these capillaries appeared to have been non-patent and functionally dormant so far as the active blood circulation is concerned. This was borne out by the difficulty and infrequency of their demonstration in the ordinary marrow injections, where they were totally collapsed and could be seen only as septa surrounding the fat-cell spaces.

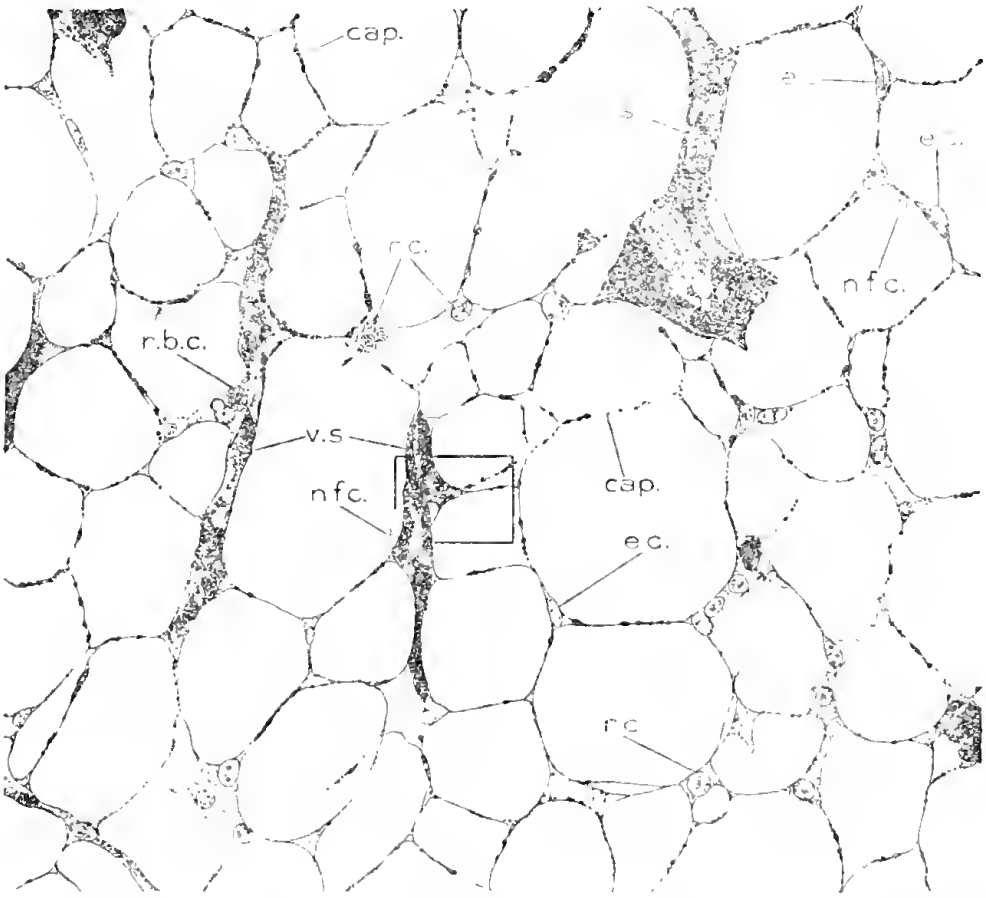

Fig. 2.—Drawing of a hypoplastic marrow, injected with india ink, showing venous sinusoid and intersinusoidal capillaries. From the radius of an adult pigeon (19 A). *e. c.*, endothelial cells lining capillaries, *r.* c., reticular cells of the marrow; *n. f.* c., nuclei of fat-cells; *r. b.* c., red blood-cells; *v. s.*, venous sinusoids; *cap.*, intersinusoidal capillaries surrounding the fat-cells, with the granules of carbon of the injection fluid scattered throughout the extent of their channels. These capillaries are seen to be in direct communication with the large venous sinusoids via the characteristic conical openings. Hematoxylin and eosin; 5μ×700.

Figure 2 shows these extensively ramifying channels to be semi-collapsed. Only a trace of fine ink-granules reveals the presence of a potential lumen, the caliber of which appears insufficient for the passage of even a single blood-cell without difficulty. Toward the epiphyses there is this complete encircling of each fat-space by these minute vessels. They are seen to lead directly from the large venous sinusoids by way of typical conical openings and appear to be continuous with them. This is illustrated in figure 3, which is an enlarged drawing of the portion of figure 2 indicated by the square. These vessels are not capillaries, in the sense of an arterio-venous transition, but extend from venous channel to venous channel; they are intersinusoidal. There is no break in the continuity of the endothelium which forms these slender channels from sinusoid to sinusoid. There was no extravasation at any point and the material injected followed these vessels everywhere. It was quite evident that these channels were closed, in the sense that there was no extravasation or diffuse permeation of the tissues by the injected ink.

The attempt to differentiate an extravasation from a true circumscribed distribution of perfused particles within definite channels was not made without a full appreciation of the marked tendency of such granules to follow a reticular framework closely in any injection into diffuse connective tissue. This characteristic of reticular tissues to be outlined by extravasated particles, thus simulating, more or less closely, definite channels, is recognized and acknowledged, and it is obvious that the possibility of error of interpretation in injections of mesenchymatous tissue requires a corresponding amount of attention and care in analysis.

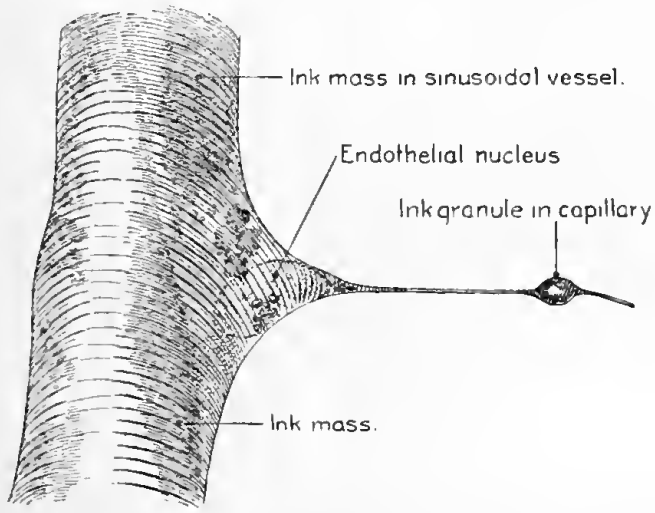

Fig. 3.—A detail drawing of one of the typical conical openings from a venous sinusoid into the semi-collapsed lumen of an intersinusoidal capillary; indicated by insert in figure 2.

There were, however, five points apparent in the interpretation of these studies which emphasize strongly the non-fenestrated character of the vascular bed of the bone-marrow. (1) In injections showing a diffuse permeation of the medullary parenchyma there have been demonstrable ruptures in vessel walls. (2) In extravasation it was clear that the extruded granules were neither phagocytized nor regularly distributed along one side, but adhered promiscuously and heterogeneously to the surface of the parenchymal cells, thus more or less concealing their outline. In contrast to this, the particles within a definite lumen were scattered here and there along the sides of the lining cells on the inside of the channel only. (3) In an analysis of comparatively complete injections, showing this extensive, inter-sinusoidal capillary bed, not only could these channels be distinctly followed by the granules of ink, but the reticular network or framework of the medullary parenchyma could be seen in the same areas without any attached granules of ink. (4) The walls of the veins and venules appeared as continuous endothelium-lined channels, similar in appearance to the vascular bed elsewhere in the body, but with conical openings into the tiny capillary network. (5) Finally, I have obtained relatively complete injections of these very fine, extensive, lace-like vessels without the slightest evidence of any of the injected particles outside the closed channels in the parenchyma. In other words, in the adult bone-marrow here studied, there was no evidence of any fenestrated vessel-wall, similar to that described by Mollier (1909) for the spleen. One need only contrast a true extravasation with one of these injections to recognize the difference at once. It is very possible, however, that in an injection of normal bone-marrow that filled only arterioles, transition capillaries, and venous sinusoids these conical capillary projections might be interpreted as fenestrated openings.

The endothelial cells of the inter-sinusoidal capillaries were thinned out, in contrast to their number and arrangement in a larger vessel, and in many instances had been forced apparently into the interstices between encroaching fat-cells and looked more nearly like primitive embryonic endothelium. They could, nevertheless, be seen to line these spaces through which granules of the injected fluid had been forced. The picture then was that of a very extensive capillary bed which simulated, in the appearance, distribution, and arrangement of its vessels and cell elements, an embryonic plexus rather than the ordinary mature capillary plexuses elsewhere recognized in the adult. This plexus was lined everywhere by intact endothelium.

It may now be possible to bring out, clearly and definitely, the really striking contrast between the type of circulation to be found in the spleen and that inherent in the bone-marrow. There has been, in the past, a tendency to draw analogies between the two circulations. This, we feel, is quite unjustified, both from the standpoint of the function and from the very different nature of the two structures. Mall (1902, 1903) showed, in a final and crucial experiment, that the spleen was adapted to an easy, rapid, and complete emptying of its blood-content at any given moment. He tied all of the splenic veins in a dog, under ether, and let the arteries fill the spleen with blood to its maximum distention; he then cut the ligatures from the veins and watched the speedy contraction of the organ, and proved by frozen sections that the pulp, which had been engorged with red cells, became totally empty in a few seconds. This could be possible only in case the entire splenic pulp were to be regarded as a peculiar capillary bed in very free communication with its efferent veins. The demonstration of the fenestrated endothelial lining of the veins of the splenic pulp by Mollier (1909) completed the understanding of this special type of circulation. The well-known bands of smooth muscle in the trabeculæ are accessory structures peculiar to this system. The spleen is therefore a contractile organ, capable of emptying itself at intervals, and thus providing a means of propelling the whole blood, which has free access to the interstitial tissues, back into and through the general circulation. In contrast to this, the venous sinuses of the bone-marrow have an intact endothelial wall; the intersinusoidal capillaries are discrete and are perhaps never, or almost never, in the direct line of the circulation. Furthermore, the organ is inclosed within rigid bony confines, frequently with bony trabeculæ subdividing the marrow-substance, a condition as far as possible from that found in the contractile spleen. The spleen and the bone-marrow are unlike both structurally and physiologically, and without any real basis for analogical comparison. C. K. Drinker, in association with K. R. Drinker and C. C. Lund, to whose work reference has already been made, attempts to explain the circulation of the bone-marrow in relation to its physiological function. He has found that no experimentally induced increase of pressure will cause an increased discharge of cellular elements from the marrow into the general circulation. He has been unable by any physiological method to "wash out" the developing cells of the marrow. The red cells are delivered into the circulation in cycles at varying intervals, independent of circulatory influences. The areas of developing red cells, as seen in the bone-marrow, show all the cells in a given area to be in the same phase. Drinker hypothesizes a "growth pressure" delivery of these blood elements into the general circulation after first having "grown through" the extremely delicate walls of the sinusoids. This process occurs periodically and without any definitely demonstrable relation to the blood-pressure or circulation and obviously without the possibility of any inherent expansile-contractile mechanism.

In injections of the white rat, the marrow (of the ribs particularly) showed the same gross vascular arrangement as that described for the long bones of the pigeon. There were two central vessels with transverse branchings giving rise to an extensive plexus toward the circumference. In a few experiments on the rabbit, cat, and dog, the normal marrow of both the radius and ulna showed the same general characteristics, though in an apparently less extensive degree throughout the shaft. An occasional section from the mammalian tissues presented here and there the typical inter-sinusoidal, semi-collapsed type of channel, with a few fine ink granules marking its existence. Drinker and his coworkers find these same indications in their most carefully controlled mammalian injections. One of their figures shows a single inter-sinusoidal lumen, as identified by a perceptible line of fine ink granules, identical in appearance with the channels we have seen so much more extensively distributed in the pigeon. While the primary purpose for inducing a hypoplasia of the pigeon's marrow was that more accurate cytological relationships might be determined, it may be, as Dr. Drinker has suggested, that the hypoplastic marrow, through an increased fluidity supplanting the depleted cellular areas, has provided the optimum conditions for demonstration by injection of this otherwise non-demonstrably patent or occult system. In other words, the normal incompressibility of the marrow-tissue within its bony cavity may be altered. If such be the case, a similar condition of induced hypoplasia in the mammal must precede the demonstration of the completeness of the analogy between the vascularization of avian and that of mammalian marrow. This is a problem in itself, inasmuch as simple starvation of the mammal will not produce the hypoplasia desired.

DISCUSSION.

The question that immediately presents itself is that of the function of this vast bed of endothelium extending throughout the bone-marrow, which, as far as can be determined, does not function as a channel for the active circulating blood-stream, at least not normally and regularly. In the absence of full experimental evidence, it is natural and helpful for one to reason by analogy in an attempt to secure working hypotheses in explanation of the phenomena not at present fully understood. This is not without full comprehension of the very great difficulty of following such a line of reasoning without the possibility of grave error.

Richards (1922) has recently reported observations on the glomerular activity in the frog's kidney. He believes that the majority of the glomerular capillaries are not continuously functioning actively, but that there are intervals during which the individual glomerular capillary is closed to the main blood-current. It is possible that could the hemopoietic tissues be examined directly and as satisfactorily as has been done in the case of the frog's kidney by Richards, a similar phenomenon in the marrow capillaries would be found.

Krogh (1918, 1919) has published some most illuminating observations on the capillary circulation in the muscle of the frog and guinea-pig. He finds that in resting muscle most of the capillaries are in a state of contraction and closed to the passage of blood. It was impossible to inject, even under high pressures, any but the few functioning capillaries that were patent at the moment; but by tetanic stimulation, with gentle massage, or in spontaneously contracting muscles a large number of capillaries were opened up and were subsequently observed to contract again. He found the average diameter of open capillaries in resting muscle to be much less than the dimensions of the red corpuscles which become greatly deformed during their passage. Finally, he has shown and called attention to the important fact that clinical hyperæmia and anæmia are due mainly to changes in the caliber and number of open capillaries, and that the capillaries are not merely passively dilated by blood pressure but are controlled by a "capillario-motor system" independent of the "arteriomotor system."

It was only through ingenious pressure injections that capillary channels, long suspected but often denied, were finally demonstrated in the valves of the heart by Bayne-Jones (1917). It is conceivable that under certain physiological conditions they may be more obviously patent. Rich (1921), in experiments on the omentum, has shown, both by induced inflammation and by histamin injection, a capillary bed much increased over that seen in the normal omentum, demonstrating the large number of ordinarily non-patent, occult vessels capable of responding and functioning protectively when occasion demands. Lee (1922), in some investigations on lymphatic circulation following the ligation of the thoracic duct, described a most interesting phenomenon. Within 10 days after the careful complete ligation of the thoracic duct he found a most extensive anastamotic distribution of fine lymphatic vessels spreading out along the wall of the aorta, and eventually (within two weeks) a completely compensated, equilibrated lymphatic circulation was established. It seems probable that these may be preexisting collapsed channels which become functionally patent under the stimulus of the new conditions. In view of what we know of the capillaries elsewhere, may it not be that, under excessive demand for blood-cells, when we recognize grossly an increased activity and vascularity of the marrow (red marrow versus yellow marrow), these otherwise collapsed capillary channels become patent and function to help meet the crisis? They may thus be a very important unit of the defensive mechanism of the body. Drinker and his associates were unable, however, to demonstrate satisfactorily these accessory channels in the mammal following the return of the blood-volume to normal after a large hemorrhage, when it might be expected that all possible avenues of delivery for cellular elements would be functioning.

On the other hand, in view of Sabin's (1920, 1921) derivation of red blood-cells, clasmatocytes, and monocytes in the chick embryo from endothelium, there remains still another possible function for the marrow-capillaries, or rather the endothelium of the marrow-capillary. It will be remembered that the endothelium of these capillaries is embryonic in appearance. In hyperplastic marrow injections, Drinker has described the disappearance of a detectable endothelial lining to the vessels and ascribes the lack of extravasation of injection granules, even with these apparently open vessel walls, to the close packing together of the developing cells, which he believes grow into and through the yielding endothelium. If the red cells were formed intravascularly in an extra-circulatory capillary bed with embryonic endothelium as their source, the apparent cellular border described by Drinker might be these developing cells inside a greatly distended capillary, with wall so stretched and endothelial cells so altered by rapid proliferation as to be unrecognizable as such. The fact that there is no parenchymal diffusion with injections, even though the wall appears to be patent, would seem to suggest this. After saponin injection, Drinker and his collaborators noted the appearance of nucleated red cells in the peripheral circulation prior to an increase in the leucocyte count. They ascribe this to the fact that the developing red cells are in "closer proximity to the circulating blood." This would be literally true were their development assuredly intravascular. Even though the extravascular origin of the erythrocytes in the adult mammal is practically universally accepted to-day, Drinker, it would seem, has more nearly sensed the only justifiable attitude tenable at the present time when he states: "Red cells are apparently formed outside the blood-stream and enter the moving current as a result of growth pressure. It will be noticed that we have not declared for the extravascular origin of the erythrocytes, but have simply said that they arise outside the blood stream." In our present state of knowledge this is all that can be said.

Finally, there is the possibility that these strands of endothelium are never opened up to the circulation as such in the bone-marrow, but represent filaments of cells, like the angioblastic chains described by Sabin (1920) in the embryo, which, in repeated cycles, multiply and make new generations of red corpuscles, the pre-existing cone-shaped openings into the sinusoids marking the avenue of entrance for the cells into the blood-stream. Such an interpretation would explain the discrepancies in connection with the relation of endothelium to the formation of the red corpuscles and thus harmonize the two divergent ideas of the intra-vascular versus the extra-vascular origin of erythrocytes. Under such a view the red cells could be considered as coming from endothelium, but endothelium so placed that the new red cells would not be in the active current of the blood as actually within the sinuses. The cells would, nevertheless, be so placed with reference to the sinuses as to gain a ready access to the functioning lumen without calling for any special destruction of the wall of the sinusoid.

Cunningham (1922), in his study of the cellular reactions during the production of exudates in the peritoneal cavity, obtains no evidence either for or against the participation of the endothelium of the neighboring capillaries of mesentery and omentum in the formation of exudative cells. He points out the difficulty of differentiating reticulum and endothelium in spleen and lymph-glands of the adult mammal when attempting to determine which of these cells is progenitor of the circulating mononuclear. However, certain observations have led him to "suggest the hypothesis that if the circulation be cut off from a group of capillaries, the endothelial cells of which still obtain sufficient nourishment to prevent cell death [the condition that probably exists in the bone-marrow normally], these cells may undergo a cataplastic reversion to the syncytial angioblastic or embryonic endothelial type, with subsequent differentiation into clasmatocytes." Sabin (1921) has proved conclusively the endothelial origin of the clasmatocyte in the embryo. Furthermore, the work of Macklin and Macklin (1920), who found that areas of endothelium in new-formed capillaries appear to become transformed into clasmatocytes, and the work of others along similar lines, make it practically certain that the protean possibilities of endothelial differentiation in various parts of the functioning mature organism are only beginning to be appreciated.

The mere knowledge and recognition of the presence of this extensive distribution of endothelium in bone-marrow not regularly functioning as a blood-channel is a step in the direction of the determination of its relation to the blood-cell production of the marrow and at least a presumptive indication for further studies, with this possible specific relationship as an objective hypothesis.

This investigation is the direct outcome of Dr. F. R. Sabin's work on the origin of blood-cells in the chick embryo and was undertaken at her instigation. Throughout the development and interpretation of the reported findings, her constant help and criticism have been indispensable. It is a pleasure to express also my gratitude to Dr. R. S. Cunningham for his advice and many helpful suggestions, and to Mr. James F. Didusch for the excellent illustrations accompanying the text.

SUMMARY.

(1) The arterial supply of the bone-marrow is secured via the medullary artery, the periosteal vessels along the shaft, and some vessels near the articular extremities which supply the epiphyses as well. The arterioles are relatively few in number.

(2) Normally there are a few "transition capillaries" functioning as the intermediary communication between arterioles and venous sinusoids.

(3) The very extensive distribution of large-lumened, thin-walled venous sinusoids, probably forming the real, active, functioning vascular bed of the marrow, is the most characteristic thing about the gross circulation in bone-marrow. The venous drainage is threefold, corresponding to that of the arterial supply.

(4) A hypoplastic marrow is essential for the analysis of the finer distribution of the blood-channels. In such a marrow can be seen a very extensive intersinusoidal capillary plexus, hitherto unsuspected, its normal state being possibly one of collapse.

(5) The vascular system of the bone-marrow is a closed system, no fenestrated vessel-walls being demonstrable in this series of experiments.

(6) Endothelium apparently forms a continuous lining throughout the vascular ramifications in the marrow, being therefore much more extensively distributed through the medium of the widespread capillary plexus than has been indicated in the usual marrow injections heretofore described.

(7) The splenic and marrow circulations are contrasted, with a view to showing the fallacy of an analogous comparison of the two.

(8) The possible significance of the endothelial distribution and occult capillary system of the marrow is discussed.

BIBLIOGRAPHY.

BAYNE-JONES, STANHOPE, 1917. The blood-vessels of the heart valves. Amer. Jour. Anat., vol. 21, pp. 449–462.

BIZZOZERO, G., 1891. Nouvelle recherches sur la structure de la moelles des os chez les oiseaux. Arch. Ital. de Biol., vol. 14, p. 294.

BRINCKERHOFF, W. R., and E. E. TYZZER, 1902. On amphophile leucocytogenesis in the rabbit. Jour. Med. Res., vol. 8, pp. 449–495.

BUNTING, C. H., 1906. Experimental anæmias in the rabbit. Jour. Exp. Med., vol. 8, pp. 625–646.

——— 1919. The regulation of the red blood-cell supply. Contributions to Medical and Biological Research, dedicated to Sir William Osler. Paul B. Hoeber, vol. 2, pp. 824–828.

CUNNINGHAM, R. S., 1922. On the origin of free cells of serous exudates. Amer. Jour. Physiol., vol. 59.

DANCHAKOFF, W., 1908. Untersuchungen über die Entwicklung des Blutes und Bindegewebes bei den Vögeln. Anat. Hefte., vol. 37, pp. 473–589.

——— 1908. Zur Herstellung der Celloïdinserien. Ztschr. f. wissensch. Mikr., vol. 25, pp. 32–37.

——— 1909. Untersuchungen über die Entwicklung von Blut und Bindegewebe bei Vögeln. Das lockere Bindegewebe des Hünhchens im fetalen leben. Arch. f. mikr. Anat., vol. 73, pp. 117–181.

DENYS, J., 1888. La structure de la moelle des os et la genèse du sang chez les oiseaux. La Cellule, Lierre and Louvain, vol. 2, p. 241.

DICKSON, W. E. C., 1908. The Bone Marrow. Longmans, Green and Co.

DOAN, C. A., 1922. The capillaries of the bone-marrow of the adult pigeon. Johns Hopkins Hosp. Bull., vol. 33, pp. 222–226.

DRINKER, C. K., K. R. DRINKER, and C. C. LUNN, 1922. The circulation in the mammalian bone-marrow, etc. Amer. Jour. Physiol., vol. 62, pp. 1–92.

EHRLICH, PAUL, 1891. Farbenanalytische Untersuchungen zur Histologie und Klinik des Blutes. August Hirschwald.

FERRATA, ADOLFO, 1918. Le Emopatie, vol. 1. Milano.

FOOT, N. C., 1921. Studies on endothelial reactions. Jour. Exper. Med., vol. 33, p. 271.

FOOTE, J. S., 1921. The circulatory system in the bone. Smithsonian Misc. Coll., vol. 72, No. 10.

HOYER, H., 1869. Zur Histologie der capillaren Venen in der Milz. Anat. Anz., vol. 17, pp. 490–497.

KROGH, AUGUST, 1918–1919. The supply of oxygen to the tissues and the regulation of the capillary circulation. Jour. Physiol., vol. 52, p. 457.

LANGER, K., 1877. Ueber die Blutgefässe der Knochen der Schädeldaches und der harten Hirnhaut. Denkschr. d. k. Akad. d. Wissensch. Math. naturw. Klasse, Wien, vol. 37, pp. 217–240.

LEE, F. C., 1922. The establishment of collateral circulation following ligation of the thoracic duct. Johns Hopkins Hosp. Bull., vol. 33, pp. 21–31.

MACKLIN, C. C., and M. T. MACKLIN, 1920. A study of brain repair in the rat by the use of trypan blue. Arch. Neurol. and Psychiatry, vol. 3, p. 353.

MALL, F. P., 1902–03. On the circulation through the pulp of the dog's spleen. Amer. Jour. Anat., vol. 2, pp. 315–332.

MAXIMOW, A., 1909. Untersuchungen über Blut und Bindegewebe. I. Die frühesten Entwicklungsstadien der Blut- und Bindegewebszellen beim Saugetierembryo, bis zum Anfang der Blutbildung in der Leber. Arch. f. mikr. Anat., vol. 73, pp. 444–561.

——— 1910. Untersuchungen über Blut und Bindegewebe. III. Die embryonale Histogenese des Knochenmarks der Säugetiere. Arch. f. mikr. Anat., vol. 76, pp. 1–113.

McJUNKIN, F. A., 1919. The origin of the phagocytic mononuclear cells of the peripheral blood. Amer. Jour. Anat., vol. 25, p. 27.

MINOT, C. S., 1912. Development of the blood. Manual of Human Embryology (Keibel and Mall), 1912, vol. 2, Philadelphia. (Handbuch d. Entwicklungsmesch. d. Menschen (Keibel and Mall), vol. 2, 1911).

Mollier, S., 1909. Ueber den Bau der Milz. Sitzngsb. d. Gesellsch. f Morphol. u. Phsyiol. in München.

——— 1911. Die Blutbildung in der embryonalen Leber des Menschen und der Saugetiere. Arch. f. mikr. Anat., vol. 74, pp. 474–524.

Pappenheim, Arthur, 1919. Morphologische Hämatologie. Band 1. Included in vol. 23 of Folia hæmatol.

Rich, A. R., 1921. Condition of the capillaries in histamine shock. Jour. Exper. Med., vol. 33, pp. 287–298.

Richards, A. N., 1922. Kidney function. Amer. Jour. Med. Sci., vol. 163, pp. 1–19.

Rindfleisch, G. E., 1880. Ueber Knockenmark und Blutbildung. Arch. f. mikr. Anat., vol. 17, pp. 1–11; also pp. 21–42.

Sabin, F. R., 1920. Studies on the origin of blood-vessels and of red blood-corpuscles as seen in the living blastoderm of chicks during the second day of incubation. Contributions to Embryology, vol. 9, pp. 213–262, A Memorial to Franklin Paine Mall, Carnegie Inst. Wash. Pub. 272.

——— 1921. Studies on blood. The vitally stainable granules as a specific criteria for erythroblasts and the differentiation of the three strains of the white blood-cells as seen in the living chick's yolk sac. Johns Hopkins Hosp. Bull., vol. 32, pp. 314–321.

Schäfer, E. A., 1912. Quain's Anatomy. Vol. 2, pt. 1, p. 154.

Schridde, H., 1907. Die Entstehung der ersten embryonalen Blutzellen des Menschen. Verhandl. d. deutsch. path. Gesellsch., Dresden, 1907; Jena, 1908, vol. 12, pp. 360–366.

Spalteholz, W., 1914. Ueber das Durchsichtigmachen von menschlichen und tierischen Präparaten. 2nd edition. S. Hirzel, Leipzig.

Van der Stricht, O., 1892. Nouvelles recherches sur la genèse des globules rouges et des globules blancs du sang. Arch. de Biol., vol. 12, p. 199–344.

Venzlaff, W., 1911. Über Genesis und Morphologie der roten Blutkörperchen der Vögel. Arch. f. mikr. Anat., vol. 77, pp. 377–431.

Weidenreich, F., 1903–1904. Die rotem Blutkörperchen. Ergebn. der Anat. u. Entwicklungsgesch., vols. 13 u. 14.

Wislocki, G. B., 1921. Experimental observations on bone-marrow. Johns Hopkins Hosp. Bull., vol. 32, pp. 132–134.

DESCRIPTION OF PLATE.

Fig. 4. Distal half of radius, pigeon 16 A_2, injected with india-ink (dilution 1–4). Marrow cleared *in situ* by the Spalteholz method. Injection very incomplete. The nutrient artery and efferent vein are seen occupying the nutrient foramen. The longitudinal distribution of the main vessels is seen. Near the epiphysis one small artery enters the marrow cavity while several small veins emerge. There is extensive anastomosis between the medullary vessels and these extra-diaphaseal vessels. There is an indication of the venous-tuft distribution seen more distinctly in the other figures. ×10.

Fig. 5. Radius from pigeon 35 A, the marrow having been embedded and sectioned serially, 150 μ. The central longitudinal vein is shown with two main venous tufts anastomosing. A branch of the longitudinal artery connects with the venous tufts by way of the "transition-capillary" link. These vessels function normally and, though few in number, appear to be the regular avenues for the passage of blood from the arterial to the venous side. ×110.

Fig. 6. Portion of radius of pigeon 36 A, cleared with marrow *in situ*, showing a more extensive injection than figure 4. The venous and arterial tufts suggest a segmental distribution. The nutrient vessels of the bony cortex are seen extending into and anastomosing with the medullary vessels. ×26.

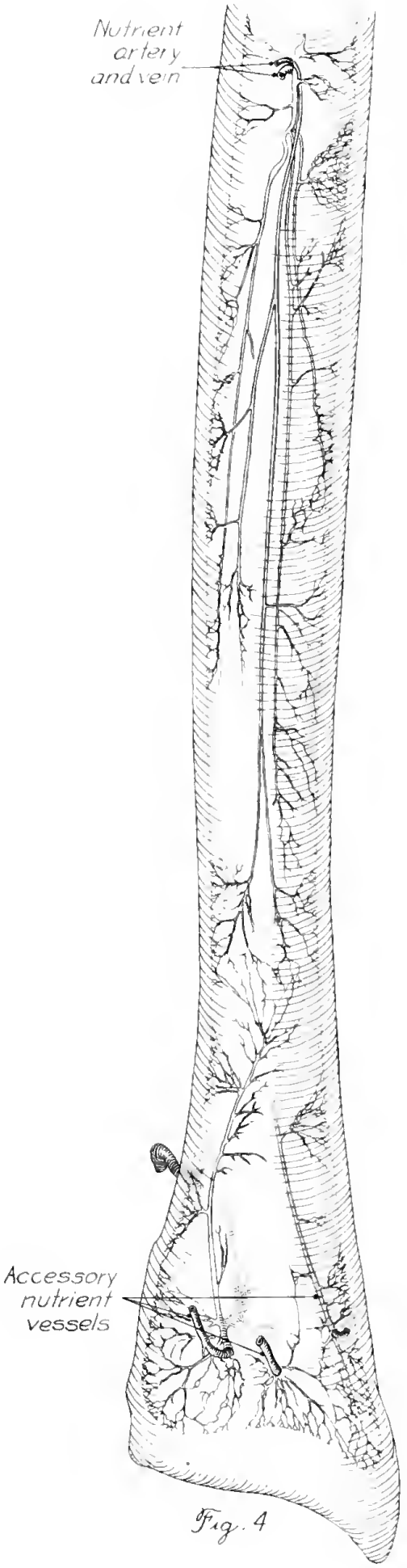

Fig. 4

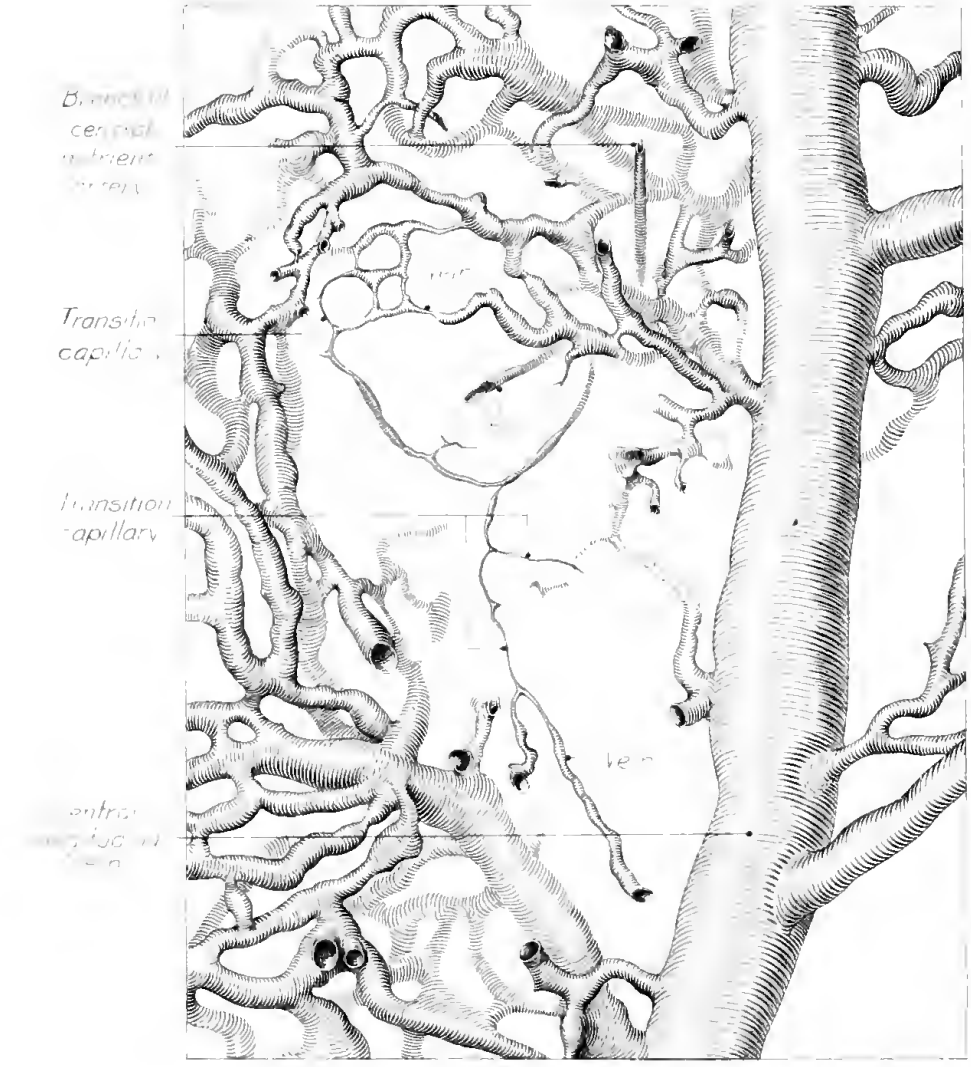

Fig. 5

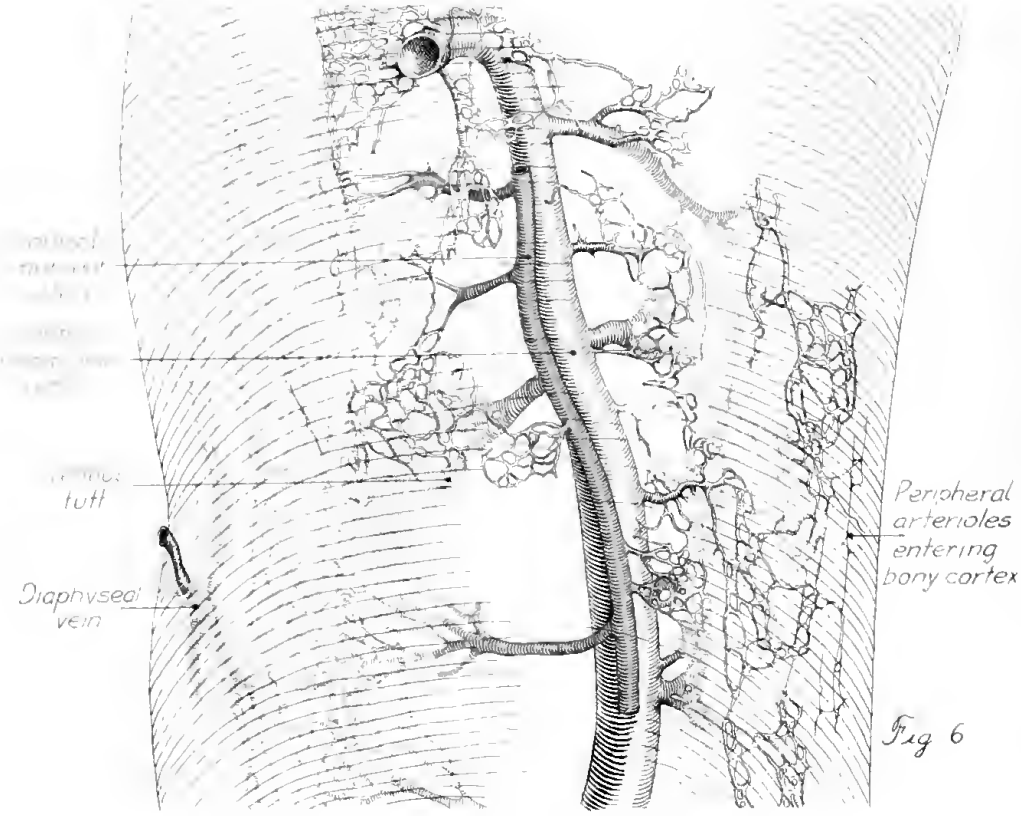

Fig 6

J. F. Didusch fec.

A. Hoen & Co. Lith.

CONTRIBUTIONS TO EMBRYOLOGY, No. 68.

TRANSFORMATION OF THE AORTIC-ARCH SYSTEM DURING THE DEVELOPMENT OF THE HUMAN EMBRYO.

By E. D. Congdon,

Division of Anatomy, Leland Stanford Junior University,
and the Department of Embryology, Carnegie Institution of Washington.

With three plates and twenty-eight text-figures.

CONTENTS.

TRANSFORMATION OF THE AORTIC-ARCH SYSTEM DURING THE DEVELOPMENT OF THE HUMAN EMBRYO.

INTRODUCTION.

It has been the experience of embryologists that the more carefully the anatomy of the mammalian embryo is studied the more apparent it becomes that the various structures of the body do not in any complete sense recapitulate their phylogenetic history. The form which the recapitulation assumes is by no means precise, since it is much foreshortened and distorted. Because it is so strikingly suggestive of the organization of a gill-bearing ancestor, the system of aortic arches has constituted a favorite illustration for the recapitulation theory; and although it has become evident, through the work of Tandler and others, that these vessels fall far short of repeating their ancestral history, nevertheless all descriptions of their development have been dominated by this theory, and the reader carries away in his memory schemata taken bodily from the branchial-arch system of the anamniotes.

A natural accompaniment to a belief in strict recapitulation was the conception of Rathke (1843) as to the nature of arterial developmental changes. He represented the transformations in the aortic-arch system as being the result of the dropping out of certain definitely fixed segments, as though the system were made up of hard and fast units existing of and for themselves. His well-known diagram has perhaps done more harm than good by forcing implications as to the manner of arterial development that are incongruous with what one actually finds in the mammalian embryo. He left out of account the formative influence of one developing organ upon another, which we are gradually coming to recognize as a factor of great importance. It is being repeatedly demonstrated that the vascular system is especially responsive to the conditions of its environment. A more striking illustration of the influence of adjacent structures could scarcely be found than occurs in the aortic-arch system. During the time that the pharynx, with its pouches, is interposed between the heart and the dorsal aorta, the channels of the arterial blood-stream, in form and position, reflect its relief; but as the pharynx changes its form and the heart descends into the thorax, a new environment is created, which brings about a complete alteration in the branchial pattern and the development of an entirely new arterial arrangement. No precise method of nomenclature for the developing arteries has as yet been evolved. There is lack of precision in using the name given to the adult vessel for the series of short stages of increasing completeness which precede the definitive vessel. The term *primitive* may be used to call attention to the incompleteness, but frequently, as in the case of the right subclavian, several successive terms would be warranted.

In this study the successive changes in the arch system and the arteries that evolve from it have been followed through human embryos ranging in length from 1.3 to 24 mm. The gaps in the developmental process are small, since 29 stages are included in the series. Microscopic study was supplemented in each case by models made by the wax-plate method. Several of these reconstructions were already in the laboratory, having been prepared in connection with other studies, notably those of Ingalls, Bartelmez, Davis, Evans, and Streeter. Plaster casts were made from some of the plates by Mr. O. O. Heard, whose skilful aid is greatly appreciated. The colored figures were the work of Mr. J. F. Didusch and were drawn from models. I am much indebted to him for their excellent rendering and for further assistance in reconstructing some parts.

I should like also to express my thanks to Dr. C. H. Heuser for his courtesy in permitting the control of the observations on models by a comparison of his beautiful india-ink injections of pig embryos. It is a pleasure to express my obligation to Dr. G. L. Streeter for the interest and encouragement he has shown in this work and for his courtesy in placing freely at my disposal the material and the facilities of the Carnegie Embryological Laboratory.

BRANCHIAL PHASE OF AORTIC ARCHES.

In following the growth changes of any structure, it is desirable to have some scale of general body development to which its successive stages may be referred. The myotomes serve the purpose for only a short time. Body-length, though available during the entire period, is unsatisfactory as a criterion, since it shows fluctuations depending upon the degree of development, individual variation, the state of preservation, and the curvature of the body. In table 1 the embryos are arranged in the order of their arterial development, and the age at the end of various developmental phases has been approximated according to Mall's (1912) curve of body-length and age. Because of the large number of embryos upon which the estimates are based, they probably closely approach the correct figures.

The transformations of the aortic-arch system progress through two strongly contrasting phases. The first we may term the *branchial* phase, since the vessels at this time approximate a pattern which in lower vertebrates is frequently the precursor of the arteries supplying the gill apparatus. The second or *post-branchial* phase is characterized by the replacement of the branchial by the adult arterial arrangement. For convenience, the breaking of the right pulmonary arch will be considered as marking the boundary between the two. Though some components of the system undergo involution while the arch is still functioning, it is the interruption of the arch that initiates a general disintegration.

Beginning with the establishment of the first arch, the branchial phase lasts about 22 days. The post-branchial period, in the strict sense, endures for nearly 28 years, if this be taken as the growth interval for man. Yet a human embryo of 24 mm. has large arteries in the cranial portion of the body which differ only in minor features from the adult condition, since the vital changes of the second phase are over within two weeks from its beginning.

TABLE 1.—*Showing correlation of size of embryos and development of the aortic-arch system.*

Embryo No.	Length in mm.	Arches present.	Characteristic features.
[Time of establishment of first arch; estimated average length 1.3 mm.; 23d day of development*]			
1878	1.3	I	Slightly plexiform. Presomite stage
1201	2	I	
391	2	I	7 somites
470	4	I	Neuropores open; 14 to 16 somites
2053	3	I; II beginning	Anterior neuropore closed; 20 somites; transverse anastomoses between primitive aortæ
1201*b*	3	I, II	
836	4	II, III	Earlier mandibular artery; paired longitudinal neural arteries; no ventral tract on cord
[Just before establishment of fourth arch; estimated average length 4 mm.; 31st day of development*]			
826	5	III, IV	Earlier mandibular and hyoid arteries
1075	6	III, IV	Subclavian
588	4	III, IV	Earlier mandibular and hyoid arteries
873	6	III, IV	Ventral arterial tract on cord
988	6	III, IV	
1380	4	III, IV; pulmonary arches almost complete	
2841	4	III, IV; one so-called fifth arch; pulmonary almost complete	Early formation of basilar artery
[Just before completion of pulmonary arch; estimated average length 6 mm.; 36th day of development*]			
810	5	III, IV, and pulmonary arches	Late stage in formation of basilar artery. Splitting of aortic sac distinct. Unpaired aorta complete
1354	6	III, IV, and pulmonary arches	
617	7	III, IV, two so-called fifth arches, and pulmonary arches	Subclavian artery surrounded by brachial plexus. Splitting of sac well marked. Islands at end of basilar artery
792	8	III, IV, and pulmonary arches	Pulmonary and IV arches widely separated below
1121	11	III, IV, and pulmonary arches	Right pulmonary artery small; basilar rounded; IV and pulmonary still farther apart
721	9	III, IV, and pulmonary arches	Cervical segmental arteries becoming interrupted
163	9	III, IV, and pulmonary arches	Anastomoses of cervical segmental arteries to form the vertebral artery are nearly complete
[Time of interruption of pulmonary arch and of branchial period; estimated average length 12 mm.; 45th day of development*]			
1771	13	III, IV, left pulmonary and remnant of right pulmonary arch	
544	10		Vertebral artery complete; identity of arches disappearing; beginning of period of rapid descent of heart and arteries
940	14		Definitive aortic arch just taking form. Right dorsal aorta between III and IV interrupted. Remnants still distinguishable. Main pulmonary channel from heart to aorta nearly straight
1909	15		Common carotid elongated
492	16		Right dorsal aorta distal to IV patent but slender
74	16		End of period of descent. Definitive aortic arch has curve of large radius. Short segment of right dorsal aorta distal to subclavian drawn out in slender thread
[End of period of rapid descent of heart and arteries; estimated average length 18 mm.; 50th day of development*]			
1390	18		Definitive aortic arch sharply bent
460	20		Summit of definitive aortic arch at superior thoracic aperture
2937	24		Sternal bands in contact through most of their length
886	43		Origin of right and left pulmonary branches in contact through most of their length

* Estimates based on Mall's (1912) curve of length and age.

PLEXIFORM ORIGIN OF ARCHES.

The opponents of the theory of a plexiform origin of the blood-vessels have pointed to the aortic arches as an unassailable example of the correctness of their view. Lewis and others have, however, placed beyond doubt the preexistence of a vascular net. The plexus from which the aortic arches develop may cover a wide field or may be restricted, depending upon the amount of mesenchymal territory available. In the case of the second, third, and fourth aortic arches, this is limited by the small cross-section of their visceral arches. The plexuses preceding the first and pulmonary arches are not so restricted and also have other distinctive features.

The first arch was shown by Lewis (1904) to arise in rabbits from an angioblastic net in company with its ventral connections and the primitive aortæ. This was confirmed by Bremer (1912). Evans (1909*a*) has demonstrated by injection the capillary net preceding it in the duck. In the youngest human embryo of our series (1.3 mm. long) the first arch, in its irregular course and in the presence of islands, still gives evidence of its origin from a net. The manner of development of the second, third, and fourth arches is well illustrated in our material, though the series is not complete for any but the second. One of the first indications of the development of an arch is a slight expansion of the dorsal aorta down into the visceral arch. A similar but more marked projection is seen at the same time pointing caudally and laterally from the common ventral chamber from which the arches arise. This will be termed, for reasons which will be explained later, the *aortic sac*.

An early stage in the formation of the second arch has recently been studied by Dr. C. L. Davis[1] in a 20-somite embryo. Angioblastic cords and capillaries extend down from the dorsal aorta on one side (plate 1, figs. 29 and 30, drawn from Dr. Davis's models), while on the other an open channel leads ventrally through the arch for a short distance and then goes over into the primitive net. There is also a vessel (not shown in the figures) which extends up from the aortic sac into the visceral arch and ends in the net. Models of three embryos, of stages ranging from 4 to 17 somites, show beautifully the process somewhat farther along. In two of these a projection from the aorta extends down nearly to the sac, where it ends in capillaries and angioblastic cords. In the other the chief projection is from the sac. It extends upward nearly to the aorta and is separated by a plexus from a short downward-directed sprout arising from the aorta. The appearance of a large channel so soon after the outgrowth of a sparse net is not readily explained as entirely the result of a working over and proliferation of the endothelium of the net. It seems more probable that the development in part takes the form of an outgrowth of the bulging, so that the artery sends out a sprout to supplement the growth activity of the net.

A 4-mm. embryo (No. 836) shows the third arch just completed. It is still irregular in caliber and tortuous. As it enlarges, however, as seen in other em-

---

[1] Through the kindness of Dr. Davis I have had an opportunity to read his finished manuscript and to examine his models and drawings.

bryos, the vessel soon becomes straightened and assumes a median position in the visceral arch.

Developing pulmonary arches are in our series frequently represented by independent dorsal and ventral ends (plate 1, figs. 31 and 32). The extension downward from the dorsal aorta lies close behind the caudal pharyngeal complex.[1] Below, a plexus, which earlier can be seen developing caudally from the aortic sac, has given rise to a vessel which has elongated and now extends backward beyond the level of the dorsal sprout, to break up in the pulmonary plexus upon the side of the trachea. The pulmonary arch is completed by an extension of the dorsal sprout which joins the ventral vessel midway in its course, thus dividing it into a proximal portion (now the ventral end of the arch) and a distal portion (the primitive pulmonary artery). Further observations bearing on the development of this arch and the earlier studies on this subject will be referred to in the description of the development of the pulmonary artery.

The pulmonary arch is more variable as regards the position of its distal end than are the others. As it enters the aorta it may be separated by a distinct interval from the fourth arch (figs. 6, 7) or may be close to it; a common upper end of the two also is frequent. These variations are dependent in part upon changes in the caudal pharyngeal complex, which sometimes lies so near the aorta as to prevent the two arches from close approximation, while at other times it is withdrawn more ventrally. The vagus nerve and its recurrent branch also limit the territory open for occupation by the pulmonary arch on its caudal side, since they pass close behind the caudal pharyngeal complex.

There have been several studies on the development of the second and succeeding aortic arches by both the reconstruction and the injection methods. The second, third, and fourth arches were found in the rabbit by Bremer (1912) to be preceded by a vascular plexus from the ventral aorta. He described this as potentially double for the second arch and multiple for the succeeding arches. Sabin (1917) figures irregular double channels for the second arch in injected chicks.

In human embryos simple loops (figs. 2, 3), of greater than capillary caliber, not infrequently come off from the aorta at the upper end of the visceral arch before any definite sprout has become established. They may remain for a time as a part of a completed vessel, where they are usually referred to as "island-formations." They were found most frequently in the pulmonary arch, but were also seen in the second, third, and fourth arches. Occasionally they were found in the ventral end of the arch. Lewis (1906), in his discussion of the fifth arch, pointed out that they are of general occurrence in mammals. A survey of the literature on the lower mammals serves to confirm this, and it may be assumed that it is true also of man. It is possible that these loops may be expressions of a tendency toward a double channel in the visceral arches, such as Bremer describes.

---

[1] This term is applied by Kingsbury to the entire pharyngeal evagination on either side, which lies caudal to the third pharyngeal pouch.

SUCCESSIVE DEVELOPMENT OF ARCHES AND SHIFTING OF CURRENT.

The existence of aortic arches is the result of the interposition of the pharynx, with its pouches, in the path of the blood-stream from heart to dorsal aorta. Since the arterial end of the heart at first lies below the cranial end of the pharynx and later shifts backward relative to it, the aortic arches develop in regular order from before backward. As the more caudal ones are completed, the first and then the second undergo involution. Later, the third arches cease to carry part of the aortic stream. The current from heart to aorta is in this way shunted caudally. Successive stages in the process are represented in figures 1 to 16.

The earliest channel is the first arch, which for a time carries the entire aortic current. It curves dorsally in a groove behind the head process in the mandibular arch. At first it faces forward, but with the increasing curvature of the head region it becomes more and more exposed to ventral view.

In an embryo of 3 mm. (No. 2053) a second arch is forming (fig. 1, and plate 1, figs. 29, 30.) In the next individual of the series (No. 1201*b*) the second arches are well developed and the first have already decreased greatly in caliber (fig. 2). The next available stage has a large third arch and a dwindling second (fig. 3). Models were made from 8 embryos in which the fourth but not the sixth arch has developed. In all but the youngest of these the first arch has gone and only a slender channel passes through the mandibular arch. In the more mature specimens the second arch also has disappeared (figs. 4, 5). The hyoid arch is now occupied by a channel too slender and tortuous to be regarded even as a remnant of an aortic arch. The phase in which the fourth arch is the most caudal feeder to the aorta begins with embryos averaging about 4 mm. in length and ends with embryos averaging 6 mm. The succeeding portion of the branchial period, which is characterized by the presence of a pair of pulmonary arches and is terminated by the interruption of the right arch, is represented by embryos from about 6 to 12 mm. in length. The approximate length in days of the various divisions of the developmental period can be obtained from table 1.

During the branchial period the changing bed of the stream from heart to aorta follows these successive paths: first arch, first and second arches, second and third arches, third and fourth arches, third, fourth, and sixth arches, and, not rarely, the latter three in company with the so-called fifth arch. It is possible that the first, second, and third arches also for a time share the current, though this condition was not observed in our series. For most of the interval before the completion of the fourth arch, a single pair of vessels carries the greater part of the blood-stream, so rapidly do the first and second arches dwindle. In the later part of the branchial period, covering 9 of approximately 22 days which constitute the total branchial span, there is comparative stability in the arch system, while the current is divided between the third, fourth, and pulmonary arches.

The length of the arches is surprisingly fixed during their entire existence, although the body more than doubles in length during the same interval. The length of the third and of the fourth arch was measured on models of 4 embryos in which the fourth arch had been very recently completed, and also of 4 at the beginning of the post-branchial period, when the arches were about to lose their identity. The measurements were divided by the magnification of the model and corrected approximately for shrinkage. Between the two periods the average length of each showed a negligible increase of less than 5 per cent. The failure

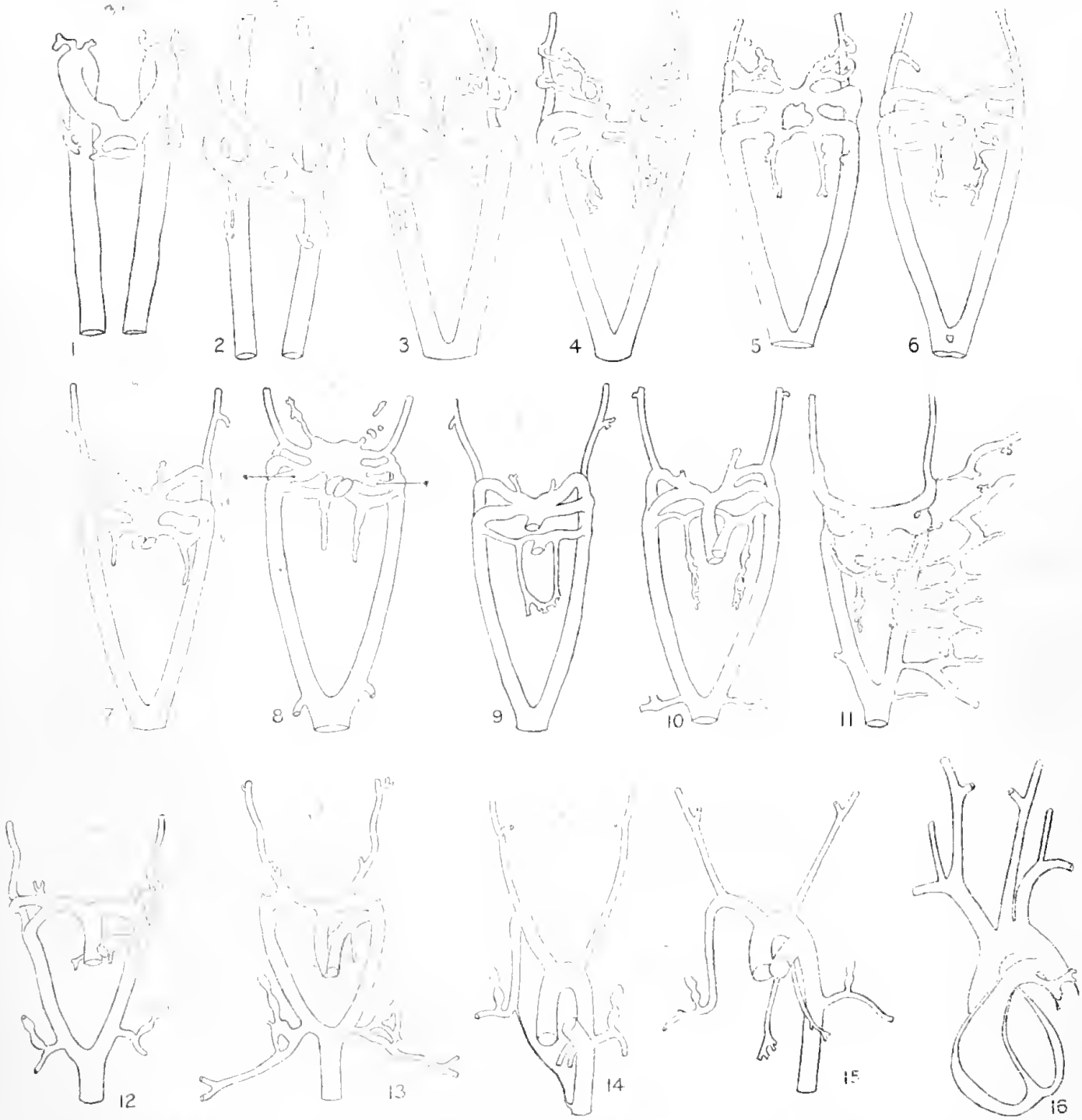

Figs. 1 to 16. Ventral views of aortic-arch system, showing successive developmental stages. In the earliest stage only the first arch is present, while in the last (a full-term fetus) the vessels have acquired nearly their adult form. The so-called fifth arch is indicated by asterisk. Figure 1, embryo No. 2053, length 3 mm.; figure 2, embryo No. 1201*b*, length 3 mm.; figure 3, embryo No. 836, length 4 mm.; figure 4, embryo No. 588, length 4 mm.; figure 5, embryo No. 1075, length 6 mm.; figure 6, embryo No. 1380, length 6 mm.; figure 7, embryo No. 810, length 5 mm.; figure 8, embryo No. 617, length 7 mm.; figure 9, embryo No. 792, length 8 mm.; figure 10, embryo No. 1121, length 11 mm.; figure 12, embryo No. 1771, length 13 mm.; figure 13, embryo No. 940, length 14 mm.; figure 14, embryo No. 74, length 16 mm.; figure 15, embryo No. 1390, length 18 mm.; figure 16, full-term fetus.

of the arches to elongate is due to the lack of active growth in their immediate environment (the caudal portion of the pharynx) at this time, and this in turn is an expression of the regressive changes which the organ undergoes.

The chief cause of the disappearance of the first and second arches is probably to be found in the shift of the blood-stream to the more caudal arches, which accompanies the caudal movement of the aortic sac. The rapid growth of the propharynx,[3] in both width and length, doubtless hastens their degeneration by increasing the length of their course.

SO-CALLED FIFTH ARCH—MORPHOLOGY OF PULMONARY ARCH.

There are two vascular types that appear in descriptions of the so-called fifth aortic arch in mammals, and both occur frequently in man. One is the island-formation of the upper end of either the pulmonary or fourth arch, the other is a channel connecting the fourth and pulmonary arches. Most frequently this vessel comes from the proximal end of the fourth arch, or the subjacent aortic sac, and enters the pulmonary arch above. Its upper end sometimes enters the fourth arch. It may be represented only by spurs corresponding to its extremities. The islands at the upper end of all of the arches but the first and at the lower extremity of some of them have already been referred to and interpreted as retained parts of the plexus which precedes the arches (fig. 4). They require no consideration in a discussion of the fifth arch.

Models of 7 embryos in which the pulmonary arch was almost or just completed were available. Among them were found 3 well-developed vessels arising from the aortic sac or fourth arch and ending above in the distal end of the pulmonary arch (figs. 8, 18, 22). One was of much smaller diameter than the arches, but another was as large as the fourth arch. They all lay in deep grooves of the caudal pharyngeal complex. Arterial sprouts corresponding to the ends of these vessels were found in relation with many of the other caudal pharyngeal complexes and usually can be shown to lie in corresponding though more shallow grooves. The propriety of regarding these channels as rudimentary fifth arches is still a matter of debate after the passage of nearly forty years since Van Bemmelen (1886) claimed their existence in mammals and in spite of the work of nearly a score of investigators. Tandler (1909) was the first to describe them for man, and figured vessels similar to those observed in our series, except that they had a somewhat longer dorsoventral course. He also found spurs corresponding to their ends. He believed that these constitute true fifth aortic arches, but regarded them as very transitory. Only 6 instances of the complete vessels in man have been described up to this time. More than 20 have been found among the lemur, mole, rabbit, cat, guinea-pig, and pig.

It was a corollary to the principle that embryonic blood-vessels depend greatly upon their environment for their form that Lewis (1906), in a study of rabbit and pig embryos, denied the authenticity of so-called fifth aortic arches, on the ground that the existence of fifth visceral arches had never been proved. Kingsbury

---

[3] Kingsbury distinguishes the cranial portion of the pharynx, including the second visceral arch, by this term, and calls the more caudal part the *metapharynx*. The propharynx grows more rapidly in length and width than the caudal division.

(1915*a*), in his study of the development of the human pharynx, points out that the nature of the components of the caudal pharyngeal-pouch complex, exclusive of the fourth pouch, is still too uncertain to justify the claim of a fifth visceral arch. He finds, however, that in the human embryo possible fifth pouches may reach the integument. Whether they are rudimentary fifth arches or not, there seems to be warrant for considering these structures as more homogeneous and definite in character in man than has been generally recognized. The residue left after the islands are eliminated consists, for the most part, of channels passing from near the dorsal end of the pulmonary arch to the proximal end of the fourth arch or the adjacent aortic sac. The chief variation from this type is offered by vessels that terminate distally in the fourth arch. The sprouts lying in grooves of the caudal pharyngeal complex and otherwise having the same relations as the ends of these channels may be regarded as incomplete stages of the same type. Their frequency, taken with that of the complete channels, was found to exceed 50 per cent.

The so-called fifth arch is described by several authors as arising later than the pulmonary. In the human embryo, at least, it will require further data to determine the time relation between the two vessels. The difficulty lies in the lack of a precise period at which we may regard an arch as coming into existence, owing to the gradual nature of its development from a plexus. Nothing is known of the manner in which the so-called fifth arch disappears. Certainly it does not retain its individuality long, since it has not been described in older mammalian embryos. As one follows the deep-seated changes of the parts of the arch system from which the aortic arch and pulmonary artery are formed, it becomes easy to picture its early interruption and the taking up of more or less of the material of its wall in these larger vessels. It may be that some of the spurs which have been described in this region are stages in the development, while others are steps in the regression, of the so-called fifth arches, and it is very likely that the transition from the former to the latter is frequently accomplished without the establishment of a complete channel.

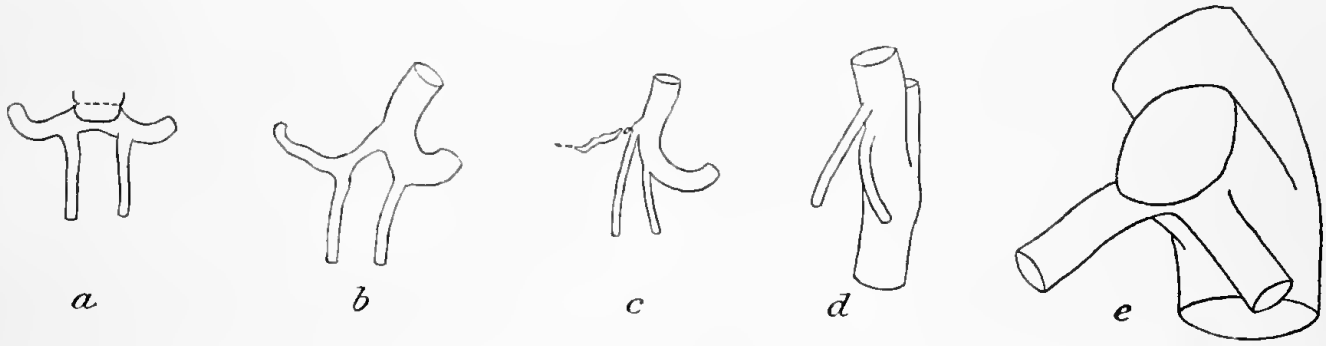

FIG. 17. Development of the pulmonary artery and ductus arteriosus, showing degeneration of distal part of right arch and the incorporation of its proximal part into right branch of pulmonary artery; also approach of right and left branches through wall of pulmonary stem. *a*, 7-mm. embryo, No. 617; *b*, 11-mm. embryo, No. 1121; *c*, 13-mm. embryo, No. 1771; *d*, 18-mm. embryo, No. 1390; *e*, 43-mm. embryo, No. 886.

Shaner (1921) states that in vertebrates it is not rare for the sixth arch to develop, after the fifth is established, as a shorter vessel coming off from both ends of the fifth. The intermediate segment of the fifth then disappears, leaving its extremities as parts of the so-called adult sixth. This suggests a possible significance in the fact that in man the so-called fifth arch enters the pulmonary arch close to its upper end. Of the 6 well-developed so-called fifth arches that have been described in the human embryo, 5 enter the pulmonary near its termination. If it be established that these vessels are true fifth arches, their usual termination would indicate strongly that the upper end of the pulmonary arch is the homologue of the distal portion of the fifth.

Not only is the status of the channel lying between the fourth and last aortic arches unsettled, but the pulmonary arch also depends on a more complete understanding of the caudal pharyngeal complex for its interpretation. Shaner has recently shown that in the turtle the terms *sixth arch* and *pulmonary arch* are not necessarily synonymous. He finds an arch caudal to the fifth, which gives off the primitive pulmonary artery but still is not the equivalent of the human pulmonary arch, since it lies craniolateral instead of caudomedial to the caudal pharyngeal complex. At the same time the equivalent of the human pulmonary arch is indicated by a spur from the upper end of this vessel curving around to the caudomedial side of the complex.

VENTRAL CONNECTIONS OF AORTIC ARCHES—AORTIC SAC.

The literature concerning the nature of the ventral connections of the heart and branchial arterial arches shows a surprisingly great diversity of view, considering the numerous accounts of vascular development. The terminology of this region is in a correspondingly unsatisfactory state. Few authors are in complete agreement in the use of such fundamental terms as *aortic trunk, bulb,* or *ventral aorta,* and we still find in recent editions of our anatomical texts portions of the paired dorsal aortæ referred to as parts of aortic arches, as in the time of Rathke and von Baer.

In the mammalian embryo a saccular enlargement intermediates between the aortic arches and trunk. A slight swelling can be made out at the junction of the first arches and trunk in the human embryo even before the second arch is established (fig. 1). It reaches its highest development when giving origin to the third, fourth, and pulmonary arches and before it has begun to separate into its aortic and pulmonary divisions (figs. 5, 6). At this time it is decidedly flattened dorsoventrally and the arches radiate from it. It varies greatly in form, corresponding to the tendency of this region to be drawn out in either its craniocaudal or transverse axis, and also in response to fluctuations in the form of the individual pouches and arches. The cleft between the points of origin of the fourth and pulmonary arches begins to deepen soon after the caudalmost arch is completed. Before the branchial stage is at an end the sac has separated completely into aortic and pulmonary portions. The pulmonary division is tubular but the part that gives rise to the third and fourth arches is for a time still somewhat flattened and saclike.

The enlargement at the origin of the arches is not confined to mammalian embryos. Greil (1903), in his work on the development of the truncus arteriosus in Anamnia, finds a similar chamber in Acanthias embryos and Salamandra larvae. It is also encountered in certain adult gill-bearing vertebrates. Röse (1890) figures it in his study of the heart in the ganoid Polypterus bichir and the urodele amphibian, Sieboldia maxima (Cryptobranchus japonicus). Dr. Harold Senior tells me that in the American form, Cryptobranchus alleghenesis, the enlargement is present, but the common cavity is much restricted by the medial extension of septa between the openings of the arches.

His (1880) and Bujard (1915) have recognized the existence of a ventral aortic swelling in the human embryo and designated it *aortic bulb*. Gage (1905) and Jordan (1909) termed it the *aortic sinus*. Griel and Röse did not devote especial attention to the sac in their studies of gill-bearing vertebrates and gave it no name. In the adult fish and amphibian it is doubtless to be classed as an aortic bulb, though these non-muscular enlargements distal to the heart do not usually give off the arches directly. In this paper the specific term *aortic sac* (saccus aorticus) will be used for the embryonic enlargement. This is meant to include not only the chambers between the arterial trunk and the arches, but also the reduced sac distal to the aortic trunk, which persists for a time after the pulmonary trunk has become separated off.

On looking for an explanation for the expansion at this point it is necessary to determine the relative importance of adaptation to function, such as is found throughout the adult circulatory system, and of factors peculiar to the developmental period. The aortic bulb of adult fish and amphibia probably shares with the elastic mammalian aortic arch and other large arteries the function of distributing the systolic pressure over a large portion of the arterial cycle. Stahel (1886) claims that an enlargement of the portion of the human aortic arch opposite the emergence of the innominate, carotid, and subclavian arteries is a response to the added strain on the wall at this point resulting from the sudden deflection of part of the current into these vessels. Thoma does not accept this explanation. It is possible that the embryonic aortic sac is the result of the combined action of these two principles. Yet it must be remembered that the embryonic chamber differs greatly in its nature from the adult bulb and arch. As to its makeup, we can say with certainty only that it consists of an endothelial sac, though histogenetic study may well show that myoblasts and fibroblasts are already to be reckoned with. In any case its wall is very thin. It follows the relief of the ventral pharyngeal wall; it is a cast of which the pharyngeal surface is a mold. If we are to consider the embryonic sac as serving as an elastic reservoir similar to the adult bulb and aortic arch, it is necessary to recognize the support afforded by the pressure of surrounding resistant organs, exerted through the intermediate mesenchyme, as, for example, the pharyngeal endoderm above and the atria of the heart below.

Kingsbury (1915*a*) noted that the arterial channels ventral to the pharynx, including the aortic arches, fitted snugly into concavities of the pharyngeal wall, and he concluded that the vessels exerted a molding influence upon it. It is difficult to say just how much of the channeling of the pharyngeal surface is due to the arteries and how much to other factors. Doubt is cast upon a preponderating influence of the blood-vessels by the fact that the grooves on the ventral floor of the pharynx, filled for a time by the first and second aortic arches, do not disappear when these vessels are lost.

An entirely different explanation for the presence of the sac has been suggested by Dr. Streeter. He has observed that it is a characteristic of early vessels, well illustrated by the early dorsal aorta, to have a diameter much greater proportionately than would be required for the adult vessel. He suggests that this may be due to proliferation of reserve endothelium which a little later will be used in the rapid differentiation of the vascular system.

The connections of the aortic arches with the arterial or aortic trunks are termed *paired ventral aortæ* in most text-books of human anatomy, and the schemata which they contain correspondingly show the arches arising from a pair of longitudinal ventral trunks. As has been stated, a few investigators have recognized the error of this description by using the term *bulb* or *sinus*. While the arterial blood in the human embryo passes from trunk to arch by an unpaired sac, there are certain temporary channels to single arches which, by their cranio-caudal course, resemble fragments of a ventral aorta. Such are the longitudinal ventral segments which appear in the later history of the first and second arches and the paired ventral sprouts which for a time run caudally from the pouch before they take on a more transverse direction as part of the pulmonary arches. One might even include the primitive ventral arterial twigs of the subpharyngeal regions, which have the position of ventral aortæ in the region of the first and second aortic arches, though at a time when the arches have already disappeared. These various more or less longitudinal elements are rightly to be regarded as indications of a general structural plan common to higher and lower vertebrates, but carried on in some of the latter to a completeness which admits of the existence of paired ventral aortæ. However, these considerations certainly offer no justification for the use of the term *ventral aortæ* in man, since such vessels are not to be found at any stage of his development.

INVOLUTION OF FIRST AND SECOND AORTIC ARCHES—ORIGIN OF STAPEDIAL AND EXTERNAL CAROTID ARTERIES.

In the region below the propharynx there is a period of instability and of readjustment of the vascular channels after the disappearance of the first and second aortic arches. Our study of this period is based on but few models, since only vessels turgid with blood or good artificial injections can be relied on to demonstrate the change of the arches into a plexus and the beginning of the arteries therefrom.

Soon after the third arch is established, the first has given place to a tortuous and much more slender channel (fig. 3). It is best developed at the upper end of the visceral arch and is usually lost in the plexus at the lower end. There is often distinguishable close to the vestibule an arterial sprout occupying the position of the ventral end of the arch before its disappearance (figs. 3 to 9). After the fourth arch is complete, a similar channel is found to have replaced the second arch; this also is usually lost in a plexus in the subpharyngeal region. These vessels are

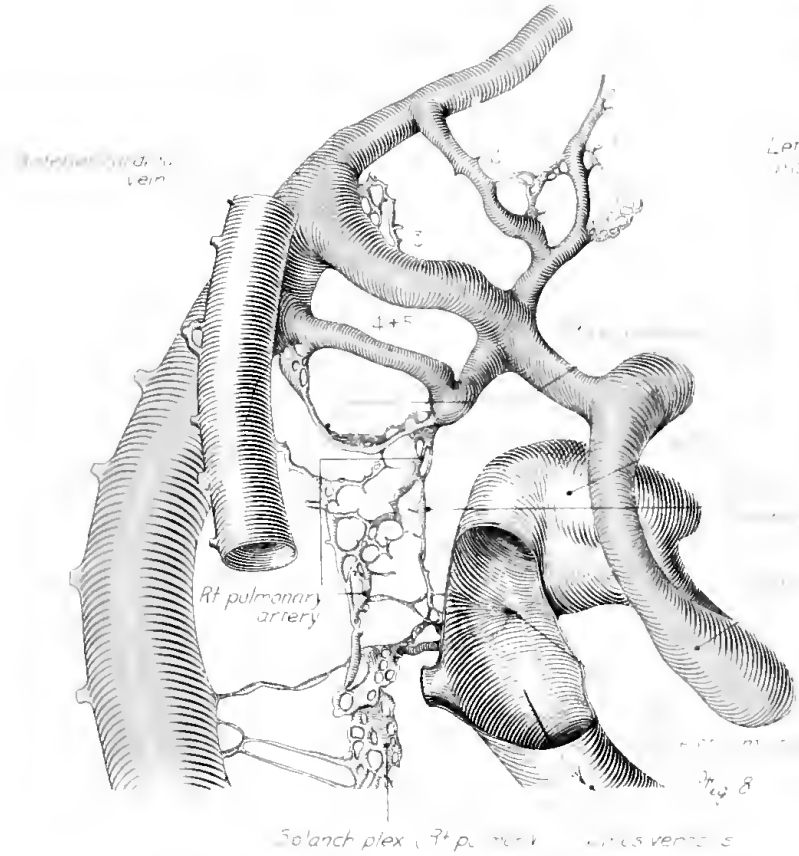

Fig 8

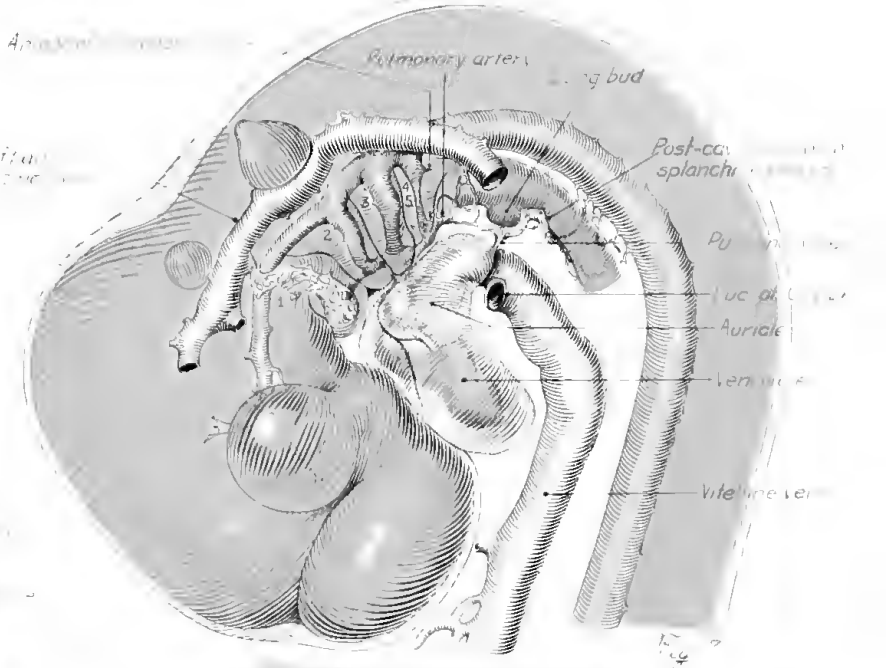

Fig 7

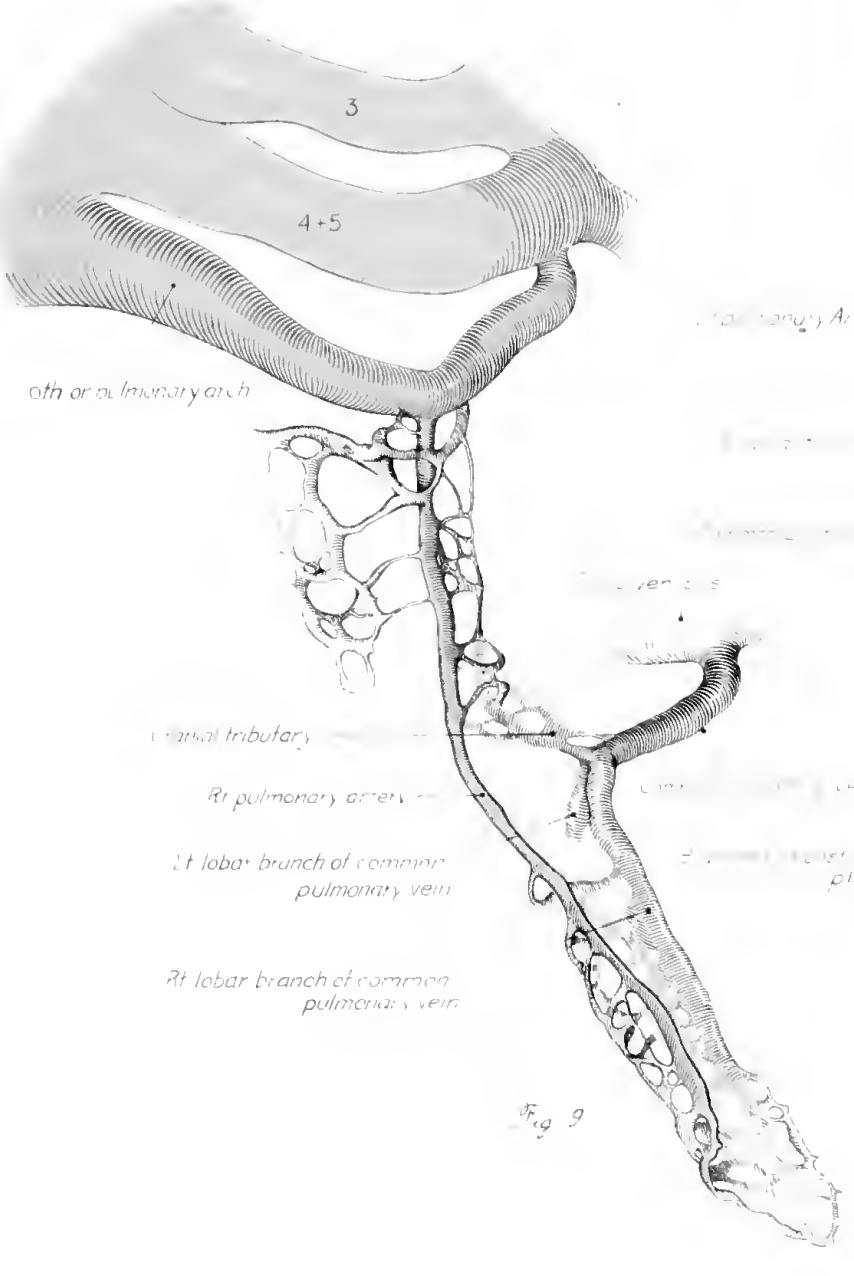

Fig 9

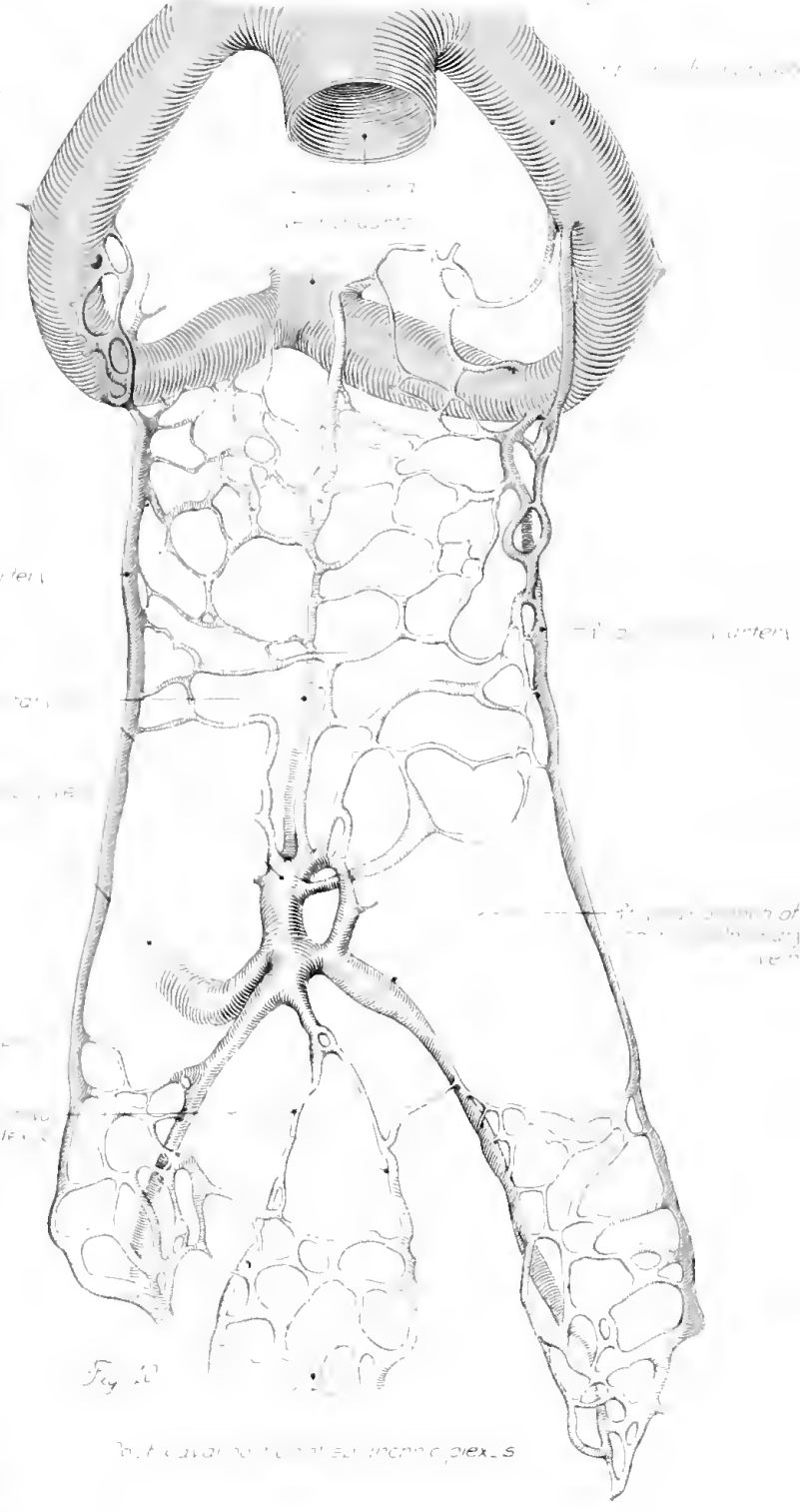

Fig 10

J. F. Didusch fec.

A. Hoen & Co. Lith.

clearly not to be regarded as late stages of the arches. They have not the size or form of the arches. Functionally, also, they differ. Since they are interrupted below, evidently their current is usually downward from the dorsal aortæ. They serve to supply the substance of the visceral arches and not to convey the blood-stream from heart to aorta.

The vascular successors of the arches remain but a short time and are in turn replaced by slender vessels, which, except near their origin from the dorsal aortæ, are scarcely more than capillaries. These run close to the caudal confines of the first and second visceral arches. These two pairs of successive vessels may be termed, respectively, the earlier and later hyoid and earlier and later mandibular arteries from the visceral arches which they supply. The later hyoid and mandibular arteries are both present in the period between the establishment of the fourth and sixth arches. In the branchial period, after the completion of the pulmonary arch, the upper end of the later hyoid vessel seems always to be present. It is still clearly distinguishable in the post-branchial period (plate 3, figs. 37 to 39). It is the equivalent of the stem of Broman's (1898) hyostapedial artery in man. Tandler has described in detail the development of the stapedial artery in the rat by the capturing of branches from the upper end of the first arch by the upper end of the second arch. There can be little doubt that the "arches" he refers to are the earlier or later mandibular and hyoid arteries of the foregoing account. He finds that the upper end of the "second arch" moves caudally a short distance along the dorsal aorta. This we recognize as the later hyoid artery, which we know has a slightly caudal position as it comes off from the dorsal aorta, due to its passing down the caudal side of the visceral arch. In 13 and 14 mm. human embryos this vessel has increased in caliber, keeping pace with the expansion of this region in connection with the development of the ear. Tandler also finds it in the human and identifies it as the stapedial artery. The development of its branches and its later history were not followed in the present study.

At the time the stapedial artery is developing in the hyoid arch, the precursor of the external carotid is taking form on the ventral side of the propharynx. While the second arch is disappearing, a pair of symmetrical arterial sprouts is usually distinguishable, extending forward from the aortic sac in the region earlier occupied by the ventral segments of the first two arches. In the two specimens showing this stage these sprouts lie ventral to the thyroid gland, and in one of these the distal branches of the right sprout have been captured by the opposite vessel. Later (fig. 3), after the second arch has gone, these ventral primitive arteries are found to be on either side of the thyroid gland. Each sends out a ventral branch to the plexus of the pericardium and integument, and also a dorsal branch, which either breaks up in the rich plexus of the thyroid gland or extends for a variable distance through the subpharyngeal plexus toward or into the base of the mandibular or hyoid visceral arches (fig. 4).

An interesting feature of the adjustment of the ventral pharyngeal vascular channels is the occurrence of small vascular enlargements in the subpharyngeal plexus or at times in the ventral primitive arteries. These are termed *lacunæ* by Tandler (1902) and Lehman (1905). In the figures of Lehman they are represented as being independent of the circulatory system; she regarded them as fragments left behind by the involution of the first and second arches. Dr. Streeter suggests that they may be proliferations of endothelium for the supply of the developing ventral arteries, and thus progressive rather than regressive in nature. No evidence for the degeneration of the endothelium of the two arches was found. It seems probable, therefore, that it is worked over into the capillary net and the larger vessels that succeed them. The regression of small vessels will be considered again with reference to the interruption of the segmental arteries during the formation of the vertebral.

In the post-branchial period the differentiation of the subpharyngeal region has permitted the ventral artery to develop branches somewhat resembling those of the definitive external carotid. There are, for example, lingual twigs passing between strata of the developing lingual muscles. The artery is now sufficiently withdrawn from the thyroid plexus to have a definite thyroid branch. Other ramifications are already present, and there also may be finer branches given off from the third arch close to it. While the vessel is thus taking form, it is gradually withdrawn from the midline. At the end of the branchial developmental phase it is given off from the third arch near its junction with the aortic sac (fig. 12).

The process of involution of the two cranial aortic arches and of the development of the arteries that succeed them has been variously interpreted. The earlier observers did not find the mandibular and hyoid arteries. As material improved and experience increased, these vessels were usually seen only in part and were interpreted as fragments, due to the breaking down of the corresponding arches, rather than as vessels that had taken their place. The point of first interruption has been placed at either end or at some intermediate point, depending probably on the chance conditions of distention of parts of the arteries rather than upon individual or specific differences among mammals. A further study of these changes of vascularization by the injection method is highly desirable.

POST-BRANCHIAL PHASE.

(Including embryos up to 25 mm. in length.)

The disappearance of the aortic-arch system is amply explained by the separation of the outflow from the heart into two streams and by the changes in the environment of these due to the shifting of the organs among which they must find their way. Though it is necessary, for convenience, to describe the arterial evolution by stages, and to a certain extent independently of the movements, it must not be forgotten that it is a gradual process and is paralleled step by step by changes in the surroundings.

During the disintegration of the branchial arterial pattern, some of the arches and their connections may be identified for a time; but since their distinguishing characters are largely topographical and their walls differ but little in structure, their individuality is gradually lost and their material worked over and increased to form the arteries which succeed them. The difficulties encountered in tracing their later history are paralleled in the study of the development of other tubular systems, as, for example, the hepatic and pancreatic ducts, or the Wolffian ducts in connection with the urogenital sinus. To follow the material derived from them to its position in the post-branchial vessels, it is necessary to know whether there is, during growth, a fusion or a splitting at the point of bifurcation of vessels, and whether changes in the interval between two lateral branches are due to an alteration in the length of an intervening portion of the main stem or to a more complex shifting of the material by which the branches move bodily along the wall.

The task of tracing the material of the arch system into the vessels of the post-branchial period is well worth while, not because we expect them to take part as distinguishable units in the adult vessels, but because, on account of the definiteness and multiplicity of the arches and their connections, they are especially good material for gaining some conception of how rapidly vascular territories in general lose their identity and to what degree their material is intermingled with adjacent regions during development. The history will, at best, be incomplete, since the largest embryo of our series, though its form is far along toward the adult condition, is but 24 mm. in length and must increase about seventyfold before the adult dimensions have been reached.

The breaking up of the arch system of the late branchial period, with its 3 pairs of arches, is made possible by its interruption in four regions. This is preceded by a movement of the arches as far caudally as their pharyngeal pouches and other structures allow. The time occupied for each interruption is brief; it can be roughly estimated as a day. The left pulmonary arch is the first to disappear, thus permitting the evolution of the pulmonary vessels. The dorsal aorta on each side, between the third and fourth arches, next loses its continuity. This is of especial help in the formation of the definite aortic arch and the innominate and common carotid arteries. Finally, the dorsal aorta, by its interruption close to its caudal end, prepares the way for the remolding of a large part of the right paired aorta, together with the right fourth arch, into the subclavian artery of this side.

The involution of the right pulmonary arch is confined to the part distal to the origin of the right primitive pulmonary artery (fig. 17, *a* to *d*). Models were made of the arch system of 2 embryos in which this region was in a condition of reduced diameter preliminary to its interruption, at the time when evidences of the causes of its degeneration should be most apparent. In fact, indications are not lacking of the presence of mechanical conditions that might cause its involution. The arch seems to be pulled caudally at its ends and held back in its middle portion by the vagus nerve and its recurrent branch. Both ends are bent somewhat caudally and are smaller in diameter than the intermediate part. The upper end comes off the aorta at about the same angle as found at this time in the more cranial segmental arteries, where it is clearly due to the caudal shifting of the aorta relative to the surroundings.

The existence of a caudal and a transverse pull upon the proximal end is indicated not only by a caudal slope of this segment just where it passes down to the origin of the primitive pulmonary artery but also by the rapid withdrawal caudally and to the left of this origin after the segment is broken. The intermediate part of the interrupted segment lies closely applied to the cranial surface of the loop formed by the vagus and its recurrent branch. The arch, in the character of its curve, shows molding by the nerve, and frequently the aorta just caudal to it is flattened. The molding is still more clearly seen on the left pulmonary arch, which does not become interrupted.

In spite of indications of pressure from the vagus on the degenerating arch, models of two embryos in which the arch is not reduced do not show any considerable flattening of the vessel walls against one another due to pressure. The lumen is rounded, and in one specimen, in which the mesenchymal layer of the wall can be made out satisfactorily, this is much thickened. The first distinguishable step in the reduction, then, is a contraction.

The disappearing segment of the arch seems to have been exposed to unfavorable conditions in regard to both longitudinal tension and pressure by the vagus nerve. Yet a comparison of the history of the right and left arches at this time brings out clearly that these factors are not the exclusive cause. The left arch shows a well-marked molding by the vagus and its recurrent branch, but it does not retrogress; on the contrary, at this time it is increasing in diameter. The reason for its persistence in spite of unfavorable surroundings is probably to be found in its more advantageous position relative to the pulmonary current. The bifurcation between the pulmonary trunk and the arches is well to the left of the mid-sagittal plane, due to the presence of the aortic trunk on the right. In consequence, the left arch has a much shorter and more direct route to the dorsal aorta than the right, thus receiving more blood and being better able to maintain itself.

One embryo, in which the arch as a functioning element had gone, still had a cellular cord extending from the junction of the right pulmonary artery and the persisting ventral segment of the arch to the ventral edge of the caudal pharyngeal complex. Though its cross-section was made up of a number of cells, the endothelial and mesenchymal elements could not be distingiushed from each other. The post-mortem changes in the surrounding tissue made it impossible to determine whether or not its cells were degenerating before the death of the embryo.

We are fortunate in having models of three stages in the breaking of the dorsal aorta between the third and fourth arches. In the first, a continuous curvature of the third arch and the aorta cranial to it had developed, while the fourth arch had similarly formed a common arch with the aorta on its caudal side (figs. 9, 11; plate 2, figs. 34, 36). This indicates that, as the current in the fourth arch passes caudally, that of the third arch moves in a cranial direction. With the perfection of these curves, the intermediate aortic segment becomes more slender (fig. 12) and its ends are pulled slightly downward and away from each other to give it an arched form. It shows contraction by a thickening of its wall and decrease of its lumen. Lehmann describes a condition in the pig (missing in our series) in which the further moving apart of the distal portions of the two arches results in the pulling out of the intermediate segment to a mere thread. In our next stage this filament is probably broken, as we find a rounded mass at the upper end of the fourth arch, evidently due to the retraction of its mesenchymal sheath (plate 3, figs. 37 to 39). The endothelial core was traced backward through a few sections as a solid rod. The anterior end of the degenerating vessel was not found.

If tension in connection with the caudal shifting of the aorta plays a causal rôle in the disruption of the pair of aortic segments, it seems to be secondary in importance to a decrease in the current-flow. The contrasting curves of the third and fourth arches, before the segment has stretched perceptibly, indicate that the current is passing from them to the aorta in opposite directions, and consequently the stream in the disappearing segment is nearly at a standstill.

The interruption of the caudal part of the right paired aorta takes place in a manner very different from that indicated by current figures and descriptions. These err in representing the obliteration of a long segment of the vessel. There is, in fact, great economy of material in this operation, since only an insignificant terminal segment actually disappears. Before it has been especially affected, the entire right paired aorta, as far forward as the fourth arch, becomes reduced in diameter, so that it retains a lumen adequate only for the supply of the subclavian. Decrease in current here seems to be the primary cause of involution, as in the case of the pulmonary arch. Here, also, the left counterpart persists, having a larger current. The cause of the falling off of the current of the right vessel relative to the left is probably to be found in changes that have come about in the pulmonary aortic trunks at this time. As has already been explained, the pulmonary trunk is now throwing its current entirely into the left paired aorta. The aortic trunk also, in the two embryos that were studied, has taken an oblique direction, well marked later, and is therefore sending more blood into the left than into the right fourth arch. The greater part of the right paired aorta caudal to the fourth arch retains a diameter equal to the subclavian. The short caudal end distal to the subclavian shows further contraction by a narrowing of its lumen and a thickening of its wall. Later, as the aorta shifts caudally, it is stretched out into a filament over 3 vertebral segments in length (fig. 14). This is made possible by the fixation of the more caudal part of the paired aorta by the right subclavian and its branch, the vertebral, which thus fastens it to the vertebral column and to the surrounding tissues.

The different interruptions here described seem to have much in common and are due to the same factors that brought about the involution of the first and second arches. In each instance there is a preliminary decrease of current-flow, though its cause in the unpaired and symmetrical segments is dissimilar. It seems probable that longitudinal tension, resulting from the caudal shifting of the heart and aorta, serves to augment the effect of the change in current. At an early stage there is lacking clear proof of tension, such as would be furnished in the case of a stretched rubber tube by the narrowing of its wall and lumen. The first decrease in caliber was due to a contraction of the vessels and was therefore accompanied by a thickening of the wall. The response of the artery to the tension and other unfavorable influences was vital in its nature and not merely physical. It was only after their walls weakened that the aortic segments were rapidly pulled out into filaments. The pressure of the vagus nerve probably assisted in the involution of the left pulmonary arch. Here, again, direct proof of its action, which in this case would be a marked lateral compression of the degenerating vessel, was lacking. There was no available material in which to study the degenerating first and second arches for evidences of unfavorable effects of tension.

Before considering in detail the manner in which the large vessels derived from the arch system take form, it might be well to become familiar with a stage midway between the late branchial and the approximately adult condition found in a 24-mm. embryo. In plate 3, figure 38, showing a 14-mm. embryo, it can be seen that the right half of the aortic sac is represented approximately by a transverse tube, concave cranially, and making, with the modified left limb of the sac and the derivatives of its third arches on either side, the arm of a candelabrum-like figure the upright stem of which is the aortic trunk. From the tube on the right and the sac on the left arises a vessel, which still bears some resemblance to the third arch, and also a derivative of the fourth arch. These vessels, however, take origin more laterally and dorsally, relative to their surroundings, and run more directly dorsal than do the arches in the branchial period. The upper end of the zone arising from the fourth arch is still marked on both the right and the left side by the tapering remnant of the interrupted dorsal aorta as earlier described. The tube of the right side and its fourth arch derivative are much longer than their equivalents on the left side, whereas the latter are of much greater diameter. Those on the left also lie almost a vertebra length more caudally.

The definitive aortic arch is already roughly outlined at this stage, and the left half of the sac and the widened left fourth arch are parts of it. The tubular derivative of the right half of the sac may be termed the primitive innominate artery, and the regions corresponding to the lower parts of the third arches, up to the origin of the primitive external carotid arteries, are the primitive common carotids. Distal to this point are the primitive internal carotids.

Individual variation must be reckoned with always in describing a single embryo as a type. In this instance the model of an embryo slightly older than our 14-mm. specimen, while also normal in appearance, shows a marked difference in the proportions of the innominate and right common carotid. The innominate has still the form of a slightly elongated half of the aortic sac. To compensate for this the common carotid is longer than in the other embryo.

The pulmonary vessels no longer show any element suggesting the proximal segment of the right pulmonary arch. The main pulmonary channel is a single large straight vessel leading to the distal end of the definitive aortic arch and giving off a pair of pulmonary arteries near its origin. The right paired aorta, though not interrupted at its distal end, is much smaller than its counterpart on the left side. The subclavian arteries are given off from the paired aortæ just before their confluence to form the unpaired aorta. The vertebral arteries are present as branches of the subclavians, and the basilar is completed through most of its later course by the fusion of the longitudinal neural arteries. In position the arch system is now about midway between its earliest location in the occipital region and its ultimate position in the thorax.

The central feature in the post-branchial arterial development is the evolution of the aortic arch. It comes into being from various sources. Its beginning is indicated by the replacement of the left fourth arch and the dorsal aorta between it and the left pulmonary by a tube of continuous curvature at the time the aorta cranial to it is narrowing its lumen preparatory to obliteration. In the arterial system of a 14-mm. embryo such as has just been described (plate 3, figs. 37 to 39), angles and inequalities of diameter block out roughly the arterial regions which are losing their individuality in the formation of the arch. These are the aortic trunk, the tube derived from the left half of the aortic sac, the left fourth arch, the left dorsal aorta between the fourth and pulmonary arches, and, finally, that portion of the left paired aorta lying distal to the pulmonary arch. The irregularities of the arch have disappeared by the time the embryo reaches a length of 17 mm.

The radius of curvature of the early aortic arch changes in connection with alterations in the direction of the long axis of the heart as it shifts downward into the thorax. While the arch is in the lower neck region and the ribs of the two sides have not become united in front by the rudiments of the presternum and sternal bands, the curve of the arch is rather open, though it will be seen that its radius is already less than when first forming (figs. 20, 24). As the heart passes into the dorsal concavity of the thorax and is encircled by the ribs, its apex points less ventrally and more caudally. In consequence the pars ascendens of the arch assumes a more longitudinal direction. Since the more distal part of the arch is held by a number of branches, a sharp bend develops between the two at the origin of the innominate and left common carotid. By the time the summit of the arch has reached the level of the first thoracic vertebra and the rudiments of the sternum have fused to complete the superior thoracic aperture, the pars ascendens is nearly aligned with the long axis of the body, and the arch for the time has more the form of a letter V than of a segment of a circle (figs. 21, 25).

The arch is also peculiar at this time in that it lies almost completely in the midsagittal plane. This is because the dorsal aorta has not yet moved to its position at the side of the vertebral bodies, which are at this time so immature as not to have assumed the strong convexity which later characterizes them in this region, and the heart has not yet taken on its obliquity relative to the long axis of the body.

The tracing of the regions of the arch system into the later arteries, as well as an understanding of the changes in the latter, is largely a matter of inference based upon changes in dimensions. Accordingly, the length and circumference of various parts of the arch system were obtained, as also the length and circumference of the parts of later vessels with which they were to be compared. For the study of most regions a series of 11 embryos of graded development were used. Of these, 6 represented the branchial stage and 5 the post-branchial. The measurements were made on models and then reduced to their true value by dividing by the magnification. The reliability of the data was considerably increased by correcting approximately for shrinkage of the vessels by a comparison of the length of the embryo at the time of fixation and after embedding and sectioning. It will suffice here to state the chief conclusions derived from the tables which were prepared from the measurements. In the further examination of the growth of the aortic arch it is to be remembered that there are three regions of the arch system to consider—the aortic trunk, the left half of the aortic sac, and the left fourth arch together with the paired aorta between it and the pulmonary arch (plate 2). These parts are to be compared, respectively, with the proximal end of the arch from valves to innominate artery (plate 3), the portion between the innominate and left common carotid, and the part between the left common carotid and the ductus arteriosus. The part of the left aorta which enters into the formation of the arch was not especially studied.

The distance from aortic valves to the left pulmonary arch, or, later, to the ductus arteriosus, which includes nearly all of the arch, does not increase from the late branchial period to the stage represented by a 24-mm. embryo with sternal bands in contact and the heart and large vessels in nearly their adult thoracic position. There is no reason for believing that this failure to elongate is only apparent and due to a proximal movement of the aortic ductus. If such a shifting should take place, it would naturally be greatest at the time of rapid descent, yet no change in the distance from the valves occurred at this time. Doubtless, then, there is a true standstill in longitudinal growth.

Though the arch does not elongate, it does increase in diameter. The measurements show that the left fourth arch and, to a less degree, the left paired aorta increase rapidly in circumference as the aortic arch is forming. The sac region of the arch alone is much larger around in the post-branchial period than is the sac in the branchial period. By these enlargements an arch is developed without local inequalities and with connection adequate to carry more than half of the entire current to the dorsal aorta, which was formerly divided between six branchial aortic arches. The changes in extent of the divisions of the arch will be best understood if the interval between the innominate and left common carotid be first considered. In the early post-branchial period this is somewhat greater than the length of the left half of the aortic sac, to which it was equivalent at the beginning of the period. It reaches a maximum at about the time of the rapid descent of the arch (16 to 17 mm. embryos) and decreases rapidly while the rudiments of ribs and sternum are closing in to form the superior thoracic aperture. The increase in length indicates a real growth, since the circumference of this region does not decrease, and it is evident that the innominate and left common carotid rather precisely mark off territory derived from the earlier left half of the sac during the first part of post-branchial development and are withdrawing from each other at this time because the part of the arch between their points of origin is conforming to the general body-growth. The later approach of the two branches in embryos of 18 to 24 mm. length must be due to a different process in the wall of the arch, for the increase in the circumference at this time is not nearly as great as the decrease in distance between the two arteries. Hence we can not explain their approach on the basis of a mere reshaping of the wall of the arch between them by which it gains in circumference what it loses in length; there must have been an actual decrease in the substance of the wall of that part of the arch or a plastic rearrangement, allowing the vessels to approach by one or both of them moving in a certain sense through its substance. As no good reason for assuming that the arteries undergo a decrease of substance while maintaining their diameter and function was found elsewhere in this study or in the literature, this alternative may be dismissed from consideration, and it may be safely concluded that the substance of the wall has shifted about to permit a movement of the origin of one or both branches. The two arch divisions lying proximal and distal to the interval between the innominate and carotid arteries differ greatly in their changes in length. The segment proximal to the innominate, taken with the truncus aorticus, to which it is equivalent at the beginning of the post-branchial period, shows an increase in length which becomes very rapid when the innominate and carotid are approaching at the time of rapid descent. The part distal to the left common carotid, extending to the upper end of the sixth arch, shortens in the late branchial and early post-branchial periods and later remains constant during the time of rapid descent.

It is clear that in the history a sharp distinction must be drawn between the period before and the period occupied by the rapid descent. Before the descent the truncus arteriosus and the succeeding division of the arch which has developed from the left half of the sac increase in length. As has been seen, no marked increase in diameter is required, since in the branchial period these vessels are relatively capacious parts of the arch system. The distal portion of the definitive aortic arch coming from the left fourth arch and from the aorta distal to it is in contrast with the more proximal part of the forming arch. They remain unchanged in length up to the time of rapid descent. In circumference the part derived from the fourth arch undergoes an especially rapid enlargement, since in the branchial period it is only one of six conveyers of the blood from heart to aorta, while at this stage it transmits more than half of the entire current. At the time of rapid descent the innominate and the left common carotid approach, while the distance between the innominate and the aortic valves increases with especial rapidity. It is natural to conclude that the innominate has moved toward the left common carotid. Since the distance between the left common carotid and the ductus arteriosus remains constant, the former probably does not change its position on the arch. These inferences, drawn from the changes in length of the various parts, agree with expectations based upon the relation of the two vessels to the forming arch at the beginning of the post-branchial period. As the left carotid is at its summit and the innominate comes off from its ascending limb, only the innominate could respond to the tension upon it by moving along the wall of the descending arch.

A result of the retardation in the elongation of the distal part of the arch relative to the proximal is a change in the region which forms its summit. In the 14-mm. embryo, in which the arch is just taking form, the entire left fourth arch is the summit (plate 3, fig. 37). The relative shortening of the distal part of the definitive arch results in a drawing down of the fourth-arch zone into the descending limb, thus leaving the left common carotid at the summit (fig. 24). The distal migration of the innominate on the ascending limb also serves to bring it to a position on the highest part of the arch.

In its change of position the left subclavian involves both the arch and the aorta and helps one to understand the manner of their growth. The interval between the left subclavian and left common carotid, as also its approximate equivalent in the branchial period, shows a marked decrease not only relatively to body length but absolutely. In fact, it is only one-fifth as long in a 24-mm. embryo as in the late branchial phase. If we subtract from it the length of its proximal part as far as the ductus arteriosus, it decreases to zero, since the subclavian shifts upon the aorta and arch upward past the ductus.

At its first appearance the subclavian arises from the unpaired aorta. It passes the bifurcation of the aorta early in its development and on to the left paired aorta. Its movement past the fusion point of the aortæ and the ductus arteriosus can only be explained by a considerable shifting of the material of the wall of aorta and arch, and in this respect it resembles the changes in position of the innominate (figs. 18, 19, 22, 23). A similar condition has been found in the large abdominal arteries. Evans (1912) suggests that their movement along the dorsal aorta may be due to an unequal growth of the dorsal and ventral walls. The exact nature of the translocation of material which permits such shifting, however, seems to be at present very uncertain.

To summarize the observations on the growth of the definitive aortic arch during the period of rapid descent of heart and arteries and the coming together of the sternal bands, before the rapid descent the proximal part of the arch extending up to the origin of the left common carotid elongates rapidly and increases moderately in diameter. The more distal region, as far as the ductus arteriosus, decreases in length. It increases rapidly in diameter, however, to compensate for its originally small cross-section as compared with the more proximal parts. Increase in length or diameter, if any, during the rapid descent, is too slight to be distinguished. The chief changes are in the movement of the innominate and the subclavian along the wall of the arch. The innominate moves up to the left common carotid, and the subclavian approaches it from the other side. The subclavian passes the ductus arteriosus but does not approach very close to the carotid at this time. The large part of the arch extending down to the ductus arteriosus does not increase in length during the considerable developmental interval included in this study, though its diameter enlarges.

The history of the main post-branchial pulmonary channel illustrates the same growth processes observed in the development of the arch. The first step is the separation of the pulmonary trunk and its pair of arches from the aortic trunk and sac (fig. 17*a*). Because the pulmonary arches arise from the sac close to the mid-sagittal plane, little of the sac is removed when they separate off, and no attempt will be made to trace the small zone derived from it in the later development. The proximal part of the right pulmonary arch remains as the origin of the right primitive pulmonary artery after its distal portion degenerates. Relieved of the longitudinal tension exerted by the complete arch, the angle between the remaining part of the arch and the primitive pulmonary artery tends to straighten out, aided, no doubt, by a formative action of the current not associated with longitudinal tension, so that the boundary between the two can no longer be identified. The loss of this tension at the junction of the two pulmonary arches, taken similarly with the action of the increasing current, permits the pulmonary trunk and the left pulmonary arch to align (fig. 17, *a* to *d*). The resulting straight vessel is the main pulmonary channel and carries the blood from the right ventricle to the aortic arch until its distal end, the ductus arteriosus, becomes closed soon after birth. The proximal segment of the right arch, now part of the right pulmonary artery, is still present to mark more or less definitely the zone corresponding to the earlier point of origin of the pulmonary arches. An idea as to how long the vessel will serve this purpose may be obtained from the changes in dimensions of the divisions of the pulmonary channel which it subtends.

There are three territories of the arch system to trace into the later pulmonary vessels: the pulmonary trunk from the valves to the origin of the pulmonary arches, the proximal part of the left arch up to the origin of the left primitive pulmonary artery, and the distal part of the arch from the artery to its upper end (plate 2). They are to be compared, respectively, with the later distance from the pulmonary to the origin of the right pulmonary artery, the interval between the origins of the two pulmonary arteries, and the length of the ductus arteriosus (plate 3).

The segment from valves to right pulmonary artery elongates during the transition from branchial to post-branchial phase. It increases as rapidly as the body length during the earlier part of the post-branchial period. The interval between the two primitive pulmonary arteries remains for a time about equal to the earlier segment of the left pulmonary arch up to the origin of the left pulmonary. During the rapid descent, however, the two vessels approach, and before a length of 40 mm. is attained they come off side by side. There is also no increase in the length of the ductus arteriosus over the part of the left arch distal to the origin of its pulmonary artery. From the late branchial period to the end of the period under consideration the ductus decreases to one-fifth of its former extent relative to body length.

The fact that there is an increase in length in the region of the main pulmonary channel proximal to the two pulmonary arteries and a decrease in the portion distal to them suggests the possibility that the points of origin of the two vessels shift distally. At least while they are approaching each other, one or both of them must move through the wall. However, a large part of the increase in the length of the proximal division of the channel and the decrease of the ductus arteriosus occurs before the distance between the two pulmonary arteries begins actually to decrease. It is probable that at this time inequalities in longitudinal growth between these two terminal segments are the chief if not the sole cause of the shifting of the arteries. If this be true, in spite of the great decrease in length of the ductus arteriosus relative to body length in the late branchial and the early post-branchial periods, increase of its wall substance must still have been taking place, because in this period its circumference is greatly augmented. By the rapid decrease in relative length the ductus is approaching the small size, relative to adjacent parts, which it maintains throughout its later existence.

The innominate and common carotid arteries change rapidly into long trunks as the aortic arch shifts caudally from the branches of the carotids in the head region. As was seen from the description of the 14-mm. embryo, the primitive innominate must, from its general relationships, be largely an elaboration of the right half of the aortic sac (plate 3, figs. 37, 39). It appears at this time as a transverse tube. As the arch makes its rapid descent, this swings around to a direction nearly parallel to the long axis of the body. Due to the rapid expansion of the arch the innominate takes on the appearance of a branch. Measurements show that its length remains about constant in the embryonic part of the post-branchial phase, but that at its beginning there is evidently a period of elongation, since it is longer than the right half of the sac. Its diameter equals that of the sac. In a series from the post-branchial period it extends over a distance of about one and a half vertebræ and is consequently much longer relatively than at maturity. The chief precursor of the external carotid artery at the end of the branchial period is found to be coming off from the third aortic arch near its origin. At the time when the arterial territories derived from the third and fourth arches can be distinguished only by means of the vanishing remnants of the aortæ which lie between their upper ends it is found to have shifted out upon the third arch.

Kingsbury (1915*a*) has given a suggestive schema to show the influence of the widening metapharynx by the successive "moving out" of the first aortic arch upon the second, the second upon the third, and the third upon the fourth. If we substitute the primitive external carotid for a persistent proximal end of the second arch and recognize that the aortic sac itself elongates rather than that the third arch moves out on the fourth, the schema is still useful as emphasizing the association of the lateral movement of ventral parts of the arch system and the vessels which succeed them with the lateral growth of the pharynx.

The portion of the third arch territory proximal to the primitive external carotid on either side constitutes the primitive common carotid artery. This vessel, like the innominate, elongates as the aortic arch moves away from the pharyngeal region and swings into a more longitudinal position (plate 2, figs. 35, 36; plate 3). As it passes upward, however, it still bends laterally and ventrally. This is a result of the large size of the head at this time relative to the neck. It is not possible to say with certainty whether the entire territory derived from the third arch is ultimately to be found in the common carotid. As this vessel elongates, it is possible that it also is pulled downward relative to the external carotid, so that the early shifting of the latter vessel, which we can recognize up to the middle of the third arch, may be continued the entire length of the arch, or even farther; or it may be that such a degree of elongation is effected by the growth of the region derived from the proximal half of the third arch that the external carotid does not shift beyond the middle of the region derived from the arch.

The late history of the right fourth aortic arch and the part of the right paired aorta caudal to it is bound up in the development of the right subclavian artery. The interruption of the left paired aorta cranial to the fourth arch and distal to the subclavian permits a swinging around of the arch and the remaining division of the aorta until they are aligned with the primitive subclavian (figs. 13 to 16). These changes will be more fully explained in the history of the subclavian arteries.

TOPOGRAPHY OF AORTIC-ARCH SYSTEM AND ITS DERIVATIVES.

FUSION OF PRIMITIVE AORTÆ.

The components of the branchial-arch system undergo shifting in the direction of all three axes of the body. Of these, the longitudinal are of greatest extent, while the dorsoventral are inconsiderable and are confined chiefly to movements of the arches which have already been discussed. In their movements the aortæ are in several respects in contrast with the rest of the system and require separate consideration. The question of the lateral movements of the primitive paired aortæ is bound up with their fusion and the two subjects will be discussed together.

It is not to be expected that the paired primitive aortæ and their continuations, the primitive internal carotid arteries, should maintain equal intervals between each other in all their parts throughout development, since they extend almost the full length of the body and must be exposed to many growth displacements by surrounding structures. There is the possibility that they may come into contact or that they may withdraw from each another, and in fact both conditions are realized in different regions. The more striking changes in the position of the arch system were appreciated by the early investigators. Von Baer (1828) pictures the caudal movement of the heart accompanied by a development of a ventral segment of the first arch and a caudal deflection of the ventral ends of the others. He also shows how the blood-stream is shifted by the loss of cranial and the appearance of caudal arches. His (1880) noted that the caudal ends of the third and fourth arches took on a more cranial direction at their proximal ends and described the changing direction of their arterial trunk. Tandler (1902) distinguished three of the various types of wandering: (1) of the "conus," causing a relative lengthening of the aortic arch; (2) upward displacement of the ventral portion of the arches; and (3) caudal shifting of the fourth and pulmonary arches. Kingsbury's analysis of the migration of the pouch derivatives and the related blood-vessels will be referred to later.

The primitive dorsal aortæ during their earlier existence are separated from each other by a contact of nerve-tube, digestive tract, and notochord, which interpose between them a barrier of considerable width. This condition exists during the appearance of the earlier somites, but the nerve-tube and notochord gradually separate from the digestive tract, and mesenchyme moves in to fill the gap. Before long the two aortæ fuse in their intermediate portions which lie opposite the throacic segments. It was of interest to ascertain whether this is preceded by any actual approach of the vessels as a whole or whether only their adjacent walls draw near due to the increase in diameter of the vessels. A comparison on models was accordingly made between the interval separating the centers of the two vessels soon after their establishment and the corresponding distance in others in which the beginning of fusion was already indicated by the establishment of transverse communications. The distances divided by the magnification are for the earlier aortæ 0.18, 0.16, 0.12, 0.15, and 0.12 millimeters; at the time of fusion they are 0.24, 0.15, 0.22, 0.14, 0.13, 0.22, and 0.24 millimeters. At the earlier time the average is 0.146 and at the later it is 0.177+. Clearly, then, the aortæ as a whole do not approach each other. If the slight difference in the average distance between the earlier and later periods has any significance, it shows that the vessels are being carried slightly apart by the general growth of their surroundings. The models show that at this time the rudiments of vertebræ and nerve-tube are expanding, so that the aortæ are gradually taking on a medial position relative to their lateral borders. Though the vessels as a whole do not approach, their increase in caliber prepares for their fusion by approximating their adjacent walls.

The fusion in the aortæ occupies about a week. In its first stage the two aortæ are connected by transverse anastomoses and lie almost in contact. No. 2053, a 3-mm. embryo, is apparently the only recorded example of this condition in man. It has 4 cross connections, the largest being of nearly aortic caliber. Sabin (1917) figures a slightly more advanced condition in a 20-mm. pig embryo, in which about 15 are present, some of the more caudal being of large dimensions. Embryos No. 2053 to No. 2841, inclusive (table 1), all show the process of fusion still under way, though a long, more caudal region of continuous fusion is already present in each. Tortuous swollen capillaries or straight transverse channels of larger dimensions connect the two vessels just cranial to the fused region. Enlargement of capillaries connecting the arteries and the development of larger transverse communications from them are clearly in progress. The process is comparable with the development elsewhere of vessels from a capillary plexus. At the cranial end of the region of continuous fusion the unpaired aorta has the cross-section of a figure 8, often for a considerable distance. This evidently is the result of the recent blending of a series of transverse communications. Tracing caudally, a remodeling can be followed into a vessel of the usual form.

It has sometimes been assumed that the fusion of the aorta progresses cranially, and the spinal ganglia or vertebral rudiments have been used as points of comparison. This method leads to entirely erroneous conclusions. During the time in which fusion is taking place, the nerve-tube and cervical vertebral column are growing cranially relative to the pharynx, to which the aorta is moored by its arches. The relative position of the pharynx and these more dorsal structures also shows much individual variability in the fixed embryo. Whether this occurs in life was not determined. It is by a comparison with the immediate environment of the aorta, especially the pharynx and digestive tube, upon which, for the time being, it does not shift, that changes in the region of fusion may be recognized. The most cranial communication, or, in the absence of a communication, the end of the region of continuous fusion, is found in all but the youngest embryo, showing fusion to vary in the branchial period from a position of 3½ to one of 5½ body segments caudal to the pulmonary arch. For these measurements in embryos too young to show the pulmonary arch, the position later to be occupied by the arch was used in place of it and was recognized by the caudal pharyngeal-pouch complex. In the youngest fusion stage the most cranial communication is 9 body segments behind the sixth-arch region. The fusion is thus shown to begin more caudally and progress forward. The presence of a region of continuous fusion caudal to the territory where it is in progress in the next older embryos points to the same conclusion. A progress of fusion from an intermediate point forward and backward is in fact to be anticipated from the relation of the primitive paired aortæ just previous to the beginning of the process, as they show a region of closer approximation from which they diverge both cranially and caudally.

A period of fixity in the position of the cranial point of fusion of the aortæ relative to the pharynx begins with embryo No. 810 and indicates that fusion in a cranial direction has been completed. The bifurcation remains stationary until the aorta begins to shift caudally relative to the digestive tube and respiratory tract. The cause of the arrest of fusion here is to be found in the active separation of the vessels due to the pressure exerted by the expanding rudiments of the vertebræ and esophagus, between which they lie. As will be seen, a separation of this nature is not unique for this region, but is much better marked in a more cranial part of these vessels.

When fusion ceases, the bifurcation of the aorta is approximately opposite the seventh body segment. Relative to the nerve-tube, this point now lies more caudal than it did at an earlier period, due to the fact that a forward shifting of the cranial end of the nervous system relative to pharynx and aorta has been taking place more rapidly than the cranial progress of the point of fusion. In this way it comes about that in embryo No. 1075, for example, fusion, though still progressing, is opposite the second cervical ganglion, while in No. 810, in which the unpaired aorta is complete, it is opposite the seventh. In embryo Strahl 10, of the Keibel and Elze (1908) table, the aortic bifurcation is also given as opposite the second cervical ganglion.

The approximation of the walls of the primitive aortæ in an intermediate region results in the existence of caudal paired aortæ for a time after an unpaired aorta has become established. They are never long vessels, because, while they are extending caudally by their differentiation from a plexus, they are shortening at their cranial end by fusion. The paired condition, except possibly in the form of slender terminals, does not remain in this region, as at the cranial end of the embryo. In 4 and 6 mm. embryos only very short double vessels are present. In other embryos, ranging from 5 to 18 mm., the vessel is seen in section to be single, at least until it has shrunken to a very small caliber.

At the time the primitive aortæ are fusing they are continuous with paired longitudinal neural arteries which pass backward under the brain. In the formation of the basilar portion of these, which is terminated cranially by the region of the hypophysis, there is a fusion much like that of the aorta. There is left a segment in the forebrain region which, like the cranial end of the paired aortæ with which they are continuous, does not fuse. On the contrary, the two originally parallel vessels, each with its longitudinal neural and carotid parts, are carried away from each other to a greater or less degree in various regions, depending upon the activity of the lateral growth of the surrounding structures. In the late branchial period they have three well-marked regions of divergence. These reach their maximum opposite the middle cervical, the anterior pharyngeal, and the diencephalic regions, respectively.

In the cervical region in a 12-mm. embryo the paired aortæ lie in a little groove on either side at the plane of contact of the condensed mesenchyme of the vertebræ and the esophagus. It is apparently the expansion of these masses that has carried them apart. In the anterior pharyngeal region the great widening at the level of the first and second pouches has carried the aorta with it just as it has carried apart the first and second aortic arches on the ventral side of the pharynx. In the early part of the branchial period the first and second arches probably aid in the separation by holding the aortæ close to the lateral borders of the pharynx as it widens. The most cranial divergence of the paired vessels is in the territory of the longitudinal neurals and is the result of the growth of the forebrain, upon which they lie. On plate 2 (figs. 33 and 35) are shown the caudal and intermediate curves.

The regions of approximation of the aortæ are interesting, since they must correspond to territories of sluggish lateral growth in the environment. The more caudal of these is at the esophageal end of the pharynx, and therefore includes the attachment of the fourth and pulmonary arteries. It is not surprising that growth should be slight here, since this division of the pharynx, as is well known, shows many regressive features. It is of interest that it has not only affected the course of the aortæ because of this characteristic but, as previously seen, has prevented any considerable growth in length on the part of the more caudal aortic arches. The point of greatest approximation is just caudal to the pharynx, and it is exactly here that in the beginning of the post-branchial period the vagus nerve often leaves an impression on the aortæ as it curves around their outer surface in its caudal and ventral course to lungs and digestive tract. It may be that the nerve exerts a minor influence in maintaining a close approximation of the two vessels.

The proximity of the arteries just in front of the pharynx indicates that the mesenchyme here has not expanded laterally as fast as the pharynx behind and the forebrain in front. There has been some separation of the vessels such as one would expect as an expression of the tendency of any growing vessel to straighten its tortuosities through the action of hydrodynamic factors. It may be that failure of the artery to grow as fast as the nerve-tube and pharynx may have assisted in decreasing the curvature engendered by the longitudinal tension.

The last important lateral displacement of the aorta is the movement of the entire thoracic aorta from the mid-line to a position more or less completely over to the left surface of the vertebral body. A lateral shifting at the bifurcation begins to show itself as soon as the right paired aorta has begun to decrease in volume relative to the opposite vessel. In a 50-mm. fetus we find the aorta and the esophagus both in contact with the vertebra in the thoracic region and lying to either side of the mid-sagittal plane. While the lateral movement at its beginning is, to a certain degree, a mere straightening of the angle between the left paired and the unpaired aortæ, due to hydrodynamic forces or longitudinal tension resulting from inequality in growth between the aorta and its surroundings, most of the displacement is doubtless the result of pressure from the vertebral column above and esophagus below. It is the same process which already has been found to cause the separation of the paired aortæ in the region just cranial and is doubtless due to the same causes.

It is probable that the initial deflection of its upper end, due to the retention of the left instead of the right paired aorta, is the cause of its slipping to the left rather than the right. It is of interest in this connection that Krause (1868), in his discussion of arterial anomalies, states that the retention of the right paired aorta and right arch is frequently accompanied by a dextral position of the thoracic aorta.

The changes in position of the aortæ along the transverse axis may be classified, therefore, as of three kinds: (1) a further separation in the middle cervical and anterior pharyngeal regions, with which may be grouped a separation of the paired longitudinal neural arteries under the forebrain; (2) an approximation of contiguous surfaces due to growth of the vessels in caliber, chiefly in the thoracic region, which results in their fusion by means of anastomoses; (3) a translocation of the thoracic and abdominal aortæ toward the left side of the vertebral column, due to the pressure of structures lying dorsal and ventral to it.

MIGRATION OF AORTIC-ARCH SYSTEM.

LONGITUDINAL SHIFTING OF AORTA.

It would be easy to interpret the cranial elongation of the region of fusion of the aortæ as a cranial shifting of the unpaired vessels did not the presence of transverse communications and peculiarities in the form of the cranial end of the fused region point to its true nature. The true caudal shifting of the aortæ begins before fusion is complete; yet there is no reason for confusion of the two processes, since it is only the cranial end of the paired vessels that is at this time involved.

The moving of the aorta relative to its surroundings is progressive, beginning in the region of the first aortic arch, perhaps even farther forward, and gradually extending to more cranial parts of the vessel. There can be no doubt that it is due to a slowing down of the longitudinal growth relative to the pharynx and digestive tube, and this must first take place only at the cranial end, later manifesting itself in regions progressively more caudal.

The first indication of the caudal movement is the shifting of the third aortic arch from a position at the middle of its visceral arch to its most caudal border and the bending backward of its upper end before entering the aorta (plate 2, fig. 34). These changes are in turn followed by the other arches, until, in the late postbranchial period (plate 2, fig. 36), even the pulmonary arch, as we have seen, bends markedly backward at its upper end before entering the aorta. At this time, also, the shifting can be seen, by the sharp caudal bend of the proximal end of the more cranial cervical segmentals, to have proceeded beyond the pharynx (fig. 27). The more moderate cranial slope of the distal part of each of these arteries is due to another cause, namely, the shifting of the nerve-tube relative to the digestive tract, which forces an oblique direction not only on the part of these vessels but also on other structures of the body segments lying between them.

The aortic region involved in the shifting does not extend to the bifurcation until the end of the branchial period. There is therefore a considerable interval of time, beginning with the completion of the pulmonary arches and extending to the involution of the right pulmonary arch, in which the bifurcation is at rest. As has been said, it lies at this time opposite the seventh body segment. In the early branchial period, as the arches are freed for further backward progress by the caudal shifting of the derivatives of the pharyngeal pouches and the successive interruption of various parts of the arch system, the cranial portion of the unpaired aorta itself moves caudally relative to the adjacent digestive and respiratory organs and the more distant organs as well. This is best shown by the movement of the aortic bifurcation.

The paired aorta is followed in its descent by the left unpaired aorta only. The right, fixed by its subclavian branch, gives way in a short terminal segment between subclavian and bifurcation in a manner previously described. The process is just beginning in one 16-mm. embryo of our series, while in another of the same length the segment has stretched to a thread whose caudal termination shows the point of bifurcation to have descended from a region opposite the sixth cervical to the second thoracic vertebra (fig. 14). Thyng (1914) also finds it here in a 17-mm. embryo. It is probable that a rather common type of anomalous subclavian described in the adult indicates roughly by its origin the ultimate position of the region corresponding to the former bifurcation. It is characteristic of these anomalous vessels that they pass between vertebral column and esophagus and come off as the most distal branch of the arch, if, indeed, they do not arise from the descending aorta itself. Their existence is probably due to the fact that in their development they tap the main stream through the caudal end of the left paired aorta instead of making use of the right aorta and the fourth arch. Subclavians of this kind are found in the adult arising from the termination of the arch or the aorta as far caudal as the fifth thoracic vertebra. Since the subclavian and other branches of the arch shift cranially upon it, there is a possibility that the aortic wall derived from the earlier region of bifurcation lies still lower. Granted that the region of bifurcation in the adult lies at the sixth thoracic, the distance at this time between it and the ligamentum arteriosum, which succeeds the arterial duct, can not be more than the length of 3 body segments. In the branchial period the bifurcation lies about 5 segments behind the pulmonary arch, as determined on models of 10 embryos. There is, then, during development, a relative shortening of the part of the definitive aorta derived from the left paired aorta. Since it has been found that the distal part of the aortic arch, and probably also the distal part of the main pulmonary channel, lags in growth behind the proximal part during the early post-branchial period, it can now be said that the proximal part is in contrast to the aorta as well as to the distal part. This contrast in growth in the different parts of the chief arterial trunks leading from the heart is an interesting condition. Perhaps it should be regarded as illustrating an accelerating effect of increased longitudinal tension upon the growth of the arteries due to the descent of the heart.

It is well established that the caudal end of the aorta withdraws cranially. Since the two ends approach each other, there must be a region not far from the thoracico-abdominal boundary where there is little shifting in either direction.

No connected account of the shifting of the dorsal aorta is to be found in the literature. Goette (1875) has noted in the toad the retreat of the bifurcation point of the aorta, and Hochstetter (1890) finds it to be a regular occurrence in amniote development. Both observers fall into the error of regarding it as the result of splitting. Hochstetter further states that it results in the lengthening of the aortic roots, which term he applies to the paired aortæ caudal to the pulmonary arch. In man, at least, as has just been seen, their change in length is of the opposite kind.

SHIFTING OF ARCHES AND THEIR VENTRAL CONNECTIONS.

The movement of the dorsal aortæ is but part of the general descent of the cervical viscera into or towards the thorax. The heart and aortic arches not only share in the movement but are not exceeded by any other structure in the distance covered. The shifting of the aortic sac in the branchial period is slow and corresponds in amount to the aortic displacement at this time.

The sac moves backward along the floor of the pharynx, keeping pace with the appearance of new caudal aortic arches and the disappearance of the more cranial ones. Kingsbury shows that the apparent distance it has moved is enhanced by the active forward growth of the anterior pharyngeal region. It is not clear whether the movement of the sac at this time is a translocation of the entire structure relative to the pharynx or a mere growth backward of its caudal portion by the development of successive bays which take part in the formation of the arches as they appear one after another. The constant position of the trunk relative to the sac speaks for the former view. In the post-branchial period there can be no doubt of a translocation of the sac. The extent of this journey may be learned from the succeeding account of the migration of the fourth arch, since the two move approximately the same distance.

The movement of the more caudal aortic arches through their visceral arches has already been referred to. At the end of the branchial phase of development the arches present at that time are hooked around the structures which are apparently preventing their caudal progress. The pharyngeal pouches are in the way of the two more cranial arches, while it is the vagus and recurrent nerves which seem to bar the way of the pulmonary arches. After their development from the pouches the pharyngeal derivatives lose their connection with the pharynx, thus removing the obstacle to the migration of the third and fourth arches. The right pulmonary arch, being under less favorable conditions of current-flow than its mate, undergoes degeneration. The left persists and apparently forces the recurrent nerve of its side to elongate in order to give way to its advance.

Sufficient for an illustration of the shifting of the arches is the left fourth arch, which gives rise to a zone of the definitive arch. At its first appearance it is below the first occipital segment, while in the adult the definitive arch overlaps the second and third vertebræ, and the zone of the fourth is caudal to the summit of the arch. The fourth arch and its derivative tissue therefore shift the length of 13 body segments (figs. 22 to 25), but not nearly so far in relation to the immediate environment (the pharynx and digestive tube), for they are only about 4½ body segments apart when the arch reaches its adult position. The movement of the fourth arch and later its derivative territory in the definitive aortic arch is very rapid after the arches are freed from the pouches and vagus nerve, though somewhat slower than the descent of the cranial end of the aorta at this time. Between the developmental stages represented usually by embryos 14 and 18 mm. long it has moved the length of about 2 vertebræ, at the rate of about one-fourth of a vertebra a day.

The heart bears a changing relation to the sac and arches. In the first-arch stage the axis of the arterial end of the heart is dorsoventral as it reaches the base of the arches. Some of the truncus arteriosus is seen to approach the arches from their cranial side (plate 1, figs. 30 to 32). This condition persists until near the end of the branchial period, accompanied by great fluctuations of the proximal end of the truncus to right or left in different individuals, as also noted in the chicks by Kranichfeld (1914). In the succeeding period the trunk is reversed so as to approach the arch from the caudal side (plate 3, fig. 37). At the time the change takes place the division of these into aortic and pulmonary parts has permitted wide separation of the lower ends of the fourth and sixth arches (plate 2, fig. 36). The reason for this condition is not clear, but it is possible that as the long axis of the heart swings past the perpendicular the heart may crowd the pulmonary and aortic trunks, thus pushing them apart.

The ultimate reason for the movement of the aorta and arches, judged from the standpoint of individual development, is the same as already given for the retreat of the cranial portion of the aorta; in each instance it is the unequal growth of different organs or regions. The cranial expansion of the forward portion of the central nervous system and skeleton surpasses that of the aorta, the heart, and ascending part of the arch, together with certain structures lying caudal to them.

In following the breaking down and movements of the parts of the arch system various arterial changes have been described that were apparently in part due to a longitudinal pull produced by the descent of the heart and the aorta. It will be well to summarize these in order to better evaluate the influence of this factor on arterial growth.

The subclavians are forced to move along the arch, and the innominate and common carotids are swung around into a more longitudinal position. As their points of origin recede, the latter elongate rapidly, as do also the proximal portion of the aortic arch and probably the corresponding portion of the early post-branchial pulmonary channel. At an early stage in the descent, segmental arteries and 3 segments of the paired aortæ contract, atrophy, stretch into long filaments, and finally give way.

The complications resulting from the lateral movement of the fourth and sixth arches, due to their continuity with the aortic sac and the aorta, are interesting. At the beginning of the post-branchial period the two pairs of arteries are bent around the pouch complex and the vagus nerve, respectively, as though the heart and aorta were pulling them caudally against these structures. Later, we have a contrast between the history of the right and left fourth and pulmonary arches, apparently because in each instance the left vessel is now receiving a larger current, and thus can react more vigorously toward its environment than its counterpart on the right. Thus the left fourth moves caudally faster than the right. The left pulmonary, though sharing the pressure of the vagus in its caudal surface, does not undergo involution but is able to move caudally. Apparently it forces the vagus and recurrens before it. Certainly they do elongate the loop which held it so that it can descend to its ultimate position. Most striking of all is the caudal shifting of various vessels, as, for example, the definitive arch.

Among these various apparent effects of pull exerted by the descending heart and other structures, some, as, for example, the stretching out of vessels into filaments at a late stage of involution, are so obviously due to this cause that a discussion is unnecessary. In the early stage of interruption of the arches and the shifting of the arterial branches on their main stems the action of pull is difficult to establish with finality. Experimental evidence or its equivalent (the study of anomalies) is needed. In the sidewise progression of the definitive arch and pulmonary channel there must certainly be factors involved other than the caudal pull at their ends; yet there can be little doubt that in all of the arterial transformations the pull of the heart and shifting of the dorsal aorta are important factors.

A demonstration of the interplay of longitudinal tension of different confluent vessels has been seen each time a segment of the arch system gave way, and in these instances some of the arteries were showing merely the tension proper to them and entirely independent of a pull due to growth displacements. When one of three converging segments of the system underwent involution and its longitudinal tension weakened, the pull of the other two segments overbalanced it, thus stretching it and straightening the angle they formed with one another. This process indicates that under usual conditions the pull of any two such vessels counterbalances the tension exerted by the third.

A helpful analysis of the movement of the structures of the neck down to and into the thorax has been given by Kingsbury in his study of pharyngeal development. He describes their displacement to fill the space left vacant by the descending heart as a "growth eddy." He points out the complexity of the forces affecting the caudal shifting of the pharyngeal derivatives and expresses his belief that the mesenchyme also moves downward. This is a very appropriate characterization of the movement in its most salient features. It implies, however, a passivity of the structures coming in to occupy the space which probably is not the exclusive condition in any one of them. The arteries seem to act rather vigorously upon their surroundings during their descent. This is indicated by the differences in the relation of the right and left pulmonary arches to the vagus and recurrens nerves which have just been described. The fourth arch also gives evidence of helping to move the structures which earlier barred its way. In the 14-mm. embryo a pharyngeal-pouch derivative is found on each side, lying in contact with the caudal surface of the fourth arch, although one of them has moved a vertebra length more caudally. The larger and more rapidly moving arch has apparently aided in the movement of the pharyngeal tissue which lies in its path. Kingsbury has pointed out that the shifting of even the pharyngeal derivatives is in part due to their own outgrowth.

In a succeeding discussion, based on models prepared to show the rudimentary ribs and sternal bands as well as arteries, it will be seen that the changes in the ribs are also somewhat suggestive of material in the growth eddy.

RELATION OF MIGRATING ARCH AND ITS BRANCHES TO SUPERIOR APERTURE OF THORAX.

The approach and entrance of the heart and its arterial vessels into the thorax is characterized by a nice coordination between the time of arrival of the heart and aortic arch at the thorax and the coming together of the ribs and sternum in front. Within an interval of 10 days the upper ribs on each side, capped by their sternal bands, have completed the thoracic arch (figs. 18 to 25).

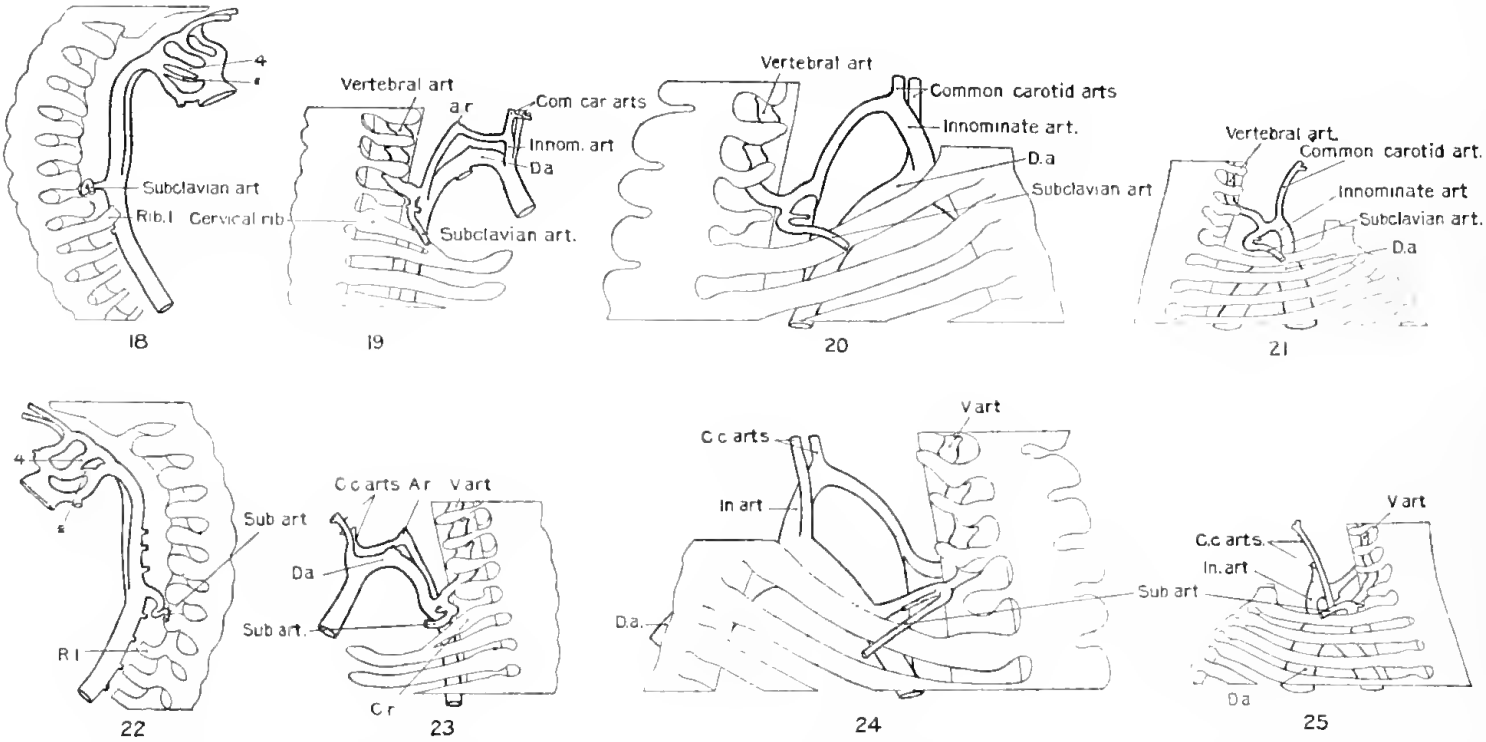

FIGS. 18 to 25. The descent of the fourth aortic arch and the definitive aortic arch into the thorax, shown in relation to the cervical vertebræ and ribs. Asterisk, so-called fifth aortic arch; 4, fourth aortic arch; *d. a.*, definitive aortic arch; *R. 1*, first rib; *in. art.*, innominate artery; *c. r.*, cervical rib; *c. c.*, common carotid; *v. art.*, vertebral artery; *a. r.*, remnant of segment of dorsal aorta, interrupted between third and fourth aortic arches; *sub. art.*, subclavian artery. In figures 20 and 24 the sternal bands are not yet in contact above and the definitive aortic arch has a large radius of curvature. In figures 21 and 25 the bands have met and the arch has become sharply bent by the swinging dorsally of the heart.

In the 14-mm. embryo the ribs are slightly concave cranially and nearly straight in the transverse plane. By the time the embryo is 24 mm. long they have grown forward and around so that the sternal bands capping their tips are fusing in the mid-line. Three models between the earliest and latest stages of this series show the rib as a whole sloping cranio-ventrally, but at 24 mm. they are once more horizontal. Between the earliest and latest stages the rib elongates about threefold. It grows forward and medially, reshapes itself, and expands. It gives the appearance of passively swinging around to fill the space left vacant by the heart, and this effect is enhanced by its free end swinging downward as well as forward. There is, however, as above indicated, an expansion and a reshaping of its substance, not a participation in a passive eddy movement. It is not improbable that the mechanical influences of the descending heart, which cause the other structures to migrate, have a formative effect upon the growth of the ribs.

Since the upper ribs move in with other structures to fill the gap left vacant by the heart, the close correlation in time between descent of the heart and closure of the upper thoracic wall becomes understandable. Arterial arrangements which would have tended to crowd the superior thoracic aperture are gradually altered as the heart sinks into the thorax. The movement of the innominate and the left subclavian near to the summit of the aortic arch is of this nature. There is also the bending of the arch so that its dorsoventral diameter is decreased. Most important of all are the changes in the position of the heart. At the beginning of the period, in the 14-mm. embryo, the direction of aortic and pulmonary trunks indicates that the apex of the heart is pointed well forward and that much of its bulk lies ventral to the tip of the ribs. In a 20-mm. embryo the superior thoracic aperture has become closed, and in correlation with this the definitive arch has sunk below the level of the aperture and the heart has swung upon it as a hinge, so that it points more caudally. To have arrived at this position, the apex of the heart must, within a week, have not only moved with the arch at the rate of half a body segment a day but, because of its caudal swing, must have exceeded the arch considerably in speed.

INDIVIDUAL ARTERIES.

PULMONARY ARTERY.

In tracing the development of a blood-vessel its history remains incomplete until one recognizes not only the capillary plexus from which it is derived but also the source of the angioblastic mass giving rise to the capillaries in the event they do not arise, directly from an open vessel. In the case of the primitive pulmonary arteries of higher vertebrates, which later evolve into approximately the right and left branches of the definitive pulmonary artery, the manner of origin of the angioblastic material seems to be well established. Fedorow (1910) and Bremer (1912) trace it in the rabbit and guinea-pig to paired growths from the aortic sac which they believe grow out to form a net from which the pulmonary arch is in turn derived. These authors figure reconstructions of the net. Buell (1922), in the most recent contribution to the development of the pulmonary vessels, which appears in this volume, also traces the angioblastic material in the chick to this source. Huntington (1919) is not in agreement with these observers, as he derives it in the cat from the dorsal aorta. The method used by him in making his preparations is not clear, and the formations figured are too unlike the findings of other writers to constitute satisfactory evidence in support of such a contention. There is also disagreement as to the form and position of the earliest pulmonary vessels themselves. Bremer and Fedorow find that a slender artery first extends caudally from the aortic sac and then becomes connected midway with a channel to the dorsal aorta. The free end of this vessel on either side constitutes the primitive pulmonary artery; the proximal part, together with the connection with the dorsal aorta, forms the pulmonary arch. Buell's injections of the chick show that the primitive pulmonary artery arises in this form not from the ventral-arch sprout but from the aortic sac, and that it is secondarily carried up upon the arch by the rapid development of the ventral end of the arch. Huntington describes in the cat the development of an isolated channel from the pulmonary plexus which is later tapped by a short outgrowth from the pulmonary arch to form each primitive artery.

The observations to be given on the development of the human primitive pulmonary arteries were made for the early stages from the study of cross-sections alone and in larger embryos by the preparation of models.

Embryos in which the vessels are well distended show that the earliest pulmonary plexus is already present at the time of establishment of the fourth arch. At this time the endodermic lung-bud is connected with the esophagus for most of its length. A net of large capillaries and of angioblastic cords extends backward from the aortic sac under the caudal pharyngeal-pouch complex and for a short distance up its posterior surface along the course of the later pulmonary arch. From its caudal extremity this plexus also sends a less developed net a little distance along the under surface and side of the laryngeal rudiment and common tracheo-esophageal mass. At this time large capillaries can be seen extending down as a plexus from the aorta into the esophagus. Later, there is a continuous tracheo-esophageal net of uniform character due to the meeting of the two earlier territories.

The earliest primitive pulmonary artery that could be recognized with certainty by a study of cross-sections was in an embryo with well-distended vessels soon after the completion of the fourth aortic arch. It could perhaps be demonstrated still earlier by total injections. At this time the lung-bud was of considerable length and the primary lobes well elongated. A slightly later stage is shown on plate 2, figures 33 and 34.

A search was made for an arterial rudiment in the tracheo-esophageal groove independent of the pulmonary arterial outgrowth from the aortic sac, such as Huntington believes to exist in the cat. The result was entirely negative, though 6 embryos of the proper stage in excellent state of preservation and with moderate vascular distention were examined. The region showed no vessel of greater than capillary caliber until the extension from the sac-vessel had reached into it. Some rather larger endothelial tubes were found on the dorsal surface of the lung-bud bifurcation, even before the fourth aortic arch was complete, but when followed in their development they proved to be the rudiments of the vein shown in figures 33 and 34. Buell has seen this earlier in his chick injections and terms it the "cephalic pulmonary tributary." He finds it to be a transitory vessel.

The succeeding history of the primitive arteries is connected with the transformations of the pulmonary arch. The study of our series led to the same conclusions as held by Bremer and Fedorow as to the developmental relations of the two arterial channels. Embryos in good histological condition showed the presence of a pair of arteries extending backward from the aortic sac before the pulmonary arch was complete (figs. 33 and 34). The arch was formed by the establishment of a connection between this vessel and the dorsal aorta in the plexus lying caudal to the caudal pharyngeal complex. Just after the arch has completed its channel, its divisions proximal and distal to the pulmonary artery join at a marked angle. As the arch increases in caliber this disappears in a continuous curve.

The next important change in the pulmonary arterial vessels is the interruption of the right arch which has been already described. As the distal portion of the arch degenerates, the angle between its proximal division and the right primitive pulmonary artery is gradually lost, and the segment from now on functions exclusively as the proximal end of the artery (fig. 17, *c*, *d*). The mechanism of these changes has already been sufficiently discussed. The interruption of the arch also similarly allows a straightening of the angle at the junction of the pulmonary trunk and the left arch. Since the origin of the right pulmonary is at the plane where these two territories are confluent, it is carried to the left, and the artery is made to pass obliquely across the trachea and also to sink ventrally, so that it is forced to curve slightly around the ascending limb of the aortic arch.

In the further history of the pulmonaries we must distinguish clearly between the earlier post-branchial phase and the period of rapid descent of heart and large vessels. Measurements on models of a series of 11 embryos showed that the distance between the origin of the two vessels remained nearly constant and equal to its precursor (the proximal segment of the left pulmonary arch) until the period of rapid descent. Then there was a quick approach, so that in a 24-mm. embryo, with the upper part of the sternal bands fused, the two vessels were almost together. They were found in contact in fetuses of less than 40 mm. in length (fig. 17, *e*). The rapid approximation of the vessels and their final meeting can not be explained by the slowing ingrowth of the wall between them. As in the movement of the innominate and subclavian, there must have been actual progression of the vessels at their origins through the substance of the wall of the parent vessel.

Bremer (1902, 1909) has made an interesting suggestion as to the nature of the approach of the two pulmonary arteries, based on the observations at later stages in the formation of the adult pulmonary artery and its branches in a number of mammals. He believes that the pulmonary stem undergoes torsion, and that the approach of the two arteries is due to their fusing with it as a result of their proximal ends being wrapped around it. In his second article on the subject, referring to man, rabbit, sheep, and cow, he says:

> "With the growth of the truncus pulmonalis and its torsion about the bulbus aortæ the two pulmonary arches are wound, as it were, around the bulbus and their walls brought into contact are absorbed so that the truncus pulmonalis grows longer at their expense, the point of bifurcation moving continually further from the heart. The left arch being the outside one in this rolling-up process receives the most pull, becomes the straighter and therefore the larger vessel and is shortened more rapidly. As a result

the truncus pulmonalis reaches the left pulmonary artery while the right is still seen arising from the right arch some distance dorsal to this point."

It can be seen from the described changes in the relative length of the parts of the main pulmonary channel incident upon the formation of the ductus arteriosus, that the interval marked off by the two pulmonary vessels moves distally on the pulmonary channel. This is as one would expect if there were such a wrapping of the pulmonary arteries around it as Bremer describes. As an argument for rotation and wrapping, however, this last circumstance loses much of its force when it is recalled that the segment on the aortic arch between innominate and left common carotid also moves distally on the arch as it grows shorter. Yet there is no reappearance of rotation of the arch nor has such been claimed. The relations of the arteries to the parent stem are not what one would expect were they brought into contact with it and fused as a result of its rotation. In the period preliminary to the rapid descent the primitive pulmonary artery comes off ventro-medially from the stem instead of from the right side, as one might expect from the source of this part of the vessel. The left pulmonary has retained its primitive ventromedial origin. After the descent the two vessels come off a little more ventrally. This change in the position is of a kind that might have been caused by a slight torsion of the stem. To produce wrapping, however, they would have to be carried around much farther to the left. One would also expect their right side to be bent over against the main stem. Instead of this, the two arteries are nearly radial to its cross-section (fig. 17 *d*).

We do not know whether the movement of the two pulmonary arteries taken together is due to the shifting in the wall of the pulmonary stem or whether it results from a retardation in the growth of the pulmonary channel distal to them, as was earlier pointed out. The approach of the two vessels is certainly due to a movement of the origin of one or both through the substance of the wall of the main pulmonary stem. It is probable that longitudinal tension of the arteries exerts an important influence in this process, and this, perhaps, may be caused by the elongation of the lung rudiments. It is of interest that the curve of the right pulmonary around the aortic stem is straightened out by the time the two pulmonaries have met, and it may be that the approach of the origin of the two vessels is entirely due to the shifting distally of the origin of this vessel in the course of its straightening.

By the coming together of the two primitive pulmonary arteries the organization of the pulmonary vessels at the end of prenatal development is closely approached. There is a pulmonary artery giving off a right and a left branch and a ductus arteriosus connecting the latter with the aorta. The pulmonary artery is formed from material derived from the pulmonary trunk and more or less of the left pulmonary arch of the branchial period. The arterial duct owes its origin, in large part at least, to material developed from the distal part of this arch. The two pulmonary arteries are morphologically dissimilar to the extent that the right has a zone produced from the proximal end of the right pulmonary arch, while the left has no corresponding region derived from an arch.

SUBCLAVIAN ARTERY.

The development of the subclavian artery in its early stages is a convincing illustration of the capacity of the blood-stream to take over and remold into a unit various vascular channels as the need arises. Though it shows great plasticity and inconstancy at this time, yet later, when it is more mature, it meets with surprising success in maintaining itself when exposed to stress due to the shifting of the surrounding organs upon one another.

In the development of the early arterial supply to the limb-bud there are considerable differences between the bird and the mammal, although at such an early period one might with reason anticipate a close correspondence. Rabl (1907), who has studied the condition in the duck by graphic reconstructions, describes a period in which there is an increase in the number of small arteries lying in successive intersomitic spaces and passing from the aorta to the plexus of the early limb-bud. Evans (1909*a*) confirms this in the chick by injections, and figures as many as four vessels passing to the bud plexus along the planes of separation of the body segments. He finds that at a still earlier period, before the 34-somite stage, there are already distinct arteries of supply to the plexus from the aorta, but they are not segmental. The vessels, both of the non-segmental and the segmental types, are referred to as subclavians, but most of them have so little to do with the development of that artery that it will be best to designate them merely as limb-bud arteries.

In the human embryo, Keibel (Keibel and Elze, 1908) described two limb-bud arteries from successive segments at the time of the first appearance of the vessel. Evans (1908) also found a similar case, though not from the same two segments. Göppert (1909) figures, from graphic reconstructions of the mouse embryo, both segmental and non-segmental limb-bud arteries. He also claims that the segmental type can be traced as independent channels well within the bud and discusses their changes. Since a segmental arrangement here implies a segmentation of the substance of the limb, there is little probability that he is correct. Woollard, in this volume of the Contributions to Embryology, gives very complete illustrations of both arterial and venous vessels of the early limb-bud from injections of pig embryos. He does not find, at any time, more than one distinct artery to the limb-bud. It is a branch of a segmental or, more precisely, intersegmental artery and passes to the limb through the intersegmental space. There are short twig-like vessels in other intersegmental spaces which come off from the segmental artery and quickly go over into a plexus lying largely in the intersegmental spaces and connecting them with the limb-bud plexus. As the embryo enlarges, these secondary connections do not increase in proportion to the single limb-bud or primitive subclavian artery and soon become negligible. Woollard does not find the non-segmental limb-bud arteries of Göppert. His study throws doubt upon the existence of both multiple segmental and earlier non-segmental limb-bud arteries in mammals, though the possibility of a certain amount of individuality in this regard in the different species must not be lost sight of.

The earliest vessels to the limb-buds that I was able to recognize in the human embryo (4 to 6 mm. in length) were found in specimens in which the fourth arch was present but the sixth was not complete. The anterior limb-buds were as yet but slight elevations from the general body-wall; they had not been penetrated by the outgrowing nerves, and they contained a nearly homogeneous vascular plexus. One definite artery was present for each forelimb bud, and this lay in an intersegmental space. Enlarged channels could frequently be traced a greater or less distance from the segmental arteries in other intersegmental spaces toward the plexus of the limb-bud. Their appearance in sections favored the interpretation that they usually broke up into a plexus at a greater or less distance from the limb-bud and were thus similar to the twigs described by Woollard. It seems not unlikely, in some instances, that there were also one or more secondary channels traceable as definite vessels to the plexus, though it was not possible to prove this from the study of sections on account of their small, almost capillary caliber. The second subclavians in human embryos described by Keibel and Evans are probably of a similar nature, but the existence of such vessels can be proved only in sections cut very favorably and probably will not be established without the use of *in toto* preparations of complete injections.

In slightly older embryos it was impossible to trace the primitive subclavian into the limb itself where it continued as the primitive brachial artery. At this time the subclavian is found to be coming off from an outpocketing of the aorta, which at the same time gives rise to a dorsal segmental branch. Later, this connection elongates into a definite vessel (the stem of the primitive segmental artery) in the manner described by Rabl (1907) and Sabin (1917) in other forms.

In a model of a 5-mm. embryo the advance in differentiation of the limb-bud is marked by the entrance of the spinal nerves into its base and is reflected in the vascular system. A venous marginal sinus draining into the umbilical vein, as described by Evans (1909*a*, 1909*b*) in the pig and chick, is now well defined. The segmental branches of the post-caval vein can be followed between the spinal nerves to their origin in the brachial plexus. They are accompanied by branches of the segmental arteries. The primitive subclavian is a branch of the seventh cervical segmental artery. Within the body it lies between the sixth and seventh nerves and passes over the dorsal surface of the plexus and soon breaks up into capillaries.

The model of the limb-bud of a 7-mm. embryo shows the limb considerably elongated and containing an axially placed nerve mass which is already giving off branches. The primitive subclavian has now become surrounded by the brachial plexus. This seems to be due to the growth of neurons across its dorsal surface to complete a canal about it, not to any development of a new arterial channel through the plexus. The brachial artery is divided into three terminals. At 14 mm. the primary branches of the nerves and arteries are well developed in the arm. Not only the radial, ulnar, and interosseus are present, but digital branches as well. Their development was not followed.

The model of a 5-mm. embryo, in which a primitive subclavian was well developed, showed a slender channel passing from subclavian to brachial artery over the dorsal surface of the plexus. Göppert (1909) explained various loops passing around and through the plexus as resulting from anastomoses between a series of limb-bud arteries and their brachial continuations in the limb-bud. Since the evidence of a limb-bud artery in more than one space is the exception in man and was not found to occur in the pig, we must regard such accessory channels as the result of a chance enlargement of a part of the general plexus.

At the beginning of the post-branchial period the primitive subclavian has thoroughly incorporated the territory derived from the stem of the earlier segmental from which it arose, and thus the latter has entirely lost its identity (figs. 11, 12). The serial position of this vessel can at first be told by its relation to the body segments. After its identity is lost in the subclavian, its place in the segmental series may be inferred from the vertebra into which the vertebral artery enters. A series of 15 embryos were examined to learn how constantly it arises from the seventh cervical segmental. The specimens ranged from 4 to 24 millimeters in length, and in the youngest the fourth arch had just been completed. In 2 of the younger ones the subclavian comes off from the sixth cervical segmental artery, while in the others it comes off from the seventh. In 1 embryo of the post-branchial period both vertebrals enter the transverse foramen of the rudimentary fifth cervical vertebra (plate 3, figs. 37 to 39); in another the right vertebral enters the fifth and theleft the sixth. In the other 4, both vertebrals enter the sixth transverse process. The frequency of variation from the origin of the primitive subclavian from the seventh segmental noted here and of the corresponding entrance of the vertebral into the sixth vertebra is far greater than is encountered in adult life. Since 2 of the embryos were in a very early limb-bud stage, when its supply is scarcely more than a plexus, it may be that, had death not occurred, a readjustment might have soon taken place by the enlargement of a twig in the interspace usually occupied by the seventh segmental superseding the aberrant subclavian. In 1 of these embryos there was an artery extending nearly to the limb-bud in the usual position. Whether or not this is the true explanation of the occurrence of these early aberrant vessels, the other embryo, which is in the early post-branchial phase with the vertebral already formed, was apparently in the course of a return to a usual type in an entirely different manner. The vertebral has a double connection with the subclavian by way of both the sixth and the seventh segmental arteries. The position of the subclavian shows that it arises from the sixth segmental artery. On the left side the subclavian slopes cranially as it leaves the aorta. It is evidently being carried along by the shifting of the aorta, which just at this time has become accelerated. It may be that this would have resulted in a breaking of the connection of the vertebral with the subclavian by way of the sixth segmental artery and an enlargement of the latter by way of the seventh, thus restoring the usual condition. Since the right subclavian will also after a time be drawn caudally, a like readjustment of the vertebral on this side would have been possible.

The changing relation of the primitive subclavian to the aortic bifurcation is significant in its development. Were the right vessel to come off below, it would arise from the descending aorta in the adult. For a time after its appearance it was always found to arise below the bifurcation. The distance of the origin from the bifurcation is not great; but because of the irregularities in the position of the bifurcation at the time when fusion ceases, it is somewhat variable, and it is not unlikely that an occasional subclavian may arise from a paired aorta even at the time of its first appearance. The subclavians do not share in the descent of the aorta but move cranially upon it as it descends. As a result, they are each soon found to be coming off from the paired aorta of its side. In 4 embryos of the branchial period, in which the pulmonary arch was complete, the subclavians of 3 were already cranial to the bifurcation. In all of 8 slightly older specimens the subclavians came from the paired aortæ. Important in the shifting of the subclavians on the aortæ is the mooring of the vessel by its large vertebral branch which is passing into the rudimentary vertebral foramen of the sixth cervical vertebra. Its comparatively large size is also a factor, for, as will be seen in the discussion of the development of the vertebral arteries, the segmental arteries lying cranial to the subclavians, though having a similar relationship to the paired aortæ at this time, are not able to move upward on these vessels and so are stretched and finally interrupted.

In the post-branchial period the asymmetrical changes in the paired aortæ involve their branches (the subclavians), and the history of the latter becomes very different on the two sides. On the left the subclavian continues its movement along the aorta; on the right this is rendered unnecessary by the interruption of the right paired vessel close to the bifurcation. This also makes it possible for the right fourth arch and the paired aorta caudal to it to become the proximal end of the right subclavian, since there has already been an interruption of the right paired aorta cranial to the fourth arch. A decrease of the right dorsal aorta to a diameter equivalent to the subclavian has taken place before it was separated from the aorta at its caudal end. Because the more cranial break occurs considerably earlier than the caudal, the sharp angle between the arch and aorta has gone and the two vessels have formed a nearly straight channel before the aorta has lost its lumen at its distal end. This distal interruption of the aorta is accompanied by abrupt changes in the arterial channel where the more primitive subclavian enters the aorta. Just before the wall of the involuting segment weakens, and while it is exerting its maximum tension at this point, due to the pull from the shifting aorta, the subclavian and aorta meet at a downwardly directed acute angle. The degeneration of the wall of the disappearing aortic segment releases its tension on the point of union of subclavian and dorsal aorta, thus permitting this point to withdraw upward until the primitive subclavian passes obliquely upward to go over into the aortic segment by a moderate curve (figs. 14, 15, 19). By the time the costal and sternal rudiments have swung toward one another and fused in the mid-line, the curves have disappeared and the fourth arch and aortic territory of the subclavian are no longer distinguishable. In this manner a channel of great tortuosity is reduced to a nearly straight segment at a time the embryo is increasing only about 30 per cent in length. It must be accomplished by a great slowing in the growth of its wall. Later, the forward and medial growth of the ribs produces another marked curve just distal to the origin of the vertebral artery, so that the part of the subclavian proximal to the rib forms a letter U (fig. 20). This is due to the fact that the part of the vessel distal to the vertebral artery shares the movement of the ribs, while the proximal portion is held to its original position by the vertebral artery and other structures. The entire subclavian now lies in nearly the same transverse plane, since its origin is about level to the upper surface of the first rib.

The left subclavian stem in the early post-branchial period continues its earlier ascent along the aorta and on up the aortic arch. It was seen, in following the development of the arch, that this is truly a process of moving of the subclavian relative to the wall of the parent trunk and not a mere shortening of the aortic segment proximal to its origin. From the relation of the proximal end of the vessel to the definitive aortic arch, just when the rapid descent is reaching its completion in embryos 21 to 24 mm. in length, it is clear that this shifting is not rapid enough to compensate entirely for the aortic descent. At this time the subclavian is still separated at its origin from the left common carotid by a considerable segment of the arch, with which it makes an acute angle. In Jackson's models of a 31-mm. and a 65-mm. human embryo, copies of which are manufactured by Hammar, the subclavian is shown already lying close to the left common carotid artery (figs. 16 and 22 to 25).

BASILAR ARTERY.

In the earliest work on the development of the basilar and vertebral arteries, His (1880) made the error of regarding the two vessels whose fusion produces the basilar artery as vertebral in nature and fixed this idea in the literature by designating them the cephalic vertebrals. Macalister (1886) concluded, apparently from a study of the chick, that these vessels are not homologous to the vertebrals but correspond to the system of vessels running along the surface of the nerve tube. De Vriese (1905) confirmed this in the rabbit. The so-called cephalic vertebrals of His are continuous with similar vessels along the anterior surface of the spinal cord. Sabin (1917) also has studied these vessels by the injection method. In chicks of about 27 somites she traced them from the subthalmic region to the caudal end of the cord and termed them the *longitudinal neural arteries.* She finds that they arise by the meeting of a prolongation of the internal carotid with a cranial extension of an anastomosis of segmental arteries under the midbrain. De Vriese claims that very early branches are found which extend from the proximal part of the internal carotid up to a point on the two neural arteries cranial to the part formed by anastomosis from the segmental arteries. It is possible that these also take part in the anastomosis, giving rise to the caudal part of the longitudinal neural arteries.

The character of the paired longitudinal neural arteries is apparently somewhat dissimilar in different species and perhaps also between the cerebral and the cord regions in the same type. Sabin describes them as originating in the pig and the chick in the form of a plexus on either side of the subthalamus and more definitely as a pair of single channels along the rest of their course. In her figures they appear not as a thickened band of plexus but as well-defined vessels. Sterzi (1904), using injections of the cord of the chick, described them as definite channels, but he did not find so great a differentiation in a number of mammals which he studied. His figure for the sheep shows them as rather large and approximately straight vessels in a thick plexus.

Evans (1909*a*) published a very full series of figures from injections of the cord of the pig, showing the paired condition and successive stages of fusion. Here we have to do as frequently with two or three vessels side by side as with a single enlarged vessel of the plexus. Taken together, these findings seem to imply specific differences in mammals in respect to their being supplied with continuous arteries running under the nerve-tube or by longitudinal tracts made up of irregularly succeeding segments of vessels which are in some places double or even triple.

The caudal connections of the paired longitudinal neural arteries in man were described by Zimmerman (1889) as the hypoglossal and first cervical segmental arteries. Since Evans (1912), by tabulating the segmental arteries in man in order of their appearance, finds the first occipital to appear first and the other segmentals in the order of position, there can be little doubt, in the light of the observations of De Vriese and Sabin on the development of the longitudinal neural arteries in other forms, that all the cranial members of the segmental series, as far back as the first cervical, contribute by anastomosis to the formation of the longitudinal neural arteries.

De Vriese (1905), in her study of the rabbit embryo, has given the only description of the formation of the basilar artery from the paired longitudinal neurals. She states that the neurals first form strong transverse anastomoses and that the segment of the right or the left tract between two successive anastomoses disappears, so that the basilar is made up of successive segments taken irregularly from the right or left tracts. Sterzi (1904) earlier described and pictured this same process in the formation of the anterior spinal artery of the cord in the chick.

The preceding discussion of the literature shows that the longitudinal neural artery in mammals varies from a zone of enlarged vessels in a plexus to a single continuous channel. Its nature and relation to the development of the basilar in man have not been described.

Two models were made covering the time of formation of the basilar, and sections of earlier embryos, before the 22-somite stage, were studied. In a beautifully preserved 4-mm. embryo, in which the third arch had just become complete, it was possible to distinguish longitudinal vessels in the region of the future basilar artery. At this time there were already paired arteries continuous cranially with the internal carotids and caudally traceable to the posterior third of the hindbrain, where they were lost among capillaries. They were not much larger in diameter than the vessels of the surrounding plexus and showed their probable origin from it by numerous lateral branches and a slight tortuosity of course. They were most closely approximated in the medullary region, where they were separated by a distance equal to about six times their diameter. In a still earlier embryo, which had 22 somites, no vessels could be identified in the plexus under the brain. It is probable, however, that the injection method would have shown at least parallel tracts of enlarged channels serving as their precursors, since Sabin found this condition in a 19-somite pig.

The paired vessels were found to be connected for the first time by anastomoses in the late fourth-arch stage. These are but slightly enlarged capillaries and are most advanced somewhat caudal to the ear vesicles. By this time the cord has a well-developed tract of enlarged capillaries on each side, which limit the corresponding plexus ventrally and mark off a ventrolateral non-vascular band along the cord. This arrangement resembles the condition found by Evans on the upper surface of the brain in the formation of the superior sagittal sinus.

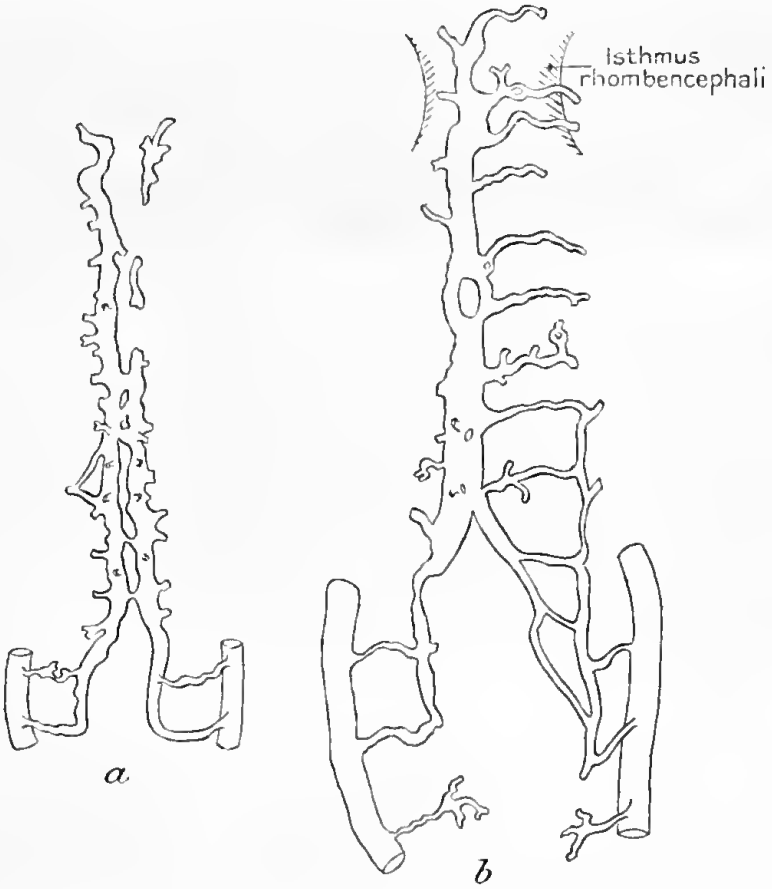

FIG. 26, *a* and *b*. Successive stages in the formation of the basilar artery, partly by connecting up of irregularly alternating segments of the right and left longitudinal neural arteries and partly by a coalescence of the two. *a*, embryo No. 2841, 4 mm. in length; *b*, embryo No. 810, 5 mm. in length.

In a 4-mm. embryo (No. 2841) the formation of the basilar is well under way and the sixth arch is present. In figure 26 *a*, drawn from a model, two strong anastomoses can be seen about opposite the otic vesicle and some slender ones lying more caudally. Behind the strong anastomoses the right longitudinal artery has enlarged but the left is still uninterrupted. Cranially the left is not only the weaker but has lost its continuity. This enlargement of irregularly alternating segments of the two longitudinal arteries is what De Vriese and Sterzi found in other forms.

In the model of a somewhat later stage we find the basilar artery as a single vessel through most of its extent, though one large and several smaller islands are present (fig. 26 *b*). Between them it lies too far midway of the position of the previous longitudinal arteries for one to be confident that it is entirely made up from segments taken over from the paired vessels. The presence of small islands in the center of its caudal portion is also strong evidence that this portion was formed by coalescence of the two arteries. The dorsal aorta, which was found unquestionably to coalesce, had similar islands. The fact that the small islands are also in line with the large anterior island at the hypophysis, which undoubtedly has on either side unchanged segments of the original paired longitudinal vessels, also speaks for this method of formation.

The longitudinal neural arteries are described as approaching each other before the formation of the basilar. The distance between their axes was compared in a series of 7 embryos, from the time of their appearance to the establishment of the basilar, to find whether this actually takes place, since a lateral movement of vessels as immature as these seems highly improbable. The measurements were made on models and Edinger projections and the values thus obtained divided by the magnification. The interval between the axes of the vessels was found to remain constant. It was therefore only their adjacent walls that approached, due to the result of their increase in diameter just as found in the fusion of the paired aortæ.

In the early sixth-arch stage the earlier history of the basilar is still indicated by the presence of occasional islands and an irregular, dorso-ventrally compressed form. In a 12-mm. embryo, with subclavian well established, this condition had passed. Tardiness in fusion was shown in a 14-mm. embryo by the persistence of the paired condition for a considerable distance back of the isthmus. It is in this manner that partly double adult basilars are formed.

The connection of first and second occipital segmental arteries and of more cranial branches from the dorsal aorta with the longitudinal neurals is to be expected at an earlier period than is represented in our series. It was found that at the time of formation of the basilar artery the hypoglossals, as well as the first cervical segmentals, connected the dorsal aorta and longitudinal arteries, though this is later than they have previously been observed. Since, in two instances, the hypoglossal vessels were very slender and were lost in a capillary plexus for a short distance, they were evidently just about to lose their identity. The first cervical segmentals were of considerable size and clearly served to supply the blood to the paired longitudinal arteries in their late stage and consequently are the chief caudal connection of the basilar.

The continuity of the paired longitudinal neural vessels of the cranial region with the longitudinal tracts of the plexus on the spinal cord was readily distinguishable before the time of formation of the basilar artery. It could not be seen from the examination of cross-sections that a pair of definite vessels superseded the tracts on the cord either before or after the establishment of the basilar.

VERTEBRAL ARTERY.

The formation of the vertebral artery is the most perfect example of the evolution of a longitudinal arterial channel from the segments of a series of transversely running arteries and the anastomoses between them. While the internal mammaries and the inferior epigastrics of the trunk and the caudal portion of the longitudinal neural arteries of the brain arise in the same general manner, the close association of the anastomoses of the forming vertebral arteries with the vertebræ and other segmental structures gives them an unequaled regularity as to position and form. In the development of the vertebral, the capacity of the blood-current to make a channel for itself by converting to its use segments of many different vessels is well shown and illustrates the hard and fast boundaries which the environment may place upon the course of a blood-stream. This mode of origin was already recognized for the vertebral by His in 1880. Froriep (1886), in connection with his description of the development of the vertebral column of the calf, showed the nature and relationships of the anastomoses. He figures them as passing from one cervical segmental artery to the next through an opening between the costal and the dorsal elements of the rudiment of the transverse process of the vertebra and lying medial to the spinal nerve. Hochstetter (1890) described a stage in the rabbit in which the anastomoses were large and swollen and the segmental arteries still complete. He noted that the proximal end of these vessels had been bent caudally by the shifting of the aorta in that direction.

The vertebral arteries come into being because the cervical segmentals are involved in the shifting of the neck structures on each other. The shifting of the cranial end of the nerve-tube relative to the digestive tube and other more ventral structures results in the cervical spinal ganglia and the spinal nerves after a while taking an oblique course ventrally and caudally. The segmental arteries also take on a similar direction (fig. 27). It is not certain whether the vessels would in time have become modified to allow the arterial current to pass upward more perpendicularly or whether the obliquity might have been permanently maintained. In any case a distinctly unfavorable condition develops for the segmental vessels at their proximal end due to the caudal shifting of the aorta. This affects only a short segment of the artery, since the more distal part is held in its intersegmental space by the condensed mesenchyme of the vertebral rudiments. As a result, the short proximal part takes on a much more oblique direction than the rest. A model of a 9-mm. embryo shows well this condition.

In the proximal region of their abrupt slope the second and fifth cervical segmental arteries form an angle of about 45° with the long axis of the aorta. In the others of the series up to the seventh the slope is somewhat less. The segmentals are evidently exposed to unusual longitudinal tension in this region. The abrupt bending at either end of it, and more especially where it emerges from the aorta, must tend to greatly retard the current-flow. The vessels are here under conditions very unfavorable for further development or for even maintaining themselves. In this part of their course they are all of very slender caliber, or, at the end closest to the aorta, have become lost in the capillary plexus. It seems probable that their involution consists in a distribution of the endothelial cells of their wall among capillaries of the plexus that succeeds them and not in a cell degeneration. The part of each segmental distal to the bend is of much greater diameter, and, taken as a whole, the vessels have a characteristically conical form due to an increase in diameter as they pass dorsally. This is seen in Hochstetter's figure and is mentioned in Barniville's (1914) account of a human embryo. The sixth artery shows much less slope, in both its proximal and distal parts, than the others. The seventh, of which the subclavian is a branch, is a robust vessel and comes off perpendicularly from the aorta. The reason for the dissimilarity between this vessel and the more cranial segmentals can be better understood after an examination of a slightly older stage.

In a second model of a 9-mm. embryo the vertebrals are midway in their formation (fig. 28). Anastomoses are now established between all the cervical segmental arteries except the first and second. A certain amount of variability in the details of the formation of the vertebral is well illustrated by the equality in the number of interrupted segmentals in this embryo and the other previously described, taken with the dissimilarity shown by the two in the development of anastomoses.

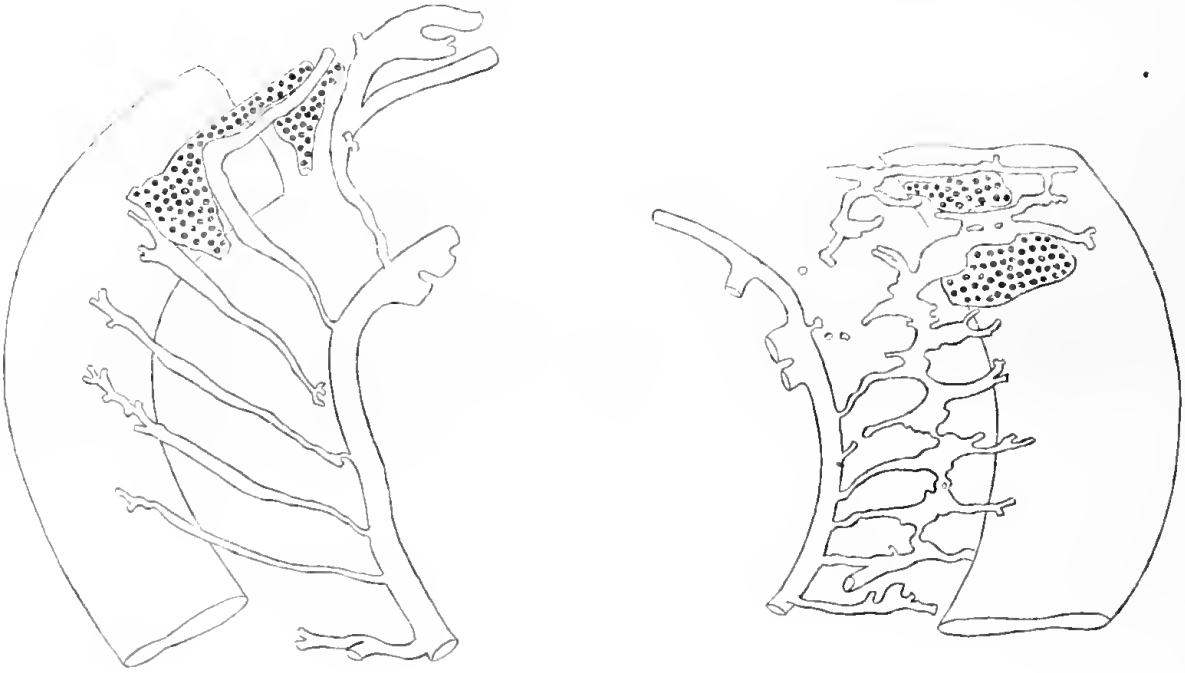

27 28

Figs. 27 and 28. Stages in the formation of the vertebral artery. In figure 27 (embryo No. 721, 9 mm.), two segmental arteries are interrupted but no anastomoses have yet formed between them. In figure 28 (embryo No. 143, 9 mm.), retrocostal anastomoses have formed between all but the first and second segmental arteries.

Also, it is not the same segmentals that are interrupted in the two embryos. The individuality in the story of the interruption of the successive arteries is clearly seen in their varying angles relative to the aorta and in the inequality of the intervals between their origins.

The anastomoses between the segmental arteries, with the exception of the first and second, are of a regular character, since they are situated among segmentally arranged vertebral nerves and arteries. They pass caudally from a segmental vessel, where it lies medial to and indented by a spinal nerve, and connect with a more distal part of the next succeeding artery. In this way a channel is developed from alternating anastomoses and segments from successive segmental arteries. The last contribute the larger amount to the vertebral artery. If the proximal ends of the segmentals are drawn up into the vertebral, as in the case of the interrupted divisions of the dorsal aorta, then a still larger fraction of its material must come from the segmentals. Corresponding to the oblique course of the latter, the vertebral artery presents a wavy or zigzag appearance when seen from the side and front. A spinal nerve lies in each laterally open notch. For some reason that was not determined, the anastomoses arch laterally for the short distance in which they are free of the spinal nerve.

We know from the course of the adult vertebral artery lateral to the anterior branch of the suboccipital nerve that the anastomoses between the first and second cervical segmental arteries must have this relation to the nerve, though more caudal anastomoses lie medially. The anastomosis at this point could not be followed from one artery to the other in any model, but it is evidently forming. It is not clear just why it passes lateral to the nerve. The environment of the first segmental differs from the surroundings of the others in that the spinal ganglion and nerve are small and separated by a wide gap from the next of their series. Other structural conditions connected with this and not so easily distinguishable evidently permit the arching of the anastomosis to reach its maximum at this segment.

The first cervical segmental arteries, as noted in the discussion of the basilar development, remain in connection with the paired longitudinal neural arteries after the more cranial segmentals have begun to separate from them. As they are still continuous with them at the time of formation of the vertebral artery, they serve to continue the vertebral of either side into the basilar. It was not determined whether or not a short caudal segment of the longitudinal neural arteries of the brain remains unfused on either side, but if it does it would furnish material for the distal end of the corresponding vertebral artery.

The vascular plexus on the lateral surface of the spinal cord and caudal end of the medulla undergo striking changes during the establishment of the vertebrals. Before anastomoses have developed we find the vessels turgid in the region of the first cervical ganglion. The segmental artery here is also much distended where it sends ramifications into the plexus of the medulla and cord. The distension of the plexus and segmentals soon extends farther caudally along the cord. This distension is perhaps due to the plexus and the distal part of the segmental arteries temporarily carrying the blood-stream which was formerly distributed to it under lower pressure from the arteries and which is soon to be taken over again by the vertebral artery. Though the walls of the capillaries have not as yet been shown to differ in strength from those of the segmentals, it is safe to assume from functional considerations that they are already weaker. It is to be expected, therefore, that, when the current of supply to the cervical cord is rather abruptly thrown directly into the plexus, the walls of its capillaries and of the distal ends of the segmentals as well should become stretched.

There is a caudal decrease in distention of the vessels and in the size of the anastomosis and a proximal tapering of the individual segmentals, which suggest that, while the vertebral is forming, the blood-stream to the more cranial part of the cervical cord is now coming by way of the basilar and internal carotid arteries. Sabin's observations, from injections in the chick, that the paired longitudinal arteries of the brain are formed by the meeting of a cranial branch from the internal carotids and a caudal vessel formed by the anastomosis of segmental arteries is reason for assuming that at the time of the establishment of the longitudinal neural arteries, at least, the carotid current passes backward under the fore part of the hindbrain. The comparative anatomical studies of De Vriese have shown that the supply of a large part of the brain by the vertebral current is an acquirement of higher vertebrates. The internal carotids primitively reach the hindbrain. De Vriese believed that she could trace in sheep embryos a progressive change in the direction of tapering of the basilar artery of such a nature as to indicate that this vessel at first acted as a branch of the carotids but later as a part of the vertebral system.

It is difficult to establish differences in diameter of vessels at this early stage because of their great distensibility, dependent upon conditions at death and later. There was, however, some evidence that the diameter of the vertebral at the time of formation was greater in its more cranial part. It seems probable, therefore, from these various considerations, that before the formation of the vertebral artery the hindbrain receives its chief supply from its cranial connections and that during the formation of the vertebral the current may pass back into its territory. The establishment of the vertebral must sooner or later put an end to this condition.

In the 14-mm. embryo the vertebral artery has acquired a nearly uniform caliber (fig. 23). The proximal end of the subclavian, which was earlier the stem of the seventh cervical segmental, has enlarged to the proper dimensions to carry both the vertebral and the subclavian streams. The vertebral now comes off very close to the aorta and it is distinctly larger than the subclavian. It is still nearly as tortuous as at first. The maintenance of this condition in an artery for a considerable time is of great rarity, since all vessels tend to straighten out their angles rapidly. It persists only because its surroundings force this course upon it. In a 21-mm. embryo (No. 448) the vessel is becoming straighter (fig. 25).

The vertebral artery is formed by the elaboration of material from so many sources that it will be well to enumerate its components. Beginning at its origin, there is a segment of the seventh cervical segmental artery distal to the origin of the primitive subclavian artery. Next come short portions of segmentals 1 to 7 with the anastomoses between them. The first cervical segmental carries on the vertebral channel from the lateral side of the first cervical vertebra to the caudal ends of the ventral neural arteries of the brain as they lie under the medulla. As has been said, it is not certain whether the ventral neural arteries themselves contribute to it.

The chief cause of the interruption of the segmental arteries has been given as the tension of their proximal segments and their abrupt bending at each end due to shifting of surrounding structures. A further understanding of the changes ending in the vertebral formation may be gained from the seventh segmental, which did not succumb to these conditions. There are two circumstances which have probably contributed to its survival. The dorsal aorta, as was earlier shown, does not shift equally throughout its entire extent, in relation to its environment, but the movement begins at the cranial end. At the time of the formation of the vertebral artery the process has just reached the caudal end of the cervical region. It may be, then, that there has as yet been no shifting at the origin of the subclavian. If there has already been a slight movement, then we must infer that since the subclavian still comes off perpendicularly it must have moved along the aorta, just as we know it does in the succeeding phase of its development. It is not improbable that of the cervical segmentals it alone can do this, since it has a greater current than its companions, due to its supply of the limb-bud.

Because of its success in maintaining itself, it naturally falls heir to the distal territory of the more cranial segmentals by means of the anastomotic chain which connects them and which earlier seems to have supplied them with blood from the opposite direction. Its ultimate capture of the vertebral as a branch, as soon as time is given it to expand, is a natural sequel of its closer connection with the main arterial stream than is possessed by its rival, the internal carotid.

SUMMARY.

The evolution of the aortic-arch system is one of the most striking and complete instances of recapitulation in human development. The arches are not, however, all present at one time, as in many anamniotes, the first disappearing before the last arises. The arches develop as a result of the interposition of the pharynx with its pouches between heart and aorta in the early embryo. As soon as the heart moves away from the pharynx they disappear. The developmental period during which the arches are present may be termed the *branchial-phase,* and the remaining time, up to the attainment of the adult condition, the *post-branchial phase.* The interruption of the sixth arch was arbitrarily taken as marking the division between the two. The branchial phase occupies about 22 days and the post-branchial 28 years, yet the organization of the adult arterial system of the head, neck, and thorax is far along toward completion in the first 14 days of the post-branchial period.

The first arch has been found in mammals to develop from a preexisting angioblastic and capillary net. In man the arches are formed of sprouts converging from the dorsal aorta above and the aortic sac below. These seem not to be preceded by a very complete net, though a sparse plexus does first grow out from a bulging of the aorta and the sac. The sprouts, because of their rapid formation and large size relative to the net, seem to develop as much from an outgrowth of endothelium as by differentiation of the net already present. In the development of the pulmonary arch the simple dorsally directed sprout from the sac does not appear. Instead, there is an outgrowth of the same nature, directed caudally. By fusion with a sprout from the dorsal aorta it is bisected into a proximal and a distal part, the first forming the ventral end of the arch and the second the primitive pulmonary artery.

The arches develop in their order from before backward. The first undergoes involution about the time the fourth is complete, and the second disappears before the pulmonary arch has become a continuous channel. Later, the third ceases to send blood caudalward into the aorta. Thus the stream from heart to aorta is shifted caudally in the branchial period. After the pulmonary arch is complete there is a period of comparative stability of the arches, the fourth and pulmonary delivering the blood caudally into the aorta, aided for a time by the third. The length of the third and fourth arches is almost constant throughout their existence, because their form is dependent on the caudal portion of the pharynx, which increases in size very little after its establishment and early shows regressive changes.

Fifth Arch.

Loops, or so-called "island-formations," appear sometimes in the angioblastic and capillary net which precedes the upper end of all arches but the first. Occasionally they are found at the lower end. Those found at the upper end of the fourth and pulmonary arches have been incorrectly classed with other arterial channels which bear a real resemblance to a fifth arch. If one omits the island-formations, 6 cases of so-called fifth arches have been described in man. In 5 of these it arose from the lower end of the fourth arch or the subjacent sac and passed to the upper end of the pulmonary arch. Lewis and Kingsbury point out that even the occasional existence of a fifth arch can not be regarded as established, since the identity of this structure depends on its lying in a fifth visceral arch, and this has never been proved. Yet there is some evidence of the occasional occurrence of the latter in a more or less complete form. Projecting from the aorta and sac are frequently found sprouts corresponding to the upper and lower ends of the fifth arches. Taken with the complete vessels, these were found in 50 per cent of the embryos representing the time of establishment of the pulmonary arch and a little later. It can not be said how many of these are developing so-called fifth arches, how many are stages of regression, and how many are incompletely developed so-called arches which never will progress farther.

The enlargement where the arches come off from the arterial trunk, which we have termed the *aortic sac*, is already present when the second arch is forming. It is best developed when the three pairs of arches are coming off from it and remains for a time after the pulmonary arches and trunk are cut off. A similar structure is found among anamniote embryos, and a sac of similar form and position is observed in some adults of the same group. Perhaps the embryonic like the adult sac either serves to distribute the diastolic pressure or is a mechanical adaptation to the forces resulting from the rapid deflection of the current from the arterial trunk into the arches. Dr. Streeter suggests, as a purely developmental explanation for its presence, that it may be due to an excessive proliferation of endothelium which is to be used up later in differentiation of the arteries.

Most writers describe paired ventral aortæ in the human embryo. There are at different times a few temporary channels leading from the sac which, by their approximately cranio-caudal course, resemble fragments of ventral aortæ. Such are the longitudinal segments that appear in the late history of the first and second arches and the paired sprouts which give rise to the proximal parts of the pulmonary arches and the primitive pulmonary arteries. These vessels are truly indicative of a general structural plan which in some lower vertebrates is elaborated to a degree that permits the development of paired ventral aortæ. There is no phase of human development, however, in which such vessels exist.

Involution of First Two Aortic Arches.

After the disappearance of the first and second arches, their corresponding visceral arches are each occupied by two successive channels; these may be termed, respectively, the earlier and later mandibular and hyoid arteries. The earlier lie near the axis of the arch; the later run close to its caudal border. These arteries all break up in a plexus in the subpharyngeal region. Their current is from the dorsal aorta, and they supply the visceral arches. Only the later hyoid artery could be found in the post-branchial period, when it constituted the stem of the stapedial artery. There was no evidence of cell degeneration during the involution of the arches. Small endothelial saccular enlargements or lacunæ were found in the subpharyngeal region after the arches had disappeared, but these were always parts of vessels. They may be due to proliferation of endothelium later to be used in the rapid differentiation of vessels.

The precursors of the external carotid arteries are seen, soon after the first and second arches have gone, as a pair of irregular and inconstant sprouts from the aortic sac. They sometimes send branches into the bases of the mandibular and hyoid arches. They first lie near the mid-line, but gradually they either move lateralward or are replaced by more lateral vessels. In the earlier part of the post-branchial period, when the identity of the third arch is becoming lost, these arteries are found coming off from the middle of the third arch. Lingual, thyroid, and other branches are distinguishable at this time.

Principal Changes during Post-branchial Phase.

The early post-branchial phase is the time when rapid disintegration of the arch system takes place. Since the identity of its parts is largely topographic, their walls differing little in structure, one can not expect to trace the parts, as hard and fast units, into the later vessels. It is of interest, however, to learn in what manner the earlier vessels give up their identity in the mature arteries which evolve from them, since this subject in any part of the vascular system seems to have received little attention.

The rapid breaking up of the arch system is effected principally by its interruption in four places. The loss of the segment between the dorsal aorta on either side, between the third and fourth arches, helps especially in the formation of the carotids. The cutting off of the right paired aorta at its caudal end makes possible the completion of the right subclavian artery. The degeneration of a part of the right pulmonary arch permits the development in the fetus of the main pulmonary channel, the two parts of which are termed the *definitive pulmonary artery* and the *ductus arteriosus*.

In each instance one immediate cause of the interruption seems to be a reduction of current-flow. In the two aortic segments between the third and fourth arch it is due to a stagnation at this point, the streams in the aortic segments cranial and caudal to it flowing in opposite directions. This in turn may be ascribed to the rapid increase in the mass of the head region and the consequent enlargement of the territory supplied by the cranial end of the aortæ. The right pulmonary artery receives less current than the left, because it is a less direct route to the aorta, due to the pulmonary trunk ending to the left of the mid-sagittal plane. The stream to the right paired aorta caudal to the fourth arch is reduced, because the sixth arch on this side has become interrupted and the aortic trunk is at this time directing its current more into the left than into the right fourth arch. The short interval of the aorta between the subclavian and the bifurcation suffers a still greater reduction of current, as it does not carry the stream to the subclavian.

The downward pull exerted by the descending heart upon the derivatives of the arch system also probably contributes to these interruptions. That the effect of tension is less important than current-strength is shown by a comparison of the right pulmonary arch and of the right end of the right aorta with the corresponding regions on the left side, since the latter were likewise exposed to the tension yet did not succumb. The excessive tension at least hastens the degeneration, therefore, after it is once begun. The regions affected first contract and then are pulled out into long filaments. These in turn are broken. With the exception of the pulmonary arch, which leaves behind a long cord of degenerating cells, the recoil of the broken filaments brings back most of the substance of the involuting region to a position close to the adjacent vessels, where it is worked over into their walls.

The development of the definitive aortic arch is complex, since its material comes from many sources. In a 14-mm. embryo the last trace of the division of the dorsal aorta between the third and fourth arches is just about to disappear, but the ends of the arches are still defined. Since the aortic arch is just taking form, one can learn the sources of its respective regions, and it is seen that the aortic trunk, left half of aortic sac, left fourth arch, left dorsal aorta between the fourth and pulmonary arches, and the part of the aorta lying next most caudally lose their identity in it. The right half of the sac elongates to become the innominate artery. The right and left third arches, as far up as the external carotids, develop into the common carotid arteries.

The history of regions of the forming definitive aortic arch may be inferred by a study of measurements of the divisions of the arch system in the late branchial period and the parts of the arch apparently arising from them. The segment between the innominate and left common carotid, originally equivalent to the left half of the aortic sac, keeps pace with the growth of the body-length until the heart and arch make their rapid descent into the thorax at the stage of 14 to 18 mm. At this time the innominate and left common carotid approach. This is almost certainly due to the origin of the innominate moving distally on the arch. The proximal part of the arch, as far as the innominate, has been elongating steadily, but its sudden extension, as the arch rapidly descends, is probably due to the origin of the innominate moving distally through the more distal region of the definitive arch as far as the ductus arteriosus. As a result, the fourth-arch region, which was at the summit of the forming definitive arch, sinks to the descending limb, and the region of the left common carotid, now shared by the innominate, comes to constitute the entire summit. The region of the arch derived from the fourth arch increases rapidly in diameter to reach in cross-section an approximate equality with the more proximal and distal parts derived from vessels which are already capacious at the beginning of the branchial period. The arch as a whole increases little in length, but considerably in circumference, up to the 24-mm. stage.

The definitive arch in its early history lies in almost the mid-sagittal plane, because at its distal end the aorta has not taken a paravertebral position and at its proximal end the heart has not yet come to lie obliquely in the thorax. The arch has a large radius before the closing of the superior thoracic aperture by the meeting in the front of sternal bands and ribs. Then, due to the swinging caudally of the apex of the heart to accommodate itself to the decreased space of the thoracic cavity, it is bent rather sharply at its summit.

The innominate and common carotids swing into a nearly longitudinal position during the rapid descent. They still slope somewhat ventrolaterally in the 24-mm. embryo as they pass upward, because of the large size of the head relative to the body. The innominate lengthens to about the same degree as it decreases in circumference; relative to the increasing body-length it is much longer proportionally in the 24-mm. embryo than it is in the adult. The common carotid arteries extend rapidly coincident with the rapid descent of the heart. It is not clear how much of this is due to the elongation of the region from the proximal half of the third arch and how much to the arch being pulled caudalward, thus forcing the external carotid to shift cranially along its wall and the wall of the dorsal aorta cranial to it.

Changes in Topography of Aortic-Arch System.

The displacements of the parts of the arch system and of the aorta, due to the unequal growth of different organs, are chiefly longitudinal and transverse. The paired primitive aortæ grow toward each other in a part of their course and are carried apart in other regions. The approach is in the thoracic region and is not a movement of the vessels as a whole toward each other, but merely an approximation of their contiguous walls due to the increase in diameter of the vessels. It is permitted by the withdrawal of the nerve-tube and notochord from the digestive tract.

The fusion of the aortæ takes place by the enlargement of capillaries lying between the vessels to form transverse anastomoses. These then fuse so that a unit vessel results with a cross-section like the figure 8. This in turn is remolded to the ordinary arterial form. The fusion begins somewhat back of the cervical region and progresses both cranially and caudally. It comes to a stop about 4½ body segments caudal to the pharyngeal territory, where the pulmonary arch is forming. Due to the growth displacement of the cranial end of the nerve-tube relative to the pharynx, the most cranial point of fusion soon after the process has begun is opposite the second cervical ganglion; while later, when fusion is complete, though it has moved forward relative to the pharynx, it is opposite the seventh ganglion.

Fusion does not progress farther cranially because the developing cervical vertebræ and the digestive tube, pressing upon the aortæ from above and below, tend to crowd the latter apart. If we take the paired aortæ in connection with their cranial extensions, the longitudinal neural arteries, we find that during growth these two vessels, at first nearly parallel, are carried widely apart in three places and to only a slight extent in two intermediate regions. The two vessels together produce a trilobed figure. The most caudal separation, which is also the least in extent, is due to the pressure of the cervical vertebræ and digestive tube, as already described. The next is over the anterior part of the pharynx and is the result of the rapid widening of this region. The third is on the forebrain and is produced by the rapid lateral expansion of the latter. At the caudal end of the pharynx is a region in which the arteries are in close approximation. The pharynx here is in a condition of regression and increases in width very slowly. It may be that the pressure of the vagus nerve on the lateral side of the vessels here, as it passes downward across them, has some effect in preventing their being carried apart, since they sometimes show its impress. Just cranial to the pharynx another approximation is due to a less rapid increase in width here than is shown by the forebrain and pharynx lying, respectively, cranial and caudal to it.

The paired aortæ and a part of the unpaired vessel shift backward relative to their immediate environment, the pharynx and digestive tube. The shifting first occurs at the cranial end of the aortæ, since here they first fall behind the surrounding structures in longitudinal growth. The withdrawal then takes place progressively in more and more caudal parts of the paired aortæ and then involves the unpaired aorta to an increasing extent. In the earlier part of the branchial period, when fusion of the aortæ has just been completed, the withdrawal has not progressed to the fusion point, but is shown only by the bending backward of the dorsal ends of the more caudal arches soon after each appears. The next indication is a sharp forward bend of the proximal end of the cervical segmental arteries as far back as the sixth. The aortic bifurcation remains at rest for a while, but the region of withdrawal has extended back to it at about the end of the branchial period. Beginning in embryos of 14 mm., there is a rapid caudal shifting of the point of bifurcation, which ends at about the 17-mm. stage. The caudal movement continues and is not complete in the 24-mm. embryo, in which the superior thoracic aperture is closed and the heart is in the thorax.

The fusion of the paired aortæ also progresses caudally as well as cranially. The caudal paired vessels are always very short, for while they are elongating distally they are fusing proximally. The paired condition, unless perhaps in the form of very slender terminals, does not remain at this end of the body. In 4 to 6 mm. embryos only very short double vessels are present and later no definite aortæ could be recognized. The distance which the territory of the aorta derived from the bifurcation shifts can not be told precisely. There is a type of anomalous right subclavian artery, however, which evidently taps the aortic system by retaining the caudal end of the right paired aorta, since in the adult it comes off as the distal branch of the aortic arch. Inasmuch as it has been found coming off as low as the fifth thoracic vertebra, there can be little doubt that the region of the aorta derived from the bifurcation also moves down this far. In fact, it is not unlikely that the subclavian has moved up the aorta somewhat from the region corresponding to the bifurcation, since the left subclavian regularly does so. It is known that the caudal end of the aorta withdraws cranially. There must, therefore, be a point intermediate between the ends which remains more or less fixed in relation to its immediate environment, and this point must be in the proximity of the thoracicolumbar boundary.

The interruption of the right paired aorta at its caudal end is quickly followed by a shifting to the left of that part of the definitive aortic channel just back of the point of the former bifurcation, as the angle between it and the right paired aorta is straightened. This is a step in the movement of the thoracic aorta to its final position in the left side of the vertebral column. It is probable that a pressure analogous to that which crowded apart the paired aortæ acts later to push the definitive unpaired aorta to the left.

The shifting of the aorta is paralleled by a caudal displacement of the arches, their ventral connections, and the heart itself. The arches not only shift at their upper ends as far caudally as possible, but the entire fourth arch is curved around the caudal pharyngeal complex at the end of the branchial period, as though this mass were resisting its caudal progress. In a similar way the loop formed by the vagus and recurrens nerves presses against and molds the pulmonary arches. The aortic sac also shifts correspondingly. In the post-branchial period the interruption of the various parts permits a rapid descent of heart, arch, and other vessels. The fourth arch moves, relative to the pharynx, about 4½ body segments. Since the nerve-tube grows forward relative to the pharynx, the arch moves on the nerve-tube about 13 body segments. During the period of rapid descent (embryos 14 to 18 mm.), the arch moves at a rate of about one-fourth of a segment a day. This displacement is the continuation, in another guise, of the shifting of the blood-stream from heart to aorta, which, in the branchial period, was effected by the loss of the cranial arches and the development of new caudal ones.

The heart changes its relation to the sac during growth. At first the arterial trunk approaches the sac from a cranial direction, indicating that the apex of the heart is pointing forward. At about the end of the branchial period we find the apex of the heart pointing in the opposite direction, so that the arterial trunk reaches it from its caudal side. The long axis of the heart is at right angles with the perpendicular axis of the body at about the time (near the end of the branchial period) when the proximal ends of the fourth and pulmonary arches are well apart. Therefore, it may be that the heart crowds against these arches at this time and pushes them apart.

The downward movement of the heart, sac, and arches, like the retreat of the aorta, is due to the failure of the heart and certain territories caudal to it to keep pace with the longitudinal growth of other adjacent parts of the body. The descent of the heart causes a movement of other structures to fill in the space vacated by it, such as the pharyngeal derivatives and probably mesenchyme. The arteries, however, probably have a more active rôle, and they themselves, while pulled by the heart, actually aid the caudal movement of some of the other structures by pressure against them. The moving in of structures to take the place of the heart has been aptly termed by Kingsbury a "growth eddy." The body-wall takes an active part in the eddy, as indicated by the change in position of the rib rudiments and sternal bands. The ribs, before the rapid descent, point upward and outward at an angle of 90° with the sagittal plane. They sink caudally at their distal ends, and by the development of a curve and an increase in length they come to form, with the aid of the sternal bands, an arch which completes the thoracic inclosure on its ventral side. This process follows quickly upon the descent of the heart into the thorax.

The heart and large vessels change their position just in time to accommodate themselves to the restricted quarters resulting from the closure of the superior thoracic aperture. The kinking of the aortic arch, which occurs at this time, results in a dorsoventral diameter commensurate with the size of the aperture. · The left subclavian and the innominate are now near the summit of the arch, so that the arches of the branch are well placed to find exit from the thorax.

The arterial changes that have been recounted include many illustrations of apparent effects of the longitudinal pull of the heart and dorsal aorta on the arteries with which they are connected, usually acting alone but sometimes associated with other causes. Among these may be mentioned the involution, the stretching into threads and the breaking of segments of the arch system, the caudal movement of vessels, swinging of vessels into an approximately longitudinal direction, especially rapid growth of arteries during the descent of the definitive arch, and the movement of the subclavian and innominate along the vessels of origin. Experimental evidence will be necessary to establish definitely the action of longitudinal tension in most of these cases, but even in the absence of light from this quarter the developmental picture offers strong indications in its favor.

Pulmonary Artery.

The pulmonary artery takes origin when the sprout from the dorsal aorta caudal to the caudal pharyngeal complex establishes a connection with the caudally extending sprout from the aortic sac, thus dividing the latter into two parts—a proximal portion, which becomes part of the pulmonary arch, and a distal portion, the primitive pulmonary artery. The sprout from the sac is preceded by a well-developed plexus, which itself has sprung from the sac and seems more to be the result of the elaboration of the endothelium of the plexus than were the other aortic-arch sprouts.

When the right pulmonary arch becomes interrupted dorsal to the origin of the right pulmonary artery, the angle between the artery and the proximal segment of the arch straightens out, so that the arch remnants become a part of the artery. Similarly, the angle between the left arch and pulmonary trunk becomes rectilinear, so that these two elements form a large trunk, slightly curved, which extends from the pulmonary side of the heart to the distal end of the aortic arch. In the straightening of this angle, the origin of the right pulmonary is carried ventrally, and near its origin the vessel becomes somewhat curved about the proximal end of the aortic arch. The segment of the main pulmonary vessel between the origin of the right and left pulmonary arteries shifts away from the heart and toward the aorta. It is not certain to what degree this is due to inequality in the growth of the segments proximal and distal to the vessels and to what degree it is a matter of movement of the origins of the two vessels in the wall of the main stem. Several things, however, point to its being due chiefly to the former cause. During the period of rapid descent, the points of origin of the two pulmonary arteries rapidly approach each other. This must be due to the movement of one or both through the substance of the main vessel. They meet before the 40-mm. stage. The manner in which they come together does not favor the view that they have become wrapped about the pulmonary stem by means of its rotation and, by fusion with it, gradually approach each other at their points of origin. After coming together the arteries are designated by their adult terminology—right and left branches of the pulmonary artery. The main stem proximal to them is the pulmonary artery, and the channel from the origin of the left pulmonary to the dorsal aorta is the ductus arteriosus.

Subclavian Artery.

In their development the subclavian and vertebral arteries show to an unusual degree the capacity of the blood-stream to take over and mold into a unit a number of previous channels. The subclavian artery can first be recognized at the time the forelimb-bud is but a slight elevation, after the completion of the fourth arch and before the pulmonary arch is complete. It is at this time a slender channel lying in the sixth cervical intersegmental space and coming off from a sac-like projection of the aorta which later develops into the stem of a segmental artery. There are similar vessels in adjacent intersegmental spaces which usually end in a plexus before reaching the limb-bud. It seems probable, as far as can be determined from the study of sections, that a second artery may occasionally extend into the limb-bud, but this was not possible to ascertain with certainty in the absence of injection of *in toto* preparations. Since the vertebral artery arises from the subclavian, it usually enters the transverse process of the sixth cervical vertebra. The situation of the origin of the subclavian and vertebral a segment more cranial than usual is of much more frequent occurrence in the embryo than in the adult. There is evidence of a regulation, in a sense, back to the usual type.

The subclavian first passes to the limb-bud on the dorsal side of the brachial plexus, but later it is inclosed by an outgrowth of neurons over its dorsal surface. In a 14-mm. embryo one can distinguish radial, ulnar, interosseous, and some digital arteries, as well as different nerves of the limb. The subclavian soon incorporates, as a part of itself, the stem of the segmental from which it arose. At this time its segmental part comes off the unpaired aorta. As the aorta shifts caudally, the subclavian is moored by the vertebrals, and their other branches move each onto the corresponding paired aorta. At the time of rapid descent the right paired aorta is interrupted just where it goes over into the unpaired aorta and the subclavian comes off just above the bifurcation. Before the interruption, as was earlier explained, the right fourth arch and the paired aorta distal to it had already been reduced to a mere channel of supply to the subclavian. The interruption of the right aorta distal to the subclavian is the final step in giving these two segments over as the proximal end of the right subclavian.

The left subclavian continues its movement up the aorta and arch until, in the 17-mm. embryo, in which the aortic arch is complete, it is but a little way from the summit.

Basilar Artery.

Paired longitudinal arteries develop along the lower surface of the brain and are continuous at their anterior ends with the aortæ in the human embryo just after the establishment of the fourth arch. They were still incomplete in a 4-mm. embryo in which the fourth arch had just formed. Only the first cervical and second occipital (hypoglossal) arteries have been seen connected with the caudal end of these paired longitudinal arteries, but this part probably arises as anastomoses between all segmental arteries cranial to the second cervical, followed by a loss of the connection of these vessels with the aorta. The paired neural arteries were traced caudally into paired longitudinal arterial tracts of the cord.

The contiguous walls of the paired longitudinal neural arteries approach, as in the case of the primitive aortæ, merely by enlargement and not by actual movement of the vessels toward each other. Cross anastomoses develop from enlarged capillaries; and in the more cranial part of the region destined to be occupied by the future basilar artery, successive segments, taken irregularly from one or the other neural artery with cross anastomoses, are remolded into the basilar. Near the caudal end there is apparently a fusion of the two neural arteries to form the basilar. By the time the pulmonary arch is established, the formation of the basilar is well under way.

Vertebral Artery.

There would never be a vertebral artery did not the aorta shift caudally. Its movement is responsible for the proximal ends of the segmentals, back to the seventh cervical, becoming stretched, decreased in diameter, and bent obliquely on the aorta. The more distal part of the segmentals also takes on a slope which is less abrupt and due to the shifting of the nerve-tube on the digestive tract and adjacent structures. It may be that this, too, is unfavorable to their maintenance. The seventh segmental, being larger than the more cranial vessels, due to its subclavian branch and because it lies in a region where there is as yet little caudal movement of the aorta, does not become oblique or constricted in diameter and does not degenerate.

Anastomoses develop between the successive cervical segmental arteries in the 9-mm. embryo. These pass caudally from one vessel and connect with the more distal part of the next succeeding member of the series. A channel is thus developed from alternating anastomoses and segments of segmental arteries. Of the two, the arteries contribute the most. The resulting vessel is tortuous in both sagittal and frontal planes. Due to the confined space in which the artery runs, it is not entirely straightened out even in a 52-mm. fetus. Each anastomosis arches laterally where it lies free of the corresponding nerve. That between the first and second segmental arteries extends more laterally than the others, so that it passes external to the suboccipital nerve. The part of the first cervical segmental artery distal to the anastomoses, up to its ending in the longitudinal neural artery, also becomes part of the vertebral. It was not decided whether the caudal end of the longitudinal neural also supplies material for the distal end of the vertebral or whether they all go into the basilar.

There are a number of considerations pointing to a cranial source of the blood passing through the entire basilar and the cranial part of the cervical cord at the time the vertebral is forming. It is probable, though less certain, that at an earlier period the longitudinal neural arteries also were supplied nearly to their caudal ends by the current passing forward into the neurals from the cranial end of the aortæ. Where the vertebral is forming, the plexus on the cranial part of the cervical cord is turgid and the segmental arteries have a characteristically swollen appearance at their distal ends. They taper proximally to enter the aorta by a slender channel or to terminate in a plexus at this end. The current formerly borne by the cervical segmentals is apparently rather abruptly thrown into the plexus and the distal ends of the segmentals, due to the interruption of their proximal ends. As it is of higher pressure than usually carried by them, their walls are stretched. They are relieved by the establishment of the vertebral artery.

The subclavian artery, because it does not succumb to the unfavorable conditions which cause the disappearance of the more cranial segmental arteries, and because it has a more direct connection with the main arterial stream than the cranial ends of the longitudinal neurals, falls heir to the anastomotic chain, thus making the vertebral its branch. The course of development of the human vertebral is in accord with the claim of De Vriese that in vertebrate phylogeny the brain is first supplied by the internal carotids and that only later does its caudal part come to be supplied by the vertebral.

DESCRIPTION OF PLATES.

PLATE 1.

Figs. 29 and 30. Ventral and lateral views of the cranial portion of the arterial system of a 22-somite embryo. The first arch is at its maximum development and the dorsal and ventral outgrowths, which are to aid in the formation of the second, are just appearing. Embryo No. 2053, length 3 mm.

Figs. 31 and 32. Ventral and lateral views of an embryo in which the first arch has gone, the second arch is much reduced in diameter, and the third arch well developed. Dorsal and ventral outgrowths for the fourth and probably for the pulmonary arch are present. Embryo No. 836, length 4 mm.

PLATE 2.

Figs. 33 and 34. Ventral and lateral views of a 5-mm. embryo (No. 1380). The third and fourth arches are in a condition of maximum development and dorsal and ventral sprouts of the pulmonary arch have nearly met. The primitive pulmonary arteries are already of considerable length.

Figs. 35 and 36. Ventral and lateral views of an 11-mm. embryo (No. 1121). The pulmonary arches are complete and the right is already regressing. The third arch is now bent cranially at its dorsal end and its stream is about to become deflected in that direction.

PLATE 3.

Figs. 37 to 39. A 14-mm. embryo (No. 940) in which the last indications of the aortic-arch system are just disappearing and a very primitive condition of the larger arteries derived from them is already recognizable. Figure 37, lateral view; figure 38 ventrolateral view; figure 39, ventral view.

Fig. 40. Ventral view of an 18-mm. embryo (No. 1390). The arterial evolution has preceded so far that the adult vessels are easily recognizable.

BIBLIOGRAPHY.

v. Baer, K. E., 1828. Ueber Entwicklungsgeschichte der Thiere. Königsburg.

Barniville, H. L., 1914. The morphology and histology of a human embryo of 8.5 mm. J. Anat. and Phys., vol. 49, 1–61.

van Bemmelen, J. F., 1886. Die Visceraltaschen und Aortenbogen bei Reptilien und Vögeln. Zool. Anz., vol. 9.

Bremer, J. L., 1902. On the origin of the pulmonary arteries in mammals. Am. J. Anat., vol. 1, 137–144.

——— 1909. On the origin of the pulmonary arteries in mammals. Anat. Record, vol. 3, 334–340.

——— 1912. The development of the aorta and aortic arches in rabbits. Am. J. Anat., vol. 13, 126–128.

Broman, I., 1898. Die Entwicklungsgeschichte der Gehörknochelchen beim Menschen. Anat. Hefte, vol. 11, 509–668.

Buell, C. E., Jr., 1922. Origin of the pulmonary vessels in the chick. Contributions to Embryology, vol. 14, No. 68.

Bujard, Eug., 1915. Description d'un embryon humain (Eternod-Delaf) de 20 somites, avec flexion dorsale. Internat. Monatschr. Anat. u. Phys., vol. 31, 238–268.

De Vriese, B., 1905. Sur la signification morphologique des artères cérébrales. Arch. de Biol., vol. 21, 357–457.

Evans, H. M., 1908. On an instance of two subclavian arteries in the early arm-bud of man and its fundamental significance. Anat. Record, vol. 2, 411–424.

——— 1909*a*. On the earliest blood-vessels in the anterior limb-buds of birds and their relation to the primary subclavian artery. Am. J. Anat., vol. 9, 281–319.

——— 1909*b*. On the development of the aortæ, cardinal, and umbilical veins, and the other blood-vessels of vertebrate embryos from capillaries. Anat. Record, vol. 3, 498–518.

——— 1912. The development of the vascular system. In Manual of Human Embryology (Keibel and Mall), vol. 2, 570–709.

Fedorow, V., 1910. Ueber die Entwickelung der Lungenvene. Anat. Hefte, vol. 40, 529–603.

Froriep, A., 1886. Zur Entwicklungsgeschichte der Wirbelsäule, insbesondere des Atlas, Epistropheus und der Occipitalregion. II. Beobachtung an Säugethierembryonen. Arch. f. Anat. u. Phys., Anat. Abth., 69–149.

Gage, S. P., 1905. A three weeks human embryo with special reference to the brain and the nephric system. Am. J. Anat., vol. 4, 409–443.

Göppert, E., 1909. Ueber die Entwicklung von Varietäten im Arteriensystem. Untersuchungen an der Vordergliedmasse der weissen Maus. Morphol. Jahrb., vol. 40, 268–410.

Goette, Alex, 1875. Die Entwicklungsgeschichte der Unke (Bombinator igneus) als Grundlage einer vergleichen den Morphologie der Wirbelthiere. Leipzig.

Greil, A., 1903. Ueber die Entwickelung des Truncus arteriosus der Anamnier. Erganzh., Anat. Anz., vol. 23, 91–105.

His, W., 1880. Anatomie menschlicher Embryonen. Leipzig.

Hochstetter, F., 1890. Ueber die Entwickelung der A. vertebralis beim Kaninchen nebst Bemerkungen über die Entstehung der Ansa Vieussenii. Morphol. Jahrb., vol. 16, 572–586.

Huntington, G. S., 1919. The morphology of the pulmonary artery in mammalia. Anat. Record, vol. 17, 165–190.

Jordan, H. E., 1909. Description of a 3-mm. human embryo. Anat. Record, vol. 3, 204–211.

Keibel, F., and C. Elze, 1908. Normentafeln zur Entwicklungsgeschichte der Wirbeltiere. Heft 8, Normentafeln zur Entwicklungsgeschichte des Menschen. Jena.

Kingsbury, B. F., 1915*a*. The development of the human pharynx. I. The pharyngeal derivatives. Am. J. Anat., vol. 18, 329–386.

——— 1915*b*. On the so-called ultimobranchial body of the mammalian embryo: Man. Anat. Anz., vol. 47, 609–627.

Kranichfeld, H., 1914. Die funktionelle Anpassungen der embryonalen Aortenbogen. Arch. f. Entw. der Organ., vol. 40, 668–671.

Krause, W., 1868. Handbuch der Gefässlehre des Menschen, vol. 3, erste Abtheilung-Gefässlehre.

Lehman, H., 1905. On the embryonic history of the aortic arches in mammals. Anat. Anz., vol. 26, 406–424.

Lewis, F. T., 1904. Intra-embryonic blood-vessels of rabbits from 8½ to 13 days. Proc. Am. Assn. Anatomists, Am. J. Anat., vol. 3, p. xii-xiii.

——— 1906. The fifth and sixth aortic arches and the related pharyngeal pouches in the rabbit and pig. Anat. Anz., vol. 28, 506–513.

Macalister, A., 1886. The morphology of the arterial system in man. Am. J. Phys., vol. 20, 193–200.

Mall, F. P., 1912. Determination of the age of embryos and fetuses. Manual of Human Embryology (Keibel and Mall), vol. 1, chap. VIII, 180–201.

Rabl, H., 1907. Die erste Anlage der Arterien der vorderen Extremitäten bei den Vögeln. Arch. f. mikr. Anat., vol. 69, 341–388.

Rathke, H., 1843. Ueber die Entwickelung der Arterien, welche bei den Saugethieren von den Bogen der Aorta ausgehen. Arch. f. Anat., 270–302.

Röse, C., 1890. Beiträge zur vergleichenden Anatomie des Herzens der Wirbelthiere. Morphol. Jahrb., vol. 16, 27–96.

Sabin, F. R., 1917. Origin and development of the primitive vessels of the chick and of the pig. Contributions to Embryology, vol. 6, Carnegie Inst. Wash. Pub. 226, 61–124.

Shaner, R. F., 1921. The development of the pharynx and aortic arches of the turtle, with a note on the fifth and pulmonary arches of mammals. Am. J. Anat., vol. 29, 407–420.

Stahel, H., 1886. Ueber Arterienspindeln und über die Beziehung der Wanddicke der Arterien zum Blutdruck. Arch. Anat. u. Phys., Anat. Abth., 45–63.

Sterzi, G., 1904. Die Blutgefässe des Rückenmarks. Untersuchungen über ihre vergleichende Anatomie und Entwickelungsgeschichte. Anat. Hefte, vol. 24, 1–364.

Tandler, J., 1902. Zur Entwicklungsgeschichte der Kopfarterien bei den Mammalia. Morphol. Jahrb., vol. 30, 275–373.

——— 1909. Ueber die Entwickelung des V. Aortenbogens und der V. Schlundtasche beim Menschen. Anat. Hefte, vol. 38, 393–423.

Thyng, F. W., 1914. The anatomy of a 17.8 mm. human embryo. Am. J. Anat., vol. 17, 31–112.

Woollard, H. H., 1922. The development of the principal arterial stems in the forelimb of the pig. Contributions to Embryology (this volume).

Zimmerman, W., 1889. Ueber einen zwischen Aorten- und Pulmonalbogen gelegnen Kiemenarterienbogen beim Kaninchen. Anat. Anz., vol. 4, p. 720.

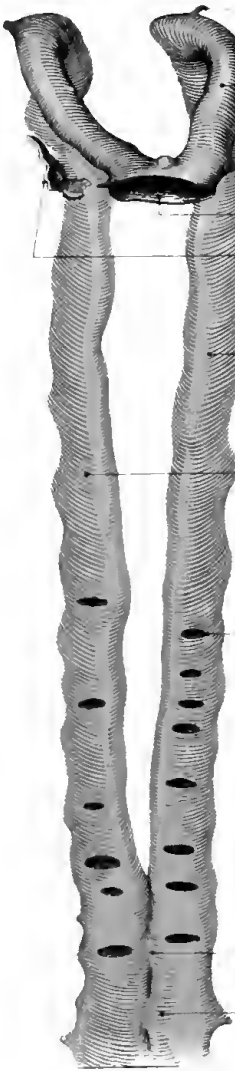

Fig 29

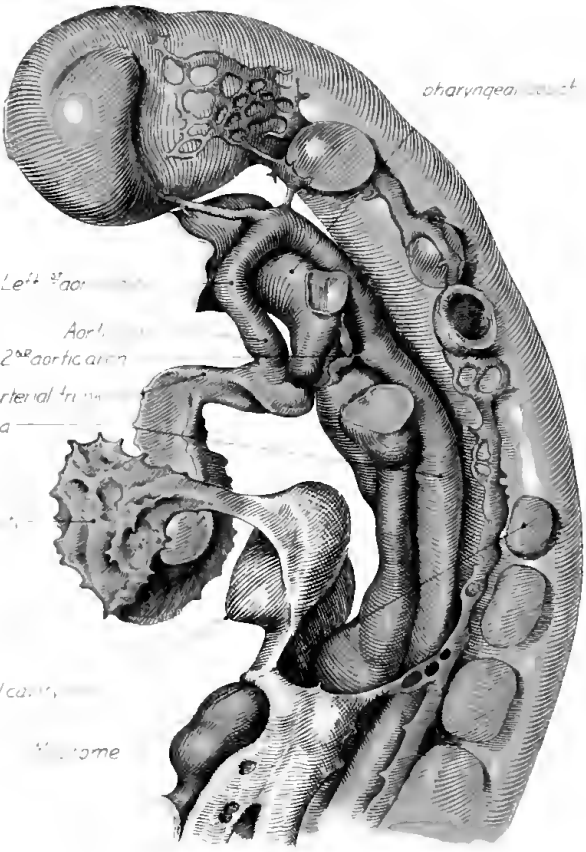

Fig 30

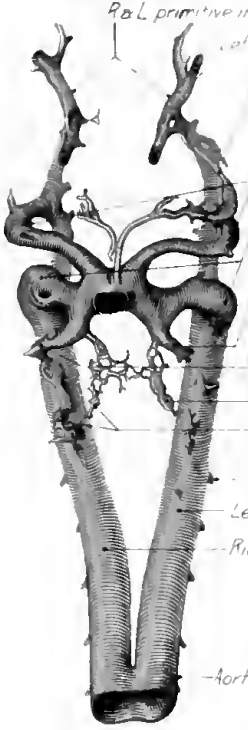

Fig 31

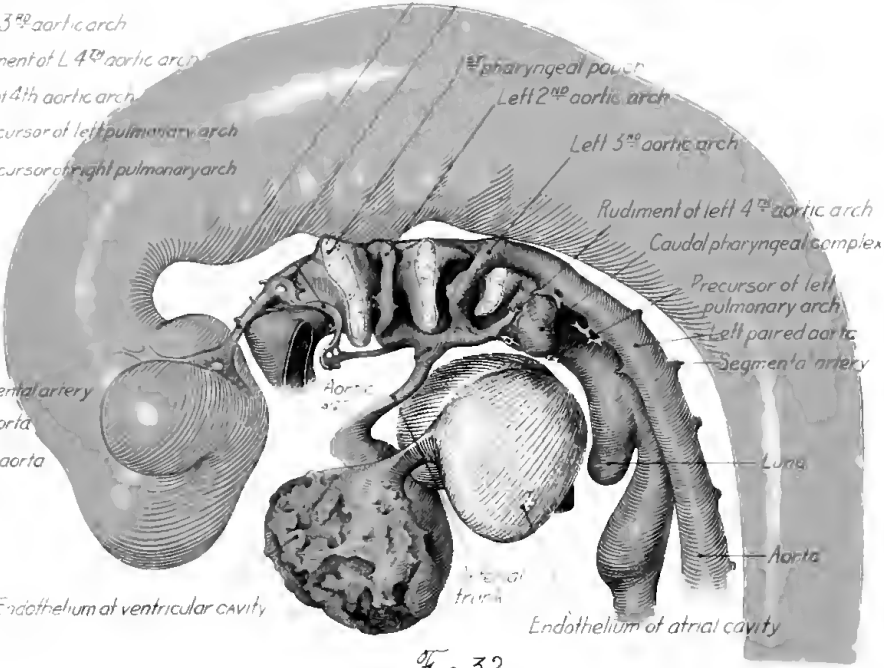

Fig 32

J. F. Didusch fec.

A. Hoen & Co. Lith.

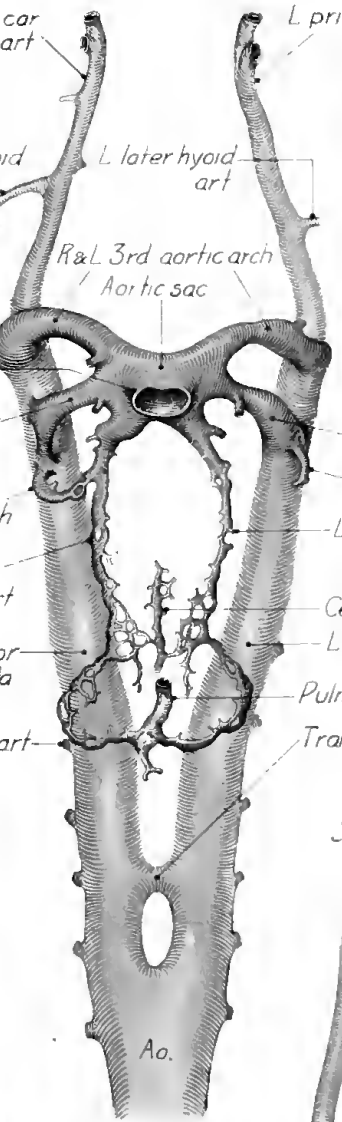

Fig 33

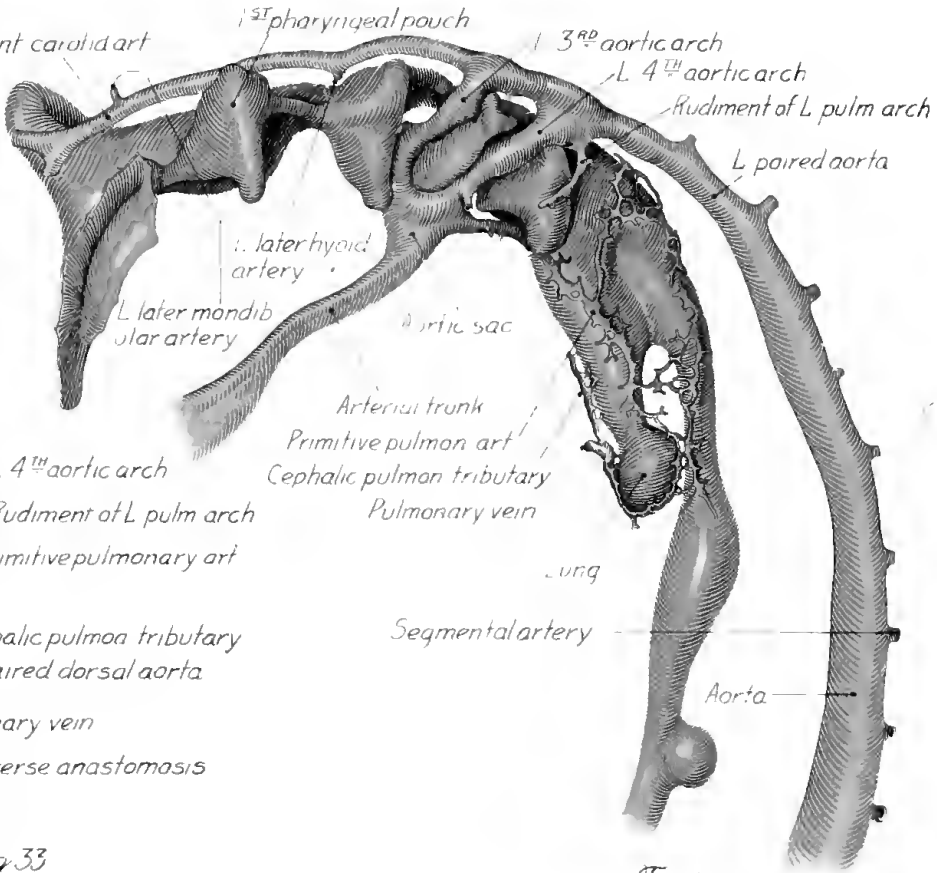

Fig 34

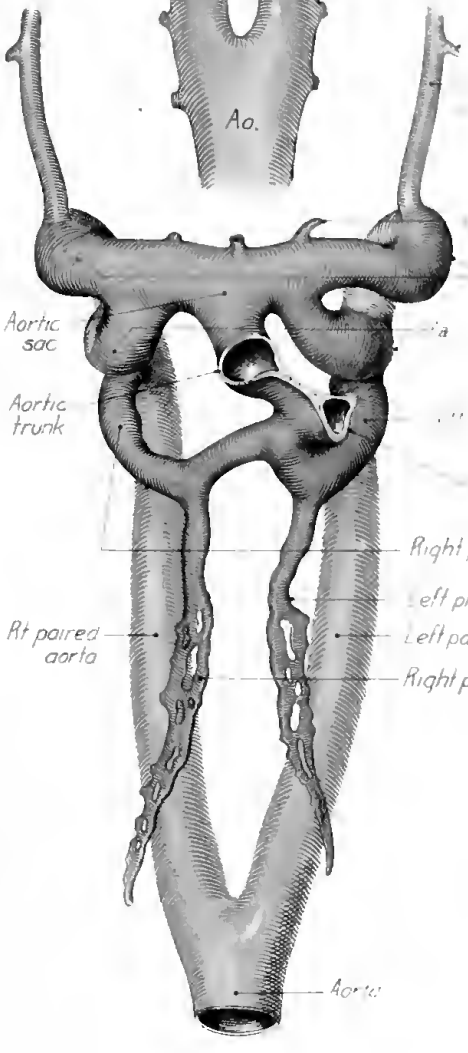

Fig. 35

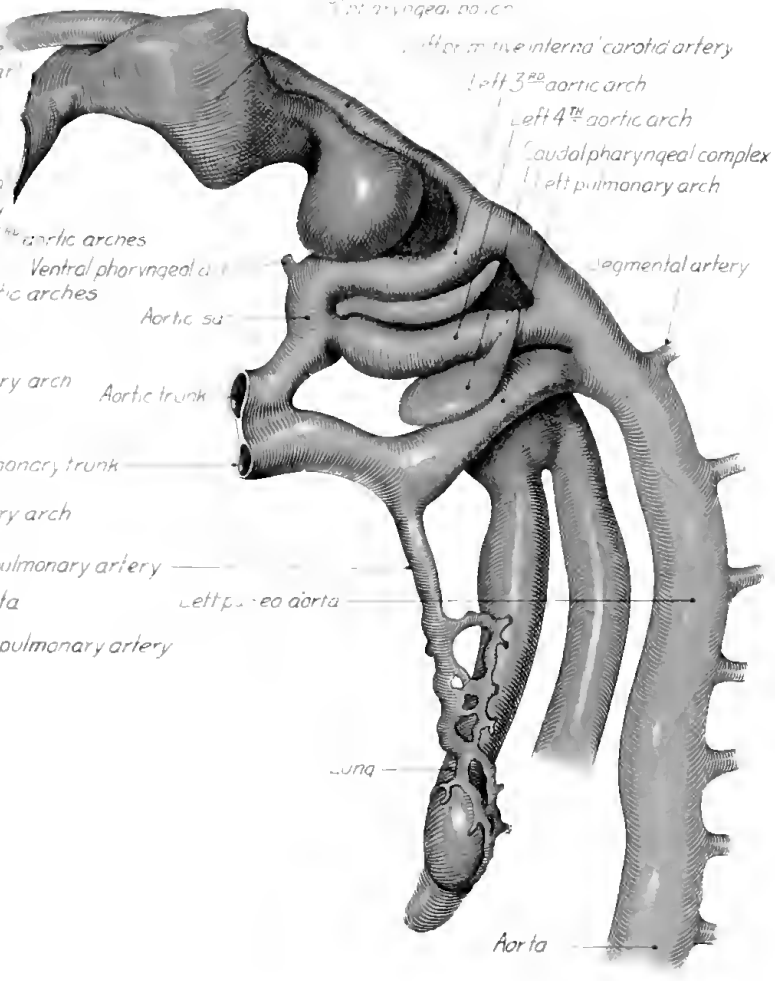

Fig 36

J. F. Didusch fec.

A. Hoen & Co. Lith.

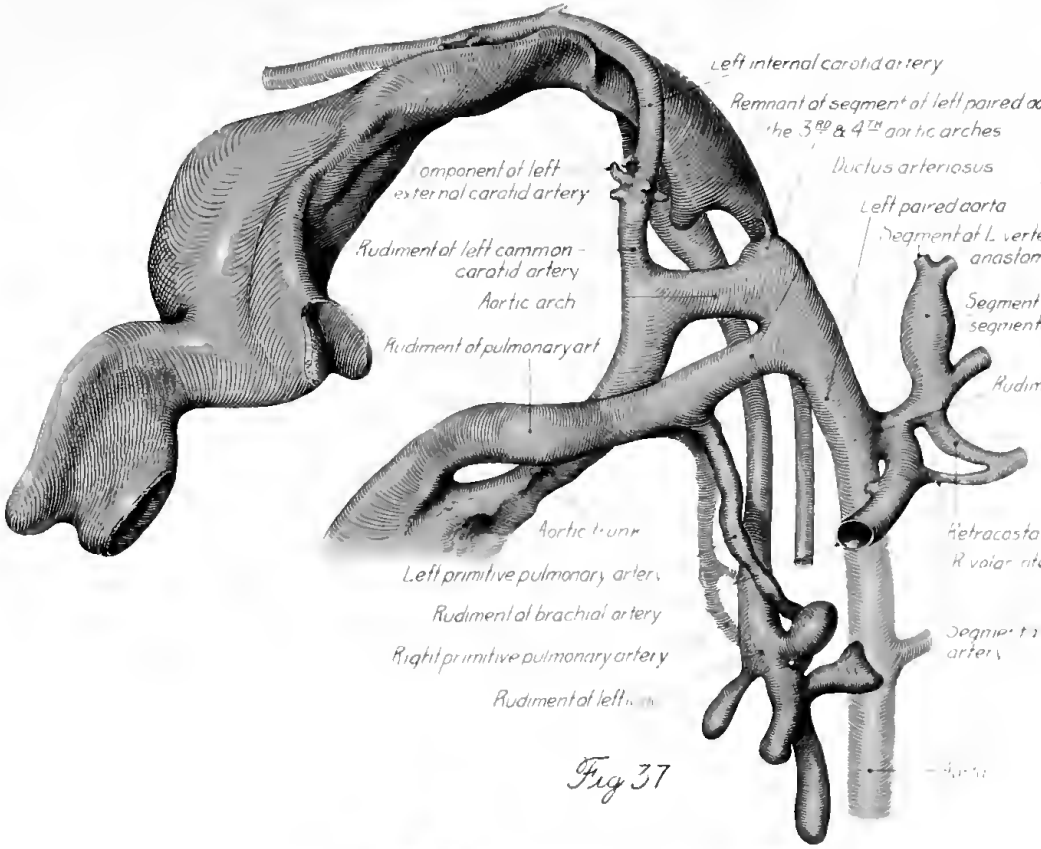

Fig 37

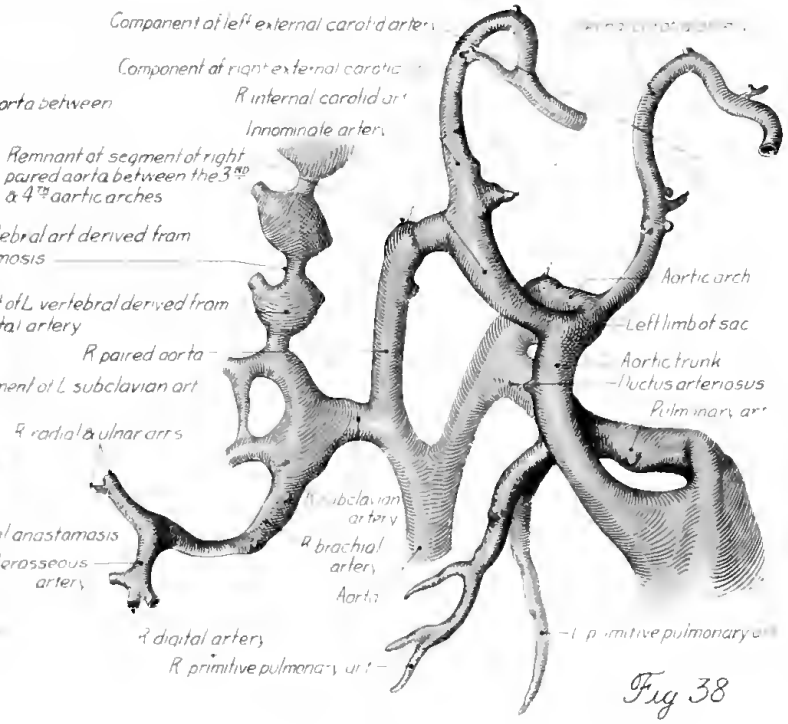

Fig 38

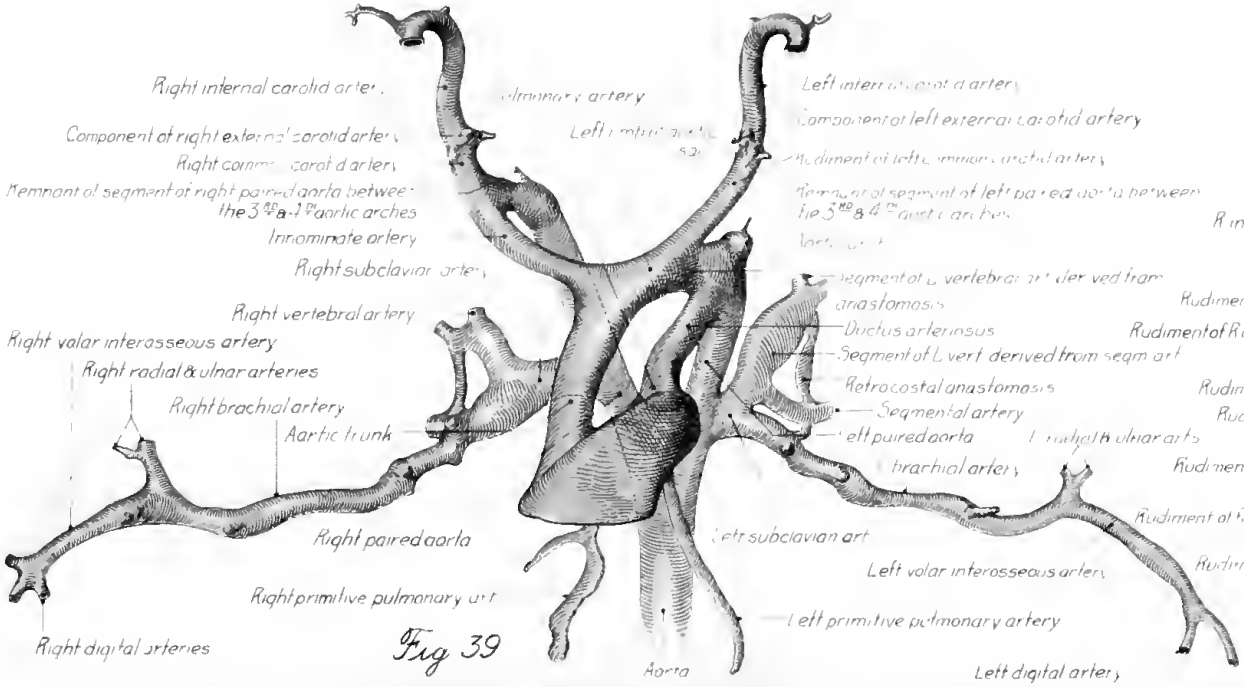

Fig 39

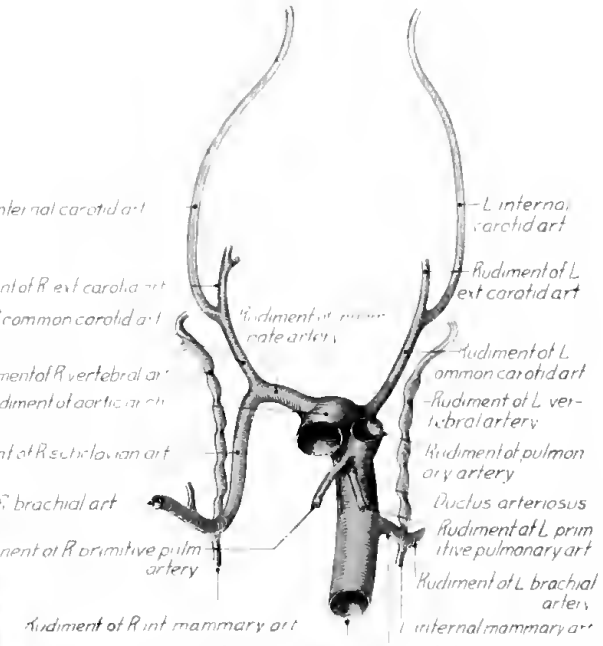

Fig. 40

J. F. Didusch fec.

A. Hoen & Co. Lith.

CONTRIBUTIONS TO EMBRYOLOGY, No. 69.

DEVELOPMENT OF THE AURICLE IN THE HUMAN EMBRYO.

By George L. Streeter,
Carnegie Institution of Washington, Department of Embryology.

With six plates and eight text-figures.

DEVELOPMENT OF THE AURICLE IN THE HUMAN EMBRYO.

INTRODUCTION.

In order to obtain objective criteria for the determination of the age of human embryos, it has been found necessary to seek characteristics other than size. The practice of basing such determinations on the length of the specimen, which is the custom at the present time among anatomists, has proved in several respects unsatisfactory, particularly as young embryos vary greatly in length according to the posture in which they happen to undergo fixation, and for the further reason that, when placed in formalin or other fixing solution, embryos become distended by the solution to a degree that adds considerably to their length and weight. This increase in volume varies according to the size of the specimen and the condition of its tissues. Smaller specimens undergo a greater relative increase than the larger ones and fresh specimens greater than macerated ones. Furthermore, this acquired distention gradually disappears and hence the size or weight of a given specimen will vary according to the time that has elapsed since its fixation.

These sources of inaccuracy, which are of disturbing importance in the case of young embryos, are of less importance in larger fetuses, because in these it is possible to standardize more accurately the measurements and to control fully the posture of the specimen. Also, in large fetuses the factor of distention by the fixative is of less moment; the increasing imperviousness of the integument retards the absorption of the fixative solution and the weekly increment in size reaches proportions that render the fixative distention a factor of progressively diminishing importance.

The period during which length is particularly unreliable as an indication of the age of a specimen, and for which we are in the greatest need of more accurate criteria of development, is the first two months; that is, from the earliest stages up to about 30 mm. length. This was pointed out by Mall (1914), who proposed the subdivision of this period into stages, based upon the development of external features, such as the branchial arches, arms, and legs.

In attempting this standardization it soon became apparent that it would be necessary to survey the details of the external form more carefully than had previously been done. This meant the study of more specimens and better photographic records, so planned as best to display individual regions. This is particularly true of the human embryo, where the difficulty of distinguishing between real and accidental differences is increased by the varied conditions under which the material for study is obtained. It was, in fact, the recognition of such a need that led Spaulding (1921) to make a detailed study of the steps in the differentiation of the external genitalia. The successful outcome of his investigation testifies to his wisdom in limiting his attention to a definite region. It is clear that before a satisfactory series of developmental stages, based on external form, can be arrived at, it will be necessary to study separately each part of the body and establish the normal sequence of differentiation, region by region.

What was done by Spaulding for the external genitalia I have endeavored to do for the branchial region, and it is my purpose in the following pages to outline what seem to be the significant morphological features in the transformation of the tissues in the neighborhood of the first gill-cleft into the definitive auricle.

HISTORICAL.

Most of the investigators who have published accounts of the development of the auricle have shown a lively interest in the branchial hillocks and have placed great emphasis on them as the essential factors in the acquirement of the final form of the auricle. I am of the opinion that too much importance has been attributed to these hillocks, and that the auricle, instead of being a composite structure—the fused product of a group of separate and discrete masses—comes into existence as an intact and continuous primordium, which, by the ordinary processes of differentiation, gradually becomes elaborated into its final form. It arises, for the most part, from the mesenchymal cells of the hyoid bar; the overlying ectoderm, also, may play an important rôle in its determination. It is possible that it is entirely of hyoid origin and that the mandibular elements are nothing more than the product of cells that have migrated forward into that region. In support of this idea is the fact that the mandibular parts, when first seen, are mostly in the deeper levels. However that may be, as soon as one can begin to outline the condensed tissues constituting its primordium, the whole auricle is continuous and exhibits the essential contours of the mature structure.

Before entering into this subject more fully, it might be well to outline the principal steps in our present knowledge regarding the development of the auricle. To make the history brief, condensed abstracts of the more significant observations will be given in chronological order, as far as I have been able to follow them.

Moldenhauer (1877), in a careful study of the development of the middle and external ear of the chick, discovers the occurrence of two pairs of hillocks on the first and second branchial arches, which he terms *colliculi branchiales externi*. He regards these as connected with the development of the external auditory meatus, the tragus being derived from the first arch and the anti-tragus from the second arch. They are present on the sixth and seventh days of incubation, and on the eighth day they become transformed into the definitive parts of the meatus. Thinking of the head as erect, with its longitudinal axis in the vertical plane, the author speaks (p. 118) of the hillocks in front of the first gill-cleft as "superior" and those behind the first gill-cleft as "inferior." The ventral pair he calls "anterior" and the dorsal pair "posterior." Thus, the hillocks of the mandibular bar become, respectively, colliculus posterior superior and colliculus anterior superior, and the hillocks of the hyoid bar become colliculus posterior inferior and colliculus anterior inferior.

His (1882), in describing the external form of human embryos between 12 and 30 mm. long, briefly mentions the occurrence of branchial hillocks around the first gill-cleft, similar to those found by Moldenhauer in the chick. Instead of four, however, he finds six. There are two hillocks on the mandibular arch, the lower one becoming the tragus, the upper becoming the spina helicis. At the upper end of the first gill-cleft is the colliculus intermedius, which forms all of the helix with the exception of the spina. On the hyoid arch he finds three hillocks, the upper one becoming the anthelix and the next lower the antitragus; the lowest one seems to disappear and become covered in by the tragus.

His (1885), in describing the development of the ear, gives a classical account of the auricular hillocks (or tubercles, as he names them) which has dominated all subsequent literature. He describes the auricle as arising from the nodular edges that surround the first gill-cleft, very early showing a subdivision into six hillocks, which he numbers consecutively 1 to 6. He divides the mandibular arch into a dorsal and a ventral portion. On the ventral portion is the first hillock (tuberculum tragicum). The remainder of this portion takes no further part in the formation of the auricle, becoming the lip-ridge and jaw-ridge, the latter subsequently covering in and fusing with hillock 6. Hillocks 1 to 5 form a plump ring surrounding the first gill-cleft, which thus becomes the fossa angularis. In this process hillocks 1 and 2, also 2 and 3, partially fuse. Between 3 and 4 there is a deep furrow; 3 is continued as a tail caudal to 4 and loses itself in the neighborhood of hillock 6. The eventual helix is formed by the union of hillocks 2 and 3, together with the tail-like process extending from the latter. The anthelix is derived from hillock 4, the lobule from hillock 6. The tænia lobularis is a remnant of 6. The tragus is derived from hillock 1, the antitragus from hillock 5. In addition to these hillocks, the author describes a tuberculum centrale, which takes the form of a transverse elevation in the floor of the fossa angularis, separating the upper and lower depressions. It consists of a connective-tissue pillow or swelling of the closure plate of the first gill-cleft. The cartilaginous strand belonging to the second arch extends into it. It contains a small blood-vessel, the stapedius artery. The furrow between hillocks 1 and 5 he designates as the sulcus antitragicus, while the lower end of the fossa angularis he calls the incisura intertragicus. The crus, or spina helicis, is derived from a fusion of hillocks 2 and 4.

Kastschenko (1887), in a study of the fate of the mammalian gill-clefts, in which he concerns himself particularly with the thymus and thyroid, describes the external auditory canal of the pig, which, he points out, is a secondary formation, its tip only being a true remnant of the first epidermal pocket. He pictures five auricular hillocks, as seen in 12, 13, and 15 mm. specimens, but does not clearly trace them into the eventual ear. Kastschenko's figures correspond fairly well with the description given by His for the human, with the exception of the fifth and sixth tubercles. Kastschenko's hillock 5 seems to correspond to His's hillock 6.

Tartaroff (1887) reports a relationship between the character of the skin and the underlying cartilage covering the auricle, particularly as to the presence of hair and subcutaneous fat. The growth of the cartilage results in tension of the skin, which he regards as the cause (pressure atrophy) of the lack of fat and the disappearance of hair, and it is inferred that the resistance of the skin may explain the folding of the ear cartilage.

Gradenigo (1888) presents a study of the development of the auricle in a series of mammals, including man, pig, cat, guinea-pig, rabbit, sheep, and cow. In the last three his studies were controlled by serial sections. Like the previous authors, he found six hillocks, three on the mandibular arch and three on the hyoid arch. According to Gradenigo, the hillocks flatten out and tend to fuse together. The four lower ones, by closing in around the lower hyomandibular groove, form the external auditory meatus and the floor of the future fossa angularis. In doing this the hillocks disappear for the most part. The hillocks do not form the auricle proper; this arises through the fusion of two elevations immediately adjacent to the hillocks, which the author names *helix hyoidalis* and *helix mandibularis.* These elevations appear at about the time of the flattening out of the hillocks. In later stages these two elevations fuse above and below, thus surrounding the region of the hillocks and thereby forming the auricle. The hillock region corresponds to the fossa angularis and becomes the future concha and the entrance to the external auditory meatus. In tracing the formation of these elevations from which the auricle is derived, Gradenigo points out that the helix hyoidalis first makes its appearance just behind the middle hyoid hillock and from there spreads behind the other two hyoid hillocks. Its upper end arches forward over the region of the hillocks. At this stage in its development we have a structure resembling the cauda of the third hillock of His. The helix mandibularis makes its appearance somewhat later than the helix hyoidalis, its upper part being better developed than the lower part. The lower part forms the tragus. In addition to fusing above and below, the helices develop processes which extend transversely across the fossa angularis. One of these becomes the eventual crus helicis, and another forms part of the crus inferius anthelicis. The other processes become lost. The paper is not very well illustrated, so that it is difficult to follow the author's description in detail. However, he reviews the pathology of this region and gives an account of a variety of teratological conditions. He points out that the lobule makes its appearance later in man than in other mammals and that it is derived from the growth of the lower end of the helix hyoidalis.

His (1889) gives a morphological description of the adult auricle in man. He goes into particular detail regarding the lower part of the ear, especially the lobule.

Schwalbe (1889), in the first of a series of important papers on the development of the auricle, briefly describes the form of the auricle in human fetuses ranging from 60 to 180 mm. sitting height, and in doing so he introduces the more accurate technique of physical anthropology. He points out that the crown of the ear (satyr tip) is not the same as the Darwin angle. The Darwin angle is the true ear-tip and first makes its appearance in the human fetus about the middle of the third month. It becomes less distinct in the later months, due to its thickening and the rolling in of its edge. The rolling in of the ear he regards as a reduction process.

Schwalbe (1891*a*), in his next paper, discusses the Darwin tubercle (*i. e.*, the true ear-tip) as it occurs in adult man. He describes six degrees of its occurrence, varying from the most pronounced type, resembling the Macacus form, to the least marked, where no trace of the ear-tip can be recognized. He explains the increase in ear dimensions, occurring with advancing age, as due to the flattening out of the various folds of the auricle. This he regards as connected with the loss of elasticity of the elastic fibers of the skin and cartilage, and as related to the wrinkling of the skin which accompanies loss of elasticity in the aged.

In his next paper, Schwalbe (1891*b*) points out the significant fact that in reptiles that lack an external ear (lizard and turtle) there occur distinct hillocks in the embryo, resembling those in vertebrates that develop an auricle. These hillocks undergo degeneration and are reduced to the level of the surrounding skin. He finds in both birds and reptiles hillocks corresponding to the tragus and antitragus hillocks of His. These animals have one hillock (Auricularkegel), situated dorsal to the first cleft, which seems to represent a more primitive apparatus than is present in mammals, although it may be related to the helix system. In Salachians it possesses a spiracle.

Schaeffer (1892-1893), reviewing the embryonic stages of the auricle, endeavors to trace them to their phylogenetic representatives in adult mammals. He describes the six hillocks as found in the embryo and notes their change in form in the 18-mm. embryo, which change he regards as due to opacities of the covering skin. The opacities are produced by cell accumulations, which usher in the fibro-cartilage of the auricle. The first part of the auricle to make its appearance is the inferior-posterior part of the helix. This is followed by the tragus and antitragus and finally (20 mm.) by the crus helicis. Schaeffer points out that the anterior crus of the anthelix is present in all mammals. The folds of the anthelix, which can be seen in the 50-mm. embryo, are present only in Primates. The lobule is a later acquisition and is found only in anthropoids and man.

In 1897 Schwalbe published an account of the development of the auricle in the human embryo which ranks with that of His (1885) in having dominated all subsequent descriptions. He describes the six hillocks substantially in the same manner as was done by His. The auricle, however, he regards as quite separate in origin from the hillocks. It appears as a fold of skin, resembling an eyelid, caudal to hillocks 4 and 5. (This fold of Schwalbe's corresponds fairly closely to the helix hyoidalis of Gradenigo.) From the region corresponding to hillocks 2 and 3 is formed the helix ascendens, the lower end of which becomes the crus helicis. Above, the helix ascendens is continuous over the first gill-cleft with the main ear-fold, the point of union being sharply kinked and corresponding to the crown angle (satyr tip) of the mature ear. The helix ascendens does not exactly correspond to the helix mandibularis of Gradenigo, in that the tragus is not derived from its lower end. Schwalbe derives the tragus from hillock 1, as did His; the antitragus he derives from hillock 6. Like Gradenigo, he derives the lobule from the lower end of the ear-fold (helix hyoidalis). He traces hillock 4 into the anthelix system, especially into the inferior crus of the anthelix. The crista anthelicis inferior is probably derived from hillock 5. With the further development of the free ear-fold, three important angles can be recognized along its margin: (1) at the junction of the helix ascendens and the ear-fold, the crown angle or satyr point; (2) in the middle of the ear-fold, the posterior angle or Darwin point; and (3) at the lower end of the ear-fold, where it merges into the lobule, the posterior-inferior angle. Schwalbe points out that one can draw a straight line separating the hillock region from that of the free ear-fold. This line falls above the upper end of the helix ascendens and passes down, posterior to the antitragus, to the point of junction of the lobule and the free ear-fold. The hillock region lies in front of this line and is more or less constant in all types of auricles; the free ear-fold lies posterior to the line, and the degree of development of this part of the ear is the chief factor in producing the different types of ears found in various mammals The author describes the occurrence, during the fourth month, of ridges in the free ear-fold, which he regards as the temporary presence of the longitudinal folds that become permanent in some of the other mammals. His paper is accompanied by an instructive table in which are listed the separate hillocks, their embryological designations, and the part each takes in the formation of the definitive auricle, including the terminology of His and Gradenigo.

Münch (1897) describes the morphology of the auricular cartilage in human embryos 20, 48, 57, 96, and 142 mm. long, as seen in wax-plate reconstructions. In studying its histogenesis, the author notes the close relationship existing between the cartilage and the ectoderm and describes the characteristic appearance of the ectoderm over the auricular region. He alludes to the relatively large size of the spina helicis in early stages and its subsequent tendency to become pinched off. It seems never to become completely detached in man, but does so in other animals. It is then designated *scutulum*.

Ruge (1898) presents a comparative anatomical study (Ornithorhynchus and Echidna) of the cartilage of the auricle. He bases his argument on its adult connections, regarding the cartilage of the auricle as a derivative of the hyoid arch. The tympanic end of the cartilage of the external auditory meatus is most closely connected with the hyoid by connective tissue and common musculature. In tracing it peripherally, its medial terminal part becomes the concha, and the lateral terminal part becomes the tragus. The author emphasizes the unity of the external auditory meatus and the auricle.

Hammar (1902), in describing the development of the middle ear and external auditory meatus in man, points out that the fossa conchæ (angularis) certainly arises directly from the first branchial cleft, and thus we have as derivatives of the first cleft the incisura intertragicus, cavitas conchæ, and cymba conchæ. All the other furrows of the auricle are secondary. In referring to the hillocks, the author states that he does not find that they take part in the formation of the floor, but rather that the auricle is derived from two ridges that are independent of the auricular hillocks, somewhat as described by Gradenigo (helix mandibularis and helix hyoidalis). The hillocks are not so sharply marked as has been indicated by previous writers. They consist only of slight thickenings of a more or less uniform subepidermal connective-tissue layer. Hammar regards it as artificial to describe them as independent structures which shove over and fuse with one another. He makes the important observation that the hillocks are more or less absorbed in the swellings from which the auricle is derived.

Schmidt (1902) made a comparative anatomical study of the auricle, with examples from the following orders: Primates, Prosimiæ, Rodentia, Perissodactyla, Artiodactyla, and Carnivora. The paper is accompanied by a limited number of excellent drawings. The author regards the human auricle as rudimentary and finds that most of its morphological characteristics can be recognized in the ear of other mammals.

Baum and Dobers (1905) describe the development of the auricle in the pig and sheep. In the early pig embryo six auricular hillocks are found, corresponding closely to the His description for man. Hillock 1 can not be recognized in the sheep; in the pig it becomes the tragus. The ear-fold is derived from hillocks 4, 5, and 6. Hillocks 2 and 3 acquire cartilage and form the crus and helix ascendens. Hillocks 4, 5, and 6, in addition to forming the ear-fold, become elongated into three longitudinal ridges which constitute the anthelix. Hillocks 2 and 5 fuse and create a transverse ridge which divides the fossa angularis into a dorsal part (scapha) and a ventral part (concha), which is continuous with the external auditory meatus. This paper is accompanied by very few figures of the earlier stages, so that it is not possible to follow accurately the transitions referred to by the authors. They describe the development of the scutulum and find that it has the same origin as the auricular cartilage and is a derivative of it. They regard it as identical with the spina helicis of man, which has become detached by the pull of the massive anterior auricular cartilage.

Keith (1906) gives the results of an anthropological study of the mature auricle, with the view of determining the relation of one group of people to another, his records extending to 8,567 males and 6,577 females, belonging to Germany, Scotland, England, Wales, and Ireland, and including representatives of the insane, criminal, and vagrant classes. He regards it as unlikely that we shall obtain any light on racial affinities from the study of the form of the auricle.

Henneberg (1908) describes the development of the auricle in the rat, rabbit, and pig. His descriptions are accompanied by a series of excellent illustrations, which give the principal stages of development from the time of the formation of the auricular hillocks until the auricle has acquired its mature characteristics. The fate of the individual hillocks appears to be the same in the three forms studied. Henneberg differs from Schwalbe chiefly in regard to hillocks 4 and 5, which, according to him, give origin directly to the ear-fold (primitive scapha). By the fusion of hillocks 1 and 6 the first gill-cleft becomes converted into the fossa angularis. Through the undermining of the surrounding wall this fossa becomes converted into the concha, while the wall itself gives origin to the tragus, antitragus, helix, and parts of the definitive scapha. In all of the three animals studied, the inner surface of the scapha shows the presence of longitudinal ridges which are derived from the hyoidal hillocks. In the rodents these disappear, but in the pig they remain as the permanent longitudinal folds.

In 1910 Henneberg made a study of the function of the auricle, in which special attention is given to the closure mechanism as it occurs in a variety of mammals. He believes that in man the auricle serves not only as a sound collector but also as a closure mechanism whose function has remained rudimentary. The presence of the anthelix, the small size and rolled-in character of the helix, and the rudimentary character of the auricular muscles are all regarded by him as evidences of the reduction of the auricle in man.

Boas (1912) published the results of a comparative anatomical study of the mammalian adult auricle and its contained cartilage. The work is accompanied by an excellent series of plates illustrating the matter exhaustively. The author has perfected a method of preparing the ear-cartilage so that it can be completely flattened out, thus greatly increasing the possibilities of comparing one form with another. He introduces a new terminology which simplifies the analysis of the different parts of the cartilage. The term *plica principalis*, used for the crus inferius anthelicis, is a term that will surely be of the greatest value.

Schwalbe (1916), in a comparative anatomical study of the primate auricle, summarizes and extends his previous studies on this subject. He still regards the auricular hillocks as the basis, in all mammals, for the form of the outer ear. The fact that they are present in reptiles he regards as proof that the organ, which first reaches its characteristic form in mammals, may make its appearance in earlier stages of phylogenetic development. In human embryos the hillocks become modified into a hillock region, whereas there is a fold back of hillocks 4 and 5 from which is formed the free ear-fold or scapha. The variations in this free ear-fold account for the chief differences in ear-tips. The author points out that in those animals that live in water, in subterranean burrows, or in trees the ear-fold is reduced, whereas these forms retain the hillock region, which serves to protect the entrance to the external auditory meatus. The free ear-fold is greatly increased in nocturnal animals. It is of interest to note that similar types of ears may occur in diverse forms living under similar conditions.

Sera (1917) maintains that the human auricle, with the folded helix and without the Darwin tubercle, constitutes the original and primary form. The unfolded ear with the Darwin tubercle represents an arrest of development and has no phylogenetic significance.

TERMINOLOGY

The terminology of the external ear now in general use is a purely descriptive one and is based upon the form usually met with in the human adult. In its establishment scant attention has been given to the embryonic stages and as little to the ear of other animals. It is therefore not surprising than one finds the terminology more or less inadequate for any critical analysis of the auricle or for the study of any other ear than that of adult man. When the appropriate time comes, the nomenclature of the external ear will benefit, as much as that of any other part of the body, by a thorough reconsideration. In this paper I shall depart but little from the prevalent terminology and then only where it seems unavoidable. As can be seen in figure 2, the following new terms have been utilized: *fossa articularis superior*, for fossa triangularis; *fossa articularis inferior*, for cymba conchæ; *plica principalis* (introduced by Boas, 1912), for crus inferius anthelicis; *crus helicis*, to include all that part of the helix derived from the mandibular arch; on the median side of the cartilage corresponding to the articular fossæ: *eminentia articularis superior,* for eminentia fossa triangularis; and *eminentia articularis inferior,* for eminentia conchæ.

It may be pointed out here that the two articular eminences (fig. 1) are continuous with each other anteriorly, and that together they constitute a relatively rigid, bowl-shaped base from which the auricle is suspended. It is this part only of the auricular cartilage that offers a contact surface suitable for its attachment to the skull, and it may therefore be designated as the *pars articularis.* It is chiefly the inferior eminence that contributes to the surface, although the anterior and lower portions of the superior eminence also take part. The band-like fenestrated cartilage surrounding the external acoustic meatus likewise has a bony attachment, but this is quite different in character from the pars articularis; it may be compared rather to the tracheal rings, serving as a mechanism to prevent collapse of the meatus. In structure and position it offers little if any support to the auricle.

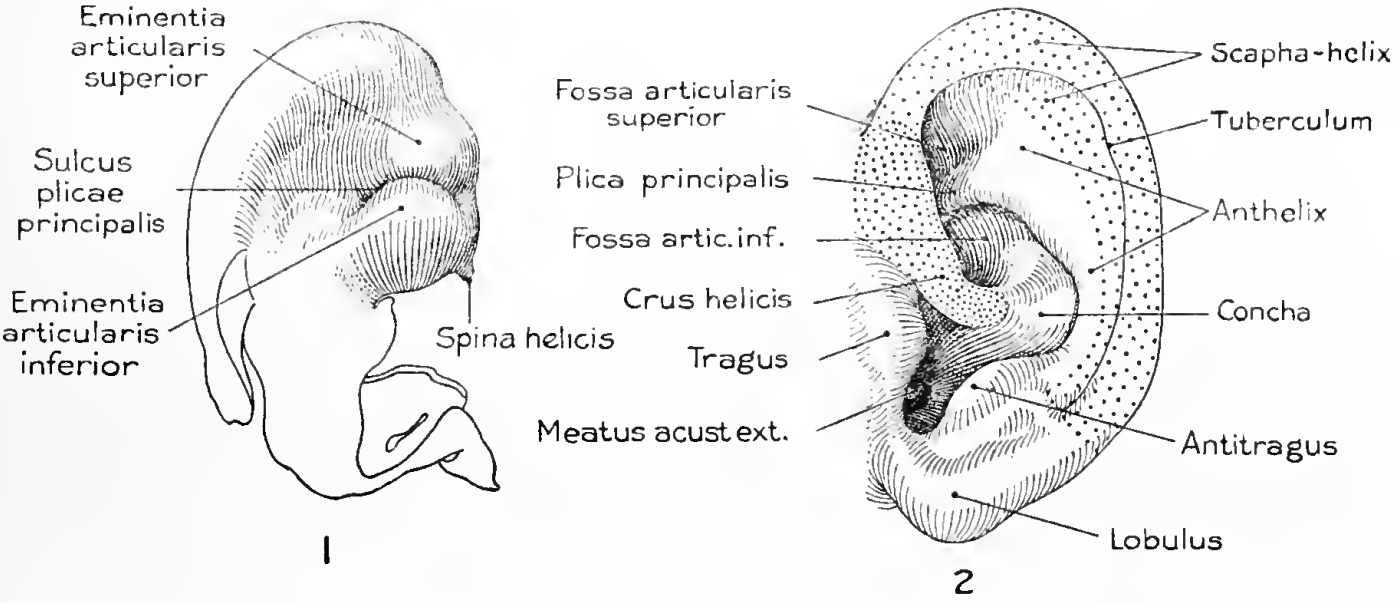

FIGS. 1 and 2.—Human adult auricle, illustrating terminology used in this paper. In figure 1 the auricular cartilage is viewed from the median side, thus showing the two eminences which constitute its main area of contact with the skull. In figure 2 can be seen the cavities (fossæ articulares) of these eminences and the plica principalis projecting between them as a strengthening ridge.

For the convenience of the reader I am appending a glossary containing the principal terms met with in the literature dealing with the development of the auricle. In some instances the author who introduced the term is mentioned.

GLOSSARY.

Anteron [Boas]. By macerating the cartilage of the auricle and auditory canal the whole system can be unrolled into a flat plate. When this is done the plate presents, along its anterior and posterior margins, and particularly in its proximal half, a series of incisures which divide the contour into a corresponding series of processes. The processes along the anterior margin are designated *anteron* 1, *anteron* 2, etc., numbering from the base of the cartilage. The processes along the posterior margin are designated *posteron* 1, etc. In the typical mammalian ear, anteron 5 corresponds to the spina helicis, posteron 4 to the tragus, and posteron 5 to the antitragus.

Anthelix. The rounded brim of the concha, from which the secondary part of the auricle flares out as the scapha-helix. (See fig. 2.)

Antitragus. The thickened ventral rim of the concha, situated between the incisura intertragica and the anthelix. Apparently a part of the closure mechanism.

Cartilago-scutiformis, or **cartilago-scutularis.** See *Scutulum.*

Cauda helicis. (1) Term applied to the terminal process of the cartilage of the helix, which is separated from the conchal cartilage by a cleft (fissura antitragico-helicina). His designated that part of it forming the skeletal part of the lobule as *lingula auriculæ.* (2) The term applied by His to the fold found in the embryo, extending from the third auricular hillock, directly posterior to the fourth and fifth hillocks. According to that author, the adult helix is derived from it.

Cavitas conchæ. See *Concha.*

Colliculi branchiales externi [Moldenhauer]. The name originally given to the hillocks that appear in the embryo on the first and second branchial arches.

Concha. The shell-shaped primary part of the auricle immediately surrounding the meatus. As previously used, the term included only the cymba conchæ and the cavitas conchæ. In this paper I have extended the term to include also what has been known as the fossa triangularis. The contour of the concha thus is outlined by the tragus, incisura intertragica, antitragus, anthelix, and crus helicis.

Crista inferior anthelicis [Schwalbe]. Used synonymously with *crus inferius anthelicis* or *plica principalis.*

Crus helicis. Formerly restricted to the horizontal portion of the helix, forming a transverse ridge in the floor of the concha. In this paper the term is extended to include all that part of the helix derived from the mandibular arch. (See fig. 2.) It constitutes the lateral free edge of the pars articularis conchæ, differing in structure and development from the remainder of the helix.

Crus inferius anthelicis. Fold in the auricular cartilage extending forward from the anthelix and separating the fossa triangularis from the cymba conchæ. Equivalent to *plica principalis,* which is a better term.

Crus superius anthelicis. Ridge limiting the upper border of the fossa triangularis (fossa articularis superior). In using the term *concha* to include this fossa, the crus superius anthelicis becomes merely the upper end of the anthelix itself.

Crus supertragicum [His]. A process sometimes extending forward from the crus helicis to the region just above the tragus. Also called *antitragicum* [Gradenigo].

Cymba conchæ. See *Concha.*

Darwin's tubercle. See *Tuberculum auriculæ.*

Eminentia articularis inferior. See *Eminentia articularis superior.* Formerly known as *eminentia conchæ.*

Eminentia articularis superior. Same as eminentia fossæ triangularis. The pars articularis of the concha, as viewed from the median side, presents two eminences which constitute the chief area of contact of the auricle with the skull. In this paper these are designated, respectively, *eminentia articularis superior* and *eminentia articularis inferior.* (See fig. 1.) The groove between them is the sulcus corresponding to the plica principalis.

Fissura antitragico-helicina. Cleft separating cartilaginous cauda helicis from conchal cartilage.

Fossa angularis [His]. Name applied to the first branchial cleft when modified by the formation of the auricular hillocks, five of which form a plump ring around it.

Fossa articularis inferior. Same as *cymba conchæ.* See *Fossa articularis superior.*

Fossa articularis superior. Same as *fossa triangularis.* When the pars articularis conchæ is viewed from the lateral side, its floor presents two fossæ (superior and inferior) separated by the plica principalis. (See fig. 2.)

Fossa conchæ [Hammar]. Essentially the same as *fossa angularis.*

Fossa intercruralis. Same as *fossa triangularis,* or, as used in this paper, *fossa articularis superior.*

Fossa scaphoidea. See *Scapha.*

Fossa triquetra. Same as *fossa triangularis,* or, as used in this paper, *fossa articularis superior.*

Free ear-fold, or **freien Ohrfalte** [Schwalbe]. The ridge representing first appearance of definitive auricle. Same as *helix hyoidalis* [Gradenigo], *cauda helicis* [His], or *primitive scapha* [Henneberg].

Helix. In adult man the rolled-in margin of the auricle, when viewed as a whole from the lateral side, resembles in outline a coiled spring and on this account it was termed *helix.* Included under it are parts that are quite different, both embryologically and structurally. Furthermore, it is not applicable to the auricle of other animals. If the term *scapha* be used for all of the auricle peripheral to the anthelix, and the term *helix* used for the rolled edge of the scapha, where this occurs, the difficulty is then largely removed. It is so used in this paper, and under *scapha-helix* will be designated only those parts of the secondary auricle derived from the hyoid arch. The crus helicis is a different structure. The lobulus auriculæ is a part of the secondary auricle and bears a similar relation to the concha as does the scapha. (See fig. 2.)

Helix ascendens [Schwalbe]. The anterior portion of the helix which is derived from the third auricular hillock of the mandibular arch. Partially synonymous with crus helicis, as used by me.

Helix hyoidalis [Gradenigo]. That portion of the helix derived from the hyoidal arch, from a fold posterior to the fourth, fifth, and sixth auricular hillocks. Same as *cauda helicis* [His] and *helix posterior* [Schwalbe].

Helix mandibularis [Gradenigo]. Fold found in the embryo directly in front of the third auricular hillock and extending down in front of the second and first hillocks. According to Gradenigo, this fold gives origin to the anterior end of the helix, crus helicis, and tragus.

Helix posterior [Schwalbe]. That portion of the helix derived from the hyoidal arch. Same as *helix hyoidalis* [Gradenigo].

Incisuræ cartilaginis meatus auditorii externi [Santorini]. Clefts in cartilage of external meatus, somewhat analogous to the clefts between the cartilaginous rings of the trachea.

Incisura intertragica. The cleft between the tragus and antitragus. A derivative of the lower end of the first branchial cleft.

Lamina tragi. Cartilaginous plate supporting tragus.

Lingula auriculæ [His]. See *Cauda helicis.*

Lobulus auriculæ. The free edge of the auricle below the antitragus continuous with the scapha helix. See *Helix.*

Margo oralis helicis [Baum and Dobers]. Anterior free border of auricle, particularly in such animals as the pig. In a similar way the posterior border is referred to as *aboral.*

Pars articularis conchæ. The upper half of the concha. It includes the two articular fossæ (eminentiæ), plica principalis, crus helicis, and spina helicis. (See figs. 1 and 2.)

Plica auricularis longitudinalis cranialis [Henneberg]. The most cranial of the three longitudinal folds of the scapha in such animals as the pig. The others are designated *medialis* and *caudalis*, respectively.

Plica principalis [Boas]. Equivalent to *crus inferius anthelicis.* Introduced because it is more accurately applied, particularly to the auricle of mammals other than man.

Ponticulus. Ridge on inner surface of conchal cartilage downward from the inferior articular eminence. It appears to be concerned with the ligamentous attachment of the auricle.

Posteron [Boas]. See *Anteron.*

Rima helicis [Albinus]. Perforation of the cartilage of the crus helicis.

Satyr-tip [Schwalbe]. The tip of the auricle toward the crown of the head. Also called *crown-tip* or *crown-angle.*

Scapha. Concave surface of the free portion of the auricle lying between the anthelix and the helix. Term applied by Henneberg to the entire free auricle from the anthelix to the free border. He applies the term *helix* to the unwrinkled border of the scapha.

Scapha primitiva [Henneberg]. Same as *free ear-fold.*

Scutellum. See *Scutulum.*

Scutulum. (Also known as *scutellum, cartilago-scutiformis,* or *cartilago-scutularis.*) This is supposed by some writers to be simply an enlarged spina helicis which has become detached. According to Schmidt, it is an accessory cartilage, connected with the complicated muscular apparatus, which is provided for the auricle of some mammals and is entirely absent in man. See *Spina helicis.*

Spina helicis. Cartilaginous process extending forward from the pars articularis conchæ. (See fig. 1.) It is not in reality a part of the helix. It is supposed that this structure is enlarged and becomes detached in some mammals to form the scutulum.

Tænia lobularis. The fold attaching the lobule to the parotid region. In the embryo it appears before the lobule itself, being derived from the ventral end of the hyoid bar below hillock 6. It is the extension and widening of the tænia as a free fold, to join the lower end of the helix, that produces the lobule.

Torus marginalis, or Randwulst [Henneberg]. The rounded border inclosing the fossa angularis. It makes its appearance as the hillocks disappear. The latter contribute in part to its formation.

Tragus. The thickened margin of the anterior wall of the concha, situated between the incisura intertragica and the crus helicis. Regarded as a part of the closure mechanism.

Tuberculum anthelicis [His]. Auricular hillock No. 4.

Tuberculum arterius [His]. Auricular hillock No. 2, the middle hillock of the mandibular arch.

Tuberculum auriculæ. The so-called *Darwin's tubercle.* Corresponds to the true ear-tip of the long-eared mammals [Schwalbe].

Tuberculum centrale [His]. Transverse elevation in floor of fossa angularis, separating it into an upper and a lower depression, the lower becoming the auditory meatus. It arises as a bulging of the closure plate of the first gill-cleft.

Tuberculum innominatum. Small cartilaginous anterolateral elevation at junction of horizontal portion of crus helicis with the helix ascendens, *i. e.,* mandibular portion of helix.

Tuberculum intermedius [His]. Auricular hillock No. 3, the one at the top of the first branchial cleft.

Tuberculum supratragicum [His]. Term applied to the accessory elevation that sometimes is found at the upper edge of the tragus. In these cases the tragus may be regarded as two-lobed. The separation of the tragus into two lobes occurs in varying degrees of distinctness.

Tuberculum tragicum [His]. Auricular hillock No. 1, the lowest hillock of the mandibular arch, giving origin to the tragus.

TOPOGRAPHY.

In very young embryos (up to 12 mm. long) the branchial area involved in the formation of the external ear constitutes a considerable portion of the ventrolateral surface of the head. Growth in this area is precocious and in advance of the surrounding structures. As the elements of the face and cranium later undergo differentiation, the auricular area becomes relatively smaller, and at the same time it appears to migrate dorsolaterally from near the median line, until it finally occupies its adult site on the lateral surface of the head. The transition in relative size and position of these structures can be traced through figures 9 to 12 (plate 1), in which the auricular area at different stages is shown in blue.

If we start with the primitive branchial arrangement existing in a 6-mm. embryo, a condition is met with such as is shown in figure 9. Specimens at this early period, when fixed in formalin, are moderately transparent, and thus it is difficult to make out their true form. By slightly staining the specimen, as was done in this case, it is possible to distinguish more clearly the surface modeling and to represent these structures accurately. In order to display completely the face region, the greater part of the trunk was removed, leaving only the pericardial dome and cut end of the aortic trunk.

The drawing which we are considering was made directly from the specimen and presents a three-quarter view of the four branchial arches of the left side. It is only by tracing backward from older stages, where the auricular area is pronounced, that one can outline it at this stage. For this purpose actual specimens were compared, as were also enlarged models in which the branchial region was completely exposed and in which analogous parts could be identified. When the same proportionate area is plotted in this way on the mandibular and hyoid arches, one obtains the result shown in blue in figure 9. Practically the whole surface of the hyoid arch subsequently takes part in three thickenings, known as the *auricular hillocks* numbers 4 to 6. In the same way the greater part of the surface of the mandibular arch enters into the formation of the first three hillocks. It is of interest to note how closely the auricular areas of the right and left sides approach each other in the midventral line. It is from the small interval between them that the mandible and its associated soft parts must be derived. It is true, there was some difficulty in determining the boundary line between the auricular area and the midventral segment of the mandibular arch, as the line of junction is not characterized by any surface marking, nor can any histological difference be yet recognized in serial sections. The area as outlined, however, agrees in form with that seen in the next older stage and is probably accurate.

When the topography of the auricular region in the stage shown in figure 9 is considered, it can be readily understood that failure on the part of the mandible to develop would leave the external ears near the median line in front of the upper part of the neck. The literature records cases of agnathia or synotia which are of this nature. Two of these are reproduced in text-figures 3 and 4. In them the early position of the auricles is retained, owing to the fact that there was nothing to wedge the two auricles apart, as is normally done by the growing mandible.

In embryos of 8 to 11 mm. the component parts of the mandible have begun to express themselves, and with their increase in size there is a corresponding spreading apart of the auricular areas of the two sides, as shown in figure 10. This drawing was made from a reconstruction model, which, because of the development of the auricular hillocks, shows very clearly the surface area that enters into the formation of the external ear. In the 6-mm. embryo we were dealing with a series of four simple branchial bars; here these bars have partially lost their identity. The first two have undergone marked development, whereas the third and fourth have become much less conspicuous. The first or mandibular portion is broken up into (1) the part that will form the lower jaw and (2) a more lateral part, whose surface forms the three mandibular auricular hillocks, two of which can be seen in the figure. These hillocks and those of the hyoid bar have caused deflections in the first gill-cleft, whose ventral termination will eventually be represented by the intertragal incisure. The surface of the hyoid bar is entirely taken up with its three auricular hillocks, all of which show in the figure. The small third branchial bar can be seen partly exposed, but the fourth is entirely covered in.

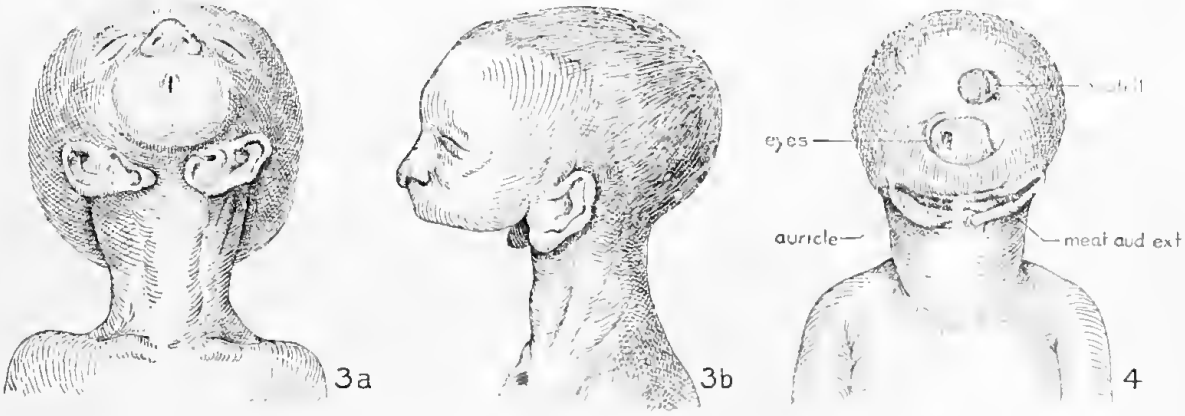

Figs. 3 and 4.—Figure 3 shows (a) ventral and (b) lateral views of an agnathous specimen illustrated in Förster's Atlas of Malformations, 1865 (plate 13, figs. 19 and 20). Figure 4 is copied from a case of cyclopia and agnathia from the Pathological Institute at Heidelberg, described by Schwalbe (1909, p. 615). In both of these cases there is a complete arrest in the development of the greater part of the mandibular arch, with the result that the auricles retain their original median position.

Between the stages of 10 and 14 mm. there is rapid progress in the formation of the face, as can be seen by comparing figures 10 and 11. Figure 11 is drawn from a model to show the details of the face region and the topography of the auricular area, the latter shown in blue. The mouth at this time is fairly well outlined, and one can recognize the region between it and the auricular area which is to form the cheek and jaw. As this region enlarges it will result in the further lateral and dorsal displacement of the auricular area. In the preceding stages the latter still extended downward on the ventral surface of the head, whereas now it is entirely on the lateral surface, and the whole area can be seen in a profile view of the embryo. At this stage the six auricular hillocks show their maximum prominence. The three mandibular hillocks, which at first covered a large part of the mandibular bar, now cover only its caudal margin. The three hyoid hillocks still represent the whole surface of the hyoid bar excepting that part which has been molded into the first cleft. It can be seen in figure 11 that this cleft is much wider than in the younger stages, and we can now speak of a distinct fossa angularis. The ventral third of this fossa becomes relatively deeper to form the external auditory meatus, while the remainder is eventually taken up in the formation of the auricle.

In embryos 16 to 18 mm. long the relations are such as are shown in figure 12, which is a drawing of a model posed similarly to those shown in figures 9 and 11. Owing to the foreshortening in a three-quarter view of this kind, one is apt to get a false impression as to the height of the head; in a true profile view the distance between the eye or ear and the dorsal midline over the midbrain or cerebellum would be much greater. At this time the auricular hillocks, except those continued as the tragus and antitragus, have lost their identity and have been molded into the early form of the definitive parts of the auricle. The beginning helix can be definitely outlined, and less distinctly the crus, the former being entirely a derivative of the hyoid bar, the latter a derivative of the mandibular bar. A fact of interest is that, whereas the crus and tragus form a relatively small part of those adult surface structures that are derived from the mandibular bar, the scapha-helix and antitragus (eventually, also, the anthelix and lobule) constitute the only permanent surface representatives of the hyoid bar.

With the topography of the auricular area thus identified in the four stages just represented, a comparison of these stages discloses certain general facts. Only two gill-bars take any prominent part in the formation of the surface structures of the lower jaw. Of these, the first or mandibular bar contributes by far the greater amount, the second or hyoid bar supplying only a portion of the auricle. The third and fourth bars have no permanent surface record of their existence. The auricular area, relative to the size of the head, covers at first a large surface, but as we pass from simple gill-bars to the stage of hillocks and then to the definite auricle it becomes progressively smaller. Were we to trace it to the stage of 20 to 30 mm., when the face is more fully formed, we would find it still smaller. Thereafter, the increased growth and spreading character of the free auricle counteract the previous relative decrease in size.

Another and perhaps the most conspicuous feature in the topography of the developing auricle is its lateral and dorsal migration. In the stage of simple gill-bars the two auricular areas nearly meet in the midventral line, but, as can be seen in figures 9 to 12, they are gradually crowded sidewise coincidentally with the development of the mandibular apparatus and the structures at the base of the skull. A true profile of figure 12 would show the auricle higher on the side of the head than it there appears. It is to be remembered that this migration is relative rather than real. At all stages the mouth line is in a plane roughly intersecting the middle of the auricle; the appearance of an upward migration is due chiefly to the growth of the angle of the jaw and the elongation of the neck.

THE BRANCHIAL HILLOCKS.

In embryos 4 to 6 mm. long the mandibular and hyoid bars are each subdivided by a transverse groove into a dorsal and a ventral part, as can be seen in figures 13 and 14 (plate 2); also figure 9 (plate 1). These are not to be confused with the branchial hillocks. The significance of the subdivision of these bars has never been determined; we shall see, however, that the closure mechanism is derived from the ventral portions, while the articular and sound-collecting mechanisms are derived from the dorsal portions. His (1882), in describing the mandibular bar in young embryos, mentions the existence of a root part (Wurzelstück) as distinguished from the more ventral portion, which he describes as divided longitudinally into a lip ridge (Lippenwulst) and a mental ridge (Kinnwulst). Careful examination of figures 10 and 11 (plate 1) will show that the ventral part of the mandibular arch is roughly subdivided into two ridges, somewhat as described by His. These ridges do not, however, correspond exactly to the eventual chin and lip, as His first thought. The more anterior one (lip-ridge) in reality gives origin to the greater part of the jaw, the lip being a much later derivative of it. The more posterior ridge (Kinnwulst) corresponds to the soft parts beneath the jaw.

The origin of the branchial hillocks and their fate are shown in figure 5. This figure is intended as a diagrammatic interpretation of figures 13 to 27 (plates 2 and 3). For convenience I have lettered these as a series of successive stages. By comparing them it will be seen that definite hillocks make their appearance in embryos about 10 mm. long, reach their full development in embryos about 14 mm. long, and disappear for the most part between 16 and 18 mm. At stage B, when they first appear (cf. fig. 14), one finds on the dorsal segment of the hyoid bar two opaque elevations corresponding to hillocks 4 and 5. Hillock 4 is strongly suggestive of a facial placode, but on tracing it into the succeeding stages (figs. 15 to 18) it becomes evident that this can not be the explanation. On the ventral segment of the hyoid bar in stage B can be seen an opaque thickening representing the first appearance of hillock 6. At stage C (cf. fig. 15) the three hyoid hillocks are clearly indicated, and at the same time the first indication of hillock 1 can be recognized on the ventral segment of the mandibular bar. The dorsal segment of this bar still forms a round mass corresponding to the Wurzelstück of His.

At stage D (cf. fig. 16) hillocks 4 and 5 are sharply rounded and have reached their maximum development. Hillock 6 becomes subdivided, as indicated in the diagram, and, as will be seen, it is hillock 6′ that eventually forms the antitragus. At this time the dorsal part of the mandibular bar shows the first evidences of hillocks 2 and 3. Along with the appearance of these hillocks the hyoid cleft is widened to form a definite fossa, the fossa angularis of His.

Stage E (cf. fig. 17) represents the hillocks at their maximum development, and it is their appearance at this time that led to the classical description of His and to the numbering of the hillocks serially 1 to 6. Furthermore, it is this appearance that we find duplicated in embryos of other mammals and which resembles also the condition found in birds and reptiles. Microscopic examination of sections through the hillocks at this time shows that they consist of rather sharply outlined masses of condensed mesenchyme cells closely packed against the covering ectoderm. The ectoderm itself is in active proliferation and is much thicker than that of the surrounding regions. In embryos about 11 mm. long the ectoderm can be seen to consist of two layers—a more superficial, flattened membrane one cell thick, beneath which is a layer of closely packed cuboidal cells with large round nuclei. It is this deeper layer that appears to be chiefly involved in the process of proliferation. In slightly older specimens it becomes several cells thick, and in some specimens one finds, at the point where it abuts against the mesoderm, a clear white line consisting of the elongated cell-bodies of the proliferating ectoderm. The changes in the ectoderm are most marked over the areas where the condensation of mesenchyme is greatest and more marked over the hyoid bar (hillocks 4 to 6) than over the mandibular bar (hillocks 1, 2, 3). The whole auricular region, however, exhibits this phenomenon and stands out in strong contrast to the adjacent portions of the head. The evidence of activity on the part of the ectoderm of the auricular region is very striking and appears to be closely related to the changes in the subjacent mesenchyme. In appearance it resembles very much the ectoderm of the arm and leg buds in their earlier stages. I shall refer to this subject later.

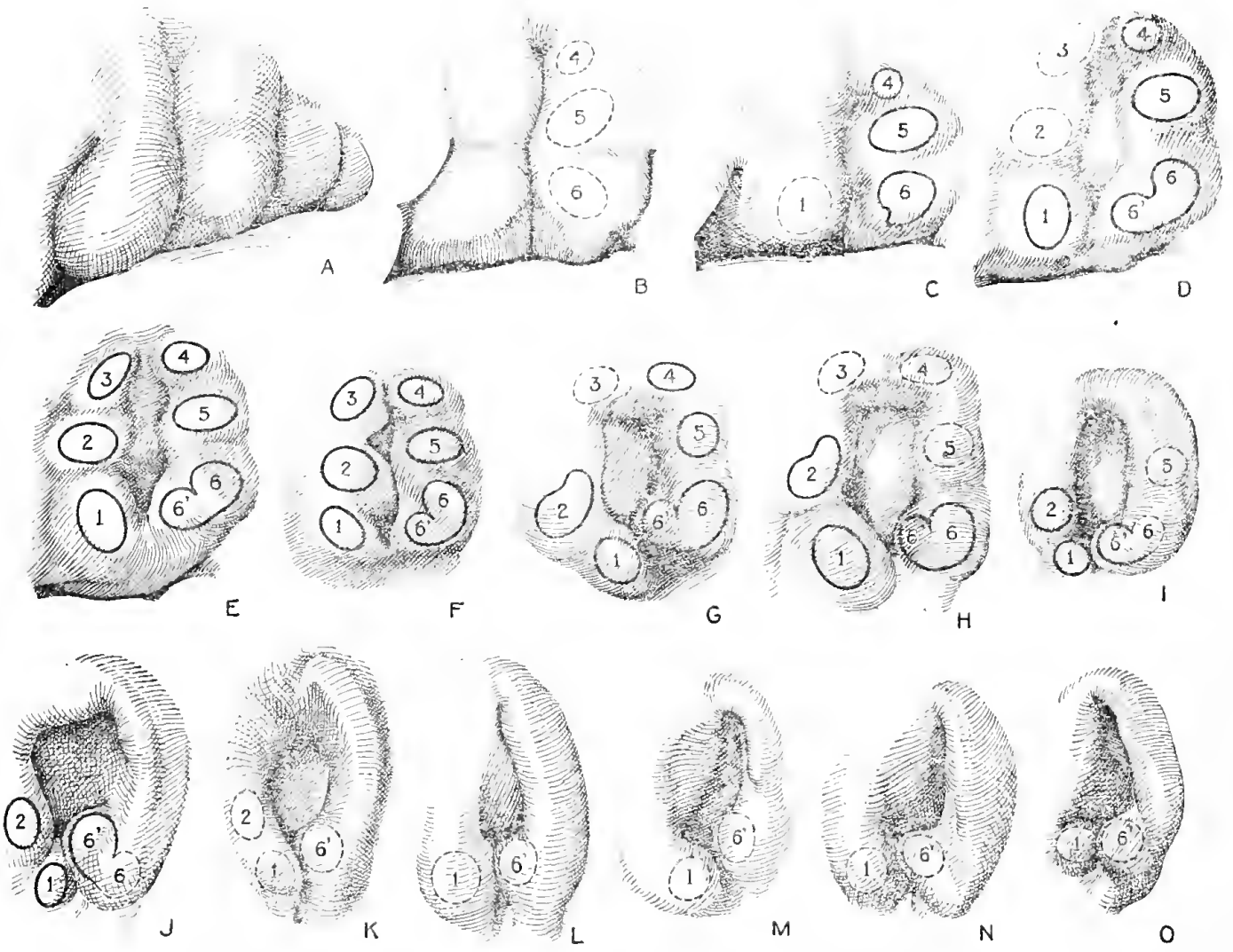

Fig. 5.—A diagrammatic interpretation of figures 13 to 27 (plates 2 and 3), showing the advent and disappearance of the branchial hillocks and the coincident changes in the mandibular and hyoid bars. These stages cover the period of transition from a state of simple branchial bars to the establishment of the primitive auricle. The hillocks are interpreted by the author as foci of more active proliferation of the condensed mesenchymal primordium of the auricle. A to C, embryos 5 to 11 mm.; D to G, embryos 13 to 14 mm.; H to K, embryos 15 to 18 mm.; L to O, embryos 18 to 33 mm. Varying magnifications were adopted so as to bring the structures to about the same size.

The branchial hillocks never reach the same degree of development on the mandibular arch that they do on the hyoid arch, making their appearance later and disappearing earlier. At stage F (cf. fig. 18) they can still be recognized, although they are less distinct than they were in the preceding stage. The specimen selected to illustrate this stage exhibits an anomaly of the fossa angularis, in that a relatively large ridge appears to extend from the region of hillock 2. This is not to be mistaken for the crus helicis; it is due apparently to some peculiarity of this specimen. Hillocks 6 and 6′ are very characteristic at this stage. The latter curves inward and forward, forming a different plane from hillock 6. The two are still, however, partially connected.

At stage G (cf. fig. 19) hillock 3 is beginning to disappear, and hillock 2 is crowded to a more ventral point by the change that has taken place in that region of the mandibular bar, which is preliminary to the formation of the crus helicis. The fossa angularis now forms a rather roomy quadrilateral depression whose floor in this and the next succeeding stages bulges out slightly, corresponding to the development of the tissues in the neighborhood of the head of Meckel's cartilage.

At stage H (cf. fig. 20) hillocks 1, 2, 6, and 6′ are still clearly defined. Hillock 5 can still be recognized but is becoming less distinct. Hillocks 3 and 4 can scarcely be outlined, but in their place is a ridge which forms the rounded contour of the upper end of the fossa angularis. The tissue lying under the other hillocks has been constantly increasing in amount, having the effect of increasing the depth of the fossa.

At stage I (cf. fig. 21), coincidentally with the gradual disappearance of the hillocks, the raised margin of the fossa angularis begins to take the form of definitive parts of the auricle. One can see in the region formerly occupied by hillock 3 that the first evidence of the crus helicis is making its appearance. In the region corresponding to hillock 4 the upper end of the fold in which will form the helix can readily be recognized. The last traces, however, of hillocks 5 and 6 are to be seen. Hillocks 1 and 2 are still quite definite. The relative sizes of hillocks 1 and 2 appear to vary, as does also the degree of separation between them.

At stage J (cf. fig. 22) the conditions are much the same as in the preceding specimen, although the fold of the helix appears to be a little more pronounced and the last vestige of hillock 5 has disappeared.

In studying these hillocks I find that the angle from which they are viewed and the method of illumination have a great deal to do with their appearance. It has also proved necessary to make considerable allowance for the condition of the tissues and the manner of fixation. In the specimens selected for illustration I have attempted to include only the normal and average ones, but even with this precaution I am conscious of the possibility of having introduced examples that are not necessarily typical. I am somewhat doubtful regarding figure 22, as well as figure 18, the peculiarity of which has already been mentioned. In figure 22 the thick fossa angularis is somewhat exaggerated, as is also the fold of the helix. The embryo is absolutely normal, but the tissues seemed a little shrunken at the time the drawing was made. I may mention at this point that all of these drawings were made directly from the specimens by Mr. J. F. Didusch. In most of them the embryo was stained slightly in order to define more clearly the surface markings.

In stage K (cf. fig. 23) the period of branchial hillocks may be regarded as having passed. The remnants of hillocks 1, 2, and 6′ can still be recognized; otherwise, the borders of the fossa angularis are now made up of the sloping surface of the crus helicis and the primitive ear-fold or scapha-helix. Microscopic examination of a transverse section through the ear-fold at this time shows it to be due to a mass of condensed mesenchyme, although differing from the condition found during the hillock period in that there is now a precartilaginous outline of the auricular cartilage, the contours of which can be made out along the posterior edge of the condensed tissue. From the outset this precartilage assumes the typical outlines of the auricular cartilage.

On coming to stage L (cf. fig. 24) we can speak only of remnants of hillocks 1 and 6′. The crus helicis is becoming more distinct and the primitive ear-fold more prominent. With the formation of the crus helicis the fossa angularis loses its identity, and in its stead there is the early form of the concha, divided by the crus into an upper and a lower half.

Stage M (cf. fig. 25) shows a rather marked primitive ear-fold, which is probably a peculiarity of this particular specimen. It may be assumed that any extreme characteristics of the adult ear would have begun to express themselves at this time, and it may be that in this case we would have had an ear with a prominent tip. The tendency toward a pointed process of the ear-fold, however, is an artifact of preservation.

The specimen used to illustrate stage N (cf. fig. 26) is somewhat fuller than the preceding specimen and is more characteristic. The transition from stage N to stage O (cf. fig. 27) brings us to a condition that may be regarded as the definitive auricle. We can now recognize the tragus, antitragus, anthelix, scapha-helix, and, distinctly separate from the latter, the crus helicis. In tracing the hillocks up to this point, it is found that the only ones that can be said to persist are hillock 1 (as the tragus) and hillock 6′ as the antitragus. All of the others lose their identity in the transition of the tissues forming the margins of the angular fossa into the definitive auricle. Sections through the auricle at this time disclose the fact that the condensed mesenchyme, which heretofore made up these elevations, is now entirely resolved into the cartilaginous plate representing the auricular cartilage and the looser subcutaneous tissues, including the muscles and ligaments of the auricle.

ELABORATION OF THE AURICLE.

On plates 4, 5, and 6 I have arranged a series of photographs showing the auricle at different stages of fetal development. It is thus possible to trace the development of its different parts by following them through these photographs. The increase in the size of the auricle holds only for the individual plate, the photographs on plate 4 being enlarged 10 diameters, those on plate 5 being enlarged 6 diameters, and those on plate 6 being enlarged 4 diameters. In studying them, one should keep in mind the considerable variation which occurs in the form of the ear in adults, for this appears to be expressed in the earliest developmental stages. The photographs, however, are sufficiently numerous to make it possible to separate the constant characteristics from the incidental variations due to normal differences in the auricle and differences in the preservation of the specimens.

The photographs on plate 4 are specimens from the third month of intrauterine life. The first two (figs. 28 and 29) overlap the oldest stage shown on plate 3; most of the parts of the auricle can here be clearly recognized, although they are still very simple in form. Derived from the mandibular bar are the tragus and the crus helicis; as derived from the hyoid bar, one can recognize the antitragus and the ridge-like primitive ear-fold or scapha-helix. The incisura intertragica, at the entrance of the concha, still bears a resemblance to the hyoid cleft from which it was derived. The concha does not acquire its concave, shell-like character until later in development, due to the relatively thick and swollen character of the surrounding parts. Figures 30 to 32 differ from the preceding ones only in the increasing prominence of the ear-fold. At this time there is very little surface evidence of the anthelix as distinct from the scapha-helix. However, if sections through this region are examined microscopically, it will be found that the cartilaginous auricle is already characteristically folded into a helix, scapha, anthelix, and concha, the free edge of the helix coming into close contact with the surface of the auricle.

Figure 33 was taken from a slightly different angle and thus exaggerates the tænia lobularis. In the earlier stages the tænia stands out more prominently. The lobule forms a free fold between the tænia and the lower end of the helix, principally at the expense or as an elaboration of the tænia. The latter thus becomes relatively less conspicuous.

In figures 34 and 35 the anthelix makes its appearance on the surface of the auricle for the first time, and as it does so a groove develops between it and the free edge of the auricle, representing the early scapha. A lobule can also be recognized as a rounded expansion from the tænia. The small tubercle on the posterior edge of the helix in figure 35 is due to a thickening of the skin and is to be regarded only as a peculiarity of this particular specimen. Figures 36 to 38 show a distinct increase in the size of the auricle. In these there is some differentiation of the scaphal groove and a corresponding prominence of the helix. The specimen shown in figure 39 is from a fetus larger than any of the preceding specimens. It falls in this place because the photographs are arranged in the order of fetal length; the auricle, however, shows a somewhat retarded degree of differentiation and in form resembles the specimen illustrated in figure 35. In size it corresponds fairly closely to its neighbors, and we may perhaps assume that if the fetus had gone on to term it would have had a simplified type of auricle and possibly a prominent tænia lobularis or an attached lobule. The method of illumination in making the photograph shown in figure 40 exaggerates the prominence of the antitragus. I am introducing it on this account, in order to illustrate the marked differences in appearance one can secure by a modification of the illumination. The auricle shown in figure 41 is from a fetus from the end of the twelfth week, and aside from a poorly defined concha it represents most of the elements of the mature auricle.

On looking back over the auricles illustrated on this plate, one can see that in all of them the mandibular derivatives—the crus and tragus—are relatively large and prominent as compared with the hyoid derivatives. In the further development of the auricle this proportion gradually decreases. It will be further noted that the crus helicis is always a distinctly separate structure from the helix proper; the line of demarcation between them persists in the adult.

The photographs shown on plate 5 represent the changes occurring in the auricle during the fourth month of intrauterine life. As compared with the photographs on plate 4, the principal change is a relative decrease in the size of the crus helicis and tragus. Corresponding to this, it is possible to recognize a conchal cavity which has heretofore been nothing more than a cleft. The concha in the first two photographs (figures 42 and 43) appears to me a little exaggerated, due, probably, to the shrinkage of the auricle. Judging from the preceding and succeeding photographs, the average auricle at this time would be somewhat plumper in appearance. Owing to the fact that these are thinner, one can see for the first time the presence of the plica principalis.

The specimen shown in figure 44 exhibits the average fulness in the region of the anthelix, with a tendency to be thrown into transverse ridges. These ridges occur in this region throughout the fourth and fifth months, depending, apparently, upon the amount of fulness in the subdermal connective tissue. The helix of this specimen is characterized by the presence of a moderately well developed tuberculum (Darwinii). In the next specimen (fig. 45) the helix shows a distinct crown angle (satyr-tip), which doubtless would have persisted in the adult. Although the concha is still not much more than a cleft, one can make out the presence of a plica principalis near its upper end. The condition shown in figure 46 is an interesting example of the flat type of auricle with a prominent tuberculum. The tendency toward obliteration of the helix appears to be due partly to the surplus tissue in the region of the anthelix, which is thrown into corresponding transverse folds. In figure 47 the transverse folds are absent and in their stead is a prominent plica principalis. The auricle shown in figure 48, although of the same size as its neighbors, is of a more rudimentary type and resembles the specimen in figure 39. It is probable that both of these would have resulted in small ears had the fetuses gone on to term.

Figure 49 shows a marked development of the transverse folds in the region of the anthelix, which were first described by Schwalbe and interpreted by him as temporary representatives of the longitudinal folds seen in some of the long-eared mammals. The fact that they are so irregular in occurrence, however, as can be seen by this and the next plate, makes it doubtful whether these folds can be safely interpreted as phylogenetic rudiments. I am inclined rather to attribute them to a redundancy of the soft tissues of the anthelix. This specimen illustrates very well the difference in character between the auricular derivatives of the mandibular bar (crus helicis and tragus) and the derivatives of the hyoid bar (scapha-helix, anthelix, antitragus, and lobule). In the last specimen on this plate (fig. 50), in contrast with figure 49, there are no distinct transverse folds, but the plica principalis is more prominent.

The photographs shown on plate 6 are taken from specimens in the fifth month of development, with the exception of the last, which has a menstrual age of 23 weeks. Figures 51 and 52 represent flattened types of auricles, such as that depicted in figure 46 (plate 5). One might think that this was due to flattening of the ear by handling of the specimen, but such is not the case; the specimens were in good condition and had not been subjected to any mechanical damage. In my opinion they can be interpreted only as early exhibitions of a poorly marked helix so commonly seen in the adult. Both of these specimens show a tendency toward a double tragus. In one the larger segment is above and in the other below. The specimen shown in figure 53 is similar to the type shown in figure 49 and is characterized by a marked development of the transverse ridges across the anthelix.

In figure 54 the auricle has a well-defined helix at its upper end, together with a tendency toward a satyr-tip. The lower half of the helix is less well marked. In this respect it represents a type seen in adults and known as the Cercopithecus type, as described by Schwalbe (1891). In this ear, as in all the succeeding ones, the plica principalis can be clearly recognized. Figure 55 shows a very perfect type of auricle, the one most usually seen, and for the first time we meet with a well-defined concha, its upper half subdivided by the plica principalis into a superior and an inferior articular fossa.

The specimen in figure 56 is interesting, in that it still shows the remnants of transverse folds over the anthelix. The fact that there is a tendency toward similar folds along the margin of the helix is strongly indicative of their being nothing more than a temporary expression of the condition of the soft tissues. The auricular cartilage never takes any part in their formation. The specimens shown in figures 57 and 58 both have a well-marked helix. In figure 58 the scapha is somewhat larger and there is a distinct tuberculum.

Figure 59, which closes the series, shows an auricle having all the essential characteristics of the mature ear. In comparing figure 59 with the first figure on this plate it will be seen that in the course of a month the auricle has about doubled in size. This was true also in the two preceding plates. The auricle in figure 59 is of a simple type, having a marked helix only along its upper border. There is now a distinct concha the definite parts of which can be clearly identified. The hair follicles are well developed over the whole of its surface. In comparing this with the auricles shown on plate 4, the marked difference in the relative sizes of the mandibular and hyoid derivatives is very evident.

SUMMARY.

In describing the development of the auricle, most investigators have traced its origin to the six branchial hillocks, which make their appearance at the fifth week as rounded nodules on the mandibular and hyoid bars adjacent to the first branchial cleft. These hillocks, since the early paper of His, have received much attention and have been variously designated, and descriptions have been given of how, by their unequal growth and subsequent coalescence, the eventual auricle comes into existence. The hillocks have been so interpreted in spite of the fact that it was known that they present much the same appearance in mammals that have, in the adult stage, very different types of ears from those of man, and that they are present even in birds and reptiles, which never acquire a distinct auricle.

From what has been stated in the foregoing pages one is forced to the conclusion that the hillocks, as such, are of a transitory character and are incidental, rather than fundamental, to the development of the auricle. Probably of more significance, as far as the derivatives of these parts are concerned, is the division of the mandibular and hyoid bars into ventral and dorsal segments, the closure mechanism being derived from the former, the articular mechanism and scapha helix from the latter.

The essential histological change which inaugurates the formation of the auricle (embryos between 4 and 14 mm.) consists of a proliferation and condensation of the mesenchyme. The mesenchymal change is accompanied by evidences of marked activity of the ectoderm over the whole auricular area. The deeper layer of ectoderm cells enlarge, proliferate, pile up two or three cells thick, and at the same time develop elongated, cylindrical bodies or processes which project toward the abutting mesenchyme, thus forming a narrow, clear cytoplasmic band at the mesenchymal junction. Directly beneath the ectoderm the mesenchymal cells are crowded into a compact line of proliferating elements from which great numbers of cells can be seen streaming into the deeper levels. The condensation of the mesenchyme is thus most intense at the ectoderm and gradually becomes less marked in the looser tissues of the central part of the bar. This phenomenon of ectodermal and mesodermal activity takes place over the whole surface of the hyoid bar, and in a less degree over the posterior half of the mandibular bar, in which the condensed mesenchyme soon becomes localized in the deeper layers. It is more prominent in those parts where the auricular cartilage arises, and almost from the first gives the outlines of the cartilage in its primitive form, so that we may speak of it as the primordium of the auricle. The relation of the branchial hillocks to the auricular primordium appears to be that they are merely foci in which the mesenchymal proliferation is temporarily most rapid; they do not represent the entire auricular primordium. This is particularly evident in hillocks 4 and 5. In the hillocks of the mandibular bar (1, 2, 3) the mesenchyme is not so compact, although there also it is in active proliferation.

The proliferation and condensation of the branchial mesenchyme constituting the primordium of the auricle and the rearrangement of the mesenchyme where the condensation is less marked produce a change in the surface form of the gill-bars. The narrow hyoid cleft thereby becomes converted into a broad fossa angularis. The width of the fossa is increased by a relative sinking in of those portions of the bars adjacent to the cleft. This depression is not so much an actual sinking in as an elevation of the surrounding parts, especially of the auricular rim, made up of those condensed parts of the hyoid and mandibular bars that constitute the auricular primordium. The widening of the angular fossa can be partly accounted for by the spreading apart of the auricular rim through the growth of the tissues composing its floor (closure plate), in which can be seen forming the head of Meckel's cartilage.

In embryos up to 16 or 18 mm. the condensed mesenchyme forming the primordium of the auricle is fairly uniform in appearance, but at about this time one can begin to see clearly the auricular cartilage separating itself from the less dense tissue as a lamina of precartilage cells. As soon as it can be recognized, this lamina is found to be folded in a manner essentially like that of the adult cartilage. The scapha-helix stands out prominently, the free edge of the helix remaining in contact with the ectoderm. The anthelix is also indicated almost from the first, whereas the concha is less sharply defined, and it is not until the embryo has reached a length of 40 to 50 mm. that the cartilage may be considered to have acquired its definitive adult form. In this respect, however, it is much in advance of the surface form of the auricle. It is quite evident that the folding of the cartilage is not produced mechanically by resistance to its expansion on the part of the ectoderm, as has been maintained; the surrounding tissues are loose enough to make folding unnecessary. Furthermore, the folding is relatively as great at first, when the cartilage is small, as it is in the later stages. The auricular cartilage clearly acquires its form with all the precision and individuality shown by the other cartilaginous parts of the body.

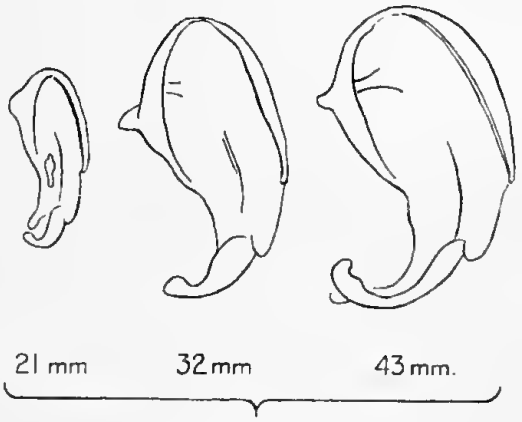

FIG. 6.

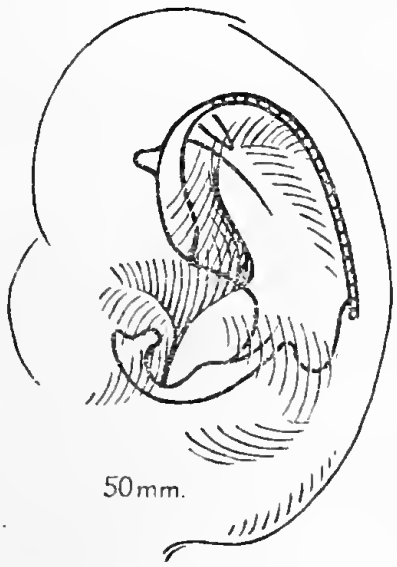

FIG. 7.

FIG. 6.—Lateral views of left auricular cartilage, taken from reconstructions of human embryos of the Carnegie Collection: No. 460 (21 mm.), No. 417 (32 mm.), No. 886 (43 mm.). ×14.

FIG. 7.—Reconstruction of left auricular cartilage of a 50 mm. fetus (No. 84, Carnegie Collection). ×14. A model of the external form of the auricle was made, in conjunction with the cartilage, to give the topographical relations. The edge of the helix in contact with the ectoderm is indicated by cross-lines. Compare with figures 35 and 38.

The transition from the arrangement of typical branchial bars to an auricle of primitive type takes place during the period represented by embryos from 4 to 16 mm. By that time the nodular elevations caused by the hillocks are for the most part smoothed out, and we find the angular fossa inclosed by a rounded border which consists of parts corresponding to the elements of the auricle. The most conspicuous of these are the scapha-helix, tragus, and antitragus. The angular fossa has the form of an elongated depression. Its anterior margin is entirely of mandibular origin and its posterior margin of hyoid origin. The greater part of this posterior margin is taken up with the scapha-helix, or the so-called free ear-fold, at the lower end of which is the modified remnant of hillock 6, which persists as the antitragus. Hillock 1 has become directly converted into the tragus, whereas the crus is slower in making its appearance; not until the embryo has reached a length of 18 or 20 mm. does this structure become evident. It arises from the mandibular tissue in the region formerly occupied by hillocks 2 and 3 and forms an oblique ridge which, enlarging, encroaches upon the angular fossa and converts it into a narrow cleft.

The transformation from the more primitive type of auricle, as just described, into the adult ear may be easily followed in figure 8. This figure is intended as a diagrammatic analysis of the changes illustrated by the photographs on plates 4, 5, and 6. The parts of the auricle derived from the mandibular bar are shown in a lighter tone, while the parts derived from the hyoid bar are stippled. It is interesting to note that the mandibular derivatives are relatively very large in the earlier stages, and this is also true of the derivatives of the lower end of the hyoid bar; in other words, those parts of the auricle concerned with the closure mechanism and the attachment of the auricle to the head are more precocious than the scapha-helix and anthelix. The latter two structures merge directly into each other. Their approximate point of junction, however, is indicated by a dotted line.

Fig. 8.—Drawings showing the development of the auricle and its primitive form to the adult type. Those parts derived from the mandibular bar are indicated in lighter tone and are relatively larger in the younger stages; the parts derived from the hyoid bar are stippled; the broken line represents the approximate junction of the anthelix and scapha-helix.

In the younger stages—for example, 85 mm.—the soft tissues of the auricle give the appearance of fulness and tend to be thrown into folds. These should not be confused with the longitudinal folds seen in the adult scapha of some of the long-eared animals. As the cartilage expands, the subcutaneous tissue becomes relatively more scant, particularly in the region of the anthelix and scapha-helix. The histological appearance of the crus helicis is quite different from the hyoid auricle (anthelix and scapha-helix). This difference consists chiefly in the presence of a great number of hair follicles and a considerable amount of subcutaneous fat. These are almost absent in the scapha-helix. The form of the concha, particularly of its articular portion (superior and inferior fossæ and plica principalis), does not make itself conspicuous until after the fetus has reached a crown-rump length of 135 mm., although the complete outline of these parts can be recognized in the cartilage in embryos of less than 50 mm.

If one studies a great many specimens, covering the period from 30 mm. to full term, it will be found that there is great variation, just as exists in the adult ear, and that the individuality of the ear is expressed early, as soon as the respective parts can be identified. The tragus may consist of a single lobe or may tend to be subdivided into two lobes; the form of the antitragus varies considerably, and still more does the lobule. The part that varies most, however, is the scapha-helix, particularly as regards its extent and the character of folding of the helix. The least variable is the articular portion, including the crus helicis, the two articular fossæ, and the plica principalis.

BIBLIOGRAPHY.

Baum and Dobers, 1905. Die Entwicklung des äusseren Ohres bei Schwein und Schaf. Anat. Hefte, vol. 28, p. 587–688.

Boas, J. E. V., 1912. Ohrknorpel und äusseres Ohr der Säugetiere. Kopenhagen.

Gradenigo, G., 1888. Die Formentwickelung der Ohrmuschel, mit Rücksicht auf die Morphologie und Teratologie derselben. Centralbl. f. d. med. Wiss., vol. 26, p. 82–86 and 113–117.

Hammar, J. A., 1902. Studien über die Entwicklung des Vorderdarms und einiger angrenzenden Organe. I. Abtheilung: Allgemeine Morphologie der Schlundspalten beim Menschen. Entwicklung des Mittelohrraumes und des äusseren Gehörganges. Arch. f. mikr. Anat., vol. 59, p. 471–628.

Henneberg, B., 1908. Beiträge zur Entwicklung der Ohrmuschel. Anat. Hefte, vol. 36, p. 107–187.

——— 1910. Ueber die Bedeutung der Ohrmuschel. Anat. Hefte, vol. 40, p. 95–147.

His, W., 1882. Auf Stellung von Entwickelungsnormen, zweiter Monat. Anatomie menschlicher Embryonen, Part II, p. 55 and 60–62.

——— 1885. Die Formentwickelung des äusseren Ohres. Anatomie menschlicher Embryonen, Part III, p. 211–221.

——— 1889. Zur Anatomie des Ohrläppchens. Arch. f. Anat. u. Physiol., Anat. Abth., p. 301–307.

Kastschenko, N., 1887. Das Schicksal der embryonalen Schlundspalten bei Saugethieren. Arch. f. mikr. Anat., vol. 30, p. 1–26.

Keith, A., 1906. The results of an anthropological investigation of the external ear. Proc. Anat. and Anthrol. Soc. Univ. Aberdeen, 1904–1906, p. 217–239.

Mall, F. P., 1914. On stages in the development of human embryos from 2 to 25 mm. long. Anat. Anz., vol. 46.

Moldenhauer, W., 1877. Die Entwicklung des mittleren und des äusseren Ohres. Morph. Jahrb., vol. 3, p. 106–151.

Münch, F. E., 1897. Ueber die Entwicklung des Knorpels des äusseren Ohres. Morph. Arbeiten, vol. 7, p. 583–610.

Ruge, G., 1898. Das Knorpelskelett des äusseren Ohres der Monotremen. Morph. Jahrb., vol. 25, p. 202–223.

Schaeffer, O., 1892–93. Ueber fötale Ohrentwicklung, die Haufigkeit fötalen Ohrformen bei Erwachsenen und die Erblichkeitsverhältnisse derselben. Arch. f. Anthropol., vol. 21, p. 77–132; also p. 215–245.

Schmidt, Joh., 1902. Vergleichend-anatomische Untersuchungen über die Ohrmuschel verschiedener Säugetiere. Berlin.

Schwalbe, G., 1889. Das Darwin'sche Spitzohr beim menschlichen Embryo. Anat. Anz., vol. 4, p. 176–189.

——— 1891*a*. Beiträge zur Anthropologie des Ohres. Internat. Beitr. z. wiss. Medicin. Virchow Festschr., vol. 1, p. 95–144.

——— 1891*b*. Ueber Auricularhöcker bei Reptilien; ein Beitrag zur Phylogenie des äusseren Ohres. Anat. Anz., vol. 6, p. 43–53.

——— 1897. Das äussere Ohr. Handb. d. Anat. d. Menschen, Herausg. K. von Bardeleben, vol. 5, part 2, pp. 125–131.

——— 1916. Beiträge zur Kenntnis des äusseren Ohres der Primaten. Ztschr. f. Morphol. u. Anthropol., vol. 19, p. 545–668.

Sera, G. L., 1917. È la forma dell' orecchio umano antica o recente? Giornale per la morfologia dell' Uomo e dei Primati, vol. 1, p. 109–125.

Spaulding, M. H., 1921. Development of the external genitalia in the human embryo. Contributions to Embryology, vol. 13, p. 69–88. Carnegie Inst. Wash. Pub. 276.

Tataroff, D., 1887. Ueber die Muskeln der Ohrmuschel und einige Besonderheiten des Ohrknorpels. Arch. f. Anat. u. Physiol., Anat. Abth.

DESCRIPTION OF PLATES.

Plate 1.

Ventrolateral view of the head in a series of human embryos, showing the change in topography of the auricle in the course of its development. The surface area of the mandibular and hyoid bars entering into the formation of the auricular primordium is colored blue. These figures show the lateral and dorsal migration of the auricle coincident with the formation of the mandible.

Fig. 9. Drawing made directly from an embryo 6 mm. long, No. 1787 Carnegie Collection. × 22. The olfactory disk and the lens of the eye are outlined by dots.

Fig. 10. Reconstruction model of an embryo 12 mm. long, No. 1121 Carnegie Collection. × 15.

Fig. 11. Reconstruction model of an embryo 14 mm. long, No. 940 Carnegie Collection. × 15. Here the parts belonging to the jaw are clearly separated from what are to be the soft parts of the upper neck by a groove, which might be called the mental groove.

Fig. 12. Reconstruction model of an embryo 18 mm. long, No. 1390 Carnegie Collection. × 12.3.

Plate 2.

Drawings of human embryos, showing the region of the first branchial cleft and its transformation into a fossa angularis. Coincident with this transformation the mesenchyme of the hyoid and mandibular bars undergoes proliferation and becomes condensed to form the primordium of the auricle. Foci of more active proliferation show on the surface as branchial hillocks. Specimens are from the Carnegie Collection.

Fig. 13. No. 1380, 5 mm. long. × 34.
Fig. 14. No. 1767, 11 mm. long. × 24.
Fig. 15. No. 1461, 10 mm. long. × 20.
Fig. 16. No. 562, 13 mm. long. × 20.
Fig. 17. No. 1232, 14 mm. long. × 17.
Fig. 18. No. 475, 15 mm. long. × 17.

Plate 3.

Drawings of human embryos, in series with the preceding plate, and showing the disappearance of the branchial hillocks and the completion of the auricle in its primary form. Specimens are from the Carnegie Collection.

Fig. 19. No. 899, 13 mm. long. × 24.
Fig. 20. No. 434, 15 mm. long. × 27.
Fig. 21. No. 492, 16.8 mm. long. × 27.
Fig. 22. No. 576, 17 mm. long. × 17.
Fig. 23. No. 547, 18 mm. long. × 22.
Fig. 24. No. 955, 17 mm. long. × 24.
Fig. 25. No. 1584, 18 mm. long. × 24.
Fig. 26. No. 1134*e*, 21.3 mm. long. × 24.
Fig. 27. No. 1358*b*, 33.2 mm. long. × 24.

Plate 4.

Photographs of the auricle of the human fetus during the third month, all being taken at an enlargement of 10 diameters. In some cases the right ear was selected and reversed for convenience in comparison. These are indicated by the letter R. All specimens are from the Carnegie Collection, and length given is crown-rump.

Fig. 28. No. 1535, 28 mm.
Fig. 29. No. 2163, 36 mm.
Fig. 30. No. 1980, 37 mm.
Fig. 31. No. 1840*a*, 38.5 mm. (R.)
Fig. 32. No. 2075, 40 mm. (R.)
Fig. 33. No. 2144, 45.5 mm. (R.)
Fig. 34. No. 642, 49 mm.
Fig. 35. No. 2170, 50 mm.
Fig. 36. No. 2095, 52 mm. (R.)
Fig. 37. No. 2095, 52 mm.
Fig. 38. No. 2066, 53 mm. (R.)
Fig. 39. No. 2079, 56.5 mm.
Fig. 40. No. 1561, 57 mm.
Fig. 41. No. 218, 62.5 mm. (R.)

Plate 5.

Photographs showing changes occurring in the auricle of the human fetus during the fourth month. In some cases the right ear was selected and reversed for convenience in comparison. These are indicated by the letter R. All the photographs are taken at an enlargement of 6 diameters. Specimens are from the Carnegie Collection, and length given is crown-rump.

Fig. 42. No. 1724, 66.2 mm.
Fig. 43. No. 2328, 65 mm. (R.)
Fig. 44. No. 2118, 69 mm.
Fig. 45. No. 981, 85 mm.
Fig. 46. No. 1845, 87 mm.
Fig. 47. No. 1449, 87.3 mm.
Fig. 48. No. 2003, 103.5 mm.
Fig. 49. No. 1858, 100 mm. (R.)
Fig. 50. No. 2274, 113 mm. (R.)

Plate 6.

Photographs showing the form of the human auricle during the fifth month of intrauterine life, with the exception of specimen shown in figure 59, which has a menstrual age of 23 weeks. The photographs are all shown at an enlargement of 4 diameters. Specimens are from the Carnegie Collection, and length given is crown-rump.

Fig. 51. No. 2185, 113.5 mm.
Fig. 52. No. 952*b*, 114 mm.
Fig. 53. No. 1811, 114 mm.
Fig. 54. No. 1716, 119 mm.
Fig. 55. No. 1957*b*, 119 mm.
Fig. 56. No. 1782, 135.6 mm.
Fig. 57. No. 1702, 150 mm.
Fig. 58. No. 1708, 154 mm.
Fig. 59. No. 1742, 191.2 mm.

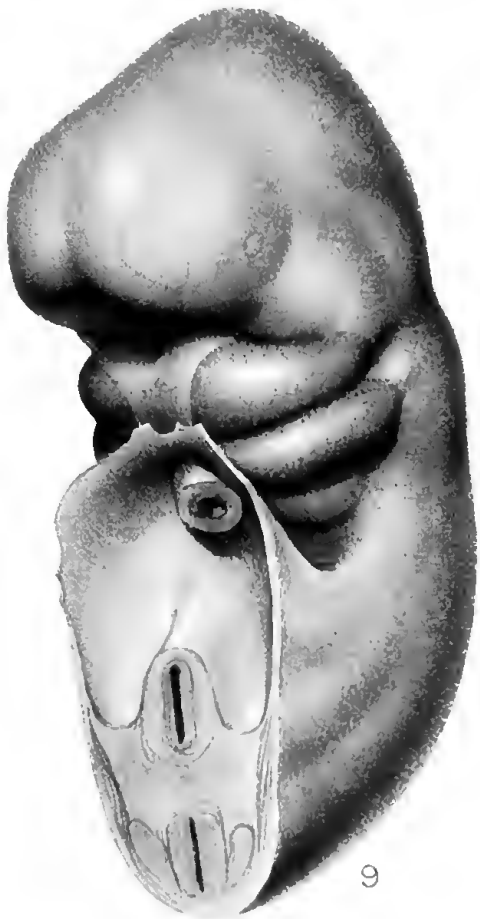

9

10

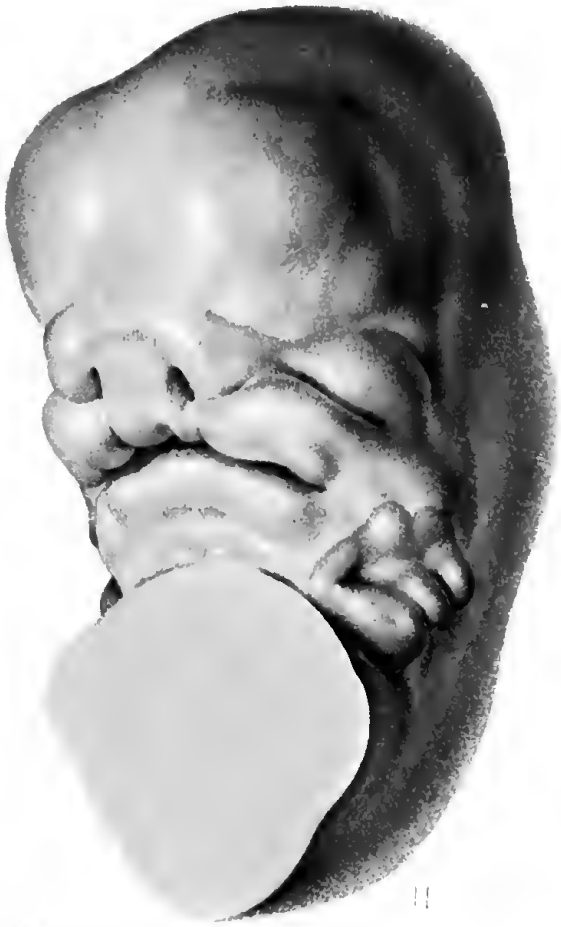

11

12

J. F. Didusch fecit

A. Hoen & Co.


13


14


15


16


17


18

J. F. Didusch fecit


19

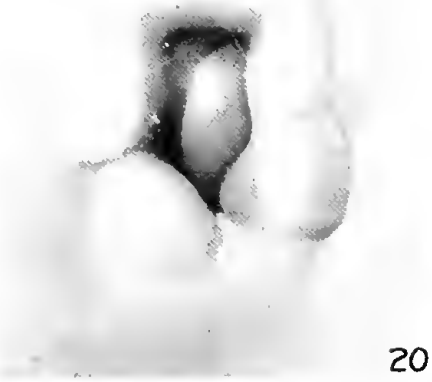
20


21


22

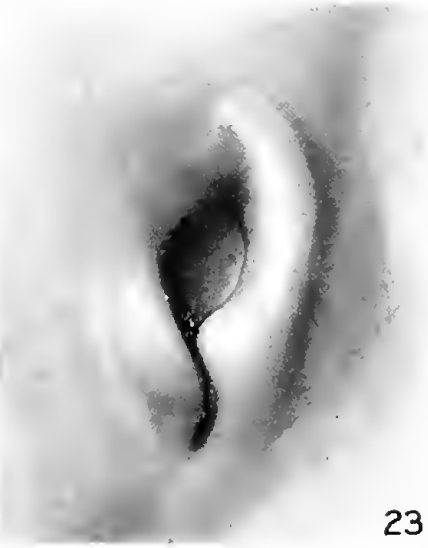
23


24


25

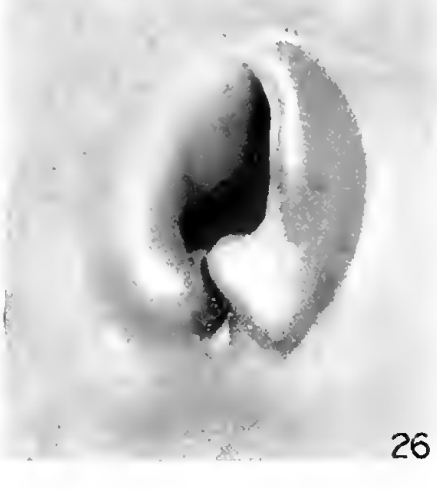
26


27

J. F. Didusch fecit


28


29


30


31


32


33


34


35


36


37


38


39


40


41


42


43


44


45


46


47


48


49


50


51


52


53


54


55


56


57


58


59

CONTRIBUTIONS TO EMBRYOLOGY, No. 70.

THE DEVELOPMENT OF THE PRINCIPAL ARTERIAL STEMS IN THE FORELIMB OF THE PIG.

By H. H. Woollard,

Department of Anatomy, University College, London.

With two plates.

THE DEVELOPMENT OF THE PRINCIPAL ARTERIAL STEMS IN THE FORELIMB OF THE PIG.[1]

INTRODUCTION.

The study of the development of blood-vessels has issued in attempts to formulate the underlying principles that govern such development. Curious to record, the principles so formulated have traveled in a circle; the recent ideas expressed by Evans (1911) are in rough agreement with those expressed by Baader in 1866. The history may be briefly told.

Baader believed that arterial anomalies were not mere accidents and that the explanation of their occurrence was to be found in the net-formation which precedes the establishment of arteries and veins. Vascular anomalies occur when some part of the net, which normally does not do so, happens to be transformed into a more adult arrangement. Baader arrived at the idea of a capillary net preceding all vessels from the diversity in the anatomical relationships presented by arterial variations. The same hypothesis was upheld by Aeby (1871) and Krause (1876) and it is often referred to as the Baader-Krause law. The weak point in the doctrine was the absence of direct evidence and when later embryological investigation seemed to point in another direction it failed any longer to command support.

As soon as it was realized that embryology did not substantiate the idea of a vascular net out of which vascular stems develop in a more or less fortuitous manner, but revealed the presence of only a single main axial trunk, the comparative anatomists imposed a new interpretation on the vascular pattern, in which phylogenetic and ontogenetic factors were the determining agencies. This took two forms. Macalister (1886) and Mackay (1889) interpreted this main axial trunk as the fusion of an original polysegmental supply to the limb. This idea also foundered because it was unsupported by any direct evidence. Ruge and others, on the other hand, regarded each arterial stem as a unit and brought direct evidence to show that the axial supply to the limb was such a unit. Ruge (1883), as the result of his study of a 25-mm. human embryo, opposed the idea that blood-vessels arise from a primordial vascular net. "It can be proved," he says, "that the blood-vessels of the upper extremity, as well as for all parts of the body, show themselves differentiated into definite paths in the same manner as the paired aortæ. That at no time does a chaotic mix-up govern the vascular system." In this interpretation Ruge was followed by Hochstetter (1890*a*) and others, and so was elaborated the doctrine of arteries that regarded each stem as of unit value to be interpreted in terms of phylogeny. Zuckerkandl (1894, 1895) showed that the volar interosseous artery of the forearm is phylogenetically the oldest artery. In *Ornithorynchus* it forms the direct continuation of the brachial. In marsupials, edentates, carnivores, and ungulates the arteria mediana appears as the largest vessel,

---

[1] The author was enabled to carry out this work in America through a fellowship generously granted by the Rockefeller Foundation.

with a rudimentary interosseous, a feeble ulnar, and a varying larger radial. First in the primates appear the radial and ulnar as large and constant arteries.

This dominant view received its first serious challenge at the hands of Müller (1903, 1904); its death blow was dealt by H. M. Evans. In the concluding paragraph of his work on the morphology of the vascular system, Müller states that through his investigations on the comparative anatomy of the forelimb arteries he finds that arterial tubes are derived from definite vascular nets; that the particular arterial arrangement in the various mammals does not permit them to be arranged in any series from lower to higher forms; that it can not be established that the ancestral form of the arm artery is an axial stem out of which the other stems arise as branches of secondary or tertiary value. His findings show that a general complicated network, such as he has described in the human embryo, forms the primordium out of which particular branches arise. Mechanical influences, working during ontogeny, are the determining factors of the various forms which the arteries in the mammals assume.

The present position is that Evans (1909) has reduced almost all vessels to a primordial vascular net, extending it to the caudal aorta, the umbilical veins, etc. Dr. Florence R. Sabin (1921) has participated in this, revealing how, in the chick and pig, the angioblasts arrange themselves in diffuse or longitudinal form.

Elze (1913) has opposed the view of Evans, his attack on the latter following two lines. In escaping from the theory of predestination, Evans has based his conclusions on the laws deduced by Thoma to explain the morphogenesis of blood-vessels. Elze attempts to refute these laws by deducing from them the course and form which the developing vessels should pursue and assume in deference to these laws. It would not serve any useful purpose to analyze here examples which he quotes to demonstrate the inapplicability of Thoma's postulates. Experimental evidence would be necessary in order to determine the validity of these speculative applications. The second line taken by Elze is to deny the universality of the "net" theory. The specific exceptions he mentions, such as the aorta, cardinal veins, and segmental arteries, have been the objects of particular study, and Evans's paper on the aorta, cardinal and umbilical veins, and other blood-vessels indicates that the strength of Elze's objections is not very great. Elze is not convinced of the existence of the plexus arteriosus subclavius. It seems difficult to understand how this objection can be maintained in the face of the investigations of Rabl (1906) and Evans (1909) on the forearm of the bird, and those of Göppert (1910) on the white mouse. Although I have not found the variability in the pig that Göppert observed in the earliest blood supply to the forearm of the mouse, the present investigation has clearly shown the polysegmental supply of the limb-bud and the plexiform arrangement of the early arm branches. The situation may therefore be summed up by saying that the primordium of the vascular system lies in the vascular net; that the vascular net depends upon the inherent properties of certain cells to form blood-vessels and blood-cells, these properties being regulated by the needs and activities of the surrounding tissues; that the circulation and vascular pattern at any one time are adequate for the needs of the tissue and carry no implication of the future pattern, as has been stressed by Streeter (1918); that out of this vascular net there will be determined particular paths, in accordance with the postulates of Thoma (1893); and lastly, that such a dynamic view of the vascular development is not in conflict with any phylogenetic view of the order of blood-vessels, since the dynamic, equally with the static, is a heritage of the past.

For the opportunity of making this investigation I am indebted to Dr. L. H. Weed and Dr. G. L. Streeter, who have so generously placed their experience and the hospitality of their departments at my disposal. To Dr. C. H. Heuser, who taught me the technique involved, and to Dr. F. R. Sabin, who allowed me to study her collection of excellent material, my best thanks are due.

METHOD AND MATERIAL.

The vascular arrangement was made obvious by the introduction of india ink and by clearing according to the method of Spalteholz. This method has advantages over that of serial sections and modeling, which reveals only blood-vessels that happen to be stuffed with red corpuscles. The collapsed vessels are apt to be ignored, while those that happen to be full are given exaggerated value and elevated to the rank of a special designation. Apart from these objections, which will vary in their justness according to the state of the material investigated, it can be urged that the injection method is necessary to study the capillary stage of blood-vessels, which the other method has almost invariably failed to establish. If the ink is introduced gently into the umbilical artery while the heart is yet beating, its presence will excite the heart to vigorous contractions and produce an altogether beautiful picture of the vascularity. Since the ink is distributed by the cardiac contractions, it naturally follows the distribution of the blood and thus gives in these tiny embryos a faithful portrait of the relative dimensions of the blood-vessels. Such has been the method adopted and it has been successful in embryos as small as 4 or 5 mm.

The embryos were obtained from an adjacent abattoir immediately after evisceration of the carcasses. They were removed from the uterus and placed in warm salt solution and immediately injected. The smaller ones were fixed in Bouin's fluid, the larger in formalin, dehydrated, and cleared in oil of wintergreen. A very great number of embryos of each of the stages about to be described were studied.

ANATOMY OF THE BLOOD-VESSELS OF THE FORELIMB.

The aorta, which is strongly curved, gives off the brachiocephalic trunk, which in turn subdivides into a right subclavian, two common carotids, and a left subclavian, which arises from the aortic arch just above the common carotid. Each subclavian gives off a dorsal, a vertebral, and a deep cervical branch, which arise close together or from a common trunk. From the same common trunk, or from the dorsal artery, arise the intercostal artery to the second intercostal space and the subcostal artery, which supplies the third, fourth, and fifth intercostal spaces. The dorsal artery emerges through the dorsal extremity of the second interspace and divides into dorsal and cervical branches. The dorsal branch runs deep to the muscles of the back which it supplies; the cervical branch passes anteriorly to the atlantal region and anastomoses with the occipital. The vertebral artery begins opposite the first intercostal space, from the brachiocephalic trunk on the right, from the subclavian on the left. It passes upwards and forwards, on the left crossing the esophagus, on the right the trachea. The deep cervical branch, smaller than the dorsal, emerges through the first intercostal space, gives off the intercostal artery, and then ramifies in the muscles of the neck. The inferior cervical artery is large and gives off branches to the thyroid and to the parotid. The internal mammary is large.

The subclavian is continued over the first rib into the forelimb. The brachial gives off the subscapular, the anterior and posterior circumflex and branches to the deltoid, corresponding to the thoracic axis in the human anatomy. In the arm the brachial gives off a large branch which follows the radial nerve (a superior profunda) and in the neighborhood of the elbow a branch following the ulnar nerve (inferior profunda).

The brachial is continued into the forearm, as the arteria mediana, in relation with the median nerve between the superficial and deep tendons. It breaks up into branches for the four digits, which branches communicate with the dorsal digital branches. Halfway along the forearm the arteria mediana gives off a slender radial artery which continues to the radial side of the radial digit. It forms, with the median artery, a representation of a superficial palmar arch. It also gives off a dorsal branch which communicates with the dorsal interosseous artery and contributes to the dorsal digital supply. From the arteria mediana arises an ulnar artery, which is small and which soon breaks up into a capillary network. This capillary network communicates with the arteria mediana and with the volar interosseous artery and thus is represented a deep palmar arch. The volar interosseous from the median artery lies between the radius and ulna and communicates with a recurrent branch of the median artery and with the ulnar. Its main continuation is by way of a dorsal branch which reaches the dorsum of the hand between the two bones of the forearm. The dorsal interosseous arises from the arteria mediana by way of the common interosseous and soon becomes reduced. It communicates with the dorsal continuation of the volar interosseous.

DESCRIPTION OF REPRESENTATIVE SPECIMENS.

Embryo 4.5 mm. (Plate 1, fig. 1).

In this embryo the forelimb-bud shows as a blunt elevation, appearing opposite the fifth, sixth, seventh, eighth, and ninth segmental arteries. The hindlimb is not apparent. From each of these dorsal segmental arteries a lateral branch arises. At its origin the lateral branch is plexiform and its connection with the dorsal segmental is multiple. These lateral branches traverse the body-wall dorsal to the cardinal vein and reach the limb-bud. In the forelimb they become converted into a capillary network which occupies the whole of the bud except a clear marginal area. The vascular drainage of the bud takes place by many veins which open at irregular intervals into the cardinal vein. At the cranial and caudal extremities the venous tributaries extend into the body of the embryo beyond the actual area giving origin to the limb-bud.

Macalister (1886), on theoretical grounds, suggested that, as the limbs arise by the consolidation of the ventrolateral appendages derived from several segments, each limb primarily receives vessels from several metameric trunks. Subsequent workers, however, succeeded only in reducing the blood supply to the limb to a single axial trunk. Müller, from his comparative studies, became convinced that the original blood supply to the limb was in the form of a capillary net and that this net was based on polysegmental contributions. Evans and Rabl showed that in bird embryos such a polysegmental arrangement was the case. In 1910 Göppert showed the same for the mouse. Evans, in his studies on the forelimb of the duck, figured a still earlier stage in which the arteries to the limb were not dominated by a metameric arrangement. Also, Göppert showed in the mouse an arrangement of blood-vessels to the limb which, in the earliest stages, bore varying relations to the cardinal veins and were not altogether in metameric order.

The embryos of the stage here described (fig. 1) show none of the variability so much stressed by Göppert and in all of the cases studied the vessels are segmentally arranged, appearing as lateral branches of the dorsal segmentals. This polysegmental arrangement has now been proved to hold for all the vertebrates except amphibia. Of the mammals, the mouse and the pig can now be included in the list and there can be no reasonable doubt that the same obtains for man. The presence of double subclaviæ in the human embryo has been described several times.

Embryo 7.5 mm. (Plate 1, fig. 2).

This specimen shows the dominance of the lateral branch of the seventh segmental artery so enlarged that it constitutes the main axial trunk of the forelimb bud. As it passes into the bud it becomes coarsely plexiform and assumes a retiform character. The components of the rete diverge in a cranial and caudal direction and in turn become broken up into dorsal and ventral capillary networks.

The contributions from the other segmentals are disappearing. The remnants of those from the fifth and sixth can still be observed, together with a slight anastomosis between these branches. Also a slender contribution from the eighth can be picked out, but the contribution from the ninth seems to have entirely disappeared.

Venous communications exist on the dorsal aspect, draining into the veins accompanying the dorsal segmental arteries. Along the ventral surface venous communications are established with the lateral body-wall. At the cranial end of the limb-bud venous communications are established with the cardinal. A similar process takes place at the caudal end. The periphery of the limb is occupied by a capillary network which will subsequently be changed into a continuous venous marginal channel.

Embryo 8.5 mm. (Plate 1, fig. 3).

This stage shows the more definite arrangement foreshadowed in the previous embryo. The limb-bud is occupied by a dense capillary network fed by a single axial trunk derived from the seventh segmental artery. The axial trunk, when followed into the limb-bud, assumes first a retiform arrangement, ending finally in a capillary net which diverges dorsally and ventrally. Comparing this with the previous stages, we can follow the gradual changes towards the formation of a definite axial vessel. First of all, there is a diffuse capillary net, a sort of equi-potential system in which each unit has the same dimensional value. This is succeeded by a coarsely plexiform arrangement—a retiform stage—in which the elements are larger but still branching and diffusely anastomosing. By coalescence, out of this stage a definite stem will form. These successive stages provide abundant opportunity for variation and the production of anomalies. These embryos also provide evidence for the theory of vascular formation, long ago set forth by Baader (1866).

The marginal vein is almost complete, but along the tip of the bud it still retains its capillary arrangement. The formation of definite veins is much more advanced along the caudal (ulnar) margin than at the cranial (radial) end. The caudal end shows a great venous plexus which receives the ulnar vein (vena basilica) and, in addition, veins that drain the dorsal surface of the limb-bud. The vena cephalica is much more indefinite than the vena basilica.

Embryo 12 mm. (Plate 2, fig. 4).

An embryo of this size discloses changes which can be made out to some extent in one of 10 mm. This refers particularly to the branches of the subclavian in the thoracic and cervical regions.

The limb-bud as a whole is occupied by a central axial stem bounded by a marginal vein and capillaries uniting the axial trunk to the margin. The axial trunk is well defined as far as the body-wall. Thereafter it becomes retiform and continues in this condition until it divides into a dorsal and a ventral system of capillaries. The proximal portion represents the brachial artery, the distal portion the volar interosseous. In the carpal region there passes dorsally a retiform mass of vessels which represents the ramus carpi dorsalis. Everywhere the retiform arrangement becomes reduced to capillaries which eventually reach the marginal venous system.

The subclavian has so increased in size that the dorsal segmental artery at its origin has been rendered inconspicuous. The vertebral can be picked up as slender capillaries joining the fifth and sixth and the sixth and seventh segmentals. A little more distal a mass of capillaries have coalesced and become defined as the posterior cervical of the swine. This represents the thyroid axis of human anatomy. On the caudal side of the subclavian the next three segmental arteries have been joined together by a capillary anastomosis. This represents the dorsal artery of the pig and corresponds to the superior intercostal and profunda cervicis of human anatomy. As this artery becomes more defined and larger, it will appear to supply the first three intercostal spaces and its dorsal branches will become distributed to muscles of the back and neck. The first three intercostal, when traced laterally, are found to be united by a capillary anastomosis and this anastomosis establishes the internal mammary artery. The marginal venous channel is complete; along the cranial or radial aspect it forms the vena cephalica, while along the caudal (ulnar) margin it forms the vena basilica. The latter is much the larger vein and reaches the cardinal vein. Before its termination it bends cranially and lies ventral and a little caudal to the subclavian artery, thereby becoming the subclavian vein. Veins which accompany the internal mammary open into it (the thoraco-epigastric vein). Slender veins from the limb-bud also reach it—that is, veins which are about now beginning to accompany the central artery of the limb.

Embryo 19 mm. (Plate 2, fig. 5).

Before describing this stage, brief reference may be made to stages intermediate between this and the earlier stages that have been studied but not figured. A series of transverse sections of a 13-mm. embryo were examined. These show the termination of the axial artery in a dorsal and ventral capillary plexus, which ramify between the differentiating musculature. A 15-mm. injected embryo was studied, but this shows no great advance over the stage last figured. Transverse serial sections show the relation of the main axial trunk of the limb-bud to the postcardinal vein and to the elements of the brachial plexus. The main axial trunk takes up a position between the dorsal and ventral elements of the plexus. The points of origin of the postcervical and the dorsal artery are indicated, as also the subscapular, and the plexiform termination of the axial trunk is seen to advantage. An embryo of 16 mm. may also be alluded to. The cervical and thoracic branches of the subclavian are more defined but have not yet emerged from a retiform condition. Axillary and brachial branches of the axial artery are beginning to coalesce and enlarge and the subscapularis and circumflex can be identified as plexiform groups. The radial and ulnar are still undifferentiated from the capillary plexus. The volar interosseous, which earlier was an indefinite plexiform aggregation, has now become a definite vessel which continues to the extremity of the bud. The ramus carpi dorsalis is defined and ends in four dorsal arteries, while the ventral portion of the volar interosseous, which is more slender, ends by joining with the digital branches of the median artery, which can now be identified. It arises from the brachial, approaches the ventral surface of the limb abruptly, and, from being plexiform at its origin, soon becomes a mass of capillaries which extend over the volar surface to the margin of the limb. Included in this capillary network are the radial and ulnar.

Figure 5 shows an injected specimen of about 19 mm. length. The arterial side of the circulation has now achieved, except in the extremity of the limb, a definite tubular arrangement. The veins, on the other hand, retain much more of the primitive anastomosing arrangement. It was found that by reducing the transparency of the cleared specimen, the form of the skeleton of the forelimb could be rendered visible. This has enabled the humerus, radius, and ulna to be represented. The wrist and hand bones could also be identified, but have not been included in the picture. The scapula also has been omitted. A knowledge of the position of the skeletal parts renders identification of the vessels more certain and easy. The vertebral, the dorsal (this artery is the equivalent of the superior intercostal and profunda cervicis of human anatomy), the thoraco-acromial, and internal mammary need no comment except to say that they are complete stems, all trace of the anastomosing network whence they have come having disappeared. The brachial has a characteristic concavity directed caudally before it passes in front of the lower extremity of the humerus. This bend is present in all observed specimens between 16 and 20 mm. The descending branch of the brachial has been identified as the subscapular artery. From this artery two branches pass on the dorsal side of the humerus; the upper one is the posterior circumflex, the lower is the profunda accompanying the radial nerve. These arteries are still very plexiform and the profunda plexus links up with the plexiform radial artery. Around the elbow are many plexiform branches of the brachial, making a rich and abundant cubital anastomosis. Many tiny plexiform branches arise from the brachial in this part of its course. At the lower extremity of the humerus the brachial undergoes subdivision. Its largest branch is the median artery, which ends in four digital capillary meshes which embrace the skeleton of the hand in a fine tracery of capillaries. Between the digits communications with dorsal vessels are apparent. Just before these digital capillary meshes are formed, the median artery itself expands into a wide plexiform mass. Just beyond the elbow the radial artery arises. It retains much of the primitive condition of all vessels. It passes toward the radial side of the limb and becomes more diffuse. Communications with the profunda artery are apparent. Towards its termination two strands can be identified. One strand becomes a capillary mesh for the radial digit, the other communicates with the digital mesh of the median, thus suggesting a superficial palmar arch. Eventually, its terminal capillaries, like the other digital capillaries, join with the marginal vein.

The ulnar is a feeble plexiform artery and in the adult pig does not get very far beyond its present condition. A fourth division of the brachial termination is the volar interosseous. This exists before the median artery can be identified and after the median has appeared the volar for a period exceeds it in dimensions. At the present stage the volar is the smaller and is tucked between the bones of the forearm. It ends in a ventral and dorsal division. The ventral division anastomoses with the digital branches of the median; the dorsal division passes between the radius and ulna, proximal to the carpals, and forms a dorsal digital capillary meshwork. The dorsal interosseous can be identified as a plexiform group, taking origin from the volar interosseous and wandering distally. Some of its terminal capillaries joining the marginal vein are apparent.

The marginal vein still forms a peripheral boundary to the limb extremity. The ulnar half is larger and more definite than the radial half. Between the digits the continuity of this venous channel is beginning to disappear and examination of the extremities of the two radial digits shows that the vein is beginning to surround these digital rudiments, a smaller loop passing ventral and a larger loop passing on the dorsal side of the blunt digital end. Each extremity of the marginal loop is continued along the margin of the limb. The radial margin bears the vena cephalica. Into this there open venous channels from the digits, for out of each dorsal digital network a venous trunk arises and, passing obliquely over the dorsum of the extremity, reaches the vena cephalica. The latter receives numerous communications as it passes, to end in the external jugular.

On the ventral surface of the limb, in close association with the median artery, is the median vein. This arises out of digital capillaries and, receiving numerous tributaries, runs along the ventral aspect. It ends in the region of the elbow chiefly in the vena cephalica, but also in the vena basilica. The vena basilica, arising as a continuation of the marginal vein, grows larger as the trunk is reached and, bending cephalad, lies ventral and slightly above the subclavian artery. At this point it terminates in the cardinal vein. The vena basilica is thus directly continued as the subclavian vein, receiving numerous tributaries from the trunk and body-wall, as well as tributaries from the arm which represent the venæ comites of the artery.

Figure 5 includes the aorta and pulmonary arteries, with the cut ends left by the removal of the heart. This specimen illustrates well the three stages in the life history of the arteries —the capillary stage, the retiform stage, and the final, definite tubular form. In comparison with the veins, it is easily seen that these retain much more of the primitive stages.

SURVEY OF SPECIAL LITERATURE.

Before summarizing these observations it may be of advantage to review the results of other investigators upon which our knowledge of the development of the blood-vessels of the arm has been based.

Dohrn (1889) showed that the subclavian artery belongs to the system of segmental branches of the aorta. He described these as vertebral arteries having two branches, a ventral branch, which supplies the lateral and ventral musculature, and a dorsal branch, which supplies the central nervous system and spinal musculature. The subclavian is one of the vertebrals. Mollier (1894) showed that more than one of these segmental arteries was concerned in the blood supply of the pectoral fin of the Selachian.

Müller (1904) described the arterial supply of the forelimb in an *Acanthias* embryo 20 mm. long. The arteries of the extremities are four in number and are given off by the aorta to the lateral body-wall. Each of these arteries sends a branch to the extremity and dissolves into capillaries in the proximal part of the limb. Out of these, one particular branch survives and becomes the main artery of the limb; the remaining branches from the aorta to this root-net dwindle away. Mollier (1895) showed a comparable arrangement for *Lacerta muralis*. Müller (1904), in a 4-mm. *Lacerta* embryo, traced three segmental arteries into the limb-mass.

Svensson (1908) investigated the subclavian in *Lacerta muralis*. He showed that the limb supply develops from three segmental arteries, the sixth, seventh, and eighth. These anastomose and enter the limb-mass. This plexus was described by Müller as the "plexus arteriosus axillaris," and this name was adopted by Svensson. Out of this plexus, by the dwindling of one part and an increase in another, the chief artery of the limb arises. The primordium of the brachial begins as a plexus, which Svensson calls the "plexus arteriosus brachialis." Hochstetter (1890*a*) studied the subclavian in the bird. He showed that the main vessel of the limb, arising as a twig from the aorta, later joins, through a secondary branch, with the third aortic arch and that the primitive subclavian forms out of these. The same condition holds for the crocodile and chelonia. C. G. Sabin (1905) and Rabl (1906) have investigated the chick, Evans (1909) the duck embryo. To the four periods in the history of the bird's subclavian, Evans adds a still earlier one.

Evans:
  (1) Period of capillary outgrowth from the aorta forming a primary limb plexus not influenced in its arrangement by metamerism.

Rabl, Müller:
  (2) Period of multiple segmental subclavians, a condition resulting from the atrophy of all the capillaries in the preexisting plexus not at segmental points.
  (3) Period of establishment of the primary subclavian artery from the persistence of one of the pairs of segmental subclavians, *i. e.*, the eighteenth.

Hochstetter, Sabin:
  (4) Period of double arterial supply through a contemporary existence of dorsal and newly arisen ventral subclavians.
  (5) Period of enlargement of the permanent channels, the secondary subclavian, and coincident atrophy and disappearance of the primary vessels.

Numerous investigations on the development of the limb-arteries in mammals are to be found. The investigators have concerned themselves primarily with the phylogenetic rise and fall of particular vascular stems in the limb.

Zuckerkandl (1894) studied rabbit and cat embryos and also two human embryos. The earliest stages seen by him showed a thick axial vessel in the limb. The forearm portion forms the arteria interossea volaris. Both human embryos showed the same. The volar interosseous gives off a thick dorsal branch which runs between the proximal parts of the radius and ulna. Distally, it supplies a branch to the volar part of the forearm, while part of the blood-stream is turned dorsally and, passing through the carpus, supplies the dorsum of the hand. Leboucq (1893) has described the same in the human embryo. In addition to the chief stem, there is present in rabbit and cat embryos a vessel running to the volar aspect along with the median nerve. Meanwhile, the volar interosseous decreases in size and the arteria mediana undergoes an increase. Similarly in man, a median period follows the interosseous (Janosik, 1891; De Vriese, 1902), and this is finally superseded by the dominance of the ulnar and radial.

Grosser (1901) described two bat embryos (*Rinolophus hipposiderus*), one of 4.75 mm., one of 6.25 mm. An axial stem shows as the main trunk of the limb supply. Its distal part forms the arteria interossea volaris. This divides at its extremity into a feeble ventral branch, which supplies the volar aspect, and a third dorsal twig, which pierces the carpal region and supplies the dorsal side of the extremity. In a 7.25-mm. embryo the ramus perforans carpi dwindles and a thick branch goes from the interosseous to the dorsal side between the radius and ulna, proximal to the carpus. Soon afterward the arteria mediana becomes the chief stem.

Even earlier, Hochstetter (1896) showed for the *Echidna* the arteria interosseus as the temporary chief vessel of the limb. Later, the radial takes on the role of the chief blood-supply of the limb. The brachial undergoes a change by which it is transformed into a capillary net. This is secondary and due to an obstruction to the flow of the blood through the brachial as the result of the arrangement of musculature and humerus (Göppert, 1905).

Zuckerkandl (1907) investigated the mole, *Talpa europea*. Embryos 6, 8, and 10 mm. long show that the ontogeny follows a quite typical path until a brachialis, an interosseous, and (as a division of the latter) a mediana are formed. Then begins the formation of a thick dorsal path which forces the old-stem artery of the arm and forearm into the background. Here, also, the new path forms itself out of numerous anastomosing vessels through quite fine twigs. Zuckerkandl sees in this the formation of a more favorable path for adaptation to the particular habits of the mole.

The investigations of Müller (1903) demand particular consideration. He studied a considerable number of human embryos and found that the definitive arrangement was reached in embryos from 16 to 20 mm. In the youngest stage (5 mm.) the limb arteries and veins are separable by their relation to the limb margin. The primordium of the arterial system belongs to an axially situated net which is supplied through a large aortic branch. This stem pushes through the brachial plexus on its way to the limb mass and divides therein into two branches which again join together. Out of the axial net arises a capillary net which carries the blood to the marginal vein.

The succeeding stage (8 mm.) shows, in relation to the nervous system, an essential continuation of the former stage.

The 11.7-mm. embryo shows a recognizable skeletal primordium. Humerus, radius, and ulna are separable. In the brachial plexus the chief paths are differentiated. The formation of the deep veins has begun. The limb arteries enter on the medial side of the plexus and here divide. A branch breaks through the ventral nerves and out of the plexiform mass which this branch forms the artery of the limb develops, running dorsal to the median nerve. Many islands in its course show its formation out of a "net" arrangement. While on one side the breaking through of the plexus is simple, on the other, the stem, in breaking through, splits into three branches, which, lying in the angle of the nerves, fuse together. Müller remarks particularly that the arteries in the region of the root of the ventral nerve-plate form an actual network of vessels which are characterized by their particular relation to the nerve primordium.

From the stem artery, after its exit from the plexus, there arises a dorsal vessel-formation out of which develop the subscapular, posterior circumflex, and profunda, probably also part of the interossea dorsalis, and recurrent radial. Furthermore, the primordia of the median, radial, and ulnar, in the form of a net, are recognizable, while the immediate lengthening of the stem artery forms the volar interosseous. Superficially situated vessels form the primordia of the superficial antibrachii. The remaining embryos (14 to 20 mm.) show the median artery as the chief stem; all the chief branches are identifiable and the network of the first primordium has dwindled.

In his later comparative work Müller (1904) dilates upon the importance of this axillary net. He sees in it many segmental lateral branches of the aorta, which break through the brachial plexus and are joined to the plexus, medially and laterally, by a longitudinal anastomosis. Only one of these remains in conjunction with the aorta and forms accordingly the subclavian. The others between the aorta and the longitudinal anastomosis disappear. In the youngest stage (5 mm.) Müller has been unable to find a plexus arteriosus, but quite certainly traces a branch of the aorta into the capillary net. (This gap is filled by my 4.5-mm. pig embryo.) Müller remarks that no one has yet been able to demonstrate in the mammals a multiple segmental supply for the limb, as in the lower vertebrates. He believes rather that the original vessel is single and subsequently divides, assuming in its divisions a segmental arrangement. In his work in 1908 he is less certain, owing to the appearance meanwhile of the work of Rabl (1906). The latter demonstrated the multiple segmental arrangement in the penguin. Müller (1908) investigated more thoroughly the sections in which Keibel came across two subclavians when preparing his book. As a result he reinterprets his plexus axillaris as being probably formed out of several segmental contributions.

Elze (1907) takes issue with the views of Müller (1904). He investigated the subclavian in four human embryos of 7, 9, 11, and 15 mm. In all, the sixth segmental (seventh of others) forms a subclavian which crosses the plexus in the region of the seventh cervical nerve. He finds no axillary net. He believes that the original polysegmental supply is quickly reduced to a single vessel and he regards the plexus axillaris of Müller as a secondary formation which has nothing to do with the segmental arteries. The finding of two subclavians in the human embryo is not an isolated one; Keibel and Elze described a second and Evans (1908) a third. These vessels belong to successive segmental arteries and end in the capillary net in the arm.

The original *net* character of the arterial primordium is appreciated in the work of De Vriese (1902). The material used consisted of 25 human embryos between 10 and 100 mm., supplemented by other mammalian material. She describes each nerve as being surrounded by a net and out of these nets are formed the stems. In the forelimb mass a net is present for the median and the interosseous. A stem in the interosseous strip becomes thicker and forms the primitive chief artery, which loses this role through the development of the median.

Göppert (1905) described his entire arterial system of the limb-mass as being preceded by a net-formation which lies near to all peripheral nerve-fibers. In 1910 he presented his studies on the development of the arterial variations and in his paper he gave a copious survey of the literature on this subject. His own investigations were made upon the white mouse. In his stage 1, which consists of five embryos fixed and studied 8 days after impregnation, he finds the limb-mass supplied by a number of branches varying from two to five, arising from the aorta. These correspond and are usually segmentally arranged, but occasionally a branch arises in a non-metameric position.

All of our specimens show the early branches to the limb-bud arising as lateral branches from the segmental arteries. In the pig no evidence is found of arteries supplying the limb-mass that are not segmentally arranged, and herein our specimens fail to agree with the findings of Evans in the duck and Göppert in the mouse. Neither can we corroborate the great variability in number and arrangement which Göppert so emphasizes. Furthermore, in all of our specimens the limb-arteries appear as lateral branches of the dorsal segmental and not as lateral branches of the aorta.

Göppert's stage 2 shows the suppression of most of the lateral branches and the elevation of one of them (the seventh) to the principal axial stem. The remnants of the preceding and succeeding segmentals still persist. In the limb-mass the principal artery breaks up into many branches. In the third stage the arteries to the limb-mass may be single or still multiple and have now fused with the dorsal segmentals. Whether single or double, they go through the third root of the brachial plexus and form a branch medial and lateral to the plexus. These fuse beyond the plexus. Thereafter the artery lies in the angle between the dorsal and ventral nerves. It continues in the axis of the limb and finally breaks up into numerous branches. The stem artery may show island-formation.

At stage 4 the limb-arteries still show multiple origin. They anastomose on the medial side of the plexus, pass through the plexus, usually just cranial to the third root. Before passing through the plexus a descending branch forms the ramus caudalis medialis. After passing through the plexus a branch goes to the radial margin of the limb, the ramus dorsalis. The main stem follows the limb axis and breaks up into numerous branches and twigs.

At stage 6 the arteries to the limb, in all except one specimen, are reduced to a single trunk. Branches such as the volar interosseous, dorsal interosseous, and internal mammary are recognizable. At stage 7 the main artery to the limb, in all cases, springs as a single vessel and all its branches can be identified.

In his discussion Göppert recognizes the stage we have called *retiform* as a stage preceding the formation of definite stems, and he appeals to the postulates of Thoma to explain the transformation. He has difficulty in accepting the terms "plexus arteriosus subclavius," etc., of Müller, because the individual elements of the plexus are much too large to be called capillaries. Our method dispels this difficulty, as we show the capillary net preceding this retiform stage.

SUMMARY.

In the mammalian forelimb the earliest vascular pattern that we have succeeded in portraying is characterized by regular segmental contributions from the fifth, sixth, seventh, eighth, and ninth segmental arteries. This contribution is somewhat retiform at its origin and in the limb elevation becomes reduced to a plexiform capillary net. Although this contribution happens to be segmental in origin, yet in the limb-bud there is not the slightest trace of segmentation in the vascular supply. In the duck, Evans (1909) discovered an arrangement of blood-vessels to the forelimb which did not exhibit the regular metameric order. Göppert, in the white mouse, similarly pictures a stage in which great irregularity and variability mark the earliest blood-supply to the limb. Perhaps these investigators have succeeded in demonstrating an earlier phase than I have. In the formation of an individual arterial tube three stages can be distinguished: (1) the stage of the capillary net, which can be best elicited when the vessels are injected; (2) the stage characterized by enlarged tubes showing island-formation, coalescence, and a tendency to fuse—the retiform stage; (3) the formation of the definite stem.

These stages stand in phylogenetic order, the first being the most ancient; also, they are repeated ontogenetically. Again, each stage is a response to definite physiological demands, the first being an angioblastic response to tissue needs, the second taking place according to the postulates of Thoma, and finally leading into the third.

Out of these available arteries of the forelimb the seventh soon dominates and the others dwindle. It is hard to resist the inference that the seventh predominates because it is opposite the center of the growing limb-mass. For a time we now have a growing limb-mass filled with a great capillary network and maintained by a central stem increasing continually in capacity. This holds until about the 10-mm. stage, when the plexus on the medial side of the transparent area begins to sort itself out into definite stems.

In the 12 to 14 mm. stage the vertebral, the posterior cervical, the dorsal, and the internal mammary begin as coalescences of capillaries, assuming more and more definite paths—a retiform stage, the definition being most marked where the stems are nearest the great vessel. In the mammary the definition is most marked where the intercostal stems meet it, but subsequently the increase in that portion which links it to the subclavian becomes greater. Beyond the body-wall the main stem is still in the plexiform state. Next, the shoulder area sorts itself into stems out of the capillary mass; so a thoracic axis, a subscapular, and an anterior and a posterior circumflex arise.

By the time the embryo has reached a length of about 16 mm., the vascular pattern has become so arranged that the principal stems can be identified. Those nearest the axial line of the embryo reach a definition early; those at the periphery of the limb remain plexiform. From the definite stem of the brachial, a profunda and an inferior ulnar collateral artery can be recognized; then a radial, a plexiform ulnar, a volar interosseous, and an arteria mediana. With the later stages the final arrangement of a dominant median and a feebler interosseous, with its relation to the dorsal interosseous, completes the development of the principal blood-vessels of the forearm.

BIBLIOGRAPHY.

Aeby, Chr., 1871. Der Bau des menschlichen Körpers mit besonderer Rücksicht auf seine morphologische und physiologische Bedeutung. Leipzig.

Baader, A., 1866. Ueber die Varietäten der Armarterien des Menschen und ihre morphologische Bedeutung. I. D. Bern. (Quoted from Müller.)

Dohrn, A., 1889. Studien zur Urgeschichte des Wirbeltierkörpers, vol. 15. Neue Grundlagen zur Beurteilung der Metamerie des Kopfes. Mitth. aus d. Zool. Station in Neapel, vol. 9.

Elze, C., 1907. Beschreibung eines menschlichen Embryo von zirka 7 mm. grosster Lange unter besonderer Berucksichtigung der Frage nach der Entwickelung der Extremitätenarterien und nach der morphologischen Bedeutung der lateralen Schilddrüsenanlage. Anat. Hefte, $1.^{35}$

——— 1913. Entwickeln sich die Blutgefäss-stämme aus netzförmigen Anlagen unter dem Einflusse der mechanischen Faktoren des Blutstromes. Verh. d. Anat. Gesellsch.

——— 1913. Studien zur allgemeinen Entwicklungsgeschichte des Blutgefäss-systems. 1. Teil. Arch. f. mikr. Anat., vol. 82.

——— 1919. Same. II. Teil. Arch. f. mikr. Anat., vol. 92.

Evans, H. M., 1908. On an instance of two subclavian arteries to the early limb-bud of man. Anat. Record, vol. 2.

——— 1909. On the earliest blood-vessels in the anterior limb-buds of birds and their relation to the primary subclavian artery. Amer. Jour. Anat., vol. 9.

——— 1909. On the development of the aortæ, cardinal and umbilical veins and the other blood-vessels of vertebrate embryos from capillaries. Anat. Record, vol. 3.

——— 1911. Die Entwicklung des Blutgefäss-systems. Handbuch der Entwicklungsgeschichte des Menschen (Keibel and Mall), vol. 2.

Göppert, E., 1904–5. Die Beurteilung der Arterienvarietäten der oberen Gliedmasse bei den Säugetieren und beim Menschen auf entwicklungsgeschichtlicher und vergleichend-anatomischer Grundlage. Ergebn. d. Anat. u. Entwicklngsges., Abth. II, vol. 14.

——— 1908. Variabilität im embryonalen Arteriensystem. Verh. d. Anat. Gesellsch.

——— 1910. Ueber die Entwicklung von Varietäten im Arteriensystem. Morphol. Jahrb., vol. 40.

Grosser, O., 1901. Zur Anatomie und Entwicklungsgeschichte des Gefässsystems des Chiropterus. Anat. Hefte, $1.^{17}$

Hochstetter, F., 1890*a*. Ueber den Ursprung der Arteria subclavia der Vögel. Morphol. Jahrb., vol. 16.

——— 1890*b*. Ueber die Entwickelung der A. vertebralis beim Kaninchen, nebst Bemerkungen über die Entstehung der Ansa Vieussenii. Morphol. Jahrb., vol. 16.

——— 1906. Beiträge zur Anatomie Entwicklungsgeschichte des Blutgefäss-systems der Krokodile. Aus: Voeltzkow. Riese in Ostafrika in den Jahren 1903–1905, vol. 4.

Janosik, J., 1891. Le développement des vaisseaux sanguins et des nerfs du membre antérieur chez l'homme et chez quelques autres animaux. Prague.

Krause, W., 1876. Henle's Handbuch der systematischen Anatomie des Menschen, vol. 3.

Lewis, F. T., 1905. The development of the veins in the limbs of rabbit embryos. Amer. Jour. Anat., vol. 5.

Macalister, A., 1886. The morphology of the arterial system in man. J. Anat. and Physiol., vol. 20.

Mackay, J. Y., 1889. Arterial system of vertebrates homologically considered. Memoirs and Memoranda in Anatomy, vol. 1.

Mollier, S., 1894. Die paarigen Extremitäten der Wirbeltiere. 1. Das Icthyopterygium. Anat. Hefte, $1.^{3}$

MOLLIER, 1895. Die paarigen Extremitäten der Wirbeltiere. Anat. Hefte, 1.^{5}

MÜLLER, E., 1903. Beiträge zur Morphologie des Gefäss-system. I. Die Armarterien des Menschen. Anat. Hefte, 1.^{22}

——— 1904. II. Die Armarterien der Säugetiere. Anat. Hefte, 1.^{27}

——— 1908. III. Zur Kenntnis der Flügelarterien der Pinguine. Anat. Hefte, 1.^{36}

RABL, HANS, 1906. Die erste Anlage der Arterien der vorderen Extremitäten bei den Vögeln. Arch. f. mikr. Anat., vol. 96.

RUGE, G., 1883. Beiträge zur Gefässlehre des Menschen. Morphol. Jahrb., vol. 9.

SABIN, C. G., 1905. The origin of the subclavian artery in the chick. Anat. Anz., vol. 26.

SABIN, F. R., 1904. On the development of the blood-vessels of the brain in the human embryo. Amer. Jour. Anat., vol. 4.

——— 1917. Origin and development of the blood-vessels of the chick and of the pig. Contributions to Embryology, vol. 6. Carnegie Inst. Wash. Pub. No. 226.

SENIOR, H. D., 1919. The development of the arteries of the human lower extremity. Amer. Jour. Anat., vol. 25.

STREETER, G. L., 1918. The developmental alterations in the vascular system of the brain of the human embryo. Contributions to Embryology, vol. 8. Carnegie Inst. Wash. Pub. No. 271.

SVENSSON, ELIS, 1908. Zur Morphologie der Arteria subclavia und axillaris bei Lacerta. Anat. Hefte, 1.^{37}

THOMA, R., 1893. Untersuchungen über die Histogenese und Histomechanik des Gefäss-systems. Stuttgart.

DE VRIESE, B., 1902. Recherches sur l'évolution des vaisseaux sanguins des membres chez l'homme. Arch. d. Biol., vol. 18.

ZUCKERKANDL, E., 1894–1895. Zur Anatomie Entwicklungsgeschichte der Arterier des Vorderarmes. I. Teil, Anat. Hefte, 1.^{4}; II. Teil, Anat. Hefte, 1.^{5}

——— 1907. Zur Anatomie und Morphologie der extremitäten Arterien. Sitzungsb. a. k. Akad. d. Wiss. in Wien. Math.-naturw. Kl., Bd. 116, Abth. III, pp. 554–561.

DESCRIPTION OF PLATES.

PLATE 1.

FIG. 1. Dorsal view of the right forelimb of a 4.5-mm. pig embryo, showing the polysegmental arterial supply to the limb and capillary net.

FIG. 2. Dorsal view of the left forelimb of a 7.5-mm. pig embryo. The polysegmental supply to the limb has undergone reduction. The bud shows retiform and capillary vessels.

FIG. 3. Dorsal view of left forelimb of an 8.5-mm. pig embryo. The seventh segmental persists as the subclavian artery and after entering the limb-bud becomes retiform and then ends in capillaries. The subclavian vein also appears.

PLATE 2.

FIG. 4. Ventral view of left forelimb of a 12-mm. pig embryo. The proximal branches of the subclavian appear as capillary nets. The subclavian is retiform. Its termination is the dorsal and ventral branches. The veins have become well defined and continuous around the limb margin.

FIG. 5. Ventral view of the forelimb in a 19-mm. embryo. Vascular pattern is nearly complete.

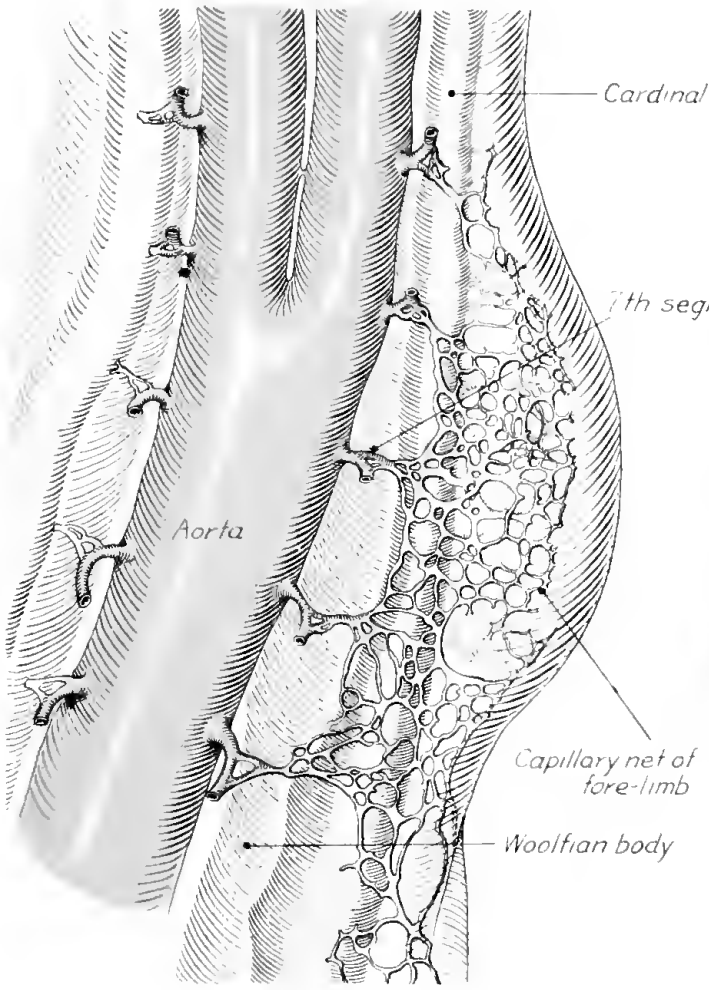

Fig 1

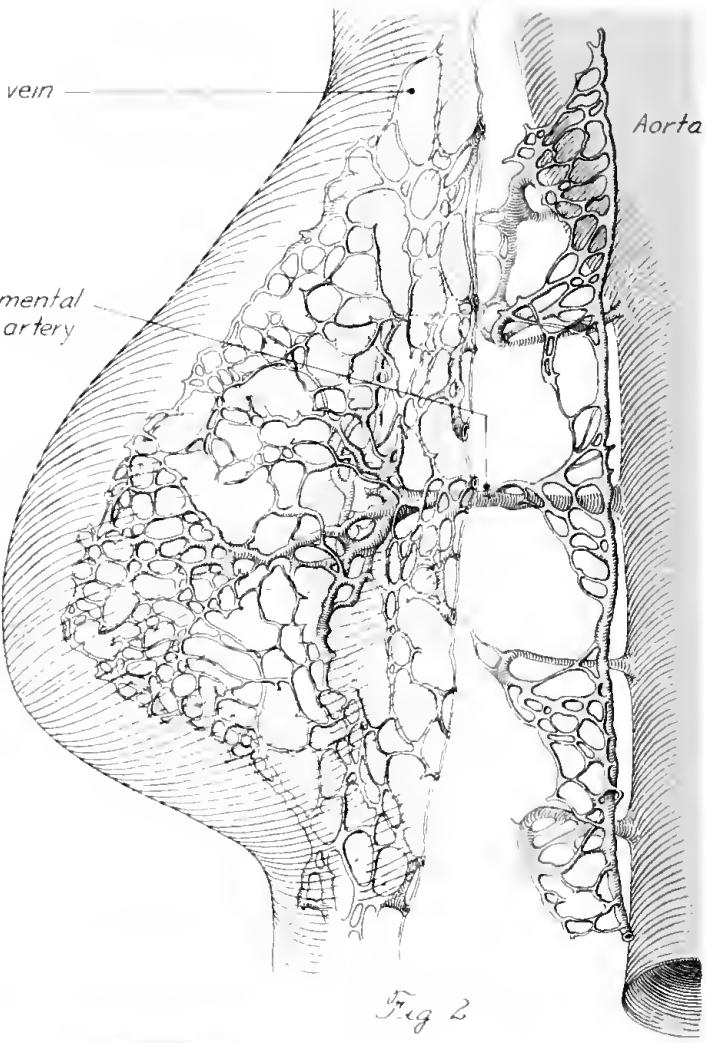

Fig 2

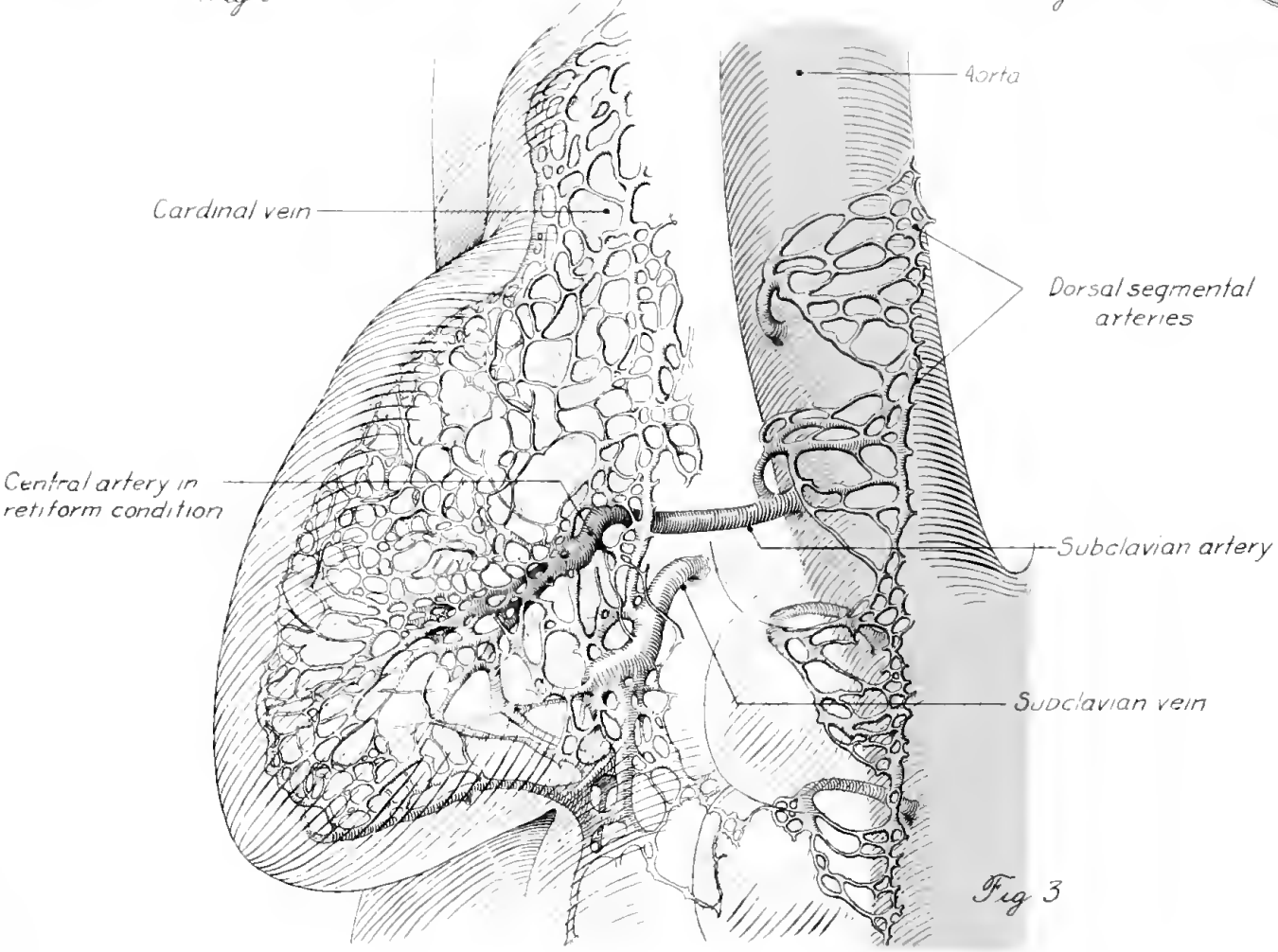

Fig 3

J. F. Didusch fec.
A. Hoen & Co. Lith.

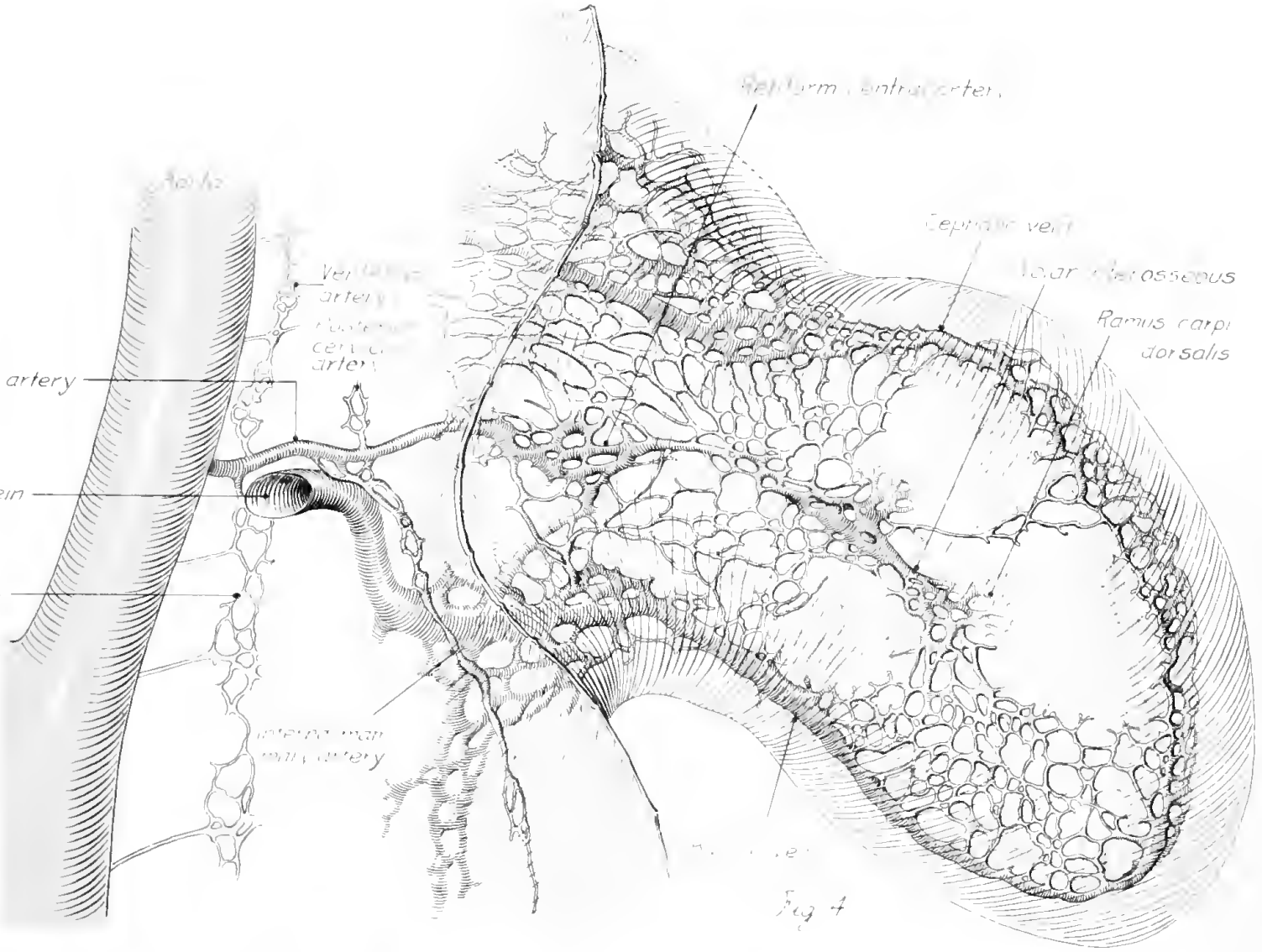

Fig 4

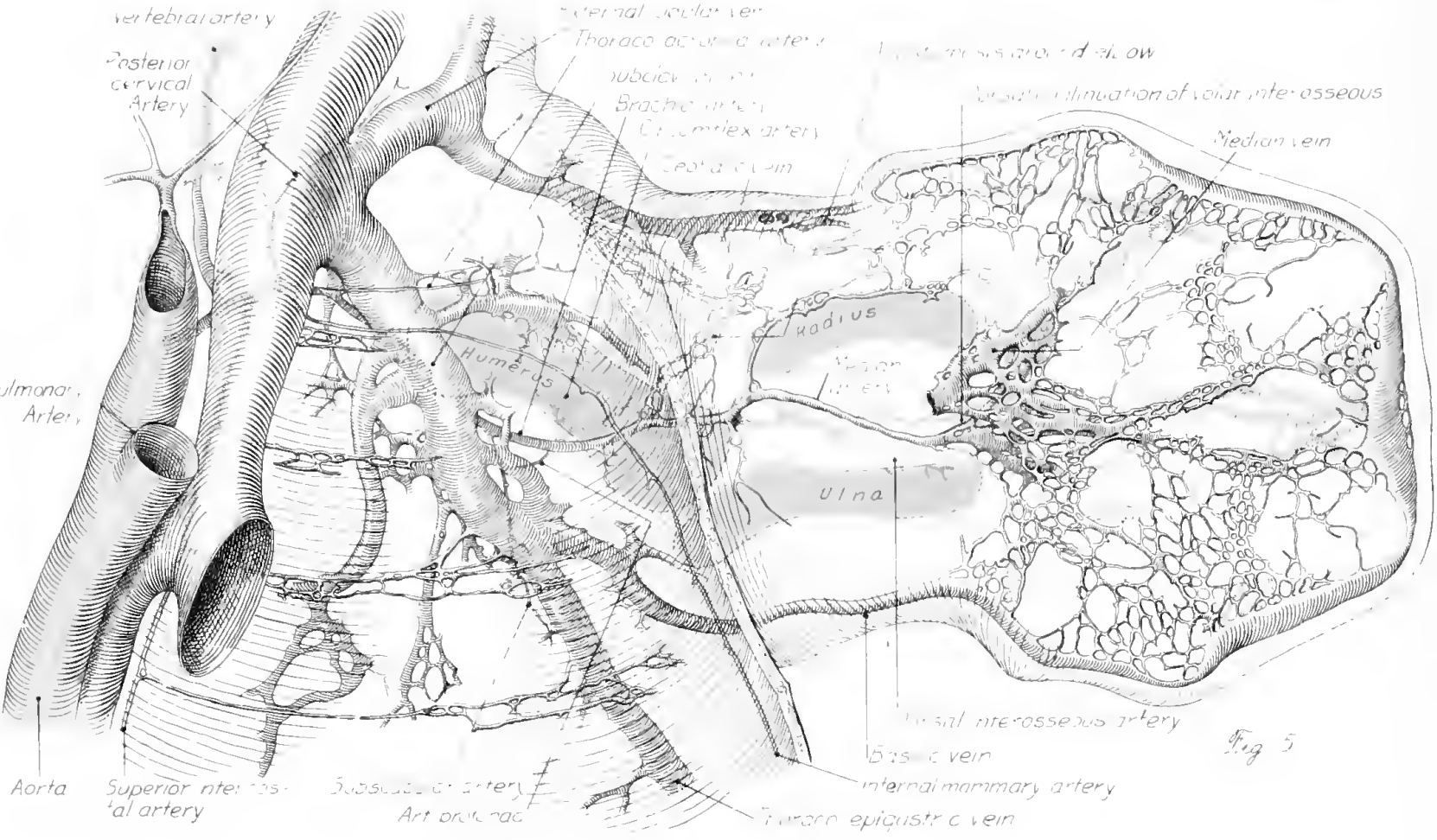

Fig 5

J. F. Didusch fec.

A. Hoen & Co. Lith.

CONTRIBUTIONS TO EMBRYOLOGY, No. 71.

THE DEVELOPMENT OF THE SUBCUTANEOUS VASCULAR PLEXUS IN THE HEAD OF THE HUMAN EMBRYO.

By Ellen B. Finley,

Anatomical Laboratory of The Johns Hopkins University.

With two plates and one text-figure.

THE DEVELOPMENT OF THE SUBCUTANEOUS VASCULAR PLEXUS IN THE HEAD OF THE HUMAN EMBRYO.

When the work of the last ten to fifteen years is analyzed, it becomes clear that the fundamental problem of the vascular system is concerned with the origin and growth of endothelium, since the entire vascular system begins from specific cells which later develop into vessels. These essential cells of the vascular system are the angioblasts of His or the vasoformative cells of Ranvier. With the term "angioblast" was early associated the idea of His that complete differentiation of vasoformative cells takes place in the yolk-sac, these cells later invading the embryo itself. This idea had to be abandoned when it was proved that angioblasts differentiate within the body of the embryo. In a living preparation of a chick embryo the aorta has been observed by Dr. Sabin to differentiate *in situ*, and it now seems probable that many of the primary veins differentiate in the same way.

In a consideration of the origin and growth of endothelium, one of the most important points to be determined is the length of the period during which angioblasts continue to differentiate from undifferentiated mesenchyme. With such a consideration in mind, the study of the development of the vascular system of the head in the human embryo becomes significant. There are two main vascular plexuses to be observed in the head: (1) the meningeal, which first appears in embryos of about 4 mm., and (2) the subcutaneous plexus, which appears at about the 20-mm. stage. There is thus a marked difference in the extent of differentiation of the embryo itself. From the meningeal plexus develop the vessels of the central nervous system, the dorsal sinuses, and the vessels of the skull, while from the subcutaneous plexus develop the vessels of the skin and of the head-musculature. The two unite in common with the vessels of the neck, but on the sides and vault of the head the two systems are completely separated by the developing membranous skull. The subcutaneous plexus, being thus isolated and spread out as a thin sheet that can be examined in a total mount, constitutes a particularly valuable field for study of angioblastic differentiation in this relatively late period of embryonic life.

The material used for the study of the subcutaneous plexus of the head consisted of serial sections of human embryos in the Carnegie Collection and of total mounts of skin flaps from the area of the head plexus. Before making the dissection, the fixed embryo was studied in the gross, whenever possible, and the general plan of the plexus was determined. Several small skin flaps were then carefully dissected from the sides of the head and examined, first unstained and later after staining. In several instances tangential serial sections were cut. The principal stains used for the total mounts were alum cochineal, and hematoxylin, either in combination with eosin, aurantia, and orange G or with eosin alone. Wright's blood-stain was used for some of the tangential sections. Total mounts were found to have distinct advantages, since they afforded an opportunity to study a portion of the vascular spread with the vascular elements intact and with their normal relations preserved, in contrast with serial sections in which the fields were necessarily discontinuous and comparatively limited.

In the gross examination of human embryos ranging from 19 to 45 mm., there could be observed a delicate, fringe-like plexus pushing up toward the vertex of the head, first described by Hochstetter (1916). It was always visible, but in some embryos it had a much more brilliant appearance than in others, due, possibly, either to the stage of development of the plexus at that particular time or to the fixing fluid used. It was most striking in an embryo that had been fixed in Bouin's solution, which is probably much better for this purpose than formalin. At earlier stages the transition from vascular to avascular conditions is more gradual. In later stages it is more abrupt and the transitional margin is in the nature of a narrow, well-defined line. The early stage is particularly well shown in plate 1, figure 2, where there appear to be two prominent foci of growth or growth centers, one anterior to the ear in the temporo-frontal region and the other posterior to the ear in the occipital region. The growth of the vessels radiates up and out from these centers. On the borders of these two semicircular areas, small, finely granular tips can be seen, a few of which seem to have no connection with the larger vessels below. The growing edge, as it advances, tends to become more and more flattened, as may be seen in figures 3 and 4, a slight indentation, however, persisting at a point almost directly above the anterior portion of the external ear. At about 40 to 45 mm. the growing tips anastomose across the mid-line and circulation over the head is established.

On microscopic examination of total mounts from the head region, four stages in the development of the blood-vessels were observed. Figure 1 shows diagrammatically four definite zones. First, toward the vertex, is the uppermost zone, which is a predominantly avascular area composed of undifferentiated mesenchyme. The zone next below consists of a network of solid, darkly staining masses of nucleated cells filled with hemoglobin. Toward their upper borders these masses often have slender tips which penetrate the avascular area. Between and beyond the tips stretches indifferent mesenchyme. This second zone may be called the zone of the angioblastic net. The third zone is a capillary network and in it can be seen delicate, branching capillaries whose endothelial walls appear to be intact and to inclose a definite lumen. Within the lumina of these vessels are scattered clumps of well-formed blood-cells (nucleated and non-nucleated), whose outlines are clearly defined. Occasionally the lumen is practically empty (plate 2, fig. 10), the most probable explanation for which is that liquefaction of cellular elements has taken place within the blood-vessels themselves, assuming that this area has been transformed from the solid zone just described. Finally, in the last zone are encountered more mature vessels, with slightly thickened walls, through which blood has evidently circulated to some extent. Some of these vessels may be forerunners of vessels destined to persist.

These zones are the expression of a developmental process, and in the growing state the characteristic elements of one zone must become quickly transformed into those of the more mature zone adjoining it. Thus, in any given preparation there is a consecutive picture of the life history of a blood-vessel, from the earliest stage to maturity, from undifferentiated mesenchyme, through angioblast and capillary, to a fully formed vessel.

The second zone—that of the angioblastic net—is particularly interesting, not only because it represents the area of actual new growth, but also because of its possible significance in connection with the relation of red blood-cells to endothelium. Plate 2 (figs. 7, 8, 9, and 11) shows a few of the varied forms which this plexus assumes. Some of the tips are club-shaped, some thick at the center with two side extensions, like tiny branches on a tree, some so vaguely outlined distally as to seem to merge directly into the mesenchyme of the avascular area, while others, slender and long, are drawn out into a fine filamentous point. The cells of this zone are all nucleated and, for the most part, contain a considerable amount of hemoglobin. Those at the extreme tips contain less, while in a few cells the cytoplasm is entirely colorless and translucent (fig. 9). The cell boundaries are not clear-cut, and the cells vary greatly in shape and size, due to their pressure against each other. In this area there are indications of a very massive transformation of mesenchyme into red blood-cells. In occasional instances the cellular masses are edged by long endothelial cells, but for the most part they are entirely composed of the earliest forms of red blood-cells, their rounded contours marking the boundaries between the angioblastic net and the avascular zone. It is obvious that this is not exactly the process by which it has been demonstrated that red blood-cells arise in the chick, because it can not be stated that these cells originated within the lumen of a vessel (Danchakoff, 1908; Sabin, 1920). On the other hand, it can not be said that these observations indicate a diffuse extravascular origin of red blood-cells that would subsequently have to migrate into preformed vessels, such as Maximow (1909) believes characterize the late origin of red blood-cells in the mammal. Rather, the process seems somewhat intermediate between these two positions, the cells clearly arising in a definite relation to the vascular system, not quite independently.

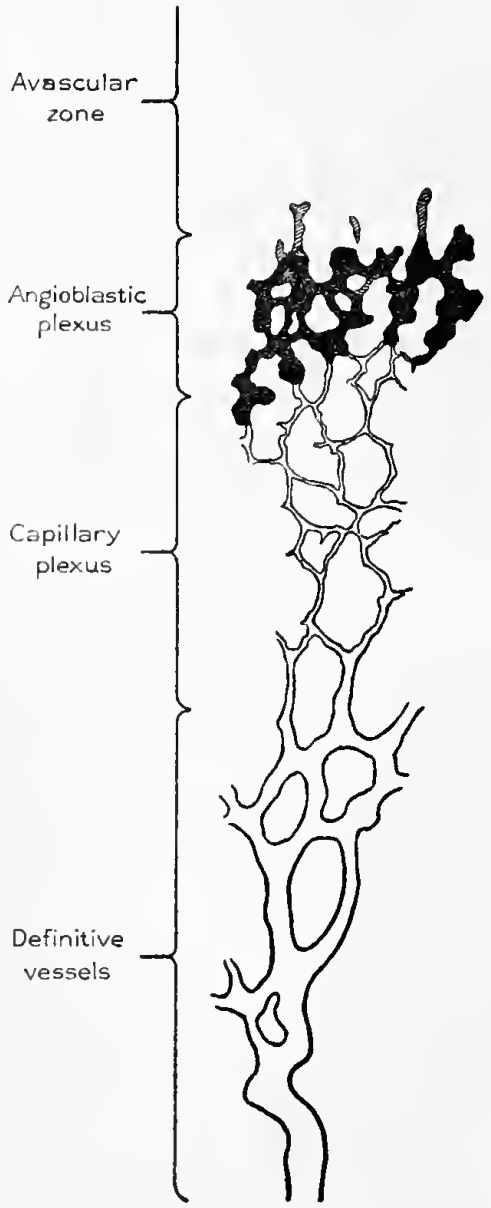

Text-figure 1.

Diagrammatic sketch of the growing edge of the subcutaneous plexus in the head of the human embryo, showing the four zones of transition from undifferentiated mesenchyme into definite vessels. Processes from the angioblastic plexus can be seen encroaching upon the territory of the avascular zone; these are indicated by lighter shading.

At the border between the first and second zones are occasionally small clumps of cells which have no visible connections with the main plexus. Plate 2 (figs. 12 and 13) shows some of these isolated clumps. They most frequently occur as single chains of nucleated cells containing a slight amount of hemoglobin and often lie in direct line with the advancing plexus, though not continuous with it. Sometimes they are seen as solid clumps of cells, with fine, thread-like processes extending out from them, strongly suggestive of those described by Dr. Sabin in the two-day chick. She found a marked tendency on the part of syncytial masses of angioblasts to put out delicate sprouts by which they joined similar masses, thus developing the vascular plexus. Since most of these isolated chains and clumps of cells contain hemoglobin, they might easily be regarded as indicating the origin of red blood-cells from mesenchyme outside the vascular system, but when their proximity to the main plexus is considered, together with the probability of their joining it to form solid cellular masses, as has been described, their position and their hemoglobin-content do not seem to militate against an angioblastic origin for red blood-cells and endothelium. It seems quite clear that this process is intermediate between the two extreme views.

There are, it seems, at least three possible explanations for the development of the vascular area in the subcutaneous tissue of the head of the human embryo. First, it is possible to conceive of the tips of the vessels forcing their way into and through the undifferentiated tissue, taking nothing from it, but pushing the mesenchymal cells aside as they advance by means of their own active cellular division and growth. One would expect, under such conditions, that when the sections of these areas are fixed, the vessels would shrink, leaving in their place a hollow space. This has never been noted, nor have the surrounding mesenchymal cells a compressed appearance. A second possibility is that the vessels lengthen by true endothelial division and sprouting. Figures 7 and 8 (plate 2) are suggestive of such a process, but they are the exception rather than the rule, since there appears to be a great enlargement of the vascular tips, due to a marked differentiation of mesenchyme into red blood-cells, before many endothelial cells are clearly differentiated. Another conception is that the tips of the growing plexus exert just the stimulus needed for the mesenchymal cells lying close to them to differentiate into angioblasts or primitive blood-cells and to become joined to the tips. From observation of many different specimens, the impression has been gained that this last is the principal method of growth. The cells may be added one by one, or they may form single strands before adding themselves to the main plexus. Either before or after becoming a part of the plexus, it is probable that they quickly divide and grow, taking on the appearance of solid masses of cells of varied size and shape. The fact that the mesenchymal cells differentiate in such a precipitous manner into hemoglobin-containing red cells is doubtless to be explained by the relatively late stage of embryonic development at which the differentiation occurs.

In closing, I should like to say that this problem was suggested to me by Dr. Sabin, and I am greatly indebted both to her and to Dr. Streeter for helpful advice and assistance throughout the course of the work.

CONCLUSIONS.

1. In this paper evidence is presented which shows that the growing edge of the subcutaneous vascular head plexus in human embryos at about the end of the second month is still in the angioblastic stage, and consists of a plexus of cells rather than a plexus of vessels.

2. The particular area studied was an interesting one for observation of the relation of red blood-cells to endothelium. Such an area is obviously simpler than adult bone-marrow, and though no distinctly angioblastic phase was noted intermediate between mesenchymal cells and red blood-cells, the origin of the red blood-cells seemed in direct relation to an advancing vascular zone. These observations indicate the origin of red blood-cells by a process somewhat between an intravascular development and an extravascular development, with subsequent entry of the cells into preformed vessels.

REFERENCES CITED.

DANCHAKOFF, V, 1908. Untersuchungen über die Entwicklung des Blutes und Bindegewebes bei den Vögeln. 1. Die erste Entstehung der Blutzellen beim Hühnerembryo und der Dottersack als Blutbildenes Organ. Anat. Hefte, vol. 1^{37}, p. 471.

HOCHSTETTER, F., 1916. Über die Vaskularisation der Haut des Schädeldaches menschlicher Embryonen. K. Akad. d. Wiss., Wien, Math.-Naturwiss Kl. Bd. 93.

MAXIMOW, A., 1909. Untersuchungen über Blut und Bindegewebe. 1. Die frühesten Entwicklungsstadien der Blut- und Bindegewebszellen beim Säugetierembryo, bis zum Anfang der Blutbildung in der Leber. Arch. f. mikr. Anat., vol. 73, p. 444.

SABIN, F. R., 1920. Studies on the origin of blood-vessels and of red blood-corpuscles as seen in the living blastoderm of chicks during the second day of incubation. Contributions to Embryology, vol. 9, Carnegie Inst. Wash. Pub. 272.

DESCRIPTION OF PLATES.

Plate 1.

Fig. 2. Photograph of a human embryo 23 mm. in length (No. 966), showing the vascular plexus in the subcutaneous tissue of the head in its earliest form. It is characterized by two distinct growth centers, the temporo-frontal and the occipital, from which the vessels gradually spread over the apex of the head. A sharply defined area between the two growth centers constitutes an angle of retarded growth. ×4.

Fig. 3. Photograph of a human embryo 27.5 mm. in length (No. 2561), showing a later stage of the plexus. The angle of retarded growth is not as prominent and the margin of the plexus appears as a narrower and more well-defined line than that in figure 2. ×4.

Fig. 4. Photograph of a human embryo 36 mm. in length (No. 1591), showing a late stage in the closing in of the plexus. ×2.

Fig. 5. Photograph from a total mount of a piece of the scalp from a human embryo 28 mm. in length (No. 1240*a*). The varied forms of the growing tips are well shown and the transition from the angioblastic net to the capillary net can easily be followed. ×80.

Fig. 6. Photograph from another portion of the same section as above, showing, under higher magnification, the first and second zones. In the center a long tip from the angioblastic plexus is seen to penetrate the avascular zone. This represents the first step in the differentiation of the mesenchyme into angioblastic tissue. ×150.

Plate 2.

Fig. 7. Drawing of a growing tip, showing red blood-cells as they first appear, seen at the edge of the head plexus in a human embryo 28 mm. in length (No. 1240*a*, total mount). The club-shaped cellular mass has an indefinite connection with the main angioblastic plexus. ×930.

Fig. 8. Drawing of a growing tip at the edge of the head plexus in a human embryo 23 mm. in length (No. 966). Several well-defined endothelial cells can be made out at the edge of the angioblastic strand, and there is a fine filamentous strand at the extreme tip, which appears to be an endothelial process. ×930.

Fig. 9. Drawing of a growing tip at the edge of the head plexus in a human embryo 28 mm. in length (No. 1240*a*, total mount). Two cells with clear, colorless cytoplasm may be observed. ×930.

Fig. 10. Drawing of a capillary from the third zone of the head plexus in a human embryo 19 mm. in length (No. 431). The capillary is seen to be empty save for three nucleated red blood-cells. ×930.

Fig. 11. Drawing of a typical growing tip at the edge of the head plexus in a human embryo 26.4 mm. in length (No. 1008). ×930.

Fig. 12. Drawing of a strand of early red cells, containing a slight amount of hemoglobin, and having no apparent connection with the main angioblastic plexus. Taken from a total mount of the scalp of a human embryo 23 mm. in length (No. 1358*f*, total mount). ×930.

Fig. 13. Drawing of a chain of early red cells, similar to that seen in figure 12, showing no connections with the main angioblastic plexus. Taken from a total mount of the scalp of a human embryo 23 mm. in length (No. 1358*f*, total mount). ×930.


2


5


3

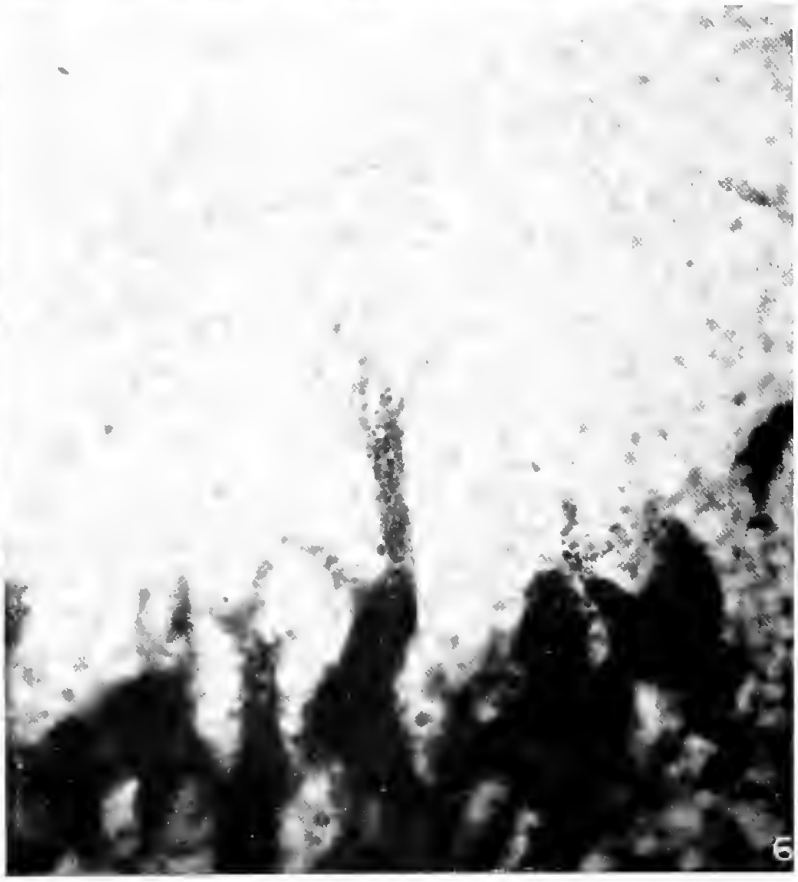
6


4

J. F. Didusch fec.
A. Hoen & Co. Lith.

CONTRIBUTIONS TO EMBRYOLOGY

VOLUME XIV, NOS. 65–71.

1902

PUBLISHED BY THE CARNEGIE INSTITUTION OF WASHINGTON
WASHINGTON, 1922