



## Marine Biological Laboratory

Received Sept. 22, 1950

Accession No. 64003

Given By The Blakiston Co.  
Philadelphia, Pa.

Place, \_\_\_\_\_

MBL/WHOI



0 0301 0017178 1







# THE CHORDATES





# THE CHORDATES

BY

HERBERT W. RAND, Ph.D.

Associate Professor of Zoology, Emeritus  
Harvard University

*Illustrated*



THE BLAKISTON COMPANY

*Philadelphia and Toronto*

1950

COPYRIGHT, 1950, BY THE BLAKISTON COMPANY

---

*This book is fully protected by copyright, and no part of it, with the exception of short quotations for review, may be reproduced without the written consent of the publisher*

PRINTED IN THE UNITED STATES OF AMERICA  
BY THE MAPLE PRESS COMPANY, YORK, PA.



# Preface

---

The chordates are a vast assemblage of animals so diversified as to include sea-squirts, sharks, toads, snakes, larks, bats, whales, mice, and men. Any one animal confronts us with many aspects—structural, functional, ecologic, geographic, geologic, historic (individual life-history, racial history), behavioristic, psychic, philosophic. Chordates differ as to the nature and degree of diversity of their activities. To hop, sit, eat, and reproduce epitomizes the life of a toad. To these elemental items of living, the human chordate adds many and much—clothing, cities, skyscrapers, motor mechanisms, telecommunication, medication. He writes poetry, composes symphonies, wages world wars, splits atoms, and fills thousands of libraries with millions of books dealing with everything, but mostly with himself. An adequate treatise on the chordates must include all of this. It is at once evident that, as a title, "The Chordates" has an inclusiveness ridiculously out of proportion to the size of this book. The attempt to devise a title which should fairly indicate the scope of the book resulted in a plethora of words which would have overtaxed a title page and probably would have condemned the book as one containing a little of everything and not much of anything.

Writing a book is inexcusable unless the product can claim some desirable feature not possessed by other books. What does this book try to do?

For an unmentionable number of years the author conducted a college course in comparative anatomy of backboned animals. It was done in the conventional way—lectures, laboratory work, and collateral reading. During the earlier years all the formal work was done in one room which combined lecture room, laboratory, and library. An ample case contained books whose titles covered in a broad way the biologic field of the course. The books were at all times freely accessible to the students.

As years passed, the annual enrollment in the course increased to a maximum of 10 times that of the first few years. Lectures were given in a hall remote from the laboratories. Students could obtain books only by going to libraries more or less distant from the laboratories, and other changes, of intangible nature, occurred. In earlier years the laboratory work was announced as requiring at least six hours a week, and it was generally understood that it might consume indefinitely more according to the interest and efficiency of the individual student. In later years the laboratory work was necessarily restricted to six hours a week and there was little opportunity for work outside the assigned hours. An earlier sense of freedom and leisure to work thoughtfully was insidiously superseded by a sense of crowding, pressure, and haste. As numbers increased, the conducting of the course inevitably became more formal and mechanized. So much "ground" to be "covered," so many facts to be "learned"—scant time was left for thinking. It was the same everywhere—more students, relatively fewer teachers, schools forced to adopt factory methods calculated to achieve "mass production."

The point at which the foregoing historical sketch is aimed is that the indication of appropriate "collateral reading" became increasingly a problem. It was evident that the student of the later years was not reading much and could not be expected to. It was therefore important to recommend a few books so selected as to cover the general field as broadly as possible. This necessity led to the search for those few books which, collectively, would enable the student to obtain a reasonably adequate knowledge and appreciation of the field. The search for these books tended to emphasize the shortcomings (for the purpose in hand) of the individual book. There were, and are, books which give excellent descriptions of structure but with little or no reference to function; books which adequately cover comparative anatomy but with quite inadequate treatment of classification—i.e., books which compare organs but do not compare animals; books which describe types (a representative animal of each large group) but do not bring the corresponding structures of the several types into close comparison; books which talk about homologous organs but do not give the reader any information as to what homology is and what significance it has; few books on comparative anatomy which offer even a brief survey of the history of chordates.

In any treatment of comparative anatomy there are two especially puzzling problems. One is presented by the necessity of giving some account of embryonic development. It is difficult to give a clear description of the embryonic stages of an organ to a reader who has little or no knowledge of the nature and structure of the organ in the adult. But

adult anatomy cannot be fully intelligible without knowledge of developmental processes. Should a chapter (or chapters) on embryology precede or follow the description of adult structure? In either order, more or less of the cart is put before the horse. The second problem is offered by the classification of animals. Classification is based chiefly on comparative anatomy and embryology. Therefore logically the classification should follow the descriptive chapters. But anatomic comparisons necessitate mention of numerous animals, many of which are quite unknown to most readers. Identification of these animals to the reader is greatly facilitated if the anatomic description is preceded by a classification in which groups are defined and representative animals are mentioned. Again, neither arrangement puts cart and horse in good working order.

Mere knowledge of facts has little value. It acquires value only when it is accompanied by such understanding as enables its possessor to act to greater advantage than he otherwise could; or when appreciation and interpretation of facts broaden the intellectual horizon and give the individual the satisfaction of feeling that his world is expanding. Appropriate *knowledge* of anatomy enables a surgeon to perform a successful appendectomy. But he who possesses *appreciation* of the significance of the facts of comparative morphology and paleontology finds himself standing on a crest of Time whence he may look backward down a vista of hundreds of millions of years and behold a vast procession of successively dominant groups of animals. In this succession he discovers certain trends which *appear* as if progressively directed. Knowing that present is but a shifting point in a continuity which is always past and future, and recognizing these trends in the past, he may then turn his eyes toward the future and gain some preview, admittedly dim and misty, of the destiny of his own race. If he is intelligent, as he claims to be, this preview should be a determining factor in his present behavior.

The foregoing paragraphs of this preface set forth the considerations which led the author of "The Chordates" to undertake a book which, to its content of anatomic fact, should add chapters (necessarily brief) giving the reader some knowledge of the history of anatomic science, the ideas and motives which have directed its progress through successive centuries, the theories and principles whereby it has worked, and, above all, an appreciation of its vital human import. The inclusion of such chapters in a book of necessarily limited size must be at the expense of its content of anatomic fact. This is to be justified on the ground that an appreciative knowledge of the more basic facts of comparative morphology is of greater value (except for some technical purposes) than a more detailed factual knowledge without the apprecia-

tion. Biology is something more than an "interesting science" whose devotees collect pretty butterflies, prepare nice white skeletons, and record songs of birds. Our present total knowledge of the chordates has a life-or-death significance for the human chordate at this present moment in the history of his race.

The plan of the book is calculated to reduce the difficulties about placing the treatments of embryology and classification in logical relation to descriptive comparative anatomy. **Part I** describes the **basic structure** of vertebrates—i.e., the structural features which are common to all vertebrates. There is little comparative anatomy in this part. The several chapters on basic structure supply ample background for the immediately following chapters on embryology and histology. **Part II** comprises the historical and theoretic chapters. The chapter on "Aim; and Method of Comparative Anatomy" is placed here so that the reader may have clearly in mind the significance of homology and the meaning of such terms as "convergence," "parallelism," etc., before passing on to the comparative description in **Part III**. This part includes not merely vertebrates but all chordates, and its comparative anatomy is supplemented, so far as need be, by comparative embryology; hence the title "Comparative Morphology of Chordates." The arrangement is by Classes. In the treatment of each Class the basic structure is assumed and the description confines itself to those specialized features which, superimposed upon the basic structure, make the animal a fish, amphibian, reptile, bird, or mammal. The animals of each Class are compared to those of the preceding (in phylogenetic sense) Classes. Hence the comparative treatment expands from a minimum in the chapter on fishes and amphibians to a maximum in the chapters on mammals. The detailed classification succeeds the descriptive and comparative account of the group.

The chapters on "Reproduction" and "Histology" and the section on endocrinal organs (in Chapter 6) have been taken, with considerable revision, from the corresponding parts of "Comparative Anatomy" by Neal and Rand. Numerous illustrations have been taken from the books ("Comparative Anatomy" and "Chordate Anatomy") by Neal and Rand. Many of them, conceived and executed by Professor Neal, pay eloquent tribute to his rare combination of competence as an anatomist and skill as an artist.

Mention of all persons to whom the author feels under obligation for assistance and encouragement in the preparation of the book would unduly extend the length of this preface. His acknowledgments must be restricted to the following few whose help has been of a quite specific or tangible sort: to Alfred S. Romer, Director of the Museum of Comparative Zoology at Harvard University, who, in response to a request

for permission to photograph specimens in the exhibition rooms of the Museum, literally handed over "the keys to the city"; to Henry B. Bigelow, Curator of Oceanography, Arthur Loveridge, Curator of Reptiles and Amphibians, and James L. Peters, Curator of Birds, all in the Museum of Comparative Zoology, for much helpful information in their several fields of zoology (but they are not to be held responsible for the author's systems of classification nor for his naming of genera and species); to Frank White, photographer for the Biological Laboratories of Harvard University, for expert photographic work, especially the photographing of numerous illustrations from very old books; to James K. Ufford, Director of Photography for the Fogg Museum of Art at Harvard University, for his skill and patience in the photographing of museum specimens under extraordinary difficulties due to cramped spaces and unfavorable lighting; to Maxwell L. French, Staff Assistant of the Museum of Comparative Zoology, for his enthusiastic and efficient aid in making museum specimens accessible to the camera; to John H. Neal and William L. Nutting for important aid in the making of drawings for new illustrations.

Appreciation is due in large measure to officials of The Blakiston Company, especially James B. Lackey, Science Editor and William B. McNett, Art Director, for their generous coöperation, unflinching courtesy and patience, and to their staff assistants for highly efficient performance on all phases of the task of publication.

From my wife I have received constant assistance, including the reading of portions of the text with special reference to pertinency of statements and to points of literary form.

H.W.R.

*Cambridge, Mass.,  
June 1950*





# Contents

---

Preface. . . . .	v
Prologue: Why Study Vertebrates? . . . . .	1
<i>Part I. BASIC STRUCTURE OF VERTEBRATES</i>	
Chapter 1. General Features . . . . .	11
2. The Inner (Alimentary) Tube and Its Respiratory Derivatives. . . . .	25
3. Circulatory System . . . . .	63
4. Excretory and Reproductive Systems . . . . .	79
5. Motor System—Muscles and Skeleton . . . . .	89
6. Integrative Systems . . . . .	139
7. Reproduction. . . . .	231
8. Histology. . . . .	301
<i>Part II. COMPARATIVE ANATOMY—ITS HISTORY, AIM, AND METHOD</i>	
9. History of Comparative Anatomy. . . . .	333
10. Aim and Method of Comparative Anatomy. . . . .	355
<i>Part III. COMPARATIVE MORPHOLOGY OF CHORDATES</i>	
11. Classification of Chordates: Protochordata. . . . .	389
12. Ichthyopsida. . . . .	413
13. Sauropsida: Class Reptilia . . . . .	463
14. Sauropsida: Class Aves. . . . .	503
15. Class Mammalia . . . . .	559
16. Mammalia: Skin, Muscles, Skeleton. . . . .	573
17. Mammalia: Visceral Systems—Respiratory, Circula- tory, Alimentary, Urinogenital . . . . .	609
18. Mammalia: Nervous System . . . . .	667
19. Mammalia: Classification. . . . .	725
Epilogue: What Comes of Studying Vertebrates. . . . .	785
Index . . . . .	821



# Prologue: Why Study Vertebrates?



On the south rim of the Grand Canyon of Arizona stands a hotel at which it used to be the custom, and perhaps still is, to entertain the guests with exhibitions of native dances performed in the hotel's courtyard by a group of Hopi Indians. Most spectacular was the "eagle dance." An enormous artificial wing built up of long feathers was attached to each arm of a dancer. The several dancers went through a series of antics, with appropriate flapping of the wings, doing their utmost to simulate the behavior of eagles. In a dramatic dance of South African Bushmen, one of two men impersonates a baboon, the other a dog. The animals fight. The two dancers,



FIG. 1. An eagle dance near Santa Fe, New Mexico. (Courtesy, American Museum of Natural History, New York.)




FIG. 2. Baboon. (Courtesy, Museum of Comparative Zoology, Harvard University.)

going down "on all fours," make nice distinctions between the attitudes and movements characteristic of the dog and those of the ape, and even imitate their facial expressions and the various howls, growls, and yelps emitted by the fighting animals. Bushmen girls, prone on the ground and dragging themselves forward by awkward movements of arms and legs, imitate crawling tortoises. Mimiery of quadruped animals and of birds is a common feature of ceremonial dances of primitive races in all parts of the world.

A child accepts the household dog or cat as a near equivalent of a human companion and playmate, perhaps even trying to attire a kitten in a doll's dress. The Indian is aware that the bird's wing somehow corresponds to a man's arm. The Bushman readily converts himself into a quadruped. The child dressing the kitten assumes that the sleeves belong on the forelegs. Neither the Hopi nor the Bushman nor the child has ever studied comparative anatomy in college. But they are, by nature, comparative anatomists. Their recognition of anatomic similarities between man and such quadrupeds as horses, dogs, and cats is intuitive. Even frogs and fishes have some obvious equivalents of human features.

To begin with, these various creatures are all alive. Trees, also, are alive but their peculiar habits of living set them far apart from man. It

is difficult to frame a satisfactory definition of "alive" but it is easy in practice to distinguish living things from those which are not alive. At least, it is easy until we come to the ultramicroscopic realm of such things as filtrable viruses and "giant molecules" which cannot be brought within direct range of the several senses which serve for our intuitive recognition of life in a dog, robin, codfish, earthworm, ameba, or fellow man.

This thing of being "alive" is accompanied by peculiarities of structure and behavior which are essentially similar in all animals. Our present considerable knowledge of these vital mechanisms makes it so evident that man and all animals are things of the same general nature as to require that the old phrase "man and animals" be amended to read "man and other animals." Whether man, in the conscious and mental aspect of his life, possesses something which other, or some other, animals lack, or whether this part of his life is merely a more elaborate development of potentialities inherent in perhaps all living things, is an important question. Whatever the answer, man is at least an animal.

Man does not stand apart from other animals. He is associated with them in many important ways. The association may be helpful, essential, harmful, or disastrous to him. In some of these associations, therefore, he is an unwilling member. In our relations to insect pests, internal and external parasites, and beasts of prey, either the other animal is the aggressor or else the association is forced upon us by some peculiar set of biologic circumstances. But man takes the initiative in associating with himself certain animals such as the dog, cat, horse, cattle, sheep, and some birds. Some of these "domesticated" animals provide him with important food. Others serve him for transportation or in connection with hunting. But his association with dogs, cats, and horses may contain something even approaching the friendship which may exist between man and man. We *feel* a certain bond of sympathy with these animals.

Some animals resemble man more than do others. The central or axial part of the human skeleton is a series of bones (vertebrae) movably jointed together and extending lengthwise of the body (Fig. 3). The series is commonly called the "backbone," otherwise the vertebral column. The dog, cat, and horse have backbones similar to man's—they are vertebrates. If land crabs grew to be as large as dogs, and long-haired caterpillars as large as Persian cats, it can hardly be imagined that such backboneless animals would become our household pets and companions. We usually lack a cordial fellow-feeling for invertebrates. This is not because of their lack of backbone but because they are so radically unlike ourselves in other respects, even to the

point of being repulsive to us. We accept the dog and cat because we tacitly acknowledge something in their nature common to our own. This something, however, is present in varying degree in backboneed animals. The goldfish, frog, turtle, and snake have backbones but these

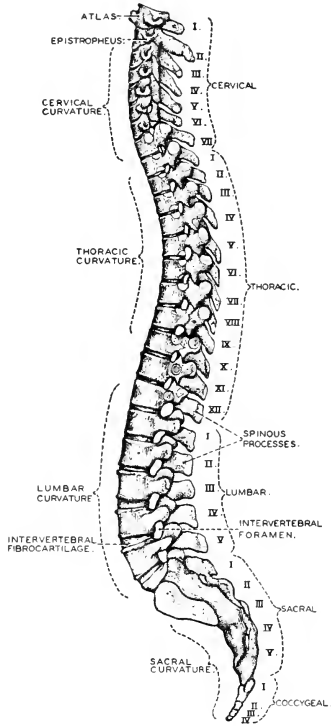


FIG. 3. The human vertebral column viewed from the left side. (After Sobotta. Courtesy, Neal and Rand: "Chordate Anatomy," Philadelphia, The Blakiston Company.)

animals are far less satisfactory as pets or companions. They are less human. Birds, also backboneed, interest us greatly but, as a rule, they are inclined to hold themselves aloof from us. It is evident that even some *vertebrate* animals resemble man much more closely than do others.

The fact that we enjoy eating some of our fellow vertebrates is not to be dwelt upon too intently lest our appetite for meat be impaired. However, our common preference for beef and lamb is certainly **not** because cattle and sheep anatomically resemble man. Quite the reverse. We, in general, are not cannibals. If monkeys or the larger apes were easily available in large numbers, our aversion to eating our own kind would doubtless be generously extended to include these animals, regardless of the particular view which we may hold concerning the origin of man, and we would still prefer our beef and mutton. Some of us have an aversion for "red meat" but may eat fish and lobster. If we *must* have animal food, our preference tends toward that which is devoid of human connotation—but with many inconsistencies, for numerous quite unhuman creatures such as snakes and insects seem to be inherently objectionable to us as food.

In the familiar facts set forth above may be found the reason why the study of biology requires early acquaintance with comparative anatomy, first of animals in general and then of vertebrates in particular. Appreciation of the facts of comparative anatomy is significant in relation to the structure of the human body, the functions of its parts, and the origin of the individual human body and the human race.

Science is the outgrowth of man's curiosity concerning the world about him. Living things especially stimulate his curiosity. The part of the world most immediately about him—that is, about his conscious *self*—is his own body. Scientific investigation, initiated by curiosity, usually leads to knowledge which may be applied to improving the conditions of human life. It is of advantage to a man that he understand the construction of such mechanisms as his watch or his automobile. He may so derive better service from them. A knowledge of his own bodily mechanism enables him to use it to his greater profit. Similarities between the structure of the human body and that of other vertebrates are far-reaching; physiologic similarities are equally so. Experimentation on animals other than man has proved of incalculable value in the relief and eradication of human disease. Therefore a knowledge of the comparative anatomy of vertebrates is helpful and broadening as part of the preparation for the study of medicine.

In theoretic biology, data derived from the study of vertebrates have played a particularly important part. Vertebrates, being the larger, more obvious, and easily obtainable animals in man's environment, were among the first to become objects of his active curiosity. They are especially favorable for biologic investigation, and their similarity to man gives added incentive to the study of them. So it has come about that the vertebrates are more thoroughly known than any other of the larger groups of animals. Certain principles or "laws" of biology and

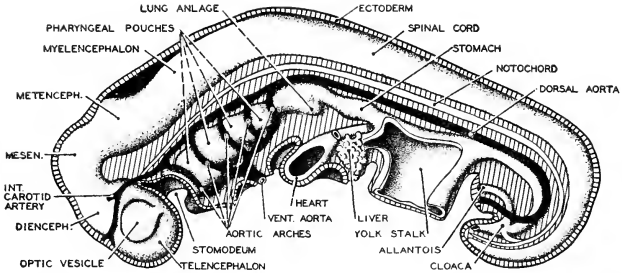


FIG. 4. A diagram of a 4.2 mm. human embryo showing five aortic arches. Why does the human embryo have six aortic arches of which only three persist in the adult, unless man's ancestors had six functional arches? (After His. Courtesy, Neal and Rand: "Chordate Anatomy," Philadelphia, The Blakiston Company.)

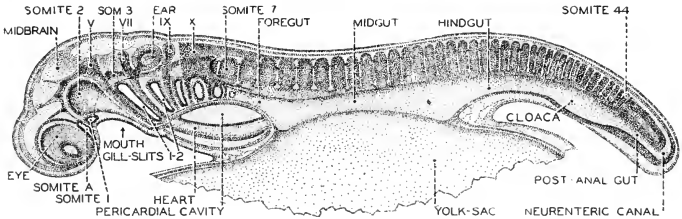


FIG. 5. A 7 mm. *Squalus* embryo viewed as a cleared specimen from the left side. The yolk-sac has been mostly removed. Two gill-chambers are open. Developing cranial nerves are indicated by Roman numerals. (Courtesy, Neal and Rand: "Chordate Anatomy," Philadelphia, The Blakiston Company.)

theories which have exerted powerful influence on human thought have been derived largely from the relative fullness of our knowledge of the vertebrates.

Facts of vertebrate comparative anatomy provided important building material for the foundations of the theory of evolution as it began to acquire definite form in the latter part of the eighteenth century. Later the theory was strengthened and elaborated by the results of comparative study of the embryonic development of vertebrates, as illustrated by the following instance. At an early stage in the development of the embryo of a reptile, bird, or mammal (Fig. 4), the anterior region of the digestive tube produces paired lateral pouches similar to those which, in a fish embryo (Fig. 5), become gill-chambers. Blood-vessels and other structures in this region of the embryo of a land vertebrate are distinctly fishlike in their anatomic relations. In later development this region undergoes a profound metamorphosis and loses



its similarity to the corresponding region of a fish. From such facts as these was derived the "law of recapitulation" which, assuming evolution, asserts that "ontogeny repeats phylogeny"—that is, an early embryo produces structures which are inherited from successive remote ancestors, even though these structures are destined to be, in later development of the embryo, either obliterated or transformed. The present-day student of biology finds vertebrate anatomy particularly rich in opportunity for making direct acquaintance with well-established facts illustrating important principles and theories of the science.



Part I

BASIC STRUCTURE OF VERTEBRATES



# General Features

---

1

**What Is a Vertebrate?** "Vertebrates are backboned animals"—a definition often given, but inexact. In laboratory courses on vertebrate comparative anatomy, the animal usually studied as an example of a vertebrate of the fish type is a small shark known as the "dogfish." This fish has no backbone. It has no bone whatever in its internal skeleton. But it does possess a dorsal axial series of structures, movably articulated, each of them in its form and relations to other parts closely resembling a bony vertebra. Their material, however, is **cartilage**, much softer than bone and very different from bone in internal constitution and mode of development. The shark has a vertebral column, but it is cartilaginous.

To define vertebrates as animals having the vertebral column would seem necessarily to be correct. The fact is, however, that most zoologic classifications include within the group called "vertebrates" certain animals which, in a strict sense, do not have a vertebral column: that is, if by "column" is meant a longitudinal series of definitely formed vertebrae articulated to one another. In the "round-mouthed" eels (cyclostomes), represented by the lamprey (Fig. 317) and a smaller eel, the hagfish, the axial skeleton is a cylindric rod or cord, the **notochord**, consisting of a somewhat gelatinous internal substance enclosed by a sheath of tough fibrous tissue (Fig. 101). The notochord itself is quite unsegmented. Its fibrous sheath extends upward on either side to enclose the dorsal nerve cord (spinal cord). In the neural arch thus formed are embedded minute rods or plates of cartilage lying at either side of the spinal cord (Fig. 318). These little cartilages evidently correspond to merely the dorsal parts of vertebrae but they are, at most, very small rudiments of vertebrae and do not articulate together to form a "column." Yet cyclostomes are called vertebrates. Some of the older classifications include under vertebrates the little externally fish-like *Amphioxus* (Fig. 312), which has a well-developed notochord but not the slightest rudiment or trace of a vertebral column.

The truth is that the vertebral column is only one of several features which identify a vertebrate, and some of the other features are quite as characteristic as a vertebral column. Even if an animal lacks a vertebral column, its possession of the other characteristics in a strongly marked way constitutes so close a similarity to animals that are literally "vertebrate" as to justify including it in the group with them. The question is, then, what are the several salient features which collectively make a vertebrate?

### SYMMETRY

The vertebrate is **bilaterally symmetric**—that is, assuming the animal to be standing on a horizontal substratum, a median longitudinal vertical plane divides the animal into right and left equivalent parts each of which is as if it were the mirror image of the other. In describing the form and position of parts of the animal, certain terms are used to designate planes of orientation and linear directions. These terms must be defined because confusion results from use of the same term in reference to a quadruped, the long axis of whose body is ordinarily in a horizontal position, and to a biped, which assumes an erect attitude. The quadruped walks or runs head foremost. In man that surface of the body which is forward during locomotion corresponds to the surface which is beneath in the quadruped.

The muscles which effect the major movements of the body are attached to the vertebral column. Therefore the vertebral column is the **mechanical axis** of the body. In fishes and tailed amphibians, this axis lies in nearly a straight line. In land vertebrates it is more or less curved in the vertical plane, especially in the region of head and neck (Fig. 3). In the definitions below, the axis is assumed to extend in a straight line and in a horizontal direction.

The more important terms used to designate position in the body are as follows:

### PLANES

**Sagittal:** the median longitudinal vertical plane; the basic plane of bilateral symmetry. **Parasagittal** is a convenient name for any plane not median, but parallel to the sagittal plane.

**Frontal:** any plane cutting the animal parallel to the vertebral axis and perpendicular to the sagittal plane. The term refers primarily to the "front" surface of the human body.

**Transverse:** any plane perpendicular to the axis; a "cross section" of the body.

### DIRECTIONS

**Anterior** and **posterior:** primarily **direction of locomotion**. In swimming vertebrates and in quadrupeds, therefore, anterior is

toward the head, posterior toward the tail. In man anterior is toward the "front" surface of the body, posterior is toward the back. Herein lies confusion which may be avoided by using "**cephalic**" to denote direction toward the head and "**caudal**" to denote that toward the tail, regardless of the animal's locomotor habits. **Cephalad** and **caudad** are adverbial forms replacing, respectively, "anteriorly" and "posteriorly." The old terms "anterior" and "posterior" are still commonly used, and safely so when it is clear that the description refers to animals other than man.

**Dorsal** and **ventral**: upward and downward, respectively, when the animal's axis is in the horizontal position.

**Right** and **left**: as in man, opposite directions perpendicular to the sagittal plane.

**Proximal** and **distal**: direction toward any axis, base, or center is called "proximal"; the reverse direction—that is, toward the surface, periphery, or tip of any part—is called "distal."

#### DEPARTURES FROM BILATERAL SYMMETRY

Perfect symmetry may be nearly or quite realized in the early embryo of a vertebrate. Most organs are either **median** or **paired**. A median organ arises exactly in the median plane of the embryo. Paired organs appear symmetrically on either side of that plane. However, in later stages of development, the primary symmetry of organs is more or less modified or, in some of them, may be quite lost.

The **digestive tube** is at first median. Later the region of it lying in the body-cavity grows lengthwise faster than the body does. It accordingly becomes more or less bent and coiled (Fig. 6). In the adult the stomach may lie more nearly transversely than lengthwise of the body. The intestine may be many times longer than the cavity in which it lies. The human intestine is about 30 feet long. The abdominal portion of the tube in the adult is usually quite devoid of any symmetry in its arrangement. The **heart**, at an early stage, is a simple median tube. Later it becomes bent (Fig. 7) and more or less twisted, and, in the adults of various mammals, lies somewhat to one side.

The two members of a pair of organs may be unequally developed in the adult. This is true of the female **reproductive organs** of some fishes. In female birds the reproductive organs of the left side only are functional. Those of the right side are rudimentary or lacking. This condition is evidently connected with the fact that the bird's egg is so large relative to the size of the body. The single long, straight, spike-like **tusk of the narwhal** (the "unicorn" of the sea) projects forward from the left side of the upper jaw (Fig. 8). It is an exaggerated upper front (incisor) tooth. The corresponding right tooth is rudimentary.

Asymmetry of paired **blood-vessels**, even the major trunks, is very common. In reptiles the chief artery of the body, the dorsal aorta, is symmetrically connected with the ventral heart by a pair of large arteries forming a so-called "aortic arch." In adult birds only the right vessel of this aortic arch, complete in the embryo, persists; in mammals only the left vessel persists (Fig. 71). The very small arteries and veins are quite devoid of symmetry in their arrangement.

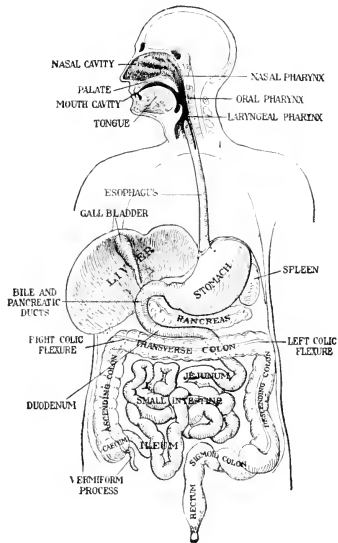


FIG. 6. Diagram of the alimentary canal. (Courtesy, Jackson: "Morris' Human Anatomy," Philadelphia, The Blakiston Company.)

The right and left lobes of the **liver** and of the **lungs** are commonly asymmetric in number, size, form, and position. The right and left **kidneys** in mammals may not be exactly opposite each other. There is more or less **functional modification** of symmetry. In a decidedly right-handed person, the right arm and hand are more strongly developed than the left.

One of the most striking cases of modified symmetry is that of the "**flatfishes**" such as the flounder, sole, and halibut. These fishes habitually rest at the bottom of the water, lying flat on one side; in some species on the right side, in others on the left. The external form of the



very young fish is perfectly symmetric but, as growth proceeds, the entire head-region undergoes a twisting or rotation, the result of which is that, in the adult fish, the eye, gills, and other organs of that side on which the fish lies are shifted around to the exposed upper surface of the fish (Fig. 9). Thus, if the fish is one which lies on the left side, the left eye appears in the same flat upper surface with the right side of the

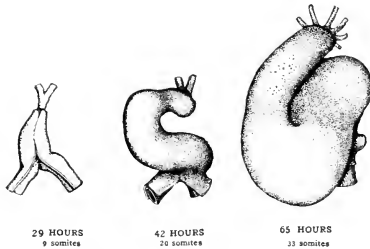


FIG. 7. Ventral views of the heart of chick embryos at successive stages to show its changes of shape and its regional differentiation. (Courtesy, Patten: "Early Embryology of the Chick," Philadelphia, The Blakiston Company.)

body. This distortion of the head is clearly an adaptation to the peculiar habit of the fish and obviates impairment of the functions of important organs which otherwise would be pressed down against the sea bottom.

Comparing the several systems of organs, it is evident that the primary symmetry of the early embryo is retained in the motor mechanism of the body (that is, the body-muscles), the corresponding parts of the nervous system, and the skeleton. It is of advantage to the animal that its capacity for bodily activity should be equally developed on the two sides of the body. But the primary symmetry may be modified or lost by organs in which symmetry has no functional importance. So long as an organ receives an adequate blood-supply, it does not matter whether the blood-vessels serving that organ are symmetrically arranged or not. So long as the animal obtains enough oxygen, it does not matter as to the shape, size, and arrangement of the several lobes of the lungs. Glandular organs such as the liver and pancreas may be extremely irregular in form. The liver, as it develops, grows back against the digestive tube and occupies such space as is left available to it by the unsymmetrically placed stomach and intestine.

Bilateral symmetry, therefore, is a feature of the "plan" of a vertebrate as laid out in the lines of the early embryo. But in the course of



FIG. 8. Narwhal skull. Bone has been removed to expose the root of the tusk and the rudimentary tusk of the other side. (Courtesy, Flower and Lydekker: "Introduction to the Study of Mammals." London, A. & C. Black, Ltd.)

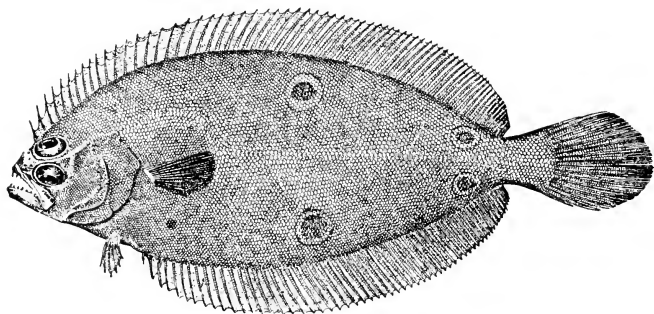


FIG. 9. Flounder, *Paralichthys oblongus* (Mitchill). (Courtesy, Jordan and Evermann: "Fishes of North and Middle America," Washington, The Smithsonian Institution.)

the development of the adult there occur numerous and various deviations from this plan, either where symmetry is not necessary for function, or where departure from symmetry favors function, as in the reproductive organs of female birds.

#### HEAD, NECK, TRUNK, TAIL

In the external form of a vertebrate, these four regions are more or less definitely demarked. A fish has no obvious **neck**. But the gills and certain glands (thyroid and thymus), situated just at the rear of the **head**, mark a region corresponding to the anterior region of the neck of a mammal. In contrast to fishes are the swan, ostrich, and giraffe. The elongated flexible muscular neck of birds and mammals gives the advantage of free mobility of the head. A fish, to look behind, must turn the whole body.

The **trunk** is hollow, and its chief cavity (**body-cavity** or **coelom**) contains the various bulky viscera of the animal (Fig. 10). The coelom does not extend into the neck or tail of the adult animal.

The **tail** is the solid muscular extension of the animal behind the hollow trunk. In most fishes the trunk tapers gradually into the nar-

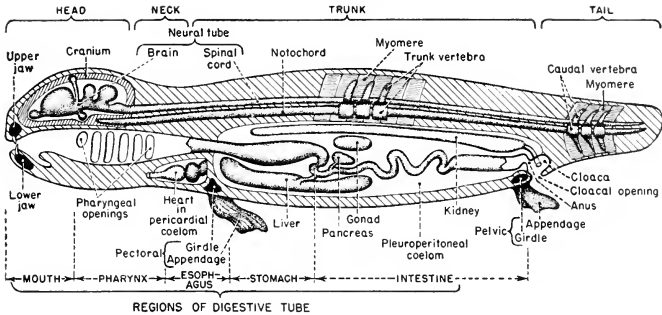


FIG. 10. Diagrammatic sagittal section of a vertebrate.

power tail, which is massive and powerfully muscular, and serves as the essential locomotor organ. In mammals the tail is relatively slender and weak. It serves various minor functions, including even expression of emotion in dogs and cats. From the human point of view, it seems more ornamental than useful. It is vestigial or lacking in adult frogs and toads, modern birds, some rodents and bats, and some primates (the group including man, apes, and monkeys).

#### LOCOMOTOR APPENDAGES

Among invertebrates, locomotor appendages are highly variable in number. In the one phylum, Arthropoda, are decapod crustaceans, hexapod insects, and centipedes. Modern vertebrates have never more than **two pairs**. One pair, **pectoral**, is at the anterior extremity of the trunk; the posterior pair, **pelvic**, is at the posterior extremity of the trunk. The Paleozoic somewhat sharklike **Acanthodii** had several (up to five) pairs of relatively small fins between the pectorals and the pelvics (Fig. 320). The pectoral appendages may be fins, legs, arms, or wings. The pelvic pair may be fins or legs. Either pair may be vestigial or lacking—in whales, sea cows, and some bony fishes, the pelvic pair; in birds of the ostrich sort, the pectoral pair; in snakes, "legless lizards," and certain amphibians (caecilians), both pairs. The "round-mouthed" eels (cyclostomes) have no paired appendages and no vestiges of them.

Most aquatic vertebrates have, in addition to paired fins, **median fins** which are functional in connection with locomotion. They are highly variable in number and position and are in no way represented in land vertebrates.

#### INTEGUMENT

Most invertebrates have a skin consisting of a cellular layer, usually only one cell in thickness, which secretes a substance—chitinous as in

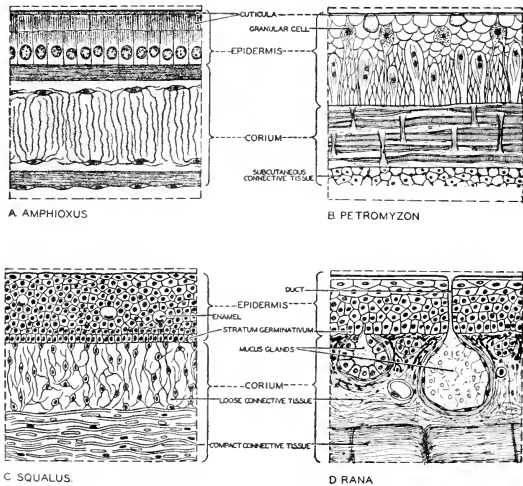


FIG. 11. Sections of the skin of four chordates, *Amphioxus*, *Petromyzon*, *Squalus*, and *Rana*, showing the fundamental differentiation of the skin into dermis (corium) and epidermis. (Mainly after Plate and Schimkewitsch. Courtesy, Neal and Rand: "Chordate Anatomy," Philadelphia, The Blakiston Company.)

arthropods, or calcareous as in mollusks—which forms a tough or hard external protective layer. Vertebrate skin is much more elaborate. It consists of two layers (Fig. 11). The outer one, the **epidermis**, is a cellular layer several or many cells in thickness. The deeper epidermal cells are actively alive, but in most vertebrates (fishes being exceptional) the more superficial cells become more or less completely filled with an inert nitrogenous substance, **keratin**, which accumulates at the expense of the protoplasm. Thus is formed the characteristic horny layer (**stratum corneum**), whose cells ultimately become quite dead horny particles which are so agglutinated together as to form a hard, tough, and somewhat elastic external protective layer.

The deeper layer of the skin, the **dermis** or **corium** (Fig. 11), consists for the most part of a fibrous tissue. The dermal cells which produce the fibers constitute a very small proportion of the bulk of the layer. Between the dermis and the underlying muscle or bone is a fibrous **subcutaneous connective tissue**, less compact and more elastic than the dermis.

**Blood-vessels** rarely occur in the epidermis but are abundantly present in the dermis, which is therefore the nutritive layer. The larger vessels supplying the skin lie in the subcutaneous connective tissue.

Cells containing pigment (**chromatophores**: Fig. 263) may be present in either the epidermis or dermis, but are usually more numerous and more highly specialized in the dermis (Fig. 12). They may occur also in the subcutaneous layer. **Fat** may be more or less abundantly deposited in the subcutaneous layer. **Sensory nervous structures** occur in both the epidermis and the dermis.

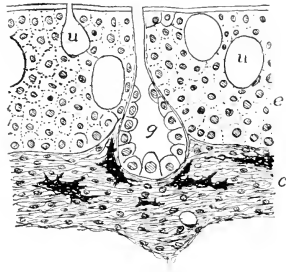


FIG. 12. Skin of lungfish, *Protopterus*: section perpendicular to surface; much enlarged. (c) Dermis (corium); (e) epidermis; (g) multicellular gland; (u) unicellular gland. (Courtesy, Kingsley: "Comparative Anatomy of Vertebrates," Philadelphia, The Blakiston Company.)

The vertebrate skin is prolific in its production of specialized structures, some mechanically protective, some glandular. The **stratum corneum** may be elaborated into **horny scales** (Fig. 15), **feathers**, or **hairs**. At the tips of the digits, it is shaped into pointed **claws**, heavy blunt **hoofs**, or flat **nails** (Fig. 13). It forms the outer sheath of such "**horns**" as those on the heads of cattle and sheep. The plates of "**whalebone**" (**baleen**) hanging from the upper jaw of toothless whales (Fig. 584) consist of horny integumentary substance.

Either the epidermis or cells in the dermis may secrete a **calcareous substance** which constitutes the several types of calcified **scales of fishes**, including the bony scale, entirely dermal in origin, which characterizes the great majority of fishes (Figs. 14, 15). In all vertebrates

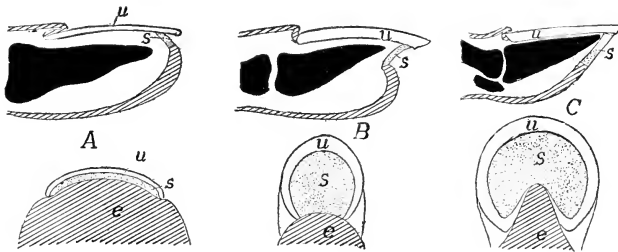


FIG. 13. Diagrams of (A) nail, (B) claw, and (C) hoof. (e) Unmodified epidermis; (u) unguis (outer plate); (s) subunguis (ventral plate). Upper figures, longitudinal dorsoventral sections; bones of digit in solid black. Lower figures, terminal surface of digit. The unguis and subunguis are thickened regions of the stratum corneum. (After Boas. Courtesy, Kingsley: "Comparative Anatomy of Vertebrates," Philadelphia, The Blakiston Company.)

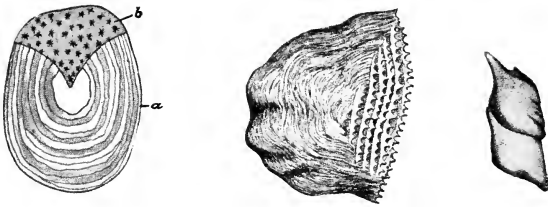


FIG. 14. (Left) Cycloid scale of *Salmo fario*. (a) Anterior portion covered by overlap of preceding scales; (b) free portion covered only by pigmented epidermis. (Center) Ctenoid scale. (Right) Two ganoid scales. (From "Cambridge Natural History," Vol. VII. By permission of The Macmillan Company, publishers.)

except some fishes, plates of **dermal bone** occur, sometimes more or less extensively over the body, as in the alligator, turtle, or armadillo, or at least as part of the skeleton of the head. The cavity of the mouth in all vertebrates is lined by infolded skin whose two layers produce the calcareous teeth.

**Glands** of many sorts are produced by the skin. The essential secretory layer of the gland is always of epidermal origin (Figs. 11, 12). Integumentary glands secrete mucus, oily substances, watery perspiration, milk, and poisonous or odorous substances.

#### CAVITIES

The trunk of the vertebrate is hollow. Its wall, the body-wall (**parietes**), encloses at least two major cavities known collectively as the

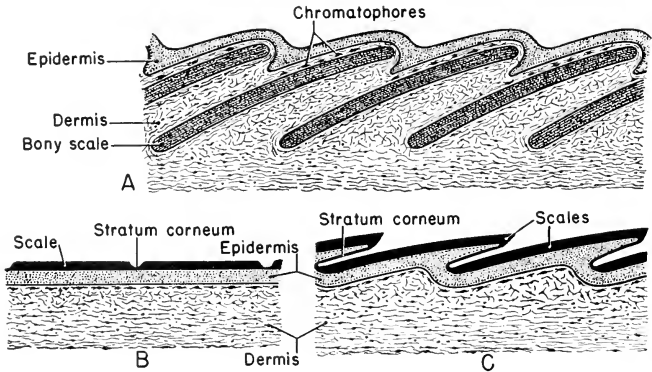


FIG. 15. Bony scales and horny scales. Diagrammatic sections perpendicular to surface of skin. (A) Overlapping bony scales of a fish. (B) Flat horny scales and (C) overlapping horny scales; especially characteristic of reptiles.

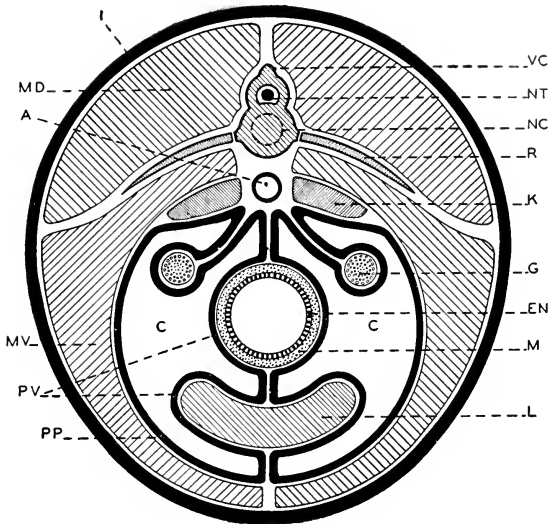


FIG. 16. Diagrammatic transverse section of the body of a vertebrate showing relations of organs to the peritoneum and coelom. (A) Dorsal aorta; (C) coelom; (EN) endodermal epithelium of digestive tube; (G) gonad; (I) integument; (K) kidney; (L) liver; (M) muscle layer of digestive tube; (MD) dorsal muscle of body-wall; (MV) ventral muscle of body-wall; (NC) position of embryonic notochord; (NT) neural tube (spinal cord); (PP) parietal peritoneum; (PV) visceral peritoneum; (R) rib; (VC) vertebral column. (Courtesy, Neal and Rand: "Chordate Anatomy," Philadelphia, The Blakiston Company.)

body-cavity or **coelom** (Figs. 10, 16). The larger of these, the **abdominal cavity**, which occupies by far the greater part of the space within the trunk, contains the stomach, intestine, liver, pancreas, kidneys, reproductive organs, spleen, and other less conspicuous organs. In all lung-breathing vertebrates except mammals, the lungs also lie in this same cavity, which is then appropriately called the **pleuroperitoneal cavity**.

The second and much smaller cavity lies immediately anterior to the abdominal or pleuroperitoneal cavity and in an extremely ventral position. This is the **pericardial cavity**, which contains only one organ, the heart. The thin membranous wall between the two cavities is the **septum transversum**.

In mammals the lungs lie in a pair of cavities, the right and left **pleural cavities**, situated just anterior to the abdominal cavity and on either side of the pericardial cavity (Fig. 17). The **mediastinal**

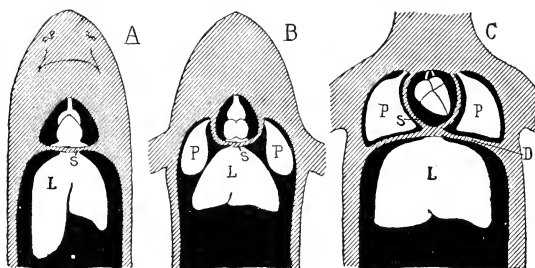


FIG. 17. Diagrams showing the relations of the coelomic cavities (black) in (A) fishes, (B) amphibians, reptiles, and birds, and (C) mammals. (L) Liver; (P) lungs; (S) septum transversum; (D) diaphragm. In B the lungs lie in the peritoneal (or pleuroperitoneal) cavity; in C they occupy special pleural subdivisions of the coelom. (Courtesy, Kingsley: "Comparative Anatomy of Vertebrates," Philadelphia, The Blakiston Company.)

**septum** is the median partition dorsal to the heart and between the two pleural cavities. The thin transverse partition between the abdominal cavity and the three cavities anterior to it is the **diaphragm** which, unlike the septum transversum, is muscular and acts as part of the mechanism of breathing. The space occupied by the three cavities anterior to the diaphragm is called the **thoracic cavity**.

#### PERITONEUM

The abdominal coelomic spaces are lined by a thin membrane, the **peritoneum** (Fig. 16). Along the middorsal line of the abdominal coelom, the peritoneal layers of the right and left sides are deflected from the surface of the body-wall and join to form a single two-layered sheet (**mesentery**) which crosses the coelomic space and attaches to the digestive tube. At the surface of this organ the two layers separate and cover opposite sides of the tube. They may be deflected from the tube and joined to form another mesentery connecting it with some other organ (e.g., the liver) which is similarly invested by the right and left peritoneal sheets. In the case of the liver, the peritoneal layers form a ventral mesentery (**suspensory ligament**) which extends between the liver and the ventral body wall (Fig. 16).

That part of the peritoneum covering the body-wall is called **parietal** or **somatic**; the part covering coelomic surfaces of organs is called **visceral** or **splanchnic**. The peritoneum-like lining of the pericardial cavity is called the **pericardium** and that of a pleural cavity is the **pleura**. The **mediastinal septum** is a double membrane consisting of right and left pleurae.

It is a noteworthy principle of animal structure that muscles,



nerves, blood-vessels, bone, cartilage, and connective tissues are never directly exposed to external space nor to any of the major internal cavities. The substance of the body-wall is mostly muscle. It is covered externally by skin and internally by peritoneum (Fig. 16). The specialized tissues of visceral organs (e.g., the secretory tissues of liver and pancreas, the excretory tissue of the kidney) are not exposed directly to the coelomic space. Everywhere the peritoneum intervenes. The peritoneum is a coelomic "skin." The muscular wall of the heart is covered externally by the **epicardium**, which is continuous with the pericardium of the pericardial cavity. In fact, no organ can be said to lie **in** the coelom except as the peritoneum investing that organ is regarded as a part of the organ. In a strict sense, median abdominal organs lie **between the peritoneal sheets** of the right and left halves of the body.

**Double-Tubular Structure of Trunk.** The trunk region of the vertebrate body may be described as having a double-tubular structure—that is, one tube inside another. The outer tube is the body-wall; the inner is the digestive tube (Fig. 16). The two tubes are similar as to their gross anatomic structure. The outer tube is mainly muscle, covered by skin outside and lined by peritoneum. The greater part of the thickness of the wall of the inner tube is muscle. It is covered by peritoneum outside and the tube is lined by a skinlike layer, the **digestive** (endodermal) **epithelium**, which, however, is much more than a mere protective covering; it is the essential secreting, digesting, and absorbing layer of the digestive tube.



# The Inner (Alimentary) Tube and Its Respiratory Derivatives

2

---

## I. Alimentary System

### ALIMENTARY TUBE

The alimentary or digestive tube extends from an anterior **mouth**, opening ventrally to the eyes and the nasal organs of the head, to a posterior aperture, the **anus**, which, in the great majority of vertebrates, opens into a shallow and usually ventral chamber, the **cloaca** (Fig. 10). Also the kidneys and reproductive organs open into the cloaca, whose contents find exit by the ventral cloacal opening. In bony fishes and adult mammals of modern types, there is no cloaca and the anus and urinogenital apertures are at the external surface.

The alimentary tube is differentiated into the following regions (Figs. 18, 19): (1) **mouth-cavity**, in the head; (2) **pharynx**, immediately behind the mouth, a respiratory region of the tube, concerned with the development of gills and lungs; (3) **esophagus**, extending through the neck region and, in mammals, also the thoracic region, and conveying food into the (4) **stomach** lying in the anterior portion of the abdominal cavity; (5) the **pylorus**, a strong muscular constriction or **sphincter** capable of closing the passage between the stomach and the (6) **intestine**, which extends from the pylorus to the anus. The intestine is differentiated into regions varying in number and nature. There is usually a definite demarcation between an anterior, longer but narrower, "**small**" intestine and a posterior, shorter but wider, "**large**" intestine whose posterior region, the **rectum**, serves merely for temporary storage of fecal waste. The terms "small" and "large" are derived from human anatomy and are not always literally appropriate as applied to corresponding regions of intestines of other animals.

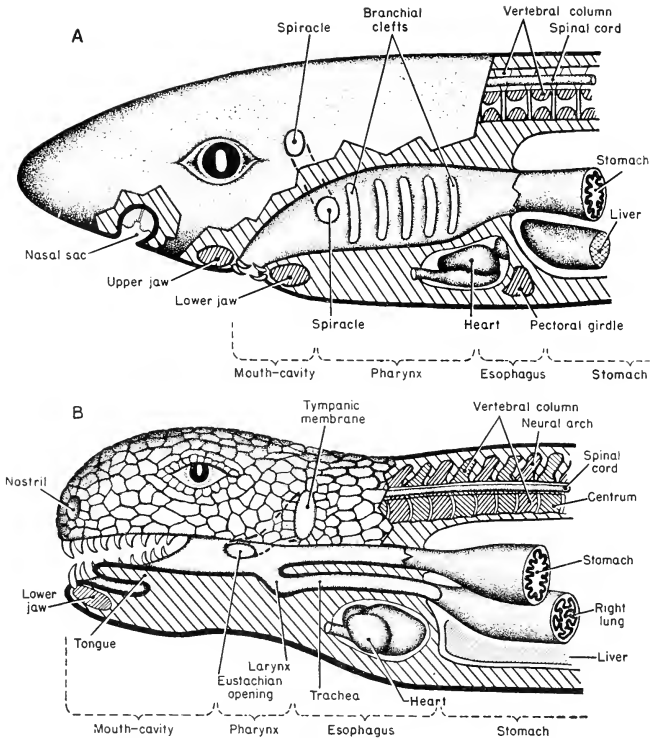


FIG. 18. Divisions of digestive tube. (A) Shark. (B) Reptile. Regions sectioned are cut in sagittal plane, except the nasal sac which, being one of a pair of lateral organs, is shown in parasagittal section.

Throughout the greater portion of the length of the digestive tube, the muscular part of its wall consists of an external layer of **longitudinal muscle fibers** and an internal layer of **circular fibers** encircling the tube (Fig. 20). The fibers are ordinarily of the simpler "smooth" or nonstriated sort, but in the more anterior part of the esophagus the layers may consist of the more complex striated fibers (see p. 312). **Sphincters**, such as the pylorus, are thickened rings of the circular layer.

The extent of internal surface available for the secretory and absorptive activities of the tube is increased in various ways. The abdominal part of the tube is usually much elongated, even to the extent

of being several or many times longer than the abdominal cavity—a condition necessitating much bending and coiling of the tube. The in-

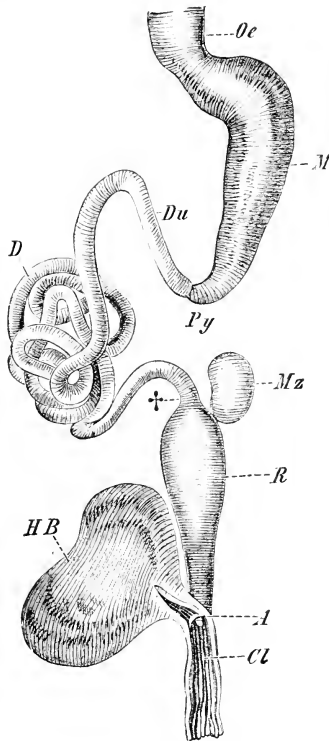


FIG. 19. Alimentary canal of frog, *Rana esculenta*. (A) Opening of the rectum into the cloaca (Cl); (D) ileum; (Du) duodenum; (†) boundary between small and large intestine; (HB) urinary bladder; (M) stomach; (Mz) spleen; (Oe) esophagus; (Py) pyloric region; (R) rectum. (From Wiedersheim: "Comparative Anatomy of Vertebrates." By permission of The Macmillan Company, publishers.)

ternal surface is complicated by inwardly projecting folds consisting of the **digestive** (or "mucous") **epithelium** and its underlying connective tissue **submucosa**. Such folds form the prominent ridges or

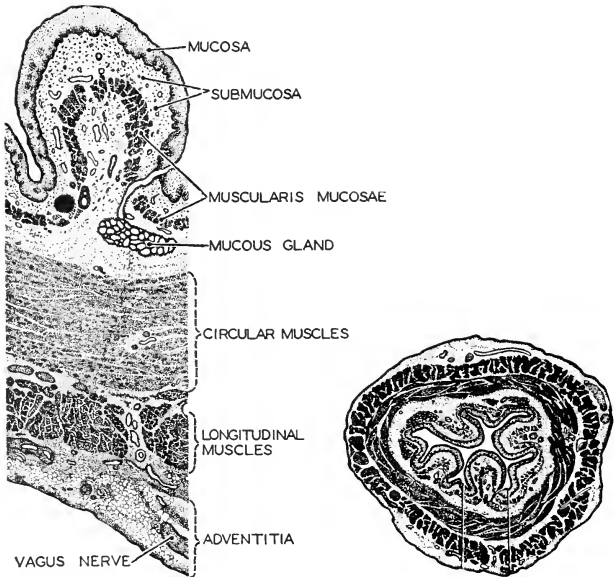


FIG. 20. The esophagus as seen in cross section. (*Right*) A section of the entire esophagus. (*Left*) A small portion much enlarged. The layers of tissue characteristic of the entire alimentary canal are found in the esophagus. (After Braus. Courtesy, Neal and Raud: "Chordate Anatomy," Philadelphia, The Blakiston Company.)

**rugae** on the wall of the stomach (Fig. 21) and the transversely directed **plicae** which may occur in both the "small" and the "large" intestine (Fig. 23). The internal surface of the more anterior region of the intestine is usually thickly beset with delicate, long, cylindric projections, the **villi**, which give the surface a velvety appearance and texture. Each villus consists of digestive epithelium enclosing a core of connective tissue filled with blood-capillaries and small lymph-vessels (Fig. 22). It is thus equipped for absorbing the digested food which bathes its surface. In cyclostome eels, sharklike fishes, and a few other fishes, an inwardly projecting fold of the intestinal lining extends lengthwise of the tube and winds spirally about it, in some cases making several or many spiral turns in its course from one end to the other (Fig. 23). This **spiral valve** greatly increases the functional surface of an otherwise short intestine. When the width of the spiral fold exceeds the radius of the intestine, as it commonly does, the fold necessarily becomes coiled upon itself in the axis of the intestine, thus occluding

direct passage through the intestine and compelling food to follow the turns of the spiral membrane. The functional length of the intestine is thereby greatly increased.

Further increase of intestinal surface is achieved by development of externally projecting hollow appendages of the tube. Most important of these and most constant in occurrence are the **liver** and **pancreas**, which are highly complex glandular structures. Of simpler nature are the pouchlike **ceca** commonly produced by the intestine. In many of

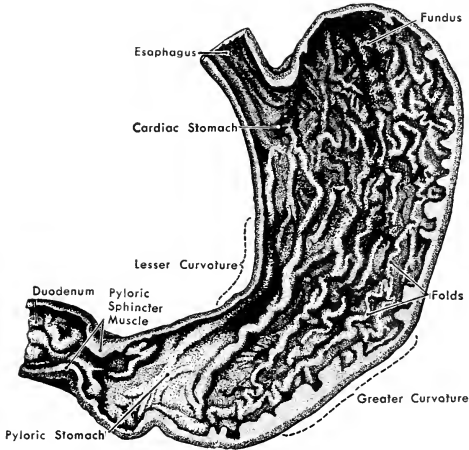


FIG. 21. The right half of the human stomach, viewed from within. (Redrawn from Braus, after Elze. Courtesy, Neal and Rand: "Chordate Anatomy," Philadelphia, The Blakiston Company.)

the bony fishes (Teleostei), there may be from 1 to upward of 100 ceca protruding from the intestine just behind the pylorus (Fig. 24). When very numerous, these pyloric ceca form a conspicuous cluster of long, slender tubes. The **rectal gland** of sharklike fishes is a narrow cecum arising from the dorsal wall of the rectal region of the intestine. Its function is uncertain. In reptiles, birds, and mammals, there is usually a cecum, or a pair of them, at the anterior end of the "large" intestine.

#### *Liver and Pancreas*

These two glandular organs, mainly digestive in function but possessing important secondary functions, are highly characteristic organs of vertebrates (Figs. 10, 25, 26). The **liver**, most massive of all the visceral organs, develops as an outgrowth from the ventral wall of the

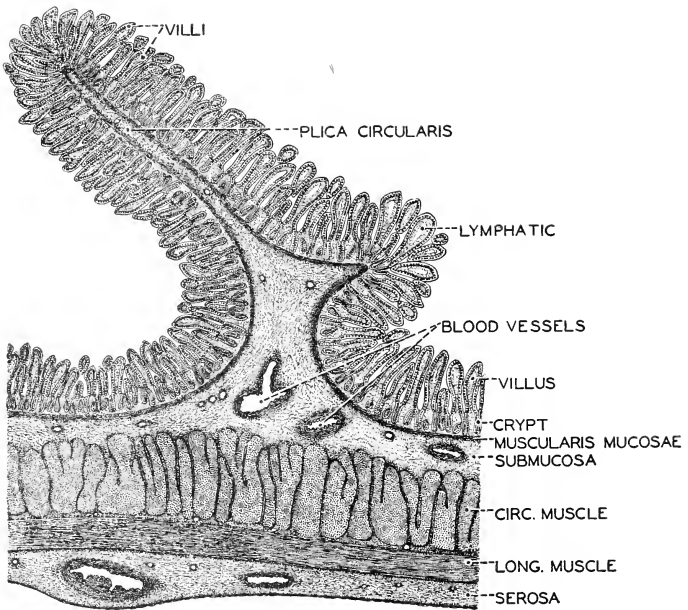


FIG. 22. A longitudinal section of the human jejunum, showing in cross section one of the circular plicae (valvulae conniventes). ( $\times 15$ .) (Courtesy, Neal and Rand: "Chordate Anatomy," Philadelphia, The Blakiston Company.)



FIG. 23. Spiral valve of a skate, *Raia*. Cartilaginous fishes increase the absorbing surface of their intestine not by elongation, as is done by higher animals, but by a spiral fold in the intestine. (After Mayer. Courtesy, Kingsley: "Comparative Anatomy of Vertebrates," Philadelphia, The Blakiston Company.)



anterior region of the embryonic intestine. In the adult it is more or less displaced from its embryonic position ventral to the digestive tube, and may be more or less definitely divided into lobes. The **bile-duct** is the persisting connection of the liver to the intestine at the point of embryonic outgrowth.

The **pancreas**, much less bulky than the liver, develops by outgrowth from the wall of the embryonic intestine, usually close behind the point of origin of the liver (Fig. 26). There are commonly two outgrowths, one dorsal and one ventral, and there may be as many as four. There is much variation in the number of connections persisting as pancreatic ducts.

As seen in the course of ordinary dissection, the liver and pancreas appear as quite solid organs. They are, however, essentially hollow. Beginning as tubular outgrowths from the intestine, each of these organs in its fully developed state consists of a system of elaborately branched tubules whose caliber is of small microscopic dimension. In the case of the **liver**, special technique and high magnification are required to render the lumen of a **hepatic tubule** even visible. In the absence of an obvious lumen, the hepatic tubules are often misleadingly referred to as "hepatic cords," but these "cords" are penetrated by the excessively narrow **bile-capillaries** which collect the products of the secretory **hepatic cells** (Figs. 27, 28). The bile-capillaries converge into larger passages which, in turn, join to form the relatively large **hepatic ducts**. The ducts from the several lobes join into the **bile-duct**. In close relation to the bile-duct there is usually a storage receptacle, the **gallbladder**. The liver is highly vascular, its chief source of blood being a system of veins, the **hepatic-portal system**, draining blood away from the stomach and intestine. This blood is especially rich in the absorbed products of digestion.

The **pancreatic cavities** are wide in contrast to bile-capillaries. The main pancreatic duct or ducts branch successively, passing ultimately into tubules of microscopic width. Each ultimate tubule terminates in an enlarged globular **alveolus** (or **acinus**) whose central re-



FIG. 24. Pyloric ceca. (Stomach above, intestine below.) (Courtesy, Owen: "Comparative Anatomy and Physiology of Vertebrates," London, Longmans, Green & Co., Ltd.)

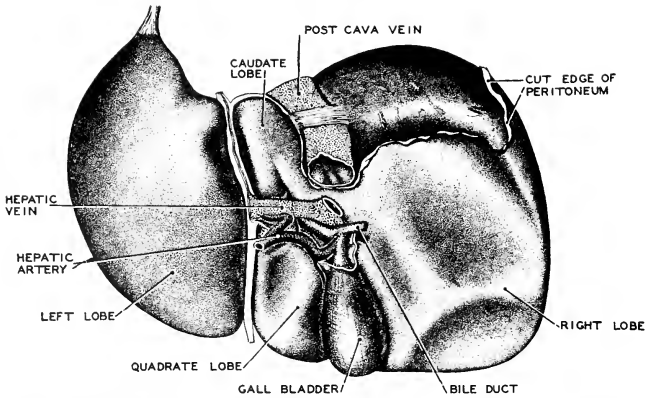


FIG. 25. The human liver viewed from below. (After Sobotta. Courtesy, Neal and Rand: "Chordate Anatomy," Philadelphia, The Blakiston Company.)

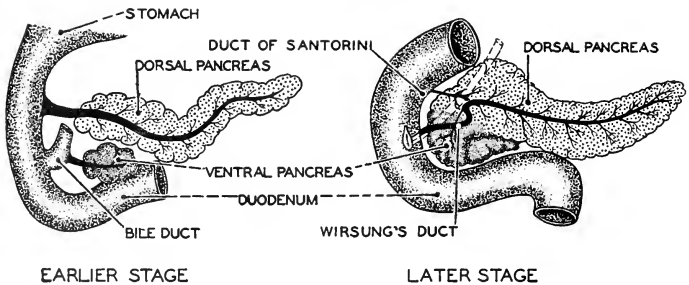


FIG. 26. Two stages in the development of the pancreas. The duct of the dorsal pancreas, Santorini's duct, may degenerate in ontogenesis. The two embryonic glands unite into a single organ in the adult. (After Broman. Courtesy, Neal and Rand: "Chordate Anatomy," Philadelphia, The Blakiston Company.)

gion, instead of being an open lumen, is largely filled by so-called "central cells" differing from the typical pancreatic secretory cells which constitute the wall of the alveolus (Fig. 29). The central cells are of doubtful significance. Scattered irregularly among the pancreatic alveoli are solid masses of cells which exhibit peculiar reactions to histologic dyes. They are known as "islands of Langerhans" (Fig. 29).

The liver is a conspicuous organ in all vertebrates, but there is doubt as to the existence of a pancreas in some fishes. Pancreatic tissue has been found buried within the liver or imbedded in the wall of the intestine of some fishes. This occasional concealment of the pancreatic

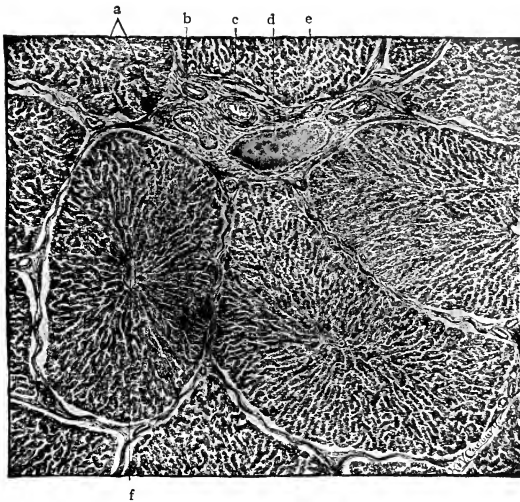


FIG. 27. Liver of a pig. The lobules have artificially shrunk from the interlobular tissue, (a), (b) Bile-duct; (c) hepatic artery; (d) interlobular vein (a branch of the portal); (e) trabeculae; (f) central vein. (Highly magnified.) (After Radasch. Courtesy, Bremer-Weatherford: "A Text-Book of Histology," Philadelphia, The Blakiston Company.)

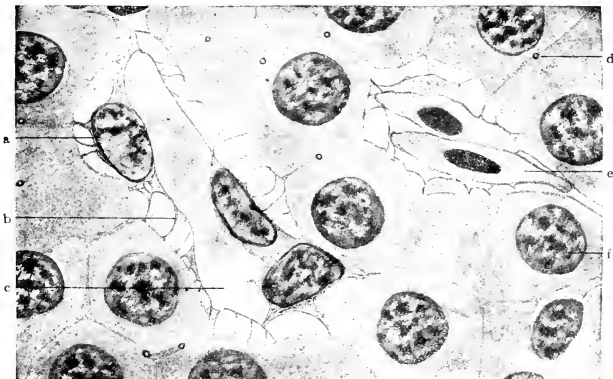


FIG. 28. Section of the liver of a salamander (*Necturus*). (a) Endothelial cell; (b) endothelial reticulum; (c) blood vessel; (d) bile capillary between liver cells; (e) red blood-cell; (f) nucleus of hepatic cell. ( $\times 380$ .) (Courtesy, Bremer-Weatherford: "A Text-Book of Histology," Philadelphia, The Blakiston Company.)

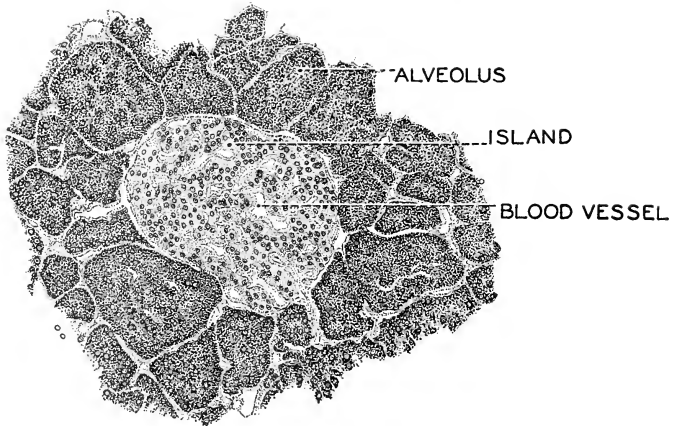


FIG. 29. A section of the pancreas, showing an island among the alveoli of the gland. ( $\times 200$ .) (Courtesy, Neal and Rand: "Comparative Anatomy," Philadelphia, The Blakiston Company.)

tissue makes it unsafe to assert that any fish lacks a pancreas. The absence of a duct in cyclostomes indicates that their pancreas is a gland of "internal secretion"—i.e., secreting into the blood-stream—not a digestive gland.

Viewed in its entirety, the **liver** is impressive only by virtue of its great bulk. Devoid of definite form, not to say "lumpish," it seems anatomically uninteresting. In its histologic architecture, however, the relations of its secretory and circulatory structures are characterized by a degree of precision, refinement, and intricacy which perhaps is not exceeded in any other visceral organ. In number and diversity of its functions, the liver even goes beyond what might be inferred from its structure. The combined output of its secretory activity is the **bile**, a fluid usually of strong color—green, yellow, or brown. Constituents of the bile aid in the emulsifying of fats in the intestine and, interacting with secretions of the pancreas and intestine, are concerned with other digestive processes. From the hepatic-portal venous blood flowing through the liver, the hepatic cells extract sugar and some protein substances and convert them into chemically starchlike **glycogen**, which is stored in the cells and, as need arises, is reconverted to sugar and returned to the blood. Some waste nitrogenous substances are removed from the blood and converted into **urea**, which is returned to the blood to be eliminated by the kidneys. The colored substances and some

other ingredients of the bile seem to be waste materials which are passed off via the intestine. During embryonic life the liver is a seat of formation of red blood-cells. In the adult certain cells in the liver remove from the blood some of its effete red blood-cells. Summarizing, the liver's functions include digestion, storage of products of digestion, rationing of sugar to the blood, excretion of waste via kidneys and intestine, and collaboration with the spleen and other organs in maintaining the efficiency of the red-cell population of the blood.

The **pancreas** is less versatile than the liver, but probably no less important. Its several chemically different secretions, either acting directly or interacting with secretions of liver and intestine, digest food substances of all sorts—proteins, starch, and fats. The **insulin**, secreted into the blood by cells of the islands of Langerhans, regulates the metabolism of sugar.

## TEETH

### *Structure of Teeth*

The alimentary mechanisms of invertebrates include a variety of structures which are functionally analogous to the teeth of vertebrates. But a series of calcareous teeth carried in movable jaws at the entrance to the alimentary canal is a type of dental equipment peculiar to the vertebrates.

The calcareous teeth in vertebrates of all classes have the same general structure, but with differences in detail. This structure may be seen to advantage in one of the relatively large and well-differentiated teeth of a mammal. Three regions of the tooth are distinguishable, a **crown** protruding into the oral cavity, a **root** buried in a bony socket or **alveolus**, and a narrower region, the **neck**, between root and crown (Fig. 30). The internal structure is best seen in a longitudinal section of the tooth (Fig. 31). The wall of the tooth, enclosing a central **pulp-cavity**, consists mainly of a calcareous substance, the **dentine** or "ivory." Dentine is composed of minute calcareous tubules which radiate from the pulp-cavity toward the outer surface of the tooth. In its course from inner to outer surface of the layer, each tubule branches several times. The exceedingly narrow cavities of the tubules are called **canaliculi**. The dentine consists mainly (about 75 per cent in man) of mineral salts, chiefly calcium phosphate and calcium carbonate. About 25 per cent of it is organic material. Usually at no place on the tooth does the dentine reach the outer surface, since the crown and neck are covered by a layer of calcareous substance, the **enamel**, while the root is covered by a bonelike **cement**.

**Enamel** is the hardest substance in the vertebrate body, containing (in man) only about 3.5 per cent of organic material. Its mineral con-

stituents are the same as those of dentine. High magnification of thin sections of a tooth shows that the enamel consists of minute hexagonal solid **prisms** which rest on the surface of the dentine and radiate to the outer surface of the crown or neck (Fig. 32). In its course from inner to outer surface of the layer, a prism does not branch, nor does it increase

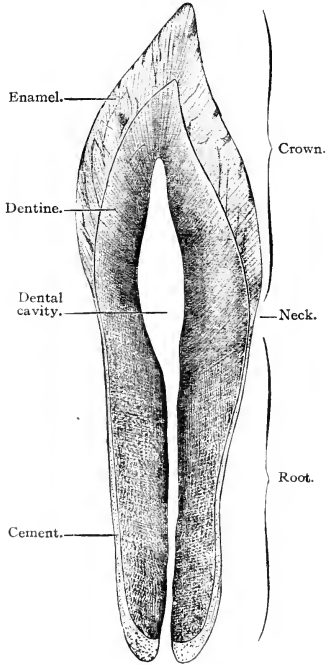


FIG. 30. Longitudinal ground section of a human incisor tooth. ( $\times 4$ .) (Courtesy, Bremer: "A Text-Book of Histology," Philadelphia, The Blakiston Company.)

in its transverse dimensions. The uniform density and hardness of the layer are maintained by occasional interpolation of additional prisms, so that the number abutting on the outer surface of the layer is greater than at the inner surface. The layer is thickest at the apex of the crown and thins out toward the root, being thinnest in the neck region—a reason why that part of the human tooth is especially vulnerable to decay.

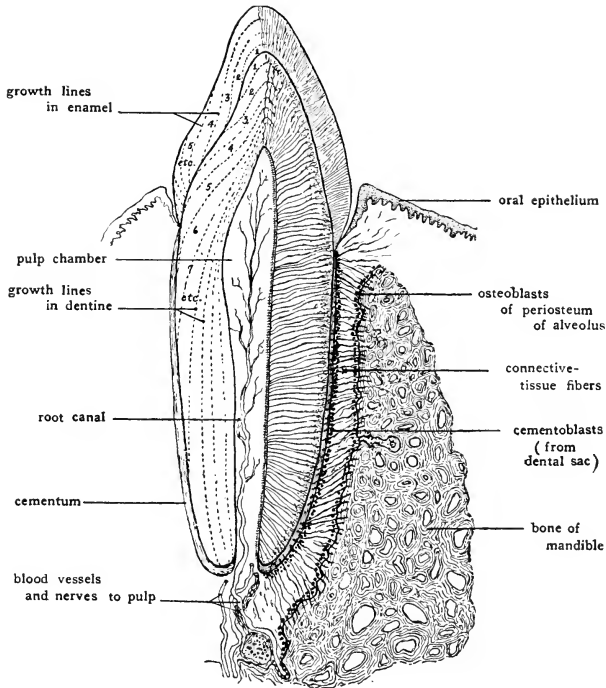


FIG. 31. Schematic diagram showing the topography of a tooth and its relations to the bone of the jaw. The numbered zones indicate empirically the sequence of deposition of the dentine and enamel. The so-called growth lines in the dentine and enamel follow the general contours indicated by the dotted lines in the figure but are much more numerous. (Courtesy, Patten: "Embryology of the Pig," Philadelphia, The Blakiston Company.)

**Cement**, resembling bone, covers the root of the tooth as a relatively thin layer. Like bone, the cement contains cells lodged in **lacunas** (Fig. 33) connected with one another by **canaliculi**. The mineral constituents are like those of bone. Surrounding the root is a connective-tissue dental sac or membrane continuous with the investing membrane (**periosteum**) of the surface of the bony alveolus and, at the neck, continuous with the mesodermal layer underlying the oral epithelium covering the "gum" (**gingiva**).

The central **pulp-cavity** is filled mainly with connective tissue containing blood-capillaries and nerves which enter the tooth through a

minute foramen at the deep end of the root. The dentinal wall of the pulp-cavity, however, is lined by a thin membrane, the **odontoblast layer**, consisting essentially of the cells (odontoblasts) which secrete the dentine. Each odontoblast gives off an exceedingly delicate proto-

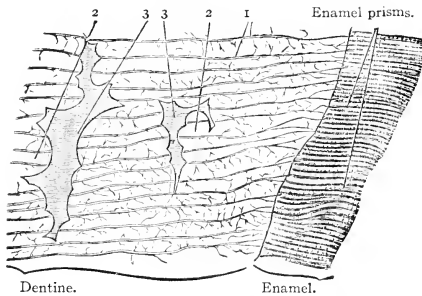


FIG. 32. Longitudinal section of the lateral part of the crown of a human molar tooth. ( $\times 210$ .) (1) Dentinal canaliculi, some extending into the enamel; (2) globules of calcified dentine projecting into the interglobular spaces (3). (Courtesy, Bremer: "A Text-Book of Histology," Philadelphia, The Blakiston Company.)

plasmic fibril (**fiber of Tomes**) which occupies the canaliculus of the dentinal tubule which was produced by that cell (Figs. 33, 34). The sensitivity of human dentine to the dentist's drill is probably due to these living fibrils which may act in the manner of nerves.

In a normal tooth the dentine remains in intimate relation to the living substance which produced it. There is reason to believe that, so long as the odontoblast cells and their dentinal fibrils are alive, the tooth is better able to resist disease. If the blood-vessels and nerves of the pulp are destroyed, the odontoblasts and their fibrils cannot survive. A "dead" tooth is, therefore, more susceptible to decay. Enamel

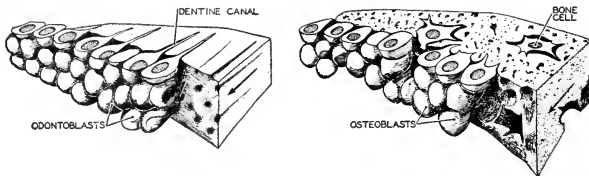


FIG. 33. Diagrams illustrating the difference in the secretion of dentine (*left*), and of bone (*right*). The functional polarization of the odontoblasts and osteoblasts is, however, similar. (After Braus. Courtesy, Neal and Rand: "Chordate Anatomy," Philadelphia, The Blakiston Company.)



contains no living substance and is incapable of self-repair, but loss of dentine at the outer surface of the layer may be compensated for by deposition of additional dentine at the internal surface.

*Development of Teeth*

Teeth develop in much the same way in all vertebrates, but the process is necessarily more complex in the larger and more highly differentiated teeth. Naturally, the development of human teeth has been especially carefully studied. A brief account of it may well serve the present purpose.

When the human embryo has attained a length of about 11 mm. —that is, by the end of the sixth week of development—the ectodermal epithelium covering the jaws grows rapidly into the underlying connective tissue to form a **dental ridge** or **lamina** extending parallel to the edge of each jaw. The lamina is formed by multiplication of cells in the deepest layer (**stratum germinativum**) of the ectodermal epithelium which is continuous with the external epidermis (Fig. 35). As growth continues, the deep edge of the lamina divides into an outer (**labial**) lamina and an inner (**lingual**) lamina. With further growth,

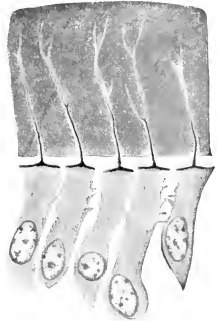


FIG. 31. Five odontoblasts, from which Tomes's fibers extend upward into the dentine; from a tooth of a newborn cat. (After Prenant. Courtesy, Bremer: "A Text-Book of Histology," Philadelphia, The Blakiston Company.)

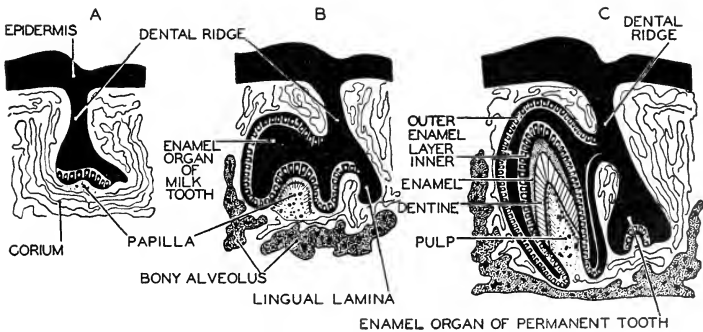


FIG. 35. Diagrams of three stages in the development of a mammalian tooth as seen in sections of the jaw. The enamel-organ of the permanent tooth lies on the lingual side of that of the milk-tooth. (After O. Hertwig and Arey. Courtesy, Neal and Rand: "Chordate Anatomy," Philadelphia, The Blakiston Company.)

the two laminae are carried apart, one extending outward (labially), the other inward (lingually). The **labial** lamina produces the first or "milk-teeth," the **lingual** lamina, the later **permanent teeth** (Fig. 35B, C).

Early in the development of the labial lamina, a series of bell-shaped enlargements, 10 in the upper and 10 in the lower jaw, appear along its labial edge (Figs. 35B, 36). Each of these **enamel-organs**, all present in a 10-week embryo, secretes the enamel of one of the 20 milk-teeth. The concavity of each enamel-organ is occupied by a dermal papilla consisting of loosely arranged mesodermal cells (mesenchyme). Adjacent to the enamel-organ, these cells form a layer which secretes dentine at the surface of the layer next to the enamel-organ (Figs. 35B, C, 37). Thus the dentine, secreted outward by the deep mesodermal papilla, and the enamel, secreted inward by the ectodermal layer, are deposited one against the other as they are destined to be in the wall of the tooth. The dentine-producing cells (**odontoblasts**) become the permanent **odontoblast layer** lining the pulp-cavity. The remaining cells of the papilla give rise to the connective tissue and blood-vessels of the pulp. As development progresses, each tooth-germ recedes from the dental lamina, but retains a temporary connection with it by means of a narrow cord of cells (Figs. 35C, 36).

Soon after the enamel-organs take form, each becomes differentiated into three layers (Fig. 35C): an inner **ameloblast layer** whose cells produce the enamel; an outer layer known as the "outer enamel layer," although it does not secrete enamel; and, between them, a mass of loosely arranged ectodermal cells. The enamel-secreting (ameloblast) cells (Fig. 37) are derived directly from the stratum germinativum of the ectodermal epithelium. Each ameloblast has the form of a hexagonal prism and it secretes, at its end which is adjacent to the odontoblast layer, a simple hexagonal solid prism of enamel. As the thickness of the enamel layer increases, multiplication of ameloblast cells increases the number of enamel-prisms. While the layer of enamel grows by addition to its external surface, the dentine increases at its deeper surface. Consequently, as the tooth develops, the ameloblast and odontoblast layers move farther and farther apart (Figs. 35, 37).

The **lingual lamina** of each jaw, ultimately losing connection with the germs of the milk-teeth, forms a set of 16 enamel-organs lying in a row parallel to and on the lingual side of the row of "milk"-germs. Thus the germs of the 32 permanent teeth come to lie embedded in the connective tissue of the jaws on the lingual side of the primary set (Figs. 35C, 38, 39, 40). The permanent teeth, however, are relatively slow in development, the most posterior molar usually not forming before the fifth year of childhood.

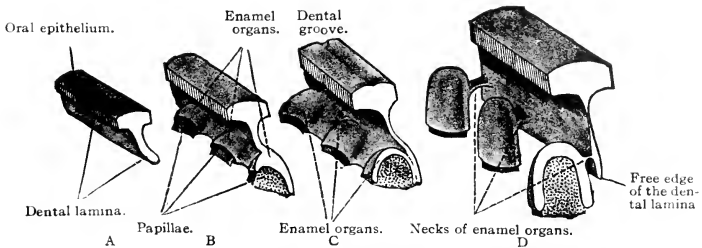


FIG. 36. Diagrams showing the early development of three teeth. (One of the teeth is shown in vertical section.) (Courtesy, Bremer-Weatherford: "A Text-Book of Histology," Philadelphia, The Blakiston Company.)

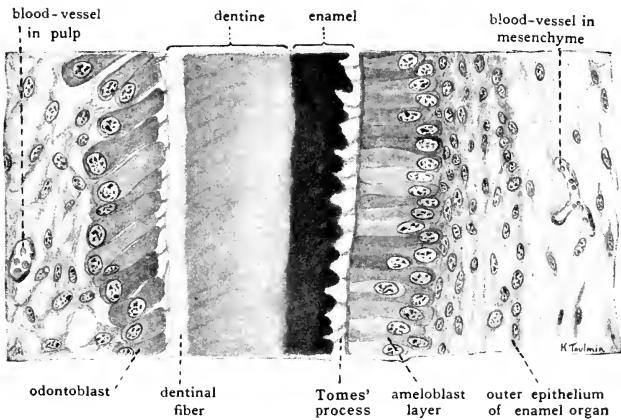


FIG. 37. Drawing of small segment of developing incisor from 130 mm. pig embryo to show formation of enamel and dentine. ( $\times 350$ .) (Courtesy, Patten: "Embryology of the Pig," Philadelphia, The Blakiston Company.)

The crown of the tooth develops first. As the tooth grows, it increases in length as well as in thickness, adding first the neck region and later the root. The opening into the pulp-cavity becomes narrower as the root elongates until finally only a minute foramen remains to admit blood-vessels and nerves. The **nerves**, branches of the **fifth cranial (trigeminal)** nerves, grow into the pulp and each terminates in delicate fibrils which are intimately related to the odontoblast cells. The layer of cement is the last part of the tooth to develop. The cement is produced by bone-forming cells (**osteoblasts**) derived from connective tissue external to the original tooth-germ. Eventually the bone of which the jaw is constituted fills in closely around the root of the tooth, forming a bony pocket or **alveolus** in which the tooth is firmly held in place.

The **eruption** (i.e., the piercing of the gum and emerging of the crown into the oral cavity) of the milk-teeth of man usually begins in

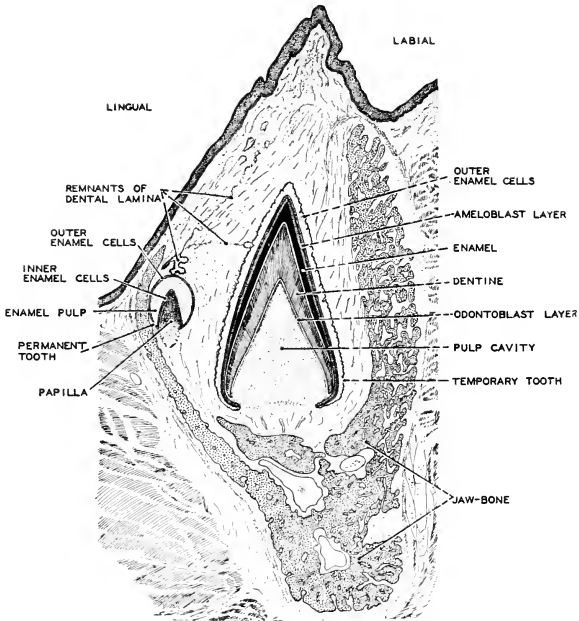


FIG. 38. A section of the jaw of a nine-month human embryo, showing a developing canine tooth. The enamel-organ of the permanent incisor is seen on the lingual side of the milk-tooth. (After Corning. Courtesy, Neal and Rand: "Chordate Anatomy," Philadelphia, The Blakiston Company.)

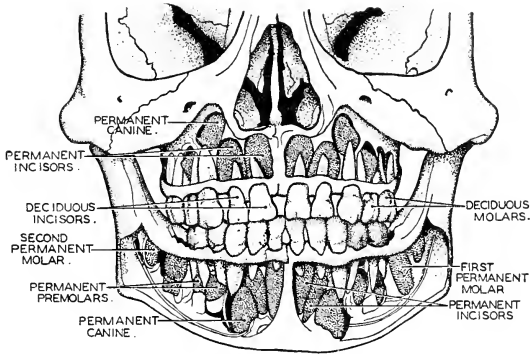


FIG. 39. The teeth of a five-year-old child. Portions of the jaws have been removed so as to expose the roots of the milk-teeth and the partially developed permanent teeth. The latter are stippled in the figure. (After Sobotta. Courtesy, Neal and Rand: "Chordate Anatomy," Philadelphia, The Blakiston Company.)

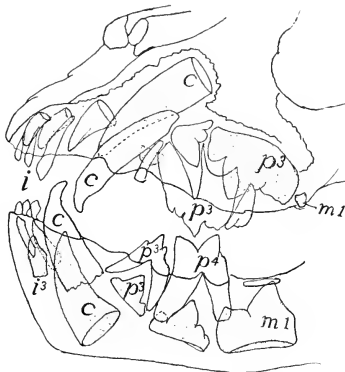

FIG. 40. Jaws of a six-month-old lion. (After Weber.) Milk-teeth white, permanent dotted. (c) Canines; (i) incisors; (m) molars; (p) premolars. (Courtesy, Kingsley: "Comparative Anatomy of Vertebrates," Philadelphia, The Blakiston Company.)

the seventh month after birth and is completed by the end of the second year. Of the permanent set, the first to erupt are the most anterior molars which appear in the sixth year. The last to erupt are the hindmost molars or "wisdom teeth."

The shape of a tooth is determined by that of the tooth-germ. If the ameloblast and odontoblast layers become folded, the form of the tooth is correspondingly modified. The complex teeth of ancient "labyrinthodont" amphibians (Fig. 41) and the elaborately ridged grinding teeth of the sheep and horse (Fig. 42E) are thus produced. The

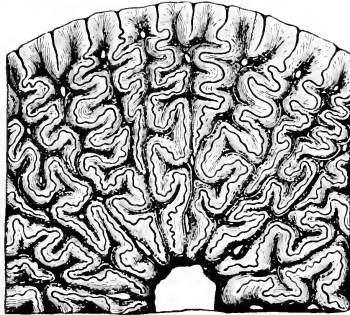


FIG. 41. Part of a cross section of a tooth of an ancient labyrinthodont amphibian. The tooth wall is elaborately folded inward and outward in relation to the central pulp cavity. (Courtesy, Owen: "Comparative Anatomy and Physiology of Vertebrates," London, Longmans, Green & Co., Ltd.)

multiplication of roots, as in large molar teeth (Fig. 43), results from the budding of the odontoblast layer of the dental papilla.

#### *Comparative Morphology of Teeth*

In the structure of teeth there are many variations. The essential part of a tooth is the **dentine**. Teeth of many vertebrates lack enamel (e.g., some fishes, and, among mammals, the sloth and armadillo). The elephant's tusk has no enamel, except that the tip is covered by a small cap of enamel which soon wears off. But there is never enamel without dentine.

A definite layer of **cement** on the root does not ordinarily occur in vertebrates other than mammals unless it be regarded as represented by the bony tissue which literally "cements" the ankylosed tooth to

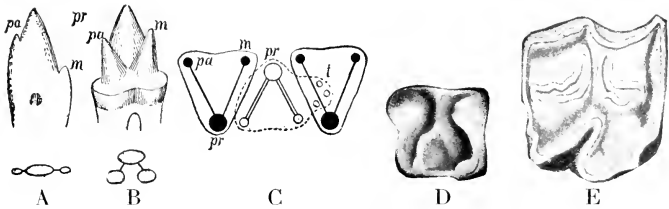


FIG. 42. (A) Triconodont tooth of *Dromatherium*. (B) Tritubercular tooth of *Spalacotherium*. (C) Interlocking of upper (dark) and lower (light) tritubercular molar teeth (after Osborn). (D) Molar of *Erinaceus*. (E) Molar of horse (selenodont type). (c) Cingulum; (m) metacone (metaconid); (pa) paracone (paraconid); (pr) protocone (protoconid); (t) talon. (Courtesy, Kingsley: "Comparative Anatomy of Vertebrates," Philadelphia, The Blakiston Company.)

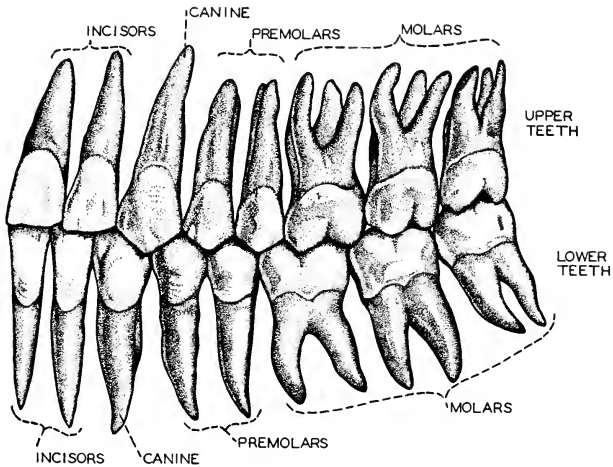


FIG. 43. Human teeth viewed from the left side. The human dental formula is:  $i^2_2, c^1_1, pm^2_2, m^3_3$ . As a result of the shortening of the human jaws the third molars frequently do not erupt. The elongated root of the canine tooth suggests that, as in lower primates, the ancestors of man may have had fangs. (After Braus. Courtesy, Neal and Rand: "Chordate Anatomy," Philadelphia, The Blakiston Company.)

the bone of the jaw. The "check-teeth" of elephants, horses, and cud-chewing hooved mammals (sheep, cattle) have not only their roots but also their crowns covered by a layer of cement. The working surfaces of these teeth are strongly ridged. The ridges are caused primarily by an up-and-down folding of the dentine-and-enamel wall of the tooth (Fig. 44). Then, before the tooth is erupted, the cement-forming tissue

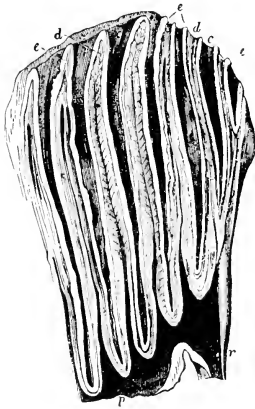


FIG. 44. Section of elephant molar. (c) Cement; (d) dentine; (e) enamel; (p) pulp-cavity; (r) root. (Courtesy, Owen: "Comparative Anatomy and Physiology of Vertebrates," London, Longmans, Green & Co., Ltd.)

around the root grows up over the crown and deposits cement external to the enamel. As the tooth is used, the relatively soft cement is worn away, exposing the enamel on the tops of the folds. Eventually this enamel is worn away, exposing the dentine of the folds. From then on, all three substances are worn down, but each upstanding layer of the more resistant enamel produces a ridge (Fig. 44). Thus the efficient grinding surface of the tooth is produced and maintained by wear. The "ivory" of the elephant's tusk is a modified dentine covered by a thin layer of cement.

A variety of dentine results from its invasion by fine blood-vessels. Ordinary dentine, containing no blood, is white or yellowish. Vascular dentine, or **vasodentine**, found in the teeth of many fishes and occasionally elsewhere, is more or less reddened by the blood in it and is softer than ordinary dentine.

In some cases the root, instead of tapering down to a point pierced by only a narrow foramen (Figs. 31, 45A), remains widely open at the base (Fig. 45B). This condition of having an "open root" or persistent pulp is characteristic of teeth which attain great length or grow continuously at the base to compensate for wear at the apex of the crown, e.g., teeth of some hooved mammals, tusks of hog and elephant, chisel-like front teeth (incisors) of rodents (Fig. 45C). Such teeth, in which there is no sharp distinction between crown and root, are sometimes described as being "rootless."

The relation of teeth to the oral skeleton varies. In sharks and some other fishes, the teeth are carried by the oral membrane (equivalent to the external skin) and are not joined to the skeleton of the jaws or to other skeletal parts. If teeth are firmly joined to the jawbone, they may be fused (**ankylosed**) to its extreme edge (lower edge of upper



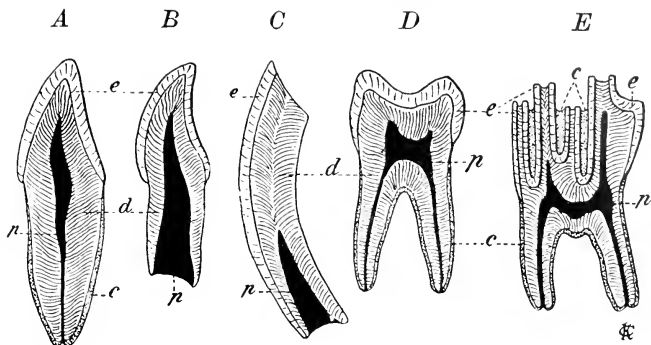


FIG. 15. Types of mammalian teeth. (A) Incisor. (B) Incompletely developed incisor with root widely open. (C) Incisor of a rodent. (D) Human molar. (E) Molar of an ox. (c) Cement; (d) dentine; (e) enamel; (p) pulp-cavity. (Courtesy, Zittel: "Handbuch der Palaeontologie," Munich, R. Oldenbourg.)

jaw, upper edge of lower)—the **acrodont** condition; or they may be ankylosed to the inner vertical surface of the jaw—**pleurodont**. Or, as in crocodylians and mammals, the root may be firmly lodged in a socket or alveolus in the jawbone, but not fused to it—**theodont** (Fig. 46).

**Teeth and Scales.** The teeth of sharklike fishes, in their structure, manner of development, and distribution, exhibit some highly significant peculiarities. They are small relative to the size of the fish, and very numerous (Fig. 47). The number functional at one time may exceed a hundred. They are arranged in several rows parallel to the jaw. A typical tooth consists of a **basal plate** embedded in the oral membrane and usually surmounted by a **spine** which projects through the membrane. The spine consists of dentine capped by a layer of harder substance commonly regarded as enamel, although question has been raised as to whether, in some cases, it is really enamel or merely a variety of dentine. The basal plate has been variously described as being dentine, bone, or cement. It is certainly calcareous. The tooth is produced by interaction of an ectodermal **enamel organ** and a mesodermal **odontoblast layer**, the developing tooth closely resembling a mammalian tooth-germ at an early stage (Figs. 48, 49).

In most sharks the projecting spine of the tooth is pyramidal and more or less elongated and sharp-pointed, with the point directed backward. In the flat skates and rays, the spines are usually reduced and the teeth may become broad flat plates close-set to form a pavement, being thus adapted to crushing hard-shelled objects of prey. In some

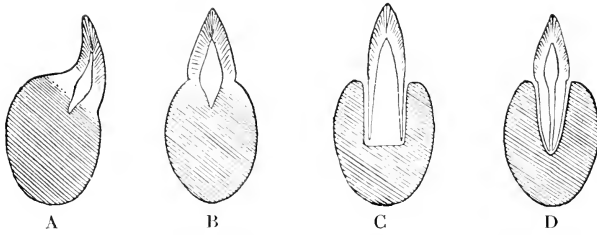


FIG. 16. Types of teeth. (A) Pleurodont. (B) Acrodont. (C) Thecodont with open root. (D) Thecodont with closed root. (Courtesy, Wilder: "History of the Human Body," New York, Henry Holt & Co., Inc.)

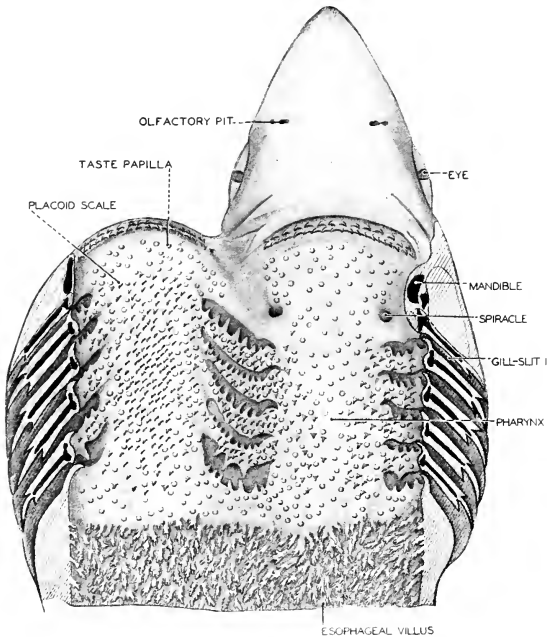


FIG. 17. The pharynx of an elasmobranch (*Squalus*) laid open to show the double row of teeth in both upper and lower jaws. Such teeth differ only in size from the placoid scales of the pharynx and skin. Elasmobranch teeth, like scales, are fastened in the skin and are not attached to the jaw cartilages. (After Cook. Courtesy, Neal and Rand: "Chordate Anatomy," Philadelphia, The Blakiston Company.)

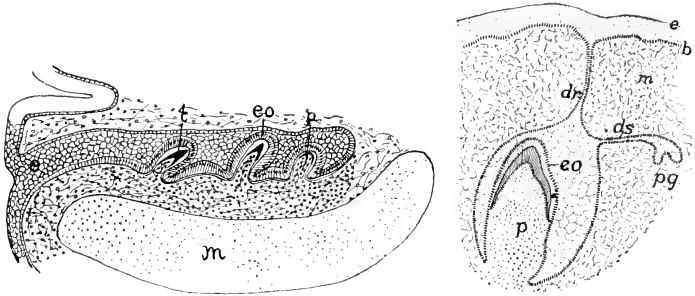


FIG. 18 (Left). Developing teeth of a shark, *Acanthias*. (e) Ingrowth of ectoderm of lower jaw; (eo) enamel-organ; (m) Meckel's (mandibular) cartilage; (p) pulp of (t) tooth. (Courtesy, Kingsley: "Comparative Anatomy of Vertebrates," Philadelphia, The Blakiston Company.)

FIG. 19 (Right). Diagram of germs of milk and permanent dentitions in a mammal. Based on Rose. (b) Basal layer of (e) ectoderm; (dr) dental ridge; (ds) dental shelf; (eo) enamel-organ of milk-tooth; (m) mesenchyme; (p) pulp of milk-tooth; (pg) germ of permanent tooth. (Courtesy, Kingsley: "Comparative Anatomy of Vertebrates," Philadelphia, The Blakiston Company.)

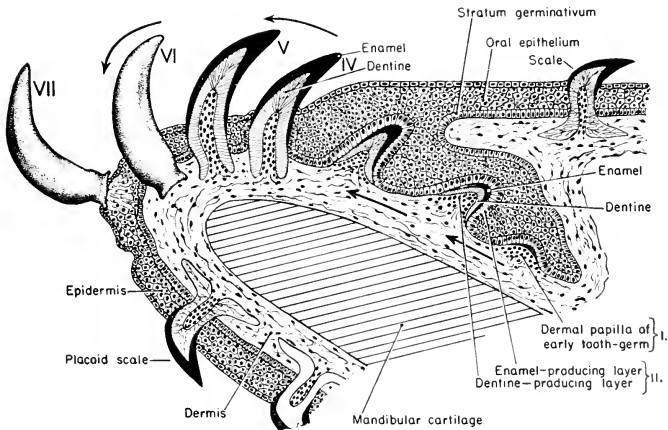


FIG. 50. Diagrammatic representation of a section of a shark's lower jaw showing the manner of origin of the teeth and indicating their successive replacement. Roman numerals I-VII indicate successively older teeth. The continuous movement of the teeth forward and outward is suggested by the arrows. V and VI are fully developed functional teeth at the edge of the jaw. VII suggests a tooth about to be shed.

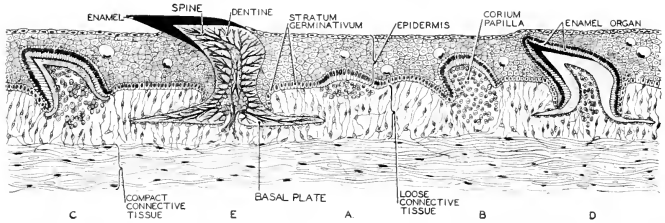


FIG. 51. Section of the skin of an elasmobranch, showing five stages in the development of a placoid scale. (After Schimkewitsch. Courtesy, Neal and Rand. "Chordate Anatomy," Philadelphia, The Blakiston Company.)

sharks the basal plates are more or less reduced. In a given species of elasmobranch, the teeth on all regions of the jaw are of the same form.

Sharks' teeth are subject to loss and **replacement**. Successive rows of new teeth are continually developing in the oral membrane posterior (lingual) to the rows of functional teeth (Figs. 48, 50). The whole dental equipment of the jaw, including its several rows of functional teeth and, posterior to them, several rows of teeth in various stages of development, is slowly and constantly moving forward and outward. As old teeth arrive at the outer edge of the jaw, they are shed. Meanwhile, behind them new teeth will have emerged and moved forward into functional position. This replacement apparently goes on continuously throughout the life of the fish.

The foregoing description of the structure and development of a shark's tooth would apply, with no important modification, to any one of the scales which are distributed over the external surface of the body (Fig. 51). In most sharks the skin is thickly beset with small scales whose sharp-pointed spines, sloping backward, project above the surface of the epidermis (Fig. 52). In some cases there is no sharp demarcation between the teeth on the jaws and the somewhat smaller **placoid scales** on the skin just external to the jaws. Very commonly, too, more or less numerous small placoid scales are scattered over the internal surfaces of the mouth and pharynx (Fig. 47).

Development of calcareous scales in the skin is a common characteristic of fishes. The skin of ancient sharks was beset with "**dermal denticles**," presumably similar to the placoid scales of modern sharks. In all vertebrates the oral cavity is lined by infolded ectoderm (see p. 274). The ectodermal oral epithelium is continuous with the external epidermis and is underlaid by a mesodermal layer which resembles the dermis of the external skin. It is evident that the "skin" of the shark's mouth shares, with the external skin, the capacity for producing plac-

oid scales. **The teeth of sharks, in form, structure, material, and manner of development, are essentially placoid scales.**

They differ from scales only in being larger and usually arranged in a series of rows parallel to the edge of the jaw. In some sharks the teeth of successive rows are placed in a pattern like that of scales on the body (Fig. 52). In relation to the grasping and holding of prey, the integumental scales situated over the jaws occupy a strategic position and, accordingly, have become more strongly developed. Depending on the




FIG. 52. Arrangement of placoid scales in elasmobranchs. The scales are in rows, and usually each scale is in line with the interval between scales of the lines in front and behind. (After Klaatsch. Courtesy, Neal and Rand: "Chordate Anatomy," Philadelphia. The Blakiston Company.)

dietary habit of the fish, the placoid spines may be so exaggerated as to increase the prehensile value of the tooth-scales, or the spine may be more or less reduced and the basal part of the scale broadened in adaptation to use for crushing.

The presence of teeth or scales on the surfaces of the pharynx raises questions. The pharynx is lined by the inner layer of the embryo, the endoderm, which otherwise lines the stomach and intestine. In general, endoderm does not produce hard calcareous structures such as scales. It is not to be expected that it should secrete enamel. It is, therefore, a question whether pharyngeal teeth, present in many fishes,

lack true enamel or possess enamel produced by endoderm. A third possibility is that enamel-organs of pharyngeal teeth consist of ectodermal cells which have migrated from the oral epithelium back into the pharyngeal endoderm, or epidermal cells which have invaded the pharyngeal lining via the gill-clefts. Such migration of cells is known to occur elsewhere in embryos.

The teeth of fishes other than sharks and those of other vertebrates so closely resemble sharks' teeth in the nature of their constituent materials, in structure, and in manner of development that there can be no doubt as to their correspondence. The external skin of the vertebrate may cease to produce calcareous scales, but they are retained in the mouth, and especially on the jaws, and there become enlarged and elaborated in various ways to serve as teeth. The teeth of terrestrial vertebrates, even those of mammals, are therefore to be regarded as remote derivatives of placoid scales of ancient sharklike fishes.

**Differentiation of Teeth.** Comparison of teeth of vertebrates reveals marked differences in number, size, distribution, form, and degree of permanency of teeth. If the differences in each one of these particulars are arranged in a graded series, the corresponding animals of that series fall into line in the following order: fishes, amphibians, reptiles, mammals. Modern birds are toothless but, if ancient toothed birds be included, their teeth (so far as information concerning them is available) put birds into line along with reptiles. The sequence of animals is the same for all of the series of differences.

The **number** of teeth, at its maximum in fishes—sometimes running into hundreds—is much reduced in amphibians, more so in reptiles, and reaches its minimum in mammals. This reduction in number is associated with restriction in **distribution**. In fishes, teeth are commonly widely distributed over the oral and pharyngeal surfaces. Amphibians and reptiles show a progressive tendency to restrict teeth to the jaws. This tendency reaches its limit in some ancient reptiles (e.g., dinosaurs) and in crocodylians and mammals, in which teeth occur only on the jaws. Reduction in number of teeth is associated also with increase in their relative **size**. As they acquire greater functional importance, they become larger, more strongly developed, and more securely attached. In some fishes the small scalelike teeth are anchored merely by the embedding of their basal plates in the oral membrane. Firmer support is gained as the teeth become ankylosed to the bones of the jaws, roof of mouth, and skeletal arches of the gills. (A theory of the evolutionary origin of the superficial or "dermal" bones of the skull proposes that they arose by enlargement and fusion of basal plates of scales.) The fusion of teeth to the jaws may be of either the **acrodont** or the **pleurodont** type (Fig. 46). In the **thecodont** crocodylians and mammals, the teeth are lodged in sockets, but not fused to the bones.

Especially important is the **differentiation of the form of the tooth** in adaptation to a diversity of diets and uses. The sharp-pointed, backward-curving teeth of fishes serve primarily for seizing and holding prey. In amphibians and most reptiles, the teeth retain this primitive function. But, especially in mammals and occasionally in other vertebrates, teeth acquire bladelike or chisel-shaped crowns (**secodont teeth**) adapted for sharp cutting; or they become massive, with crowns flat-topped and transversely corrugated (**lophodont teeth**) adapted for grinding; or certain front teeth may become much elongated, sharp-pointed fangs or tusks serving for holding prey, tearing flesh, digging, or as weapons of combat. The large "cheek-teeth" of mammals are especially complex in form. The crown may bear two, three, or more projecting cusps or tubercles ( **bunodont teeth** adapted for crushing—**bicuspid, tricuspid, triconodont, tritubercular, multitubercular**), and the tooth may have two or more roots (Figs. 42, 43).

The evolutionary origin of these large, complex teeth of mammals is a problem for whose solution two opposed theories have been offered. The **concrecence theory** holds that the multiple cusps and roots indicate origin of the tooth by fusion of two or more primitive simple conical teeth. The theory is supported by some evidence that the large mammalian molar develops by fusion of two or more embryonic tooth-germs. The **differentiation theory**, strongly supported by paleontologic evidence, maintains that the mammalian molar has been derived from a single primitive tooth by progressive increase in size and complexity.

In most fishes and in amphibians, the teeth of an individual animal are of the same form in all regions of the jaws—the dentition is **homodont**. In some of the more primitive reptiles and in nearly all mammals, the individual dentition becomes locally differentiated so that the teeth in one region of the jaw may perform a function quite unlike that of teeth in another region. The animal may bite or cut with blade-like front incisors, crush with massive cheek-teeth, and grasp, tear, or fight with conical canine tusks. This **heterodont** condition reaches its extreme development in mammals (Figs. 43, 53).

**Replacement of Teeth.** Another marked difference in vertebrate teeth is in the frequency of their replacement. The shark has a continual stream of teeth flowing (slowly) across the jaw—new teeth forming on the lingual side and becoming old as they slide across to the labial side to be eventually shed (Fig. 50). In other fishes and in amphibians, the replacement of teeth occurs in a relatively desultory manner, but apparently a tooth in a certain location may, from time to time, be shed and replaced for an indefinite number of times. In case of a tooth situated on the jaw, the replacing tooth develops on

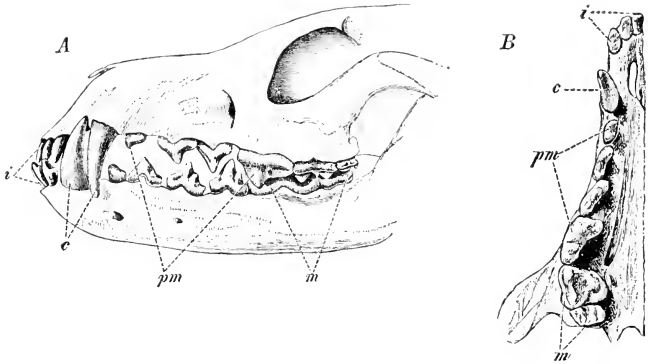


FIG. 53. Teeth of dog. (A) In profile. (B) Upper teeth seen from the cavity of the mouth. (c) Canines; (i) incisors; (m) molars; (pm) premolars. (Courtesy, Wiedersheim: "Grundriss der vergleichenden Anatomie der Wirbeltiere," Jena, Gustav Fischer.)

the lingual side of the old tooth. In reptiles, so far as is known, there is indefinite replacement, but probably less frequently than in fishes, especially when the teeth are large. In mammals one replacement is the limit (Fig. 40). Most mammals develop a set of **deciduous** or "**milk-teeth**" which, in early life, are replaced by the definitive or **permanent** dentition—but, unfortunately, not always literally "permanent." If a tooth of the second set is lost, whether by accident or old age, it is not replaced. Quite commonly the second dentition not only replaces the "milk-teeth" but adds some cheek-teeth behind those of the "milk" series. Teeth which replace "milk" cheek-teeth are called "**premolars**." Cheek-teeth added behind the "milk" set are called "**molars**" (Figs. 39, 40, 43). In some mammals there is little or no replacement. A dentition developed in the young animal is retained indefinitely.

Vertebrates having indefinitely numerous replacements of teeth are called "**polyphyodont**." Mammals in which deciduous teeth are replaced by a second dentition are **diphyodont**, and those which develop only one dentition are **monophyodont**. But the distinction between the diphyodont and monophyodont conditions is not absolute. In so-called "monophyodont" mammals, embryonic tooth-germs are commonly found, in some cases on the lingual side and in others on the labial side of the functional dentition. In embryos of diphyodont mammals, occasional tooth-germs may be found either lingual to the permanent dentition or labial to the "milk" dentition. The presence



of these embryonic rudiments of teeth has been interpreted as indicating the polyphyodont ancestry of mammals.

**Exceptional Dentitions.** At one extreme of the vertebrate dental equipment are **fishes**. In most of them the teeth are small, very numerous, widely distributed, of simple form, homodont, and polyphyodont. At the other extreme are mammals, whose teeth are relatively large and usually few, always restricted to the jaws, more or less complex in form, heterodont, and diphyodont or (at least approximately) monophyodont. The general trend is from one extreme to the other. But all along the line there are exceptions. The Australian lungfish (*Neoceratodus*) has only six teeth. Some fishes are toothless—e.g., sturgeons, sea horses, pipefish. The adult swordfish is not only toothless but scaleless. Some fishes are heterodont. In *Neoceratodus* the upper front pair of teeth are small and bladelike. A pair behind these and a similar pair in the lower jaw are large, flattish, ridged crushers. The wolf fish, cunner, and tautog have front “canines” and back crushers. The scup and sheepshead have large, chisel-like front teeth and back crushers. Thus equipped, a fish may scrape mollusks or barnacles off a rock with the front teeth and crush them with the back teeth. Among **amphibians**, frogs have teeth on the upper jaw but none on the lower. The common toad is toothless. Of **reptiles**, turtles are toothless and venomous snakes are heterodont, having certain pairs of front teeth differentiated as **poison-fangs** (Fig. 54). The fang is long, conical, and sharp-pointed. It is traversed by either a superficial longitudinal groove or an enclosed canal. The venom, secreted by a pair of glands on the upper jaw, is conveyed by a duct to the base of each fang and passes along the groove or canal into the wound made by the fang. The poison-canal might seem to be a modified pulp-cavity, but

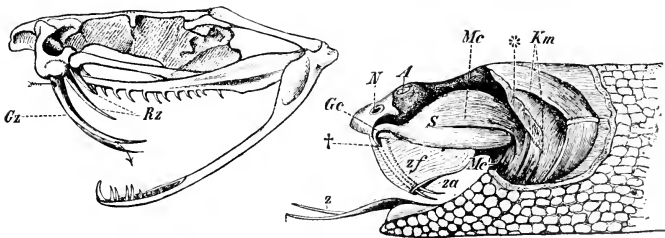


FIG. 54. (Left) The skull of the rattlesnake. (*Gz*) Poison-fang; (*Rz*) reserve fang. (Right) The poison apparatus of the rattlesnake. (*A*) Eye; (*Gc*) poison-duct; (*N*) nostril; (*S*) poison-sac, which is emptied by constriction of the constrictor muscle (*Mc*); (*z*) tongue; (*†*) opening of poison-duct into canal of fang. (Courtesy, Wiedersheim: “Grundriss der vergleichenden Anatomie der Wirbeltiere,” Jena, Gustav Fischer.)

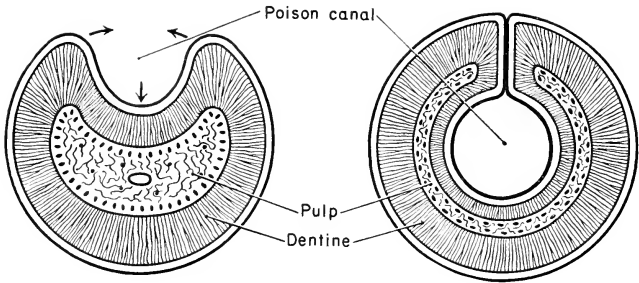


FIG. 55. Cross sections of poison-fangs. (*Left*) The poison-canal is an open groove. (*Right*) The canal is closed. The arrows suggest the process of folding whereby a groove may be arched over to form an enclosed duct.

it is not. It develops as a superficial groove whose opposite edges later overarch and enclose it. Accordingly it is lined by enamel. In a cross section of the fang, the pulp-cavity is seen to be concentric with the poison-canal (Fig. 55). Well-developed replacing fangs are embedded in the jaw close behind the functional fangs. Of **mammals**, most ant-eaters and some whales are toothless, while sperm whales and dolphins have numerous teeth (over 200 in some dolphins) which are homodont.

**Horny Teeth.** Certain vertebrates which lack calcareous teeth produce functional substitutes for them by development of epidermal horny structures. The round-mouthed eels (cyclostomes) have small, conical, horny teeth on the surface of the suctorial disk which surrounds the mouth. These purely epidermal teeth are, from time to time, shed and replaced by others which are already well formed beneath the old teeth. The jaws of the tadpoles of many of the frogs and toads bear numerous minute, spiny, horny teeth, but these larval teeth are not retained by the adult. Larvae of salamanders do not develop horny teeth. In the toothless turtles and tortoises and in birds, the jaws are ensheathed by a thick layer of horn derived from the **stratum corneum** of the epidermis. In some turtles the horny sheath develops spines which simulate teeth. In others, and in birds the horn may be so shaped as to provide the jaws with cutting edges, or formed into the hooked beak of the hawksbill turtle, parrot, and other birds.

## II. Respiratory Organs

### GILLS AND LUNGS

**Gills** are structures which serve to bring blood into close relation to the external water in which the animal lives. They consist of very thin membranous plates (**branchial lamellas**: Fig. 56), or some-

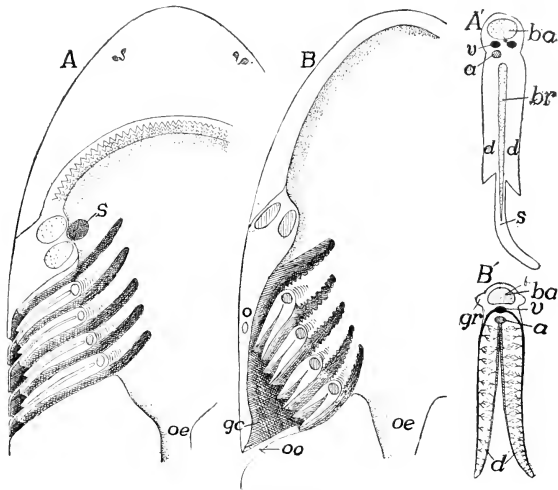


FIG. 56. Diagram of gill-clefts in (A) elasmobranchs and (B) teleosts. (A', B') A single gill of each. (a) Artery; (ba) branchial arch; (br) branchial ray; (d) demi-branches; (gc) atrial chamber; (gr) gill raker; (o) operculum; (oe) esophagus; (oo) opercular opening; (s) spiracle (in A); (s) septum (in A') (v) veins. (Courtesy, Kingsley; "Comparative Anatomy of Vertebrates," Philadelphia, The Blakiston Company.)

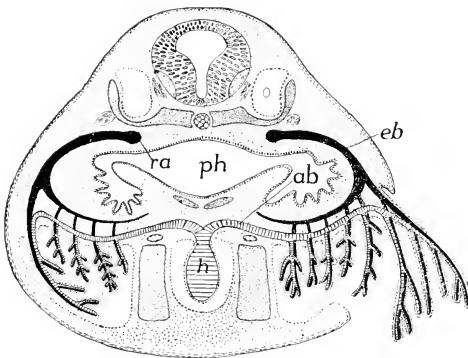


FIG. 57. Diagram of the relations of external and internal gills in the anuran (frog or toad) tadpole. (ab, eb) Afferent and efferent branchial arteries; (h) heart; (o) ear cavity; (ph) pharynx; (ra) radix aortae. (After Maurer. Courtesy, Kingsley; "Comparative Anatomy of Vertebrates," Philadelphia, The Blakiston Company.)

times slender filaments (Fig. 57), richly filled with small blood-vessels which lie so close to the surfaces of the lamellas or filaments that the respiratory interchange of oxygen and carbon dioxide between

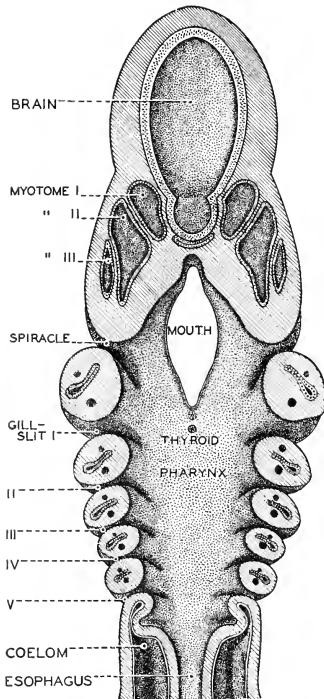


FIG. 58. The pharyngeal region of a young *Squalus* (shark) embryo, showing the visceral arches and clefts in frontal section. (Courtesy, Neal and Rand: "Chordate Anatomy," Philadelphia, The Blakiston Company.)

blood and external water readily occurs by diffusion through the exceedingly thin layers of tissue which separate them.

**Lungs** are internal air-chambers which may be filled or emptied via the nasal passages or mouth. Respiratory interchange of gases occurs by diffusion between the air in the lung and blood contained in

small vessels lying closely adjacent to the very thin lining (**pulmonary epithelium**) of the lung.

Gills are the characteristic respiratory organs of fishlike aquatic vertebrates. Lungs are characteristic of land-dwellers. But some fishlike vertebrates have both gills and lungs, and whales have only lungs. Both gills and lungs are derived from the pharyngeal region of the digestive tube.

#### PHARYNGEAL CLEFTS

One of the most unique features of vertebrate structure is found in the pharyngeal region. Paired right and left lateral apertures in the wall of the pharynx lead into passages or chambers which usually penetrate to the external surface of the body and open there as a longitudinal series of slits or clefts (Figs. 5, 56, 58). These pharyngeal chambers occur in the embryos of all vertebrates. They vary in number from 14 pairs in some cyclostome eels (*Myxine*) to a comparatively small number in land vertebrates. In fishes the respiratory gill-structures develop in the walls of these passages, which then persist throughout life. In land vertebrates the pharyngeal chambers or pouches occur only temporarily in the early embryo and may not completely perforate to the exterior. They are later obliterated, except that those of the first pair persist in a highly modified way in connection with the development of the accessory mechanism of the ear.

#### STRUCTURE OF LUNGS

Lungs develop as a midventral outgrowth from the wall of the pharynx (Fig. 59). The outgrowth bifurcates to form the right and left lungs. Their common connection with the pharynx is the **trachea** ("windpipe"), whose median pharyngeal aperture is the **glottis**. Posteriorly the trachea divides into right and left **bronchi**, each bronchus passing into the corresponding lung. The region of the trachea adjacent to the glottis may be elaborated into a vocal apparatus, the **larynx** (Figs. 60, 61).

Such lungs as occur in fishes and amphibians are relatively simple sacs whose thin walls are, in some cases, quite devoid of complication (Fig. 62). In the other vertebrates, however, the lumen of the lung is, in one way or another, more or less elaborately and minutely divided into air-spaces, all communicating with the bronchus (Fig. 63). The area of the pulmonary surface is thus increased. Respiratory efficiency depends on the amount of surface available for exposure of blood to oxygenation by the air.

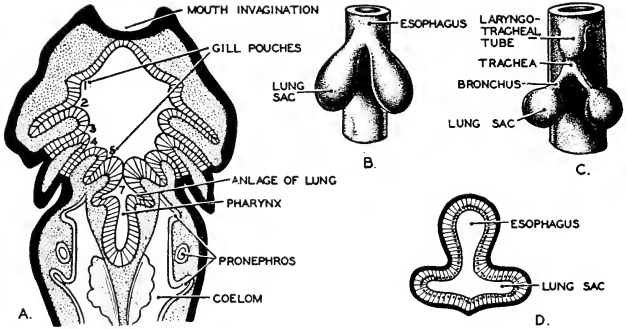


FIG. 59. Stages in the development of lungs in vertebrates. (A) A frontal section of a salamander embryo showing the series of paired pouches which form the gill-slits. (After Goette.) The last pair of pharyngeal pouches develop into the lungs. Such evidence suggests that lungs may have arisen in phylogenesis from a pair of gill-pouches which failed to reach the surface. (B, C) Earlier and later stages in the development of the lungs in an amphibian. (D) A cross section of the early embryonic lung-sac in a reptile. (After Wiedersheim.) (Redrawn from Ihle. Courtesy, Neal and Rand: "Chordate Anatomy," Philadelphia, The Blakiston Company.)

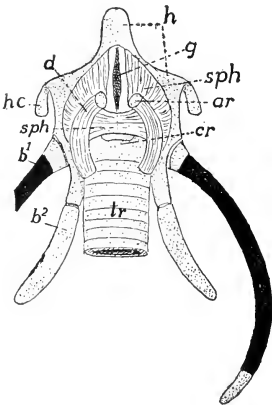


FIG. 60. Laryngeal apparatus of a turtle, *Chelone*. (*ar*) Arytenoid; (*b<sup>1-2</sup>*) first and second branchial arches; (*cr*) cricoid; (*d*) dilator laryngis muscle; (*g*) glottis; (*h*) hyoid; (*hc*) hyoid cornua; (*sph*) sphincter laryngis; (*tr*) trachea. Cartilage dotted, bone black. (After Göppert. Courtesy, Kingsley: "Comparative Anatomy of Vertebrates," Philadelphia, The Blakiston Company.)

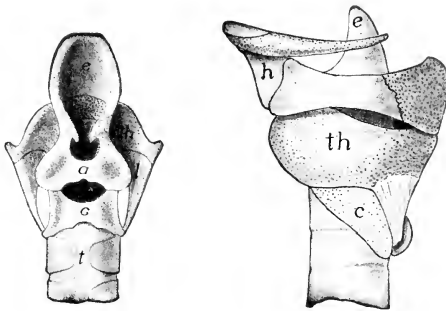


FIG. 61. Dorsal and left-side views of larynx of opossum, *Didelphys virginianus* (Princeton, 1739). (a) Arytenoid; (c) cricoid; (e) epiglottis; (g) glottis; (h) hyoid; (l) ligament; (t) trachea; (th) thyroid. (Courtesy, Kingsley: "Comparative Anatomy of Vertebrates," Philadelphia, The Blakiston Company.)

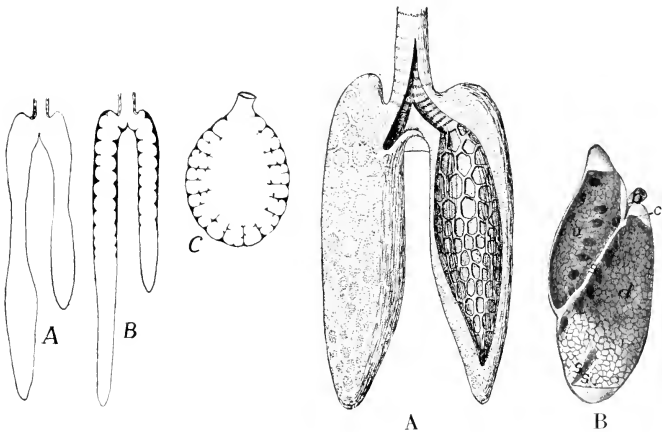


FIG. 62. (Left) Types of amphibian lungs. (A) *Necturus*, without alveoli. (B) Alveoli in the proximal portion. (C) Frog, alveoli throughout. (Courtesy, Kingsley "Comparative Anatomy of Vertebrates," Philadelphia, The Blakiston Company.)

FIG. 63. (Right). (A) Lungs of *Sphenodon* (after Gegenbaur): one lung open to show the alveoli. (B) Left lung of a lizard, *Iguana*. (b) Bronchus; (c) connection between dorsal and ventral chambers; (d) dorsal chamber; (s) septums; (r) ventral chamber. (Courtesy, Kingsley: "Comparative Anatomy of Vertebrates," Philadelphia, The Blakiston Company.)





# Circulatory System

---

3

## GENERAL RELATIONS OF HEART AND CIRCULATORY CHANNELS

The **heart** is always ventral to the alimentary tube and anterior to the abdominal cavity (Fig. 10). It pumps the blood cephalad into **arteries** which convey it to all parts of the animal (Fig. 64). The arteries give off successively smaller branches which ultimately lead into the narrowest vessels, the **capillaries**. The caliber of a capillary may be only slightly larger than the diameter of a blood-cell. The capillaries, usually forming a network or plexus, bring the blood into intimate relation to the cells of the various tissues. A certain amount of the fluid part of the blood, the **plasma**, diffuses through the capillary walls into minute **intercellular spaces**. This escaped plasma brings to each cell the nutriment and oxygen necessary for the cell's existence and picks up the waste substances which are given off by the cell. The intercellular fluid is called **lymph**. It contains "white blood-cells" (**leukocytes**) but no red blood-corpuscles (**erythrocytes**).

Passing through the capillaries, the blood emerges into small **veins** which unite to form progressively larger veins. These ultimately converge into a relatively small number of main venous trunks which return the blood to the heart, entering at its posterior end. At their region of junction with the heart, these main veins usually join to form a capacious thin-walled **venous sinus** (Fig. 65) which opens by a single aperture into the posterior chamber of the heart. The sinus is sometimes described as a part of the heart, but in a strict sense it is not.

The **lymph** drains away from the intercellular spaces into a system of **lymph-vessels** which, for the most part, parallel the courses of the veins and finally open into some large vein near the heart, thus returning the lymph to the main circulatory channels (Fig. 66). Along the course of the lymphatics are occasional **lymph-nodes** or "glands"

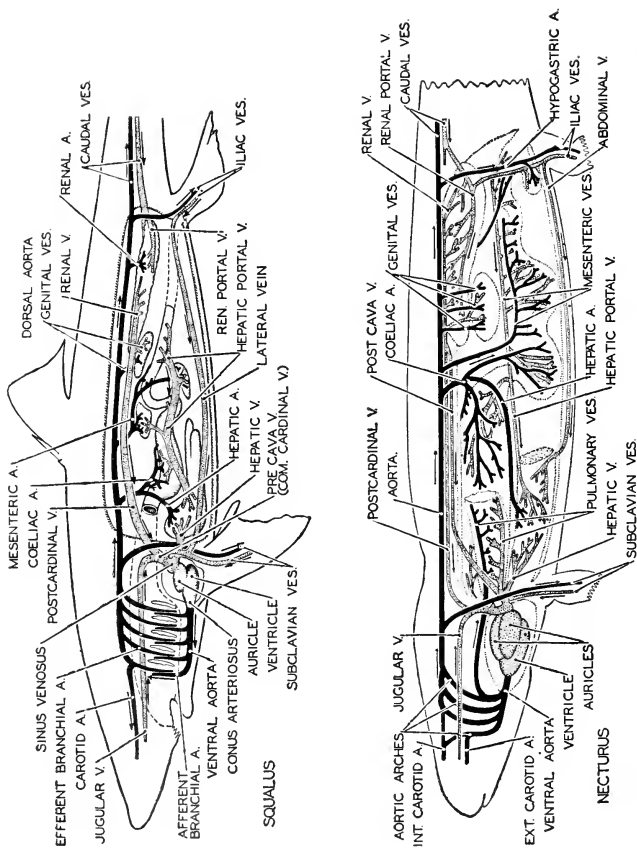


FIG. 64. Diagrams of the circulatory system of a shark (*Squalus*) and an amphibian (*Necturus*). Arteries black, veins stippled. The vessels are shown as if projected upon the median plane. Arrows indicate the direction of the flow of blood. (After Wierstratz, Woodruff, and Kingsley. Courtesy, Neal and Rand: "Chordate Anatomy," Philadelphia, The Blakiston Company.)

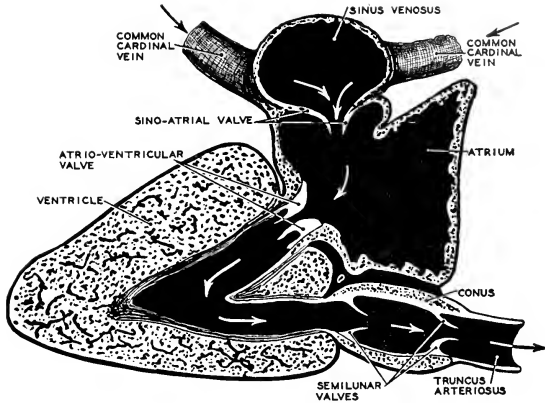


FIG. 65. A diagram of the primitive (fish) heart, as seen in a median longitudinal section. Anterior is to the right. The course of blood in the heart (indicated by arrows) takes the form of a letter S. (After Keith. Courtesy, Neal and Rand: "Chordate Anatomy," Philadelphia, The Blakiston Company.)

(see p. 67) which are seats of formation of **leukocytes** (Fig. 67). The lymph-vessels in the wall of the intestine are especially concerned with the absorption of the fatty constituents of the digested food. The minute globules of fat, carried by the watery lymph in a state of emulsion, give it a milky white appearance. This fat-laden lymph is called **chyle**, and the lymphatics which carry it away from the intestine are called **lacteals**.

**Hemal "glands"** ("blood-glands") resemble lymph-nodules but occur on the course of blood-vessels instead of on lymphatics, and therefore are traversed by red blood, not by colorless lymph. The **spleen**, a deep red organ of glandlike appearance but having no duct connecting it with any other organ, is the largest of the hemal glands. It is a seat of formation of red blood-cells (**erythrocytes**) and **leukocytes**, and serves also to remove degenerating red blood-cells from the circulation. It is usually attached to the digestive tube by a sheet of membrane in the region of the stomach.

**Structure of Vessels.** **Arteries** have relatively thick and strongly muscular walls and, except at the junction of the main arteries with the heart, they do not have internal valves. Walls of **veins** are less muscular and thinner than those of arteries, and a vein is of greater diameter than the corresponding artery, the velocity of the blood-stream in the vein being less than that in the artery. At intervals along the course of a vein are **valves**, each consisting of flaps or pockets formed by the

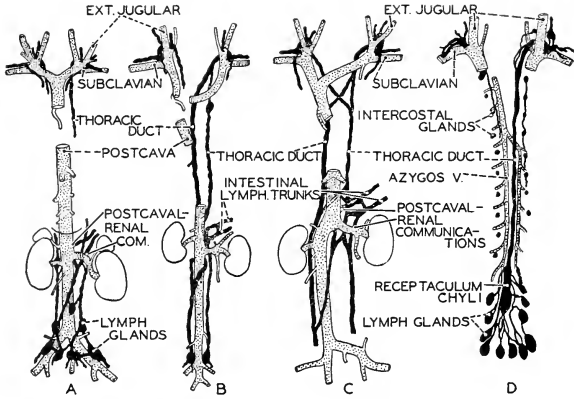


FIG. 66. Diagrams illustrating the chief lymphatic trunks and their relations to the veins in mammals. Ventral views. (A) South American monkeys. (B) Mammals (*Lepus*) in which postcaval-renal communications are wanting. (C) Mammals in general. (D) Man. (Postcava and kidneys not shown).

In all mammals lymph enters the veins at the point of junction between the jugular and the subclavian veins. In most mammals there is also communication between the lymph-vessels and the postcaval and renal veins. In man the right thoracic duct degenerates in part and the only communication with veins is at the root of the jugulars. (Courtesy, Neal and Rand: "Chordate Anatomy," Philadelphia, The Blakiston Company.)

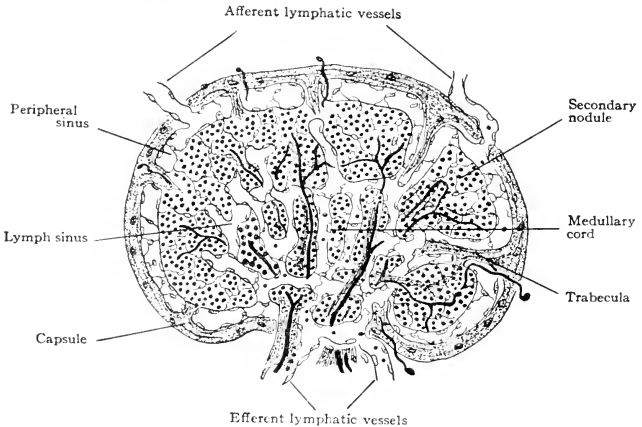


FIG. 67. Diagram representing two stages in the development of a lymph-gland. The left half of the diagram is an earlier stage than the right half. (Modified from Bremer: "Text-Book of Histology," Philadelphia, The Blakiston Company.)

lining of the vessel and so placed that any tendency of the blood to flow backward—that is, away from the heart—distends the pockets and occludes the passage (Fig. 68). The wall of a capillary is reduced to the extreme of thinness. It is only one cell in thickness, being the continuation of the delicate lining (**endothelium**) of the adjoining small arteries and veins, and quite devoid of muscle and connective tissue. **Lymphatics** resemble veins but are narrower than the corresponding veins and have even thinner walls, the internal pressure of the circulatory current being at its minimum in lymphatics and at its maximum in arteries. Certain localized and more strongly contractile regions of larger lymphatics, **lymph-hearts**, assist the flow of the lymph. Valves similar to those in veins help prevent backing of the lymph. In mammals, lymph-hearts are rarely, if ever, present, but valves are especially numerous (Fig. 69).

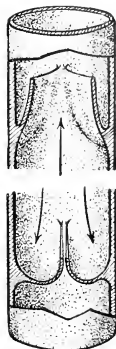


FIG. 68. Valve in vein. Arrows indicate direction of pressure. (Top) Blood moving toward heart; valve open. (Bottom) Pressure reversed; pockets of valve dilated, occluding passage.

#### RELATIONS OF RESPIRATORY ORGANS TO CIRCULATION

The respiratory organs are interpolated into the main course of the circulation immediately anterior to the heart so that the blood becomes oxygenated before it starts on its way to the capillaries, where its essential work is to be done.

In **gill-breathers without lungs**, the heart consists of two chambers: a posterior receiving chamber, the **auricle** or **atrium**; and an anterior more strongly muscular **ventricle** (Fig. 65). The ventricle pumps the blood cephalad into a short **ventral aorta**, whence several pairs of **afferent branchial arteries** distribute the blood to the several pairs of gills, in whose lamellas or filaments the arteries pass into capillaries where the oxygenation occurs (Figs. 64, *Squalus*: 70). From these branchial capillaries the now "pure" blood passes into several pairs of dorsal **efferent branchial arteries**, which all converge into the anterior end of the chief artery of the body, the median **dorsal aorta**, which extends along the roof of the coelom. The pairs of arteries intervening between ventral aorta and dorsal aorta encircle the pharyngeal region of the digestive tube. They are called **aortic arches**. In adult fishes there are usually four or five aortic arches. The aortic arches correspond approximately in number to the branchial clefts and alternate with the clefts in position (Figs. 64, 70).

From certain of the efferent branchial arteries, a pair of **carotid**

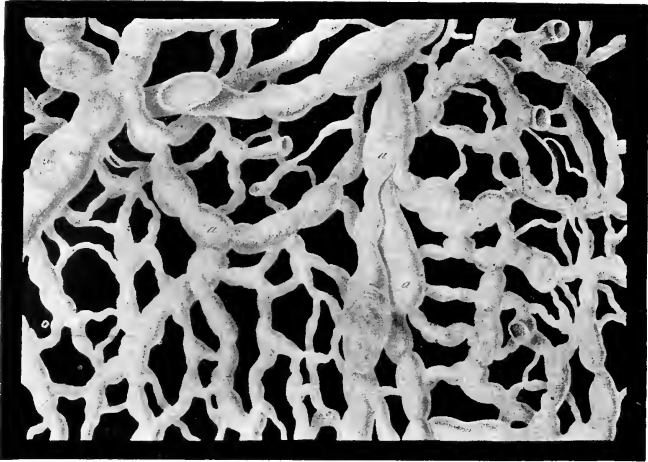


FIG. 69. The lymphatics of the scrotum, showing the transition of the capillaries to the vessels with valves (*a, a, a*). (After Teichmann. Courtesy, Jackson: "Morris' Human Anatomy," Philadelphia, The Blakiston Company.)

**arteries** pass to the head, and a **subclavian artery** (sometimes connected to the dorsal aorta) to each pectoral fin or leg. The dorsal aorta gives off branches to the viscera—a **celiac artery** to the stomach and liver, two or more **mesenteric arteries** to the intestine, and pairs of **ovarian, spermatic, and renal arteries**. Segmentally arranged pairs of **parietal arteries** pass to the muscles of the body-wall, a pair of **ilia arteries** supply the pelvic fins or legs, and, posterior to the trunk, the aorta continues as the **caudal artery** (Figs. 64, *Squalus*; 71A).

In **lung-breathers without gills** (Fig. 71D, E), the bloodstream is "shunted" off from the main course of the circulation to pass through the respiratory capillaries of the lungs. In connection with this arrangement, the heart becomes more or less completely divided and the blood passes through the heart twice in each of its trips around the body. A median partition divides the primitively single auricle into **right and left auricles** and in reptiles, birds, and mammals, the **ventricle** is similarly divided into **right and left chambers**, although the division is incomplete in most reptiles (Fig. 72). The "impure" blood returning from the general (**systemic**) circulation passes through the right chambers of the heart, and the right ventricle pumps it to the lungs via the **pulmonary arteries**. Returning from the lungs, **pul-**

**monary veins** deliver it into the left auricle, and the left ventricle—much more strongly muscular than the right—pumps it into the main arterial channels, whose distribution is essentially the same as in the gill-breathing vertebrates (Fig. 71).

#### EMBRYONIC AORTIC ARCHES

In the early embryonic stages of all vertebrates is developed a series of **aortic arches** which, in their relations to the heart, dorsal aorta, and pharyngeal pouches of the embryo, are essentially similar to the aortic arches of an adult fish (Fig. 70). But in lung-breathing land animals no gills are developed at any time, and therefore no capillaries corresponding to the branchial capillaries of gill-breathers intervene between ventral and dorsal aorta. In later embryonic stages of reptiles, birds, and mammals—all of them being lung-breathers—this system of arches undergoes great reduction and modification (Fig. 73). In adult reptiles only one complete arch persists—the fourth (numbered from anterior to posterior) of the several arches of the embryo. In adult birds and mammals the left ventricle and the aorta are joined by only a single vessel which in birds is the right member of the fourth arch and in mammals is the left member of that arch (Fig. 73). The pulmonary arteries are a remnant of a more posterior embryonic arch, probably the sixth.

#### VEINS

**Main Trunks.** In the basic arrangement of the veins, as they appear in the embryos of vertebrates (Fig. 74), the chief trunks con-

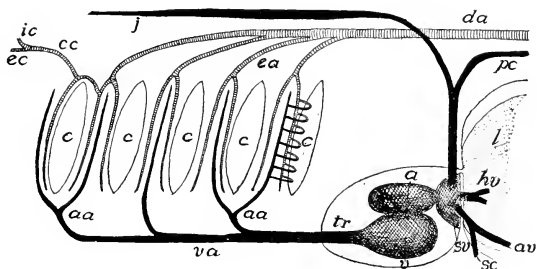


FIG. 70. Scheme of branchial circulation in elasmobranchs. (a) Auricle; (aa) afferent branchial arteries; (av) abdominal vein; (c) gill-clefts; (cc) common carotid; (da) dorsal aorta; (ea) efferent branchial arteries; (ec) external carotid; (hv) hepatic vein; (ic) internal carotid; (j) jugular vein; (l) liver; (pc) postcardinal vein; (sc) subclavian vein; (sv) sinus venosus; (tr) truncus arteriosus; (v) ventricle; (va) ventral aorta. (Courtesy, Kingsley: "Comparative Anatomy of Vertebrates," Philadelphia, The Blakiston Company.)

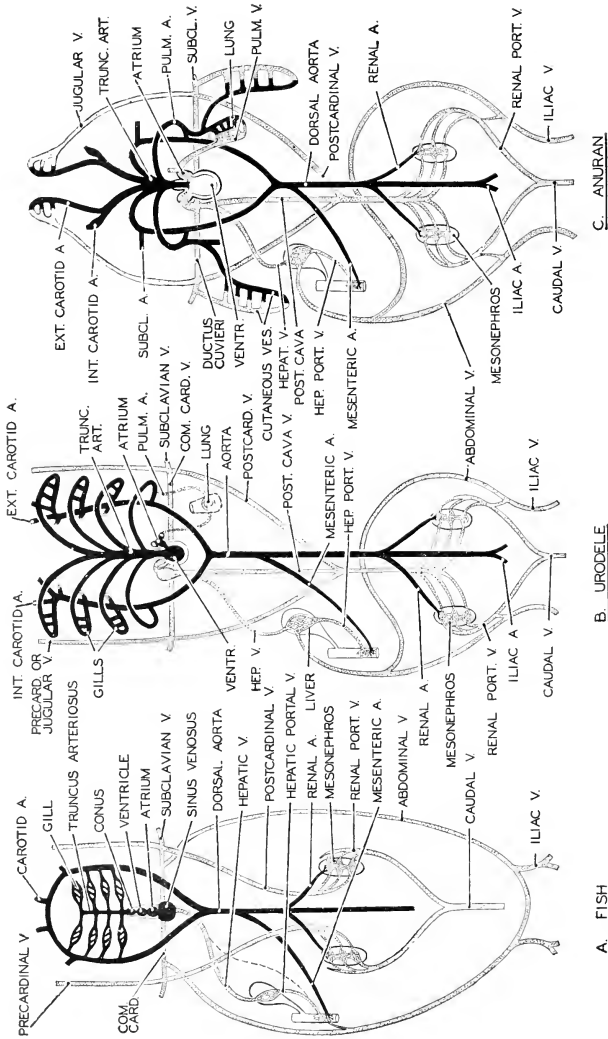


Fig. 71. For descriptive legend see p. 71.



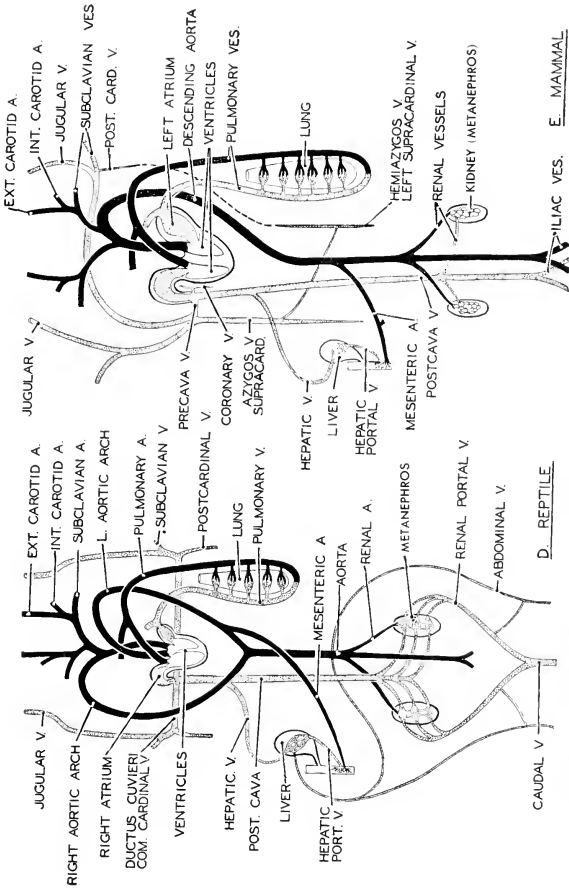


Fig. 71. Diagrams of the main circulatory vessels in fish, amphibian (trodole, a tailed amphibian; anuran, a frog or toad), reptile, and mammal. Arteries black, veins stippled. It will be noted that some blood-vessels persist throughout the entire series. In general features the series may be interpreted as representing stages in the phylogenesis of the mammalian circulatory system. (After Stempell, Courtesy, Neal and Rand; "Chor-date Anatomy," Philadelphia, The Blakiston Company.)

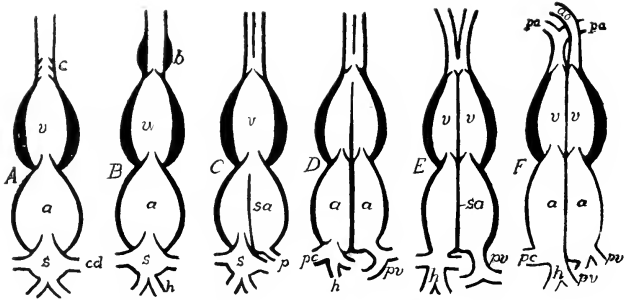


FIG. 72. Stages in the differentiation of the parts of the heart. Ventral view. (A) Elasmobranch. (B) Teleost. (C) Amphibian. (D) Lower reptile. (E) Alligator. (F) Bird and mammal. (a) Auricle; (ao) aorta; (b) bulbus arteriosus; (c) conus; (cd) duct of Cuvier; (h) hepatic veins; (pa) pulmonary artery; (pc) pre- and postcaval veins; (pv) pulmonary vein; (s) sinus venosus; (sa) septum atriorum; (v) ventricles. (Courtesy, Kingsley; "Comparative Anatomy of Vertebrates," Philadelphia, The Blakiston Company.)

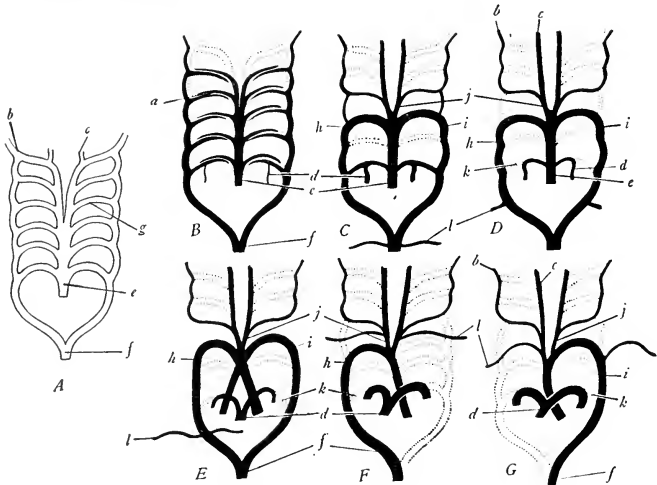


FIG. 73. Diagrams to show the evolution of the aortic arches. Ventral views. (A) Primitive condition with six aortic arches. (B) Fishes, the first aortic arch missing. (C) Some urodeles, the first, second, and fifth arches missing, with the connection (k) between the pulmonary arteries (d) and the aorta obliterated. (E) Reptiles, showing the ventral aorta split into three trunks and the fourth aortic arch (h and i) persistent on both sides. (F) Birds, the ventral aorta split into two trunks, and the fourth aortic arch (h) persistent on the right side only. (G) Mammals, the ventral aorta split into two trunks and the fourth aortic arch (i) persistent on the left side only. (a) Interruption of the aortic arches by the gill capillaries in fishes; (b) internal carotid; (c) external carotid; (d) pulmonary, developed from the sixth arch; (e) ventral aorta; (f) dorsal aorta; (g) aortic arch; (h) right fourth aortic arch; (i) left fourth aortic arch; (j) common carotid; (k) arterial ligament, a vestige of the vessel originally connecting pulmonary and aorta; (l) subclavian. (Modified from Wilder. Courtesy, Hyman: "Comparative Vertebrate Anatomy," University of Chicago Press.)

necting more or less directly with the heart include a pair of **anterior cardinal** (**precardinal** or **jugular**) veins collecting blood from the head and neck, and a pair of **posterior cardinals** (**postcardinals**) situated on the dorsal wall of the coelom and extending to the posterior end of the abdominal cavity. Just lateral to the heart, the anterior and the posterior cardinal of each side meet and join to form a short transverse **precava** (**anterior vena cava**, or **duct** or **sinus of Cuvier**) which opens into the venous sinus. Each precava receives a **subclavian vein** from the adjacent pectoral appendage and, at least in the fishlike vertebrates, a **lateral vein** collecting from the lateral abdominal wall. The blood from the liver is collected into one or two **hepatic veins** (or sinuses) which pass forward directly into the venous sinus (Fig. 74, *h*).

In most adult fishes the two **postcardinals** persist as chief veins of the trunk. In the lungfishes (Dipnoi) and all other vertebrates, the veins of the embryonic trunk undergo a complex metamorphosis resulting in formation of a single median vein. Certain veins, a pair of **subcardinals** and a pair of **supracardinals**, which may be regarded as derivatives or collaterals of the postcardinals, arise in connection with the development of the kidneys (Figs. 74, 75). The several veins of this postcardinal system acquire complex and transitory connections with one another. Gradually, from this early embryonic maze of small veins, a central main channel begins to emerge (Fig. 75*F-K*) and eventually becomes one large median vein extending from the region of the kidneys forward along the roof of the abdominal cavity, whence it descends to enter and pass through the liver directly into the venous sinus or right auricle (Figs. 71*B-E*, 76). Thus is formed the **postcava** (**posterior vena cava**) which functionally more or less completely replaces the postcardinals, although in part derived from them or from their associated subcardinals and supracardinals. The anterior segment of this built-up postcava consists of an embryonic **hepatic vein** (Fig. 75*I, K*). The embryonic history of the postcaval veins of vertebrates of the several classes is not uniform. The definitive veins differ as to the fractions of embryonic veins which constitute them, and therefore do not exactly correspond—or are not completely homologous (see p. 362).

With the shifting of the main venous flow from the paired postcardinals to the median postcava, the anterior regions of the postcardinals become reduced or may be represented by mere vestiges. A pair of small **azygos veins** just behind the heart in mammals have been regarded as remnants of postcardinals, but recent study of their origin indicates that only their anterior extremities are postcardinal, their greater part being probably of supracardinal origin (Fig. 75*G-K*).

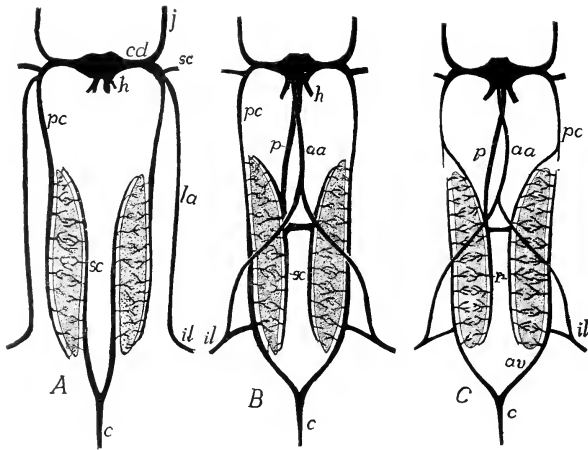


FIG. 74. Relations and modifications of the post- and subcardinal, abdominal, and postcaudal veins in successive developmental stages of an amphibian. (A) The veins (*il*) from the hindlimb return directly to the heart by the lateral abdominal veins (*la*), while the blood from the tail (*c*) passes by way of the subcardinals (*sc*) through the mesonephroi to the postcardinals (*pc*). (B) The lateral abdominals have united in front to form the anterior abdominal vein (*aa*); the iliacs have sent a branch to the postcardinals, which have grown back to join the caudal, while the subcardinals have lost their connection with the caudal and have acquired one with the postcava (*p*), a backward growth from the sinus venosus. (C) The postcardinals have been interrupted, the posterior half of each now forming an advehent renal vein (*ar*) while the subcardinals, as in B, form the revent veins (*r*). (*cd*) Duct of Cuvier (precava); (*h*) hepatic vein; (*j*) jugular vein. (Courtesy, Kingsley: "Comparative Anatomy of Vertebrates," Philadelphia, The Blakiston Company.)

**Hepatic-Portal System.** A highly unique feature of the arrangement of the veins in a vertebrate exists between the digestive tube and the liver. In general, the blood, in the course of its round trip from heart to tissues and back to heart, passes through only one system of capillaries. But the blood which is delivered by arteries to the walls of the coelomic portion of the digestive tube, having passed into capillaries in the tissues of the tube, is drained away by veins which convey it directly into the liver and distribute it into capillaries throughout the entire mass of the liver (Fig. 64). From these hepatic capillaries the blood is re-collected by the **hepatic veins**, which then take it directly to the heart. The blood, therefore, in its circuit from heart to heart, has passed through two systems of capillaries. This peculiar set of veins interposed between the digestive tube and liver is called the **hepatic-portal system**. The arrangement enables the liver to remove from the

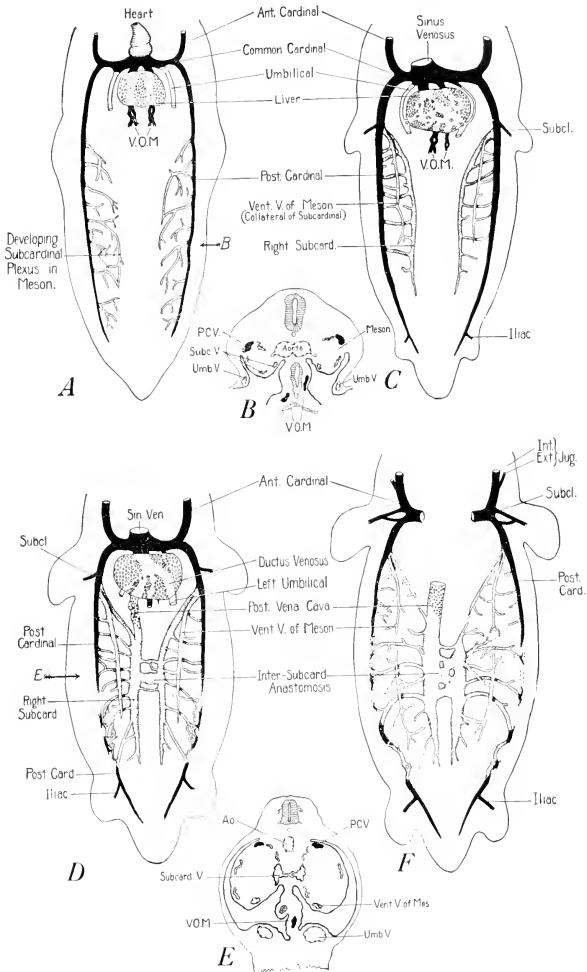


FIG. 75. Diagrams illustrating stages in the development of the systemic veins of the pig. The cardinal and omphaloenteric veins are shown in black, the subcardinal system is stippled, the supracardinals are horizontally hatched, and vessels arising independently of these three systems are indicated by small crosses. (A) Ground plan of the veins of a young mammalian embryo. (B) Cross section (at level of arrow in A) showing dorsoventral relations of the various veins. (C) Diagrammatic plot of veins of 5-6 mm. pig embryos. (D) Arrangement of veins in

## Basic Structure of Vertebrates

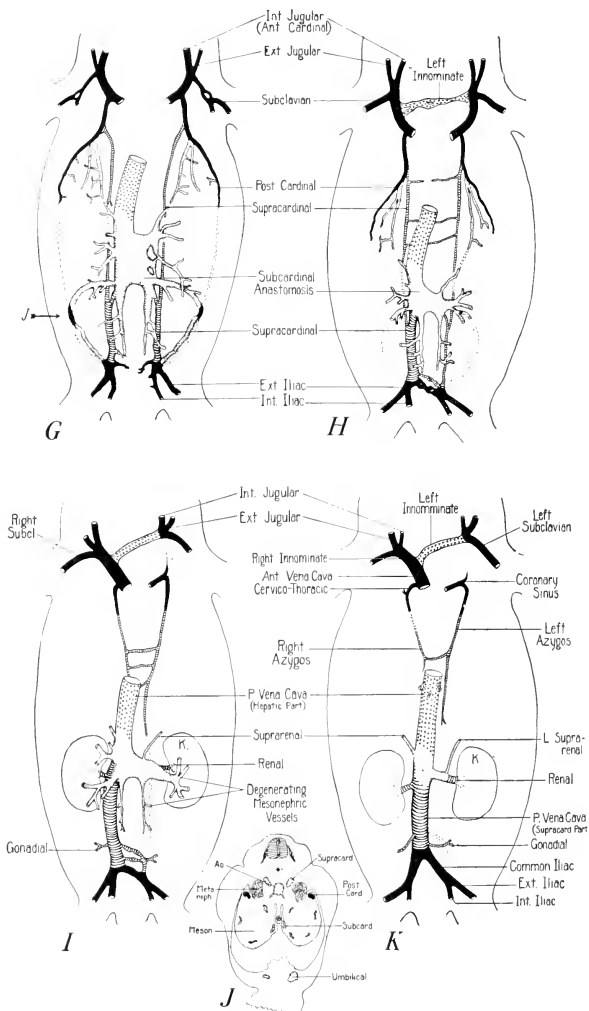


FIG. 75 — (Continued)

6-7 mm. pig embryos. (*L*) Cross section (at level of arrow in *D*) showing dorso-ventral relations of vessels. (*F*) Veins in 12-13 mm. embryos. (*G*) Veins in 16-19 mm. embryos. (*H*) Veins in 22-24 mm. embryos. (*I*) Veins in 30-35 mm. embryos. (*J*) Cross section of 17 mm. embryo at level of arrow in *G*. (*K*) Plan of veins in adult pig. (After Butler. Courtesy, Patten: "Embryology of the Pig," Philadelphia, The Blakiston Company.)

blood the excess sugar, picked up by the blood in the walls of the digestive tube, before it passes into the general circulation. This characteristic hepatic-portal system is well developed in all vertebrates.

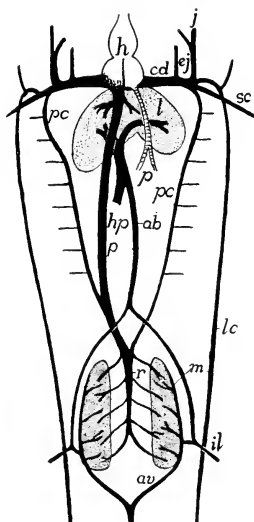


FIG. 76. Venous system of a urodele amphibian; ventral view. (*ab*) Abdominal vein; (*av*) venae advehentes; (*cd*) duct of Cuvier; (*ej*) external jugular; (*h*) heart; (*hp*) hepatic-portal; (*il*) iliac; (*j*) jugular; (*l*) liver; (*lc*) lateral cutaneous; (*m*) mesonephros; (*p*) postcava; (*pc*) postcardinal; (*r*) venae revehentes; (*sc*) subclavian. (Courtesy, Kingsley: "Comparative Anatomy of Vertebrates," Philadelphia, The Blakiston Company.)

**Renal-Portal System.** A second portal system, but less constant in its degree of development, is related to the kidneys. In fishlike vertebrates the **caudal vein** (derived from an embryonic subintestinal vein) bifurcates at the base of the tail to form right and left branches (Fig. 71A-C). Each of these, except in fishes, joins with the **iliac vein** coming in from the adjacent pelvic appendage. The resulting trunk passes

into the kidney, where it breaks up into branches ultimately passing into the renal capillary network, which is likewise the terminus of the ultimate branches of the incoming **renal arteries**. Consequently the blood circulating through the renal tissue is a mixture of arterial and venous blood and, as in the case of the hepatic-portal vein, the vein which enters the kidney, known as the **renal-portal vein**, begins and ends in capillaries. The blood emerging from the renal capillaries passes into outgoing **renal veins** (*venae revehentes*: Fig. 76) which deliver it into the **postcardinals** (Fig. 71A) or **postcava** (Fig. 71B-D). This renal-portal system, more or less well developed in vertebrate embryos, persists in the adults of fishes and amphibians and, in a somewhat reduced way, in adult reptiles and birds. In adult mammals the caudal and iliac veins do not enter the kidneys, but pass directly into the postcava (Fig. 71E).



# Excretory and Reproductive Systems

4

The excretory and reproductive systems, functionally very far apart, are closely related anatomically. This relation evidently results from the fact that the two systems have a common need—namely, passages leading to posterior exits from the body. Certain ducts are **urinogenital**.

## EXCRETORY (RENAL) ORGANS

These organs consist of systems of minute **excretory tubules** aggregated to form a pair of **kidneys** which are always situated on the dorsal wall of the abdominal cavity and close to either side of the median plane. The renal tubules are so closely adjacent to small blood-vessels as to allow waste substances to diffuse from the blood into the cavities of the tubules.

Systems of renal tubules may develop (1) at the extreme anterior end of the embryonic coelom, (2) at a more posterior position, or (3) at a still more posterior location and in a manner differing from that in which the more anterior kidneys develop. According to the position and the manner of embryonic origin, three types of kidney are recognized (Fig. 77): (1) **pronephros**, (2) **mesonephros**, (3) **metanephros**. In fishes and amphibians the definitive adult kidney may be (but rarely) a pronephros, but in most cases it is regarded as being a mesonephros. In adult reptiles, birds, and mammals, the functional kidney is a metanephros, but in the embryos there appear a vestigial pronephros and a temporarily functional mesonephros, the anterior part of which persists in the male adult as a system of tubules (the **epididymis**) transporting sperm from the testis into the sperm duct (Fig. 78C).

## REPRODUCTIVE "GLANDS"

The gonads, **ovary** and **testis**, develop as a pair of organs situated on the dorsal body-wall in the anterior region of the embryonic ab-

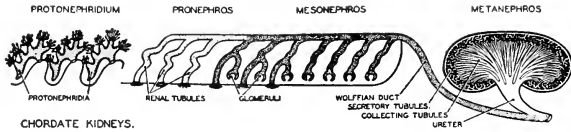


FIG. 77. A diagram illustrating the four types of kidneys which occur in chordates. The excretory tubules in *Amphioxus* are ectodermal in origin like the protonephridia of annelids, while they are mesodermal in vertebrates. In the course of phylogenesis the excretory organs of chordates have been successively pronephros, mesonephros, and metanephros. (Courtesy, Neal and Rand: "Chordate Anatomy," Philadelphia, The Blakiston Company.)

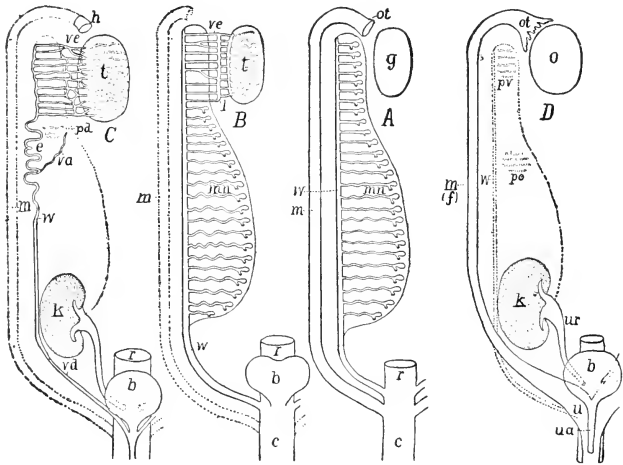


FIG. 78. Diagrams of urinogenital structures in (A) indifferent and female elasmobranchs and amphibians; (B) male elasmobranchs and amphibians; (C) male amniote (mammal); (D) female amniote (mammal). (b) Urinary bladder; (c) cloaca; (e) epididymis; (f) Fallopian tube; (g) gonad; (h) "stalked hydatid"; (k) kidney (metanephros); (l) longitudinal tubule; (m) Müllerian duct (oviduct), rudimentary in B and C; (mn) mesonephros; (o) ovary; (ot) ostium tubae abdominale; (pd) paradidymis; (po) paroöphoron; (pr) parovarium; (r) rectum; (t) testis; (u) uterus; (ua) urethra; (ur) ureter; (va) vas aberrans; (vd) vas (ductus) deferens; (ve) vasa efferentia; (w) Wolffian duct, urinary in A, urinogenital in B, genital in C, and rudimentary in D. (Courtesy, Kingsley: "Comparative Anatomy of Vertebrates," Philadelphia, The Blakiston Company.)

dominal cavity and in close relation to the developing kidneys. They may later shift to a more posterior position.

### URINOGENITAL DUCTS

Outlets for the gonads and kidneys are provided by ducts which lead into the cloaca. Two pairs of such ducts develop in nearly all vertebrate embryos, the exceptions being some fishes. In conjunction with the development of the pronephric tubules, a pair of ducts are formed, each connecting the pronephric tubules of one side of the body with the cloaca. These **pronephric ducts** extend back along the dorsal body-wall. The mesonephric tubules, developing later and just behind the pronephric tubules, acquire connection with the adjacent regions of the pronephric ducts (Fig. 77). With the eventual degeneration of the pronephric tubules, the corresponding part of each pronephric duct degenerates, or at least ceases to be concerned with the kidneys. The remaining and decidedly major part of the pronephric duct thereby becomes a **mesonephric duct**, otherwise commonly known as the "**Wolffian duct**" (Fig. 78, *w*). Meanwhile, a second duct, known as the "**Müllerian duct**," is formed lying closely lateral and parallel to each Wolffian duct and opening into the cloaca (Fig. 78, *m*). These embryonic Müllerian ducts become the functional oviducts of the female but are represented only by vestiges in adult males. The Wolffian ducts serve as renal (urinary) ducts in both sexes, and in males are urinogenital, providing outlet for both kidney and testis.

### PRONEPHROS, MESONEPHROS, METANEPHROS

The **pronephros** is functional in the free-living larvae of some fishes and of amphibians, and in the adults of a very few bony fishes. The **mesonephros** is certainly functional in the adults of the great majority of fishes and amphibians, but in many cases there is doubt as to the nature of the posterior part of the kidney in these animals, by reason of the fact that the kidney extends into the extreme posterior region of the abdominal cavity, thereby intruding into metanephric territory. The distinction between mesonephros and metanephros probably must be based more on manner of development than on position. The mesonephric tubules, formed from mesoderm just ventral to the muscle-forming myotomes (Fig. 79), acquire direct connection with the adjacent region of the prospective Wolffian duct ("primitive duct") (Figs. 77, 80, 81). Development of a typical **metanephros** is initiated by outgrowth of a forward-growing tubular branch from the cloacal end of each Wolffian duct. This pair of branches, extending forward in the dorsal body-wall, become the ureters of the prospective metanephric kidneys (Figs. 77, 82). The tubules of the metanephros are derived

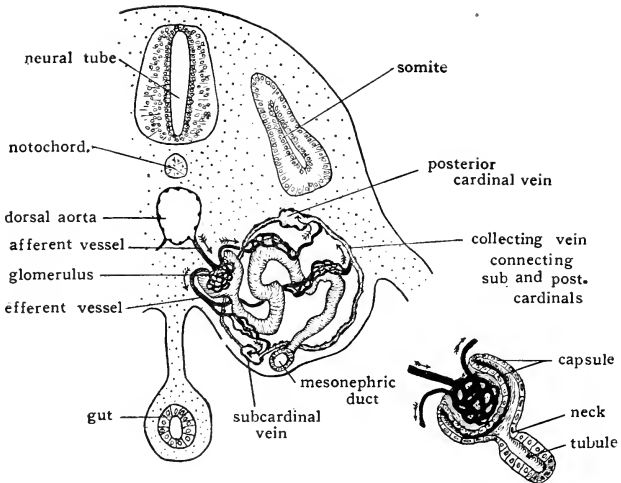


FIG. 79. Diagrams showing the relations of the blood-vessels to an embryonic mesonephric tubule. (After McCallum. Courtesy, Patten: "Embryology of the Pig," Philadelphia, The Blakiston Company.)

partly from branching outgrowths of the expanded end of the ureter (Fig. 83). These derivatives of the ureter push out into mesoderm lying posterior to that which gives rise to mesonephric tubules and differing in no obvious way from the mesonephric mesoderm. In this **nephrogenic tissue** (Fig. 82) adjacent to the end of the ureter are developed tubules each of which acquires connection with one of the tubules produced by the ureter (Fig. 84). The structures produced by the nephrogenic tissue are essential **excretory tubules**, while the tubules derived from the ureter serve to collect the excreted fluid and convey it into the ureter. In the kidney of a mammal the excretory tubules, which are very long and much coiled, constitute the outer layer, or **cortex**, of the kidney. The deeper **medulla** consists of the relatively straight and branching **collecting tubules** (Fig. 85).

In fishes and amphibians the mesonephric tubules of the embryo usually open into the coelom, the wall of the tubule being continuous with the peritoneum (Fig. 81). The aperture (**nephrostome**) is surrounded by a ciliated zone of the wall. Beating of the cilia produces a current draining fluid from the coelom into the tubule, whence it passes via the Wolffian duct out to the cloaca. This arrangement resembles the nephridial excretory mechanism of an earthworm and other inverte-

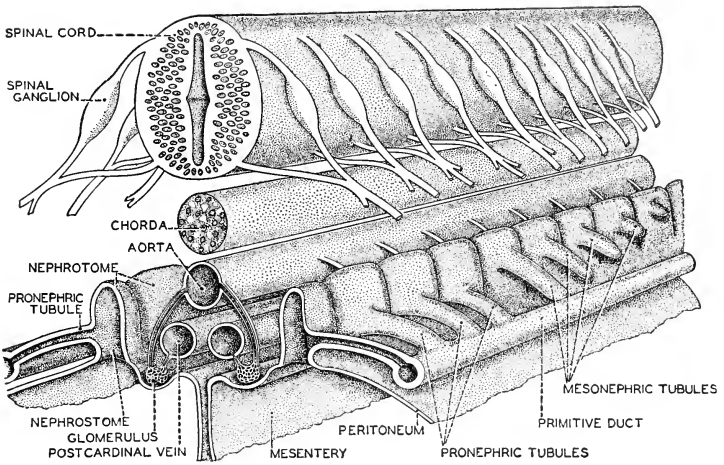


FIG. 80. Stereogram of the developing pronephros and mesonephros. The cut surface in foreground is anterior. (After Kingsley. Courtesy, Neal and Rand: "Chordate Anatomy," Philadelphia, The Blakiston Company.)

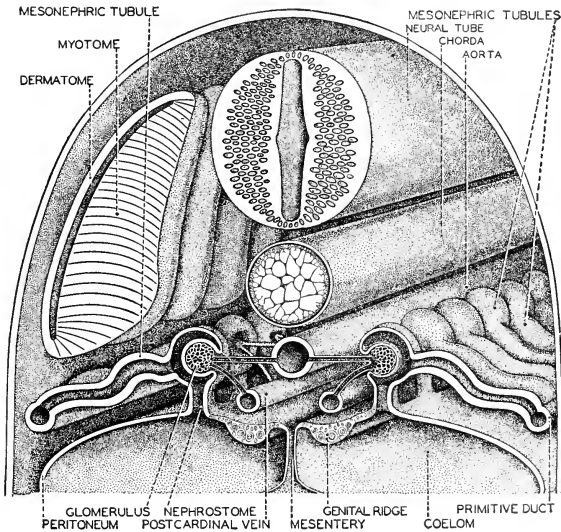


FIG. 81. Stereogram of the developing mesonephros; stage later than that of Fig. 80. (After Kingsley. Courtesy, Neal and Rand: "Chordate Anatomy," Philadelphia, The Blakiston Company.)

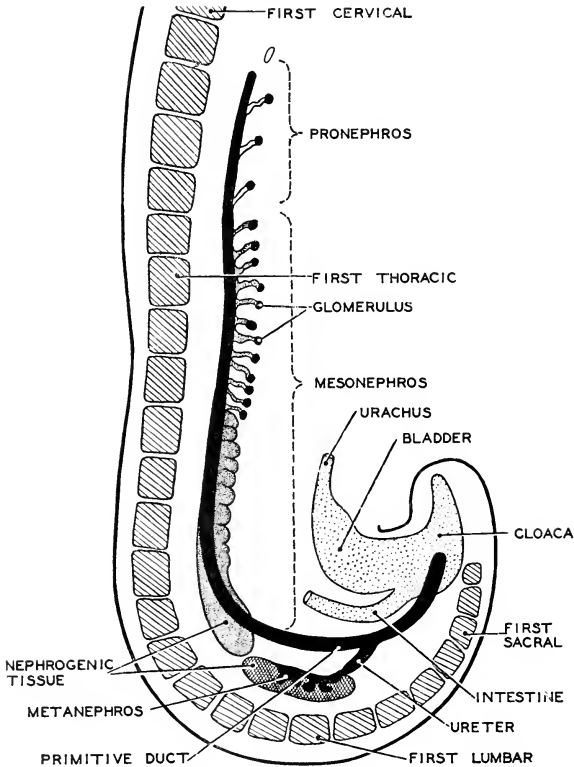


FIG. 82. A diagram of pro-, meso-, and metanephroi in a 5–6 mm. human embryo. Somites are cross-hatched. (After Braus. Courtesy, Neal and Rand: "Comparative Anatomy," Philadelphia, The Blakiston Company.)

brates. In some cases—e.g., *Necturus*—the nephrostomes persist in the adult, appearing as minute holes on the ventral surface of the kidney. Usually, however, the nephrostomes do not persist. In vertebrates other than fishes and amphibians, the embryonic mesonephric tubule ordinarily does not possess a nephrostome. The tubules of the metanephros never acquire nephrostomes.

An important excretory mechanism common to both mesonephric and metanephric tubules is the **renal** or **Malpighian corpuscle**. The tubule produces a cup-shaped expansion, **Bowman's capsule** (Figs.

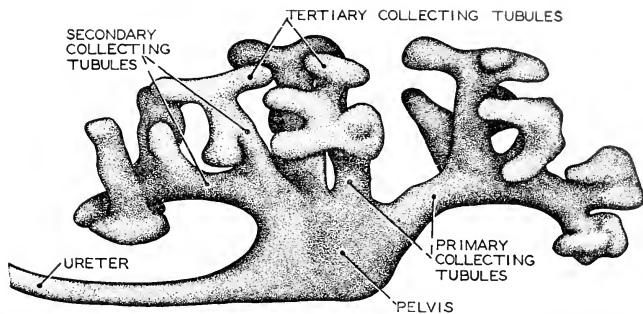


FIG. 83. The anterior expanded portion of the ureter in a 20 mm human embryo, showing the beginning of formation of collecting tubules. Anterior is to the right. (After Huber. Courtesy, Neal and Rand: "Comparative Anatomy," Philadelphia, The Blakiston Company.)

79, 86), the hollow of the double-walled cup being occupied by a dense network of fine blood-vessels, the **glomerulus**. The arrangement serves to bring a large quantity of blood into close relation to the lumen of the tubule, thus favoring diffusion of waste into the tubule. The corpuscle is situated near the nephrostome of a mesonephric tubule and on the coiled excretory segment of a metanephric tubule.

Some perplexing problems arise in the study of this series of successive vertebrate kidneys. The reason for the existence of so much complication in the performance of a relatively simple function is far from obvious. It seems likely that some very primitive vertebrates may have had a segmentally arranged series of renal tubules extending through the entire length of the abdominal cavity, a "**holonephros**," and that the several types of kidney found in modern vertebrates have resulted from local accentuation within the holonephros, accompanied by a tendency toward degeneration of its then weaker regions. But it still does not become clear why there should have been so much shifting in the locality to be accentuated. It might be urged that the extreme rear of the abdominal cavity is the appropriate place for such an organ as a kidney, but in most adult mammals the metanephros has somehow come to lie more nearly in the middle region of the cavity. The doubt as to the interpretation of the extreme posterior extension of the "mesonephros" of fishes and amphibians has led to the suggestion that this somewhat ambiguous kidney should be called an "**opisthonephros**."

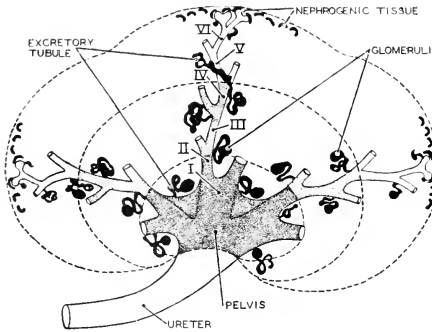


FIG. 34. A diagram illustrating the repeated branching of the collecting tubules in a nine-week (30 mm.) human embryo. Roman numerals indicate successive branchings. The diagram shows also the origin of excretory tubules from the nephrogenic tissue. (Redrawn from Braus, after Kampmeier. (Courtesy, Neal and Rand: "Chordate Anatomy," Philadelphia, The Blakiston Company.)

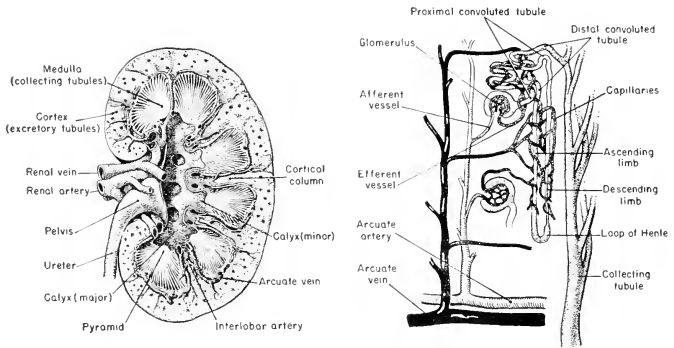


FIG. 35. Diagrams of the finer structure of a mammalian kidney. (Left) A section of the entire kidney showing the contrast between cortical and medullary regions. The relations of the chief arteries and veins are indicated. (Right) A reconstruction of a single excretory tubule, showing its relation to the glomerulus, its differentiation into a proximal convoluted region, loop of Henle, and a distal convoluted region whence it emerges from the cortex and passes on into one of the collecting tubules of the medulla. The relations of blood-vessels to the excretory structures are shown.



## ORIGIN OF MÜLLERIAN DUCT

The **Müllerian duct** presents problems. In adult females its anterior end opens into the abdominal coelom. Ripe eggs are discharged from the external surface of the ovary (exceptional conditions existing in bony fishes) into the coelom, whence they pass, via the Müllerian oviduct and cloaca, to the exterior. The funnel-like expansion of the coelomic end of the oviduct may be so closely wrapped about the ovary that the discharged eggs do not become free in the body-cavity, but they are at least potentially temporarily in the coelom.

Just as the oviduct is a passage from coelom to exterior, so do the nephrostomes of renal tubules put the coelom into communication with

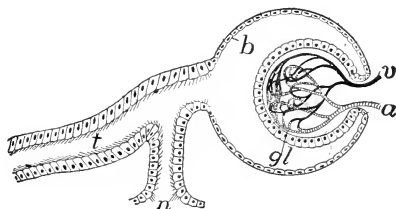


FIG. 86. Diagram of renal (Malpighian) corpuscle. (a) Artery; (b) Bowman's capsule; (gl) glomerulus; (n) nephrostome; (t) excretory tubule; (v) vein. (Courtesy, Kingsley: "Comparative Anatomy of Vertebrates," Philadelphia, The Blakiston Company.)

the exterior via the urinary ducts. The relatively few tubules of the usually briefly transitory pronephros possess nephrostomes. Very satisfactory evidence exists that, in sharks, the premesonephric region of the pronephric duct persists as the anterior region of the Müllerian duct, and that the **ostium (mouth) of the oviduct is an enlarged pronephric nephrostome**, or possibly results from fusion and enlargement of two or more nephrostomes. It has been shown, further, that during the development of the shark's mesonephros, the prospective mesonephric part of the pronephric duct splits throughout its entire length. Its more median derivative loses all connection with the pronephric duct and becomes the definitive Wolffian duct, while the more lateral derivative retains its original continuity with the premesonephric part of the pronephric duct, thus preserving a continuous passage from the coelom to the cloaca—a passage (Müllerian duct) destined to be used for transmission of eggs from the coelom to the exterior.

Amphibians give some evidence that the anterior part of the Müllerian duct is derived from pronephric structures, as seems to be true for sharks. In reptiles, birds, and mammals, the Müllerian duct develops independently of the Wolffian duct

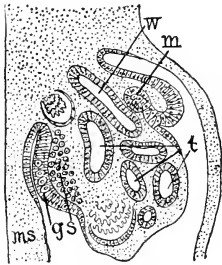


FIG. 37. Transverse section through the urinogenital region of a four-day chick embryo. (*g*) Mesodermal epithelium (peritoneum) of genital ridge; (*m*) infolding of peritoneum to form Müllerian duct; (*ms*) mesentery; (*s*) mesenchyme cells which give rise to the stroma (nongenital tissue) of gonad; (*t*) mesonephric tubules; (*w*) Wolffian duct. (After Waldeyer. Courtesy, Kingsley: "Comparative Anatomy of Vertebrates," Philadelphia, The Blakiston Company.)

usually possess vestiges of the Müllerian ducts, and adult females having the metaephros may possess vestiges of mesonephric structures.

but very closely parallel to it (Fig. 37), and there is some evidence that the anterior region and ostium of the Müllerian duct arise in very intimate relation to the pronephros. On the whole, it seems somewhat likely that the oviducts are modified derivatives of pronephric structures.

#### DIFFERENTIATION OF SEX

The vertebrate embryo, during its earlier stages of development, is anatomically indifferent as to sex. Every embryo contains the rudiments of all of the urinogenital organs of both sexes. As the gonads, in later stages, acquire their definitive differentiation as ovaries or testes, the embryonic parts appropriate to the sex indicated by the gonad likewise proceed to acquire complete and functional differentiation. But the embryonic rudiments corresponding to the other sex either cease developing and gradually dwindle away or, at most, progress only to the point of becoming relatively small and imperfectly developed parts having little or no functional significance. Adult males

# Motor System—Muscles and Skeleton

5

## I. Muscles

### GENERAL BODY-MUSCLES

The term "**body-muscle**" designates the muscles which effect locomotion and other major movements of the body or regions of it, in distinction from **visceral muscles** such as occur in the walls of the digestive tube and other internal organs. Body-muscle and visceral muscle are histologically different (see p. 96).

In an adult **fish** the body-muscle is segmented—that is, it is divided transversely into blocks or plates which constitute an anteroposterior series of similar muscular units, the **myomeres**. The muscle-fibers of the myomere extend anteroposteriorly (Figs. 88, 89). Between adjacent myomeres is a thin layer of tough fibrous connective tissue, a **myoseptum** or **myocomma**, which binds the myomeres together and transmits the pull from one to the next. The myomere is usually bent into highly complex form, so that the edges of the myoseptums, as they appear at the external surface of the body-muscle, follow sharply zig-zag lines (Fig. 89). In well-cooked fish the myoseptums are so softened that the meat readily separates into thin flakes, the myomeres. In a fish the number of segments may run into hundreds. On each side of the body a myomere is horizontally divided into a dorsal (**epaxial**) part and a ventral (**hypaxial**) part, the two being separated by a **horizontal septum** of connective tissue. In fishes the horizontal septum is approximately halfway between middorsal and midventral lines (Fig. 88C).

In **early embryonic stages of all vertebrates**, the muscle-forming mesoderm gives rise to pairs of masses lying close upon either side of the median dorsal nerve-tube and notochord and forming a series extending from head to tip of tail (Figs. 5, 90). In a fish these **mesodermal somites**, or **myotomes**, develop directly into the myomeres

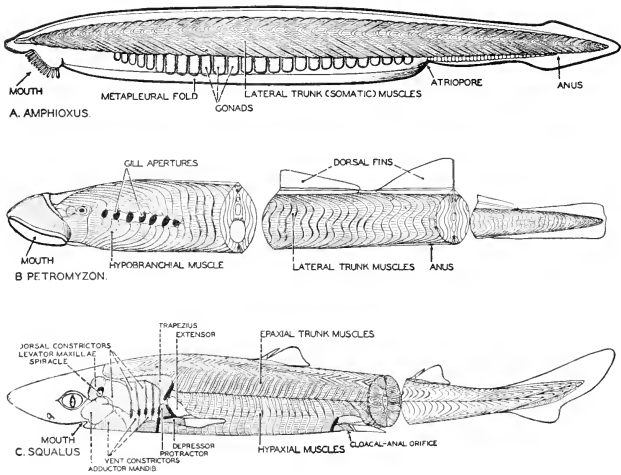


FIG. 88. The lateral trunk muscles of a cephalochordate, a cyclostome, and an elasmobranch, showing their striking metamerism and fundamental similarity. (A) *Amphioxus*. (B) *Petromyzon* (lamprey eel) (C) *Squalus* (dogfish). (Courtesy, Neal and Rand: "Chordate Anatomy," Philadelphia, The Blakiston Company.)

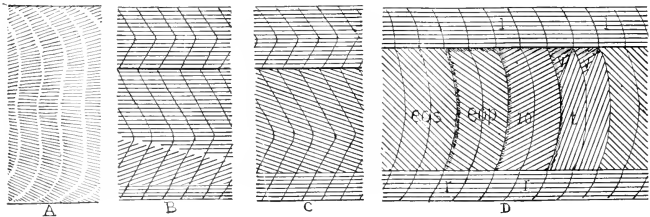


FIG. 89. Scheme of arrangement of myomeres and muscle-fibers in (A) *Petromyzon*, (B) elasmobranch, (C) teleost, and (D) urodele. (eop, eos) Deep and superficial external oblique; (io) internal oblique; (l) longissimus dorsi; (r) rectus abdominis; (t) transversus; (v) subvertebral. (Courtesy, Kingsley: "Comparative Anatomy of Vertebrates," Philadelphia, The Blakiston Company.)

of the adult. In later embryonic stages of other vertebrates, there is more or less modification of the segmental arrangement of the muscle-forming material. In amphibians and reptiles the horizontal septum is at a somewhat higher level than in fishes (Fig. 91A–B). In adult birds and mammals there is no definite septum (Fig. 91C). The epaxial muscles become concentrated along the vertebral column, with whose movements they are chiefly concerned, leaving the hypaxial regions of

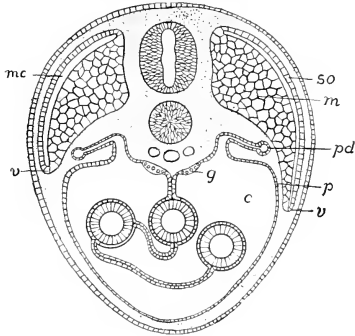


FIG. 90. Diagrammatic transverse section of the body of a vertebrate embryo at an advanced stage. The muscle-forming myotome is beginning to extend into the ventral body-wall of the embryo. (*c*) Coelom; (*g*) genital ridge; (*m*) muscle derived from myotome; (*mc*) myocoel; (*p*) peritoneum; (*pd*) pronephric duct; (*so*) somatic layer (dermatome) of somite; (*v*) advancing ventral border of myotome. The finely dotted areas are occupied by mesenchyme. (Courtesy, Kingsley: "Comparative Anatomy of Vertebrates," Philadelphia, The Blakiston Company.)

the myomeres to become the relatively thin layer of muscle of the lateral and ventral walls of the coelom. Fusion of parts of successive somites produces long muscles extending over distances of several or many of the original segments. Broad, thin sheets of muscle, such as occur in the abdominal walls (Fig. 91), may be formed, usually showing in the adult no trace of segmentation. In all vertebrates, however, the primary segmentation is retained in systems of short muscles such as those extending from one vertebra to the next or between two adjacent ribs.

The point of special significance is that, in all vertebrates from fish to man, the embryonic mesoderm which produces body-muscle (with

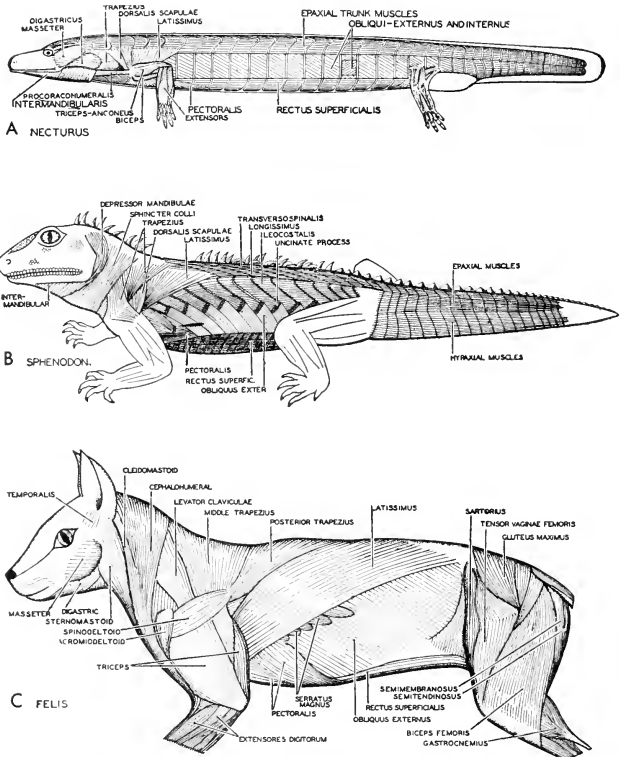


FIG. 91. Superficial lateral trunk-muscles in an amphibian, a reptile, and a mammal. (A) *Necturus*. (B) *Sphenodon*. (C) *Felis*. The metameres of the lateral trunk-muscles, which is such a striking feature of the lower vertebrates, is retained in urodeles and reptiles, but is much reduced in adult mammals. (Courtesy, Neal and Rand: "Chordate Anatomy," Philadelphia, The Blakiston Company.)

some possible exceptions in the region of the head and neck, and in the appendages) is at first definitely and completely segmented. In adults those muscles which lack obvious segmentation are, nevertheless, built up of segmented material.

## SPECIAL GROUPS OF MUSCLES

### APPENDICULAR MUSCLES

The **appendages** grow out from the trunk. Their muscles are derived from mesoderm of the trunk. In sharks the muscles of the pec-

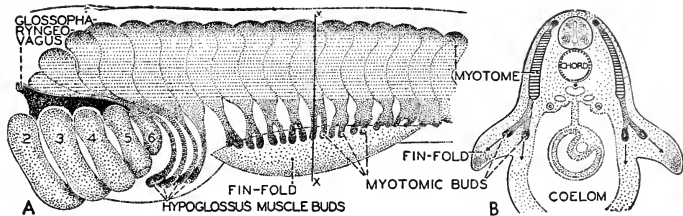


FIG. 92. Diagrams showing budding of hypoglossal- and pectoral or fin muscles from trunk myotomes in an elasmobranch embryo. (A) Lateral view after Braus, (2-6) Visceral arches. (B) Cross section in region of pectoral fin-fold. (Courtesy, Neal and Rand: "Chordate Anatomy," Philadelphia, The Blakiston Company.)

toral and pelvic fins are developed from mesoderm which grows out from several myotomes adjacent to the base of the "limb-bud" (Fig. 92). Presumably the appendicular muscles of primitive vertebrates were derived from segmented mesoderm. There is some doubt, however, as to the exact source of the appendicular mesoderm in the tetrapods. It is possible that it may be derived in part from the unsegmented ventrolateral mesoderm of the embryo—i.e., from the somatopleure which otherwise becomes the parietal peritoneum (Fig. 90, *p*).

The muscles of a **lateral fin** of a fish are few and simple (Fig. 93). These fins are ordinarily used not for propulsion but for steering and balancing. While the skeletal rays which stiffen the fin may be jointed, the protruding part of the fin works as a whole in relation to its basal skeleton or girdle, which is embedded in the muscle of the body-wall. A muscle extending from the dorsal part of the girdle onto the dorsal surface of the fin serves as an **elevator** (or **extensor**) of the fin, its action

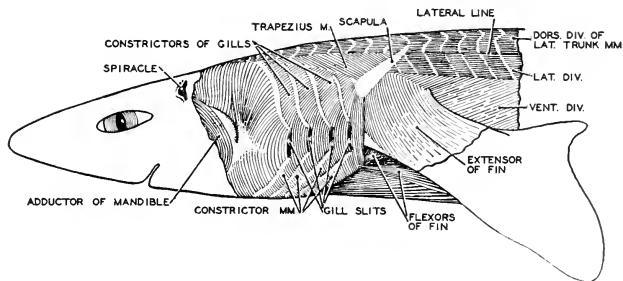


FIG. 93. The superficial muscles in the shoulder region of a dogfish, *Squalus*. (After A. Brazier Howell. Courtesy, Neal and Rand: "Chordate Anatomy," Philadelphia, The Blakiston Company.)

being opposed by a ventral **depressor** (or **flexor**). In some cases there is an anterior **abductor** which causes the blade-like pectoral fin to project from the body so that the anterior edge of the fin "cuts" the water; and there may be a posterior **adductor** which draws the fin back flat against the side of the body.

The **leg** of a **tetrapod**, in contrast to the **one-segment fin**, consists of **three major segments**—the **upper arm, forearm, and hand**

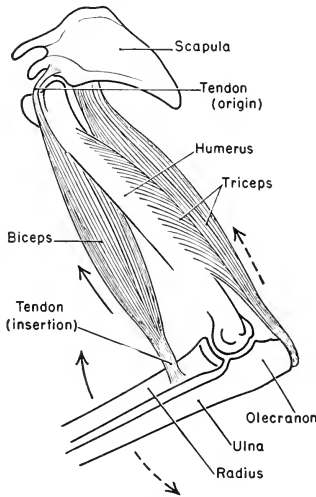


FIG. 94. Relations of the biceps and triceps of the mammalian arm. Contraction of the biceps raises or flexes the forearm at the elbow joint. Contraction of the triceps lowers or extends the forearm. The distal end of the humerus serves as a fulcrum on which the bones of the forearm (radius and ulna) work as a lever.

of man; the **thigh, shank, and foot**. The foot and hand contain numerous minor segments. The leg as a whole, like the fin of a fish, may be moved in relation to its girdle. But the numerous joints within the leg itself make possible a great variety of movements of one part of the appendage in relation to other parts. The effecting of these movements requires many muscles, and their arrangement is necessarily complex. In contrast to the three or four muscles of the fin of a fish, there are more nearly three or four scores of them in one appendage of a mammal (Fig. 91).



Certain terms are used in describing muscles. When a muscle contracts, one end (of an elongated muscle) or edge (of a sheet of muscle) remains relatively fixed and the structure to which the other end or edge attaches is moved. The fixed end or edge is called the **origin** of the muscle; the other is the **insertion** (Fig. 94). An elongated muscle is usually more or less spindle-shaped, its muscle-tissue forming a thick, "fleshy" middle region called the "**belly**," which tapers at each end into a nonmuscular **tendon** by which the muscle is attached. Muscles are usually attached to skeletal parts but in some cases attach to **fascia**, sheets of tough, fibrous connective tissue.

A distinction may be made between **extrinsic muscles** which extend between the body (in a narrow sense, exclusive of its appendages) and the appendages, and **intrinsic muscles** whose extent is confined within the territory of the appendage.

**Extrinsic muscles** may arise from the vertebral column or other parts of the body and attach to a girdle. Such are the dorsal muscles, the **trapezius** and **rhomboideus**, which move the pectoral girdle in relation to the body (Fig. 91). Other muscles arise from the body and by-pass the girdle to attach on the proximal segment of the leg; e.g., the **latissimus dorsi** has origin from numerous trunk vertebrae and inserts on the humerus (in the upper arm); the ventral **pectoralis** or "**breast muscles**" have origin upon or near the sternum and insert on the humerus (Fig. 91C). There is an important distinction, however, between pectoral and pelvic girdles. In modern tetrapods the pectoral girdle is never rigidly attached to other parts of the skeleton, while the pelvic girdle is immovably joined to the adjacent sacral region of the vertebral column. (Slight movement may be possible in some amphibians.) Therefore, in the case of the pelvic appendage, such extrinsic muscles as exist must by-pass the girdle and insert on the bone of the upper leg, the femur—e.g., the **gluteus muscles**, having origin mainly on the vertebral column (Fig. 91C).

The **intrinsic muscles**, in general, have origin on one segment, extend over one joint, and insert on the next segment. But there are many exceptions. The **biceps** of cat and man has origin on the "shoulder-blade" or **scapula** and inserts on the **radius** of the **forearm** (Fig. 94). The thick belly of the muscle lies in the upper arm. The shoulder and elbow joints are traversed by the tendons. It is true in general that bellies of muscles lie within segments of the limb and only the tendons cross the joints. Certain of the tendons which effect movements of the digits belong to muscles whose origins are on the humerus or femur, all of the joints intervening between origin and insertion being crossed by the tendons.

The numerous intrinsic muscles are described according to their

action as being **extensors, flexors, abductors, adductors, retractors, protractors, rotators, pronators** (acting to put the palm or sole down on the ground in quadrupedal locomotion), or **supinators** (rotating hand or foot so that the palm or sole is up).

#### BRANCHIOMERIC MUSCLES

The head and the branchial region of a fish are occupied by systems of muscles which are specialized in relation to the alimentary and respiratory functions of the regions. The most anterior of these muscles are attached to the **jaws**, serving to open and close them. Behind the jaws are complex sets of muscles attached to the skeletal **visceral arches** which encircle the pharyngeal region of the digestive tube. These arches strengthen the wall surrounding the pharynx and support the gills. The muscles attached to the arches effect the respiratory movements which operate to maintain a flow of water entering by the mouth and passing out through the branchial chambers (Figs. 93, 95). Sheets of superficial muscles whose fibers extend transversely act as **constrictors** of the pharynx. Small muscles extending between adjacent arches serve to shorten the pharyngeal region. Others compress it dorsoventrally. Dorsal **levators** pull the arches upward. Ventral **depressors** pull them down. In gill-breathing amphibians these respiratory muscles are reduced and simplified in connection with the reduction in the number of visceral arches and gills.

These muscles of the jaws and visceral arches have long been called "visceral muscles" because they are intimately related to the wall of the pharynx and are concerned with the visceral functions of alimentation and respiration. Also, a peculiarity of their embryonic origin sets them apart from the ordinary body-muscles of the trunk. The **body-muscles** are derived from **segmented mesoderm**, the **dorsal myotomes**. These "visceral muscles" develop from the **unsegmented ventrolateral mesoderm** which, in the region of the trunk, produces the peritoneum—both parietal and visceral—and the layers of non-striated "involuntary" muscle in the wall of the digestive tube (Fig. 90). However, they do secondarily acquire a segmented arrangement corresponding to that of the visceral arches and gill-chambers, but this secondary segmentation probably does not correspond to the segmentation of the somatic myomeres. The fibers of "visceral" muscles are striated and "voluntary" and are histologically like body-muscles. Their innervation, however, comes entirely from cranial nerves while, with very few exceptions, body-muscles are innervated by spinal nerves. All things considered, the term "visceral," as applied to the muscles of the jaws and branchial region, is misleading because it seems to ally them with the truly visceral nonstriated muscles of the wall of the di-

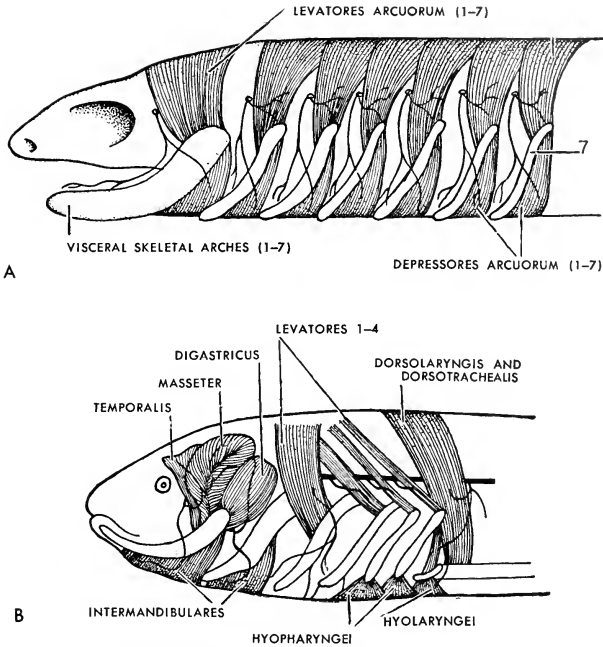


FIG. 95. Diagrams illustrating the hypothetic evolution of the branchiomeric muscles. (A) Hypothetic ancestral form. (B) Branchiomeric muscles in urodele amphibian. (Redrawn after Wilder: "History of the Human Body," New York, Henry Holt & Co., Inc.)

gestive tube. Their origin from unsegmented mesoderm does not necessarily make them "visceral." It has already been mentioned that unsegmented mesoderm of the trunk may contribute to formation of appendicular muscles. This mesoderm in the region of the coelom produces somatic (parietal) as well as visceral peritoneum, and the coelom puts a wide anatomic gap between visceral and somatic muscles. In the pharyngeal region there is no coelom, except transitory embryonic vestiges of it. In the absence of a coelomic space, the muscles in question may just as well be regarded as belonging to the body-wall as to the digestive tube, and structurally they are like somatic muscles. If they are assigned to the inner tube, a large part of the anterior lateral region of a fish is left with no body-wall except the skin.

These muscles of the jaws and respiratory region are still commonly

called "visceral," but a better name is "**branchiomic**," which implies only that such segmentation as the muscles exhibit corresponds to that of the branchial structures.

In reptiles, birds, and mammals, muscles which in embryonic origin and in innervation correspond to these branchiomic muscles of fishes can be recognized in the muscles of the jaws and floor of mouth, small muscles of the larynx and pharynx, and two still smaller ones (**stapedius** and **tensor tympani**) related to the auditory mechanism of the mammalian eardrum, and in a complex set of thin superficial **facial muscles** which effect small movements

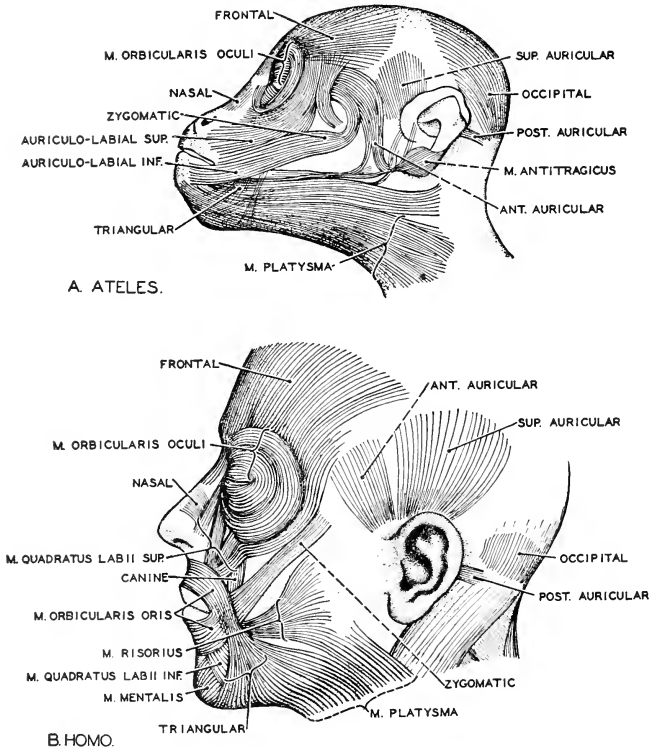


FIG. 96. Mimetic muscles in monkey (*Ateles*) and man. (A) *Ateles* (redrawn from Wilder after Ruge). (B) *Homo*. The similarity of these muscles both in function and in relations attests their similar genetic derivation. (Courtesy, Neal and Rand: "Chordate Anatomy," Philadelphia, The Blakiston Company.)

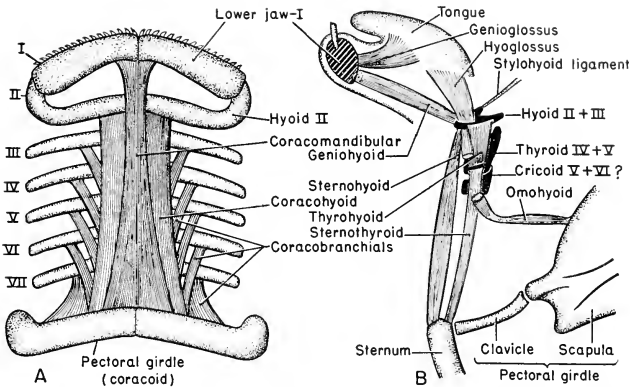


FIG. 97. Diagrammatic representation of the hypobranchial muscles. (A) Shark ventral view. (B) Mammal: left side view.

of the skin (Fig. 96). Even the **trapezius**, an extensive and important superficial dorsal muscle of the pectoral appendage, has, at least in part, been assigned to this group. To call the human facial muscles "visceral" seems a perversion of the term. "Branchiomeric" relieves the vertebrate of the embarrassment of having numerous visceral parts externally exposed.

#### HYPOBRANCHIAL MUSCLES

These are ventral muscles which, in fishes, extend longitudinally forward from the pectoral girdle and are attached in various ways to the ventral parts of the several skeletal arches of the pharyngeal region and to the lower jaw (Fig. 97). Although situated in close relation to the branchiomeric muscles, the **hypobranchial** muscles are typically **somatic**. They are produced by extension of several embryonic myotomes downward and forward (Fig. 92A), and retain traces of their segmental origin. Judging by embryonic origin and innervation, these hypobranchial muscles of the fish correspond to certain ventral muscles (**hypoglossal**) of the throat and muscles of the tongue in higher vertebrates.

#### EYE-MUSCLES

The eyeball is moved in its orbit by six muscles (described in the account of the cranial nerves on p. 162). These are striated voluntary muscles innervated by cranial nerves. They are derived from the most anterior three pairs of myotomes of the embryo (Fig. 5). They must

therefore be regarded as highly specialized body-muscles. The first myotome produces the four muscles which are supplied by the third (oculomotor) cranial nerve. From the second and third myotomes come, respectively, the muscle supplied by the fourth (trochlear) and the one supplied by the sixth (abducent) nerve.

#### SUBCUTANEOUS (INTEGUMENTAL) MUSCLES

These are thin sheets or slips of muscle which split off from superficial muscles of the body and acquire attachment to the skin. The skin of a fish is quite firmly adherent to the body. The layer of highly elastic subcutaneous connective tissue intervening between the dermal layer of mammalian skin and the surface of the adjacent muscle makes possible some movement of the mammal's skin in relation to the body-muscles. Subcutaneous muscles have their **origin** on external surfaces of body-muscles, or on such skeletal parts as are near the external surface, and have their **insertion** on the inner surface of the dermal layer of the skin. Their contraction causes the skin to slide over the surface of the body-muscle.

Subcutaneous muscles are most highly developed in mammals, but are represented in birds and, to a small extent, in reptiles. In many mammals a very thin sheet of muscle, the **panniculus carnosus**, spreads over a large part of the surface of the body. It seems to have been derived by cleaving off from certain muscles which have extensive superficial exposure, the **latissimus dorsi** above and the ventral **pectoralis** (Fig. 91C). The **sphincter colli** of reptiles (Fig. 91B), birds, and mammals is a subcutaneous sheet investing more or less of the neck, the fibers of the muscle extending transversely to the neck. The **platysma** of mammals (Fig. 96), an extensive subcutaneous sheet covering more or less of the lower part of the side of the face and neck, is probably derived from the sphincter colli. Many of the thin superficial **facial muscles**, best developed in man (Fig. 96), are essentially subcutaneous in nature. These facial muscles, together with the platysma and sphincter colli, in their general location and in being innervated by the seventh (facial) cranial nerve, correspond to superficial parts of the **branchiomerie** group of fishes.

The subcutaneous muscles are striated and "voluntary." They enable the animal to wrinkle and twitch the skin. Their action is well exemplified by the horse as it twitches the skin of an area where a fly has alighted. The extensive **panniculus** possessed by the hedgehog and armadillo assists the animal in its defensive act of curling itself into a ball. The human facial muscles serve for small movements of the lips and nose and to close the eyelids and wrinkle the forehead. They are, in general, "muscles of expression."

## II. Skeleton

The substance of living tissue is relatively soft. Minute aquatic organisms may have no supporting or protective structures aside from the delicate cell-membrane. Large animals would be impossible without skeletons. Among invertebrates, with few exceptions, skeletal structures are external, consisting of hard substance secreted by the skin. The shell of mollusks is **calcareous**. Arthropods have a **cuticular exoskeleton**, consisting essentially of a secreted nitrogenous substance, **chitin**.

Such exoskeletons as those of invertebrates impose a limit on the size of an animal. A lobster as large as an elephant would be mechanically difficult, if not impossible—certainly impossible if it were necessary for the elephantine arthropod to go through an occasional molting stage leaving it temporarily in a "soft-shelled" condition. Many vertebrates possess **exoskeletal structures** of one sort or another—the calcareous scales of fishes; the dermal bony plates of some ancient amphibians and of alligators, turtles and the armadillo; the thick, horny scales of reptiles and of the mammalian pangolin. The superficial dermal bones of the skull are, in a broad sense, exoskeletal. But in the great majority of modern vertebrates there is no extensive development of external skeletal structures to serve for mechanical support and protection.

The present place held by vertebrates in the organic world and the vast size and power attained by so many of them are due in no small measure to the mechanical advantages accruing to them from the fact that their essential and characteristic skeleton is internal. With increase in the size of an animal, a supporting exoskeleton becomes increasingly inefficient, but an **endoskeleton** may be reinforced and amplified to make it adequate for the larger and heavier animal. An ancient and basic mechanical contrivance is the lever. The vertebrate skeleton is, for the most part, a system of levers. To each of these power is applied by muscles appropriately placed in relation to the fulcrum, which is the joint at which the part moves. In the jointed legs of arthropods, the muscles are *inside the skeleton*, an arrangement which has mechanical limitations. The vertebrate leg, with its freely jointed skeletal parts, and muscles working on all sides of a joint, achieves a maximum of free mobility.

In addition to the fact that the vertebrate skeleton is internal, it is unique as to the nature of the materials of which it is constituted and as to the manner of its embryonic development and its growth (see Chap. 7). Three quite different kinds of material enter into the composition of the skeleton. The **notochord** consists of a soft, highly vacuolated

cellular tissue which owes its supporting capacity to the fact that it is enclosed by a tough and elastic fibrous sheath. **Cartilage** is a solid material somewhat resembling moderately hard rubber in consistency and texture and in being usually somewhat elastic. It consists essentially of a complex protein substance secreted by cells which remain permanently embedded in it. **Bone** consists mainly of calcareous substance, which makes it harder and more rigid than cartilage. Its histologic structure is much more complex than that of cartilage (see pp. 323-327).

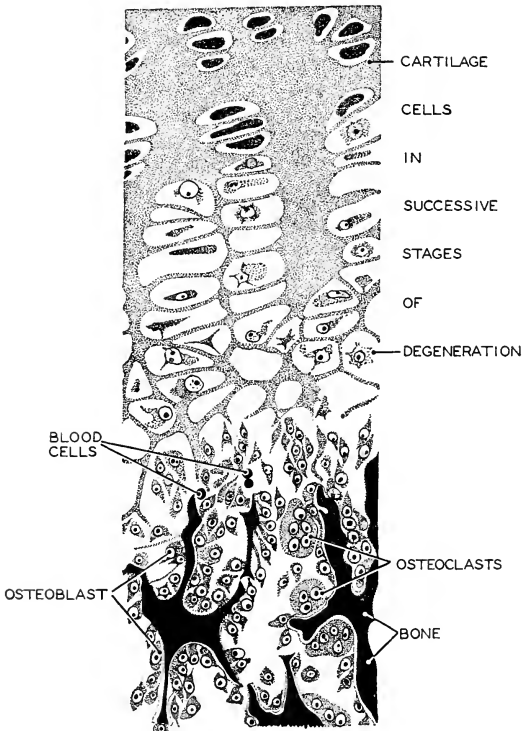


FIG. 98. Formation of endochondral bone at the end of a long bone. Destruction of cartilage is followed by the deposition of lime in the form of thin lamellas. Osteoblasts then lay down bone upon these lamellas. In this way cancellous bone replaces cartilage. (After Dahlgren and Kepner. Courtesy, Neal and Rand: "Chordate Anatomy," Philadelphia, The Blakiston Company.)



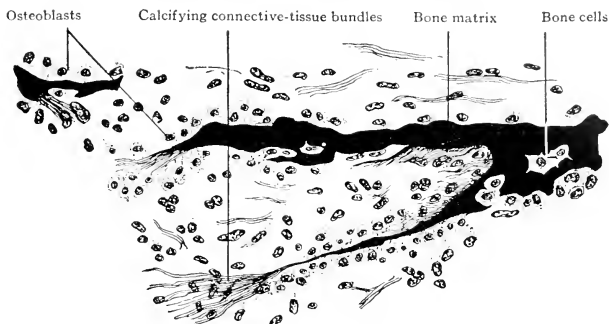


FIG. 99. Development of dermal (secondary) bone from mesenchyme. From a section of the mandible of a human embryo of four months. ( $\times 210$ .) (Modified from Bremer: "A Text-Book of Histology," Philadelphia, The Blakiston Company.)

Depending on method of development, two kinds of bone are distinguished. In one the skeletal structure is first formed in cartilage in the early embryo. Later the cartilage is invaded by bone-forming tissue, gradually destroyed, and eventually entirely replaced by bone (Fig. 98). Bones developing in this way are called "**cartilage bones**" or "**replacing bones.**" **Membrane-bones** are produced directly by embryonic tissue, not preceded by cartilage (Fig. 99). Most membrane-bones develop in deep extensions of the embryonic tissue which otherwise produces the dermal layer of the skin, and are accordingly called "**dermal bones.**" Membrane-bones are often called "**investing**" bones because they commonly develop closely adjacent to cartilage or cartilage-bones, as when the embryonic cartilaginous lower jaw becomes "invested" by thin sheets of dermal bone. Whether of cartilage or bone, the growth of vertebrate skeletal parts requires no periodic "molting." The growth of the skeleton keeps pace consistently with that of the whole animal.

In general, skeletal structures serve for mechanical **protection** from impact of external agencies, or for **support** of internal parts, or for **attachment of muscles.** The protective function of the vertebrate skeleton is most important in relation to the central nervous organs (the brain and spinal cord) and to such delicately constructed sense-organs as the **olfactory** (organ of smell), **eye,** and **ear.** Some bones of the skull are protective only. The long bones of a limb provide internal support and serve for attachment of muscles. The vertebral column provides protection for the spinal cord dorsally and, in the tail, to the caudal blood-vessels ventrally. It is important also as a longi-

tudinal supporting axis for the body, and its surfaces are thickly beset with the attachments of the numerous muscles which effect the bending movements of the body and of some muscles which move the limbs.

In all of the major movable parts of a vertebrate—the trunk, tail, and paired limbs—skeletal structures constitute the axis of the part. The muscles are disposed around the skeletal axis. The head can be moved as a whole only in relation to the trunk. Even in such minor parts as digits, the skeleton is axial and the muscles are external to it.

### SKELETON OF NOTOCHORDAL AXIS

There are vertebrates without backbone or vertebral column, but every vertebrate possesses a skeletal structure which is the chief mechanical axis of the body.

One of the earliest organs to develop in a vertebrate embryo is the **notochord**, which appears as a median longitudinal cylindrical rod of cells lying dorsal to the embryonic digestive cavity and ventral to the developing central nervous organs (Figs. 100, 133). In later stages each

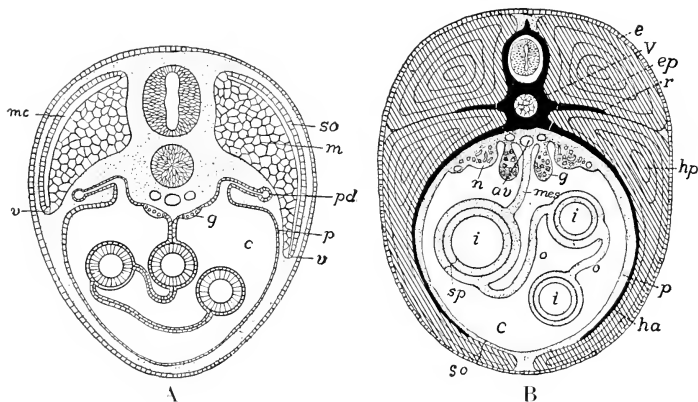


FIG. 100. (A) Diagrammatic transverse section of the body of a vertebrate embryo at an advanced stage. The muscle-forming myotome is beginning to extend into the ventral body-wall of the embryo. (c) Coelom; (g) genital ridge; (m) muscle derived from myotome; (mc) myocoel; (p) peritoneum; (pd) pronephric duct; (so) somatic layer (dermatome) of somite; (v) advancing ventral border of myotome. The finely dotted areas are occupied by mesenchyme.

(B) Diagrammatic transverse section of the body of an adult vertebrate. (av) Aorta; (c) coelom; (e) ectoderm; (ep) epaxial (dorsal) muscle; (g) gonad; (ha) hemal rib; (hp) hypaxial (ventral) muscle; (i) intestine; (mes) mesentery; (n) kidney; (o) omentum; (p) somatopleure; (r) rib; (so) (sp) splanchnopleure; (v) centrum of vertebra and, above it, neural arch containing spinal cord. (Courtesy, Kingsley: "Comparative Anatomy of Vertebrates," Philadelphia, The Blakiston Company.)

cell becomes greatly distended by a fluid-filled vacuole, and the entire rod is invested externally by a tough, fibrous sheath (Fig. 101). The texture of the notochord combines firmness and elasticity. Mechanically it resembles a length of rubber tubing with closed ends and filled with fluid. It supports but also bends readily. **It is never segmented.**

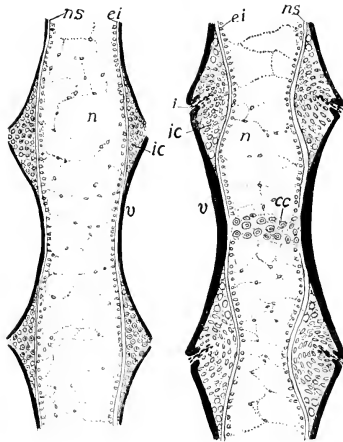


FIG. 101. Longitudinal sections of developing vertebrae of the amphibian, *Ambystoma*. (Left) Earlier. (Right) Later. Cartilage and bone are forming around the notochord. (*cc*) Cartilage in center of vertebra; (*ei*) epitheloid internal elastic sheath of notochord; (*i*) incisure cutting through (*ic*) intercental (intervertebral) cartilage; (*n*) notochord; (*ns*) outer notochordal sheath; (*v*) developing bone (black) of centrum of a vertebra. (Courtesy, Kingsley; "Comparative Anatomy of Vertebrates," Philadelphia, The Blakiston Company.)

The notochord persists throughout the life as the functional axial skeleton of the fishlike round-mouthed eels (cyclostomes). In its functional estate, it may be studied to advantage in the tail of the full-grown tadpole of frog or toad. It serves as the embryonic foundation around which a cartilaginous vertebral column may be developed (Fig. 100B), as happens in all vertebrates except the cyclostomes. In vertebrates with backbones, the bone replaces the cartilage of the embryonic cartilaginous vertebral column. Traces of the notochord may persist between successive vertebrae.

This embryonic sequence of skeletal materials and the very indirect mode of development of a backbone raise perplexing questions. Why should a notochord develop in mammals, even in man? Why should a somewhat elaborate cartilaginous vertebral column be built up in the embryo only to be obliterated and replaced by bone? Bones *can* develop without being preformed in cartilage.

#### VERTEBRAL COLUMN

A single unit of the backbone is a **vertebra**. The structure of vertebrae varies depending on the region of the vertebral column in which the vertebra occurs and the animal to which the column belongs. Certain basic features, however, are common to all vertebrae except those which are more or less reduced (e.g., the vestigial vertebrae in the distal region of a tail), or those which become specialized in relation to some local peculiarity of function in the column (e.g., the one or two anterior vertebrae of the neck, which are concerned with the support and movement of the skull). Cartilaginous vertebrae, such as those of sharks, have the same general form as bony vertebrae.

The main body of a vertebra is the **centrum**, usually solid and approximately cylindrical (Figs. 102, 103, 104). It lies ventral to the spinal cord and in the position of the embryonic notochord, which it replaces. The articulating surfaces of centra may be concave, convex, or flat. An **amphicoelous** centrum has both surfaces concave (as in most fishes); a **procoelous** centrum is concave in front; an **opisthocoelous** centrum is concave behind; if flat at both ends, it is called "**amphiplatyan**" (Fig. 104). The spaces between successive amphicoelous centra may be occupied by persisting remnants of the embryonic notochord. Dorsally, a centrum is surmounted by a **neural arch** through whose aperture, the **vertebral canal**, extends the spinal cord. The apex of the arch is more or less prolonged upward to form a **neural spine**. Caudal vertebrae also usually have a **hemal arch** depending from the ventral surface of the centrum and enclosing the caudal artery and vein (Fig. 103). The hemal arch may be prolonged downward to form a **hemal spine**.

In a cartilaginous vertebral column such as occurs in sharklike fishes, the spaces between successive neural arches are filled by cartilaginous plates known as **interdorsals** (Figs. 105, 106). Similarly, in the tail, the spaces between hemal arches are filled by **interventral** cartilages. All of the parts in these cartilaginous columns are closely tied together by fibrous connective tissue. Consequently, the spinal cord and caudal blood-vessels are completely surrounded by vertebral structures. There are, in a strict sense, no joints in such a vertebral column. Bending is not localized at intervertebral joints but involves

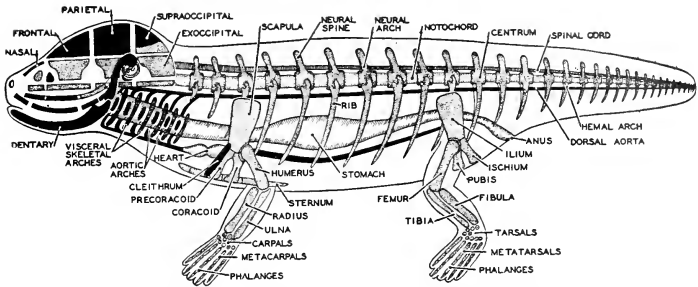


FIG. 102. A diagram of the vertebrate skeleton. Membrane-bones are shown in black, cartilage-bones stippled. (Courtesy, Neal and Rand: "Chordate Anatomy," Philadelphia, The Blakiston Company.)

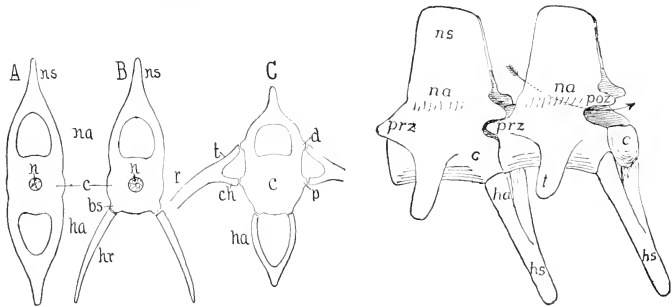


FIG. 103. (Left) Diagrams of (A, B) fish vertebrae and (C) vertebra from higher groups. (bs) Basal stumps; (c) centrum; (ch) capitular head of rib; (d) diapophysis; (ha) hemal arch; (hr) hemal rib; (n) notochord; (na) neural arch; (ns) neural spine; (p) parapophysis; (r) rib; (t) tubercular head. (Right) Two caudal vertebrae of the alligator. (c) Centrum; (ha) hemapophysis; (hs) hemal spine; (na) neuropophysis; (ns) neural spine; (poz, prz) post- and prezygapophyses; (t) transverse process. The arrow passes through the neural arch. (Courtesy, Kingsley: "Comparative Anatomy of Vertebrates," Philadelphia, The Blakiston Company.)

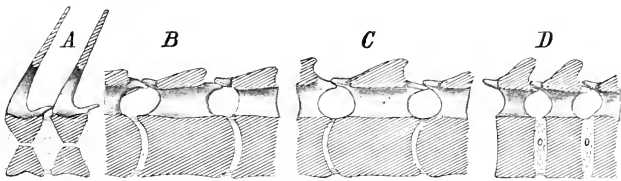


FIG. 104. Diagrammatic sagittal sections of (A) amphicoelous, (B) procoelous, (C) opisthocelous, and (D) amphiplatyan vertebrae. Anterior is at the left. Cut surfaces are obliquely lined. (Courtesy, Kingsley: "Comparative Anatomy of Vertebrates," Philadelphia, The Blakiston Company.)

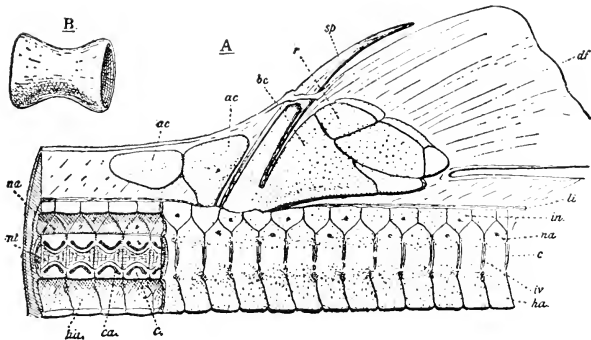


FIG. 105. *Squalus vulgaris*, Risso. (A) Dorsal fin and portion of the vertebral column; four anterior (at left) vertebrae are cut in sagittal section. (*ac*) Anterior cartilages (either modified radials or neural spines); (*bc*) basal cartilage; (*c*) centrum; (*ca*) calcified cylinder; (*df*) dorsal fin; (*ha*) hemal arch; (*in*) interdorsal cartilage; (*li*) intervertebral ligament; (*li*) dorsal ligament; (*na*) neural arch; (*nl*) notochord; (*r*) radial cartilage; (*sp*) fin spine, with base cut away to expose cartilage core. The cartilage is dotted. (B) Calcified cylinder of a centrum. (From Goodrich: "Studies on the Structure and Development of Vertebrates." By permission of The Macmillan Company, publishers.)

the structure as a whole, being made possible by the inherent elasticity of all of the vertebral materials. Since bone is rigid, a bony vertebral column must have joints.

Bony vertebrae bear various projecting processes, most of them serving for attachment of muscles.

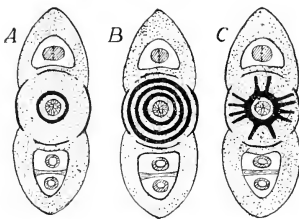


FIG. 106. Diagrammatic sections of elasmobranch vertebrae. (A, B) Cyclospondylous. (C) Astero-spondylous (Courtesy, Kingsley: "Comparative Anatomy of Vertebrates." Philadelphia, The Blakiston Company.)

Most constant are a pair of **transverse processes** projecting laterally from the sides of the centrum (Fig. 103). A second pair of transverse processes may project laterally from the lower region of the neural arch. Also, there are usually accessory articulating processes, **zygapophyses**, consisting of a pair of **prezygapophyses** projecting forward from the anterior face of the neural arch and articulating with a pair of **postzygapophyses** projecting backward from the posterior face of the neural arch of the adjacent vertebra (Figs.

103, 104). Other processes, less common in occurrence, may be present on either the centrum or the neural arch.

Inspection of the vertebral processes gives an experienced anatomist much information concerning the disposition of muscles along the column. The length of its spines and processes is an indication of the extent to which the vertebra is used for attachment of muscles. The

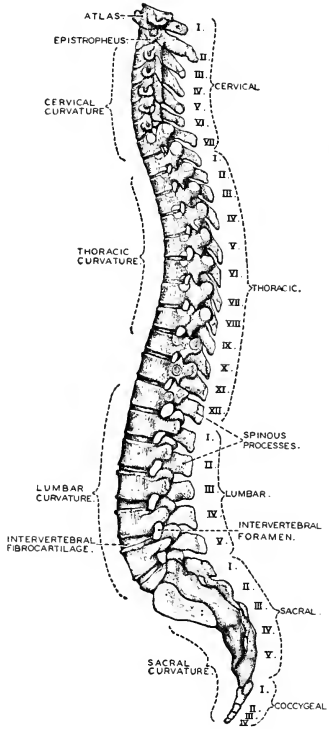


FIG. 107. The human vertebral column viewed from the left side. (After Sobotta. Courtesy, Neal and Rand: "Chordate Anatomy," Philadelphia, The Blakiston Company.)

leverage or "pull" which a muscle may exert in relation to the fulcrums, which are the intervertebral joints, varies with the length of the process—i.e., with the distance from the muscle's point of attachment to the axis of the centrum. The thickness of a process indicates the intensity of the strain which it must sustain. The slope of the process in relation

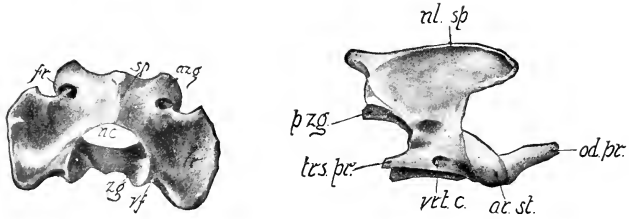


FIG. 108. (Left) Dorsocaudal aspect of atlas. (*azg*) Anterior articular process; (*fr*) aperture of the transverse foramen which enters the atlas at (*vf*); (*nc*) neural canal; (*sp*) spinous process; (*tr*) transverse process; (*zg*) posterior articular process.

(Right) Lateral aspect of the epistropheus (axis). (*ar. st.*) Anterior articular process; (*nl. sp.*) neural spine or spinous process; (*od. pr.*) odontoid process; (*p. zg.*) posterior articular process; (*trs. pr.*) transverse process; (*vrt. c.*) transverse foramen. (Courtesy, Stromsten: "Davison's Mammalian Anatomy," Philadelphia, The Blakiston Company.)

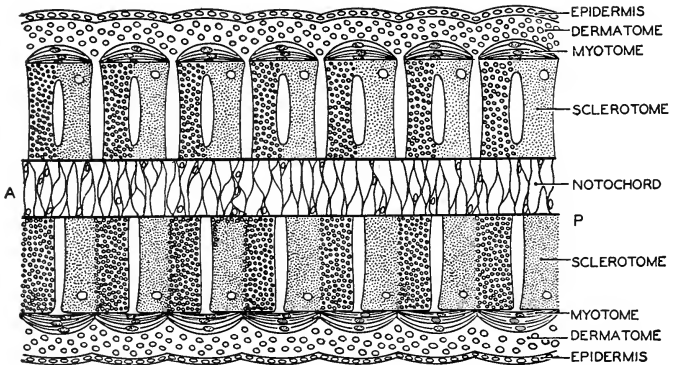


FIG. 109. A diagram showing the relations of myotomes and sclerotomes as seen in a horizontal section of a vertebrate embryo. (A) Anterior; (P) posterior. The upper half of the figure shows the relations in an earlier stage of development, while the lower half represents a later stage. The posterior half (finely dotted) of each sclerotome unites with the anterior half (coarsely dotted) of the following sclerotome to form a centrum. Thus the centra alternate in position with the myotomes and each myotome becomes attached to two vertebrae. (Courtesy, Neal and Rand: "Chordate Anatomy," Philadelphia, The Blakiston Company.)



to the axis of the column suggests the direction of the dominant strain exerted upon the process. A complete vertebral column (Fig. 107), viewed with special attention to the processes of its vertebrae, is virtually a three-dimensional diagram of the mechanical stresses sustained by its various parts.

Except in fishes, the first one or two vertebrae of the column are more or less modified in relation to the support and movement of the skull. The first vertebra, called the **atlas** (in ancient Greek mythology a giant named "Atlas" bore the world upon his shoulders), articulates with the one or two rounded prominences, **condyles**, carried by the occipital bones at the rear of the skull. In reptiles, birds, and mammals, the atlas is a bony ring consisting mainly of a neural arch and having only a vestige of a centrum (Fig. 108A). In the embryo, the atlas develops a centrum consisting (as is usual in other vertebrae) of two parts, a larger **pleurocentrum** and a small **hypocentrum**. But in the later embryo, the pleurocentrum becomes separated from its own vertebra and fuses onto the anterior face of the centrum of the second vertebra, leaving only the hypocentrum as permanent property of the atlas. The annexed pleurocentrum forms a knoblike process (Fig. 108B) which projects forward into the lower part of the large aperture in the ring-shaped atlas—i.e., into the place where the first centrum should be. Known as the **odontoid process**, it serves as a pivot on which the atlas (and the skull with it) may rotate. The second vertebra is accordingly called the **axis** (or **epistrophæus**).

Numerically, vertebrae usually correspond to the myomeres to which the column is immediately adjacent but, in position, the vertebrae and the myomeres alternate (Fig. 109). The **vertebrae are intersegmental**. The middle of a centrum is opposite a myoseptum. This arrangement is necessary, at least for such short muscles as retain the primitive segmentation (e.g., as in fishes). To cause bending at a vertebral joint, a muscle must be attached to the two vertebrae involved in the joint. An exceptional condition is found in the tail of sharklike fishes and a few others, where the number of vertebrae is doubled—i.e., within a given region there are twice as many vertebrae as myomeres. The vertebrae are complete and typical in structure although they may be shorter than those elsewhere in the column. This condition, known as "**diplospondyly**," doubtless increases the flexibility of the tail—important because most fishes use the tail as a stern propeller, bending it sharply back and forth laterally.

#### CRANIUM

At the anterior end of the vertebral column, the central nervous cord contained within its neural arches continues forward and expands

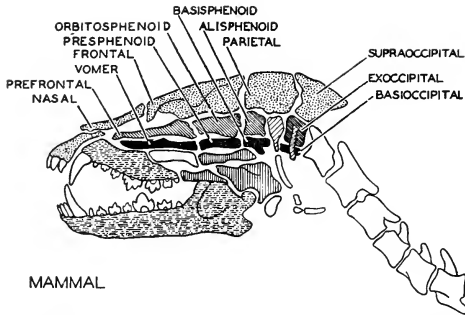


FIG. 110. One of Owen's figures illustrating the Goethe-Oken vertebral theory of the skull. Owen regarded the mammalian skull as constituted of four enlarged and highly modified vertebrae (their centra shown in solid black). (After Wilder. Courtesy, Neal and Rand: "Chordate Anatomy," Philadelphia, The Blakiston Company.)

into the more complex brain. Similarly, the axial skeleton continues forward and becomes elaborated into a suitable protective structure, not only for the brain but also for the three pairs of important sense organs of the head, the nasal organs, eyes, and ears. This anterior terminus of the axial skeleton is the **cranium**, a part of the skeletal complex known as the "skull." In the structure of the cranium are features which suggested to the early anatomists that it is virtually a series of expanded and modified vertebrae. Thus the atlas articulates with the ventral portion of a complete ring constituted of four bones. A massive midventral bone, the **basioccipital**, underlies the rear part of the brain. At each side the basioccipital joins an **exoccipital** and the ring is completed dorsally by the **supraoccipital** (Fig. 110). This whole **occipital arch** of four bones can be imagined to be a vertebra, its centrum being the basioccipital surmounted by a "neural arch" enclosing the central nervous organ. The arrangement of cranial bones anterior to the occipital ring is such as to suggest a series of two or three more modified vertebrae. The vertebral column is concerned primarily with muscular action, but incidentally affords protection to the overlying central nervous organ. The cranium serves mainly as protection for the brain and is to a relatively small extent concerned with muscles. Leaving aside questions of interpretation, the cranium is mechanically or functionally a continuation of the vertebral column. The main axial skeleton of a vertebrate consists of a longer **vertebral part** which serves as the mechanical axis of neck, trunk, and tail, and a shorter **cephalic part**, the **cranium**.

## RIBS AND STERNUM

**Ribs** are elongated skeletal parts (cartilaginous or bony) attached to the vertebral column and projecting laterally into the body-wall. They strengthen the body-wall and provide attachment for muscles. They develop in the connective tissue between myomeres or parts of myomeres. They are at first cartilaginous but, except in sharklike fishes, are more or less completely ossified in the adult. Two types of ribs are distinguished, depending mainly on the relation of the rib to the body-muscle. A **dorsal** (or “true”) **rib** arises from a vertebra at the level of the horizontal septum—i.e., between the epaxial and hypaxial parts of a myomere—and extends outward and downward in a myoseptum—i.e., between two myomeres (Fig. 100B). A **ventral** (or **pleural** or **hemal**) **rib** arises at a lower level on a vertebra and extends



FIG. 111. Vertebrae and ribs of (left) anterior and (right) posterior trunk region of *Polypterus*. (*h*) Hemal rib; (*p*) pleural rib. (After Gegenbaur. Courtesy, Kingsley: "Comparative Anatomy of Vertebrates." Philadelphia, The Blakiston Company.)

downward at the intersection of a myoseptum with the peritoneum, therefore internal to the hypaxial muscle and closely adjacent to the peritoneum. A vertebra carries only one pair of dorsal ribs or one pair of ventral ribs, but ribs of both kinds may occur on one vertebra.

In the great majority of vertebrates, the ribs are of the dorsal type. Of modern vertebrates, only the fishes possess ventral ribs, and they are the characteristic ribs of most fishes. But the relatively short cartilaginous ribs of sharklike fishes are dorsal, and ventral ribs are lacking. Some fishes (e.g., sturgeon and gar pike—"ganoid" fishes) have ventral ribs only, while in many fishes both series of ribs are present (Fig. 111). In many of the so-called "bony fishes," one or more pairs of riblike **intermuscular bones** may be attached to a vertebra in addition to its two pairs of ribs. These intermuscular bones, however, usually develop as direct ossifications of myoseptal connective tissue—i.e., they are membrane bones. With this multiplicity of ribs and riblike appendages of the vertebrae, many fishes become excessively "bony."

The **ventral ribs**, in their relations to vertebrae and to the divisions of the body-muscle, resemble the lateral parts of **hemal arches**. Both are situated internally to the body-muscle. The ribs partially, or sometimes almost completely, encircle the coelom and all of its enclosed viscera, but never actually join ventrally. The hemal arch surrounds the only visceral structures present in the tail—i.e., the caudal blood-vessels—and is complete ventrally.

Most fishes have well-developed ribs on all the trunk vertebrae and even on the more anterior caudal vertebrae. In the land vertebrates, the ribs tend to become more or less reduced or vestigial except in the anterior trunk (thoracic) region, where they are an important part of the mechanism of breathing.

The **sternum** is a midventral skeletal structure situated in the anterior region of the body-wall of the trunk. It develops as cartilage and may be permanently cartilaginous, as in some amphibians and many reptiles, or may become more or less completely ossified. It may consist of one or several parts (Fig. 112). A dermal bone, the **epi-sternum** or **interclavicle**, is joined to the anterior end of the sternum of some reptiles (lizards and crocodilians) and of primitive mammals

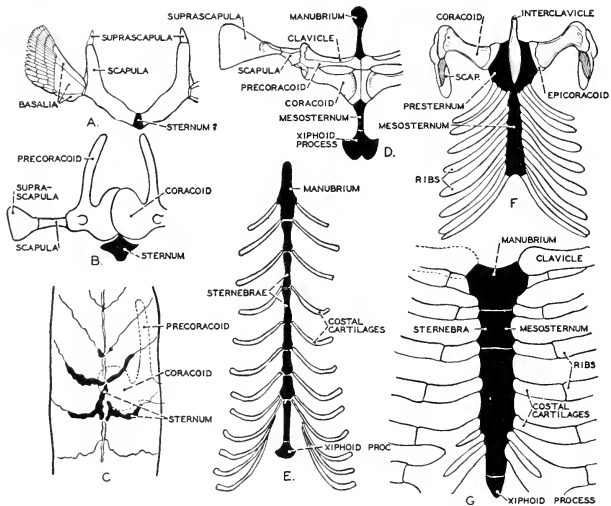


FIG. 112. Types of vertebrate sterna. (A) *Squalus*. (B) *Salamandra*. (C) *Neoturus*. (D) *Rana*. (E) *Felis*. (F) *Crocodilus*. (G) *Homo*. The sternum is shown in black. (Courtesy, Neal and Rand: "Chordate Anatomy," Philadelphia, The Blakiston Company.)

(Fig. 112F). In reptiles, birds, and mammals, a varying number of thoracic ribs are attached to the sternum (Fig. 112) so that the thorax is completely enclosed by a skeletal frame—vertebral column above, sternum below, and pairs of ribs connecting them. Also the skeleton of the forelegs usually has a connection with the anterior end of the sternum. But legless animals such as snakes have no sternum. The so-called “sternum” of amphibians has no connection with the very short dorsal ribs—a fact which throws doubt on the correspondence of the amphibian “sternum” with that of other vertebrates. Fishes have no sternum. The sternum is evidently primarily related to terrestrial locomotion and to air-breathing.

### SKULL

The **skull** is usually thought of as being the skeleton of the head. Strictly defined, however, it must be made to include a series of skeletal rings or arches which develop in close relation to the pharynx and lie rather more in the territory of the neck than in that of the head. Defined thus, the **skull** consists of the **cranium** (already referred to as being the anterior terminal division of the skeleton of the notochordal axis, and enclosing the brain and organs of smell, sight, and hearing) and the **visceral arches** which primarily surround (partially) the digestive tube. In a shark (Fig. 113) the cranium and the visceral skeleton have so little connection with one another that it would seem more reasonable to regard them as two quite distinct skeletal structures rather than as together constituting a “skull.” In contrast to a shark, an adult reptile or mammal (Fig. 114) has a skull whose many parts are so completely unified into a compact whole that there is no obvious reason for regarding it as a duplex thing. But its embryonic history reveals its double origin.

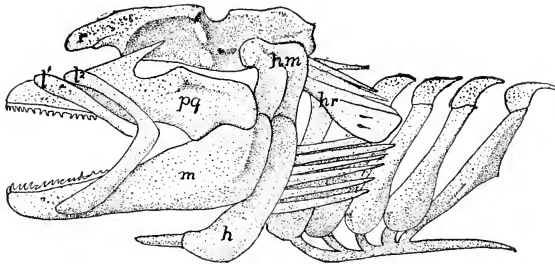


FIG. 113. Skull of a shark, *Squatina*. (*h*) Hyale; (*hm*) hyomandibula; (*hr*) hyomandibular rays; (*l*, *l*<sup>2</sup>) labial cartilages; (*m*) mandibular (Meckel's) cartilage; (*pq*) pterygoquadrate; (*r*) rostrum. (After Gegenbaur. Courtesy, Kingsley: "Comparative Anatomy of Vertebrates," Philadelphia, The Blakiston Company.)

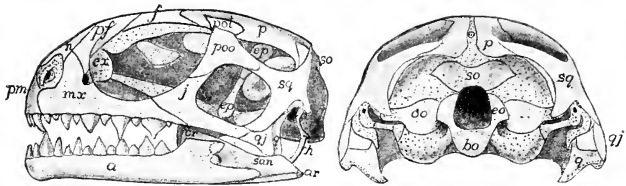


FIG. 114. Side and posterior views of skull of young *Sphenodon*. Cartilage is dotted. (a) Dentale; (ar) articular; (bo) basioccipital; (cr) coronoid; (eo) exoccipital; (ep) epiterygoid; (ex) extranasal; (f) frontal; (h) hyoid; (j) (jugal) zygomatic; (mr) maxilla; (n) nasal; (oo) opisthotic; (p) parietal; (pf) prefrontal; (pm) premaxilla; (pof) postfrontal; (poo) postorbital; (q) quadrate; (qj) quadratojugal; (san) supra-angular; (so) supraoccipital; (sq) squamosal. (After Howes and Swinerton. Courtesy, Kingsley: "Comparative Anatomy of Vertebrates," Philadelphia, The Blakiston Company.)

#### CHONDROCRANIUM

At an early stage of a vertebrate embryo, whether shark or mammal, the anterior end of the dorsal neural tube begins to elaborate itself into a brain. Meanwhile the outermost embryonic layer, the ectoderm, gives rise to a pair of ingrowing sacs which lie in close relation to the anterior end of the brain. These sacs are the prospective **nasal** or **olfactory organs** (Fig. 115A). Another pair of ectodermal sacs develop, each of them lying lateral to the hind part of the brain. These are destined to form the internal sensory parts of the **ears**. Skeletogenous tissue becomes concentrated about the brain and each of the four sacs. It builds a cartilaginous case enclosing the brain ventrally and laterally but more or less incomplete dorsally. Each olfactory sac becomes enclosed in a cartilaginous **olfactory capsule**, and each otic (referring to the ear) sac acquires an **otic capsule**. Later, as all of these structures increase in size, the two pairs of capsules become joined to the brain-case, and eventually all five parts are unified to form one skeletal structure whose cartilaginous wall is continuous throughout, showing no traces of the separate origin of the several parts (Figs. 115B, C, 116). This structure is the cranium or **chondrocranium** (**chondrin** being the essential protein constituent of cartilage). Its middle narrower part is the **brain-case**. The wider anterior region contains the olfactory organs, and the annexed otic capsules occasion the prominent lateral projections at its posterior region. In the roof of the brain-case there may be one or more large openings known as "**fontanels**," while laterally and ventrally there are small **foramens** which serve for exit of nerves connected with the brain. From the posterior end of the brain, the spinal cord emerges through a large median posterior aperture in the cranial wall, the **foramen magnum**.

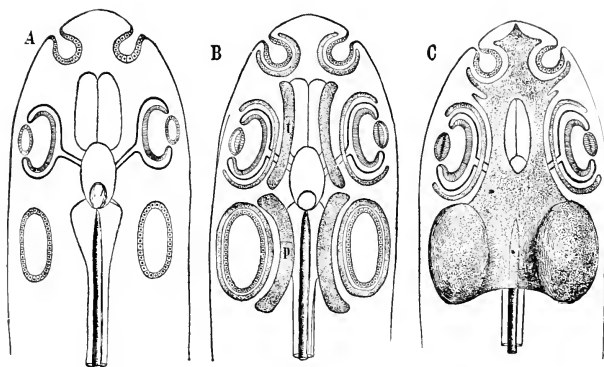


FIG. 115. Diagrams showing the development of the primordial skull. Ventral aspect. (A) Early stage, before the appearance of cartilage. The notochord is seen lying along the nerve-cord as far forward as the hypophysis. The three sense-organs, nasal sac, eye, and ear, have already appeared. (B) This stage shows the trabeculae (*t*), the parachordals (*p*), and the cartilaginous capsules around the sense-organs. (C) In this the trabeculae, the parachordals, and the nasal and otic capsules have fused into a single mass, the primordial skull, or chondrocranium. The anterior end of the notochord is embedded in it. The cartilaginous capsule of the eye remains free to allow the necessary movements of the eyeball. (Courtesy, Wilder: "History of the Human Body." New York, Henry Holt & Co., Inc.)

The **eyes** are not enclosed within the cranium. The essential nervous part of the eye, the **retinal layer** of the eyeball, is developed by outgrowth from the middle region of the brain. This outgrowth occurs before the cranium begins to develop. The prospective retinal material acquires the form of a hollow hemisphere, and this "**optic cup**" (Fig. 115A) is connected with the brain by a slender **optic stalk**. The optic cup becomes surrounded by embryonic tissue (derived from the middle embryonic layer, the mesoderm) which is potentially skeletogenous. It builds around the optic cup a supporting and protective layer, the **sclera** (Fig. 115B, C), which in most vertebrates is to a greater or less extent cartilaginous, and in many reptiles and birds the cartilage may even ossify to form small **bony plates** (**sclerotic bones**—Fig. 369). In most mammals, however, the sclera consists only of dense fibrous connective tissue. The sclera, especially when it is cartilaginous, resembles the capsules of the olfactory and otic sacs. It differs from them in that it does not become joined to the brain-case—a quite intelligible difference, because the eyeball must be free to move. The eyeball does, however, derive much protection from the cranium because it lies in a lateral recess, the **orbit**, between the laterally projecting nasal capsule in front and the otic capsule behind.

## VISCERAL SKELETON

The **visceral skeleton**, as seen in embryonic stages of all vertebrates and in adult sharklike fishes, consists of a series of cartilaginous rings or "**arches**," each more or less completely encircling the anterior region of the digestive tube (Figs. 116, 117, 120). The first or most anterior arch is close behind the oral aperture and constitutes the upper and lower jaws, therefore (at least in the adult) completely surrounding the digestive tube. It is called the "**mandibular arch**." The second, or **hyoid arch**, is just behind the mandibular. It is incomplete dorsally, extending from the ventral side of each otic region of the cranium downward to the midventral line. The remaining arches, placed in close succession to one another behind the hyoid arch, attain their maximum development in fishes, serving mainly for the support of the gills and hence called "**branchial arches**." They are all incomplete dorsally. The several visceral arches alternate in position with the pharyngeal respiratory apertures of the gill-breathing vertebrates and with the pharyngeal pouches of the embryos of land vertebrates. In sharklike fishes, the **spiracle**, a modified gill-cleft, passes between the mandibular and hyoid arches; the first branchial cleft is between the hyoid and the first branchial arch; and the gill-clefts and arches alternate thus to the posterior end of the series (Fig. 116).

The maximum **number** of visceral arches occurs in a genus of shark, **Heptanchus**, having a pair of spiracles and seven pairs of gill-clefts and, accordingly, nine visceral arches. In most fishes the number of arches is seven or six, but in some cases less.

(There is frequent confusion in the use of the names of the arches. They are **all visceral arches**. The **mandibular** is the **first visceral**, the **hyoid** is the **second visceral**, the **first branchial** is the **third visceral**, and so on.)

Each arch is divided into several parts. The embryonic **mandibular arch** consists, on each side, of one elongated dorsal cartilage called the "**palato-pterygo-quadrato**." This cumbersome name is derived from the fact that the palatine, pterygoid, and quadrato bones of the upper jaw are derived from the cartilage or in close relation to it. The embryonic lower jaw consists, on each side, of a slender cartilage known as the **mandibular** (or **Meckel's**) **cartilage**. The **hyoid arch** consists, on each side, of a dorsal **hyomandibular cartilage** (**hyomandibula** or **pharyngohyal**) and below it, in the order mentioned, an **epihyal**, a **ceratohyal**, and a **hypohyal**. The two hypohyals join a midventral **basihyal**. In the **branchial arches** the maximum number of parts in an arch is nine—four pairs and a median ventral part (Fig. 118). Named in order from above downward, they are the **pha-**



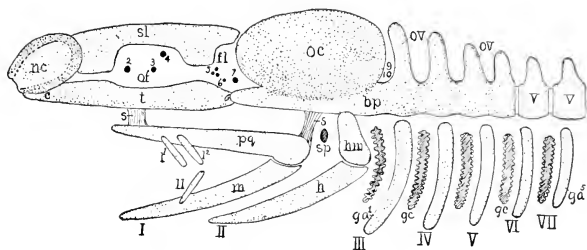


FIG. 116. Diagram of early elasmobranch skull. (*bp*) Basal plate; (*c*) trabecular cornu; (*fl*) foramen lacerum; (*ga*<sup>1-5</sup>) gill arches; (*gc*) gill cleft; (*h*) hyale; (*hm*) hyomandibula; (*l*, *l'*) upper labials; (*ll*) lower labial; (*m*) mandibular (Meckel's) cartilage; (*nc*) nasal capsule; (*oc*) otic capsule; (*of*) orbital foramen; (*ov*) occipital vertebrae; (*pq*) pterygoquadrate; (*s*) suspensor ligament; (*sp*) spiracle; (*sl*) sphenolateral; (*t*) trabecula; (*v*) vertebrae; (I-VII) visceral arches; (1-10) cranial nerves. (Courtesy, Kingsley: "Comparative Anatomy of Vertebrates," Philadelphia, The Blakiston Company.)

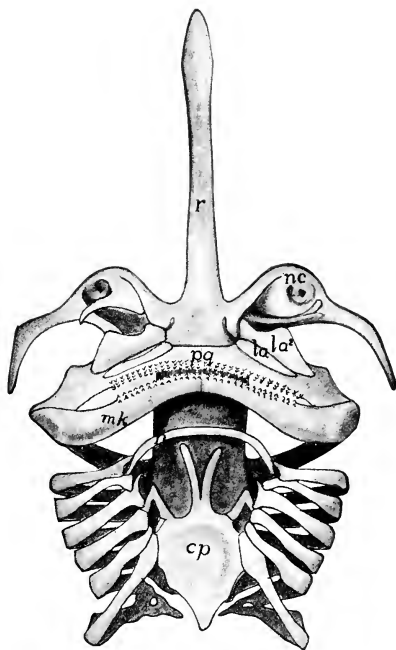


FIG. 117. Ventral view of cranium and visceral arches of skate (*Raia*) after Gegenbaur. (*cp*) Copula; (*h*) hyoid; (*hm*) hyomandibula; (*la*) upper labials; (*mk*) mandibular (Meckel's) cartilage; (*nc*) nasal capsule; (*pq*) pterygoquadrate; (*r*) rostrum. (Courtesy, Kingsley: "Comparative Anatomy of Vertebrates," Philadelphia, The Blakiston Company.)

ryngobranchial, epibranchial, ceratobranchial, and hypobranchial, and the median basibranchial. In the hyoid and branchial arches there is a tendency toward

reduction in the number of parts and fusion of parts, especially in the posterior region of the series. There may be much fusion in the longitudinal series of basibranchials.

The cranium is a quite immobile structure. Therefore the wall of a cartilaginous cranium may be continuous throughout. The walls of the mouth and pharynx must be capable of executing the movements required for swallowing and, in gill-breathers, for maintaining the respiratory flow of water through the branchial chambers. Therefore the visceral arches must consist of parts free to move in relation to one another. The somewhat elaborate set of **branchiomerics** extending in various ways between parts of the visceral skeleton provides for the necessary movements.

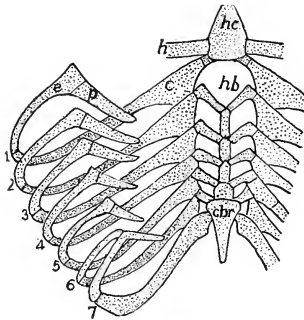


FIG. 118. Branchial arches of a shark, *Heptanchus*. (*c*) Ceratobranchial; (*cbr*) cardiobranchial (posterior basibranchial); (*e*) epibranchial; (*h*) hyoid; (*hb*) hypobranchial; (*hc*) hyoid copula; (*p*) pharyngobranchial; (1-7) branchial arches. (After Gegenbaur. Courtesy, Kingsley: "Comparative Anatomy of Vertebrates," Philadelphia, The Blakiston Company.)

#### BONY SKULL

The foregoing account of the skull has concerned itself mainly with the cartilaginous skull as it appears in vertebrate embryos and in adult sharklike fishes. In the great majority of vertebrates, the adult skull is more or less completely bony. Transformation of the cartilaginous skull into a bony skull is effected by two quite distinct but closely coördinated processes: ossification of the cartilage to form **cartilage-bones** or "replacing bones," and development of **dermal bones** which are always external or superficial in relation to the cartilaginous elements—therefore "investing bones." In "ganoid" fishes (e.g., sturgeon), the dermal scales of the head fuse to form large bony plates whose arrangement is closely similar to that of the dermal bones of the skulls of tetrapod vertebrates. Presumably, therefore, the dermal bones of the skull have been derived from bony scales of primitive fishes (Fig. 119).

The **bony skull** is an exceedingly complex structure and presents a bewildering array of adaptive modifications in the various groups

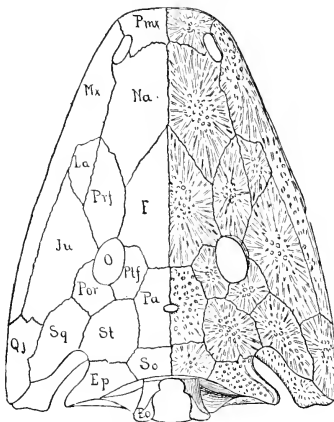
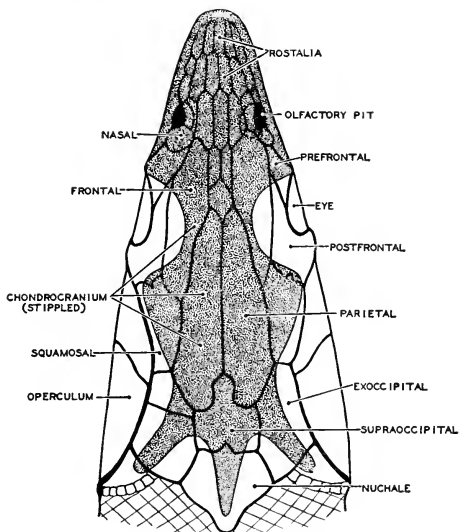


FIG. 119. (Top) The head of a sturgeon, viewed from above as a translucent object. Membrane-bones (scutes) are outlined, and the inner cartilaginous cranium stippled. Comparative anatomy identifies certain scutes as homologs of bones in the mammalian skull. (After Gegenbaur. Courtesy, Neal and Rand: "Chordate Anatomy," Philadelphia, The Blakiston Company.)

(Bottom) Skull of an ancient stegocephalan amphibian (*Capitosaurus*). (*Ec*) Exoccipital; (*Ep*) tabulare; (*F*) frontal; (*Ju*) zygomatic (jugal); (*La*) lacrimal; (*Mx*) maxilla; (*Na*) nasal; (*O*) orbit; (*Pa*) parietal; (*Pmx*) premaxilla; (*Por*) post-orbital; (*Prf*) prefrontal; (*Ptf*) postfrontal; (*Qj*) quadratojugal; (*So*) dermooccipital; (*Sq*) squamosal; (*St*) supratemporal. (After Zittel. Courtesy, Kingsley: "Comparative Anatomy of Vertebrates," Philadelphia, the Blakiston Company.)

Table 1  
CHIEF BONES OF SKULL OF RECENT VERTEBRATES

		The cross (X) indicates that the bone is present in the group named at top of column. But it may not be present in every animal of that group.										
		Much doubt and divergent opinion exist concerning homologies of some bones of the skull, especially dermal bones. The accuracy of this table is not to be regarded as complete and final.										
		Fish	Amphibian	Reptile	Bird	Mammal	Man					
CRANIAL BONES	OCCIPITAL ARCH	1 Basioccipital m	X	X	X	X	Fused to form single OCCIPITAL BONE					
		2 Exoccipital l	X	X	X	X						
		3 Supraoccipital* m	X	X	X	X						
	PARIETAL ARCH	4 Basisphenoid m	X	X	X	X	Constituents of complex SPHENOID BONE					
		5 Alisphenoid l	X	X	X	X						
	FRONTAL ARCH	6 Parietal l	X	X	X	X	Constituents of complex SPHENOID BONE					
		7 Presphenoid m	X	X	X	X						
		8 Orbitosphenoid l	X	X	X	X						
	REGION of EAR	9 Frontal l	X	X	X	X	Petrosal	Fused to form TEMPORAL BONE				
		10 Prootic	X	X	X	X						
11 Opisthotic		X	X	X	X							
12 Epiotic		X	X	X	X							
REGION of ORBIT	13 Squamosal	X	X	X	X	X	X					
	(Circumorbitals)											
	14 Postorbital	X	X	X	X							
	15 Postfrontal	X	X	X	X							
	16 Supraorbital	X	X	X	X							
	17 Prefrontal	X	X	X	X							
NASAL REGION	18 Lacrimal	X	X	X	X	X	X					
	19 Ethmoid† m and l	X	X	X	X							
ROOF of MOUTH	20 Nasal	X	X	X	X	X	X					
	21 Parasphenoid m	X	X	X	X							
	22 Vomer	X	X	X	X	X	X					
		Pterygoid, palatine, maxillary extend into roof of mouth										
VISCERAL SKELETAL ARCHES	MANDIBULAR ARCH	Upper Jaw	23 Quadrate	X	X	X	Incus	INCUS				
			24 Pterygoid*†	X	X	X			X	Pterygoid processes on sphenoid		
			25 Palatine	X	X	X					Malar	MALAR
			26 Quadratojugal	X	X	X						
		27 Jugal§	X	X	X	X	X					
		28 Maxillary	X	X	X			Malleus	X			
		29 Premaxillary	X	X	X					X	Fused with temporal	
		30 Mandibular Cartilage	X	X	X							X
	Lower Jaw	31 Articular	X	X	X	X	X					
		32 Dentary	X	X	X			X	Fused with temporal			
		33 Angular	X	X	X					X	X	
		34 Supra-angular	X	X	X							X
	35 Splenial	X	X	X	X	X						
	36 Coronoid	X	X	X			X	X				
	HYOID ARCH	Dorsal	37 Hyomandibula	X					X	X	Columella	
			38 Symplectic	X					X	X		Stapes
39 Interhyal		X	X	X	A variable number of ventral hyoid elements	HYOID BONE m						
40 Epiphyal		X	X	X			X	X				
Ventral	41 Ceratohyal	X	X	X					X	X		
	42 Hypohyal	X	X	X							X	X
	43 Basihyal m	X	X	X	X	X						
BRANCHIAL ARCHES	44 Maximum number in adult	7	4	2			1	1	1			
			Additional and more posterior arches are represented in cartilages of larynx and perhaps of trachea									
OPERCULUM of FISHES	45 Operculum	X					Probably not represented in vertebrates above fishes					
	46 Preoperculum	X										
	47 Interoperculum	X										
	48 Suboperculum	X										

Cartilage bones are in bold-face type; dermal bones in italics.

l, bones which are lateral and paired; m, a median bone. All bones not otherwise designated are lateral and paired.

\* Cartilage bone more or less augmented by addition of dermal bone.

† A name which (with appropriate prefixes) applies to two or more bones which are closely related in origin and position; e.g., mesethmoid, ectethmoid; entopterygoid, metapterygoid, etc.

‡ Homology of alisphenoid and vomer of mammals with alisphenoid and vomer, respectively, of lower vertebrates is questionable.

§ The position of the jugal is ambiguous. Its dorsal edge commonly forms more or less of the ventral border of the orbit (Fig. 121). Therefore it may be regarded as a circumorbital bone.

(Modified from Rand, "Comparative Anatomy of Vertebrates," Harvard University Press, 1929.)

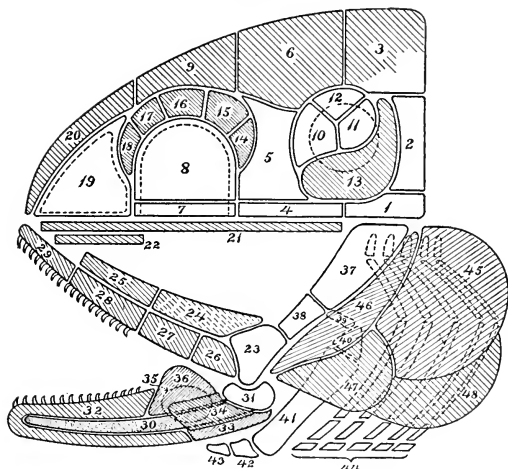


FIG. 120. General plan of the skull. With the exception of some elements of comparatively rare occurrence, all the bones that occur in any skull are indicated in the diagram. But the skull of no one animal would contain all the bones there shown. The figure represents a side view. All the elements of one half of the skull, including those that are actually dorsal or ventral in position, are brought into view. The diagram aims to express correctly the essential facts regarding the positional relations of the elements. It conveys nothing as to their form and size. Dermal bones are cross-lined. The numbers refer to the table on p. 122.

In this diagram the general relations of cranium and visceral arches are such as obtain in a bony fish. In higher vertebrates the bones of the upper jaw are annexed to the floor and side regions of the cranium, more or less enclosing and obscuring the true cranial elements (see Fig. 121).

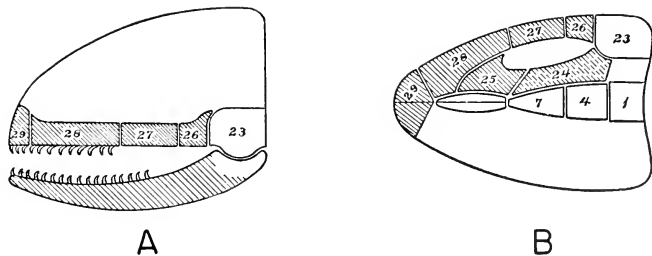


FIG. 121. Diagrams showing the relations of the jaws to the cranium in a reptile. The true cranial elements and the elements of the lower jaw are not fully indicated. (A) Side view. (B) View of the roof of the mouth.

of vertebrates. Such skulls as those of a codfish, frog, snake, bird, and whale are so different in appearance that a casual observer could hardly suspect that they possess any basic similarity. The truth is, however, that careful analysis of skulls, different as they may be, reveals a general plan or "pattern" which is common to all of them. Bones which may be identified as corresponding parts of various skulls maintain constant spatial relations to one another. The differences between two skulls are due mainly to differences in shape and size of corresponding bones or to addition or omission of bones, but not to changes in the spatial relations of the bones that are present. The "pattern" is constant, but its constituent parts are highly modifiable. The present purpose will be best served by describing the "pattern" rather than any particular skulls.

Throughout the following description of the bones of the skull, constant reference should be made to the diagrams (Figs. 120, 121), and to Table 1 related to them (see p. 122).

#### *Bones of Cranium*

In the **bony cranium**, as already mentioned, may be recognized a series of segments or, better, "arches," since they certainly do not correspond to the segments of the vertebral column or body-muscle (Fig. 110). That they do not is proved by the fact that, during embryonic development of the chondrocranium, several of the adjacent cartilaginous vertebrae ("**occipital vertebrae**") fuse with the hind end of the cranium and with one another, eventually being completely and unrecognizably incorporated into its occipital region (Fig. 116).

At the posterior end of the cranium is the **occipital arch**, consisting of a **basioccipital**, a pair of **exoccipitals**, and a **supraoccipital**. These are all cartilage bones except that the supraoccipital may be augmented by dermal ossification. Anterior to the basioccipital is a **basisphenoid** flanked laterally by a pair of **alisphenoids**. These three are cartilage bones. The arch is completed dorsally by a pair of dermal bones, the **parietals**—hence it is called the "**parietal arch**." Anterior to the basisphenoid may be a narrow median **presphenoid** joined laterally to a pair of **orbitosphenoids**, which form a part of the wall of the orbit. The three sphenoids are cartilage bones and this **frontal arch** is completed by a dorsal pair of dermal bones, the **frontals**. The frontals lie over the region of the orbit. The remaining anterior or **nasal region** of the cranium (Fig. 120, 19, 20) is not so definitely archlike. The embryonic cartilage ossifies to form a somewhat complex group of **ethmoid bones**, the mesethmoid being the partition between right and left nasal cavities and an **ectethmoid** forming the upper part of the wall of each cavity. The nasal region is

roofed by a pair of dermal bones, the **nasals**, each of which joins the anterior end of a frontal bone.

Certain cranial bones are related to the **ear** or to the **eye**. The otic capsule usually ossifies to form three bones, an **epiotic** above, a **prootic** in front, and an **opisthotic** behind (Fig. 120, 12, 10, 11). In some cases, one or two more bones develop. These otic bones often become more or less fused together. They may all fuse into a single **periotic** (or **petrosal**) **bone**. This otic group is situated between the occipital arch and the parietal arch, therefore locally separating the two arches which are contiguous above and below the otic region. A usually large dermal bone, the **squamosal** (Fig. 120, 13), is developed in close relation to the otic bones and also to the joint between the upper and lower jaws.

In the **region of the orbit** appear several dermal bones (Fig. 120, 14-18) forming in part the wall of the orbit or else serving to extend the cranial roof laterally so that it overarches the orbit, giving added protection to the eye. In some fishes the outer rim of the orbit is completely encircled by **circumorbital bones**. In some reptiles these orbital bones form, over the orbit, an anteroposterior arch consisting of a **postfrontal**, a **postorbital**, one to three or four **supraorbitals**, and a **prefrontal**. A dermal **lacrimal** bone (Fig. 120, 18) makes part of the anterior wall of the orbit.

The **floor of the cranium** is reinforced by dermal bones. The cranial floor is also the roof of the mouth-cavity. This cavity is lined by a membrane which is continuous with the external skin and has the same general structure as the skin. Its deeper layer produces dermal bone. A median dermal **parasphenoid**, extending forward from the region of the cartilaginous sphenoid bones, usually constitutes an important part of the roof of the mouth. Anterior to the parasphenoid is a pair of dermal bones commonly called **vomers**. Just here there is some confusion in names. In mammals a median bone in the anterior part of the roof of the mouth has long been known as the "vomer." There is, however, some evidence that it corresponds to the parasphenoid of other vertebrates. If this should prove true, giving mammals priority on the name "vomer," then the parasphenoid of vertebrates other than mammals should be (but is not) called "vomer," and the two dermal bones just in front of it could be (and frequently are) called "**prevomers**."

#### *Bones of Visceral Skeleton*

The **mandibular arch** produces some cartilage bones but the definitive jaws consist mainly of dermal bones. The **palato-pterygoquadrate cartilage** of some fishes ossifies to form an anterior **palatine**

**bone**, a middle **pterygoid** (or **pterygoids**), and a posterior **quadrate** which is the upper member of the joint between the upper and lower jaws. In vertebrates other than fishes, the cartilaginous upper jaw is more or less deficient anteriorly, and the deficiency is compensated for by development of dermal bones which, according to their location, are named **palatine** or **pterygoid**. **The quadrate is invariably developed as a cartilage bone.** In the middle or pterygoid region of the jaw, one or more pterygoid bones develop, partly cartilaginous and partly dermal in origin. Except in some fishes, the palatine bones are probably entirely dermal. Closely parallel and adjacent to the palatopterygo-quadrate series of bones is developed a second series (Fig. 120, 26-29) consisting entirely of dermal bones, named, beginning anteriorly, the **premaxilla**, **maxilla**, **jugal** (called "malar" in mammals), and the **quadratojugal**, which adjoins the quadrate. The premaxilla and maxilla are the tooth-bearing bones in mammals, but in other vertebrates teeth may be present not only on them but also on various other dermal bones of the jaw and roof of mouth.

In the **lower jaw** the only cartilage bone formed is at the posterior end of the mandibular cartilage—the **articular** (Fig. 120, 31) which, except in mammals, is the lower member of the joint between lower and upper jaws. In all bony skulls the **mandibular cartilage** becomes completely invested by dermal bones. Chief and most anterior of them is the **dentary**, the tooth-bearing bone. At the posterior region of the lower jaw may be a ventral **angular**, an external **supra-angular** (or **surangular**), an internal **splénial** (sometimes bearing teeth), and a prominent dorsal **coronoid**, to which are attached the strong muscles which close the jaws. In mammals each lateral half (**ramus**) of the lower jaw is a single dermal bone articulating with the squamosal, which functionally replaces the quadrate.

The **hyoid and branchial arches**, except in the sharklike fishes and a few others, undergo more or less ossification, reaching a maximum in the "bony fishes." But ordinarily no dermal bone is formed in relation to these arches. In adult vertebrates other than fishes, these arches are greatly reduced and modified.

In fishes other than the sharks and their allies, the external apertures of the gill-chambers are covered by a thin plate, the **operculum**, whose free posterior edge permits escape of water from the gill-chambers. The operculum is a fold of skin supported by extensive sheets of dermal bone. There are at most four of these bones (Fig. 120, 45-48), named, according to their relative positions, **opercular**, **preopercular**, **subopercular**, and **interopercular**. These opercular bones are peculiar to fishes.



## RELATIONS OF JAWS TO CRANIUM

Comparison of various vertebrates reveals radical differences in the relations of the jaws to the cranium. In the sharklike fishes, the upper jaw is somewhat loosely suspended from the under side of the cranium. The attachment may be merely by ligaments at the anterior and posterior ends of the jaw, the hyoid arch being quite independent of the mandibular arch (Fig. 116). In many sharks, however, the hyoid arch becomes attached to the mandibular arch at the joint between upper and lower jaws, the lower end of the hyomandibula being especially tightly bound to the jaw and its upper end strongly attached to the otic region of the cranium. The **hyomandibula** thus becomes a **suspensor** of the jaws, while the more ventral portion of the hyoid arch is loosely swung behind the lower jaw (Fig. 113). In the bony fishes the hyomandibular cartilage usually ossifies to form two bones, a dorsal one which retains the name **hyomandibula**, and a ventral **symplectic** (Fig. 120, 37, 38). These two hyomandibular bones serve as a suspensor for the jaws much as the single cartilaginous hyomandibula does in sharks. The dorsal end of the upper bone is joined to the otic part of the cranium and the lower end of the symplectic attaches to the quadrate bone. Thus the series of bones of the upper jaw and the hyoid suspensor, as viewed laterally, are arranged in the form of the letter V, the upper ends of the arms of the V being attached to the ventral side of the cranium, and the quadrate bone, to which the lower jaw articulates, forming the point of the V (Fig. 120).

In all vertebrates other than fishes, the hyoid structures of the adult have nothing to do with the jaws. The V loses its posterior arm. It is as if, in the absence of the hyoid suspensor, the upper jaw had rotated bodily upward—its anterior attachment to the cranium being the pivot of rotation—to the level of the floor of the cranium. It arrives in this new location in such a way that the bones of the **primary palato-pterygo-quadrates series** are nearer the **median** plane and those of the **secondary dermal series** are **lateral** to them (Fig. 121). The members of the first series thus come to be adjacent to bones of the floor of the cranium and acquire rigid (usually) attachment to certain of them—commonly to the vomer (prevomer), parasphenoid, and basisphenoid—thereby becoming bones of the roof of the mouth. The bones of the second series lie along the outer border of the roof of the mouth. The premaxilla and maxilla commonly become so much broadened as to add to the extent of the anterior region of the roof of the mouth. Another feature of the new arrangement is the sepa-

ration of the middle region of the outer series of bones from the inner series (Fig. 121B). The detached region becomes more or less convex outward, forming the **zygomatic arch**, which springs outward from the **maxilla** and posteriorly joins the **quadrate** or (in mammals) the **squamosal**. The greater part of the arch consists of the **jugal (malar)** bone. The space between the zygoma and the lateral wall of the cranium is occupied by the bulky elevator muscles of the lower jaw, which extend from the coronoid region of the jaw to the posterolateral surface of the cranium.

**In mammals the quadrate and articular do not appear as bones of the adult skull.** The all-dermal lower jaw articulates with the dermal squamosal above. Embryonic vestiges of the quadrate and articular become converted into parts of the accessory auditory mechanism of the ear (Fig. 520). This is a radical departure from the arrangement which exists in all amphibians, reptiles, and birds.

Reviewing the whole vertebrate series, three markedly different arrangements of the jaws may be recognized: (1) upper jaw and hyomandibular suspensor swung in V shape below cranium, as in many fishes; (2) no suspensor; upper jaw incorporated into roof of mouth and (with certain exceptions) immovably attached to cranial bones; joint between articular and quadrate; this arrangement characteristic of amphibians, reptiles, and birds; (3) as in (2), but joint between dentary and squamosal; the arrangement peculiar to mammals.

In lizards, snakes, and birds, more or less mobility in the upper jaw is secured by various specialized arrangements of the jawbones.

## APPENDICULAR SKELETON

### PAIRED APPENDAGES

The paired locomotor appendages are the **pectoral** and **pelvic fins** of fishes and the **pectoral** and **pelvic limbs** of the four-footed vertebrates or "tetrapods." Whether fin, leg, wing, or arm, the skeleton of the appendage consists of a **girdle**, lying in the body-wall and capable of relatively little or no movement, and serving as a foundation for attachment of the skeleton of the externally projecting structure which is, in a more literal sense, an "**appendage**" of the body (Fig. 102). The appendage is more or less elaborately jointed and freely mobile. The pectoral and pelvic appendages, including girdles, are constructed on the same general plan, differing merely as to details.

A simple type of fin appears in **sharks** (Fig. 122). The **pectoral girdle** is a stout transverse cartilaginous bar, convex downward, situated in the ventral body-wall just behind the branchial region. Laterally, it is prolonged upward as a tapering process. By analogy

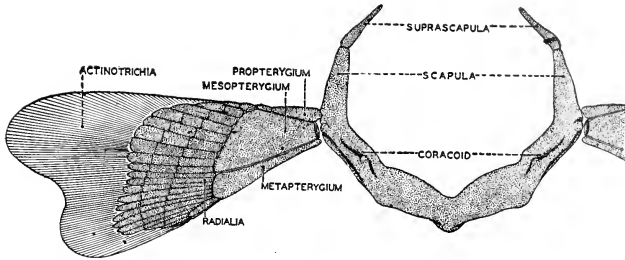


FIG. 122. Diagram of the pectoral appendage of a shark. (Courtesy, Neal and Rand: "Chordate Anatomy," Philadelphia, The Blakiston Company.)

with corresponding regions of a tetrapod girdle, the ventral bar is called the **coracoid** and each dorsal projection is a **scapular process**. At the junction of each scapular process with the coracoid, the movable fin is attached. The surface on the girdle where the fin articulates is the **glenoid facet**. The skeleton of the fin consists of three basal plates of cartilage, an anterior **propterygium**, a **mesopterygium**, and a posterior **metapterygium**. Distal to these are numerous cartilaginous **fin-rays (radialia)**, each divided into several parts. The thin, bladelike distal part of the fin is supported by a system of parallel coarse fibers consisting of an elastic hornlike substance produced by the dermis. The **pelvic appendage** is not so strongly developed. The **girdle** is just behind the coelom or at the base of the tail. Its transverse part is called the "**ischiopubis**" and the dorsal process at each end of it is the **iliac process**. The facet for articulation of the fin is the **acetabulum**. The fin, smaller than the pectoral, may have only one or two basal cartilages.

The **appendicular skeleton of bony fishes** is, in its general plan, like that of sharks, but in the adult it is more or less completely ossified (Fig. 123). In the **pectoral girdle**, the embryonic **coracoid cartilage** may consist of right and left parts not joined midventrally. Centers of ossification arise by pairs, producing on each side a ventral **coracoid bone** and a dorsal **scapula**. The cartilaginous girdle is usually more or less reduced and functionally replaced by membrane bones. Of these, the largest and most commonly occurring are a pair of ventral **clavicles** which supplement the coracoids and a pair of **cleithra** situated dorsolateral to the clavicles. The two clavicles may meet midventrally, thus restoring the completeness of the ventral arch. The girdle may be augmented by other membrane bones, and commonly a series of several of them connect the cleithrum with the

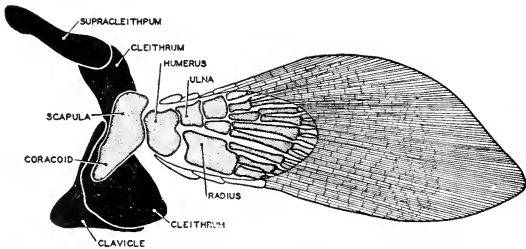


FIG. 123. The pectoral girdle and fin of *Sauripterus*, an upper Devonian cross-pterygian fish. Interest in this type of fin lies in the similarity of relations of the proximal elements of the fin to those found in the pectoral appendage of tetrapods. (After Broom. Courtesy, Neal and Rand: "Chordate Anatomy," Philadelphia, The Blakiston Company.)

otic region of the cranium so that the girdle is anchored to the skull. The **pelvic appendage** is weakly developed and in some cases merely vestigial. Each fin is supported by a bone lying in the body-wall, but whether this pair of bones represent the girdle or are merely enlarged basal elements of the fin itself is a disputed question. No membrane bones are developed in the pelvic appendage.

**The paired appendages of tetrapods** differ from those of fishes mainly in that the freely movable part of the appendage is relatively elongated and more elaborately jointed. The tetrapod girdle, like that of fishes, consists of a ventral and a dorsal part, but with the difference that the ventral part is double, consisting, on each side, of an anterior and a posterior part. A typical tetrapod girdle may be described as three-pronged (Fig. 124). The pectoral girdle consists of a **dorsal scapula**, a **posterior ventral coracoid**, and an **anterior ventral precoracoid** (or **procoracoid**). The three parts meet at the **glenoid facet** or **fossa** where the forelimb is articulated. In the **pelvic girdle** a **dorsal ilium**, a **ventral posterior ischium**, and a **ventral anterior pubis** meet at the **acetabulum** where the hindlimb is articulated. Both girdles are preformed in cartilage but, except in amphibians, the adult girdles are largely or completely ossified. In the pectoral girdle the precoracoid undergoes more or less reduction and is functionally replaced by the **clavicle** (human "collarbone"), a membrane bone which invests the cartilaginous precoracoid (Fig. 125). No membrane bones are developed in the pelvic girdle. The right and left ventral members of the pectoral girdles are usually joined, directly or indirectly, to the sternum. In the pelvic girdle, the corresponding right and left ventral parts usually join one another directly, the junctions being known as the **pubic symphysis** and the **ischial symphysis** (Fig. 126).

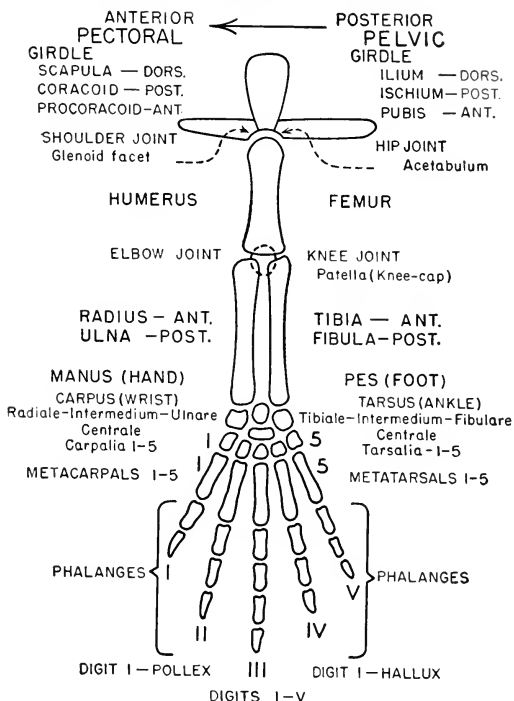


FIG. 124. Tetrapod appendage. In their general plan, pectoral and pelvic appendages are alike; the diagram applies to either. The corresponding names of pectoral and pelvic parts are placed opposite one another, pectoral at the left and pelvic at the right of the part or region.

The number of phalanges in each digit is highly variable. In many cases, two small bones or cartilages appear in the position of the centrale.

External to the girdle, the tetrapod appendage (Fig. 124) consists of a longitudinal series of three major segments; in the pectoral limb a **brachium** (upper arm of man), an **antebrachium** (forearm of man), and a **manus** (hand); in the pelvic limb a **femur** (thigh), a **crus** (shank), and a **pes** (foot). The proximal segment of each limb contains one long bone, the **humerus** (pectoral) or **femur** (pelvic); the middle segment contains two parallel long bones, the **radius** and **ulna** (pectoral), or the **tibia** and **fibula** (pelvic). In the **manus** there are three regions—a **carpus** (wrist) consisting of a group of 9 or possibly 10 compactly arranged small bones, a **metacarpal region**

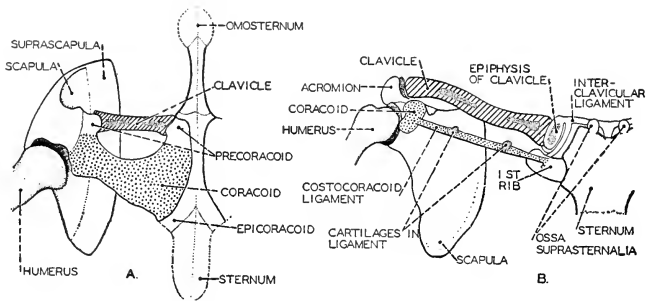


FIG. 125. Diagrams illustrating the fundamental similarity of the human (B) and amphibian (A) pectoral girdle. In man the coracoid element has degenerated into a process (coracoid) and a connective-tissue ligament containing occasional cartilage nodules. (After Huntington. Courtesy, Neal and Rand: "Chordate Anatomy," Philadelphia, The Blakiston Company.)

containing 5 elongated bones lying between the wrist and the **digits** (fingers), of which the normal maximum number is 5. Similarly, in the **pes** there is a **tarsus** (ankle) consisting of 9 or 10 bones, a middle region containing 5 **metatarsals**, and distally the 5 **digits** (toes). The digits consist of varying numbers of short bones jointed together, the **phalanges**. The digits are indicated by numbers, the first in the manus being on the side corresponding in position to the radius, and known as the **pollex** (thumb). In the pes the first digit is on the tibial side of the foot and is known as the **hallux** ("great toe"). The carpal

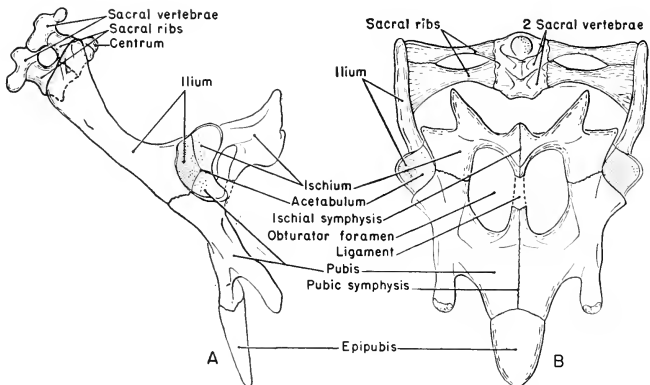


FIG. 126. Pelvic girdle of turtle. (A) Left lateral view. (B) Ventral view.

and tarsal bones are arranged in a proximal row of three, a distal row of five (each at the base of a digit), and one or two inserted between the rows.

For descriptive purposes, the limb is imagined to be extended in a straight line perpendicular to the axis of the body, and without any twisting among its parts. The pectoral limb being placed thus, the radius and the pollex are on its anterior side and the palm of the manus is ventral. Similarly, in the pelvic limb, the tibia and hallux are anterior and the sole (**plantar** surface) is ventral.

The skeletal parts of the tetrapod limb are accurately preformed in cartilage, but in the adult, except tailed amphibians, they are usually completely ossified. No membrane bones are added, except in the pectoral girdle, but there are occasional local ossifications in tendons forming so-called **sesamoid bones**. Such is the **patella** ("kneecap"), common among mammals and found in some reptiles and birds. Another sesamoid is the **pisiform**, a small bone commonly found on the posterior edge of the carpus.

In the **relations of the girdles to the vertebral axial skeleton**, there are significant differences. In most fishes the pectoral girdle is attached to the axial skeleton but the pelvic girdle is never thus attached. In modern tetrapods the pectoral girdle never has skeletal connection with the vertebral axis, while the pelvic girdle (except when the hindlegs are vestigial, as in whales) is always attached to one or more sacral vertebrae. The attachment is by means of one or more pairs of very short, stout ribs, each of which is strongly joined distally to the upper end of the ilium and, proximally, usually fused to the short, thick transverse process of its vertebra.

In most fishes the essential propelling organ is the tail. The well-developed pectoral fins serve mainly for balancing and steering. The reduced condition of the pelvic fins shows that their locomotor function is unimportant. Consistent with these facts, the pectoral girdle of bony fishes is commonly attached, via the cleithrum and other membrane bones, to the hind end of the cranium. In skates (broad, thin, flat, but otherwise sharklike fishes: Fig. 122), the scapular process of the girdle is greatly prolonged and joined to the vertebral column. This exceptional condition is related to the fact that the skate's tail is so reduced as to be useless for propulsion. Swimming is effected by an undulatory flapping of the enormously expanded pectoral fins.

In the locomotion of terrestrial tetrapods, the power is applied at the rear—as in an automobile. The body is pushed forward by the hindlegs. Mechanical efficiency—prevention of "lost motion"—requires a rigid connection between the pelvic girdle and the main sup-

porting axis of the body. The action of the forelegs exerts upon the body more "pull" than "push." For transmission of a pull, the tense muscles connecting the pectoral girdle with the vertebral column and ribs are quite adequate and, on occasion, the absence of a rigid connection between girdle and vertebral column is a great advantage. During such actions as leaping and galloping, the forelegs sustain great impact. The cushioning of the girdle in a bulky mass of shoulder muscles provides an excellent "shock absorber"—and even better when, as in the cat, the clavicle is much reduced and only loosely tied to the sternum; or, as in the horse, the clavicle is lacking, leaving the girdle without rigid connection to the sternum.

The basic plan of the tetrapod appendage has been described. The "pattern," however, is subjected to innumerable functional adaptations, depending on the mode of life of the animal. The mechanical demands imposed by swift running, climbing, swimming, digging, flying, or grasping must be met by appropriate anatomic adjustments which may involve changes in relative size and form of skeletal parts, and reduction by omission of parts or by fusion of adjacent parts (see Figs. 295, 441, 599). To a great extent, these changes in the skeleton merely reflect necessary modifications of the muscular mechanism of the appendage.

#### MEDIAN APPENDAGES

Median or unpaired appendages exist in most wholly aquatic vertebrates. Fishes commonly have **dorsal** and **ventral median fins** varying in number and position, and the tail tapers back into the base of the bladelike vertical **caudal fin** (Fig. 127). The dorsal and ventral fins are supported by basal "bars" and "rays," either cartilaginous or bony (Fig. 128). The thin distal part of the fin is usually stiffened by slender rays of a dermal hornlike substance. The basal structures of dorsal fins may lie between successive neural spines of vertebrae or may be tied to the spines so that the fin is anchored to the vertebral column. The caudal fin may receive its chief support from the greatly enlarged and laterally flattened neural and hemal spines of several vertebrae at the base of the fin (Fig. 129).

A median caudal fin occurs in amphibian tadpoles and in adult aquatic salamanders but has no skeletal support other than the notochord or vertebral column which forms its axis. The dorsal median fin of many of the whalelike mammals contains no special skeleton. The caudal fin of whales ("tail-flukes") extends in a horizontal plane and has no skeleton other than the tip of the vertebral column.



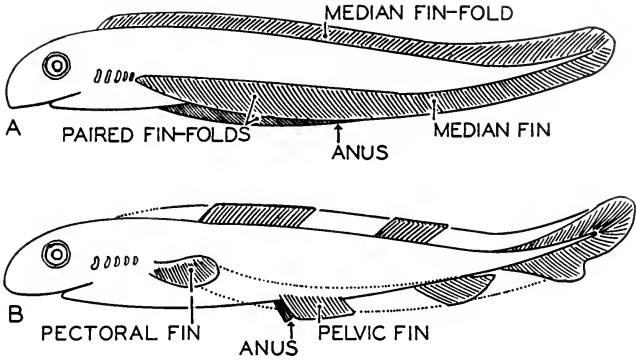


FIG. 127. Diagram illustrating the hypothetical evolution of the paired fins. (A) The primitive stage of continuous fin-folds. The dorsal fin and the ventral fin posterior to the anus are median and unpaired. (B) The definitive elasmobranch stage. The paired fin-folds persist only in the region of pectoral and pelvic fins. The median fins also become discontinuous. (After Wiedersheim. Courtesy, Neal and Rand: "Chordate Anatomy," Philadelphia, The Blakiston Company.)

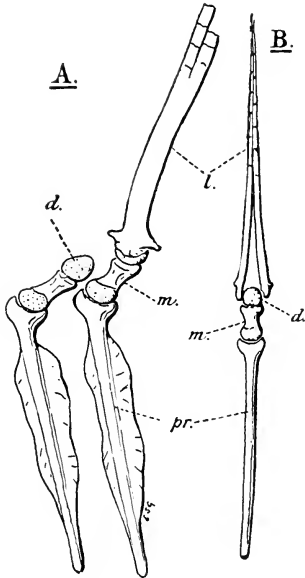


FIG. 128. *Esox lucius*, L. (A) Two radials of the dorsal fin, left side view. (B) Radial and dermal ray seen from in front. (d.) Distal cartilage; (l.) dermal lepidotrich, broken short in (A); (m.) median segment and (pr.) proximal segment of radial. (From Goodrich: "Studies on the Structure and Development of Vertebrates." By permission of The Macmillan Company, publishers.)

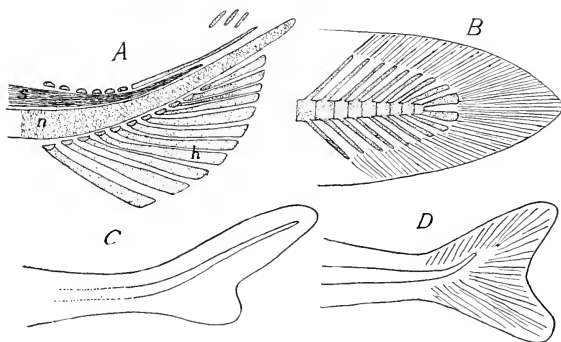


FIG. 129. Tails of fishes. (A) Young *Amia*. (h) Hypurals; (n) notochord; (s) spinal cord. (B) Diphyccercal. (C) Heterocercal. (D) Homocercal. (Courtesy, Kingsley: "Comparative Anatomy of Vertebrates," Philadelphia, The Blakiston Company.)

#### SKELETAL AXES

In descriptions of the vertebrate skeleton, it is the common practice to define the "axial skeleton" as consisting of the vertebral column, skull, ribs, and sternum—that is, the entire skeleton is "axial" except such parts as constitute the "appendicular skeleton." Some authors make three divisions of it—axial, visceral, and appendicular. In either case, "axial" obviously refers to the vertebral or notochordal axis. The division of the skeleton into two parts, axial and appendicular, has the virtue of simplicity, but otherwise it seems inadequate and lacking in significance.

The vertebrate body has more than one axis. Built on the "tube-within-a-tube" plan (see p. 23 and Fig. 16), the inner or alimentary tube establishes a **visceral axis**. The elongated coelom has a **coelomic axis**. If the digestive tube, straightened out, is regarded as being the central organ in the coelom, the visceral and coelomic axes coincide. The basic *structural*—i.e., "architectural"—axis of the animal-as-a-whole is the axis of the inner tube, the visceral axis. (Nutrition is certainly the basic *physiologic axis* of the animal!) But, regarding the body as a dynamic thing, its chief *mechanical axis* is occupied by the vertebral column which is situated in the dorsal body-wall, whose heavy musculature effects the major movements of the body.

The **visceral arches** develop around the alimentary tube. They are "axial," but it is in relation to the visceral axis. It is true that the dorsal part of the first visceral arch becomes secondarily joined to the floor of the cranium. But, in doing so, the bones of the upper jaw do not cease to be visceral. The floor of the cranium is also the roof of

the mouth and the mouth is a "visceral" cavity. The dermal bones of the jaw originate in the deep tissue of the lining of the mouth. The hind part of the floor of the embryonic chondrocranium develops around the anterior end of the notochord and actually encloses a part of the notochord. *The floor of the primary cranium, therefore, definitely lies in the notochordal axis.* Bones developed in the dorsal wall of the oral cavity are ventral to the notochordal axis. Teeth, carried by certain bones of the upper jaw, certainly have more to do with the food below them than with the brain above them.

The skeleton of the visceral axis and that of the notochordal axis are merely tangent at their anterior ends (Fig. 130), the region of tangency being the roof of the mouth and the floor of the cranium, but this fact does not justify assigning the whole visceral skeleton to the notochordal axis. In fact, reason could be found for considering such bones as the vomers (prevomers) and parasphenoid to be visceral rather than cranial, for they originate in the wall of the mouth and may carry teeth. The skull, therefore, in terms of axes, is a duplex thing, being pierced by both the notochordal axis and the visceral axis.

**Ribs** develop in the myoseptums. They are products of the body-wall. They are attached to the vertebrae, but structurally they belong to the lateral body-wall and their primary function is to strengthen it and provide attachment for certain of its muscles. They embrace the coelom. If they are "axial," it is in relation to the **coelomic axis**. It would seem most significant to describe the ribs as constituting the **lateral parietal skeleton** (parietal referring to the body-wall), for

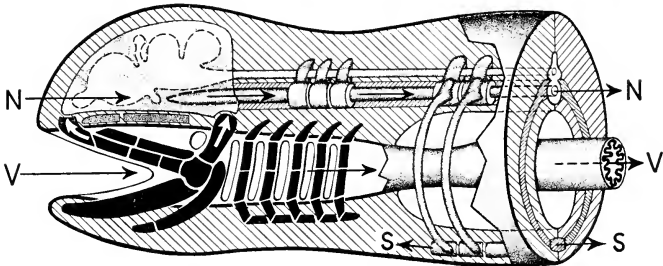


FIG. 130. Skeletal axes. (N) Notochordal axis; (S) sternal axis; (V) visceral axis. The white arrows, one at the anterior end of the upper jaw and the other on the dorsal member of the hyoid arch, indicate the points of tangency of the skeletal systems of the notochordal axis and the visceral axis.

The diagram is a composite in that the visceral skeletal structures are shown as they would appear in a fishlike vertebrate, while the ribs and sternum are mammalian.

For identification of visceral parts, compare with Fig. 120.

they are the characteristic skeletal parts of the lateral body-wall (Figs. 100B, 130).

The **sternum** is commonly classed with the ribs because, except in amphibians, it develops in close relation to the ventral ends of the ribs and is possibly a derivative of the ribs. But, situated as it is, as far away from the vertebral column as possible, its only claim to being assigned to the vertebral axis seems to be the fact that it is attached to the ribs and the ribs are attached to the vertebral column. By analogy then, the hindlegs would be "axial," for they are attached to the pelvic girdle and the girdle is attached to sacral vertebrae! The fact is that the sternum establishes a midventral axis of its own. While it is a minor axis, it is an important one, for the sternum serves for attachment of a bilaterally arranged system of muscles, including the especially important pectoral muscles which operate to move the pectoral appendages downward. In most mammals the sternum is a longitudinal series of segmentally arranged elongated bones jointed together, the whole being suggestive of a simplified and miniature replica of the vertebral column (Fig. 112E). Structurally and functionally, it constitutes a very definite **ventral** or **sternal axis**.

If it is desirable, for descriptive purposes, to devise some scheme calculated to indicate the axial relations and regional differentiation of the vertebrate skeleton, the following arrangement, based on existing structure rather than on more or less dubious phylogenetic origins, is suggested.

1. **Skeleton of the Notochordal Axis (Dorsal Parietal)**
  - Vertebral Column
  - Primary Cranium.....
2. **Skeleton of the Visceral Axis** } **Skull**
  - Visceral Arches.....
3. **Lateral Parietal Skeleton**
  - Ribs
4. **Skeleton of the Sternal Axis (Ventral Parietal)**
  - Sternum
  - Interclavicle (Episternum)
5. **Appendicular Skeleton**

# Integrative Systems

---

# 6

It is necessary for an organism that its various organs should work together harmoniously. The more complex an organism, the more complicated must be the mechanism which effects functional correlation among its different but interdependent parts. This functional integration of the highly complex vertebrate body is secured by two quite different mechanisms, one nervous, the other glandular. The structure of the nervous system is such as to suggest some analogy with telephonic or telegraphic systems of communication. By means of nerves, each a bundle of exceedingly delicate nerve fibers, "messages"—i.e., nervous impulses—are transmitted from one part of the body to another. The glandular mechanism operates by transportation of chemically specific secreted substances via the blood-stream. The glands of this system are called "ductless glands" because the specific products of its secreting cells diffuse directly into the blood which is flowing through the capillaries of the gland. The secreted substance acts as a "chemical messenger" (**hormone**), inducing characteristic and appropriate reactions in various structures to which it is carried by the blood. Nervous transmission is almost instantaneous. The speed of the blood-current is relatively slow. Therefore, in general, quick adjustments, correlation of muscular activities, and responses to stimuli received from the external environment are effected by the nervous system. But the relatively slow adjustments, and such processes as metabolism and growth, are largely controlled by the ductless or **endocrinal glands**. It has recently been discovered that the stimulating action of a nerve, at least in some cases, depends on release, by the nerve-endings, of minute quantities of chemically specific substances which are of the nature of hormones and act in the manner of hormones. The existence of these "neurohumors" makes it appear that the difference between nervous action and endocrinal action may be mainly structural.

## I. Nervous System

The protoplasmic properties on which the action of nerves depends are **irritability** and **conduction**. If one of several pseudopodia of an ameba is touched, all of the pseudopodia may contract. Both irritability and conduction are concerned in this reaction. All cells of the more complex animals probably possess these two facilities, but they become the special and emphasized functions of cells of the nervous organs.

Every nerve-fiber develops as an outgrowth from a nerve-cell and is permanently in vital connection with the main body of the cell. The structural element of the nervous system is a nerve-cell together with the nerve-fiber or fibers which it has produced (Fig. 131). This element is called a **neuron**. A cell or fiber which is specialized for reception of a stimulus from any source external to the nervous system is known as a **sensory** cell or fiber, or a **receptor**. If it is so situated as to receive stimuli from sources external to the animal, it is called an **exteroceptor**. A receptor situated on some internal surface—e.g., the lining of the stomach—and thus exposed to stimulation by some agency in the adjacent cavity, is called an **interoceptor**. **Proprioceptors** are receptors which are buried within masses of tissues—e.g., a muscle, a tendon, or at a joint. Nerves are **conductors** (Fig. 132). A **central nervous organ** is a more or less complex system of physiologically connected neurons which effect the coördination and integration of nervous impulses. A **ganglion** is a minor center consisting of cell-bodies of neurons together with the adjacent region of their nerve processes. A conductor which transmits impulses toward a central

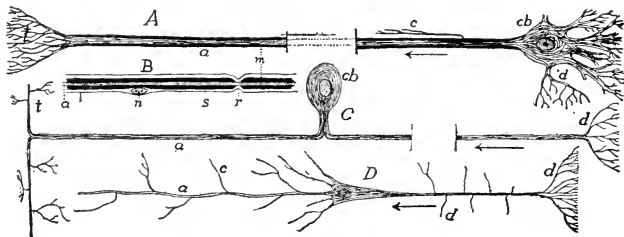


FIG. 131. Types of nerve-cells. (A) Multipolar cell. (B) Portion of nerve-fiber with sheaths. (C) Unipolar cell (such a cell may arise by modification of a bipolar cell, as shown in Fig. 260). (D) Pyramidal cell (from cerebral cortex). (a) Axon; (c) collateral; (cb) cell-body; (d) dendrites; (m) medullary sheath; (n) nucleus of cell of Schwann's sheath; (r) node of Ranvier; (s) sheath of Schwann; (t) telodendron. (Courtesy, Kingsley: "Comparative Anatomy of Vertebrates," Philadelphia, The Blakiston Company.)

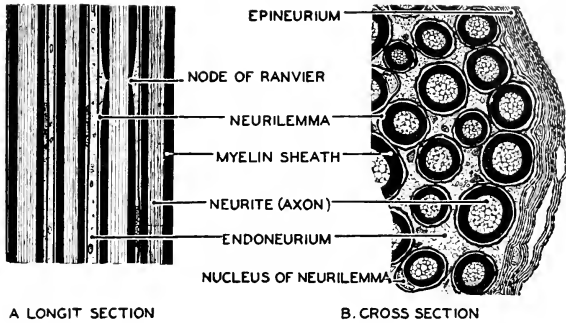
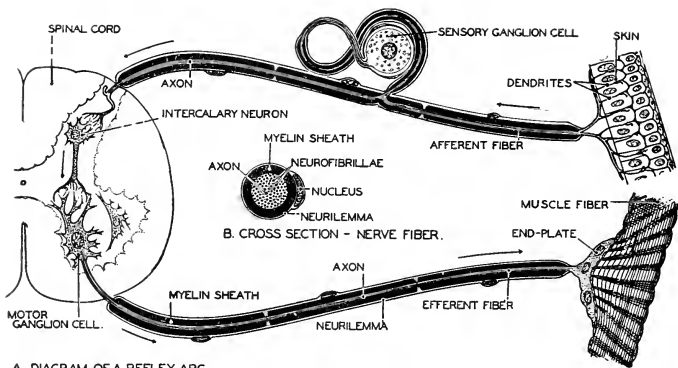


FIG. 132. A portion of (A) longitudinal and (B) cross section of a nerve prepared by the vom Rath method. A nerve is a bundle of axons (neurites) covered by an epineurium. Each axon is surrounded by an inner myelin (fatty) sheath and an outer cellular neurilemma sheath. (Courtesy, Neal and Rand: "Chordate Anatomy," Philadelphia, The Blakiston Company.)

nervous organ is designated as **afferent** or **sensory**; one which transmits away from a central organ and toward a reacting organ is **efferent** or **motor**. The reacting organ, usually a muscle or gland, is called an **effector**. In the case of a gland, the efferent fibers may be related to the secreting cells themselves, controlling their secretory activity, or to muscle-fibers in the wall of the gland, controlling the discharge from the gland.

A nervous reaction of the simple type known as a **reflex** is initiated by stimulation of a receptor. A nervous impulse produced by effects of the stimulation is transmitted from the receptor along a conductor, which may be a nerve-fiber belonging to the receptor cell (as in the olfactory organ), or a fiber of another neuron (as in the ear). From this conductor, the impulse is relayed over to another neuron which is related to the effector. But few reactions are as simple as this. Most reflexes are complicated by the fact that additional neurons are interpolated between the two conductors of the simple "reflex arc" just described (Fig. 133). By this means, a simple and sharply localized stimulus may bring into action a complex system of effectors, as when a pin-prick causes a jerking of the entire arm. It is these interpolated neurons—**association** and **correlation neurons**—which make up a large part of the bulk of the central nervous organs.

The physical nature of the relationship between two adjacent neurons in a nervous circuit is doubtful. In some cases there is apparently continuity of the delicate protoplasmic fibrils of the two neurons. There is, however, much evidence that, at least in higher animals, the related fibrils are not physically continuous but merely closely approxi-



A. DIAGRAM OF A REFLEX ARC.

FIG. 133. Diagram of a nervous arc. (A) Three neurons—afferent, intercalary, and efferent—are shown in their relations to one another and to the skin and muscle. The intercalary neuron is located in the gray matter of the spinal cord. (B) An enlarged section of a nerve-fiber. (Courtesy, Neal and Rand: "Chordate Anatomy," Philadelphia, The Blakiston Company.)

mated so that the nervous impulse passes from one fibril to another in a manner analogous to that in which an electric current passes from one to another of two wires which are merely in contact, but not continuous, or even "sparks" across a small gap. This type of relation between fibrils of two neurons is known as a **synapse** (Fig. 133; cells in spinal cord). There is accumulating evidence that transmission across a synapse is effected by instantaneous secreting of a specific chemical substance by the fibrils of the neuron which is sending the impulse across, this secreted "neurohumor" thus acting chemically on the adjacent fibrils of the other neuron.

### CENTRAL NERVOUS ORGANS

Some invertebrates, such as arthropods and annelid worms, have a dorsal cephalic ganglion or "brain," but the central nervous organ in the body is a cord, or pair of cords, situated ventrally to the digestive tube. In flatworms there are one or more pairs of nerve-cords placed more or less laterally. In no invertebrate do the central nervous organs resemble closely those of vertebrates.

Of all vertebrate organs, the **central nervous organs, brain and spinal cords** are most constant in manner of embryonic development, in position, and in general features of structure. Along the entire length of the middorsal line of the early embryo, a band of the outer layer (ectoderm, which otherwise gives rise to the outer layer, epidermis, of the skin) becomes infolded, detached from the outer ectoderm, and



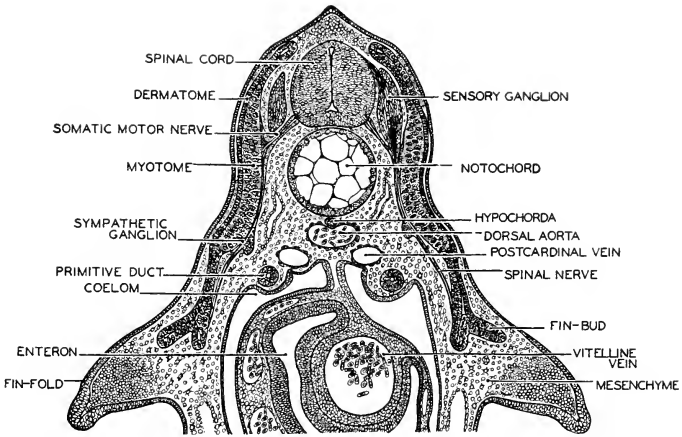


FIG. 134. A cross section of a 17 mm. elasmobranch (*Squalus*) embryo, in the trunk region, showing an early stage in the formation of sympathetic ganglions. The yolk-sac to which the embryo is attached has been removed. (Courtesy, Neal and Rand: "Chordate Anatomy," Philadelphia, The Blakiston Company.)

shaped into a tube which extends through the length of the embryo (Figs. 225, 228). This **neural tube** is immediately dorsal to the notochord. The wider anterior region of the tube enlarges to form the highly complex **brain**, which retains its continuity with the longer, narrower, and less complex remainder of the tube, the **spinal cord**.

From the wall of the neural tube, cells, or groups of cells, which are prospective neurons become detached and migrate to deeper positions in the embryo, where they become massed and develop into **ganglions** which, in the adult, lie in various regions external to the brain and cord, even in quite deep parts of the body (Fig. 134). From cells in these ganglions, nerve-fibers may grow back into the central nervous tube. From cells in the wall of the tube, nerve-fibers grow outward and become collected into bundles, **nerves**, which extend into all, even the most remote, parts of the body. So far as is known, all ganglions and nerves external to the brain and cord are derived from the neural tube, or from ectodermal thickenings (**placodes**) closely adjacent to it, with the single exception of the nerves from the nasal organ of smell. The fibers of these **olfactory nerves** grow out from the olfactory receptor cells in the lining of the nasal cavities and pass into the front end of the brain.

In the adult the brain and spinal cord are dorsal to the alimentary tube and also to the notochord. They are hollow, retaining the central

cavity of the embryonic neural tube. In the arrangement of **cranial** and **spinal nerves**, connected with brain and cord respectively, is seen a segmentation corresponding to that of the body-muscles.

Both notochord and neural tube become involved in development of the vertebral column. The usually solid bodies or **centra** of the vertebrae are formed around the notochord. Each centrum bears dorsally a skeletal arch, the **neural arch**, which encloses the spinal cord (Fig. 100).

The **dorsal location** and the **central cavity** are the especially unique features of the vertebrate central nervous organs as compared to those of invertebrates.

#### BRAIN

In all vertebrates the wider cephalic region of the neural tube early produces three enlargements (Fig. 135) known as **primary brain-vesicles** and indicated by number beginning anteriorly, or called **forebrain**, **midbrain** and **hindbrain**. Meanwhile, the **olfactory sacs** are developing just in front of the brain, the **otic sacs** at each side of the rear of the brain, and an **eye** between the olfactory and otic sacs of each side (Fig. 115). The primary nervous connections of the olfactory organs are with the forebrain (i.e., with parts of the adult brain which are derived from the embryonic forebrain); the optic nerves become connected with the midbrain; and the nerves to the ear proceed from the hindbrain.

In the course of the later development of the brain, the embryonic forebrain is differentiated into two well-defined parts of the adult brain; the midbrain remains undivided; and the hindbrain forms two distinct regions. These five regions are clearly recognizable in all adult

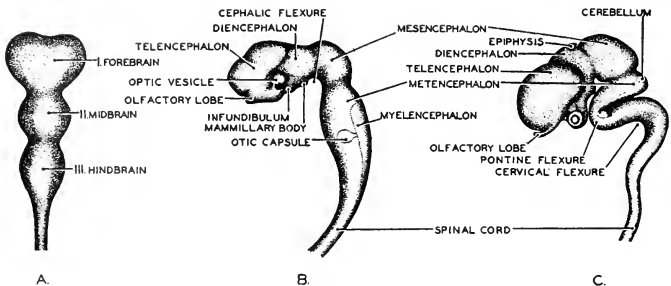


FIG. 135. Three stages in the development of the human brain, showing the brain-vesicles and flexures. (A) Early stage, dorsal aspect. (B) Brain of a three-week embryo in lateral aspect. (C) Brain of an eight-week embryo in lateral aspect. (After His and Hardesty. Courtesy, Neal and Rand: "Chordate Anatomy," Philadelphia, The Blakiston Company.)

vertebrate brains (Fig. 135B, C). They are designated by a series of names in which "**encephalon**" (brain) is combined with appropriate prefixes indicating the relative positions of the several regions. Beginning anteriorly, they are the **telencephalon** (or **prosencephalon**), **diencephalon**, **mesencephalon**, **metencephalon**, and the most posterior region—transitional between brain and spinal cord—the **myelencephalon** (**myelon**, spinal cord). (Confusion sometimes arises from the fact that, in an older terminology, the part behind the mesencephalon was called "epencephalon," and "metencephalon" was applied to the most posterior region.) The lumen of the embryonic neural tube persists in the adult brain, forming a continuous series of cavities known as **ventricles** (or otherwise designated by "**coele**" with the prefix appropriate to the region: e.g., mesocoel, metacoel, etc.).

The gross anatomy of the brain is mainly a matter of formation of local thickenings of the wall of the neural tube, these "**lobes**" giving the brain its characteristic external configuration. The gross anatomic differences among brains of various vertebrates are due largely to differences in the relative size of the several lobes. The characteristic structural features of the several regions have, to a large extent, received names which were originally used in human anatomy and are not always literally significant as applied to brains other than mammalian.

The **telencephalon** is more or less definitely divided into right and left **cerebral hemispheres** partially separated by an anterodorsal fissure (Fig. 136). The ventral wall of each hemisphere is always much thickened, forming the **corpus striatum** or basal ganglion (Fig. 138). The dorsal wall, the **pallium**, varies from a thin and quite non-nervous membrane in many fishes to the most massive part of the brain in man and some other mammals (Fig. 139). Anteroventrally, each hemisphere is continuous with a relatively small **olfactory lobe** (Figs. 136, 140). The olfactory lobes develop as hollow outgrowths of the telencephalon. Primarily, the telencephalon, especially the corpus striatum, is concerned with the olfactory mechanism but, with increased development of the pallium, the cerebral hemispheres become the dominant coordinating mechanism of the brain.

The **diencephalon** gives rise to no prominent lobes. Its lateral walls, the **thalami** (Fig. 138), are thickened by the presence of important masses of ganglionic material. A large part of its dorsal wall is non-nervous. The anterior region of the roof is a thin membrane which becomes elaborately folded into the adjacent ventricular spaces and

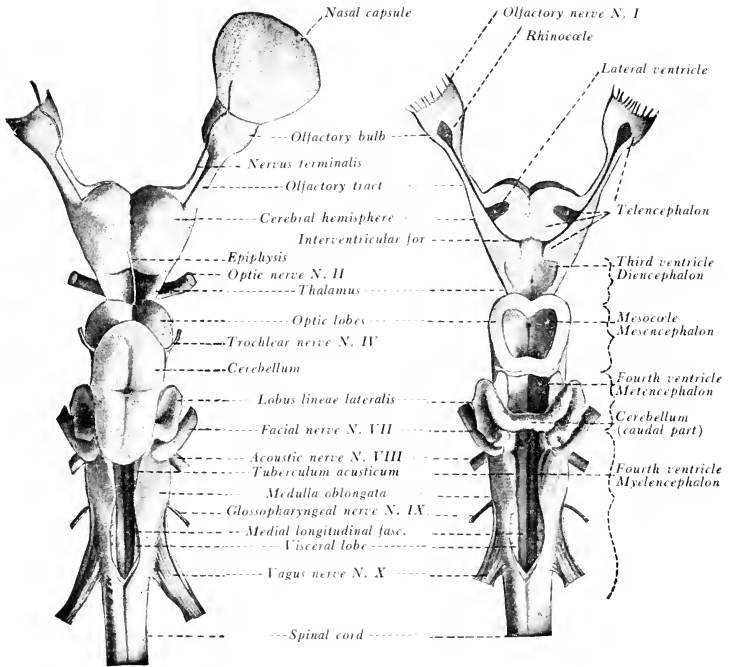


FIG. 136. (Left) The brain of the dogfish, *Squalus acanthias*, dorsal view. (Right) The brain of the dogfish, *Squalus acanthias*, with the ventricles opened, dorsal view. (Courtesy, Ranson: "The Anatomy of the Nervous System," Philadelphia, W. B. Saunders Co.)

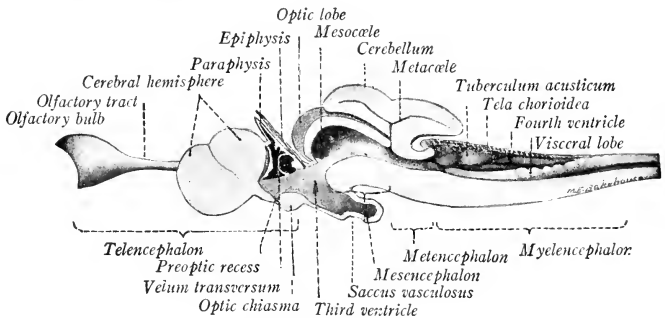


FIG. 137. The brain of the dogfish, *Squalus acanthias*, sagittal section. (Courtesy, Ranson: "The Anatomy of the Nervous System," Philadelphia, W. B. Saunders Co.)

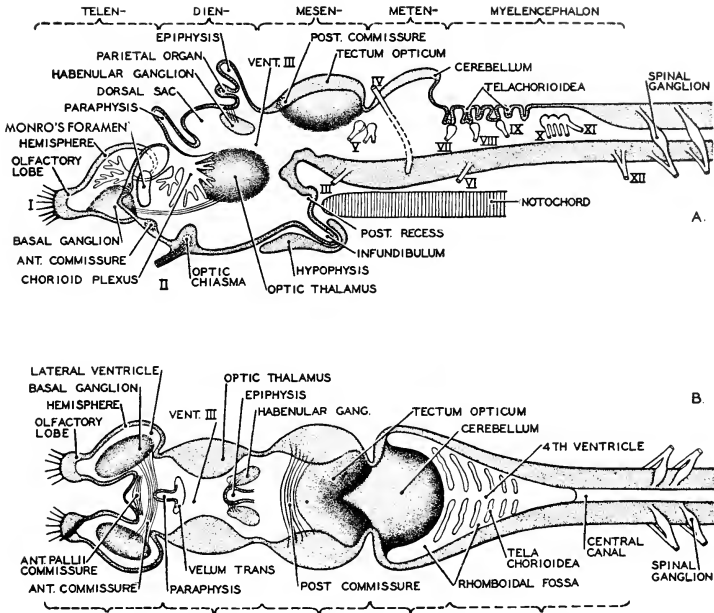


FIG. 138. Diagrams of the vertebrate brain, based upon the brain of a cyclostome. (A) The brain in sagittal section, with nerves shown as if projected upon the median plane. (B) The brain viewed from above. (Redrawn from Plate, after Bütschli. Courtesy, Neal and Rand: "Chordate Anatomy," Philadelphia, The Blakiston Company.)

carries with it a network of fine blood-vessels (Fig. 138). This **choroid plexus** serves to bring blood into close relation to the lymphlike cerebral fluid which fills the ventricles. At the junction of the roof of the diencephalon with the telencephalon is a small, thin-walled, non-nervous dorsal outgrowth, the **paraphysis** (Figs. 137, 138), which seems to be of the nature of a choroid plexus which projects from the wall externally instead of internally. (In a strict sense, the paraphysis should be regarded as within the territory of the telencephalon, but structurally it resembles the closely adjacent products of the diencephalic roof.)

The extraordinary feature of the diencephalon is that it gives rise to some highly specialized organs which physiologically are not parts of the central nervous system, but are exteroceptors. From the walls of the diencephalon, as many as **four eyes** may develop—one pair

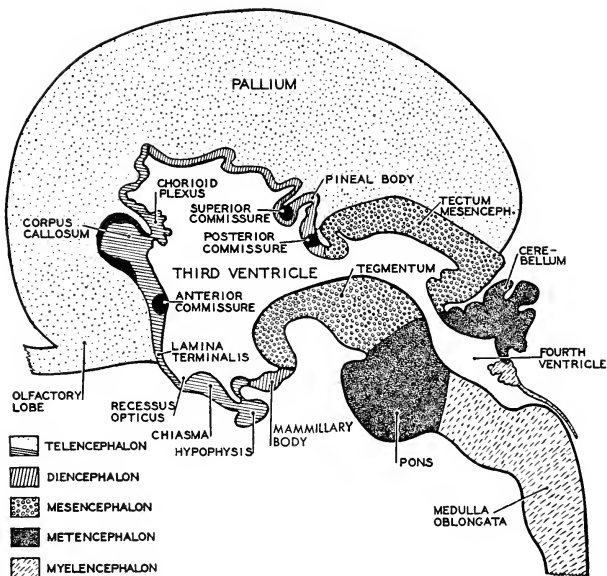


FIG. 139. A diagram of the brain of a four-month fetus as seen in sagittal section. The figure shows the location of the more important brain commissures. (Redrawn from Corning, after Burckhardt. Courtesy, Neal and Rand: "Chordate Anatomy," Philadelphia, The Blakiston Company.)

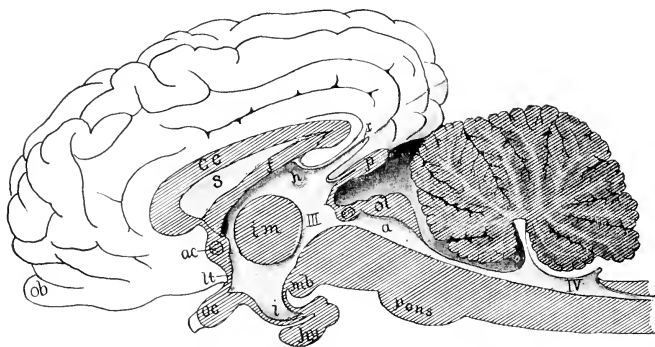


FIG. 140. Median section of the brain of a calf. (a) Aqueduct; (ac) anterior commissure; (cc) corpus callosum (f) fornix; (h) habenula; (hy) hypophysis; (i) infundibulum; (im) intermediate mass ("soft commissure"); (lt) lamina terminalis; (mb) mammillary body; (ob) olfactory lobe; (oc) optic chiasma; (ol) optic lobes; (p) pineal body; (r) recessus suprapinealis; (s) septum pellucidum; (III, IV) third and fourth ventricles. (After Bütschli. Courtesy, Kingsley: "Comparative Anatomy of Vertebrates," Philadelphia, The Blakiston Company.)

and **two median**. The **retina**, the essential nervous layer of the paired eyes possessed by all vertebrates, develops as a hollow ventro-lateral outgrowth from the posterior region of the forebrain (Figs. 135B, 141) The outgrowth shapes into a cuplike vesicle connected with the brain by a relatively narrow **optic stalk**, along which the fibers of the optic nerve later develop. Accordingly, in the adult, the optic nerves join the brain in the floor of the diencephalon (Figs. 137, 140).

The **median eyes** develop from the roof of the diencephalon. Just behind the choroid plexus are usually formed two small, hollow, external projections, one close behind the other (Fig. 138). The anterior one is called the **parietal organ**; the other is the **pineal organ**. Either is sometimes called an "**epiphysis**." Either or both of them may produce at its distal end a small eyelike organ with pigmented retina, lens, and a nerve passing down into the deeper part of the diencephalon (Fig. 142). When thus well developed, the eye lies at or near the surface of the head, and the skin covering it is thin or transparent.

In lamprey eels, both the parietal and the pineal eye are fairly well developed. The parietal eye is especially characteristic of lizards, in which it lies in a **parietal foramen** between the parietal bones and is covered by a transparent scale. The pineal organ is prominent in shark-like fishes and in toads and frogs, but not strongly eyelike. In adult birds and mammals, it appears as the "**pineal gland**," a small non-nervous lobe closely attached to the roof of the diencephalon (Figs. 139, 140), apparently glandular but of uncertain function. In what way and to what extent these median eyes on top of the head are useful to their possessors is quite problematic.

The floor of the diencephalon, just behind the place where the optic nerves enter it, projects downward as a hollow conic structure, the **infundibulum**, which bears at its tip a small solid lobe, the **pituitary body (hypophysis)**, a highly important endocrine gland (Fig. 140).

The **ventricle** of the diencephalon (**diacoel**, or "**third ventricle**"

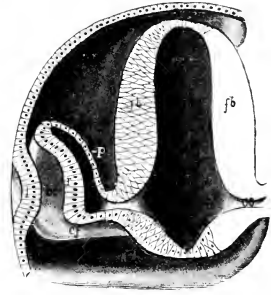


FIG. 141. Stereogram of the developing eye. The head of the embryo is cut transversely in the region of the forebrain. (*cf*) Choroid fissure; (*fb*) wall of forebrain; (*l*) ectodermal thickening which invaginates to form lens; (*oc*) optic cup; (*os*) optic stalk; (*p*) outer thin wall of optic cup, becoming the pigmented epithelium which lies behind the definitive retina; (*r*) inner thick wall of optic cup, becoming the sensory retina of the eye. (Courtesy, Kingsley: "Comparative Anatomy of Vertebrates," Philadelphia, The Blakiston Company.)

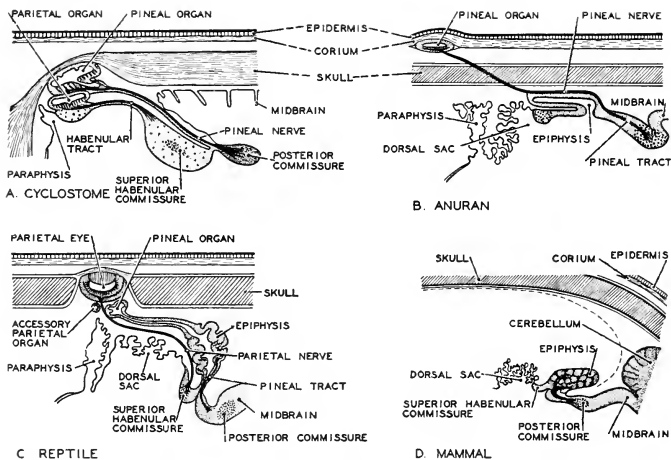


FIG. 142. Parietal and pineal organs of vertebrates as seen in sagittal section. (A) Cyclostome. (B) Anuran. (C) Reptile. (D) Mammal. Either the parietal or the pineal organ may be more or less eyelike—in amphibians it is the pineal organ, in reptiles the parietal organ. In man and other mammals the pineal organ is a gland of doubtful function. (Redrawn from Oppel, after Studnicka. Courtesy, Neal and Rand: "Chordate Anatomy," Philadelphia, The Blakiston Company.)

of human anatomy) is the foremost of the median cavities of the brain, each hemisphere of the telencephalon having its own **lateral ventricle**. Each of these lateral ventricles communicates with the median diacoel via an aperture, the **foramen of Monro** (Fig. 138A). The anterior wall of the diacoel is a thin **lamina terminalis** which terminates the median cavities of the brain, the foramina of Monro being at either side of the lamina (Fig. 139).

The **mesencephalon** is thickened on all sides. The dorsal thickening assumes the form of a pair of prominent lobes, the **optic lobes** (**corpora bigemina**: Fig. 136), or, in mammals, two pairs of lobes (**corpora quadrigemina**: Fig. 140, *ol*). These optic lobes contain primary centers of the optic nerves. It is to be emphasized that, whereas the retina develops as an outgrowth from the diencephalon and the optic nerves join the floor of the diencephalon, the ultimate connections of the optic fibers are mainly in the mesencephalon. The floor of the mesencephalon contains a pair of approximately longitudinal nervous tracts, the **crura cerebri** (cerebral peduncles: Fig. 530), which are more or less prominent on the ventral surface. The optic lobes may



contain small cavities connecting with the median **mesocoel** (Fig. 136), which is usually very narrow (the "**aqueduct of Sylvius**" of human anatomy; Fig. 140, *a*).

The **metencephalon**, the anterior division of the embryonic hind-brain, produces a dorsal lobe, the **cerebellum**, which in most vertebrates attains a bulk that makes it one of the most conspicuous features of the brain (Figs. 136, 137, 140). The exceptions are the small group of lungfishes and the amphibians, in which the cerebellum is relatively small. The cerebellum is a single lobe of compact form except in birds and mammals, in which it is divided into three regions or lobes, a median **vermis** and a pair of **lateral lobes** (Figs. 416, 521). Along with this tripartite lobing, there is developed in the thick ventral wall of the metencephalon a massive transverse bridge of nerve-fibers, the **pons Varolii** (Figs. 139, 140, 530), connecting the two lateral cerebellar lobes.

The chief function of the cerebellum is the coördination of muscular activity. For example, when a four-legged animal runs, numerous muscles of each of the four legs are in action. For smooth operation of the locomotor mechanism as a whole, it is necessary that the contraction of each muscle be precisely timed as to its beginning and duration and that the degree of its contraction be determined. All of this control is effected automatically—i.e., not "voluntarily"—by the nervous mechanism in the cerebellum.

The **myelencephalon** produces no prominent lobes and merges, without definite demarcation, into the spinal cord (Figs. 136, 137). Its nervous material is confined to the thick ventral and lateral walls. Its broad roof is entirely a thin non-nervous membrane, most of which is highly vascular and is elaborately infolded to form a choroid plexus, the **posterior tela chorioidea** (Figs. 137, 138A). The main mass of the lateral and ventral walls consists of longitudinal tracts of fibers which continue forward from the spinal cord into the brain. Certain of these tracts occasion a more or less prominent pair of elongated swellings, the **pyramids** (Fig. 530), on the ventral surface of the medulla. The tracts of the pyramids continue forward as the **crura cerebri** of the mesencephalon and thence eventually into the cerebral hemispheres. The broad, shallow cavity of the medulla is the "**fourth ventricle.**"

The medulla contains the various sensory centers whose receptors are in the skin, the centers for the sense of taste whose receptors are located within the mouth of all vertebrates and also in the external skin of many fishes, and the primary centers for the mechanism of the ears and for various interoceptors of the digestive and respiratory or-

gans. It is also the seat of important motor centers concerned with the muscles of the mouth, pharynx, esophagus, stomach, and intestine.

#### SPINAL CORD

Compared to the brain, the **spinal cord** is simple in external form and relatively simple in its internal structure. Also, its structure is more nearly constant throughout the group of vertebrates.

In external form, the cord ranges from being dorsoventrally flattened to nearly cylindrical (Fig. 143). From the medulla backward it tapers slowly, but with a more or less marked **brachial enlargement** opposite the pectoral region, occasioned by the larger nerves going off to the appendages, and with a similar **lumbosacral enlargement** opposite the pelvis (Fig. 156). The cavity of the embryonic neural tube persists in the adult cord, but the walls of the tube become so greatly thickened that the lumen appears as an extremely narrow **canalis centralis** (Figs. 143, 144). The canal is continuous with the ventricles of the brain and occupied by the lymphlike **cerebrospinal fluid**. The cord is partially divided into symmetric right and left parts by a connective-tissue **dorsal septum** which extends more or less deeply into

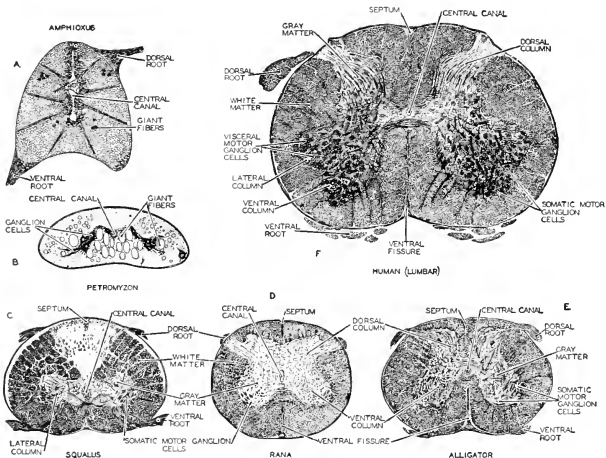


FIG. 143. Cross sections of the spinal cords of various vertebrates. (A) *Amphioxus*. (B) *Petromyzon*. (C) *Squalus*. (D) *Rana*. (E) Alligator. (F) *Homo*. The magnification is not to the same scale. The section of the cord of *Amphioxus* is enlarged four times as much as that of *Petromyzon*. In these two animals the axons are non-medullated. The striking differences between the cord of *Amphioxus* and that of man are bridged over by intermediate conditions in lower vertebrates. (Courtesy, Neal and Rand: "Chordate Anatomy," Philadelphia, The Blakiston Company.)

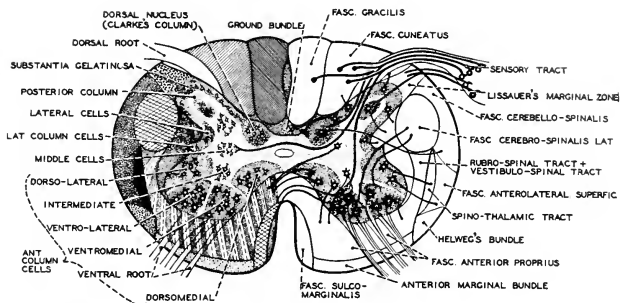


FIG. 144. A diagram of a cross section of the mammalian spinal cord, showing the fiber tracts or fasciculi, and the arrangement of nuclei in the gray matter. (After Sobotta. Courtesy, Neal and Rand: "Chordate Anatomy," Philadelphia, The Blakiston Company.)

it above, and a **ventral fissure** which cuts up into it below (Figs. 143, 144).

The somewhat greater part of the nervous substance of the cord consists of nerve-fibers, most of which are medullated (see p. 319). Cell-bodies of neurons constitute the rest of it. Some of these cells belong to the motor fibers which emerge from the cord in the spinal nerves. Others are cells of association-neurons, one or more of which may be interpolated between the primary afferent neuron and the ultimate efferent neuron of a reflex arc. And some are commissural neurons connecting neuron systems of right and left sides of the cord. The vast numbers of fibers which extend lengthwise of the cord are more or less definitely massed into a thick external layer of "**white matter**"—white because of the fatlike substance of the medullary sheaths. The deeper "**gray matter**" consists of the cell-bodies and the adjacent regions of their related fibers which, so far as they lie within the "gray" substance, are usually not medullated.

The "**gray matter**," as seen in a cross section of the cord (Figs. 143, 144), appears as a dorsoventrally elongated mass on each side of the cord, the two lateral masses being connected by a transverse mass, the **gray commissure**, which lies near the center of the cord and surrounds the small central canal. The dorsal and ventral extensions of the gray region are known, respectively, as **dorsal** and **ventral gray columns**. A **lateral column**, intermediate between dorsal and ventral columns, is sometimes recognized.

The fibers in the outer "**white matter**" are disposed in bundles or tracts, each consisting of fibers of similar origin and function. Groups of tracts form **fasciculi**. A fasciculus may contain both sensory tracts

and motor tracts. Fibers extending from their region of origin toward the brain are called “**ascending**”; extending in the reverse direction, they are “**descending**” (Fig. 151).

#### “SOMATIC” AND “VISCERAL”

Preliminary to a description of the nerves which are related to the brain and spinal cord, it is necessary to make a digression for the purpose of clarifying certain terms whose common usage is not intelligible without explanation.

The general structure of a vertebrate has been described (see p. 23) as “double-tubular”—one tube inside another. The outer tube is the body-wall; the inner is the alimentary tube. There are important structural differences between the two tubes. Muscle constitutes by far the greater part of the substance of the body-wall, and such skeletal parts as it may contain are necessary adjuncts of the muscle. Compared to the body-wall, the alimentary tube contains a small amount of muscle and a relatively large proportion of secretory tissue. The segmented muscles which essentially constitute the body-wall—that is, the muscles which effect the bodily movements and locomotion of the animal—consist of highly specialized striated muscle-fibers (see p. 89). These striated muscles develop from the paired dorsal mesodermal segments (somites) of the embryo (see p. 277). The muscle of the alimentary tube is of the simple and more primitive nonstriated or “smooth” variety and develops from ventrolateral unsegmented mesoderm. In the coelomic space between alimentary tube and body-wall are various organs, some of which, such as the lungs and liver, are derivatives of the alimentary tube; and others, such as the gonads and urinogenital ducts, are derived from the body-wall. The kidneys are products of the body-wall but usually they are not freely suspended in the coelom. So far as these derivatives of the two primary tubes possess muscle, it is, with a few exceptions, of the nonstriated variety. But the muscles of the locomotor appendages, which are external derivatives of the body-wall, are striated.

In a strict anatomic sense, “somatic” refers to the body-wall; “visceral” refers to the alimentary tube and all organs which occupy coelomic space, or, more precisely (see p. 21), all organs which lie internal to the somatic striated muscle. So far, then, it seems quite simple—somatic muscle is segmented and striated, visceral muscle is unsegmented and nonstriated. But closer scrutiny of the body-wall reveals complicating facts. The body-wall is richly penetrated by blood-vessels. All except the very small blood-vessels, both arteries and veins, possess layers of muscle in their walls, and this muscle is smooth. In the walls of various glands developed in the skin, smooth muscle-fibers

are present—e.g., poison-glands of amphibians, sweat-glands of mammals. Attached to the follicle which contains the “root” of a hair are small nonstriated muscles which cause the hair to “stand on end” (Fig. 443). The iris of the eye contains muscles which regulate the size of the aperture of the pupil, and certain internal muscles of the eyeball (ciliary muscles: Fig. 175) effect accommodation of the eye for vision at varying distances. All of these intrinsic muscles of the eye are smooth. It may seem, therefore, that a distinction between body-wall and viscera based on the nature of their respective muscles is mainly quantitative and not of great significance. But a little consideration of the functions of the several structures in question reveals some highly valid distinctions.

Consistent with the fact that the great bulk of the **body-wall** is constituted of muscles and the skeletal structures necessary for their operation, the chief function of the body-wall is **movement**—changes in relative position of parts of the body, or locomotion of the body as a whole. The energy expended in muscular contraction is derived from products of digestion of food in the inner tube. The oxygen necessary for the chemical liberation of this energy is obtained from the external medium by the visceral respiratory organs. Waste products, some of them toxic, must be drained away from the muscles for elimination by the kidneys. These necessities are all supplied by *visceral organs, but only via the blood-stream*. Therefore, the blood-vessels that enter the body-wall and all their ramifications throughout the body-wall must be regarded as being, both anatomically and functionally (but not in their embryonic origin), *extensions of the coelomic visceral systems* making available the necessary visceral services to every part of the body-wall.

Whereas muscular contraction is the dominant somatic function, it is secondary or lacking in most **visceral organs**. The essential process of digestion is the **chemical action** of secreted substances. Muscular movements in the walls of the digestive tube are accessory. **Secretion** of specific substances and the **absorption** or **diffusion** of substances through cell-membranes (as in the organs of respiration and excretion) are the primary and characteristic functions of most visceral organs. Therefore, in so far as glandular organs are present in the body-wall (with a few exceptions, they are derived only from the skin), they are structures whose functions are of the visceral type and not of the dominant somatic type. Sweat-glands of mammals are important thermoregulators (Fig. 160). Muscular contraction is a source of heat. In regulating the disposition of a by-product of muscular contraction, the sweat-glands perform a function somewhat analogous to that of an excretory organ.

**Somatic** and **visceral** activities differ in their **environmental relations**. Somatic activity is, for the most part, directly concerned with the external environment; visceral activities, with the internal environment. The outer and inner tubes are vitally related to each other. The food which the visceral tube digests must be supplied by somatic activity, and the body-wall is wholly dependent on the visceral organs. But in the business of *getting* the food, the somatic activity is *directly* concerned with the external situation, while the visceral activities involved in digesting the food and distributing its nutriment are wholly directed toward maintaining a normal internal economy.

A most important difference between somatic and visceral activities involves an intangible and undefinable factor which can be stated only in terms of human experience. Actions resulting from contraction of **striated somatic muscles** are, with few exceptions, **voluntary** or potentially voluntary. **Visceral activities** are, with rare exceptions, **involuntary** and commonly do not rise into consciousness at all. The "I" that wills to do things cannot make himself sweat by willing to do so. But he can will to run or to saw wood and may thus produce increased output of perspiration. To assert that somatic activities are voluntary in all vertebrates involves some assumptions. We can only say that there are such similarities in structure and behavior as would seem to justify the assumption that all vertebrates, even fishes, possess in some degree the capacity for voluntary action. In such vertebrates as fishes and salamanders, the range of voluntary action is, no doubt, narrowly limited, and the volition may not rise far above the level of instinctive action.

**To summarize:** The activities of the vertebrate body are of two types, which may be designated as "**somatic**" and "**visceral**," each name referring to the division of the body of which the type is especially, but not exclusively, characteristic.

The primary **somatic function** is **movement**, produced by contraction of muscles which are (at least primitively) usually **segmented** and always constituted of **striated** fibers.

The primary or essential **function of a visceral organ** is commonly some such process as **secretion**, **excretion**, **absorption**, or **diffusion**. In a lymph-node or gonad, it is **proliferation of cells**. In a blood-vessel or ureter, it is mere passive **conduction** of a fluid. Muscular contraction plays a secondary or accessory part in visceral activities, and the muscles, if present, are usually **nonstriated** and are always developed from **unsegmented** mesoderm.

**Somatic muscles** are relatively massive, powerful, and quick-acting. **Visceral muscles** commonly occur in thin sheets and are relatively weak and slow in contracting.

The primary **somatic function** is performance of gross mechanical work. It is mass action or *molar* activity, whereas characteristic primary **visceral function** consists in *molecular* activity, chemical change, or some nonmotor cellular activity.

**Somatic activity** is, for the most part, immediately related to the **external environment**; **visceral activity**, to the **internal environment**.

Contraction of somatic striated muscle is essentially **voluntary**; visceral activities, including contraction of the usually nonstriated muscles which may be concerned in them, are **involuntary**.

The body-wall is primarily "somatic" in the nature of its function, but its blood-vessels and glands perform various essential accessory functions which are of the visceral type. The coelomic visceral territory is not invaded by anything typically somatic.

## PERIPHERAL NERVOUS ORGANS

### FUNCTIONAL CLASSES OF NERVES

In comparative descriptions of nerves and their associated receptors and effectors, the more important characteristics which are usually considered are the following: **position** in the animal; **intrinsic structure** (segmentation and striation of muscles); **relation to central nervous parts**; nature of **function**—whether of the "somatic" or the "visceral" type, in the sense of the foregoing discussion; **embryonic origin**; and **evolutionary origin**. There is no complete correlation among these several characteristics. Certain nerves may possess some of them in common and differ as to the others. In the attempt to classify nerves and their related structures, it is the general practice to give most weight to their functional nature (recognition of "**functional systems**"). Mere position in body is considered least important. Embryonic origin is likely to be regarded as more important than definitive intrinsic structure, and relations to central nervous parts more important than peripheral connections.

Application of these principles results in recognition of four main classes of nerves. In the following table are set forth the characteristics of a *typical* nerve of each class. Certain of the data given refer specifically to a **spinal nerve**, but the cranial nerves, except the olfactory and optic, may be resolved into components whose characteristics are essentially like those of corresponding parts of a spinal nerve. In the brain (the medulla) the centers related to the roots of the nerves are located at four dorsoventral levels as they are in the cord. Named in order from above downward, they are **somatic sensory**, **visceral sensory**, **visceral motor**, and **somatic motor** (Fig. 145). It is significant to note that, in this arrangement of centers, the brain and cord

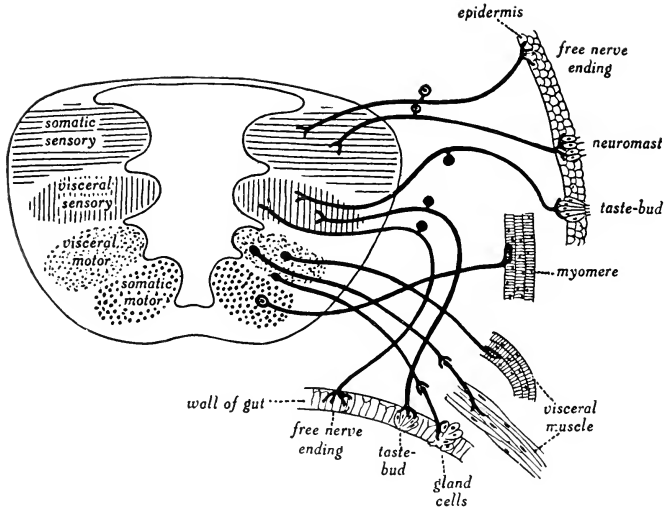


FIG. 145. Diagram showing the central origin (from medulla) and the peripheral distribution of systems of nerve components. (From Goodrich: "Studies on the Structure and Development of Vertebrates." By permission of The Macmillan Company, publishers.)

reflect the general plan of the body—an outer somatic tube and an inner visceral tube.

A distinction between "general" and "special" nerves doubles the number of classes of nerves. "General" is applied to nerves which are related to numerous widely distributed structures of the same general sort; e.g., the myomeres, the various sensory receptors distributed throughout the skin. "Special" nerves innervate organs which are more or less definitely localized and highly specialized; e.g., the eye, ear, and olfactory organ, the extrinsic muscles of the eyeball. In each of the four main classes of nerves defined above, both "general" and "special" nerves may be recognized.

The central nervous system consists of the brain and spinal cord. The remotest outposts of the nervous system are the sensory receptors, wherever situated, and the nerve-terminations on all effectors. Between the central organs and the peripheral termini of the system is an overwhelmingly complex system of nerves whose ramifications extend into every part of the body. For the most part, these nerves consist of fibers which pass from the periphery directly and without interruption



*Table 2*  
SENSORY (AFFERENT) NERVE

	<i>Central Connection</i>	<i>Exit from Central Organ</i>	<i>Location of Cell-Body</i>	<i>Receptors</i>
Somatic . . .	Dorsal region of dorsal column of gray matter in spinal cord	Dorsal root	Ganglion on dorsal root	Exteroceptors in skin of body-wall and proprioceptors in muscles of body-wall
Visceral . . .	Deep region of dorsal column of gray matter in spinal cord	Dorsal root	Ganglion on dorsal root	Interoceptors and proprioceptors of digestive tube and other coelomic viscera

MOTOR (EFFERENT) NERVE

	<i>Central Connection and Location of Cell-Body</i>	<i>Exit from Central Organ</i>	<i>Effectors (Muscles)</i>					<i>Environmental Relation of Function</i>	<i>Psychic Correlate</i>
			<i>Embryonic Origin</i>	<i>In Adult</i>	<i>Histologic Nature</i>	<i>Position</i>			
Somatic . . .	Ventral region of ventral column of gray matter in spinal cord	Ventral root	Dorsal segmented mesoderm	Segmented	Striated	Body-wall	External environment	Voluntary	
Visceral . . .	Deep region of ventral column of gray matter in spinal cord	Ventral root	Ventrolateral unsegmented mesoderm	Unsegmented	Nonstriated	Walls of viscera	Internal environment	Involuntary	

into the central organs—into the brain via cranial nerves and into the spinal cord via spinal nerves. There is, however, another system consisting of fibers which are connected to a somewhat definitely localized series of ganglions interposed between the central organs and the periphery. These ganglions have nervous connections with the central nervous system, but the peripheral distribution of the nerves proceeding outward from them is to those structures whose functions are of the "visceral" type, whether the structures are situated in visceral or somatic territory. This interpolated system is known as the "**autonomic**," or formerly commonly called the "sympathetic," nervous system.

CRANIAL NERVES

Nerves entering or emerging from the brain are called "cranial." They are all paired. Fishes and modern amphibians possess 10 pairs. In

reptiles, birds, and mammals, the corresponding 10 pairs are present, plus 2 pairs added at the posterior end of the series. Fossil skulls of primitive amphibians give evidence of the presence of 12 pairs of cranial nerves.

A **cranial nerve** may contain only afferent or only efferent fibers, in which case it is described as, respectively, **sensory** or **motor**. A nerve containing fibers of both kinds is called "**mixed**." Nerves passing to receptors in the body-wall are called "**somatic sensory**," except that such fibers as go to structures which are of the "visceral" type but situated in the body-wall (e.g., blood-vessels) may be called "visceral." Nerves connected with striated (voluntary) muscles in the body-wall are **somatic motor**. Similarly, there are **visceral sensory** and **visceral motor** nerves related to the visceral organs.

Excepting the olfactory and optic nerves and a part of the fifth cranial nerve, the sensory fibers of a cranial nerve are outgrowths of cells located in its ganglion which is external to the brain, appearing as an enlargement of the nerve near its junction with the wall of the brain (Figs. 146, 147). The motor fibers in the root of a cranial nerve arise from cells inside the brain. These motor cells commonly occur in groups or "centers" which are virtually ganglions but are often called "nuclei"—an unfortunate term: a motor "nucleus" must not be confused with the internal nucleus of a single cell.

Brief descriptions of the cranial nerves follow. Points of origin of nerves from the brain are shown in Figs. 136, 138, 146, 147. For distribution of nerves, see Figs. 146, 147.

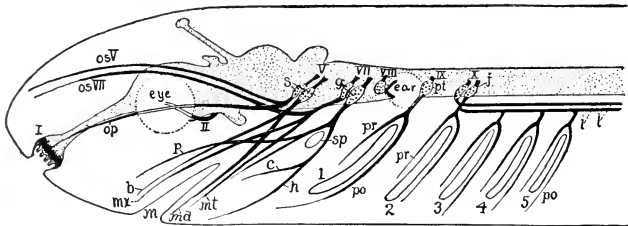


FIG. 146. Diagram of cranial nerves of lower vertebrate. Eye-muscle nerves are omitted; central nervous system is dotted; fifth nerve is represented as composed of two nerves; lateralis nerves are separated from the ninth and tenth nerves. (I-X) Cranial nerves; (1-5) gill-clefts; (b) buccalis nerves; (c) chorda tympani; (g) geniculate ganglion; (h) hyoid nerve; (i) intestinal (pneumogastric) nerve; (j) jugal ganglion; (l) lateral-line nerve of (X); (m) mouth; (md) mandibular nerve; (mt) mentalis nerve; (mr) maxillary nerve; (op) ophthalmicus profundus nerve; (os V, os VII) superficial ophthalmic nerves of (V) and (VII); (p) palatine nerve; (po) posttrematic nerves; (pr) pretrematic nerves; (pl) petrosal ganglion; (s) semilunar (Gasserian) ganglion; (sp) spiracle. (Courtesy, Kingsley: "Comparative Anatomy of Vertebrates," Philadelphia, The Blakiston Company.)

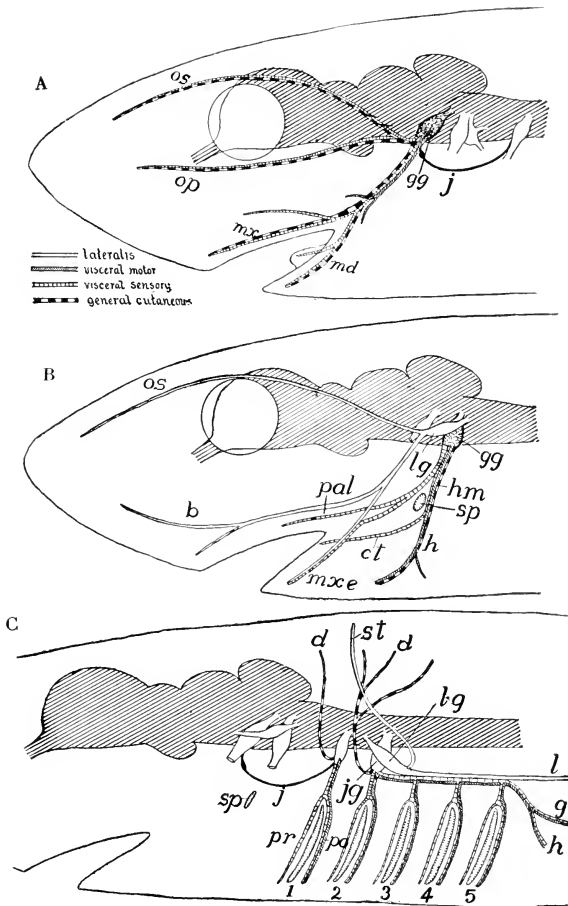


FIG. 147. Diagrams of the branches and components of (A) the trigeminal, (B) the facial, and (C) the glossopharyngeal and vagus nerves of a lower vertebrate. (*b*) Buccal nerve; (*ct*) chorda tympani; (*d*) dorsal rami of IX and X; (*g*) gastric nerve; (*gg*, in A) Gasserian ganglion; (*gg*, in B) geniculate ganglion; (*h*) hyoid nerve; (*hm*) hyomandibular trunk; (*j*) Jacobson's connective; (*jj*) jugular ganglion, (*l*) lateralis nerve; (*lg*, in B) lateral ganglion of VII; (*lg*, in C) lateral ganglion of X; (*md*) mandibular; (*mxe*) external mandibular; (*mx*) maxillary; (*op*) ophthalmicus profundus nerve; (*os*) superficial ophthalmic nerve; (*pal*) palatine nerve; (*po*, *pr*) post- and pretrematic rami; (*sp*) spiracle; (*st*) nerve to supratemporal lateral-line organs; (1-5) gill-clefts. (Courtesy, Kingsley: "Comparative Anatomy of Vertebrates," Philadelphia, The Blakiston Company.)

**I. Olfactory**, consisting of fibers developed as processes of the sensory cells in the lining of the olfactory (nasal) chamber and passing into the olfactory lobe of the telencephalon. **Sensory**. Closely associated with each olfactory nerve is a relatively small **nervus terminalis** (Fig. 136), which passes to the olfactory surface, but its fibers are derived from cells in a small ganglion borne by the nerve. Apparently sensory, the nature of the function of the nerve is not known.

**II. Optic**, consisting mainly of **sensory** fibers derived from cells in the retinal layer of the eye. Most, if not all, of the fibers pass through the diencephalon to primary optic centers in the roof of the mesencephalon. Except in fishes, however, some optic fibers pass directly to centers in the thalami. These thalamic connections are most numerous in mammals. A small minority of the optic fibers have origin from nerve cells in the mesencephalon and grow forward and outward along the optic stalk into the retina. The function of these centrifugal fibers is problematic. At the base of the diencephalon, the right and left optic nerves meet and some or all of the fibers of one nerve cross those of the other, so that fibers of either nerve pass to optic centers in the opposite side of the brain. The region of crossing, the **optic chiasma**, occasions more or less of a prominence on the ventral surface of the diencephalon (Figs. 140, *oc*, 530). In most vertebrates the crossing (**decussation**) is complete, but in mammals the decussation is incomplete, each nerve distributing fibers to centers on both sides of the brain.

It is to be emphasized that the optic nerve differs from all other cranial nerves in that the exteroceptors to which it is related are themselves a product of the embryonic brain. The entire mechanism of vision is a pair of highly specialized lateral protrusions of the brain.

**Nerves III, IV, and VI** innervate the small muscles which rotate the eyeball in its orbit (Fig. 148). In all vertebrates there are six of these extrinsic muscles of the eyeball. Four of them constitute a **rectus** group—according to the positions of their points of attachment to the eyeball, a dorsal, a ventral, an anterior, and a posterior rectus muscle. These four muscles converge to their attachment at the posterior region of the orbit. The two others, a dorsal and a ventral **oblique** muscle, pass obliquely forward to attach at the anterior region of the orbit.

**III. Oculomotor**, consisting *mainly* of **somatic motor** fibers coming from a motor center in the base of the mesencephalon and innervating four of the muscles of the eyeball, the **dorsal, ventral, and anterior recti**, and the **dorsal oblique** muscle. A small branch goes outward to supply the muscle which raises the upper eyelid, the **levator**

**palpebrae superioris.** The oculomotor contains relatively few sensory fibers, which are related to proprioceptors situated in the several muscles. Some autonomic motor fibers, derived from cells in the small

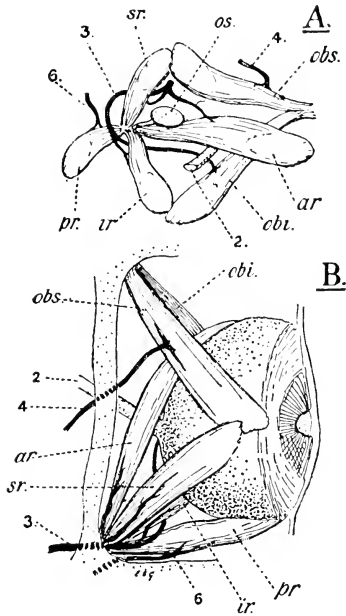


FIG. 143. *Squalus acanthias*. (A) Outer lateral view of muscles and nerves of right orbit, from which the eye has been removed. (B) Dorsal view of right eye. (*ar*) Anterior, (*ir*) inferior (ventral), (*pr*) posterior, and (*sr*) superior (dorsal) rectus muscles; (*obi*) inferior, and (*obs*) superior oblique muscles; (*os*) cartilaginous optic stalk; (2) optic nerve; (3) oculomotor nerve; (4) pathetic (trochlear) nerve; (6) abducent nerve. (From Goodrich: "Studies on the Structure and Development of Vertebrates." By permission of The Macmillan Company, publishers.)

autonomic **ciliary ganglion** with which the nerve is connected, penetrate into the eyeball and supply the internal smooth muscular mechanism of the eye.

**IV. Trochlear, mainly somatic motor**, its fibers coming from a motor center located ventrally in the region of junction of the mesencephalon and the metencephalon, and supplying the **dorsal oblique muscle**. It may include some proprioceptive fibers. The trochlear nerves are the only nerves which emerge from the dorsal surface of the brain (Figs. 136, 138A). At the region of emergence, between the optic lobes and the cerebellum, the right and left nerves cross, forming a **trochlear chiasma**.

**V. Trigeminal**, so called because in all vertebrates it has **three** main divisions (Fig. 147A): a **sensory ophthalmic** extending above the eye to the skin on the upper side of the snout or the forehead; a **sensory maxillary** to the skin on the side of the snout and the region of the upper jaw and to the upper teeth; and a **mixed mandibular** supplying skin, teeth, and muscles of the lower jaw, and the tongue. Most of the sensory fibers of the nerve arise from cells in the large **semilunar (Gasserian) ganglion** situated on the base of the nerve just external to its place of emergence from the medulla. But a unique feature of the trigeminal nerve is a sensory ganglionic center located *inside* the brain—in the roof of the mesencephalon. The trigeminal **motor center** is in the lateral column of the medulla.

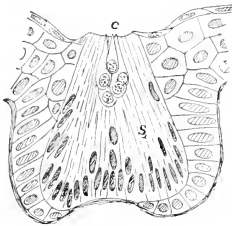


FIG. 149. Sense-organ of lateral line of the amphibian, *Diemyctylus* (aquatic form). (c) Cone-cells; (s) spindle-cells. (After Kingsbury. Courtesy, Kingsley: "Comparative Anatomy of Vertebrates," Philadelphia, The Blakiston Company.)

the medulla posterior to that of the abducent nerve. Of all the cranial nerves, its distribution is most complex (Fig. 147B).

In fishes and wholly aquatic amphibians, an important part of the facial nerve is concerned with the **lateral-line organs**, a system of sense-organs peculiar to these groups. A single lateral-line organ, a **neuromast**, is a cluster of elongated epidermal cells, at whose bases are the terminal fibrils of afferent nerve-fibers belonging to cells situated in a ganglion of the facial nerve (Fig. 149). Usually these neuromasts occur on the walls of canals which lie deep in the skin but are *lined by epidermis*. At intervals, the canal opens to the exterior by small pores. The lumen of the canal is filled by mucus. The longest of these

**VI. Abducent**, a **somatic motor** nerve (but containing some proprioceptive fibers) emerging from the medulla ventrally and behind the trigeminal, and supplying the **posterior rectus muscle** of the eyeball (Fig. 148).

**VII. Facial**, a **mixed nerve** which may have two or three ganglions. Its motor component comes from a center in the medulla posterior to that of the abducent nerve. Of all the cranial nerves, its distribution is most complex (Fig. 147B).

**VIII. Vestibulocochlear**, a **somatic motor** nerve (but containing some proprioceptive fibers) emerging from the medulla ventrally and behind the facial, and supplying the **posterior rectus muscle** of the eyeball (Fig. 148).

**IX. Glossopharyngeal**, a **mixed nerve** which may have two or three ganglions. Its motor component comes from a center in the medulla posterior to that of the abducent nerve. Of all the cranial nerves, its distribution is most complex (Fig. 147B).

**X. Vagus**, a **mixed nerve** which may have two or three ganglions. Its motor component comes from a center in the medulla posterior to that of the abducent nerve. Of all the cranial nerves, its distribution is most complex (Fig. 147B).

**XI. Accessory**, a **somatic motor** nerve (but containing some proprioceptive fibers) emerging from the medulla ventrally and behind the vagus, and supplying the **posterior rectus muscle** of the eyeball (Fig. 148).

**XII. Hypoglossal**, a **somatic motor** nerve (but containing some proprioceptive fibers) emerging from the medulla ventrally and behind the accessory, and supplying the **posterior rectus muscle** of the eyeball (Fig. 148).

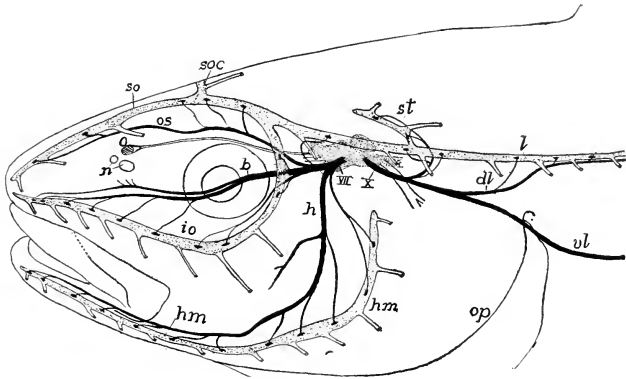


FIG. 150. Head of pollack, showing lateral-line canals and nerves of the lateralis system. Lateralis nerves are black, canals and brain dotted. (*b*) Buccal ramus of VII nerve; (*dl*) dorsal ramus of lateralis of X nerve; (*h*) hyomandibular nerve; (*hm*) hyomandibular line of organs; (*io*) infraorbital line; (*l*) lateral-line canal; (*n*) nares; (*o*) olfactory lobe; (*op*) operculum; (*os*) superficial ophthalmic nerve; (*so*) supraorbital line of organs; (*soc*) commissure connecting lines of the two sides; (*st*) supratemporal part of lateral line; (*vl*) ventral ramus of lateralis of X nerve; (*X*) visceral part of X nerve. (After Cole. Courtesy, Kingsley: "Comparative Anatomy of Vertebrates," Philadelphia, The Blakiston Company.)

canals is the **lateral-line canal**, which extends from head to tail along the side of the body at the level of the horizontal septum separating the epaxial and hypaxial parts of the body-muscle. In the region of the head, the canals are arranged in a more or less complex branching system (Fig. 150). In some fishes, the neuromasts lie in open superficial grooves instead of deep canals. In round-mouthed eels and amphibians, each neuromast is in a separate pit. They are not always arranged in rows, but may be scattered over localized areas of skin—e.g., on the heads of sharks are patches of pores, each pore leading into a deep pit at whose bottom are neuromasts. These scattered structures are known as **organs** (or **ampullae**) of **Lorenzini**.

The neuromasts are probably stimulated by low-frequency vibrations in the water, or possibly by currents in the water or by pressure.

A special division of the facial nerve, having its separate ganglion, supplies most of the lateral-line organs in the region of the head. Of this division, there are three main branches, the **ophthalmic**, **buccal**, and **external mandibular** (Figs. 147B; 150), these three branches running closely parallel to the respectively corresponding trigeminal trunks, the ophthalmic, maxillary, and mandibular. In each locality served by this double innervation, the **facial fibers go exclusively to lateral-**

**line organs**; the trigeminal fibers go to other receptors in the skin but never to neuromasts. In vertebrates which do not possess lateral-line organs, the facial nerve totally lacks anything corresponding to its lateral-line division in fishes and amphibians.

The facial nerve in all vertebrates has a large **geniculate ganglion** (Fig. 147B), whence an important **sensory palatine branch** goes to the roof of the mouth and a sensory **internal mandibular (chorda tympani)** of mammals) to the lower jaw and floor of the mouth and to taste-receptors on the anterior region of the tongue. The main motor component of the facial is a **hyomandibular trunk** which distributes to numerous striated voluntary muscles (the **branchiomic muscles**) in the region of the lower jaw, hyoid, and pharynx.

The seventh nerve acquires its name from the fact that, in mammals—especially man—it comes into prominence as being the chief nerve supplying the greatly expanded superficial musculature of the whole facial region, including some muscles of the external ear. These facial muscles apparently had their evolutionary origin in the branchiomic muscles of fishes (Figs. 95, 96).

**VIII. Acoustic (or auditory)**, but inaccurately so called because the ear serves not only for hearing, but also for equilibration, and it is possible that the ears of some fishes do not mediate a sense of hearing. The nerve is purely **sensory**. It is virtually two nerves, each having a ganglion. The **vestibular ganglion** and **vestibular trunk** are concerned with **equilibration**, the **spiral ganglion** and **cochlear nerve** with **hearing**. The fibers of both nerves pass to primary centers in the medulla. The eighth nerve is the only cranial nerve that does not emerge from the cranium, the ear itself being within the cranium.

**IX. Glossopharyngeal, a mixed nerve.** Its visceral sensory fibers come from the **petrosal ganglion** (Fig. 146, *pt*), the motor fibers from nuclei in the medulla. In some fishes the nerve includes somatic sensory fibers passing to neuromasts of a small dorsal division (**supratemporal**: Fig. 150, *st*) of the lateral-line system.

In **gill-breathers** the main nerve passes to the roof of the first branchial chamber and there divides into two trunks (Fig. 147C), a purely sensory **pretrematic** distributing to the anterior wall of the chamber and a mixed **post-trematic** to the posterior wall. The **pretrematic** is, accordingly, associated with the **hyoid arch** and the **post-trematic** with the **first branchial arch**. The sensory fibers, mostly visceral, pass to interoceptors of the pharynx and hind part of the oral cavity. The relatively small somatic division goes to the skin in the region of the first gill-cleft. The post-trematic trunk supplies the striated branchiomic muscles of the first branchial arch.



In **terrestrial vertebrates** the ninth nerve distributes to interoceptors of the pharynx and to the taste-receptors of the posterior region of the tongue. In mammals the somatic sensory part of the nerve is represented by a branch going to the skin of the external ear. Since the external auditory passage corresponds to the spiracular passage of fishes and the entire auditory mechanism develops in close relation to the embryonic hyoid arch, this **auricular branch** of the nerve does not stray far from the primitive territory of the nerve. The motor division of the nerve distributes to striated muscles in the hyoid region and on the walls of the pharynx.

**X. Vagus** (or **pneumogastric**), a large **mixed nerve** formed by union of several small roots which emerge along the side of the medulla just behind the ninth nerve (Figs. 136, 530). Several ganglions are associated with it, chief of them being the **jugular** and the **nodose ganglions**. In vertebrates having lateral-line organs, there is a special **lateral ganglion**. The motor nuclei of X are closely associated with those of IX in the medulla.

In **gill-breathers** (Fig. 147C) the vagus passes dorsally to the region of the gills and gives off a trunk to each chamber behind the first (which is supplied by IX). Each **branchial trunk** divides into a **sensory pretrematic** and a **mixed post-trematic** branch which innervate their respective regions and the adjacent region of the pharynx. The post-trematic trunks innervate the striated **branchiomic muscles** posterior to those supplied by IX. From the branchial region, a large **visceral trunk** (Fig. 147C, *g*) continues back into the coelom to an extensive distribution comprising interoceptors, proprioceptors, and muscles of the esophagus, stomach, and anterior region of the intestine, the lungs (if present), and also the heart. The **lateral division** of the vagus, arising from the lateral ganglion (*lg*), supplies the neuromasts of the entire length of the main lateral-line canal. It is usually the longest nerve in the animal, its fibers extending continuously from the brain nearly to the tip of the tail.

In **terrestrial vertebrates** the lateral division of the vagus is in no way represented. In the absence of gills, the nerve provides sensory and motor innervation to the respiratory region of the pharynx and to the respiratory organs which develop by outgrowth from the floor of the pharynx—the larynx, trachea, and lungs. This innervation includes many small striated muscles (**branchiomic**) related to the hyoid and the larynx. The vagus may supply a small posterior area of taste-receptors. In mammals a small somatic sensory branch assists IX in supplying the skin of the external ear. As in gill-breathers, there is extensive distribution to the esophagus, abdominal viscera, and heart.

**XI. Accessory** (or **spinal accessory**), a purely motor nerve partly associated with the vagus—i.e., “accessory” to the vagus (Figs. 138, 530)—and in part resembling a spinal nerve. Some of its centers are in the medulla and others in the spinal cord. Some of its fibers may join vagus fibers in supplying thoracic and abdominal viscera. Its chief distribution is to certain muscles of the neck (**cleidomastoid, sternomastoid**) and to the **trapezius**, an important superficial dorsal muscle extending between the vertebral column and the shoulder girdle (Fig. 91).

**XII. Hypoglossal**, purely motor, innervating small muscles of the hyoid and larynx and the important muscles which constitute the tongue (Fig. 530).

The **accessory** and **hypoglossal nerves** appear, as such, only in reptiles, birds, and mammals, although possibly present in ancient amphibians. Their origin is problematic. Some fishes have several pairs of nerves which are typically spinal in character but arise from the extreme hind region of the medulla and, therefore, inside the cranium. It has been mentioned (see p. 112) that, in development of the cranium, several embryonic “occipital vertebrae” may become incorporated into its occipital region. There is much evidence that the vertebrate head and neck have been, in effect, so pushed into one another that some vertebrae have been “absorbed” into the skull and some spinal nerves find themselves inside the cranium (**spino-occipital nerves**). The accessory nerve may be regarded as a hybrid compounded partly of fibers extracted from the vagus and partly spinal in origin. The hypoglossal is evidently constituted entirely of spinal motor roots.

#### *Groups of Cranial Nerves*

The 10 or 12 cranial nerves fall naturally into definite groups.

**I and II** are **nerves of special sense organs**. The unique manner of origin of the olfactory fibers and the fact that the retinal receptors of the optic nerve are themselves derived from the brain set these two nerves apart from all the others.

**III, IV, and VI** constitute an **oculomotor group**. It is a striking fact that the small muscles of the eyeball monopolize 3 of the 12 nerves.

**V, VII, and VIII** are closely related in their embryonic origin and there is much overlapping in the distribution of V and VII. The sense-organs within the ear, like the neuromasts of the lateral-line system, are stimulated by vibrations of the external medium. This similarity in function, and peculiarities in the manner of development and in the structure of the ear, indicate strongly that the sensory mechanism of

the ear is a highly specialized part of the lateral-line system. Nerve VIII may be regarded as part of the lateral-line division of VII.

**IX and X** are closely allied in origin and distribution.

**XI and XII** occupy a confused "no-man's land" in the region of transition between brain and cord.

While there is considerable overlapping in the territorial distribution of V and VII and of IX and X, it is possible to recognize a territorial center for each nerve. V is concerned mainly with the region of the mandibular arch; VII, with the spiracular and hyoidean region; IX, with the first branchial chamber; and X serves the entire branchial territory behind the first gill-chamber, however many the gill-chambers and arches may be. In terrestrial vertebrates, these nerves retain their primitive territorial relations, serving such structures as may have persisted from gill-breathers or new structures which may have arisen in the respective old territories of the several nerves. The extraordinary feature of X is the extreme posterior extent of its somatic lateral-line trunk and its important intestinal division.

One striking feature common to V, VII, IX, and X is that each has its **pretrematic** and **post-trematic divisions** (*trema* meaning a "hole"). V sends a trunk to the upper jaw and one to the lower jaw. (In sharks the upper jaw is anterior to the lower jaw.) Similarly the spiracle is straddled by VII, the first gill-chamber by IX, and each of the remaining gill-chambers by a division of X.

#### SPINAL NERVES

The spinal nerves are segmentally arranged—a pair to each segment of the body-muscle. Two trunks or "roots" intervene between the cord and the main nerve, a dorsal and a ventral root (Figs. 144, 151). The exit of the nerves from the vertebral column is usually intervertebral, but in sharklike fishes the roots pierce cartilaginous elements of the column and in some other vertebrates the nerves may pierce bony vertebrae.

The **dorsal root** is composed mainly or entirely of **sensory** fibers which arise from cells of a **spinal ganglion** situated on the root near its junction with the ventral root (Fig. 151). Each cell of the ganglion produces a bifurcating process (Fig. 152), one of whose branches passes along the root into the cord, where it divides usually into a long **ascending** and a short **descending fiber**. From each of these pass very fine branches into the dorsal column of the "gray matter," where synaptic connection with other neurons is made. The other of the two primary branches of the ganglion-cell passes outward into the main trunk of the spinal nerve and proceeds directly to some receptor. The

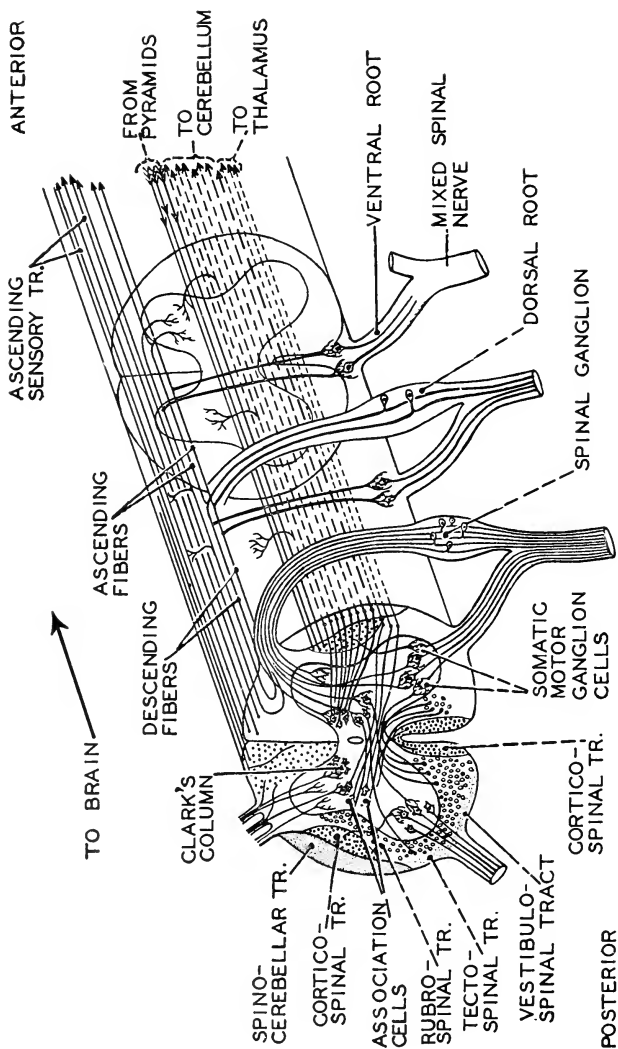


FIG. 151. Diagram showing relations of fibers in spinal cord and nerves. (After Plate, Courtesy, Neal and Rand: "Chordate Anatomy," Philadelphia, The Blakiston Company.)

**ventral root**, usually emerging from the cord in several small rootlets, consists entirely of **motor** fibers derived from cells in the gray matter of the cord (Fig. 151).

The fibers which enter the cord via the ganglion-cells of the dorsal root come from exteroceptors (in the skin), interoceptors, and proprioceptors—i.e., they include both somatic and visceral conductors (Fig. 152). In many vertebrates, but ordinarily not in mammals, the dorsal root contains a relatively small number of visceral motor fibers. These come from cells in the gray matter and pass through the spinal ganglion, but have no connection with the cells in the ganglion.

Of the fibers that constitute the ventral root, some are somatic and some are visceral (Fig. 152). The somatic fibers innervate the striated (voluntary) muscles of the body-wall. The visceral fibers are connected,

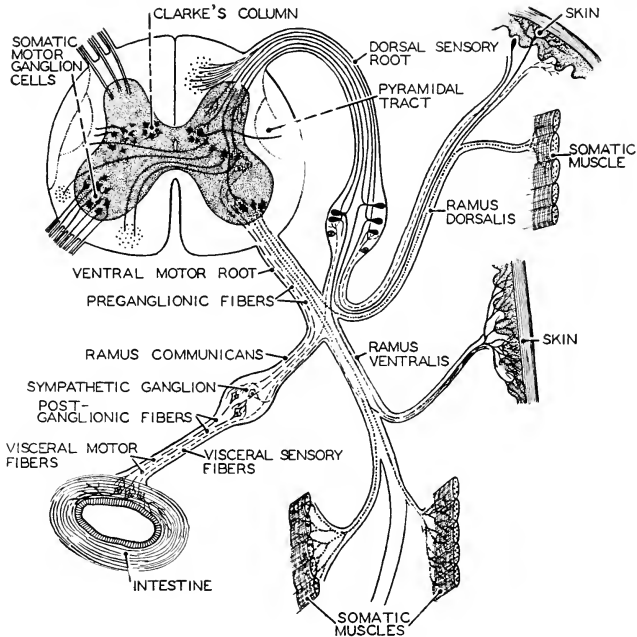


FIG. 152. A diagram of neurons of the spinal cord and spinal nerves, showing relations of the neurons to one another and to their end-organs. Somatic sensory fibers are shown by continuous lines, somatic motor fibers by fine dots. Visceral sensory fibers are indicated by short broken lines, visceral motor by long broken lines. (After Plate. Courtesy, Neal and Raud: "Chordate Anatomy," Philadelphia, The Blakiston Company.)

via the autonomic ganglions, with the smooth or involuntary visceral muscles and with glands.

The two spinal roots unite near the ganglion to form a mixed nerve which then divides into three trunks (Fig. 152). Two of them pass outward into the body-wall. One, the **dorsal ramus**, goes to the epaxial division of the body-muscle and to the corresponding region of the skin. The other, the **ventral ramus**, innervates the hypaxial muscle and the corresponding ventral region of skin. The third and smaller trunk, the **ramus communicans**, is a visceral branch which passes into a neighboring ganglion of the autonomic system.

**Plexuses.** In general, the distribution of a spinal nerve is fairly closely restricted to its particular segment of the body, but, in the region of the paired appendages, this relation seems to be modified by union of the ventral rami of several nerves to form an interlacing network or **plexus** (Fig. 153) from which nerves emerge distally and pass into the appendage. Four such plexuses occur in vertebrates, **cervical**, **brachial**, **lumbar**, and **sacral**. Commonly, the anterior two join to form a **cervicothoracic plexus**, and the posterior two form a **lumbo-sacral plexus**. The number of spinal nerves involved in the plexus of

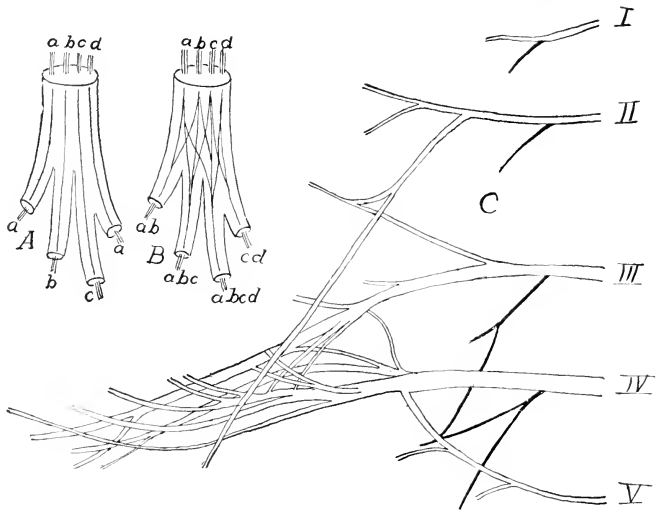


FIG. 153. (A) Diagram of a collector nerve. (B) Diagram of a nerve plexus. (After Braus.) (C) Diagram of a brachial plexus of *Salamandra maculata*. (After Fürbringer.) (Courtesy, Kingsley: "Comparative Anatomy of Vertebrates," Philadelphia, The Blakiston Company.)

an appendage has some relation, but not an exact one, to the number of somatic segments which contribute to the development of the appendage. In the skate, a fish having the pectoral fin enormously expanded anteroposteriorly, there are about 25 nerves in the cervicothoracic plexus. In general, there is great variation in the number of nerves in the plexuses of the paired limbs, the range being usually between 2 and 10.

The anatomic consequence of the interconnecting of the several nerves of a plexus is that a single muscle of the appendage receives nerve-fibers from several, or perhaps all, of the spinal nerves which enter the plexus. This may mean that one muscle is compounded of material derived from all of the several segments corresponding to the nerves which contribute to its innervation. It is certain that the embryonic segmentation of the muscle-forming mesoderm is at least much modified and usually quite obliterated in the course of development of the complex group of muscles of a tetrapod appendage. It is not certain that the plexus is functionally significant.

In most fishes and in tailed aquatic amphibians, the tail is the chief swimming-organ. The segmentally arranged muscles continue from the trunk back to the tip of the tail, and the spinal cord is coextensive with the muscles, giving off nerves throughout the entire length of the tail. In animals whose tails are not locomotor and are of minor functional importance, muscles are present only in a short proximal region of the tail, and a greater or less extent of the caudal region of the neural tube fails to produce nervous tissue, persisting in the adult as a slender nonfunctional vestige, the **filum terminale**. In many cases (e.g., frog and man), the longitudinal growth of the vertebral column exceeds that of the spinal cord, with the result that the more posterior spinal nerves, whose foramina of exit are established at an early stage, are dragged backward by the elongating vertebral column and form a bundle of nerves extending back alongside the cord and inside the vertebral canal. This bundle, together with more or less of the **filum terminale**, is called the **cauda equina** (Fig. 156).

#### AUTONOMIC NERVOUS SYSTEM

The basic activities of cells may proceed independently of excitation or control by nervous mechanism. A gland-cell may secrete or a muscle-cell may contract in complete absence of any connection to a nerve-cell. A heart continues its rhythmic pulsation after all nerves connected to it externally have been cut. But there is much nervous tissue upon or in the walls of the heart itself. A small fragment of muscle completely detached from the wall of the heart and placed in a suitable chemical

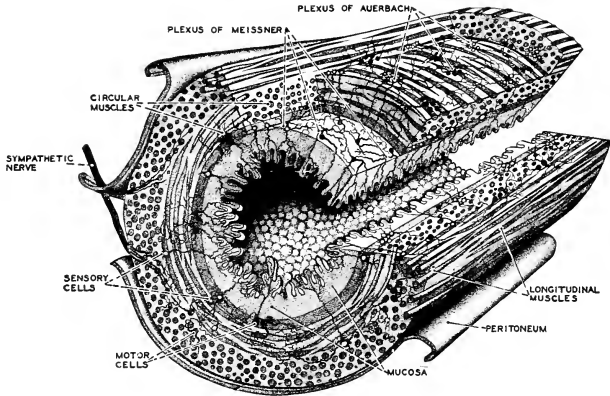


FIG. 154. Stereogram of a portion of the small intestine, showing the arrangement of sympathetic neurons in the plexuses of Meissner and Auerbach. Motor cells are shown in black, sensory cells with white nuclei. (After Kahn. Courtesy, Neal and Rand: "Chordate Anatomy," Philadelphia, The Blakiston Company.)

environment continues to pulsate, but in this case it is difficult to ascertain that the fragment is quite devoid of nervous elements. When a short tubular piece of the intestine is cut out and isolated from all external nervous connection, its characteristic **peristalsis** (anteroposterior waves of contraction) continues. In this case, it is certain that nervous tissue is present, for throughout the wall of the intestine (also the stomach and esophagus) and between its inner circular layer and outer longitudinal layer of smooth muscle is a delicate and complex network consisting of nerve-cells and their connecting nerve-fibers, the **plexus of Auerbach**. A similar **myenteric plexus (plexus of Meissner)** lies at the internal surface of the layer of circular muscles (Fig. 154). It is evident that these plexuses constitute a nervous system which immediately controls the muscular activities of the intestine, presumably by providing numerous local reflex arcs. This control may be exercised in total absence of any connection with the cerebrospinal system. Not only the intestine but also the heart, lungs, and most other hollow visceral organs possess their intrinsic nervous mechanisms consisting of neurons whose cell-bodies are more or less definitely segregated into ganglions or gangliated plexuses which lie on the external surface of the organ or may be embedded in its wall.

Some of the secretory activities involved in digestion of food are directly or indirectly excited by the mere presence of food in the digestive tube. Various glands of the body are stimulated to secretory ac-



tivity by hormones carried in the blood. From the fact that some visceral activities may be initiated and may proceed without stimulation by nerves external to the organ, and the additional fact that most visceral organs possess intrinsic mechanisms which are adequate for maintenance of the basic or routine activity of the organ, it follows that, up to a certain point, a visceral organ is autonomous. The numerous visceral ganglions and plexuses are the most peripheral (i.e., most remote from the cerebrospinal system) elements of the **autonomic nervous system**.

A human community such as that of a town or city is autonomous in the administration of most of its routine internal affairs. But in some matters it is subject to control by the state or federal government. The common welfare of the local community and the larger political whole makes such control necessary. In the animal, each of the various parts and the whole are mutually dependent and the parts are vitally dependent upon one another. It is the somatic animal—the “outer tube” that most directly meets the impact of agencies in the animal’s outside world. An outfit of autonomous visceral organs, each going its own way and performing its routine function with inexorable uniformity, would not serve the purpose. If the outer voluntary somatic animal is to make effective reaction and adjustment to the vicissitudes of living, the visceral functions must be capable of prompt and appropriate regulation to meet the ever changing requirements of the somatic animal. The nervous mechanism which provides for this necessary correlation of visceral (in the broad sense of “visceral”—see p. 156) activities and their regulation in relation to somatic activities consists of a complex system of ganglions and connecting nerves interposed between the viscera and the cerebrospinal system. This intermediating system has numerous connections with the brain and spinal cord and is to be regarded as including the intrinsic nervous mechanisms of the viscera themselves. In its entirety it is known as the **autonomic system** (formerly commonly called “**sympathetic**”). In the following anatomic description, some details refer particularly to mammals, whose autonomic system is best known. In other vertebrates, the general arrangement of the system is like that in mammals but with differences in details.

### *Autonomic Ganglions*

The most conspicuous part of the autonomic system is a pair of longitudinal nerve-cords lying just beneath the vertebral column and close alongside and parallel to the dorsal aorta. The cords extend throughout the regions of the trunk and neck, and into the base of the tail in some vertebrates (Figs. 155, 156, 157). In the region of the trunk, ganglionic enlargements occur at regular intervals along each cord.

These ganglions are segmental in arrangement, each pair corresponding to an adjacent myomere and its pair of spinal nerves. In the cervical region of each **autonomic cord** there are usually three ganglions, the **anterior** and **middle cervical** and, behind them, a large **stellate ganglion** which is apparently produced by fusion of several posterior cervical and anterior thoracic ganglions (Figs. 156, 157). Each cord and its several ganglions are often described as being a "chain" of ganglions. Accordingly, the ganglions are commonly called "**chain ganglions**," otherwise **lateral ganglions**.

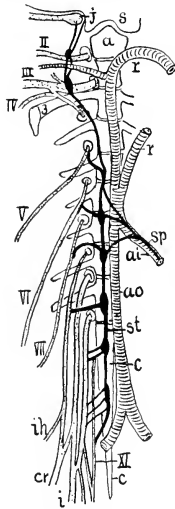


FIG. 155. Autonomic system of right side of a frog. Somatic nerves are dotted, autonomic black. (a) Atlas; (ai) common intestinal artery; (ao) aorta; (c) coccyx; (cr) crural nerve; (i) sciatic nerve; (ih) iliohypogastric nerve; (j) jugal ganglion; (r) radices aortae; (s) base of skull; (sp) splanchnic nerve; (st) autonomic trunk; (II-XI) second to eleventh trunk nerves. (After Gaupp. Courtesy, Kingsley: "Comparative Anatomy of Vertebrates," Philadelphia, The Blakiston Company.)

The double series of ganglions is continued forward into the head by pairs, usually five, of ganglions which are external to the cranium and in close ventrolateral proximity to it. These, mentioned in order from anterior backward (Fig. 157), are the **ciliary** (A, lying in the orbit), **sphenopalatine** (B, in the roof of the mouth), **sublingual** and **submaxillary** (E, each close to the salivary gland of the same name), and the **otic** (C, at the base of the external ear). (See also Fig. 159.) From the anterior cervical ganglion, a small nerve extends forward and connects, directly or indirectly, with the several cephalic ganglions of the corresponding side of the head.

All of these paired **autonomic ganglions** are connected with the cerebrospinal system. Each lateral ganglion within the thoracic, lumbar, and sacral regions, with the occasional exception of one or two

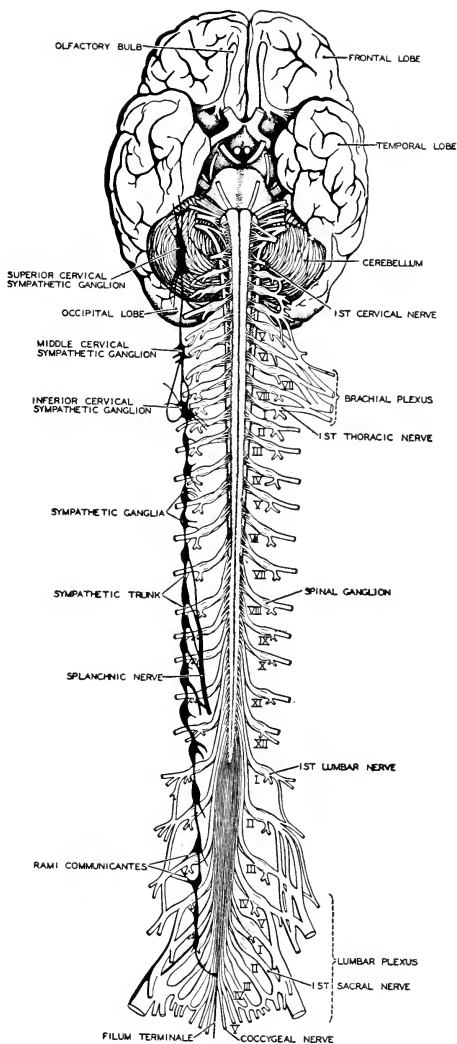


FIG. 156. The brain and spinal cord of man, in ventral aspect, showing relations of spinal nerves to the chief autonomic ganglions. (Redrawn from Morris, after Allen Thomson. Courtesy, Neal and Rand: "Chordate Anatomy," Philadelphia, The Blakiston Company.)

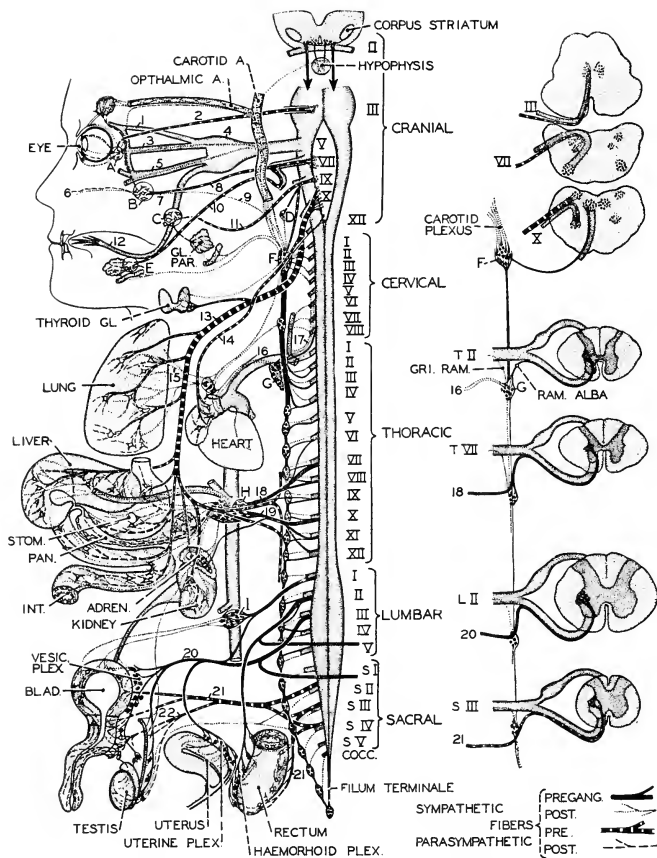


FIG. 157. The autonomic nervous system in man. Autonomic ganglia are lettered, autonomic nerves given Arabic numerals; craniospinal nerves are indicated by Roman numerals. Relations to brain and spinal cord are shown to the right by a series of cross sections taken at various levels. (1) Lacrimal nerve; (2) oculomotor nerve; (3) nasociliary nerve; (4) Gasserian ganglion; (5) ramus maxillaris; (6) posterior nasal nerve; (7) Vidian nerve; (8) superficial petrosal nerve; (9) deep petrosal nerve; (10) chorda tympani nerve; (11) minor superficial petrosal nerve; (12) lingual nerve; (13) vagus nerve; (14) inhibitor cordis nerve; (15) bronchodilator nerves; (16) accelerator cordis nerve; (17) vertebral nerve; (18) major splanchnic nerve; (19) minor splanchnic nerve; (20) hypogastric nerve; (21) pelvic nerve; (22) nervus erigenus. (A) Ciliary ganglion; (B) sphenopalatine ganglion; (C) otic ganglion; (D) carotid ganglion; (E) sublingual ganglion; (F) superior cervical ganglion; (G) stellate ganglion; (H) celiac ganglion; (I) inferior mesenteric ganglion. (Redrawn from Ariëns Kappers, after L. R. Müller, Courtesy, Neal and Rand: "Chordate Anatomy," Philadelphia, The Blakiston Company.)

ganglions, is entered by the visceral trunk (**ramus communicans**) of the corresponding spinal nerve (Figs. 152, 158). The ganglions in the cervical region receive no incoming fibers from cervical spinal nerves, but are entered by systems of fibers which arrive in the autonomic cord via the rami communicantes of several thoracic spinal nerves and then extend forward, or else send branches forward, to all the cervical ganglions (Fig. 159). The ganglions in the head are connected with certain cranial nerves (Figs. 157, 159). The **ciliary ganglion** lies on a branch of the **oculomotor** (III). The **sphenopalatine**, **sublingual**, and **submaxillary** are connected to branches of the **facial** (VII), and the **otic ganglion** is on the **glossopharyngeal** (IX).

In the midtrunk region is a group of large ganglions which are apart from the main autonomic cords, lying in the dorsal mesentery. Although of duplex origin, each is a single median ganglion. There are usually three (Figs. 157, 159), a **celiac**, an **anterior mesenteric**, and a **posterior mesenteric**, each lying in close relation to the artery of the same name. These three "**collateral ganglions**," as they are called, are connected with the spinal cord by paired **splanchnic nerves** (Fig. 157, 18, 19), each formed by union of parts of the **rami communicantes** of several spinal nerves of the thoracolumbar region. A splanchnic nerve is essentially a much-elongated ramus communicans. Therefore the relation of the collateral ganglions to the spinal cord is like that of the lateral ganglions, except as to position.

From one or another of these ganglions—**lateral**, **collateral**, and **cephalic**—nerves pass to the coelomic viscera and to structures, wherever situated, which possess smooth muscles or secretory cells. It is to be remembered, too, that in addition to the extrinsic ganglions are the intrinsic ganglions and plexuses of the viscera themselves. These intrinsic ganglions are sometimes called "**terminal**." The cephalic ganglions, in that each is situated very close to the organ with which it is concerned, resemble terminal ganglions rather than the lateral and collateral ganglions.

### *Functional Components of Autonomic Nerves*

The foregoing description is concerned only with the gross anatomy of the autonomic system. Appreciation of its mode of operation requires some knowledge of the nature and relations of the constituent neurons of the system.

A typical or complete **ramus communicans** of a spinal nerve contains **afferent fibers** whose cell-bodies are in the dorsal root ganglion of the spinal nerve, and **efferent fibers** whose cell-bodies are in the gray matter of the spinal cord (Figs. 152, 158). These visceral efferent fibers constitute the great majority of the fibers that pass into the

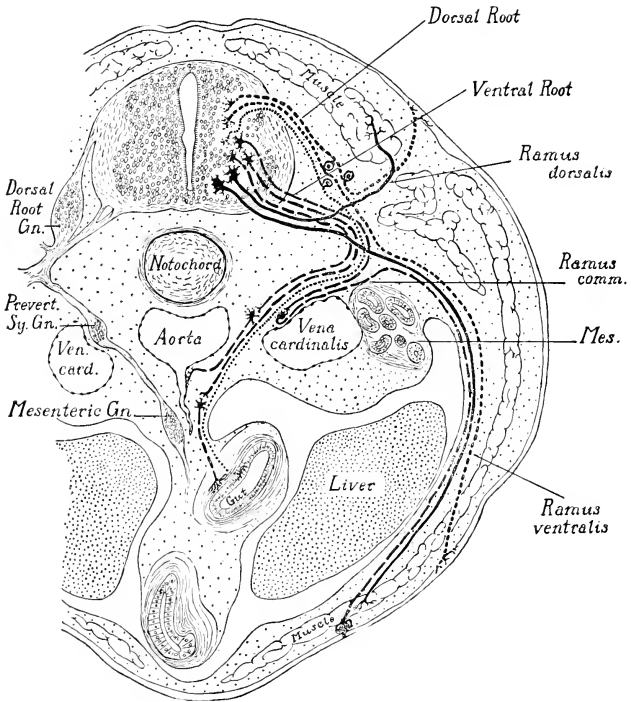


FIG. 153. Diagram of the nerve components of a spinal nerve. Somatic motor fibers are indicated by continuous lines; visceral motor by long broken lines; somatic sensory by short broken lines; visceral sensory by fine dotted lines. (After Froriep. Courtesy, Patten: "Embryology of the Pig," Philadelphia, The Blakiston Company.)

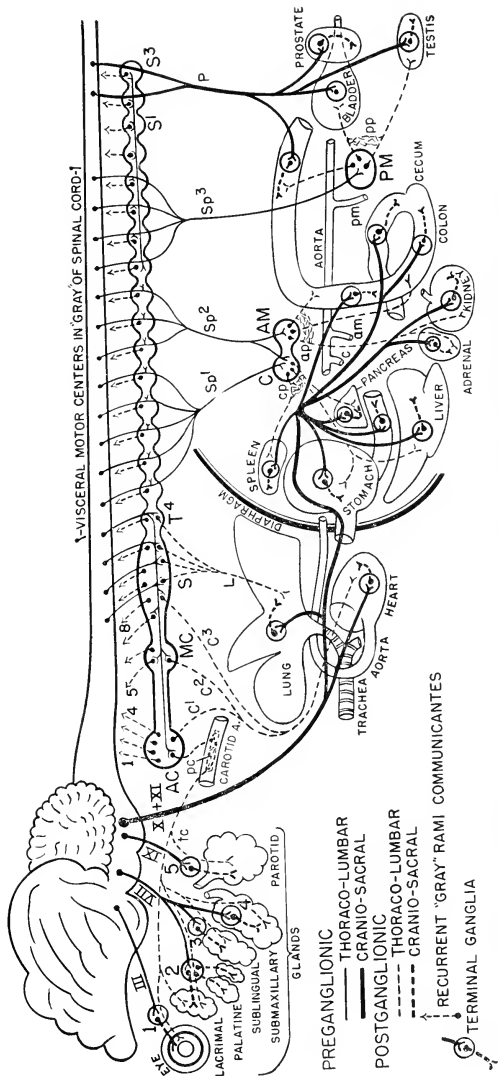


Fig. 159. Diagram showing general plan of the mammalian autonomic nervous system. The lateral ganglions are shown as much enlarged and the interganglionic segments of the autonomic cord are correspondingly shortened. (Modified from Reighard and Jennings: "Anatomy of the Cat," New York, Henry Holt & Co., Inc.)

- |   |  |   |
|---|--|---|
| Cranial Nerves containing visceral motor components: III, VII, IX, X, XI                            | Lateral ("Chain") Ganglions (AC) Anterior cervical (MC) Middle cervical (S) Stellate (S1-S3) Sacral, I-3 (T1-T4) Fourth thoracic | Nerves (1-8) Rami communicantes of cervical spinal nerves (c1-c3) Cardiac (L) Pulmonary (P) Polvic (sacral) to pelvic viscera (Sp1-Sp5) Lumbal splanchnic nerves (c) Thoracolumbar nerves to cranial organs |
| Cranial Terminal Ganglions (1) Ciliary (2) Spheroopalatine (3) Sublingual (4) Submaxillary (5) Otic | Collateral Ganglions (AM) Anterior mesenteric (C) Celiac (PM) Posterior mesenteric   | Plexuses (ap) Anterior mesenteric (cp) Celiac (pc) Carotid (pp) Posterior mesenteric  |
|   |  | Arteries (am) Anterior mesenteric (c) Celiac (pm) Posterior mesenteric  |

autonomic system. Having entered the autonomic ganglion, whether lateral or collateral, the **afferent fibers** merely pass through it without making connection to any cell in the ganglion. Emerging from the ganglion, the afferent fiber (bound together with other fibers, chiefly efferent, all together constituting a **visceral nerve**) continues, without interruption, to its visceral destination. Therefore, in its mode of distribution it does not differ from a somatic sensory fiber. In each case, one continuous fiber derived from a cell-body in the dorsal spinal ganglion passes directly to its peripheral receptive end, whether that be in somatic or in visceral territory, and regardless of the distance to be traversed. (Some exceptional afferent fibers having the cell-body in an autonomic ganglion have been described.) The visceral afferent fiber usually has no specialized receptor other than its own terminal fibrils. It is the mode of distribution of the **efferent**, but not the afferent, fibers which distinguishes the visceral system from the somatic system.

A **somatic efferent fiber**, derived from a cell-body in the gray matter of the spinal cord, passes out in the dorsal or ventral trunk of the spinal nerve and continues uninterruptedly to its termination in some **striated muscle** (Fig. 152). This direct relation necessitates some incredibly long fibers, as, for example, in the case of the nerve which supplies the most distal muscles in the foreleg of a giraffe. In contrast to the *direct* relation of the somatic fiber to its effector, that of the visceral efferent fiber is *indirect*. There are no efferent "through trains" from central nervous stations to visceral destinations. Any nervous impulse that makes the trip travels over **two neurons**. An autonomic ganglion is a way station where the transfer is made at the synaptic junction of the two neurons. The synapse may be in any ganglion—lateral, collateral, or terminal. The central or proximal neuron, making the connection between the central organ and a ganglion, is conveniently called the "**connector**" (or **preganglionic**) neuron. The distal or peripheral neuron, being the one that finally delivers the impulse to the effector, is called the "**exciter**" (or **postganglionic**) neuron (Fig. 152). If the synapse is in a lateral ganglion, the connector is short and the exciter may be very long. But, if the synapse is in a terminal ganglion, the connector is long and the exciter may be very short—e.g., connector-fibers in the intestinal trunk of the vagus nerve arise from cell-bodies in the medulla and pass as far back as the hind end of the "small" intestine, where they make synapses with neurons of the myenteric plexus. Having entered a lateral ganglion, a connector, or a branch of it, may turn and extend forward or backward along the cord for a distance of several segments. Meanwhile it may give off several branches, each of which ultimately makes synaptic connection with an exciter. Therefore the total number of exciters greatly exceeds



that of the connector-neurons. Connector-fibers and exciter-fibers may be distinguished by the fact that the **connectors** have the **myelin sheath (medullated fibers)** and the **exciters** are usually **nonmedullated**.

### *Distribution of Autonomic Nerves*

The general relations of the several autonomic ganglions are, briefly, as follows (see Figs. 157, 159):

**Ciliary ganglion:** connector-fibers enter from **cranial nerve III**. Exciters pass to smooth muscles of **iris** (regulating aperture of pupil) and to the accommodatory **ciliary muscles** within the eye (see p. 201).

**Sphenopalatine ganglion:** connectors from **VII**. Exciters go to **lacrimal ("tear") gland** and **glands of nasal cavity**.

**Sublingual and submaxillary ganglions:** connectors from **VII**. Exciters go to, respectively, **sublingual** and **submaxillary salivary glands**.

**Otic ganglion:** connectors from **IX**. Exciters go to **parotid salivary gland**.

The **vagus (X)**, like **III**, **VII**, and **IX**, contains efferent fibers which serve as connectors to autonomic ganglions. Some fibers of the **accessory nerve (XI)** accompany those of **X** in this distribution. But, in contrast to **III**, **VII**, and **IX**, whose connectors pass to ganglions related to small organs of visceral nature situated in cephalic territory, the **vagus** assembles its vastly greater number of connectors into the large **visceral** or **intestinal trunk** which proceeds backward into thoracic and abdominal territory, where it breaks up into a widely ramifying system of branches, all of which connect with **terminal ganglions**—i.e., with the intrinsic ganglions and gangliated plexuses of the viscera. In these terminal ganglions, the **vagus-fibers** make synaptic connection with exciters which pass to smooth muscle-fibers and gland-cells of the various organs. There is reason to believe that in some cases the ganglion may be reduced to its lowest terms, an isolated neuron, a single connector-fiber making synapse with an exciter lying close to the muscle-cell which it excites. It is in this *indirect* manner, then, that the **vagus fibers** are related to the motor and secretory effectors of viscera. The major organs thus innervated are the lungs, heart, esophagus, stomach, liver, pancreas, the entire length of the "small" intestine, and the spleen and kidney.

**Lateral ganglions:** All of these ganglions contain some exciter-neurons whose fibers distribute to the body-wall. Instead of running out toward the coelomic viscera, a fiber may bend centralwards and enter a ramus communicans, in which it continues back to the point where the ramus emerges from the main spinal nerve. There the fiber

turns outward and passes into either the dorsal or the ventral **somatic ramus** of the nerve (Fig. 158). These **recurrent fibers** distribute into all the larger branches of the two rami and thus arrive at their effectors, which are smooth muscles and secretory cells, wherever situated in the body-wall. They even reach the skin, innervating the sweat-glands (Fig. 160) and the muscles attached to hair-follicles. The recurrent fibers are nonmedullated. Therefore a ramus communicans consists of two divisions: the "white" ramus includes the medullated connectors which convey impulses into the ganglion; the nonmedullated recurrent fibers collectively constitute a "gray" ramus, whose fibers conduct impulses away from the ganglion. Both sets of fibers are efferent, but the "white" connectors are **preganglionic** and the "gray" **exciters are postganglionic**, although bound up in the same nerve-trunk. The spinal nerve by which a recurrent fiber emerges from the autonomic cord is usually not the one by which its connector enters.

Each **cervical spinal nerve** is connected by a ramus communicans to a **cervical lateral ganglion**, two or more to each of the three ganglions—a fact indicating fusion of ganglions. But these cervical rami contain no connector-fibers. They consist entirely of outbound

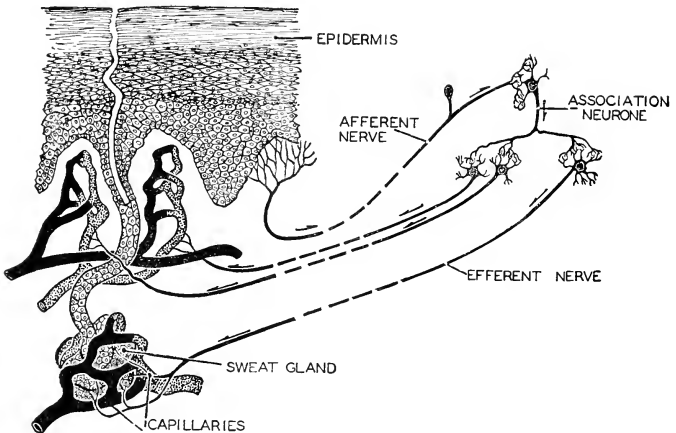


FIG. 160. Diagram illustrating the nervous mechanism of temperature regulation in man. The quantity of secretion of the sweat-glands (and consequently the amount of sweat which may evaporate to cool the body) depends upon the quantity of blood in the capillaries associated with the glands and dermal papillae. Through a reflex arc the circulation is regulated by the temperature of the skin. (After Hough and Sedgwick. Courtesy, Neal and Rand: "Chordate Anatomy," Philadelphia, The Blakiston Company.)

fibers of exciters whose cell-bodies are in the lateral ganglions. They are, therefore, purely **gray rami** (Fig. 159). Certain spinal nerves in the posterior lumbar and sacral region may have only gray rami.

The **peripheral distribution from the lateral ganglions**, aside from that which is effected through the gray rami, is as follows (Figs. 157, 159): The **cervical ganglions** are constituted largely of exciter-neurons whose fibers are assembled into nerves passing forward to the region of the head, where their distribution includes smooth muscles of **blood-vessels**, secretory cells of **salivary and lacrimal glands**, and the **intrinsic muscles of the eye**. All of the cervical ganglions send exciters to the **heart**. It is to be emphasized that, in all of this distribution, the exciter-fiber goes directly to a muscle-cell or a gland-cell, not to any terminal ganglion. From the **stellate and adjacent thoracic ganglions**, exciter nerves pass to the **lungs**. Most of the connectors which enter the more posterior thoracic and the lumbar lateral ganglions pass through the ganglions (i.e., without making synapses with exciters in the ganglions) and become assembled into the paired **splanchnic nerves** which pass on to the celiac, anterior mesenteric, and posterior mesenteric **collateral ganglions**. Similarly, most of the connectors of the two or three sacral lateral ganglions emerge without synapse and join to form a pair of **pelvic nerves** which distribute to numerous **terminal ganglions** of the "large" **intestine, urinary bladder, prostate gland, and genital organs**, but apparently not to the uterus.

**Collateral ganglions** (Figs. 157, 159): connectors entering the **celiac ganglion** via the splanchnic nerves make synapse there with exciters which pass to smooth muscle-fibers or secretory cells of the **stomach, liver, pancreas, and spleen**. Similarly, connectors to the **anterior mesenteric ganglion** are there related to exciters which distribute to the entire "small" **intestine** and more or less of the anterior region of the "large" **intestine**, and to the **kidneys**. The celiac and anterior mesenteric ganglions may be closely joined.

The distribution from the **posterior mesenteric ganglion** is confused by the close relation of the ganglion to a group of lumbar connectors which may pass through the ganglion without synapse within it, or may pass by the ganglion without entering it and go on to a distribution which more or less overlaps that of exciters from the ganglion. These through, or by-passing, connectors combine into a pair of **hypogastric nerves** (Fig. 157, 20) which go to pelvic viscera. The walls of these viscera—the **rectum, urinary bladder, uterus**, and other urinogenital parts—are invested by a maze of plexuses into which pass not only the hypogastric nerves but also the sacral or **pelvic nerves**. Since the nerves of both of these pairs are constituted of connectors,

they must find their exciters in the gangliated plexuses. The exciter-fibers which proceed from the posterior mesenteric ganglion enter this same intricate region and, presumably, pass directly to effectors in the walls of the organs. Apparently, posterior-mesenteric exciters and terminal exciters related to hypogastric connectors may innervate the same organ. The chief organs which receive innervation from one or both sources are the **large intestine** (except, perhaps, its anterior region), **urinary bladder** and **urethra**, **uterus** and other urinogenital ducts, and **external genital organs**.

### *Origin of Autonomic Neurons*

That all cells of the autonomic system are of ectodermal origin has been well established. The cells of the lateral ganglions have common origin with those of the spinal ganglions from a ridge (ganglionic or neural crest) of ectodermal cells lying dorsolaterally along each side of the neural tube (Fig. 161). From the developing lateral ganglions (Fig. 134), some cells move into deeper positions and establish the collateral ganglions. In short, all neurons of the terminal ganglions and plexuses, however deeply situated, are derived from the ganglionic crest by successive migrations of cells from one ganglionic site to a deeper one. In general, the nerves connecting the more remote gan-

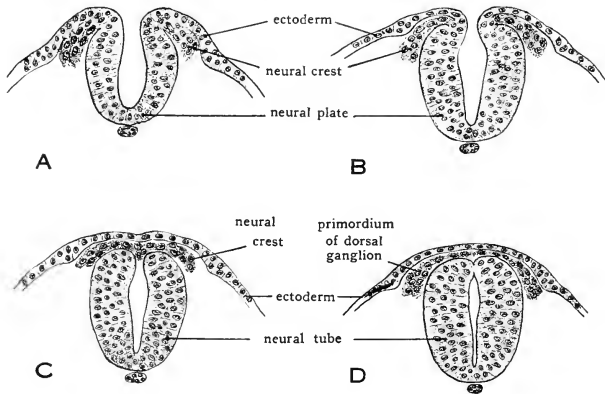


FIG. 161. Drawing showing closure of the neural tube and formation of the neural crest. From pig embryos of (A) 8 somites; (B) 10 somites; (C) 11 somites; (D) 13 somites. ( $\times 135$ .) (Courtesy, Patten: "Embryology of the Pig," Philadelphia, The Blakiston Company.)

glions with those nearer the neural tube mark the pathways which the migrating cells followed.

### *Divisions of Autonomic System*

Inspection of the relations of the autonomic structures discloses some features which are correlated with the general functional characteristics of the system. On *structural grounds*, four regions may be distinguished, briefly defined as follows:

**Cranial (cephalic):** connectors from cranial nerves; exciters in terminal ganglions.

**Cervical:** no connectors from cervical spinal nerves; exciters in lateral ganglions.

**Thoracolumbar:** connectors from nearly all of the thoracolumbar spinal nerves; exciters usually in lateral or collateral ganglions (the exception being those related to the hypogastric nerves).

**Sacral:** connectors from sacral spinal nerves pass to exciters in terminal gangliated plexuses.

On *functional grounds*, the cervical region disappears. Its connectors all come forward from the trunk. It merely provides exciters to forward impulses received from more posterior segments and therefore is functionally an extension of the thoracolumbar region. Further, the cranial and sacral regions are structurally alike in that their relatively long connectors pass to terminal ganglions, whereas most of the thoracolumbar connectors are relatively short and pass to exciters in lateral or collateral ganglions. Therefore the four regions reduce to two structural types, the **craniosacral** and the **thoracolumbar**. The name "**sympathetic**," originally applied to the whole system, has been replaced by "**autonomic**" ("sympathy" being neither anatomic nor physiologic), but it persists (quite illogically) in a narrower sense as applied to the **thoracolumbar** autonomic division. The **craniosacral** division then becomes the "**parasympathetic**."

### *Autonomic Functions*

Between the craniosacral and thoracolumbar divisions, there are some radical functional differences. The outstanding difference is commonly described by saying that the two divisions are usually "antagonistic" in their mode of action. A difference of this sort is highly significant in view of the fact that many visceral structures receive innervation from both divisions. Perhaps "antagonistic" is not the best word. In so far as it may seem to imply conflict or inharmonious organization, it is misleading. A device commonly used to hold some mechanical part firmly in place consists in arranging two

springs so that they press upon the part in opposite directions. Their "antagonistic" action conduces to proper working of the machine. The two autonomic divisions are "antagonistic" only in the sense that they *coöperate* toward the welfare of the animal as a whole by inducing reactions of opposite nature.

The autonomic system is essentially an **action-controlling** mechanism. Its afferent constituents are relatively few and the sensations which they mediate are mostly rather vague and not capable of precise localization. The effectors of the autonomic system are **muscle-cells** (usually nonstriated, but striated in the heart), **secretory cells**, and various large integumentary pigment-cells (**chromatophores**) which are capable of alternately dispersing and concentrating their contained pigment-granules so as to make the cells more effective or less so in determining the color of the skin. The "antagonistic" actions of the autonomic system consist in starting and stopping or accelerating and retarding processes; in causing contraction and relaxation of muscles or increase and decrease in quantity of secretion; and concentration and dispersing of granules in a chromatophore. It might be expected that, in general, the starting and accelerating of activities might be the function of one autonomic division while the other would attend to the retarding and stopping. But that is not the fact, as may be appreciated by inspection of the following list of some typical autonomic controls.

<i>Stimulation by Thoracolumbar (Sympathetic) Division</i>	<i>Stimulation by Craniosacral (Parasympathetic) Division</i>
<ol style="list-style-type: none"> <li>1. Accelerates heartbeat</li> <li>2. Relaxes muscles (exclusive of sphincters) of stomach and intestine</li> <li>3. Contracts sphincters of stomach and intestine</li> <li>4. Retards intestinal peristalsis</li> <li>5. Relaxes muscles of bronchial tubes, dilating air-passages</li> <li>6. Contracts (usually) muscles of blood-vessels</li> <li>7. Contracts radial muscle of iris, dilating pupil</li> <li>8. Contracts muscles of hair-follicle, erecting hair</li> <li>9. Decreases secretory activity of salivary glands, stomach, intestine, liver, and pancreas</li> <li>10. Increases activity of sweat-glands</li> </ol>	<ol style="list-style-type: none"> <li>1. Retards or inhibits heartbeat</li> <li>2. Contracts muscles (exclusive of sphincters) of stomach and intestine</li> <li>3. Relaxes sphincters of stomach and intestine</li> <li>4. Accelerates intestinal peristalsis</li> <li>5. Contracts muscles of bronchial tubes, constricting air-passages</li> <li>6. Relaxes muscles of blood-vessels</li> <li>7. Contracts circular muscle of iris, narrowing pupil</li> <li>8. No craniosacral innervation</li> <li>9. Increases secretory activity of salivary glands, stomach, intestine, liver, and pancreas</li> <li>10. No craniosacral innervation</li> </ol>

It appears that either contraction of muscles (items 3, 6, 7, 8) or relaxation of muscles (items 2 and 5) may be associated with sympathetic stimulation. Similarly, parasympathetic stimulation may be followed by either contraction (items 2, 5, 7) or relaxation of muscles (items 3 and 6). Sympathetic stimulation increases activity of sweat-glands and decreases production of salivary and other digestive secretions. On the whole, excitatory activity is more characteristic of the sympathetic than of the parasympathetic, but there is no sharp distinction between them so far as the types of reaction are concerned.

**Double innervation**—i.e., innervation from both divisions of the autonomic system—occurs in most of the major viscera, but is much more prevalent in coelomic than in somatic territory. While it is true that nerves of either division may elicit a “plus” reaction in one organ and a “minus” reaction in some other organ, there are two characteristics in which the double innervation never departs from consistency. First, in no case, so far as is known, do the nerves of the two divisions elicit the same response from any one organ. Second, however inconsistent the two divisions may seem to be as to the nature of their respective actions on the several organs, it is invariably true that the resultant of their “antagonistic,” but coöperative, actions on each organ tends to enable that organ to perform the best possible service for the animal under the circumstances which obtain at the moment. And, further, the simultaneous autonomic controls of the several organs are so correlated that the “grand total” result is such as to enable the animal to do its most and best in times of stress and, with the passing of the emergency, to return automatically to the physiologic economy of a period of peace.

The **distribution** of sympathetic innervation is more extensive than that of parasympathetic. The sympathetic penetrates into every part of the body. Parasympathetic distribution is mainly coelomic, and an organ so important as the uterus seems to be devoid of it. Consistent with this difference in distribution, it is the sympathetic division that plays the paramount role in periods of stress. It is, therefore, given to large-scale operations, a wave of stimulation sweeping over wide territories or the whole body. The parasympathetic is necessarily more local in its action, and, within the territory of double innervation, it assists in restoring the routine working order after a period of sympathetic excitation.

To illustrate: when a cat is confronted by a menacing dog, rays of light reflected from the dog stimulate the cat's retinal receptors. These receptors initiate impulses which pass via the optic nerves to the optic centers in the midbrain, whence they are relayed back through the more posterior parts of the brain and then down the spinal cord to

visceral efferent cells in its gray matter. From these cells pass connector (preganglionic) fibers via "white" rami communicantes to lateral autonomic ganglions. Here synapses are made with exciters whose postganglionic fibers emerge via "gray" rami communicantes and, passing into somatic branches of spinal nerves, follow certain of the branches of these nerves to their ultimate distribution in the skin, where the sympathetic fibers cause contraction of the smooth muscles attached to the bases of hair-follicles. In less time than it takes to read this statement, the hairs over the cat's entire body are "standing on end." Meanwhile other things are happening internally. The wave of sympathetic stimulation contracts the blood-vessels of the skin and the viscera. But the vessels which supply the striated somatic musculature do not contract, nor do those which supply the tissues of the heart (coronary vessels), the lungs, and the central nervous organs. The result is an important redistribution of the blood. Faced by the prospect of strenuous somatic muscular activity, blood is withdrawn from regions where, at the moment, it is less needed, and concentrated into the tissues whose organs are likely to be called upon to do hard work. At the same time, the bronchial air-passages are dilated and the respiratory movement and heart-rate accelerated. These effects of sympathetic stimulation are augmented by endocrine action. The sympathetic excites secretory activity of a pair of small glands, the **adrenals**, situated near the kidneys. The deeper tissue (medulla) of these glands at once pours into the blood a small quantity of **epinephrine**, ("**adrenalin**"), which is soon circulating through all the tissues. The physiologic effects of this hormone are similar to those produced by sympathetic stimulation. The combined action of the sympathetic nerves and adrenal secretion is to put the endangered animal on a "war basis." The danger past, cessation of sympathetic stimulation and some counteracting parasympathetic stimulation restore normal internal balance.

The similarity between the responses to sympathetic stimulation and those induced by presence of epinephrine in the blood is intelligible in the light of the comparatively recent discovery that the activation of an effector by its nerve is a chemical process. The efferent fiber terminates in fine fibrils which are in intimate relation to the muscle-cell. It has been shown that the terminal fibrils of an active sympathetic fiber produce a substance which chemically is closely similar to epinephrine. This substance has been named "**sympathin**." It is evidently the sympathin that brings about the reaction of the muscle. Similarly, the terminal fibrils of a parasympathetic nerve produce a quite different substance, **acetylcholine**, which induces the response of the effector. In general, sympathetic stimulation causes decrease in secre-



tory activity, but activity of sweat-glands is increased by sympathetic stimulation. Evidence that the sympathetic nerve-endings on sweat-glands produce acetylcholine instead of sympathin goes far toward explaining this anomaly. While the nerves to the sweat-glands are anatomically sympathetic, they are functionally parasympathetic.

**Autonomic activities**, with one or two possible exceptions (e.g., action of the ciliary muscles of the eye), are **involuntary**. Within the autonomic system itself there are no obvious structural barriers to volition. Its apparent inability to traverse rami communicantes and operate in visceral territory is probably due, not to any obstacles in the visceral field, but rather to lack of appropriate connections between autonomic reflex circuits and the dominating nervous centers in the dorsal wall of the telencephalon. However that may be, it seems quite clear that the animal is fortunate in having a well-trained and efficient autonomic servant to do the daily routine drudgery of attending to the intricate details of visceral activity, leaving the somatic master free to devote himself to outside affairs. Under ordinary circumstances, most visceral activities do not even rise into consciousness. But any derangement, such as results when unacceptable food is thrust upon a stomach, may be attended by consequences which rise acutely into consciousness. Even so, the somatic animal is unable to do anything about it directly. The visceral mechanism has its own ways of meeting emergencies, and its responses are usually corrective in their nature.

### MENINGES

The central nervous organs (brain and cord) are invested by connective-tissue membranes, the **meninges**, which serve for their protection and nourishment. In fishes, the cranium and the vertebrae are lined by compact perichondrium or periosteum (connective-tissue membranes investing surfaces of cartilage or bone, respectively), between which and the brain or cord the connective tissue is loose, except where it comes in contact with the central nervous organs. There it becomes the more compact and highly vascular **meninx primitiva**.

Two such meninges occur in amphibians, a highly vascular **pia mater primitiva** next to the brain and cord and, outside this, a thicker **dura mater**. The wide space between dura mater and periosteum is bridged by connective-tissue strands.

In mammals three meninges are differentiated (Fig. 162). Innermost is the **pia mater**, thin and highly vascular, from which connective-tissue processes growing into brain and cord carry in blood-vessels and support the nervous tissue. Outside this is the **arachnoid** which, as its name suggests, is a delicate weblike tissue. Only its outer layer

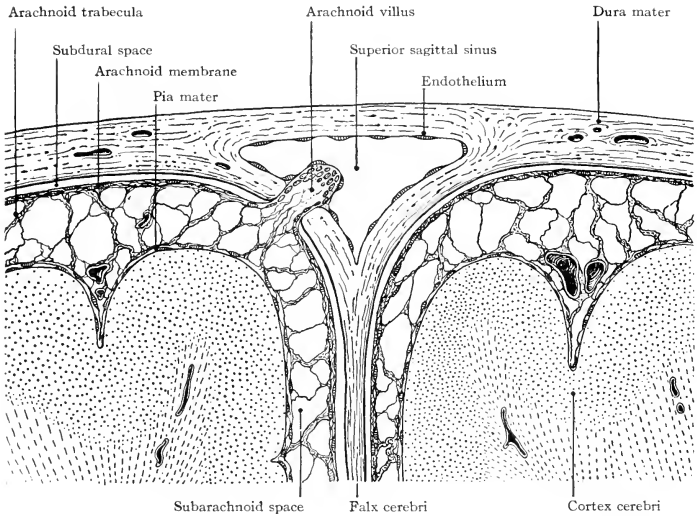


FIG. 162. Diagram of arachnoid and subdural spaces. (From original by L. H. Weed, *Am. J. Anatomy*, 31:202.)

is organized into a membrane. Outermost of the three is the **dura mater**, thickest and toughest of all, and more or less closely attached to the periosteum, which is sometimes regarded as a part of the dura mater.

The dura mater of mammals folds in between the cerebral hemispheres to form the **falx cerebri**. A similar fold between the hemispheres and the cerebellum is the **tentorium cerebelli**.

The meninges are derived from loose mesoderm (mesenchyme) which surrounds the embryonic neural tube.

#### SENSE-ORGANS

Sense-organs consist of cells or groups of cells adapted to respond to stimuli and transmit impulses to the nerves associated with them. The essential property of a sense-cell is irritability. The stimuli may be caused by physical or chemical agencies either in the environment or within the animal. The conductor may be a nerve-fiber derived from the sense-cell itself, or an afferent fiber whose cell-body is in a ganglion of a cranial or a spinal nerve.

The more highly elaborated sense-organs possess various structures

serving to support or protect the sense-cells or facilitating access of stimuli to them. These accessory structures will be described in the chapters dealing with the animals in which they occur.

#### CUTANEOUS SENSE-ORGANS

Receptors existing in large numbers and widely distributed in the skin are designated as "**general cutaneous.**"

At least four senses, **pressure or touch, warmth, cold, and pain,** are mediated by cutaneous organs. Corresponding with these sensations are several sorts of nerve-terminations. The simplest and most common consists merely of the finely branched terminal fibrils of the afferent nerve itself, **free nerve-termination** (Fig. 163). In others the end of the nerve is related to a specialized cell or a group of cells.

**Free nerve-terminations** in the dermis may become encapsulated by concentric layers of connective-tissue cells, as in the so-called "**corpuseles**" of **Pacini, Krause, and Golgi-Mazzoni** (Figs. 164, 165). Some nerve-terminations are associated with **tactile cells** which are usually in the dermis. In some instances, a single lenticular tactile cell rests upon a cup-shaped termination of a sensory neurite, or the nerve may branch among a cluster of such cells (Fig. 164, D-D<sup>2</sup>). Such a cluster of tactile cells, connected with the dendrites of a sensory nerve, may become encapsulated by connective tissue to form a "**Meissner's corpusele**" (Figs. 164, D<sup>3</sup>; 166).

Free nerve-terminations may lie in the epidermis or in the dermis. They are found in all classes of vertebrates and are believed to be the sensory mechanism of painful sensations arising in the skin. The sense of touch or pressure probably depends chiefly upon the tactile cells or corpuseles in the dermis.

In birds and reptiles, nerve-endings are connected with tactile "cells of Merkel" but without a connective-tissue capsule. These tactile cells are sometimes solitary, sometimes clustered. The **Grandry's corpuseles** of birds are encapsulated, the nerve-termination lying between two tactile cells.

In the relatively small **corpuseles of Krause** and in the large one of **Pacini**, both found in **mammals**, the nerve-termination is club-

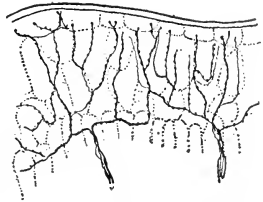
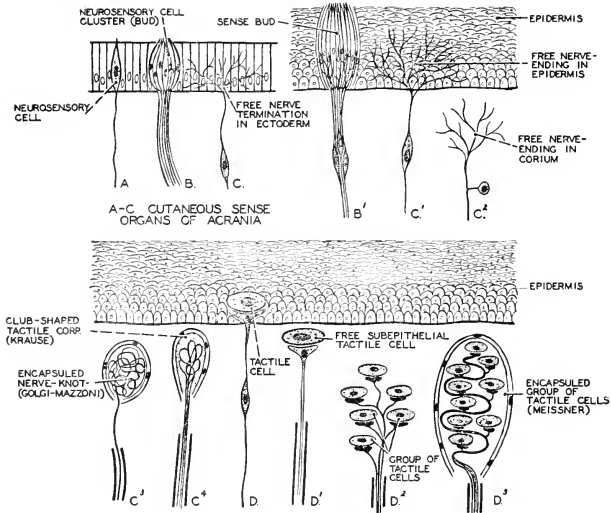


FIG. 163. Free nerve-terminations in the skin of *Salamandra*. (After Retzius. Courtesy, Kingsley: "Comparative Anatomy of Vertebrates," Philadelphia, The Blakiston Company.)



DIAGRAMS B'-D' CUTANEOUS SENSE ORGANS IN CRANIOTES WITH SECONDARY SENSE CELLS.

FIG. 164. Varieties of cutaneous sense-organs in chordates. (A-C) Sensory terminations in the skin of *Amphioxus*. (B<sup>1</sup>-D<sup>3</sup>) Varieties of terminations in vertebrates. (C<sup>1</sup>-C<sup>4</sup> and D<sup>1</sup>-D<sup>3</sup>) respectively represent probable stages in the evolution of encapsulated nerve-terminations of two different types. (After Plate. Courtesy, Neal and Rand: "Chordate Anatomy," Philadelphia, The Blakiston Company.)

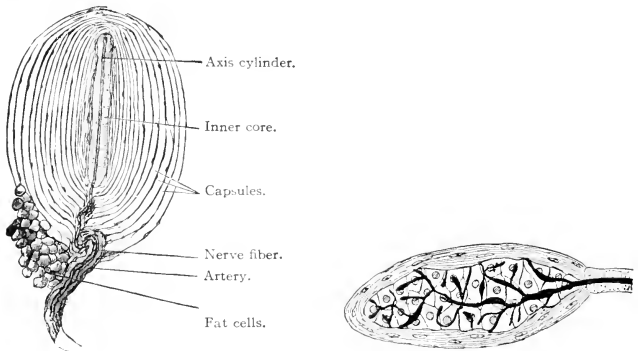


FIG. 165 (Left). Small lamellar corpuscle from the mesentery of a cat. The nuclei of the capsule cells appear as thickenings on the walls of the capsules. The myelin of the nerve-fiber may be traced to the inner core. (× 50.) (Courtesy, Bremer: "Text-Book of Histology," Philadelphia, The Blakiston Company.)

FIG. 166 (Right). Meissner's corpuscle. (Courtesy, Kingsley: "Comparative Anatomy of Vertebrates," Philadelphia, The Blakiston Company.)

shaped and encapsuled. **Pacini's corpuscles** are located not only in the deeper layers of the skin, but also in the mesenteries, tendons, and periosteum. Those present in tendons give rise to sensations such as those which serve to indicate the position of a limb. Those in the deeper parts of the body probably give rise to the painful sensations associated with disease. The spherical or club-shaped **Golgi-Mazzoni corpuscles**, in which the nerve-termination is coiled, occur in the dermis and in the conjunctiva of the eye (see p. 198). Similar corpuscles, but not "cutaneous," occur in the peritoneum.

The **lateral-line organs** of fishes and aquatic amphibians (described in connection with the account of the cranial nerves on p. 164) are cutaneous sense-organs, but differ from the others in being somewhat localized and in their linear arrangement.

#### ORGANS OF TASTE AND SMELL

The skin of aquatic invertebrates is usually sensitive to substances dissolved in the external water. Vertebrate skin, except in some fishes, seems to be quite devoid of chemical sensibility. But the oral cavity and the nasal cavities are lined by a membrane whose superficial layer, the oral and nasal epithelium, is continuous with the external epidermis and, like the epidermis, is of ectodermal origin. The oral and nasal cavities are developed by formation of ingrowing ectodermal pouches and are permanently freely accessible to the external medium. In all vertebrates, more or less extensive areas of the epithelia of these cavities possess organs of chemical sense. The oral and nasal chemical organs are similar in that they are stimulated by substances dissolved in water or in a watery mucus. They are similar also in that they are stimulated by substances of the same general nature and are especially important in the detection and selection of food. Aside from their difference in location, they differ structurally in these two respects: the nasal receptors are sense-cells scattered singly throughout the sensitive area of the epithelium, while the oral receptors are compact clusters of sense-cells; the nasal receptor produces its own conductor-fiber which extends back into the brain, while the oral receptors transmit impulses to terminal fibrils of nerves whose cell-bodies are in ganglions of cranial nerves (Fig. 167). The sense mediated by the nasal receptors is "**smell**"; that by the oral receptors is "**taste**." The similarity of these two senses is such that, at least in man, it is difficult to separate the sensations which they produce. Most of the flavors of our food we unthinkingly credit to taste although, in fact, these sensations of flavors are derived from the nasal or olfactory sense-organs. The oral gustatory organs give us only sensations of sweet, sour, bitter, and salty substances.

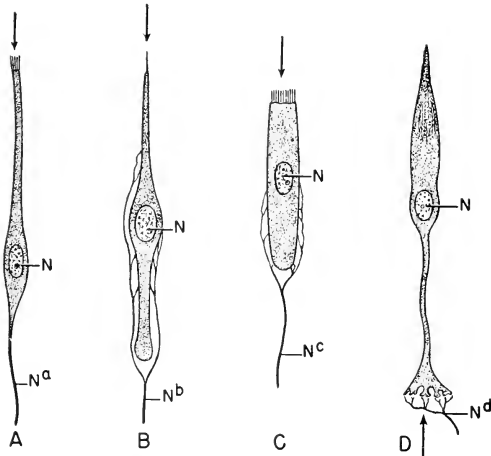


FIG. 167. Receptor cells. (A) Olfactory, from the nasal epithelium. (B) Gustatory, from a taste-bud. (C) Auditory, a "hair cell" from the organ of Corti. (D) Visual, a cone cell of the retina.

The gustatory cell bears, at its distal end, a single stiff "bristle"; the olfactory and auditory cells bear, distally, numerous fine "hairs," in appearance resembling cilia.

The arrows indicate the direction of the incoming stimulating agency. The retinal cell is "inverted" in relation to the impact of incoming light.

(N) Nucleus; (N<sup>a</sup>) fiber of (afferent) olfactory nerve I; (N<sup>b</sup>) afferent fiber of cranial nerve VII, IX, or X; (N<sup>c</sup>) fiber of (afferent) cranial nerve VIII; (N<sup>d</sup>) dendrites of a retinal bipolar cell, a neuron interpolated in the afferent pathway from the receptor to the optic ganglionic layer of the retina.

The olfactory fiber is an outgrowth of the olfactory receptor. The gustatory, auditory, and visual fibers are outgrowths of cells situated in cranial ganglions, and have merely superficial contact with their receptors.

**Gustatory Organs.** The individual organ, known as a "taste-bud," is an ovoid cluster of columnar epithelial cells, each of which bears at its free end a delicate bristle or "hair." The ends of the several sense-cells converge around a small pore through which the fluid from the oral cavity gains access to the sense-cells. Terminal fibrils of a nerve (cranial VII, IX, or X) are closely related to the sense-cells (Fig. 168). The cells of the epithelium adjacent to the sense-cells are elongated and arranged to form a supporting and protecting rampart about the taste-bud.

- Taste-buds occur usually only in the mouth and, to some extent, in the pharynx. In fishes they are usually widely distributed in the

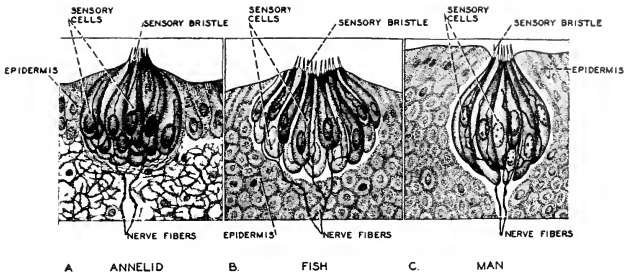


FIG. 168. Diagrams of taste-buds in (A) annelid, (B) fish, and (C) man, showing their fundamental similarity. (Redrawn after Fritz Kahn: "Der Mensch," Zürich, Albert Müller.)

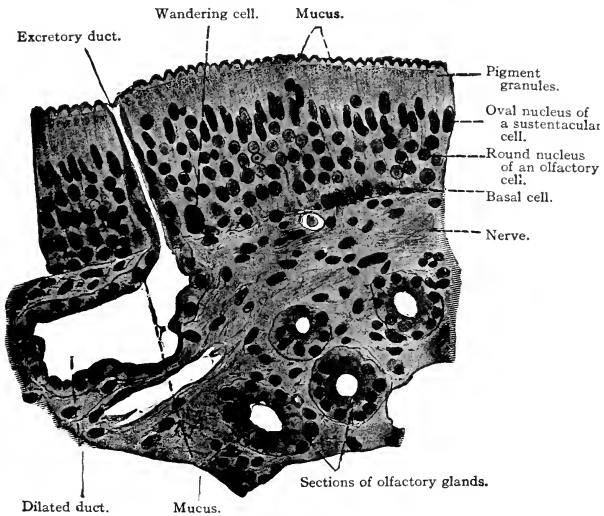


FIG. 169. Section perpendicular to the surface of the adult human nasal cavity in its olfactory region. (X 400.) (Courtesy, Bremer: "Text-Book of Histology," Philadelphia, The Blakiston Company.)

mouth and pharynx, and in some bony fishes occur even in the external skin of the trunk and fins. These external taste-buds, however posterior they may be, are innervated by cutaneous branches of the facial nerve (VII). In terrestrial vertebrates the taste-buds are more or less restricted to the tongue and roof of mouth.

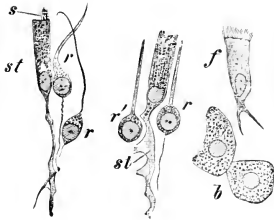


FIG. 170. Isolated cells of the olfactory mucosa of a rabbit. (b) Cells of olfactory glands; (f) ciliated cell; (r) olfactory cells; (r') olfactory cell from which the lower process has been torn off; (s) extruded mucus resembling cilia; (st) sustentacular cells. ( $\times 560$ .) (Courtesy, Bremer: "Text-Book of Histology," Philadelphia, The Blakiston Company.)

**Olfactory Organs.** There are always separate right and left nasal cavities except in adult round-mouthed eels (cyclostomes), in which the two embryonic nasal sacs become joined into a single median chamber, but with two olfactory nerves.

The epithelial lining of the olfactory area of the nasal surfaces consists of a single layer of tall columnar cells among which are dispersed the **olfactory sense-cells**, which are of extremely attenuated form (Figs. 169, 170), each usually having at its free end one or more fine "hairs" (Fig. 167). The deep end of each olfactory cell continues into the conductor-fiber. The numerous olfactory fibers from one nasal chamber constitute collectively the **olfactory nerve**, which passes back into the **olfactory lobe** of the **telencephalon**, where the fibers make synaptic connections with neurons passing into more posterior parts of the brain.

The **olfactory cells** are the only vertebrate sense-cells which produce conductors. Among invertebrates, however, cells of this type are common. It would seem, therefore, that the vertebrate olfactory organ is more primitive in its nervous arrangement than the other sense-organs.

The **nasal chambers** in the great majority of fishes do not communicate with the mouth or other cavities. There are various devices, valvular and otherwise, which serve to introduce external water into them or maintain a current of water in and out. In the small group of lungfishes (Dipnoi) and in all vertebrates other than fishes, each nasal chamber opens into the mouth or pharynx dorsally by an **internal naris** or **choana**. The nasal passage thus acquires a respiratory function, air entering at the external naris (nostril) and passing back into the lungs via the trachea. The choanae pierce the anterior region of the roof of the mouth, except in crocodilians and mammals. In these



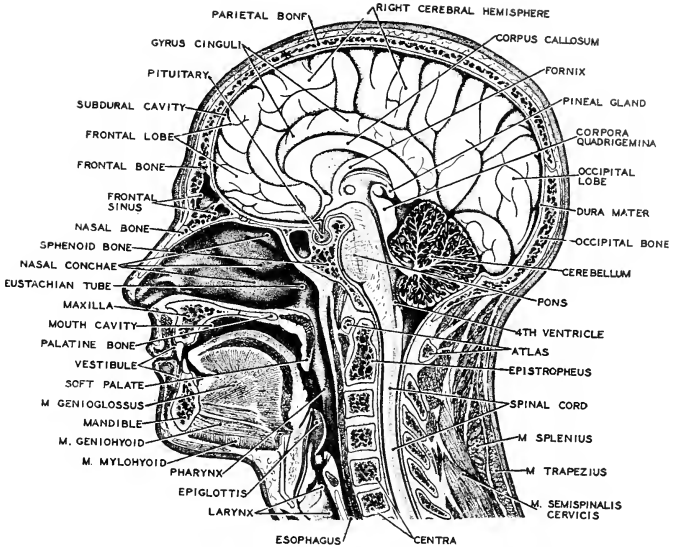


FIG. 171. A sagittal section of the human head showing the relations between the digestive and respiratory passages in the pharyngeal region. (After Braus, Courtesy, Neal and Rand: "Chordate Anatomy," Philadelphia, The Blakiston Company.)

groups the development of a horizontal partition (**secondary palate**) across the oral cavity and more or less of the pharynx extends the nasal passages backward and brings the choanae into a much more posterior position (Fig. 171). Stimulation of the olfactory receptors by substances contained in the air is favored by this respiratory arrangement.

In fishes the olfactory receptors are stimulated by substance dissolved in the external water which is drawn into the nasal chambers. In lung-breathers numerous small **serous glands** secreting a watery fluid, and other glands secreting **mucus**, maintain over the olfactory surfaces a thin layer of moisture, in which substances present in the air may become dissolved and thus brought within stimulating range of the sense-cells whose "hairs" are bathed by the secreted moisture. A **lacrimal duct** leads from the space beneath the eyelids into the corresponding nasal passage and contributes to the moistening of the nasal surfaces.

The olfactory receptors are very much more keenly sensitive than the gustatory receptors.

## EYES

The **paired eyes** work on the principle of the photographic camera. In the camera a lens, or system of lenses, focuses light to form an image on a chemically sensitized plate or film. In the eye a lens, together with other refracting mediums, forms an image on a nervously sensitive retina. In both camera and eye, the amount of light admitted is regulated by an iris-diaphragm whose aperture can be increased or diminished.

The essential nervous parts of the eye are derived from the neural tube. At an early embryonic stage, a pair of globular **primary optic vesicles** bulge out ventrolaterally on either side of the most anterior of the three primary divisions of the brain (Figs. 141, 172). Later the outer wall of each primary optic vesicle is concaved to such an extent that the vesicle becomes a more nearly hemispheric thing with a double wall, the **secondary optic vesicle** or "**optic cup**" (Fig. 172D). The basal region of the vesicle becomes constricted to form an **optic stalk** which connects the "cup" with the floor of the prospective dien-cephalon. The inner layer of the double wall differentiates into the complex nervous **retina**. The outer layer appears in the adult eye as

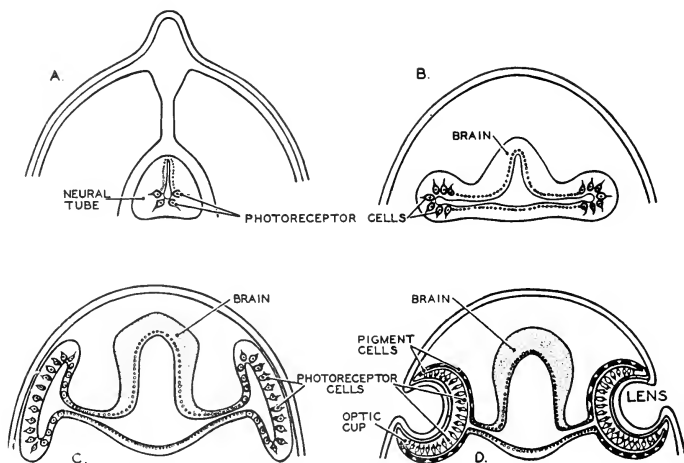


FIG. 172. Diagrams illustrating Boveri's theory that the paired eyes of vertebrates have evolved from lateral outgrowths of the brain-wall. The theory accords well with embryologic evidence. (Courtesy, Neal and Rand: "Chordate Anatomy," Philadelphia, The Blakiston Company.)

a very thin **pigmented epithelium** at the base of the retina. Meanwhile, a thickened area of the adjacent superficial ectoderm is folded into the interior of the cup, where it acquires the form of a biconvex **lens** and becomes detached from the superficial ectoderm (Fig. 173).

These two ectodermal structures, one formed by outgrowth from the brain, the other by ingrowth from the embryonic skin, are surrounded by a mass of loosely aggregated mesodermal cells, mesenchyme, from which are differentiated a nutritive layer, the **choroid**, adjacent to the retina, and an external supporting layer, the **sclera** (Fig. 174).

The **sclerotic layer** consists of compactly interwoven bundles of connective-tissue fibers in which may develop plates of cartilage or even bone. The layer is opaque except the region of it external to the lens, where it is necessarily highly transparent—the region known as the **cornea** (Figs. 175, 176). The external skin is closely joined to the outer surface of the cornea but it is exceedingly thin, devoid of pigment, and transparent. If eyelids are present, this thin skin, the **conjunctiva**, continues from the corneal surface over the inner surfaces of the lids (Fig. 176).

The **choroid layer** is richly filled with blood-vessels. The main vessels enter the eyeball together with the optic nerve (Fig. 176). The layer is usually heavily pigmented. At the periphery of the cornea, the choroid becomes separated from the inner surface of the sclera and continues as a free membrane, the **iris**, across the space between the lens and the cornea (Figs. 175, 176). The iris is pierced by an aperture, the **pupil**, whose center is in the optic axis. The pupil is usually circular, but may be elliptic with the long axis either horizontal or vertical. The iris is usually pigmented. It contains two systems of smooth muscle-fibers, **radial fibers** which dilate the pupil, and **circular fibers** which contract it. Just beyond the outer border of the iris, the choroid develops a thickened ring of vascular and muscular tissue projecting into the cavity of the eyeball. The ring as a whole is called the **ciliary body** (Figs. 175, 176). It contains a system of smooth muscle-fibers which extend around the circumference of the ciliary body, and a system of meridional fibers which, as the name implies, lie in meridians of the eyeball, but are entirely in the choroid layer. Their contraction increases the diameter of the ciliary body, thus opposing the action of the circular muscle. Both muscles serve in accommodating the eye for vision at varying distances.

The **lens** is a fairly hard but elastic transparent body invested by a highly elastic fibrous outer coat or **capsule**. The body of the lens consists of cells elongated into thin fibers and compactly arranged in concentric layers. Delicate fibers extend from the periphery of the

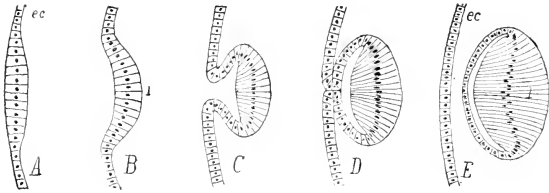


FIG. 173. Sections of successive stages in the development of the lens of the eye from the first thickening of the ectoderm (*ec*) to the complete separation of the lens (*l*). (Courtesy, Kingsley: "Comparative Anatomy of Vertebrates," Philadelphia, The Blakiston Company.)

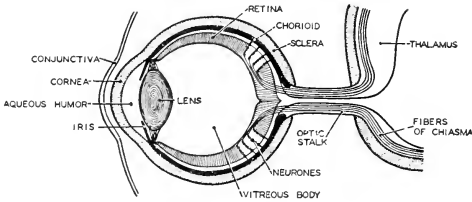


FIG. 174. Diagram illustrating the growth of optic nerve-fibers from the retina along the optic stalk into the brain. Some of the fibers cross below the brain to form the optic chiasma, while the remaining pass into the thalamus of the same side. (Courtesy, Neal and Rand: "Chordate Anatomy," Philadelphia, The Blakiston Company.)

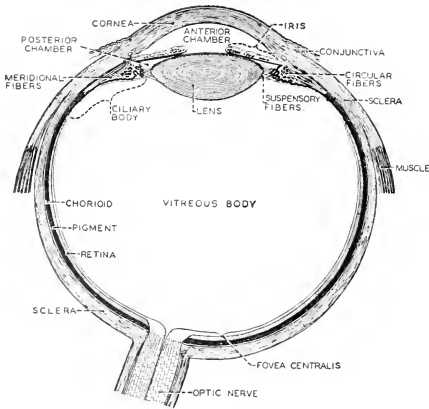


FIG. 175. Diagram of a median section of the eye. (After Sobotta. Courtesy Neal and Rand: "Chordate Anatomy," Philadelphia, The Blakiston Company.)

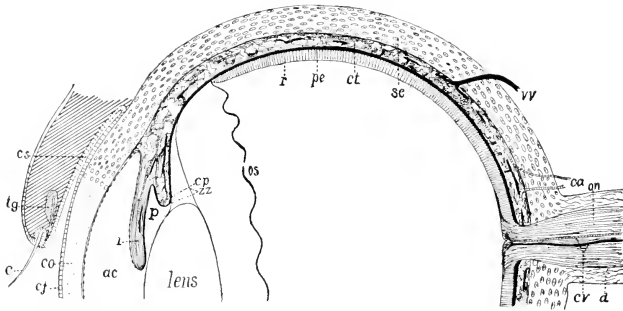


FIG. 176. Diagrammatic section of half a mammalian eye. (*ac*) Anterior chamber; (*c*) eyelash (cilium); (*ca*) ciliary arteries; (*cj*) conjunctiva; (*co*) cornea; (*cp*) ciliary process; (*cs*) conjunctival sac; (*ct*) choroid tunic; (*cr*) central retinal artery and vein; (*d*) dura of optic nerve; (*i*) iris; (*on*) optic nerve; (*os*) ora serrata; (*p*) posterior chamber; (*pe*) pigmented epithelium; (*r*) retina; (*sc*) sclera; (*tg*) tarsal gland; (*vv*) vorticose vein; (*zz*) zonula zinnii. (Courtesy, Kingsley, "Comparative Anatomy of Vertebrates," Philadelphia, The Blakiston Company.)

lens to the ciliary body, forming a **suspensory ligament** (or **zonula**) which holds the lens in place back of the iris.

The **cavities** within the eyeball (Fig. 175) are filled by liquid or semifluid substances, the "**humors**" of the eye. Between cornea and lens is the **aqueous humor**. The large central space behind the lens is occupied by the **vitreous humor**, a transparent substance of jelly-like consistency.

The **retina** lines the cavity of the eyeball, but thins out and is non-nervous in the zone adjacent to the ciliary body, that being a region where little or no light strikes it. This non-nervous zone continues outward, covering the ciliary body and the entire inner surface of the iris even to the edge of the pupil (Fig. 176).

In its functional region, the **retina** contains three layers of neurons (Figs. 177, 178), those of one layer being joined to those in adjacent layers, presumably by synaptic connection. The neurons of the most **peripheral layer** (i.e., the layer most remote from the center of the eyeball) are the **receptors**. They are much-elongated cells whose peripheral regions are cylindrical in some and conic in others. The receptors are accordingly known as "**rods**" and "**cones.**" Beyond the rod-shaped or cone-shaped region, the nucleus occasions an expansion of the body of the cell. Beyond the nucleus, a slender process continues toward the middle one of the three retinal layers. In a **rod**, this process ends in a knoblike enlargement which is in close (synaptic) relation to

a set of fibrils belonging to a cell in the adjacent layer. The corresponding process of a **cone** ends in a cluster of short branches which, similarly, are engaged by fibrils of a cell in the next layer. The **middle layer** consists mainly of these bipolar neurons, each having peripheral fibrils (dendrites) connecting with rods or cones and, at its opposite pole, fibrils related to those of a neuron in the next (toward the center of the eyeball) ganglionic layer. It is from the large cells of this **innermost ganglionic layer** that most of the fibers of the optic nerve arise. Each cell produces a fiber which, emerging from the inner (central) surface of the layer, bends sharply (Fig. 178) and passes into a layer of such fibers which converge toward a point at the back of the eyeball, where they are collected into a bundle which is the optic nerve (Figs. 174, 175). But an occasional large "stellate cell" (Fig. 178) in the middle layer of neurons produces a nerve-fiber which penetrates the inner ganglionic layer without making a synapse with any of its cells and continues directly into the optic nerve. Also, a few fibers of the optic nerve come from cells in the brain and terminate in the middle layer of the retina. A consequence of the manner of origin of the optic nerve is that the retinal tissue adjacent to the vitreous humor is a fairly thick layer of nerve-fibers. At the place of exit of the optic nerve, there are no rods and cones. It is therefore a "blind spot."

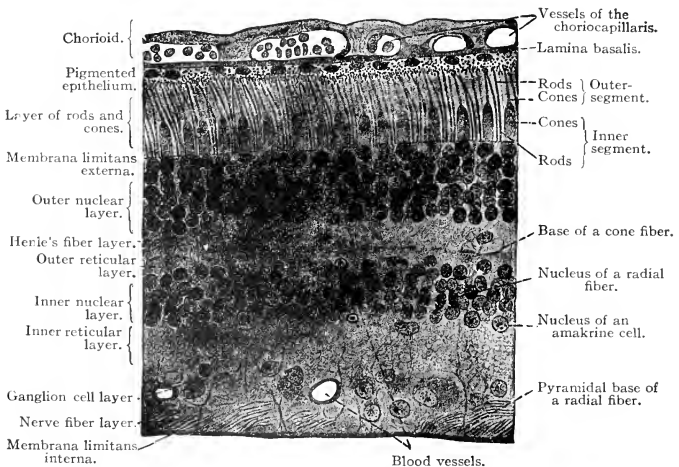


FIG. 177. Section perpendicular to the surface of a human retina. ( $\times 36$ ). (Courtesy, Bremer: "Text-Book of Histology," Philadelphia, The Blakiston Company.)

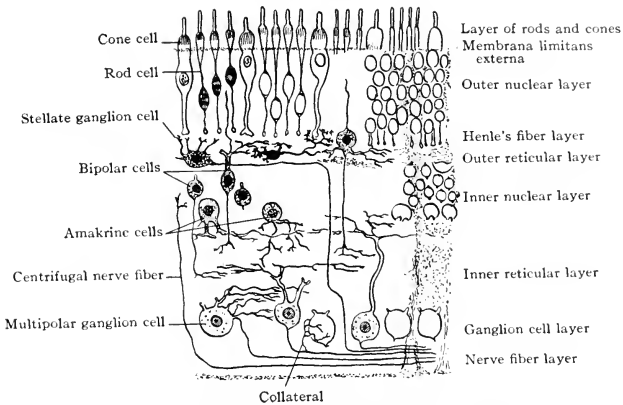


FIG. 178. Diagrammatic section showing the nervous layers of the human retina. (Modified from Bremer: "Text-Book of Histology," Philadelphia, The Blakiston Company.)

Peripheral to the rods and cones is the **pigmented epithelium** (Fig. 177). When the retina is flooded by strong light, processes of the pigment-cells penetrate between the receptors. In light of low intensity or in darkness, these processes are withdrawn.

#### *Functions of Rods and Cones*

The rods and cones are functionally unlike. In animals which habitually live in dim light, the retina ordinarily contains only rods. In animals accustomed to relatively strong light and having good discriminative vision, the cones are most numerous in the central region of the retina and fewer or entirely lacking in zones more or less remote from the central region. Within a small spot at the exact visual center, the retinal structure is modified. Its layers are pervaded by a yellowish pigment, the spot being therefore called the "**macula lutea**." At the center of the macula is a shallow concavity of its surface, the **fovea centralis** (Fig. 175). It is as if local pressure had been applied with the result that the constituent elements of the retina had been squeezed away centrifugally in all directions from the center of the spot and to such an extent that, at the deepest region of the fovea, nothing is left but the layer of receptors—and these are *all cones*.

Retinal zones remote from the optic center produce mental pictures, which, according to the degree of remoteness, are more or less

vague and "done" all in tones of gray. When an eye is focused for optimum vision of an external object, the image is centered on the fovea. There are, accordingly, at least three reasons why the fovea should be the region of keenest vision: it is in the optic axis; rays of light may reach its receptors without passing through the maximum thickness of the ganglionic layers; and, presumably, adequate recognition of colors is correlated with presence of cones. The rods apparently serve for recognition of different intensities of illumination but without distinction of colors.

#### *Accessory Optic Structures*

The muscles which move the eye in the orbit have been described in connection with the account of the cranial nerves (see p. 162). Eyelids, present in most terrestrial vertebrates, are folds of skin above and below the eye (Fig. 176). The skin of the external surface of the fold is similar to that of the adjacent region of the head. The internal layer consists of the very thin **conjunctiva** which continues over the cornea. **Lacrimal ("tear") glands** may be present within the lids, and small **oil-glands** along the edges of the lids serve to prevent overflow of the watery lacrimal secretion.

#### *The "Inverted" Retina*

An extraordinary feature of the retina is that it seems to be functionally inside-out. A sense-cell at the surface of the body has its receptor-pole at the outer surface and its conductor-pole at its deep end. The receptor-pole is directed toward the source of the stimulus. The rods and cones are so placed that their conductor-poles are directed toward the source of the stimulus. The entering light-rays are further embarrassed by the necessity of penetrating a considerable thickness of nervous tissue before they may arrive at even the "wrong" end of the receptor. In these respects, the vertebrate retina seems poorly contrived. It is commonly referred to as an "inverted retina."

A reason for this inversion may be found by taking into account the embryonic history of a rod or cone (Fig. 172). It may be imagined that a certain ectodermal cell in the anterior middorsal region of an early embryo is a prospective rod or cone with its potential receptor-pole directed outward as it should be in a sense-cell. After infolding of the dorsal ectoderm to form the neural tube, the receptor-pole of that cell will point into the lumen of the tube (Fig. 172A). If the cell happens to lie at the center of the optic outgrowth, it will later be found with its receptor-pole pointing into the cavity of the primary optic vesicle (B). Following the infolding which produces the optic cup, the cell will lie with its receptor-pole against the prospective



pigmented epithelium and its conductor-pole directed toward the developing lens (C, D). So far as the individual rod or cone is concerned, there is no "inversion." They retain the primitive polarity of epidermal sense-cells. It is the manifold manipulation of the layer to which they belong that brings them into their final anomalous situation. But, in spite of it, the eye is a highly efficient organ.

The foregoing description of the eye refers, in some of its particulars, to the mammalian eye. The general structure of the eye is the same in all vertebrates, but there are differences in details.

The **median parietal** or **pineal eyes** have been included in the description of the diencephalon (see p. 145). It is to be noted that the retina of a median eye is not "inverted." The retinal cells are so placed that their receptor-poles point toward the source of the stimulus.

#### ORGANS OF EQUILIBRATION AND HEARING

A common ability of animals is to respond to gravitation and maintain an appropriate orientation of the body in space. In the vertebrates this orienting is accomplished by operation of special sense-organs related to a purely reflex nervous mechanism which automatically effects such muscular adjustments as are necessary to enable the animal to hold any particular posture or maintain the balance of the body during locomotion. The special sense-organs involved in this mechanism are commonly called "static organs." The eyes, however, play an important accessory role in equilibration.

In all vertebrates the **ear** is a **static or equilibratory organ**. It seems possible that in some fishes and some aquatic amphibians equilibration is its only function, but in all other vertebrates the ear is functionally duplex and structurally differentiated into two regions, one containing the static receptors, and the other containing receptors which are stimulated mechanically by vibrations of the external medium and thus mediate a sense of hearing.

The essential nervous organ associated with the static and auditory functions is a very thin-walled membranous sac, highly complex in form, filled with a watery fluid and immersed in a similar fluid, all contained within a skeletal capsule which is joined, one upon each side, to the rear of the brain-case. These **otic sacs** develop by infolding of a pair of thickened regions (**placodes**) of ectoderm situated close alongside the hindmost of the three primary vesicles of the embryonic brain (Fig. 179). Each infolded placode becomes a simple, spherical, liquid-filled vesicle which (except in sharklike fishes) loses its connection to the superficial ectoderm. In the course of its further development, the otic vesicle is subjected to an elaborate series of formative

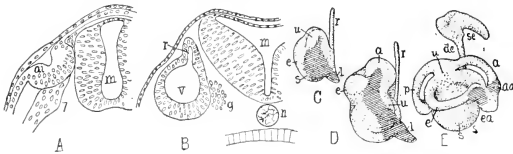


FIG. 179. Development of ear of *Amblystoma* (Norris). (A) Beginning invagination of otic vesicle. (B) Vesicle closed. (C) Model of early vesicle. (D) Older vesicle. (E) Parts all outlined. Sensory patches are lined. (a) Anterior canal; (aa) anterior ampulla; (ai) auditory invagination; (de) endolymph duct; (e) external canal; (ea) external ampulla; (g) otic ganglion; (l) lagena; (m) medulla oblongata; (n) notochord; (p) posterior canal; (r) vestibular recess; (s) sacculus; (se) endolymph sac; (u) utricle; (v) otic vesicle; (7) seventh nerve. (Courtesy, Kingsley: "Comparative Anatomy of Vertebrates," Philadelphia, The Blakiston Company.)

changes consisting of local expansions, constrictions, and hollow outgrowths, which ultimately convert it into the more or less complicated "membranous labyrinths" of various vertebrates (Fig. 180).

#### Structure of the Otic Sac

The main or central region of the **otic sac** is divided, by a constriction, into a dorsal **utricle** and a ventral **sacculus** (Fig. 180). From the **utricle** spring the **semicircular canals**, usually three of them. Each is a slender tube arching through approximately a half-circle and freely open into the utricle at each end. **Two** of the three tubes lie in **vertical** planes (assuming a horizontal axis in the animal) which are at approximate right angles to one another, and the **third** tube is **horizontal**—therefore perpendicular to the plane of each of the others. The ventral end of each vertical tube expands into a so-called "**ampulla**," and the anterior end of the horizontal tube has a similar enlargement. The cyclostome eels have no horizontal canal. The lamprey eel (*Petromyzon*) has the two vertical canals. Another cyclostome, the hagfish (*Myxine*) has what appears as a single vertical canal, but it has an ampulla at each end, suggesting that it may correspond to the two canals of the lamprey (Fig. 180A, B).

The **sacculus** produces a hollow outgrowth which, in fishes and amphibians, is a short protuberance known as the "**lagena**." In reptiles, especially crocodylians, the lagena is more elongated. It is well developed also in birds, but attains its maximum in mammals, in which it appears as the greatly elongated and spirally coiled **cochlea** (Fig. 180G).

The thin wall of the **otic labyrinth** consists throughout of two layers of tissue. The inner is the original ectoderm of the embryonic placode and is a simple epithelium only one cell in thickness. The

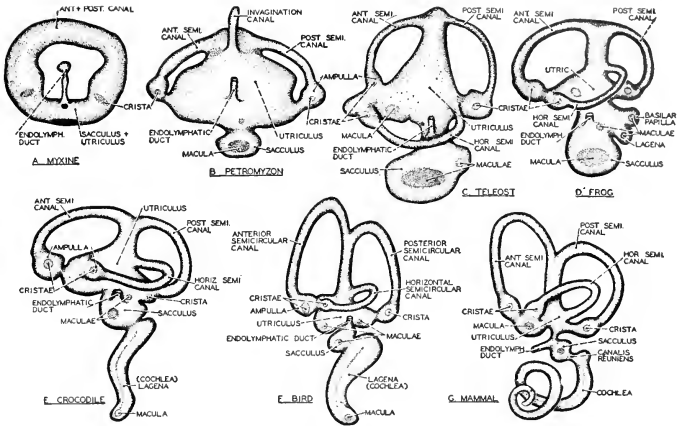


FIG. 180. The left membranous labyrinth of vertebrates as seen in lateral view. (A) *Myxine*. (B) *Petromyzon*. (C) Teleost. (D) Frog. (E) Crocodile. (F) Bird. (G) Mammal. (After Hesse. Courtesy, Neal and Rand: "Chordate Anatomy," Philadelphia, The Blakiston Company.)

outer is a thicker layer of connective tissue. All cavities within the labyrinth are filled by a watery **endolymph**. The space everywhere present between the labyrinth and the internal surface of the cartilaginous or bony **otic capsule** is filled by a similar lymphlike fluid, the **perilymph**. It is only in sharklike fishes that the primary embryonic communication between the cavity of the otic vesicle and the exterior is retained in the adult, appearing as the slender **endolymph duct** which opens externally on top of the head. The pair of **endolymph pores** are not far apart on either side of the middorsal line. In at least some of these fishes, the fluid filling the interior of the labyrinth is probably sea water, not endolymph. Calcareous particles (**otoconia**), or even large solid calcareous masses (**otoliths**), are commonly present in the endolymph of the utricle, sacculus, and ampullae.

The **sensory structures** of the otic labyrinth are restricted to a few small, definitely localized areas which are fairly constant in location in all vertebrates. Each sensory area consists of a group of relatively long columnar cells (i.e., "long" in contrast to the flattish cells of the non-nervous epithelium), each sense-cell bearing a brush of "sensory hairs" projecting from its free surface into the endolymph (Fig. 181A). A sensory area may be a roundish spot or **macula**, or it may be an elongated ridge or **crista**. On the main wall of the utricle

is a **macula acustica utriculi** (Fig. 182). Each of the three ampullae contains a **crista acustica**. On the main wall of the sacculus is the **macula acustica sacculi**. Sometimes there is a small **macula neglecta** near the region of junction of utriculus and sacculus. In the lagena is a **macula** (or **papilla**) **acustica lagenae**. Near the lagena in some amphibians is a **papilla acustica basilaris**. Corresponding to the great elongation of the lagena to form the mammalian cochlea (Fig. 180G), the sensory area is elongated and elaborated into a complex

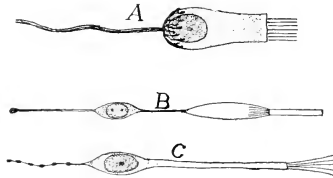


FIG. 181. Sensory cells. (A) Crista cell of ear. (B) Rod-cell of eye. (C) Olfactory cell. (After Fürbringer. Courtesy, Kingsley: "Comparative Anatomy of Vertebrates," Philadelphia, The Blakiston Company.)

mechanism, the **organ of Corti**, which extends throughout the length of the spiral cochlea (see p. 209).

**Cranial nerve VIII** divides into as many branches as there are sensory areas, sending one branch to each macula, crista, or other area. In mammals the largest trunk goes to the cochlea.

The ampullar receptors are probably stimulated by currents in the endolymph caused by movements of the body. The utricular and saccular maculas are probably static in function. The effect which motion of the endolymph may have on the receptor-cells is doubtless augmented by the otoconia and otoliths. The function of the primitive lagena is uncertain, but as it becomes highly developed, as in some reptiles and in birds, it is certainly auditory. The cochlear organ of Corti is the all-important organ of discriminative hearing in mammals.

#### *Accessory Auditory Structures*

In so far as the ear of fishes may be stimulated by vibrations of the external medium, the vibrations may reach the receptors only by transmission through the tissues of the head. But some amphibians, most reptiles, and all birds and mammals possess important auxiliary

auditory mechanisms which serve for more direct and effective transmission of external vibrations into the internal ear. The equilibratory mechanism of the ear shows little change in structure throughout the

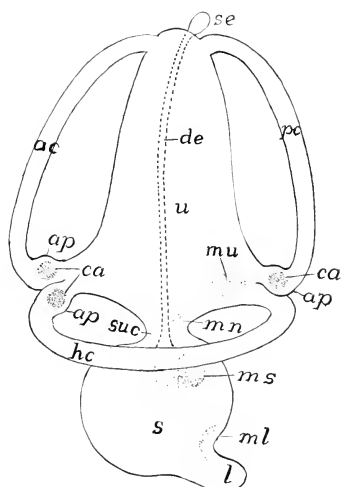


FIG. 132. Diagram of the membranous labyrinth of a vertebrate, the sensory areas dotted. (*ac*) Anterior semicircular canal; (*ap*) ampullae; (*ca*) cristae acusticae in the ampullae; (*de*) ductus endolymphaticus; (*hc*) horizontal (external) canal; (*l*) lagena; (*ml*, *mn*, *ms*, *mu*) respectively macula lagenae, m. neglecta, m. sacculi, and m. utriculi; (*pc*) posterior semicircular canal; (*s*) sacculus; (*se*) saccus endolymphaticus; (*suc*) sacculo-utricular canal; (*u*) utricle. (Courtesy, Kingsley: "Comparative Anatomy of Vertebrates," Philadelphia, The Blakiston Company.)

vertebrate series. The auditory mechanisms of amphibians, reptiles and birds, and mammals show progressive development culminating in mammals.

#### PROPRIOCEPTORS

Afferent fibers belonging to cells situated in cranial and spinal ganglions pass into many of the deep tissues of the body, ultimately

dividing into fine fibrils which are in close relation to cells of the tissue—**free nerve-termination** like that in the skin. Such terminations in an internal epithelium are doubtless interoceptive in function. But the free nerve-terminations commonly found within masses of muscle-tissue and in tendons and connective tissue are **proprioceptive**. Even the marrow in hollow bones contains proprioceptive nerve-terminations. Some of these deep nerve-terminations are in relation to specialized proprioceptors such as the “spindles” of muscles and tendons.

**Muscle-spindles** are found deeply embedded in striated muscles, usually near the junction of a muscle with its tendon. The organ has the form of a very long but thin spindle. In man the length may be 1.0 to 4.0 mm. and the diameter 0.1 to 0.2 mm. The spindle has a relatively thick sheath of connective tissue. Within the sheath is a bundle of several (up to 20 in man) muscle-fibers. They are shorter and thinner than ordinary fibers of the muscle and their striations are weakly developed. Each spindle is entered by one or more nerve-fibers which are related in various ways to the muscle-fibers of the spindle. The nerves may form rings or spirals around the muscle-cells or may terminate in systems of branching fibrils (Fig. 183). The sheath is usually attached by one end to the tendon, the other end continuing into the intramuscular connective tissue. These spindles presumably register the degree of contraction of a muscle and the varying positions of the part of the body.

**Tendon-spindles** resemble those of muscle, but the fibers contained within the sheath are, of course, similar to those of the tendon by which the spindle is enclosed. They presumably register the degree of strain in the tendon.

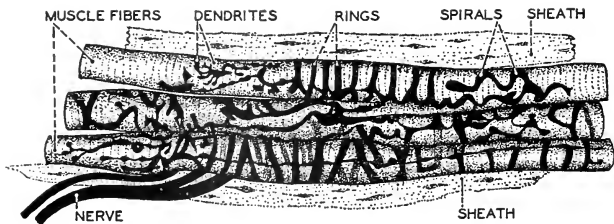


FIG. 183. A portion of a muscle-spindle from a gold chloride preparation of a cat muscle. The sensory nerve-terminations take the form of spirals, or rings, or branched dendrites. A connective-tissue sheath surrounds the spindle. (Redrawn from Jordan and Ferguson, after Ruffini. Courtesy, Neal and Rand: "Chordate Anatomy," Philadelphia, The Blakiston Company.)

The afferent impulses transmitted from these proprioceptors do not necessarily result in sensations which rise into consciousness. Many of them are concerned with such automatic reflex mechanisms as that of equilibration.

#### SOMATIC AND VISCERAL ANOMALIES

In regard to the distinction between "somatic" and "visceral" structures, as discussed on pages 154-157, there are some things whose status is either exceptional or ambiguous.

The **heart** is a **visceral organ** but its muscles are **striated**, yet they are **involuntary**. Its muscular walls, especially those of the ventricle, are thick and contract strongly and quickly. The constituent striated fibers of the muscle are, in various details of their structure, quite unlike somatic striated fibers. Cardiac muscle arises from **unsegmented mesoderm** of the same sort as that which produces ordinary nonstriated muscle. The beating of the heart is not only involuntary but also automatic to the extent that it will continue, for a limited time, after all nervous connections of the heart have been cut.

Muscle which is **striated**, but **involuntary**, occurs in the terminal regions, especially the anterior, of the wall of the **digestive tube**. In mammals striated muscle continues from the pharynx back into the esophagus, and, in the rabbit, even throughout its entire length. The embryonic origin of these striated esophageal muscles is like that of nonstriated muscles. Although striated, their action is involuntary. At least in man, swallowing is under voluntary control until food arrives in the rear part of the pharynx, but, once it has entered the esophagus, no exercise of "will power" can prevent its going down.

The **diaphragm**, dividing the coelom, may seem to lie in visceral territory, and, as a muscular organ, it is concerned with the visceral function of breathing. But its muscles are developed by growth of mesoderm downward and backward from **myotomes** (usually three pairs) in the **cervical region** of the embryo. The **phrenic nerves**, supplying the diaphragm, are the third, fourth, and fifth pairs of cervical nerves. The muscle-fibers of the diaphragm are of the typical somatic striated sort. Its action is potentially voluntary, although ordinarily it is automatically reflex. So far as its muscle is concerned, the diaphragm is an ingrowing derivative of the body-wall and is typically somatic in its segmental origin, in its structure, and in being voluntary.

The **branchiomic muscles** are especially perplexing. In embryonic origin they resemble **visceral** muscle (see p. 154) and primitively they are concerned with alimentation and respiration. Their nerves come from motor nuclei situated at that level of the medulla

which is generally regarded as a territory of visceral centers. But in position in the body, in their histologic structure, and in being voluntary, they are of **somatic** nature. They and their nerves are commonly called "visceral." But no mere calling of names can abolish the ambiguity of their nature. They confront us with the alternatives of asserting that vertebrates have some external "viscera," or else admitting that some somatic muscle can come from unsegmented mesoderm and that some somatic motor centers may occur at that level of the brain which is mainly visceral.

The existence of **external taste-receptors** in the skin of the body of some fishes is similarly perplexing. Taste is generally regarded as a visceral sense because its receptors are ordinarily in the mouth and pharynx, and because it has to do with food. Taste being thus essentially visceral, the external taste-buds, in spite of their position, are commonly called "visceral" receptors, and a special "visceral-sensory" branch of the facial nerve (VII) innervates them. The embryonic origin of the external taste-buds is not certainly known. It is possible that their sensory cells are derived from the lining of the mouth or pharynx by migration of cells out via the mouth or pharyngeal clefts. It is even uncertain whether the internal taste-buds are derived from pharyngeal endoderm or from the infolded ectoderm that lines the mouth. Whatever their origin, we may either assert that some fishes have a visceral sense in the external skin, or else admit that, while the receptors for taste are usually visceral, some vertebrates may have accessory somatic gustatory receptors and that the facial nerve may have a somatic special-sensory branch.

The fact is that animals resort to such diverse expedients in the achievement of their vital necessities that rigid distinctions between what is "somatic" and what is "visceral" cannot be made to hold for all the structures and functions of all animals. In some amphibians respiration is carried on partly in the poorly developed lungs but mainly through the thin epidermis over the entire body. Is the skin therefore "visceral"? The muscles connecting adjacent ribs (**intercostal muscles**) of mammals are as important in relation to lung-breathing as the branchiomic muscles are in relation to gill-breathing. Are the intercostal muscles "visceral"?

Between **striation** of muscle-fibers and **voluntary action**, there is no necessary correlation. The external transverse bands on the fiber are incidental to a complex internal structure which gives the fiber a high capacity for contractile efficiency. In any situation, whether somatic or visceral, where muscular action of high efficiency is needed, the muscle becomes striated. Voluntary control of muscular activity



exists where it is advantageous to the animal to have it. Quick and vigorous action is required of somatic muscles. They are accordingly striated, and it is obviously to the animal's advantage that they be under voluntary control (unless it can be shown that it would be better if the animal-as-a-whole were an absolute automaton). Unquestionably it is to the animal's advantage that its internal visceral activities be under autonomic control. But where there is local need of high muscular efficiency, as in the heart, the visceral muscle becomes striated. In doing so, it does not thereby become voluntary.

## II. Endocrinal Organs

The secreting of **hormones** is carried on by several organs which are exclusively devoted to that function. In other organs, whose primary functions may be concerned with such processes as digestion or reproduction, the secreting of endocrinal substances may occur as an incidental or secondary function. Specialized endocrinal organs are of various and most unlike origin. An important group, including the **thyroid, parathyroid, and thymus glands**, arises by outgrowth of endodermal pouches from the embryonic **pharynx**. Two glands develop by outgrowth from the wall of the brain—a **pituitary lobe** from the floor, and the **pineal gland** from the roof, of the **diencephalon**. Certain important glands in the trunk region have common origin with the **autonomic ganglions**. All of the three basic embryonic tissues or "germ layers" are represented among the endocrinal organs. Some come from **endoderm** via the digestive tube, some from **ectoderm** via the neural tube, and some develop from local **mesoderm**.

The English physiologists, **Bayliss and Starling**, discovered that, when the acid contents of the stomach enter the intestine, the digestive secretion of the pancreas is poured into the intestine. This happens even when all nervous connections between the organs have been cut. They concluded that a "chemical messenger" or hormone must be produced by epithelial cells lining the duodenum and carried to the pancreas by the blood. They gave to this hypothetic substance the name "**secretin**." The duodenum, primarily a digestive region of the intestine, is secondarily an endocrinal organ.

### *Pancreas*

The **pancreas** has an endocrinal as well as a digestive function. Scattered among lobules of the pancreas are aggregations of peculiar cells, the "**pancreatic islands**" or **islands of Langerhans** (Fig. 184). These "islands" secrete a hormone, **insulin**. Carried by the blood, it regulates the oxidation of carbohydrates in the tissues and the stor-

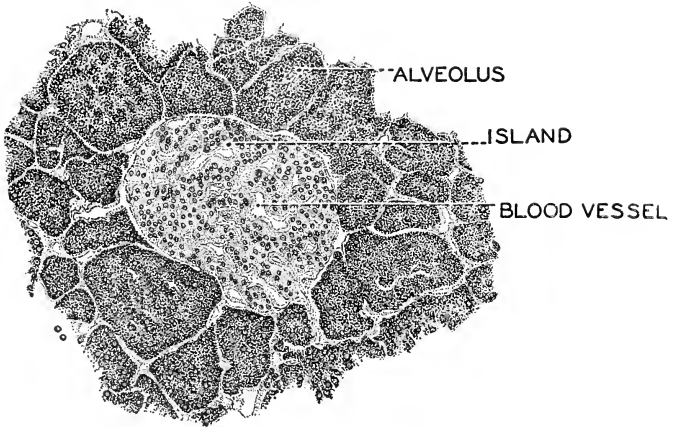


FIG. 184. A section of the pancreas, showing an island of Langerhans among the alveoli of the gland. ( $\times 200$ .) (Courtesy, Neal and Rand: "Chordate Anatomy," Philadelphia, The Blakiston Company.)

age of glycogen in the liver. Pancreatic islands occur in all classes of vertebrates, usually in connection with the pancreas, though in some bony fishes the two glands are independent. Both arise from the endoderm.

#### *Male Sex-Glands*

Removal of the **testes** of an immature animal prevents the development of the secondary sexual characteristics of the male. It is evidently due to the action of testicular hormones that the young human male begins to acquire, at puberty, some of the adult male characteristics such as beard, deeper voice, and broadened shoulders.

#### *Female Sex-Glands*

In the **ovary**, as in the testis, may be distinguished germ-cells and nongerminal "interstitial cells." That the interstitial cells have an endocrinal function is suggested by the fact that they increase during pregnancy.

The **mammalian ovary** is known to produce an important hormone, **estrone**, a fatty substance having the chemical formula  $C_{18}H_{22}O_2$ . Estrone induces puberty and menstruation. Another ovarian hormone is **progesterone** whose action is, in some respects, opposite to that of estrone which stimulates sexual activity, while progesterone

causes preparation of the uterus for reception of the fertilized egg and induces functional activity of the mammary glands.

### *Adrenal (or Suprarenal) Glands*

The terms **adrenal**, or **suprarenal**, and **interrenal** refer to certain endocrinal organs which have no relation to the renal organs except that of proximity. Considering these glands collectively, they involve secretory tissues of two sorts, differing in origin, histologic characteristics, and functional effects. Tissue of one sort is derived from mesoderm; the other, from cells which have common origin with neurons of the autonomic ganglions, being therefore derivatives of the ectodermal neural tube. The ectodermal glandular tissue is histologically distinguished from the mesodermal by its relatively large "**chromaffin cells**," so called because they have a strong affinity for chromic salts, which stain them brown. In the **cyclostome eels** the mesodermal glands appear as a paired series of small **interrenal bodies** which lie throughout the length of the body-cavity near the postcardinal veins. The chromaffin cells are arranged as strands along the dorsal aorta. In the **sharklike fishes**, the interrenal bodies tend to aggregate in the posterior part of the body-cavity, while the chromaffin cells occur in segmentally arranged groups near the sympathetic ganglions. In **terrestrial vertebrates** the two secretory tissues tend to become localized in more definite glandular organs in the posterior region of the coelom, and tend also to occur together within the confines of the same glandular mass, but yet retaining their histologic and functional specificity. These tendencies reach their culmination in **mammals**, in which the two tissues are localized in one pair of **adrenal (or suprarenal) glands**, situated usually very close to the kidneys (Fig. 185). There may be, however, some small accessory adrenal bodies nearby.

In the **mammalian adrenal** there is an outer yellowish **cortex** consisting of the mesodermal tissue, and a central brownish **medulla** in which appear the characteristic chromaffin cells of the ectodermal tissue. They are arranged in clusters separated by numerous blood-spaces. A compact connective-tissue capsule encloses the glandular tissues (Fig. 186).

**Functions of Adrenals.** The adrenals have a double function corresponding to their two tissues. The **cortex** secretes an endocrine, **cortin**, of unknown chemical composition, which is essential to life. Destruction of the cortex is followed by Addison's disease, which is characterized by a deep pigmentation of the skin and great weakness. Death comes rapidly unless cortin is administered. The cortex of the adrenal is, relative to the medulla, largest during fetal life, and there is little doubt that its secretions have a strong influence upon growth.

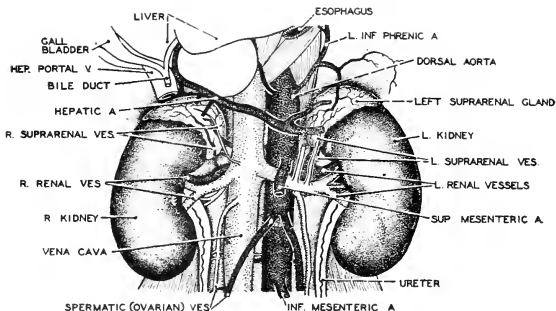


FIG. 185. The adrenals or suprarenals shown in relation to the kidneys as seen when the fat which normally encloses them is removed. The relations of the blood-vessels which supply them are shown. (A.) Artery; (L.) left; (R.) right; (V.) vein. (Courtesy, Neal and Rand: "Chordate Anatomy," Philadelphia, The Blakiston Company.)

The endocrine secreted by the **medullary tissue** of the adrenal is **epinephrine** or **adrenalin**, its empiric chemical formula being  $C_9H_{13}O_3N$ . Like the sympathetic nerves, epinephrine has a stimulating effect upon smooth muscle. It is so potent that its physiologic effects appear even when it is diluted to 1 part in 400,000,000 of blood.

The well-known experiments of W. B. Cannon led him to his emergency theory of adrenal action. He found that in a quiet, undisturbed animal epinephrine is absent from the blood. When, however, the animal is excited by pain, fear, or anger, epinephrine increases. As a result, the heart beats more strongly, breathing becomes deeper and more rapid, intestinal action ceases, the liver releases sugar more rapidly, the muscles respond more quickly to stimulation, the tonus of the blood-vessels is raised, the coagulability of the blood increases, and so the animal is prepared either to run or fight. Thus the medullary secretion reinforces the action of the sympathetic nerves.

Cannon has shown also that a substance which resembles epinephrine is given off at the junction of a sympathetic nerve with its effector. This substance has been called "**sympathin.**"

The adrenal gland has characteristic **visceral innervation**, being entered by nerves from both the sympathetic and the parasympathetic autonomic divisions. The medulla serves as an amplifier for the thoracolumbar division. A radio station may receive a message over one telephone line and then broadcast the message to the world. The medulla receives an impulse from a sympathetic nerve and thereupon broadcasts epinephrine to the whole body. The embryonic origin of

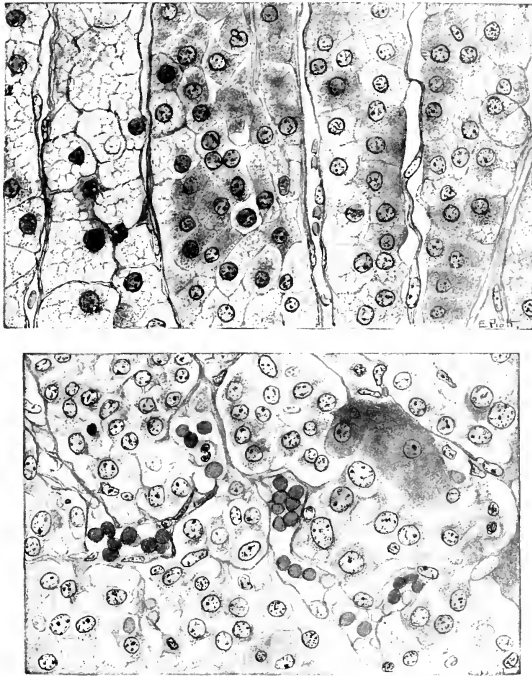


FIG. 186. Adrenal gland, human. (*Top*) Section through the zona fasciculata. (*Bottom*) Section of medulla. (Courtesy, Bremer: "Text-Book of Histology," Philadelphia, The Blakiston Company.)

the medulla and the nature of its secretion justify regarding it as being virtually an autonomic ganglion whose exciters, lacking post-ganglionic conductor-fibers and possessing exaggerated secretory capacity, broadcast their stimulating substance to their distant effectors via the blood-stream instead of giving them individual service through nerve-fibers. Consistent with this interpretation, the autonomic fibers directly related to the medullary cells are described as being **preganglionic**. If they are, it puts the secreting cells in the position of exciter (postganglionic) neurons.

The **endocrinal glands derived from the pharynx** resemble those of the adrenal group in respect to their number and degree of

localization in the body. In fishes the pharyngeal glands are small and numerous. Many or all of the pharyngeal pouches may produce glands. In amphibians and reptiles, and culminating in birds and mammals, there appears a tendency toward reduction in number of glandular outgrowths and further reduction in ultimate number by fusion of embryonic units. The persisting glands in birds and mammals are, for the most part, in the more posterior pharyngeal region.

### *Thyroid Gland*

The **thyroid gland**, present in all vertebrates, arises as a mid-ventral outgrowth from the pharynx opposite the first pair of pharyngeal pouches (Fig. 187). It becomes completely detached from the floor of the pharynx and remains near its place of origin or may shift to a somewhat more posterior position. In terrestrial vertebrates it

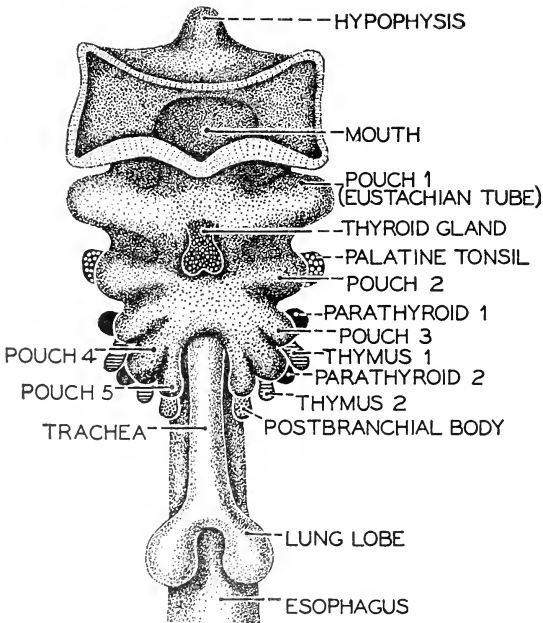


FIG. 187. Ventral view of pharyngeal region of a human embryo showing the pharyngeal pouches and their glandular derivatives; semidiagrammatic. (Courtesy, Neal and Rand: "Chordate Anatomy," Philadelphia, The Blakiston Company.)

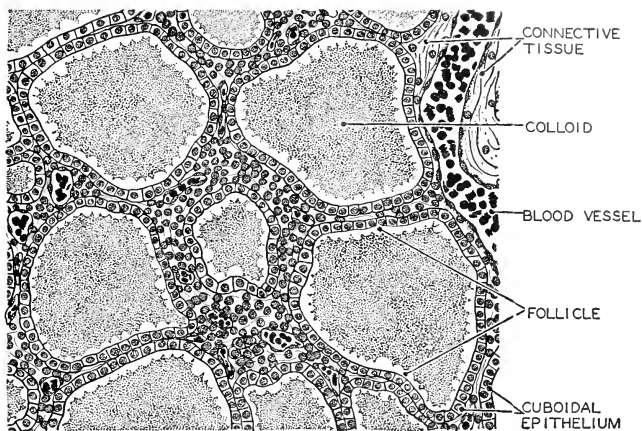


FIG. 188. A portion of a section of the thyroid gland, enlarged, showing the secretory epithelium and the colloid-filled follicles. (Courtesy, Neal and Rand: "Chordate Anatomy," Philadelphia, The Blakiston Company.)

lies ventral to the trachea and just posterior to the larynx. It is usually a single median body but in some cases, especially among amphibians and mammals, it becomes more or less definitely bilobed.

The thyroid is formed of numerous masses of glandular tissue, separated from one another by connective tissue (Fig. 188). The glandular tissue consists of rounded follicles, each enclosed by a single layer of cuboidal epithelium. Loose connective tissue filled with blood-vessels and lymphatics binds the follicles together. Each follicle is filled with a jelly-like colloid material which has a strong affinity for acid dyes such as eosin.

The most important, if not the exclusive, endocrinal secretion of the thyroid gland is an iodine-containing compound, **thyroxin**, whose empiric chemical formula is  $C_{15}H_{11}O_4NI_4$ . A substance with identical properties has been made synthetically, and it is generally the synthetic drug which is used in medical practice.

One function of thyroxin is to control metabolism, especially that of the carbohydrates. Also, it regulates growth before birth, through infancy, and at puberty. Tadpoles fed with thyroid may become frogs prematurely, but of abnormally small size. Excessive activity of the human gland is a common malady, manifested by extreme nervousness, rapid pulse, insomnia, and basal metabolism above normal, so that the patient loses weight. As too much thyroxin speeds up the

vital processes, too little slows them down. Basal metabolism becomes low, and the tendency is to "put on fat." In the young, both growth and development are retarded, and, if the deficiency is very great, a child, unless given thyroid artificially, may become an idiotic dwarf.

### *Parathyroid Glands*

These glands, found in all vertebrates except fishes, develop by outgrowth from the endodermal wall of the pharyngeal pouches of the third and fourth pairs (Fig. 187). In the adult they are a pair of small glands lying close to the thyroid or sometimes inside the connective-tissue capsule enclosing the thyroid. Functionally, however, they are quite unlike the thyroid.

The **parathyroids** consist of masses and cords of the originally epithelial cells, among which numerous blood-vessels are interspersed. Histologically, they resemble lymph-nodes (Fig. 67). Colloid-filled follicles are rare, but they multiply in number when the thyroid is removed, and may take over the function of the thyroid in an emergency. An animal may lose its thyroid gland without necessarily fatal consequences, but removal of the parathyroids is followed by convulsions and death unless parathyroid extract is administered intravenously. There is a marked decrease in the calcium of the blood, followed by cramps and muscular tetany. Apparently calcium salts prevent acute stimulation of muscular contraction.

Even a slight excess of activity of the parathyroids may have serious consequences. The reserve supply of calcium for bodily use is limited, and excess of parathyroid endocrine in the blood may cause the withdrawal of calcium from the bones and teeth, which then lose their hardness and become fibrous.

The chemical nature of the parathyroid endocrine is not yet known.

### *Thymus Gland*

In the **cyclostome eel, *Petromyzon***, small thymus outgrowths develop from the dorsal regions of all seven pairs of pharyngeal pouches. In other vertebrates the number is more or less reduced, the derivatives of the third and fourth pairs (Figs. 187, 189) usually persisting or, in some mammals, the derivatives of only the fourth pair. In **fishes** the thymus bodies of each side usually fuse to form an anteroposteriorly elongated gland lying dorsal to the branchial chambers. In **amphibians** and **reptiles** they are situated laterally in the region of the neck. In **mammals** they lie at the base of the neck and in the partition (mediastinum) between the right and left pleural cavities—therefore close to the heart. These glands in mammals are the "throat sweetbreads."



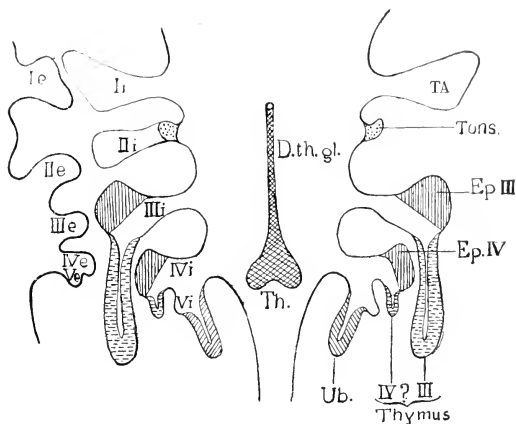


FIG. 189. Diagram to show the derivatives of the pharyngeal pouches. (Ie, He, IIe, IVe, Ve) External pharyngeal grooves; (Ii, Iii, Iii, Ivi, Ivi) internal pharyngeal pouches; (D.th.gl.) ductus thyroglossus; (Ep. III, Ep. IV) parathyroid glands; (TA) auditory (Eustachian) tube and tympanic cavity; (Th.) thyroid gland; (Tons.) palatine tonsil; (Ub.) ultimobranchial (postbranchial) body. (After Keibel and Mall, Courtesy, Schaeffer: "Morris' Human Anatomy," Philadelphia, The Blakiston Company.)

The **human thymus glands** are of pinkish color in childhood but in older persons undergo more or less fatty degeneration and become yellowish. They enlarge up to puberty, and thereafter gradually shrink. Contrary to earlier opinion, the gland does not completely disappear in the adult, but persists as a shrunken remnant within the mediastinum. The endocrinal function of the thymus is doubtful, since removal of the gland is not followed by disturbances of normal functions. The enlargement of the gland in early life and its later atrophy suggest that its functional activity may be limited to stages of growth and differentiation.

There is some evidence that the thymus glands of **birds** have some relation to the normal formation of the shell, shell-membrane, and albumen of the egg.

#### *Ultimobranchial Bodies*

Among the pharyngeal derivatives are the **ultimobranchial bodies**, called also **postbranchial** and **suprapericardial bodies**. These are paired glands which arise from or near the fifth pair of gill-pouches (Figs. 187, 189). They come to lie near the posterior border of the thyroid and attain a vesicular structure. They occur in all verte-

brates except cyclostomes and possibly the bony fishes. They may have an embryonic endocrinal function.

### *Pituitary Gland*

The **pituitary gland** is located at the base of the brain just behind the optic chiasma, where it is attached by a stalk to the lower end of the infundibulum. Lodged in a cavity, the **sella turcica**, in the sphenoid bone, the mammalian pituitary is as safe from injury as possible (Fig. 190).

Like the suprarenals, the pituitary is formed of two elements of diverse origin and function (Fig. 191). The chief parts are a larger anterior and a smaller posterior lobe. The latter is partly surrounded by the anterior lobe. Between the two major lobes are two smaller glandular masses, the **pars intermedia** and the **pars tuberalis**. The anterior lobe consists of epithelial cells forming cordlike masses among which are numerous spaces filled with blood or lymph. In the **pars intermedia** are some colloid-filled follicles resembling those of the thyroid. The cells of the posterior lobe resemble certain non-nervous ectodermal cells (neuroglia) of the brain. Among them are numerous connective-tissue fibers.

The pituitary gland has a double origin. The **anterior lobe** comes from an ectodermal sac, "Rathke's pouch" (hypophysis), in the roof of the mouth, while the **posterior lobe** is formed as an outgrowth of the base of the diencephalon (Figs. 191, 192). The posterior end of Rathke's pouch comes into contact with the infundibular outgrowth from the base of the brain. As development proceeds, Rathke's pouch loses connection with the ectoderm and breaks up into vesicles, the cavities of which are remnants of the cavity of the pouch. The ventral end of the infundibulum becomes thickened to form the posterior lobe. The cells which later become differentiated as **pars intermedia** and **pars tuberalis** are derived from the hypophyseal pouch.

The pituitary gland occurs in all vertebrates. Its elements make their first appearance in cyclostomes from whose hypophyseal pouch (or "duct": Fig. 191) are proliferated cells which form an intermediate lobe, while other clusters of cells produce hollow vesicles which are believed to represent the beginning of a glandular anterior lobe. The infundibular (posterior) lobe, however, is not definitely differentiated. In sharklike fishes, the infundibular lobe of the gland is only slightly indicated. Through the vertebrate series from fishes to man, all three elements seen in cyclostomes are present. The anterior lobe steadily increases in relative size while the intermediate lobe shrinks. An increase takes place in size and differentiation of the posterior lobe. The presence of colloidal material in the pituitary in all

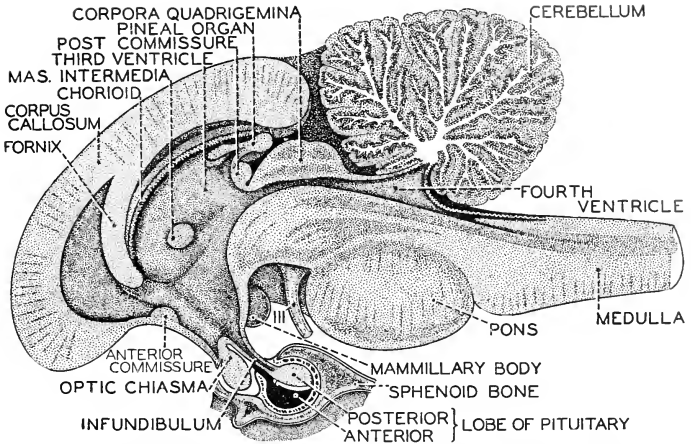


FIG. 190. A median section of the human brain-stem, showing the relations of the pituitary gland. (After Sobotta. Courtesy, Neal and Rand: "Chordate Anatomy," Philadelphia, The Blakiston Company.)

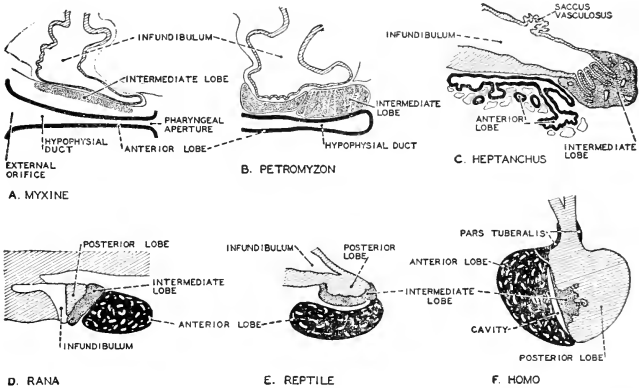


FIG. 191. A series of diagrams showing conditions in six different vertebrates. The series suggests possible stages in the evolution of the pituitary gland. The complexity of origin of this gland is correlated with the complexity of its endocrinal functions. The posterior lobe is cross-hatched, intermediate lobe stippled, anterior (hypophyseal) lobe piebald, and the pars tuberalis solid black. (Redrawn from Oppel, after Stendell. Courtesy, Neal and Rand: "Chordate Anatomy," Philadelphia, The Blakiston Company.)

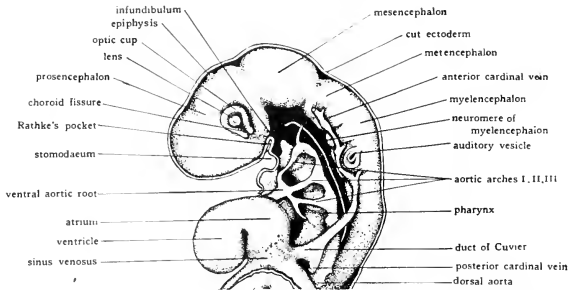


FIG. 192. Left lateral view (seen as a transparent object) of the head and heart of 50-hour chick embryo. (After Prentiss. Courtesy, Patten: "Early Embryology of the Chick," Philadelphia, The Blakiston Company.)

vertebrate groups justifies the assumption that the gland has an endocrinal function throughout the series.

**Functions.** One of the important functions of the anterior lobe is stimulation of growth. Enlarged pituitary in early life is accompanied by excessive growth of bone. Deficient secretion, on the other hand, produces a certain type of dwarf, the **ateliotic dwarf** or "midget."

After the growth of the long bones has ceased, as in the normal adult, it is of course impossible to stimulate further growth in height. But when, as the result of tumorous enlargement, anterior-lobe secretion is increased, a local growth of bone, sometimes asymmetric, may occur. Such cases of **acromegaly** are not infrequent. Experiments demonstrate that deficiency of anterior-lobe hormone in young animals results in failure of sexual development and atrophy of the sex glands.

Of all the endocrinal organs, the pituitary is most important in that it produces not merely one but numerous hormones, some of which act directly on various parts of the body and others affect the activities of other endocrinal organs, especially the adrenals and the thyroid. Therefore, either directly, or indirectly through these interrelations with other glands, the effects of the pituitary probably extend to every part and function of the body. Hormones of the **anterior lobe**, in addition to their control of growth, are essential to the normal development and functional activity of the reproductive organs, including the mammary glands. They affect processes so unlike as the deposition of fat and the movements of pigment-granules in black pigment cells (melanophores) of amphibian skin. The functions of the **posterior lobe** are apparently less important—at least, less numerous or less well known. There is evidence that it exercises some control over metabolism, especially with reference to water, fats, and

carbohydrates, and affects blood-pressure. It is definitely known that it stimulates contraction of the muscles of the mammalian uterus.

### *Pineal Body*

In the description of the diencephalon (see p. 145) were mentioned two median dorsal outgrowths, the **epiphyses** or **parietal** and **pineal** structures (Fig. 138). Among fishes, amphibians, and reptiles are animals in which one or the other, rarely both, of these epiphyses may develop into a small, eyelike organ. Birds and mammals possess nothing resembling a median eye, but the thin roof of the diencephalon does give rise to a structure which appears in the adult as a small, solid body projecting outward just anterior to the optic lobes (corpora quadrigemina of mammals: Fig. 140, *p*). In position and manner of origin, it seems to correspond to the more posterior or pineal epiphysis of other vertebrates. Known as the "**pineal body**," it is usually included in the list of endocrinal glands. Histologically its structure is indifferent. The main reason for regarding it as a gland is that it seems less likely that it could be anything else. Secretion is a function which is not necessarily associated with conspicuous differentiation of cellular structure. In the human brain, the pineal organ is deeply buried beneath the bulky overhanging masses of the cerebral hemispheres and cerebellum (Figs. 190, 139). The "body" being thus concealed in the innermost recesses of the brain, the seventeenth-century philosopher, Descartes, conceived it to be the seat of the soul. The considerable amount of experimental investigation to which it has been subjected has not proved that it is anything else. At most, there is some inconclusive evidence that it plays some part in the control of development and growth. It remains a mystery.

### **The Vertebrate "Pattern"—Basic but Flexible**

The foregoing survey of the "basic features" of vertebrates makes it apparent that certain of their features are to be seen clearly only in embryonic stages or, indeed, may not be recognized at all in the adult. A study of the adult mammal would fail to reveal any pharyngeal clefts or notochord. In view of the fact that the very early embryonic stages of all animals, invertebrate and vertebrate, are strikingly similar, it may be objected that recourse to the embryo in the search for common features distinctive of vertebrates is not valid.

It is true that eggs of all animals are essentially alike in so far as they are all minute bodies of protoplasm (plus more or less food material), each organized as a single cell. The diverse organs which they are capable of producing are not visibly present, as such, in the egg. Certain early stages—the one-layered blastula and the two-layered gas-

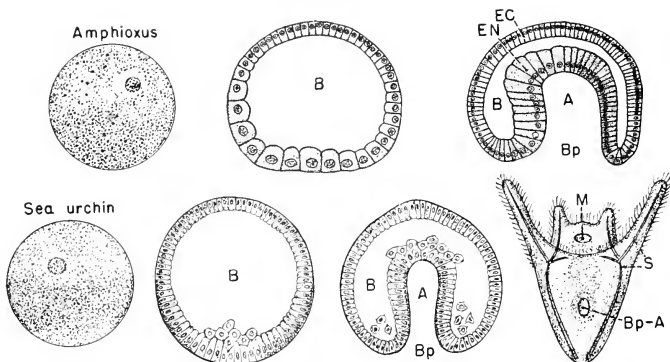


FIG. 193. Early embryonic stages of *Amphioxus* (a chordate) and a sea urchin (an echinoderm).

(Top) Egg, blastula, and gastrula of *Amphioxus*. (Bottom) Egg, blastula, gastrula, and early larval (pluteus) stage of sea urchin. The eggs are of about the same size (diameter 0.1 mm.). The eggs and the pluteus are represented as semi-transparent entire objects. The blastulas and gastrulas are represented in axial section. (A) Archenteron, the prospective digestive cavity; (B) blastocoel; (Bp) blastopore; (Bp-A) blastopore persisting as anus; (EC) ectoderm; (EN) endoderm; (M) mouth; (S) calcareous skeletal rods.

The gastrula of *Amphioxus* proceeds directly to develop a neural tube and notochord, basic features of a chordate. The gastrula of the sea urchin within a few hours becomes transformed into a pluteus which, in form and structure, is totally devoid of chordate characteristics.

trula—are common to the great majority of animal embryos. The egg, blastula, and gastrula of a sea urchin would seem to differ in no important way from the corresponding stages of the embryo of *Amphioxus*, a small, somewhat fishlike animal sometimes classified as a vertebrate (Fig. 193). However, that animals resemble one another more and more closely the earlier the stages which are compared, is not because points of similarity become more numerous but because points of difference become fewer. By the time the sea urchin embryo has passed over into the characteristic larval form, the pluteus, it has positively declared itself to be a sea urchin. The chick embryo as early as its second day of development has a dorsal neural tube, an unmistakable notochord, and a ventral heart. It is irrevocably a vertebrate. In the foregoing enumeration of basic features of vertebrates, the embryonic stages to which reference has been made have in no case been earlier than a stage in which the general body-plan and the pattern of organs have become so definitely established as to amount to a "declaration of intentions" to become a vertebrate.

This general body-plan, with its several basic organs, constitutes




FIG. 194. All the animals of this motley collection possess the backbone and the basic structure of backboned animals—illustrating the extreme plasticity of the vertebrate "pattern." (1) Dove. (2) Lizard. (3) Bat. (4) Crane. (5) *Phyllopteryx* (a small Pacific fish which looks like a tangled tuft of seaweed). (6) Elephant. (7) Giraffe. (8, 9, 10) Corresponding views (front) of, respectively, a man, an ape, and a batfish. (11) Toad. (12) Snake. (13) Fish. (1 and 4, courtesy, Saunders: "Manual of British Birds," London, Gurney & Jackson. 2, courtesy, Cope: "The Crocodylians, Lizards and Snakes of North America," Washington, The Smithsonian Institution. 3 and 9, courtesy, Vogt and Specht: "Die Säugetiere in Wort und Bild," Munich, F. Bruckmann-Verlag. 5, from "Cambridge Natural History," Vol. VII. By permission of the Macmillan Company, publishers. 6 and 7, courtesy, Flower and Lydekker: "Introduction to the Study of Mammals," London, A. & C. Black, Ltd. 8, "David," by Michelangelo. 10, courtesy, Jordan and Evermann: "Fishes of North and Middle America," Washington, The Smithsonian Institution. 11, by permission from "Biology of the Amphibia," by Noble. Copyrighted 1931, McGraw-Hill Book Co., Inc. 12, courtesy, "Brehm's Tierleben," Leipzig, Bibliographisches Institut. 13, courtesy, Neal and Rand: "Chordate Anatomy," Philadelphia, The Blakiston Company.)

a "pattern" sufficiently definite to mark off distinctly a great group of animals, and yet so elastic as to admit of great diversity of form within the group. This elasticity of the pattern, enabling the animal to adapt itself to a wide range of environments and manners of living, is achieved in a variety of ways. The proportions of parts may be varied; e.g., the long hindlegs of the frog and the kangaroo, and the long forelegs of the giraffe; exaggeration of teeth to form tusks in the elephant and the walrus. The spatial relations of parts may be secondarily modified, as when a liver, having developed in its typical ventral position, is pushed laterally or dorsally by crowding of neighboring organs. By variation of the internal differentiation of an organ, its function may be greatly altered, as when a portion of the gastric region of the digestive tube of a grain-eating bird becomes the powerfully muscular grinding gizzard and relegates the function of chemical digestion of food to a more anterior region. Secondary and accessory structures of a great variety of sorts may be produced—bony scales, horny scales, feathers, and hair, all developed by the skin; glandular structures in great variety, both integumentary and internal; external ears; marsupial pouches. By such means as these, and without violation of the basic vertebrate pattern, have come into existence vertebrates so different as minnow and elephant, mouse and python, hummingbird and whale, toad, turtle, and man (Fig. 194).



# Reproduction

---

7

Animals exist not only in space but also in time. The anatomy of an animal is more than the form which it possesses at a particular instant. It is form which passes through a series of definite and characteristic changes in the course of development of the egg into the adult. The anatomy of an adult is merely a cross section of the animal's whole anatomy. Therefore anatomy, broadly defined, includes embryology.

Many anatomic peculiarities of animals are unintelligible so long as only the adult is studied. Embryology gives some reason for such facts as that the chief artery emerging from the heart turns to the right in a bird but to the left in a mammal, and that the diaphragm of a mammal is supplied by nerves from the neck region instead of from the neighboring trunk region of the spinal cord. The theory of evolution rests to an important extent on facts derived from the comparative embryology of vertebrates.

(This chapter on reproduction contains occasional statements which imply or assume that the main line of evolution of the vertebrates began with fishes and proceeded via amphibians to reptiles where it bifurcated to produce birds and mammals. The facts which indicate this order are derived largely from comparative adult anatomy, which is discussed in later chapters (Part III). If the anticipation of conclusions which may be drawn from the later chapters should seem to violate the logical structure of this book, the fault may be condoned on the ground that appreciation of the possible significance of the embryologic facts may best be assured if the significance is pointed out as the facts are presented. See the Preface.)

**Sexes.** Reproduction in the vertebrates always involves gonads of two types—the ovary, which produces eggs (ova), and the testis, which produces sperm (spermatozoa). In some tunicates (Urochorda), presumably remote allies of vertebrates, alternation of sexual and asexual generations occurs. A fertilized egg becomes an asexual indi-

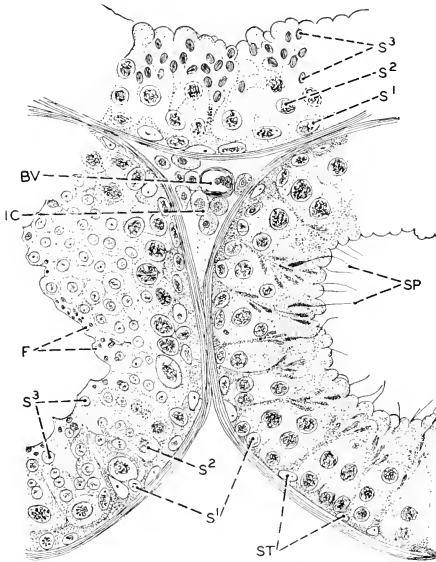


FIG. 195. Cross sections of testis tubules of a mouse. (BV) Blood-vessel; (F) fat granules; (IC) interstitial cells; (S<sup>1</sup>) spermatogonia; (S<sup>2</sup>) spermatocytes; (S<sup>3</sup>) spermatids; (SP) spermatozoa; (ST) sustentacular cells. ( $\times 360$ .) (Modified from Bremer: "Text-Book of Histology," Philadelphia, The Blakiston Company.)

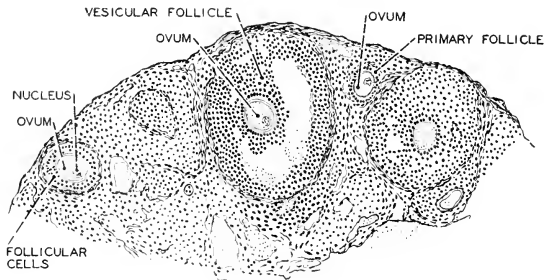


FIG. 196. Section through cortical region of the ovary of a mouse showing young (primary) ovarian follicles and older (vesicular) follicles. ( $\times 76$ .) (Courtesy, Neal and Rand: "Comparative Anatomy," Philadelphia, The Blakiston Company.)

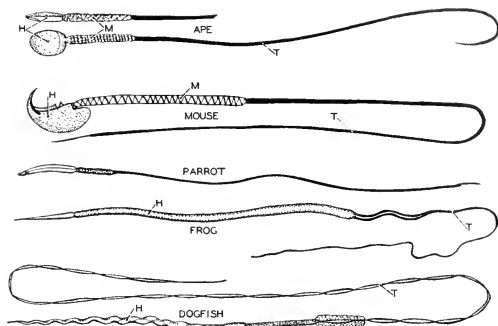


FIG. 197. Spermatozoa of ape (*Inuus*), mouse (*Mus*), parrot (*Psittacus*), frog (*Rana*), and dogfish (*Squalus*). (H) Head; (M) middle piece; (T) tail. In the upper of the two views of the ape spermatozoon, the thin, flat head is seen edgewise. The spermatozoon of the frog is about 0.1 mm. long. (After Retzius. Courtesy, Neal and Rand: "Chordate Anatomy," Philadelphia, The Blakiston Company.)

vidual from which arise buds. These become sexual adults which are **hermaphrodite**—that is, they produce both eggs and sperm.

In all vertebrates except a few fishes, the individual is either male or female—the **dioecious** condition. The eel-like hag, *Myxine* (a cyclostome or "round-mouthed" eel), and several of the bony fishes (Teleostei) are normally hermaphrodite (**monoecious**). Among vertebrates which are normally dioecious, many abnormal cases have been reported, especially in fishes and amphibians, in which germ-cells of both sexes were found in one individual.

**Germinal Bodies.** The spermatozoa are derived from cells in the walls of delicate tubules which are the essential part of the testis (Fig. 195). The ova come from primordial germ-cells contained within the tissues of the usually solid ovary (Fig. 196).

The "head" of the spermatozoon (Fig. 197) consists of compacted nuclear material (chromatin) derived from the primordial germ-cell. A locomotor "tail" is formed from the cytoplasm (extranuclear protoplasm) of the original cell. The "ripe" spermatozoon is essentially a motile nucleus.

The egg in the course of its differentiation acquires a greatly increased body of cytoplasm within which is deposited more or less food material, the **yolk** or **deutoplasm**. The egg may become invested by membranes or envelopes, either protective (e.g., the vitelline or yolk membrane; the hard calcareous shell of a bird's egg—see Fig. 200) or nutritive (e.g., the albumen or "white" of a bird's egg).

Eggs differ most remarkably as to the amount of contained yolk and as to their outer coverings. The microscopic egg of a mammal and

the gigantic ostrich egg encased in its hard shell would seem to be hardly comparable objects. The thing referred to in kitchen and market as an "egg" consists of the egg in strict sense, or **ovum**, plus various extraneous substances and structures. The hen's ovum, corresponding to the small egg of some fish, is merely the yellow sphere commonly called the "yolk" of the "egg," enclosed in its vitelline membrane (Fig. 200). The following data illustrate the differences in ova in regard to size and content of yolk:

<i>Egg</i>	<i>Approximate Diameter, mm.</i>	<i>Relative Volumes</i>
<i>Amphioxus</i> .....	0.1	1
Some frogs .....	2.0	8,000
Domestic fowl (ovum or "yolk") .....	30.0	27,000,000

The volume of an ostrich ovum would be hundreds of millions of times greater than that of a mouse egg, whose diameter is about 0.06 mm. Size of eggs is correlated primarily with the method of development. The ovum of the oviparous hummingbird is tremendously larger than that of the viviparous whale. But correlation with size of body may appear when the developmental methods of the animals are similar—e.g., in reptiles and birds.

The number of eggs produced at a time or in a breeding season ranges from one to several millions. The maximum number occurs in some of the bony fishes—e.g., the cod. Among amphibians, some frogs produce a single egg per season, others 30,000 or more. In reptiles, birds, and mammals, the number is relatively small.

The **eggs of fishes** are usually relatively small, less than 5 mm. in diameter. Eggs of sharks and skates, however, contain much yolk and rival in size the eggs of birds. These large eggs are enclosed in shells consisting of a hornlike material secreted by the anterior part of the oviduct. In oviparous sharks and skates, the shell is usually flat and quadrangular and has long tendrils which serve to anchor it to seaweed or other objects (Fig. 198).

The **eggs of amphibians**, which always contain considerable yolk, are larger than the eggs of many fishes but smaller than the average for reptiles and birds. Eggs of various frogs range from 1.5 to 3 mm. in diameter. Eggs of large salamanders (*Necturus*, *Cryptobranchus*) are 5 or 6 mm. in diameter. The amphibian oviduct deposits upon the egg a layer of gelatinous substance which, after the egg has been extruded into the water, swells to form a thick, jelly-like envelope (Fig. 199).

**Reptiles and birds** produce eggs containing an enormous amount of yolk (Figs. 200, 208). The protoplasm in these great eggs is aggregated at one spot on the surface of the egg, marking the **animal pole**, while the remainder of the egg is yolk nearly, if not quite, devoid of protoplasm. The localized protoplasm (**germ-disk**; Fig. 208) appears as a small white fleck on the surface of the yellow yolk. Before the

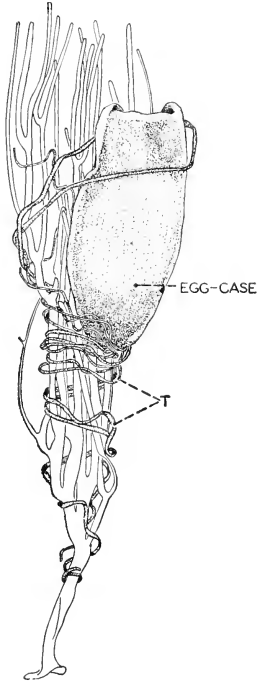


FIG. 198. Egg-case of small shark. (T) Tendrils coiled around branches of a horny (gorgonian) coral. (About half actual size.) (Courtesy, Neal and Rand: "Chordate Anatomy," Philadelphia, The Blakiston Company.)

ovum is fertilized, the germ-disk contains a single nucleus, consistent with the fact that the ovum is one cell, however much gorged with yolk. But as a dynamic thing—i.e., physiologically—the germ-disk is the essential cell. These large eggs are invested by a tough **vitelline membrane** external to which may be more or less nutritive **albumen** (the "white" of a hen's egg) and an outer **shell** which in most reptiles is of a leathery texture, but in crocodiles, alligators, and birds is highly calcified and, therefore, hard and brittle. Against the inner surface of the shell lies a thin, fibrous **shell-membrane**.

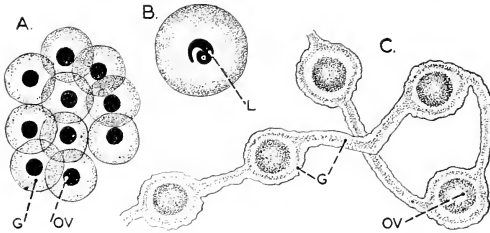


FIG. 199. Amphibian eggs. (A) Of frog, soon after laying. (B) Early larva of frog, just before hatching. (C) Of the salamander, *Cryptobranchus allegheniensis*. (G) Gelatinous layer; (L) larva; (OV) ovum. (A and C, approximately actual size; B, enlarged.) (A and B, after Marshall; C, after Reese. Courtesy, Neal and Rand: "Chordate Anatomy," Philadelphia, The Blakiston Company.)

**Eggs of mammals**, with two exceptions, are minute, containing a minimum of yolk. The exceptions are the duckbill (*Ornithorhynchus*) and the spiny anteater (*Echidna*) of the Australian region. These two mammals, presumably of primitive type, lay large eggs encased in tough shells. In general, these mammals are reptilian in their methods of reproduction. Otherwise, mammalian eggs are of microscopic dimensions (0.06 to 0.3 mm. in diameter). The egg (Fig. 201) is covered by a delicate membrane (**zona pellucida**), external to which may be a cellular membrane (**corona radiata**), both contributed by the ovary.

**Fertilization.** Development is initiated by the "fertilization" of the egg. A spermatozoon penetrates the egg (**impregnation**) and the

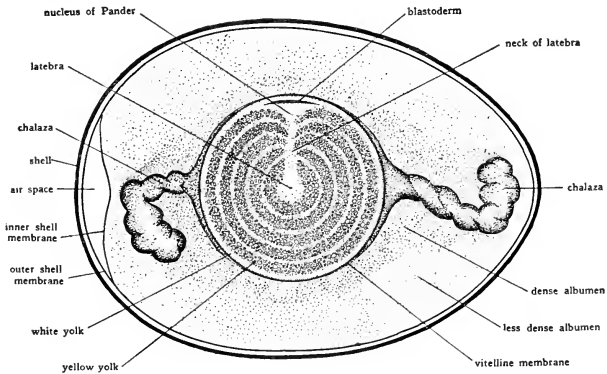


FIG. 200. Diagram representing a section of a hen's egg cut in a plane including the long axis of the egg and passing through the blastoderm. (After Lillie. Courtesy, Patten: "Early Embryology of the Chick," Philadelphia, The Blakiston Company.)

sperm chromatin becomes joined with the chromatin of the egg nucleus. The "maturation" process through which all germ-cells pass reduces their chromatin to approximately half that contained in body cells, so that the union of sperm chromatin and egg chromatin provides the fertilized egg with a nucleus containing the full complement of chromatic bodies (**chromosomes**) characteristic of all body cells of the animal. Therefore the fertilized egg, although the product of two cells, possesses the mechanism of a single cell. It possesses no visible structures which would adequately account for its development into a large complex animal like the parent animals. Compared to such cells as those of muscle and nervous tissue, it is strikingly devoid of visible special mechanism. Yolk is characteristic of eggs, but yolk is an inert food substance, not a mechanism.

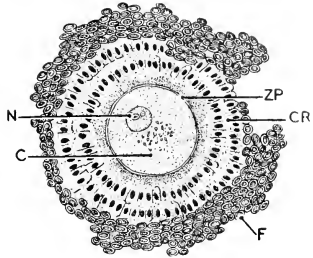


FIG. 201. Human ovum surrounded by follicular cells. Actual diameter of ovum about 0.25 mm. (C) Cytoplasm containing some yolk; (CR) corona radiata; (F) follicular cells; (N) nucleus; (ZP) zona pellucida. (After Nagel. Courtesy, Neal and Rand: "Chordate Anatomy," Philadelphia, The Blakiston Company.)

**Developmental Potentialities.** The motile and aggressive spermatozoon might seem to be the essentially "animal" body in development, while the relatively large unfertilized egg, burdened with inert yolk, would appear rather as a passive and vegetative thing. But in normal development the spermatozoon merely imparts the stimulus which initiates development and provides for inheritance from a male parent. Experimentation has proved that artificially applied mechanical or chemical agencies may stimulate an egg to develop and produce a characteristic adult without the assistance of a spermatozoon. Obviously, however, such an adult inherits only from a mother, since its "father" may have been a mere needle-prick or a change in osmotic pressure of the external medium.

**Exit of Sperm and Eggs.** The sperm is usually carried by ducts which lead from the testis to the exterior, but in cyclostomes and some bony fishes it is discharged from the testes into the body-cavity and finds exit through abdominal or genital pores which pierce the body-wall.

Ova are usually liberated from the surface of a solid ovary (Fig. 196) into the body-cavity, whence they pass into oviducts which lead to the exterior. In cyclostomes and some bony fishes, the eggs pass out through abdominal pores. In other bony fishes, the ovary is hollow

and eggs are liberated into its lumen and pass out by way of a duct which is an extension of the wall of the ovary.

The genital ducts are usually closely associated with the duct system of the kidneys. Exceptional conditions occur in bony fishes.

**Oviparity, Viviparity, Impregnation.** The means whereby ovum and spermatozoon are brought together depends on whether the animal is oviparous or viviparous; also on whether the outer envelopes of the egg can be penetrated by a spermatozoon.

In most oviparous **fishes** the eggs are impregnated after the genital products have been discharged into the water ("external fertilization"). But oviparous sharks and skates produce eggs whose shells are impenetrable by sperm. Therefore copulation must occur and the egg must be reached by the sperm before the shell is deposited. Some sharks, some skates, and a few bony fishes are viviparous; copulation and "internal fertilization" are therefore necessary.

Among **amphibians** there is much diversity. In most frogs and toads impregnation is external. In tailed amphibians (Urodela) it is commonly internal, in oviparous as well as in viviparous species, and in many cases is effected by means of a **spermatophore**, a mass of sperm agglutinated together by a secretion from the cloacal glands of the male. The spermatophore may be introduced into the cloaca of the female or else attached to the external surface of the female. In some cases it is merely discharged, and picked up later by the female.

Most **reptiles** are oviparous, but some lizards and many snakes are viviparous. All **birds** are oviparous. But in all reptiles and birds, the eggshell necessitates copulation and internal impregnation.

Modern **mammals**, except the duckbill and spiny anteater, are viviparous. The two exceptional animals lay eggs of reptilian sort. Therefore in all mammals impregnation must be internal.

In general, eggs which acquire such envelopes as a layer of albumen or a hard shell must be impregnated while in the anterior region of the oviduct and before these external coverings have been deposited. Development begins immediately after fertilization. Therefore, if fertilization has actually occurred, the "egg" which is "laid" by the reptile or bird contains not an ovum but an embryo at an early stage of development.

**Provisions for Protection, Nutrition, and Respiration.** In most **fishes** the eggs are abandoned to the hazards of the environment. Some fishes, especially those of fresh water, arrange crude nests in gravel, sand, or mud. Some fishes guard their eggs. In the sea horse (Fig. 202) and pipefish, the male carries the developing eggs in a brood-pouch on the ventral surface of the body or tail—an arrangement suggestive of the marsupial pouch of a female kangaroo. The



smaller fish eggs, scantily endowed with yolk, develop rapidly and soon become free-living and self-supporting while still very minute. The miniature fish then enters upon a long period concerned mainly with feeding and growth. Eggs containing larger quantities of yolk and, in some cases (e.g., sharks and skates), invested by a protective shell pass through a longer period of development, and the young fish attains relatively large size before it is obliged to obtain food from an external source. The embryo and young of the viviparous fish not only receive maximum protection but may obtain from the mother some food in addition to the initial supply of yolk. In so-called "placental" sharks, the wall of the oviduct develops highly vascular folds or processes, and similar folds arise on the abdominal wall of the embryo. The two sets of projecting structures, maternal and embryonic, become closely approximated, thus providing for diffusion of substances from the blood of one to that of the other.

Among **amphibians** there is, in general, better provision for protection of eggs and young than in fishes. The great majority of them lay the eggs in water—always *fresh* water except in the case of a large toad (*Bufo marinus*) of the American tropics. Nests and guarding of eggs are common. Among frogs and toads occur various peculiar ways of caring for eggs and young. The male of the European "obstetric" toad carries the long strings of eggs wound about his body and legs until the tadpoles emerge. In some cases eggs are carried in the mouth or vocal pouch of the male. In the South American "marsupial" frog, the eggs develop in a capacious pouch formed in the skin on the back of the female. The eggs of the toad *Pipa americana* develop in individual vesicles in the skin on the back of the mother. Viviparity, affording a maximum of protection, occurs in a few amphibians, including representatives of each of the three orders, Urodela, Anura, and Apoda (Gymnophiona).

The amphibian egg, whether laid in the open or enclosed in some protective way, develops rapidly into a highly characteristic **larva**, the tadpole or "polliwog" (Figs. 203, 343), which, with its functional gills and locomotor tail, as well as in many features of internal anatomy, is a distinctly fishlike animal and, if its environment is external water,

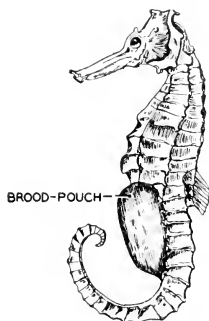


FIG. 202. Sea horse (*Hippocampus*): male, with brood-pouch. (After Boulenger. Courtesy, Neal and Rand: "Chordate Anatomy," Philadelphia, The Blakiston Company.)

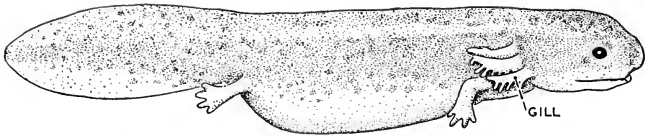


FIG. 203. *Neoturus* larva of about 25 mm. length. (After Eycleshymer. Courtesy, Neal and Rand: "Chordate Anatomy," Philadelphia, The Blakiston Company.)

lives the life of a fish. The larval period, ranging from a few weeks in some salamanders to a year or more in some frogs, is devoted mainly to feeding and growth. It terminates in a metamorphosis, in the course of which the animal acquires the adult characteristics. The transformation is most radical in frogs and toads; legs and lungs develop, tail and gills are absorbed, gill-clefts close, and other changes occur. In certain exceptional species of frog, especially large eggs are laid on land and develop to adult form without passing through a tadpole stage. In the Urodela the changes are less marked, the tail and sometimes also the gills being retained. Adult *Neoturus*, with its tail and functional gills, is sometimes called a "permanent larva." Sexual maturity is ordinarily not attained during the larval state. But the Mexican axolotyl, the larva of the salamander *Ambystoma tigrinum*, regularly breeds in the larval state.

The diversity of reproductive arrangements in amphibians is in marked contrast to the uniformity which prevails in **reptiles** and **birds**. All oviparous **reptiles**, even those that are aquatic (alligator, turtle), and all **birds**, deposit the eggs on land. The large yolk-mass of the eggs of these animals makes possible a long developmental period during which the young can attain relatively great size. A newly hatched alligator is gigantic compared to a newly hatched salmon. These circumstances, together with the fact that development takes place within a thick shell, make necessary some special provision whereby food derived from the yolk may be made accessible to all parts of the large embryo and an adequate supply of oxygen obtained from some external source—an especially urgent need in warm-blooded birds.

The outstanding feature of the development of the reptile or bird appears when the embryo itself goes about the business of constructing a complex system of membranes so disposed and so equipped with blood-vessels as to serve very efficiently not only for respiration but also for some other and secondary functions.

Early in development, at a time when the main organs are in process of formation (Fig. 239), the outer layer of the embryo, representing the prospective body-wall of the animal, throws up a system of folds which arch over and ultimately enclose the whole of the definitive embryo—

much as if an animal should enwrap itself in a highly exaggerated fold of its own skin. Thus are formed the investing membranes known as the **amnion** and the **chorion** (**serosa**). The amnion is derived from the inner layer of the fold, the chorion from the outer. The amnion does not fit the embryo snugly. The intervening space is occupied by a watery solution whose chemical constitution resembles that of blood—*and also resembles that of sea water*. Thus the embryo during its further development is bathed by a fluid whose chemical nature is compatible with that of the embryonic tissues. Further, immersion of the embryo in watery fluid affords the best possible protection from externally caused mechanical pressures and impacts.

Meanwhile the enormous yolk-mass has been enclosed (Fig. 239) by cellular layers which are prospectively the wall of the digestive tube. Then, from the hinder region of the embryonic digestive tube, a sac bulges out ventrally (Fig. 239) and, like a great and growing hernia, pushes beyond the ventral body-wall. Having thus attained the exterior of the embryo proper, it becomes vastly expanded (by growth) and eventually spreads out so that the greater part of its outer surface is, in conjunction with the chorion, in close relation to an extensive area of the inner surface of the eggshell. This sac is the **allantois**. It becomes highly vascular, its arteries and veins communicating with the main vessels of the embryo. A considerable part of the blood of the embryo is diverted into the allantoic arteries and circulates vigorously through a rich system of small vessels lying close to the inner surface of the shell. The shell is porous. Thus ready interchange of respiratory gases between the blood and the external air is provided for. The allantoic sac serves also as a receptacle for embryonic waste. The ducts from the embryonic kidneys open into the extreme hind end of the digestive tube, whence the fluid excreted by the kidneys readily passes into the cavity of the allantois.

The inner cellular layer (**yolk-sac**: Fig. 239) immediately enclosing the yolk-mass is highly vascular, and its blood-vessels, like those of the allantois, communicate with the main arteries and veins of the embryo. The blood circulating through these **vitelline** vessels picks up dissolved yolk materials which are conveyed to all parts of the embryo, thus making the yolk available everywhere for metabolism and growth.

In viviparous reptiles, the amnion, the allantois with its vascular system, and the yolk-sac circulation are developed as in the embryos of oviparous reptiles. The oxygen obtained by the allantoic vessels, however, must be derived from the maternal blood in the wall of the oviduct.

In reptiles and birds, building of nests and parental care of young are much more prevalent than in fishes and amphibians, reaching high

specialization and efficiency in birds. Correlated with the greatly increased protection afforded during development, relatively few eggs are produced.

**Primitive mammals**, as indicated by such surviving examples as the duckbill and the spiny anteater, must have retained reptilian methods of reproduction. The duckbill, a burrowing animal, deposits the eggs (usually two) in the burrow. The anteater, producing usually only one egg in a season, places the egg in a fold of abdominal skin, a temporary **marsupium**, where it is carried and incubated by the warmth of the body until the young hatches. The embryos of these two mammals develop amnion, chorion, allantois, and allantoic and yolk-sac circulations essentially as do reptiles. The one new thing which these animals do is to provide the young with a convenient source of food to serve for a time immediately after hatching. Milk, produced by mammary glands (see Fig. 417) developed in and by the abdominal skin, serves to prolong the period of dependence on maternal food.

All known **existing mammals** except the duckbill and spiny anteater are viviparous. The minute eggs contain so little yolk that they could never pass beyond the very early stages of development unless additional food material were somehow provided. In the great majority of mammals this is done by means of an organ which is one of the most characteristic features of a mammal. The egg, liberated from the ovary and fertilized, becomes caught and lodged in the superficial tissue of the uterine wall. Here it passes into the early phases of development and very shortly gives rise to an amnion, a chorion, and an allantois, essentially similar to those structures as developed in reptiles and birds. Curiously, in spite of the absence of any considerable amount of yolk, a yolk-sac is formed although devoid of yolk. This is usually interpreted as a relic of reptilian ancestors. The allantoic sac becomes greatly expanded, more or less wrapping itself around the embryo, and certain regions of it fuse with the adjacent chorion and enter into a very peculiar relation to the uterine wall (Fig. 241). From the conjoined allantoic and chorionic membranes grow out slender extensions (**villi**) which penetrate more or less deeply into the adjacent uterine wall. They may become more or less branched. These villi are highly vascular, fetal blood circulating in them under the drive of the fetal heart. The surrounding uterine tissue is likewise highly vascular. There is, however, no open communication between the blood-vessels of the villi and those of the uterine wall. But the fetal and maternal vessels are so close together that materials readily diffuse from one blood to the other. Dissolved food-substances and oxygen pass from the maternal to the fetal blood; waste materials and certain special fetal

substances of hormone nature pass from the fetal to the maternal blood. By means of this **placenta**, intervening between mother and young, the nutrition and respiration of the young animal are provided for through the usually long period of intrauterine development.

Mammals show many variations in the mode of origin and details of structure of the placenta. The **marsupial mammals** (**Metatheria**—the kangaroo and its allies) produce only a weakly developed and briefly temporary placenta or none at all. Accordingly, the development of the young cannot proceed beyond what is made possible by the initial small yolk supply plus what nutritive material may be absorbed by the embryo and its investing membranes directly from the neighboring uterine tissues and fluids. The young marsupial is, therefore, necessarily born at an early fetal stage and while very small. The deficiency of the intrauterine arrangements is compensated for by the **marsupium**, a pouch formed by a fold of abdominal skin. The mammary glands are within this pouch. The very immature and quite helpless newborn young (in the great kangaroo, *Macropus major*, being only about 1 inch long) is transferred to the marsupium by the mother. The young becomes attached to one of the mammary nipples and feeds passively, the milk being pumped in by contraction of muscle about the mammary gland. This "mammary fetus" inhabits the marsupium for a time which is usually much longer than its period of intrauterine development. For example, in the great kangaroo the period of intrauterine gestation is between five and six weeks, but the young kangaroo is carried in the pouch and nourished by mammary glands for about eight months.

In **placental mammals**, as compared to marsupials, the young are born at a relatively advanced stage of development and growth. The mammary organs, however, are in all cases an important postnatal provision for bringing the young animal along to a degree of size and strength favorable to ultimate success. They afford the great advantage, too, that the young animal is not thrown upon the world abruptly, but may acquire independence gradually.

#### EVOLUTIONARY SIGNIFICANCE

Surveying the whole group of vertebrates, the great diversity in the conditions and arrangements attending reproduction is most impressive. It would be difficult to imagine any practicable reproductive expedient or condition which is not exhibited by some animal. There are microscopic eggs and there are ostrich eggs. The quantity of yolk may be vast or it may be next to nothing. The primary food supply, yolk, may in various ways be supplemented by secondary sources of nutriment—egg albumen, maternal blood, mammary milk, pigeon

"milk." One egg or millions of them may be produced at a time. They may or may not have shells. Parental care of eggs or young ranges from nothing to the human maximum. Vertebrates may be oviparous or viviparous. A primary oviparity may be succeeded by a secondary substitute for viviparity, as when eggs develop within a fish's mouth, an amphibian vocal sac, or integumentary pouches of various sorts. Differentiation of organs may precede growth or it may be delayed until the embryo is relatively large. The newly hatched larva of so large a fish as the Atlantic salmon is about 0.65 inch long; a newborn whalebone whale is about 20 feet long. The embryo may develop directly to the adult form or there may be a larval period terminated by a metamorphosis. The embryo may or may not produce a complex set of temporarily functional membranes—amnion, chorion, allantois.

The important point to be appreciated is that the association together of any two or more of these various alternatives in a single animal is not haphazard. If one circumstance is, in itself, inadequate for the success of reproduction, it is supplemented by something else. If a large fish were to produce one single microscopic egg annually and deposit it anywhere in the Pacific Ocean, the species would soon become extinct. On the other hand, there is no unnecessary duplication of highly specialized arrangements. A placental mammal does not produce a large yolky egg. The entire complex of reproductive conditions occurring in any one animal comprises a consistent grouping of such alternatives as make it, as a whole, adequate. Despite the great differences in methods of reproduction, the net results are equally good, or nearly so, and generation after generation the life of the world goes on with at most only very slow change in the general biologic balance and scheme of things.

Fishes and amphibians show this reproductive diversity most markedly. Assuming a genetic series from fish to bird and mammal, the evolution of reproduction has not been a direct progress along one straight and narrow path. Instead, the animals within each class, especially the lower, have tried (so to speak) a variety of methods. From the many reproductive "experiments" of the lower vertebrates finally emerge two distinct types to which the higher vertebrates adhere fairly closely. Reptiles and birds exhibit one of these types, mammals the other. Yet certain distinctive features of these finally emergent types of reproduction are anticipated by some lower vertebrates. The enormous eggs of oviparous sharks and skates, encased in thick shells, resemble eggs of reptiles. Some viviparous sharks produce vascular uterine structures (see p. 239) suggestive of the mammalian placenta. Certain viviparous lizards (genus *Seps*) develop what is practically a placenta. But there can hardly be any direct genetic

connection between these structures in sharks and the somewhat similar structures in reptiles or mammals, nor between the "placenta" of a lizard and that of a higher mammal. The exaggerated filamentous gills of the intrauterine larvae of some viviparous salamanders and the much-expanded, bell-shaped gills of the larvae of the "marsupial" frog, *Gastrotheca*, suggest that the larva may obtain nutriment as well as oxygen from neighboring maternal sources—practically a "branchial placenta."

Viviparity is commonly thought of as something peculiarly mammalian. Yet there are viviparous fishes, amphibians, and reptiles. Viviparity in fishes is certainly a secondary rather than a primitive condition. This is attested by the fact, among others, that in some viviparous sharks the large egg is encased in a shell whose vestigial character is indicated not only by the extreme thinness and delicacy of the shell but by its possession of filamentous extensions which correspond to the curling "tendrils" (Fig. 198) whereby the deposited eggs of other sharks are attached to external objects. Similar evidence indicates that viviparity has been secondarily acquired by some amphibians and reptiles. The only vertebrate class which contains no viviparous members is Aves.

In view of the fact that all birds and the most primitive mammals that we know are oviparous, and the further fact that oviparity predominates among the lower classes of vertebrates, it is highly probable that the earliest vertebrates were oviparous and that the animals which constituted the main trunk of the vertebrate genealogic tree were oviparous. But viviparity has appeared on twigs of various lower branches of the tree as well as at its mammalian top.

The marsupial structures of vertebrates afford another example of **convergence** in evolution—that is, the independent origin of functionally similar but genetically unrelated things. Defining a marsupium as a brood-pouch developed on the external surface of the body-wall, there are marsupial fishes (sea horse; pipefish), marsupial frogs, and marsupial mammals.

The chordate ancestors of vertebrates must have been small animals and presumably produced small eggs with little yolk. It is likely that primitive vertebrates had small eggs and that large yolk-masses have been secondarily acquired. But even within a small group of vertebrates, the yolk content of eggs may be highly variable, being apparently easily susceptible to evolutionary change. In point of size and content of yolk, the vertebrate egg has evidently had many ups and downs.

In spite of the diversity of vertebrate methods of reproduction, an evolutionary trend is clearly to be seen. There is a certain extravagance

about the primitive method—millions of eggs, perhaps, in a season, but only a small percentage of survival. With increase in chance of survival there is reduction in number of eggs produced. This result has the appearance of achieving economy, but there is perhaps room for question as to just how and where the economy comes in. Does it cost a cod any more to produce seven million minute eggs that it costs a viviparous dogfish to bear four or five large “pups”? By either method of reproduction the numerical status of the species may be maintained, and so, as remarked above, the net results of the two methods are equally good.

The evolutionary tendency has been, by introduction of efficient protective, nutritive, and respiratory arrangements, together with parental care, toward the guarantee of the survival of every potential adult. This tendency bifurcates and culminates in two very differently specialized methods, one in birds, the other in mammals. Unquestionably the essential peculiarities of avian and mammalian reproduction were primarily correlated with the necessity of adaptation to the circumstances of living on land and in air. The primitive piscine methods would obviously be impracticable. An aquatic larval stage in the development of a horse or an elephant can hardly be imagined although, developing as it does in the fluid-filled amnion, the terrestrial descendant of ancient aquatic ancestors does spend its early life in a fluid medium. But, as we observe the high degree of specialization and the efficiency of these reproductive methods, we are inclined to feel that they are somehow correlated also with a superior *importance* of the avian and mammalian individual as contrasted with an individual fish or amphibian. The bird and mammal are “higher” vertebrates.

## DEVELOPMENT

### CLEAVAGE AND BLASTULA

Development involves great protoplasmic activity. There must be a building up of new protoplasm, rapid dividing of cells, movement, and change of form. All of this calls for rapid metabolism. Metabolism requires interaction of nuclear material and cytoplasm and exchange of materials between the protoplasm and the external medium. The area of the nuclear membrane and area of the external surface of the cell therefore impose a limit on metabolic rate. Two cells are capable of more rapid metabolism than one cell whose nuclear and cytoplasmic volumes are respectively equal to the combined volumes of the corresponding parts of the two cells, since the limiting membranes of the two cells have greater total area than those of the single cell.

The smallest egg-cells are large compared to most tissue-cells of the



animal to which the egg belongs. The metabolic rate in an egg before fertilization is relatively low. After fertilization the rate increases. Before entering upon a prolonged period of activity at high metabolic rate, the bulky ovum increases its surfaces by dividing into small cells—the process called **cleavage**. The successive divisions of the original egg nucleus are, in fact, accompanied by absolute increase in the quantity of nuclear chromatin, a substance which undoubtedly plays an important part in determining the course of development.

**In Amphioxus.** *Amphioxus* is not literally a vertebrate. But it is a chordate and in many respects obviously primitive. The adult is a slender, fishlike animal about 5 cm. long (Fig. 313). The egg is correspondingly small, about 0.1 mm. in diameter, and contains very little yolk (Fig. 204).

The plane of the first cleavage (Fig. 205) of the egg corresponds to the definitive median (sagittal) plane of the future adult. The two cells resulting from the first cleavage therefore represent the right and left halves of the body. The plane of the second cleavage is perpendicular to that of the first, and the third cleavage plane is perpendicular to both the first and second. The second and third cleavages each divide the egg slightly unequally. Further cleavages follow one another in rapid succession, their planes adhering to a fairly rigidly determined order. Meanwhile the cells gradually shift their relative positions and surfaces of contact in such a way that a space opens out at the center of the whole mass. At the 32-cell stage, the cells are disposed to form a hollow sphere whose wall is everywhere one cell in thickness. Thus every cell of the 32 is in direct relation to the exterior, a most favorable position for respiration and excretion. This hollow spheric shape is retained as cleavage continues (Fig. 205G–I) until between 200 and 300 cells have been formed. This stage of the embryo is called the “**blastula**.” The name **blastocoele** is applied to the cavity.

The second and third cleavages introduce inequality of size among

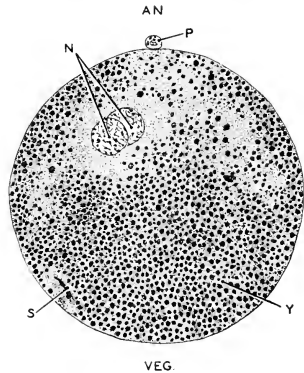


FIG. 204. Median section of a fertilized egg of *Amphioxus*. Diameter of egg about 0.1 mm. (AN.) Animal pole; (N) male and female pronuclei; (P) polar body; (S) remnant of spermatozoon; (VEG.) vegetal pole; (Y) region of cytoplasm occupied by coarse granules of yolk. (After Cerfontaine. Courtesy, Neal and Rand: "Chordate Anatomy," Philadelphia, The Blakiston Company.)

the resulting cells. This inequality persists as cleavage goes on. It is correlated with the distribution of yolk in the protoplasm, the larger cells containing the more yolk. The cells of the blastula grade from minimum size at one pole (**animal**) of the sphere to maximum size at the opposite pole (**vegetal**). This polarity is established in the egg before cleavage begins.

**In Amphibians.** Some amphibian eggs (not including the gelatinous envelope) are about 2 mm. in diameter. Such an egg would possess

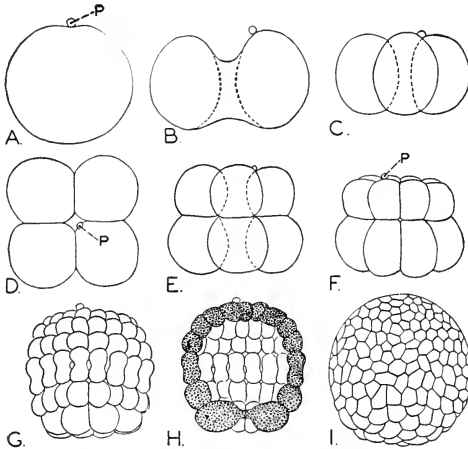


FIG. 205. Cleavage of egg of *Amphioxus*. (A) Undivided egg. (B) In process of first cleavage. (C) Four-cell stage, lateral view. (D) Four-cell stage, polar view. (E) Eight-cell stage, lateral view. (F) Sixteen-cell stage, lateral view. (G) Eighty-eight cells, lateral view. (H) Same stage as (G), median section. (I) Later stage, lateral view. (P) Polar body. (After Hatschek. Courtesy, Neal and Rand: "Chordate Anatomy," Philadelphia, The Blakiston Company.)

a volume about 8000 times that of an egg of *Amphioxus*. The greater part of the increased bulk is yolk. The egg (Fig. 206) is strongly polarized with reference to the distribution of the yolk in the protoplasm. From the **animal pole**, where yolk is at a minimum, the quantity increases toward the opposite **vegetal pole**, where the maximum occurs.

Yolk is a nonliving, quite inert substance. The active material in development is protoplasm. The developmental behavior of eggs containing much yolk shows quite clearly that the yolk is an impediment

to the free carrying out of developmental operations—just as the necessity of carrying a heavy burden of supplies may impede the progress of a company of explorers.

Figure 207 represents the cleavage stages of a frog's egg. The successive divisions follow the same general order as in *Amphioxus*. Cleavages succeed one another at intervals of about an hour, but the period varies with temperature. The yolk evidently hinders cleavage, especially in the vegetal hemisphere. The second cleavage begins at the animal pole before the first is completed at the vegetal pole. In fact, the third cleavage may begin while both first and second are still incomplete in the region of the vegetal pole. Further, the inequality in size

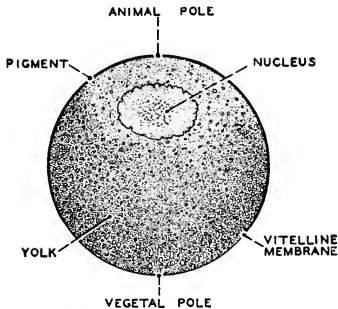


FIG. 206. Ovarian egg of frog; median section. (After Morgan: "The Development of the Frog's Egg." By permission of The Macmillan Company, publishers.)

of cells at animal and vegetal poles is much greater than in *Amphioxus*, another consequence of the greater yolk-mass.

After the third cleavage, a cavity appears in the midst of the group of eight cells. As cleavages proceed, this cavity enlarges and the embryo, as in *Amphioxus*, becomes a hollow sphere or **blastula** (Fig. 207E). Its cavity (**blastocoele**) is excentric, occupying approximately the animal hemisphere only. Its wall is more than one cell thick. The great thickness of the wall of the vegetal hemisphere and the consequent excentricity of the blastocoele are obviously due to the yolk.

**In Reptiles and Birds.** In eggs whose yolk-mass greatly exceeds that of the amphibian egg, all the protoplasm is segregated into a thin plate, the **germ-disk**, lying on the surface of the relatively enormous mass of yolk (Fig. 208). In such an egg, obviously, there is no mechanism for dividing the yolk. Cleavage is confined to the protoplasm of the germ-disk which, following fertilization of its nucleus, splits up rapidly

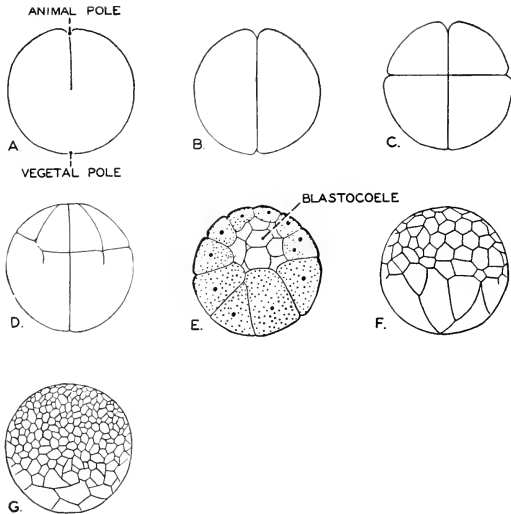


FIG. 207. Cleavage of the frog's egg. (A) First cleavage in process. (B) Two cells. (C) Eight cells. (D) Fourth cleavage complete in animal hemisphere but just beginning in the four cells at the vegetal pole. (E) Early blastula, median section. (F, G) Successively later stages, lateral view. (D, F, G, after Morgan: "The Development of the Frog's Egg." By permission of The Macmillan Company, publishers. E, after Marshall. Courtesy, Neal and Rand: "Chordate Anatomy," Philadelphia, The Blakiston Company.)

and soon consists of hundreds of small cells forming what is then called the **blastoderm** lying as a thin plate of cells on the surface of the yolk (Figs. 208, 209). But there is continuity of blastoderm with yolk only around the periphery of the blastoderm. Elsewhere a thin space, the **subgerminal cavity**, intervenes between blastoderm and yolk (Fig. 209). Comparing this embryo with the blastula stages of *Amphioxus* and frog, it seems reasonable to interpret it as a blastula whose blastocoel is the subgerminal cavity, while its blastoderm is the animal region and the yolk-mass is the vegetal region of the embryo. This recognition of a blastula stage, comparable to that of *Amphioxus*, in the development of a reptile or bird would hardly have been possible but for the intermediate condition exhibited by the amphibian with its moderate yolk-mass and total cleavage.

The blastula is an essentially one-layer stage of the embryo, the "layer" being the wall of the blastula, whether one cell thick or more than one cell thick. This stage has twofold significance. Its immediate

importance is that it gives the embryonic material increased superficial contact with the environment, thus favoring metabolism. Its prospective significance lies in the fact that further development is to consist,

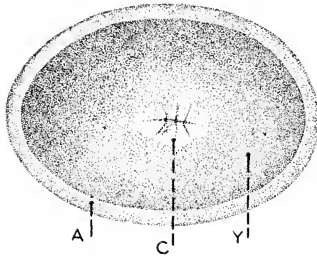


FIG. 208. Cleavage of the germ-disk of the egg of a turtle (*Glyptemys insculpta*); eight-cell stage. The eggshell is not shown. About twice natural size. (A) Albumen; (C) the eight-cell blastoderm; (Y) yolk. (After Louis Agassiz. Courtesy, Neal and Rand: "Chordate Anatomy," Philadelphia, The Blakiston Company.)

to a large extent, in the manipulation of **layers** of embryonic material. The adult is hollow. It has a body-cavity and other cavities. Most of its organs are hollow. The walls of the hollow structures are constituted

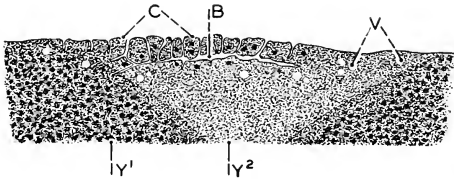


FIG. 209. Early blastoderm of chick; plane of section passes through center of egg. (B) Blastocoele (subgerminal or cleavage cavity); (C) cells of blastoderm; (V) fluid-filled vesicles; (Y<sup>1</sup>) yellow yolk; (Y<sup>2</sup>) white yolk. (Magnified nearly 20 diameters.) (After Duval. Courtesy, Neal and Rand: "Chordate Anatomy," Philadelphia, The Blakiston Company.)

of layers—skin, epithelium, endothelium, peritoneum, muscle layers, connective-tissue layers. For the construction of such a many-layered thing, the embryo naturally proceeds as early as possible to dispose its building material in the form of layers.

## GASTRULA

**In Amphioxus.** The blastula stage is briefly transitory. At once changes set in which transform it to a two-layer embryo. In *Amphioxus* the two-layer **gastrula** form is attained in a very simple way (Fig. 210). The vegetal hemisphere first flattens, then becomes curved inward. The infolding (**invagination**) continues until the material of the original vegetal hemisphere comes into close relation with the inner surface of the wall of the animal hemisphere. The spheric blastula thus becomes an approximately hemispheric embryo whose wall consists of two layers (Fig. 210C), an **ectoderm** and an **endoderm**. As the process goes on, the blastocoele is reduced and finally obliterated. The gastrula is hollow. Its cavity, resulting from the invagination, is the primary digestive cavity or **archenteron**. At first it opens

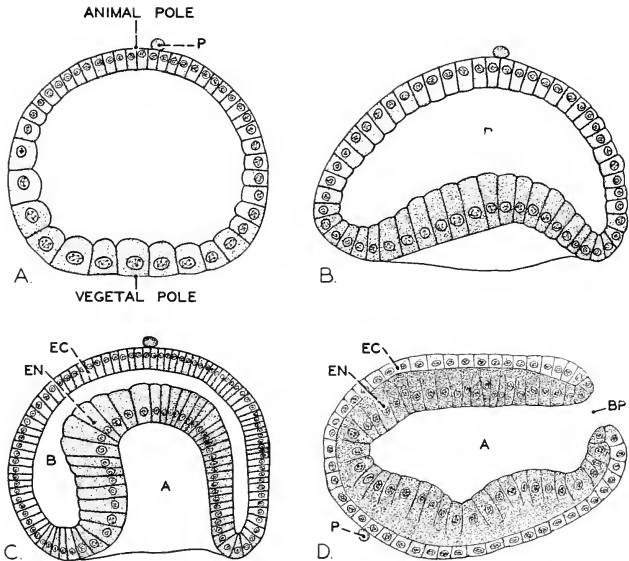


FIG. 210. Gastrulation in *Amphioxus*. The figures represent sections through the polar axis of the embryo. (A) Blastula with vegetal region flattened. (B, C) Earlier and later stages of invagination of vegetal hemisphere. (D) Gastrulation completed; with elongation of the gastrula, its long axis becomes the horizontal anteroposterior axis of the embryo. (A) Archenteron; (B) blastocoele; (BP) blastopore; (EC) ectoderm; (EN) endoderm; (P) polar body. (After Cerfontaine. Courtesy, Neal and Rand: "Chordate Anatomy," Philadelphia, The Blakiston Company.)

widely to the exterior, but the width of the opening is rapidly diminished by inbending of the wall about it and it is soon reduced to a narrow **blastopore**. In consequence of this contraction of the wall around the blastopore, the form of the entire gastrula tends at first to become spheric, but before the contraction is completed the gastrula begins to elongate in the direction of the axis which passes through the blastopore.

An important accessory activity attends this process of narrowing the blastopore. The blastoporal rim is a region of transition from the outer to the inner layer. This region is marked by very rapid proliferation of cells, especially at the dorsal edge of the blastopore (Fig. 210D). Cells produced within this growth zone or **germ-ring** are added, some to the outer layer and some to the inner layer. This growth process, then, is concerned both in the narrowing of the blastopore and in the elongating of the embryo. A direct consequence of it is that the material of a certain region of the inner layer immediately adjoining the blastopore attained its internal position, not as result of the primary invagination, but by the secondary process of growth.

At the close of the gastrula period (Fig. 210D) the embryo is an elongated ovoid, the slightly larger end being anterior while the now very narrow blastopore marks the posterior end of the long axis. So rapid is development that this stage is attained about seven hours after fertilization.

**In Amphibians.** In the amphibian the vegetal wall of the blastula (Fig. 207E-G) is so thick that the vegetal hemisphere is, in effect, solid. It consists of large cells heavily laden with inert yolk. Such a wall cannot readily bend inward as does the corresponding thin and labile layer of the *Amphioxus* blastula.

Three processes going on simultaneously effect gastrulation. The beginning of gastrulation is seen when a crescent-shaped groove (Fig. 211A, I) forms at a certain place on the surface of the blastula. It lies just on the vegetal side of the equator determined by the animal and vegetal poles and extends transversely to the median plane determined by the first cleavage. The equator and a zone extending superficially somewhat into the vegetal hemisphere are marked by especially rapid cell-proliferation. It is in this particularly active region, the **germ-ring**, that the groove appears. Figure 211A' represents a section in the median plane of an embryo at this stage. The groove (I) is the result of an invagination which occurs near where the upper thin wall and lower thick wall of the blastula join. The outer layer bounding the invagination consists of smaller cells which have moved inward from the superficial germ-ring region; the deeper wall of the invagination consists of yolk-cells. The groove, initiated as a slight invagination,

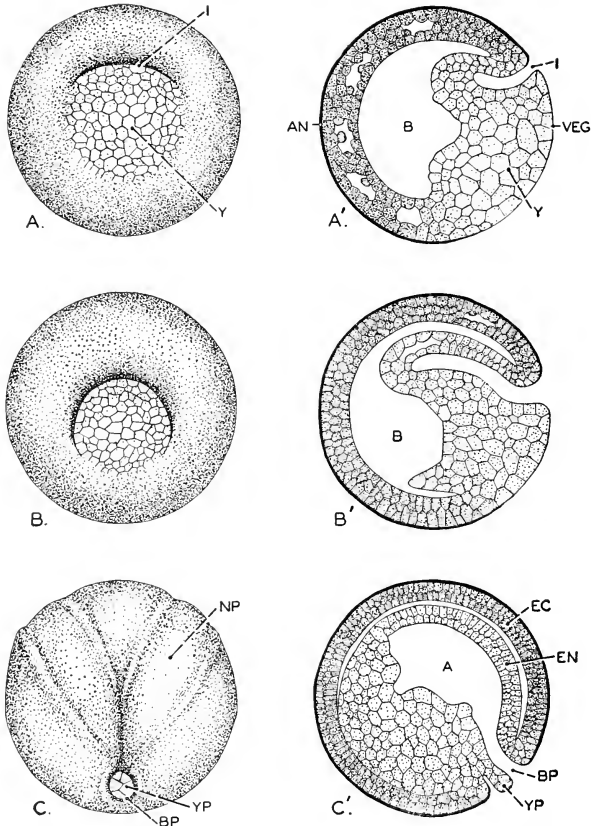


FIG. 211. Gastrulation in the frog. (A, B, C) The whole embryo at successively later stages: viewed toward the vegetal pole. (A', B', C') Represent, in a somewhat diagrammatic way, sections of corresponding stages cut in the plane including the polar axis and bisecting the gastrular invagination. (I); this plane corresponds to the median plane of the adult. During the latter part of the period of gastrulation, as the result of shifting of the heavy yolk (compare B' and C'), the embryo rotates so that the axis passing through the blastopore (BP) becomes horizontal (see Fig. 215A). (A) Archenteron; (AN) animal pole; (B) blastocoel; (BP) blastopore; (EC) ectoderm, (EN) endoderm; (I) invagination; (NP) neural plate; (VEG) vegetal pole; (Y) yolk; (YP) yolk plug. (Courtesy, Neal and Rand: "Chordate Anatomy," Philadelphia, The Blakiston Company.)



rapidly deepens (Fig. 211B-B'), *not by continued invagination*, but by active growth of the upper (for later events prove it to be dorsal) lip of the groove—that is, the lip resulting from the infolding of germing material. This growth process serves to build out the dorsal lip of the original invagination so that the fold is caused to extend farther and farther downward over the yolk-cells. Meanwhile the groove, originally a short crescent, as seen on the surface of the blastula, lengthens laterally or in the direction of the curve of the crescent (Fig. 211B) until it describes a semicircle and, continuing, finally completes a circle. As the groove progressively lengthens, the newly arisen region of its outer fold, continuous with the “dorsal lip” of the initial region of the groove, grows centripetally over the surface of the yolk-cells. Therefore the radius of the curve described by the groove is ever decreasing. The groove is obviously deepest at the region where it began to form and shallower in the successively newer parts of it. Having completed the circle, the centripetal growth of the outer fold of the groove continues until the original vegetal hemisphere is completely covered except for a small aperture, through which bulges a mass of yolk-cells, the so-called **yolk plug** (Fig. 211C-C').

The result of the processes just described is the formation of a new cavity in the embryo. This cavity is bounded externally by the two layers of the overgrowing fold and internally by the yolk-cells. It potentially opens to the exterior but its actual opening is partly blocked by the yolk plug. If no process other than those already mentioned were involved, the cavity would be exceedingly thin. It is, in fact, greatly enlarged by another process. During the progress of the overgrowth of the vegetal hemisphere, the large yolk-cells become extensively rearranged. They move into the blastocoel, finally practically obliterating it. They carry out this movement in such a way that the space left vacant by them is added to the cavity formed by invagination and overgrowth.

Figure 211C' represents a median section of a frog embryo at the close of gastrulation. The embryo is two-layered throughout. The outer layer, **ectoderm**, is uniformly thin. The inner layer, **endoderm**, is very thin over approximately the dorsal half of the embryo but thick in the ventral region, where the greater part of the original mass of yolk-cells persists. The endoderm surrounds a capacious cavity, the **archenteron**, whose external opening, the **blastopore**, is occupied by the **yolk plug**. The blastopore marks the posterior end of the embryo. The greater part of the original yolk is now in the endoderm.

The difference between gastrulation in *Amphioxus* and in the amphibian is essentially this: in *Amphioxus* the vegetal hemisphere (prospective endoderm) of the blastula actively moves into the interior

of the embryo; in the amphibian the eventual interior position of the endoderm material is due mainly to the enclosing of the yolk-mass by overgrowth (**epiboly**) carried out by the fold which was initiated by invagination. In *Amphioxus* the endoderm *goes inside*; in the amphibian it is *put inside* by being covered over. The essential process in formation of the archenteron of *Amphioxus* is invagination. The amphibian archenteron results from interaction of three processes, invagination, epiboly, and re-arrangement of yolk-cells. Quite clearly, the difference is the necessary consequence of the presence of the great mass of inert yolk in the amphibian blastula.

**In Reptiles and Birds.** A reptilian or avian embryo, whose yolk-mass may be millions of times that of *Amphioxus*, could hardly be expected to carry out a process of gastrulation similar to that of *Amphioxus*—if, indeed, anything comparable to gastrulation were to be recognized at all. Yet the original single layer of the blastoderm, formed by cleavage (Figs. 208, 209), must somehow give rise to additional layers. The fact is that the blastoderm does, at an early period, become two-layered. The details of the mode of origin of the second layer differ considerably in various members of the Sauropsida (reptiles and birds). The significant fact is that the deeper layer (endoderm) results, in part if not entirely, from an inward movement of blastoderm cells at the median region of what proves to be the posterior edge of the blastoderm (Fig. 212). This inward movement may consist in the formation of a small pit, an actual invagination, from whose bottom cells move forward and laterally underneath the original blastodermic layer to become the endoderm. In other cases there is merely an inturning of the midposterior edge of the blastoderm without formation of a complete pocket or invagination. In either case the process is confined to the midposterior region of the edge of the blastoderm. The endoderm, thus initiated, rapidly spreads over the yolk-mass and under the original layer, which is now identified as the ectoderm. The growth of the endoderm may be augmented by cells which become detached from the under surface of the outer layer.

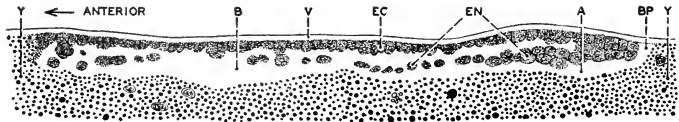


FIG. 212. Gastrulation in the pigeon. Section approximately median, showing formation of endoderm by invagination at posterior edge of blastoderm. (A) Archenteron; (B) blastocoel (cleavage cavity); (BP) blastopore; (EC) ectoderm; (EN) endoderm; (V) vitelline membrane; (Y) yolk. (Magnified about 100 diameters.) (After Patterson. Courtesy, Neal and Rand: "Chordate Anatomy," Philadelphia, The Blakiston Company.)

It is noteworthy that the place of origin of the endoderm in the sauropsidan embryo is always at the posterior edge of the blastoderm. If the primary blastoderm is to be regarded as corresponding to the animal hemisphere and the yolk-mass to the vegetal hemisphere of the amphibian embryo, then the formation of endoderm in the sauropsidan embryo begins at a point which corresponds very closely to the position of the primary gastrular invagination in the amphibian (Fig. 211A', D). This fact, together with later events in the sauropsidan embryo, justifies the application of the term "blastopore" to the aperture of the little invagination or the slit formed by infolding of the hind edge of the blastoderm.

**Comparisons.** Comparison of the early development of *Amphioxus*, amphibian, and reptile or bird compels the conclusion that, were it not for difference in volume of yolk, the several embryos would be practically alike in form, at least through the gastrula stage. It is as if the embryo with the larger yolk-mass "tried" to behave like the embryo of *Amphioxus* but is compelled by the yolk to modify its behavior. *Amphioxus* with total and nearly equal cleavage, the amphibian with total but very unequal cleavage, the reptile or bird with partial cleavage, the several embryos at corresponding stages exhibiting radical differences in the configuration of their materials—yet analysis of the *processes* concerned in the development of all these animals reveals a basic similarity.

The actual animal is the protoplasm. Developmental processes are its dynamic expression. Yolk, although necessary, is mere inert luggage. In all these animals, its composition is essentially the same. The similarities which exist in spite of variation in yolk volume are certainly much more significant than the differences which exist because of variation in yolk volume. The method whereby the embryo of a reptile or bird achieves a two-layered condition is not the simplest imaginable. The easy and direct way would consist in the splitting of the original blastoderm to form two layers, an inner and an outer. Such splitting or "delamination" of layers commonly occurs at other stages in development. The fact that the embryo initiates endoderm formation by invagination or infolding at the posterior edge of the blastoderm is open to no better explanation than that there is some necessity of adhering as closely as possible to the developmental methods employed by amphibians and *Amphioxus*. Such necessity can come only through inheritance.

There is reason to believe that the *Amphioxus* embryo with its nearly minimum encumbrance of yolk reveals, at least in the early stages of development, the primitive and basic processes which, in most other chordates, become more or less obscured by yolk.

## THE THIRD LAYER, MESODERM

The greater extent of the ectoderm of the embryo persists as the essential layer, epidermis, of the adult skin. The endoderm gives rise directly to the lining epithelium of the adult digestive tube. But in the adult animal a great complex of structures—muscle, skeleton, central nervous organs, lungs, liver, and the reproductive, excretory, and circulatory organs, making up the greater part of the bulk and weight of the animal—intervenes between the epidermis and the endodermal digestive epithelium. Some of these intermediate organs take origin directly and independently from the primary ectoderm or endoderm. For example, before the close of the gastrula stage, the central nervous organs begin to differentiate from the dorsal ectoderm. Later, lungs, liver, and pancreas arise as separate localized outgrowths from the endoderm of the early digestive tube. Others of the intermediate organs have an indirect relation to the primary layers of the gastrula. The close of the gastrula stage is marked by the formation of a layer, or system of layers, of embryonic material which comes to be interpolated between the outer and inner layers of the gastrula. This middle and third layer, the **mesoderm**, spreads extensively between the primary layers and at first appears to be quite undifferentiated throughout. Later it undergoes local differentiation to form muscle, skeleton, kidneys, circulatory organs, and various other structures.

**In Amphioxus.** At the close of the gastrula stage, the *Amphioxus* embryo is approximately ovoidal, the long axis anteroposterior with the blastopore at its posterior end. The dorsal surface of the embryo is somewhat flattened. Figure 210D shows a sagittal section of the embryo at this stage. Figure 213A shows a section cutting the embryo transversely and within the anterior third of its length. Except for the dorsal flattening, the configuration of layers is as simple as possible. Parts B–G of Fig. 213 show transverse sections at stages successively later than that of Fig. 213A. Several things are happening simultaneously. A broad band of dorsal ectoderm (NP), slightly thicker than the adjacent regions of the layer, becomes separated, along its right and left edges, from the neighboring ectoderm. This process involves the middorsal ectoderm continuously from the blastopore almost to the anterior end of the embryo. The median ectoderm thus delimited from the lateral ectoderm is the material of the prospective central nervous organ, the **neural tube**. In this initial stage it is called the **neural** (or **medullary**) **plate**.

The dorsal endoderm is at first flattened in conformity with the neural ectoderm, but later (Fig. 213D–F) it becomes convoluted along three lines extending lengthwise of the embryo. Its median, slightly

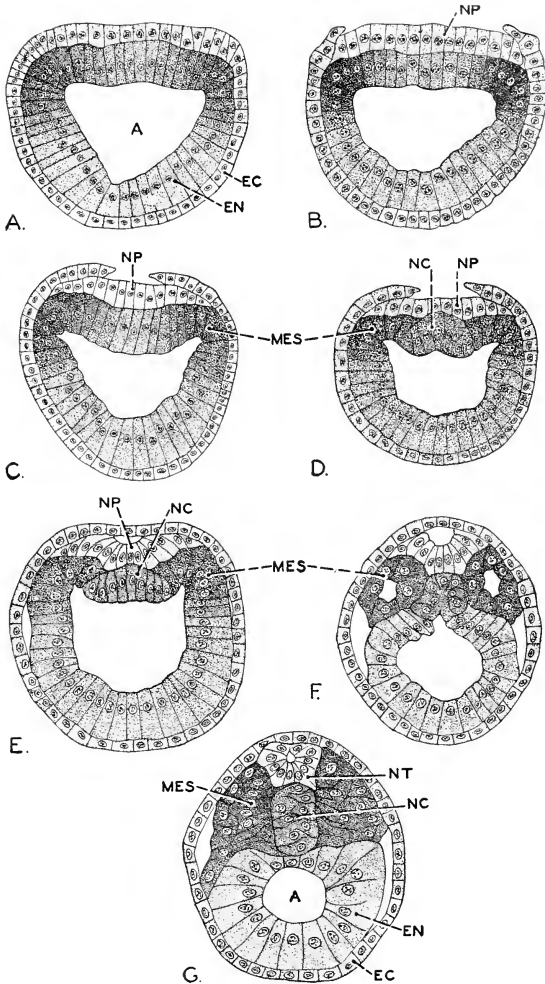


FIG. 213. *Amphioxus*. Transverse sections of embryos at successively later stages, showing origin of notochord, neural tube, and mesoderm. (A) Section somewhat anterior to the middle of the length of an embryo slightly older than that represented in Fig. 210D. (E) From embryo having two pairs of mesodermal pouches. (G) Section near the middle of the length of an embryo having nine pairs of mesodermal pouches. (A) Archenteron; (EC) ectoderm; (EN) endoderm; (MES) mesoderm; (NC) notochord; (NP) neural plate; (NT) neural tube. (After Cerfontaine. Courtesy, Neal and Rand: "Chordate Anatomy," Philadelphia, The Blakiston Company.)

thicker region becomes sharply folded upward. On either side of this median fold, a longitudinal groove appears on the inner surface of the endoderm. Then the endoderm in the region of each of these grooves assumes the form of a fold extending outward dorsolaterally. Thus arise three folds, one median and a lateral pair, all convex outward, and extending nearly the whole length of the embryo. As time goes on, these folds become more emphasized, but soon a difference arises between the median fold and the lateral folds. The median fold remains continuous throughout its entire length. The lateral folds, however, become interrupted by the formation of sharp, deep transverse folds which cut from above downward through each lateral fold. This process of subdivision or **segmentation** begins near the anterior ends of the lateral folds. Its immediate result is a pair of approximately globular pouches lying symmetrically on either side of the median fold, each pouch having a small central cavity opening by a narrow passage into the archenteron. Later this passage is closed and then the pouch becomes detached (Fig. 213F) from the archenteric wall which, at the place where the pouch had formed, closes so that nothing is left to mark the spot.

Immediately behind each pouch of the first pair, another similar pouch forms exactly as the first did. At this stage of development, marked by the presence of two pairs of these pouches, the embryo escapes from the egg membrane ("hatches"). The period between fertilization and hatching varies considerably, its average being probably not far from 12 hours.

These two pairs of pouches derived from the dorsolateral endodermal wall of the archenteron constitute the first definitely delimited mesodermal material. The remainder of the dorsolateral folds, extending back to the blastoporal region, is destined to give rise, after hatching, to additional mesodermal pouches. The median endodermal fold, which has remained intact during this process of segmentation of the lateral folds, is the material of the future **notochord** (Fig. 213, NC).

At the time of hatching, then, the embryo has made important progress beyond the gastrula stage. Not only has the segregation of mesoderm begun but two important organs, the central nerve tube and the notochord, are indicated.

After hatching, additional pairs of mesodermal segments are cut off from the lateral mesodermal folds, the addition taking place progressively from anterior to posterior, until a total of ordinarily 14 pairs have been produced. In several of the more posterior segments, cavities do not occur, the mesodermal folds merely breaking up into a succession of solid blocks of cells (Fig. 213G).

In the formation of these 14 pairs of mesodermal pouches, the

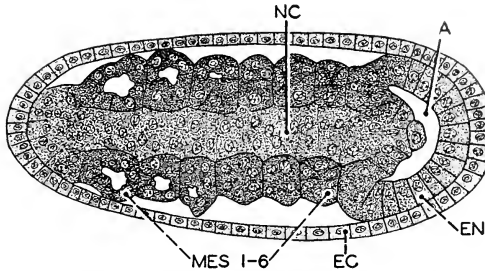


FIG. 214. *Amphioxus*. Frontal (horizontal) section of an embryo having six pairs of mesodermal somites. The section is through the notochord and just below the blastopore. At the posterior end of the section may be seen a region where the notochord, endoderm, and mesoderm merge indistinguishably. (A) Archenteron near the blastopore; (EC) ectoderm; (EN) endoderm; (MES 1-6) mesodermal somites; (NC) notochord. (After Cerfontaine, Courtesy, Neal and Rand: "Chordate Anatomy," Philadelphia, The Blakiston Company.)

material of the original mesodermal folds is completely utilized. Later the series of segments is extended backward by addition of successive solid blocks of cells which become detached from the growth zone (**germ-ring**) encircling the blastopore (Fig. 214). By this means, the number of pairs of mesodermal segments is increased to the adult total, usually 61.

**In Amphibians.** In amphibians, as in *Amphioxus*, the blastoporal rim or **germ-ring** is the all-important source of mesoderm. The amphibian, however, gives little evidence of anything comparable to the paired mesodermal pouches which push out from the dorsolateral endoderm of *Amphioxus*.

During the process of gastrulation in the amphibian, the material destined to become mesoderm lies within the advancing edge of the overgrowing fold (Fig. 211) which is the chief agency in the enclosing of the yolk. As the edge of this fold, the narrowing blastoporal rim, advances, it (in effect) leaves behind it—"behind" being anterior because the fold advances posteriorly—a trail of potential mesoderm which, however, is at first in no way distinguishable from other material destined to be permanently endoderm (Fig. 211C', EN). That is, the two materials together and in no way delimited from one another constitute the deeper layer of the overgrowing fold. Later this layer virtually splits (the process called "delamination") to form two layers, an inner one abutting on the archenteric cavity and an outer one which is then recognizable as a definite mesoderm (Fig. 215B). This layer, although now distinct from the endoderm which parallels it, for a time retains continuity with its source, the proliferating zone about the

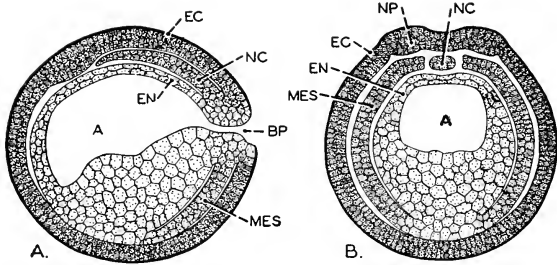


FIG. 215. Sections of an amphibian embryo at an early stage in the development of the notochord and mesoderm. Semidiagrammatic. (A) Median longitudinal section. (B) Transverse section near the middle of the longitudinal axis. (A) Archenteron; (BP) blastopore; (EC) ectoderm; (EN) endoderm; (MES) mesoderm; (NC) notochord; (NP) neural plate. (Courtesy, Neal and Rand: "Chordate Anatomy," Philadelphia, The Blakiston Company.)

blastopore (Fig. 215A). Initiated in this way, the mesoderm extends

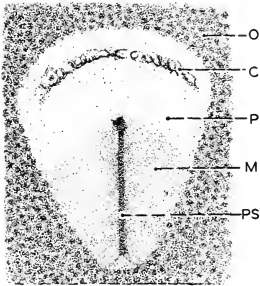


FIG. 216. Surface view of blastoderm of chick after 15 hours' incubation. (C) "Anterior crescent," occasioned by an irregular fold of underlying endoderm; (M) region occupied by mesoderm; (O) area opaca whose opacity is caused by adherence of yolk to the blastoderm; (P) area pellucida—transparent in absence of adhering yolk (see Fig. 212); (PS) primitive streak. ( $\times 14$ .) (After Duval. Courtesy, Neal and Rand: "Chordate Anatomy," Philadelphia, The Blakiston Company.)

into the lateral and anterior regions of the embryo partly by growth within itself, partly by continued contributions from the blastoporal growth zone, and possibly augmented by the detachment of cells from neighboring surfaces of the endoderm.

The mesoderm of *Amphioxus* is segmented at the time of its detachment from the primary gastrular layers, and some of the more anterior segments are hollow. The amphibian mesoderm is primarily unsegmented and solid. In view of the fact that it later acquires segmentation and hollowness, these initial differences are outweighed by the essential similarity in the relations to the blastoporal region.

**In Reptiles and Birds.** In reptiles and birds, endoderm is initiated by a small invagination or infolding at the posterior edge of the early blastoderm (see p. 250). The abortive blastopore thus produced exhibits the usual feature of a blastopore in that, in terms of germ-layers, it is an indifferent region where ectoderm and endoderm merge



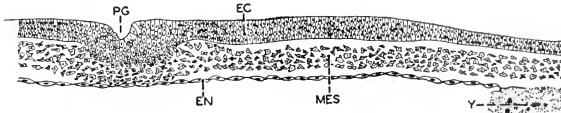


FIG. 217. Section transverse to the primitive streak of a chick embryo of about 15 hours' incubation. The section is taken near the middle of the length of the streak. (EC) Ectoderm; (EN) endoderm; (MES) mesoderm; (PG) primitive groove of primitive streak; (Y) yolk at inner margin of area opaca. ( $\times 100$ .) (After Duval. Courtesy, Neal and Rand: "Chordate Anatomy," Philadelphia, The Blakiston Company.)

together without sharp demarcation (Fig. 212). Following gastrulation, the blastodermal layers continue to spread rapidly over the surface of the yolk. In so doing, the growth posteriorly causes the somewhat thickened region of the blastoporal rim to become drawn out into a long streak, the **primitive streak**, lying in the median line of the blastoderm (Fig. 216). Along the whole extent of this modified blastoporal region, the ectoderm and endoderm merge without sharp demarcation, just as they did in the earlier blastoporal walls (Fig. 217).

This primitive streak is the primary seat of mesoderm formation. Rapid proliferation of cells within the substance of the thickened streak gives rise to masses of cells which move out into the space between ectoderm and endoderm (Fig. 217, MES). These masses of cells increase by continued contribution from the streak and by growth within themselves, and soon become arranged in a layer which rapidly grows laterally and forward from the primitive streak and always in the space between ectoderm and endoderm. This layer, like the early mesoderm of amphibians, is at first unsegmented and devoid of cavity.

In the sauropsidan embryo, then, as in the amphibian, rapid growth and cell proliferation within the blastoporal rim is the primary source of mesoderm.

#### EARLY DEVELOPMENT IN PLACENTAL MAMMALS

The early development of placental mammals exhibits features peculiar to the group and more or less difficult of comparison with anything in the development of lower vertebrates. The minute egg (Fig. 202) contains a bare minimum of yolk. Cleavage is total, more or less unequal, and often very irregular in respect to planes and sizes of cells (Fig. 218A). The cells resulting from cleavage remain in a solid cluster, the **morula**, until as many as 60 or 70 cells are present. Then, as the number increases further, a cavity appears within the morula (Fig. 218B-C). Most of the cells remain in a solid group at one side of the cavity, whose wall elsewhere is only one cell thick. At this stage the embryo looks like a blastula, but further development proves

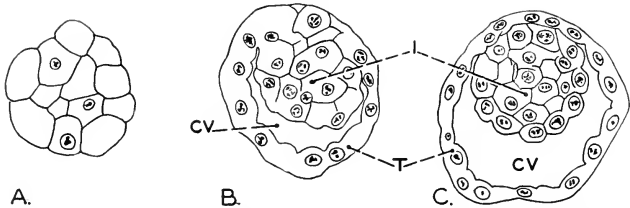


FIG. 218. Early stages in development of a rabbit. (A) Morula stage, 47 hours after coitus. (B) Early blastodermic vesicle, 80 hours. (C) Blastodermic vesicle at 83 hours. The investing layers of the embryo are not shown. (CV) Cavity of blastodermic vesicle; (I) inner cell-mass; (T) trophoblast. (Magnified about 285 diameters.) (After Assheton. Courtesy, Neal and Rand: "Chordate Anatomy," Philadelphia, The Blakiston Company.)

that the stage is not the equivalent of a blastula of a lower vertebrate. The term **blastodermic vesicle** is applied to this stage of the mammalian embryo. The definitive embryo is developed entirely from the thick cell-mass of the vesicle. The thin region (**trophoblast**: Fig. 218, T) of the wall of the vesicle becomes concerned with the early attachment of the embryo to the wall of the uterus.

The fluid-filled cavity of the blastodermic vesicle rapidly enlarges, and meanwhile the thick cell-mass splits off a thin layer adjoining the cavity (Fig. 219). This inner sheet of the thick mass then extends over the inner surface of the thin wall of the vesicle and ordinarily completely lines it. The vesicle as a whole thereby becomes two-layered throughout, a condition which characterizes a gastrula stage. The further history of the two layers identifies them as embryonic ectoderm and endoderm. However, both in mode of origin and in further history, the mammalian embryo at this stage shows perplexing discrepancies as compared to the gastrula of a lower vertebrate.

As stated above, the material which constitutes the definitive embryo is within the thick and solid cell-mass (Fig. 218, I) of the early blastodermic vesicle. As development proceeds, the behavior of this cell-mass is very much like that of the blastoderm of the embryo of a reptile or bird. If the cavity of the vesicle were occupied by yolk instead of by a watery fluid, the whole embryonic complex would resemble closely an early reptilian embryo. The thick cell-mass, lying in relation to the vesicular cavity much as the reptilian blastoderm lies upon the surface of the yolk, flattens and thins out to form the **embryonic shield** (Fig. 220), in the axis of which appears an elongated thickening similar to the primitive streak of a sauropsidan embryo. At the anterior end of this mammalian streak is usually found a small pit or even a perforation extending through the shield into the cavity of

the blastodermic vesicle—very suggestive of an abortive blastopore. It is along the mammalian primitive streak, as in the similar sauropsidan structure, that rapid proliferation of cells produces a mesoderm (Fig. 221) which progressively interpolates itself between the already separated ectoderm and endoderm and spreads eventually into all regions of the embryo. The mesoderm is at first a continuous layer—unsegmented—and devoid of cavity.

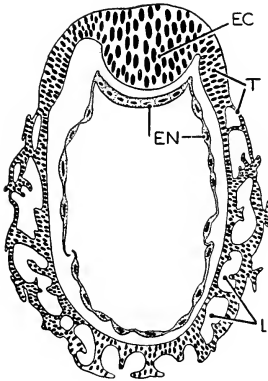


FIG. 219. Early stage of the blastodermic vesicle of the hedgehog. (EC) Ectoderm; (EN) endoderm; (L) lacunas, spaces occupied by maternal blood; (T) trophoblast (trophoderm). (After Hubrecht. Courtesy, Neal and Rand: "Chordate Anatomy," Philadelphia, The Blakiston Company.)

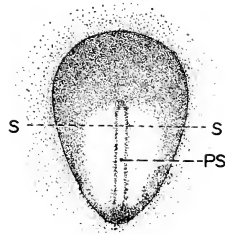


FIG. 220. Embryonic area or "shield" of the blastodermic vesicle of the rabbit after about 172 hours' development. (PS) Primitive streak; (S-S) position of section represented in Fig. 221. (After Assheton. Courtesy, Neal and Rand: "Chordate Anatomy," Philadelphia, The Blakiston Company.)

In a rabbit embryo the embryonic shield is established ordinarily by the fifth day of development, the entire blastodermic vesicle then having a diameter of about 1.5 mm.

The early development of the placental mammal presents many perplexing features. It could be expected that the minute egg, unembarrassed by yolk, would revert to the relatively simple and direct methods of early development which characterize *Amphioxus*. But it does not. Mammalian stages precisely comparable to the blastula and gastrula of *Amphioxus* or amphibians cannot be recognized. When it comes to the formation of mesoderm, the laying out of the germ layers, and the early shaping of the embryo, the behavior of the mammal is closely similar to that of a reptile or bird. This similarity exists in spite

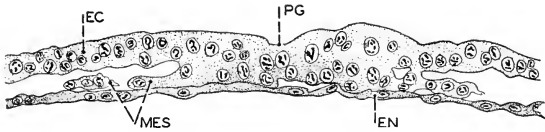


FIG. 221. Transverse section of the embryonic shield of a rabbit at the stage represented in Fig. 220. The section is taken at the position indicated by the line S-S in Fig. 220. (EC) Ectoderm; (EN) endoderm; (MES) mesoderm; (PG) primitive groove of primitive streak. ( $\times 175$ .) (After Assheton. Courtesy, Neal and Rand: "Chordate Anatomy," Philadelphia, The Blakiston Company.)

of the absence of a large yolk-mass in the mammal. These facts point to the conclusion that the developmental behavior of the reptilian embryo had become so strongly established in the protoplasm of ancestral reptiles and primitive mammals that it persisted even though the reduction of yolk had removed the immediate necessity for many of its peculiarities—e.g., the yolk is reduced to a minimum, but a yolk-sac still persists. The many millions of years of primitive mammalian and reptilian lineage constituted a barrier quite impassable by any possible tendency for reversion to the indefinitely more remote developmental methods of primitive *Amphioxus*-like chordates.

Yet some primitive features persist. There can be little doubt that the blastoporal growth-zone or germ-ring of *Amphioxus* and amphibians and the primitive streak of reptiles are genetically continuous. If, as seems very likely, the axial thickening of the mammalian embryonic shield corresponds to the reptilian primitive streak—with even a mammalian relic of a blastopore—then the manner of origin of the mesoderm is essentially similar from primitive chordate to mammal.

Unquestionably the yolk content of the chordate egg is much more readily subject to evolutionary change than is the developmental mechanism of the germinal protoplasm. That mechanism *can* be changed, but there is a high degree of inertia about it. The embryo—i.e., the *living* protoplasmic thing exclusive of inert yolk—is highly conservative. It tends to follow the old methods and it changes only as it must. It adheres to old processes which, under new circumstances, are indirect and unnecessarily complicated.

#### ORGANOGENESIS

The earlier period of development is concerned with laying out the building materials, the embryonic or "germ" layers. In the later and longer period, these layers are shaped into organs. The formation of the central nervous organs and the notochord may begin, however, before the mesoderm is fully established. *Amphioxus*, partly because it is so small and partly because it is in so many respects primitive, affords

what may be regarded as a simplified and diagrammatic view of the early relations of the organs in chordates.

### *Organogenesis in Amphioxus*

In the preceding account of the early development of *Amphioxus*, the embryo has been followed to a stage where the middorsal ectoderm has become delimited from the lateral ectoderm to form the neural plate, the middorsal endoderm has given rise to a sharp, thick upward fold which is the prospective notochord, and paired mesodermal pouches are in process of formation from the dorsal endoderm on either side of the notochordal fold, the pouches increasing in number by addition of new pouches in successively more posterior positions (Figs. 213, 214).

In the course of further development, the thickened ectodermal **neural plate** becomes depressed slightly below the level of the neighboring lateral ectoderm (Fig. 213B-D). Along the line of demarcation between neural plate and lateral ectoderm, separation occurs, following which the lateral ectoderm extends progressively over toward the median plane and external to the neural plate. Eventually the edges of the right and left sheets of ectoderm meet in the median plane and coalesce to form a continuous layer above the neural plate (Fig. 213E). Meanwhile the neural plate transforms itself into a tube by bending its lateral regions upward and inward until the edges meet in the median plane, where they become joined (Fig. 213F-G).

The neural plate originally extends back to the blastopore. The overarching process whereby the neural plate is covered proceeds backward and around the posterior margin of the blastopore. Thus neural plate and blastopore come to lie under a common roof of ectoderm, and the blastopore, no longer opening directly to the exterior, opens into the small space between the neural plate and its newly acquired ectodermal roof. The resulting relation of layers and cavities are shown in Fig. 222, a sagittal section of an embryo at this stage. Upon conversion of the plate into a tube, the blastopore is left in communication with the lumen of the tube. At its anterior end, the closure of the neural tube is delayed so that for a time its lumen is open to the exterior by a small aperture, the **neuropore**. The extraordinary result of these changes is an embryo whose prospective digestive cavity, still devoid of definitive mouth and anus, communicates via the **neurenteric canal** (the former blastopore) with the hind end of the cavity of the prospective spinal cord, and thence to the outside by the anterior neuropore (Fig. 222, P).

These relations, however, are merely temporary. Eventually neuropore and neurenteric canal close. The definitive enteric apertures,

**mouth, gill-clefts, and anus,** arise by very similar processes. At the appropriate locality, enteric endoderm and superficial ectoderm approach one another and coalesce. The resulting double layer then thins out until perforation occurs.

The **notochord,** whose development is initiated by an upward folding of middorsal endoderm (Fig. 213D–F), early becomes detached from the enteric endoderm and acquires its characteristic cylindric form. The enteric endoderm meanwhile closes in beneath the notochord and restores the integrity of the dorsal wall of the enteron (Fig. 213G). As

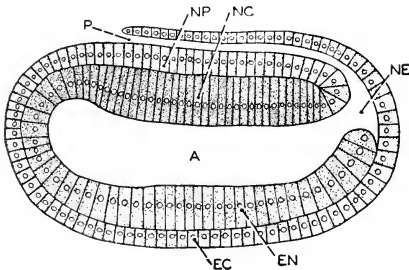


FIG. 222. *Amphioxus*. Median longitudinal section of an embryo having two mesodermal pouches, a stage approximately like that of the transverse section in Fig. 213E. The blastopore, roofed over by ectoderm, has become the neurenteric canal. (A) Archenteron; (EC) ectoderm; (EN) endoderm; (NC) endoderm destined to become notochord; (NE) neurenteric canal; (NP) neural plate; (P) neuropore. ( $\times 350$ .) After Hatschek. Courtesy, Neal and Rand; "Chordate Anatomy," Philadelphia, The Blakiston Company.)

the embryo increases in length, the notochord grows within itself and receives accessions from the active blastoporal region with which its posterior end remains for some time connected (Fig. 214).

The more anterior **mesodermal pouches** (or **somites**), soon after their formation and long before the more posterior somites have been developed, begin to acquire their characteristic differentiation. The pouch expands, especially ventralwards, and its cavity is correspondingly enlarged. That part of its wall lying against the notochord becomes much thickened, while elsewhere the wall remains relatively thin. The expansion of the pouches continues until the walls of right and left pouches meet in the median plane beneath the enteric endoderm. At this stage three regions of the mesoderm may be distinguished: the thickened part lying alongside the notochord, an outer thin layer contiguous to the ectoderm, and an inner thin layer similarly

contiguous to the endoderm. The thick part is destined to form a segment of body-muscle and is therefore called the **myotome** (Fig. 223, M). The outer layer, being, in conjunction with the ectoderm, the body-wall of the embryo, is called the **somatic** or **parietal** layer. The inner layer, associated with the wall of the enteron, is called **visceral** or **splanchnic**. The now capacious cavity resulting from expansion of the pouch is a segment of the embryonic body-cavity or **coelom**.

The myotome rapidly thickens and also increases its dorsoventral extent. As it thickens, the adjacent upper portion of the coelomic space is correspondingly reduced. Eventually the somatic and visceral layers become joined by a horizontal septum formed just below the myotome (Fig. 223). Consequently, a lower major part of the original coelomic space is separated from an upper remnant of it, the **myocoel** (MC), which, with continued expansion of the myotome, is finally obliterated, while only the lower cavity participates in forming the definitive coelom (C). The thin portion of the wall of the myocoel later gives rise to connective tissue including the **myoseptums** (**myocommas**), which intervene between and tie together successive segments of muscle.

As a result of the general expansion of the mesodermal layers, not only, as stated above, are the walls of right and left pouches brought together in the midventral region, but the adjacent walls of successive pouches on the same side of the embryo become closely pressed together. At this stage, then, the paired coelomic spaces of the several pouches are separated from one another by thin partitions, some transverse and others median, each consisting of two layers of cells. These partitions become progressively thinner until they perforate and finally disappear completely except that remnants of the median ventral wall may persist in connection with the development of blood-vessels. With the obliteration of these partitions, the several segmentally developed coelomic cavities are all thrown into free communication to form one large space, the definitive coelom, which finally shows no trace of its segmental origin.

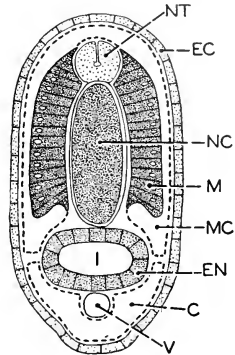


FIG. 223. *Amphioxus*. Transverse section midway of the length of the body of a larva with five gill-clefts. (C) Coelom; (EC) ectoderm; (EN) endoderm; (I) intestine; (M) myotome; (MC) myocoel; (NC) notochord; (NT) neural tube; (V) sub-intestinal vein. (After Hatschek. Courtesy, Neal and Rand; "Chordate Anatomy," Philadelphia, The Blakiston Company.)

Just as the mesodermal pouches arise in sequence from anterior to posterior, their differentiation also proceeds anteroposteriorly. Those of the first pair may have progressed to the point of differentiating muscle while as yet only 10 of the eventual 61 pairs have been definitely formed.

An embryo of *Amphioxus*, at a stage when 14 or 15 pairs of mesodermal pouches are present, is a delicate, colorless, transparent animal having a length of about 1 mm. and a diameter of one-eighth that except at the somewhat enlarged anterior end (Fig. 224). It has a straight digestive tube (enteron, I) extending from an anterior mouth to a posterior anus. There is a single gill-cleft, opening from the right side of the anterior region of the digestive tube. The mouth also is unsymmetric at this stage, opening on the left side. Later, as numerous additional gill-clefts are formed, they shift their positions so as to become ultimately a series of symmetrically placed paired apertures. Meanwhile the mouth shifts from its original left to a median position. Just above the digestive tube lies the median rodlike notochord (NC), extending the entire length of the animal. Immediately above the notochord is the neural tube (NT), its somewhat enlarged anterior region suggesting a brain. At the anterior end of the neural tube, the dorsal neuropore (NP) is still open. The neurenteric canal (NE), at this stage, has ordinarily become closed. In the anterior region, where the differentiation of the mesoderm is most advanced, a coelom intervenes between the enteric tube and the outer body-wall (Fig. 223, C). The body-wall (**somatopleure**) consists of the ectoderm and the somatic layer of mesoderm. The enteric endoderm, together with the contiguous visceral or splanchnic layer of mesoderm, constitutes the wall (**splanchnopleure**) of the digestive tube. The somatic and visceral sheets of mesoderm provide the coelom with a continuous and complete lining, the **peritoneum**. The superficial ectoderm is a skin. The

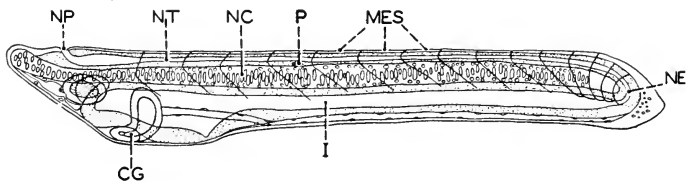


FIG. 224. *Amphioxus* at beginning of larval period; 14 or 15 pairs of mesodermal somites. Actual length of larva about 1.0 mm. (CG) Club-shaped gland; (I) intestine; (MES) mesodermal somites; (NC) notochord; (NE) neurenteric canal; (NP) neuropore; (NT) neural tube; (P) pigment spot in neural tube. (After Hatschek. Courtesy, Neal and Rand: "Chordate Anatomy," Philadelphia, The Blakiston Company.)



more anterior myotomes contain partially differentiated muscle-tissue capable of feeble contraction. The animal is free-swimming but the locomotor mechanism consists merely of long cilia produced by the ectodermal layer.

In its main features, this young *Amphioxus* is like a vertebrate. If its true origin and nature were not known, it might reasonably be expected to proceed to develop directly into a typical vertebrate. But it does not. It acquires no vertebral column; the notochord serves as definitive axial skeleton. It develops no structures morphologically similar to the heart, kidneys, specialized sense organs, or paired appendages of a vertebrate. Further, in later development it acquires, especially in the head region, a variety of unique structures which adapt the adult to its peculiar mode of living but make it conspicuously unlike any adult vertebrate. Nevertheless, *Amphioxus* is "vertebrate" in too many features to make it credible that they could have arisen otherwise than in genetic relationship with those of the vertebrates. Herein, then, lies in part the justification for describing the early development of *Amphioxus* to illustrate the main features of the corresponding stages of vertebrates. Further justification is derived, as already stated, from the fact that the paucity of yolk in the egg of *Amphioxus* relieves the embryo of the factor which introduces varying degrees of complication into the development of vertebrates and occasions much difficulty in the study and interpretation of the processes.

### *Organogenesis in Vertebrates*

In the late embryo of *Amphioxus*, the main lines of the body plan of a vertebrate are drawn. Brief statements concerning the embryonic origin of the major organs of vertebrates follow.

**Neural Tube.** In *Amphioxus* the neural plate becomes detached from the adjacent lateral ectoderm (Fig. 213) and does not transform itself into a tube until after it has been covered by the lateral ectoderm. In vertebrates a longitudinal folding of the neural plate and adjoining ectoderm occurs in such a way that the movement of the neural material into a deep position, its conversion into a tube, and the covering of it by lateral ectoderm take place simultaneously (Fig. 225). Not until the tubular form is attained does the neural ectoderm of vertebrates become detached from the overlying superficial ectoderm. Figure 226 shows, in a diagrammatic way, the characteristic appearance of a recently formed neural tube with its **neural crests**, dorsolateral extensions of ectodermal material on each side of the tube. Later the neural crest becomes detached from the tube, undergoes segmentation corresponding to that of the myotomes, and gives rise to **spinal ganglions** (Fig. 151). Cells of the crest become ganglion-cells, whence grow

out nerve-fibers which constitute the dorsal sensory root of a spinal nerve. The fibers of the other constituent root of a spinal nerve, the ventral motor root, grow out from cells within the neural tube. Some

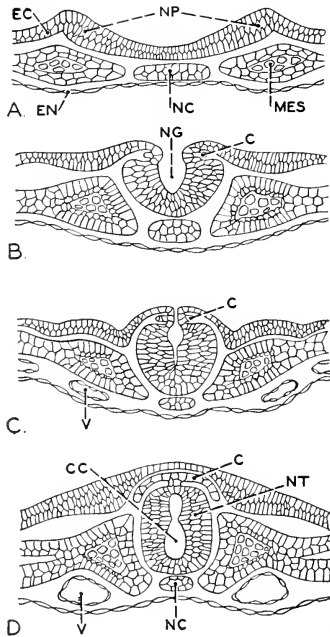


FIG. 225. Diagrams illustrating method of origin of the neural tube of vertebrates. Transverse sections in the mid-trunk region of embryos at successively (A-D) later stages. (c) Neural crest; (cc) canalis centralis of neural tube; (EC) ectoderm; (EN) endoderm; (MES) mesoderm; (NC) notochord; (NG) neural groove; (NP) neural plate; (NT) neural tube; (v) blood-vessel (paired dorsal aorta). (Courtesy, Neal and Rand, "Chordate Anatomy," Philadelphia, The Blakiston Company.)

cells of the neural crests migrate into various visceral localities and give rise to ganglions ("sympathetic": Fig. 157) and nerves of the autonomic system.

The anterior region of the tube expands to form the brain. Three enlargements, the primary brain vesicles—**forebrain**, **midbrain**, and **hindbrain** (Fig. 228)—characterize the cephalic part of the tube in all vertebrate embryos. Later subdivision of the first and third vesicles results in the five brain regions universally characteristic of adult vertebrates. The nervous structures (retina and optic nerve) of the paired eye grow out from the second (numbered from the front) region, but the lens of the eye is derived from

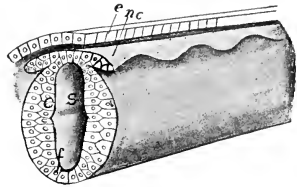


FIG. 226. Stereogram of embryonic neural tube showing the segmenting neural crest. (*e*) Superficial ectoderm; (*nc*) neural crest; (*s*) central canal. (Courtesy, Kingsley: "Comparative Anatomy of Vertebrates," Philadelphia, The Blakiston Company.)

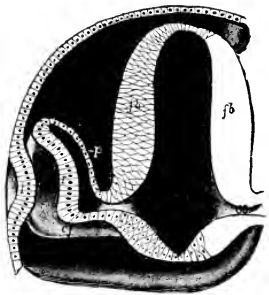


FIG. 227. Stereogram of the developing eye. The head of the embryo is cut transversely in the region of the forebrain. (*cf*) Choroid fissure; (*fb*) wall of forebrain; (*l*) ectodermal thickening which invaginates to form lens; (*oc*) optic cup; (*os*) optic stalk; (*p*) outer thin wall of optic cup, becoming the pigmented epithelium which lies behind the definitive retina; (*r*) inner thick wall of optic cup, becoming the sensory retina of the eye. (Courtesy, Kingsley: "Comparative Anatomy of Vertebrates," Philadelphia, The Blakiston Company.)

neighboring superficial ectoderm (Fig. 227). The receptor (that is, stimulus-receiving) nervous structures of the ear and olfactory organ originate not from the neural tube but from superficial ectoderm.

**Notochord.** The notochord in the several classes of vertebrates exhibits many variations in details of its mode of origin. The essential fact is that, in vertebrates as in *Amphioxus*, its material is derived from middorsal endoderm and from the actively growing region (**germ-ring**) about the blastopore—the primitive streak of reptiles, birds, and mammals being interpreted as a modified blastoporal region. The origin of the notochord is always closely related to that of the mesoderm. In reptiles, birds, and mammals, its material, like that of the mesoderm, usually seems to be derived from the primitive streak (see p. 263), a region where ectoderm and endoderm merge indistinguishably. As cells proliferated from the streak laterally give rise to mesoderm, so proliferation forward from the anterior end of the streak produces a

median cord of cells which form the notochord. It may, however, receive accessions from the endoderm, with which it is usually in close relation.

**Enteron.** Gastrulation produces a two-layer embryo whose endoderm surrounds a cavity opening to the exterior by the blastopore. This **archenteric cavity** is the prospective digestive cavity. As the embryo elongates, the cavity is correspondingly elongated, and in later development the enteric tube increases in length faster than the embryo, with the result that the tube becomes bent or even coiled to adapt itself to the coelomic space.

In the early embryo the ectoderm at a median anteroventral position gives rise to a shallow depression or pit, the **stomodeum**, whose deeper wall meets the forward-growing endoderm to form temporarily a two-layer **oral membrane** (Fig. 228) separating the external stomodeal cavity from the enteric cavity. Soon a perforation appears at the center of the membrane and its peripheral remnant is rapidly obliterated. The perforation and obliteration of the membrane apparently result from progressive centrifugal flow or movement of its cellular substance. Thus is formed the mouth. The posterior enteric aperture or embryonic "anus" usually develops by a similar process. The blastopore rarely persists as a definitive posterior aperture, although it does so in cyclostomes and possibly in some urodele amphibians. Otherwise, exactly as in *Amphioxus*, it becomes roofed over by the neural folds and thus converted temporarily into a **neurenteric canal** (Fig. 228) connecting the hind ends of neural tube and enteric cavity—in reptiles and birds, more or less obscured by the massive yolk. An ectodermal pit, the **proctodeum**, situated just below the neurenteric canal, perforates into the hind end of the enteric cavity to form the definitive hind aperture, either anal or cloacal (Fig. 228). As result of the mode of development of the enteric apertures, the lining of more or less of the mouth cavity is derived from stomodeal ectoderm and that of the posterior region from proctodeal ectoderm. The remaining and by far greater part of the adult enteric tube is lined by endoderm which constitutes the digestive epithelium, the essential secreting and absorbing layer of the tube.

It is a noteworthy fact that various organs which have nothing directly to do with digestion have their origin in the enteric endoderm. The anterior region of the embryonic enteron—the part becoming the **pharynx** of the adult—is concerned particularly with the organs of respiration. Gills of fishes and amphibians develop in relation to paired apertures, the pharyngeal or visceral clefts, which pierce the lateral walls of the enteron and the ectoderm and open to the exterior. A **pharyngeal cleft** is developed as follows: A deep lateral pouch or

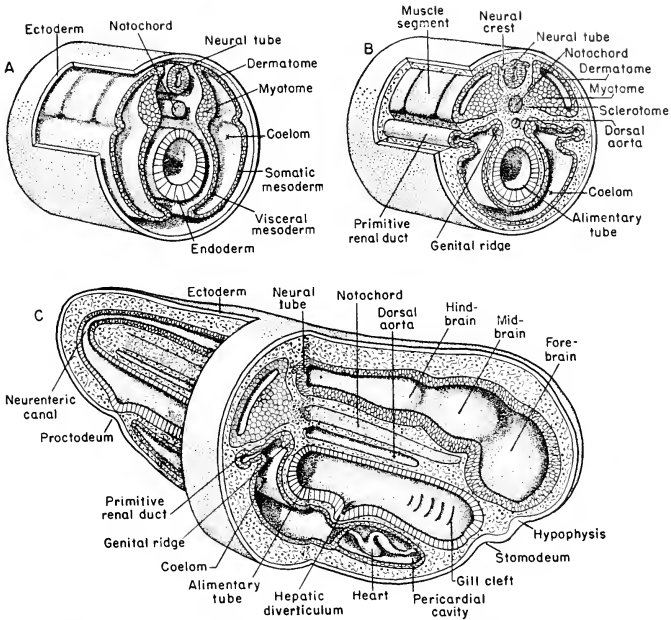


FIG. 228. Stereograms illustrating early stages in the development of a chordate. The figures are generalized, but in some particulars are based on embryonic stages in such "lower" vertebrates as a shark or amphibian. (A) Shows an earlier and (B) a later stage in the differentiation of the mesoderm. In (C) an embryo at about the stage of (B) is represented as cut, except in a narrow midtrunk zone, in sagittal section.

furrow of the endoderm bulges outward and meets a similar but shallower pouch or furrow which the ectoderm pushes inward. The resulting two-layer membrane is then obliterated by the same process which removes the oral membrane, leaving a free passage between the pharynx cavity and the exterior. Vascular complications of the endodermal lining of these clefts produce **internal gills**—although it is possible that some so-called "internal gills" are derived from ingrowing ectoderm. **External gills** are ectodermal structures developed in close relation to the external apertures of pharyngeal clefts. The number of pharyngeal pouches ranges from 14 pairs in some round-mouthed eels (*Myxine*) to four or five pairs of more or less incompletely developed pouches in reptiles, birds, and mammals. Those of the first pair become the **spiracles** of sharklike fishes and appear in a modified way in the

auditory passages of most other vertebrates. The pouches, except those of the first pair, are merely temporary embryonic features in reptiles, birds, and mammals.

**Lungs** develop by outgrowth from the endoderm of the pharynx (Figs. 59, 187). The entire epithelial lining, being the essential respiratory membrane of the adult lung, is endodermal and continuous, by way of the lining of bronchi and trachea, with the lining of the digestive tube.

The **air-bladders** (swim-bladders) of fishes are endodermal sacs which grow out from an anterior region of the embryonic enteron. They are usually dorsal, rarely lateral, or ventral as in the ganoid *Polypterus*.

The important endocrine glands, **thyroid**, **parathyroid**, and **thymus**, and various glandlike bodies, mostly of dubious nature and function, arise as outgrowths of the endoderm of the pharyngeal pouches or the wall of the pharynx (Fig. 189).

More posterior regions of the enteric endoderm give rise to various accessory digestive organs, most important of which are the **liver** and **pancreas**. The liver develops as a midventral outgrowth, sometimes more than one, from the anterior region of the prospective intestinal portion of the enteron. The pancreas arises similarly and in close relation to the liver. Vascular and connective tissues make up a large part of the bulk of the adult organs, but the essential hepatic cells and the secretory tissue of the pancreas are endodermal. The position of the opening of the bile duct into the intestine makes the point of origin of the embryonic liver.

The **cloaca** of the adult vertebrate is a superficial chamber situated at the hind end of the body-cavity and opening ventrally to the exterior. Into it open the intestine and the ducts of the kidneys and genital organs. It is commonly present in vertebrates below mammals except in bony fishes (Teleostei). It is derived from the extreme hind end of the embryonic enteron, although the ectodermal proctodeum may contribute to it. The cloaca of the frog has been described as being wholly proctodeal in origin. Mammalian embryos develop a cloaca, but only those primitive mammals, the duckbill and spiny anteater, retain it as such in the adult. In other mammals the embryonic cloaca becomes divided into a dorsal part connected with the intestine and a ventral part which receives the urinogenital ducts. In the course of further development, these two divisions of the cloaca are separated and carried apart and acquire independent openings to the exterior, the latter being the more ventral. The urinogenital passage and urinary bladder of the adult, both male and female, are a remnant of the cloaca, while another remnant of it persists in the posterior region of the rectum.

**Mesoderm.** The vertebrate mesoderm is at first devoid of segmentation and ordinarily contains no definite cavity (Fig. 215). At an early embryonic stage, the mesoderm upon either side splits into two layers: an outer lying against the ectoderm, and an inner lying against the endoderm. The two layers remain connected, however, at the upper and thicker region of the original sheet (Figs. 228, 229A). At about the same time, this dorsal and thicker zone of the mesoderm develops transverse fissures which divide it into a series of paired blocks (**somites**) lying symmetrically on either side of the neural tube (Figs. 228, 230). This segmentation begins in the anterior part of the embryo and progresses backward just as, in *Amphioxus*, the mesodermal pouches are formed successively from anterior to posterior.

The process of segmentation involves only the upper part of the mesoderm. As segmentation goes on, the space between the lower thin and unsegmented layers on either side becomes wider—a space already recognizable as the **coelom** bounded externally by a **somatopleure** consisting of ectoderm and the outer sheet of mesoderm, and internally by a **splanchnopleure** consisting of endoderm and the adjacent layer of mesoderm. The mesodermal layers upon either side grow down to

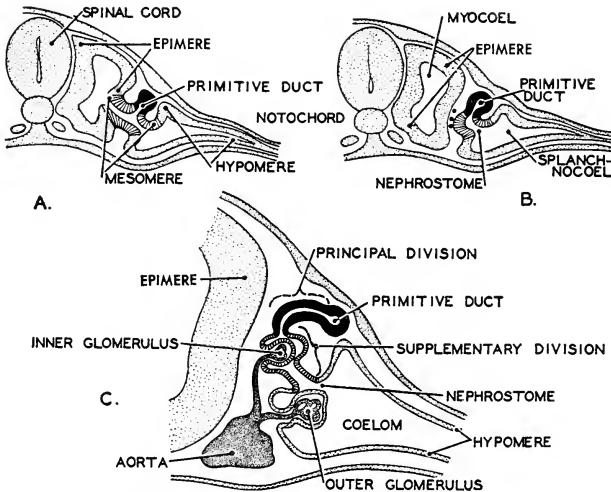


FIG. 229. Diagrams showing the primary differentiation of the embryonic mesoderm, and three stages (A-C) in the development of the primitive renal duct and a pronephric tubule. The duct and each tubule connected with it arise from the mesomere. Two types of glomeruli—outer and inner—become associated with the pronephric tubules. (After Felix, Courtesy, Neal and Rand: "Chordate Anatomy," Philadelphia, The Blakiston Company.)

the midventral region, carrying with them the coelom, and meet mid-ventrally to form a double vertical layer, a ventral **mesentery**, extending from the enteron to the outer body wall and separating right and left coelomic cavities (Fig. 228).

The splitting of the original sheet of mesoderm may extend dorsally so far as to involve the somite, which accordingly contains a more or less definite cavity, the **myocoele**—"myo-" because the somite is mainly muscle-forming. Shortly, the somites become detached from the lower somatic and visceral sheets of mesoderm and the myocoeles lose continuity with the permanent coelom (Figs. 229A, B; 230). Eventually, as the somite differentiates, the myocoele is obliterated.

The differentiation of the vertebrate mesoderm in the prospective trunk region is more elaborate than in *Amphioxus*. Here, upon each side, early arise three zones of differentiation: the **epimeric** zone, a dorsal, mainly muscle-forming, region; the **mesomeric** zone, a kidney-forming zone situated just below the former; and the **hypomeric** zone, the most ventral, constituting the somatic and visceral layers of peritoneum (Figs. 228, 229).

The **epimeric mesoderm** early undergoes a segmentation (already described: p. 277) which breaks it up into a longitudinal series of paired muscle-forming somites or **epimeres**. Each epimere undergoes three kinds of differentiation. Its heavier inner wall is mainly converted into striated body-muscle, not only the dorsal but also the ventral muscle. The muscle-forming material grows ventralwards, pushing its way between the ectoderm and the somatic mesoderm, until it reaches the midventral plane (compare Figs. 230 and 231). The medial region of the epimere gives rise to loosely aggregated cellular masses (**mesenchyme**) surrounding the notochord and neural tube (Figs. 228, 230). This material produces such supporting structures—connective tissue, cartilage, and bone—as may later be developed around these two axial organs. The outer layer of the epimere breaks up to form loose cellular masses, mesenchyme, which give rise to the **dermis**, the deeper fibrous and vascular layer of the skin.

The terms **myotome**, **sclerotome**, and **dermatome** are applied respectively to the muscle-forming, skeleton-forming, and dermis-forming regions of the epimere (Fig. 228).

The **mesomeric mesoderm** gives rise to the tubular structures of the kidneys. In fishes and amphibians, it undergoes a segmentation dividing it into a longitudinal series of **mesomeres**, each adjacent to an epimere (Fig. 229). Since the embryonic coelom extends into the mesomeric zone, each mesomere is hollow. From each of them is formed one primary renal tubule whose cavity is continuous with the coelomic space within the hypomeric zone (Figs. 228, 229). In later



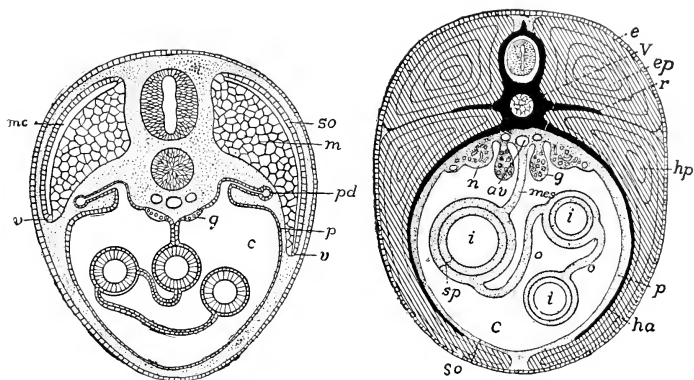


FIG. 230 (Left). Diagrammatic transverse section of the body of a vertebrate embryo at an advanced stage. The muscle-forming myotome is beginning to extend into the ventral body-wall of the embryo. (*c*) Coelom; (*g*) genital ridge; (*m*) muscle derived from myotome; (*mc*) myocoel; (*p*) peritoneum; (*pd*) pronephric duct; (*so*) somatic layer (dermatome) of somite; (*v*) advancing ventral border of myotome. The finely dotted areas are occupied by mesenchyme. (Courtesy, Kingsley: "Comparative Anatomy of Vertebrates," Philadelphia, The Blakiston Company.)

FIG. 231 (Right). Diagrammatic transverse section of the body of a vertebrate. (*av*) Aorta; (*c*) coelom; (*e*) ectoderm; (*ep*) epaxial (dorsal) muscle; (*g*) gonad; (*ha*) hemal rib; (*hp*) hypaxial (ventral) muscle; (*i*) intestine; (*mes*) mesentery; (*n*) kidney (nephridium); (*o*) omentum; (*p*) somatopleure (peritoneum); (*r*) dorsal rib; (*sp*) splanchnopleure; (*V*) centrum of vertebra and, above it, neural arch containing spinal cord. (Courtesy, Kingsley: "Comparative Anatomy of Vertebrates," Philadelphia, The Blakiston Company.)

development of the kidney, the primary tubule may produce branches which become additional renal tubules.

In vertebrates other than fishes and amphibians, the embryonic coelom does not extend into the mesomeric zone and the material of the zone does not become definitely segmented—i.e., no distinct "meres" are formed. The renal tubules develop as solid cords of mesoderm, the cords later hollowing out to become tubules.

The development of renal tubules begins in the more anterior region of the mesomeric zone and progresses posteriorly. Certain differences in mode of development and eventual structure compel the distinction between an earlier and more anterior system of tubules, the **pronephros** (Fig. 229), and a later more posterior and more extensive system, the **mesonephros** (Fig. 80). In fishes and amphibians, the mesonephros becomes the adult kidney and the pronephros disappears except that in a few fishes it is the definitive and only kidney. In all other vertebrates, following development of a pronephros and a mesonephros, the tubule-forming process continues backward, but with

some modifications, to form a third kidney, the **metanephros**, which becomes the adult kidney. The tubular **epididymis**, associated with the testis of the adult amniote, is a part of the embryonic mesonephros which otherwise disappears except for certain vestiges which are apparently of little functional importance.

While the more anterior or **pronephric tubules** are forming, the mesomeric material on each side of the embryo gives rise to a longitudinal tube (Figs. 228, 229) which extends from the pronephric region to the cloaca, into which it finally opens. The pronephric tubules of each side join the corresponding longitudinal **pronephric duct**, thus putting the coelom into communication with the exterior by way of the cloaca. The coelomic openings or **nephrostomes** (Figs. 80, 229) of the pronephros are ciliated. The arrangement apparently serves for drainage from the coelom to the exterior.

The **mesonephric tubules** acquire connection with the already formed longitudinal duct (Fig. 80) which, as the pronephros degenerates, then serves, at least in part, as the **mesonephric** or **Wolffian duct**. In Anamnia each mesonephric tubule usually has a ciliated nephrostome opening into the coelom. In the kidneys of amniotes, nephrostomes rarely appear.

Mesonephric and metanephric tubules usually form specialized excretory structures. The tubule (Figs. 81, 86) gives rise to a cup-shaped expansion (**Bowman's capsule**). The hollow of the cup is occasioned by ingrowth of a dense network of fine blood-vessels, the **glomerulus**. The capsule and glomerulus together constitute a **renal** (or **Malpighian**) **corpuscle**. The part of the tubule between the corpuscle and the mesonephric duct eventually becomes much elongated, coiled, and locally differentiated.

In the absence of nephrostomes, drainage of waste from the coelom does not occur and the function of excretion must be confined to the renal corpuscle, where the glomerulus brings blood-vessels into close relation to the lumen of a kidney tubule, and to other vascular regions of the tubule.

The **metanephros** has outlet by way of a duct, the **ureter**, which develops as a forward-growing branch from the cloacal end of the mesonephric duct of the same side of the embryo (Fig. 82). The tubular structures of the metanephros are formed partly from mesomeric material, but largely by outgrowth from the anterior end of the ureter.

The adult kidney (Fig. 85) consists of the entire system of tubules—mesonephric or metanephric—of one side of the embryo, increased to great number by formation of secondary tubules from the primary tubules, each tubule tremendously elongated and much coiled, the tubules bound together by connective tissue with blood-vessels richly

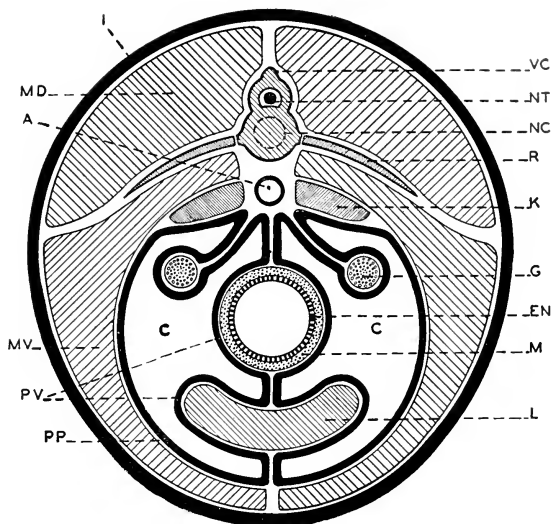


FIG. 232. Diagrammatic transverse section of the body of a vertebrate showing relations of organs to the peritoneum and coelom. (A) Dorsal aorta; (C) coelom; (EN) endodermal epithelium of digestive tube; (G) gonad; (I) integument; (K) kidney; (L) liver; (M) muscle layer of digestive tube; (MD) dorsal muscle of body-wall; (MV) ventral muscle of body-wall; (NC) position of embryonic notochord; (NT) neural tube (spinal cord); (PP) parietal peritoneum; (PV) visceral peritoneum; (R) rib; (VC) vertebral column. (Courtesy, Neal and Rand: "Chordate Anatomy," Philadelphia, The Blakiston Company.)

interspersed, and the whole complex ensheathed by connective tissue and thereby delimited from adjacent tissues of the body-wall.

The **hypomeric mesoderm**, later backed up by a layer of connective tissue, becomes the definitive **peritoneum**. Its somatic layer completely lines the body-wall. Its visceral layer covers the coelomic surfaces of the digestive tube and of all other organs which occupy the coelom. In the median plane at all regions not occupied by median organs (Fig. 228), the right and left visceral layers of the hypomere meet one another to coalesce and become membranes or **mesenteries** which connect and support the viscera. In later stages of development, the mesenteries undergo considerable reduction, especially those between the digestive tube and the ventral body-wall (Figs. 230, 231). The mesenteries not only support the viscera but provide embryonic bridges across which nerves and blood-vessels pass from body-wall to viscera, or ducts (e.g., the bile-duct) which traverse coelomic space between one organ and another. An adult blood-vessel may appear to

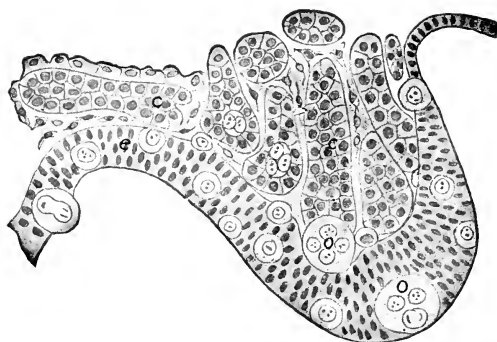


FIG. 233. Section of genital ridge of a chick of five days' incubation. (c) Genital cords; (e) peritoneal epithelium of ridge; (o) primordial germ-cells. (After Semon. Courtesy, Kingsley: "Comparative Anatomy of Vertebrates," Philadelphia, The Blakiston Company.)

extend across coelomic space freely and without support, but it is always encased in peritoneum left surrounding it after the adjacent region of mesentery degenerated. The embryonic mesenteries provide a scaffolding, necessary during the period of construction, but to a large extent removed after the work is finished. Figure 232 shows the ideal relations of the **peritoneum** and **mesenteries** to the coelomic organs. It is clear that no organ can be said to lie in the coelom except as the peritoneum investing that organ is regarded as a part of the organ. In a strict sense, median organs lie *between* the peritoneal sheets of the right and left halves of the body.

The peritoneum plays a part in the development of the **gonads**, although it is not necessarily the source of the germ-cells. The prospective gonads first appear as longitudinal thickenings or **genital ridges** in the dorsal peritoneum, one on each side and between the dorsal mesentery and the mesonephros (Figs. 230, 231, 233). The earlier belief that the germ-cells are derived from the peritoneal layer has been shaken by evidence that the primordial germ-cells first appear in the middorsal enteric endoderm whence they migrate, via the mesentery, into the genital ridge. The deeper substance of the definitive gonad is derived either from the thickened peritoneum of the genital ridge or, especially in the male, from the mesoderm of the closely adjacent mesonephros. The gonad eventually becomes detached from the body-wall but retains its peritoneal covering, which remains in continuity with the parietal peritoneum forming a supporting membrane, the **mesorchium** for the testis and the **mesovarium** for the ovary (Fig. 232).

The gonads find outlet by way of ducts which arise in relation to the kidneys. The seminiferous tubules of the testis (Fig. 195) acquire connection with the neighboring mesonephric tubules and thereby gain exit by way of the Wolffian duct which therefore, in fishes and amphibians, serves as a urinogenital duct. In other vertebrates the adult male retains, in the **epididymis**, that part of the embryonic mesonephros which provided connection between the testis and the Wolffian duct. With metanephros and ureter serving the urinary function, the Wolffian duct is left as a **vas deferens** or sperm-duct only.

The **oviducts** in elasmobranchs and probably some amphibians arise by longitudinal splitting of the pronephric duct, one portion of it serving thereafter as the mesonephric duct while the other portion (**Müllerian duct**) acquires, by fusion of several pronephric nephrostomes, a wide anterior opening into the coelom in the vicinity of the ovary. In other vertebrates, a Müllerian duct develops as a fold of peritoneum (Fig. 87, *m*) closely parallel to the Wolffian duct but independent of it. The Müllerian duct develops alike for a time in both male and female embryos, but only vestiges of it persist in the adult male.

**Mesenchyme.** Reference has been made (p. 278) to the fact that certain regions of the mesodermal somite, the sclerotome and the dermatome, are the source of cellular material which becomes detached from the somite and aggregates in the spaces between the somite and neighboring organs or layers, where it produces skeletal, connective, and integumentary tissues. This secondary mesoderm ("derm" implying a sheet or layer), being usually not disposed in definite layers, is called **mesenchyme**. But the somite is not the only source of mesenchyme. Quantities of it are produced in most or all regions of the embryo.

Beyond question, most of the mesenchyme comes from the mesoderm. The parietal and visceral layers of the hypomere are a prolific source of it, numerous cells becoming detached from the outer (next to the ectoderm) surface of the parietal layer and from the inner (next to the endoderm) surface of the visceral layer. Also the endoderm contributes to the mesenchyme which accumulates between the enteric wall and the adjacent layers of mesoderm. The ectoderm plays a minor part, but evidence has been found indicating that mesenchyme of ectodermal origin, "mesectoderm," participates in the development of parts of the skeleton of the pharyngeal region.

Mesenchyme spreads from its place of origin and eventually is found in all parts of the embryo. Although late in origin, its importance is by no means secondary. Chief among its derivatives are the following materials and structures.

Fibrous **connective tissue** is omnipresent in the adult vertebrate. It invests, supports, connects, separates, or cushions parts of the body. It penetrates throughout massive organs such as a liver or kidney, binding together their delicate tubules or other constituent parts and serving as a basis for entrance and distribution of blood-vessels. In a modified form, it produces layers or masses of fat.

Every location where **cartilage** or **bone** is destined to develop is occupied by mesenchyme. The deeper parts of the skull, the vertebral column, ribs, sternum, and the skeleton of the paired appendages, are first constructed of cartilage. The entire endoskeleton is permanently

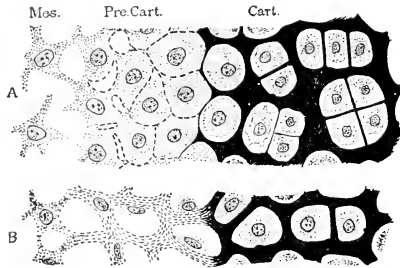


FIG. 234. Diagrams illustrating formation of cartilage by mesenchyme. (A) In fishes, according to Studnicka. (B) In mammals, according to Mall. (Cart.) Cartilage; (Mes.) mesenchyme; (Pre. Cart.) precartilage. (Courtesy, Bremer: "Text-Book of Histology," Philadelphia, The Blakiston Company.)

cartilaginous in elasmobranchs. Cartilage is a direct product of mesenchyme. Cells of the mesenchyme become cartilage cells (Fig. 234) and deposit the ground substance or matrix of the cartilage. A connective-tissue membrane, the **perichondrium**, invests the surface of a cartilage. In the great majority of vertebrates the primary cartilaginous skeletal structures are, in later development, more or less completely replaced by bone. The process of replacement (Fig. 98) involves the destruction of the greater part of the cartilage. The remnants of the cartilage are in the form of a spongy meshwork whose strands become calcified and serve as a framework upon which bone-producing cells, **osteoblasts** (derived from the perichondrium), build up layers (**lamellas**) of bone. Occasionally an osteoblast becomes enclosed in a minute space (**lacuna**) between lamellas and remains as a permanent bone-cell.

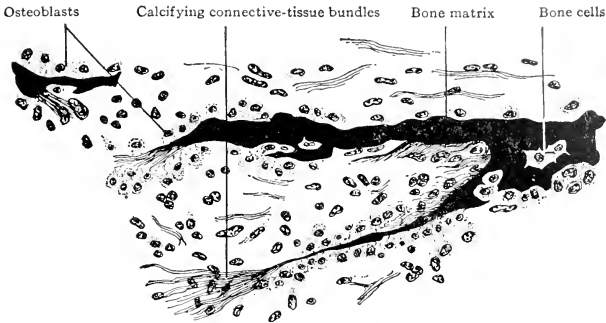


FIG. 235. Development of dermal (secondary) bone from mesenchyme. From a section of the mandible of a human embryo of four months. ( $\times 240$ .) (Modified from Bremer: "Text-Book of Histology." Philadelphia, The Blakiston Company.)

In the development of one of the long bones of an appendage, perichondral osteoblasts deposit a shell of bone (**perichondral bone**) on the external surface of the cartilage. Meanwhile, ingrowing extensions of the perichondrium provide osteoblasts which build up **endo-chondral bone** on the calcified remnants of the cartilage.

In the development of certain of the more superficial bones of the cranium, the outer bones of the jaw skeleton, and some parts of the shoulder girdle, no cartilage is formed. Mesenchyme cells, becoming osteoblasts, build up bone lamellas directly on the surfaces of strands of calcified connective tissue (Fig. 235). Most of the bones which develop in this manner are derived from the embryonic mesenchyme of that same general superficial layer which otherwise gives rise to the dermis of the skin. They are accordingly called **dermal bones**. Certain deep-lying bones (e.g., the clavicle of the shoulder girdle) which develop directly from mesenchyme are called **membrane-bones**. They presumably had phylogenetic origin from dermal bones. Bone resulting from replacement of cartilage is called **cartilage-bone**.

Mesenchyme is the source of nearly all **nonstriated** or "**smooth**" **muscle**, whether in the walls of viscera or in the body-wall. Most visceral organs are hollow. In their early embryonic stages, their primary and essential walls are either endoderm, as in the case of the digestive tube, lung, or urinary bladder, or mesoderm, as in the urinogenital ducts. The outer surfaces of these primary walls are always adjacent to regions occupied by mesenchyme. The nonstriated muscle-fibers of these organs are differentiated from cells of the adjacent mesenchyme. Nonstriated muscle-fibers occur in the walls of larger blood-vessels and of some integumentary glands, where they serve to

expel the contents of the gland. Hairs and feathers are erected by contraction of delicate muscles, usually nonstriated. The dilator fibers in the iris of the human eye, however, are apparently of ectodermal origin.

The statement that **blood-vessels** are derived from mesenchyme is probably admissible although some vessels seem to arise fairly directly from the mesoderm. They may arise as solid cords of cells, later becoming hollow, or may be hollow from the beginning. The essential wall or **endothelium** having been established, the outer layers of connective tissue and nonstriated muscle are provided by adjacent mesenchyme.

The **heart** develops in the region just behind that where the pharyngeal clefts are forming. The right and left hypomeres of the mesoderm push ventralwards, and in the median ventral space between them (Fig. 236) accumulate cells derived from the adjacent hypomeres and, therefore, essentially mesenchymal. These cells arrange themselves to form a very thin layer which becomes the endothelial lining or **endocardium** of the prospective heart. In some cases, at first two endothelial tubes are formed, lying side by side, later coalescing into one. The thick muscular layer (**myocardium**) and the outer layer (**epi-cardium**) of the wall of the heart, also the **pericardium** lining the

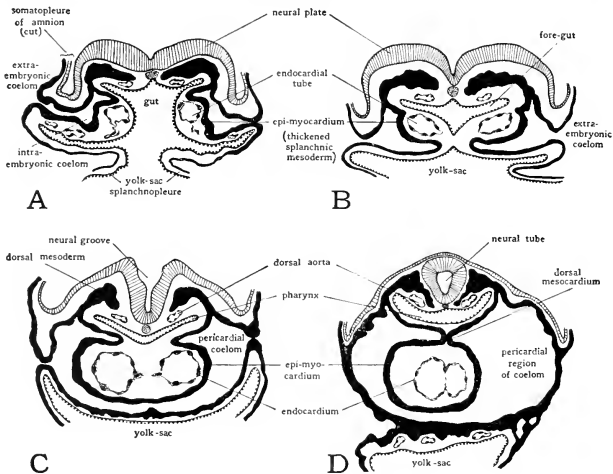


FIG. 236. Sections cut transversely through the cardiac region of pig embryos of various ages to show the origin of the heart from paired primordia. (A) 5-somite embryo. (B) 7-somite embryo. (C) 10-somite embryo. (D) 13-somite embryo. (Projection diagrams  $\times 50$ , from series in the Carnegie Collection.) (Courtesy, Patten: "Embryology of the Pig." Philadelphia, The Blakiston Company.)



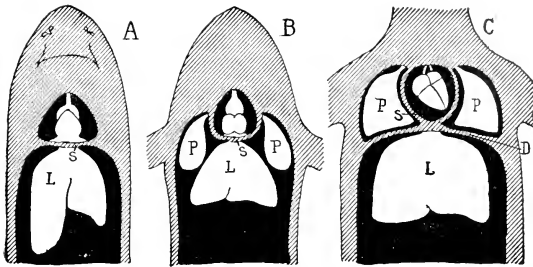


FIG. 237. Diagrams showing the relations of the coelomic cavities (black) in (A) fishes, (B) amphibians and Sauropsida, and (C) mammals. (D) Diaphragm; (L) liver; (P) lungs; (S) septum transversum. In (B) the lungs lie in the peritoneal (or pleuroperitoneal) cavity; in (C) they occupy special pleural subdivisions of the coelom. (Courtesy, Kingsley: "Comparative Anatomy of Vertebrates." Philadelphia, The Blakiston Company.)

pericardial cavity and continuous with the epicardium, are derived from the adjacent hypomeric mesoderm. The heart muscle, however, unlike that of blood-vessels, is striated. The coelomic space at either side of the developing heart remains as the **pericardial cavity**. The pericardium and epicardium correspond to the peritoneum of more posterior regions of the coelom.

The **transverse septum**, separating the pericardial from the abdominal cavity, consists of pericardium in front and peritoneum behind, with connective tissue between. The **diaphragm** of the mammal is not the exact equivalent of the transverse septum of other vertebrates (Fig. 237). That part of the coelomic space lying on the cephalic side of the diaphragm is subdivided into three cavities, the pericardial and the right and left pleural cavity containing the corresponding lobes of the lungs. The diaphragm is muscular. Its muscle is striated and, like body-wall muscle, is derived from epimeric mesoderm. Strangely, however, it is mesoderm which shifts backward from somites of the neck region. This accounts for the innervation of the diaphragm by cervical spinal nerves.

**Head, Neck, Tail.** The mesoderm of the **head** is less definitely segmented than that of the trunk. There is nothing corresponding to the mesomere of trunk mesoderm. The six muscles, consisting of striated fibers, which effect the movements of the eyeball in its orbit are developed from head mesoderm which is probably the equivalent of three somites or epimeres of the trunk.

The **neck** region, whether or not differentiated externally, corresponds approximately to that of the embryonic pharyngeal pouches. In this region the dorsal mesoderm forms epimeres which give rise to

neck muscles. The lateral mesoderm, remaining unsegmented, corresponds to the hypomere of the trunk. Whereas the trunk hypomere ordinarily forms only the **nonstriated** muscle of the digestive tube and other visceral parts, the pharyngeal hypomeric mesoderm produces **striated** muscle which differentiates into an elaborate system of muscles (**branchiomic muscles**) related to the skeleton of the jaws and gill region (Fig. 95).

The **tail** is produced by growth of ectodermal and mesodermal parts backward from the region of the blastopore. Growth of the mesoderm keeps pace with that of the neural tube and notochord. The mesoderm forms somites which produce the segmental striated caudal muscle and the mesenchyme which gives rise to skeletal, vascular, and connective-tissue structures of the tail.

#### *Relation of Yolk to Organogenesis*

Cleavage, gastrulation, and the mode of origin of the mesoderm and notochord are necessarily much affected by the presence of the bulky and inert yolk. Yet, regardless of the quantity of yolk, after the germ-layers have been established the development of organs proceeds in vertebrates of all classes with only minor differences in details of the processes. But the presence of a large mass of yolk does so profoundly affect the general configuration of the early embryo that sections of embryos of amphibian and bird at similar stages and corresponding planes seem to be hardly comparable. Apparently each germ-layer is capable of producing certain structures and no others, and those particular structures arise from that layer in all vertebrates, whether fish or man. Yet at early stages of development the embryonic material may not be so rigidly determined. By appropriate operations at sufficiently early stages of embryos, both vertebrate and invertebrate, it has been proved that a certain region of germ material may be caused to produce structures other than those which it would have produced normally.

Yolk is food. The appropriate place for food is in the enteron. In an amphibian embryo the yolk is contained *within* cells. Gastrulation having established the enteron, the greater part of the embryonic food is then present, not in the enteric cavity but, even better than that, within the cells which constitute the wall of the enteron, where it may be directly acted upon by the endodermal protoplasm and made available, as the blood-system develops, for transportation to all parts of the growing embryo.

The enormous yolk of the egg of a shark, reptile, or bird is morphologically a part of the original ovum. But by the time cleavage of the

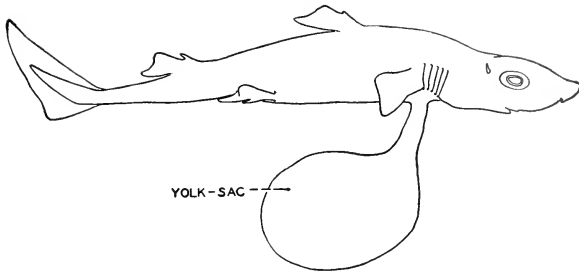


FIG. 238. Young dogfish shortly before birth. The yolk-sac, containing a remnant of the yolk of the egg, protrudes from the ventral body-wall. (Courtesy, Neal and Rand: "Chordate Anatomy," Philadelphia, The Blakiston Company.)

germ-disk has progressed so far as to produce a many-celled blastoderm spreading out thin and flat on the surface of the yolk, the cells of the blastoderm can be regarded as, at most, merely joint proprietors of the food supply, and the yolk has become essentially extracellular. As development proceeds, the blastoderm differentiates into the typical germ-layers, the mesoderm splits to form somatic and visceral sheets with coelomic space between them, and all of these layers progressively spread over and around the nonliving yolk until eventually it is entirely enclosed (Fig. 239) by splanchnopleure and somatopleure with coelom between them. Thus the embryo of these large-yolked animals is put to the necessity of building not only its enteron but also its body-wall around its prospective food.

In the course of development, the yolk is assimilated and utilized in the building of new protoplasm. It therefore steadily decreases in bulk, both relatively and absolutely. As the body of the embryo begins to take form, a constriction involving both somatopleure and splanchnopleure (Fig. 239) appears between the yolk-sac and the remainder of the embryo. The constriction deepens until the embryo presents the appearance of a small animal having a narrow-necked globular sac suspended from the under side of the body (Fig. 238). The amnion is concerned in this constriction (Fig. 239). As the embryo increases in size, the shrinking yolk-sac is drawn up into the body. The inner wall (splanchnopleure) of the sac finally constitutes a small region of the wall of the intestine. In elasmobranchs the somatopleure of the yolk-sac finally flattens out and persists as a part of the abdominal wall. In reptiles and birds, at the time of hatching, the somatopleure is ruptured at the constriction between the definitive body and the extra-embryonic structures and everything external to the rupture is abandoned.

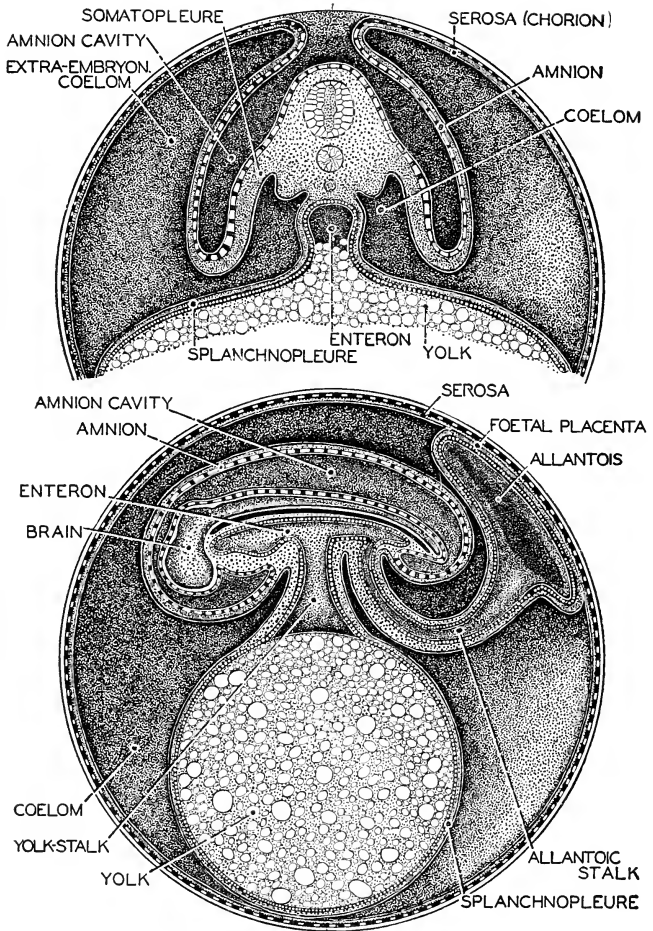


FIG. 239. Diagrams illustrating the development of the amnion and allantois. (Top) Earlier stage; section transverse to long axis of embryo. (Bottom) Later stage; sagittal section of embryo. (After Kingsley. Courtesy, Neal and Rand: "Chordate Anatomy." Philadelphia, The Blakiston Company.)

*Embryonic and Fetal Membranes*

In the description (pp. 240–243) of the reproductive arrangements in vertebrates, a general account of the embryonic membranes, amnion, chorion, and allantois, of reptiles, birds, and mammals was given. The foregoing account of the origin of the germ layers and the shaping up of the embryonic body now makes it possible to appreciate the manner of formation of these membranes in terms of germ-layers.

All eggs are invested by protective coverings which are either produced by the ovum itself or secreted about the egg by the oviduct. Such membranes consist of material which is not cellular and not in any sense living. They have merely passive functions. The amnion, chorion, and allantois are produced by the germ-layers at a relatively advanced stage of the embryo. They are constituted of living cellular material and are actively concerned with such important functions as nutrition, respiration, excretion, and circulation.

The **amnion** and **chorion** are simultaneously produced by an up-rising fold of the somatopleure (ectoderm accompanied by mesoderm)

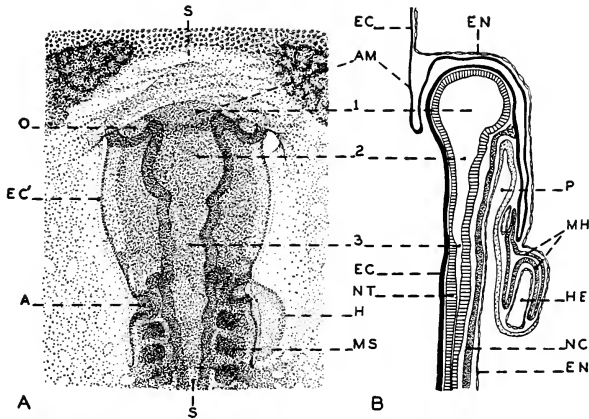


FIG. 240. (A) Dorsal view of the head of a chick embryo after about 33 hours' incubation. The head-fold of the amnion covers a small anterior portion of the embryo's head. ( $\times 32$ .) (B) Section of the head of an embryo at a similar stage, the plane of section indicated by S-S in (A). (A) Auditory invagination of ectoderm; (AM) head-fold of amnion; (EC) ectoderm; (EC') superficial ectoderm of head; (EN) endoderm; (H) heart; (HE) endothelial cavity of heart; (MH) hypomere mesoderm which gives rise to the myocardium, epicardium, and pericardium (see p. 286); (MS) mesodermal somites; (NC) notochord; (NT) neural tube; (O) optic vesicle; (P) pharynx; (1) forebrain; (2) midbrain; (3) hindbrain. (After Duval. Courtesy, Neal and Rand: "Comparative Anatomy," Philadelphia, The Blakiston Company.)

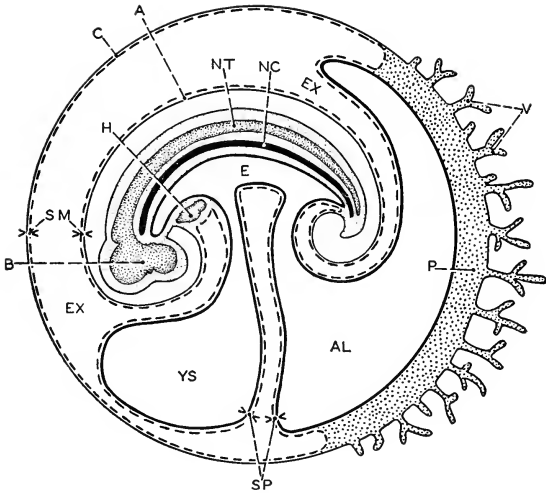


FIG. 241. Diagram of the fetal structures of a mammal. Sagittal section. The broken lines represent mesoderm. (A) Amnion; (AL) cavity of allantois; (B) brain; (C) chorion; (E) enteron; (EX) extra-embryonic coelom; (H) heart; (NC) notochord; (NT) neural tube; (P) placental region of allantois and chorion; (SM) somatopleure; (SP) splanchnopleure; (V) chorionic villi; (YS) cavity of yolk-sac. (Courtesy, Neal and Rand: "Chordate Anatomy," Philadelphia, The Blakiston Company.)

or embryonic body-wall (Figs. 239, 240). The embryo becomes completely surrounded by such a fold, which then grows in centripetally from all directions and finally encloses the embryo. Where opposite edges of the fold meet above the embryo, they coalesce. Reference to Figs. 239 and 241 will serve better than description to make clear the resulting relations of layers and spaces.

The somatopleural folds which give rise to the amnion and chorion are, at the time of their formation, a living part of the embryo. The statement that the folds eventually enclose the embryo anticipates the fact that the amnion and chorion do not become any part of the adult. Therefore "the embryo" which the folds enclose is the definitive body region of the embryo. Everything else is conveniently referred to as extra-embryonic.

The **allantois**, an outgrowth from the hind region of the enteron (Figs. 239, 241), is a product of the splanchnopleure and therefore lined by endoderm. Becoming extensively fused with the chorion, the apposed mesodermal layers of the two membranes develop a rich net-

work of fine blood-vessels which are connected by a pair of **allantoic arteries** and a corresponding pair of **veins** to the main blood-vessels of the embryo.

In reptile and bird, the expanding allantois pushes aside such albumen as may be present, permitting the richly vascular region of the allantois to come into close relation to the inner surface of the porous eggshell, thus providing for exchange of respiratory gases between blood and external medium. The albumen is gradually absorbed by the embryonic tissues. Before the time of hatching, the shrinking yolk-sac is drawn up into the growing body. The **umbilical stalk**—that is, the whole complex of connections between the definitive body of the embryo and the extra-embryonic membranes—becomes narrowly constricted. At the time of hatching, the amnion and the slender neck of the allantois are ruptured at the umbilicus. As the young animal emerges, the amnion and chorion and the extra-embryonic part of the allantois are abandoned. The proximal portion of the allantois, remaining within the body, may, to a greater or lesser extent, persist as a distal region of the urinary bladder of such adult reptiles as possess that organ. In birds, since the adult has no urinary bladder, the proximal remnant of the allantois degenerates.

Among mammals, there is some diversity as to the manner of origin of the amnion and chorion. Once established, however, these membranes possess the same relations to the germ-layers and to the definitive body of the embryo as in reptiles. An abortive yolk-sac is present but devoid of yolk except in the duckbill and spiny anteater, whose manner of development is essentially reptilian.

The main facts concerning the development of a **placenta** by the chorio-allantoic membrane have already been stated (see p. 242). In most mammals the region of conjunction of allantois and chorion becomes thickly beset with slender, more or less branched, highly vascular **villi**. These villi (Fig. 241) may be merely lodged in depressions in the uterine wall or they may pierce more or less deeply into its tissues. In extreme cases (e.g., in man) there is destruction of walls of uterine blood-vessels, and the extravasated blood fills large sinuses in the uterine wall. The villi project into these sinuses so that the villous surfaces are directly bathed by maternal blood, an arrangement providing maximum efficiency in the exchange of materials between fetal and maternal blood.

Mammals exhibit various types of placenta, depending on the distribution of villi in the chorionic surface. When the villi are uniformly distributed over the chorion, as in the horse, pig, and other ungulates, the placenta is called **diffuse**. In most ruminant ungulates, such as cattle, the villi are localized in numerous patches or clusters of varying

sizes—the **cotyledonary** placenta. In carnivores the placenta usually takes the form of a broad band or zone encircling the chorion at a position about midway between head and tail of the fetus—the **zonary** placenta (Fig. 242). A **discoidal** placenta, in which villi are restricted to a single relatively large area of the chorion, occurs in insectivores, bats, rodents, and higher primates, including man.

A fetal placenta whose villi do not penetrate deeply into the uterine wall separates from it readily and without loss of uterine material. Such a placenta, called **nondeciduate**, occurs in most ungulates, in the whale and dugong, and in lemurs. When, however, the fetal villi are deeply embedded in the uterine wall, at time of birth the involved layer of the uterus is split off and discharged with the fetal placenta.

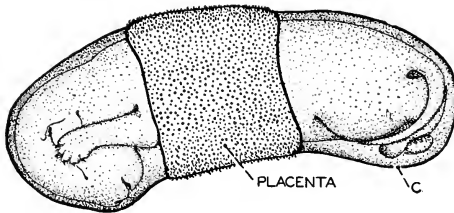


FIG. 242. Fetus of cat, removed from uterus without rupturing chorionic sac (C), showing zonary distribution of placental villi. (Courtesy, Neal and Rand: "Chordate Anatomy," Philadelphia, The Blakiston Company.)

This **deciduate** condition occurs in carnivores, in the elephant, and commonly in animals having a discoidal placenta.

In marsupial mammals the chorio-allantoic membrane forms at most (in the bandicoot, *Perameles*) only a very limited vascular area. Usually there is merely contact of a nonvascular chorion and the uterine wall without villi or other connection. It is a noteworthy fact that in the "Australian cat," *Dasyurus*, the splanchnopleure of the yolk-sac joins the chorion and produces a placenta-like vascular area in relation to the uterine wall. It is possible that in early mammals both yolk-sac and allantois were potentially placenta-forming. In higher primates, the allantoic sac is rudimentary and the fetal portion of the placenta is of chorionic origin only; yet the allantois develops far enough to bring its blood-vessels into connection with the chorionic vessels of the placenta.

The mammalian **umbilical cord** is the much-elongated and attenuated connection between the body of the fetus and the extra-fetal membranes. It contains somatopleure extending from fetal body-wall



to amnion (Fig. 241), and the stalks of the yolk-sac and allantois with their vitelline and allantoic blood-vessels.

At the time of birth, the amnion and chorion are ruptured and the young mammal is expelled, along with the amniotic fluid, by muscular contraction of the uterine walls. The amnion, chorion, extra-fetal part of the allantois, fetal placenta, and more or less uterine tissue in a placenta of the deciduous type are discharged later as the "afterbirth." The umbilical cord is severed. That portion of the allantois remaining within the body undergoes degeneration except that more or less of its proximal region may persist as the distal portion of the urinary bladder.

**Functions of Embryonic and Fetal Membranes.** The **amnion** is protective in mechanical ways. It provides a fluid medium in which the embryo is suspended and protected from deforming pressures. The amniotic mesoderm produces nonstriated muscle-fibers which render the amnion contractile. Its gentle undulations keep the fluid moving, thus preventing local stagnation and possible adhesions of embryonic parts.

The **chorion**, in conjunction with the allantois (rarely the yolk-sac) serves to produce nutritive, respiratory, and excretory membranes.

The **allantois** (in conjunction with the chorion) of reptiles and birds is the respiratory organ. In viviparous reptiles its circulation may pick up some nutriment and oxygen from the uterine wall or fluids. The allantoic cavity is a receptacle for waste from the embryonic kidneys. Its proximal or coelomic portion, after hatching or birth, persists to greater or less extent (varying in different animals) as the distal portion of the urinary bladder of reptiles and mammals. Or, instead of discussing the possible part played by the allantois in forming the urinary bladder, it may come nearer the truth to regard the allantois as merely an exaggerated urinary bladder, developed precociously, and temporarily subserving some vital needs of the embryo.

In mammals the allantois is the essential part of the **placenta**. The placental villi are primarily chorionic, but their vascular structures are derived mainly or entirely from the allantois. In the placenta are concentrated all the vital functions, nutrition, respiration, and, at least in part, excretion.

The vascular splanchnopleural wall of the **yolk-sac** is the essential nutritive membrane in reptiles, birds, and primitive mammals. In some early mammals the yolk-sac may have produced a placenta. In later mammals it is vestigial.

#### SUMMARY AND SOME EVOLUTIONARY IMPLICATIONS

**Cleavage** is a process of mobilizing the agencies within the fertilized egg, always a relatively large cell. Metabolism, necessarily involving

the limiting surfaces of cells, proceeds at a high rate during development. Cleavage increases the ratio of cell-surface to cell-volume and, at the same time, increases the quantity of the essential nuclear material, both absolutely and relatively to the volume of cytoplasm.

In the **blastula** the embryonic material is in the form of a hollow sphere (more or less modified by yolk), a form providing favorable exposure of surface to the external medium, and significant in view of the fact that the adult animal is built up largely by manipulation of *layers* of cells. The blastula cavity is not permanent.

**Gastrulation** transforms the one-layer blastula into a hollow two-layer embryo, the **gastrula**, whose new cavity, produced in the process of gastrulation, is the prospective digestive cavity. This **archenteron** opens externally by the **blastopore**. The **ectoderm**, potentially protective and nervous, provides for relations of animal to environment; the **endoderm** is nutritive. Respiration and excretion may be carried on at all surfaces, as in coelenterates. At the gastrula stage, therefore, a minimum metazoan animal is established.

Ectoderm and endoderm provide the bare necessities of animal life. Addition of a **mesoderm** provides for some luxuries, especially that of being large, powerful, and active. Swift movement of massive bodies requires powerful motors. Muscles are necessarily bulky. The metabolic necessities of cells situated deep in bulky masses of tissue can be met only by a circulatory system which brings them food and oxygen and removes their wastes. The circulating mediums, blood and lymph, must be related to appropriately specialized organs of "intake" (digestive organs, gills, or lungs) and organs of "output" (kidneys). Increase in bulk and complexity calls for mechanical support. There must be tensile connective tissues and rigid supporting structures—skeleton. Mesoderm is the main source of all these organs, which become necessary with increase in size of the animal. There are small animals which have a mesoderm, but there are no very large animals without mesoderm.

Mesoderm produces directly the striated muscle of the body-wall and the essential tubules of kidneys. Indirectly, via mesenchyme (with minor contributions from ectoderm and endoderm), arise circulatory organs, nonstriated muscle of the viscera, connective tissues, and skeleton. The **notochord** is not derived from already formed mesoderm but develops simultaneously with the mesoderm, and the two are closely similar in manner of origin. **Respiratory surfaces** may be provided by either ectoderm or endoderm, or by both. The pharyngeal endoderm is the usual seat of origin of specialized respiratory organs. internal gills and lungs. Ectoderm serves as the respiratory surface in

the epidermis of amphibians and the external gills (larval or permanent) of some fishes and amphibians.

**Significance of Gastrula.** An animal carries on perpetual interchange of materials, nutritive and respiratory, with its environment, and must be able to react to external stimuli in a manner favoring survival. Digestion and absorption of food are best effected at an internal surface. Protective structures and reaction mechanisms must be at, or in close relation to, an external surface. Respiration can be provided for at either an external or an internal surface.

The gastrula is a multicellular animal in its bare essentials. The outer layer, **ectoderm**, gives rise to the essential outer part of the adult skin, which produces so many important protective structures, and to the whole nervous system, both peripheral and central. The inner layer, **endoderm**, is nutritive. The cavity within it is the primary digestive cavity. It is significant that the wall of the archenteron is derived from the vegetal hemisphere of the blastula. Thus, appropriately, the greater quantity of yolk comes to lie in the lining of the embryonic digestive cavity. In the vertebrates the blastopore never becomes mouth and rarely becomes anus. The future motor mechanism, muscle, is derived indirectly from the gastrula layers.

In view of the fact that all vital functions are carried on in an organism so small as to be organized as a single cell, it is conceivable that the minimum multicellular animal might be a gastrula-like thing but with a wall only one cell thick. But, in accord with the principle of specialization or "division of labor," two layers of cells, each layer structurally specialized for its peculiar activities, are functionally more efficient than one layer could be.

The gastrula is strongly suggestive of the two-layer body plan of a coelenterate. A simple coelenterate such as *Hydra*, two-layered throughout, including even the tentacles, can be regarded as a somewhat elaborated gastrula, the *Hydra* "mouth" corresponding to the blastopore (Fig. 285). Contractile fibrous processes are produced by cells of both layers, forming a very thin sheet of tissue, essentially muscular, between ectoderm and endoderm. The gastrula-like form of the coelenterate, together with the fact that a gastrula stage, modified in one way or another, occurs nearly universally in the development of metazoan animals, gave rise to Haeckel's "gastraea" theory, which proposed that gastrula-like animals (essentially coelenterates) must have been the ancestors of all Metazoa. According to this theory, the occurrence of the gastrula form in the ontogeny of a vertebrate is a "repetition" of the coelenterate stage in phylogeny. This may very well be true, but it is not necessary to hold this view in order to account for

the gastrula stage in ontogeny, for some such form as the gastrula is the necessary precursor of any adult metazoan which has a skin (ectoderm) and a digestive tube (endoderm).

**“Determination” in Germ-Layers.** After the germ-layers have been established, the development of organs proceeds with a high degree of uniformity in vertebrates of all classes. It would appear that each germ-layer is rigidly “determined”—capable of producing certain organs and no others. From fish to mammal, brains and the deep-seated autonomic ganglions are ectodermal; livers and lungs are endodermal. Indeed, there is so much evidence of rigid necessity that the germ-layer origin of organs is generally regarded as the safest criterion in judging their phylogenetic relationships. But at early stages of development the embryonic material is not so rigidly “determined.” If one cell of the two-cell cleavage stage of *Amphioxus* or an amphibian is removed, the remaining cell may produce a complete embryo, nearly or quite normal except in size. A large portion of the early blastoderm of a fish egg may be destroyed and yet the surviving fraction will develop into a normal young fish. By appropriate operations at early stages of embryos, both invertebrate and vertebrate, it has been proved that a certain region of germ material may produce structures other than those which it normally produces.

**“Recapitulation.”** Ernst Haeckel in 1874 asserted that “Ontogeny is a brief repetition of Phylogeny.” The embryology of the succeeding three or four decades was inclined to overwork the idea, expecting—and often claiming—to find “repetition” in minute details of ontogeny. Thus the theory was brought into some disrepute.

There are many facts which seem to justify, or even compel, the conclusion that there is a direct relation between the phylogenetic and the ontogenetic order. The notochord is unquestionably the most ancient axial skeleton. It develops in the early embryo of all modern vertebrates. In sharks cartilaginous vertebrae are developed around the notochord. In reptiles, birds, and mammals, the notochord becomes surrounded by cartilaginous vertebral structures which are later replaced by bone. Nowhere else in the body is bone preceded by any such structure or tissue as the notochord. Many bones (dermal) develop directly from mesenchyme. In general, formation of bone is not necessarily dependent on preëxisting cartilage or notochord. Sharks have an all-cartilaginous skull. In reptile, bird, and mammal, the adult skull is nearly all bone. But the embryo develops a cartilaginous skull similar to that of a shark. Later the cartilage is almost wholly replaced by bone and numerous dermal bones are developed superficially to the cartilage. This succession of materials or structures—notochord, cartilage, bone—in higher vertebrates has been generally regarded as an

instance of "recapitulation." Some evidence from paleontology, however, indicates that bone may be more ancient than cartilage and suggests that the cartilaginous skeleton of sharks may have resulted from "degeneration" of an originally bony skeleton.

The pharyngeal region of the mammalian embryo exhibits an apparently good case of "repetition." With its paired visceral pouches, cartilaginous visceral arches, and numerous aortic arches, it is essentially fishlike. During later development the region undergoes a complex metamorphosis, in the course of which some transitory reptilian features appear, especially in the aortic arches. Here, as in numerous other instances (e.g., the succession of kidneys—pro-, meso-, metanephros), the embryo pursues a course of development which is indirect, complex, and laborious, involving breaking down structures already formed and replacing by others, to arrive finally at a condition simpler than that at the start. Such facts are difficult to explain otherwise than as due to some inherited necessity.

It should be emphasized that the embryo repeats, not the adult stage, but an embryonic stage of an ancestor. The mammalian embryo does not have *gill-pouches*; it has *pharyngeal* pouches similar to those which, in a fish, develop into gill-clefts.

Accepting the basic idea of "recapitulation," it must be admitted that the ontogenetic record is incomplete and exhibits many departures from the phylogenetic order. Cartilage is an ancient skeletal material; the amnion is comparatively recent. Yet in a modern embryo the amnion develops long before any cartilage is formed. The record is further confused by the insertion of new ("**cenogenetic**") structures into early stages of an embryo. The amnion and allantois are cenogenetic structures. The notochord of a mammalian embryo is relatively ancient or "**palingenetic**."

The embryo whose development is studied in our laboratory today has had unbroken protoplasmic continuity with ancestors hundreds of millions of years ago. Herein is a material basis for "recapitulation." Nevertheless, it is almost incredible that a substance chemically so active and structurally so delicately complex as protoplasm should so tenaciously retain the impress of structures which, long ages ago, lost all functional significance for the adult animal. Protoplasm, or the organism constituted of it, is a paradox. It exhibits extraordinary capacity for adaptation to new situations and modes of living, along with inability to discard obsolete embryonic processes and structures whose retention more or less complicates and hampers embryonic development. Vestiges of obsolete organs may even persist on into the adult stage, sometimes (e.g., the human vermiform appendix) proving to be even worse than useless.



Animals are constituted of “living substance” or **protoplasm**, together with various nonliving materials which are produced by protoplasm. It is chemically complex and possesses a definite, elaborate, and minute physical structure. Its basic activities as “living” substance are nutrition, respiration, and excretion. For the adequate carrying on of these processes, every particle of protoplasm must be in close relation to an environment containing food and oxygen and providing for removal of wastes. Therefore protoplasm cannot exist in indefinitely large continuous masses. The protoplasm of larger animals is subdivided into minute (usually microscopic) structural and physiologic units, **cells**. Circulation of fluid in **intercellular spaces** provides for the metabolic requirements of the individual cell.

Animals—e.g., most of the Protozoa—may be so small as to be organized as single cells. Attainment of relatively large size along with capacity for powerful movement and diversified activities, compels the differentiation of a high degree of structural complexity. To say that an animal is large because it has many organs and is complex, reverses the truth. Protoplasm is so constituted that a large animal *must be* multicellular, and, if it is also powerful and active, it *must be* complex.

The body of a large animal is locally differentiated for the carrying on of various functions. The specialized regions, more or less definitely delimited from one another and each characterized by a configuration which is consistent with its special function, we call **organs**. These organs, in contrast to the organs of a protozoan, comprise many cells, and the cells of any one organ, so far as they are concerned in carrying on one common function, all exhibit intracellular differentiation of the same kind. Such a group or system of cells, coördinated in one common function and alike in their internal differentiation, constitutes a **tissue**.

An ideally simple organ would consist of only one tissue. As a matter of fact, nearly all organs are concerned with more than one

function. An organ's primary function usually demands certain accessory functions, and a corresponding diversity of tissues enters into the constitution of the organ. In a stomach the primary tissue is the lining layer or digestive epithelium. Muscular, nervous, vascular, and connective tissues play accessory but nevertheless necessary roles. Vascular and connective tissues enter into the constitution of all major organs.

**Anatomy** deals with organs as such. **Histology** concerns itself with the internal and specific structure and organization of tissues. Since the tissue is constituted of cells, histology is necessarily concerned with them. **Cytology**, narrowly defined, deals with cells as such—that is, with that fundamental cell mechanism which is common to all cells and independent of tissue specialization.

Most vital functions involve **the surface between protoplasm and the medium immediately external to it**. Food enters from without. Respiratory gases pass in and out. Waste is expelled from the surface. Special secretions are produced at the surface. External forces impinge upon the surface. Further, most of the organs of the adult animal are hollow. They contain something or they convey something—food, air, blood. Even such organs as the liver and pancreas, upon casual inspection apparently quite solid, are minutely hollow. The hollowness of the vertebrate brain and spinal cord is an incident of their mode of development and not due to any physiologic necessity which could not be provided for otherwise. Muscles, however, are solid. Connective and skeletal tissues may form bulky solid masses—solid, that is, except in so far as they are penetrated by blood vessels. Bone may contain cavities, but these cavities have a merely passive mechanical significance. The occupation of bone cavities by a blood-forming marrow makes advantageous use of what might otherwise be mere waste space in the animal, but this marrow tissue has no direct relation to the skeletal function of the bone. Such nervous organs as brains, ganglions, central nerve-cords, and nerves need not be hollow and ordinarily are not.

Every surface of the animal, whether apposed directly to the external medium or to some internal cavity, is a critical region. It is a surface on one side of which is living substance while on the other side may be food, water, air, blood or something else between which and the protoplasm some vitally necessary activity is being carried on—digestion, respiration, absorption, secretion, excretion, diffusion. Or it may be a surface at which the underlying protoplasm deposits a protective nonliving substance.

Provision for the adequate carrying on of these essential and diverse surface activities can be afforded only by the presence of a superficial membrane constituted of living material and specialized appropriately



for the functional requirements of the particular surface. Consequently, with very rare exceptions, every free surface of an animal, external or internal, is the surface of a more or less specialized cellular layer, an **EPITHELIUM**.

### EPITHELIAL TISSUES

Epithelia are tissues of primary importance. They are, in double sense, the most primitive of tissues. The smaller, simpler coelenterate consists merely of an outer and an inner epithelium. The gastrula of animal embryos consists of two epithelia. Therefore all adult tissues are derived from epithelia. It is evident, then, that epithelium provides for all animal needs. All-epithelial animals may and do exist.

Not only are epithelia the immediate agencies in the necessary interaction between animal and environment, but they tend to prevent invasion by disease-producing organisms, and they seal surfaces against leakage of the omnipresent intercellular fluid (lymph). If human skin is abraded so slightly as not to cause bleeding, a clear, watery lymph exudes. The outer layer of the intact epidermis prevents such leakage.

The outer layer of the vertebrate gastrula, while it is the source of various structures which attain a deeper position, otherwise persists as the **epidermis**, which is the external epithelium of the adult body. The inner layer of the gastrula, giving rise to various organs such as the liver, pancreas, and lungs, which grow outward from the enteron, otherwise persists as the lining of the digestive tube, the **digestive epithelium**, which is the innermost epithelium of the adult body. By far the greater part of the massive adult has been inserted between the two primary layers.

The term **endothelium** is commonly applied to the lining layer of blood-vessels and lymphatics. Lymph-glands are exceptional in that their irregular lymph-filled spaces have no definite endothelial covering. An important function of the deeper tissue of these glands is the liberation of single cells which drift away in the lymph stream as new white blood-cells. An endothelium would hamper this process of shedding cells. In "blood-glands" such as the spleen, the blood-filled spaces are more or less deficient in endothelial lining. The term **mesothelium** may be used for the peritoneal epithelium. Cells may form a layer resembling an epithelium but not abutting upon a cavity. The tissues of some endocrinal glands are of this nature. To such tissues is applied the adjective **epithelioid**.

Epithelia carry on functions of most diverse kinds. The diversity is reflected in the structure of epithelia. Only a few of the more general features of structure can be mentioned here.

**Simple Epithelium.** An epithelium only one cell in thickness is termed **simple**. There is, however, great variation in the thickness of simple epithelia. The cells, seen in sections perpendicular to the surface, may be approximately square in outline. Such an epithelium is called **cuboidal** (Fig. 243), but incorrectly, for the cells are usually hexagonal prisms. A simple epithelium consisting of tall prismatic cells (Figs. 244C, 245) is called **columnar**. At the extreme of thinness are epithelia (**flat** or **squamous**) each of whose cells is a broad flat plate, hexagonal in outline (Figs. 243, 241B). Endothelia of blood-vessels are among the thinnest of epithelia.

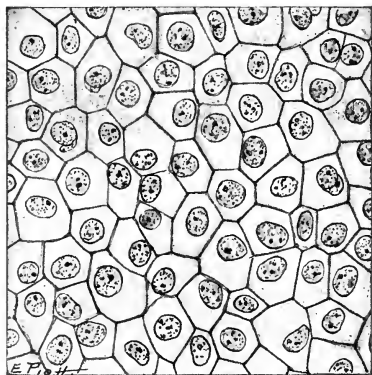
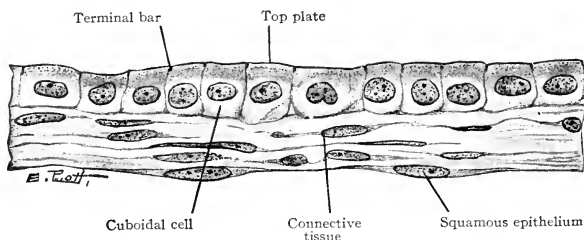


FIG. 243. (*Top*) Section of the amnion and allantois of a 60 mm. pig embryo at a region where the mesodermal layers of the two membranes have coalesced. The section is perpendicular to the surfaces of the allantois (*above*: cuboidal epithelium) and the amnion (*beneath*: squamous epithelium). The "top plate" is a superficial denser layer of the cuboidal cell. "Terminal bars" are thickenings of intercellular substance just beneath the surface of the epithelium.

(*Bottom*) Surface view of allantois. (Courtesy, Bremer-Weatherford: "Text-Book of Histology," Philadelphia, The Blakiston Company.)

**Stratified Epithelium.** On *Amphioxus*, a slender marine animal only 4 or 5 cm. long, an epidermis one cell thick affords adequate protection. On an elephant it would not. Surfaces of large, heavy animals are exposed to excessive mechanical friction and impact. Loss of material at the surface is best compensated for by a stratified epithelium whose lower layers persistently grow to replace the loss.

A stratified epithelium may be two or several or many cells in thickness (Fig. 244*D-F*). In all vertebrates the epidermis is stratified (Fig. 246). Its thickness varies with the size and habits of the animal, and, in a particular animal, it varies locally depending upon the degree of exposure to mechanical wear.

In a thick stratified epithelium the cells of the bottom layer are usually columnar, their deeper ends resting on a thin nonprotoplasmic **basement membrane**, and those of the outer layers are more or less flattened. The intermediate cells have a form such as would result from crowding tightly together a mass of compressible spheres—that is, polyhedral. Yet the cells are not actually packed tightly together. They are separated by excessively thin intercellular lymph spaces through which seeps lymph derived from underlying blood-vessels and serving to provide for the metabolic needs of the individual cells. Cells on opposite sides of the intercellular space are connected by delicate strands of solid, or at least dense, substance. Presumably protoplasmic, the strands are called **protoplasmic bridges** or **plasmodesms**.

Epithelia, even thick stratified, rarely contain blood-vessels. Certain salamanders (amphibians) possessing neither gills nor lungs carry

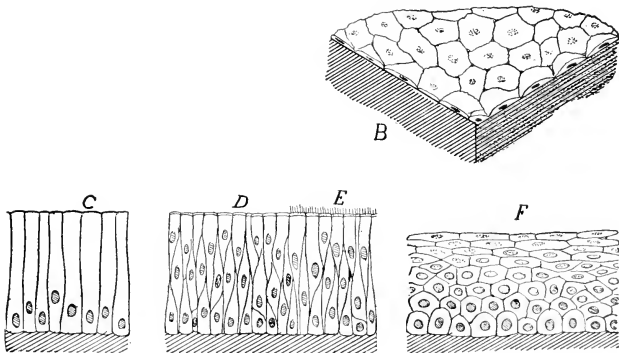


FIG. 244. Types of epithelia. (B) Simple squamous. (C) Simple columnar. (D) Stratified columnar, ciliated at (E). (F) Stratified polyhedral, upper cells squamous. (Courtesy, Kingsley: "Comparative Anatomy of Vertebrates," Philadelphia, The Blakiston Company.)

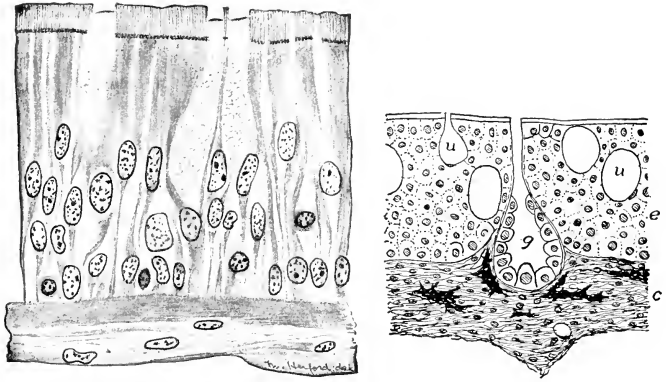


FIG. 215 (*Left*). Columnar ciliated epithelium from human trachea. Most of the cells are slender, with axes more or less curved, and extend from the basement membrane to the free surface of the epithelium. Occasional short cells, basal cells, lie at or near the basement membrane and do not extend to the free surface. Several swollen mucous cells ("goblet" cells) are shown. (Courtesy, Bremer: "Text-Book of Histology," Philadelphia, The Blakiston Company.)

FIG. 216 (*Right*). Skin of lungfish, *Protopterus*; section perpendicular to surface; much enlarged. (*c*) Dermis (corium); (*e*) epidermis; (*g*) multicellular gland; (*u*) unicellular gland. (Courtesy, Kingsley: "Comparative Anatomy of Vertebrates," Philadelphia, The Blakiston Company.)

on their respiration via the external skin and the pharyngeal lining. Their epidermis and the pharyngeal epithelium may contain blood-capillaries.

Many epithelia, although "simple" in the sense of being only one cell thick, are not the ideally simple tissue of the definition (p. 301), constituted of cells all "alike in their internal differentiation." Among the special functions of an epithelium are the following: (1) production of a superficial covering of nonliving, mechanically protective substance ranging, in vertebrates, from the delicate cuticular film over the body of a small fish to the massive horny scales on a big alligator or the horny hoofs of a horse; (2) production of special secretions such as mucus; (3) reception of external stimuli; (4) provision for motile activity. Two or more of these functions may be carried on by one "simple" epithelium or by a stratified epithelium. Within the epithelium, then, cells will exhibit differentiation of as many types as there are functions.

1. Most epithelia produce a protective covering at the free surface.

A **cuticula** is a dense, tough or hard material, partly nitrogenous, deposited on the exposed surface of an epithelium. The cells which

produce it and underlie it remain alive. A thin cuticula is present on the epidermis of fishes and larval amphibians and on some internal epithelia.

**Keratin** is a nitrogenous organic substance which is formed within some epithelial cells. It is the basis of the **horny** structures of the vertebrate skin.

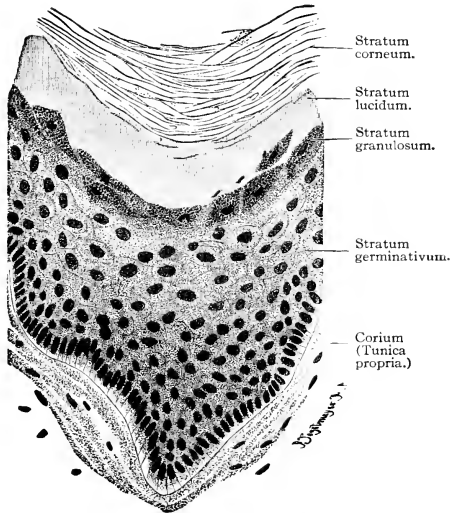


FIG. 247. Epidermis from the sole of the foot of an adult man. Section perpendicular to surface of skin. External to the stratum germinativum, the strata show successive stages in the production of the stratum corneum. ( $\times 360$ .) (Courtesy, Bremer: "Text-Book of Histology," Philadelphia, The Blakiston Company.)

The "horny layer" (**stratum corneum**: Fig. 247) developed on the skin of vertebrates other than fishes consists of one or more of the outer strata of the epidermis, the cells more or less filled with keratin and strongly adherent to one another so that the whole layer acquires a high degree of mechanical resistance. Completely keratinized cells are dead. No stratum corneum occurs on the skin of fishes, and in most amphibians it is only one cell thick. Hair, feathers, reptilian scales, claws, nails, and hoofs are local specializations of the stratum corneum.

In amphibians and reptiles the horny layer is usually shed and replaced periodically (**ecdysis**). In birds and mammals minute flecks

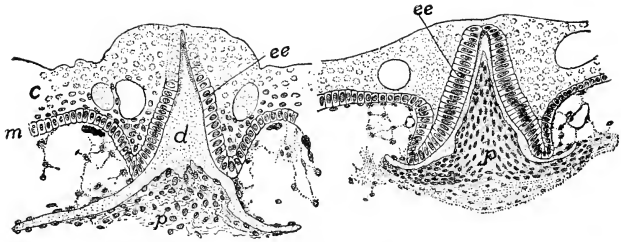


FIG. 248. Developing scales of dogfish, *Squalus*; sections perpendicular to surface of skin; much enlarged. (*c*) Upper layers of epidermis; (*d*) dentine of scale, deposited by dermal cells beneath it; (*ee*) enamel-forming organ of scale—a specialized region of the germinative layer (*m*) of the epidermis; (*p*) "pulp," the dentine-forming organ. (Courtesy, Kingsley: "Comparative Anatomy of Vertebrates," Philadelphia, The Blakiston Company.)

of it are constantly being sloughed off. The material thus lost is replaced by perpetual growth in the deep layer of epidermis.

**Calcareous material** may be deposited by an epithelium, either at its outer surface (e.g., shell of a mollusk) or, exceptionally, at its inner surface (e.g., enamel of teeth: Figs. 35, 248).

2. A **glandular epithelium** is one in which secreting cells, either singly or organized into multicellular glands, are distributed more or less abundantly throughout the layer (Fig. 246).

3. In a **sensory (or neuro-) epithelium** certain cells are specialized for reception of stimulation by some agency in the cell's environment (Fig. 249). They are usually elongated slender cells possessing one or more delicate "hairs" or "bristles" at the end exposed to the stimulating agency. The opposite end is related to a nerve-fiber. Epithelial sensory cells may be grouped in clusters to form sense-organs (Fig. 250). An epithelium may be rendered sensory by **free nerve-termination**, that is, the terminal twigs of a nerve-fiber ramifying among the epithelial cells (Fig. 251). These nerve-fibers, however, are not produced by the epithelium itself but invade it from adjacent tissue.

4. **Cilia** are extremely delicate motile filaments borne by the free ends of epithelial cells. A single cell may carry from one to over a hundred. A **ciliated epithelium** is one in which some or all of the cells carry cilia (Figs. 244E, 245).

The stroke of a cilium is effective in one direction only—as in rowing a boat. Beating of cilia may produce motion of the body which carries them; e.g., the gastrula of *Amphioxus* is propelled through the sea water by the cilia on the ectoderm. Or cilia may cause movement of fluid or of solid bodies along the ciliated surface, as when cilia on

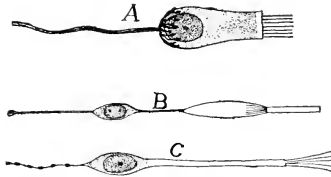


FIG. 249. Sensory cells. (A) Cell from the sense-organ (crista acustica) of an ampulla of the ear. (B) Rod-cell from the retina. (C) Cell from the olfactory epithelium. (After Fürbringer. Courtesy, Kingsley: "Comparative Anatomy of Vertebrates," Philadelphia, The Blakiston Company.)

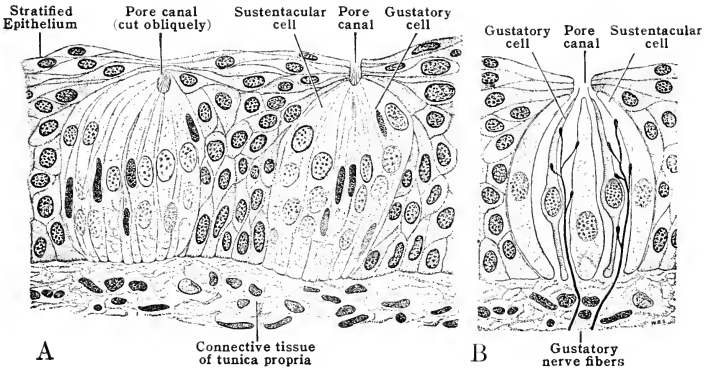


FIG. 250. (A) Taste-buds from a vallate papilla of the human tongue; as seen in section perpendicular to the surface of the epithelium. (B) Diagrammatic representation of the structure of one "bud." ( $\times 175$ .) (Courtesy, Schaeffer: "Morris' Human Anatomy," Philadelphia, The Blakiston Company.)

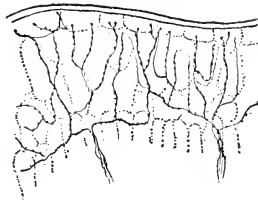


FIG. 251. Free nerve-termination in the epidermis of *Salamandra*. (After Retzius. Courtesy, Kingsley: "Comparative Anatomy of Vertebrates," Philadelphia, The Blakiston Company.)

the tracheal epithelium propel inhaled particles of dust upward and outward.

Cilia and mucous glands commonly occur in the same epithelium. The simple external epithelium of an earthworm and the stratified epidermis of a fish combine cuticular, glandular, and sensory specializations.

#### GLANDS

“Glands” whose products are as different as are sweat, eggs, and blood-cells hardly merit the same name. Accepting the name, it is necessary to distinguish different types of gland: (1) **secretory glands**, whose products are retained at least temporarily and serve some useful purpose—e.g., mucous, salivary, and thyroid glands; (2) **excretory glands**, which eliminate waste—e.g., kidneys; (3) **cytogenic glands**, which produce living cells—e.g., reproductive glands producing eggs or sperm, various lymph- and blood-glands in which white blood-cells are produced.

**Secretory glands** may be unicellular (Figs. 245; 246, *u*) or **multicellular** (Fig. 246, *g*). Nearly all multicellular glands develop directly from epithelia and retain their epithelial character. Some endocrine glands are epithelioid.

Most secretory glands develop from either the ectodermal or the endodermal epithelium and discharge at the surface of their native epithelium. Such are the many kinds of skin glands and digestive glands. The mesoderm gives rise to some secretory glands, especially in connection with the reproductive system—e.g., the albumen glands and shell glands of oviducts and the mucous glands of the mammalian uterus.

Multicellular glands may be **tubular** (Fig. 252*A–D*), or **alveolar** (**acinous**; Fig. 252*E, F*). Glands of either type, complicated by branching, are called **compound** (Fig. 252*C–F*).

The larger multicellular glands, especially those which are compound, require certain accessory structures. A good blood-supply must be provided. Therefore the gland may have an outer investment of connective tissue containing blood-vessels and lymphatics. A thin layer of nonstriated muscle fibers may be present on the wall of a gland which discharges its contents abruptly. The muscle would be accompanied by nerve-fibers, and in some glands nerves may be traced to the secretory cells.

Secretory glands in vertebrates range from unicellular mucous glands in the skin of fishes and amphibians and in the digestive epithelium of all vertebrates, to such massive compound multicellular glands as the mammary glands and liver.



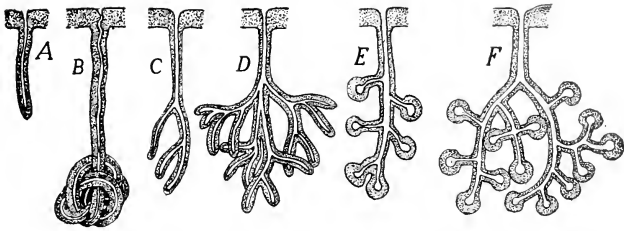


FIG. 252. Types of multicellular glands. (A-D) Tubular. (E, F) Alveolar or acinous. (A) Simple. (B) Coiled. (C-F) Branched or compound. The duct pierces the epithelium from which the gland has been produced. (Courtesy, Kingsley: "Comparative Anatomy of Vertebrates," Philadelphia, The Blakiston Company.)

### NONEPITHELIAL TISSUES

The primarily essential parts of a metazoan animal are the epidermal epithelium and the enteric epithelium. Certain of the organs which, in the adult, lie between these two layers consist of tissues which do not retain the epithelial character of the embryonic tissues from which they are derived but give rise to more or less bulky and solid masses of material.

The important types of adult nonepithelial tissues are the following: (1) muscular; (2) nervous, exclusive of neuroepithelial structures; (3) tissues serving for mechanical support—the connective and skeletal tissues; (4) adipose tissue or fat; (5) blood.

### MUSCULAR TISSUE

Locomotion in some protozoans is effected by beating of cilia. The movements of large animals depend on contractile mechanisms. Contractility is inherent in protoplasm. The least specialized protoplasm is apparently able to contract in the direction of any of its axes. When protoplasmic mechanism for effecting vigorous, quick, or long-continued contracting is established, the ability to contract becomes restricted to one axis. The protoplasmic structures which seem to be somehow immediately concerned with contraction are exceedingly fine fibrils, the **myofibrils**, which extend through the cell parallel to the axis of contraction.

The movements of *Hydra* are caused by contractile fibers which are not independent cells but are merely long processes from the basal ends of the epithelial cells of both ectoderm and endoderm. It is significant that, in the absence of a mesoderm, the two primary epithelia can produce an essentially muscular layer situated at the mid ("meso-") level of the wall of the hollow animal.

Among invertebrates the usual type of muscle element is a much-elongated cell having a single nucleus, more or less numerous myofibrils extending through the protoplasm lengthwise of the cell, and the usual cell-wall devoid of any special membranous covering. Such cells, associated together to form layers, bundles, or masses, constitute the muscles of the body-wall and the viscera. Certain invertebrates, however, whose muscles are, in one way or another, especially efficient, have muscle-cells of a more complex sort. The myofibrils become strongly developed and each fibril exhibits an alternation of darker and lighter zones. The zones of either type lie exactly alongside one another on adjacent fibrils so that they give the impression of transverse bands or striations extending continuously across the cell. Muscle-cells of this sort are called **striated**. Uninucleate striated fibers occur in the heart of some mollusks. In arthropods, especially insects, striated fibers attain great length, are multinucleate, and exhibit a complex system of transverse striations.

Vertebrates possess both striated and nonstriated (or "smooth") muscle (Fig. 253). In general, the muscle of the body-wall is striated and visceral muscle is nonstriated. But nonstriated muscle occurs in the walls of blood-vessels which lie in the body-wall, in connection with some skin structures such as hair and certain glands, and also in the iris of the eye. The muscles in the walls of the mouth, pharynx, and at least the upper part of the esophagus are striated, and it is said that striated muscle occurs in the wall of the stomach of some fishes. Also the external anal muscle is striated. The muscular part of the diaphragm is derived from the embryonic body-wall and its muscle is accordingly striated. And in all vertebrates the muscle of the wall of the heart is striated.

Nonstriated muscle fibers in vertebrates are much like those of invertebrates. They are ordinarily not over a fraction of a millimeter in length and, in man, much less than a hundredth of a millimeter in diameter. They are usually spindle-shaped (Fig. 253A), lying in the tissue with their tapering ends overlapping.

The somatic striated fibers of vertebrates are enormously larger than nonstriated fibers (Figs. 253B, 254). Their diameter may approach a millimeter, and their length, not accurately known, doubtless reaches several or many millimeters. But these great fibers are not, in strict sense, single cells. They contain scores or hundreds of nuclei which may be scattered throughout the interior of the fiber, but more commonly are at the surface as if crowded out of the deeper region by the myofibrils.

The myofibrils of striated fibers are much coarser than those of nonstriated fibers. They are embedded in a peculiar fluid, **sarcoplasm**,

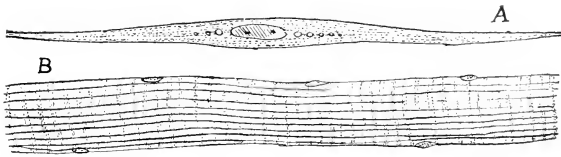


FIG. 253. (A) Nonstriated ("smooth") muscle-cell with single nucleus. (B) A small portion of the length of a multinucleate striated fiber. (Courtesy, Kingsley: "Comparative Anatomy of Vertebrates," Philadelphia, The Blakiston Company.)

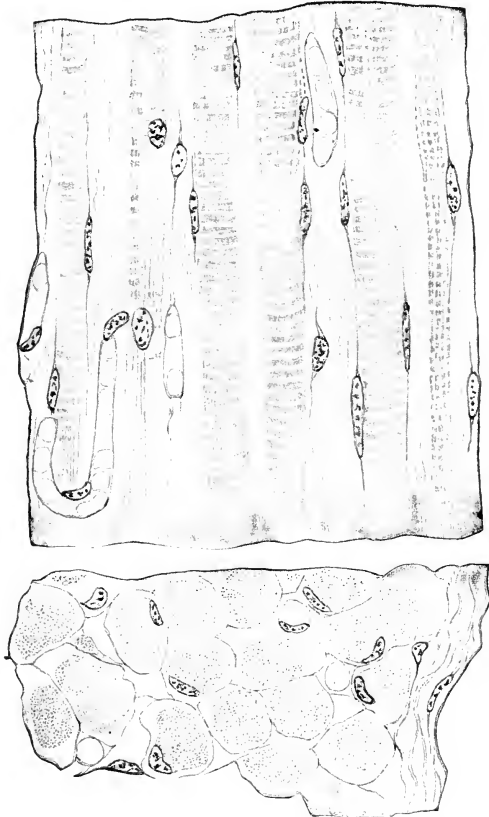


FIG. 254. Striated muscle; human. (Top) Longitudinal section, showing small portions of several fibers. (Bottom) Section transverse to the length of the fibers. Nuclei lie at the surface of the fiber. (Courtesy, Bremer: "Text-Book of Histology," Philadelphia, The Blakiston Company.)

which is probably a nutrient medium rather than ordinary cytoplasm. The wall of the fiber, much more prominent than an ordinary cell-wall, is called the **sarcolemma**.

The alternate dark and light bands on the individual fibril are due to physical differences such that, in polarized light, the dark bands

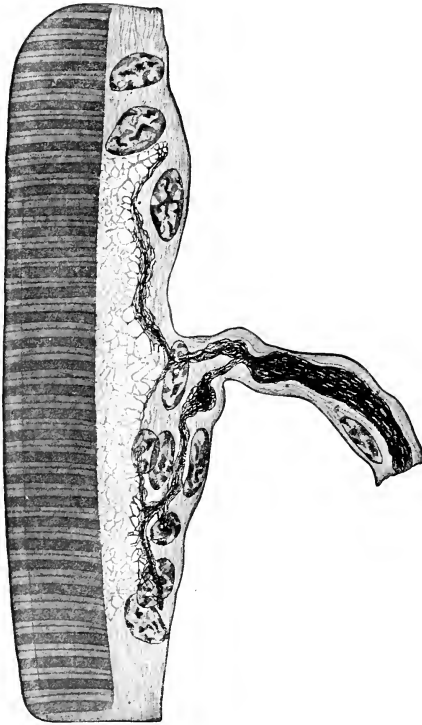


FIG. 255. Motor nerve-ending: part of a longitudinal section of muscle-fiber. (After Boeke. Courtesy, Bremer-Weatherford: "Text-Book of Histology," Philadelphia, The Blakiston Company.)

are doubly refractive (anisotropic) while the lighter bands are singly refractive (isotropic). Both the dark and the light bands are traversed by finer markings seen only under high magnification.

The relation of a nonstriated fiber to its nerve is apparently of the simplest sort. A terminal twig of nerve merely attaches to the surface

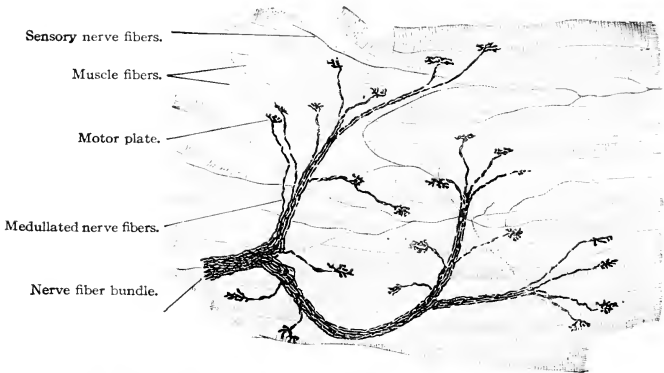


FIG. 256. Motor nerve-endings on intercostal muscle-fibers of a rabbit. ( $\times 150$ .) (Courtesy, Bremer: "Text-Book of Histology," Philadelphia, The Blakiston Company.)




FIG. 257. Human cardiac muscle. Section parallel to length of fibers. The occasional very dark transverse bands are the intercalated disks. (After Heidenhain. Courtesy, Bremer-Weatherford: "Text-Book of Histology," Philadelphia, The Blakiston Company.)

of the fiber, the end of the nerve often showing a knotlike enlargement. Presumably, every striated fiber has a nerve connected to it. The nerve, however, enters a small, flat plate of nucleated protoplasm lying superficially on the muscle fiber. Within this **motor plate** (Figs. 255, 256) the nerve ramifies into fine twigs which seem to terminate in the substance of the plate.

Striated fibers are bound together in bundles enwrapped by a connective-tissue **perimysium**. Thick muscles consist of several or many such bundles wrapped together.

**Cardiac muscle** has striations which resemble those of somatic muscle, but the fibers are relatively short and are branched. The sarcolemma is less strongly developed than in somatic fibers. A peculiar feature of the cardiac fiber is the presence of conspicuous transverse bands, the **intercalated disks** (Fig. 257), which are quite distinct from the ordinary striations. Their significance is not known.

#### NERVOUS TISSUE

All nervous functions are carried on by protoplasm organized, as always, in cells. To say, as is often done, that nervous tissues consist of nerve-cells and nerve-fibers is inaccurate. So far as is known, every fiber which conducts nervous impulses is developed as an outgrowth from a cell and can function and survive only so long as it remains in physical and physiologic continuity with the nucleated region of the cell of which it is an integral part. Any cell engaged in nervous operations, together with all conducting fibers which have grown out from it, is called a **neuron**.

A **central nervous organ** is a more or less complex system of physiologically related neurons serving for the proper association, coordination, and integration of nervous impulses. A **ganglion** is a minor localized nerve center consisting of the cell-bodies of neurons together with the adjacent regions of their nerve-processes.

Neurons are of various types, depending on the form of the cell-body and the number of nerve-processes (Figs. 258, 259). **Unipolar** cells, of comparatively rare occurrence, have a single process; **bipolar** neurons are usually spindle-shaped and have a process at each end; **multipolar** cells have several processes of which one, the **neuraxon** (**axon** or **neurite**), is relatively long, while the short **dendrites** branch out into fine twigs which end within a short distance of the cell-body. The neuraxon may give off lateral branches (**collaterals**), and its distal extremity breaks up into fine branches forming the **terminal arborization**. The apparently "unipolar" cell of a spinal ganglion is a disguised bipolar cell (Fig. 260).

Most types of receptor neurons are epithelial. In some of these the

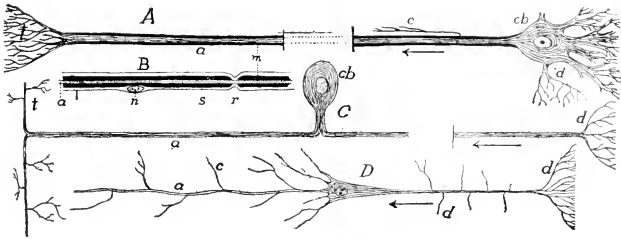


FIG. 258. Types of nerve-cells. (A) Multipolar cell. (B) Portion of nerve-fiber with sheaths. (C) Unipolar cell (such a cell may arise by modification of a bipolar cell, as shown in Fig. 260). (D) Pyramidal cell (from cerebral cortex). (a) Axon; (c) collateral; (cb) cell-body; (d) dendrites; (m) medullary sheath; (n) nucleus of cell of Schwann's sheath; (r) node of Ranvier; (s) sheath of Schwann; (t) telodendron. (Courtesy, Kingsley: "Comparative Anatomy of Vertebrates," Philadelphia, The Blakiston Company.)

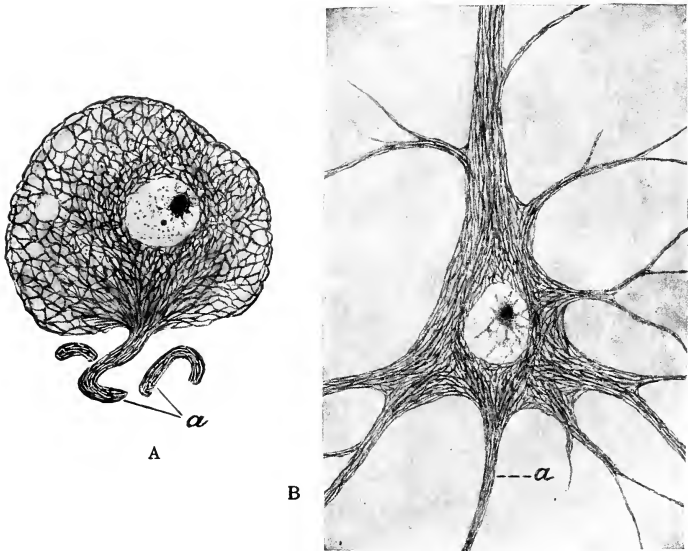


FIG. 259. Cell-bodies of neurons showing arrangement of neurofibrils. (A) From human spinal ganglion; two cut fragments of the neuraxon lie near the cell-body. (B) "Giant pyramidal cell" from human cerebral cortex. (a) Neuraxon. (Highly magnified.) (Courtesy, Jackson: "Morris' Human Anatomy," Philadelphia, The Blakiston Company.)

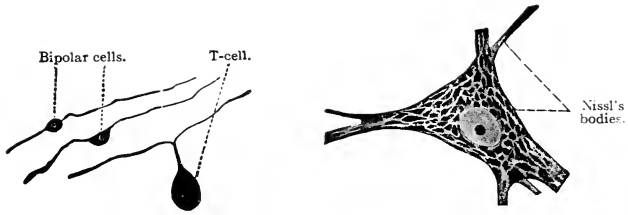


FIG. 260 (*Left*). Diagram showing how an embryonic bipolar nerve cell is transformed into a unipolar cell ("T-cell") such as occurs in ganglions of the dorsal roots of spinal nerves. (Courtesy, Bremer: "Text-Book of Histology," Philadelphia, The Blakiston Company.)

FIG. 261 (*Right*). Nerve-cell, with processes cut short; from human spinal cord. ( $\times 430$ .) (Courtesy, Bremer: "Text-Book of Histology," Philadelphia, The Blakiston Company.)

receptor cell itself produces a nerve-fiber which conducts to the central organ—e.g., an olfactory cell and its fiber (Figs. 167, 249C). In such cases one neuron serves as both receptor and conductor. In other cases, as in the auditory organ and taste-buds (Figs. 167, 250), the epithelial receptors do not produce nerve-fibers, but are intimately related to the terminal twigs of afferent nerve-fibers whose cell-bodies lie in some deep ganglion such as the acoustic ganglion or a spinal ganglion.

Nerve cells vary greatly in size, but in general are relatively large. They are often the largest cells in the body exclusive of eggs. Some possess two or more nuclei, and the bulky mass of cytoplasm, invested by a supporting membrane of connective tissue, may be penetrated by narrow canals serving for an intracellular circulation of lymph.

The most striking characteristic of the body of a neuron is the presence of large masses of a granular substance which has a strong affinity for the aniline dye, methylene blue. These **Nissl's bodies** (Fig. 261) have been shown to become reduced in neurons which have been excessively active, indicating that the bodies contain something which is a source of energy for nervous activity. Less conspicuous are the **neurofibrils** (Fig. 259), extremely fine fibrils which ordinarily are seen only after use of special staining methods. Such neurofibrils may form an elaborate system within the body of the neuron and may be traced into the neuraxon and larger dendrites. The appearance and arrangement of these neurofibrils strongly suggest that they are specialized avenues for conduction of impulses.

The **neuraxon** is a delicate thread consisting of a probably modified protoplasm in which, as just mentioned, neurofibrils may be demonstrated. It may attain extraordinary length, as when it extends from a spinal ganglion of a giraffe to the extremity of a foreleg. It is



vitaly dependent, throughout its entire length, on substances derived from the cell-body. Any part of it whose connection with the cell-body is severed promptly degenerates.

The neuraxon may be surrounded by one or two special ensheathing layers. The **medullary** or **myelin sheath** is a relatively thick layer of fatlike substance, myelin, fitting the neuraxon closely. The **neurilemma** or **sheath of Schwann** is an exceedingly thin cellular layer wrapped around the neuraxon (Figs. 132, 258).

A neuraxon may possess either, both, or neither of these two sheaths. When both are present, the myelin sheath is always next to the nerve-fiber and, at fairly regular intervals (in man averaging about 0.5 mm.) along the fiber, it seems to be nearly or quite interrupted so that the neurilemma there comes into close relation with the nerve-fiber (Fig. 258B). The neuraxon therefore presents a segmented appearance due to these **nodes of Ranvier**.

Nerves whose individual fibers possess the myelin sheath appear more nearly white than do nonmedullated nerves. The so-called "white" parts of the brain and spinal cord consist mainly of medullated nerves. Nonmedullated fibers and the cell-bodies of neurons are the chief constituents of "gray matter." Medullated nerves inside the brain and spinal cord usually have no neurilemma. Most autonomic nerves and the olfactory nerves are nonmedullated. The terminal twigs of a neuraxon are always bare.

The sheaths doubtless serve for the protection, insulation, and nutrition of the nerve-fiber. The source of the myelin is not definitely known.

A nervous organ is constituted of neurons supported by connective

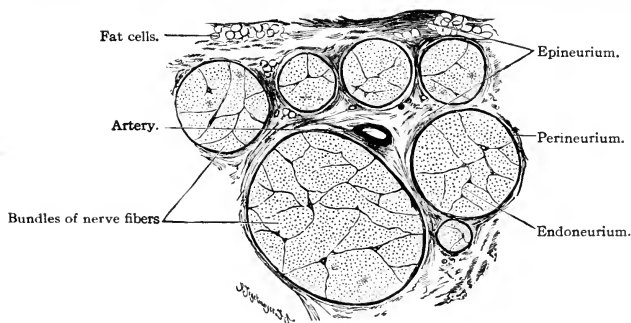


FIG. 262. Structure of a nerve. The figure represents a small part of a transverse section of a large nerve constituted of many bundles of medullated fibers. ( $\times 20$ .) (Courtesy, Bremer: "Text-Book of Histology," Philadelphia, The Blakiston Company.)

tissues accompanied by vascular tissues. In the brain and spinal cord of vertebrates occurs not only the usual mesenchymal connective tissue but also another, which is unique in that its cells have ectodermal origin in common with the nerve-cells. Some of the cells of this **neuroglia** possess branched processes which make them appear confusingly similar to nerve-cells. The neuroglia cells form, by means of their processes, a supporting network for the nerve-cells.

A **nerve** is a bundle of neuraxons, each of which may be ensheathed as described above, and all wrapped together within a sheet of connective tissue, the **perineurium** (Fig. 262), extensions of which (**endoneurium**) may penetrate into the bundle. Larger nerves consist of several or many bundles all tied together by connective tissue and enwrapped by a relatively thick **epineurium**. Small blood-vessels traverse the connective-tissue layers of the nerve.

#### TISSUES SERVING FOR MECHANICAL SUPPORT

Protoplasm is a substance of semifluid or gelatinous consistency. An elephant constituted of protoplasm only is a mechanical impossibility. Large animals, especially if they are land animals, require mechanical support. Protoplasm provides such support by appropriating various materials from the environment and building them into nonliving structures which are external to the cells and physically adapted to the mechanical needs of the animal as a whole and of its parts. Just as man uses steel wires, various cements and masonries, so protoplasm has its connective-tissue fibers, intercellular cements, and that most delicate calcareous masonry, bone.

The basis of the material of these supporting structures consists of various nitrogenous or protein substances. By impregnation of the material with inorganic salts, chiefly those of calcium, hard or rigid supporting structures are produced. The protoplasmic or cellular agencies concerned in building the supporting tissues are mesenchyme cells, except in the cases of the notochord and the ectodermal neuroglia of nervous organs.

The embryonic precursor of supporting tissues other than the exceptions mentioned is a more or less spongy mesenchyme (Fig. 263A) whose individual cells have branching processes by means of which the cells are joined together. The spaces within the meshwork of cells are filled by a homogeneous fluid substance, the **matrix**. Presumably the cells are the source of the matrix.

#### *Connective Tissue*

The essential mechanical structures in connective tissue are relatively coarse white fibers consisting of an albuminoid substance, **colla-**

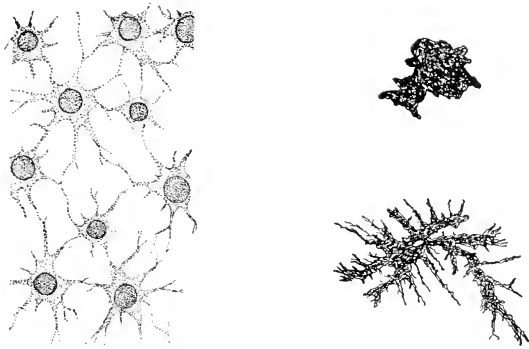


FIG. 263. (A) Mesenchymal tissue from embryo of the amphibian, *Ambystoma*. (B) Pigment-cells from *Ambystoma*; (below) a cell with pigment dispersed in numerous branched processes of the cell; (above) a "contracted" cell with pigment concentrated, the transparent processes not shown. (Courtesy, Kingsley: "Comparative Anatomy of Vertebrates." Philadelphia, The Blakiston Company.)

**gen**, the source of gelatin and glue. These **collagenous fibers** are only slightly elastic. They may be branched. Each fiber is a bundle of very delicate fibrils. Exceedingly flattened cells with flat nuclei appear as if clinging closely to the surface of a fiber. These connective-tissue cells or **fibrocytes** are presumably the agencies which have brought about the production of the fiber in the intercellular matrix.

**Elastic fibers** are usually finer than collagenous fibers and differ from them chemically in being composed of **elastin**, which is not a source of gelatin. An occasional elongated connective-tissue cell, a **fibrocyte**, may be seen stretching along the surface of a fiber (Fig. 264). Elastic fibers commonly occur intermingled with collagenous fibers.

**Reticular tissue** consists of cells whose branched processes join to form a network. It resembles embryonic mesenchymal tissue (Fig. 263A). It occurs in such organs as lymph-glands and the spleen.

**Arcolar tissue** is a loose, open meshwork of connective-tissue fibers—e.g., the subcutaneous tissue lying between the skin and the muscle of the body.

**Tendons and ligaments** are connective-tissue structures highly adapted to resisting tensile strain. They consist of connective-tissue fibers arranged in compact bundles. Tendons are inelastic.

**Chromatophores**, pigment-cells (Fig. 263B), may occur in connective tissue, especially in the dermal layer of the skin. The specific pigment appears as granules lying in the cytoplasm. Black pigment (melanin) is most common, and cells containing it are called **melano-**

**phores.** Chromatophores are usually richly branched. The pigment may at one time be distributed throughout the processes ("expanded" phase), at another time densely massed in the central part of the cell ("contracted" phase). Some pigment-cells are migratory.

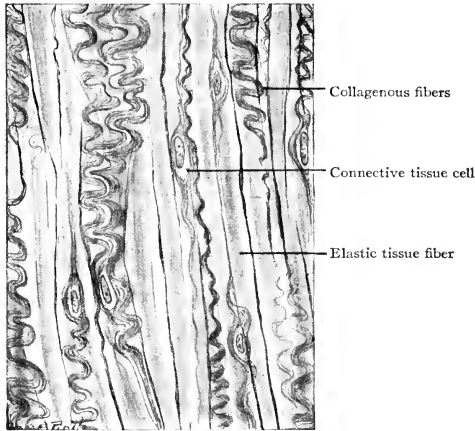


FIG. 264. Elastic tissue. Ligamentum nuchae of ox. The elastic tissue fibers are broad and straight, the collagenous fibers are in wavy bundles. Note the scarcity of connective-tissue cell nuclei. (Courtesy, Bremer-Weatherford: "Text-Book of Histology," Philadelphia, The Blakiston Company.)

### *Skeletal Tissues*

**Notochord.** The essential material of the notochord consists of cells each of which contains a relatively enormous vacuole occupied by a fluid, or possibly a gelatinous substance. The cytoplasm of the distended cell is so stretched that it appears as the thinnest possible layer surrounding the vacuole. The very flat nucleus occasions a bulge in the contour of one side of the cell (Fig. 265). The outer cell-membrane, while very thin, is probably of semirigid consistency. Seen under the microscope, this tissue looks like a mass of soap bubbles crowded closely together, the cytoplasm and cell-membrane of each cell being the wall of a bubble.

The vacuolated notochord tissue is enclosed by sheaths which differ in number and nature in various animals. There is commonly an inner elastic sheath (Fig. 265, *ei*) composed of material secreted by an outer epithelioid layer of the notochord tissue, and a thick outer sheath of dense fibrous connective tissue. Mechanically, the notochord resembles

a length of rubber tubing, closed at the ends, and filled with liquid under pressure.

**Cartilage.** In development of cartilage, mesenchyme cells become densely massed and then produce an abundant intercellular substance whose accumulation causes the cells to become more or less widely separated from one another (Figs. 234, 266). The intercellular **matrix**

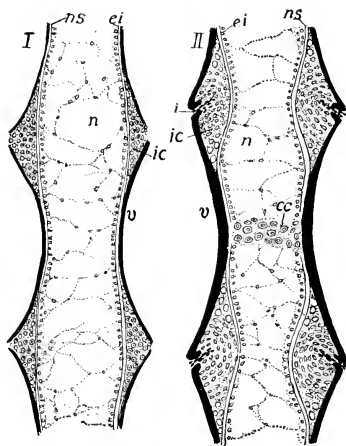


FIG. 265. Developing vertebrae of the amphibian, *Ambystoma*. (I) Earlier. (II) Later. Longitudinal sections. Cartilage and bone are forming around the notochord. (cc) Cartilage in center of vertebra; (ei) epithelioid internal elastic sheath of notochord; (i) incisure cutting through (ic) intercentral (intervertebral) cartilage; (n) notochord; (ns) outer notochordal sheath; (v) developing bone (black) of centrum of a vertebra. (Courtesy, Kingsley: "Comparative Anatomy of Vertebrates," Philadelphia, The Blakiston Company.)

becomes solid and acquires a firm or even hard consistency. Chemically it is a complex of collagenous, albuminoid, and other protein substances. The cartilage-cells remain embedded in the matrix, each occupying a close-fitting space, a **lacuna**. Some cartilages have been described as containing exceedingly fine canals penetrating the matrix and putting any one lacuna into communication with neighboring lacunas.

The external surface of cartilage is invested by a connective-tissue membrane, the **perichondrium** (Fig. 266), which contains blood-vessels, but they do not penetrate into the cartilage. Hence cartilage cannot occur in thick masses.

In growing cartilage, cells from the perichondrium become cartilage-cells and add cartilage to the exterior of the mass already formed. At the same time, deep cartilage-cells divide. The resulting cells secrete matrix substance whereby they become separated, each to lie in a lacuna of its own. Therefore cartilage grows by a combination of external addition and internal expansion.

Most cartilage, containing little or no fibrous material, is bluish and clear—hence known as **hyaline cartilage** (Fig. 266). In **fibrocartilage** the matrix contains fibers similar to those of ordinary con-

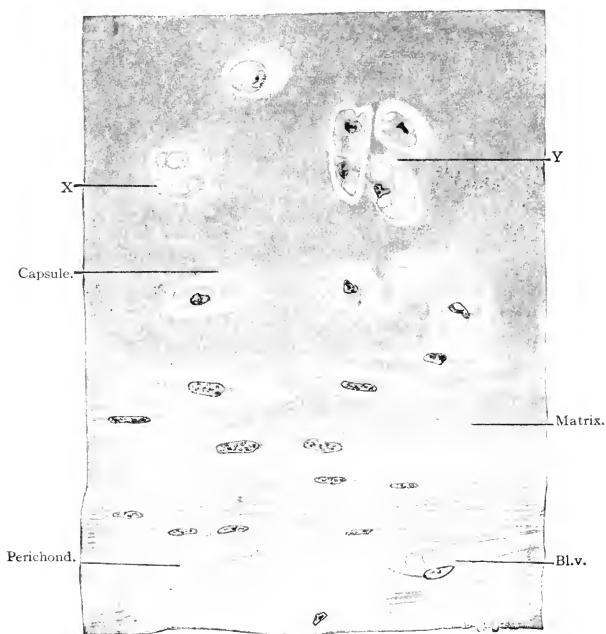


FIG. 266. Hyaline cartilage, with perichondrium; from human trachea. (Bl.v.) Blood-vessel; (X) cartilage-cell whose nucleus is not in section; (Y) new matrix forming between two cells resulting from a recent division of a cartilage-cell. (Courtesy, Bremer: "Text-Book of Histology," Philadelphia, The Blakiston Company.)

nective tissue. **Elastic cartilage** contains numerous elastic fibers. **Calcified cartilage** is rendered white and relatively hard by deposit of calcium salts in the matrix.

**Bone.** Cartilage and bone are similar in that their essential skeletal material is a nonliving matrix within which are embedded living cells. Bone differs from cartilage in that the matrix is highly calcified and correspondingly hard, and also in that it never exhibits the apparent homogeneity of the matrix of hyaline cartilage but is disposed in very thin parallel layers. Usually the deeper substance of a bone is of a porous or spongy texture (**cancellous bone**), while the outer region is dense or solid (**compact bone**).

A section of fully developed compact bone, seen under high magnification, shows the matrix layers or **lamellas** arranged in parallel or concentric order (Fig. 267*B*, 268). Flattened between adjacent lamellas are minute cavities, the **lacunas**. Exceedingly fine canals, the **canaliculi**, extend between each lacuna and neighboring lacunas, piercing the intervening lamellas. In bone of a living animal, each lacuna is occupied by a living bone-cell (**osteoblast**) from which processes extend into the adjoining canaliculi. Therefore bone is richly occupied by living material.

All external surfaces of bone are covered by a membrane, the **periosteum**, of dense fibrous connective tissue well supplied with blood-vessels which enter the bone and branch throughout it. Most bones, notably the long bones of the appendages, have internal cavities occupied by a more or less vascular soft tissue, the **marrow**. The "yellow marrow" of long bones contains much fat. "Red marrow" is highly vascular, contains little fat, and may be a source of blood-cells of various types.

Blood-vessels from both the periosteum and the marrow enter and branch throughout the bone. From these vessels, substances necessary for the metabolism of the bone-cells diffuse through the system of connected lacunar spaces.

In long bones the larger blood-vessels lie approximately parallel to the long axis of the bone. Around such vessels the bone lamellas are arranged in concentric order (Figs. 267, 268) forming so-called **Haversian systems**. These concentric systems are much less prominently developed in flat bones.

The matrix of bone consists of commingled organic and inorganic materials. Collagenous and other protein substances constitute the organic part while various salts of calcium, mostly the phosphate and carbonate, are the most important inorganic ingredients. Bone, because of the rigidity of its calcified matrix, is incapable of such interstitial growth as occurs in cartilage. A further difference between

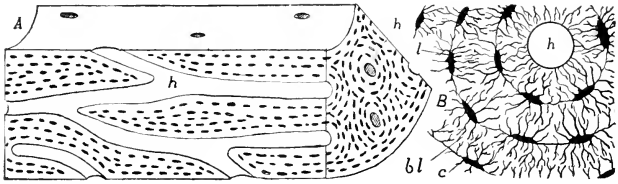


FIG. 267. (A) Stereogram representing a sector of the shaft of a long bone. (B) Transverse section, much more enlarged, showing part of one Haversian system. (*bl*) Bone lamellae; (*c*) canaliculi; (*h*) Haversian canal; (*l*) lacuna. (Courtesy, Kingsley: "Comparative Anatomy of Vertebrates," Philadelphia, The Blakiston Company.)

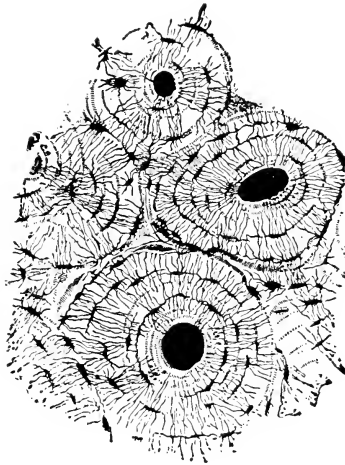


FIG. 268. Section, highly magnified, of compact bone from the shaft of the human humerus. The section, cut transversely to the long axis of the bone, shows four Haversian systems with their central canals, concentric lamellae of bone, lacunae between adjacent lamellae, and canaliculi extending between lacunae. (After Sharpey. Courtesy, Bremer: "Text-Book of Histology," Philadelphia, The Blakiston Company.)



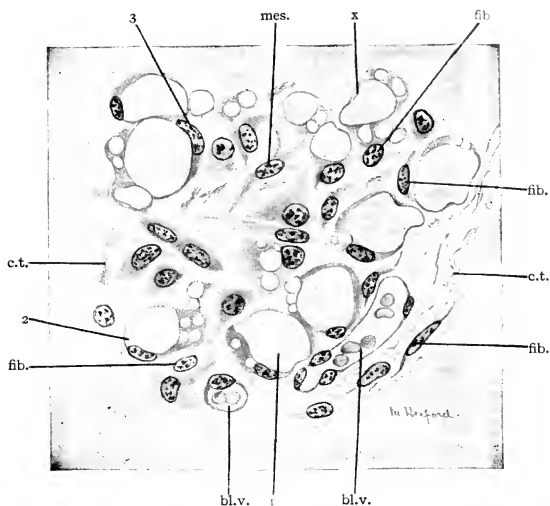


FIG. 269. Fat-cells in subcutaneous tissue of a human embryo of four months. (bl.v.) Blood-vessel; (c.t.) white connective-tissue fibers; (fib.) young fibrocyte; (mes.) mesenchymal cell; (x) young fat-cell, nucleus not in section; (1, 2, 3) developing fat-cells. (Courtesy, Bremer: "Text-Book of Histology," Philadelphia, The Blakiston Company.)

cartilage and bone lies in the fact that the cartilage-cell produces matrix in all directions and thus surrounds itself by its own product, whereas the osteoblast produces matrix only at such part of its surface as is adjacent to the already formed bone. A layer of bone cells building up lamella upon lamella of bone may be likened to a group of masons laying course upon course of stone at the unfinished top of a wall. But, in the case of the bone, every now and then one of the masons, an osteoblast, is left behind and buried between successive courses of the wall, remaining there in his little lacuna as a permanent and *living* bone-cell.

Bone once formed may be broken down or "resorbed." By this means, the marrow cavity of a long bone is enlarged as the bone grows. The resorption is attributed to the action of special cells called "**osteoclasts.**"

#### ADIPOSE TISSUE

Adipose tissue or "fat" consists of cells each of which contains a globule or vacuole of oil so large that the cytoplasm appears as merely an exceedingly thin layer surrounding the vacuole (Fig. 269). The flat

nucleus lies in the peripheral layer of cytoplasm. The irregular polyhedral form of the cells is doubtless the result of their mutual pressures. As seen in microscopic sections, it looks very much like tissue of a notochord.

#### BLOOD

The circulatory function of blood requires that it be fluid, but various special services are rendered by cells suspended in the fluid, some of them passively carried by it, others capable of independent motion somewhat like that exhibited by an ameba.

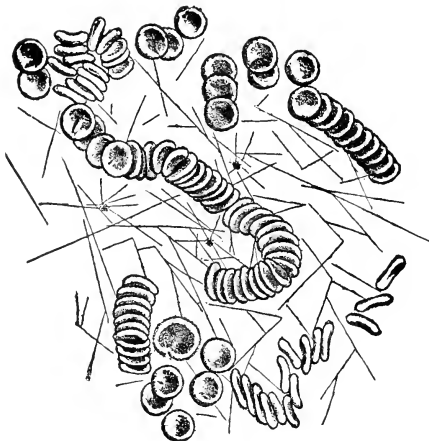


FIG. 270. Coagulated blood. Biconcave red corpuscles arranged in "rouleaux"; filaments of fibrin radiating from minute blood-platelets. (After Da Costa. Courtesy, Bremer: "Text-Book of Histology," Philadelphia, The Blakiston Company.)

The fluid part of blood, the **plasma**, is water containing all the other substances which enter into the constitution of protoplasm together with various hormones and the waste products of metabolism. Derived from digested food are various dissolved proteins and sugar, and minute fat droplets are suspended in the watery plasma. In its inorganic chemical constitution, the plasma resembles sea water.

In the coagulation of blood, on exposure to air or under some other circumstances, a nitrogenous substance, **fibrinogen**, carried by the plasma in solution, becomes transformed into fine solid filaments of **fibrin** (Fig. 270). The uncoagulated portion of the plasma is called

**serum.** The "clot" is a mass of fibrin with blood-cells caught in its meshes.

Blood-cells are of two main kinds, **red corpuscles** or **erythrocytes** and **white corpuscles** or **leukocytes**. The red cells are much more numerous. In human blood, the red cells outnumber the white in the ratio of five or six hundred to one.

**Erythrocytes** (Figs. 270, 271) are relatively small and usually have the form of flat disks with elliptic outlines. These blood-cells are the oxygen-carriers, being heavily loaded with **hemoglobin**, a complex protein substance containing iron and having a strong affinity for oxygen which the cells pick up at the respiratory surfaces of the animal. Their color is due to the hemoglobin. The mature erythrocytes of all vertebrates except mammals are nucleated. In adult mammals, the red cells in the course of their differentiation lose their nuclei, thereby acquiring the form of biconcave disks (Fig. 270).

In the embryo, erythrocytes are produced in mesenchymal tissue of the liver and spleen. In the adult, their chief source is probably red bone-marrow. They serve for a limited time as oxygen-carriers and then degenerate. Their debris is removed from the blood by phagocytic cells in the spleen and smaller blood-glands.

**Leukocytes** are permanently nucleated and do not carry hemoglobin. Several types are recognized (Fig. 271), as follows:

**Lymphocyte:** usually small, cytoplasm scanty and usually non-granular, nucleus spheric and relatively large.

**Large mononuclear leukocyte (monocyte):** cytoplasm more abundant and nongranular, nucleus excentrically placed.

**Polymorphonuclear leukocyte:** large, with conspicuous granules in cytoplasm, nucleus indented, lobulated, irregular, or separated into two or more parts. Several kinds are distinguished on the basis of the reaction of their granules to aniline dyes. **Basophils** have granules which take basic stains; **eosinophils** have an affinity for eosin, an acid dye; the granules of **neutrophils** take both basic and acid dyes.

Most leukocytes are capable of active ameboid motion. Some may penetrate the wall of a blood-vessel and so emerge into intercellular spaces of adjacent tissue. Many are phagocytic. They are produced in lymph-glands, bone-marrow, and lymphoid tissue variously situated in the body.

**Blood platelets** (Figs. 270, 271) are minute bodies which seem to be protoplasmic and yet are not nucleated. They probably result from fragmentation of cells in bone marrow or elsewhere. They seem to have

some relation to the clotting of blood, as indicated by the fact that the filaments of fibrin tend to radiate from blood-platelets.

**Lymph** resembles blood but lacks erythrocytes and is therefore colorless. The fluids occupying the coelomic spaces and the cavities of brain and spinal cord, the aqueous humor of the eye, and the amniotic fluid are all of the general nature of lymph but contain relatively few cells and differ from one another in details of chemical constitution.

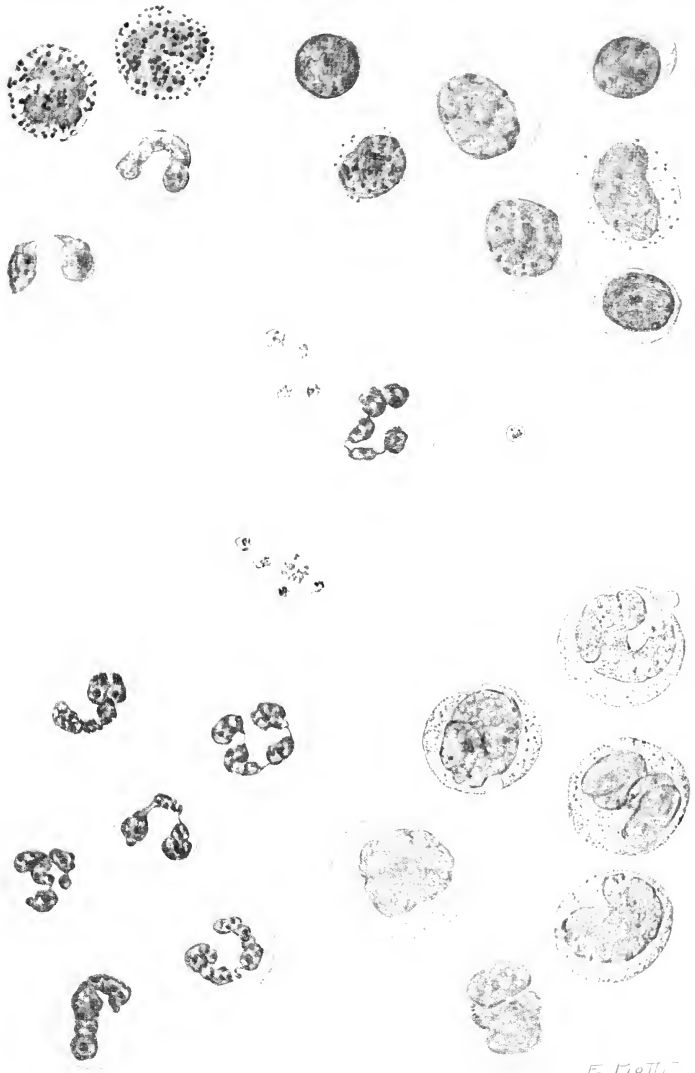
### HISTOLOGIC SPECIFICITY

In general, histologic differences are less conspicuous than the corresponding anatomic differences. Nonstriated muscle-fibers appear much the same whether they are in the wall of a stomach or of a lung. Nevertheless, cells and tissues usually exhibit characteristics which mark them as belonging to a particular organ or animal. The nerve-cells of a spinal ganglion differ from the motor nerve-cells in the spinal cord of the same animal. Striated muscle of the vertebrate heart differs from that of the body-wall. Vertebrate cardiac muscle differs from that of a lobster. Epidermal tissue of a fish differs from that of a reptile.

It follows, therefore, that the individual tissue-cell may, in its visible structure, exhibit characteristics reflecting as many as four grades of organization. First, there are those cell organs, such as nucleus and chromatin bodies, which represent the fundamental organization of protoplasm as cells. Second, there are those intracellular structures such as myofibrils or neurofibrils which mark the cell as belonging to a particular tissue—muscular or nervous. Third, there may be features which identify the cell as belonging to tissue of a certain organ—for example, the intercalated disks in the heart muscle of vertebrates. Finally, the individual tissue element may have peculiarities which are specific for animals of a certain group; for example, the striated muscle-fiber of an insect differs in details of structure from that of a vertebrate. From bottom to top of this series of levels of protoplasmic organization—cell, tissue, organ, individual, species, etc.—there must be corresponding chemical specificity. To a considerable extent, it has been demonstrated.

---

FIG. 271. (See facing page.) Cells from smear preparation of normal human blood; Wright's stain. (Center) Adult red blood-corpuscles, blood-platelets, and a polymorphonuclear neutrophil. (Top, left) Two polymorphonuclear basophils and two polymorphonuclear eosinophils. (Top, right) Three large and four small lymphocytes. (Bottom, left) Polymorphonuclear neutrophils; two of these cells, the uppermost and lowermost of the group, are young, with merely crooked nuclei; the mature cells have multilobed nuclei. (Bottom, right) Six monocytes; in the younger cells the nuclei tend to be rounded; in the adult cells they are horse-shoe-shaped, indented, or lobed. (Courtesy, Bremer-Weatherford: "Text-Book of Histology," Philadelphia, The Blakiston Company.)



E. MOTTI



Part II

COMPARATIVE ANATOMY—ITS HISTORY,  
AIM, AND METHOD





# History of Comparative Anatomy

---

9

## PRESCIENTIFIC ANATOMY

The beginnings of a knowledge of anatomy can be traced into the indefinite past. Prehistoric inhabitants of Europe left, on the walls of their cave-dwellings, drawings which indicate much appreciation of animal form and some crude knowledge of anatomy (Fig. 608). They knew the location of the heart of the elephant and bison—important to know in the business of hunting. Documents dating from 15 centuries B.C. show that the Egyptians then possessed a considerable knowledge of human anatomy and a primitive system of medicine and surgery. In Mesopotamia, too, even several centuries earlier, anatomy, medicine, and surgery were a part of the culture of the period. Naturally many of these early ideas of animal structure were distorted, even to the point of grotesqueness.

The early Greeks doubtless derived something from Egyptian and Babylonian sources, but by nature they were philosophers rather than investigators, and what they added to it prior to the fourth century B.C. became an inverted pyramid of speculative thinking resting insecurely on its apex of observed fact. Especially prominent in this pre-scientific period were Empedocles, Hippocrates, and Heraclitus, all about the fifth century B.C. It is noteworthy that in many instances the speculations of these early Greeks anticipated the essence of what, centuries later, came to be established as scientific fact.

## ARISTOTLE

The beginning of a science—in the modern sense—of natural phenomena is accredited, by common consent, to the Greek naturalist and philosopher **Aristotle** (384–322 B.C.), a pupil of Plato. Son of a physician, Aristotle was destined by both heredity and environment to be interested mainly in living things. His intellectual influence, however,

profoundly affected all "natural philosophy" as, in course of the centuries, it ramified into the several natural sciences. His contribution to the factual knowledge of nature vastly exceeded in importance anything that had yet been done, but much more important was his abandonment of the speculative procedure of his predecessors and his vigorous and convincing insistence that knowledge and understanding of the truth must rest primarily on observation of fact.



FIG. 272. Aristotle (384-322 B.C.). Bronze from Herculaneum; in Naples Museum. Work of first century A.D. from original of fourth century B.C. (Courtesy, Singer: "The Evolution of Anatomy." New York, Alfred A. Knopf, Inc.)

Aristotle acquired an extensive knowledge of the animals which were accessible to him. He recognized some 500 kinds of vertebrates and many invertebrates. He learned much about the development of the chick in the hen's egg and about the reproductive processes in fishes. Especially noteworthy was his discovery that certain small sharks (dogfishes) do not "lay eggs," as do most fishes, but are viviparous, and that the young fish developing within the maternal body possesses nutritive arrangements resembling the placenta of viviparous mammals.

Most remarkable was Aristotle's anticipation of the essential principle which, 2000 years later, was elaborated into the Theory of Evo-

lution. Having become well acquainted with a large number of diverse animal forms, invertebrate and vertebrate, he saw that it was possible to arrange them in a graded series ranging from the smaller, simpler invertebrates to larger and more complex animals such as mammals. He proposed that the lowest living forms must have emerged somehow from nonliving substance. The foot of his "ladder" ("*scala naturae*") rested on earth, and on the top rung stood man. He believed that the higher forms of his "*scala*" were somehow derived from lower forms—a genetic continuity of all living things.

Of Aristotle's numerous writings, three great biologic works have come down to us in more or less incomplete form—"Historia Animalium," "De Partibus Animalium," and "De Generatione Animalium."

#### GALEN

It was to have been expected that Aristotle's brilliant achievement would have given to science, especially biology, an impetus which would have carried it steadily forward through succeeding centuries. But it did not. Following Aristotle's time comes a stretch of about 16 centuries during which science, as Aristotle conceived of it, showed only occasional sparks of life. The brightest of these is seen in the work of **Galen** (about 130–200 A.D.), a physician and anatomist of Greek origin, born in Pergamum, Asia Minor. Much of his work was done in Rome, where he was physician to the Emperor Marcus Aurelius. His voluminous works are largely compilations of existing knowledge and highly philosophic, but he made important contributions to human anatomy, his work on the muscular system being especially valuable.

#### THE "DARK AGES"

Immediately following Galen began a period of some eight centuries, the "Dark Ages," during which science was at its lowest ebb. During these earlier centuries of the Christian era, the prevailing theology created an atmosphere unfavorable for science. Human interests tended to shift from things of the present and of this world to a future life in some other world. Human thought was dominated by authority. It was enough that a physician of the time should know what Aristotle and Galen had taught, but even the works of these authors seem to have been largely forgotten. In medical schools, anatomy was taught mainly from books and with very little dissection and demonstration.

#### DAYBREAK—MEDIEVAL MEDICAL ANATOMY IN EUROPE

Breaking of dawn after the long night occurred in the eleventh and twelfth centuries. The returning light entered Europe from the east

from Arabia where, during the Dark Ages of science in Europe, the knowledge and philosophies of the early Greeks and of Aristotle and Galen were not only preserved but extended. Arabic versions of the works of these authors were brought to Europe and translated into Latin. In the twelfth and several succeeding centuries, many new universities were established and most of them acquired medical faculties. These new intellectual centers were at first more numerous in Italy than in any other country.



FIG. 273. Portrait of Galen (*ca.* 130–200 A.D.). No bust of Galen has survived from antiquity. The only ancient representation of him is to be found in the so-called Juliana Anicia Manuscript. (Drawing by Poulton. Courtesy, Singer: "The Evolution of Anatomy," New York, Alfred A. Knopf, Inc.)

During this period, anatomic and medical science, at first somewhat bound by traditional respect for Aristotle and Galen, soon began to free itself and to become progressive. The necessity, for medical purposes, of dissecting the human body was appreciated, and it was at the University of Bologna that such dissection was first done on an important scale. Teaching at Paris, **Jacobus Sylvius** (1478–1555) emphasized the essential need of dissection in teaching anatomy to medical students and made important contributions to anatomic knowledge. (The "fissure of Sylvius," a conspicuous feature of the mammalian brain, was named after Franciscus Sylvius, a Hollander

of the seventeenth century.) Among the students of Sylvius was a young man, **Vesalius** (1514-64), who, born in Brussels and having received his early education at the University of Louvain, went to Paris to study medicine. He became professor of anatomy at the University of Padua.




FIG. 274. Vesalius (1514-64), from the "Fabrica," 1543. (Courtesy, Singer: "The Evolution of Anatomy," New York, Alfred A. Knopf, Inc.)

**Vesalius** published, in 1543, his "Seven Books" on human anatomy—"De Humani Corporis Fabrica," a work which stands as a monument marking the end of the old and the beginning of the new in anatomic science. The work is a great monograph of original observation. The author declares his complete emancipation from authority. The numerous illustrations are of such high artistic value as to have led to the belief that they were executed by Titian. Historians refer to Vesalius as "the Reformer of Anatomy."

**Eustachius** (1520–74) was a Roman contemporary of Vesalius. He is at a disadvantage historically because much of his work was unpublished and lost. Enough remains to show that he was a very capable anatomist and possibly even a rival of Vesalius, with whose work he found considerable fault. His name comes down to us in the term “Eustachian tube,” referring to the passage leading from the “middle ear” to the rear of the nasal passage (nasopharynx).

**Fallopian** (1523–62) was a student of Vesalius and became professor of anatomy at Padua. He studied especially the viscera and nervous system. His name is attached to the anterior division, “Fallopian tube,” of the vertebrate oviduct.

**Fabricius ab Aquapendente** (1537–1619), having studied under Fallopian, succeeded him at Padua and did permanently important work in vertebrate comparative anatomy and also on the embryology of the chick and of mammals.

#### PHYSIOLOGY, HISTOLOGY, EMBRYOLOGY

From Vesalius to the present, there has been no interruption of the progress of anatomic and medical science. Its rate of progress, however, has been variable and the science has undergone important changes in point of view and objective. A notable event in the seventeenth century was the discovery of the circulation of the blood. **William Harvey** (1578–1657), an Englishman, took his “arts” degree at the University of Cambridge and then went to Padua to study medicine. He worked in anatomy under Fabricius and so became an intellectual descendant of Vesalius. Having obtained his medical degree, he returned to England and devoted his life to medical practice and research. His great work on the movements of the heart and the circulation of the blood is commonly regarded as marking the beginning of modern **Physiology**. He did important work also on the embryology of the chick and of mammals.

The invention of the compound microscope at about the middle of the seventeenth century opened the door to fields vitally related to anatomy. **Malpighi** (1628–94), working mainly at Bologna, supplied a deficiency in Harvey’s account of the circulation by demonstrating the microscopic capillaries through which the blood flows from arteries into veins. He also saw the blood-corpuscles. Malpighi and his Dutch contemporaries, **Swammerdam** (1637–80) and **Leeuwenhoek** (1632–1723), directed their primitive microscopes toward the study of the anatomy of minute organisms, the minute anatomy of larger organisms, and the finer structure of tissues. Their work therefore included the beginnings of **Histology**. The name Malpighi remains attached to several vertebrate structures—the “Malpighian layer” of the epi-

dermis, the "Malpighian corpuscles" in the kidney, and certain bodies in the spleen.

**Embryology**, even more important than histology as a working ally of anatomy, had its beginnings in Aristotle, Fabricius, Harvey, and Malpighi. The optical limitations of the early microscopes put embryology temporarily on the wrong track. Malpighi, studying chick embryos, concluded that most, if not all, of the organs of the adult must be already present in a formed state in the unincubated egg. During most of the eighteenth century, this idea of "performance," strongly advocated by the naturalist **Bonnet**, the physiologist **Haller**, and the philosopher **Leibnitz**, dominated embryology. Development consisted essentially in mere enlargement of miniature organs preëxisting in the germ and then unfolding to view, somewhat as the bud of a flower opens. The term "evolution," meaning literally an "unfolding," was first applied to embryonic development as thus conceived. Harvey, however, believed, as did Aristotle 20 centuries before him, that organs *develop*—that is, gradually acquire form and structure—from an unformed germinal substance. To this method of development Harvey applied the name "epigenesis." Better microscopes enabled later embryologists—notably **C. F. Wolff** (1733–94), **J. F. Meckel** (1781–1833), and **Karl E. von Baer** (1792–1876)—to obtain positive proof that development is epigenetic.

#### THEORY OF EVOLUTION

Comparative anatomy, established as a science by Aristotle and revived after the Dark Ages by Vesalius, entered, at about the middle of the eighteenth century, a period within which its point of view, purposes, and methods were to undergo profound change. This period, extending through the middle third of the nineteenth century, was lighted by a brilliant constellation of names. First, in Sweden was the naturalist **Linnaeus** (1707–78), and in France the philosopher and naturalist **Buffon** (1707–88). Then in England appeared **Erasmus Darwin** (1731–1802), naturalist, philosopher, poet, and grandfather of Charles Darwin. In France a little later were the philosophic naturalist **Lamarck** (1744–1829), and **Geoffroy Saint-Hilaire** (1772–1844), a philosophic comparative anatomist, and also **Cuvier** (1769–1832), perhaps the most eminent of comparative anatomists, founder of Paleontology, but little inclined toward speculative and philosophic thinking. Meanwhile, in Germany was **Goethe** (1749–1832), sometimes botanist and anatomist, sometimes poet, and always a philosopher. The highly speculative ideas of **Oken** (1779–1851), another German, made a temporary impress on anatomic science.

Biologic knowledge in the eighteenth century comprised an extensive volume of firmly established fact. The microscope had made highly

important additions to it. As never before, it was realized that all living things have much in common; that the same general plan of structure may occur throughout some large group of plants or animals, merely so modified in its details as to adapt members of the group to diverse environments and habits of living. The existence of what appeared to be rudimentary, vestigial, and even useless parts was recognized. "Nature" seemed to be a paradox of striking unity and endless diversity. The more inquiring minds of the age found themselves confronted by an insistent need for interpretation and causal explanation. To some of these minds, the literal acceptance of the account of "Creation," as offered by the dominant theology of the time, was unsatisfying.

The period in question became highly controversial. It produced a welter of ideas, often confusingly blended one with another. It is possible, however, to recognize three main centers around which the tides of argumentation surged. One was the orthodox belief in "special creation"—that is, every existing type of organism originated by a "supernatural" creative act, independent of preëxisting types. A second asserted that new types arise from preëxisting types by a "natural" process—Evolution. Basic similarity between the new and the old is due to inheritance; differences result from environmental or other agencies. There is genetic continuity of all living things. A third view referred "unity of plan" to a pure abstraction, an ideal or "**archetype**." For the special-creationist, the archetype was a general plan upon which the Creator molded various creatures, but modifying the details of the plan to suit their diverse needs. Strangely, however, the idea of the archetype was not restricted to special creation. In various more or less vague ways, it became associated with the doctrine of evolution. This anatomy of abstractions is now commonly called "transcendentalism."

Linnaeus clung to "special creation," although in later life he admitted the possibility that a new species might arise in a hybrid between members of two specially created species. He was strongly impressed, however, by the "unity of plan" observable in groups of organisms, and saw in it the basis for a classification far more logical and useful than any yet attempted. Early classifications defined a group on the basis of one or few characteristics—and in many cases these were superficial or irrelevant. Thus Aristotle separated animals into two great divisions, those "with blood" and those "without blood." To him all blood was red. **John Ray** (1628–1705) devised a far better classification than any that preceded it but, even so, his two main divisions of invertebrates were "Majora" and "Minora"—"larger" and "smaller" invertebrates. Linnaeus, in his great work, the "*Systema Naturae*," classified plants and animals, so far as his limited knowledge permitted, on the basis of general structure. He elaborated the "binomial nomen-



clature" which is now universally used in classification. Any plant or animal is identified by two names (in Latin), one indicating the larger group, Genus, to which it belongs and the second the subdivision or Species of that group.

It was **Buffon** who revived Aristotle's idea of a "scala naturae" up which living things have continuously progressed from "lower" to "higher" or more nearly "perfect" forms. But Buffon seems to have been hesitant about carrying the idea of genetic continuity to its logical conclusions. **Erasmus Darwin** accepted the idea much more wholeheartedly. Having a poetic bent, he set forth his scientific and philosophic ideas in verse. The following lines are from his "Temple of Nature."

Hence without parents, by spontaneous birth,  
Rise the first specks of animated earth.

Organic life beneath the shoreless waves  
Was born and nurs'd in ocean's pearly caves;  
First, forms minute, unseen by spheric glass,  
Move on the mud, or pierce the watery mass;  
These, as successive generations bloom,  
New powers acquire and larger limbs assume;  
Whence countless groups of vegetation spring,  
And breathing realms of fin and feet and wing.

It remained for **Lamarck** to develop the idea of genetic continuity into a well-organized Theory of Evolution. He pointed out that the ascent of "Life" from nonliving to Man is not adequately represented by a "scala." It is not a "ladder" that "Nature" has climbed, but a tree, produced in the process of climbing—a tree of numerous branches, larger and smaller, and innumerable terminal twigs. He offered a clearly formulated causal explanation of the process of evolution. The reactions of an organism to its environment produce structural changes in the organs concerned and the changes thus acquired are transmitted to the offspring—"inheritance of acquired characters." Vigorous use of an organ tends to strengthen it and perpetuate it in the race; disuse is attended by atrophy of the organ. Very similar ideas had been expressed, but less fully worked out, by Erasmus Darwin. This causal theory, as offered by Darwin and Lamarck, seemed attractively plausible and reasonable. Biology has been reluctant to reject it in spite of the fact that the century and a half since Lamarck has yielded no convincing evidence that "acquired characters," in the sense of Lamarck's theory, can be inherited. Nevertheless Lamarck must be credited with having laid out the main lines of the modern Theory of Evolution. His study of fossil invertebrates was of special importance.



FIG. 275 (Left). Erasmus Darwin (1731-1802). (Courtesy, Locy: "Biology and Its Makers," New York, Henry Holt & Co., Inc.)

FIG. 276 (Right). Geoffroy Saint-Hilaire (1772-1844). (Courtesy, Locy: "Biology and Its Makers," New York, Henry Holt & Co., Inc.)

**Geoffroy Saint-Hilaire** was preëminently an investigator of the comparative anatomy of vertebrates. His particular achievement was his demonstration of the "unity of plan" in all vertebrate animals. He gave much attention to the **correspondence** of certain organs of different animals. For example, a foreleg of a quadruped, the wing of a bird, and the human arm correspond anatomically. They are constituted of similar parts similarly related to one another and to the body. In spite of their very unlike form, they *correspond* and must be regarded as the **same** or **homologous** organs. He did not accept Lamarck's causal explanation of evolution, but believed that evolutionary change resulted from direct action of environment on the structures of an organism. Also in contrast to Lamarck, who believed that all evolutionary change was very gradual, Saint-Hilaire maintained that major changes may occur abruptly ("saltatious"—i.e., evolution by leaps). He went so far as to suggest that the original bird may have hatched from the egg of some reptile.

**Cuvier's** great work as a comparative anatomist covered not merely the vertebrates but the whole animal kingdom. His study of collections of fossil bones found near Paris marked the beginning of the science of Vertebrate Paleontology. But he was decidedly fact-minded and so found himself at odds with some of his philosophic contemporaries. He deplored their speculative habit of thinking and claimed that it led them to absurd vagaries. He seemed content with "special creation" as an explanation of the beginning of things. His controversy with Saint-Hilaire, culminating in a debate before the Academy of Sciences

in Paris on February 15, 1830, is one of the classics of biology. Cuvier had the popular side of the argument and the public opinion of his time awarded him the victory over the evolutionists.

Meanwhile **Goethe**, working in Germany, was quite apart from the intellectual turmoil of Paris. He apparently did not even know of Lamarck's writings. In 1790 he published his "Metamorphosis of Plants." His work as an anatomist was concerned mainly with comparative osteology. He gave special attention to the skull and is credited with the discovery of the obscure premaxillary bones in the human upper jaw. His ideas of "unity of type," of vestigial organs, and of the derivation of "higher" from "lower" forms of life run closely parallel to, and in some points anticipate, the ideas of the French evolutionists.




FIG. 277. Cuvier (1769-1832) at the zenith of his power. (Courtesy, Loey: "Biology and Its Makers," New York, Henry Holt & Co., Inc.)

**Oken** gave to biology some sound morphology and much fantastic speculation. He was the most radical of the transcendentalists who sought for unity of plan, or uniformity, not only among various organisms as wholes, but among the parts of an individual organism. They not only sought, but insisted upon finding, uniformity. In some instances uniformity is an inescapable fact. In number and general relations of bones, the skeletons of the pectoral and pelvic appendages are alike. The vertebrae of the neck, trunk, and tail all possess the same general structure, differing merely as to the number and degree of development of the various spines or processes which vertebrae may have. But the uniformity discovered in the "vertebral theory" of the skull is by no means obvious. Yet it is a possible view of the skull. Just as a typical vertebra possesses a solid ventral centrum surmounted by a bony arch (neural arch) enclosing the central nervous organ (spinal cord), so it is possible to resolve the skull into three or four (but Goethe counted six) segments, each consisting of a median ventral bone (Fig. 278) to which are joined other bones extending laterally and dorsally to form a much-expanded "neural arch" surrounding the central nervous organ (brain). This idea seems to have occurred first to Goethe, by whom it was fully elaborated. It was accepted by competent anatomists of later times, including even one so recent as **Richard Owen** (1804-92). It was Oken who pointed out that the human head and trunk are

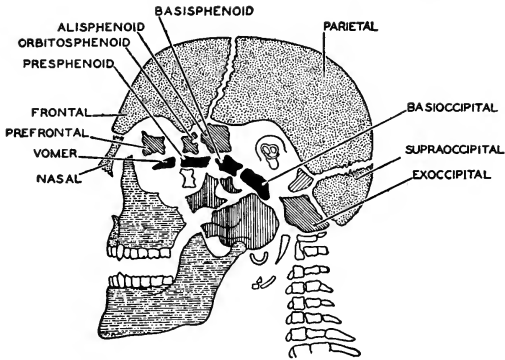


FIG. 278. One of Owen's figures illustrating the Goethe-Oken vertebral theory of the skull. The mammalian skull was conceived to be constituted of four enlarged and modified vertebrae. (After Wilder. Courtesy, Neal and Rand: "Chordate Anatomy," Philadelphia, The Blakiston Company.)

built on the same plan. In the lower part of the trunk is a cavity (abdominal) occupied mainly by organs which are concerned with food. Above is a cavity (thoracic) in which are organs (lungs) concerned with breathing. Between the two cavities is a partition, the diaphragm. Similarly, in the head, the mouth cavity below and the nasal cavities above are, respectively, "abdominal" and "thoracic." The palate, between mouth and nasal cavities, is the "diaphragm" of the head. So far, we follow easily. But, to make the uniformity complete, it is necessary to discover, in the head, the equivalents of the two pairs of appendages of the trunk. Under urge of necessity many a discovery has been made, and so Oken discovered that the right and left halves of the lower jaw are the "legs" and, similarly, the lateral halves of the upper jaw are the "arms" of the head. Granting this, it is obvious that the lower teeth are "toes" and the upper teeth are "fingers." All of this and much more of the same sort was put forth by Oken and his disciples as serious anatomy. It is not surprising that a hard-headed man such as Cuvier lost patience with speculative anatomy.

Study of the history of anatomy makes it clear that the earlier development of the science took place in close association with medicine and surgery. Man's primary interest in anatomy was in himself and with reference to his own physical disabilities. In Aristotle and occasional others, we see men of broader interests. The rapid progress of anatomy in the four centuries following the twelfth took place almost entirely in the medical schools of Italy and France. In earlier times,

public opinion did not tolerate dissection of the human body. Therefore much "human anatomy" was merely inferred or assumed from study of dogs, monkeys, and other backboned animals which could be dissected. While this was literally "comparative anatomy," it was only incidentally comparative. Likenesses to human anatomy, if not assumed, were at least hoped for because of their medical utility. Differences were unfortunate for medical purposes and otherwise had no special significance. The seventeenth and eighteenth centuries witnessed a great expansion of interest. The microscope had much to do with this. The study of living things became increasingly comparative because of the growing conviction—or at least the hope—that a full knowledge of the world of life might have human significance even more important than relief of bodily ills. And from this age emerged the Theory of Evolution, a concept which, to those who held it, gave promise of an answer to the problem of human origin and even hinted at the possibility of throwing light on human destiny.

CHARLES DARWIN AND ALFRED R. WALLACE

The beginning of the nineteenth century found comparative anatomy entering a new epoch. No longer merely the servant of medical science, it had acquired a goal whose achievement would mean a revolution in human thought. At the opening of the century, Evolution was the view of only a small minority. Whether the theory should stand or fall must await a massing of all evidence available from comparative anatomy, comparative embryology, and the as yet little-developed science of paleontology—collectively, Comparative Morphology. This, then, was the great project which biology faced, although at first without clearly seeing it.

During the first half of the nineteenth century, progress was steady but not spectacular. Especially valuable work was done in Germany by **J. F. Meckel** (1781–1833), a student of Cuvier, by **Rathke** (1793–1860), and by **Johannes Müller** (1801–58), eminent both as comparative physiologist and as comparative anatomist. At the middle of the century, a dynamic center developed in England. In 1858 **Charles Darwin** (1809–82) and **Alfred Russel Wallace** (1823–1913) simultaneously announced the theory of "Natural Selection" as the main causal factor in evolution. In 1859 was published Darwin's "Origin of Species." Later appeared "The Variations of Animals and Plants under Domestication" and "The Descent of Man." The most important of Wallace's several books is "The Geographical Distribution of Animals." In comprehensiveness, volume, and richness of accurately reported observations and results of experimentation, Darwin's work greatly exceeded Wallace's.




FIG. 279 (*Left*). Johannes Müller (1801–58).

FIG. 280 (*Right*). Thomas Henry Huxley (1825–95). (Courtesy, Loey: "Biology and Its Makers," New York, Henry Holt & Co., Inc.)

The first half of the nineteenth century was a period of fact-gathering. The evolution theory was not under active discussion. Apparently it was accepted by only a very small and mostly silent minority. The comparative anatomy of the period was strongly impregnated with transcendentalism. It was the fashion to search for unity of plan, uniformity, repetition of similar parts—to try to reduce many things to one thing—and all with little regard for causal explanation. But the need for interpretation was merely somnolent, not dead. The half-century's accumulation of fact built up a state of intellectual high pressure which merely awaited something to release it into open demand for interpretations. The work of Darwin and Wallace effected the release. Evolution at once became the chief subject for scientific discussion. The weight of Darwin's evidence and the clearness of his reasoning were irresistible. The forceful writings and lectures of **Thomas Henry Huxley** (1825–95) greatly strengthened the case for evolution. Within two decades, evolution, in the sense of genetic continuity accompanied by change in form and structure, came to be the accepted view of the great majority of scientists. But opinions differed, as they still do, in regard to the causal factors in the process of evolution.

#### POST-DARWINIAN COMPARATIVE MORPHOLOGY

The post-Darwinian period is marked, first of all, by the consolidation of the grounds for evolution. This was done not so much by making additions to morphologic knowledge as by reinterpretation of the old knowledge. Transcendental anatomy had not been altogether a waste of time. "Archetypes" had served as a useful basis for comparison and analysis of structures. Translation into terms of evolution often re-



FIG. 281. Professor Richard Owen and the extinct fossil bird (*Dinornis*) of New Zealand. (Courtesy, Loey: "Biology and Its Makers," New York, Henry Holt & Co., Inc.)

quired merely that the *imaginary* "archetype" be replaced by a *real* "common ancestor"—but in some instances the common ancestor had to be, at least tentatively, an imaginary "missing link." The existing "natural classifications," based, as proposed by Linnaeus, on general structure, were revised, without great difficulty, to become systems based on genealogic relationship.

Especially in relation to vertebrate anatomy, outstanding figures in the latter part of the century were Owen, Huxley, and Gegenbaur. **Richard Owen** (1804–92) was, in a sense, the Cuvier of the period. In

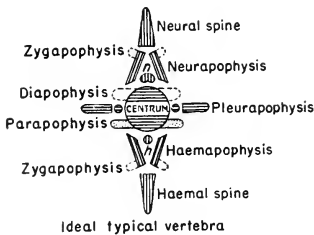


FIG. 282. Archetype vertebra. (After Owen: "Comparative Anatomy and Physiology of Vertebrates," London, Longmans, Green & Co., Ltd.)

1831 he visited Cuvier in Paris and examined his anatomic collections. Owen's great three-volume work "Comparative Anatomy and Physiology of Vertebrates" and his "Odontography," a monograph on the teeth of vertebrates, are anatomic classics and vast storehouses of accurate information. He made important contributions to paleontology by his studies of fossil mammals of Australia and the extinct giant bird, moa, of New Zealand. But, unlike Cuvier, Owen was a transcendentalist.

He constructed an elaborate archetype for the entire vertebrate skeleton. Figure 282 represents his ideal vertebra. It is a composite possessing everything that any vertebra has, and it is a vertebra that no animal ever possessed. He firmly believed in Goethe's vertebral theory of the skull and elaborated on it. But Owen's ideas included none of the fantastic vagaries which discredited Oken's views. Owen may fairly be described as the greatest of the transcendentalists, certainly the sanest of them, and probably the last of them. It is true that a more or less definite current of transcendental thinking can be traced through anatomy down to the present but, since Owen, no more great "archetypes" have been constructed and probably none ever will be.

**Huxley** made important contributions to anatomy and paleontology, as well as to the philosophy of evolution. One achievement, mainly on embryologic grounds, was his demolition of Goethe's theory that the skull is composed of modified vertebrae. **Gegenbaur** (1826–1903) was the foremost German anatomist of the period. His "Vergleichende Anatomie der Wirbelthiere" and his other works are not only indispensable sources of factual information but contribute much to the clarification of the theories and concepts of the science as viewed from the standpoint of evolution.






FIG. 283 (*Left*). Karl Gegenbaur (1826–1903). (Courtesy, Locy: "Biology and Its Makers," New York, Henry Holt & Co., Inc.)

FIG. 284 (*Right*). Ernst Haeckel (1834–1919). (Courtesy, Locy: "Biology and Its Makers," New York, Henry Holt & Co., Inc.)

It was at this period that the theories of **Ernst Haeckel** (Germany: 1834–1919) came into prominence. He was impressed by the fact that metazoan animals pass through an early stage in which the embryo consists of two layers of cells, ectoderm and endoderm, enclosing a cavity which is the prospective digestive cavity, opening to the exterior by way of a single aperture, the blastopore (Fig. 285). This gastrula form, modified in one way or another, occurs almost universally in metazoan embryos. He interpreted it as signifying common ancestry of all metazoans. He created a purely hypothetic common ancestor to which he gave the name "gastreae." In form and structure the "gastreae" was essentially like a gastrula and also similar to a simple two-layered animal (coelenterate) such as *Hydra* (Fig. 285). He pointed out also that the more highly differentiated metazoans not only pass through the supposedly ancestral gastreae stage but later produce various briefly transitory structures whose obvious counterparts in embryos of "lower" or presumably ancestral animals persist to become functional organs of the adult. The temporary presence of pharyngeal clefts and a notochord in embryos of reptiles, birds, and mammals is a striking example of this. On the basis of such facts, he elaborated the theory of "**Recapitulation**" or "**Law of Biogenesis**," which asserted that ontogeny (the embryonic development of the individual) repeats or "recapitulates" phylogeny (the evolutionary development of the race). The essential idea in the theory had been recognized by earlier embryologists, especially von Baer, and was clearly stated by **Fritz Müller** in 1863, but Haeckel first gave it broad application. For a time embryologists, in an excess of zeal for discovering instances of

recapitulation, so strained the theory as to tend to bring it into disrepute. If, however, evolution is to be accepted at all, such things as

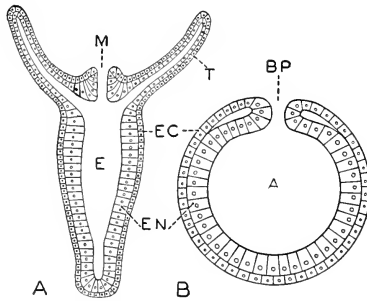


FIG. 285. Diagrams showing structural similarity of a coelenterate and a gastrula. (A) *Hydra*, longitudinal section. (B) Gastrula, axial section. (A) Archenteron, prospective digestive cavity; (BP) blastopore; (E) enteric (digestive) cavity; (EC) ectoderm; (EN) endoderm; (M) mouth; (T) tentacle. (Courtesy, Neal and Rand: "Chordate Anatomy," Philadelphia, The Blakiston Company.)

transitory pharyngeal clefts, aortic arches, and notochords would seem to be open to no more reasonable explanation than that they are due to long-range inheritance.



FIG. 286. Louis Agassiz (1807-73).

Of the two indispensable allies of Comparative Anatomy, **Embryology** owed its rapid advance in the latter part of the nineteenth century largely to **F. M. Balfour** (1851-82) in England and, in Germany, to **Wilhelm His** and, a little later, **Oskar Hertwig**. In America, the work of **Louis Agassiz** (1807-73: Harvard University; founder of the Museum of Comparative Zoology) on the embryology of the turtle was of permanent significance. Outstanding figures in the last two decades of the century

were **W. K. Brooks** (Johns Hopkins University), **C. S. Minot**

(Harvard Medical School), **C. O. Whitman** (University of Chicago), and **Edmund B. Wilson** (Columbia University).

In **Paleontology**, Cuvier's pioneering work was carried forward by **Louis Agassiz** who studied the European fossil fishes in Cuvier's great collection in Paris and published (1833-44) a three-volume monograph on them. The brilliant work of **Charles Lyell** (1797-1875) in England, primarily geologic, but having highly important bearings on the interpretation of fossils, was followed by that of Owen and Huxley, already mentioned, while in Germany the leader was **Karl von Zittel** (1839-1904). In America, three men, **Joseph Leidy** (1823-91), **E. D. Cope** (1840-97), and **O. C. Marsh** (1831-99), devoted their lives to exploration of the extraordinarily rich deposits of fossils in the western United States. A little later, notable contributions to vertebrate paleontology, both factual and theoretic, were made by **Henry F. Osborn** (1857-1935), long associated with The American Museum of Natural History in New York City.

#### TWENTIETH-CENTURY CAUSAL MORPHOLOGY

In the last decade of the nineteenth century, Biology stood at the threshold of a new epoch. Evolution was no longer an issue. To most scientific minds it had become an accepted fact. Biologic knowledge had been rearranged and set in order on the evolutionary basis. But it is not to be inferred that nothing was left for Comparative Morphology to do. While the main lines of the evolutionary picture seemed clearly discernible, a vast number of intricate pieces of the picture puzzle remained to be fitted into place. For Anatomy, there were obscure and poorly understood organs, and numerous animals which had never been fully studied. In Embryology, only a comparatively few conveniently available or supposedly representative animals had been thoroughly studied, and every stage of development presented problems. Paleontology had little more than scratched the surface. While the main trunks of genealogic trees seemed safe enough, many branches were admittedly shaky and the arrangement of the smaller twigs was being changed daily. For anyone inclined toward morphologic work, there was no lack of things to be done, and that still holds true.

But some scientific minds are like an explorer who, having discovered a country, is not content to settle there but must push on in the attempt to discover another. Evolution had been "discovered" and so the more restless minds, accepting evolution as an established fact, began to push into new territory. The causal factors in evolution were still subject to as much doubt and disagreement as ever. "Inheritance of acquired characters" had not been proved. "Natural selection" had been judged inadequate to account for all of evolution. **Weismann**

(1834–1914) emphasized the “continuity of the germ-plasm” from generation to generation and proposed that variations are initiated by varying combinations of the highly complex germ-plasms of male and female parent, with the possibility of direct action of environment on germ-plasm. In 1901 **de Vries**, in Holland, announced his Mutation Theory, which asserted that new species originate in relatively large abrupt variations. Whether or not the form so produced shall persist may then depend on “natural selection.” **Bergson**, French philosopher, proposed that the progressive *creativity* of evolution is the expression of an internally acting nonmechanical factor, a “vital impulse” (*élan vital*).

About 1900, de Vries and other European botanists rediscovered “Mendel’s Law of Inheritance,” lost to science for nearly 40 years. With this highly important addition to the existing assemblage of theories, the stage was well set for the next act in which leading roles were taken by **Biometry** which applied mathematics to biologic data and undertook statistical studies of organisms, especially their variations, and by **Genetics** which, using every available technique of experimentation and of cytology, attacked the problem of the protoplasmic mechanism of inheritance. It is highly significant of the period that in 1903 the Carnegie Institution of Washington organized its Department of Experimental Evolution, and in 1904 established, on Long Island, New York, its research station with a permanent staff of investigators. Meanwhile it became more and more clearly recognized that, whatever the causal factors in evolution, they must in one way or another involve relations between the physical and chemical constitution of living substance and the physical-chemical complex of the environment. Therefore it was necessary, on the one hand, to learn as much as possible about the chemistry and physical structure of protoplasm and, on the other, to find out how experimental modification of the physical-chemical environment will affect protoplasm and its characteristic activities such as growth and cell-division. Also the embryologists turned to experimentation. Development is a process of continual change and elaboration of form. When we see substance changing its form, we want to know what mechanical agency—that is, what actual “push” or “pull” present at the instant—is effecting the change of form. Therefore experimental modification of the immediate environment of the embryo should reveal to what extent and in what way development depends upon external physical and chemical factors. It early appeared that, within certain limits, development is *internally* controlled. Therefore embryos have been subjected to a great variety of operative procedures—removal, addition, interchanges of parts—

with a view to getting some light on the location, mode of operation, and nature of the "internal factors."

A "bird's-eye view" of Biology as it moved forward into this twentieth century reveals the science advancing on three main fronts. One includes **Biophysics** and **Biochemistry**. A second consists of **Biometry** and **Genetics**, which are investigating the *processes* of inheritance and evolution. A third, **Experimental Morphology**, includes experimental embryology, the study of regenerative development in adult organisms, and experimentation of any sort calculated to yield information concerning the dynamics of form in living substance. The three fronts, however, are not sharply distinct. They overlap and the subjects are interdependent. Comparative Anatomy, or, more broadly, **Comparative Morphology**, describing normal form, is the indispensable foundation on which all systematic, physiologic and experimental biologic work must be based.



# Aim and Method of Comparative Anatomy

10

---

Comparative anatomic description is of little interest and of no scientific value unless it can be made to yield meaning. Facts of vertebrate comparative anatomy played an especially important part in the beginnings of the Theory of Evolution. Much of the strongest evidence which led to general scientific acceptance of the theory was derived from vertebrate anatomy and embryology. The theory has great human significance. Aside from the practical importance of vertebrate anatomy in relation to Medicine, its primary scientific importance is in its bearing on the problems of Evolution.

Since the time of Lamarck, therefore, the dominant purpose of Comparative Anatomy, always allied with Comparative Embryology and Paleontology, has been the obtaining of such knowledge as will either establish Evolution as a fact or else compel discarding the theory. In so far as the evidence justifies acceptance of the theory, the further business of Comparative Anatomy is to work out the complete evolutionary history and relationships of animals—and Man is a back-boned animal. In going about this latter business, how shall Comparative Anatomy proceed?

The **method** of the science is implied in the name **Comparative Anatomy**. The principle is very simple. Animals are judged to be closely related or more or less distantly related according to whether they are anatomically closely similar or more or less unlike. In practice, it is far from simple. It is difficult to find accurate measures of anatomic difference. Also it often happens that two animals may be closely similar in nearly all respects, but very unlike in one or two points, or else mainly different and yet, in some conspicuous way, alike. Further, in the mere process of comparing, various perplexities are encountered.

Animals can be compared as wholes with respect to external features such as color, size, form of body, and appendages. Complete comparison, however, requires that the animal be taken apart and compared part by part. Then the question arises, what parts should be compared? The obvious answer is "corresponding parts." The brain of one animal is to be compared with the brain of the other animal, heart with heart, and so on. Of course, any two things *can* be compared. If a brain be compared with a liver, some similarities may be found and many marked differences will be found. But the net result has no special significance. It seems obvious that it would be equally futile to compare a breathing organ with a sense-organ. Experience, however, teaches that it is wise to be careful about the obvious. To the ancients the world was obviously flat. As a test case, let us compare a simple

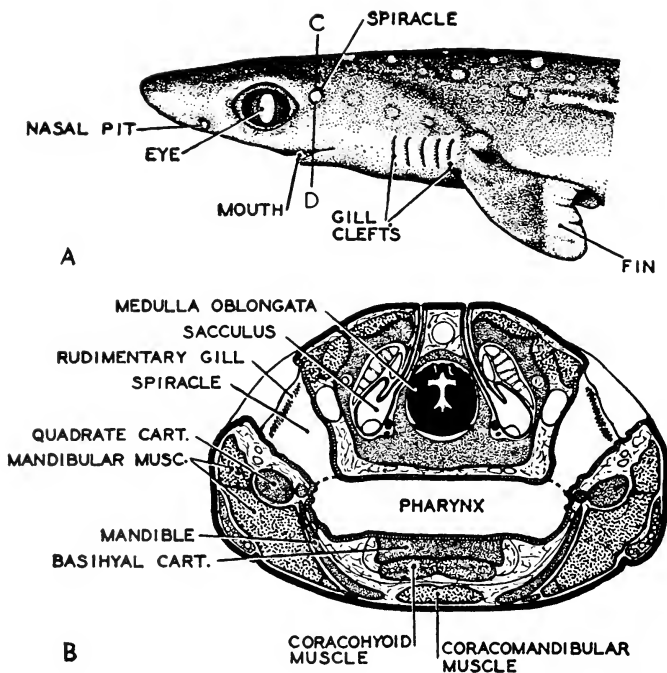


FIG. 287. Dogfish head. (A) Side view. (B) Cross section at plane indicated by the line C-D in the side view. (Modified from Neal and Rand: "Chordate Anatomy," Philadelphia, The Blakiston Company.)



breathing organ of a fish with the highly complex auditory organ of a mammal.

In the common dogfish, a small shark, there are six pairs of respiratory passages leading from the pharynx to the exterior (Fig. 287). On the walls of all of these, except those of the first (most anterior) pair, are well-developed branchial "filaments," thin projecting plates of soft tissue densely filled with minute blood-vessels (Fig. 56). These are the essential respiratory structures. The passages of the first pair, known as spiracles, are short and broad or more nearly tubular as compared to the thin, flat gill-chambers, and gill-filaments are only very weakly developed in the spiracle, which is merely a passage for water. The mammalian ear (Fig. 288) consists of three divisions. The more or less funnel-like external ear leads into a broad passage (meatus) which terminates against a taut tympanic membrane. The essential nervous part of the ear is the complex "inner ear" embedded in the bone of the skull. Between the tympanic membrane and the inner ear is the tympanic cavity ("middle ear"), which communicates with the nasal region of the pharynx by a long, narrow passage, the Eustachian tube. Swung across the tympanic cavity are three very small bones movably jointed together, and so forming a chain whose outer end is attached to the tympanic membrane, while the inner end is movably inserted into a

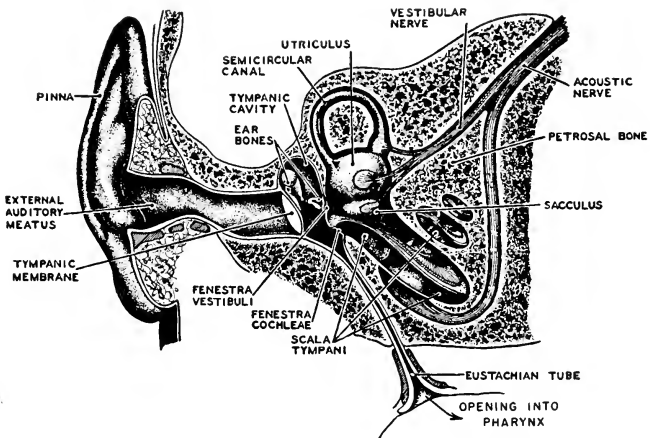


FIG. 288. The human ear; diagrammatic section showing its three divisions. External, consisting of the pinna and the auditory meatus. Middle, the tympanic cavity. Internal, including the utriculus with its three semicircular canals and the sacculus with its spiral cochlea. (After Howell and Czermak. Courtesy, Neal and Rand: "Chordate Anatomy," Philadelphia, The Blakiston Company.)

small aperture in the thin wall between the tympanic cavity and the space within which the inner ear lies. This chain transmits vibrations from the tympanic membrane to the fluid which fills the thin space between the wall of the sensory internal ear and the bone surrounding it.

Comparing the shark's breathing organs with the mammal's auditory mechanism, three points of resemblance are noted. The shark's spiracle opens on the surface of the head at about the place where an external ear might be expected, if the shark had one. Secondly, the spiracle leads from the pharynx to the exterior, and so would the Eustachian tube lead from the pharynx to the exterior by way of the external auditory canal (meatus), if the passage were not closed by the tympanic membrane. Thirdly, the sensory ear of the shark, a nervous structure resembling the "inner" ear of the mammal, but much simpler, is enclosed within a lateral projection of the posterior region of the cartilaginous cranium (Fig. 115C), and the spiracular cavity is situated very close to the wall of this auditory region of the cranium, just as the tympanic cavity is close to the inner ear of the mammal. No other resemblances appear in the adult organs—but now we recall that paired pharyngeal pouches, usually piercing to the exterior, are present in *all* vertebrate embryos.

In the dogfish embryo there are six pairs of pharyngeal pouches, all opening externally. Those of the most anterior pair become the spiracles of the adult. The others become the five pairs of gill-chambers. In mammals the embryonic pharyngeal pouches ordinarily do not penetrate to the exterior and they are soon completely obliterated, *except those of the most anterior pair*. These pouches, judged by their relations to neighboring embryonic parts, clearly correspond to those which, in the shark, perforate and form spiracles. In the mammalian embryo each of these pouches extends toward the lateral surface of the head and *almost perforates*, but remains closed by a thin membrane consisting of the ingrowing external layer (ectoderm) of the embryo closely joined with the outgrowing wall (endoderm) of the pharynx. *This double layer persists as the tympanic membrane*. In later development the pouch becomes elongated and changed in form, appearing in the adult as the tympanic cavity and Eustachian tube. The three small ear-bones of the mammal arise from embryonic parts corresponding to those which, in the embryos of fishes, give rise to certain skeletal elements of the jaw mechanism (Fig. 520).

Comparison of the breathing mechanism of a shark with the auditory mechanism of a mammal leaves us in some perplexity. Viewing the two mechanisms as wholes, there would seem to be no correspondence between them. There is certainly none as to function. Resolving the

mechanisms into their anatomic elements, we discover some resemblance between the spiracle and certain cavities of the ear. Turning to the embryos, we find that the most anterior pharyngeal pouches become spiracles in a fish and "middle-ear" cavities in a mammal, while certain embryonic parts in a mammal produce two of the three ear-bones and corresponding parts in a reptilian embryo produce the two bones which serve as the members of the joint between the upper and lower jaw.

It would seem that a kidney should correspond to a kidney. As organs of excretion, they correspond functionally. If a mammalian kidney is compared with that of a fish or amphibian, it will be found that there is general similarity in structure, although there are some differences. But in their embryonic histories they do not correspond. As to the position and source of the embryonic kidney-forming material, and in manner of development, they are very different. Further, the mammalian embryo produces *temporary* renal structures which correspond anatomically to the kidneys of fishes and amphibians.

Lungs and gills correspond in function. In gross anatomy they are totally different. In bodily position they are far apart, but a point of resemblance is found in the fact that gill-chambers open into the pharynx and lungs connect with the pharynx by way of the trachea ("windpipe"). In the embryo lateral pharyngeal pouches produce gill-chambers, and a single median ventral outgrowth of the wall of the pharynx produces lungs.

In the foregoing comparisons we have encountered correspondences in function, position, structure, and embryonic origin. But, for the purposes of comparative anatomy, confusion arises from the fact that two organs may correspond in one or more of these particulars but not in all of them. Adult organs (e.g., kidneys) which are so similar that they would seem to correspond may have very different embryonic origins. Corresponding embryonic parts may produce organs which, in the adults, are totally unlike in structure and function. The vital question comes to be, then, *what kind of correspondence is relevant to our purpose?*

If an animal be compared with one of its parents or grandparents, there is no confusion about correspondence—unless some major mutation has occurred. Organs which *seem* to correspond *do* correspond, brain to brain, eye to eye, heart to heart. We may speak of an organ as being **the same organ** as the corresponding organ of parent or grandparent. In the remainder of this discussion, the word "same" will be used to signify **correspondence due to inheritance**. Evolution, however, implies change. If we were to compare two animals which are many thousands of generations and millions of years apart, we might

find that a certain organ of the ancient ancestral animal had become so changed that we could not recognize it in the recent animal. Jaw-bones may have become ear-bones. It is imaginable, too, that some organ of the ancient animal may, in the course of long evolution, have undergone degeneration and completely disappeared. Then, in the later history of the same race, a new organ may have appeared and become so like the earlier organ that, not knowing the intervening history, we would naturally make the mistake of regarding the recent organ as the "same" as the apparently corresponding organ of the remote ancestor. Some whales have a median dorsal fin which seems to correspond to a median fin of a fish. They do, in fact, correspond in function, but they cannot be the *same* if, as the evidence indicates, the immediate ancestors of whales were land mammals.

For the purpose of working out the genetic relationships of animals, we need some way of measuring the genealogic distance between animals. From the foregoing discussion, it appears that comparison of animals as wholes gives us no adequate measure. They must be compared part by part. Further, it becomes clear that the only measure significant for our purpose is derived from comparison of an organ of one animal with that organ which, in another animal, is genetically identical with the first—the *same* organs, however different in position, form, or function.

#### ANALOGY AND HOMOLOGY

It is not surprising that the early comparative anatomists were confused by the fact that organs of different animals might correspond in some ways and not in others. It was Geoffroy Saint-Hilaire who first gave special attention to this problem. Convinced of the "unity of plan" of all vertebrates, he asserted in his "Théorie des Analogues" that the same parts or units of structure occur in all vertebrates and he designated the corresponding parts as "analogues" (Fig. 289). For recognition of "analogous" parts in different animals, he depended not so much on form and structure but mainly on *position* and especially "position" in the sense of the spatial relations of a part to neighboring parts and their attachments to one another—the "principle of connections." He was not always consistent, however, and some of his "analogies" depended more on function than on position and connections. He did not clearly recognize genetic relationship as being the basis for his "analogies."

Richard Owen, in the preface to his "Comparative Anatomy and Physiology of Vertebrates" (1866), criticized Saint-Hilaire's use of the word "analogy." Owen pointed out that "analogy" signifies "a likeness of ratios"—that is, similarity of relation. Therefore it may prop-

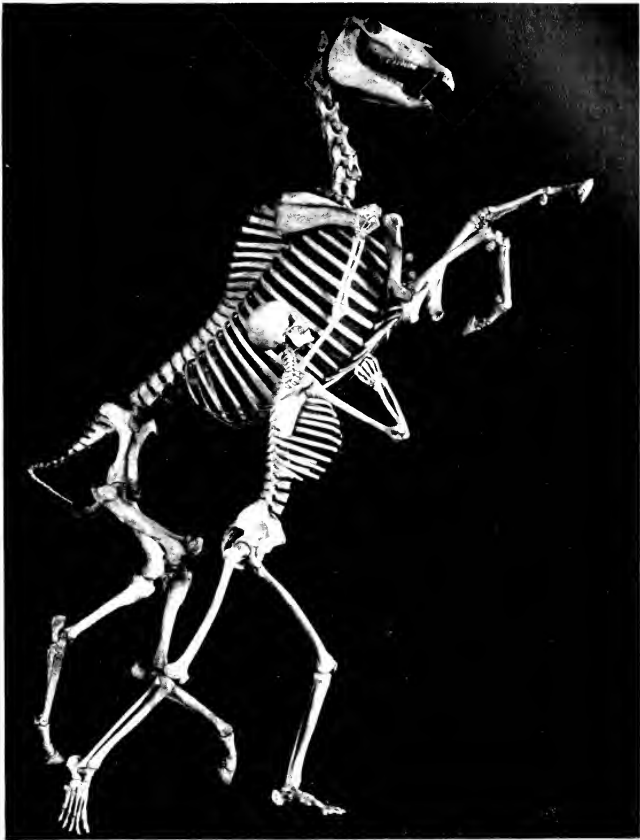

FIG. 289. Skeletons of horse and man. Corresponding skeletal parts are mounted in approximately parallel alignment. (Courtesy, American Museum of Natural History, New York.)

erly be applied to correspondence in function. But when a certain organ in one animal is the *same* organ as that in another animal, the relation demands a word signifying "sameness." Such a word is "**homology**," from the Greek word meaning "identical." The tail-fin of a fish and the screw-propeller of a motorboat are analogous, both being mechanisms of propulsion. But they are not homologous.

The word "homology" had been used in anatomy before Owen's

time, but in a very loose way. He offered the following definitions: "A 'homologue' is the same part or organ in different animals under every variety of form and function." And again, a " 'homologue' is a part or organ in one organism so answering to that in another as to require the same name." Elsewhere he defines homology in one word, "namesake-ism." It is noteworthy that the idea of genetic relation does not enter into his definitions, but near the end of his long preface appears the statement, "The most intelligible idea of homologous parts . . . is that they are due to inheritance."

Gegenbaur further clarified the concept of homology. He—as did Charles Darwin and Haeckel—recognized inheritance as the essential basis of homologies. Owen had applied the term "special homology" to the correspondence between organs of different animals and "general homology" to correspondence of similar parts within the body of an individual animal. Gegenbaur elaborated on Owen's distinction and defined several types of "special" and "general" homology as follows:

### Special Homology.

**Complete:** when all of the parts of an organ in one animal are represented in the homologous organ of another animal.

**Incomplete:** when not all of the parts of the one organ are represented in its homolog. An "incomplete homology" is "**defective**" when, in the course of evolution, the original organ loses some of its parts. The foot of the modern horse has only one functional toe, in contrast to the five of the foot of the supposed ancestral mammals. The incomplete homology is "**augmentative**" when, in the course of evolution, an organ acquires more parts. The heart of a mammal corresponds to the heart of a fish plus the venous sinus, a receiving chamber lying immediately behind the heart of the fish.

### General Homology.

**Homotypy:** bilateral correspondence. Right eye and left eye are "homotypic" organs.

**Homodynamy:** correspondence of parts arranged in a linear series along the main axis of the body—i.e., serial homology. Vertebrae of the several regions of the vertebral column have the same general structure. The neural arch of one corresponds to the neural arch of another—they are "homodynamic" parts.

**Homonomy:** the relation of similar multiple parts which lie in an axis transverse to some long axis. The several fingers are "homonomic" parts.

**Homonymy:** the relation of similar parts lying in some minor long axis. The several segments (phalanges) of any one finger are "homonymic" parts.

The term "**homomorphic**" has been applied to such things as hairs, which are similar in general structure but have no definite relation to axes of the body.

These names which have been applied to the several types of "general homology" are not important, but they have been mentioned as a means of emphasizing the fact that "repetition of parts" is a common and important feature of animal structure and that the occurrence of such repetition in various axial relationships results in internal correspondences of definitely different sorts.

History shows that the concept of homology has undergone a slow evolution. To the anatomists of a century ago, homology (or "analogy," indifferently) was a correspondence based on function, structure, position, connections, and anything else. To Owen, it was a vaguely defined set of structural (but not functional) resemblances which led him to feel justified in giving the "same name" to organs of two different animals. It is as if by an afterthought that he suggests that inheritance is probably at the bottom of his "namesakeism." Charles Darwin and Haeckel realized clearly enough that homologies depend upon inheritance. But now it has become quite clear that the idea of Homology, if Comparative Anatomy is to use it as the tool for digging out the histories of races of animals, must be rigidly restricted to **genetic correspondence** of parts. This necessity is recognized in the admirable definition offered by **T. H. Montgomery, Jr.**\* (University of Pennsylvania), in 1902. He defined homology as "**a relation of genetic descent.**" **Hatschek**, in 1888, expressed the same idea but in many more words.

It is true that homologous organs are usually similar in many or even in all respects, including function. But Montgomery's definition recognizes the possibility that two organs which are different in all particulars are the *same* organ if they can be traced to common genetic origin. Resemblances in form, structure, position, and connections may point to the conclusion that two organs are homologous, but such resemblances, in themselves, do not constitute homology.

It is necessary that the "relation of genetic descent" be clearly understood. It does not involve any *direct* relation of one organ to another. A brain is not descended from the brain of an ancestor, whether remote or immediate. The relation between organs which are "the same" in animals of successive generations is an indirect one depending on the production of successive individuals from a continuous germ-plasm (Fig. 290). In a strict sense, a metazoan animal, repro-

\* Montgomery, T. H., Jr.: On Phylogenetic Classification, Proc. Acad. Natur. Sc. 54:187-232, Philadelphia, 1902; The Analysis of Racial Descent in Animals, New York, Henry Holt and Co., 1906.

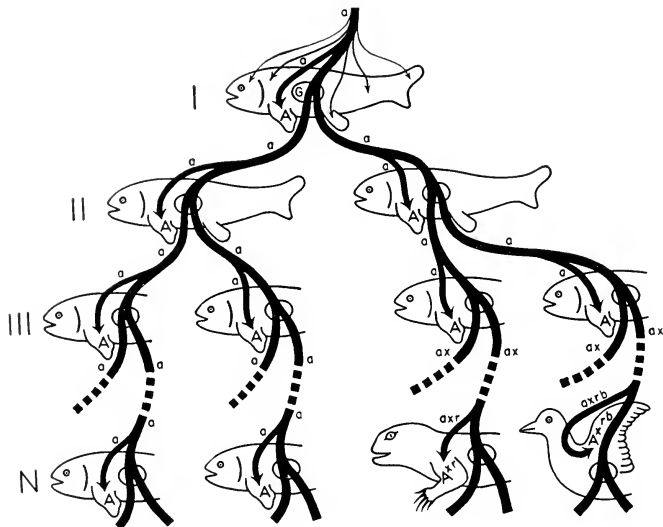


FIG. 290. Continuity of the germ-plasm, the basis for homology.

Each animal outlined in the diagram must be regarded as representing both male and female parent. The heaviest lines represent the main line of germ-plasm passing from one adult generation to the next via the fertilized egg and the developing embryo. In the single ( $\sigma + \text{♀}$ ) individual of Generation I the several fine lines suggest the distribution of embryonic products of the germ-plasm to form the several parts of the animal. *G* is the gonad. The organ chosen for special consideration is the pectoral fin. *A*. The complex of germinal factors determining the development of *A* is represented by *a*.

Along the left one of the two lines of germ-plasm proceeding from Generation I, no change occurs in *a* through Generations II and III and thence onward through an indefinitely great number of generations to the Nth generation (N) in which *A* is still a fish fin.

Along the right one of the two lines of germ-plasm, *a* persists unchanged into Generation III. But in some of the members of III it undergoes change and emerges as *ax* and the adult organ in succeeding generations becomes *A<sup>x</sup>*. In the course of an indefinitely great number of generations (the broken lines indicating their omission from the diagram), additional modifications are incurred. The *ax* becomes *axr*. Meanwhile correlated modifications occur in the germinal factors which determine other organs, with the result that, at the Nth generation, *A<sup>xr</sup>* is a foreleg of a reptile. Along another line of descent proceeding from Generation III, *axr* undergoes still further modification and becomes *axrb* which produces an organ *A<sup>xrb</sup>*. Meanwhile, correlated changes occur in the other organs, and eventually *A<sup>xrb</sup>* appears as a bird's wing.

Organs *A*, *A<sup>x</sup>*, *A<sup>xr</sup>*, and *A<sup>xrb</sup>* are homologous because they all possess the basic *a* which has come down to them via the germ-plasm from the common ancestor, Generation I.



ducing sexually, does not give rise to new individuals. They are derived, not from the parental animal as a whole, but entirely from the localized germ-plasm of the parents. The germ-plasm, becoming differentiated into eggs and spermatozoans, produces the entire body of a new individual including, along with the various other constituent organs of that body, the gonads, which are simply more germ-plasm derived directly from the parental germ-plasm and destined to produce individuals of the next generation.

The development of "the same" adult organ "A" (Fig. 290) in all individuals of successive generations results from the presence of a determining factor, or complex of factors, "a" (the "determinants" of Weismann; the "genes" of modern genetics) in the germ-plasm. This "a" ordinarily persists unchanged from generation to generation for an indefinitely great number of generations and, accordingly, the "A" organs of all the numerous individuals of the many generations are not only homologous but are substantially alike in all respects. If, however, a change somehow occurs in the germinal "a" complex, the organ "A" will be changed in one or more particulars. Experiments show that such a change may be restricted to a single germ-cell, so that only one adult individual among the several of that generation may show the variation or mutation in organ "A." The changed germinal factor may be indicated by  $ax$  and the modified organ by  $A^x$ . Once initiated, and provided that the change in the organ is favorable for the individual, or at least not unduly harmful, the change may be perpetuated indefinitely through successive generations of descendants, if bred only among themselves. Further, it appears to be possible that the original alteration may be augmented by additional successive variations or mutations, and that changes affecting other characteristics of the organ may be added so that, in the course of time, the organ may become  $A^{xx}$  and, still later,  $A^{xrb}$ , an organ so unlike "A" that the comparative anatomist might see no reason for suspecting that the two organs were related in any way. If, however, he were able to trace back along the continuous germ-plasm and so discover that  $axrb$  (the germinal basis for organ  $A^{xrb}$ ) arose by modification of  $ax$ , which, in turn, arose by a change in the ancient "a" he would be led to conclude that  $A^{xrb}$  is the homolog of "A" and of all modified "A" organs, whether of contemporary or of most ancient animals. He would conclude also that a long course of evolution must have intervened between the ancient "A" and the recent  $A^{xrb}$ , and that accordingly the animals possessing  $A^{xrb}$  are only very distantly related to those having "A." But the two organs, however different in form and function, are "the same" by virtue of their "relation of genetic descent."

Figure 290 illustrates a specific case, the modification of the pec-

toral fin "A" of an ancient fish, to become the foreleg  $A^x$  of a reptile and, with further modification, to become a bird's wing  $A^{xb}$ .

#### PARALLELISM, ADAPTIVE RADIATION, CONVERGENCE

Certain results of experimental genetics introduce some complication into the concept of homology. Reverting to Fig. 290, if the change which converted "a" into ax is represented as having occurred in only a single individual, all the other members of the generation retaining the old organ "A," that individual would be the "common ancestor" of races of animals possessing  $A^x$  or various modifications of  $A^x$ . There is reason to believe, however, that *similar modifications* of an organ may arise in several or many individuals of a species quite independently, at different times and at geographically distant points (Fig. 291). If this should happen, the "common ancestor" of animals having some particular modification of organ "A" would be not any individual animal (or pair), but rather the species—or, collectively, the germ-plasm of the species. Nevertheless, the modified "A" organs are related by genetic descent, whether the "common ancestor" is to be thought of as an individual animal, or as numerous individuals whose germ-plasm is the similarly constituted germ-plasm of all members of the species, or as merely the primitive germ-plasm itself.

It is apparently possible, therefore, that two or more lines of descent (Fig. 291,  $A^f$ – $A^f$ ) originating within the same species (not from a single individual or pair), but otherwise quite separate from one another in time or geographically, may undergo progressive modifications which are closely similar or even identical in nature. The result would be that new types of animals produced along the several lines could be classified as belonging to the same or closely allied species. This parallel but separate evolution of similar structure, whether affecting a single organ or an entire organism, is appropriately called "**parallelism.**" (Unfortunately that term has sometimes been confusingly applied to another evolutionary process better known as "convergence" (see p. 367).)

Figure 290 illustrates the genetic modification of only the one organ, "A." As a matter of fact, change in one organ is usually associated with changes in others. It may be imagined, then, that the individual shown on the right in Generation II of the diagram is the point of departure of lines of descent which come to differ from one another in that the variations or mutations which occur from time to time in several or most of the organs are not alike in all the lines. It may be imagined further that unfavorable changes are weeded out by "natural selection," with the result that the progeny differentiate into several new species, or larger groups, adapted to various environments

and modes of life. In such a case, a single genetic point (an individual or a species) is the origin of lines of progressive modification which diverge into diversity—**adaptive radiation** (Fig. 291).

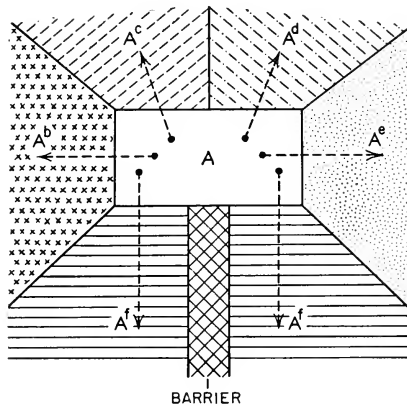


FIG. 291. Adaptive Radiation and Parallelism.

The central territory (white) is the primitive habitat of a group of animals (A). This territory is surrounded by regions which differ from it and from one another in their physical and biologic characteristics. The primitive group invades all of these regions, undergoing structural modifications appropriate to each of the different environments. If A is a genus, A<sup>b</sup>, A<sup>c</sup>, A<sup>d</sup>, and A<sup>e</sup> may be species—Adaptive Radiation.

The region south of the central territory is homogeneous in its characteristics, but it is divided into eastern and western areas by a barrier which is impassable to animals of the A group. The group invades the two areas. The original invaders were genetically similar. Encountering similar environments on either side of the barrier, the eastern and western races (A<sup>f</sup>) undergo similar adaptive modifications—Parallel Evolution.

The reverse of adaptive radiation is a possibility, and one which has been realized—to the confusion, at least temporarily, of comparative anatomists. From two or more points far separated from one another in time, place, and genetic relationship, there may arise lines of progressive modification which converge into similarity (Fig. 292). Striking examples of such **convergence** are found among the aquatic vertebrates. Whales, sea cows, seals, sea lions—all mammals, have more or less definitely fishlike form of body and, in general, similar adapta-

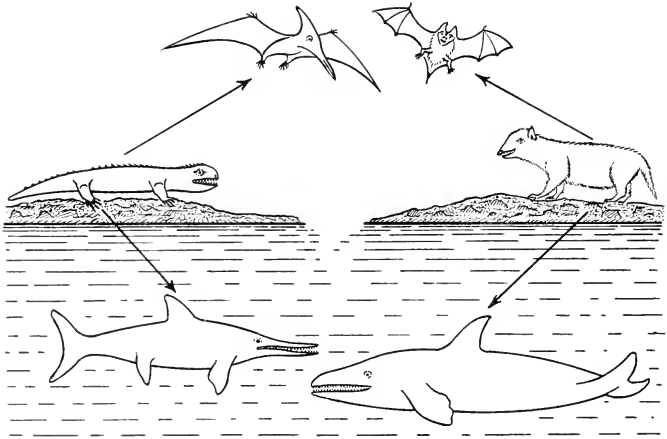


FIG. 292. Convergence. (*Above*) The pterosaur, an ancient reptile, and the bat, a later mammal, acquired similar adaptations for flight. (*Below*) The ichthyosaur, an ancient reptile, and cetaceans, later whalelike mammals, acquired similar adaptations for aquatic life.

tions to aquatic life. They might reasonably be supposed to be more or less closely related, particularly the whale and sea cow with their similar finlike pectoral flippers, with only internal vestiges of pelvic appendages, and with similar horizontal tail-fins. But the evidence from all sources—internal anatomy, development, and paleontology—indicates that the aquatic adaptations of these animals go back to no mammalian common ancestor. Sea cows trace back to early hoofed animals. Seals and sea lions are carnivores, remote relatives of dogs and cats. There is some evidence that even the seals and sea lions have had separate origin, the “earless seals” (i.e., without external ears) having possibly come from some otter-like ancestor, and the “eared seals” (sea lions and fur seals, having small external ears) being derived from bears. Figure 293 shows the close similarity, as regards external features, of a shark, an extinct aquatic reptile, and an aquatic mammal. But these similarities cannot be due to any “relation of genetic descent” because the immediate ancestors of the ichthyosaur must have been land reptiles and those of the porpoise were land mammals.

**Convergence** has produced snakelike animals of several sorts. In addition to snakes there are the legless lizards, in external features closely resembling snakes, and certain tropical burrowing amphibians (caecilians) which, at first sight, might be mistaken for small snakes. There are many instances, too, in which the convergence is restricted

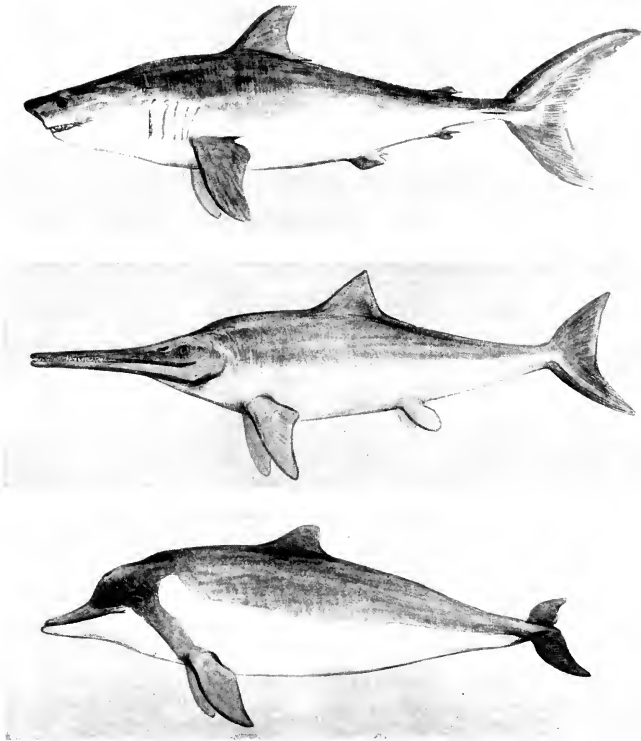


FIG. 293. Convergence. Adaptation for swimming in fish, reptile, and mammal. (Top) Shark, a fish. (Center) Ichthyosaur, an extinct reptile. (Bottom) Porpoise, a modern mammal. (Courtesy, American Museum of Natural History, New York.)

to a single organ instead of involving the whole body. Stiff, sharp spines, such as are produced by the skin of our common porcupine, occur also on the European hedgehog and on the "spiny anteater" of the Australian region—animals genetically very far apart (Fig. 294). The "flying membrane," a broad fold of skin extending along the side of the body from foreleg to hindleg, is similarly developed in flying squirrels (rodents) and in flying phalangers (Australian marsupials), and reaches its extreme differentiation in bats (Fig. 547). The East Indian "flying lemur" (*Galeopithecus*; affinities uncertain) has flying membranes very much like those of the squirrel (Fig. 593). The wings of the pterodactyls, extinct flying reptiles, were similar to those of



FIG. 294. Convergence in modification of hairs to become stiff, sharp spines. (Top) Porcupine, a rodent. (Bottom, left) Hedgehog, an insectivore. (Bottom right) Spiny anteater, a monotreme (Top, Courtesy, American Museum of Natural History, New York. Bottom, Courtesy, Museum of Comparative Zoology, Harvard University.)

modern bats (Fig. 439). But, so far as we know, the earliest mammals were all nonflying. The flying membranes of these several animals must have had independent origin—admitting, however, a remotely possible genetic relation between the wings of the bat and the flying membranes of *Galeopithecus*.

#### CRITERIA OF HOMOLOGY

The method is *comparison*. The parts to be compared must be related by genetic descent—*homologous parts*. Relationship between two animals is to be judged according to the *degree of similarity* between their homologous organs. The great difficulty which the anatomist encounters lies in the fact that so many homologies are not self-evident. Homology may be obscured by profound structural difference of the

organs. Organs which are not homologous may correspond in function and structure and therefore appear deceptively like homologs. It is precisely these obscured homologies and misleading semblances of homology that are most important because it is they that most positively indicate radical evolutionary change and genetic distance between the animals concerned. Therefore the anatomist's first and most difficult task is to discover the hidden homologies and to expose the falsity of the pseudohomologies. His all-important question is, *how may homology be recognized?*

There is no single and infallible criterion of homology. Each case must be considered on its own merits. The germ-plasm is continuous only from its present into the future. Its past is marked only by a trail of discontinuous fragments of the organisms which it produced in past thousands and millions of years. The animal lying on the dissecting table today is merely a recent and more nearly complete relic of the germ-plasm. It is true, however, that the experience of nearly a century of evolutionary morphology has given us a little appreciation of the relative values of our comparisons.

Comparison of two animals requires that the animals be dismembered and compared organ by organ. Similarly, two organs cannot be compared immediately as wholes. They must be resolved into their several characteristics, which may then be considered one at a time. Experience teaches that some characteristics are much more significant than others in the testing of homologies. **Color** is of little, if any, significance. It is true that spleens are usually deep red and a pancreas is yellowish or brown, but these colors are merely incidents of difference in the underlying structure. The spleen is more richly filled with blood-vessels. **Size** has merely functional significance. The hearts of mouse and elephant are certainly homologous.

**Number** of such multiple parts as vertebrae and muscle segments is usually of little significance. Animals which are certainly very closely related may have quite different numbers of myomeres, vertebrae, and ribs. Modern sharks have six, seven, or eight pairs of pharyngeal gill-clefts. In some organs, however, number seems to have become firmly fixed—the paired appendages, for example. When we find a vertebrate with only one pair or none at all, we are confident that the deficient animals are genetically far removed from ordinary four-finned or four-legged vertebrates. In land vertebrates the number of major jointed segments arranged successively along the main axis of the appendage is fixed. Shoulder girdle, upper arm, forearm, wrist, and hand correspond respectively to hip girdle, thigh, shank, ankle, and foot. These divisions remain numerically constant whether the appendage is the foreleg of a giraffe, the hindleg of a kangaroo, or any leg of a dachshund.

There is some variation, however, in the number of segments (phalanges) in a finger or toe. Functional adaptation is effected by changing proportions of segments and sometimes by the fusion of neighboring bones (leg of bird; hindleg of frog: Fig. 295). In mammals the number of vertebrae in the neck is nearly always seven. The exceptions are the manatee (a sea cow) with six, and certain sloths having six, eight, or nine. In birds the number of cervical vertebrae varies with the length of the neck, but among mammals the number is seven in mouse and man, in the giraffe, and also in the whale. In the latter, the seven vertebrae are shortened into flat disks and more or less fused together.

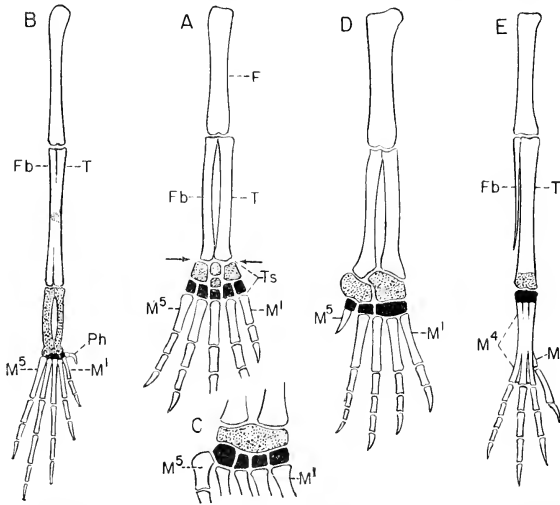


FIG. 295. Adaptive modifications in the skeleton of the hindleg. (F) Femur; (Fb) fibula; (M<sup>1</sup>, M<sup>4</sup>, M<sup>5</sup>) metatarsals; (Ph) prehallux; (T) tibia; (Ts) tarsus. Distal tarsals, solid black; proximal tarsals, stippled.

The primitive hindleg (A) consists of three long segments—thigh, shank, and foot. The frog's hindleg (B) acquires a fourth by elongation of proximal tarsals, the tibiale and fibulare. In birds (E), fusion of elongated metatarsals produces a segment whose length is further augmented proximally by addition of the distal tarsals all fused together and solidly joined to the metatarsal complex. The proximal tarsals, likewise fused together, are solidly joined to the distal end of the tibia.

The bird's ankle-joint, interposed between the tibio-tarsus and tarso-metatarsus, is a midtarsal joint and therefore does not correspond to the primitive ankle-joint (indicated by arrows in A) which is between shank and tarsus.

The bones of the reptilian tarsus (C, turtle; D, crocodilian) tend to segregate into a proximal group and a distal group, within each of which occurs more or less fusion—a condition suggestive of a midtarsal joint.

The additional long segment in the leg of frog and bird is of mechanical advantage in the leaping and hopping activities of these animals.



**Form and structure** must be carefully considered. In general, homologous organs are similar in form and structure. But it must never be forgotten that form and function are vitally related. Organs which are not homologous may perform similar functions and, accordingly, may have similar form and structure. The cuttlefish (*Sepia*, a cephalopod mollusk) has an eye whose very complex structure is closely similar to that of a vertebrate eye, but there can be no genetic relation between the two. External form is much less significant than internal structure. In external form, the horse's front leg, human arm, bird's wing and whale's flipper are very different, but the internal structure of all of them is, with adaptive modifications, that of a typical pectoral appendage. Livers are highly variable in form. Lungs range from the simple slender tubular sac of tailed amphibians (urodeles) to the massive several-lobed mammalian lung minutely subdivided internally. Brains, by contrast, are more stable in form. All vertebrate brains show externally five main divisions. Differences in the form of the brains of various vertebrates consist mainly in differences in the relative bulk of the several regions.

In so far as form is independent of function (e.g., as in the gross form of a liver), it is, so to speak, left free to vary according to the incidental circumstances in which the organ finds itself. A liver looks as if its form had been impressed upon the organ by impact of neighboring organs. The extreme difference between the form of a feather and that of a hair throws grave doubt upon their homology but, taken alone, is not sufficient to prove that a feather is not a highly elaborated hair. Facts quite apart from the difference in form make it likely that feathers and hair had common origin in horny scales of reptiles and therefore are only remotely homologous.

Structure implies differentiation of constituent parts and a set of definite and correlated relations of one part to others. All of this, again, hangs upon function. Nevertheless, it is possible that a considerable change in the function of the whole and in the external form of the whole may occur without so radically altering internal structure as to make the organ unrecognizable as the original organ. The flipper of a whale looks like the fin of a fish, but the internal structure of the flipper (Fig. 579) corresponds to that of the foreleg of a land mammal. The flipper as a whole is homologous with the pectoral fin of a fish, but the *immediate* homologies of the bones constituting the skeleton of the flipper are with bones of the foreleg of a quadruped, the wing of a bird, and the human arm.

The **grade of structure** to which the anatomist must give chief attention in his search for homology is that of the **organ**. The structure of the tissues and cells of which the organ is constituted should not be

ignored but, in general, cellular structure and histologic structure have little or no significance in relation to homology. Types of architecture cannot be classified on the basis of building materials. A Gothic church or a modern office building may be constructed of bricks of the same sort. Skull bones are histologically similar regardless of homologies. Glandular structures of various sorts may be histologically very much alike. But this does not imply that the anatomist need not use his microscope. Many elementary organs are of microscopic size. Renal tubules and hepatic tubules are, respectively, elementary constituent organs of those larger organ complexes, the kidney and liver. *Microscopic anatomy* must be distinguished from *histology*.

In contrast to the characteristics mentioned above, **position of organs** is of great significance—but the comparative anatomist uses that word in a special sense. To him, "position" is not necessarily the place which the organ occupies in the body of the animal. It is *relative position* or, most especially, position as indicated by the *connections of one part to other parts*. A century of comparative anatomy affords ample evidence that an organ, once established in certain spatial relations to other organs, strongly tends to retain those relations, however much it may change in function, form, and structure. This "principle of connections" was vaguely appreciated by Goethe, elaborated and emphasized by Geoffroy Saint-Hilaire, recognized by Charles Darwin as highly important, and used by Owen as the chief, or even the only, criterion of homology. Gegenbaur and later anatomists admit its value.

The "**principle of connections**" may be illustrated by imagining a fleet of ships anchored in a large harbor. Because of the contour of surrounding mountains and irregularities of shore-line and bottom, the winds and currents are not uniform over the entire harbor and they vary considerably in the course of the day. Each ship, riding freely at anchor, swings now this way and now that, depending on the local breeze and tide. The ships do not all swing in the same direction at once. In the afternoon, ship "A" is lying at the spot where ship "B" was in the morning. The pattern of the spots occupied by the several ships in the course of the day changes. But, unless a ship drags anchor, the pattern of the locations of the anchors on the bottom remains the same. Organs are anchored by supporting membranes, ligaments, tendons, ducts, nerves, and blood-vessels. (Blood-corpuses drift freely in the blood-stream, but they are single cells, not anatomic organs.) Subject to the changing winds and tides of function and adaptation, organs may shift from one place to another in the body, but they rarely "drag anchor." If the anatomist can find the anchors, he will not mistake ship "B" for ship "A," nor will he identify the mid-ventral sternum ("breastbone") of land vertebrates with somewhat

similarly located parts of the branchial skeleton of fishes, as did Saint-Hilaire and other early anatomists, in spite of their appreciation of "connections."

Having observed where an organ *is* in the animal, the anatomist must next find out where it *belongs*. Figure 296 represents cross sections in the midtrunk region of two animals of different kinds. In "I" there is a complete system of mesenteries extending from dorsal to ventral body-wall. An organ, "A," lies in the mesentery dorsal to the intestine, and a different organ, "B," is swung in the ventral mesentery. In the other animal, "II," is found an organ, "X," whose structure resembles that of "B," but "X" is dorsal to the intestine. Ventral to the intestine of "II" is an organ, "Y," which is structurally similar to "A." Structural similarity would indicate that "Y" is the same as "A," and "X" the same as "B," but "A" and "X" are alike in their dorsal location and "B" and "Y" in their ventral location. However, a study of *connections* in "II" shows that "Y" lies in a broad sheet of mesentery extending from the middorsal line to the intestine and "X" is supported by a membrane passing indirectly from the intestine to the midventral line. If the "A-Intestine-B" system of "I" were rotated on the long axis of the intestine through an arc of 180°, without changing any attachments and with the consequent necessary expansion of the

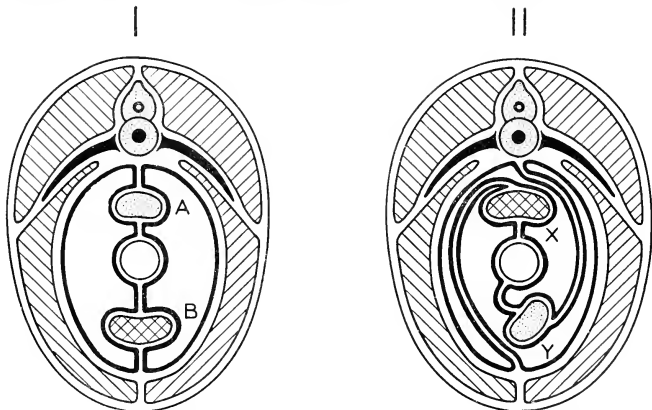


FIG. 296. The "principle of connections." I and II are cross sections in the trunk region of animals of quite different sorts. Organs A and X are situated dorsally to the intestine; B and Y are ventral to the intestine. But A and Y are attached by mesentery to the middorsal line of the coelom, while B and X are similarly attached to the midventral line. Structurally A resembles Y and B resembles X. Similarity in their connections, along with similarity in structure, indicates that A corresponds to Y and B to X.

mesenteries, the result would be the relations found in "H." Having ascertained the connections, the comparative anatomist asserts that "Y" is a dorsal organ and, being structurally similar to "A," is the homolog of "A." For similar reasons, "X" and "B" are homologous.

Such rotations commonly occur along the digestive tube. In the early embryo the tube is nearly straight. In later development its great increase in length necessitates bending, which may be accompanied by local rotation on its long axis, with the result that mesenteries and organs suspended in them are more or less displaced from their primary median position. In the dogfish, *Squalus acanthias*, commonly dissected in laboratory courses in anatomy, the anterior region of the adult intestine has undergone a rotation of nearly  $180^{\circ}$ . The primarily dorsal pancreas is thereby shifted into a ventral position while the point of attachment of the bile-duct to the intestine, midventral in the embryo, is found well up toward the secondarily dorsal side of the intestine. The bile-duct extends between the intestine and that anterior mass of the liver which lies ventral to the stomach and attached to the ventral body-wall by a short mesentery, the suspensory ligament. This ventral attachment identifies the liver as an organ ventral to the digestive tube, regardless of the positions which may be assumed by the long, slender, and quite unsupported lateral lobes of the liver. Therefore the bile-duct, coming from the ventral liver, is a duct ventral to the digestive tube in spite of the nearly dorsal attachment of the duct to the intestine.

A glance at a row of skulls including those of shark, tailed amphibian, bird, reptile, and man (Fig. 297) would not suggest that there could be any similarity in plan and arrangement of bones in structures so very unlike in form and general appearance. Careful analysis, how-

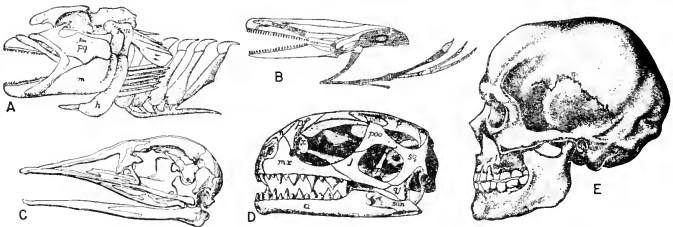


FIG. 297. Skulls of (A) shark, (B) urodele amphibian, (C) bird, (D) reptile and (E) man. (A and B, courtesy, Kingsley: "Comparative Anatomy of Vertebrates"; D, courtesy, Kingsley: "The Vertebrate Skeleton"; E, courtesy, Neal and Rand: "Chordate Anatomy"; Philadelphia, The Blakiston Company. C, courtesy, Owen: "Comparative Anatomy and Physiology of Vertebrates." London, Longmans, Green & Co., Ltd.)

ever, reveals close similarity. In all bony skulls, the bones which constitute the greater part of the cranium are disposed in the form of three arches, each of which completely encircles the brain. Named in order, beginning at the rear of the cranium, these arches are the occipital, parietal, and frontal (Fig. 298). Each arch consists of four or five bones. A mid-ventral bone is joined to one lateral bone on each side and the arch is completed dorsally by one or a pair of bones (the supraoccipital, the two parietals, the two frontals). The early anatomists recognized

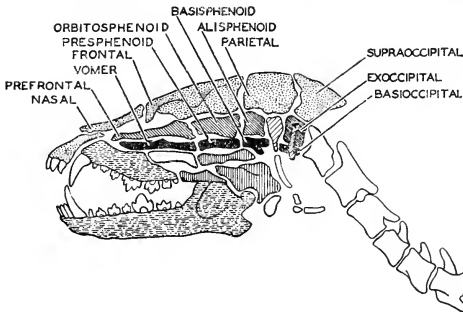


FIG. 298. One of Owen's figures illustrating the Goethe-Oken vertebral theory of the skull. Owen interpreted the mammalian skull as constituted of four enlarged and modified vertebrae. Not knowing the embryology of the skull, he did not realize that vertebrae lack the membranous bones which constitute so large a part of the skull. (After Wilder. Courtesy, Neal and Raud: "Chordate Anatomy," Philadelphia, The Blakiston Company.)

these arches and, led by Goethe, interpreted them as modified vertebrae. Enthusiasm for complete "unity of plan" led to more or less dubious recognition of additional "arches," but with wide disagreement as to their number and constitution. The "vertebral theory" was long since abandoned, but the three arches mentioned above are neither imaginary nor theoretic. As for the remaining bones of the skull, if not arranged in the form of arches they are at least arranged in very definite and constant relations to the inner ear, eye, and nasal cavities and to the jaws and branchial structures (Fig. 120).

The very striking differences in the form of skulls depend not on change of plan of structure but on alteration in the form of the individual bones. Imagine a skull of average proportions modeled in soft rubber. Let the boundaries (sutures) of bones be represented by lines painted on the rubber. By application of appropriate tensions and pressures, either to the model as a whole or locally, it could be made to

resemble the form of *any* skull. But these changes in the form of the model would involve no change in the relative position of the areas circumscribed by the painted lines. With elongation of the model, the individual areas would become longer and narrower, but whatever the change of form, there would be no change in the position of any one area in relation to contiguous areas. So the study of the common pattern in various skulls reveals very little "slipping" of bones out of their usual relations to neighboring bones. It may occur, but rarely goes far enough to obscure the identity of a bone. The main causes of confusion for the anatomist lie in the occasional adding, omitting, or fusion of bones.

There appears to be no reason for doubting that the uniformity in the general plan of structure of vertebrate skulls depends on inheritance. Were it not so—that is, if the embryo were free to produce its own peculiar type of skull in the quickest and easiest way—it surely would not employ the indirect and laborious methods which are especially characteristic of the development of skull bones. Beyond question, in the building of the skull, the embryo, bound by inheritance, begins by using the old material and the old methods. The definitive adult structure is achieved in later stages, but at the cost of much reforming and even replacement of parts first constructed. A primary skull is built up of cartilage, but most of it is destined to be destroyed and replaced by bone. Granting that the general plan of the skull is inherited, it becomes the task of the anatomist to ascertain the homologies of the bones. The highly complex and variable form of the skull as a whole, the great number of bones which enter into it, the intricate forms and connections of individual bones, and the obscurity in the embryonic origin of many of them, combine to make the homologies of these bones a most difficult field of study. In undertaking it, the anatomist must rely mainly on *relative position*, the "*principle of connections*," and *embryonic origin*.

There are some cases in which an organ seems to have "dragged anchor." In the common cod and similar fishes (hake, haddock and pollock), there are two pairs of fins (Fig. 299). Those of one pair are larger, situated well up on the side of the body and close behind the gills. Those of the other pair are smaller, situated near the midventral line and *anterior* to those of the other pair. The distance between the two pairs varies in the several species. By definition and in conformity with the "general body-plan" of a vertebrate, pectoral appendages are anterior and pelvic are posterior. Primitively, the pelvic fins of fishes are near the anus and have no skeletal connection with the vertebral column. The pectoral fins are more strongly developed, have a more elaborate internal skeleton, and commonly have strong skeletal attach-




FIG. 299. *Melanogrammus aeglefinus* (Linnaeus), the haddock. (Drawing by H. L. Todd. Courtesy, Jordan & Evermann: "Fishes of North and Middle America," Washington, The Smithsonian Institution.)

ment to the rear of the skull (see p. 133). Dissection of the cod's paired fins reveals that the larger posterior fin has all the skeletal features of a typical pectoral fin, while the smaller anterior fin has the much simpler skeleton of a pelvic fin, without attachment to any other skeletal part. Internal structure and skeletal connections therefore indicate that the cod's posterior fin is the pectoral. Highly significant is the fact that the nerves which pass from the spinal cord to the small *anterior* fin arise from the cord *posterior* to the nerves which pass to the large posterior fin. This crossing of the two sets of nerves indicates that the small fin "belongs" behind the large fin and is truly pelvic—the nervous "anchorage" holds fast.

Assuming genetic continuity of fishes, we are required to imagine that, in the ancestry of the cod, the pelvic fins have somehow "migrated" to their extraordinary position anterior to the pectorals. The pelvic fins of fishes are usually much less strongly developed than the pectorals. The pelvic girdle is merely embedded in the muscle of the ventral body-wall and has no connection with the vertebral column. It may be imagined, therefore, that the pelvic fins are comparatively free to shift their position. In most fishes the chief propelling organ is the tail. The paired fins are used for balancing and guiding. This being so, the pelvic fins may become mechanically more effective by shifting forward. But these suggestions offer no clue to the evolutionary process whereby functional advantage was gained by shifting the fins forward, nor do they explain why pelvic fins should have moved so far forward in the cod family and less or not at all in other fishes. The immediate point of importance is that *position*, in the sense of mere spatial relation, is not infallible as a criterion of homology. The pelvic fins of the

cod have drifted far forward, but their anchorage certifies to their posterior origin.

**Embryonic origin** is generally regarded as of great significance in the judgment of homologies. Leaving aside all controversial issues as to whether ontogeny "repeats" or "recapitulates" phylogeny, it is merely an observable fact that a notochord, pharyngeal pouches, aortic arches, and a cartilaginous internal skeleton are temporarily present in embryos of reptiles, birds, and mammals. Inheritance offers the only reasonable explanation of their presence. It is not safe to say that these temporary structures are "useless vestiges." The results of recent investigations in experimental embryology indicate the possibility that these "vestiges" may be essential. It has been proved that, in many cases, the embryonic development of one part is dependent upon stimuli produced by some other part which has already been formed. Normal development of the lens of the vertebrate eye from the outer layer of the embryo depends upon the prior development of the "optic cup," which grows out from the embryonic brain and becomes the retinal part of the eye (Fig. 141). It may be that the notochord and other transitory embryonic structures are necessary as sources of stimuli which initiate and control the development of other structures which are to be permanent. If this should prove true, it would make it even more certain that the transitory parts are a heritage from remote ancestors.

If it is admitted that inheritance is the basis for the temporary presence of such conspicuous things as the notochord and pharyngeal pouches, then it becomes reasonable to expect that any organ may pass through early stages closely similar to early stages of that *same* (i.e., homologous) organ in some remote ancestor, even though the adult organ of the recent animal and that of the ancestor may be very different in form and function. When we discover that a shark's spiracles and the middle-ear cavities of a mammal pass through closely similar early embryonic stages, we may infer that spiracles and middle-ear cavities are the *same*. Unfortunately, we cannot observe the development of the spiracle in the remotely ancestral shark. We observe it only in a recent shark. We are accordingly forced to the more elaborate inference that ancient sharks were the starting point of lines of "adaptive radiation." Along one line, sharks remained sharks and retained spiracles down to the present. Along another line (or lines), sharks became successively amphibians, reptiles, and mammals, and the old spiracles became middle-ear cavities, although still retaining the ancient method of embryonic origin. In terms of the genetic scheme illustrated in Fig. 290, the germ-plasm of ancient sharks contained a complex of factors, *s*, which determined development of a spiracle, *S*. Along some lines of descent the germinal *s* remained *s* and always



produced  $S$ , a spiracle. Along other lines  $s$  became  $s^a$ , which produced  $S^a$ , the simple middle-ear cavity of some amphibians—frogs and toads. Later  $s^a$  became  $s^{ar}$ , the germinal basis for the modified middle-ear cavity ( $S^{ar}$ ) of a reptile, and, still later, became  $s^{arm}$  which produces  $S^{arm}$ , the more complex middle-ear cavities of a mammal. The evidence is admittedly indirect, but it is the best obtainable.

Charles Darwin regarded embryonic origin as most important, or even sufficient in itself, as a criterion for homology. In the Glossary of his "Origin of Species," he defines homology as "That relation between parts which results from their development from corresponding embryonic parts, either in different animals, as in the case of the arm of man, the foreleg of a quadruped, and the wing of a bird; or in the same individual, as in the case of the fore and hind legs in quadrupeds. . . ."

Discussion of the criteria for homology leads to this conclusion: In establishing homology of organs, all available data must be carefully considered. No one characteristic is trustworthy by itself. Probably **embryonic origin** is most important, but its evidence is inevitably circumstantial and involves some large assumptions. **Relative position** and **connections** of parts are always highly important. *Structure*—internal differentiation—is significant, but the close alliance of structure with function may lead to deceptive similarity where no homology exists. *External form* of organs usually has little significance. *Number* of multiple constituent parts of organs is rarely significant; *size* and *color* still less so. *Function* is quite independent of homology. Organs having the *same function* are *analogous*; they may or may not be homologous.

#### "CONSERVATISM"

In judging homology of organs, more weight is given to some characteristics than to others. Similarly, in using homologies as the basis for judging genetic relationship of animals, some organs, or systems of organs, are more significant than others. The findings of comparative anatomy make it clear that some organs are much more readily changed than others. An organ which is subject to rapid (in terms of evolutionary time) and radical change provides a poor clue to the anatomist who is trying to thread his way through the maze of ancestry. The organ becomes unrecognizable, or even disappears, and he loses the trail. An organ which is little prone to change may guide him safely into the very remote past. Organs of the latter sort are called "**conservative.**"

If we were to judge the relationships of vertebrates on the basis of the skin only, we would find no good reason for thinking that reptiles, birds, and mammals were related to amphibians and fishes. The charac-

teristic integumentary structures of the former three groups—horny scales, feathers, and hair—have no counterparts in the latter two groups. Further, the scale, feather, and hair are so very different in structure that, taken by themselves, no safe conclusion would be justified concerning the mutual relationships of reptiles, birds, and mammals. The hair might be a simplified feather or the feather might be an elaborated hair. Structures produced by the skin readily undergo adaptive change in relation to various environmental conditions. In contrast to the skin, the *central nervous structures are highly conservative*. The dorsal neural tube, with its uniformly five-part brain from which emerge 10 or 12 pairs of very definitely located cranial nerves, and its spinal cord with segmentally arranged pairs of spinal nerves, is a constant feature of all known vertebrates. The *neural tube* of a shark is unquestionably the *same organ* as that of a mammal. Those highly characteristic structures, the *notochord* and *pharyngeal pouches*, while less conservative than the neural tube, are nevertheless certainly recognizable in all vertebrates. These three very unique and more or less *conservative* things, taken together, give us a satisfactory guarantee of the genetic homogeneity of vertebrates of the most different sorts.

The **reproductive system** is more conservative than some others, although much less so than the nervous system. All the evidence indicates that birds were derived from reptiles. In spite of profound anatomic differences, the bird has retained the reptilian method of reproduction. Mammals, too, have apparently come from reptiles, but the old reptilian type of reproduction persisted long after hair, milk-glands, and other mammalian characteristics had been acquired. At the present time, in the Australian region, there are two mammals, the duckbill (*Ornithorhynchus*) and the spiny anteater (*Echidna*), which lay large eggs similar to reptilian eggs.

The **motor mechanism**, muscles and skeleton, is readily adapted to changes in environment and locomotor habits. Yet, in spite of the extreme differences in the external form and manner of use of ordinary land legs, the whale's flipper, the wing of pterodactyl, bird, and bat, and the human arm, the basic structure remains the same. The skeletons of all vertebrates exhibit the same basic pattern. In vertebrates having paired appendages of the pentadactyl type, the homologies of parts, even down to the minor details of the skeleton, are clearly recognizable. Adaptation of the skeleton to the animal's mode of living is effected by modification of the form, relative size, and number of its constituent elements, but the *pattern* is conservative (Fig. 300). Muscles seem to be more susceptible to change than skeletal parts.

**Digestive and respiratory organs, kidneys, and the blood-vascular system** are relatively low in the scale of conservatism. Di-

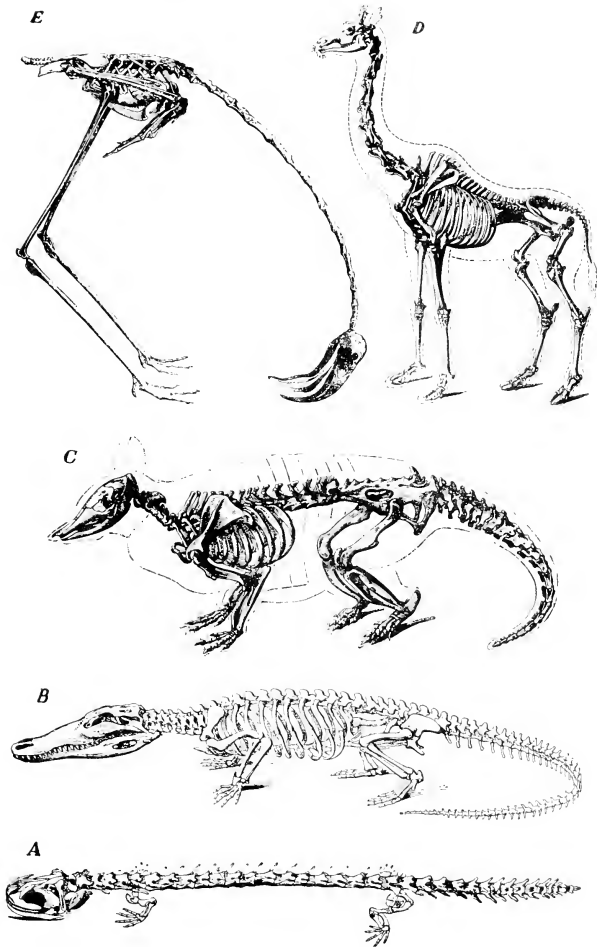


FIG. 300. Some modifications of the basic pattern of the vertebrate skeleton, with special reference to the paired appendages. In some tailed amphibians (A) the small, weak legs, incapable of lifting the body, merely drag it along the substratum. The alligator (B) has more efficient legs. The armadillo (C) is a short-legged mammal with some superficial resemblances to a reptile. The long legs of a giraffe (D), together with the long neck, enable the animal to feed on foliage of trees. The long legs of the flamingo (E, in posture of feeding), a wading bird, keep the body out of the water and necessitate a long neck in order that the bird may obtain food from the bottom of the water. (Courtesy, Owen: "Comparative Anatomy and Physiology of Vertebrates," London, Longmans, Green & Co., Ltd.)

gestive organs are adapted to various kinds of food. Vertebrates may breathe by gills only, by lungs only, by skin only (some adult amphibians), and in some fishes the tail-fin and the rectum serve as accessory respiratory organs. Blood-vessels are notably variable. Even the main channels, especially the veins, differ greatly in the several classes of vertebrates.

It is evident, therefore, that discovery of long-distance genetic relationship depends on recognition of the homologies in organs which are of the highest degree of conservatism. The homologies of organs of less conservative character serve for the recognition of comparatively short-range relationships.

Final judgment as to an animal's place in a genealogic scheme requires that the numerous homologies between the organs of that animal and those of other animals be somehow summed up. Close similarity revealed in one homology may be offset by striking differences in some other. The Australian spiny anteater (Fig. 294) is like a mammal in having milk-glands and hair, and its body bristles with stiff, sharp spines; but the animal reproduces like a reptile. Is it, therefore, to be classified as a reptile or as some sort of porcupine? How can the similarities and differences be evaluated? In the present state of our knowledge, it is impossible to do this describing, comparing, and summing up in any mathematically exact way. Final judgment is largely a matter of personal opinion. Therefore, the smaller branches and twigs of our genealogic trees are in a more or less unstable condition.

Whether or not the Theory of Evolution is true may be debatable, but that the theory *exists* and has played an important part in science is a plain matter of fact. A science must not *try* to prove a theory. It must *test* theories, but without bias as to whether they stand or fall. It has been the main business of a century of Comparative Anatomy to test the Theory of Evolution. At the outset, it was logically possible that Comparative Anatomy might eventually prove that the idea of Evolution must be abandoned. To say that nearly all present-day scientists regard Evolution as fully proved is merely a statement of fact.

The following chapters are devoted mainly to presenting facts of comparative anatomy. Occasionally, attention will be directed to the bearing of facts on theory. In the reading of the remaining chapters, the theories and concepts which have been stated and defined in the present chapter should be kept in mind, in order that the reader may form his own judgment as to how well the Theory of Evolution fits the facts.

Part III  
COMPARATIVE MORPHOLOGY  
OF CHORDATES



# Introduction

The **basic structure** common to all vertebrate chordates has been described in Part I. This common structure, however, is highly susceptible to adaptive modification. The function of Part III is threefold: (1) to **describe** the major structural adaptations related to the animal's habitat and mode of living; (2) to **compare** the more conspicuous and functionally important modifications; (3) to **classify** the chordates in accord with the principles set forth in Part II.

In Part III, therefore, knowledge of the basic structure is assumed and the descriptive material is, in the main, restricted to those specialized structural features which enable us to distinguish the more important subdivisions (subphyla, classes, orders) of the **PHYLUM CHORDATA**. Organs and systems, the nature or degree of whose specialization is not especially significant for the group under consideration, may receive only brief mention or may be quite omitted. In some instances, extinct vertebrates are mentioned. Occasional necessarily brief and very general references to important epochs in the past of vertebrates may serve to give the reader some fragmentary glimpses of the tremendously dramatic history of the group. The classification is restricted to the now living groups. Collateral reading in paleontology will be helpful.







# Classification of Chordates: Protochordata

11

---

Animals in the wild are not classified. Forest, jungle, ocean—each has its characteristic motley population. Animals with and without backbones seem indiscriminately mixed. But it is a well-ordered promiscuity. Each animal is in a biologic (ecologic) environment that fits it. In the matter of food, for example, the animal is placed so that it may get the other animals or plants which it needs, and—the inevitable converse of that—so that a certain proportion of those of its kind may be eaten by others. The species of animal which cannot maintain a balance between eating and being eaten disappears from the local scene.

Classification of organisms is a practical necessity for purposes of describing and comparing them. Modern classification arranges animals according to those similarities and differences which may be taken to indicate degree of genetic relationship. Such a classification is, therefore, a summary of the findings of Comparative Morphology (including Paleontology) working by the “method” described and illustrated in the preceding chapter.

Although the main lines of the classification of vertebrates are fairly well established, there is still much difference of opinion as to the best way of arranging and naming the groups. No two authors offer classifications which are identical in plan and naming. While the vertebrates are more fully known than any other large group, there are still some whose systematic position is dubious. As a matter of convenience, it seems necessary that every animal should be included in a classification. Therefore animals of doubtful affinities are placed according to the best judgment of the classifier—with the result, in one case, that the “flying lemur” of the East Indies (Fig. 546) may be found in any of three Orders of mammals. It might be better to set up an unclassified class to include all the doubtful cases.

The basic definition of a group must include *all* of the characteristics which have been taken into account in estimating the genetic position of the animals to be included in it. However, for purposes of a condensed summary of a classification, it is convenient to devise very brief descriptive designations using perhaps only one or two of the most salient features of a group. Modern birds may be safely distinguished as vertebrates having feathers, but birds have many other characteristics which are quite as distinctive as feathers.

The animal kingdom is usually divided into some 12 to 14 groups distinguished from one another by morphologic differences of major importance. Each of these groups is called a Phylum. The Phylum is subdivided into a series of groups whose distinguishing characteristics are of successively lower orders of importance. Named in descending sequence, the series includes Classes, Orders, Families, Genera, and Species. Sometimes it is found convenient to make a subphylum, subclass, or suborder. Occasionally two or more groups are collected together under some descriptive heading for which there is no special taxonomic name. The terms Anamnia, Amniota, Sauropsida, and others used in classifying vertebrates, are of this unnamed sort. They are referred to informally as "groups" or "divisions."

The scientific name of the individual animal is the Linnaean binomial (see p. 340), consisting of the Genus and Species to which the animal belongs. The common cat is **Felis domestica**; the lion, **Felis leo**; the tiger, **Felis tigris**; and there are, in all, some 40 species more in the genus **Felis**. Linnaeus called man **Homo sapiens**. We belong to the **family** Hominidae (of which we are the only living species), to the **order** Primates, the **class** Mammalia, the **phylum** Chordata.

The names of the several phyla which are commonly recognized are shown in the hypothetical "tree" (Fig. 301). The name, Chordata, of the phylum to which the vertebrates belong does not appear in the figure. The Chordata are shown as divided into their several subphyla and classes, comprising all of the right trunk of the tree above the level of the Echinoderms.

The phylum **Protozoa** occupies a unique position. Its members are those animals which are so small (most of them being of microscopic dimensions) that the protoplasmic body is organized as a single cell—the "unicellular animals." The members of all the other phyla, with a few exceptions, are relatively large, and their living substance is therefore organized into numerous cells, because the necessities of protoplasmic metabolism impose limits on the maximum volume of a cell. All the phyla aside from Protozoa are referred to collectively as the **Metazoa**, the "multicellular animals." It is generally believed that

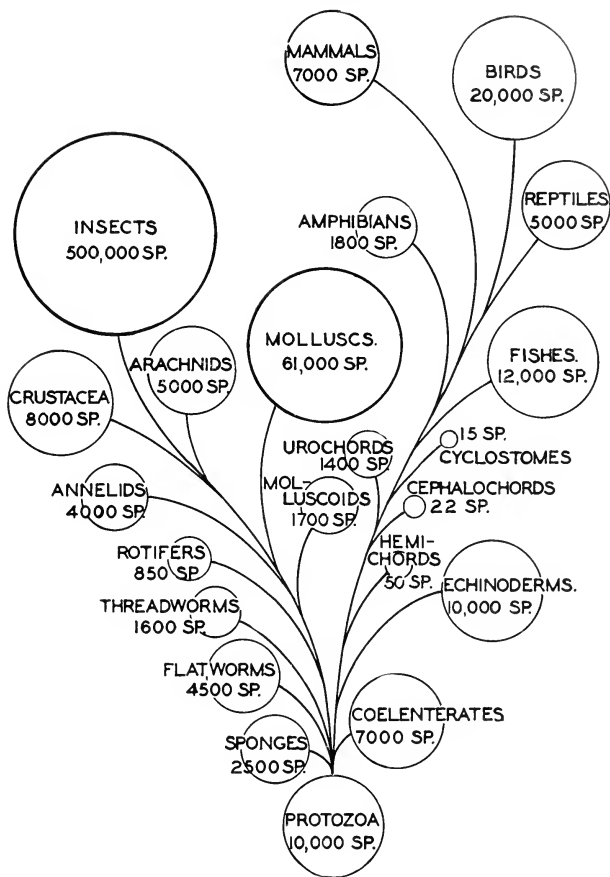


FIG. 301. A phylogenetic tree of the animal kingdom, showing its dichotomy into Proterostomians and Deuterostomians.

The number of species in a group cannot be exactly stated. Estimates made by presumably equally good authorities may be at wide variance. The numbers given in the "tree" have little significance beyond giving an approximate idea of the *relative size* of groups. (Courtesy, Neal and Rand: "Chordate Anatomy," Philadelphia, The Blakiston Company.)

the earliest metazoans must have been somehow derived from ancient protozoan ancestors.

The dichotomous branching of the "tree" in Fig. 301 illustrates a recent view for which there is some embryologic evidence. According to the "gastraea" theory of Haeckel (see p. 349), the two-layered gastrula stage of the embryo, which commonly occurs throughout Metazoa, indicates common ancestry of all metazoans from two-layered coelenterates (Fig. 285). The digestive cavity of the coelenterate has only one external opening, the mouth or "mouth-anus." The gastrular cavity, which is the prospective digestive cavity of the adult, opens to the exterior by the "embryonic mouth" or blastopore. It is a striking fact that, in some metazoans (Fig. 302C, D), the blastopore persists as the adult mouth, or at least marks the oral end of the animal and, becoming closed, is replaced by the definitive mouth, whereas, in other metazoans (Fig. 302E-H), the blastopore either persists as the adult anus or marks the prospective anal region of the embryo, the mouth then developing at the opposite end as an entirely new opening. This completely opposite polarity of embryos, in some the blastopore marking the head end, in others the tail end, seems a matter of quite fundamental importance. It may justify showing the metazoan "tree" as splitting, just above the level of the sponges, coelenterates, and flatworms, to form two grand trunks. One of them, the **Protostomians** (or Proterostomians; on the left in Fig. 301), includes the phyla in which the adult mouth is formed at the blastoporal region of the embryo or may even be the persisting primary

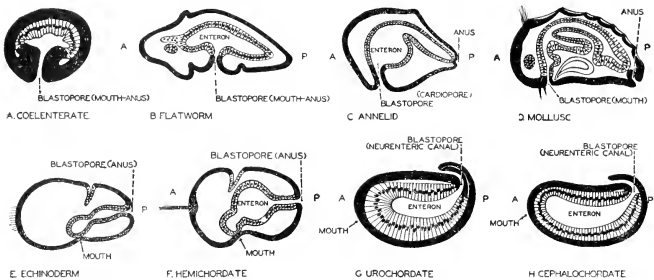


FIG. 302. Diagrams of embryonic stages illustrating the contrast in the fate of the blastopore in various groups of animals. The forms in which the embryonic blastopore becomes the mouth were grouped together by Grobben as *Proterostomia*. The *Deuterostomia* include those animals in which the blastopore becomes the anus or lies in the anal region. The coelenterates, flatworms, annelids, and mollusks are Proterostomians, while echinoderms and chordates are Deuterostomians. (Courtesy, Neal and Rand: "Chordate Anatomy," Philadelphia, The Blakiston Company.)

("proto-") mouth (i.e., blastopore) of the embryo. The second trunk, the **Deuterostomians** (on the right in Fig. 301), includes the phyla in which the adult mouth is a second ("deutero-") mouth formed at a position opposite that of the primary blastoporal "mouth," which may persist as the adult anus.

In the succeeding chapters dealing with the various organs of vertebrates, reference will be made to invertebrates whenever comparison of a vertebrate organ with an invertebrate organ seems relevant. It is fair to assume that anyone who uses this book must already have made some acquaintance with the invertebrate phyla. Therefore no further attention will be given here to the characteristics and classification of invertebrates.

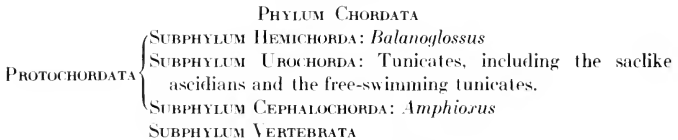
### Phylum Chordata

The most highly distinctive characteristics of vertebrates are these three things: the **notochord**, well developed in all vertebrate embryos; the *dorsal* position and hollow or *tubular* form of the **central nervous organs**; the **pharyngeal clefts** or pouches, always present at least in the embryo. In these three features, the vertebrates are very far removed from all of the clearly defined phyla of invertebrates. Nevertheless, there are a few animals which are literally invertebrate, in the sense that they have no vertebral column, and yet they more or less definitely possess these three features of vertebrates. Even though they may possess little or no other resemblance to vertebrates, these three characteristics are generally regarded as more significant than the lack of other vertebrate features. These animals are therefore put in the same phylum with vertebrates on the assumption that they must be remote allies of the vertebrates.

Since the notochord is perhaps the most peculiar of the vertebrate characteristics, it is taken as the basis for the name of the Phylum, **Chordata**. The notochord (or chorda dorsalis) is defined as a supporting (skeletal) rod lying dorsal to the digestive tube and ventral to the central nervous organ (neural tube). It is constituted of a histologically peculiar soft tissue—i.e., neither bone nor cartilage—developing in the embryo from, or in close relation to, the middorsal wall (endoderm) of the digestive cavity.

The nonvertebrate chordates include three types of animal which are so very unlike that it seems best to set up a separate subphylum for each type. Those of one type, represented by *Balanoglossus* (Fig. 303), are in most respects wormlike. The structure which may be interpreted as a notochord, in contrast to the vertebrate notochord which extends nearly the whole length of the animal, is confined to the anterior region of the animal. Hence the name of the subphylum,

**Hemichorda** (inaccurate, for the animal has much less than "half" a notochord). The second subphylum includes animals most of which, in the adult stage, are sessile, saclike things, unlike anything else, vertebrate or invertebrate. These are the "sea squirts" or ascidians (Fig. 308). The chordate features appear in the embryo, which develops into a long-tailed larva. The notochord is confined to the posterior part of the body and tail—hence the name of the subphylum, **Urochorda**. The third subphylum contains the externally fishlike little "lancelet" or *Amphioxus* (Fig. 312). The notochord extends not only throughout the tail and trunk but almost to the tip of the head—therefore **Cephalochorda** as the name of the subphylum. These three subphyla are conveniently referred to collectively as the **Protochordata**, as set off from the fourth subphylum, **Vertebrata**. The general plan of the Phylum Chordata is, therefore, as follows:



Nearly 50,000 species of chordates are known.

Brief descriptions of the three protochordate subphyla follow.

#### SUBPHYLUM HEMICHORDA

The hemichordates hold a doubtful place in the animal kingdom. It is not certain that their closest affinities are with chordates. The adults are, in general, wormlike, but the larval stage closely resembles the larva of an echinoderm. Their inclusion among chordates rests on their possession of pharyngeal gill-slits, a short notochord-like outgrowth of the foregut, and a dorsal nerve-cord—but there is also a ventral nerve-cord. There are possibly 50 species, all marine.

**Balanoglossus** (Fig. 303) is the best-known representative. The body is wormlike and is divided into three regions, proboscis, "collar," and trunk. The **proboscis** is a hollow muscular organ with an opening on the left dorsal side of its neck (Fig. 304). The mouth is on the ventral side between proboscis and collar. The **collar**, like the proboscis, is



FIG. 303. *Balanoglossus*, a hemichordate. (After Bateson. Courtesy, Neal and Rand: "Chordate Anatomy," Philadelphia, The Blakiston Company.)

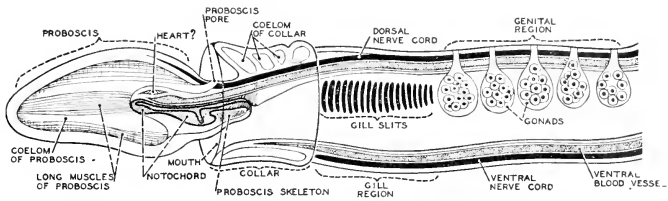


FIG. 304. Anterior half of *Balanoglossus*, seen, in left lateral aspect, as a semi-transparent object. (After Stempell. Modified from Neal and Rand: "Chordate Anatomy," Philadelphia, The Blakiston Company.)

hollow and muscular. These muscular structures are used for burrowing into the sand or mud in which the animal lives—usually between low and high tide levels.

In the anterior part of the **trunk**, the digestive tube is differentiated into a respiratory region or **pharynx** which is divided into a dorsal portion containing the many paired gill-apertures (40 to 50 or more pairs in old animals) and a ventral alimentary passage. In the more posterior region of the trunk, the intestine has a series of paired pouches, each of which causes a corresponding bulge of the relatively thin body-wall. These pouches are glandular and presumably have a digestive function; hence they are called "liver" diverticula. Behind this "liver" region, the intestine passes directly to the posterior anus.

The **central nervous system** consists of a dorsal nerve-cord together with a ventral nerve-cord similar to that of an invertebrate. They are connected with one another in the region of the collar. The dorsal cord in this region is hollow to an extent varying in different species. There are no locally specialized sense-organs.

The so-called **notochord** is a short, tubular diverticulum of the alimentary tube extending into the proboscis from a point just behind the mouth (Fig. 304). It apparently serves to strengthen the base of the proboscis and is therefore presumably skeletal in function.

The **circulatory system** resembles that of annelid worms.

The **reproductive organs** consist of a series of paired gonadic sacs situated some in front of and some behind the junction of the pharynx and the "liver" region of the intestine. Each sac has a pore opening to the exterior. The sexes are separate.

*Balanoglossus* and some related genera constitute a group called **Enteropneusta**. Other hemichordates are **Cephalodiscus** and **Rhabdopleura**, which show resemblances to *Balanoglossus*, but are short-bodied and have a U-shaped alimentary tube. *Rhabdopleura* lacks gill-slits. Both are sessile, living either at shallow or deep sea-levels. *Rhabdopleura* forms colonies.

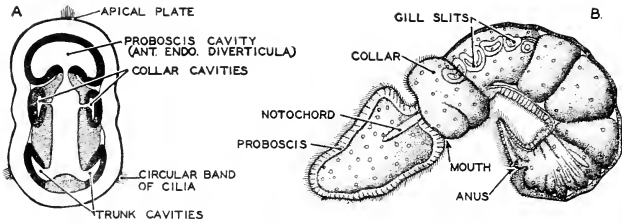


FIG. 305. *Balanoglossus* embryos. (A) Horizontal section of a young embryo, showing the origin of mesodermal pouches. McBride and others have noted the similarity of this section to that of a young *Amphiorus* embryo as evidence of the close affinity of the two animals. (B) A young *Balanoglossus* larva (tornaria) with five pairs of gill-slits, viewed from the left side. The gill-slits of *Balanoglossus* resemble those of *Amphiorus*. On the other hand, the young larva of *Balanoglossus* is strikingly like the larva of echinoderms. (After Bateson. Courtesy, Neal and Rand: "Chordate Anatomy," Philadelphia, The Blakiston Company.)

The larva of *Balanoglossus*, known as a "tornaria" (Fig. 305), is very similar to the larva of an echinoderm. As in echinoderms, the blastopore becomes the anus. The subphylum, therefore, is included in the Deuterostomia.

#### SUBPHYLUM UROCHORDA

The urochordates or **tunicates** are all marine. Most of them, in the adult stage, are saclike in form and are sessile ("sea-squirts"), attaching to submerged objects such as rocks or wharf pilings in shallow or moderately deep water. Some sessile forms produce colonies of numerous individuals attached to one another. In some of these colonial forms the individual is very minute—a small fraction of an inch in diameter—but some of the isolated sea-squirts may be several inches long. A few of the tunicates are free-swimming in the adult stage. Most tunicates are hermaphroditic. In some both sexual and asexual reproduction occurs. About 1400 species have been recognized.

The most significant thing about the tunicates is the fact that, in the early stages of their embryonic development, they closely resemble vertebrates, and in nearly all of them the embryo develops into a larval form which is definitely chordate in structure (Fig. 306). It has a typical notochord extending from the rear of the trunk to the tip of the long tail. Dorsal to the notochord is a tubular nerve-cord whose enlarged anterior end is suggestive of a brain. This "brain" contains an eyelike **ocellus** and a "static organ," perhaps earlike. The anterior region of the digestive tube is expanded into a pharynx whose wall is perforated by several gill-slits (**stigmas**) which communicate indirectly with the exterior by opening into a peribranchial or **atrial cavity** which opens to the exterior. But there is no segmentation of the



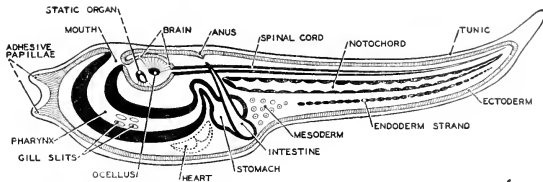


FIG. 306. Diagram of a larval urochordate. The similarity of the larval urochordate to the embryo of a cephalochordate (*Amphioxus*) suggests that the urochordate is near the main line of vertebrate ancestry. (After von Beneden and Julin. Courtesy, Neal and Rand: "Chordate Anatomy," Philadelphia, The Blakiston Company.)

body such as occurs in vertebrates, and the digestive tube becomes bent upon itself so that eventually the anus lies near the mouth. The mature larva swims actively by means of its long, muscular tail and, in a general way and except for its comparatively minute size, strongly resembles the tadpole of a frog or toad.

In the great majority of tunicates, the larva eventually attaches itself to some submerged object by means of the anterior adhesive papilla. The tail, together with the notochord and the greater part of the dorsal nerve-cord, is absorbed (Fig. 307). These and various other changes combine to transform the larva into the saclike adult (Fig. 308).

The general anatomy of the adult of such typical sessile tunicates as *Ascidia*, *Ciona*, and *Molgula* is represented in Fig. 309. The outermost layer of the animal is a "test" or "tunic" whose substance is secreted primarily by the skin. The essential constituent of the tunic is a substance, *tunicin*, which is chemically similar to the cellulose of plants. Beneath the test, and connected with it loosely, except in the region of the two apertures of the body, lies the body-wall or "mantle." This consists of an external simple-epithelial layer, and, beneath this, connective tissue containing a network of muscle-fibers which are more abundant in the region of the two apertures of the body, which they serve to close and open.

In the ventral region of the median plane of the animal, the deeper tissue of the body-wall extends inward and is joined to the wall of the pharynx, but on each (right and left) side of the pharynx an extensive space intervenes between it and the body-wall. Dorsally, these two spaces join into a large median space which leads to the exterior through the dorsal "siphon." These spaces collectively are known as the peribranchial or atrial cavity. Its median division, into which the anus and the genital ducts open, is sometimes called a "cloaca." The atrial cavity is not to be confused with a coelom, which it deceptively resembles.

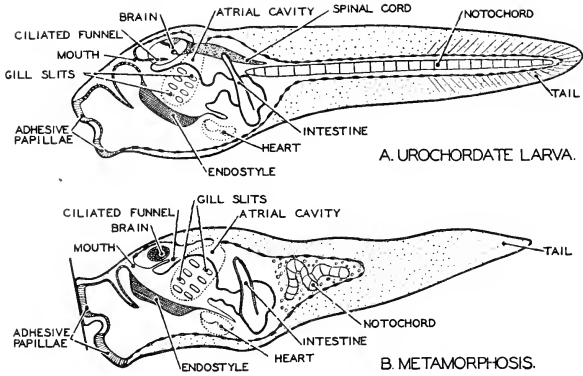


FIG. 307. Diagrams of stages in the metamorphosis of a urochordate larva. When the larva settles down and becomes fixed by its adhesive papillae, the tail is lost and the notochord disappears. Thus the chordate characters which are so evident in the larva are partly lost in the mature animal. (Redrawn from Korschelt and Heider, after Seeliger. Courtesy, Neal and Rand: "Chordate Anatomy," Philadelphia, The Blakiston Company.)

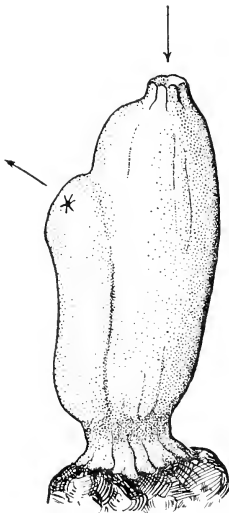


FIG. 308. A tunicate, *Ascidia*, attached to a stone; seen from right side. Arrows indicate the oral (incurrent) and the atrial (excurrent) openings.

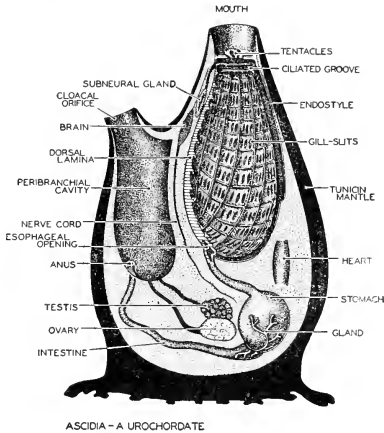


FIG. 309. *Ascidia*, a urochordate. The animal is viewed as if cut in sagittal section and seen from the right side. (Redrawn from Sewertzoff, after Boas. Courtesy, Neal and Rand: "Chordate Anatomy," Philadelphia, The Blakiston Company.)

Of the two external apertures, the more ventral is the inhalant or oral "siphon" and the other the exhalant or atrial "siphon." The former leads directly to the mouth, which is surrounded by a circle of tentacles. The mouth opens into a greatly enlarged pharynx, which is perforated by numerous gill-slits or **stigmas**. The action of the cilia on the bars between these slits serves to maintain a current of water from the pharynx into the surrounding peribranchial (atrial) cavity. Along the floor of the pharynx extends a longitudinal grooved thickening, the **endostyle**, whose surface is ciliated and coated with secreted mucus. A similar groove extends along the dorsal wall of the pharynx, terminating posteriorly at the opening of the esophagus. A circular **peripharyngeal** ciliated groove joins the anterior ends of the endostyle and the dorsal groove. Particles of food in the water are caught in the mucus and transported along these grooves into the esophagus by ciliary action. Posterior to the pharynx, the alimentary canal consists of a short esophagus, a spherical stomach, and an intestine which leads to an anus opening into the atrial chamber.

The heart lies ventral to the esophagus in a coelomic (pericardial) chamber. There are no closed blood-vessels, but the blood is pumped from the heart forward to the pharynx through irregular spaces (*lacunas*) which resemble functionally the afferent brachial vessels

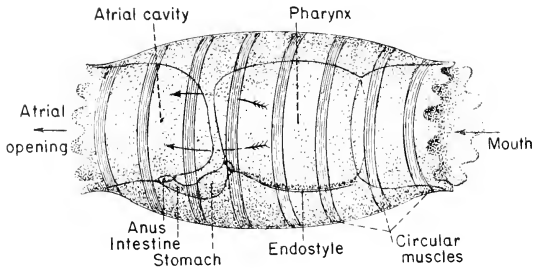


FIG. 310. *Doliohum*, a free-swimming tunicate. The somewhat diagrammatic figure, taking advantage of the fact that the thin body-wall of the small animal is semitransparent, assumes that the main features of internal structure may be seen through the outer wall. The many branchial slits (stigmata) through which water passes from the pharynx into the atrial cavity are not shown, but are suggested by arrows. The animal's swimming movements are effected by contractions of the circular muscles.

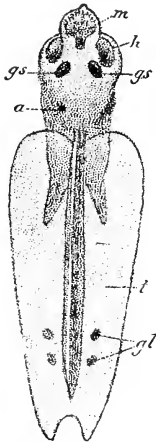


FIG. 311. *Appendicularia (Fritillaria) furcata*, from the ventral surface. (a) Anus; (gl) unicellular glands; (gs) gill-slits; (h) dorsal hoodlike fold of integument; (m) mouth; (t) tail. (After Lankester. From Willey: "Amphioxus and the Ancestry of the Vertebrates." By permission of The Macmillan Company, publishers.)

of vertebrates. The reproductive organs lie in the loop of the intestine, posterior to the stomach. Their ducts extend forward and open into the atrial cavity near the anus. The gonads are hermaphroditic. There are no excretory tubules.

The nervous system consists of a ganglion or "brain," derived from the anterior end of the larval nerve-cord. It lies in the body-wall between the two apertures of the body. Ventral to the brain is a "neural gland" which has been compared to the neural part of the pituitary gland of vertebrates. The single eye and the static organ of the larva degenerate during metamorphosis.

Some tunicates, although anatomically similar to the sessile "sea-squirts," do not become attached but are free-swimming in the adult stage, propelling themselves by forcible ejection of water from the atrial aperture. Such a form is *Doliolum*, having a barrel-shaped body with oral and atrial openings at opposite ends. *Salpa* resembles *Doliolum* (Fig. 310).

Of the three or four orders of Urochorda, the **Larvacea** are of special interest because they undergo no metamorphosis. The adult retains the larval tail with its notochord and spinal cord and is actively free-swimming. **Appendicularia**, one of the Larvacea, resembles a very minute tadpole (Fig. 311).

That *Appendicularia* is a persistent, primitive, free-swimming tunicate—i.e., one in whose ancestry metamorphosis has never occurred—is an interesting possibility. But it is also possible that it is what might be described as a "persistent larva"—i.e., a descendant of metamorphosing ancestors, but with loss of the metamorphosis and acquisition of capacity for reproducing at a structural stage corresponding to that of the larva of its metamorphosing ancestors.

#### SUBPHYLUM CEPHALOCHORDA

This subphylum includes the fishlike little "lancelet," **Amphioxus**, first named *Branchiostoma* (Fig. 312), and a few closely similar animals—perhaps 20 or more species in all. *Amphioxus* may attain a length of 40 to 50 mm. They are all marine, living in the shallow coastal waters of both Eastern and Western Hemispheres. *Amphioxus* burrows in clean sand and commonly rests in the sand with merely the head exposed. It swims very actively and, curiously, with the body in a vertical position.

The cephalochordates resemble vertebrates much more closely than do the other protochordates. The adult has a well-developed and functional notochord extending from tip of head to tip of tail. Dorsal to it is a tubular nerve-cord, slightly enlarged at its anterior end to form a so-called "brain." The respiratory arrangement strongly resembles

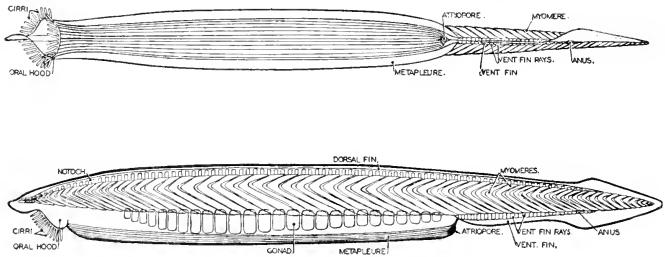


FIG. 312. *Amphiorus*, in ventral and side views. Metamerism, lacking in invertebrates, and scarcely evident in hemichordates, is strikingly shown by *Amphiorus*. Whether this metamerism is inherited from annelid-like ancestors or is a convergent trait independently acquired, is problematic. (After Kirkaldy, Courtesy, Neal and Rand: "Chordate Anatomy," Philadelphia, The Blakiston Company.)

that of urochordates. A much-enlarged and elongated pharynx communicates, through numerous (over 100) pairs of gill-openings, with a **peribranchial (atrial) cavity** which has exit to the exterior via a median ventral **atriopore** just behind the elongated pharyngeal region. In contrast to the other protochordates, in which there is no segmentation of the body, the body-muscle of cephalochordates is definitely segmented (about 60 pairs of myomeres in *Amphiorus*) throughout the whole length of the animal, and the nerves which emerge from the nerve-cord, like the spinal nerves of a vertebrate, are arranged segmentally to correspond to the myomeres. In further contrast to other protochordates, *Amphiorus* has numerous (about 90) pairs of excretory or **renal tubules**, but they are not aggregated into definite kidneys. The embryonic origin of these tubules has been disputed. If, as now commonly held, they are derived from the ectoderm of the embryo, they would seem to correspond to the excretory nephridia of annelid worms rather than to the kidney-tubules of vertebrates, which develop from the mesoderm.

The **skin** of *Amphiorus* is a simple-epithelial epidermis which secretes a delicate external protective cuticula (Fig. 11A). The ventral mouth, surrounded by a circle of tentacles, leads directly into the pharynx (Fig. 313). A median ventral groove whose surface is mucous and ciliated extends the entire length of the pharynx, constituting an **endostyle** similar to that of urochordates. In the roof of the pharynx is a similar **epipharyngeal groove**. Just behind the mouth, the dorsal and ventral grooves are connected by **peripharyngeal** ciliated bands. Mucus secreted along the endostyle is driven forward by the cilia, then upward via the peripharyngeal bands, and finally backward along the

epipharyngeal groove. Particles of food, swept into the pharynx by the respiratory current of water, are caught on the moving bands of mucus and thus transported back into the intestine.

No stomach is differentiated. The pharynx opens into a straight tube, the **intestine**, at whose anterior end is a ventral tubular glandular diverticulum (**hepatic cecum**), possibly corresponding to the liver of vertebrates.

The relations of coelom and peritoneum are essentially as in vertebrates. The sexes are separate. The **gonads**, about 25 segmentally arranged pairs of them, are embedded in the outer wall of the atrial cavity (Fig. 314). There are no genital ducts. When the eggs or sperms are mature, temporary rupture of the enclosing wall of each gonadic pouch permits escape of the genital products into the atrial cavity, whence they find exit via the atriopore. The apparently extraordinary position of the gonads results from the manner of origin of the atrial cavity. A pair of lateral longitudinal folds (**metapleural folds**) of the embryonic body-wall grow outward and downward (Fig. 311). Later the two folds become joined by a transverse horizontal partition (Fig. 316A). The external space thus enclosed between the folds and the body-wall becomes the atrial (peribranchial) cavity, which is therefore lined by ectoderm. Incomplete union of the folds at their hind ends leaves the atriopore. The gonads, originally situated on the internal surface of the body-wall, are carried down into the atrial wall by the downgrowth of the atrial folds.

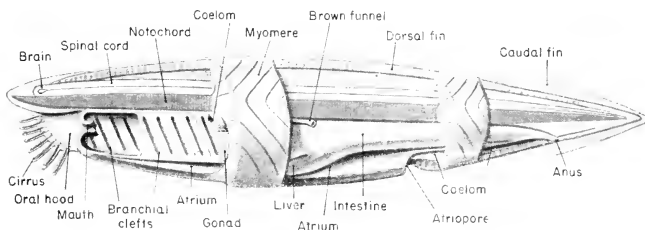


FIG. 313. *Amphiorus*; longitudinal view showing the major anatomic features. The body-wall, spinal cord, and notochord are cut in the median plane. A short anterior region of the pharynx is cut in the median plane, revealing the internal openings of four gill-clefts of the right side. Posterior to this region may be seen five gill-clefts opening into the atrium whose external wall has been removed along with the body-wall. (In the fully adult animal the gill-clefts are much more numerous than shown in the figure.) The intestine is not cut, and its posterior end bends slightly to the left so that the anus is on the left side of the thin caudal fin. The liver extends forward on the right side. The "brown funnel" is one of a pair of tubules, presumably excretory, opening into the atrium.

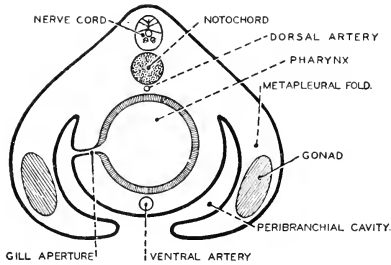


FIG. 314. Diagrammatic cross section of a larval stage of *Amphioxus* showing relations of the metapleural folds, peribranchial (atrial) cavity, and pharynx. (After Gaskell. Courtesy, Neal and Rand: "Chordate Anatomy," Philadelphia, The Blakiston Company.)

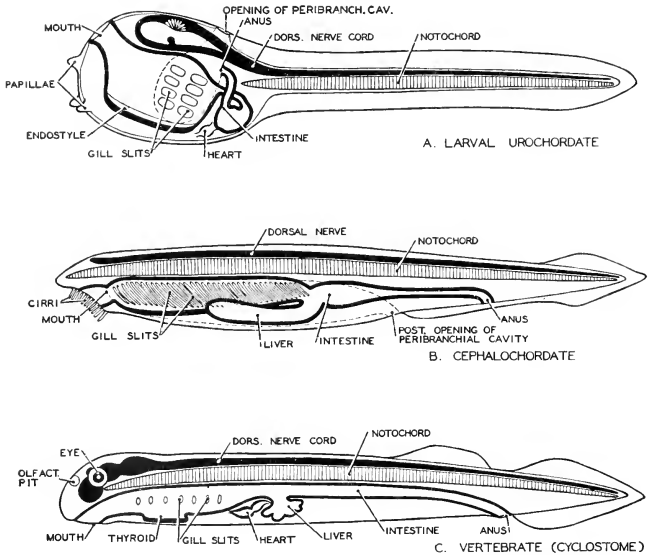
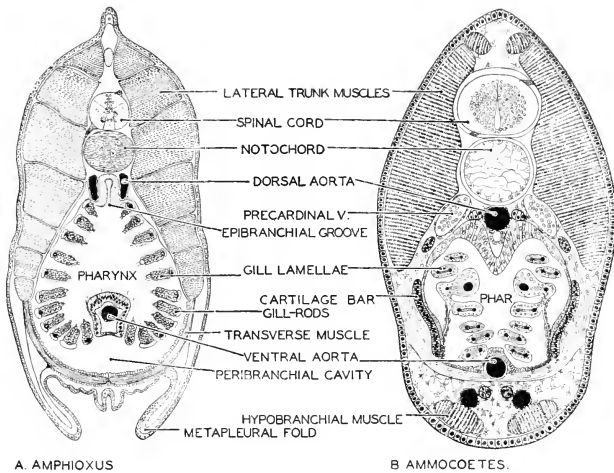


FIG. 315. Diagrams of (A) larval urochordate, (B) cephalochordate (*Amphioxus*), and (C) vertebrate (*Pelomyzoon*), illustrating the fundamental characteristics of chordates. (After Hesse-Doflein. Courtesy, Neal and Rand: "Chordate Anatomy," Philadelphia, The Blakiston Company.)





A. AMPHIOXUS

B. AMMOCOETES.

FIG. 316. Cross sections of (A) *Amphioxus* and (B) ammocoetes (larval *Petromyzon*) through the pharyngeal region, showing their fundamental resemblance. (Courtesy, Neal and Rand: "Chordate Anatomy," Philadelphia, The Blakiston Company.)

Compared to a vertebrate, however, the cephalochordates lack certain characteristic and highly important features. There are no paired locomotor appendages of any sort. There is no definitely localized blood-pumping organ such as the vertebrate heart. The blood is colorless, containing no red blood-cells and few, if any, white cells (leukocytes). In every known vertebrate, the conspicuous features of the head are three pairs of highly specialized and functionally important sense-organs, the olfactory (nasal) organs, eyes, and ears. Cephalochordates have no counterparts of these sense-organs. (*Amphioxus*, however, is keenly sensitive to light.) In the absence of such organs and possessing only a very feebly developed brain, there is no need of a protective skeletal structure such as the "brain-case" or cranium of vertebrates. Hence the cephalochordates, having no cranium, are often called the Acrania.

The cephalochordate embryo develops into a larva similar to that of a tunicate, but the changes involved in the metamorphosis into the adult are far less profound than those that occur in a tunicate.

The **Protochordata** have received a large amount of careful study because they seem to offer the possibility of the discovery of the long-sought "connecting links" between vertebrates and invertebrates. The

unmistakable chordate features of the larva of tunicates and the almost vertebrate nature of *Amphioxus* compel the conclusion that these animals stand in close relationship to the vertebrates. The close similarity in the general plan of structure of the urochordate larva, *Amphioxus*, and a "low" vertebrate such as the round-mouthed lamprey eel, *Petromyzon*, is illustrated in Fig. 315. Compare also the corresponding cross sections of *Amphioxus* and the larva (ammocoetes) of *Petromyzon*, shown in Fig. 316.

Admitting that the "notochord" of the **hemichordates** is a more or less dubious thing, the pharyngeal clefts and the dorsal nerve-cord, by themselves, are enough to give these animals some claim to a place among the chordates. The resemblance of the hemichordate larva, the tornaria, to the larvae of echinoderms is perplexing. This difficulty, however, would be disposed of if the hemichordate line and the echinoderm line could be traced backward to some remotely ancient ancestor common not only to them but to all the other chordates, the latter, however, in the course of their long and much more progressive careers, having completely eradicated the echinoderm taint from their germ-plasms. This possibility is suggested in the hypothetical "family tree" in the animal kingdom, shown in Fig. 301. The echinoderms and chordates at least agree in being deuterostomian.

The **urochordates** are of special interest because of their metamorphosis, which is commonly described as being of a "degenerative" nature since, for the most part, it consists in losing structures which the larva possesses. From the point of view of such a highly superior chordate as man, the metamorphosis is "degenerative" because we regard a life of free and energetic activity as much more respectable than the lazy sedentary habit of the adult sea-squirt. We must admit, however, that the structure of the ascidian is quite adequate for the life which the animal lives.

The free-swimming tunicates such as *Salpa* and *Doliolum* must have an extraordinary history, if current views concerning the urochordates are accepted. According to these views, the primitive urochordates were, as adults, long-tailed and free-swimming chordates similar to the larvae of modern tunicates. In the course of time most of them, the Larvacea being possible exceptions, acquired the "degenerative" metamorphosis. Then, in the course of later time, the descendants of some sessile, saclike forms must have regained the habit of living a free-swimming adult life. But in doing so they did not retain or re-acquire a locomotor tail and notochord. The adults are, in a general way, anatomically similar to sessile ascidians. The main differences are those consequent upon a shifting of axes so that the oral and atrial "siphons" come to point in opposite directions, thus achieving the

possibility of propulsion by forcible ejection of water from the atrial siphon—the skyrocket principle or “jet propulsion.” *Doliolum* passes through a transitory larval stage in which there is a characteristic tail and notochord. *Salpa* omits this stage. Development in both involves a highly complex alternation of sexual and asexual generations. The vertebrates afford numerous instances of this reversion to an ancient mode of life, but without reversion to the ancient anatomy. Externally, the flipper of a seal looks like a fin, but its internal structure is that of a land leg.

### SUBPHYLUM VERTEBRATA

In the now living Vertebrata, the **notochord**, present in all embryos, persists in the adult in a functional condition (in association with some rudimentary vertebral structures) only in the round-mouthed eels (Cyclostomata) and in certain fishes (Holocephali, sturgeons, and lungfishes or Dipnoi). In all other vertebrates it is functionally replaced by a vertebral column composed either of cartilage or of bone. **Pharyngeal clefts**, present in all embryos, persist in the adult stage of such vertebrates as are gill-breathing throughout life (fishes and some amphibians). In all other vertebrates the clefts are restricted to the embryonic period, except in so far as those of the most anterior pair may persist in relation to the adult ear. The **central nervous organ** is dorsal and permanently hollow and expands at its anterior end into a more or less massive and complex brain. A protective skeletal brain-case, the cranium, composed either of cartilage or of bone, is developed around the brain and in intimate relation to the three important sense-organs, the olfactory organ, eye, and ear. In distinction from the Acrania (CEPHALOCHORDA), the name Craniata is often used as the equivalent of Vertebrata.

The several other characteristic features of vertebrates have been set forth in Part I.

A mere glance at the great and highly diversified group of vertebrates reveals the fact that their most conspicuous anatomic differences are those which relate to the external medium with which the animal is directly in contact—water, land, air. The animal parts which are most immediately put to the necessity of being adapted to the nature of the medium are the locomotor organs, the organs of breathing, and the skin. In such a typical aquatic animal as a fish, the paired appendages are fins, breathing is by gills, and the skin is coated by a thin layer of mucus (“slime”). In the typical land vertebrate, the paired appendages, adapted for walking and running on a hard substratum, are jointed legs having a normal maximum of five digits (fingers or toes) on each—therefore **pentadactyl** appendages. Breath-

ing is by lungs, and either the skin is dry or, if glandular, the secretion is not mucus.

According to the findings of paleontology, the earliest vertebrates were aquatic and fishlike. Land vertebrates appeared very much later. It would seem, therefore, that in the attempt to classify vertebrates the first step would be very simple. It could be expected that a line might be drawn separating them into two groups: on one side, aquatic animals with fins, gills, and mucous skin; on the other side, land animals with legs, lungs, and nonmucous skin. But in reality it is not so simple. There are a few animals (some amphibians) which have land legs but pass their lives in the water. There are many which breathe only by lungs, yet live in the water (sea turtles, whales, porpoises). Some fishes have lungs. The "mud puppy" (*Necturus*, an amphibian) has a combination of legs, lungs, gills, and a mucous skin, and lives all the time in the water. Further, there are some amphibians which have legs and lungs and live on land, but have a mucous skin and otherwise are anatomically much more like fishes than like typical land animals. And there are many vertebrates which are highly adapted to aquatic life and yet, in their general anatomy, are like land vertebrates. In short, on the basis of habitat and adult organs directly related thereto, it is very difficult, if not impossible, to make any satisfactory primary subdivision of the vertebrates. The study of the embryonic development of vertebrates, however, has revealed something which proves very significant as a basis for classification.

In the development of some vertebrates (e.g., turtle, bird, cat), the embryo becomes enclosed within a system of thin membranes (Figs. 239, 241) which are produced by the embryo and are composed of living cellular material. In certain of these membranes (allantois and yolk-sac) there are blood-vessels through which the embryonic blood circulates. This system of membranes provides for the mechanical protection, the respiration, and, to varying extents, the nutrition of the developing animal. The membrane which is next to the body of the embryo is the **amnion**. In other vertebrates (e.g., fish, frog), no such membranes are produced by the embryo, which therefore usually develops in direct contact with the external medium, water.

If, now, the vertebrates are separated into two groups, one, **Amniota**, including those whose embryos have the amnion and the other membranes which are always associated with it, and the other group, **Anamnia** (or Anamniota), including those in which no such membranes are produced, the result is perfectly satisfactory as the initial step in classifying vertebrates. The adult members of each group have a high degree of anatomic similarity. However great their differences, the members of one group are more like one another than like members

of the other group. The great majority of the Anamnia are aquatic and most of these are lifelong gill-breathers. Some (amphibians) have gills only in a temporary larval stage. A few amphibians omit the larval stage and never have gills. The paired appendages are fins in most of the Anamnia, but in some (amphibians) are legs; and the skin is always mucous, even in the land-dwellers. The great majority of the Amniota are terrestrial. All are lung-breathers, whether living on land or in water, and never at any time possess gills. The skin does not produce mucus. The paired appendages are structurally of the land type, even in the aquatic members of the group. In short, despite the apparently anomalous occurrence of lungs and legs in water-dwellers and a mucous skin in a few land-dwellers, the distinction between Anamnia and Amniota seems to be sound and in full accord with all evidence bearing on the genetic relationships of the groups.

The next step in the classification is comparatively easy. The members of each of the primary divisions, Anamnia and Amniota, readily fall into several groups which, so far as recent vertebrates are concerned, are sharply marked and readily defined—fishes, amphibians, reptiles, birds, and mammals. Among “fishes,” however, are a few which are so very unlike the rest that it seems best to separate them. These are the “round-mouthed” eels. Accordingly, it is the common practice to recognize six **Classes** under Vertebrata as follows: **Cyclostomata, Pisces, Amphibia, Reptilia, Aves, Mammalia**. The first three classes are anamniote; the second three are amniote. The following classification includes only groups which contain living representatives. Inclusion of extinct groups would greatly extend and complicate the classification. Certain extinct groups which are important as “connecting links” will be briefly mentioned. The general scheme of the major subdivisions of Vertebrata is as follows:

## SUBPHYLUM VERTEBRATA

		DIVISION ANAMNIA		
AGNATHA.....		Class <b>Cyclostomata</b>	}	} ICHTHYOPSIDA
		Class <b>Pisces</b>		
		Class <b>Amphibia</b>		
GNATHO- STOMATA	}	DIVISION AMNIOTA		
	}	Class <b>Reptilia</b> .....	}	} SAUROPSIDA
	}	Class <b>Aves</b> .....		
	}	Class <b>Mammalia</b>		
				} Homothermous

The cyclostomes have a round suctorial mouth devoid of jaws. Therefore, in contrast to the jawless (agnathous) **Cyclostomata**, all

other vertebrates, having a transversely elongated mouth with upper and lower jaws, are collectively called **Gnathostomata**. In contrast to the four-finned fishes, the Amphibia and Amniota, whose members are, in general, four-legged, constitute the **Tetrapoda**. Even birds are tetrapods because the internal structure of the wing is, in a modified way, like that of a foreleg. The hoatzin (*Opisthocomus*, a South American bird), before it acquires the power of flight, uses the wings in climbing and crawling about. The terms **Ichthyopsida** and **Sauropsida**, devised by T. H. Huxley, are often convenient. "Ichthyopsida" means "fishlike." Authors differ as to whether it should or should not include the cyclostomes. They are included in it here on the ground that they are as fishlike as are the frogs and toads. Birds are conspicuously reptilian in many respects. Therefore "Sauropsida" is a useful term comprising reptiles and birds. (A somewhat different use of "Sauropsida" has been recently proposed: see p. 629.) Finally, a highly important distinction is that based on the temperature of the body. Some vertebrates are "cold-blooded," others are "warm-blooded." But these terms are inaccurate. "Cold-blooded" is intended to designate that condition in which the animal's temperature approximates that of the external medium and varies with changes of external temperature. Animals having such variable temperature are "**poikilothermous**." In "warm-blooded" animals the internal temperature is stabilized at a particular level independently of changes in external temperature—the "**homothermous**" condition, characteristic of birds and mammals only.

Conveniently brief definitions of the several Classes follow.

**Cyclostomata:** round-mouthed eels.

**Pisces:** permanent gills; paired appendages are fins.

**Amphibia:** gills either temporary or permanent or (rarely) lacking; jointed pentadactyl legs.

**Reptilia:** poikilothermous amniotes; dry skin with thick external horny layer differentiated into scales.

**Aves:** feathers.

**Mammalia:** hair, milk (mammary) glands.

In the following accounts of the several Classes, more extended descriptions will be given and the larger subdivisions of each class will be described.

#### GEOLOGIC TIMES

In the following chapters, occasional reference will be made to the ancient history of groups of vertebrates. Readers who may be unfamiliar with the names and sequence of the more or less arbitrary

divisions of the earth's geologic history should refer, when necessary, to Table 3.

*Table 3*  
SEQUENCE OF ORGANISMS IN GEOLOGIC TIME

<i>Eras</i>	<i>Periods</i>	<i>Duration in Millions of Years</i>		<i>Characteristic Organisms</i>
Cenozoic	Recent		66	Modern races of men. Recent plants and animals
	Pleistocene (Glacial)	1		Early species of men and other primates. Mammals dominant
	Tertiary	65		Lemuroids and insectivores appear. First placental mammals
Mesozoic	Cretaceous	60	125	Mammals mostly marsupials. Reptiles highly specialized. Bony fishes abundant. Flowering plants appear
	Jurassic	35		Diverse reptiles. Ganoid fishes. <b>First birds</b>
	Triassic	30		Crocodyles and dinosaurs. Reptiles dominant. <b>First mammals</b>
Paleozoic	Permian	30	350	Mammal-like reptiles. Trilobites disappear
	Pennsylvanian	35		Amphibians and <b>first reptiles</b> . Coniferous plants
	Mississippian	15		Earliest amphibian fossils. Horse-tails and club-mosses
	Devonian	15		<b>Amphibian footprints</b> . Lungfishes. Earliest land plants
	Silurian	35		Ostracoderm (armored) fishes. Elasmobranchs. Land plants begin
	Ordovician	35		<b>Vertebrates appear</b> . <b>First fishes</b> . <b>First insects</b>
	Cambrian	75		Invertebrates abundant. First trilobites





The division Ichthyopsida includes three Classes: the fishlike Cyclostomata; the typical fishes, Pisces; and the Amphibia.

## I. Class Cyclostomata

**Cyclostomes** (Fig. 317) are the round-mouthed lamprey eels (**Petromyzon**) and hagfishes (**Bdellostoma** and **Myxine**). The mouth, devoid of jaws, is at the center of a suctorial disk whose surface bears small teeth composed of a horny substance produced by the epidermis. By means of the oral sucker, the cyclostome attaches itself to the body of its prey, usually a fish, and by rasping movements of the toothed sucking disk bores into the flesh of the prey. They have a persistent notochord and, in *Petromyzon*, suggestions of vertebrae in the occurrence of cartilaginous rods or plates, two pairs to each pair of myomeres, forming a series of incomplete and discontinuous **neural**

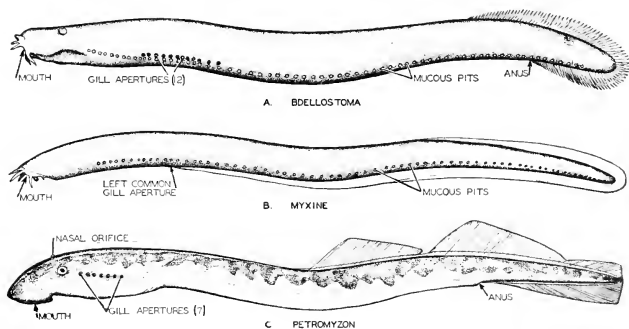


FIG. 317. Three characteristic genera of cyclostomes—*Bdellostoma*, *Myxine*, and *Petromyzon*. (After Dean. Courtesy, Neal and Rand: "Chordate Anatomy," Philadelphia, The Blakiston Company.)

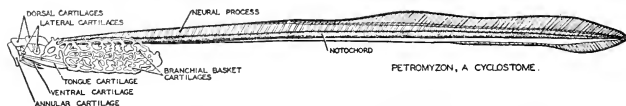


FIG. 318. Skeleton of a cyclostome, *Petromyzon*. (After Dean. Courtesy, Neal and Rand: "Chordate Anatomy," Philadelphia, The Blakiston Company.)

arches embedded in the connective-tissue sheath surrounding the spinal cord. This sheath is continuous with the similar investment of the notochord (Figs. 318, 319). The cartilaginous cranium is incomplete and the visceral skeleton consists of an irregular cartilaginous "branchial basket" (Fig. 319) instead of definite arches. The gill-chambers are numerous. Some species of *Bdellostoma* have as many as 14 pairs. *Petromyzon* has seven pairs.

Cyclostomes have no paired fins. There are no scales in the highly mucous skin. The **nasal chamber** in the adult is single and median, but it originates by fusion of two embryonic nasal sacs. The single external naris is median and dorsal. Some species are hermaphroditic.

*Petromyzon* undergoes metamorphosis during its development. Its larval stage is known as **ammocoetes** (Fig. 316B). This larva has a

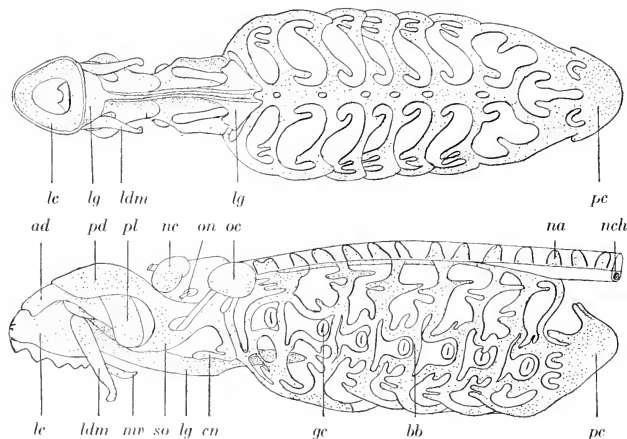


FIG. 319. Ventral and lateral views of the skull of lamprey (*Petromyzon marinus*). (*ad*) anterior dorsal cartilage; (*bb*) branchial basket; (*cn*) cornual cartilage; (*gc*) gill-cleft; (*le*) labial (annular) cartilage; (*ldm*) lateral distal mandibular; (*lg*) lingual cartilage; (*mv*) median ventral cartilage; (*na*) neural arch; (*nc*) nasal capsule; (*nch*) notochord; (*oc*) otic capsule; (*on*) optic nerve; (*pc*) pericardial cartilage; (*pd*) posterior dorsal cartilage; (*pl*) posterior lateral cartilage; (*so*) subocular arch. (After Parker. Courtesy, Kingsley: "Comparative Anatomy of Vertebrates," Philadelphia, The Blakiston Company.)

pharyngeal endostyle like that of the tunicates and *Amphioxus*. During metamorphosis, the endostyle becomes transformed into the thyroid gland of the adult.

The cyclostomes range in length from a meter to about a third of that. They are geographically widely distributed. Lampreys occur both in fresh and in salt water. The hags are marine.

Of special interest in connection with the Cyclostomata is the extinct Paleozoic group, **Ostracodermi**. These fossil and more or less fishlike animals (Fig. 320A) resemble cyclostomes in some striking respects. They had no jaws and probably no paired fins, although in some cases there is doubtful evidence of them. The nasal aperture was median and dorsal. Unlike the cyclostomes, however, they were covered

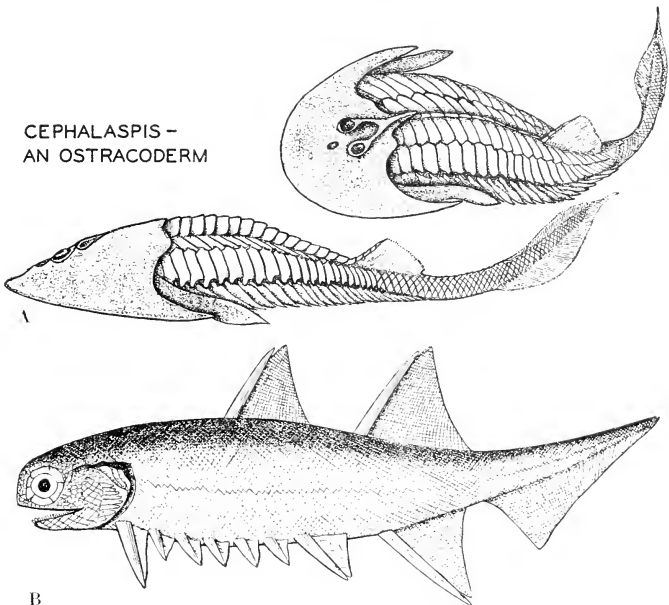


FIG. 320. (A) *Cephalaspis*, an ostracoderm: (*above*) approximately dorsal, (*below*) lateral aspect. It may have affinities with cyclostomes. According to W. Patten, it relates vertebrates to arachnids. (B) *Climatius*, a lower Devonian acanthodian with accessory paired fins: about 3 inches in length. (A, Courtesy, Neal and Rand: "Chordate Anatomy," Philadelphia, The Blakiston Company. B, After Traquair and Watson. Courtesy, Romer: "Vertebrate Paleontology," Chicago, University of Chicago Press.)

by bony armor which was especially strongly developed over the head. Little is known concerning the internal skeleton. It seems probable that they possessed the notochord, although they lacked any internal skeletal parts capable of becoming fossilized. They were small animals, usually less than a foot long.

The Ostracodermi comprised a considerable number of members which were highly diversified as to form of body and as to the nature and distribution of the external bony plates. It is probable that the ostracoderms and cyclostomes are remotely related. They are included together in the group *Agnatha*.

## II. Class Pisces

Fishes are now the dominant aquatic animals of the world. In number of species they are exceeded, among vertebrates, only by the birds. Their extremely diverse anatomic adaptations enable them to live in fresh, brackish, or salt water and, in fact, to inhabit successfully

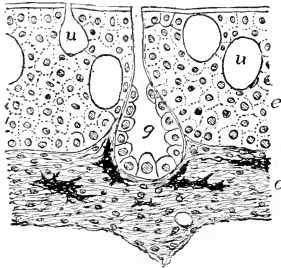


FIG. 321. Skin of lungfish, *Protopterus*; section perpendicular to surface; much enlarged. (c) Dermis (corium); (e) epidermis; (g) multicellular gland; (u) unicellular gland. (Courtesy, Kingsley: "Comparative Anatomy of Vertebrates," Philadelphia, The Blakiston Company.)

a variety of aquatic environments ranging from clean, well-aerated water to mud. Some live near the surface. Others, living at depths beyond the penetration of sunlight, are equipped with highly specialized integumentary light-producing organs. In size they range from the whale shark, which may attain a length of 45 feet, to the Philippine pygmy (*Pandaka pygmaea*) which, when full grown, is about two fifths of an inch long.

In addition to their **permanent gills** and **paired fins**, fishes have the typical aquatic skin—that is, a skin richly provided with mucus-producing glands, usually of the simple unicellular type (Fig. 321). In most fishes, too, the skin produces scales which exist in great variety of form and structure but are alike in being composed of calcareous material. Taking the group as a whole, the endoskeletal materials include the notochord, cartilage, and bone. There is always a more or less well-developed vertebral column except in the sturgeons and the lungfishes, in which the notochord persists and vertebrae are represented only by segmentally arranged and discontinuous neural arches surrounding the spinal cord and, in the caudal region, hemal arches enclosing the main caudal blood-vessels

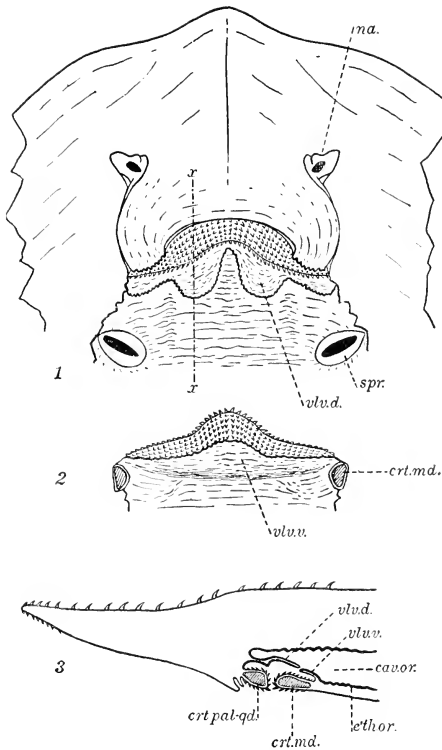


FIG. 322. Breathing valve of a skate. (1) Lower jaw removed; ventral view of upper jaw and roof of mouth. (2) Dorsal surface of the detached lower jaw. (3) Parasagittal section at position indicated by *x-x* in (1). (*cav. or.*) Oral cavity; (*crt. md.*) mandibular cartilage; (*crt. pal-qd.*) palatoquadrate cartilage; (*eth. or.*) oral epithelium; (*na.*) nostril; (*spr.*) internal opening of spiracle; (*vlv. d.*) dorsal flap of breathing valve; (*vlv. v.*) ventral flap of breathing valve.

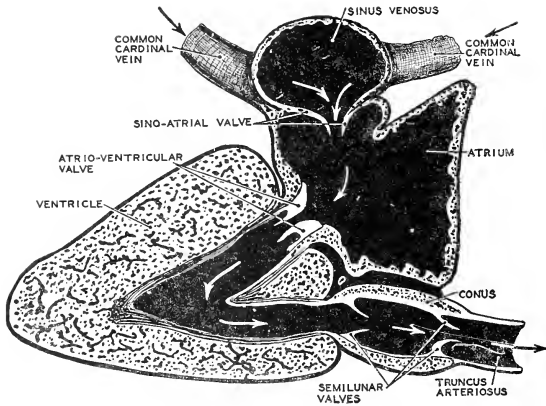


FIG. 323. A diagram of the primitive (fish) heart, as seen in a median longitudinal section. Anterior is to the right. The course of blood in the heart (indicated by arrows) takes the form of a letter S. (After Keith. Courtesy, Neal and Rand; "Chordate Anatomy," Philadelphia, The Blakiston Company.)

which lie just under the notochord. The arches may be cartilaginous or bony. They are, however, much more strongly developed than the neural arches of cyclostomes.

The maximum number of **pharyngeal clefts** occurs in a shark, *Heplanchus* (Fig. 329A), having a pair of spiracles and seven pairs of gill-clefts. Most adult fishes have no spiracles and only five pairs of gill-clefts. In some cases there are fewer than five. The highly characteristic **visceral skeleton**, cartilaginous or bony, is developed around the pharynx, consisting of arches alternating in position with the pharyngeal clefts (Fig. 120).

Most fishes have a **breathing valve** which prevents exit of water from the mouth when the pharyngeal wall contracts to force water out via the gill-chambers. Just inside the oral aperture are a dorsal and a ventral inwardly projecting fold of the oral lining (Fig. 322). Pressure of water against these flaps from behind forces them forward so that they meet and occlude the oral passage.

In most fishes the **heart** consists of two chambers, a receiving chamber, the auricle, and a pumping chamber, the ventricle (Fig. 323). In lungfishes there are two auricles, the right one receiving blood from the general circulation and the left receiving blood from the lungs. The two auricles open into a common single ventricle.

The **nervous organs** of fishes are arranged on the same plan as in all other vertebrates. Of all organ-systems, none is more conservative

than the vertebrate nervous system. The brain of the fish is differentiated into five regions which, beyond question, correspond structurally and, at least in a general way, functionally, to the five main divisions of the human brain (Fig. 324). In the telencephalon, however, cerebral hemispheres are poorly developed, and their roof, the **pallium**, contains little or, in most fishes, no nervous tissue. In modern fishes, there are 10 pairs of cranial nerves. The autonomic nervous system is well developed.

The "five senses" of man (but in reality he has several more than five) are provided for in fishes by organs which differ only in details and in degree of efficiency from corresponding organs in mammals. **Eyes, ears, and olfactory (nasal) organs** are well developed in fishes. In the mouth are organs of **taste**, but—unlike anything found in Amniota—sense-organs similar to the oral organs of taste commonly occur on the external skin, especially on the head and sometimes far back on the trunk and even on the fins (see p. 196). Apparently many fishes may become aware of the proximity of food by "tasting" it through the skin. The skin is also well supplied with **tactile** sensory structures but in a limited variety of types as compared to the skin of land animals.

In addition to these external organs of chemical and tactile sense, fishes have an integumentary sensory equipment which has no exact

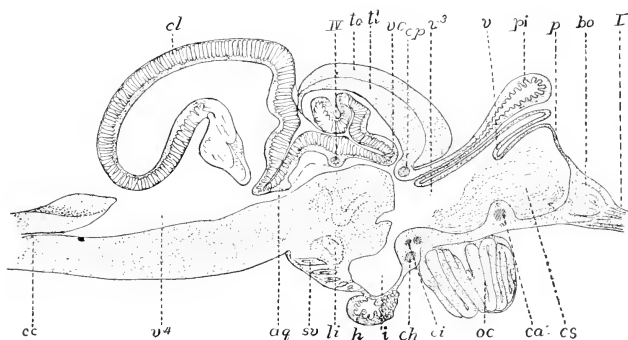


FIG. 324. Sagittal section of brain of trout. (*aq*) Aqueduct; (*bo*) bulbous olfactorius; (*ca*, *ch*, *ci*, *cp*) anterior, horizontal, inferior, and posterior commissures; (*cc*) central canal; (*cl*) cerebellum; (*cs*) corpus striatum; (*h*) hypophysis; (*i*) infundibulum; (*li*) inferior lobe; (*oc*) optic chiasm; (*p*) pallium; (*pi*) pinealis; (*sv*) saccus vasculosus; (*tl*) torus longitudinalis; (*to*) tectum of optic lobes; (*v*) velum transversum; (*v<sup>3</sup>*, *v<sup>4</sup>*) ventricles; (*vc*) valvula cerebelli; (*I*) olfactory nerve; (*IV*) trochlear nerve. (After Rahl-Rückhard. Courtesy, Kingsley: "Comparative Anatomy of Vertebrates," Philadelphia, The Blakiston Company.)

counterpart among Amniota. It consists of minute organs which are sensitive to stimulation by vibrations transmitted through the water. The effective vibrations are of much lower frequency (i.e., "slow" vibrations) than those which ordinarily affect a vertebrate ear. Each organ is a small cluster of specialized epidermal cells which, at their bases, are related to branches of nerves which connect with the posterior part of the brain (see p. 164, and Fig. 149). Organs of this kind are arranged at regular intervals along a line extending, on each side of the body, from head to tail at the level of the division between the dorsal and ventral parts of the myomeres, and usually in a canal enclosed within the skin. From this fact the organs derive their name, "**lateral-line organs.**" Rows of the organs may occur elsewhere on the body. On the head is a somewhat complex pattern of rows of these organs (Fig. 150). Similar organs occur also singly and distributed in no particular order. These lateral-line organs may serve to make the fish aware of the proximity of solid objects or of anything which may set up a commotion in the water.

#### CLASSIFICATION

All classifications of fishes rest, in the main, on the condition of the skeleton. At one extreme are sharks whose endoskeleton is entirely cartilaginous; at the other are fishes whose adult skeleton is completely bony. Between the extremes are fishes whose adult skeletons include both cartilage and bone, and in highly varying proportions. Most classifications begin, therefore, by separating fishes into **Chondrichthyes**, having (in addition to a possibly persisting notochord) only cartilage in the endoskeleton; and **Osteichthyes**, having the skeleton more or less ossified. The first of these divisions includes, of modern fishes, only those that are sharklike. The second is vastly larger and highly diversified.

In the further classification of the **Osteichthyes**, much stress has been laid on the structure of the pectoral fin. In certain extinct fishes the proximal region of the projecting fin consisted of a thick muscular lobe containing heavy basal skeletal parts. In most modern fishes the muscles which move the fin extend only slightly, if at all, onto the basal region of the projecting fin which, therefore, is thin and bladelike even to its base and is supported by slender rays developed in the skin. Distinction is made, accordingly, between "lobe-fin" fishes, **Crossopterygii**, and "ray-fin" fishes, **Actinopterygii**. Other features are consistently associated with the difference in the fins. The **Crossopterygii** are nearly, if not quite, extinct. A South African deep-sea fish (**Latimeria**), known from only one incomplete specimen, has been adjudged to be a genuine crossopterygian—the only genus known to



have survived since the Mesozoic. Two existing African fishes, **Polyp-terus** (Fig. 329D) and **Calamoichthys**, have been commonly regarded as being survivors of the group. Recent studies, however, favor assigning these two fishes to the "ray-fins"—in spite of the fact that the pectoral fin is prominently "lobed." Leaving Latimeria and the two problematic African fishes out of account, all modern Osteichthyes except lungfishes are certainly actinopterygians. The "lobe-fin" and "ray-fin" fishes are commonly comprised together under the name **Teleostomi** (meaning "terminal mouth"), referring to the fact that in most of them—but it is not true of all—the mouth is at the tip of the head, in contrast to the shark's mouth, which is usually far back on the ventral surface of the head. The Osteichthyes are separated into groups defined mainly on the basis of the degree of ossification of the skeleton.

The possession of functional lungs, together with other peculiarities, including the three-chambered heart, is regarded as sufficient grounds for putting lungfishes in a group by themselves.

If **ancient fishes** be taken into account, fossils reveal the existence of an abundant and highly diversified Paleozoic piscine fauna, the chief point of resemblance of whose members was possession of a more or less complete and usually heavy dermal armor consisting of either small bony scales or large plates of bone. Because of this common feature, the whole otherwise motley population is put under the name **Placodermi**. Of these placoderms, some (the **Acanthodii**; Fig. 320B) were externally suggestive of sharks, and others (**Stegoselachii**) were dorsoventrally flattened and broadened in the manner of modern skates (Fig. 330). Most of them were small (less than a foot long), but among the **Arthrodira** were fishes which ranged up to a length of perhaps 30 feet.

Possession of a **jaw skeleton** of a somewhat simple and primitive type sharply distinguishes the Placodermi from the agnathous Ostracodermi. Further, unlike the Agnatha, the placoderms usually had well-developed pectoral and pelvic fins and in some cases (**Acanthodii**) several, up to five, pairs of relatively small fins between the pectorals and pelvics (Fig. 320B). The skeleton of the notochordal axis seems to have been poorly developed. In some cases, evidence of bony neural arches, and sometimes centra, is found.

The placoderms were literally "bony fishes," but their boniness was chiefly dermal. The pattern of their elaborate exoskeleton was so unlike that of the dermal bones of modern fishes that it is most unlikely that there is any direct phylogenetic relationship between the Placodermi and modern Osteichthyes. The placoderms apparently comprised

various groups which flourished in Paleozoic times and became highly specialized in their several peculiar ways, but they all died out without giving rise to any race of fishes capable of going on into the succeeding ages.

A comparatively simple classification of modern fishes may be arranged as follows:

## CLASS PISCES

### A. CHONDRICHTHYES

SUBCLASS I. ELASMOBRANCHII (SELACHII): sharks and rays (skates)

SUBCLASS II. HOLOCEPHALI: *Chimaera*

### B. OSTEICHTHYES

SUBCLASS III. CROSSOPTERYGII: "lobe-fins"

SUBCLASS IV. ACTINOPTERYGII: "ray-fins"

**Order Chondrostei:** sturgeons

**Order Polypterini:** *Polypterus*

**Order Holosteii:** gar pike (*Lepidosteus*), *Amia*

**Order Teleostei:** common "bony fishes"

SUBCLASS V. DIPNOI: lungfishes

#### SUBCLASS I. ELASMOBRANCHII

**Sharklike Fishes. Endoskeleton cartilaginous** (Fig. 325). **Well-developed vertebral column**, with only vestiges of notochord between successive biconcave (**amphicoelous**) vertebrae (Fig. 326). Caudal fin **heterocercal**—i.e., two-lobed—the vertebral column bending upward into the larger dorsal lobe (Fig. 327C). **Upper jaw** usually suspended **movably** below the cranium (Fig. 116). Skin usually thickly beset with small **placoid scales**, each consisting of a basal plate surmounted by one or more sharp projecting spines (Fig. 328). Respiratory passages consist of **spiracles** (closed in a few sharks) and five to seven pairs of branchial clefts which open independently and directly to the exterior. Internal surface of intestine increased by presence of an extensive spiral fold of the inner layer of the tube—the "**spiral valve**" (Fig. 23). Urinogenital ducts and anus open into a common **cloaca** which has a single external aperture.

The elasmobranchs are marine, only rarely occurring in fresh water. They inhabit the warmer and temperate waters of all seas. The sharks (Fig. 329A) and dogfishes are powerful swimmers, of roving habits, and predaceous. The rays or skates (Fig. 330) are anatomically sharklike except in the extreme dorsoventral flattening of the body and exaggeration of the pectoral fins—a form related to their sluggish bottom-dwelling habit.

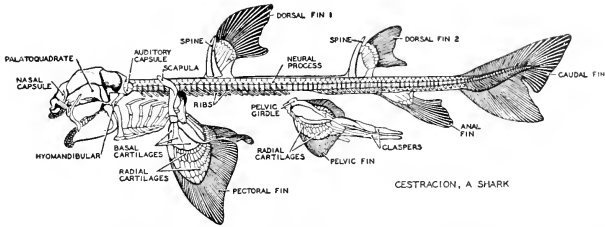


FIG. 325. The skeleton of an elasmobranch, *Cestracion*. (After Dean, Courtesy, Neal and Rand: "Chordate Anatomy," Philadelphia, The Blakiston Company.)

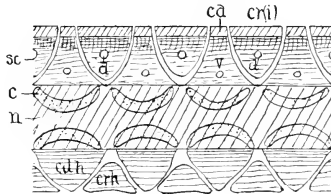


FIG. 326. Sagittal section of *Squalus* vertebrae, cut surfaces obliquely lined. (*c*) Calcifications of centra; (*cd*) caudineurals; (*cdh*) caudihemals; (*crh*) cranihemals; (*cri*) cranineurals (intercalaria); (*d*) exits of dorsal nerve-roots; (*n*) notochord; (*n*) exits of ventral nerve-roots. (Courtesy, Kingsley: "Comparative Anatomy of Vertebrates," Philadelphia, The Blakiston Company.)

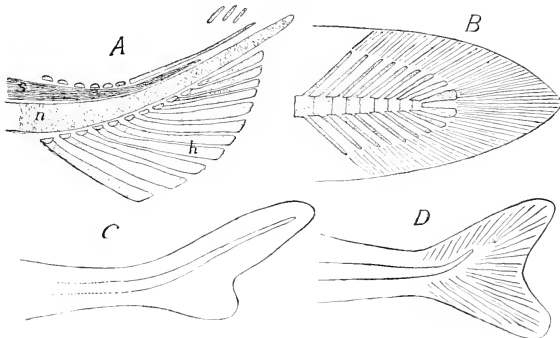


FIG. 327. Tails of fishes. (A) Young *Amia*, skeleton. (B) Diphyercal. (C) Heterocercal. (D) Homocercal. (*h*) Hypurals; (*n*) notochord; (*s*) spinal cord. (Courtesy, Kingsley: "Comparative Anatomy of Vertebrates," Philadelphia, The Blakiston Company.)

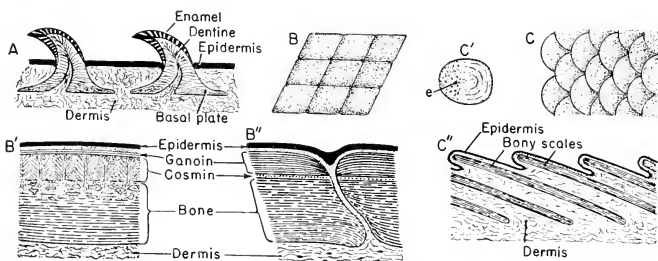


FIG. 328. Diagrams illustrating the chief types of fish scales. In all the figures anterior is toward the right.

(A) Placoid scales of shark: section perpendicular to surface of skin.

(B) Surface view of flat, slightly overlapping rhomboid scales. (B') Part of a section perpendicular to the surface of a cosmoid rhomboid scale, much enlarged. The histologic structure of the cosmin suggests that it is produced by fusion of numerous units, each resembling a placoid spine (but without enamel), compactly crowded together on a thick bony base. (B'') Section, perpendicular to the surface of the skin and much enlarged, showing contiguous regions of two ganoid rhomboid scales.

(C) Surface view of overlapping teleost scales. (C') A single teleost scale. Epidermis (e) covers the region of the posterior surface which is not overlapped by other scales. (C'') Section, perpendicular to the surface of the body, of overlapping teleost scales.

#### SUBCLASS II. HOLOCEPHALI

Endoskeleton cartilaginous except for a **persisting notochord** around which are developed **incomplete cartilaginous vertebrae**. Caudal fin heterocercal. Upper jaw **immovably** joined to cranium. Most of skin devoid of scales. **No spiracles** and only four pairs of branchial clefts. The four clefts on a side open under an **operculum**, a flap of skin extending from in front backward over the gill region. The space beneath the operculum opens by a single lateral aperture at the rear of the gill region. Spiral valve in intestine. **No cloaca**, the anal and urinogenital passages opening separately on the ventral surface.

These fishes are, in general appearance, sharklike (Fig. 329B). They attain a length of 1 to 3 feet and are all marine, having a wide distribution in the oceans of both Eastern and Western Hemispheres. There are only three living genera, of which the best known is *Chimaera*. Some classifications place the Holocephali as a subdivision under Elasmobranchii.

#### SUBCLASS III. CROSSOPTERYGII

Endoskeleton **more or less nearly completely ossified**. Skull usually strongly ossified, including both dermal and cartilage bones

whose general arrangement resembles that of the bones of the skull in modern fishes. A large hyomandibular bone, extending from otic region of cranium to the quadrate bone, assists in supporting the jaws. Degree of vertebral ossification variable; centra usually incomplete or lacking; presumably a persistent notochord. Caudal fin heterocercal or diphyccercal (Fig. 327).

**Scales** are strongly developed, each consisting of a thick plate of bone overlaid by a thick layer of calcareous substance, **cosmin**, resembling dentine in structure. The cosmin is covered externally by a very thin layer of a harder enamel-like substance, ganoin. Scales of this type are called "**cosmoid**" (Fig. 328).

External apertures of each lateral series of gill-clefts are covered by an **operculum** (Fig. 329C), a backwardly projecting fold of skin stiffened by thin plates of dermal bone and free at its posterior edge to allow egress of water from the gill-chambers. **Internal nares** (**choanae**) piercing anterior roof of mouth indicate possession of lungs as accessory respiratory organs.

The especially distinctive characteristics of the group are the **lobc-fins**, **cosmoid scales**, **choanae**, and **incomplete vertebral ossification**.

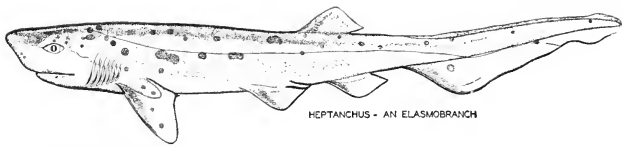
The crossopterygians (Fig. 329C), primitive fresh-water fishes, were at their height in the Devonian, but steadily diminished during the Mesozoic, and only one genus (*Lalimeria*), so far as is known, now exists.

#### SUBCLASS IV. ACTINOPTERYGII

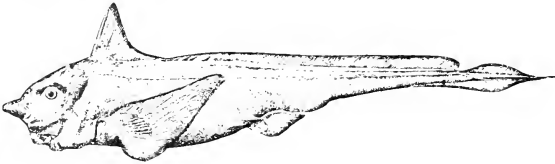
**Endoskeleton partly or completely bony.** Embryonic notochord usually replaced by a bony vertebral column. Vertebrae usually amphicoelous. Scales, sometimes lacking, are calcareous and of several structurally different types but rarely placoid and **never cosmoid**. Gill-clefts (exclusive of spiracles) never in excess of five pairs; sometimes fewer. External branchial apertures of each side covered by an **operculum**. **No cloaca**.

Spiracles, the spiral valve, and the heterocercal tail-fin do not appear in the great majority of adult modern actinopterygians, but in a small minority of them and in many extinct members of the group these three elasmobranch features occur, together with other characteristics which are reminiscent of sharks.

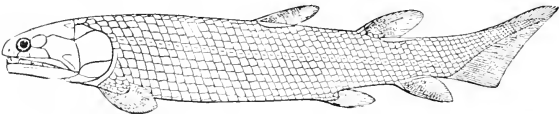
An especially prominent feature of most actinopterygians is an organ whose equivalent is not to be found among sharks. This is the **air-bladder** or "swim-bladder." It is a thin-walled sac, single or paired, which develops as a hollow outgrowth from the wall of the pharynx or from a region of the digestive tube more or less posterior to the pharynx (Fig. 331). In the adult the sac may or may not retain its original open



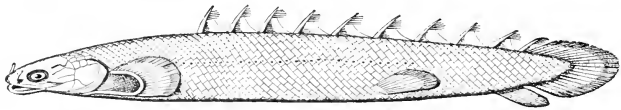
A. ELASMOBRANCHII




B. HOLOCEPHALI




C. CROSSOPTERYGII



D. POLYPTERINI



E. TELEOSTEI



F. DIPNOI

FIG. 329. (A) *Heptanchus*. (B) *Chimaera*. (C) *Osteolepis*. (D) *Polypterus*. (E) *Scomberomorus*, Spanish mackerel. (F) *Neoceratodus*, Australian lungfish. (A, D, E, courtesy, Neal and Rand: "Chordate Anatomy," Philadelphia, The Blakiston Company. B, courtesy, Jordan and Evermann: "Fishes of North and Middle America," Washington, The Smithsonian Institution. C, F, from "Cambridge Natural History," Vol. VII. By permission of The Macmillan Company, publishers.)

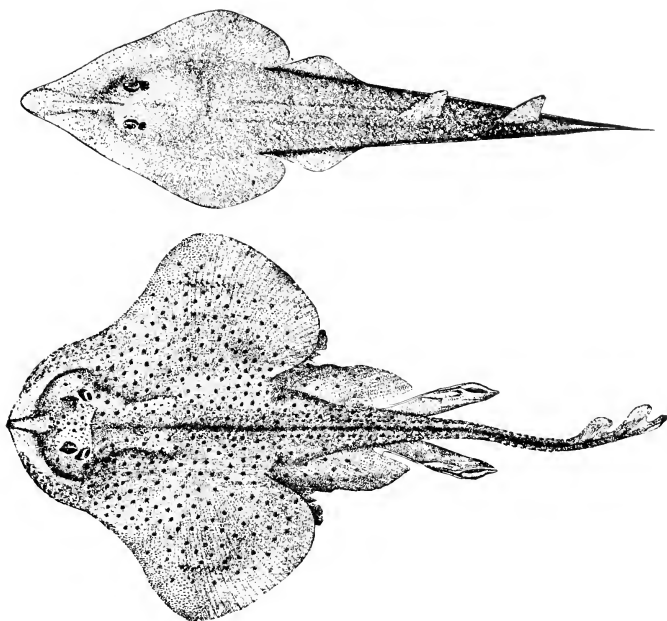


FIG. 330. (Top) *Rhinobatus lentiginosus* (Garman): in form of body, intermediate between an ordinary shark and the very broad thin skate. (Bottom) *Raja erinacea* (Mitchill). (Courtesy, Jordan and Evermann: "Fishes of North and Middle America," Washington, The Smithsonian Institution.)

connection with the pharynx. This air-bladder may serve as an accessory respiratory organ (when open into the pharynx) or it may have a hydrostatic function, making possible the adjustment of the specific gravity of the fish to that of the water by changes in the volume of gas within the air-bladder. In some fishes the organ probably serves both functions. The gas within the closed air-bladder is mainly oxygen derived by diffusion from blood contained in vessels in the wall of the organ. The volume of gas in the bladder may, on occasion, be reduced by absorption into the blood.

The following subdivisions of Actinopterygii are generally recognized.

#### *Order Chondrostei*

**Notochord** fully persistent; vertebrae represented only by cartilaginous or partly bony arches—**no centra**. Skull largely cartilaginous.

Tail-fin **heterocercal** (Figs. 327, 332A). **Spiracles** usually open; five pairs of gill-clefts. **Air-bladder dorsal** to digestive tube and permanently open. **Spiral valve** in intestine well developed.

These are the **sturgeons** (Fig. 333A), found in large rivers and lakes of the northern hemisphere, and the "spoonbill" (**Polyodon**) of

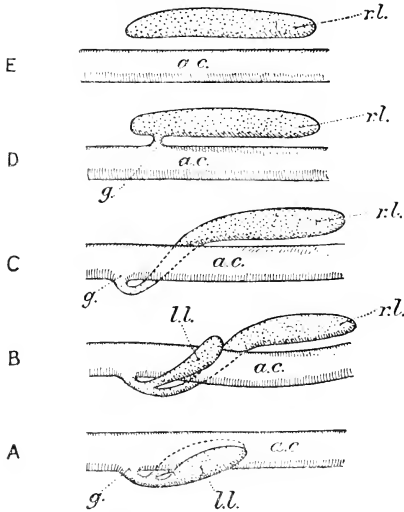


FIG. 331. Diagram illustrating the air-bladder or lung in fishes, as seen from the left side. (A) Primitive symmetric arrangement. (B) *Polypterus*. (C) *Neoceratodus*. (D) Physostomous teleost. (E) Physoclistic teleost. (a.c.) Alimentary canal; (g.) glottis; (ll.) left lung; (rl.) right lung. (From Goodrich, "Studies on the Structure and Development of Vertebrates." By permission of The Macmillan Company, publishers.)

the Mississippi River. A conspicuous feature of the common sturgeon, **Acipenser**, is the scales, which are massive plates consisting entirely of bone and arranged in rows extending lengthwise of the trunk and tail. The spoonbill is nearly devoid of scales.

#### Order Polypterini

**Skeleton well ossified**, although much cartilage persists in cranial portion of skull. **Complete bony vertebrae with centra**. Tail-fin **diphycercal** (Fig. 327B). Body completely invested by an armor of thick rhomboidal scales (Fig. 328) consisting of bone covered externally



by a thick layer of peculiar and very hard calcareous substance, **ganoin**, resembling enamel but of dermal origin. **Spiracles open**; four pairs of gill-clefts. **Air-bladder ventral** to digestive tube and permanently open into pharynx, therefore virtually a lung.

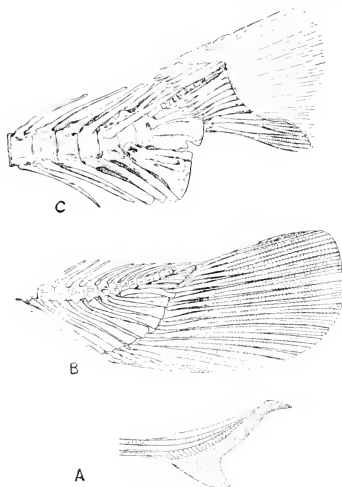
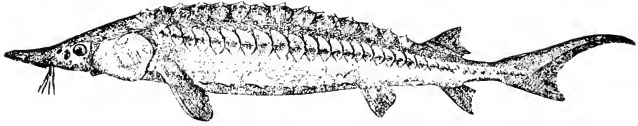


FIG. 332. Skeletons of tails of fishes. (A) Sturgeon (*Acipenser*). (B) Gar pike (*Lepidosteus*). (C) Tarpon, a teleost. (Courtesy, American Museum of Natural History, New York.)

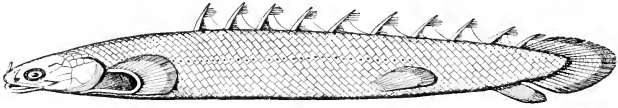
This order includes only two living genera, **Polypterus** (Fig. 333B) and **Calamoichthys**, occurring only in Africa. Best known is *Polypterus*, found in the Nile and Congo rivers, the generic name referring to the numerous small dorsal fins.

#### Order Holostei

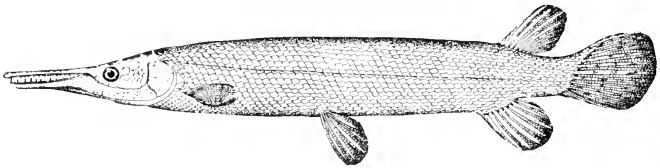
**Skeleton well ossified** except for more or less cartilage persistent in cranial part of adult skull. Bony vertebrae with centra. **Notochord not persistent**, or only remnants of it, in adult. Tail-fin **heterocercal** (*Lepidosteus*: Fig. 332B) or approximately **homocercal** (*Amia*: Fig. 333D). Body completely covered by scales (Fig. 328) of the heavy ganoin-covered type (*Lepidosteus*) or merely thin plates of bone (*Amia*). Embryonic **spiracles closed** in adult; five pairs of gill-clefts. **Air-bladder dorsal** to digestive tube and permanently open. Spiral valve very weakly developed.



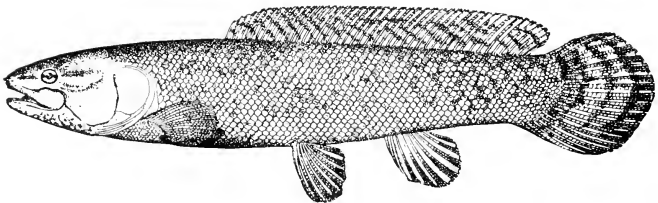
A



B



C



D

FIG. 333. Examples of Chondrostei (A), Polypterini (B), and Holostei (C, D). (A) *Acipenser rubicundus* (Le Sueur). (B) *Polypterus bichir*. (C) *Lepidosteus trisetochus* (Bloch and Schneider). (D) *Amia calva* (Linnaeus), female. (A, C, D, courtesy, Jordan and Evermann: "Fishes of North and Middle America," Washington, The Smithsonian Institution. B, after Dean. Courtesy, Neal and Rand: "Chordate Anatomy," Philadelphia, The Blakiston Company.)

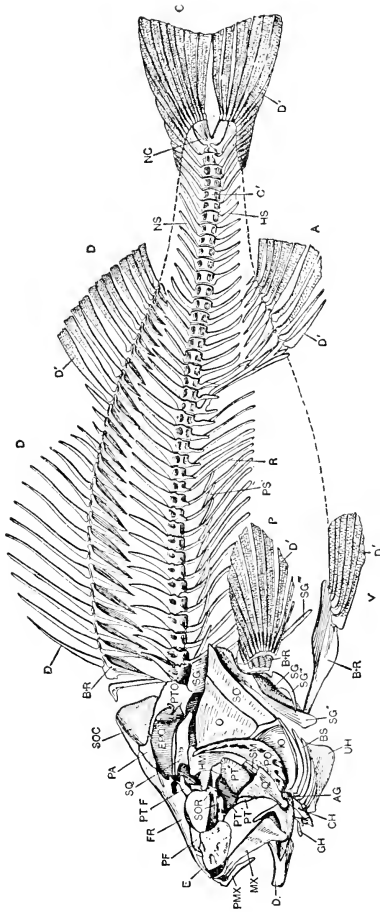


FIG. 331. The skeleton of a teleost, the perch, *Perca fluviatilis*. (A) Anal fin; (AG) angular; (B+R) basal and radial cartilages; (BS) branchiostegal rays; (C) caudal fin; (CH) ceratohyal; (D) dentary; (D') dermal rays of fins; (E) ethmoid; (EPO) epiotic; (FR) frontal; (GH) glossohyal (hypobranchial); (HM) hyomandibular; (HS) hernal spine (and arch); (IO) interoperculum; (MX) maxillary; (NC) urostyle, ossified tip of notochord; (NS) neural spine (and arch); (O) operculum; (P) pectoral fin; (PA) parietal; (PF) prefrontal; (PMX) premaxillary; (PO) preoperculum; (PS) supporting processes of ribs; (PT, PT', PT'') ento-, ecto-, and meta-ptyergoid; (PTF) postfrontal; (PTO) pterotic; (Q) quadrate; (R) ribs; (SG) shoulder girdle; (SG') dorsal process of SG; (SG'') outer rim of SG; (SG''') posterior processes of SG; (SM) symplectic; (SO) suboperculum; (SOC) crest of supraoccipital; (SOR) suborbital ring; (SQ) squamosal; (UH) urohyal; (V) pelvic ('ventral') fin. ( $\times 1\frac{1}{2}$ ). (Drawn by Dr. A. Graf, after Zittel, From Dean, "Fishes, Living and Fossil.")

Of living fishes, the only members of Holostei are the gar pike (*Lepidosteus*) and the "mudfish" or "bow-fin" (*Amia*). Both are North American fresh-water fishes (Fig. 333C, D). The vertebrae of *Lepidosteus* are exceptional for fishes in being convex in front and concave behind (opisthocoelous). The "alligator gar" may attain a length of 10 feet. *Amia* is a comparatively small fish.

### Order Teleostei

"**Bony Fishes.**" Ossification of skeleton at the maximum for fishes (Figs. 334, 335). (The name "Teleostei," meaning "completely bony," is not to be confused with "Teleostomi," referring to the terminal mouth.) Tail-fin **homocercal** or **diphycercal** (Figs. 327, 334). Pelvic fins more or less reduced or sometimes lacking, and commonly placed more or less in front of their typical position at the rear end of the trunk, in extreme cases (e.g., the cod and its allies, Gadidae) lying actually anterior to the pectoral fins (Fig. 299). In some eels, both pairs of fins absent. **Scales** usually simple, thin, overlapping **plates of bone** developed in lower layer (dermis) of skin (Fig. 328); sometimes elaborated into projecting spines (porcupine fishes) or other specialized forms; sometimes lacking (eels, swordfish, many catfishes). **Spiracles always closed**; five pairs of gill-clefts or in some cases fewer. Intestine has **no spiral valve** other than possible vestiges of it in a few cases.

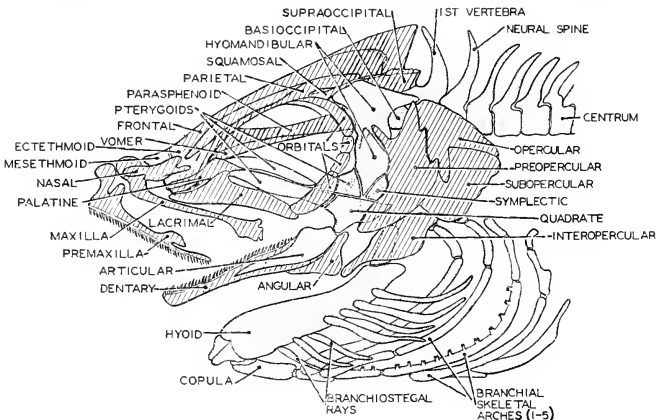


FIG. 335. Skull of hake in left lateral aspect. Membrane bones are cross-hatched, cartilage bones stippled. Compared with the skulls of other fishes, that of teleosts shows an increased dominance of membrane bones over those preformed in cartilage. (Courtesy, Neal and Rand: "Chordate Anatomy," Philadelphia, The Blakiston Company.)

The **air-bladder of teleosts** is always dorsal to the digestive tube. In some groups its embryonic communication with the lumen of the digestive tube is permanently retained; in others it becomes secondarily closed. In form, and in details of structure and relations, it exhibits great diversity among the many groups of Teleostei. Especially significant are the relations of the air-bladder to the ears. Many teleosts have anatomic arrangements which apparently utilize the static sensory mechanism of the ear (see p. 207) for control of gas pressure in the air-bladder. In some cases a pair of branches or diverticula project forward from the air-bladder, and the anterior end of each diverticulum abuts against the perilymph space of the otic sac of that side of the head. There is no open communication—the anterior end of the diverticulum is a “blind” end. In catfishes (**Siluridae**) and the carplike fishes (**Cyprinidae**), a skeletal mechanism intervenes between air-bladder and otic sacs. Just beneath the vertebral column are two chains of small bones articulated together—the “**Weberian ossicles**” (Fig. 336). The relatively large posterior ossicle of each chain is attached to the wall of the air-bladder. The very small but elongated anterior ossicle penetrates into the otic region and terminates against a membrane, on the other side of which is perilymph. (Incidentally, the right and left saccular regions of the ears are transversely joined beneath the brain so that the right and left otic cavities are continuous.) A third small ossicle is intercalated between the posterior and anterior members of each chain.

The structure of the **Weberian apparatus** indicates that effects of changes of pressure in the air-bladder are transmitted by the ossicles to the fluids (perilymph and endolymph) of the otic sacs. By this means, the reflex static mechanism of the ears is activated and appropriate adjustments of pressure in the air-bladder are automatically made. The **origin** of the two series of Weberian ossicles is obscure. They seem to derive their skeletal material from the closely adjacent region of the embryonic vertebral column or possibly, in part, from the dorsal ends of ribs.

In older classifications it was a common practice to subdivide Teleostei into two groups distinguished by the relation of the air-bladder to the digestive tube in the adult. The **Physostomi** were teleosts whose air-bladder remains in open communication with the digestive tube, as in the catfishes (**Siluridae**), pickerel, carp, salmon, trout, herring, and others. In the **Physoclisti** the air-bladder loses its embryonic connection with the digestive tube and becomes a closed sac. The great majority of teleosts are physoclastic. It has come to be realized, however, that, for purposes of genetic classification, these relations of the air-bladder to the digestive tube are not dependable. In

general, the less specialized fishes are physostomous and the highly specialized forms, such as the "headfish" and sea horse (Fig. 337: 7,9), are physoclistic. But there are many exceptions. It seems clear that the permanence of the duct of the air-bladder is not a sufficiently "conservative" characteristic to give it more than very limited or "short-range" significance in classification.

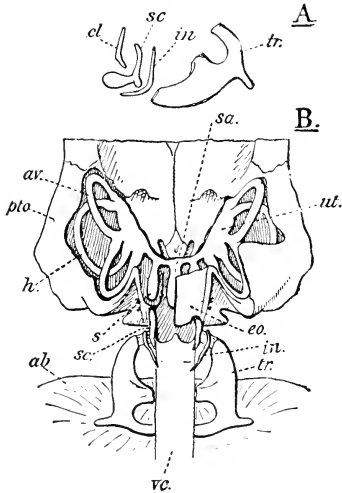


FIG. 336. Weberian apparatus of the catfish, *Macrones nemerus*. (A) The Weberian ossicles. (B) Portion of the skull, the otic labyrinth, and Weberian apparatus diagrammatically represented from above. (*ab*) Air-bladder; (*av*) anterior vertical canal of the ear; (*cl*) claustrum; (*eo*) exoccipital; (*h*) horizontal canal; (*in*) interclarium; (*pto*) pterotic; (*s*) sacculus; (*sa*) endolymphatic sinus; (*sc*) scaphium; (*tr*) tripus; (*ut*) utricle; (*vc*) vertebral column. (After Bridge and Haddon. From Goodrich, "Studies on the Structure and Development of Vertebrates." By permission of The Macmillan Company, publishers.)

The living members of Chondrostei, Polypterini, and Holostei, taken together, are usually regarded as representing eight genera. These genera are all narrowly restricted in their distribution and their members are not numerous anywhere. In contrast, the number of

species of Teleostei runs high into the thousands and the group has achieved dominance of the modern aquatic world. Viewing the Order as a whole, its most striking characteristic is the enormous diversity of those anatomic adaptations which have enabled fishes to succeed in every imaginable aquatic habitat and even make temporary excursions into the air (flying fishes) and ashore (the "climbing perch," *Anabas*, of southern Asia). In connection with these adaptations, the basic plan of the vertebrate body has been more profoundly and variously modified than in any other group of vertebrates. The results in some cases are creatures whose external appearance is such that they are hardly recognizable as fishes or even as vertebrates—e.g., the sea horse (*Hippocampus*) which looks like the "knight" of a set of chess, and a related fish (*Phyllopteryx*) which resembles nothing more than a scraggy bunch of seaweed (Fig. 337).




FIG. 337. Some of the more highly specialized teleosts. (1) *Acestra*. (2) *Saccopharynx*. (3) *Chirolophius*. (4) *Himantolophus*. (5) *Psettus*. (6a) *Ogcocephalus* (dorsal view). (6b) *Ogcocephalus* (anterior view). (7) *Hippocampus* (sea horse). (8) *Phyllopteryx*. (9) *Orthogoriscus mola* (headfish). (10) *Erocoetus volitans*. (11) *Ostracion*.

There is wide range in size of these fishes. Approximate lengths are as follows: 6 inches or less, numbers 4, 5, 7, 8; 12 inches or less, numbers 1, 3, 6, 10, 11; up to 6 feet, number 2; up to 8 or 10 feet and weight of 1300 pounds, number 9. (6a, 6b, and 10, courtesy Jordan and Evermann: "Fishes of North and Middle America," Washington, The Smithsonian Institution. All others from "Cambridge Natural History," Vol. VII. By permission of The Macmillan Company, publishers.)

In **size**, the teleosts range from the 10 mm. Philippine *Pandaka* to such giants as the halibut, the swordfish, and tuna, which attain lengths of 12 to 15 feet, and the grotesque marine sunfish (**Mola**) which may be 8 or 10 feet long and weigh about 1 ton—in spite of the fact that it appears to be only half of a fish (Fig. 337:9). Otherwise known as the "headfish," its trunk has been foreshortened to such an extent that the animal seems to consist mainly of head.

So far as is known, no teleost has ever attained the size of the larger sharks. The shark is a strong swimmer and, considering its bulk, can make good speed. But the teleost, relative to size, can do very much better. Compared to the shark, a teleost has bone in place of cartilage, a somewhat more highly differentiated muscular system, improvement in the "streamlining" of the external form of the body, the great advantage of the hydrostatic air-bladder, and, over all, a more highly elaborated nervous mechanism. These differences combine to make possible such speed and precision of control as to enable the teleost to arrive at the perfection of aquatic locomotion. A shark at its best is a clumsy swimmer compared to a salmon swimming upward through a waterfall.

The **Chondrostei**, **Polypterini**, and **Holostei** are, in many respects, anatomically intermediate between Elasmobranchii and Teleostei. The relatively abundant fossilized remains of fishes from the late Paleozoic and Mesozoic geologic ages indicate that fishes more or less closely resembling the members of these three now living groups were the most numerous and widely distributed fishes of those times. The name "**Ganoidei**" is sometimes used in a general and not very sharply defined way to indicate all of these fishes, extinct and living, which, both in geologic time and in anatomic characteristics, are intermediate between "cartilaginous fishes" (Elasmobranchii) and "bony fishes" (Teleostei). The words "Ganoidei" and "ganoin" are derived from a Greek word meaning "brightness" and refer to the smooth and shining outer surface of such ganoin-covered scales as those of *Polypterus* and the gar pike. But not all so-called "ganoids" have ganoid scales.

Although anatomically intermediate between sharks and teleosts, the phylogenetic position of the modern "ganoids," especially the Chondrostei with their largely cartilaginous skeletons, is not at all certain. Are they relatively primitive piscine relics which have persisted down through the ages with little or no evolutionary progress, at least in the matter of ossification? Or is it possible that, descended from ancestors with highly ossified skeletons, they have undergone, to varying extent, progressive reduction in degree of ossification? In our



attempts to discover phylogenetic relationships, we are often embarrassed by the fact that evolution progresses sometimes by addition and sometimes by subtraction.

#### SUBCLASS V. DIPNOI

**Lungfishes.** Lungs—single or two, well-developed, and vitally important in addition to gills—are the characteristic to which this group owes its name ("Di-pnoi," very broadly translated, referring to the double breathing mechanism). Aside from lungs, various other characteristics of these fishes require making a special subclass for them. Their more important peculiarities are as follows.

Single **lung-sac** (in *Epiceratodus*), or pair of sacs (in *Protopterus* and *Lepidosiren*), opening into esophagus through an aperture (glottis) in its **ventral** wall. Nasal cavities have openings (**internal nares**) into mouth-cavity.

**Gill-clefts**—five pairs (*Epiceratodus*; *Protopterus*) or four pairs (*Lepidosiren*), opening externally, on each side, beneath an **operculum** supported by thin plates of bone. Spiracles closed in adults.

**Skeleton incompletely ossified.** Cranial part of skull mainly cartilaginous. **Notochord persistent**, vertebrae represented only by neural and hemal arches, partly bony; no centra. Tail-fin **diphycercal**.

**Paired fins** long, narrow, pointed, each having a thick muscular basal "lobe," and supported by a jointed cartilaginous axis bearing (in *Epiceratodus*) on each side of it a series of projecting rays of cartilage (Fig. 338)—a "biserial" fin. Pelvic fins at extreme rear of trunk.

**Scales**, thin, overlapping plates of dermal bone.

Intestine contains a well-developed **spiral valve**. Anus and urogenital ducts open into a common **cloaca**.

**Heart three-chambered**, although the partition between right and left auricles is not complete.

There are only three living genera of Dipnoi: **Epiceratodus** (*Ceratodus* or *Neoceratodus*) of Australia (Fig. 329F); **Protopterus** of Africa; and **Lepidosiren** of South America. These fishes all inhabit rivers in warm climates subject to prolonged dry seasons during which the streams may become reduced to pools of more or less stagnant water, or may completely dry up. The fishes survive the dry season by breathing air through the nasal passages into the lungs. The African and South American dipnoans burrow into the mud, leaving only the tip of the head and the nostrils exposed to the air.

The **Dipnoi** exhibit a motley collection of characteristics. Having lungs, and nasal cavities opening into the mouth, they possess the respiratory equipment typical of land vertebrates. The intestinal spiral valve and the cloaca are elasmobranch features. In degree of ossifica-

tion of the skeleton they resemble Chondrostei. The scales of existing Dipnoi are similar to those of Teleostei. The skeleton of their paired fins is quite unlike that of any known living fish. Also their geographic distribution—a single genus in each of three widely separated land areas—is perplexing. The several questions to which the modern dipnoans give rise are answered to some extent by paleontology. Evi-

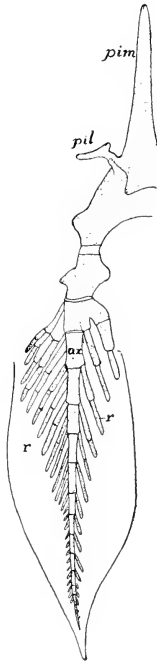


FIG. 338. Pelvic fin and part of girdle of *Epiceralodus*. (*ax*) Axial skeleton of fin; (*pil*) iliac process; (*pim*) processus impar; (*r*) radialia. (After Davidoff. Courtesy, Kingsley: "Comparative Anatomy of Vertebrates." Philadelphia, The Blakiston Company.)

dence from fossils indicates that fishes of the dipnoan type have existed continuously since very early geologic times, being traceable back to nearly the middle (Devonian Period) of the Paleozoic Era. In ancient times these fishes were much more numerous and more widely distributed than now. The fossil skeletons of the older dipnoans have many points of resemblance to those of the crossopterygians contemporary with them. These crossopterygian skulls show evidence of internal nares (choanae) which would imply air-breathing and lungs—although in rare cases, in the absence of lungs, the nasal cavity of a fish may open, in one way or another, into the mouth-cavity, as in the

cyclostome hag (*Myxine*) and the teleost "stargazer" (*Astroscopus*). Also the dipnoan has the "lobe-fin" characteristic of crossopterygians. It seems likely, therefore, that the two groups were closely related at their beginnings, since which the crossopterygians have become nearly (or quite?) extinct and the dipnoans have been reduced to three surviving genera. On the ground that the choanae of crossopterygians imply possession of lungs, the Dipnoi and Crossopterygii may be included together under the name **Choanichthyes**, a division of Osteichthyes.

ELECTRIC ORGANS

Stories have been told of a curious mishap which may be suffered by horseback riders while fording streams in Brazil or other tropical parts of South America. For no obvious reason, the rider may be plunged into the water by sudden panic or even collapse of the animal under him. The cause of the mishap is mere contact with a harmless-looking eel-like fish. But mere contact suffices to allow the fish to

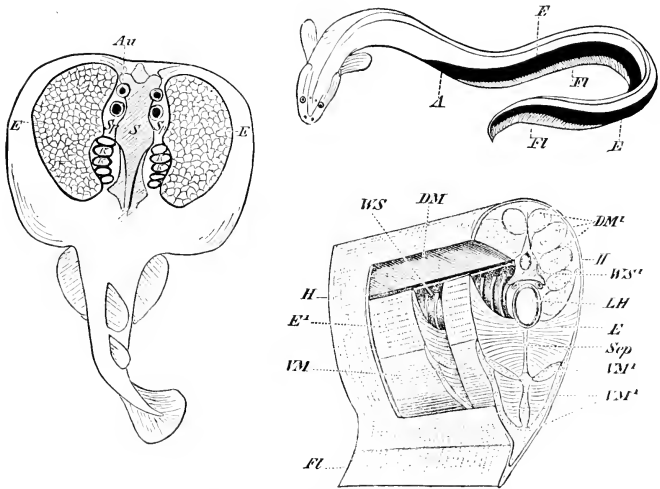


FIG. 339. Electric organs. (Left) Electric ray, *To-pedo*: dorsal view; electric organs exposed by removal of skin and superficial tissue. (Right, above) Electric eel, *Electrophorus (Gymnotus)*: caudal location of electric organs indicated by solid black. (Right, below) Stereogram showing relations of eel's electric organs to caudal muscles and skeleton. (A) Anus; (Au) Eye; (DM, DM<sup>1</sup>) dorsal muscles; (E, E<sup>1</sup>) electric organs; (FL) ventral fin; (H) skin; (K) gill-clefts; (LH) hemal canal; (S) cranium; (Sp) connective-tissue septum; (Sp) spiracle; (VM, VM<sup>1</sup>) ventral muscles; (WS, WS<sup>1</sup>) vertebral column. (Courtesy, Wiedersheim: "Grundriss der vergleichenden Anatomie der Wirbeltiere," Jena, Gustav Fischer.)

discharge its powerful electric batteries. The fish is the "electric eel," **Electrophorus** (or **Gymnotus**), a teleost. The electric organs are bulky paired masses of peculiar tissue occupying most of the ventral region of the very long tail (Fig. 339). The corresponding region in other fishes is occupied by the hypaxial divisions of the caudal myomeres.

Another formidable fish is the **electric ray, Torpedo**, an elasmobranch commonly found in the tropical and temperate waters of the Atlantic and occasionally elsewhere (Fig. 339). It is a large fish, in extreme cases attaining a length of 5 feet and a weight of 200 pounds. The electric organs consist of a pair of large masses of electric tissue, each situated between the gill-chambers and the musculature of the pectoral fin of one side, and filling the entire space between dorsal skin and ventral skin.




FIG. 340. Diagram of electric organ of *Torpedo* (e) Electroplax; (g) gelatinous layer; (n) nerve. (After Bütschli. Courtesy, Kingsley: "Comparative Anatomy of Vertebrates," Philadelphia, The Blakiston Company.)

**Malapterurus**, a fresh-water catfish (Family **Siluridae**) of tropical Africa, is another electrically potent teleost. Its electric tissue is disposed as a subcutaneous layer (i.e., between skin and body-muscle) investing the greater part of the body but thickest in the middle region of the trunk.

In several other groups of fishes, relatively weak electric organs are present. The "stargazer" (**Astroscopus**), an Atlantic teleost having eyes directed upward, possesses a pair of electric organs situated dorsally, each close behind an eye. Members of the teleostean Family **Mormyridae**, African fresh-water fishes, have electric organs in the tail. Among elasmobranchs, some of the common **skates** have weak electric organs in the anterior region of the tail.

The structural unit of an electric organ, wherever situated, is an exceedingly thin plate of protoplasm containing numerous nuclei, but not subdivided by cell-walls. The internal structure of this **electroplax** is too complex to admit of brief description (Fig. 340). Large numbers of these plates, usually placed together flatwise, form rows or columns of electric tissue. An electric organ includes numerous such columns of plates.

Except in *Malapterurus*, the electric organs occupy space corresponding to that which, in nonelectric fishes, is occupied by muscles. Consistent with this fact, it has been found (in such cases as have been investigated) that the electric tissue is produced by mesoderm corresponding to that which, in other fishes, produces striated muscles.

The embryonic cells even develop into short and definitely striated muscle-fibers, each of which then undergoes an elaborate metamorphosis and becomes an electroplax. (The origin of the electric tissue in *Malapterurus* is not certainly known.) Further, the innervation of an electric organ is such as would be received by striated muscles occupying the position of the electric organ. Caudal electric organs and the subcutaneous electric mantle of *Malapterurus* are innervated by somatic efferent spinal nerves. The bulky electric masses of *Torpedo* are in the region of branchiomic muscles and accordingly receive branches from cranial nerves V (?), VII, IX, and X. The motor centers for these **electric nerves** occasion a pair of prominent **electric lobes** on the medulla. The electric organs of *Astroscopus* and their nerves are said to develop in very close relation to the extrinsic muscles of the eye and the corresponding nerves. Each electroplax, in all electric organs, is entered by one or more branches of an electric nerve.

The discharge from the stronger electric organs may paralyze or even kill small animals. Unquestionably such organs are highly efficacious for defense and in securing prey. In this connection it is noteworthy that the skin of *Torpedo* is devoid of scales. The value of such feeble electric organs as those in the tails of some skates is problematic. The control of an electric organ is presumably voluntary, like that of the striated muscle whose place it occupies. Mere contact with the body of the electric fish is not necessarily followed by discharge.

These electric organs of fishes are extraordinary in every particular—the specializing of protoplasm for production and liberation of electric energy; the use of electricity in defensive and offensive operations; the actual transformation, *during ontogeny*, of young striated muscle-fibers into electroplaxes; the independent origins of electric organs in widely separated regions of the body, and in several genera of fishes genetically very far apart.

Transformation of a striated muscle-fiber into an electroplax is to a certain degree intelligible. Contraction of muscle is attended by a very slight electric discharge. In the electroplax the release of electric energy, which is a trivial by-product of muscular activity, has been accentuated and elevated to the rank of the chief function, at the expense of loss of contractility.

The diverse positions and innervations of caudal, branchiomic, postoptic, and subcutaneous electric organs preclude any possibility of homology among them. The genetic distance between elasmobranch rays and teleosts is so great that there can be no homology between the caudal electric organs of various teleosts and those of a ray. Even inside the small group of rays appears *Torpedo* with electric organs in the branchial region, while in other rays the organs are caudal. The

subcutaneous electric mantle of *Malapterurus* is unique. Electric organs, so far as is known, exist in no vertebrates other than fishes, and in only a very few of the vast number of species of fishes. This fact makes it the more remarkable that organs of such peculiar nature should have had so many separate origins. Paleontologists have suggested that some of the ancient **ostracoderms** may have had electric organs in the branchial region. The suggestion is based on evidence of the existence of a group of large cranial nerves in a position corresponding to that of the electric nerves of *Torpedo*.

### III. Class Amphibia

This Class, taken as a whole, is amphibious, but many of its members are not. Some spend their whole lives in the water; others spend it on land. The great majority begin life in the water but, as adults, live more or less after the manner of the common frog, never far from the water's edge, sometimes in and sometimes out. None inhabits salt water. Its unique relations to both land and water give the Class special interest and importance.

The most highly characteristic feature of amphibians is the **larval stage**. In most of them the egg develops into an aquatic fishlike "tadpole" having a long locomotor **tail** supported by a **notochord**. The larva acquires three pairs of gills which, however, are unlike fish gills in that they are tufts of vascular filaments projecting externally from the surfaces between successive gill-clefts, of which four pairs usually perforate to the exterior (Fig. 341). In frogs and toads these **external gills** are later absorbed and replaced by **internal gills** which are more like those of fishes (Figs. 342, 343). Meanwhile, a fold of skin grows back over the external gill-apertures on each side, forming an **operculum** similar to that of fishes. In most genera the right and left folds become joined so that the gill-clefts of both sides open into one common opercular space, and this eventually has exit to the exterior through only one aperture, which is usually on the left side but is sometimes median and ventral. The opercular space is very similar to the peribranchial (atrial) cavity of *Amphioxus* and the tunicates. In larvae of amphibians other than frogs and toads, the opercular folds are rudimentary or absent. In some amphibians the larval period is passed, not in external water, but in some internal cavity of one of the parents—in the oviduct or in a pouch of the skin (Fig. 344) or even in the oral cavity of the male (see p. 239). Under these circumstances, the gills become variously modified. In certain terrestrial frogs the larval stage is entirely omitted and the egg develops directly into a very small frog.

In addition to gills and other piscine features, the larvae of amphibians possess **lateral-line sensory organs** which differ from those of

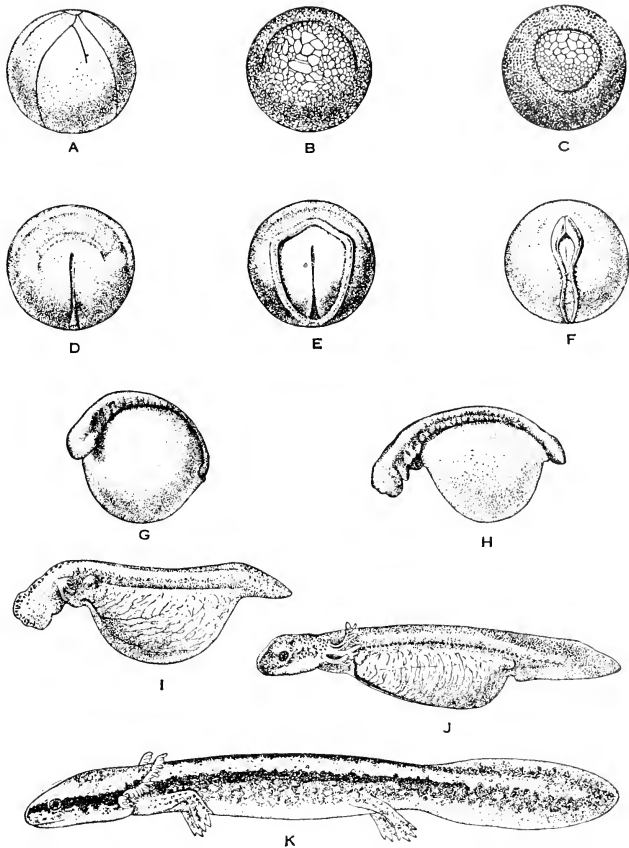


FIG. 341. The development of *Necturus maculosus*. (A) Side view of egg 1 day and 8 hours after deposition, showing second and third cleavage grooves. (B) Bottom view of egg 6 days and 16 hours old. The crescentic blastoporal fold sharply separates the large yolk-cells from the small cells of the blastodisk. (C) Bottom view of egg 10 days and 10 hours old, showing large circular blastopore. (D) Top view of egg 14 days and 4 hours old. Blastopore narrow. Beginning of neural-fold formation, especially prominent anteriorly. (E) Top view of egg 15 days and 15 hours old. Yolk plug still visible. Neural folds prominent. Their posterior ends extend to the blastopore. (F) Top view of egg 18 days and 15 hours old, with three or four pairs of myotomes visible. Right and left neural folds nearly meet (G). Dorsolateral view of embryo 22 days and 17 hours old; length 8 mm.; 16 to 18 myotomes. (H) Side view of embryo 26 days old; length 11 mm.; 26 to 27 myotomes. Eye, ear, nasal pits, and mouth well defined. (I) Side view of embryo 36 days and 16 hours old; length 16 mm.; 36 to 38 myotomes. (J) Side view of larva 49 days old; length 21 mm. (K) Side view of larva 97 days old; length 34 mm. (After Eycleshymer and Wilson. By permission from "Biology of the Amphibia," by G. K. Noble, copyrighted 1931. McGraw-Hill Book Co., Inc.)

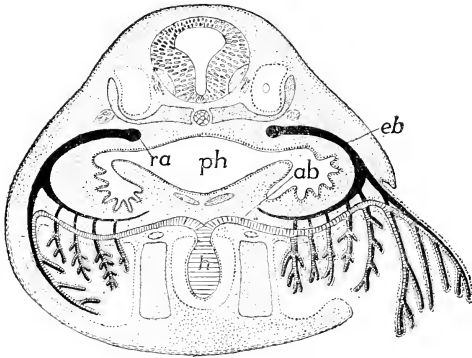


FIG. 342. Diagram of the relations of external and internal gills in the anuran tadpole. (*ab*, *eb*) Afferent and efferent branchial arteries; (*h*) heart; (*o*) ear cavity; (*ph*) pharynx; (*ra*) radix aortae. (After Maurer. Courtesy, Kingsley; "Comparative Anatomy of Vertebrates," Philadelphia, The Blakiston Company.)

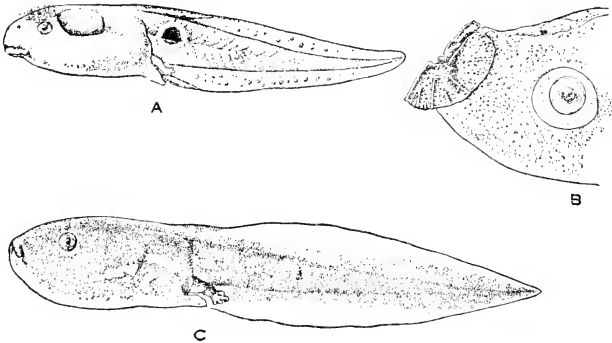


FIG. 343. Tadpoles. (A) *Rana atlicola*. (B) *Microphyla heymonsi*. (C) *Gastrophryne carolinensis*. The shape of the mouth may be correlated either with the type of habitat or with the method of feeding. The umbrella mouth (B) characterizes surface-film feeders. Some species, notably the Brevicipitidae (C), show very little specialization of the mouth in spite of radically different feeding habits. (By permission from "Biology of the Amphibia," by G. K. Noble, copyrighted 1931. McGraw-Hill Book Co., Inc.)



fishes only in some details of structure and arrangement. These organs, at least in part, persist in those tailed amphibians which are wholly aquatic in adult life and also in some aquatic adult frogs and toads. They are organs which can function only in water.

The larval period passes over into a period of **metamorphosis**. In amphibians whose adults are permanently aquatic, the changes are relatively small (Fig. 341), but in frogs and toads the metamorphosis involves absorption of tail and gills, closing of gill-clefts, and various internal changes. Meanwhile, legs develop, the lungs become fully functional, and the bodily proportions are altered to those of the adult.

The immediate stimulus which brings about metamorphosis is provided by the secretion of the thyroid gland. The chemical peculiarity of the secreted substance is its high content of iodine. If thyroid substance, or even pure iodine, is fed or injected into a tadpole, metamorphosis may be accelerated or induced prematurely.

In some amphibians the larval stage may be indefinitely prolonged, the larva becoming sexually mature and reproducing while otherwise in the larval form. The Mexican "axolotl" and the axolotls of the Rocky Mountain region are sexually-mature persistent aquatic larvae of the tailed amphibian (salamander) **Ambystoma tigrinum** which, in other parts of the country, regularly metamorphoses into a gill-less adult. Under appropriate environmental conditions, temperature perhaps being a factor, or if thyroid material is administered, the axolotl may undergo metamorphosis. Reproduction by an animal which is still in a larval form is called **neoteny** or **paedogenesis**.

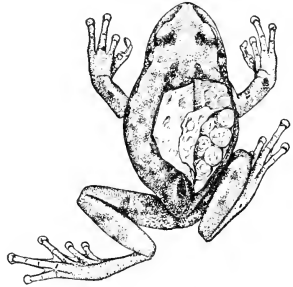


FIG. 341. *Gastrotheca marsupiala*, the purselike brood-pouch cut open on the side to show the eggs within. (By permission from "Biology of the Amphibia," by G. K. Noble, copyrighted 1931. McGraw-Hill Book Co., Inc.)

**Respiration** in adult amphibians may be carried on by means of **gills, lungs, skin**, and the lining of the cavities of the mouth and pharynx (**buco-pharyngeal** surfaces). In some cases the respiratory function may extend back even into the esophagus. Respiration may take place in all four regions at once in an individual amphibian. The relative importance of the several regions differs greatly in various amphibians. In all cases the nasal cavities, as in lungfishes, open into

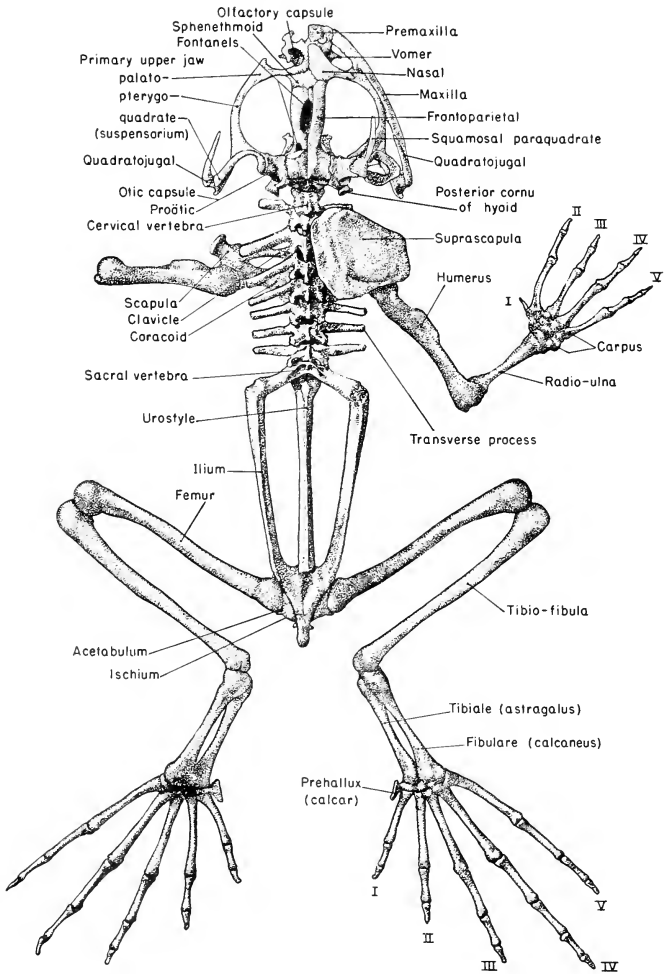


FIG. 315. Skeleton of frog (*Rana calesbiana*): dorsal view except that the feet are extended backward so that they are seen in ventral aspect. In the skull most of the dermal bones of the left side have been removed (the quadratojugal remaining), together with a narrow strip of the right frontoparietal, so as to expose the chondrocranium and the primary cartilaginous upper jaw (palatopterygoquadrate) continuous with the cartilaginous olfactory capsule in front and the auditory (otic)

the mouth. The apertures (**internal nares** or **choanae**) are in the anterior region of the roof of the mouth.

The **skin** is more or less important as a respiratory membrane in all amphibians, whether living in water or on land—probably least so in common toads, whose skin is thicker and less mucous than that of other amphibians. **Buccopharyngeal respiration** probably occurs to varying extents in all amphibians, whether the cavities are occupied by water or by air. Some aquatic salamanders have **gills** and **lungs**, both functional, but the air-capacity and blood-supply of the lungs are so small as to indicate that the gills are functionally more important. Most long-bodied tailed amphibians (Urodela) in the adult stage are without gills and have lungs which are more or less efficient in conjunction with the skin and buccopharyngeal surfaces. It is likely that, when the animal is in the water, the lungs may serve also a hydrostatic function, as do the air-bladders of teleostome fishes.

Still another respiratory complex is found in the **lungless salamanders**. There are many species in whose adults gills and lungs are totally absent. Respiration is entirely cutaneous and buccopharyngeal. These vertebrates have therefore reverted functionally to the respiratory method of such an invertebrate as an earthworm, in which there are no specialized and localized organs for respiration. Some salamanders have lungs which are, in varying degree, small and weakly developed—animals which therefore seem to be intermediate between those that are lungless and those with well-developed lungs. It is probable that absence of lungs is an adaptation to habitat. Most of the lungless salamanders live in regions of swift-running mountain streams. In the absence of lungs, the specific gravity of the body is greater. The animal is therefore less likely to be carried downstream by the current.

The **paired appendages** are never finlike. From the beginning of their differentiation in the larva, they are **pentadactyl** legs—but not always literally “penta-,” for the number of digits is often reduced to four and sometimes to three or even two. The pelvic girdle in modern amphibians has skeletal attachment to a single vertebra, the **sacral vertebra**. In the long-bodied amphibians the legs are short and not strong enough to support the weight of the body, which is therefore dragged rather than carried. In certain much-elongated eel-like amphibians (Fig. 349) the legs are so small and weak as to seem to be of

---

FIG. 345.—(Continued)

capsule behind. The proötic bone is the only ossification in the otic capsule and, in the adult frog, is fused with the adjacent exoccipital ossification. On the right side the suspensorium is omitted so as to expose to view the annulus tympanicus which supports the tympanic membrane of the “middle ear.”

little or no use to the animal. In one of these "eels" (*Siren*), hindlegs are entirely absent. At the other extreme are the frogs and toads, whose legs are strongly developed and modified for vigorous leaping locomotion (Fig. 345). A **median tail-fin** is present in larvae and in gill-breathing adults, but it differs from the tail-fin of fishes in having no skeletal fin-rays.

The **skeleton** is mainly bony, although more or less of the embryonic cartilage persists in the skeleton of the head (Figs. 345, 346) and in the appendages. In tailed amphibians remnants of the larval **notochord** may persist in the vertebral column. The skull is much simpler and contains fewer bones than that of a bony fish. In modern amphibians ribs are always poorly developed—short, mere rudiments, or entirely lacking.

The **skin** is of the aquatic type—thin and richly mucous (Fig. 347)—even in those that live on land, although in toads it is thicker and less mucous. In modern amphibians there are usually no scales of any sort. In certain frogs, especially some having a burrowing habit, there are bony plates in the skin of the back, and in some of the externally snakelike caecilians there are very small bony scales buried in the skin and invisible externally. In early amphibians, the **Stegocephalia**, the animal was more or less completely covered by an armor of heavy bony plates, sometimes especially large and heavy over the head.

The amphibian **heart**, like that of lungfishes, has two auricles and one ventricle, the right auricle receiving blood from the general circulation, the left receiving from the lungs. In frogs and toads the partition between right and left auricles is complete, but in other amphibians it is more or less incomplete.

**No intestinal spiral valve** is found in any modern amphibian. In all of them the anus and urinogenital ducts open into a **cloaca**.

Between the **nervous organs** of amphibians and those of fishes there are no very striking anatomic differences other than the relatively small size of the cerebellum (Fig. 348). The amphibian **brain**, however, has one feature which, although not conspicuous, is functionally very significant. In most fishes the dorsal wall (pallium) of the most anterior (telencephalon) of the five regions of the brain contains no nervous tissue. This is in utmost contrast to the fact that in mammals, including man, the **pallium**, forming the thick roof of the cerebral hemispheres, becomes elaborated into a vast complex of nervous elements whose cell-bodies (i.e., "bodies" in distinction from the nerve-fibers which are outgrowths from them) are massed into a sharply delimited superficial layer of "gray substance," the **cerebral cortex**. This cortex con-

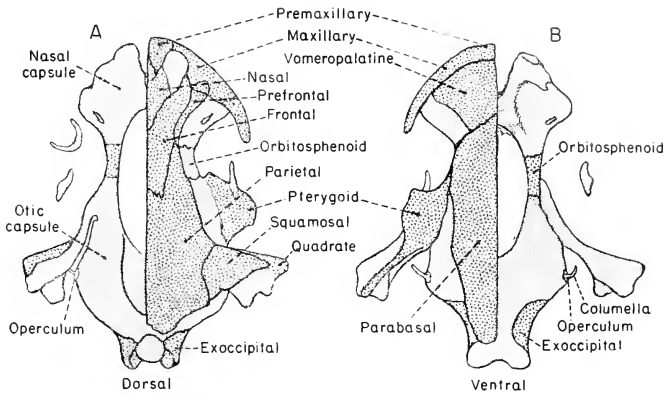


FIG. 316. Two views of the skull of *Cryptobranchus alleganiensis*, an aquatic salamander. Dermal bones are stippled heavily. Cartilage bones are stippled lightly, except for portions of the orbitosphenoid and quadrate and the exoccipital. The isolated semilunar bone (upper left) is the eye capsule. Other cartilaginous parts are columella, operculum (stapes), nasal capsule, and otic capsule. In both figures the dermal bones have been retained on the right side of the skull and removed on the left. (After Wilder: "History of the Human Body," New York, Henry Holt & Co., Inc.)

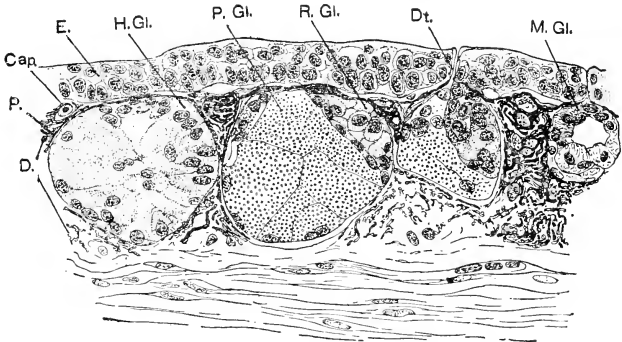


FIG. 317. Section perpendicular to the surface of the skin: from the dorsal surface of the tail-base of *Plethodon cinereus*, showing three types of integumentary glands. (Cap.) Capillary; (D.) dermis; (Dt.) duct of exhausted granular or poison gland; (E.) epidermis; (H.Gl.) hedonic gland (cut to one side of main axis); (M.Gl.) mucous gland; (P.) melanophore; (P.Gl.) poison gland; (R.Gl.) developing poison gland. (By permission from "Biology of the Amphibia," by G. K. Noble, copyrighted 1931. McGraw-Hill Book Co., Inc.)

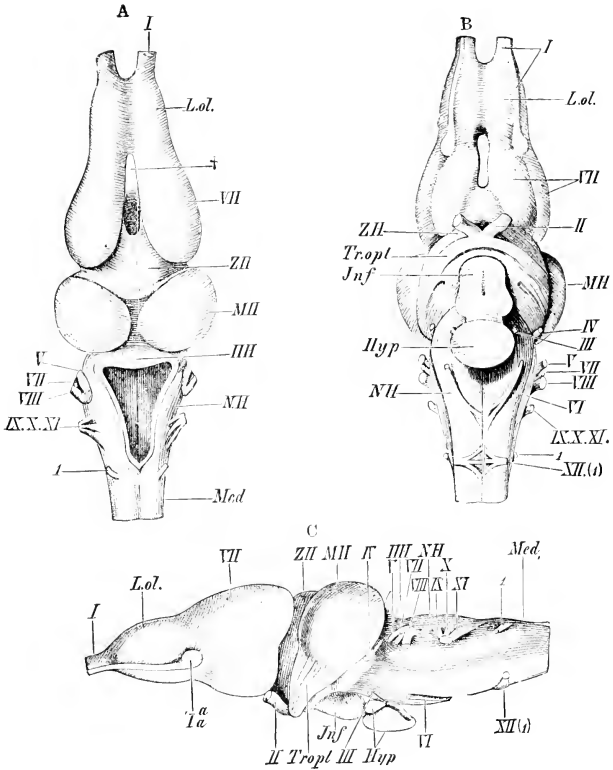


FIG. 318. Brain of *Rana esculenta*. (A) Dorsal, (B) ventral, and (C) lateral view. (III) Cerebellum; (Hyp) hypophysis; (Jnf) infundibulum; (L.ol.) olfactory lobe; (Med) spinal cord; (MII) midbrain; (NH) medulla oblongata; (Tropt.) optic tract; (VII) cerebral hemispheres; (ZII) thalamencephalon; (I-X) cranial nerves; (XI) accessory, not detached from vagus; (Ia') lateral root of olfactory nerve; (XII(d)) ventral root of first spinal nerve (hypoglossal?), and (I) its dorsal root; (†) space between the two hemispheres. (From Wiedersheim: "Comparative Anatomy of Vertebrates." By permission of The Macmillan Company, publishers.)

tains the nervous mechanisms which dominate the activities of the animal. In sharks and to a small and varying extent in some "ganoids," the pallium, although thin, contains nervous tissue. But in that largest and most specialized group of fishes, the Teleostei, the pallium is extremely thin and contains no nervous elements (Fig. 324). In modern lungfishes (Dipnoi) cerebral hemispheres are definitely formed, although not strongly developed, and the thin pallium consists mainly of nervous tissue. In the amphibian brain the cerebral hemispheres are somewhat better developed than in Dipnoi, and the "gray substance," although mostly situated in the deeper layer of the pallium (Fig. 371), shows a slight tendency to extend toward its outer surface—an incipient cortex. In existing amphibians there are 10 pairs of **cranial nerves**, as in fishes. There is evidence that some ancient amphibians had 12 pairs.

As for **sense-organs**, the possession of **lateral-line organs** by aquatic amphibians has been mentioned (p. 442). Organs of taste ("taste-buds"), however, do not occur in the skin of the body as they do in fishes. Although found on the skin of the head in a few amphibians, they are ordinarily restricted to the mouth-cavity. While the amphibian probably cannot "taste" food through the external skin, there are present in the skin certain types of nerve-endings which are stimulated by various chemical agencies such, for example, as weak acids.

The **eyes** are moderately well developed, except in cave-dwellers and burrowers. In fishes eyelids are rarely present and even more rarely movable. Some sharks have them. Amphibian eyes, when well developed, are usually equipped with **upper** and **lower lids**, the lower being more freely movable; and there may be a third lid, the very thin **nictitating membrane**, between the other two and the eyeball, best developed in frogs and toads.

The **ear**, doubtless always important as an organ of equilibration, acquires in frogs and toads an important accessory apparatus which increases its auditory capacity (see p. 456). In other amphibians this mechanism is lacking or represented by rudiments suggesting its degeneration.

#### CLASSIFICATION

This Class, next to Cyclostomata, is the smallest of the vertebrate classes. **G. K. Noble** ("The Biology of the Amphibia" 1931) counts "some 1900 species and 234 living genera" of frogs, toads, and salamanders. To these must be added (according to F. Nieden) 19 genera and 55 species of the snakelike caecilians. The Class breaks into three groups (Orders) which are widely separated and easily defined.

*Order Urodela (Caudata)*

“**Tailed Amphibians.**” Body elongated. Adult retains larval tail. Fore- and hindlegs of nearly equal size. Larval gills and gill-clefts may or may not be retained by adult. Living mainly in the northern hemisphere; most abundant in the more temperate parts of it.

The following two divisions, based on gill-structures, are convenient, but probably have little phylogenetic significance.

**PERENNIBRANCHIATA:** Three pairs of external gills in adult. Wholly aquatic.

**Necturus:** Two pairs of gill-clefts in adult. Length, 12 to 15 inches. Common “mud puppy” of eastern United States and Canada (Fig. 349C).

**Proteus:** Two pairs of gill-clefts in adult. Three digits on foreleg, two on hindleg. Skin almost devoid of pigment. The blind cave-dwelling “olm” of southern Europe.

**Siren (Iacertina):** Three pairs of gill-clefts in adult. Eel-like in form (Fig. 349D). Length, 2 feet or more. Forelegs weakly developed; no hindlegs. “Mud eel” of southeastern United States.

**CADUCIBRANCHIATA:** Adult without gills.

**Cryptobranchus (alleganiensis,** the only species): Adult has only one pair of gill-clefts. Wholly aquatic. The “hell-bender” of eastern United States (Fig. 349E). Length, 18 inches or more. Conspicuous fold or “frill” of skin extending lengthwise of the body on each side, probably serving to increase respiratory surface.

**Megalobatrachus (japonicus,** the only species): Very similar to *Cryptobranchus*; wholly aquatic, but with no gill-clefts in adult and very much larger. Length, up to 5 feet or more. “Giant salamander” of China and Japan; the largest living amphibian.

**Amphiuma:** One pair of gill-clefts in adult. Wholly aquatic. Eel-like in form; length, up to 3 feet. Both pairs of legs much reduced. “Congo eel” of southeastern United States (Fig. 349B).

In all caduceibranchs except *Cryptobranchus* and *Amphiuma*, the larval gill-clefts are entirely closed in the adult. The following genera include some of the better-known salamanders and newts (Fig. 350).

**Ambystoma,** common North American salamander; **Salamandra,** European salamanders, mostly terrestrial; **Triturus,** common American newt; **Plethodon, Desmognathus,** and other genera of the Family **Plethodontidae** include the majority of American urodeles—some brook-dwellers, some terrestrial, all lungless; **Hynobius,** Asiatic land salamander; **Ranodon,** Asiatic brook-dweller with reduced lungs; **Onychodactylus,** Asiatic genus including two lungless species.



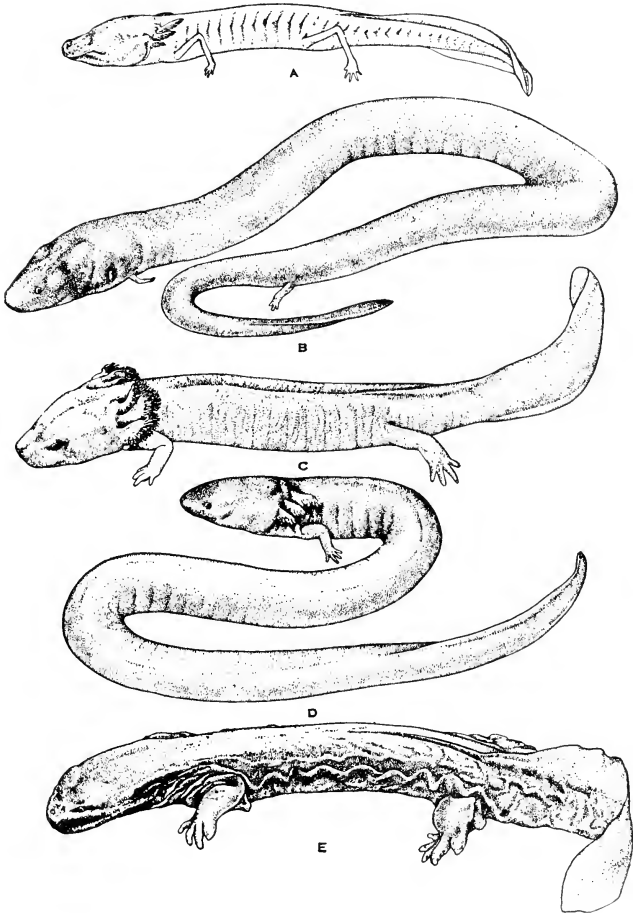


FIG. 349. The perennibranch and derotreme salamanders. (A) *Typhlomolge rathbuni*. (B) *Amphiuma means*. (C) *Necturus maculosus*. (D) *Siren lacertina*. (E) *Cryptobranchus alleganiensis*. (By permission from "Biology of the Amphibia," by G. K. Noble, copyrighted 1931. McGraw-Hill Book Co., Inc.)

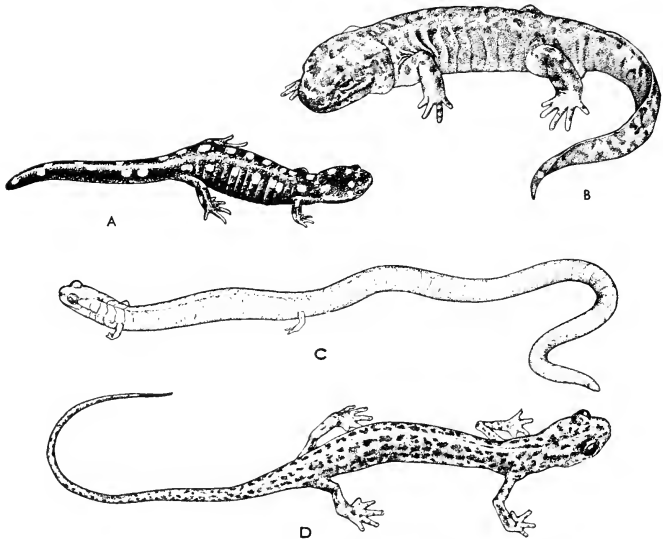


FIG. 350. (A) *Ambystoma maculatum*. (B) *Dicamptodon ensatus*. (C) *Batrachoseps attenuatus*. (D) *Eurycea lucifuga*. (By permission from "Biology of the Amphibia," by G. K. Noble, copyrighted 1931. McGraw-Hill Book Co., Inc.)

There is no sharp distinction between **salamanders** and **newts**. In general, the smaller salamandroid urodeles are called "newts" or "efts." With the exceptions mentioned above, the larger salamanders ordinarily do not exceed a foot in length. Most salamanders and newts are amphibious. Some are wholly terrestrial.

#### Order Anura\* (*Salientia*)

**Frogs and Toads.** Body short and broad. Larval tail not retained by adult. No gills or gill-clefts in adult.

In the more or less elongated amphibians of the other two orders, the **number of vertebrae** may go as high as 200 or even 250. In contrast, the Anura ordinarily have only nine, sometimes fewer, within the region of the trunk. The first of these articulates with the skull. The ninth is strongly joined to the pelvic girdle supporting the hind-

\* "Salientia" is the more logical name for this order of leaping amphibians. Adult members of the third order, Apoda, have no tail and are therefore literally "anuran" like frogs and toads. "Anura" as the name for the second order is justified only by common usage.

legs. Behind the ninth, or **sacral, vertebra** is a long, straight, unsegmented rod of bone, the **urostyle**, whose mode of development

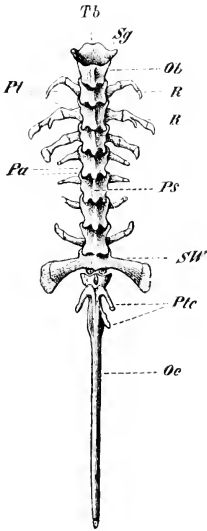


FIG. 351. Vertebral column of frog; dorsal view. (*Ob*) Neural arch of first vertebra; (*Oc*) urostyle; (*Pa*) articulating processes; (*Ps*) neural spine of trunk vertebra; (*Pl*) transverse process; (*Plc*) transverse processes of caudal vertebrae which are fused into the urostyle; (*R*) ribs; (*Sg*) right facet articulating with right occipital condyle of skull; (*SW*) sacral vertebra; (*Tb*) first (cervical) vertebra. (Courtesy, Wiedersheim: "Grundriss der vergleichenden Anatomie der Wirbeltiere," Jena, Gustav Fischer.)

indicates that it is constituted of several (perhaps in some cases as many as 12) vertebrae fused together (Fig. 351). In vertebrates in general, it is customary to designate as "caudal" all vertebrae that lie behind the sacrum. In this sense the urostyle ("uro-" meaning "tail") is a caudal structure, but in a strict sense it is not caudal and the adult anuran has no tail. The vertebrae in Anura are more solidly ossified than in most other amphibians and the adults ordinarily do not retain vestiges of the embryonic notochord, whereas in many adult urodeles remnants of the notochord may, to varying extents, persist. Further, in contrast to "lower" (less specialized) urodeles whose vertebral centra are commonly biconcave (amphicoelous) like those of fishes, the centra of Anura are usu-

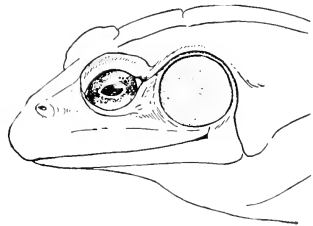


FIG. 352. Head of bullfrog, *Rana catesbeiana*, showing tympanic membrane just behind eye. (By permission from "Biology of the Amphibia," by G. K. Noble, copyrighted 1931. McGraw-Hill Book Co., Inc.)

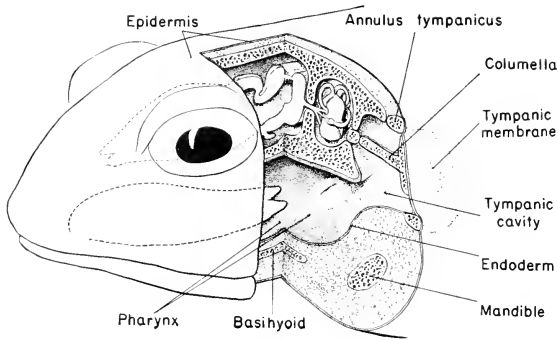


FIG. 353. Auditory apparatus of an anuran. The stereogram exposes a narrow vertical band of the animal's sagittal plane and the left half of a transverse section which has been swung several degrees backward on its sagittal axis to bring it into a favorable angle for the observer. Both sections cut through the pharynx. The transverse section bisects the tympanic membrane and shows the left auditory nerve (VIII) passing from the medulla oblongata to the internal ear (membranous labyrinth). The sagittal view shows the forked anterior tip of the retracted tongue pointing backward into the pharynx.

ally **procoelous** (concave only on the anterior face) or **opisthocoelous** (concave only on the posterior face) or may have some modification of these forms.

The **legs** are strongly developed—forelegs short; hindlegs much elongated and adapted to leaping locomotion, having, instead of the usual three segments (thigh, shank, and foot), a fourth interposed by great elongation of two bones of the ankle (Fig. 345).

The **ear** in Anura possesses an accessory mechanism not found in other modern amphibians or in fishes. In the posterior region of the head there is, on each side, a cavity which internally opens into the pharynx and externally is separated from outside space only by a thin, taut **tympanic membrane** which, as viewed from outside, appears as a nearly circular flat area of skin just behind the eye (Figs. 352, 353). A slender rod of bone, the **columella**, extends across this cavity (**tympanic cavity**), its outer end being attached to the inner surface of the tympanic membrane and its deeper end attached to a very small bone (**stapes**) which is inserted into that part of the wall of the cranium within which the "internal" or sensory ear is lodged. Vibrations of the external medium impinge upon the tympanic membrane and are transmitted by the columella to the internal ear. In fishes the ear is probably more important as an organ of equilibrium than as an

organ of hearing. The tympanic mechanism serves to increase the efficiency of the ear as an organ of hearing. In this connection, it is significant that most anurans are capable of producing sounds. In some anurans, especially those of burrowing habit, the tympanic apparatus is rudimentary or entirely absent.

The Anura are much more specialized than the Urodela. The members of the two orders pass through very similar embryonic and larval stages, but the metamorphosis of frogs and toads involves profound anatomic changes while, aside from loss of gills and gill-clefts, the metamorphic changes in urodeles are relatively inconspicuous. Further, the Order Anura is anatomically more homogeneous than Urodela—that is, the anatomic differences among the frogs and toads are not so great as those among the urodeles. It is easy to distinguish the common toad from certain equally common frogs (Fig. 354), but, taking the group as a whole, the two types so blend into one another that it is impossible to draw a sharp line between frogs and toads.

The Anura are much more widely distributed than the Urodela. They are found in all parts of the world except where it is very cold or very dry or where, as on small oceanic islands, there is lack of fresh-water streams and ponds. Their modes of living are most diverse. Most of them are amphibious. Some are wholly aquatic, others wholly terrestrial. In a few of the latter the eggs, especially large, are laid on land and develop directly into the adult, omitting the larval stage. The terrestrial anurans may live on the surface, or burrow, or spend most of the time in trees. In Java and Borneo there are "flying frogs." By extending all four legs and spreading apart the long digits so that the intervening webs of skin are stretched to the limit, the frog becomes a "glider plane" capable of making a sailing "flight" of perhaps 20 or 30 feet from one tree to another or to the ground. In one of the largest



FIG. 354. (Left) Frog, *Rana sphenocephala*. (Right) Toad, *Scaphiopus holbrookii*. (Courtesy, Dickerson: "The Frog Book," New York, Doubleday & Co.)

anurans, the "Goliath frog," the total length of head and trunk is about 12 inches.

The Anura are divided into several (Noble makes 11) families whose many species make up the great majority, perhaps nine tenths, of the species of amphibians. The common toad, **Bufo americanus**, is of the **Family Bufonidae**. The **Family Ranidae** includes many of the more common frogs of the northern hemisphere—**Rana clamitans**, the green frog; **R. pipiens**, the leopard frog; **R. catesbiana**, the aquatic bullfrog. The **Family Hylidae** includes tree frogs (or tree toads), noted for their ability to change color—e.g., **Hyla versicolor**.

#### *Order Apoda (Gymnophiona)*

This smallest of amphibian orders includes animals which might easily, at first glance, be mistaken for small snakes or for earthworms



FIG. 355. *Siphonops*, one of the Apoda. (Courtesy, Brehm: "Tierleben," Leipzig, Bibliographisches Institut.)

10 or 12 inches long (Fig. 355). Their amphibian nature is revealed by the fact that most of them pass through the typical **larval stage** of amphibians. A **metamorphosis** takes place, during which the three pairs of external gills are absorbed, the clefts are closed, and the tail is nearly or quite absorbed so that the cloacal aperture of the adult is at or very near the hind end of the long cylindric body. No trace of legs appears in either adult or larva. In some members of the Order the larval stage is omitted. It is a noteworthy fact that the embryonic pharyngeal pouches of the most anterior pair, corresponding to those which become the **spiracles** of sharks, are temporarily open to the exterior in the larva. So far as known, this does not occur in other

amphibians. No accessory auditory structures (tympanic cavity and membrane) are developed.

The **lungs** are well developed except that the left lung is usually very much smaller than the right. This is apparently an adaptation to the extreme narrowness of the body, because in reptilian snakes there is a similar reduction of the left lung.

The **skeleton** is fairly well ossified; the vertebrae, of which there may be 250 or more, are amphicoelous. The **skin** is typically amphibian in being thin and highly mucous, but in many genera it contains numerous very small **bony scales** buried in its dermis. It is marked by external transverse grooves encircling the body—increasing the animal's resemblance to an earthworm.

Most of the Apoda are burrowing animals. One genus is aquatic. In the burrowing species the eyes are very small, poorly developed, and more or less deeply covered by skin or even lying beneath bones of the skull. Presumably in compensation for poor sight or blindness, most of these animals have a pair of sensory "**facial tentacles.**" Each "tentacle" is a minute papilla projecting from the bottom of a pit situated between the eye and the nostril of one side. The papilla may, on occasion, be distended (apparently by increase of blood-pressure within it) and protruded from the mouth of the pit. A minute muscle retracts the tentacle into the pit. The rich supply of nerves to the organ indicates its sensory function. Its sensory nature is not definitely known, but it is probably an organ of touch. Its like is not known in other vertebrates.

The Apoda, otherwise known as "**caecilians**" or "**blindworms,**" are widely distributed in the tropic regions of both Eastern and Western Hemispheres, although not found in Madagascar. The best-known genus is **Ichthyophis**, meaning "fish-snake," from southern Asia.

#### EARLY AMPHIBIANS

The Class Amphibia is very ancient. Fossil skeletal material identified as amphibian has been found in strata of the late Devonian Period in Greenland (see Table 3, p. 411). The relative abundance of amphibian fossil material in rocks of the Carboniferous Period indicates that the group was in its prime at that time.

The early amphibians were long-bodied animals with short legs and a long tail. They differed from the modern in various ways. They resembled fishes in that the girdle of the pectoral appendages was attached to the rear of the skull, while there was no skeletal connection between the pelvic girdle and the vertebral column. In modern amphibians the pectoral girdle has no skeletal connection with the skull, and the pelvic girdle is firmly joined to a single sacral vertebra. The early

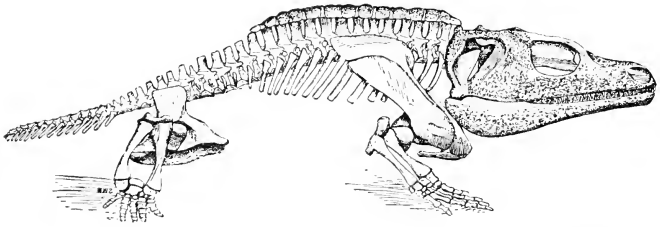


FIG. 356. *Cacops*, a small labyrinthodont amphibian from the Lower Permian. Original about 16 inches long. (After Williston. Courtesy, Romer: "Vertebrate Paleontology," Chicago, University of Chicago Press.)

amphibians were more or less extensively covered by dermal bony scales, especially on the ventral surface of the body. The teeth had a peculiarly complex internal structure (Fig. 41), because of which the group is named **Labyrinthodontia**. Because of the cephalic covering by extensive plates of dermal bone (enlarged scales), it is also called **Stegoccephalia** (Fig. 356). In size, many of the old amphibians greatly exceeded even our modern 5-foot salamander of eastern Asia, some being probably as much as 15 feet long. Others, however, were of the size of modern salamanders and newts.

In the course of the later history of the Class, the pectoral girdle lost connection with the skull and the pelvic girdle acquired connection with a sacral vertebra, thereby increasing the efficiency of the hind-legs in pushing the body forward. The scaly armor of the body was all but lost, the labyrinthine pattern of the teeth vanished, the average size of the animals was much reduced, and the group differentiated into the types represented by the three existing orders. This later history is known in only a very fragmentary way because of scarcity of fossil evidence. No fossil caecilians (Apoda) have ever been found.

The early amphibians were contemporary with crossopterygian ("lobe-fin") fishes whose beginnings were considerably before (early Devonian) those of amphibians. In structure of skull and in other skeletal features, and especially in the possession of an armor of calcareous scales, there is much resemblance between the early amphibians and the fishes. The skulls of the fishes give evidence of connection between nasal cavities and mouth (**internal nares**), which implies possession of lungs. All of the facts indicate that the fishes and amphibians lived in similar fresh-water environments where, as in the case of our modern lungfishes (Dipnoi), there was a seasonal necessity for breathing by lungs instead of by gills. While there are obvious similarities between urodele amphibians and modern lungfishes, the early amphibians were more similar to the crossopterygians than to the early



Dipnoi. Taken all together, the facts point to origin of amphibians from crossopterygian fishes.

It would seem that the modern **perennibranch urodeles**, with their wholly aquatic mode of living, their permanent gills, poorly developed lungs, long tail, feeble legs, and incompletely ossified skeleton, might reasonably be regarded as more "primitive" than amphibians whose larvae undergo radical metamorphosis to become terrestrial adults. If amphibians were derived from fishes, it is necessary to assume that they acquired lungs and at least the beginnings of legs while living in the water, because they could not have lived on land with gills and ordinary fins. It is easy to imagine that our present perennibranchs have come directly down from such pre-amphibious "amphibians" along a line of descent in which, for unknown reasons, no further progress toward terrestrial living was ever made. It would add much to the scientific interest and importance of the perennibranchs if we could feel confident that they are living and unchanged relics of Devonian pre-amphibians. However, evidence from paleontology, admittedly scanty, throws doubt on this view. It reveals, in the long history of amphibians, a tendency to simplify structure by loss of parts. The modern amphibian skull contains fewer bones and more cartilage than the skull of old amphibians. The skeleton, in general, shows this tendency, which may have extended to other organs, and it may have so involved the metamorphic changes in some ancient amphibians which had become terrestrial as adults that they ceased to complete their metamorphosis and so reverted to aquatic adult life. It is a question, therefore, whether such animals as **Necturus** come of a line of descent along which, beyond the early acquisition of lungs and legs, no further progress toward terrestrial life was ever made, or whether, at some period in their ancestral line, terrestrial living had been achieved, only to be abandoned later. Is *Necturus* merely a backward child of its race, or is it a backsliding degenerate? If the latter, it is possible that the degenerative process may have brought the animal down to a condition resembling, at least in a general way if not in all particulars, a stage in the early history of its race. However it may be, as we, from our human viewpoint, contrast the crawling, generally sluggish and retreating "mud puppy" with the sturdy, upsitting, dignified toad in our garden, skillfully catching his daily ration of insects by lightning strokes of an incredibly mobile tongue, we cannot help feeling that the mode of existence of the toad savors rather more of "the higher life."



Fishes live in water. The Class Amphibia straddles the line between water and land. Reptiles are land animals. Some of them manage to live in the water but, even so, they possess the basic anatomic peculiarities of land animals. Adaptation of the animal to the external medium in which it lives is most immediately necessary for the **skin**, the **respiratory mechanism**, and the **locomotor appendages**.

The necessity for adaptation to the environment is not more urgent in any part of the animal than in the skin. The amphibian skin, thin, soft, and coated with a moist mucus, would be wholly impracticable on a big heavy animal living in a dry atmosphere and constantly subject to impact of the body against such solid objects as rough ground, rocks, or bark of trees. The retention of the aquatic type of skin by land amphibians has very narrowly restricted their range of possible life on land. In modern reptiles, the skin is adapted to a land-and-air environment.

**The skins of amphibians and reptiles** have the same general structure. In both there is a cellular epidermis and beneath that a dermis composed mainly of fibrous tissue. In the amphibian the outermost very thin layer of the epidermis is composed of a hard, tough substance like that which constitutes claws, fingernails, and horns in mammals. This horny layer (**stratum corneum**) is usually only one or two cells in thickness (Fig. 11D). When shed by the animal, as frequently happens, it appears as a gauzy, transparent film, like an unusually thin sheet of cellophane. The reptilian epidermis also produces an external horny layer, but it is indefinitely thicker than that of the amphibian and is constituted of several or many layers of epidermal cells (Fig. 357). Its thickness varies with the size of the reptile. This reptilian stratum corneum is hard, very tough, and moderately elastic. It is an ideal protective covering for a land animal. It is mechanically resistant and impervious to water. It is usually differenti-

ated into **scales**, each of which is merely a local thickening of the stratum corneum, joined to one another by intervening thin bands of the horny layer (Fig. 357). This arrangement greatly increases the flexibility of the protective covering. In some reptiles the horny scale is reinforced by an underlying bony plate produced in the dermis. Horny scales appear locally in birds and in some mammals, but it is only in reptiles that they have become so highly elaborated as to be one of the most distinctive characteristics of the Class.

In contrast to the highly glandular skin of amphibians, reptilian skin is totally devoid of **glands** except that in some cases there are localized and highly specialized glands, such as the pair of scent ("musk") glands situated on the under side of the head in alligators and some turtles (the "stinkpot" or "skunk turtle"), and similar glands in the cloacal region of crocodilians and some snakes. In all modern reptiles the general surface of the skin is hard and dry—the surest external means of distinguishing a lizard from a newt, which resemble one another except in the soft, moist skin of the latter.

Comparing amphibian and reptilian skins, it is evident that nothing new is to be found in the latter. Each has its stratum corneum, in amphibians exceedingly thin, in reptiles tremendously thicker and locally formed into scales. Mucous glands in the one are absent from the other.

**Respiratory interchange of gases** can take place through the delicate film of horny material on an amphibian skin, but it is quite

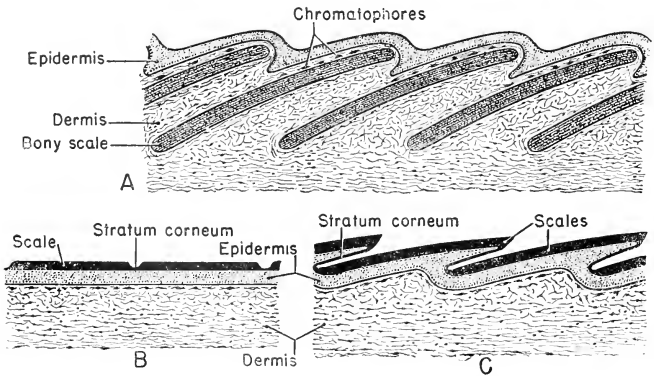


FIG. 357. Bony scales and horny scales. Diagrammatic sections perpendicular to surface of skin. (A) Dermal bony scales of a fish. (B, C) Epidermal horny scales of reptiles: (B) flat; (C) overlapping.

impossible through such a horny layer as that of reptiles. Modern reptiles do not at any time of life breathe by gills. On the walls of the temporary embryonic pharyngeal clefts have been observed minute papillae which can be interpreted as vestiges of gill-filaments, but nothing approaching functional gills appears in any reptilian embryo. In the adult reptile, therefore, respiration must be entirely pulmonary, unless in some cases (probably so in sea turtles) the buccopharyngeal surfaces are auxiliary to the lungs. Consistent with their prime importance, the lungs are much more highly developed than in amphibians. They have greater capacity, relative to the size of the animal, and their respiratory surface is greatly increased by development of partitions which divide the internal space into numerous communicating chambers (Fig. 358).

With concentration of the respiratory function in the lungs, it becomes increasingly important that the **heart** should be so arranged that the oxygenated blood received from the lungs will be distributed into the general circulation, while the venous ("impure") blood re-

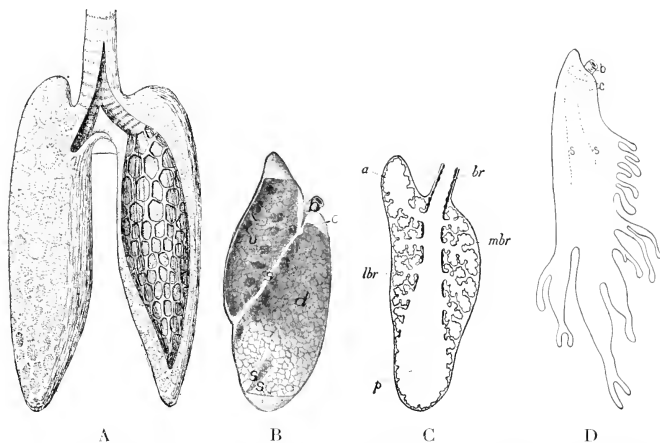


FIG. 358 (A) Lungs of *Sphenodon* (after Gegenbaur); the left lung opened to show the alveoli. (B) Left lung of *Iguana*. (b) Bronchus; (c) internal opening of bronchus; (d, v) dorsal and ventral chambers; (s) septum. (C) Diagram of longitudinal section through lung of lacertilian. (a, p) Anterior and posterior saccular extensions of bronchus; (br) lateral external bronchus; (lbr) lateral secondary bronchus leading to air-cells; (mbr) main internal bronchus. (D) Lung of *Chamaeleon* (Wiedersheim). (b) Bronchus, dividing into three bronchi (c) which open into the three chambers formed by the incomplete septums (s). (A, B, D, courtesy, Kingsley; "Comparative Anatomy of Vertebrates," Philadelphia, The Blakiston Company. C, from Goodrich; "Studies on the Structure and Development of Vertebrates." By permission of The Macmillan Company, publishers.)

turned to the heart should go to the lungs. In dipnoan fishes and amphibians the two kinds of blood are kept separate in the longitudinally divided auricular part of the heart but mingle in the undivided ventricle. In the reptilian heart, as in the others, the systemic venous blood is received by a right auricle and the blood from the lungs by a left auricle, but the ventricle also is divided into right and

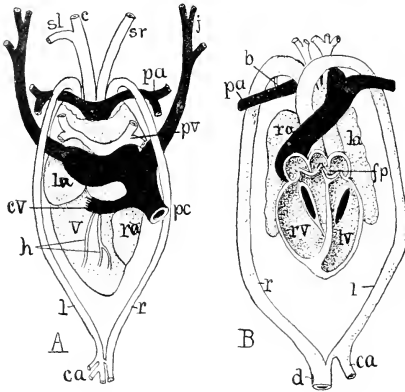


FIG. 359. (A) Dorsal view of heart of crocodile (after Röse). (B) Ventral scheme of heart laid open (after Greil). (*b*) Remnants of Botallo's duct; (*c*) carotid trunk; (*ca*) celiac artery; (*cv*) cardinal vein; (*d*) dorsal aorta; (*fp*) foramen Panizzae; (*h*) coronary arteries; (*j*) jugular vein; (*l*) left aortic arch; (*la*) left auricle; (*lv*) left ventricle; (*pa*) pulmonary artery; (*pc*) postcava; (*pv*) pulmonary vein; (*r*) right aortic (fourth) arch; (*ra*) right auricle; (*rv*) right ventricle; (*sl*, *sr*) left and right subclavian arteries; (*v*) ventricle. (Courtesy, Kingsley: "Comparative Anatomy of Vertebrates," Philadelphia, The Blakiston Company.)

left chambers (Fig. 359). The partition, however, is not complete except in alligators and crocodiles. Because of its deficiency and certain peculiarities in the arrangement of the main arteries that carry blood from the heart, a certain amount of systemic blood, instead of going to the lungs, passes into the general circulation (Fig. 73). In alligators and crocodiles, too, the arterial outlets of the heart are so placed that, in spite of the complete division of the ventricle into right and left chambers, some blood from the right auricle passes into the dorsal aorta.

The **general contour of the reptilian body** is less streamlined than that of typical aquatic anamniotes. A cervical region, at most only faintly suggested in anamniotes, is distinctly differentiated in reptiles, and in some, notably turtles, becomes much elongated. Gill-chambers, with the intervening gill-arches and internal gills, require much space. The absence of gills in the reptile permits of considerable narrowing of the region just behind the head and, further, important functional advantage is gained by the narrowing and elongating of the neck region. A fish, to change the direction of the line of vision, must rotate the whole body. It is of obvious advantage that the mobile neck of the land animal enables it to "look around" without changing its position and to look backward while running forward. Most modern reptiles have relatively long tails. The very long tail of the chameleon is prehensile and may be coiled around a twig to assist the lizard in holding on to its perch in a tree. In some lizards, and in turtles and tortoises, the tails are short.

The **paired appendages** are somewhat more strongly developed than in amphibians, although in living reptiles they are short and in many cases incapable of lifting the body off the ground. Among extinct reptiles, however, were some dinosaurs whose long and strongly built legs indicate capacity for swift running. In the "ostrich dinosaurs" the short forelegs and the long, powerful hindlegs suggest a habit of bipedal locomotion (Fig. 360). In some reptiles legs are rudimentary or totally

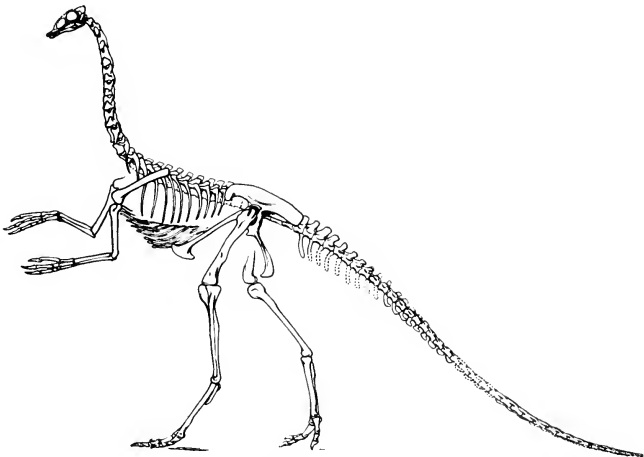


FIG. 360. *Struthiomimus*, an ostrich-like Cretaceous dinosaur, about 5 feet in height. (Courtesy, American Museum of Natural History, New York.)

lacking. Among fishes are eels without paired fins, among amphibians are legless caecilians, and among reptiles are legless lizards and snakes. In modern reptiles the connection of the skeleton of the pelvic legs with the vertebral column involves **two sacral vertebrae**, in contrast to the one of amphibians. This strengthening of the sacral connection is consistent with the fact that greater strain is incurred by skeletal parts in land animals than in aquatic animals, because in the latter the body is buoyed up by the water.

In addition to these terrestrial adaptations of the skin, respiratory organs, and locomotor appendages, there are many internal differences between aquatic anamniotes and reptiles. Most of these differences more or less directly reflect the change of environment.

The **reptilian skeleton** is, in general, more strongly built than that of fishes and amphibians. In many fishes the bones are so deficient in calcium that they are soft and flexible. Reptilian bones are heavily calcified.

The reptilian **skull** is, with some exceptions (the tuatara and some lizards), strongly ossified and contains a much greater number of bones than the skull of any modern amphibian, resembling rather the skulls of early labyrinthodont amphibians (**Stegocephalia**) and crossopterygian fishes (Fig. 361). In the absence of gills, it might be expected that such skeletal arches as support them in anamniotes would not occur in reptiles. The fact is, however, that in the ventral region of the mouth and pharynx are found certain skeletal parts, the **hyoid apparatus**, which, in position and relation to other structures, clearly correspond to portions of several of the more anterior visceral arches of fishes (Fig. 362). This hyoid apparatus supports the base of the **tongue** and the **larynx**, which corresponds to the "voice-box" (larynx) of mammals. It serves also for attachment of small muscles related to neighboring structures.

The embryonic **notochord**, except in some lizards (geckos) and in the New Zealand "tuatara" (*Sphenodon*; Fig. 374), is completely obliterated by development of the thoroughly ossified vertebral column (Fig. 363). The vertebral centra are of various forms, but only exceptionally of the amphicoelous type characteristic of fish vertebrae. With the differentiation of a neck, the **vertebral column** becomes definitely marked out into four regions: (1) **cervical**, the first cervical vertebra (**atlas**) being a bony ring articulating with the skull and separated from its own centrum, which has become secondarily joined to the anterior face of the second vertebra (**axis**), forming the conical **odontoid process** on which the atlas is pivoted (Fig. 364); (2) **trunk**, occupying the trunk region of the body and terminated by (3) the



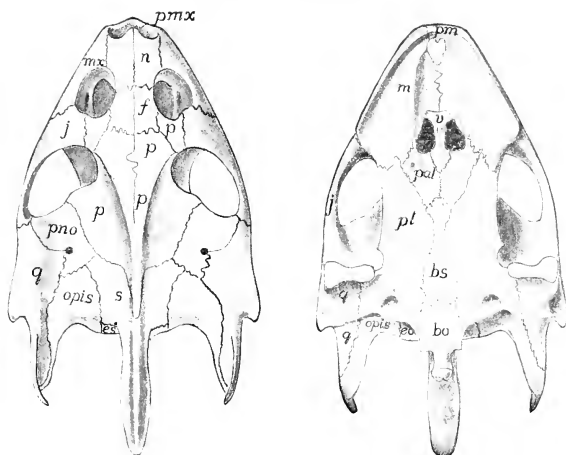


FIG. 361. Dorsal and ventral views of the skull of a turtle, *Trionyx*. Compared with the skull of the bony fish, that of reptiles shows increased compactness and integration of elements. (*bo*) Basioccipital; (*bs*) basisphenoid; (*co*, *ex*) exoccipital; (*f*) frontal; (*j*) zygomatic (jugal); (*m*, *mx*) maxilla; (*n*) prefrontal (naso-prefrontal?); (*opis*) opisthotic; (*p*) (behind orbit) postfrontal, (others) parietal; (*pal*) palatine; (*pm*, *pmx*) premaxilla; (*pno*) postnasal; (*pl*) pterygoid; (*q*) quadrate; (*s*) supraoccipital; (*v*) vomer. (Courtesy, Kingsley: "Comparative Anatomy of Vertebrates," Philadelphia, The Blakiston Company.)

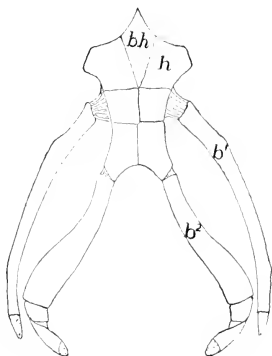


FIG. 362. Hyoid apparatus of a turtle, *Trionyx*. (*b*<sup>1</sup>, *b*<sup>2</sup>) First and second branchial arches; (*bh*) basihyal (copula); (*h*) reduced hyoid. Cartilage dotted. (Courtesy, Kingsley: "Comparative Anatomy of Vertebrates," Philadelphia, The Blakiston Company.)

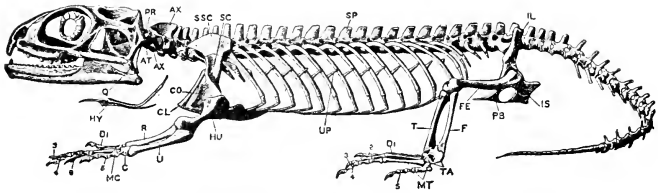


FIG. 363. Skeleton of *Sphenodon*. (AT) Atlas; (AX) axis; (C) carpal bones; (CL) clavicle; (CO) coracoid; (DI. 2, 3, 4, 5) digits; (F) fibula; (FE) femur; (HU) humerus; (HY) hyoid; (IL) ilium; (IS) ischium; (MC) metacarpals; (MT) metatarsals; (PB) pubis; (PR) pro-atlas; (Q) quadrate; (R) radius; (SC) scapula; (SP) spinal column (points to the spinous process of one of the thoracic vertebrae); (SSC) suprascapula; (T) tibia; (TA) tarsals; (U) ulna; (UP) uncinat process. (After Headley. From Parker and Haswell: "Text-Book of Zoology." By permission of The Macmillan Company, publishers.)

sacral region, including, in modern reptiles, only two vertebrae; (4) the **postsacral**, commonly called the "caudal," region, but inaccurately so because its more anterior vertebrae lie within the hinder trunk region of the body and not actually within the projecting tail. The

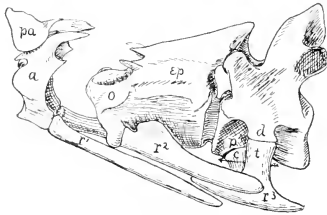


FIG. 364. Three anterior vertebrae of *Rhamphostoma*, a crocodilian (Schimkewitsch). (a) atlas; (c) capitular head of rib; (d) diapophysis; (ep) epistropheus; (o) odontoid process; (p) parapophysis; (pa) pro-atlas; ( $r^1, r^2, r^3$ ) cervical ribs; (t) tubercular head of rib. The arrow is in the vertebral canal. (Courtesy, Kingsley: "Comparative Anatomy of Vertebrates," Philadelphia, The Blakiston Company.)

numbers of vertebrae in the several regions are highly variable according to the proportions of the body in different types of reptile. The total number ranges from a minimum in short-bodied, short-tailed turtles (usually 20 exclusive of the postsacrals) to nearly 100 in some snakes. In snakes, legs being absent, no sacral region is recognizable and there is no distinction between cervical and trunk regions. In the alligator there are 9 cervical, 15 trunk, 2 sacral, and about 40 caudal vertebrae.

In contrast to amphibians, reptiles have well-developed **ribs**. They may be present on at least some of the vertebrae of each of the four regions of the column (Fig. 363). Cervical ribs are usually short and may be fused to the vertebrae. They may be absent from the first two or three vertebrae, but in crocodylians even the atlas and axis carry ribs. It is in the trunk region, and especially the more anterior part of it, that the ribs are best developed. Here they are so long as to nearly encircle the body. Each rib may consist of two or three segments, the ventral one being cartilaginous. Posteriorly, they diminish in length

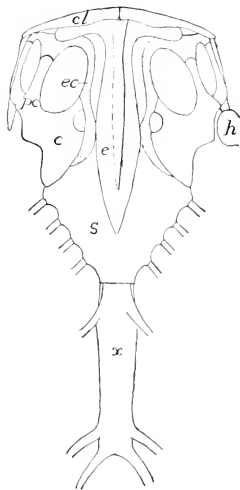


FIG. 365. Sternum, etc., of *Iguana tuberculata*. (*c*) coracoid; (*cl*) clavicle; (*e*) episternum; (*ec*) epicoracoid; (*h*) humerus; (*pc*) precoracoid; (*s*) sternum; (*x*) xiphisternum. (After Blanchard. Courtesy, Kingsley; "Comparative Anatomy of Vertebrates." Philadelphia, The Blakiston Company.)

and several of the most posterior trunk vertebrae may lack ribs. Each of the two sacral vertebrae carries a pair of short, stout ribs. The two ribs on each side are joined to the upper end of the dorsal bone (**ilium**) of that side of the pelvic girdle. The more anterior postsacral vertebrae may carry short ribs. In snakes, usually all vertebrae behind the axis and as far back as the cloacal region carry ribs which nearly encircle the body and are of nearly equal length throughout the entire distance—which is considerable in a snake.

In reptiles except snakes, some of the "legless lizards," and turtles, there is a median ventral skeletal plate, usually entirely cartilaginous, with which the ventral ends of several of the more anterior pairs of trunk ribs are joined. This is the **sternum**, corresponding to the "breastbone" of man (Fig. 365). The shorter, more posterior ribs do not meet the sternum. Attached to the anterior end of the sternum

is a median dermal bone, the **episternum** or **interclavicle**, which articulates with the right and left clavicles.

Bones known as "abdominal ribs" or "**gastralia**" occur in crocodilians, some lizards, and the tuatara. These are pairs of slender bones lying superficially in the abdominal wall. They have no connection with vertebrae and are apparently derived from the skin—"dermal bones." They are therefore more in the nature of scales and not truly endoskeletal.

The structure of the skeleton of the reptilian trunk is highly significant with reference to the **mechanism of breathing**. In amphibians, with very short ribs or none at all and a body-wall which, beyond the vertebral column, has no stiffening structures in it, air must be forced into the lungs by muscular movements of the floor of the mouth and the walls of the pharynx, the mouth and nostrils meanwhile being closed. Air is thus pushed back into the trachea in much the same way that food is pushed back into the esophagus. In reptiles the long ribs of the anterior region of the trunk, several pairs of them anchored ventrally to the sternum, impart considerable rigidity to the body-wall. The ribs, when in a resting position, slope somewhat sharply backward (Fig. 363) from their points of attachment to the vertebrae. When rotated forward by action of appropriate muscles, the diameter of the coelomic space is increased, with the result that air pressure within the lungs is decreased and external atmospheric pressure then forces air via nostrils, mouth, and trachea back into the lungs—or, as we loosely say, air is "sucked in." With return of the ribs to their resting position, air is forced out of the lungs. (In turtles the enclosing of the body in the "shell" necessitates another method of breathing. See p. 495.)

It is significant, too, that the accentuation of ribs in the anterior region of the trunk and their tendency to be shorter, or even entirely lacking, on several vertebrae just anterior to the sacral region, result in a condition closely approaching that in mammals, in which the trunk is sharply divided into an anterior **thorax** with long ribs, most of them meeting in a sternum, and a posterior **abdominal region** (Figs. 451, 452). But in mammals the cavities of the two regions are separated by a transverse partition, the diaphragm, which does not appear in reptiles. The vertebral column of the mammalian trunk is accordingly differentiated into an anterior rib-bearing **thoracic region** and a posterior ribless (or nearly so) **lumbar region**, terms which may be applied in some reptiles.

**The muscles of reptiles** show much more differentiation than those of anamniotes. In fishes there is very little local differentiation of the transverse muscle-segments (myomeres) which extend in a uni-

form series from head to end of tail (Fig. 88). The paired fins are relatively small and capable of only a few simple motions for which no elaborate set of muscles is required (Fig. 93). The most complex set of muscles in the fish is the branchiomeric system, which effects the respiratory movements in the gill-region. The pentadactyl leg, with its basal girdle, three jointed segments, and five digits, at once requires a set of muscles much more complex than that of a one-segment lateral fin. The high degree of mobility of the reptilian head and neck depends upon a corresponding degree of differentiation of muscles in those regions. In the anterior or "thoracic" region of the trunk, there must be muscles specialized to effect the respiratory movements (Fig. 366, *bottom*). The muscles of the abdominal part of the body-wall show least specializing of the primitive myomeres. Altogether, therefore, the muscular system of reptiles is vastly more complex than that of fishes, and considerably more so than that of amphibians (Fig. 366, *top*).

The **kidney** of an adult reptile differs from that of an amphibian. At a very early stage in the development of a fish or amphibian, a small number of excretory (renal) tubules develop at the anterior end of the coelom. The several tubules of each side constitute, in effect, an embryonic kidney, the **pronephros**. These structures, however, are briefly transitory and are replaced by a more extensive set of paired tubules which develop in a more posterior position. Those on each side become elaborated and compacted into a definite organ, the **meso-**

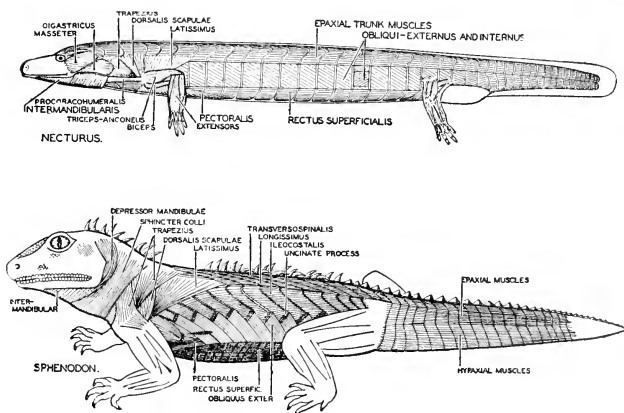


FIG. 366. Superficial lateral trunk muscles in an amphibian and a reptile. (*Top*) *Necturus*. (*Bottom*) *Sphenodon*. (Courtesy, Neal and Rand: "Chordate Anatomy," Philadelphia, The Blakiston Company.)

**nephros**, which persists as one of the pair of functional kidneys of the adult. In males the anterior part of the mesonephros becomes connected with the testis of the same side, and sperm passes through the mesonephric tubules into the outgoing duct (Wolffian duct) of the kidney (Fig. 78). The posterior part of the mesonephros serves only the renal function. The duct, therefore, is not merely urinary, but is a **urinogenital duct**. In females the mesonephros has nothing to do with the ovary or eggs.

The reptilian embryo develops structures which agree in all essentials with the pronephros and mesonephros, but neither of them persists to the adult stage except that in males the anterior part of the mesonephros becomes transformed into the "accessory testis" or **epididymis** (Fig. 78C) which intervenes between the testis and the sperm-duct (**vas deferens**). The definitive kidneys of the adult reptile are a third pair, each of which (a **metanephros**) develops in close relation with, but posterior to, the embryonic mesonephros. The reptilian kidney, therefore, is merely **analogous** to the anamniote kidney, but the two are **not homologous**. (It is possible, but doubtful, that the hind part of the kidneys of some elasmobranchs and amphibians may be of metanephric nature. See p. 85.)

In all reptiles the urinogenital ducts and the anus have exit by way of a common superficial chamber, the **cloaca**. A **urinary bladder**, opening out from the midventral wall of the cloaca, may or may not be present. In the New Zealand tuatara, a supposedly "primitive" reptile, the bladder is especially large. It occurs in turtles and tortoises and in most lizards. It is lacking, among lizards, in the monitors and legless lizards (amphisbaenians), and is absent also in snakes, alligators, and crocodiles.

The **nervous organs** of reptiles are, in general, similar to those of amphibians, but there are numerous differences which, although not conspicuous anatomically, do indicate a higher degree of nervous efficiency in the reptile. The most striking difference consists in the **absence of lateral-line organs**. No trace of them is found in the adult reptile or in the embryo. Constructed as they are in anamniotes, they could not endure exposure to dry air and impact of hard objects, and their presence in reptilian skin would be quite incompatible with the development of a horny layer. They are peculiarly adapted to an aquatic environment. Any disadvantage which the reptile might suffer in their absence is doubtless fully compensated for by improvements in other sensory organs. Equally incompatible with the horny layer would be organs such as the integumentary organs of "taste" as they occur on the bodies of fishes.

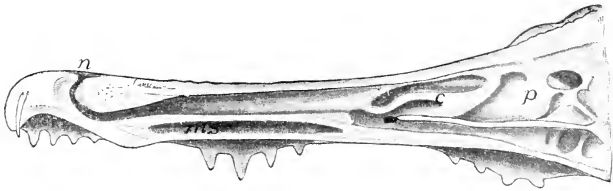


FIG. 367. Longitudinal section of nasal region of alligator. (*c*) Concha; (*ms*) maxillary sinus; (*n*) naris; (*p*) pseudoconcha. (After Gegenbaur. Courtesy, Kingsley: "Comparative Anatomy of Vertebrates," Philadelphia, The Blakiston Company.)

In reptiles the **sense of taste** is confined to the mouth. Lack of external organs of taste is probably offset by better development of the nasal organ of chemical sense, the **olfactory organ**. The efficiency of this organ depends in part on the extent of the nasal surface occupied by the olfactory sensory cells. This surface is increased by various complications of the walls of the nasal cavities. In reptiles the lateral wall of each cavity gives rise to an elongated, inwardly projecting ridge or "shelf," the **concha**, which is more or less curled downward (Fig. 367). In birds and mammals such conchae are more numerous and more elaborately curled (Figs. 505, 507). The skeletal support of a concha consists of a thin layer of cartilage or bone belonging to the **ethmoid** region of the cranium. In mammals the keenness of the sense of smell is, in general, correlated with the number and expanse of the conchae. In some amphibians the lateral wall of the nasal cavity bears a low ridge which may be regarded as a weakly developed concha. As to expansion of olfactory surface, therefore, the reptiles are intermediate between amphibians and mammals.

Some reptiles possess what appears to be an accessory olfactory organ, the **vomerinal organ** or **organ of Jacobson** (Fig. 368). It develops as a ventral hollow outgrowth from each nasal cavity, forming a pair of small pouches lying in the anterior region of the roof of the mouth and each opening into the oral cavity by a narrow **nasopalatine duct**. The two ducts open close together just behind the front teeth and anterior to the internal nares. Nerve-fibers from the olfactory (first cranial) nerve, and some trigeminal (V) fibers, are distributed to the epithelial lining of the organ. The structure and connections of the organ indicate that it may enable the animal to smell substances contained in the oral cavity. Jacobson's organ is well developed in *Sphenodon* and in lizards and snakes, but absent or rudimentary in crocodilians and turtles. A similar organ occurs in most amphibians but is less well developed than in reptiles.

Reptilian **eyes** give evidence of being more effective visual organs

than eyes of amphibians. The external supporting layer (**sclerotic**) of the eyeball usually contains considerable cartilage. In lizards and turtles ossification of the cartilage forms a circular series of small **sclerotic plates** surrounding the exposed outer face of the eyeball

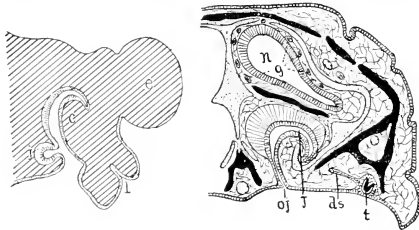


FIG. 368. Sections of larval (Born) and adult (Schimkewitsch) nasal organs of *Lacerta*. Bone black. (c) Embryonic concha; (ds) dental shelf; (e) eye; (g) Jacobson's glands; (j) organ of Jacobson; (l) lacrimal groove; (n) main nasal cavity; (oj) duct of organ of Jacobson; (t) tooth-germ. (Courtesy, Kingsley; "Comparative Anatomy of Vertebrates," Philadelphia, The Blakiston Company.)

(Fig. 369). Reptiles have a more refined method for "accommodating" or focusing the eyes for objects at varying distances. In teleost fishes the resting eye is focused for near objects. For seeing distant objects the lens is pulled back toward the retina by a muscle (retractor lentis)

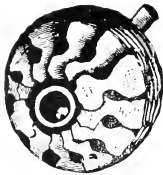

FIG. 369. Circular series of bony sclerotic plates in the outer wall of the eyeball of a lizard. (Courtesy, Wiedersheim; "Grundriss der vergleichenden Anatomie der Wirbeltiere," Jena, Gustav Fischer.)

inside the eyeball. In **amphibians** the resting eye is set for distant objects. For near sight, the lens is moved away from the retina. In **reptiles** the lens is quite elastic. By action of the ciliary muscles situated in the adjacent region of the wall of the eyeball (see p. 201), the degree of convexity of the lens may be altered. For distant vision the lens becomes less convex; for near vision the convexity is increased. In birds and mammals accommodation is effected in a similar way, although differing in details (see Fig. 510). **Eyelids** are better developed than in most amphibians. There are ordinarily upper and lower lids, both freely

movable, and under them a semitransparent **nictitating membrane** which may be pulled across the eye from front to rear. The chameleon, however, has a single circular lid with a central hole in it. In most lizards of the gecko family and in all snakes, eyelids are quite



lacking except that the development of the snake's eye gives evidence that the adult eye is covered by a nictitating membrane which is immovably attached and has become quite transparent.

The **sensory internal ear** of the reptile differs in one significant particular from that of the amphibian. In all vertebrates except cyclostomes and a few fishes, the ventral chamber (**sacculus**) of the main ear sac bears a more or less elongated hollow outgrowth, the **lagena** (Fig. 130), containing an area of sensory cells (**papilla acustica lagenae**) to which a branch of the auditory nerve is related. In fishes the lagena is so small as to be sometimes hardly noticeable, and its function is doubtful. In mammals, in conjunction with a closely adjacent sensory area (the **papilla basilaris**), it becomes greatly elongated and curved into a close spiral forming the so-called "**cochlea**." The complex sensory mechanism (**organ of Corti**) of the cochlea is the essential organ of hearing. The keenness and range of the sense of hearing in mammals are directly related to the degree of elongation of the cochlea. In amphibians the lagena is somewhat more prominent than in fishes. In reptiles it is more or less elongated—least so in turtles and snakes, more so and highly variable in lizards. In crocodylians it attains greatest elongation, its axis is curved, and its internal sensory mechanism is closely similar to the mammalian organ of Corti (Figs. 130, 517). The name "**cochlea**" is commonly applied to the elaborated lagena of the crocodylian. It is highly probable that the degree of development of the lagena is a fair index of the efficiency of the sense of hearing in reptiles.

In all modern reptiles except snakes and legless lizards, the ear possesses a more or less well-developed **tympanic apparatus** similar to that of frogs and toads (Fig. 353). The embryonic pharyngeal pouches of the most anterior pair fail to perforate to the exterior and give rise to the **tympanic cavities**, each covered externally by a **tympanic membrane**. In turtles and some lizards the membrane lies at the level of the surrounding skin. In other lizards it is more or less depressed below the surrounding surface so that it lies at the bottom of a pocket which, except for its shallowness, resembles the deeper external auditory passage (meatus) of a mammal (Fig. 518). In crocodylians the tympanic membrane is fairly deep and the external auditory cavity is nearly covered by folds of skin, one above and one below (resembling upper and lower eyelids), with only a narrow slit between them. The passage whereby the tympanic cavity opens into the mouth is longer and narrower than that in the amphibian, resembling more the **Eustachian tube** of mammals.

The **columella** extends from the tympanic membrane across the tympanic cavity and is joined to a small bony plate, the **stapes**, which

fits into an oval aperture (**fenestra ovalis**) in the bony wall of the auditory capsule, the part of the cranium containing the internal ear. (Fig. 353). The stapes is attached by membrane to the edge of the "oval window" and is, therefore, capable of a certain small amount of movement in and out as the columella transmits external vibrations to it. The columella, cartilaginous in the embryo, may ossify to form two, or even three, connected parts. A second "window," the **fenestra rotunda**, pierces the bony wall of that part of the auditory capsule against which the tympanic cavity abuts, but it is a closed window—closed by a taut membrane. This "round window" serves to facilitate the passing of vibrations through the watery fluid (**perilymph**) which fills the considerable space intervening between the delicate auditory sac (internal ear) and the wall of the bony capsule within which it lies. The otic sac is not only immersed in perilymph but is filled by a similar **endolymph**. As the vibrating columella pushes the stapes slightly inward against the perilymph, the membrane filling the fenestra rotunda may bulge slightly outward, and meanwhile the vibrations will have affected all the fluids, endolymph as well as perilymph, within the auditory capsule.

In the New Zealand tuatara (*Sphenodon*) there are well-developed tympanic cavities and the usual columellar apparatus, but no definitely differentiated tympanic membrane. The tympanic cavity is covered externally by ordinary thick skin containing a very small cavity which may be interpreted as a vestige of an external auditory cavity.

In **snakes tympanic cavity and membrane** are lacking. There is, however, a somewhat reduced **columella** which is merely embedded among the muscles adjacent to the auditory capsule and in some cases is connected by ligament to the **quadrate**, the skull bone to which the lower jaw is articulated. In the externally snakelike legless lizards, the tympanic mechanism is in a more or less reduced condition. The feeding habits of snakes probably account, at least in part, for the absence of the tympanic mechanism. A snake may take a month's ration of food at one mouthful, as when a rattlesnake swallows a rabbit. An extremely loose-jointed jaw-skeleton makes this possible. In the absence of a sternum, the ribs are free to swing outward. As the prey passes from mouth to stomach, the body-wall of the intervening region is severely stretched. The normal position for the tympanic apparatus is immediately behind the jaws. It is clearly not a safe place for the delicately articulated columellar mechanism.

The **reptilian brain** is larger, relative to the body, than the brains of fishes and amphibians. All five regions of the brain are strongly developed and exhibit more internal complexity than is found in brains

of aquatic anamniotes. This is in accord with the fact that the reptile has the more highly differentiated and complex muscular system and, in general, is capable of greater range and diversity of activities. A greater number of nervous elements and their arrangement in a more elaborate pattern are therefore necessary. The most noteworthy point concerns the most anterior (**telencephalon**) of the five regions (Fig. 370). It consists mainly of a pair of large lobes, the **cerebral hemispheres**. The roof, **pallium**, of each hemisphere is thinner than the lateral and ventral walls, which together constitute the **corpus striatum**. The pallium, however, is somewhat thicker than the corresponding part of the amphibian brain. In fishes the pallium is comparatively thin. In the largest and most specialized group, Teleostei, it is exceedingly thin and contains no nervous tissue whatever (Fig. 324). The amphibian pallium however, consists mainly of nervous tissue, most of whose cell-bodies are massed into a deep layer of "gray substance" while an external layer of "white substance" consists mainly of the nerve-fibers. In the reptilian pallium the relative position of "gray" and "white" tends to be the reverse of that in the amphibian (Fig. 371). The fibers are mostly deep and the bodies of the nerve-cells are more or less massed into an external layer of "gray" corresponding to the more strongly differentiated external gray layer, the **cortex cerebri**, of the mammalian hemispheres.

The cerebral cortex of mammals is the seat of nervous mechanisms which exert the supreme control over the voluntary activities of the body. To a large extent, bodily activities are carried out automatically. We breathe, cough, and sneeze "without thinking." The central nervous mechanisms which immediately control such automatic activities are located in the several parts of the brain other than the cerebral cortex, in the spinal cord, and in the more deeply situated autonomic nervous system. But if a person "stops to think" about it, he may (within limits) hold his breath or suppress the cough or (less likely) the sneeze. Walking and running require that numerous muscles shall alternately contract and relax in perfectly harmonious coordination. Such coordination is automatically effected by nerve-centers situated in the cerebellum. But *when* we may walk and *where* we go and *whether* we walk or run are usually determined by something that happens in the cortex cerebri. The general orders having gone forth from the cortex, the routine details of locomotion are managed automatically by the cerebellum. Thinking, conscious deliberation with consequent choice of one line of action rather than another, and activities which we describe as "intelligent," involve nervous activity in the cortex.

Study of the **behavior** of fishes, amphibians, and reptiles makes it quite clear that their activities are predominantly the outcome of the

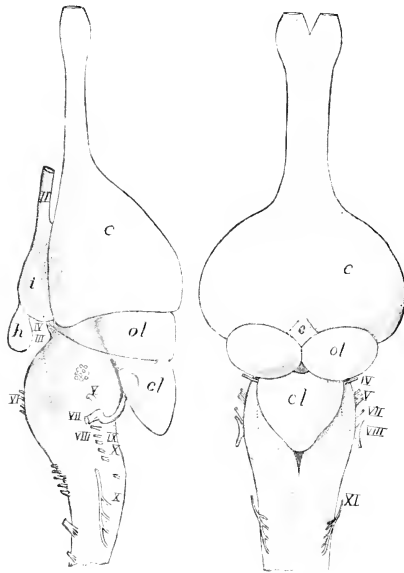


FIG. 370. Side and dorsal views of brain of young alligator. (*c*) Cerebrum; (*cl*) cerebellum; (*e*) epiphyseal structures; (*h*) hypophysis; (*i*) infundibulum; (*ol*) optic lobes; (II-XII) cranial nerves. (After Herrick. Courtesy, Kingsley: "Comparative Anatomy of Vertebrates." Philadelphia, The Blakiston Company.)

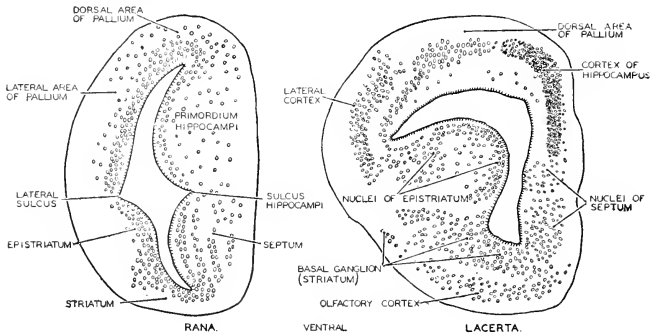


FIG. 371. Cross sections of the left cerebral hemisphere of an amphibian (*Rana*) and a reptile (*Lacerta*), showing the increasing importance of the pallium as a region of nervous centers—i.e., the development of a cerebral cortex. The epistriatum is a local thickening of the ventrolateral wall of the hemisphere. (Redrawn from Plate, after Kuhlbeck. Courtesy, Neal and Rand: "Chordate Anatomy," Philadelphia, The Blakiston Company.)

operation of inherited specialized nervous mechanisms. They are **instinctive** activities. The young animal does not have to be taught. As its nervous mechanisms acquire complete development, the animal automatically and inevitably carries out the activities which are normal and characteristic of its species. And yet this instinctive determination of behavior is not complete and rigid. Even an earthworm can be "taught" to modify its behavior and may "learn by experience"—which does not necessarily imply intelligence. So also, in fishes and amphibians, there is a certain degree of flexibility in the pattern of behavior. To a very limited extent a fish may learn by experience and may modify its customary behavior. In amphibians, and especially in frogs and toads, the capacity for modifying behavior is somewhat greater than that in most fishes (so far as can be judged from the scanty data available). In fact, some observers have gone so far as to ascribe intelligence to frogs and toads. If, however, intelligence is to be understood as implying deliberate thinking about two alternative lines of action and contrasting the desirability of their *foreseen* consequences, then it is quite certain that the evidence at hand does not warrant describing these animals as intelligent.

The behavior of reptiles is certainly on a higher level than that of amphibians in general, but perhaps not so much higher than that of toads. The common toad seems to have achieved the peak of behavior for amphibians. Reptiles can learn, remember, and form new habits. They respond more quickly than amphibians. Here, again, there is no proof of intelligence, but an interested observer of reptiles is likely to find it difficult to restrain himself from crediting them with faint glimmerings of something akin to intelligence at its lowest level.

Fishes, amphibians, and reptiles constitute a series in which the degree of differentiation of the muscular system, the diversity and complexity of the animal's activities, and the adaptive modifiability of behavior are at the minimum in fishes and at the maximum in reptiles. Parallel to these differences, the cerebral hemispheres in the series are successively more strongly developed. The pallium, non-nervous in most fishes, becomes an important nervous layer in amphibians and, in reptiles, possesses a "gray" cortex resembling that of a mammal. Therefore the fact that the cortex of the mammal contains the nerve-centers responsible for such intelligence as the animals' behavior may exhibit has some implications for reptiles.

From the reptilian brain arise **12 pairs of cranial nerves**. Of these, 10 pairs correspond in all particulars to the 10 pairs always present in fishes and amphibians. The eleventh (**accessory**) and twelfth (**hypoglossal**) arise from the extreme hind end of the brain and behind the tenth pair. The embryonic origin and the connections

of the eleventh and twelfth nerves indicate that they correspond, at least in part, to certain anterior spino-occipital nerves of fishes and amphibians, but the accessory (XI) seems to have annexed some posterior roots of the vagus (X).

The **reproductive methods** which prevail among anamniotes are quite unsuited to terrestrial animals. Although amphibians are to some extent adapted for living on land, the gilled larval stage in their development forbids their living far from fresh water. Some of them have found means (see p. 239) of passing the larval stage without recourse to external water, and a few of them omit the "tadpole" stage. The great majority of them, if not wholly aquatic, must seek water at the breeding season.

Vertebrate eggs range in size from the microscopic to the size of ostrich eggs. The eggs of anamniotes, with some exceptions, are well toward the lower end of the range. Small eggs contain a correspondingly small amount of food material for the building up of the embryo. Therefore the small anamniote egg, usually deposited and left to its fate in the open water, must develop rapidly into an animal which, while still very minute, has all of its organs (except the reproductive) developed to a functional state so that, as soon as the food within the egg is exhausted, the animal will be able to feed itself and begin its independent life. Then follows a prolonged period of growth before the animal, if ever, attains sexual maturity and adult size. If a python or dinosaur were to hatch out of its egg and begin free life on land at a length of 2 or 3 mm., the size of many a newly hatched fish, it could hardly hope to grow up.

**Eggs of reptiles**, compared to those of most anamniotes, are of enormous size. They are fertilized (by copulation) before they are laid. The **copulatory organ (penis)** in turtles, tortoises, and crocodilians is a median longitudinal thickening of the ventral wall of the cloaca. It is vascular, erectile, and protrusible through the cloacal aperture. A groove along its dorsal surface conducts the sperm. Lizards and snakes have a pair of protrusible cloacal structures, the **hemipenes**.

The eggs are invested by protective shells of a tough leathery texture, or hard like shells of birds' eggs. They are deposited on land (except in viviparous species). In contrast to the usual anamniote development in which differentiation of organs is early and rapid but accompanied by little growth, the reptile has a prolonged prehatching period during which differentiation proceeds, so to speak, at leisure, and relatively great size is attained before hatching. A newly hatched alligator is about 8 inches long. The early embryo surrounds itself by a system of membranes produced from its own tissues (see p. 291). The

space between the innermost **amnion** and the body of the embryo is filled with a watery fluid having a chemical composition resembling that of sea water. The **allantois**, growing out from the hindgut, contains a system of blood-vessels and spreads out in close relation to the inside surface of the porous shell, thus providing for respiratory interchange of gases between the blood and the external air (Fig. 372). The embryo, although that of a land animal, develops in an aquatic medium, the **amniotic fluid**. This fluid, however, being produced by the embryo itself, cannot be a source of the oxygen necessary for the rapidly growing animal. Therefore gills would be of no use. The early embryo, although immersed in fluid, declares its terrestrial nature by improvising the temporary allantoic "lung" to serve for the breathing of air until emergence from the shell makes it possible to use the internal lungs.

The reproductive method of reptiles and their complete structural adaptation to terrestrial life open to them all the land surfaces of the earth except so far as temperature may be a restricting factor. Being "cold-blooded" (poikilothermous), reptiles must confine themselves to those regions whose temperatures are not so low as to make animal metabolism impossible.

#### CLASSIFICATION

A classification including all reptiles, present and extinct, requires the defining of 30 or more orders. Reptiles now existing fall into either four or five orders, depending on whether lizards and snakes are

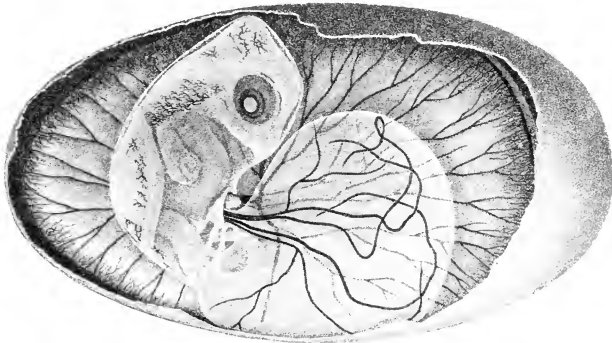


FIG. 372. Turtle (*Chrysemys picta*) embryo: enlarged about 3 times. The well-developed eye, the legs, and the beginning of the carapace may be seen. The amnion appears (in optical section) as a very thin pale membrane fitting snugly about the head and body. The nearly spherical yolk-sac is marked by prominent blood-vessels. The fully expanded allantois, seen in the distance, spreads over the inner surface of the shell. (Courtesy, Louis Agassiz: "Embryology of the Turtle," Boston: Little, Brown & Co.)

classed as separate orders or as subdivisions of one. Crocodylians and turtles obviously represent separate orders. Aside from the four types just mentioned, only one modern reptile type remains—the New Zealand tuatara. The following arrangement makes five orders of existing reptiles.

#### *Order Rhynchocephalia*

**Sphenodon.** Vertebrae with **amphicoelous centra** perforated (at least in younger individuals) by the **persisting notochord**, which is continuous but constricted by each centrum. **Skull** resembles that of early reptiles and differs from that of lizards in many particulars—most notably in that the **quadrate** (the upper jawbone to which the lower jaw is articulated) is **immovably** joined to adjacent bones of upper jaw and cranium (Fig. 373). **Legs** well developed. **Ribs** have **uncinate processes** (Fig. 363). **Sternum** and **gastralia** (“abdominal ribs”) are present. Median dorsal **parietal eye** especially well developed. **Cloacal aperture** is a **transverse slit**. Large **urinary bladder**. **Oviparous**.

The only living member of the order is the **tuatara**, **Sphenodon (Hatteria) punctatum**, found only in New Zealand (Fig. 374). Externally resembling a lizard (length 18 inches or more), the animal’s internal peculiarities forbid classifying it with lizards and identify it as the sole survivor of one of the most ancient and once widespread orders of reptiles. Sometimes spoken of as a “living fossil,” it is of such great scientific importance that, in the hope of preventing its untimely extinction, it has been protected by legislation prohibiting its capture except for scientific purposes.

#### SUPERORDER SQUAMATA

**Lizards and Snakes.** **Quadrate bone** more or less elongated; its dorsal end **movably** (except in chameleons) joined to adjacent bones of the otic region of the cranium. Thus, **between lower jaw and brain-case, two joints intervene**—an arrangement giving greater freedom to the movement of the lower jaw and increasing the extent to which the mouth may be opened (Fig. 375). **Cloacal aperture** is a **transverse slit**.

#### *Order Sauria (Lacertilia)*

**Lizards.** **Notochord not persistent** and vertebral centra usually procoelous, except in the geckos, whose vertebrae resemble those of *Sphenodon*. Pectoral and pelvic **legs usually strongly developed** (Fig. 376). **Sternum** usually present; several pairs of anterior “thoracic” ribs attached to it. **Gastralia** rarely present; they occur in “monitors” (*Varanus*) and in some others. **Movable eyelids**, the



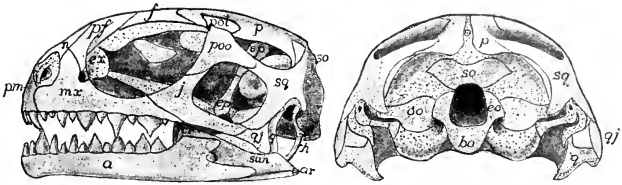


FIG. 373. Side and posterior views of skull of young *Sphenodon*. Cartilage dotted. (*a*) Dentale; (*ar*) articular; (*bo*) basioccipital; (*er*) coronoid; (*eo*) exoccipital; (*ep*) epipterygoid; (*er*) extranasal; (*f*) frontal; (*h*) hyoid; (*j*) zygomatic (jugal); (*mx*) maxilla; (*n*) nasal; (*oo*) opisthotic; (*p*) parietal; (*pf*) prefrontal; (*pm*) premaxilla; (*pol*) postfrontal; (*poo*) postorbital; (*q*) quadrate; (*qj*) quadratojugal; (*san*) supra-angular; (*so*) supraoccipital; (*sq*) squamosal. (After Howes and Swinerton. Courtesy, Kingsley: "Comparative Anatomy of Vertebrates," Philadelphia, The Blakiston Company.)



FIG. 374. *Sphenodon*. (Photographed in its natural environment in New Zealand by Frieda N. Blanchard.)

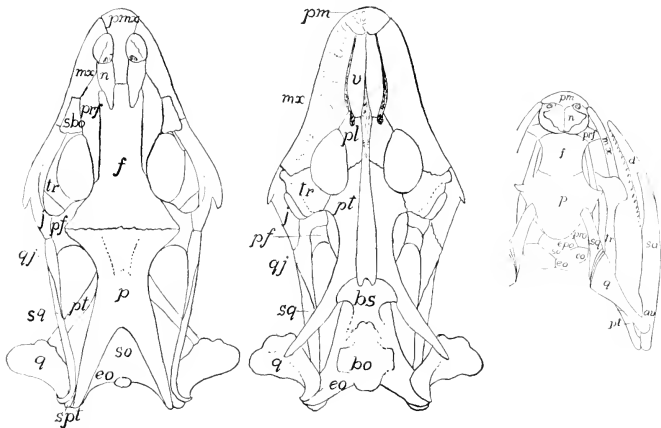


FIG. 375. (Left and Center) Skull of a lizard (*Gerrhontus imbricatus*). (After Siebenrock.) (Right) Skull of snake, *Tropidonotus*. (After Parker.) (av) articular; (bo) basioccipital; (bs) basisphenoid; (d) dentale; (eo) exoccipital; (epo) epiotic; (f) frontal; (j) jugal; (mx) maxilla; (n) nasal; (oo) opisthotic; (p) parietal; (pf) postfrontal; (pl) palatine; (pm, pmx) premaxilla; (prf) prefrontal; (pro) proötic; (pt) pterygoid; (q) quadrate; (qj) quadratojugal; (sa) supra-angular; (sbo) subocular; (so) supraoccipital; (spt) supratemporal; (sq) squamosal; (tr) transversum; (v) vomer. (Courtesy, Kingsley: "Comparative Anatomy of Vertebrates," Philadelphia, The Blakiston Company.)

**tympatric auditory apparatus** and the **parietal eye** (Fig. 377) usually well developed. **Urinary bladder** present in most groups. Some lizards are viviparous.

Some lizards are exceptional in that, in varying degree, the body is elongated and the legs are reduced (Fig. 378)—a condition culminating in the "**legless lizards**," **Amphisbaenia**. These burrowing animals appear snakelike, having no external legs, although vestiges of girdles may persist. The sternum is reduced or absent. The tympanic structures of the ear are less well developed than in typical lizards. The urinary bladder is lacking, as in snakes.

#### Order Serpentes (*Ophidia*)

**Snakes** (Fig. 379). Body much elongated and cylindric. **No legs**, although occasional vestiges of the pelvic (but never the pectoral) girdle occur and in pythons there are vestiges of hindlegs appearing externally as a pair of clawlike projections (Fig. 380). Bones of upper jaw (**maxillary, palatine, pterygoid**) **movably joined** by elastic ligaments. Right and left halves (rami) of lower jaw joined in front by

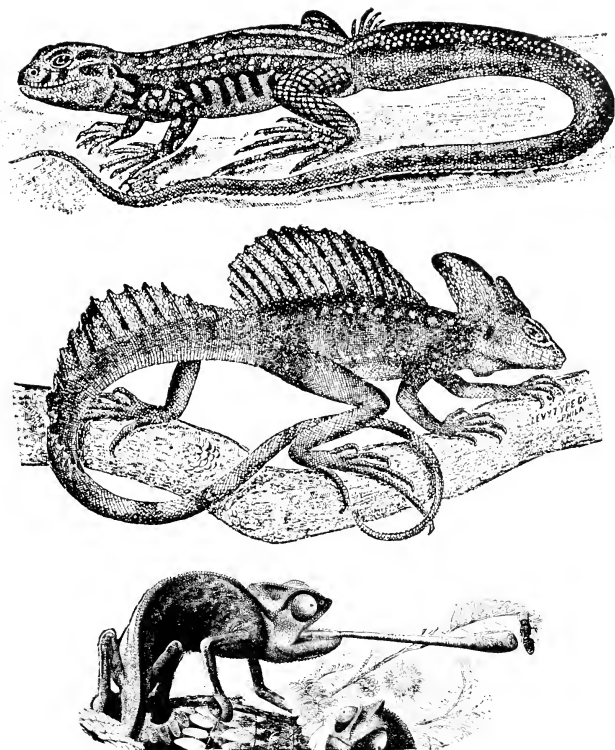


FIG. 376. Lizards. (Top) *Liolepis*. (Center) *Basiliscus*. (Bottom) Chameleon. (Top and Center, courtesy, Cope: "The Crocodilians, Lizards and Snakes of North America," Washington, The Smithsonian Institution. Bottom, courtesy, Brehm: "Tierleben," Leipzig, Bibliographisches Institut.)

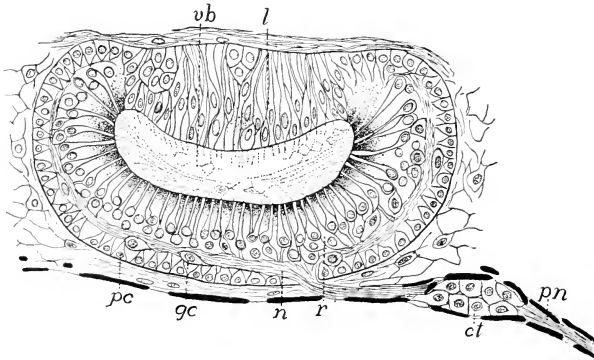


FIG. 377. Parietal eye of the legless lizard, *Anquis fragilis*. (*ct*) Connective-tissue cells around nerve; (*gc*) ganglion-cells; (*l*) lens; (*n*) nerve-fibers; (*pn*) parietal nerve; (*pc*) pigment-cells; (*r*) retinal cells; (*vb*) vitreous body. (After Nowikoff. Courtesy, Kingsley: "Comparative Anatomy of Vertebrates," Philadelphia, The Blakiston Company.)



FIG. 378. *Chirotles*, an almost legless lizard. (Courtesy, Brehm: "Tierleben," Leipzig, Bibliographisches Institut.)

elastic ligament. **No sternum. Movable eyelids, tympanic cavity and membrane are lacking.** Parietal organ not eyelike. **No urinary bladder.** Many snakes are viviparous.

In snakes, as in lizards, the **movable quadrate** increases the extent to which the mouth may be opened, but in snakes the potential "gape" is further greatly increased by the elastic connections of the several bones of the upper jaw and of the two rami of the lower jaw

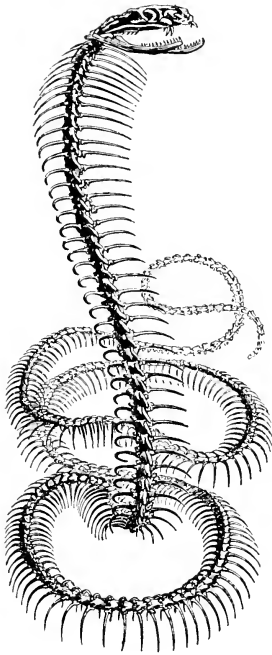


FIG. 379. Skeleton of a cobra. (Courtesy, Owen: "Comparative Anatomy and Physiology of Vertebrates," London, Longmans, Green & Co., Ltd.)

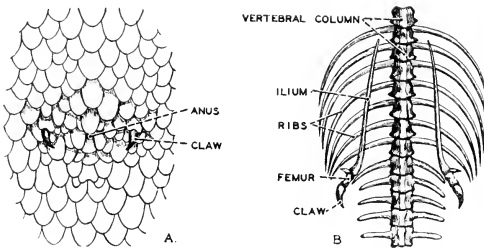


FIG. 380. (A) Ventral external aspect of anal region of python. (B) Skeleton of pelvic region, showing rudimentary femur and ilium (After Romanes. Courtesy Neal and Rand: "Comparative Anatomy," Philadelphia, The Blakiston Company.)

(Fig. 381). The snake's ability to swallow relatively enormous objects of prey is due to the extreme elasticity of the whole complex of jaw-bones, and to the freedom of the ribs in the absence of a sternum.

The superficial resemblance of legless lizards and snakes affords a good example of "convergence." In most respects the amphisbaenians are definitely lizard-like. The skull is not like that of snakes and even has some features which seem more amphibian than lacertilian. There is doubt as to the proper classification of amphisbaenians. Although usually placed in a suborder of Lacerilia, it is possible that they should be ranked as a third order of Squamata.

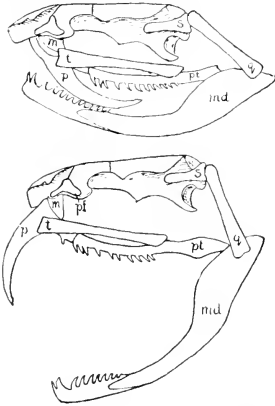


FIG. 381. Diagrams of skull of a venomous snake with open and closed jaws. (*m*) Maxilla; (*md*) mandible; (*p*) poison-tooth; (*pf*) prefrontal; (*pt*) pterygoid; (*q*) quadrate; (*s*) squamosal; (*t*) transversum. (After Bütschli. Courtesy, Kingsley: "The Vertebrate Skeleton," Philadelphia. The Blakiston Company.)

The **Squamata**, both lizards and snakes, are the most widely distributed and numerous of living reptiles. They range over the whole earth where temperature permits. The majority are terrestrial, many are arboreal, some are burrowing, a few are aquatic, and the "flying lizards" (*Draco volans*: Fig. 605) of southern Asia and the Malayan region make long gliding flights by use of their flying membranes, which consist of a broad, thin fold of skin projecting from each side of the body and stiffened by greatly elongated ribs.

Among ancient reptiles were some real fliers, the **pterosaurs** (**pterodactyls**: Fig. 389), which were the reptilian equivalent of mammalian bats. The burrowing amphisbaenians are mostly American, but some occur in Africa and the Mediterranean region.

Most snakes and lizards are relatively small animals, but they range in size up to that of the python and boa constrictor and, among lizards, the American iguana, which may exceed 5 feet in length, and the "monitors" (*Varanus*) of southern China and the Malayan region, for which lengths up to 9 or 10 feet have been reported.

### Order Crocrodilia

**Crocodiles and Alligators.** Large **horny scales strongly developed**, especially on the back, where they are reinforced by thick

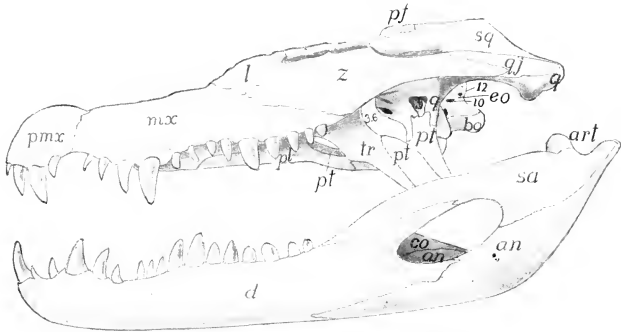


FIG. 382. Skull of a crocodilian, *Caiman latirostris*, the irregularities of the surface omitted. (*an*) Angular; (*art*) articular; (*bo*) basioccipital; (*co*) coronoid; (*d*) dentale; (*eo*) exoccipital; (*l*) lacrimal; (*mx*) maxilla; (*pf*) postfrontal; (*pt*) palatine; (*pmx*) premaxilla; (*pt*) pterygoid; (*q*) quadrate; (*qj*) quadratojugal; (*sa*) surangular; (*sq*) squamosal; (*tr*) transversum; (*z*) zygomatic (jugal); (3, 5, 6, 9, 10, 12) foramina for exit of cranial nerves. (After Reynolds. Courtesy, Kingsley: "Comparative Anatomy of Vertebrates," Philadelphia, the Blakiston Company.)

dermal **bony plates**. In some species bony plates occur both dorsally and ventrally. Skull with **quadrate bone firmly joined** to adjacent bones and all other bones of upper jaw immovably connected; right and left rami of lower jaw firmly united in front (Fig. 382). **Ribs** (as also in *Sphenodon*) have **uncinate processes**—a prong projecting backward from one rib overlaps the rib next behind, thus tying the ribs together (Fig. 363). **Sternum** well developed. **Gastralia** present. **Parietal organ** not eyelike. **Ventricle** of heart **completely divided** into right and left chambers. **Cloacal aperture** is a **longitudinal slit**. **No urinary bladder**. **Oviparous**.

The anatomic differences which distinguish the several members of the **Order** are not important (Figs. 383, 384). Alligators have a broad head with a blunt snout. In crocodiles the head is narrower and more nearly triangular, and the snout is sharper. The heads of the several species of caiman are intermediate in shape between heads of alligator and crocodile. The gavial has an extremely long, narrow, and pointed snout-region.

**Alligators** are found in North America and (another species) in China; **crocodiles** in tropical America, Africa, southern Asia, and Australia; **caimans** in Central and South America; the **gavial** in India and the Burmese region. The largest crocodilian is the gavial, whose length may exceed 20 feet. Alligators and crocodiles range up to 12 or 15 feet. Most caimans are smaller, but one species ("black caiman") may attain 20 feet.

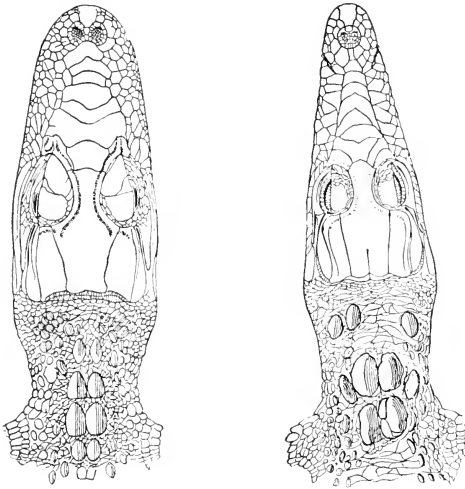


FIG. 383. (*Left*) Alligator head. (*Right*) Crocodile head. Dorsal views. (Courtesy, Cope: "The Crocodylians, Lizards and Snakes of North America," Washington, The Smithsonian Institution.)




FIG. 384. (*Left*) Ceylon crocodile. (*Right*) Gavial. (*Left*, courtesy, Deraniyagala: "Tetrapod Reptiles of Ceylon," London, Dulau & Co., Ltd. *Right*, courtesy, Brehms: "Tierleben," Leipzig, Bibliographisches Institut.)



## Order Chelonía

**Turtles and Tortoises.** Body enclosed within a protective "shell" consisting of a **dorsal carapace** and a **ventral plastron** joined in the middle region of the body (Fig. 385). Each part is composed of large plates of bone usually overlaid by equally large horny plates or scales; the patterns of the two sets of plates do not coincide. Vertebrae of trunk immovably fused to median (**neural**) plates of carapace (exceptions mentioned later); only cervical and caudal regions of vertebral column are movable. Ribs of trunk region immovably fused with corresponding paired plates (**costal**) of carapace (Fig. 385C). **Skull** massively and compactly built (Fig. 361); **quadrate** and related bones of upper jaw **immovably joined**; rami of lower jaw firmly united. **No teeth**; jaws heavily invested with horn which may be so formed as to provide crushing surfaces, cutting edges, or spines substituting for teeth. **No sternum**. Gastralia possibly represented by certain paired bones (hyoplastron and hypoplastron) of plastron (Fig. 385). **Legs well developed** and variously modified according to the wholly terrestrial, wholly aquatic, or amphibious habits of the species. **Tympanic apparatus** of ear well developed. Parietal organ not eye-like. Median **urinary bladder** present and, in some cases, also a pair

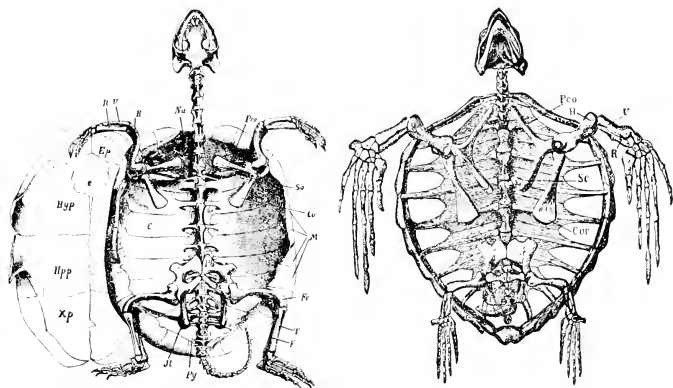
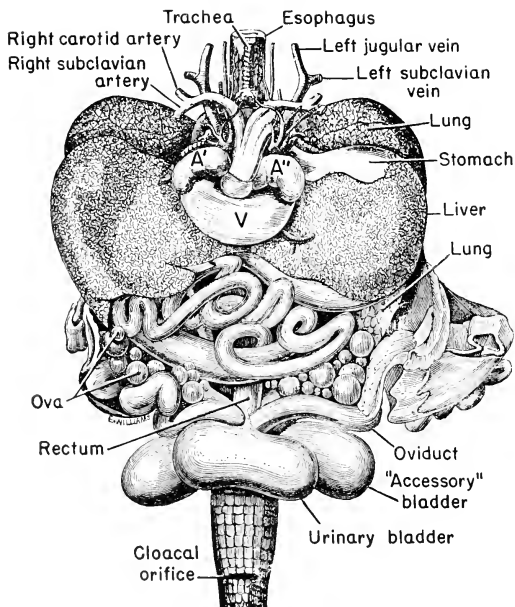


FIG. 385. Skeletons of turtle, *Cistudo* (left), and sea turtle, *Thalassochelys* (right). (C) Costal plate; (Co, Cor) coracoid; (e) entoplastron or episternum; (Ep) epiplastron; (F) fibula; (Fe) femur; (H) humerus; (Hyp) hyoplastron; (Hpp) hypoplastron; (Il) ilium; (Is) ischium; (M) marginal plates; (Nu) nuchal plate; (Pb) pubis; (Pco) process of scapula (procoracoid?); (Py) pygal plate; (R) radius; (Sc, So) scapula; (T) tibia; (U) ulna; (Xp) xiphoplastron. (Courtesy, Zittel: "Handbuch der Palaeontologie," Munich, R. Oldenbourg.)



VISCERA OF FEMALE TORTOISE  
(*Emys europaea*)

FIG. 386. Turtle viscera: ventral view. Most of the stomach is hidden by the left lobe of the liver. (Modified from Owen: "Comparative Anatomy and Physiology of Vertebrates," London, Longmans, Green & Co., Ltd.)

of lateral "accessory bladders" of uncertain function (Fig. 386). All chelonians are **oviparous**.

The most distinctive features of **Chelonia** are those which relate to the shell. It is composed mainly of dermal bone. The living epidermis is entirely external to the bony plates and produces the superficial horny plates. The trunk vertebrae, usually 10, have massive neural processes which expand dorsalward and contribute a considerable amount of bone to the overlying dermal **neural plates**, with which they are fused (Fig. 385). Similarly, each rib of the trunk expands into a broad, flat plate which fuses with, and merges indistinguishably into, the dermal bone of a **costal plate**. The **marginal** and other plates of the carapace and the plates (usually four pairs and one median) of the plastron are wholly dermal (Fig. 385). In the "soft-shelled tortoises" the horny layer does not form definite scales.

and the underlying dermal plates are incompletely ossified. In the marine "leatherback" turtle (*Dermochelys* or *Sphargis*) the carapace is not joined to the endoskeleton, the dermal plates of the shell are arranged in 12 longitudinal rows, and the horny layer is not formed into scales.

A most perplexing peculiarity of the chelonian is the relation of the pectoral girdle to the ribs. In other animals the girdle is external to the ribs. Thus the human "shoulder blade" (scapula) is the outermost skeletal part in the upper region of the back. The chelonian pectoral girdle is completely inside the ribs. The long scapula is movably attached dorsally to the inside of the carapace (Fig. 385).

Fusion of the carapace with the vertebrae of the trunk eliminates possibility of relative motion among those parts. In the absence of anything that can be moved, there is a corresponding absence of muscles. Therefore the muscles of the body are reduced to those which have to do with movement of the legs, neck, and tail.

Enclosure of the body within the shell and the immobility of the ribs make it impossible for the chelonian to breathe as other reptiles do. **Breathing** is accomplished partly by the amphibian method of "swallowing" air and partly by varying the external pressure on the lungs, which are a pair of very capacious and internally subdivided sacs lying in the anterior part of the pleuroperitoneal cavity (Fig. 387). The pressure is varied by alternately protruding and retracting the head and neck. In retraction the neck is strongly pushed back against the anterior body-wall in the space between carapace and plastron. The pressure on the lungs may be made to vary also by movements of the muscles of the legs. Animals of the notoriously sluggish habits of chelonians are probably not seriously inconvenienced if the breathing is somewhat desultory.

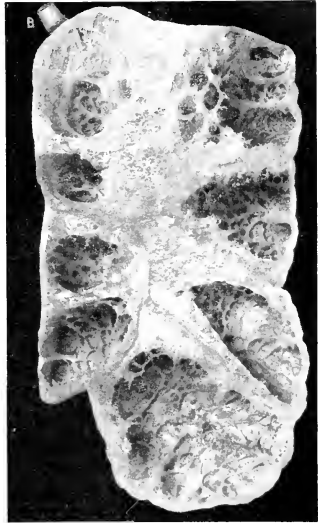


FIG. 387. Lung of a large turtle (species?). Length of lung about 7 inches. Photographed from a dried lung cut in a frontal plane.

The large chambers open freely into a central air-passage. Into them open smaller cavities whose walls are thickly beset with shallow alveoli which add to the respiratory surface. (B) Bronchus.

All chelonians, like all other oviparous reptiles, **deposit the eggs on land**. Sea turtles, whose legs are adapted for swimming and are ineffective for locomotion on land, come ashore and clumsily crawl to a level above high tide, where the eggs are laid in sand. These facts are highly significant. Amphibia, taking the Class as a whole, are vertebrates in which aquatic characteristics predominate—they are fishlike, "ichthyopsidan." Many of them in adult life possess such adaptations as make possible for them a terrestrial existence of a very limited sort. But (with rare exceptions) *they must return to water for reproduction*. Reptiles are primarily land animals. In a few of them digits have become webbed or pentadactyl legs have become modified into flippers, adapting the animal for moderately successful aquatic life. But (unless

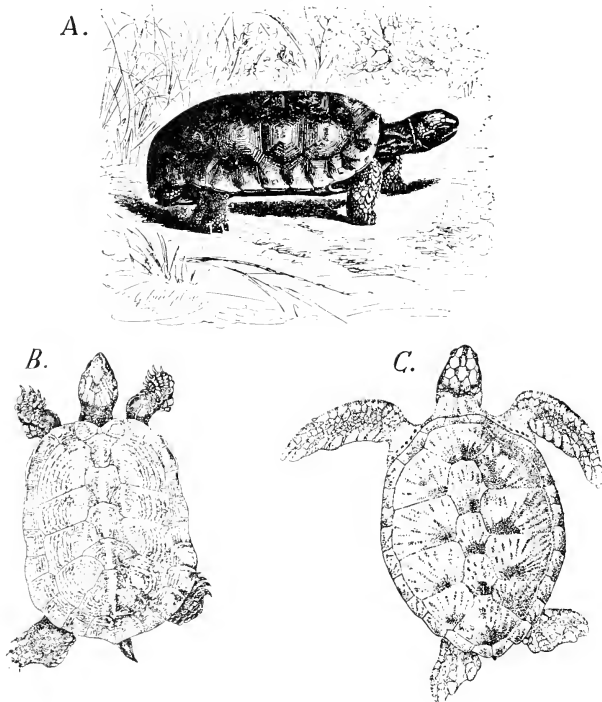


FIG. 388. (A) Tortoise. (B) Terrapin. (C) Turtle. (A, courtesy, Brehm: "Tierleben," Leipzig, Bibliographisches Institut. B, C, courtesy, Deraniyagala: "Tetrapod Reptiles of Ceylon," London, Dulau & Co., Ltd.)

viviparous) *they all deposit eggs on land*. It is evident that the reproductive mechanism and processes are highly "conservative." Adaptive changes in form of body and in the motor mechanism—muscles and skeleton—are made with comparative readiness, but in the reproductive methods there is a marked "lag."

In the use of the names "turtle," "tortoise," and "terrapin" there is much inconsistency (Fig. 388). The wholly terrestrial chelonians are generally, but not always, called "tortoises." Marine chelonians are "turtles," but commercial "tortoise shell" is derived from a marine turtle, the "hawksbill" (*Chelonia imbricata*). Numerous small chelonians, mostly of amphibious habits, are indiscriminately called "turtles" or "tortoises." "Terrapin" is applied to various amphibious or aquatic (fresh water or, rarely, brackish) chelonians which some persons esteem highly as food.

The Chelonia are widely distributed throughout the tropical and temperate zones. The largest living chelonians are found among the sea turtles, some of which weigh hundreds of pounds or even exceed a half-ton. The largest land chelonians are the "giant" tortoises of the Galápagos Islands.

#### EARLY REPTILES

Geologically, reptiles have been traced back to the early days of amphibians. The earliest definitely recognizable reptilian fossils are found in the Carboniferous Period, when amphibians had already become strongly established (see Table 3, p. 411). They show strong resemblances to the labyrinthodont amphibians, especially in the possession of an extensive system of superficial dermal bones in the head. In fact, some early fossils are difficult of diagnosis as being reptilian or amphibian. If, as the evidence indicates, reptiles were derived from primitive amphibians, in many of which most of the body was covered by heavy dermal bony plates, the occurrence of such structures as gastralia, the dermal bony scales of crocodilians, and the dermal plates of the chelonian shell is quite understandable.

The amphibians and reptiles were contemporary for long ages, in the course of which the reptiles perfected their adaptations for terrestrial life and thereby gained over the amphibians an advantage that carried the group to a position of dominance which could never have been achieved by amphibians as such. The **Mesozoic Age** is commonly called the "**Age of Reptiles**." The earlier reptiles were terrestrial and comparatively small, but some of the later types were aquatic, with pentadactyl legs transformed into externally finlike paddles. In others, the **pterosaurs**, a broad, thin fold of skin grew out from each side of the body, supported anteriorly by the pectoral limb and, for the most part, by the greatly elongated fourth digit of that limb, and extending back



FIG. 389. Pterosaurs. An artist's conception of a scene on a Jurassic coast. (Courtesy, American Museum of Natural History, New York.)




FIG. 390. *Tyrannosaurus* and *Triceratops*. (From a painting by C. R. Knight. Courtesy, American Museum of Natural History, New York.)

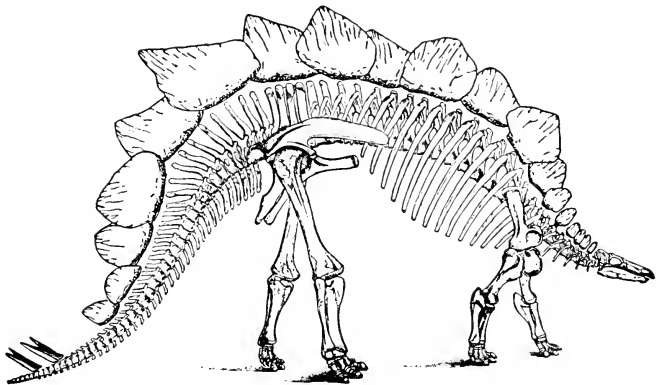


FIG. 391. *Stegosaurus*, a Jurassic armored dinosaur about 18 feet in length. (After Marsh and Gilmore. Courtesy, Romer: "Vertebrate Paleontology," Chicago, University of Chicago Press.)

along the body to the hindleg and tail (Fig. 389). This pair of integumentary membranes must have made possible not merely a gliding excursion through air but a positive flight and, judging by the mechanism, it was doubtless very effective flying. And so it came about that land, water, and air were dominated by reptiles. They existed in such diversity of forms as is indicated by the fact that their classification requires the making of 30 or more orders. Chief of the land types were the **dinosaurs** (Figs. 390, 391). Some were no larger than cats and dogs; others ranged up to monsters 100 feet long and weighing 50 tons. Some, with long, strong hindlegs and very short forelegs, must have been bipedal in habit. Some were herbivorous; many were carnivorous. In the water were the externally fishlike **ichthyosaurs** (Figs. 392, 393), some of them 30 feet long, and even longer **plesiosaurs** having a long, slender neck and a very small head quite out of proportion to the broad, heavy body (Fig. 392). There is some evidence that ichthyosaurs were viviparous; skeletons of small ones are sometimes found inside the skeleton of a large individual. In various parts of the world were aquatic lizards, **mosasaurs**, up to 40 feet long. Some of the best specimens of them have been found in Kansas, which was at the bottom of a Mesozoic sea. Many of these large aquatic reptiles were carnivorous. The heavy coat of armor worn by the numerous "ganoid" fishes of the time must have been useful. The batlike flying reptiles, **pterosaurs** or **ptero-dactyls**, were abundant in the later Mesozoic, some measuring 25 feet across the spread wings. The **Rhynchocephalia**, **Crocodylia**, and **Chelonia** were well established in the early Mesozoic. The **Sauria** (**Lacertilia**) appear somewhat later and the **Serpentes** (**Ophidia**) not until the latter part (Cretaceous) of the Mesozoic.

The **skulls** of ancient reptiles are of four types, as distinguished by differences in the structure of the posterior-lateral (temporal) region. In all cases there is a considerable space on each side between the lateral wall of the brain-case, including the auditory capsule, and



FIG. 392. Plesiosaurs and ichthyosaurs. (From a painting by C. R. Knight. Copyright, Chicago Natural History Museum.)



an outer plate consisting of dermal bones, mainly the **squamosal**, **jugal**, and **postorbital**. In its simplest form this plate is an uninterrupted arch extending from the lateral border of the parietal above, down to the series of bones forming the upper jaw. The space thus enclosed (**temporal cavity**) opens externally in front and behind. It is occupied by the bulky and powerful muscle which closes the mouth by pulling the lower jaw upward. In most reptiles, however, the temporal arch, or "arcade," is pierced by one or two large "windows" or **fenestrae**. These openings doubtless ease the working of the muscle by giving opportunity for bulging when it contracts. When there are two fenestrae in each arcade, one is dorsal to the other and they are separated by a bridge formed by extensions of the squamosal and postorbital bones (Fig. 394). In some reptiles there is only an upper temporal fenestra, the squamosal and postorbital meeting below it. In others there is only a lower fenestra, the squamosal and postorbital meeting above it. Skulls of the **anapsid** type, having **no temporal fenestrae**, are found in the most ancient reptiles (**cotylosaurs**) and in Chelonia (more or less modified in many of them). A skull having only the **upper fenestra** is called "**parapsid**." The skulls of lizards and ichthyosaurs have been described as being of the parapsid type, but much doubt exists as to the interpretation of the obscure structure of the temporal regions of these skulls. The **diapsid** skull, having **both upper and lower fenestrae**, is found in Rhynchocephalia (Fig. 373), dinosaurs, pterosaurs, and crocodilians. With considerable modification, it appears in birds. This type was most common in ancient reptiles. The **synapsid** skull, having only the **lower fenestra**, occurred in the mammal-like reptiles (**Theromorpha**, **Therapsida**) and is found, with some modification, in mammals.

Systematic groups of reptiles (**Anapsida**, etc.) have been defined on the basis of these differences in the number and position of temporal fenestrae. It is by no means certain, however, that these characteristics, by themselves, are a reliable index to phylogenetic relationships.

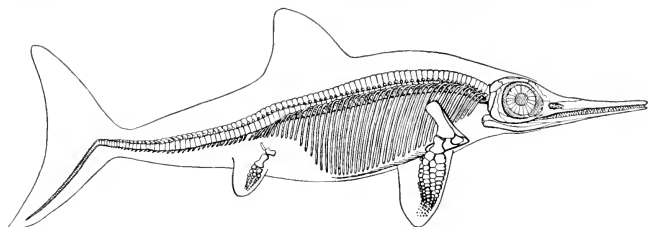


FIG. 393. A Jurassic ichthyosaur, much reduced. (After von Stromer. Courtesy, Romer: "Vertebrate Paleontology," Chicago, University of Chicago Press.)

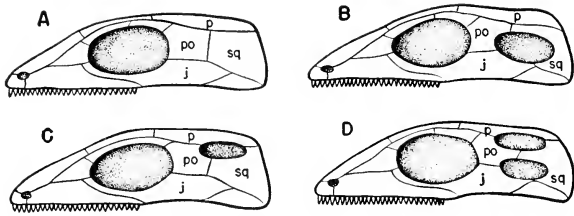


FIG. 391. Diagrams showing types of temporal openings in reptiles. (A) Anapsid. (B) Synapsid. (C) Parapsid. (D) Diapsid. (j) Jugal; (p) parietal; (po) postorbital; (sq) squamosal. (Courtesy, Romer: "The Vertebrate Body," Philadelphia, W. B. Saunders Co.)

During the Cretaceous Period the reptiles went into a decline so rapid—that is, in terms of geologic time—as to be fairly called cataclysmic. By the end of the period, the reptilian masters of the Mesozoic world had become entirely extinct. Nothing survived of the Class but the five Orders which have come down to the present. The causes of reptilian decline are obscure. Probably changes in configuration of lands and waters were accompanied by climatic changes which upset the biologic balance of vegetation and animal life. Reptiles of today are not only a small remnant of a once mighty group, but a dwindling remnant, for many of them seem fated for early extinction. Their greatest enemy is the human mammal with his liking for terrapin, turtle soup, and alligator leather, and his unreasonable antipathy toward harmless snakes and lizards.

The terms "lower" and "higher" are often applied to groups of vertebrates. The Classes are usually mentioned in this sequence: fishes, amphibians, reptiles, birds, mammals. The fishes and amphibians are often referred to as "lower vertebrates." The implication is that mammals are "highest." Without discussing the several possible meanings of "low" and "high" as used in biology, it will suffice for the present to say that they are commonly used to express *degree of anatomic specialization*. There are certain broad and general features which are common to all vertebrates, a "general body-plan" (Part I). Any one of these features is subject to adaptive modification or "specialization." This is carried to a much greater extent in some animals than in others. It will perhaps be not too great a feat of imagination to take a dogfish, an amphibian necturus, a reptilian tuatara and, for a mammal, even a cat (some other mammals would serve the purpose a little better except that they are less familiar), and, after reducing them all to the same size, cause them all to occupy the same space at the same time in such a way that their corresponding outlines and shapes, both external and internal, shall merge together and produce a composite or average of the several animals. This may be done, in imagination, without extremely violent distortion of any one of the subjects. But take, instead of a dogfish, a sea horse (Fig. 337) together with a toad, a snake or turtle, and an elephant. To imagine a blend or composite of this series is much more difficult because each of the animals has, in some respects and in very different ways, gone to extremes of anatomic specialization.

Whether a bird is more specialized than a snake, a whale, or an elephant is perhaps open to debate. Some birds are, in some ways, more specialized than others, but it is certainly true that *all* birds are very highly specialized. In each of the other Classes, except Cyclostomata, there are important groups which, relative to others in the Class, are

little specialized. The salamander is less so than a toad, the tuatara less so than a snake. But it is probably fair to say that birds, taking the Class as a whole, possess a higher average degree of specialization than any other vertebrate Class. If this be admitted, then birds—not mammals—are the “highest” vertebrates. Factors other than anatomic ones may justify placing mammals at the apex of the vertebrate series—and it must not be overlooked that there may be some class prejudice on the part of the classifier, who acknowledges himself to be not only a vertebrate but a mammal.

The various organs of an animal are dependent upon one another to such an extent that specialization of one organ is necessarily accompanied by appropriate modification of the organs related to it. In birds specialization for flight involves nearly every part of the animal. The immediate agency which keeps a bird aloft is impact of wings against air. The parts of the wing which directly encounter the air are feathers. Arrangement of the essential flight-feathers in a linear series calls for great modification of a pentadactyl pectoral limb. Walking, running, and the vigorous leap required in “taking off” for flight devolve upon the pelvic limbs, which are, accordingly, highly modified. The powerful muscles of wings and legs create extraordinary strains. These must be sustained by the skeleton of the trunk, which is in various ways so specialized as to give it great rigidity. Loss of flexibility in the trunk is attended by reduction and modification of muscles. The great output of energy in the excessively vigorous and long-sustained activities of flight demands a generous supply of oxygen. This is provided by lungs, whose efficiency is highly increased by an elaborate system of air reservoirs so connected as to give the lungs a “through draft.” In reptiles the aerated blood from the lungs, in passing through the heart, is contaminated by “impure” blood, but in birds the heart and arteries are arranged so that the highly oxygenated blood from the lungs passes undiluted into the general circulation. Sustained flight requires rapid liberation of energy, which necessitates rapid metabolism in the muscles. In general and within limits, metabolism is accelerated by rise of temperature. Heat is a by-product of metabolism, whose final phase is oxidation. Conservation of this heat, making the bird “warm-blooded,” facilitates the maintenance of a high metabolic rate. The most important factor in the conservation of heat is prevention of loss from the surface of the body. The plumage is a highly effective heat insulator.

It is to be noted that the series of successively related structures mentioned in the preceding paragraph begins with feathers as the immediate mechanical agency in flight and ends with feathers as conservators of energy, facilitating the rapid metabolism necessary for

flight. This illustrates well the extraordinary importance of the feather in the life of the bird, justifying our regarding the feather as the most significant and distinctive of the many avian anatomic peculiarities. It now remains to examine somewhat more fully these several related structures, and, in doing so, they will be considered in the serial order of the preceding paragraph.

### FEATHERS

The feather is the characteristic integumentary structure of a bird, but on the legs, below the feathers, are horny scales of reptilian type.

A feather is an elaboration of the epidermal stratum corneum. The fully developed feather is constituted entirely of quite lifeless horny epidermal tissue (excepting some dead vestiges of embryonic dermal material). A feather of the most complex type, such as a wing-feather or one of the larger feathers of the body, is deeply but very obliquely inserted in the skin. The inserted part is a hollow cylindrical **quill** (**calamus**), at whose proximal end is an aperture, the **umbilicus** (Fig. 395). There may be a second umbilicus at the distal region of the quill. The cavity of the quill contains a dry, spongy pith which is the dead remnant of living vascular dermal tissue present there while the feather is developing. External to the skin, the axis of the feather is the solid **shaft** (**rachis**), from whose opposite sides extend **barbs** arranged in bilateral symmetry with reference to the axis of the feather. Each barb bears bilaterally arranged **barbules**. The barbules on the distal side of one barb overlap the barbules on the proximal side of the

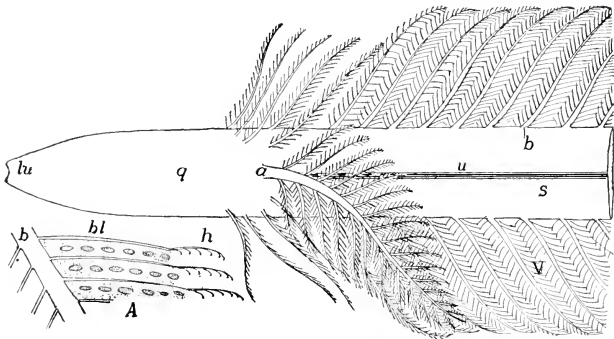


FIG. 395. Diagram of base of contour feather. (A) Portion of barb showing the barbules and hooks. (*a*) Aftershaft; (*b*) barbs; (*bl*) barbules; (*h*) hooks on ends of barbules; (*lu*) lower umbilicus; (*q*) quill; (*s*) shaft; (*u*) umbilicus; (*V*) vane. (Courtesy, Kingsley: "Comparative Anatomy of Vertebrates," Philadelphia, The Blakiston Company.)

adjacent barb. Each distal barbule (Fig. 396) has, along its deeper edge, a series of minute sharply curved hooks. The outer ("outer" and "deeper" in relation to the surface of the body) edge of a proximal barbule is sharply curled over. Each hook on a distal barbule is firmly caught underneath the curling flange of one of the several proximal barbules which are overlapped by the distal barbule. Thus the successive sets of barbules are so firmly tied together that the whole system of barbs and barbules is converted into a fairly rigid web or **vane (vexillum)** capable of offering effective resistance to the air at the down-

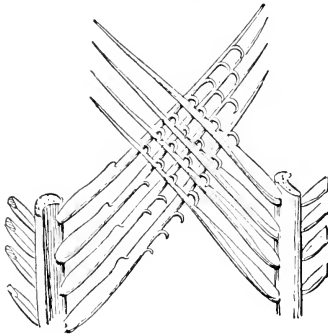


FIG. 396. Two enlarged barbs of a feather, showing the interlocking barbules. (Courtesy, Knowlton and Ridgway: "Birds of the World," New York, Henry Holt & Co., Inc.)

stroke of the wing. In the absence of this interlocking arrangement of barbules, the feather is of a loose or fluffy texture, as is conspicuously seen in ostrich plumes. Quite commonly an **aftershaft**, consisting of a smaller secondary rachis equipped with barbs and barbules, projects from the proximal end of the main rachis (Fig. 395). In the ostrich-like birds, the emu (*Dromiceius*) and the cassowary (*Casuaris*), the aftershaft is as large as the main feather so that, in effect, two equal feathers spring from one quill.

The **quill** is inserted into an appropriately deep pocket, the **follicle**, extending obliquely into the skin (Fig. 397). Around the feather the epidermis turns inward to form the wall of the follicle and, at the bottom of the follicle, is continuous with the proximal end of the quill, which is of epidermal origin. At least in the case of the larger feathers, delicate strands of muscle-fibers connected with the deeper region of the follicle extend obliquely upward through the dermis. By contractions of the muscle on a particular side of the follicle, the slope of the

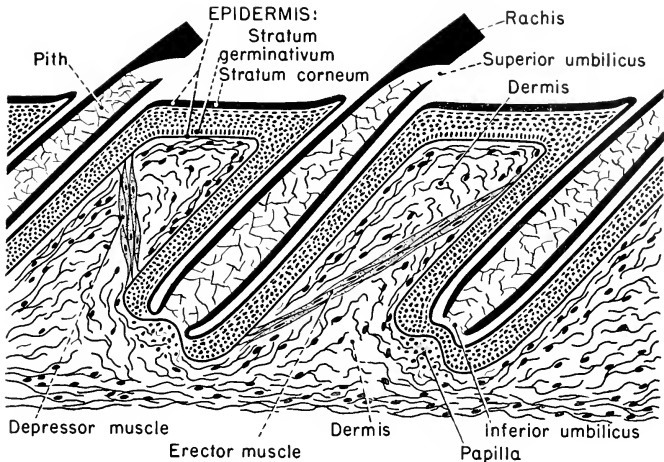


FIG. 397. Feather follicles: diagrammatic section perpendicular to surface of skin.

feather in relation to the surface of the body may be changed. By use of this mechanism, the bird is able to erect ("fluff up") the plumage when sleeping or in response to cold.

Feathers exist in great variety of form. The larger feathers which are effective in giving the characteristic form to the body of the bird are called "**contour feathers**" (or **plumes**). These are usually of the complex structure which has just been described. Much simpler are **down-feathers** (**plumules**), which are comparatively small and consist of a tuft of filaments (barbs) springing from the distal end of the small quill, but without a rachis (Fig. 399C). Barbules, if present, are not interlocked. Most simple are "**hair-feathers**" (**filoplumes**), consisting of a hairlike rachis without barbs, or having merely a small vestige of a vane at the tip of the shaft. Feathers intermediate between one and another of these three types exist in great variety. "**Powder down-feathers**" are plumules which lie beneath the contour feathers on the ventral surface of the body of some birds, especially carnivorous birds. They have the curious property of disintegrating to form a fine, soft, powdery substance like a layer of "talcum powder" covering the skin and perhaps serving to protect the ventral skin from becoming soiled by contact with the not always immaculate interior of the nest.

The feathers which are first developed on the young bird are plumules ("**nestling down-feathers**"). These are succeeded by contour feathers which, however, are usually restricted to certain well-

defined areas, **pterylae**, of the body. The intervening areas, **apteria**, are bare, or occupied only by sparsely distributed feathers of the smaller varieties (Fig. 398). However, the length and slope of the contour feathers are such that the bird is externally completely covered by them. The feather pattern, or **pterylosis**, is characteristic for a species. In some birds (penguins, screamers, toucans, and ostriches), pterylae are not distinguishable, the contour feathers being uniformly distributed over the body, or the apteria are, at most, restricted to very small areas or merely temporarily evident in the very young bird (ostriches).

The **color** of feathers is due partly to pigments and partly to physical action of the horny substance. There are commonly yellow, orange, red, black, and, rarely, green pigments; the bright blue and purple, and usually green, and the iridescence of some feathers, are spectral effects resulting from the disruption of white light as it encounters surfaces of the more or less transparent horny substance—"structural colors." White results from absence of pigment.

Feathers, like most horny structures, are not permanent organs. While in birds there is no periodic shedding of the stratum corneum, there is usually a seasonal **molting** during which extensive loss of feathers occurs. The attachment of the quill of the old feather at the

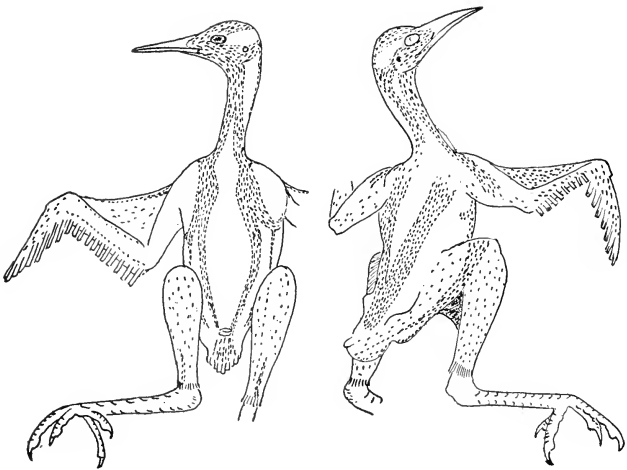


FIG. 398. Feather tracts of a cuckoo, *Geococcyx californianus*. (After Shufeldt. Courtesy, Kingsley: "Comparative Anatomy of Vertebrates," Philadelphia, The Blakiston Company.)



base of the follicle loosens, and the feather comes out. A new feather is developed in the old follicle.

The **development** of a feather is initiated by formation of a papilla involving both dermis and epidermis (Fig. 399A). The papilla elongates and at the same time sinks bodily into the dermis, carrying the surrounding epidermis along with it, and thus forming the follicle (Fig. 399B, C). The dermal core of the papilla is richly vascular, its blood providing nourishment for the developing feather. Then the epidermis of the protruding region of the papilla becomes arranged according to the pattern of the prospective feather. In the case of a **down-feather**, it splits into numerous longitudinal divisions, each of which becomes shaped into a slender rod (Fig. 100). The outermost layer of epidermal cells remains undifferentiated, forming a sheath (**periderm**) enclosing the developing feather. The epidermal rods eventually cornify (i.e., become transformed into horny substance) and, rupturing the sheath, emerge and separate to become the tuft of barbs of the down-feather. The dermal core of this portion of the young feather dies, dries, and is cast off with the ruptured sheath. The epidermal wall of the proximal portion of the feather cornifies to become the quill, whose dermal core is gradually reduced to a dead, dry, spongy pith.

A follicle of a nestling down-feather may later give rise to one of the larger **contour feathers**. The follicle deepens and enlarges and a new and larger papilla consisting, like the first, of epidermis with a dermal core grows out from its bottom. The development of the contour feather is necessarily a more complex process than that of a down-feather, but it follows the same principle. The epidermal tissue of the papilla becomes arranged so as to map out the pattern of the feather (Fig. 399D). Rachis, barbs, and barbules take shape in the living tissue but are confined within a delicate epidermal sheath. The differentiation begins at the apex of the papilla and extends toward the base. At a late stage, it is as if a finished feather had been carefully rolled up and wrapped in cellophane. Even the development of the minute hooks and the interlocking of barbules is all perfected while the vane is tightly rolled up within the sheath. The tip of the feather matures first, ruptures the sheath, emerges, and unrolls. The remainder of the feather is gradually pushed out as the completion of differentiation progresses proximally. At any given level of the feather, cornification does not begin until the structures in that region are well formed, and is not completed until they have attained definitive size, proportions, and pigmentation. Completely cornified tissue is no longer alive.

The essential **feathers concerned in flight** are long and stiff, and the broad, smooth vane is so compactly built that air does not leak

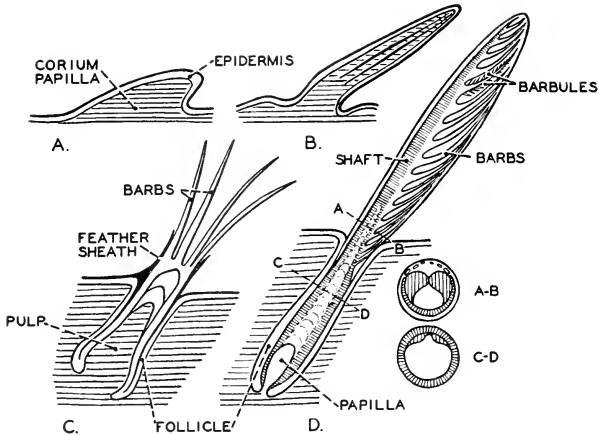


FIG. 399. Four stages in the development of a feather. (A, B, C) Stages in the development of a down-feather. (D) A contour feather in the feather-sheath. (A-B) and (C-D) are sections of a young contour feather at the levels indicated in (D). (Redrawn from Ihle, after Bütschli. Courtesy, Neal and Rand: "Chordate Anatomy," Philadelphia, The Blakiston Company.)

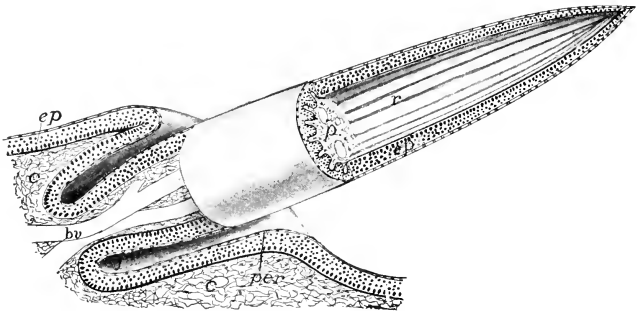


FIG. 100. Stereogram of a developing down-feather. (*br*) Blood-vessels entering pulp; (*c*) dermis (corium); (*ep*) epidermis; (*f*) feather follicle; (*p*) pulp (mesenchyme) of developing feather; (*per*) periderm; (*r*) rods of epidermis, which later dry, separate, and form the down. (Courtesy, Kingsley: "Comparative Anatomy of Vertebrates," Philadelphia, The Blakiston Company.)

through it during the downstroke of the wing. These flight-feathers, called "**remiges**" (singular, "**remex**") are arranged in a single row with their large quills strongly and deeply inserted into the skin of those parts of the wing which correspond to the forearm and hand of man (Fig. 398). Those attached to the three-fingered hand are called **primaries**, and those between wrist and elbow are **secondaries**. The number of each is constant in a given species of bird. Similar feathers called **rectrices** (singular, **rectrix**), symmetrically arranged in pairs (commonly six or seven pairs) at the tail-end of the bird, are used for steering.

Feathers are the most complex and highly specialized of all the structures produced by the skin of vertebrates.

Avian skin is devoid of glands except for the oil-secreting **uro-pygial gland** situated on the dorsal surface of the short tail (**uro-pygium**). By means of the beak, the bird distributes the waterproofing oil over the plumage. The gland is absent in ostriches, parrots, and some other birds, and is especially well developed in aquatic birds. In lack of glands, avian and reptilian skins are similar. Distal to the feathered regions of the legs, the skin produces horny scales of reptilian type.

#### SKELETON

The function of the bird's **hand** is to support the remiges. Since these are arranged in a single longitudinal row, a pentadactyl hand would supply a superfluity of parts. In the hand of a bird there are three digits (Fig. 401), of which only the middle one is well developed, the other two being weak vestiges. The three probably correspond to the thumb and first two fingers of the human hand. The three metacarpals are more or less fused together and the more distal carpals are fused to the **proximal** end of the fused metacarpals, the result being a complex **carpo-metacarpus** (Fig. 401, *Mc*). Two proximal carpals (*C*, *C'*) remain free. These several modifications of the typical limb serve to provide a simple and strong axis for support of a row of remiges.

**The pectoral girdle** (Fig. 401) consists of the usual dorsal **scapula** and ventral **coracoid** and **clavicle**, but the ventral ends of the right and left clavicles are solidly fused to form the characteristic **furcula** ("wishbone"), which is more or less strongly attached to the sternum. The coracoid also is attached to the sternum, so that the girdle is well anchored.

In "taking off" for flight, the bird leaps vigorously into the air. The **legs** are strongly developed. Somewhat as in frogs and toads, the leg is made more effective for leaping by modifications which give it four long movable segments (Fig. 402) instead of the three of ordinary

quadrupeds. The **tibia** is thick and strong, but the **fibula** is reduced to a splint which is largely fused with the tibia. The proximal **tarsals** (Fig. 402B) become solidly fused to one another and to the distal end of the tibia, thus forming a **tibio-tarsus** (Fig. 402A). The **meta-tarsals** are much elongated and, except the very small first, are fused

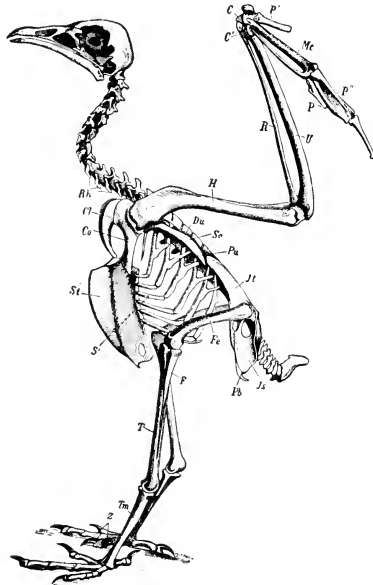


FIG. 101. Bird skeleton. (*C, C'*) Carpals; (*Cl*) clavicle; (*Co*) coracoid; (*F*) fibula; (*Fe*) femur; (*H*) humerus; (*Jl*) ilium; (*Js*) ischium; (*Mc*) metacarpals (carpo-metacarpus); (*P', P'', P'''*) phalanges of digits 1-3; (*Pb*) pubis; (*Pu*) uncinat process of rib; (*R*) radius; (*Rh*) cervical ribs; (*S'*) sternal rib; (*Sc*) scapula; (*St*) sternum; (*T*) tibia; (*Tm*) tarso-metatarsus; (*U*) ulna; (*Z*) Phalanges of toes. (Courtesy, Zittel: "Handbuch der Palaeontologie," Munich, R. Oldenbourg.)

together. To the proximal end of the resulting bone the distal tarsals are solidly fused, thus forming a complex bone, the **tarso-metatarsus**. Therefore, in addition to the usual thigh and shank, there is a moderately long tarso-metatarsal segment, and the set of long toes makes a fourth segment. The joint between tibio-tarsus and tarso-metatarsus evidently does not correspond to the usual tetrapod ankle-joint, which is between tibia (and fibula) and the tarsal region. In many reptiles

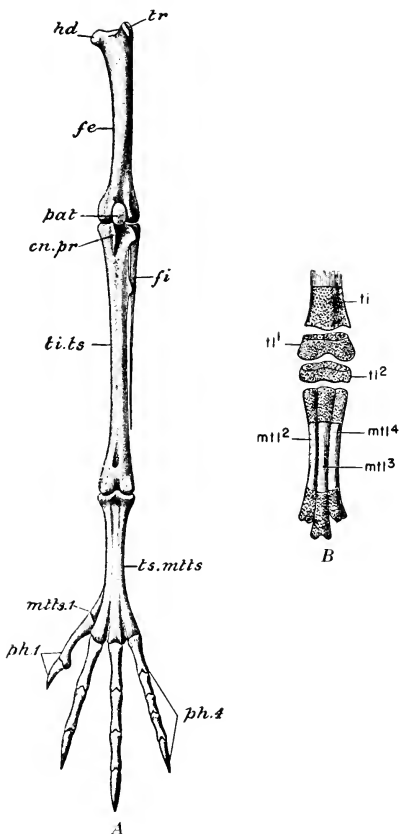


FIG. 402. *Columba livia*. (A) Bones of the left hindlimb. (*cn. pr*) Cnemial process; (*fe*) femur; (*fi*) fibula; (*hd*) head of femur; (*mtts. 1*) first metatarsal; (*pat*) patella; (*ph. 1*) phalanges of the first digit; (*ph. 4*) phalanges of fourth digit; (*ti. ts*) tibiotarsus; (*tr*) trochanter; (*ts. mtts*) tarso-metatarsus. (From Parker and Haswell: "Text-book of Zoology." By permission of The Macmillan Company, Publishers.)

(B) Left tarso-metatarsus of an unbatched embryo, with the distal end of the tibia; dorsal view. ( $\times 5$ ). The tarsal cartilages ( $tl^1$ ,  $tl^2$ ) are represented as separated from the tibia and metatarsus respectively. The cartilaginous parts are dotted. ( $mtl^2$ ,  $mtl^3$ ,  $mtl^4$ ) Second, third, and fourth metatarsals; (*ti*) tibia; ( $tl^1$ ) proximal tarsal cartilage, afterward fusing with tibia; ( $tl^2$ ) distal tarsal cartilage, afterward fusing with metatarsus. (From Parker: "A Course of Instruction in Zootomy." By permission of The Macmillan Company, publishers.)

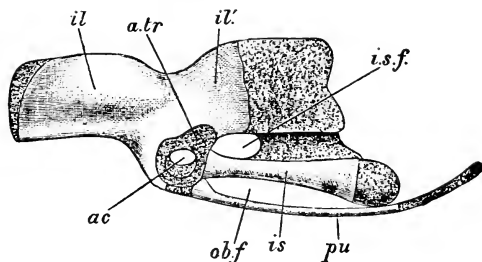


FIG. 403. *Columba livia*. Left os innominatum (pelvic girdle) of a nestling (14 days); external side view. The cartilage is distinguished by dotting. (ac) Acetabulum; (a.tr) antitrochanter; (il, il') pre- and postacetabular portions of ilium; (is) ischium; (i.s.f.) iliosciatic foramen; (ob.f) obturator fissure; (pu) pubis. ( $\times 2$ ) (From Parker: "A Course of Instruction in Zootomy." By permission of The Macmillan Company, publishers.)

the ankle-joint is midtarsal, as it is in birds. There are usually four toes, of which the first (**hallux**) commonly projects backward (Fig. 401) and is opposable to the other three, an arrangement which gives the bird a firm grasp on a branch of tree.

The great strains produced by the muscles which operate the wings and legs must be supported by the skeleton of the trunk (Fig. 401). All parts of it show profound modifications which combine to give it much rigidity. Conspicuous among these modifications are those of the tremendously expanded **pelvic girdle**. Viewed as a whole (Figs. 401, 403), it appears as a system of broad, thin, bony plates, firmly joined and curved to fit the external contour of the dorsolateral region of the body. The **ilium** is elongated to such an extent that it overlaps a long region of the vertebral column. The upper edge of the expanded **ischium** fuses with the posterior part of the ilium. The long narrow **pubis**, which in most tetrapods points forward and does so in the bird embryo, rotates so as to point backward and lie alongside the ventral edge of the ischium, with which, in some cases, it is partially fused. Whereas in most tetrapods the corresponding right and left ventral bones (ischia and pubes) meet and are joined at the midventral line, in modern birds, except the ostrich (*Struthio*), this junction (**symphysis**) does not occur. The opposite ventral bones are usually spread far apart, leaving the ventral abdominal wall unconfined by bone—an adaptation to the relatively enormous size of the egg which the bird lays.

The only region of the **vertebral column** which retains complete freedom of movement is the cervical. The number of **cervical verte-**

**brae** varies with the length of the neck—in the common pigeon, 11, including atlas and axis; in the swan, 25; in some birds, only 9. The extreme flexibility of the bird's neck is due to a peculiar type of joint. Usually the posterior surface of a bird's centrum is saddle-shaped (Fig. 404), being concave in the sagittal plane and convex in the frontal plane. The anterior surface of the centrum next behind is shaped to fit this saddle-like surface. Such centra are called **heterocoelous**. The cervical vertebrae, except atlas and axis, bear short ribs, most of which are fused to the vertebrae (Figs. 401, 404).

In all of the **postcervical** regions of the bird's vertebral column, there is more or less extensive loss of mobility, resulting from fusion of successive vertebrae. The corresponding regions of different birds show much variation as to the number of vertebrae and the extent and nature of the fusion. Between the last cervical and the beginning of the sacral region, there are commonly 4 or 5 vertebrae, but in some birds fewer or several more, most of them usually immovably fused together.

The **sacral region** (Fig. 401) includes a varying, but always large, number of vertebrae; in the domestic fowl (*Gallus*), 14 or 15; in many birds, more—15 to 23. In the embryonic development of the vertebral column, the first connection with the pelvic girdle is usually made by 2 vertebrae whose short ribs become joined to the ilia. Somewhat later, additional vertebrae, some anterior and some posterior to the primary two, become connected with the girdle. This fact, together with the numerical relations between corresponding regions of the columns of reptiles and birds, indicates that the **primary 2 sacral vertebrae** of the bird correspond to the usual 2 sacral vertebrae of reptiles, and therefore the remaining sacral vertebrae of the bird correspond to vertebrae of the posterior trunk (lumbar) region and anterior caudal (postsacral) region of reptiles. Applying this interpretation to the sacrum of the pigeon, it consists of the hindmost thoracic vertebra, 6 lumbar vertebrae, the 2 primary sacrals, and the first 5 caudal vertebrae, a total of 14. The term **synsacrum**, applied to the avian sacrum, expresses the idea that it has appropriated to itself regions of the column anterior and posterior to a "primary" sacrum. The **tail** of modern birds is a mere stump serving for insertion of the long

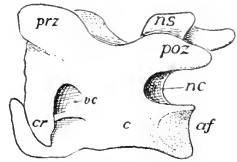


FIG. 401. Cervical vertebra of a bird, showing the saddle-shaped articular surface (*af*) on the centrum (*c*); (*cr*) cervical rib; (*nc*) neural canal; (*ns*) neural spine; (*poz*, *prz*) post- and prezygapophyses; (*rc*) vertebral arterial canal. (Courtesy, Kingsley: "Comparative Anatomy of Vertebrates," Philadelphia, The Blakiston Company.)

rectrices. Its skeleton consists of several freely movable vertebrae followed by a more or less elongated and pointed bone, the **pygostyle** (Fig. 401), formed by fusion of several embryonic vertebrae. In the pigeon, there are 6 movable caudal vertebrae, and the pygostyle consists of 4 or more vertebrae. But to these 10 or more vertebrae which are literally postsacral for the pigeon may be added the 5 reptilian caudals (postsacral for the reptile) which have become incorporated into the pigeon's synsacrum.

The **skull** of the bird (Figs. 401, 405), as regards the number and general arrangement of its constituent bones, is very similar to that of a reptile. The following several factors, however, combine to give it a highly characteristic form. Relative to the size of the body, the bird's brain is somewhat larger than that of the reptile, but of very different form, being shorter and thicker (Fig. 416). The eyes are extraordinarily large, but the nasal organs are not especially well developed. The jaws are narrow and taper forward into the pointed beak. Therefore the skull, viewed dorsally, has a roughly triangular outline (Fig. 405B). The much-enlarged posterior cranial region contains the short, compact

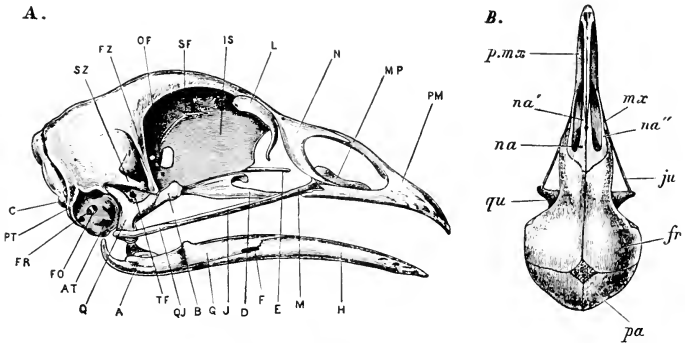


FIG. 405. (A) Skull of *Gallus domesticus*. (A) articular; (AT) recess leading into Eustachian tube; (B) pterygoid; (C) occipital condyle; (D) palatine; (E) rostrum; (F) mandibular foramen; (FO) fenestra ovalis; (FR) fenestra rotunda; (FZ) zygomatic process of frontal; (G) supra-angular; (H) dentary; (IS) interorbital septum; (J) jugal; (L) lacrimal; (M) maxillary; (MP) maxillo-palatine process; (N) nasal; (OF) optic foramen; (PM) premaxillary; (PT) posterior tympanic recess; (Q) quadrate; (QJ) quadratojugal; (SF) olfactory foramen; (SZ) zygomatic process of squamosal; (TF) foramen for trigeminal nerve. (Courtesy, Marshall and Hurst: "Practical Zoology," London, John Murray & Co.)

(B) *Columba livia*. Skull of a young bird (about six weeks old); dorsal view. (fr) Frontal; (ju) jugal; (mx) maxillary; (na, na', na'') nasal; (pa) parietal; (p.mx) premaxillary; (qu) quadrate. (From Parker: "A Course of Instruction in Zootomy." By permission of The Macmillan Company, publishers.)



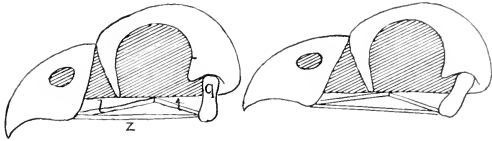


FIG. 406. Diagram illustrating the movement of the upper jaw of birds. (*l*) Palatine; (*q*) quadrate; (*t*) pterygoid; (*z*) zygomatic arcade. (After Boas. Courtesy, Kingsley: "Comparative Anatomy of Vertebrates," Philadelphia, The Blakiston Company.)

brain. Immediately in front of the brain-case, the enormous orbits (the right and left concavities which contain the eyeballs) occupy nearly the entire width of this narrower region, being separated only by a thin median vertical plate of bone (or partly cartilage), the **interorbital septum** (Fig. 405A). This is in striking contrast to the relations of the corresponding parts in amphibians and early reptiles, in which the comparatively small orbits are far apart and the longer, narrower brain extends forward between the eyes. The form of skull in this case is called **platybasic**—a type found in elasmobranchs, some ganoids, lungfishes, amphibians, and early reptiles. In modern reptiles the orbits, more or less enlarged, approach one another and in many cases, most notably lizards, are separated only by a thin interorbital septum as in birds—a type of skull called **tropibasic**. In birds the tropibasic form is carried to its extreme. It is as if the eyes, enlarging in a narrowing region of the skull, had crowded the brain backward, forcing it to atone for shortness by adding width and height.

The **quadrate bone** in birds is movably joined to the otic region, as in Squamata (Figs. 405, 406). Also, the other bones of the upper jaw are capable of more or less movement relative to the cranium, somewhat as in snakes—a condition most marked in parrots which can swing the upper beak up and down through a large angle.

A most striking feature of the skull is the extensive **fusion** of the bones in the adult. In most cases the sutures become nearly or quite obliterated, so that recognition of the bony elements which make up the skull is possible only during the period of growth while the sutures are still open. The bony tissue of the skull, too, is very highly calcified and therefore especially hard. And most of the bones are exceedingly thin. These peculiarities combine to produce a skull of maximum strength with minimum weight. A further saving in the weight of the head results from **absence of teeth**. The earlier birds known from fossils had teeth, but no modern adult bird has teeth. In the jaws of the embryo appear temporary configurations of cells which resemble early stages in development of teeth. The bird's jaws are ensheathed

in a thick layer of horn, as in *Chelonia*, forming the **beak**, or **bill**, which is usually sharp-pointed and provided with cutting edges so that it in part serves the function of teeth.

The **ribs** and **sternum** (Fig. 401) enclose the thoracic region of the trunk. The thoracic ribs, commonly five pairs, but only three pairs in *Rhea* ("South American ostrich") and nine in the swan, articulate with their corresponding vertebrae and connect ventrally with the sternum. Each rib is divided into a dorsal **vertebral part** and a ventral **sternal part**, movably jointed together. In most birds each vertebral part, except the hindmost, bears a strong **uncinate process** which projects backward to overlap the next rib, to which it is tied by fibrous tissue. Both vertebral and sternal parts of the rib consist of fully ossified and very hard bone, in contrast to the fact that in most animals other than birds the sternal segments of ribs are cartilaginous.

The **sternum** is greatly expanded (Fig. 401). It is a broad, thin, undivided plate of bone curving laterally upward to fit the contour of the breast region of the bird. It provides extensive bony enclosure for the anterior ventrolateral part of the trunk in much the same way that the expanded pelvic girdle serves for the posterior dorsolateral region. Along the median ventral line of the sternum, a thin blade of bone projects outward in the median plane. The entire sternum, with this blade extending lengthwise of the externally convex surface of it, strongly resembles the under side of a round-bottomed boat with a keel (Latin *carina*). The **carina** is prominently developed in all strong fliers. In the ostrich and similar "running birds" and in various birds which are poor fliers or incapable of flight (e.g., certain ground-living rails of New Zealand, and the recently extinct dodo and solitaire of islands near Madagascar), the carina is more or less reduced or entirely lacking. There are aquatic birds which fly poorly (some members of the auk family) or not at all (penguins and the recently extinct "great auk"), but make very effective use of their short wings in swimming. In these birds the carina is strongly developed. Our common domestic fowl, however, in the course of its brief (in terms of geologic time) period of existence under conditions of domestication, has become a very feeble and reluctant flier, but it still retains a well-developed carina. It is a noteworthy fact that the sternum of reptilian pterosaurs and mammalian bats is provided with a carina.

#### MUSCLES

The massive muscles which operate the wings occupy the angular recess, on either side, between the carina and the main body of the sternum. Most of this space is filled by the enormous **pectoralis**

muscle whose tendon passes upward and attaches to the ventral surface of the humerus, effecting the downstroke of the wing. Removal of the pectoralis by dissection exposes to view a comparatively small and thin muscle (**subclavius** or **pectoralis minor**) whose tendon goes to the shoulder joint and, there passing through a smoothly lined aperture (**foramen triosseum**), makes a turn of about 180 degrees and attaches to the *dorsal* surface of the humerus. Mechanically, the arrangement is equivalent to a pulley. When the subclavius contracts, the direct downward pull is transformed by the curving tendon into an upward pull on the wing. This is an extraordinary feature of the bird. In other vertebrates the pectoral limb is raised by direct upward pull of muscles which are situated on the animal's back.

Aside from the muscles of the wing and leg, the bird has no heavy muscles. Movements of the neck are effected by a complex system of small muscles attached to the cervical vertebrae. In the trunk, loss of mobility as a result of fusion of vertebrae is attended by great reduction in the dorsal muscles. The more prominent muscles which remain in the trunk are those concerned with the breathing movements of the thoracic wall and the usual thin muscular layers of the abdominal wall.

#### RESPIRATORY SYSTEM

Birds, of all vertebrates, possess the most complex and most highly efficient respiratory system, and it is unique in its mechanism and mode of operation. Its efficiency is due to the following factors: the lungs, although not of large volume relative to the body, are minutely subdivided internally so that the respiratory surface is enormously increased; the ultimate subdivisions are so arranged that there are no "dead ends" in which the air cannot be wholly changed; capacious air sacs annexed to the lungs provide for complete change of air throughout the lungs at both inhalation and exhalation.

The **trachea** divides, at the base of the neck, into a **right** and a **left bronchus**. Each bronchus enters the anterior end of its lung and passes back through the central region of it (**mesobronchus**), giving off several large branches, the **secondary bronchi** (Fig. 407). These are connected with one another by numerous tubes (**parabronchi**) which are smaller and of uniform diameter (Fig. 408). Adjacent parabronchi are connected by very minute tubes, **air-capillaries**. The interstices among the air-capillaries are occupied by a close network of blood-capillaries. Thus blood and air are brought very close together. The bird's lung, as seen in dissection, is bright red because of the abundance of blood in it, and its tissue has a minutely spongy texture.

Of the numerous **air-sacs** connected with the lungs, there are five pairs which are fairly constant in position and occurrence (Figs. 409,

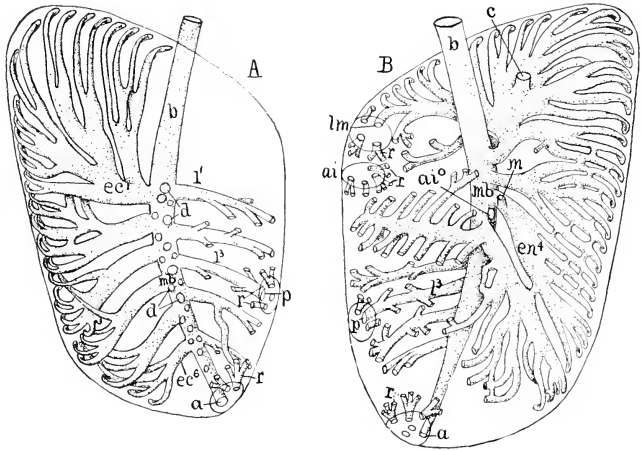


FIG. 107. Diagrams of (A) dorsal and (B) ventral aspects of lung of hen. (*a*) Point of connection of mesobronchus with abdominal air-sac; (*ai*) region of recurrent bronchi from anterior intermediate sac; (*ai'*) connection of anterior intermediate sac with bronchus; (*b*) bronchus; (*c*) attachment of cervical sac; (*d*) roots of dorsibronchi; (*e*) ectobronchi; (*en*) endobronchi; (*l*) laterobronchi; (*lm*, *m*) connections of lateral and mesial moieties of interclavicular sac; (*mb*) mesobronchus; (*p*) connection of posterior intermediate sac; (*r*) retrobronchi (recurrent) from air-sacs. (After Loey and Larsell. Courtesy, Kingsley: "Comparative Anatomy of Vertebrates," Philadelphia, The Blakiston Company.)

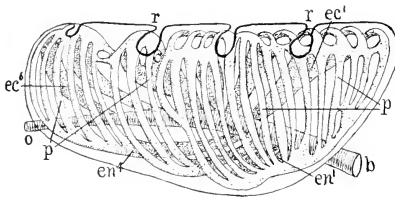


FIG. 108. Diagrammatic side view of bird lung, showing the parabronchi connecting ecto- and endobronchi. (*b*) Bronchus; (*ec*) ectobronchi; (*en*) endobronchi (*o*) abdominal orifice, point of connection with abdominal air-sac; (*p*) parabronchi; (*r*) impressions of ribs. (After Loey and Larsell. Courtesy, Kingsley: "Comparative Anatomy of Vertebrates," Philadelphia, The Blakiston Company.)

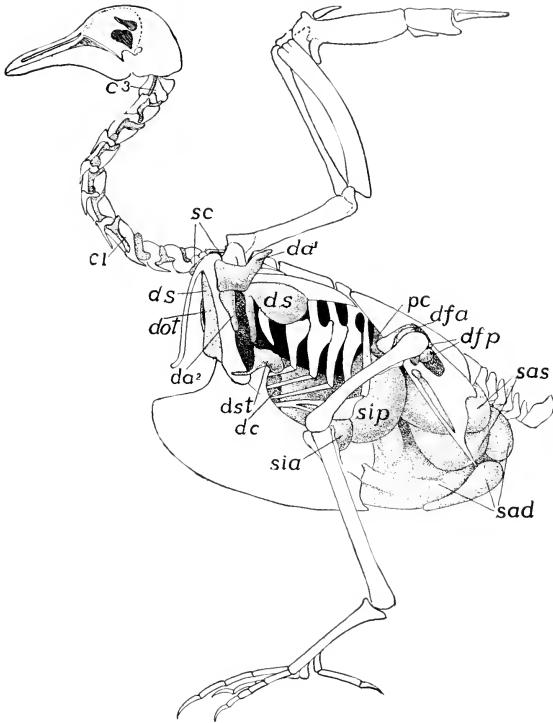


FIG. 409. Air-sacs and canals of pigeon. ( $c1, c^3$ ) Intertransverse canals; ( $da^1$ – $da^2$ ) axillary sac and its ventral diverticulum; ( $dc$ ) canal for ribs; ( $dfa, dfp$ ) anterior and posterior femoral ducts; ( $dot$ ) infraclavicular canal; ( $ds$ ) subscapular sac; ( $dst$ ) sternal canal; ( $pc$ ) preacetabular canal; ( $sad, sas$ ) right and left abdominal sacs; ( $sc$ ) cervical sac; ( $sia, sip$ ) anterior and posterior intermediate sacs. (After Müller. Courtesy, Kingsley: "Comparative Anatomy of Vertebrates," Philadelphia, The Blakiston Company.)

110): **cervical**, lying on either side of the base of the neck (but single and median in the common chicken); **interclavicular**, commonly fused into a single median sac, in front of the sternum and between the two prongs (clavicles) of the furcula; **anterior thoracic** and **posterior thoracic**, situated as the names indicate, and ventral to the lungs; **abdominal**, the largest of all, lying dorsally in the abdominal cavity. Each cervical sac usually connects with a smaller **axillary** sac lying just beneath the skin under the base of the wing. All of the sacs are

outgrowths from the lungs. From each lung a single secondary bronchus passes directly into each of four of the major adjacent sacs, the cervical, interclavicular, anterior and posterior thoracic; but it is the mesobronchus which, passing to the posterior end of the lung, emerges to connect with the great abdominal sac. In addition to the one large air-tube entering the sac from the lung, each of the sacs except the cervicals is connected with the adjacent region of the lung by several comparatively small tubes, **recurrent bronchi** (Figs. 407, 410) which open into the smaller bronchial tubes within the lungs.

**Smaller air-sacs**, their number and distribution varying greatly in different species, extend throughout the body of the bird. They may occur among the viscera, beneath the skin, between muscles, and even inside bones. The **pneumaticity of the skeleton** is a most extraordinary feature of birds. In most birds the bones are, to greater or less extent, occupied by air-filled spaces. In other animals the long bones of the legs contain central cavities filled by a soft marrow. In birds the central cavities of the long bones of leg and wing are usually filled with air. Bones as remote from the lungs as the metatarsals may be pneumatic. If the humerus of the wing of a dead pigeon is cut across, a fluid (such as latex or hot melted wax) may be injected into the central cavity of the bone and caused to flow into the interclavicular sac and thence into the lungs, trachea, and at least the larger air-sacs. In this way a cast of the main respiratory cavities may be obtained. Not only the bones of the limbs but also the girdles, sternum,

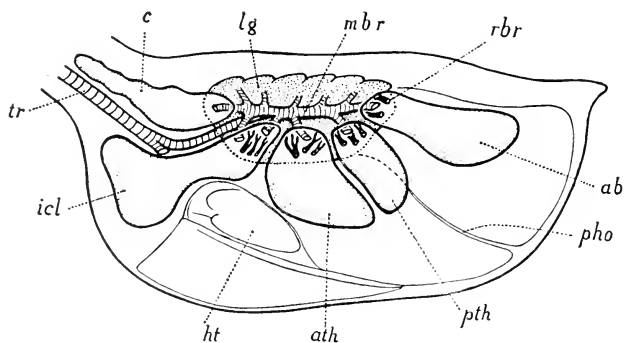


FIG. 410. Diagram of respiratory organs of a bird, left side view. (*ab*) Abdominal air-sac; (*ath*) anterior thoracic air-sac; (*c*) cervical air-sac; (*ht*) heart; (*icl*) interclavicular air-sac; (*lg*) left lung; (*mbr*) mesobronchus; (*pho*) posthepatic septum; (*pth*) posterior thoracic air-sac; (*rbr*) recurrent bronchi; (*tr*) trachea. (From Goodrich: "Studies on the Structure and Development of Vertebrates." By permission of The Macmillan Company, publishers.)

ribs, vertebrae, and even bones of the skull are, in varying degrees, pneumatic. In general, the skeletons of good fliers are more highly pneumatic than those of less capable fliers. Pneumaticity is especially highly developed in large birds which do much sailing or soaring while in flight—e.g., the albatross, frigate bird, and crane. In the flightless ground-living kiwi (*Apteryx*) of New Zealand, in the wholly aquatic penguin, and in waterfowl such as ducks, there is little pneumaticity except in the skull. Usually the bones of smaller birds are less pneumatic. There are, however, many exceptional cases—e.g., the hornbills are clumsy fliers but their skeletons are pneumatic to an extraordinary degree.

All these lesser air-spaces, so far as is known, communicate directly or indirectly (i.e., via adjoining air-spaces) with a major air-sac of the neighboring region of the body. They are all lined by a delicate membrane which is continuous with the thin wall of some major air-sac, this being a consequence of the fact that the lesser air-spaces develop by penetration of small ramifying hollow extensions of the primary air-sacs into more or less remote parts of the body. The primary air-sacs are outgrowths from the lungs, and the lungs grow out from the ventral wall of the embryonic pharynx. There is, perhaps, no more extraordinary—indeed, almost incredible—example of specialized modification of the basic general plan of the vertebrate than that all regions of the adult body should be honeycombed with air-filled spaces which are in communication, via the larger air-sacs, lungs, trachea, mouth, and nostrils, with the outside world. Stating the matter in terms of tissues instead of cavities, the endodermal wall of the gill-producing, lung-producing pharyngeal region of the vertebrate alimentary tube may give rise to hollow ramifying outgrowths which penetrate the whole body, even the interior of vertebrae and bones of the skull, and sometimes extend almost to the tips of the locomotor limbs.

This system of air-filled spaces in birds has some structural analogy to the respiratory tracheal system of insects. The epidermis of insects produces numerous delicate tubules which penetrate into all parts of the body, even its deepest organs. But the **tracheae** are developed by **ingrowth** from the outermost epithelium (**ectoderm**) of the animal, whereas the **air-spaces of birds** are produced by **outgrowth** from the innermost epithelium (**endoderm**). There cannot be the remotest homology between them, and their physiologic analogy is incomplete because the tracheae are wholly respiratory, but in birds the minute air-spaces remote from the lungs can hardly have any respiratory significance. Both systems, however, are striking examples of extreme departure from the primary structure of a metazoan animal.

The coelenterate hydra and the common gastrula stage of the metazoan embryo alike consist of an ectoderm and an alimentary cavity whose wall is the endoderm (Fig. 285). In adult stages of large, complex, three-layered metazoans, the two primary layers become widely separated by development of systems of bulky mesodermal structures, but in birds the endoderm invades the entire body, even to the deeper level of the skin, and in insects the ectodermal skin penetrates even into the territory of the digestive tube.

The bird, in **breathing**, alternately contracts and expands the body-wall. In contraction the thoracic ribs (Fig. 401) become more sharply bent at the joints between their vertebral and sternal parts, and the sternum is raised. The volume of the body-cavity is thereby decreased and air is expelled from the respiratory cavities. Inhalation accompanies the reverse movements, the straightening of the ribs and lowering of the sternum increasing the dorsoventral diameter of the body. The lungs are so closely confined by adjacent structures that they can undergo only very slight change of volume during these respiratory movements. The structures which are free to expand and contract are the large primary air-sacs. During inhalation the air is not merely drawn *into* the lungs but sweeps entirely *through* them, in a volume many times greater than that of the lungs themselves, and fills the capacious air-sacs. At exhalation a large part of the contents of the air-sacs, on its outward course, again sweeps through the lungs. The arrangement of the bronchial tubes connecting lungs and air-sacs indicates that the incoming air enters a sac mainly via the single large bronchial connection with the lung, whereas the sac empties itself mainly through the several smaller recurrent bronchi (Fig. 410). It seems likely that there is some muscular control of the diameters of these tubes. The extent to which the air is changed in the small outlying sacs must depend on their location. In those which are very small blind pockets remote from the lungs, and in those situated in the interior of bones, there can be little or no change of air except by slow diffusion. The important respiratory surface is that of the air-capillaries in the lungs. The walls of the air-sacs lack the close network of capillary blood-vessels necessary in an effective respiratory membrane. The great importance of the large air-sacs is the effecting of **complete ventilation** of the lungs during both inhalation and exhalation. The volume of air inhaled is so great and it rushes so swiftly through the lungs that it cannot become much vitiated. Therefore the air returned through the lungs from the air-sacs still has high respiratory value. In mammals the minute air-spaces in the lungs are "dead ends." Exhalation leaves a residuum of vitiated air. Therefore the air in the lungs merely alternates between better and worse; it is never pure. In birds it is pure during intake and nearly so during outgo.



The function of the numerous small air-spaces remote from the lungs is somewhat problematic. The one thing certain is that the entire system of air-sacs, large and small, reduces the specific gravity of the body as a whole—an obvious advantage in flight. Because of the dorsal position of the major air-sacs, the heavy viscera being below them, the bird's center of gravity is low in the body—also an advantage and one which is augmented by the great reduction of muscles along the vertebral column of the trunk, and by the extremely ventral position of the muscles of flight. The heavy mass of muscle on the lower side of the sternum must be important as ballast. In this connection, the fact that the elevator muscle (subclavius) of the wing is on the sternum, instead of on the back as in land tetrapods, is of interest. In swimming birds the air-sacs are doubtless important as "floats," serving in a manner somewhat analogous to that of the swim-bladders of fishes. It is very probable, too, that the air-sacs, especially the larger, are important in connection with the regulation of the temperature of the body. The mechanism of heat regulation in the bird is not fully known. In mammals the rate of loss of heat from the surface of the body is controlled by increasing or diminishing the flow of blood to the skin and by variation in the output of perspiration. Birds do not perspire, having, like reptiles, a dry skin. The plumage, enclosing innumerable minute particles of air among the dry horny filaments of the small and deeper downy feathers, is an efficient conservator of the heat of the body. On a cold day the bird "fluffs up" the plumage, increasing the volume of air confined within it and thereby increasing the thickness of the insulating layer. A considerable amount of heat must be lost at the inner surfaces of lungs and the larger air-sacs. In control of the bird's temperature, the feathers, skin, and respiratory surfaces are all concerned.

The **vocal organs** of vertebrates are always developed in some part of the respiratory passages. Except in birds, it is the enlarged and modified anterior region of the trachea which becomes the "voice box" or **larynx**. In birds the corresponding region of the trachea appears as a weakly developed larynx, but the vocal function shifts to a "lower larynx" or **syrix** situated at the region of junction of the trachea and right and left bronchi. In some birds it is entirely within the posterior end of the trachea; in others it is a duplex structure involving the adjacent anterior ends of the two bronchi; most commonly it is bronchotracheal, all three tubes participating in its structure. It consists essentially of a resonance chamber formed by enlargement of the air-tubes and containing membranous structures so placed that they may be caused to vibrate by the passing of air through the chamber (Fig. 411). The walls of the trachea and bronchi are strength-

ened by skeletal rings placed fairly close together and, except in the syrinx, at nearly equal distances apart. These rings, cartilaginous in the young bird, are more or less completely bony in the adult. They usually encircle the tube, in contrast to the similar rings which, in

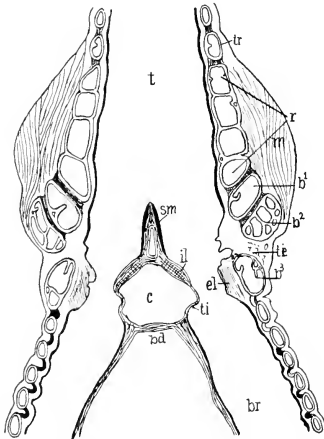


FIG. 411. Section of syrinx of thrush, *Turdus* (after Häcker). ( $b^1$ - $b^3$ ) Bronchial half-rings; ( $bd$ ) bronchidesmus; ( $br$ ) bronchus; ( $c$ ) cavity opening ventrally; ( $el$ ,  $il$ ) external and internal labia; ( $m$ ) muscle; ( $r$ ) resonator; ( $sm$ ) semilunar membrane; ( $t$ ) trachea; ( $te$ ,  $ti$ ) external and internal tympaniform membranes; ( $tr$ ) tracheal rings. (Courtesy, Kingsley: "Comparative Anatomy of Vertebrates," Philadelphia, The Blakiston Company.)

mammals, are incomplete dorsally. In the wall of the syrinx the rings are enlarged and so modified in form and arrangement as to leave certain relatively large areas of the wall unoccupied by skeletal tissue. In such areas the wall is a soft and flexible membrane, free to vibrate in and out, therefore resembling the tympanic membrane of an ear. In a syrinx of the bronchotracheal type, there may be two pairs of such membranes, those of one pair (**external tympaniform membranes**) situated in the right and left sides of the trachea, and those of the other pair (**internal tympaniform**) in the adjacent inner walls of the bronchi (Fig. 411). Where the walls of the two bronchi meet in the median plane, their membranous lining is continued to form a fold

projecting forward into the cavity of the syrinx. This **semilunar membrane** is supported by a delicate rod of cartilage or bone, the **pessulus**. Small muscles situated in the walls of the syrinx (Fig. 411, *m*) regulate the tension in the several vibratory membranes, thus changing the pitch and quality of the sound. The location of the semilunar membrane indicates that it is especially important in production of sound. The syrinx varies greatly in details of structure, being more or less complex according to the vocal abilities of the species of bird. In some birds (e.g., ducks) it is asymmetric, the enlargement to form the resonance chamber being mostly or entirely on one side.

### CIRCULATORY SYSTEM

The circulatory organs of birds differ from those of reptiles in one highly important respect. In reptiles the heart and arteries are so arranged that the blood from the lungs, received in the left chambers of the heart, is mixed with "impure" blood from the right side of the heart before it passes into the general arterial circulation. For a "cold-blooded" reptile with relatively slow metabolism, it is not a serious matter if the blood is not at its possible best. For the bird such an arrangement, counteracting the high efficiency of the lungs, would be most unfortunate. The result would be equivalent to trying to get the best performance out of an airplane engine with insufficient air mixed with the fuel.

**In reptiles** the connection between the heart and the dorsal aorta is a complete aortic arch (the fourth of the embryonic series) consisting of a right and a left arterial trunk. Curiously, however, the trunk which ascends from heart to aorta on the right side of the body connects with the left ventricle and therefore carries oxygenated blood, while the trunk passing up on the left side of the body carries "impure" blood from the right ventricle (Fig. 73*E*). The blood distributed to the body by the dorsal aorta is therefore mixed—even in the crocodylians whose ventricle is completely divided into right and left chambers.

**In birds** the heart is completely divided into four chambers, right auricle and ventricle and left auricle and ventricle. At an early stage in the development of the bird, the heart is connected with the dorsal aorta by the complete fourth aortic arch, consisting of right and left trunks. In rare cases the two trunks cross just in front of the heart and connect with the ventricles in reverse right-and-left order, as in adult reptiles. Usually, however, the left trunk begins to degenerate before the internal subdivisions of the heart and its excurrent trunks have been completed, so that the full equivalent of the reptilian arrangement is not attained. In all cases the left aortic trunk eventually dis-

appears completely, leaving the heart connected with the dorsal aorta by only the **right half** of the aortic arch, **connected with the left ventricle** (Fig. 73*F*). Therefore all parts of the adult arterial system carry "pure" oxygenated blood.

The rate of heartbeat in birds is incredibly rapid. The "basal" rates in an English sparrow, a canary, and a hummingbird have been reported as being, respectively, about 350, 500, and 600 beats per minute (in contrast to about 75 in man).

#### DIGESTIVE ORGANS

The digestive organs of birds exhibit some highly distinctive features. The length of the esophagus necessarily varies greatly according to the length of the neck. In the large majority of birds, the posterior region of the esophagus is more or less dilated to form a chamber, the **crop (ingluvies)**, which serves for temporary storage of the food before it is passed on for digestion. The possession and degree of development of the crop is closely correlated with the feeding habits of the bird. In omnivorous birds and those whose chief food is insects or fruit, the crop is usually small or lacking. It is strongly developed in birds whose main food is grain or seeds. It is especially prominent in such large birds of prey as the vulture and eagle. It is well developed in the domestic fowl, pigeon, and duck but lacking in the goose, swan, and most waders. In general, the crop is small or absent in birds whose food is easily digested and taken in small quantities at frequent intervals, but more strongly developed when the food is difficult to digest (e.g., grain) or when it is taken in enormous quantity at a single meal with long and irregular intervals between meals, as in birds of prey. Usually the crop serves only for storage, but in grain-eaters its lining secretes a fluid which softens the food and prepares it for the action of digestive secretions. In pigeons the crop during the breeding season produces "pigeon's milk," which is regurgitated and fed to the young birds. It resembles mammalian milk in appearance, but the two are unlike chemically.

The region between the esophagus and the intestine is more or less definitely divided into two chambers (Fig. 412). The anterior one (**proventriculus**) is usually smaller than the other, the muscular layer of its wall is thin, and its epithelial lining is thick and closely beset with glands which secrete the characteristic digestive fluids of a stomach. The posterior chamber (**gizzard**), when strongly developed, is much the larger and has an enormously thickened muscular layer differentiated into a massive and powerful muscle on each of two opposite sides of the organ. The internal epithelium is highly glandular. The secretion, however, has no digestive function but is a substance

which hardens to form a thick protective lining resembling in appearance and texture the substance of horny structures produced by the skin. Integumentary horn, however, is not a secreted substance (see p. 18).

The degree of development of the gizzard is closely correlated with the character of the food. It attains maximum development in the grain-eaters. In these birds the food, softened during its stay in the

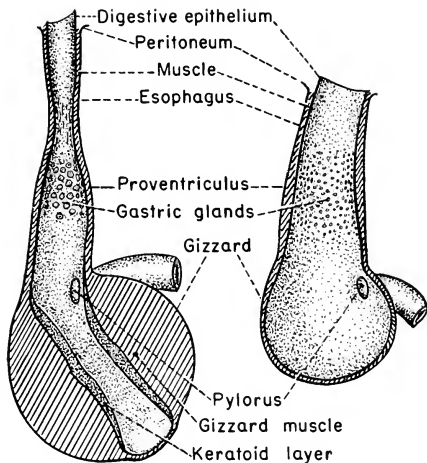


FIG. 412. (Left) Stomach of turkey, a grain-eating bird. (Right) Stomach of buzzard, a flesh-eating bird. Diagrammatic sections. (After Kingsley: "Comparative Anatomy of Vertebrates." Philadelphia, The Blakiston Company.)

crop and mingled with digestive fluids derived from the proventriculus, is subjected to the vigorous crushing and grinding action of the muscular gizzard. It is the common habit of these birds to swallow small pebbles or other hard indigestible objects which assist in the grinding process. The gizzard is more or less well developed in insectivorous birds. Hard-shelled beetles must be crushed before they can be digested. Obviously the gizzard serves in place of teeth. It is least differentiated in birds of prey (eagle, hawk, owl, gull), in which its muscular layer is relatively thin and no hard lining is produced.

The length of the **intestine** varies from twice to several times the total length of the bird, in general being longer in vegetarians than in carnivores. Two main regions are recognized, the anterior **small intestine** and the posterior **large intestine**, the "small" and "large"

referring to diameter, not length. The long small intestine is disposed in turns and coils which have several different patterns, each characteristic of a particular group of birds. The large intestine, better called **rectum**, is relatively short—usually a small fraction of the length of the body. The ostrich is a notable exception, having a very long and capacious rectum. Since the chief function of the rectum is storage of the waste residue of digestion, the extreme abbreviation of this region of intestine in the flying birds is significant in its economy of useless weight.

In most amniote vertebrates the region of junction of small and large intestines is marked by outgrowth of the intestinal wall to form one or two blind pouches, **ceca**, which serve to augment the secretory and absorbing surface of the intestine. In the heron and a few other birds, the cecum is single and quite short. In parrots, woodpeckers, and toucans, the ceca are absent or very rudimentary. In most birds they are paired and in many cases attain extraordinary length and give evidence of great functional importance. In the common pigeon they are less than an inch long; in the domestic fowl, about one-third the length of the body; in a grouse, according to Richard Owen, each cecum is “a yard long” and, on the same authority, the ostrich has two ceca, each “upwards of two feet” long and having its internal epithelium uplifted to form a projecting membrane extending spirally lengthwise of the cecum—a “spiral valve” structurally similar to that in the intestine of a shark. In the grouse, too, the internal surface of the long ceca is much increased by the presence of several projecting longitudinal folds of the lining, but they are not spirally arranged. Unquestionably the ceca in birds are important digestive organs. Partly digested food from the small intestine passes into the ceca to undergo further or complete digestion and absorption. Thus the ceca compensate for the relative shortness of the main intestinal tract.

The **liver** and **pancreas** are well developed—the pancreas especially so—and, as usual, connect by ducts with the extreme anterior end of the small intestine. An unusual feature is the multiplicity of ducts—commonly two hepatic or bile-ducts and two or three pancreatic ducts. Many birds, including pigeons, have no gallbladder.

The **rectum** opens into a capacious **cloaca**, in whose cavity may be recognized three regions delimited by transverse folds or constrictions of the wall (Fig. 413). Most anterior is the **coprodeum**, into which opens the rectum only. The middle region, **urodeum**, contains the apertures of the urinogenital ducts. These two chambers are derived from the endodermal wall of the embryonic digestive tube. The posterior chamber, the **proctodeum**, is lined by infolded ectoderm. In young birds a thick-walled glandular pouch, the **bursa Fabricii**, opens

dorsally into the proctodeum (although apparently the embryonic origin of the bursa is from endoderm). In adults the bursa is much reduced or entirely absent. Its function is not definitely known.

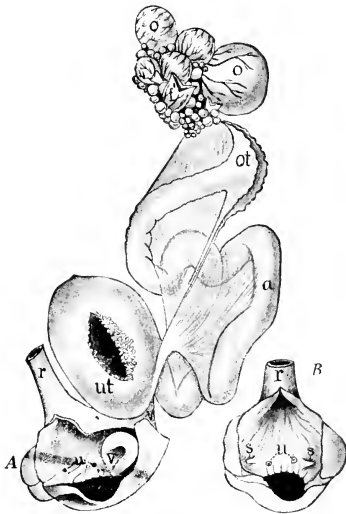


FIG. 413. (A) Genitalia of hen. (B) Cloacal region of cock. (a) Albumen-secreting region of oviduct; (f) discharged follicle of ovary; (o) advanced ova in follicles; (ot) ostium tubae abdominale; (r) rectum; (s) openings of vasa deferentia; (u) urinary openings; (ut) uterus or shell-gland with the villi showing in the opening; (v) cloacal opening of left oviduct. (After Tichomiroff. Courtesy, Kingsley: "Comparative Anatomy of Vertebrates." Philadelphia, The Blakiston Company.)

#### URINOGENITAL ORGANS

The **kidneys** of birds are **metanephric**, as in reptiles. From each metanephros the **ureter** passes directly into the urodeum (Fig. 413). There is **no urinary bladder**—another point where the bird omits useless weight. But it must be remembered that some reptiles omit the bladder, and without the good reason which birds seem to have for doing so.

The **reproductive organs** of the male have no unusual features. Right and left testes and vasa deferentia (sperm-ducts) are fully de-

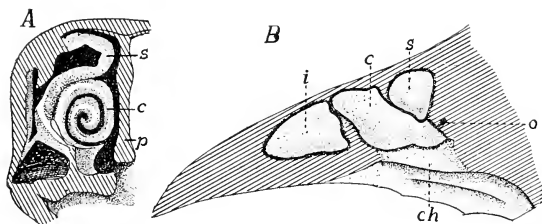


FIG. 414. Olfactory region of hen. (A) Transverse section. (B) Longitudinal section. (*c*) Middle concha; (*ch*) choana; (*i*) inferior (anterior) concha; (*o*) connection of air-cavity of head; (*p*) septum of nose; (*s*) superior concha. (After Gegenbaur. Courtesy, Kingsley: "Comparative Anatomy of Vertebrates." Philadelphia, The Blakiston Company.)

veloped and functional. A copulatory organ (penis) of the reptilian type is present only in ostriches, ducks, geese, and a few other birds. In the female embryo paired ovaries and oviducts are formed, but usually only those on the left side develop to functional maturity (Fig. 413). The right ovary and duct may persist in a rudimentary condition or may disappear. This reduction of a paired to a unilateral system is clearly related to the fact that birds' eggs are of such enormous size relative to the diameter of the body that they must mature and pass out in single file.

#### NERVOUS ORGANS

Some of the nervous organs of birds are more elaborately developed than the corresponding organs of reptiles. On the whole, however, the avian nervous system and the type of behavior which it mediates conform to the reptilian pattern and show little approach toward the mammalian.

The structure of the **olfactory organ** indicates that the sense of smell plays a secondary part in the life of the bird as compared to sight and hearing. The nasal cavities are relatively small. From the outer wall of each cavity three **conchae**, or "turbinals," project into its interior (Fig. 414), in contrast to the single concha of reptiles. This increase of nasal surface, however, is not attended by corresponding increase of olfactory surface because (in the few birds which have been examined in this particular) the distribution of the olfactory sensory cells is restricted almost or entirely to the posterior concha. The **organ of Jacobson** is quite lacking in adult birds, but rudiments of it have been observed in embryos.



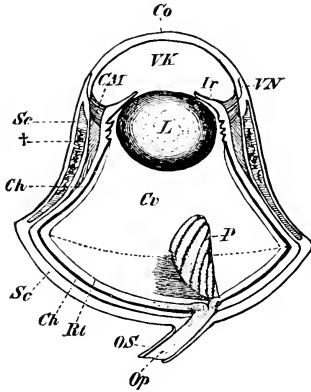


FIG. 415. Eye of an owl; section in optical axis. (*Ch*) Choroid; (*CM*) ciliary muscle; (*Co*) cornea; (*Cv*) vitreous humor; (*Ir*) iris; (*L*) lens; (*Op*) optic nerve; (*OS*) sheath of nerve; (*P*) pecten; (*RT*) retina; (*Sc*) sclerotic; (*VK*) aqueous humor; (*VN*) junction of sclerotic and cornea. (†) marks location of bony plates in the sclerotic layer. (Courtesy, Wiedersheim: "Grundriss der vergleichenden Anatomie der Wirbeltiere," Jena, Gustav Fischer.)

The eye is developed to a high degree of efficiency. It is extraordinarily large relative to the size of the head. Whereas in Anamnia and Reptilia the eyeball is approximately spherical or, in many fishes, more nearly hemispherical with the flattened surface external, in birds it is more or less elongated in the direction of the optic axis, and its exposed surface is strongly convex. The elongation is especially marked in nocturnal birds such as owls (Fig. 415). The **sclerotic layer** of the eyeball is largely cartilaginous and a ring of bony **sclerotic plates** surrounds the corneal region (Fig. 415†).

A conspicuous but problematic feature of the bird's eye is a structure which lies in the midst of the vitreous humor (Fig. 415, *P*). It is a folded membranous thing whose form is best likened to that of a half-folded fan, the narrow end attached to the rear wall of the eyeball at the region of entrance of the optic nerve. It projects freely into the vitreous humor, the length varying greatly in different species and in some cases extending even to the inner surface of the lens. Its tissue is pigmented, highly vascular, and well supplied with nerves. The function of this structure, the **pecten**, is not definitely known. That it has something to do with accommodation has been proposed and denied. Its richness in blood-vessels suggests that it may serve to make nutrient and oxygen more readily available to the internal tissues of the eyeball. A similar structure, but much less well developed, occurs in lizards, and appears in a very weakly developed condition in other reptiles.

In **accommodation** of the eye for vision at varying distances, the convexity of the lens is altered, as in reptiles, but the effect of this

change is augmented by a corresponding change in the convexity of the cornea. Both structures become more convex for near vision, less so for distant vision. These changes are effected by the system of small **ciliary muscles** developed in the choroid layer and forming a muscular zone encircling the eyeball at the region of the periphery of the cornea (Fig. 415, *CM*).

**The ear** is well developed in all birds. In general structure it closely resembles the reptilian ear at its best—namely, as it is in the crocodylians. The tympanic mechanism is uniformly well developed. The **tympanic membrane** is depressed below the surface of the skin, lying at the bottom of a fairly deep **external auditory meatus**.

The most significant difference between the ears of reptile and bird is in the **cochlea** (see p. 208). It is longer in the bird (Fig. 180F) and there is a definite twist in its axis suggestive of the spiral of the much longer mammalian cochlea (Fig. 180G). With increase in the length of the cochlear tube, its internal sensory **organ of Corti** is correspondingly extended. Unquestionably this gives the bird, compared to the reptile, a wider range of hearing and higher capacity for discriminating qualities of sound. All of this is consistent with the fact that the birds' highly specialized syringeal organs give them vocal abilities far surpassing the reptilian repertory of hisses, grunts, and the unmusical but thunderous bellow of an old male alligator. The biologic utility of the bird's song requires that those "birds of a feather" which, by nature, "flock together" should have an ear adequate for hearing and discriminating the songs. If, for man, the song is an element of beauty in the world of life of which he is a part, it is only because it is his good fortune to have an ear whose structure is closely similar to that of the bird's ear.

**Brain.** All of the major regions of the bird's brain are strongly developed *except the pallium*. Viewing the brain dorsally or laterally (Fig. 416), the conspicuous parts are the **cerebral hemispheres**, the **optic lobes**, and the **cerebellum**. The hemispheres and cerebellum are so enlarged that they nearly or quite meet dorsally and cover a large part of the optic lobes which project laterally, while the diencephalon is almost completely hidden. It is as if, in a brain shortened in the manner described in discussing the skull, the expansion of hemispheres and cerebellum had squeezed the optic lobes outward laterally.

The relative proportions of the parts of the brain are always a good index to the animal's sensory capacities and to the general nature of its somatic (in distinction to visceral) motor activities. The larger the eye, the greater is the number of sensory elements and, accordingly, the

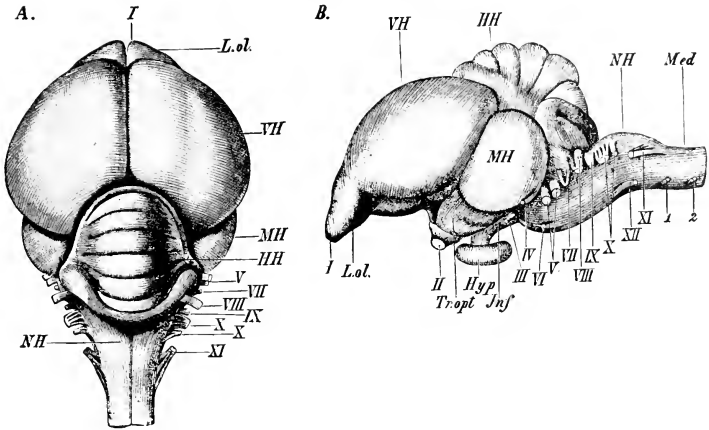


FIG. 116. Brain of pigeon. (A) Dorsal view. (B) Lateral view. (*Hyp*) Hypophysis; (*Jnf*) infundibulum; (*L. ol.*) olfactory lobes; (*III*) cerebellum; (*Med*) spinal cord (medulla spinalis); (*MH*) optic lobes; (*NH*) medulla oblongata; (*Tr. opt*) optic tract; (*VII*) cerebral hemispheres; (*I-XII*) cranial nerves; (*1, 2*) first and second spinal nerves. (Courtesy, Wiedersheim: "Grundriss der vergleichenden Anatomie der Wirbeltiere," Jena, Gustav Fischer.)

more fibers in the optic nerve and the greater the number of nervous elements in the optic centers of the brain. The extraordinarily large eyes of the bird are associated with large **optic lobes**.

The all-important function of the **cerebellum** is the coördination of the activities of the complex sets of muscles involved in locomotion and in maintaining bodily equilibrium—balancing, posture. This coördination depends upon stimuli received by the various sense-organs, especially important being those received by the eyes and by the equilibratory organs (semicircular canals) of the ears. Each type of sensory organ has its corresponding *primary sensory center* in the brain—smell in the forebrain; sight in the midbrain (optic lobes); equilibrium and hearing, taste, and the various integumentary senses in the hindbrain. Therefore, from these several primary sensory centers, nervous impulses must be relayed into the cerebellum along connecting tracts of nerve-fibers. The muscular activities concerned in flight are of a peculiarly complex sort and require, for their precise coördination, a correspondingly complex nervous mechanism. The cerebellum, however, merely *coördinates* these activities. Whether or not flight shall occur, its direction and speed, and, in short, the whole pattern of the animal's activities, are determined within nervous centers situated elsewhere in the brain and, for the most part, in regions anterior to the

cerebellum. A complex system of nervous pathways connects the cerebellum with these dominating centers. The conspicuously great size of the bird's cerebellum is therefore referable to several factors—the richness of the incoming stream of impulses having origin in the highly developed sense-organs; the vast number of neurons entering the cerebellum along the pathways connecting it with the higher dominating centers; the number, also “vast,” of intrinsic neurons required for the correlation of the diverse incoming impulses and their translation into a set of outgoing impulses appropriate for the effecting of a precisely coordinated set of muscular responses.

It would not be of advantage to an animal that its activities should at any time be wholly dominated by a single sense-organ. Proper adjustment to the external situation requires that all of the animal's senses shall participate in the determination of behavior. This favorable arrangement is achieved by the existence of numerous **correlation centers** which intervene between the primary sensory centers and those ultimate motor centers which send out impulses causing muscular contraction or other responses. A correlation center is a localized mass of “gray substance” having nervous connection with two or more primary centers, with other correlation centers, and, directly or indirectly, with motor centers. Such correlation centers exist in all of the main regions of the brain. They are least well developed in fishes, better developed in amphibians and reptiles, and very highly developed in birds. It is the function of the higher correlation centers to “analyze” and “evaluate” (figuratively speaking) sensory stimuli and then to synthesize them into a resultant which shall determine the type of response best adapted to the whole external situation. Reports from different sense-organs may be contradictory. The eyes may report that a certain external object appears to be a desirable morsel of food. The olfactory organs may report that it has a bad odor. Whether or not it is to be eaten is “decided” by correlation centers.

In birds it is the forebrain in which correlation centers are most numerous and most highly developed. They occur in the lateral walls (**thalami**) of the diencephalon, but most especially in the cerebral hemispheres, which are accordingly much enlarged. The increase in volume, however, is entirely due to thickening of the ventrolateral wall, the **corpus striatum**. The dorsal wall, **pallium**, remains thin and, in fact, relative to the corpus striatum, the pallium is thinner in birds than in reptiles and its superficial gray layer is less strongly developed.

In the account of the reptilian brain (pp. 479–481) were set forth reasons for regarding the **pallium** as the particular seat of the nervous mechanisms concerned with behavior which at least approaches the level of intelligence. Behavior controlled solely by the mechanisms of

the spinal cord and of the brain exclusive of the pallium is predominantly of the automatic, reflex, or instinctive type. In a simple reflex a nervous impulse initiated in some sense-organ is transmitted into the spinal cord or brain and there passes over directly into a motor nerve which connects with some effector—a muscle which contracts or a gland which secretes. It is automatic and invariable so long as its particular “reflex arc” is not acted upon by some higher dominating center. Instinctive behavior is merely a highly elaborated system of very complicated reflexes seated in a nervous mechanism which is inherited unaltered from generation to generation.

In the **behavior of birds** there is much that bears the outward semblance of intelligent action. The uncritical observer marvels at the skill, wisdom, and foresight exhibited by the bird in building its nest. But the bird does not learn how. When the time comes to build the first nest, the bird does it, and quite well. The pattern of the nest and of the mechanism for building it were somehow in the egg which produced the bird. Critical study of the bird's activities makes it clear that they conform to a pattern characteristic for the particular species of bird and so rigid that there is only a very narrow margin of possible modifiability. Showmen exhibit their trained dogs, seals, horses, and elephants, but birds are too little amenable to training to make an interesting show. They do, to a limited extent, remember, learn, and profit by experience, but so does a teleost fish whose pallium is devoid of nervous tissue. In these capacities birds are probably somewhat inferior to reptiles.

It is probably safe to say that birds exhibit the most complex and highly differentiated instinctive behavior to be found in the animal kingdom, unless it is equalled by that of some insects and spiders. In the structure of the bird's brain is to be seen extraordinary development of all regions which have to do with activity of the nearly or quite automatic sort, the corpus striatum becoming especially prominent as the seat of instinctive nervous mechanisms. The teleost fish, entirely lacking pallial nervous tissue, still has a certain small capacity for modifying behavior. It is probable that in all vertebrates the correlation centers of the corpora striata and regions posterior to it allow for a small measure of modifiability. In the case of the bird, the weakly developed pallium seems to add little, if anything, to the modifiability which presumably exists in the lower correlation centers.

The **12 pairs of cranial nerves** correspond closely in all particulars with those of reptiles.

#### REPRODUCTION

Reproduction in birds is essentially similar to that in reptiles. No birds, however, are viviparous. The eggs, relative to size of body, are

even larger than in reptiles, and contain a greater store of food (yolk). The shell is calcified and hard in contrast to the flexible parchment-like shell of most reptilian eggs. The protective, nutritive, and respiratory embryonic membranes—amnion, yolk-sac, and allantois—closely resemble those of reptiles.

### EARLY BIRDS

Definitions of the Class Aves put such great emphasis on adaptations for flight that other characteristics and exceptions are overshadowed. The mere mention of "bird" suggests something flying. But, just as there are "vertebrates" without the vertebral column, so the name "bird" is applied to some animals which cannot fly. The ostrich and penguin have wings which are insufficient for flight. The remains of the recently extinct gigantic moa of New Zealand show, in some cases, no trace of pectoral limbs. Birds which are strong fliers possess a complex of highly specialized features, but in flightless birds these are, in varying degree, so reduced that they cannot be said to be universally characteristic of birds, and their close equivalent may be found in some reptiles. The one highly specialized thing which, without any exception, is common to all animals which we call "birds" is the feather. The ostrich does not fly, but ostrich plumes are extraordinary examples of the feather. A bird without feathers can perhaps be imagined, but no such animal is known to exist at present. A feather without a bird is equally foreign to our experience.

About 1860, on a slab of fine-grained (lithographic) limestone obtained from a quarry in Bavaria, was found what appeared to be the impression of a single feather. Its identity was doubted until, about a year later and in the same locality, there was found a nearly complete vertebrate skeleton with which were associated unmistakable impressions of feathers. Through the effort of Sir Richard Owen, this fossil was bought and deposited in the British Museum. In 1863 Owen published a detailed account of it. About 16 years later the original locality yielded another and still better specimen (deposited in the Berlin Museum) differing from the first in some details but evidently representing a related genus or species. Since then no similar fossils have been found anywhere.

The two fossil skeletons represent animals of "about the size of a crow." The skeleton is, in general, distinctly reptilian (Fig. 417). The skull is more heavily built than that of a modern bird. The upper jaw carried numerous well-developed conical teeth. Teeth were probably present in the lower jaw, but less numerous. There were about 50 vertebrae, of which only about 10 were in the short neck. There was no fusion of trunk vertebrae. The sacral region included 5 or 6 vertebrae. The long tail contained some 20, which were all freely movable

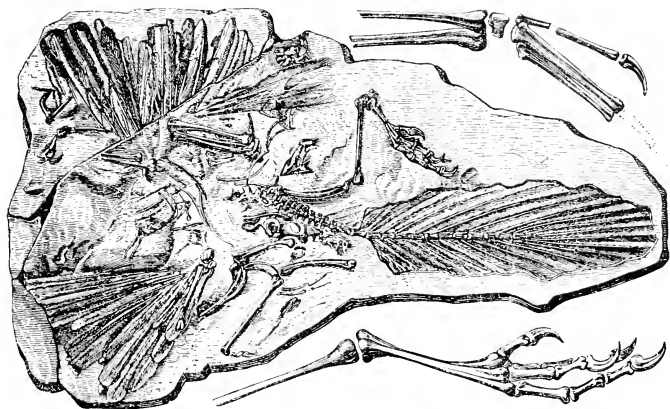


FIG. 117. Fossilized bones and feathers of *Archaeopteryx*, as they appear on a slab of limestone. Above the slab is shown a partial reconstruction of the distal part of the wing, and below is represented the foot. (Courtesy, Zittel: "Handbuch der Palaeontologie," Munich, R. Oldenbourg.)

and tapered gradually to the tip of the tail as in a lizard—there was no terminal pygostyle. So far as can be ascertained, the vertebrae were amphicoelous (as in *Sphenodon*). The ribs lack uncinuate processes, but the animal may have had cartilaginous uncinaes which did not fossilize. The sternum, very poorly preserved, was probably small and without a carina. Abdominal ribs (gastralia) were present (as in *Sphenodon* and *Crocodylia*). The skeleton of the limbs is more reptilian than avian, especially that of the forelimb, which has three strongly developed digits, each terminating in a long, pointed claw. The three metacarpals are not fused to one another nor to the carpals—that is, there is no carpo-metacarpus as in modern birds. The skeletons show no signs of pneumaticity of bones.

These two skeletons so closely resemble numerous fossil reptilian skeletons (being especially similar to those of certain small dinosaurs) that they would not arouse great interest but for the fact that the fossils not only prove the existence of feathers but to a large extent show the relations of the feathers to regions of the body. The feathers were large and, apparently, structurally similar to the quill-feathers of modern birds. The fossils clearly show well-developed primary and secondary remiges attached to the hand and forearm respectively, as in modern birds. The long tail carried numerous rectrices arranged in a single row along each side of it. They were symmetrically placed, possibly each vertebra supporting a pair. Their axes sloped sharply

backward. The tail must have presented a great expanse of flat surface which served as an important factor in the aerial activities of the animal. There are also indications of well-developed feathers on the body.

The nature of the locomotion in these animals is a matter of speculation. The relatively small expanse of the wing and the probably weak condition of the sternum forbid regarding them as strong fliers. It is possible that they merely glided or sailed from tree to tree in the manner of "flying" squirrels.

The animal represented by the fossil described by Owen was named **Archaeopteryx lithographica**. The three fossils (the single feather being one) were found in limestone strata belonging to the Jurassic (mid-Mesozoic) Period, a time when reptiles were at the apex of their career as a Class. *Archaeopteryx*, so far as may be judged from the skeleton and feathers, may be regarded as either a feathered reptile or a very reptilian bird. The unique importance of feathers in the life of the modern bird favors placing the animal on the avian side of the purely imaginary line between reptiles and birds. It is, in a sense, a "connecting link," but at present it is merely an isolated link and not a part of any continuous chain of *known* transitional animals. So far as feathers are concerned, it is not even a connecting link, for they seem to have attained the level of differentiation of the average feather of modern birds. A really satisfactory connecting link would be a reptilian creature having elongated overlapping horny scales with their free distal ends split into filaments suggesting the barbs of a feather. If *Archaeopteryx* was literally "the first bird," we would be forced to accept Geoffroy Saint-Hilaire's suggestion (p. 342) that the first bird hatched from a reptile's egg. But our present knowledge of inheritance forbids the assumption that so complex a structure as a quill-feather could be the product of a single mutation or even several successive mutations.

*Archaeopteryx* is the earliest bird at present known, but between it and typical scaly reptiles must be a very long history which is unwritten in the geologic record—or, at least, has not yet been unearthed. Our knowledge of the birds that must have existed during long ages following the days of *Archaeopteryx* is not much better than the total blank of the earlier period. At all geologic levels, fossil birds are few and far between.

In rocks of the later Mesozoic (Cretaceous) occur fossils representing birds whose skeletons had gone far toward acquiring the specialized features characteristic of modern flying birds. The tail was short and its series of several free vertebrae terminated in a pygostyle. The large sternum usually bore a strong carina. However, teeth similar to those



of *Archaeopteryx* were present in upper and lower jaws. Best known of these toothed birds are **Ichthyornis** and **Hesperornis** (Fig. 418), found in Cretaceous strata of Kansas, which was then at the bottom of a sea. *Ichthyornis*, except for the teeth, must have resembled a modern tern in size and form, and probably in mode of life. Its wings were strongly developed. *Hesperornis* was an enormous bird (3 or 4 feet long) having no functional wings. The pectoral limb was represented only by the vestigial girdle and humerus. The feet projected laterally outward and probably served as powerful swimming paddles. The sternum had no carina. No remains of toothed birds have been found in strata later than the Cretaceous.

So far as can be judged from the scanty evidence, the dominant birds since early Cenozoic times have been toothless and otherwise very much like modern flying birds. By the middle of the age, however, appeared birds with wings much reduced or entirely lacking and legs powerfully developed—the “running birds” such as the ostriches.

The geologic history of birds, fragmentary as it is, gives us a clue to the general course of development of the Class. Three periods may be recognized, characterized as follows: (1) Animals of distinctly reptilian features including **long tail** and **teeth**, but feathered and having a pectoral wing adequate for at least a short gliding flight. (2) Birds closely approaching modern birds in their numerous anatomic adaptations for effective sustained flight; strong sternum with well-developed carina; **tail short**, but **teeth** of reptilian type still persisting; contemporaneous with these flying birds are some swimmers and

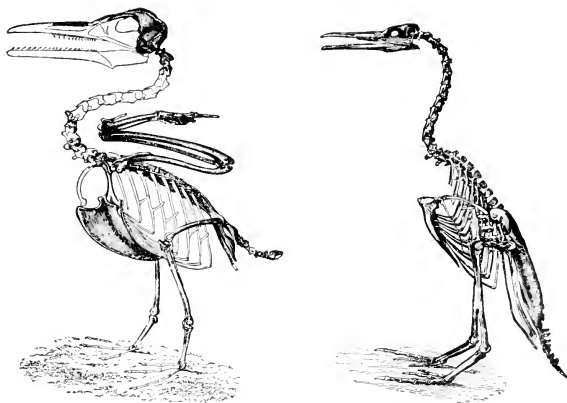


FIG. 418. (Left) *Ichthyornis*. (Right) *Hesperornis*. (Courtesy, Coues: “Key to North American Birds,” Boston, L. C. Page & Co.)

divers, also toothed, having apparently useless vestiges of wings. (3) Numerous diversified types of more or less capable fliers, all **short-tailed** and **toothless**; along with them, some aquatic birds having wings more or less reduced—poor fliers or incapable of flight; a few, mostly very large birds, having wings reduced below the level of flight or entirely lacking and, in most cases, legs long and strongly built for running; all birds in this third period are short-tailed and toothless.

#### CLASSIFICATION

The classification of birds is less satisfactory than that of the other Classes, partly because of the dearth of fossil material and also because the diversification of modern birds is so extreme. Comparison of birds of two types is likely to reveal a complex of resemblances and differences from which it is difficult to select those which should be regarded as most significant for purposes of classification. This is true of even the main subdivisions of modern birds. It has long been the common practice to separate birds into two groups—**Carinatae**, **flying birds** with a well-developed keel on the sternum; and **Ratitae**, **running birds** having reduced wings, the carina poorly developed or lacking, and the terminal region of caudal vertebrae usually not fused into a pygostyle. (“Ratitae”—from the Latin *ratia*, a raft—has nautical significance, referring to the flat-bottomed keelless sternum.) This grouping, however, is not satisfactory because there are some carinate flying birds (the South American tinamou) which, on the basis of other characteristics, seem to be much more closely related to the Ratitae than to modern carinate birds. This difficulty arises from the fact that the carina is readily subject to adaptive change corresponding to change in the locomotor activities of the animal—that is, not in the individual, but in the long course of phylogeny. It is apparently not a stable or “conservative” character and not trustworthy for determination of long-range relations.

Probably more confidence may be placed in the structure of the skull, whose form is to a large extent not directly related to motor activities. In some birds the skull follows the reptilian pattern much more closely than in others. The structure of the roof of the mouth (palate) and the upper jaw has come to be regarded as especially significant. In some birds the vomers (or “prevomers”: see p. 125), a pair of bones lying in the median region of the anterior part of the palate (Fig. 375, *center*), are large and each one articulates with the palatine and pterygoid, which are rigidly joined together. These relations are commonly found in less specialized reptilian skulls. In other birds the vomers are relatively small, usually very narrow and fused, or sometimes lacking, and they may articulate with the palatines but

not with the pterygoids, the two latter bones being movably joined. Skulls having the more reptilian (therefore presumably older) type of palate are called *paleognathous*; those of the other type are *neognathous*. On this basis, modern birds are separated into two divisions: **Palaeognathae**, including all of the "running birds" and the flying tinamous; and **Neognathae**, including all the others.

Of the many classifications of birds, no two are quite alike. In other vertebrate Classes the major divisions, such as subclasses, usually break directly into a small number (not including extinct groups) of orders which are distinguished by such conspicuous anatomic differences that there can be no doubt about the validity of the subdivisions. Any attempt to split up the major divisions of Aves at once compels recognition of some 20 or more living groups, most of which can be defined only on the basis of peculiarities which seem trivial as compared to those which separate, for example, Urodela and Anura or Ophidia and Chelonia. These subdivisions of Aves are somewhat unfairly given the dignity of *Orders*, but it is obvious that, in the general scale of classification, they stand more nearly at the level of the *families* in other classes. In the following outline of avian classification, the so-called "Orders" will not be defined beyond mention of some of the better-known representatives of each and a few of their general characteristics.

## CLASS AVES

### SUBCLASS ARCHAEORNITHES

Mesozoic birds: Long tail with many freely movable vertebrae, no pygostyle; teeth of reptilian type (conical) in both jaws. **Archaeopteryx**.

### SUBCLASS NEORNITHES

Later Mesozoic birds and all Cenozoic birds: Short tail usually ending in a pygostyle; teeth in some extinct Cretaceous birds, later birds all toothless.

#### I. ODONTOGNATHAE:

Extinct Cretaceous toothed birds. **Ichthyornis**, **Hesperornis** (p. 541).

#### II. PALAEOGNATHAE:

[RATITAE (p. 542): **Orders** 1-4]

**Order 1. CASUARIIFORMES: Cassowary** (**Casuaris**) and **emu** (**Dromicis**); ostrich-like, but smaller than African ostrich; wings extremely vestigial; no carina on sternum; three toes present (second, third, fourth); aftershaft on feathers; found only in Australia and some neighboring islands (Fig. 419).



FIG. 419. Bennett's cassowary, *Casuaris bennetti*. (Courtesy, Knowlton and Ridgway: "Birds of the World," New York, Henry Holt & Co., Inc.)

**Order 2. STRUTHIONIFORMES: Ostriches (Struthio)** of Africa and Arabia; largest living birds; wings much reduced, flightless; no carina on sternum; legs long and strong; only two toes (third and fourth); no aftershafts (Fig. 420).

**Order 3. RHEIFORMES: South American ostrich (Rhea);** similar to African ostrich, but smaller and three-toed; wings less reduced; no aftershafts.

**Order 4. APTERYGIFORMES: Kiwi (Apteryx)** of New Zealand (Fig. 421); slightly larger than common fowl; short neck; long, sharp bill; thick coat of loose, fluffy plumage, no aftershafts; wings extremely vestigial and buried under plumage; no rectrices; no carina on sternum; legs short and stout; four toes; eyes small and poorly developed; olfactory organs highly developed; egg 5 inches or more in length; ground-inhabiting, sometimes burrowing; nocturnal.

[CARINATAE (p. 542): **Orders 5-20**]

**Order 5. TINAMIFORMES (Crypturiformes): Tinamous (Tinamus)** of Mexico and South America; resemble partridges; poor fliers, strong runners (Fig. 422).

### III. NEOGNATHAE:

**Order 6. SPHENISCIFORMES: Penguins** (Fig. 423); flightless; short wings used as powerful swimming paddles; carina well developed; Southern Hemisphere only.



FIG. 420. North African ostrich, *Struthio camelus*. (Courtesy, Knowlton and Ridgway: "Birds of the World," New York, Henry Holt & Co., Inc.)

**Order 7. COLYMBIFORMES: Loons, grebes;** divers: usually good fliers; webbed feet used as swimming paddles; widely distributed, but loons in Northern Hemisphere only. (The loons, *Gavia* (Fig. 424), are sometimes put in a separate ORDER GAVIFORMES.)

**Order 8. PROCELLARIIFORMES: Albatrosses, petrels** (Fig. 425): large oceanic birds; strong fliers; webbed feet.

**Order 9. PELECANIFORMES: Pelicans** (Fig. 426), **cormorants, frigate birds;** aquatic, but good fliers (except a flightless cormorant); fish eaters; widely distributed.

**Order 10. CICONIIFORMES: Herons** (Fig. 427), **egrets, storks, ibises, flamingos;** waders: long legs keeping the body above the water, accompanied usually by long neck and long bill enabling the bird to feed from the water or bottom.




FIG. 421. New Zealand kiwi, *Apteryx australis*. (Courtesy, Knowlton and Ridgway: "Birds of the World," New York, Henry Holt & Co., Inc.)

**Order 11. ANSERIFORMES: Ducks, geese, swans;** swimmers and waders; short legs, webbed feet; with few exceptions, strong fliers.

**Order 12. FALCONIFORMES: Falcons, eagles, hawks, buzzards** (Fig. 423), **vultures;** carnivorous; hooked bill and long-clawed toes adapted for capture and rending of prey; strong fliers.

**Order 13. GALLIFORMES:** Mostly ground birds and poor fliers: **quails, pheasants, grouse, turkeys, peafowls, and jungle fowls** (*Gallus*) from which have been derived the many breeds of domestic fowls. The South American **hoactzin** (*Opisthocomus*; see p. 410) is commonly included but perhaps should be assigned to a separate order.

**Order 14. GRUIFORMES: Rails, coots, cranes** (Fig. 429)—marsh-inhabiting; **bustards**—large plain-inhabiting birds of Eastern Hemisphere; South American **cariamas;** poor fliers.

**Order 15. CHARADRIIFORMES: Plovers, snipe, sandpipers** (Fig. 430), **curlews**—mostly along seacoasts and shores of fresh waters; **gulls, terns**—oceanic and cosmopolitan, long wings, strong fliers, good swimmers; **auks, puffins, murre**s—oceanic, confined to North-





FIG. 422 (Left). Rufous tinamou, *Rhynchotus rufescens*. (Courtesy, Knowlton and Ridgway: "Birds of the World," New York, Henry Holt & Co., Inc.)

FIG. 423 (Right). Penguin, *Endiptes antipodium*. (After Buller. From Parker and Haswell; "Text-Book of Zoology." By permission of The Macmillan Company, publishers.)




FIG. 424. Loon (*Gavia*). (Courtesy, Cones: "Key to North American Birds," Boston, L. C. Page & Co.)




FIG. 425. Capped petrel, *Oestrelata haesitata* (Kuhl). (Courtesy, Saunders: "Manual of British Birds," London, Gurney & Jackson.)

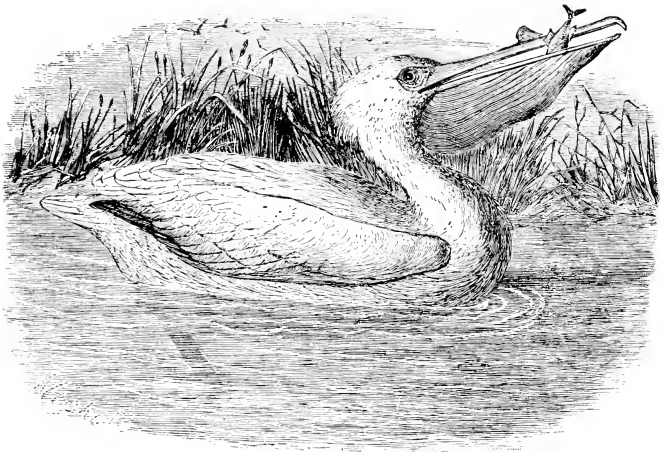


FIG. 426. American white pelican, *Pelecanus erythrorhynchos*. (Courtesy, Knowlton and Ridgway: "Birds of the World," New York, Henry Holt & Co., Inc.)






FIG. 427. Great blue heron, *Ardea herodias*. (Courtesy, Knowlton and Ridgway: "Birds of the World," New York, Henry Holt & Co., Inc.)




FIG. 428. Common buzzard, *Buteo vulgaris*, Leach. (Courtesy, Saunders: "Manual of British Birds," London, Gurney & Jackson.)



FIG. 429. Crane (*Grus*). (Courtesy, Saunders: "Manual of British Birds," London, Gurney & Jackson.)




FIG. 430. Sandpipers (*Tolanus*). (Courtesy, Saunders: "Manual of British Birds," London, Gurney & Jackson.)

ern Hemisphere: expert swimmers and divers, and fairly good fliers except the recently extinct flightless "great ank."

**Order 16. COLUMBIFORMES: Pigeons, doves;** all strong fliers; some 500 species; cosmopolitan. (Sometimes included under Charadriiformes.) The **dodo** (Fig. 431) and **solitaire**, recently extinct, were large pigeon-like birds, but flightless.




FIG. 431. Dodo (*Didus ineplus*). Facsimile of Piso's figure, made in 1658. (Courtesy, Knowlton and Ridgway: "Birds of the World," New York, Henry Holt & Co., Inc.)

**Order 17. CUCULIFORMES: Cuckoos;** of medium or small size; mostly arboreal; widely distributed; most of them deposit eggs in nests of other birds. Some 45 genera.

**Order 18. PSITTACIFORMES: Parrots, cockatoos, macaws, parakeets;** tropical and warm latitudes of both hemispheres; some 80 genera. (Sometimes included under Cuculiformes.)

**Order 19. CORACIFORMES:** A large and heterogeneous group broken into several divisions which older classifications usually list as suborders, but which the more elaborate recent classifications raise to the rank of orders. Mainly comparatively small birds, arboreal, short-legged, and good fliers. In the Eastern Hemisphere, **rollers, bee-eaters, hornbills, hoopoes** (Fig. 432); in the Western Hemisphere, **motmots, nighthawks, whippoorwills, hummingbirds, toucans;** in both hemispheres, **kingfishers** (Fig. 433), **owls, swifts, woodpeckers, trogons.**



FIG. 432. Hoopoe, *Upupa epops*, Linnaeus. (Courtesy, Saunders: "Manual of British Birds," London, Gurney & Jackson.)




FIG. 433. Kingfisher, *Alcedo ispida*, Linnaeus. (Courtesy, Saunders: "Manual of British Birds," London, Gurney & Jackson.)

The heterogeneity of this Order is reduced by segregating the following birds into additional Orders: **Owls**, STRIGIFORMES; **oil-birds, goatsuckers, whippoorwills, nighthawks**, CAPRIMULGIFORMES; **trogons**, TROGONIFORMES; **swifts, hummingbirds**, MICROPODIFORMES; **woodpeckers, toucans**, PICIFORMES; **colies** (small finchlike African birds), COLIFORMES.

**Order 20. PASSERIFORMES:** "Sparrow-like" birds; a very large and homogeneous group in which as many as some 7000 species and subspecies have been recognized. Birds of medium or small size, short-legged arboreal perchers and good fliers; most of them songsters of proficiency ranging from that of **crows** and **blue jays** to that of **larks** and **nightingales**. Most of the genera are cosmopolitan: **Sparrows, thrushes, robins, finches, flycatchers, wrens, warblers, swallows, orioles, starlings**, and many others.

#### RELATIONSHIPS

The geologic evidence clearly indicates that reptiles gave rise to flying animals of two very different types. In the **pterosaurs** (Fig. 439) the wing was a broad lateral web of skin stretching from the pectoral limb, whose fourth digit was greatly elongated to support the web, back to the pelvic limb. The pterosaur was presumably cold-blooded and scaly, but certainly not feathered. It had a low carina on the sternum but otherwise, so far as can be judged from the fossil skeletons, its anatomy was not so highly specialized in relation to flight as to forbid classifying it as a reptile. It was a flying reptile just as the modern bat is a flying mammal.

**Birds** also were derived from reptiles—probably from some small terrestrial dinosaur-like animal which had a tendency toward bipedal locomotion. Such reptiles existed. But birds acquired feathers and a complex of specialized features involving all parts of the body. The wing, totally unlike that of the pterosaur, consists essentially of a system of feathers supported by the highly modified pectoral limb. Pterosaurs and birds were probably allied in their remote ancestry, but certainly neither was derived from the other. Birds departed so far from the anatomic pattern of terrestrial reptiles that they must be regarded as forming a distinct Class of vertebrates. But, in view of the reptilian features which birds retain, they are included with reptiles in a "superclass" SAUROPSIDA.

Between the **Archaeornithes** and their terrestrial reptilian ancestors, there must have been a long period of gradual acquisition of avian characteristics. It is highly likely that feathers were acquired before flight was achieved. If feathers make a bird, then there must have been running birds before there were flying birds. It is therefore

pertinent to inquire whether our modern ostrich-like birds may not be persisting primitive types tracing back to a point in that "pre-archaeopterygian" period when flight had not yet been fully achieved. Is it possible that capacity for flight has never existed in the ancestry of "Ratitae"? It seems quite safe to answer this question in the negative. The forelimb of the ostrich is vestigial but it is not a vestigial foreleg. It is definitely a reduced wing. It has, in atrophied form, the essential peculiarities of the wing of a good flier. In numerous other respects, especially in possession of well-developed air-sacs and a considerable degree of pneumaticity in the skeleton (only in the skull in *Apteryx*), the Ratitae, except in degree of development of wings, resemble flying birds and, at least so far as the skeleton is concerned, are very unlike *Archaeopteryx*.

Scanty fossil remains of birds of the ostrich type date back into middle or early Cenozoic time. Flying carinate birds existed in the late Mesozoic, but no evidence that ratite birds existed then has been found. Two notable examples of ratite birds, the **moa** (*Dinornis*) of New Zealand and the **elephant-bird** (*Aepyornis*) of Madagascar, became extinct in comparatively recent times. The moas (Fig. 281), some of them 11 feet tall (or more, according to some accounts), were the largest known birds. Their wings were reduced to trivial vestiges, or, in some cases, no trace of wing-skeleton, including the girdles, can be found. In some of the several species of *Aepyornis*, the birds were of the size of the larger modern ostriches. The wings were vestigial and the legs were of massive build. Although smaller than moas, the elephant-birds laid the largest known eggs. As the story goes, the discovery of skeletal remains of the birds followed recognition of the fact that certain curious domestic utensils used by the Madagascan natives, especially as receptacles for rum, were eggshells. The dimensions of the larger eggs are given as somewhat over 13 inches in long diameter and  $9\frac{1}{2}$  inches in short diameter. *Aepyornis* may have been the gigantic "roc" of Arabian mythology. The remains of both the moa and the elephant-bird are found associated with early human remains in such a way as to make it probable that the birds lived contemporaneously with the early human inhabitants of their respective islands.

Among recent birds are many instances of reduction or loss of capacity for flight, associated with assumption of either terrestrial or aquatic habits of living. The South American **tinamou** has small wings incapable of more than a short, low flight (several hundred yards) and resorts to flight only as a desperate measure. It is a rapid runner, although the legs are short and stout. The sternal carina, however, is fairly well developed. Most of the GALLIFORMES are

sluggish and reluctant fliers, spending most of the time on the ground. The New Zealand **ground parrot** (**Stringops**) has much-reduced wings and a poorly developed sternum with a mere vestige of a carina. The **rails** (**GRUIFORMES**) have moderately long legs and are good runners but poor fliers. In New Zealand there are several species of quite **flightless rails**, and some recently extinct flightless species existed there. Of the same Order are the South American **cariamias**, long-legged runners and reluctant fliers (Fig. 434). Among **COLUMBIFORMES** are the famous **dodo** (Fig. 431) and **solitaire**. Dutch explorers landing on the island of Mauritius (East of Madagascar) in 1598 found the island inhabited by large numbers of a "heavy-bodied, short-legged," and apparently wingless pigeon-like bird somewhat larger than a swan. It proved, however, to have extremely vestigial wings buried under the loose plumage, but no keel on the sternum. Although not good for eating, they were hunted to the point of extinction before the end of the seventeenth century, but immortalized in "Alice in Wonderland." A similar large bird, the solitaire, but of less



FIG. 431. Chunia, or Burmeister's cariana, *Chunia burmeisteri*. (Courtesy, Knowlton and Ridgway: "Birds of the World," New York, Henry Holt & Co., Inc.)

clumsy proportions than the dodo, was found in a neighboring island, Rodriguez, at about the same time and suffered extermination by man before the end of the eighteenth century.

On assuming aquatic life, the bird's adaptive complex becomes triangular, involving relations to air, water, and land. Increase in the adaptation of the locomotor mechanism to aquatic activities is at the cost of facility of motion in the air or on land, or both, inasmuch as swimming and diving may be effected by use of either the wings, the legs, or both. It is to be noted, however, that, while the wings may be vestigial or lacking, the legs, even if highly adapted for swimming, must remain capable of taking the bird ashore. Birds' eggs must be laid on land and must develop in air. The **albatross** and **petrel** (PROCELLARIIFORMES: Fig. 425) and the **gulls** and **terns** (CHARADRIIFORMES) retain efficiency at all three points of the triangle. The wings, not used in swimming, remain capable of strong and long-sustained flight. The bird floats lightly and by use of large webbed feet swims easily but not swiftly. On shore the legs serve well enough for birds not given to hopping or running. In ANSERIFORMES the feet are more highly adapted for swimming, to the detriment of the walking gait, which becomes the waddle of the duck. The wings remain unimpaired as organs of flight. The **loon** (COLYMBIFORMES: Fig. 424) is a marvelous swimmer and diver and an especially strong flier, but very clumsy ashore. In the **auks** (CHARADRIIFORMES) the wings, which are relatively short and rounded, are used as paddles in swimming and are correspondingly less well adapted for flight. The birds are slow and heavy fliers. In the "**great auk**" of the North Atlantic, extinct since about 1850, the wings had become so highly specialized for swimming that they were quite incapable of flight. This condition in the northern great auk finds a close parallel in the antarctic **penguin** (SPHENISCIFORMES: Fig. 423), whose wings are functionally flippers or fins. The feathers on the wings are reduced to short, compactly arranged, almost scalelike structures. In these quite flightless birds the very short legs are set far back on the body and the big feet, fully webbed, are used for steering. In swimming and diving these birds rival fishes, but as pedestrians they are pitifully (and laughably) incompetent.

Exceptional are aquatic birds whose wings are so reduced as to be capable of neither flight nor swimming, the webbed feet serving as paddles. Such a bird is the flightless "**Harris' cormorant**" of the Galápagos Islands. Another example is the extinct Cretaceous **Hesperornis** (Fig. 418), a gigantic (nearly 4 feet long) loonlike swimmer and diver but with only trivial vestiges of wings. There is a certain parallel



between *Hesperornis* and the dodo. The attainment of bulk and weight so great as to be incompatible with good flying was associated with terrestrial living in the dodo and with aquatic living in *Hesperornis*—and both suffered extinction. The flightless cormorant, too, is the largest of the cormorants.

It is certain that these adaptations for terrestrial or aquatic living, accompanied by reduction or loss of capacity for flight, must have had origins widely separated from one another in time, space, and genetic relation. The modern orders of birds have become differentiated since the Cretaceous. The aquatic modifications of *Hesperornis*, the antarctic penguin, and the great auk of the North Atlantic cannot be of common genetic origin. The dodo, a flightless pigeon-like bird, is no more closely related to ostriches than are flying pigeons. Flightless rails must have been derived from flying rails, Harris' cormorant from flying cormorants. The "steamer duck" of southern South America is an especially large seagoing duck which, while young, is able to fly, but whose body eventually acquires size and weight disproportionate to the spread of wings, so that flight becomes impossible. The wings, however, are used as paddles as the bird floats on the water—a mode of propulsion suggesting the old-fashioned "side-wheel" steamer. This case is significant in that, within the lifetime of the individual animal, a flightless bird is derived from a flying bird. The young bird is a typical duck but the adult, in being flightless and using the wings as paddles, simulates a penguin.

Both the reptiles and the birds strikingly exhibit that common propensity of living things for such adaptive diversification as enables them to occupy environments of maximum extent and variety. Reptiles were primarily land animals but, in the course of time, many of them assumed aquatic life and a few became flying reptiles. Other descendants of reptiles became flying birds but, in the course of time, descendants of flying birds reverted to terrestrial living or assumed aquatic living and became flightless, yet retaining so many of the basic anatomic peculiarities of their flying ancestors that we cannot regard them as anything but birds.

In these terrestrial and aquatic adaptations, birds show numerous and striking instances of **convergence in evolution**. Flightless terrestrial birds can persist only in an environment where large carnivorous mammals are few or lacking. Of all localities, New Zealand, an island quite devoid of native carnivorous mammals, is richest in flightless birds, some aquatic and many terrestrial, representing various Orders.

The **Class Aves**, in two respects, stands at the apex of the chordate series. In the bird's adaptation for flight, the vertebrate structure reaches an extreme of specialization only approached, but scarcely equaled, by some bony fishes. The activities of birds, characterized by a complexity and a degree of adaptiveness which give them deceptive resemblance to intelligent action, mark the peak of development of instinctive behavior.

---

## ORIGIN—GENERAL CHARACTERISTICS

Lungs and pentadactyl limbs make possible for most amphibians terrestrial life of a very restricted sort. But aside from lungs and legs—and some fishes have lungs—amphibians are ichthyopsidan. Their delicate mucous skin compels them to live in moist places. Their aquatic larval stage forbids them to wander far from ponds and streams. Reptiles, replacing external mucus by the dry, impervious protective stratum corneum, are able to withstand dry air. The reptilian egg, deposited on land, develops an equipment of membranes which serve for the protection, nourishment, and respiration of the young animal, thus enabling it to attain an advanced stage of development and growth before hatching. Therefore reptiles, relieved of all necessity for living near bodies of water, were able to disperse themselves widely and become dominant terrestrial animals. Secondarily, however, some of them reverted to aquatic life and some acquired the power of flight. Birds, sauropsidan in a general way, elaborated the stratum corneum into feathers, transformed the pectoral limb into a wing, and stabilized internal temperature at a high level, thus achieving that perfection of aerial locomotion which opened to them new realms of living.

With fishes perfectly adapted to aquatic life, reptiles capable of acquiring mastery of the earth's land surfaces, and the air well populated by birds, it would seem that the vertebrates had fulfilled all possibilities. But something went wrong with reptiles. In late Mesozoic times they suffered a rapid decline, and only a feeble remnant survives to the present. Geologic evidence gives no fully satisfying explanation of the cause of the decline. Changes in configuration of land surfaces; falling temperature; reduced atmospheric moisture; nature of vegetation altered to the disadvantage of the herbivores and thus indirectly

affecting the carnivores; too prolific reproduction, overpopulation, crowding, and famine, perhaps inducing preying of carnivores upon one another—some combination of these circumstances must have upset the biologic balance and precipitated the almost total reptilian disaster.

In Mesozoic times the earth's surface was much warmer than now. Presumably, ancient reptiles were poikilothermous. In "cold-blooded" animals metabolism is slow. Relatively little internal heat is produced. The reptilian skin affords little protection against loss of heat. For maintenance of an internal temperature adequate for metabolism, the reptile is largely dependent on the external medium. Reptiles flourish in a tropic climate. At present, the larger reptiles—crocodiles, pythons, giant monitor lizards—occur only in the tropics and warmer temperate zones. In cooler temperate latitudes reptiles are smaller and fewer. In the polar regions there are none.

This relation of size to temperature is a matter of geometry. In similarly shaped bodies of varying size, surface varies with the square, and volume with the cube, of linear dimension. The large reptile has relatively much less surface than the small one. At the surface of the animal, heat may be either absorbed or lost, depending on the relative internal and external temperatures. If, after a cool night, a 6-inch lizard and a 12-foot alligator are lying in the warm morning sunshine, the lizard will become warmed through much sooner than the alligator. It was the world's extensive areas of warm climate that made possible the spectacular Age of Reptiles. If reptiles had not appeared until the late Mesozoic, probably there would never have been an Age of Reptiles.

The lower temperatures of the Cenozoic restricted to the earth's warmer zones such large reptiles as had survived the late Cretaceous disaster. But, while the gigantic and masterful Mesozoic reptiles were passing out, the birds, only recently (in geologic time) arrived, not only survived but increased, and in the course of time adapted themselves to diverse environments. This they were able to do because they had become homothermous. If that far-reaching occupation of the earth's land surfaces which had been attained by reptiles was to be retained by vertebrates during a cooling age, the two essential requirements were warm-bloodedness and a method of reproduction which would obviate exposure of the developing young to the hazards of environmental temperatures. These requirements were, in fact, met by birds (for it seems a safe assumption that high temperature and feathers were acquired together), and from early avian times down to the present there have been some birds which, incapable of flight, have lived as biped land animals. But the entire structure of birds had become so

extremely specialized in connection with aerial locomotion that they could never have realized all the possibilities of terrestrial living unless they had undergone an anatomic remodeling so profound that the result must have been something other than a bird. At this critical juncture in the history of vertebrates, mammals began to come into prominence.

### EARLY MAMMALS

Mammals, like reptiles, are and always have been mostly terrestrial. It is therefore not to be expected that quadruped mammals should differ anatomically from reptiles to such an extent as do birds, whose capacity for flight requires drastic and far-reaching modification of the basic vertebrate structure. The characteristics of mammals consist of numerous relatively inconspicuous anatomic peculiarities which, however, combine to improve and refine—as compared to reptiles—the animal's adaptation to terrestrial life. Most notable among these are the high and stable temperature of the body, hair, placental viviparous reproduction, and mammary glands. Unfortunately these are all characteristics concerning which fossils yield little or no information. In the case of mammals, the geologic record has produced nothing so spectacular as *Archaeopteryx*, that halfway stage in the origin of birds.

Knowledge of the remote past of mammals can be derived only from fossil skeletons and teeth. The skeleton of a modern terrestrial mammal differs from that of a reptile in various particulars, of which some of the most significant pertain to the skull. There is considerable reduction in number of skull-bones, due in part to fusion of some bones which are distinct in reptiles. A **secondary** or “**false**” **palate** is formed by development of a bony partition separating the primitive mouth-cavity into an upper portion, which becomes functionally a backward continuation of the nasal cavities, and a more capacious lower part, which is the definitive oral cavity (Fig. 435). The partition, the “**hard palate**,” arises by ingrowth of thin bony plates from bones of the upper jaw (maxillary and palatine), the corresponding plates from opposite sides meeting and joining in the median plane. This “**false**” palate, however, is not exclusively characteristic of mammals, for a similar structure occurs in crocodylians.

The articulation between the skull and the vertebral column in mammals is effected by a **pair of occipital condyles**, rounded protuberances situated at either side of the foramen magnum through which the spinal cord emerges from the cranium. In all modern reptiles, also in birds, there is a single median condyle ventral to the foramen magnum. Modern amphibians have a pair of condyles, but the earliest known amphibians and reptiles had the single median condyle.

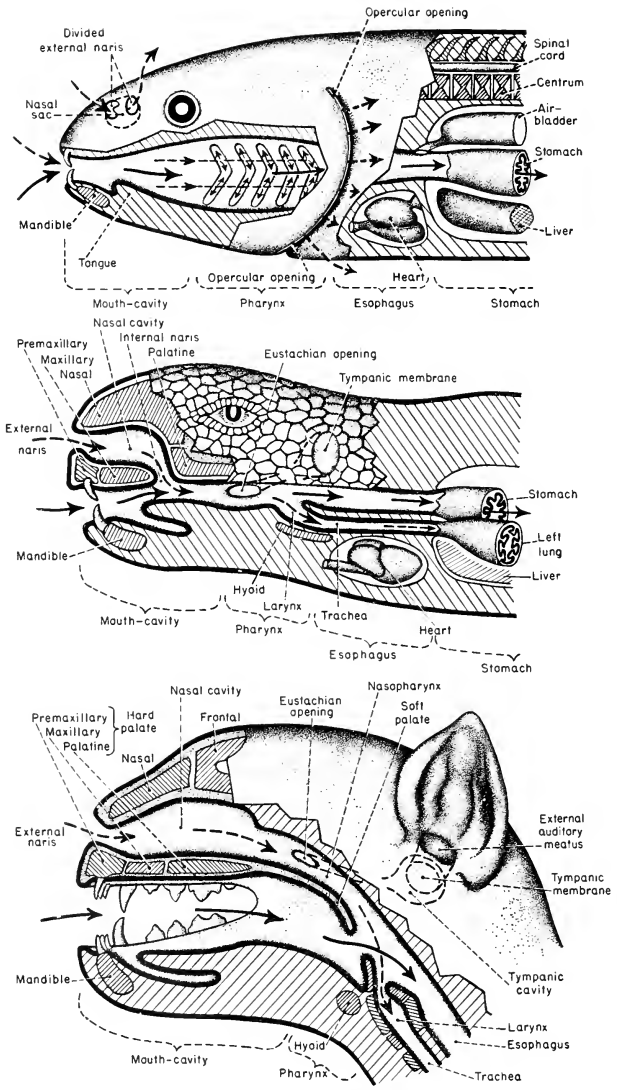


FIG. 135. Alimentary and respiratory passages of fish (top), reptile (center), and mammal (bottom). The solid arrows indicate alimentary and the broken arrows respiratory passages.

Especially characteristic are peculiarities of the mammalian jaw and of the closely adjacent bony mechanism of the ear. In modern **reptiles** the joint between lower and upper jaw is between the **articular**, a bone formed by ossification of the posterior end of the embryonic cartilaginous lower jaw, and the **quadrate**, a cartilage bone of the upper jaw. The squamosal, a dermal bone, adjoins the quadrate but has no part in the joint (Fig. 436A). In adult **mammals** the lower jaw is composed entirely of dermal bone and articulates with a bone which unmistakably corresponds to the reptilian **squamosal** (Fig. 436B). The definitive **upper jaw** contains no bone recognizable as a quadrate, and there is no articular in the lower jaw. In the reptilian ear the tympanic membrane is connected with the bony wall of the auditory capsule by a single skeletal structure (partly cartilaginous, partly bony), the **columella**. In mammals the connection between tympanic membrane and auditory capsule is by means of a jointed chain of three ossicles, the **malleus**, **incus**, and **stapes** (see Fig. 518).

**Mammalian teeth** exhibit a highly characteristic differentiation (Fig. 436B). In vertebrates other than mammals, with rare exceptions, the teeth are of simple form and, in a given species of animal, they are of the same form on all regions of the jaws—the condition known as **homodont**. But in most mammals there is local differentiation of teeth—a **heterodont** condition. At the front of the jaws are sharp-edged cutting teeth (**incisors**) in each jaw. At either end of the row of incisors there is a characteristic conical or pointed tooth (**canine**), best developed in carnivores. Behind each canine is a series of "cheek-teeth," **premolars** and **molars**, usually of heavier build and variously

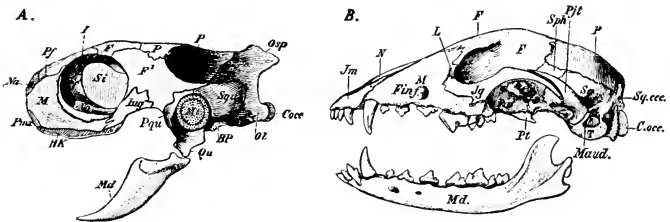


FIG. 436. (A) Skull of turtle, *Emys*. (B) Skull of dog. (BP) Cartilage; (C. occ.) occipital condyle; (F) frontal; (F<sup>1</sup>) postfrontal; (F<sup>inf</sup>) infraorbital foramen; (HK) horny sheath on jaw; (I) olfactory foramen; (Jq, Jug) jugal; (Jm) premaxillary; (L) lacrimal; (M) maxillary; (Maud.) external auditory meatus; (Md) mandible; (Mt) tympanic membrane; (N) nasal; (Na) nostril; (Ol) exoccipital; (Osp) supraoccipital; (P) parietal; (Pf) prefrontal; (Pjt) jugal (zygomatic) process of temporal; (Pmx) premaxillary; (Pqu) quadratojugal; (Pt) pterygoid; (Qu) quadrate; (Si) interorbital septum; (Sph) alisphenoid; (Sq, Squ) Squamosal; (Sq. cc.) Supraoccipital; (T) tympanic bulla of temporal; (Vo) vomer. (Courtesy, Wiedersheim: "Grundriss der vergleichenden anatomie der Wirbeltiere," Jena, Gustav Fischer.)

differentiated for crushing or chewing food. The degree and character of the differentiation of the several types of teeth varies greatly in the numerous orders of mammals and is one of the most important characteristics used in defining the groups. These peculiarities of skull and teeth have been most important in making possible the recognition of mammalian fossils.

The **history of mammals** has been traced, so far as the main facts are concerned, in a fairly satisfactory way as far back as the latter part of the Mesozoic. The fossil material is, so far, much more abundant than that of birds. Earlier Mesozoic strata have as yet yielded only scanty and fragmentary mammalian material—mostly incomplete skulls and teeth—but it is unquestionably mammalian, so far as can be judged from skeletal parts and teeth. It is likely, therefore, that mammals came into existence in the Triassic Period, probably in the early part of it. It is just here that facts of special significance come to light.

The earliest known reptiles (**cotylosaurs**), some of them hardly distinguishable from amphibians, are found in the Permian. Their skulls are of the **anapsid** type (see p. 501), and the **occipital condyle** is **single**. As the primitive group began to differentiate, there appeared some animals which, while unquestionably reptilian, yet had some peculiarities suggestive of mammals—hence called **Theromorpha**, meaning “mammal-like.” The skull was of the **synapsid** type (Fig. 394). In some later (Triassic) theromorphs, the **Therapsida**, there were **two occipital condyles**. In some of these “mammal-like” reptiles there was a rudimentary **secondary palate**, incomplete posteriorly because the right and left palatine bones were not fully joined in the median line. But **Cynognathus** (Fig. 437B), a Triassic therapsid, had a complete and distinctly mammalian secondary palate. The theromorphs retained the reptilian joint between the articular of the lower jaw and the quadrate of the upper, but in *Cynognathus* and others the quadrate was very small and apparently not firmly joined to neighboring bones, while the dentary, chief dermal bone of the lower jaw, was greatly enlarged, at the expense of other bones of the lower jaw, and came into such close relation to the squamosal as to indicate that the dentary and squamosal must have served to augment the joint between articular and quadrate. The tympanic mechanism, however, is reptilian, only a single auditory ossicle, the columella, being present.

The earlier theromorphs show a tendency toward a heterodont dentition, and in some of the later (Triassic) therapsids, such as *Cynognathus*, the dentition is definitely of the mammalian pattern and



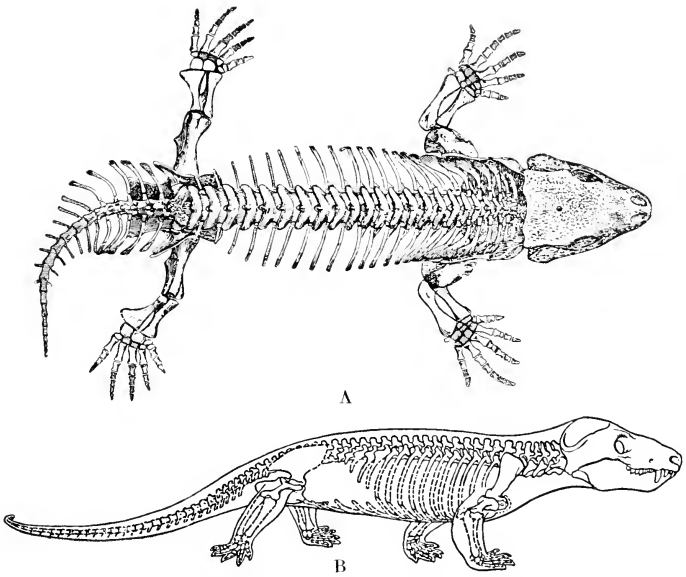


FIG. 437. (A) Skeleton of *Seymouria*, in dorsal view; original about 20 inches long. It is uncertain whether *Seymouria* should be regarded as a very primitive reptile (a cotylosaur) or as a somewhat reptilian amphibian. (After Williston.) (B) Skeleton of the Lower Triassic cynodont *Cynognathus*. (After Gregory and Camp.) (Courtesy, Romer: "Vertebrate Paleontology," Chicago, University of Chicago Press.)



FIG. 438. (Left) Alligator. (Right) Australian dog, dingoo. In most lower tetrapods the short legs sprawl and the animal crawls. In most mammals the longer legs, with elbow-bend pointing backward and knee-bend pointing forward, are adapted for speed and agility. (Left, courtesy, Ditmars: "The Reptile Book," New York, Doubleday & Co., Inc. Right, courtesy, Museum of Comparative Zoology, Harvard University.)

there is some evidence that the animal had two successive sets of teeth, early "milk-teeth" later replaced by a permanent dentition, as in most modern mammals. In vertebrates other than mammals a tooth is relatively temporary. Loss and replacement of a tooth occurs repeatedly.

The **legs of theromorphs** resembled those of mammals. In typical quadruped amphibians and reptiles, the legs are relatively short, project laterally outward from the body, and do not raise the body off the ground. *Cynognathus*, found in the early Triassic of South Africa, was an animal 4 feet or more in length. Its legs were relatively longer and more slender and must have raised the body well above the ground. Instead of projecting laterally, the foreleg is rotated backward at the shoulder-joint so that the bend at the elbow-joint points backward, while the hindleg is rotated forward at the hip-joint so that the bend at the knee points forward as in modern mammals (Figs. 437, 438). The result is to bring the support more nearly directly underneath the body and the several joints are brought into positions which greatly facilitate speed and agility.

It would be of utmost interest if we could know whether these theromorphs were scaly or hairy. Or were they covered by something intermediate between horny scales and hair? Were they warm-blooded? How did they reproduce? Did they have mammary glands? Probably answers to these questions can never be obtained. As for reproduction, however, it is very likely that it was typically reptilian, because even now there are mammals which "lay eggs" and in all respects reproduce in the reptilian manner.

It can hardly be said that fossils show us an uninterrupted series transitional between typical reptiles and typical mammals. It is an undeniable fact, however, that the skeletons of certain ancient vertebrates, while for the most part distinctly reptilian, yet possess some of the most characteristic features of mammalian skeletons. It is true also that in regard to some of these mammalian features—the secondary palate, the jaw-joint, and the teeth—the theromorphs show a graded series which progresses from the reptilian toward the mammalian condition.

The chronology of the groups is significant. Theromorphs, so far as is known, first appear in the Permian. In the Triassic they reached their height in diversity of species and were widely distributed. Their remains occur most abundantly in North America and South Africa, but have been found also in South America, Europe, and Asia. But the group seems to have died out before the end of the Triassic. The earliest fossils which are certainly mammalian occur in the late Triassic of South Africa and Europe. They represent small animals which, judging from skulls and teeth, must have resembled modern rodents.

Incisors were strongly developed and sharp-edged. There were no teeth in the position of canines. The molars were large and surmounted by numerous pointed protuberances or "cusps"—wherefore the group is called **Multituberculata**. The group persisted through the Mesozoic and into the early part of the Cenozoic Age.

Taken all together, the established facts indicate that, in Triassic times and along a line of relatively small and somewhat primitive reptiles, mammalian characteristics were gradually acquired. Toward the latter part of this period and for reasons at present not definitely known, the reptiles which were merely "mammal-like" in some particulars perished, while certain of their contemporaries which had acquired more nearly the full complement of mammalian characteristics survived. Most important for survival were the more efficient locomotor mechanism, in all probability some degree of warm-bloodedness and control of body temperature associated with possession of hair, improvements in the sensory apparatus, and a brain necessarily more highly developed in connection with the possession of improved sensory and motor mechanisms. Having, then, the advantages of superior speed and agility and the capacity for a wider range of favorable reactions to external conditions, these early mammals survived through a long period which was the "golden age" for reptiles but a time of extraordinary peril for other vertebrates. Apparently the mammals did little more than merely survive. They remained obscure and small animals, most of them less than a foot long. No doubt their chief concern was to keep out of the way of their gigantic but clumsy reptilian contemporaries, and in this their smallness, speed, agility, and better brains must have served them well. Even so, it is likely that they suffered much from the carnivorous reptiles. Fossil Mesozoic mammals are very rare. It may well be that a fossil carnivorous reptile accounts for many mammals which escaped fossilization because they had been eaten by the reptile.

Toward the close of the Mesozoic, the scene begins to change. Reptiles are on their way out. After long ages of mere survival in a world dominated by reptilian monsters, the mammals, hitherto obscure and "meek," begin to "inherit the earth." The incoming of the Cenozoic Age finds the mammals well started on their career as a Class, becoming larger and stronger and undergoing a diversification destined to give them world dominance and make the **Cenozoic an Age of Mammals**.

The **evolutionary differentiation of mammals**, in its main lines, repeats that of reptiles. Beginning as small, obscure, indifferently specialized land animals, the group expanded and became highly

diversified. Most of its members remained terrestrial, but some acquired burrowing habits (fossorial) and others became arboreal. Still others reverted to water, becoming amphibious (seals) or wholly aquatic (whales), and the aerial bats are the mammalian equivalent of Mesozoic reptilian pterodauctyls (Fig. 139).

In **adaptation to climates**, the homothermous mammals did what the reptiles could not: mammals range from the equator to the polar regions. It is to be noted, however, that in the colder latitudes it is the larger mammals that have the advantage, whereas the larger reptiles inhabit the warmer regions. It is, in both, a matter of the relation of surface to volume. In a cold climate the necessity of conserving internal heat gives the advantage to the larger mammal because of its

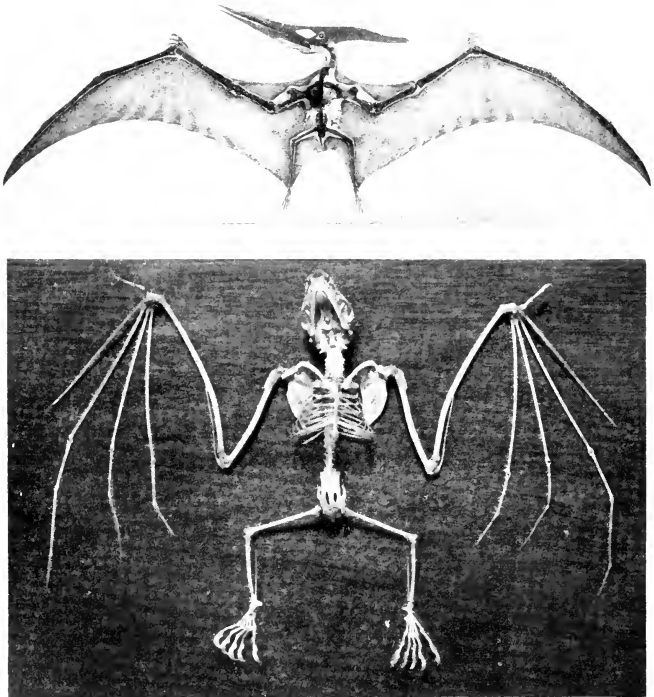


FIG. 139. (Top) Skeleton of a pterosaur, *Pteranodon*. (Bottom) Skeleton of bat. (Top, courtesy, American Museum of Natural History, New York. Bottom, courtesy, Ward's Natural Science Establishment, Inc.)

relatively small surface. The reptile must obtain most of its heat from outside; the smaller animal has a relatively larger surface. If external temperature is so low that the heat necessary for metabolism cannot be obtained, the reptile must hibernate or die. Some mammals hibernate, but it is perhaps not unfair to them to describe it as an easy and lazy way of getting through the cold season. The more energetic mammals keep their internal fires effectively burning and maintain full activity through even an arctic winter.

Mammals have become adapted to living at external pressures ranging from that at sea-level to that at mountainous altitudes, and some whales can withstand the enormous pressures met in diving to submarine depths of perhaps a mile.

In size (Fig. 440), mammals range from the mouse and the even smaller insect-eating shrews, some only an inch long exclusive of tail, to the rorqual, a baleen whale which "approaches a length of 100 feet" (A. B. Howell: "Aquatic Mammals").

Their diets are most varied. Many are vegetarian, each addicted to a particular kind or part of the vegetation—grasses, grains, herbs, roots, bark, foliage, fruit. Some eat ants or other insects. Many eat their fellow vertebrates—"fish, flesh, or fowl." In short (but in long words), they are **herbivorous**, **frugivorous** (fruit-eating), **insectivorous**, **myrmecophagous** (ant-eating), **carnivorous**, or **omnivorous**. The nature of the mammal's diet is accurately reflected in the specialization of the teeth and the digestive organs.

Mammals use their legs in most varied ways. They walk, run, hop, leap, climb cliffs or trees, glide or parachute from tree to tree, swing from branch to branch by the forelegs, go erect on the hindlegs, walk flat-footed or on tiptoe. Some dig burrows or dig up roots with the forelegs. A squirrel uses the forepaws to hold a nut against the teeth.

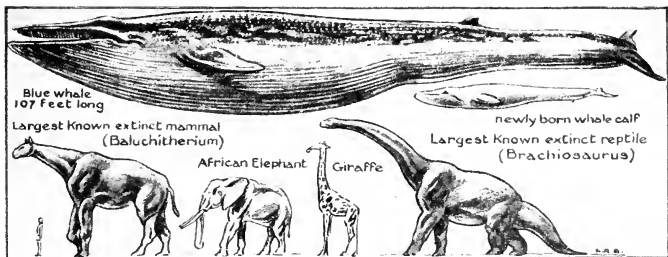


FIG. 440. Relative size of mammals. Several mammals and, for comparison, one of the largest reptiles are represented, all drawn to the same scale. A mouse on this scale would be microscopic. (Courtesy, American Museum of Natural History, New York.)

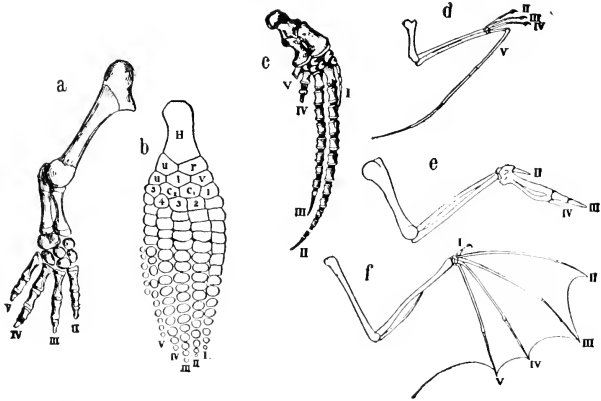


FIG. 441. Modifications of the forelimb. (a) *Neoturus*, a salamander. (b) *Ichthyosaurus*, an extinct marine reptile. (c) *Globicephalus*, a cetacean (dolphin). (d) Pterodactyl, an extinct flying reptile. (The digits were probably I-IV, not II-V as shown by Wilder.) (e) Bird. (f) Bat.

(a) represents a slightly modified limb skeleton—one digit lacking; (b) and (c), limbs modified for swimming; (d), (e), and (f), those modified for flight. (H) Humerus; (r) radius; (u, articulating with H) ulna; (I-V) digits. In (b) a typical carpus may be recognized: three proximal bones (v.i.u), five distal bones (1-5), and two centralia (c<sub>1</sub>, c<sub>2</sub>). (Courtesy, Wilder: "History of the Human Body," New York, Henry Holt & Co., Inc.)

Certain omnivorous bipeds use the forepaws to hold a knife and fork by which they manipulate their food. And some mammals swim, dive, or fly. In speed of locomotion they range from the arboreal sloth which, on the ground, merely crawls along, to the horse, greyhound, and antelope, and the cheetah, a long-legged Asiatic and African catlike carnivore, which can overtake an antelope. For each of these many modes of use, the legs are anatomically adapted (Fig. 441).

In **general mode of life**, some mammals—especially the smaller and the herbivorous—are timid and retiring in disposition. Others are powerful, predacious, and, in general, aggressive. Still others, such as the elephant, hippopotamus, and other large herbivores, by virtue of great bulk of body and a thick hide, have no need of being timid and retiring, yet ordinarily are not aggressive.

#### TYPES OF MAMMALS

Every animal must be anatomically fit for a particular environment, diet, mode of locomotion, and pattern of behavior. Mammals, emerging from the reptile-dominated Mesozoic Age, advanced into a friendlier Cenozoic which gradually opened up before them an almost

unlimited range of possible modes of living. For each mode a specific anatomic complex must be achieved. A survey of the present world's mammals shows that they have gone far in realizing these possibilities. If their thousands of species (whether 6,000 or 18,000 is a matter of opinion) are passed before us in review, a mere casual inspection, without detailed anatomic consideration, suffices for recognition of a relatively small number of well-marked types which may be briefly distinguished as follows:

Two mammals of the Australian region, the **duckbill (Ornithorhynchus; Fig. 532)** and **spiny anteater (Echidna; Fig. 533)**, unique in being egg-laying; also in having only one posterior opening, the cloacal aperture—hence called ..... **Monotremes.**

Numerous mammals found only in the Australian region (e.g., **kangaroos**) and a few American mammals (**opossums**) whose young are born at an early fetal stage and then reared in an external pouch (marsupium) formed by the skin of the mother's abdominal wall (Figs. 534, 539): ..... **Marsupials.**

Small, relatively unspecialized, mostly insectivorous; e. g., the burrowing **moles** and the **hedgehogs**: ..... **Insectivores.**

Mostly small and herbivorous; strong, chisel-like gnawing incisors; **rat, mouse, squirrel, beaver, porcupine**: ..... **Rodents.**

Flying mammals; mostly insectivorous, some frugivorous: ... **Bats.**

Teeth lacking or poorly developed; external armor of bony or horny scales in some; **armadillo, sloth, South American anteaters, pangolin** (Figs. 552-555): ..... **Edentates.**

Large herbivores, most of them having only one or two functional digits on each foot, each digit bearing a horny hoof; **horse, pig, ox, sheep, deer, elephant, coney (Hyrax)**: ..... **Ungulates.**

Large aquatic herbivores; Atlantic and Pacific **sea cows** (Fig. 577): ..... **Sirenians.**

Large, aquatic; fishlike in external form: **whale, porpoise, dolphin**: ..... **Cetaceans.**

Teeth specialized for eating flesh; **dog, wolf, cat, tiger, bear, seal, walrus**: ..... **Carnivores.**

Mostly arboreal; no extreme anatomic specialization; **monkeys**, more or less monkey-like **lemurs, chimpanzees** and other large **apes**—and, regarded anatomically and impartially, the **human mammal** must be included here among ..... **Primates.**

More extended and precise definitions of the various types of mammals can be given after the anatomic peculiarities of mammals have been discussed.

*General Form*

Typical terrestrial mammals differ considerably from quadruped reptiles (leaving Chelonia out of account), as to their general form. The trunk in mammals is relatively shorter, the neck longer and more slender, and the tail is so much reduced in diameter that it appears more as a slender appendage of the trunk instead of a postsacral continuation of it as in most amphibians and reptiles. The legs are relatively longer and are so placed (see p. 566) that the elbow-joint points backward and the knee-joint points forward. The most striking internal difference is the division of the mammalian coelomic space into two major cavities, the **abdominal** (posterior) and the **thoracic** (anterior), by a transverse muscular (therefore contractile) partition, the **diaphragm** (Fig. 17). When relaxed, the diaphragm is convex anteriorly. Its rhythmic contractions are an important part of the mechanism of breathing. The thoracic space includes the median **pericardial cavity** and a pair of **pleural cavities** containing the right and left divisions of the lungs.



## SKIN

The skin has the same basic structure as in other vertebrates but has some elaborately specialized features, although they include no structure so complex as a feather (Fig. 442).

**Hair** is as characteristic of mammals as feathers are of birds. A hair is a comparatively simple filamentous horny structure, a modification of the stratum corneum and therefore wholly epidermal (Fig. 443). The root of a hair is contained in an epidermal follicle. Small strands of nonstriated muscle-fibers attached to the deeper part of the follicle make possible the erection of the hair—as in response to cold or fright. The statement that all mammals possess hair comes dangerously near to having some exceptions. Hair is scanty on such large thick-skinned animals as the hippopotamus and elephant. In sea cows (*Sirenia*) and the whalelike mammals (Cetacea), the adults are nearly or quite devoid of hair. The fetus, however, usually possesses some hair, or at least a few short, stiff bristles, especially about the mouth. It has been claimed, however, that the fetus of the narwhal (*Monodon*) and of the white whale (*Delphinapterus*) are quite hairless.

**Horny scales** resembling those of reptiles occur in some mammals—on the feet and tail of some marsupials, insectivores, and rodents; over the entire body in the pangolin (*Manis*). In most mammals **horny claws** on the digits are strongly developed, but in some the stratum corneum at the tip of the digit is elaborated into a massive **hoof**, while in man, apes, and usually in monkeys, it acquires the form of a flat **nail** (Fig. 444). In many hoofed mammals (Ungulata) the head bears so-called “**horns**,” but only the outer layer of the “horn” is horny, the core being dermal bone. **Antlers** in the deerlike ungulates are, when fully developed, entirely bony (Fig. 445).

In the armadillo (*Dasypus*; Fig. 554) there are vestigial horny scales underlaid by massive dermal **bony plates** which constitute a

heavy armor investing the dorsal and lateral surfaces of the animal. The occurrence of small bony plates in the skin of some cetaceans has been asserted and denied. Otherwise, bony scales are not known to occur in mammalian skin.

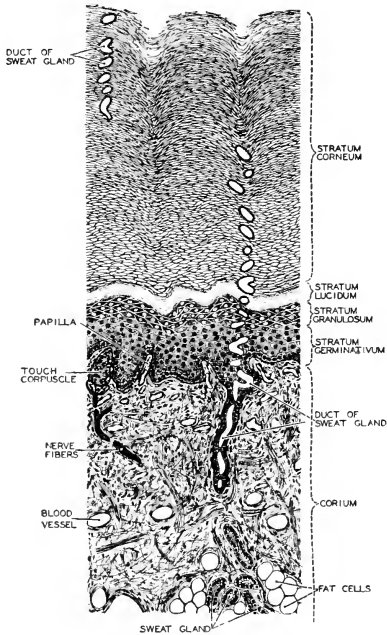


FIG. 442. A section of the thickened skin of the human sole. The stratum corneum is especially thickened on the sole and on the palm of the hand. (Courtesy, Neal and Rand: "Chordate Anatomy," Philadelphia, The Blakiston Company.)

In striking contrast to reptilian skin, the skin in most mammals is **richly glandular**. The glands, however, are not the primitive mucous glands. Mucus and hair would not combine to advantage. In mammals the glands of the general integument are the tubular **sweat-glands** (Fig. 446), secreting a more or less abundant watery fluid, and the alveolar **sebaceous glands**, usually attached to the follicles of hairs and secreting an oily substance (Fig. 443). These secretions protect the skin from becoming unduly dry and keep it soft and pliable. In

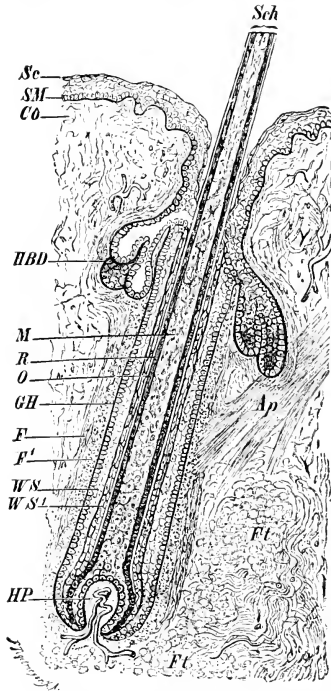


FIG. 443. Section of hair. (*Ap*) Erector muscle; (*Co*) dermis; (*F*, *F'*) layers of longitudinal (outer) and circular (inner) connective-tissue fibers; (*Ft*) fat; (*GH*) hyaline layer; (*HBD*) sebaceous gland; (*HP*) dermal papilla containing blood-vessels; (*M*) medulla; (*O*) cuticle of shaft; (*R*) cortex; (*Sc*) stratum corneum; (*Sch*) shaft; (*SM*) germinative layer of epidermis; (*WS*, *WS'*) outer and inner layers of epidermal sheath of follicle. (Courtesy, Wiedersheim: "Grundriss der vergleichenden Anatomie der Wirbeltiere," Jena, Gustav Fischer.)

mammals in which perspiration is produced in sufficient quantity and whose fur is not so thick as to interfere with ready evaporation at the surface of the body (e.g., horse and man), the sweat-glands play an important part in the regulation of the temperature of the body. The oily secretions check absorption of external water by the skin and fur.

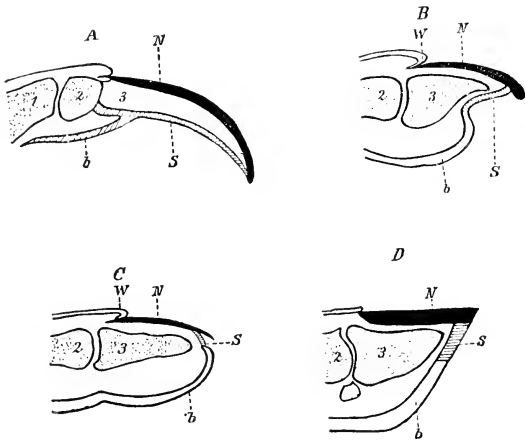


FIG. 44. Diagrammatic longitudinal sections through the distal ends of the digits of (A) *Echidna*, (B) an unguiculate mammal, (C) man, and (D) a horse (1-3) Phalanges; (b) torus; (N) nail-plate (unguis); (S) sole-horn (subunguis); (W) bed of claw or nail. (After Gegenbaur and Boas, from Wiedersheim [Parker]: "Comparative Anatomy of Vertebrates." By permission of The Macmillan Company, publishers.)

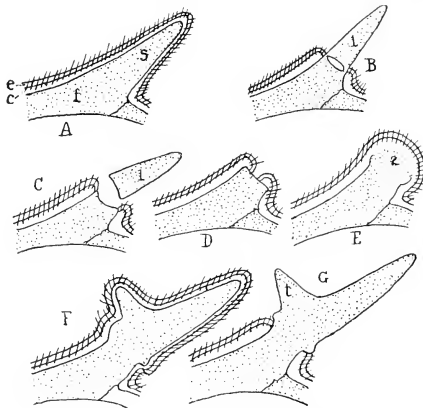


FIG. 445. History of antler of deer (Nitsche in Weber). (A) First appearance of spike on frontal bone. (B) Skin retracted from spike, latter with resorption sinus at base. (C) Loss of spike. (D, E) Stages of development of antler of second year; covering of pedicel with skin; outgrowth of antler, continued in (F) with axis and tine of new horn shown, all covered with skin and hair ("velvet"). (G) Skin lost from antler. (c) Dermis; (e) epidermis with hair; (f) frontal bone; (s) spike; (t) tine; (1, 2) antlers of first year and second year. (Courtesy, Kingsley: "Comparative Anatomy of Vertebrates," Philadelphia, The Blakiston Company.)

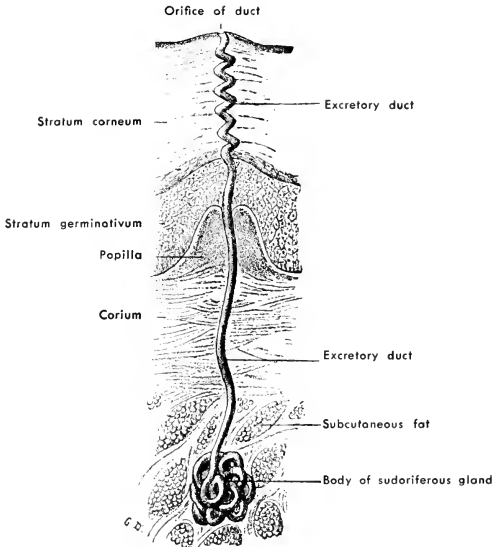


FIG. 446. Section of the human palmar skin showing an isolated sweat-gland. (After Testut. Courtesy, Schaeffer: "Morris' Human Anatomy," Philadelphia, The Blakiston Company.)

In aquatic mammals, sweat-glands and sebaceous glands are more or less reduced or entirely lacking.

There are also various localized and specialized glands, such as wax (**ceruminous**) glands in the external ear, **tear (lacrimal) glands**, and various **scent-glands**, usually anal in location (e.g., in the skunk). The **mammary glands** are highly specialized integumentary glands situated in paired organs on the ventral surface of the body, secreting milk for nourishment of the young after hatching or birth. These milk-glands are the especially distinctive glands of mammals.

**Mammary Organs.** A mammary organ consists of one or more **milk-secreting glands** whose ducts, except in monotremes, open upon or into an externally protruding **nipple** or **teat**. A milk-gland is usually of the alveolar type (said to be tubular in monotremes) and always so elaborately branched that a single gland becomes a large mass of secretory tissue. When several such glands are present in one mammary organ, they form a bulky mass lodged in the dermal and subcutaneous layers and causing an external elevation of the skin. But

the entire gland, however deeply it may penetrate, is of epidermal origin. A mouse usually has only 1 gland at each nipple; carnivores have 5 or 6 per nipple; man, 15 to 20. The interstices of the glandular tissue are filled by richly vascular connective tissue.

The early embryo of a mammal develops a pair of "**milk-lines**," each being an ectodermal thickening or ridge which extends ventrolaterally from the axillary region to the groin (Fig. 447). The paired mammary organs develop at intervals along these milk-lines. The number and location of the definitive organs is highly variable among the several orders of mammals. In general, the number varies with the number of young in a litter, ranging from a maximum of 11 pairs in a Madagascar hedgehog, *Centetes* (an insectivore) to a single pair in such large mammals as the horse, elephant, whale, and man. In apes, man, bats, elephant, and sea cows, the one pair is anterior or pectoral in position. The one pair in the whale and horse is posterior or inguinal. The cow's **udder** consists of the contiguous glandular masses of two pairs of mammary organs. The marsupial opossum has six pairs of nipples plus an odd one in the middle of the mammary region.

The **mammary organs of monotremes** lack nipples. In the **duckbill**, the several milk-ducts of each of the one pair of mammary organs merely open on the flat surface of a hairless area of skin. This pair of "milk-fields" is situated ventrally about midway of the length of the trunk. The young licks off the milk as it exudes from the pores of the ducts. In *Echidna* (Fig. 448A) each of the pair of milk-fields is depressed to form a shallow "**mammary pocket**" into which the snout of the feeding young is inserted.

All **mammals other than monotremes** possess nipples. A mammary organ develops at a locally thickened spot on the milk-line (Fig. 447A, B). Each gland is formed by a cord of ectodermal cells which grows inward from the thickened region (Fig. 447C). This region becomes temporarily indented to form a shallow pouch resembling the "mammary pocket" of *Echidna* (Fig. 447C). In some mammals the embryonic pouch is finally everted to become the protruding nipple at whose apex open the milk-ducts (Fig. 448B). In others the integumentary rim of the pouch grows outward so that the broad and shallow cavity of the pouch is transformed into a narrow and long canal at whose bottom open the milk-ducts (Fig. 448E, F). The solid nipple is commonly called "**true**," the hollow one "**false**." "True" nipples are found in marsupials, rodents, elephants, sea cows, and primates; "false" in cetaceans, cattle and other cud-chewing ungulates, and horses.

Mammary glands normally become functional only in the female. Their differentiation is not completed until puberty and they are

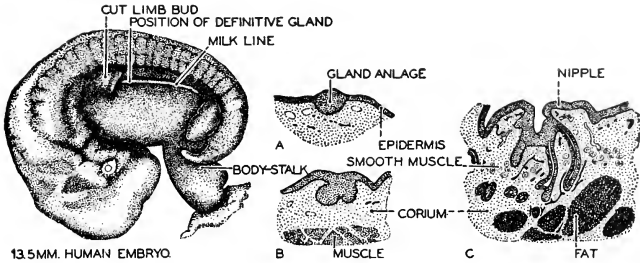


FIG. 147. A figure illustrating the development of the mammary gland in man. A 13.5 mm. embryo (left) shows the "milk-line," a ridge which extends from the axillary region to the groin. The definitive gland develops only from the anterior portion of this line. (Redrawn from Arey, after Kollmann.)

(A, B, C) Sections of the definitive mammary gland in successive stages of development. (A) From a two-month embryo. (B) From a four-month embryo. (C) From a seven-month embryo. The mammary gland is a compound tubular gland. (Redrawn from Arey, after Tournoux.) (Courtesy, Neal and Rand: "Chordate Anatomy," Philadelphia, The Blakiston Company.)

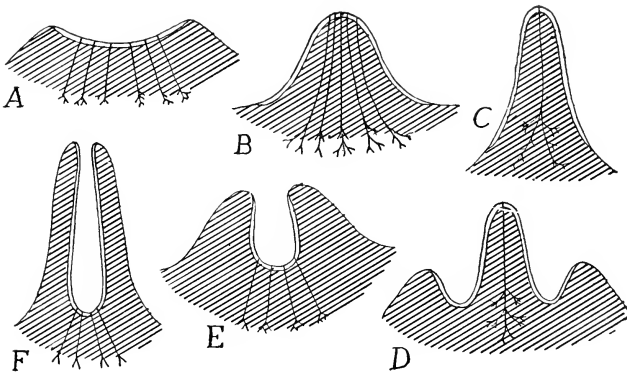


FIG. 148. Scheme of different kinds of nipples. Single line indicates ordinary integument; double line, that of primary mammary pocket. (A) Primitive condition, found in *Echidna*. (B) Human nipple. (C) *Didelphys* at lactation. (D) *Didelphys* before lactation. (E) Embryonic conditions in cow. (F) Adult conditions in cow. (B) and (C) are true nipples, (F) a pseudonipple (teat). (After Weber. Courtesy, Kingsley: "Comparative Anatomy of Vertebrates," Philadelphia, The Blakiston Company.)

functional only during the period of rearing young. In males, they are present in a rudimentary state.

The wide range of difference in number and position of the mammary organs in the several groups of mammals is, in some degree, made intelligible by the common occurrence of the milk-lines in mammalian embryos. The milk-line apparently is potentially mammary throughout its entire length. In a given species it produces organs whose number and position are appropriate in relation to the number

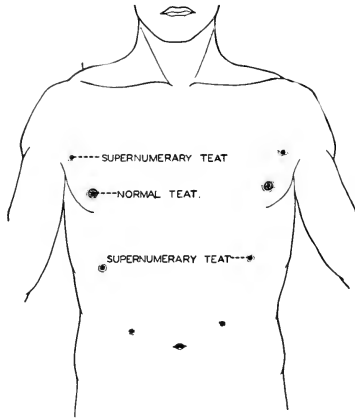


FIG. 449. The occasional presence of supernumerary teats (polymastism) in man indicates the genetic continuity of man and other mammals. (After Wiedersheim. Courtesy, Neal and Rand: "Chordate Anatomy," Philadelphia, The Blakiston Company.)

of young and the conditions under which suckling takes place in that species. Within a species, especially one which normally has a large number of mammary organs, there is commonly some variation in the number. Sometimes, even in man, and from unknown causes, the milk-lines produce organs in excess of the normal number and in unusual localities. In the human female the "supernumerary" organs, situated usually above the normal pair, may become functional (**polymastism**). In human males supernumerary nipples are not uncommon (**polythelism**), even to such extreme overproduction as that of the case represented in Fig. 449.

In its highly glandular character mammalian skin resembles amphibian rather than reptilian skin. It is possible that the very early



reptiles from which the mammals have apparently been derived still retained some integumentary glands inherited from amphibian ancestors.

In mammals **integumentary sensory organs** are present in greater number and diversity of types than in reptilian skin. A dry, scaly skin such as that of reptiles is not well adapted to being highly sensitive.

The "roots" of hairs, situated in elongated follicles (Fig. 443), and the long tubular sweat-glands are both of epidermal origin, but they burrow deeply into underlying tissue. Accordingly, the mammalian **dermis** is usually relatively thicker than reptilian dermis. Also in contrast to the reptilian dermis, whose connective-tissue fibers are more or less definitely arranged in bundles and layers, the dermal fibers in mammals are not arranged in parallel systems but are intricately interwoven or "felted."

The layer of **subcutaneous connective tissue** is more prominently developed in mammals. It is highly elastic, admitting of movement of skin in relation to the body-muscle. Such movements are effected by thin sheets of **subcutaneous muscle** situated in the subcutaneous layer but derived from the adjacent body-muscle. These subcutaneous muscles are especially well developed in the anterior region of the animal—e.g., the facial "muscles of expression" in man (Fig. 96).

#### MOTOR MECHANISM—MUSCLES AND SKELETON

In general, the mammal excels the reptile in speed and agility and is capable of a greater diversity of activities. These improvements are most directly reflected in the anatomy of the motor mechanism and the respiratory system. The changes in the proportions of the body and in the arrangement of the coelomic spaces are consequences incidental to the changes in the mechanisms of locomotion and breathing. The anatomy of the skeleton is intelligible only in connection with the organs which it serves to protect and, of broader importance, the muscles whose strains are sustained by the skeletal parts. Therefore, in the following description, muscles and skeleton will, so far as possible, be considered together, beginning with the appendages as the immediate locomotor organs and proceeding then to regions of the body—trunk, neck, tail.

#### APPENDAGES

In connection with the greater length and altered positions of the legs, the locomotor muscles are more elaborately differentiated than

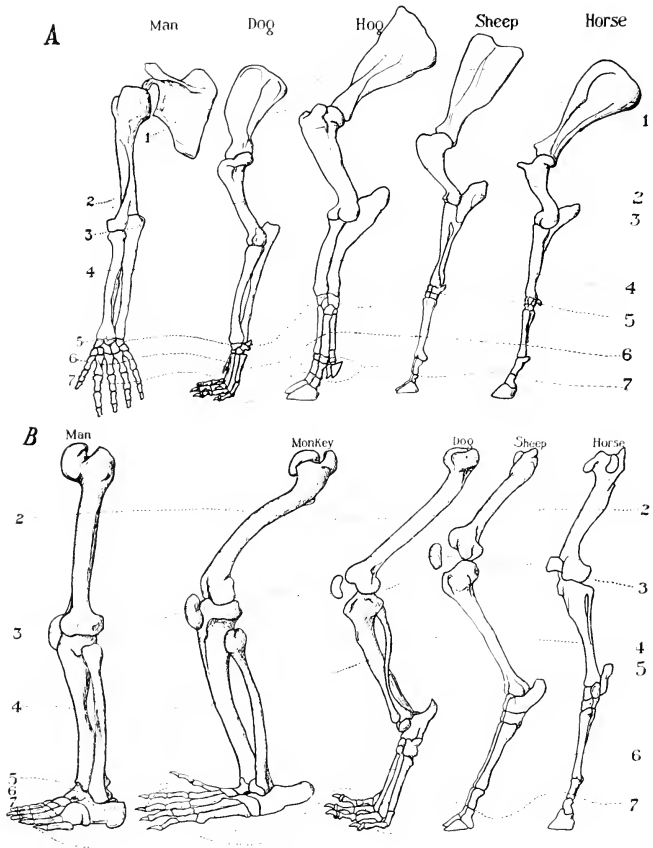


FIG. 450. (A) Forelegs of mammals. (B) Hindlegs of mammals. The dotted lines pass through corresponding bones and joints. (Courtesy, American Museum of Natural History, New York.)

in reptiles (Fig. 454). Increased bulk of the muscles provides the greater power needed. The weight of the leg muscles is a much greater proportion of the animal's total weight in mammals than in reptiles. Increase in number of muscles and modifications in their attachments to skeletal parts give the animal better control and greater variety of leg movements. The most bulky locomotor muscles are those massed at the base of the limb (particularly the pelvic) and having their proximal attachments on the dorsal region of the girdle and the neighboring region of the vertebral column (Fig. 454, *bottom*). Consequently, the dorsal portions of the girdles are more strongly developed than the ventral parts. In the **pectoral girdle** the **scapula** is the all-important bone, the ventral parts—coracoid, procoracoid, and clavicle—being, in most mammals, more or less reduced or even completely absent except that a rudimentary coracoid commonly fuses to the glenoid region of the scapula to become the **coracoid process** of the scapula (Fig. 125B). The **clavicle** is lacking in some marsupials, in ungulates, cetaceans, and sea cows, and in some carnivores and a few rodents.

Conspicuous superficial dorsal muscles of the pectoral appendage are the **trapezius** and **latissimus dorsi**, opposed in their action by ventral muscles which constitute the **pectoralis** group (Figs. 454, 455, 456).

The relation of the leg to the ground while walking or running varies (Fig. 450). In some mammals the entire length of manus and pes is applied to the ground, the upward inclination of the leg beginning at the region of wrist and heel respectively. This **plantigrade** condition is illustrated by the bear and man. In most mammals only the ventral surfaces of the digits are applied to the ground, the metacarpal and metatarsal regions inclining more or less sharply upward so that wrist and heel are clear of the ground—the **digitigrade** condition, seen in dogs and cats. Minimum contact with the ground occurs in mammals which walk on the distal tips of a much-reduced number of digits, the distal phalanx of each digit being encased in a blunt, horny hoof. The extreme of this **unguligrade** condition is seen in cattle and the horse. In cattle the distal tips of only two digits of each leg touch the ground; in the horse, only one.

#### TRUNK

Consequent upon the separation of the coelom into major anterior and posterior divisions by the transverse diaphragm, the thoracic body-wall and the abdominal body-wall become anatomically very different. The differences are necessarily related to the functions and mechanical requirements of the organs contained in the two cavities. The heart and lungs must be protected from external impacts and pressures. The lungs, incapable of filling themselves with air, are filled

and emptied by alternate expansion and contraction of the thoracic wall, assisted by contraction and relaxation of the diaphragm. Mechanical protection of the thoracic organs and this bellows-like breathing movement of the wall both require that it should have a considerable degree of stiffness. The chief contents of the abdominal cavity are organs of digestion, excretion, and reproduction. Not only are the functions of these organs less susceptible to external mechanical interference, but a rigid abdominal wall would be positively objectionable. The stomach is sometimes full, sometimes empty. The uterus may be collapsed and shrunken or it may be greatly distended by developing young. The abdominal wall must be able to adapt itself to great variations in the volume of its contents.

Throughout the entire extent of the **thoracic region, ribs** are present (Figs. 451, 452). Each usually consists of two parts: a dorsal **vertebral rib** articulated to the vertebral column, and a ventral **sternal rib** joined to the sternum. In the egg-laying duckbill and spiny anteater (monotremes), the thoracic rib is in three parts, a short intermediate segment being interposed between the vertebral and sternal parts. (A similar condition exists in the trunk-ribs of crocodilians and some lizards.) The vertebral rib, in the adult mammal, is bony, but the sternal rib usually remains cartilaginous, although in

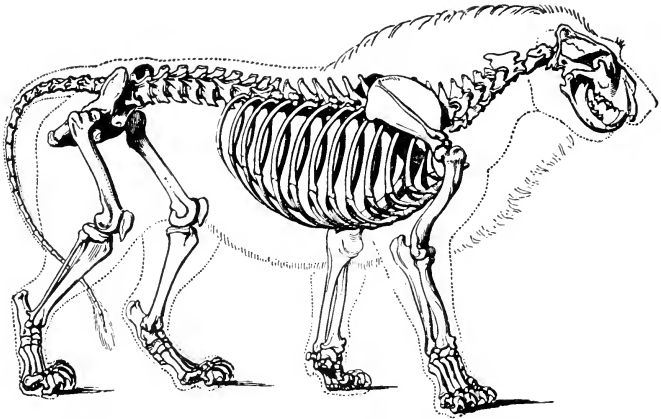


FIG. 451. Lion. Owen's idea of showing the animal's external outline in relation to the skeleton results in a picture which reflects the perfect correlation between the distribution of the dynamic musculature and the arrangement of the static skeletal parts which provide support and leverage. (Courtesy, Owen: "Comparative Anatomy and Physiology of Vertebrates," London, Longmans, Green & Co. Ltd.)

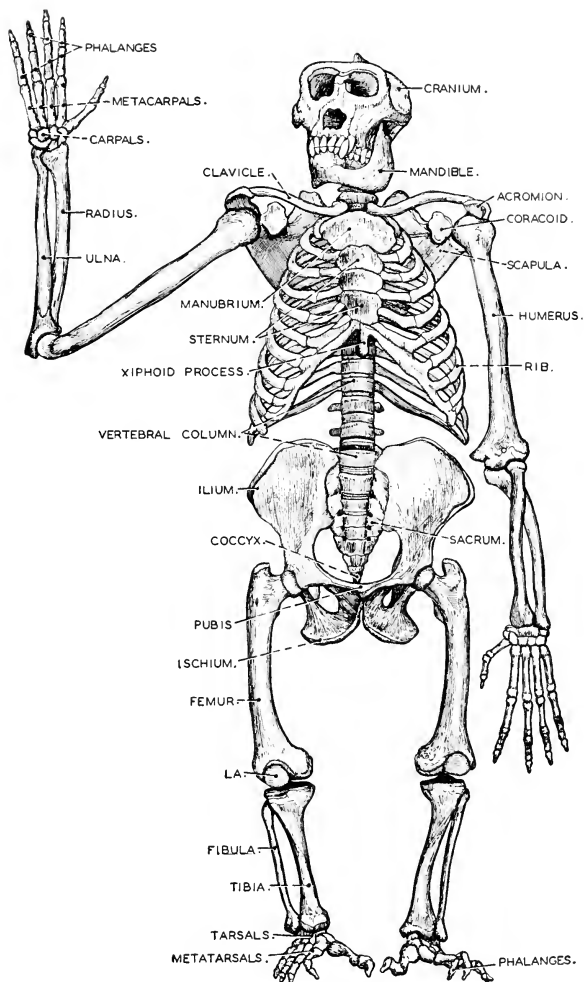


FIG. 452. Skeleton of gorilla viewed from front. The bones of the gorilla correspond to those of man. Differences of proportion, however, are seen. The differences in the relative length of arm and leg bones is most striking. The limb proportions of the human infant, however, tend to resemble those of the ape. (After Brehm. Courtesy, Neal and Rand: "Chordate Anatomy," Philadelphia, The Blakiston Company.)

old animals it may become hardened by calcification (not ossification). In the posterior region of the series of ribs, there are usually several pairs of "false" ribs which are only indirectly connected to the sternum, the lower end of each being connected to one ahead of it. Behind

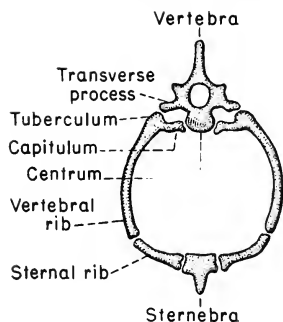


FIG. 453. Thoracic arch.

the "false" ribs may be one or more pairs having no connection with the sternum—"floating" ribs. The **sternum** is more strongly developed than in reptiles. It consists usually of a longitudinal series of somewhat elongated bones, **sternebrae** (Fig. 112E), corresponding to the ribs in segmental arrangements. A complete skeletal segment of the thorax consists, therefore, of a dorsal vertebra, a pair of vertebral ribs, each joined ventrally to a sternal rib which attaches to a median sternebra (Fig. 453). In sea cows and some cetaceans, the sternum

is a single broad plate of bone showing no segmentation, this unusual form being associated with the fact that the sternum is joined to only a few of the more anterior ribs.

The ribs develop in the connective tissue of the myoseptums. Therefore the strongly developed thoracic ribs perpetuate the original segmentation of the muscle of the thoracic wall (Fig. 460). Between successive ribs extend **intercostal muscles** arranged in two thin layers, **external** and **internal intercostal**. Contraction of these muscles draws the ribs closer together.

A complete rib, consisting of vertebral and sternal parts, forms a semicircular arch pivoted at one end to the vertebral column and at the other end to the sternum (Fig. 453). When the muscles attached to the ribs are relaxed, the plane in which each costal arch lies is not perpendicular to the sagittal plane but slopes sharply backward (caudad) in relation to the plane determined by the two points of attachment of the rib and perpendicular to the sagittal plane (Fig. 151). When, in breathing, the intercostal and other muscles attached to the ribs contract, the effect is to swing each costal arch forward (cephalad; therefore upward in man) on its pivoted ends. This increases the diameter and capacity of the thoracic cavity and permits external atmospheric pressure to force air into the lungs. Simultaneous flattening of the diaphragm augments the increase in thoracic capacity. Expiration of air, following relaxation of the muscles involved in inspiration, results for the most part passively in consequence of the

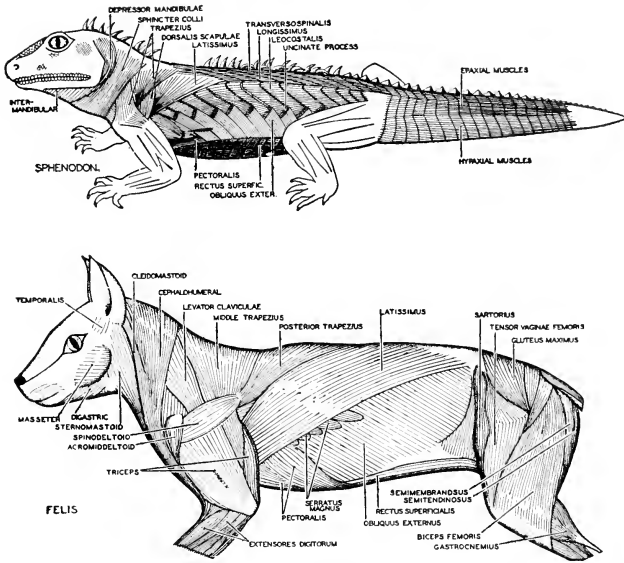


FIG. 151. Superficial lateral trunk muscles in a reptile (*Sphenodon*) and a mammal (*Felis*). The metamerism of the lateral trunk muscles, which is such a striking feature of the lower vertebrates, is reduced and modified in reptiles and almost disappears in adult mammals. (Courtesy, Neal and Rand: "Chordate Anatomy," Philadelphia, The Blakiston Company.)

elasticity of the lungs and of the thoracic wall, but it may be hastened or strengthened by contraction of muscles of the abdominal wall.

In the **abdominal wall** there are ordinarily no ribs. In rare cases the first lumbar vertebra bears a pair of ribs. They sometimes appear, as an anomaly, in man, being known as "gorilla ribs" because they commonly occur in the gorilla. Aside from the vertebral column there are usually no skeletal parts of any sort between the diaphragm and the pelvic girdle. In the ventral abdominal wall of monotremes and marsupials, however, there is usually a pair of **epipubic** or **marsupial bones** supporting the marsupial pouch (when present). They are attached to the pubes.

In the absence of ribs, the segmental myoseptums are obliterated throughout the greater part of the abdominal wall. The primary segmentation is retained only by certain short muscles passing from one vertebra to the next. Except for the muscles that lie closely adjacent to the vertebral column, the muscles of the abdominal wall consist

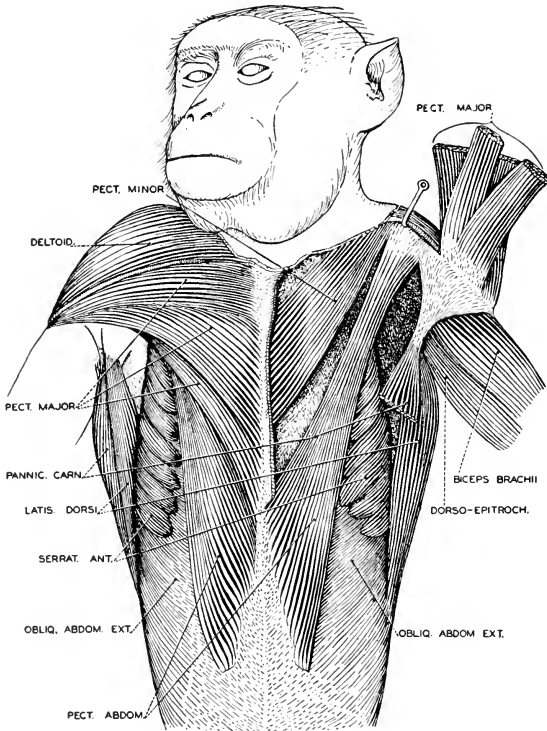


FIG. 455. Pectoral and abdominal musculature of the rhesus monkey. (Courtesy, Hartman and Straus: "Anatomy of the Rhesus Monkey," Baltimore, Williams & Wilkins Co.)

of thin layers whose muscle-fibers extend parallel to the surface of the layer. Certain of these layers extend in unbroken continuity throughout the greater part of the abdominal wall of one side of the body, but the layers of right and left side are separated in the midventral region by a median band of connective tissue, the **linea alba**. Most constant of these abdominal layers are the **external oblique**, whose fibers extend diagonally ventrocaudad (Figs. 454, *bottom*; 455); the **internal oblique**, whose fibers extend diagonally ventrocephalad; and, still deeper, the **transverse**, whose fibers run in approximately transverse direction (Fig. 458). Lying close upon either side of the linea alba is a pair of **rectus muscles** extending from the anterior region of the



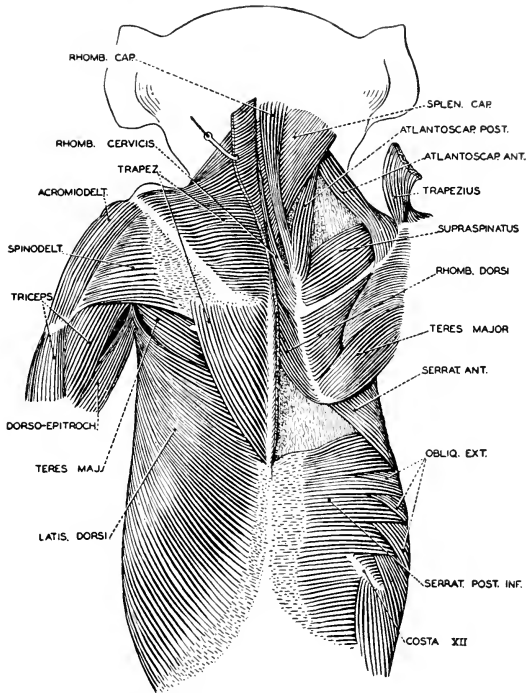


FIG. 456. The superficial dorsal muscles of the rhesus monkey. On the right side, the trapezius and latissimus dorsi have been removed, exposing the deeper extrinsic back musculature. (Courtesy, Hartman and Straus: "Anatomy of the Rhesus Monkey," Baltimore, Williams-Wilkins Co.)

sternum to the pelvic girdle (Figs. 454, *bottom*; 458; 460). The fibers of the rectus muscles extend longitudinally and may be interrupted by several narrow transverse bands of connective tissue (*inscriptiones tendineae*), which are commonly regarded as persistent myoseptums.

The muscles which are most important in effecting the **bending movements of the trunk** constitute an extremely elaborate system massed along the vertebral column. Most conspicuous of these is the **longissimus dorsi**, which begins at the sacrum and pelvis and extends forward, one on each side, dorsal to the vertebral column and lying in the angle between the neural spines and the transverse processes of the vertebrae (Figs. 457, 458). It traverses the entire length of the trunk and has complex relations to many vertebrae. Along the

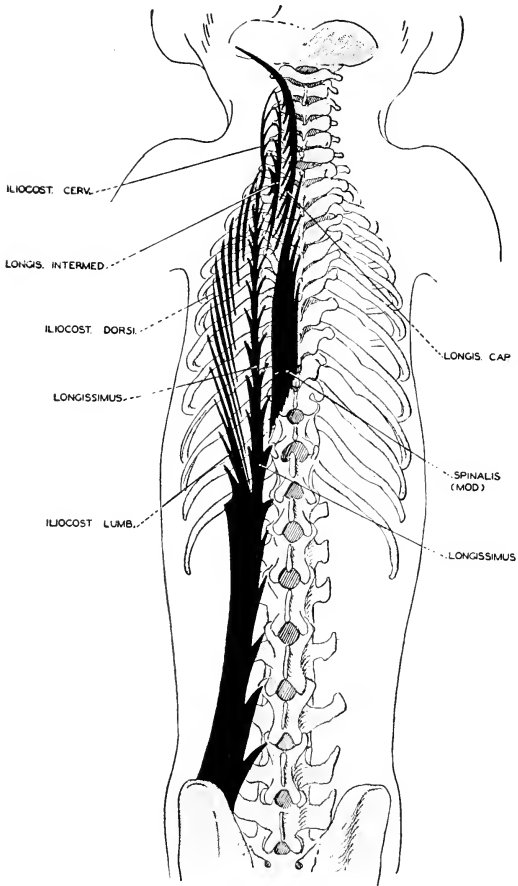


FIG. 157. Semidiagrammatic view of the long system of deeper dorsal muscles. (Courtesy, Hartman and Straus: "Anatomy of the Rhesus Monkey," Baltimore, Williams & Wilkins Co.)

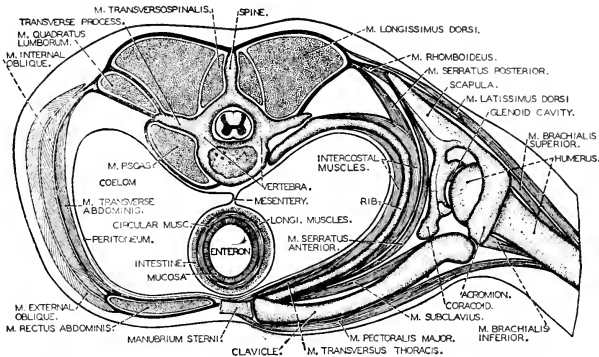


FIG. 158. Thoracic and lumbar muscles of man as seen in cross section. Thoracic muscles on the right, lumbar on the left. The muscle arrangement is fundamentally like that of any mammal. (After Braus. Courtesy, Neal and Rand: "Chordate Anatomy," Philadelphia, The Blakiston Company.)

ventral surface of the thoracic and lumbar regions of the vertebral column extend longitudinal muscles whose action opposes that of the longissimus dorsi. The shortest of the vertebral muscles extend only from one vertebra to the next, representing a single primary segment of the body. They attach either to similar or to unlike parts of the adjacent vertebrae (**interspinales**, **intertransversarii**, **transverso-spinales**). Longer muscles extend over distances of two or more vertebrae.

#### NECK

The vertebrate head is equipped with important sense-organs whose value to the animal is increased if their relation to external space can be altered—that is, if the animal can "look about" or "listen" in a particular direction. There is also a mouth furnished with teeth whose primary use is the grasping of food rather than the chewing of it. The advantage of possessing a neck derives from the free mobility which it gives to the head, thereby enhancing the utility of the sense organs, increasing the facility of getting food, whether plant or animal, and enabling the animal to use the teeth more effectively as organs of combat. The neck is well developed in birds, but it seems likely that the ability to look backward while moving forward may be of even greater value to the terrestrial mammal than to the bird, the mammals being, in general, more prone to eat one another than are the toothless birds.

In most mammals the neck is well elongated, but there is considerable variation in length. At one extreme is the giraffe, at the other

the whale. If "neck" is defined as a constricted region between head and trunk, the whale has no neck, but internal anatomy reveals some cervical features (see Fig. 578).

The neck, except as traversed by the esophagus and trachea, is a solid region of the animal, consisting mainly of the vertebral column and muscles. Ribs are of chief importance as support for thin walls of a large cavity. In the neck they are very much reduced. In some cases (South American sloths) the last one or two, or even three, cervical vertebrae bear ribs which, however, are shorter than thoracic ribs. Otherwise, cervical ribs appear only as very short embryonic rudiments which eventually become solidly fused to the corresponding vertebrae. Like the thoracic ribs, the cervical rib has two protuberances or "heads" whereby it is attached to its vertebra. Between the two heads is a space or notch. After the short rib-rudiments have fused to a cervical vertebra, the effect is that of a vertebra having a pair of projecting lateral processes each pierced by a foramen (Fig. 364). Through this **vertebrarterial foramen** (or **foramen transversarium**) passes an important blood-vessel, the **vertebral artery**.

The free mobility of the head depends on an elaborate system of cervical muscles so arranged as to bend the neck in relation to the trunk, to bend the neck within itself, and to give the head a variety of motions in relation to the neck. These muscles are, for the most part, closely massed along the series of cervical vertebrae. The highly complex system of muscles constituting the **longissimus dorsi** of the trunk continues forward into the neck (**longissimus cervicis**), attaching to transverse processes of the cervical vertebrae. A further anterior continuation of it (**longissimus capitis**) attaches finally to the temporal region of the skull (Fig. 457).

Action of the dorsal cervical muscles is opposed by muscles having ventral attachment on the cervical vertebrae. The **scalenus** (Fig. 460) arises from ribs in the lateral thoracic wall and extends forward to attach to transverse processes of the cervical vertebrae. The **longus colli** (paired) is an important muscle attaching to the ventral surfaces of cervical vertebrae and continuing back along the more anterior thoracic vertebrae. Another ventral muscle, the **longus capitis**, arises from several cervical vertebrae and inserts on the ventral side of the occipital bones. The shortest vertebral muscles, **interspinales**, **intertransversarii**, and **transversospinales**, occur throughout the neck region just as in the trunk.

The action of these cervical muscles can be inferred from their attachments. Muscles extending between the thoracic wall and cervical vertebrae bend the neck in relation to the trunk. Muscles whose connections are restricted to the cervical vertebrae bend the neck

within itself. Movements of the head in relation to the neck are effected by muscles extending between the skull and more posterior parts. Especially significant for movements of the head on the neck is a complex set of small muscles extending from the **atlas** and **axis** to the adjacent occipital region of the skull. The surfaces are so shaped that the joint between skull and atlas provides for up-and-down movements of the head, while right-and-left movements result from rotation of the atlas on the pivot provided by the **odontoid process** of the axis (Fig. 108).

On the ventral side of the neck is an important set of paired muscles (Figs. 454, *bottom*; 459, 460) having no relations to the vertebral column, but extending from anterior parts of the thoracic skeleton (anterior end of sternum and first thoracic ribs) forward to the posterior region of the skull (the **sternomastoid** muscle) or to parts of the visceral skeleton (**sternohyoid** and **sternothyroid** muscles). The latter two, in their ventral position and in their occasional possession of **inscriptiones tendineae**, resemble the rectus muscles of the abdomen. Such of these ventral longitudinal muscles as attach to parts of the visceral skeleton, or extend between parts of it—all innervated by the hypoglossal nerve (XII)—correspond to the hypobranchial muscles of Anamnia. The group includes the chief muscles of the tongue (**genioglossus** and **hyoglossus**; Fig. 459), the **geniohyoid** (connecting lower jaw and hyoid), and some small muscles of the laryngeal apparatus. The sternomastoid, innervated by XI, is probably of branchiomic origin (p. 96).

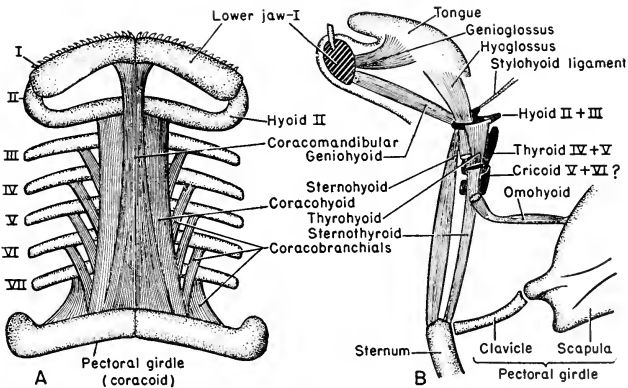


FIG. 459. Hypobranchial muscles: diagrammatic. (A) Shark: ventral view. (B) Mammal: lateral view. Exact homology of particular muscles can hardly be recognized, but the relations to skeletal parts and the innervation indicate the homology of the hypobranchial group throughout the vertebrates.

## TAIL

Comparing mammalian neck and tail with corresponding regions of amphibians and reptiles, it appears that the neck gains importance while the tail loses it. In fishes, aquatic urodeles, and crocodilian reptiles, the tail is the chief agency in swimming. Throughout its length,

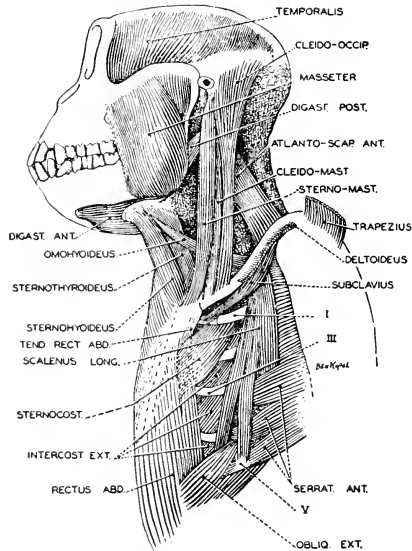


FIG. 460. Muscles of the head, neck and thorax of the rhesus monkey; left lateral view. The facial and pectoral muscles have been removed. (Courtesy, Hartman and Straus: "Anatomy of the Rhesus Monkey," Baltimore, Williams & Wilkins Co.)

nearly or quite to its posterior tip, it conforms to the primitive pattern of segmentally arranged muscles (myomeres), spinal nerves, and vertebrae. In most mammals the tail is extremely attenuated and the characteristic caudal structures are well developed only in its anterior region. Its more important muscles arise from the sacrum and pelvic girdle, extend back for varying distances into the anterior part of the tail, and then break up into slender tendons which attach to the more posterior vertebrae. A posterior region of the tail, varying in extent in different mammals, is quite devoid of muscular tissue and its move-

ments depend on tendons attached to muscles in the anterior region. The nervous structures of the tail are even more restricted. Thus, in the common cat there are about 22 caudal vertebrae, but there are only seven or eight pairs of caudal spinal nerves. They occur in series immediately behind the sacral nerves. These caudal nerves, however, emerge from the spinal cord considerably anterior to their points of emergence from the vertebral column, and the cord itself continues into the caudal region only as a non-nervous filament, the **filum terminale** (Fig. 157).

In some monkeys (the South American **Cebidae**) the long tail is so strongly developed as to allow the animal to swing by it from a branch of a tree. Also, in the opossum (Fig. 531) and some other marsupials, in some South American anteaters, and in the kinkajou, a Central and South American carnivore, the **tail is prehensile**. The whale is an exceptional mammal in having a massive tail, the trunk tapering back gradually into the caudal region as in fishes. Muscles are present far back in the posterior region of it. However, in the absence of hindlegs, there is no recognizable sacral region of the vertebral column, and it is difficult to say just where the postsacral (caudal) region begins. It is to be remarked, too, that as the vertebrate tail appears in its primitive functional importance in the whalelike mammals the neck vanishes—all of which, of course, is a matter of streamlining the body for aquatic living. How the tail "came back" in the history of whales is an as yet unsolved problem in evolution.

In the longer-tailed mammals the more anterior vertebrae have the typical vertebral structure, but, passing posteriorly, the neural arches and the various lateral processes of the vertebrae are progressively reduced to the extent of their complete absence in the posterior region of the tail, where the column consists merely of slender, elongated, cylindrical centra (Fig. 451). In the anterior region of a long tail commonly occur a varying number of small bones, each shaped like a miniature "wishbone" or a "V" and attached by its two ends, point downward, to the ventral surface of a corresponding vertebra, or else attached intervertebrally. The caudal artery and vein pass through the aperture between the two arms of the bone. These "**chevron bones**," present also in many reptiles, are possibly homologous with the hemal arches of anamniotes.

The shifting of locomotion from the anamniote tail to the amniote legs has a point of practical significance for man. Our most important animal food consists of locomotor muscles. Steaks of halibut and swordfish are slices cut across the tail. The oxtail may serve for soup, but our heavy beefsteaks and roasts come from the upper part of the hindleg and the region of the pelvic girdle.

## VERTEBRAL COLUMN

The larger structural characteristics of the mammalian body-wall are clearly reflected in the vertebral column. The differentiation of the five regions of the column is accentuated and they are sharply delimited from one another. In total number of vertebrae and in the relative numbers within the several regions, there is much less variation than among reptiles. Most striking is the fact that the number of **cervical vertebrae** is almost invariably **seven**, regardless of the length of the neck. In duckbill, mouse, cat, man, and giraffe the number is seven. In the whalelike mammals, between the skull and the first vertebra whose ribs attach to the sternum (being therefore the first thoracic), there is a bony complex whose structure and mode of development show clearly that it consists of seven vertebrae much flattened and more or less completely fused together so that in some cases the seven occupy scarcely more length in the vertebral column than would a single vertebra of ordinary proportions. The only known departures from seven occur in the Atlantic sea cow (manatee) which has only six, the two-toed sloth (*Choloepus hofmanni*) with six, and the three-toed sloth (*Bradypus*) with eight or nine. The first two cervical vertebrae are differentiated as **atlas** and **axis** as in reptiles, but with the difference that the anterior face of the atlas is shaped to fit the **paired occipital condyles** of the mammal.

The number of **thoracic vertebrae** is commonly from 12 to 14, and of **lumbar vertebrae** 5 to 7. But the Asiatic coney (*Hyrax*) has a total of from 29 to 31 trunk vertebrae.

In the number of vertebrae involved in the **sacral region**, there is considerable variation. The bone called "**sacrum**" usually consists of two or more vertebrae fused together, but some of the fused vertebrae may have no direct connection with the pelvis and therefore may or may not be counted as sacral vertebrae. In a strict sense, a sacral vertebra is one that connects, by means of its pair of short thick ribs, with the ilia. Some statements about number of vertebrae in the sacral region are confusing because it is not clear whether the number refers to the "**sacrum**" or, in a narrower sense, to the vertebrae which are joined to the pelvis. The egg-laying duckbill has two sacral vertebrae fused together—the typical reptilian number. In kangaroos and many other marsupials two sacral vertebrae constitute the sacrum. But in the Australian bandicoot (*Perameles*) there is the minimum sacrum, one vertebra only. The wombat (*Phascalomys*), another marsupial, is exceptional, having a sacrum of seven vertebrae, but only the anterior four join the ilia. Among placental mammals, with some exceptions, the number of vertebrae in the sacrum ranges from three to five (Fig.



461), but usually some of its posterior members do not connect directly with the girdle. In rodents the sacral number is commonly three or four, but usually only two, or sometimes only one, join the girdle. In the rhinoceros sacrum of four vertebrae, three join the girdle. In the elephant all of the three sacral constituents join the girdle. Of the five vertebrae in the human sacrum, usually only the anterior three join the ilia. The maximum sacrum is that of the armadillo, containing 8 to 10 vertebrae. This great expansion of it is due to the fact that it serves to support the heavy bony exoskeletal carapace. The sacrum

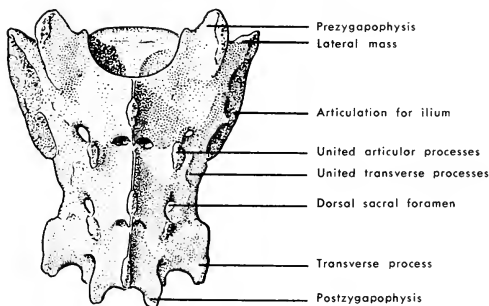


FIG. 461. Dorsal aspect of cat's sacrum. (After Stromsten: "Davison's Mammalian Anatomy," Philadelphia, The Blakiston Company.)

not only joins the ilia, but its posterior region acquires connection with broad dorsal extensions of the ventral ischia (Fig. 462). At the anterior end of the sacrum each ilium bears a strong dorsal process, and at the posterior region of the sacrum each ischium bears a similar process. These two pairs of bony posts are attached to the inner surface of the carapace.

In the **caudal region**, in striking contrast to the cervical region, the number of vertebrae varies with the length of the tail. Even in a given species there is some variation in the number. The approximate numbers of postsacral vertebrae in several mammals are as follows: in some pangolins (Manidae), 50; common rat, 30; common cat, 22; rabbit, 15; man, 3 to 5. In the human embryo there are usually rudiments of eight caudal vertebrae, but several of the posterior rudiments fail to complete their development.

An important feature of the mammalian vertebral column is the presence of **intervertebral disks** consisting of a fibrocartilage which is very tough, slightly compressible, and highly elastic (Figs. 107, 452). The apposed faces of the centra are usually flat (amphiplatyan centra).

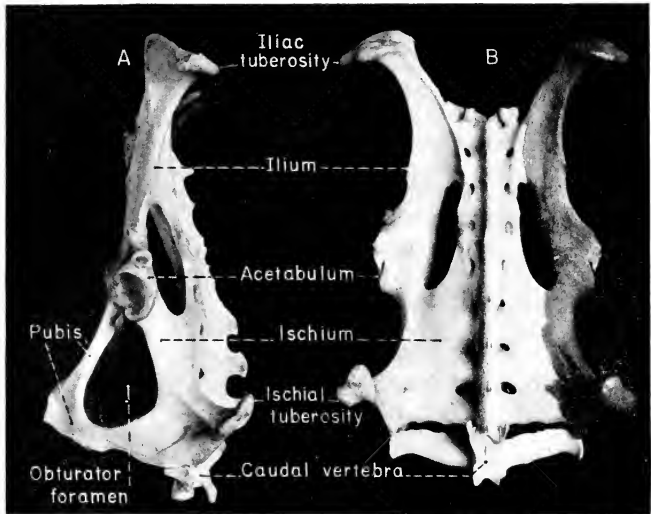


FIG. 462. Armadillo sacrum. (A) Lateral view. (B) Dorsal view.

These rather thick disks or ligaments intervene between adjacent centra, serving as shock-absorbers and imparting the necessary flexibility to the column. Other than in mammals, such disks are well developed only in crocodylians and birds.

In the **development of mammalian bones** there is a unique feature, best exemplified in vertebrae and the elongated bones of the legs. The embryonic cartilaginous centrum of a vertebra ossifies in three parts, forming a thin anterior plate, a similar posterior plate, and a thicker middle part. Between the middle bony mass and the adjacent thin bony plates (**epiphyses**), a thin layer of cartilage persists without ossifying until the growth of the vertebral column is completed. Increase in the length of the centrum is accomplished by progressive deposition of new bone on the anterior and posterior faces of the middle part of the centrum, each of the faces being adjacent to a layer of cartilage. When growth is completed, the epiphyses fuse solidly with the middle mass of the centrum. Similarly, at an early stage in the development of one of the elongated bones of an appendage (Figs. 463, 464), a bony **epiphysis** is formed in each end of the cartilaginous precursor of the bone, and the intermediate region of the cartilage ossifies separately to form the shaft (or **diaphysis**) of the bone, but a

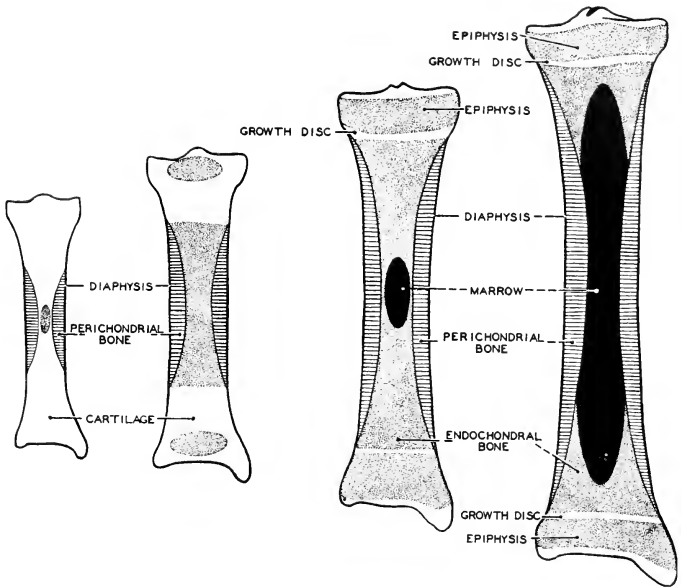


FIG. 163. Diagrams illustrating four stages in the development of a long bone. Perichondral bone cross-hatched; endochondral bone stippled; marrow black; cartilage unshaded. (After Corning and Duval. Courtesy, Neal and Rand: "Chordate Anatomy," Philadelphia, The Blakiston Company.)

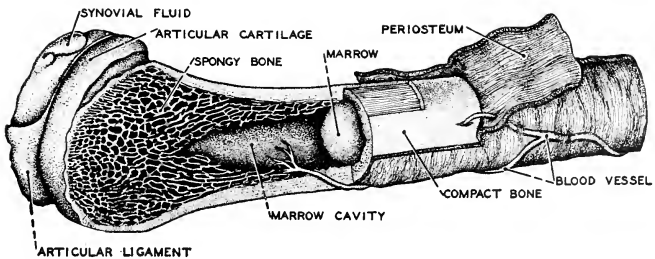


FIG. 161. Diagram of the structure of a long bone. (After Kahn. Courtesy, Neal and Rand: "Chordate Anatomy," Philadelphia, The Blakiston Company.)

disk of cartilage persists between the diaphysis and each epiphysis, permitting growth of the shaft at its ends. When growth is completed, the epiphyses usually fuse to the shaft. The advantage in this method of development lies in the fact that the terminal region of the bone is relieved of the necessity for growing and at the same time maintaining a suitable surface for a working joint. Early ossification of the epiphysis makes possible the establishing of a finished joint long before longitudinal growth of the bone is finished. Mammals are usually most active during youth, and they may well be so, for the joints are then at their best even though the development of the skeleton is not completed. Epiphyses are not known to occur in reptiles. It is to be noted that epiphyses are absent or very poorly developed in the monotremes—mammals which reproduce in the reptilian manner.

### SKULL

The mammalian skull has the same general structure as that of a reptile, but the adult skull, in form and in details of structure, is simpler than a reptilian skull and very much simpler than that of a bony fish. Its simpler condition results in part from reduction in number of dermal bones, especially in the region of the orbit, on the roof of the mouth, and along the jaws. In part, however, the simplicity is of secondary nature in that two or more bones which are quite separate in the embryo may fuse to form a single bone in the adult. In the human skull the sphenoid bone is a fusion of eight embryonic parts (see Table 1, p. 122) of which all but one correspond to reptilian bones. The mammalian temporal bone includes all the cartilage bones formed in the auditory capsule, the squamosal bone, and, in some cases, still others (see Table 1).

The brain does not extend forward between the orbits—that is, the skull is of the **tropibasic** type (p. 517), but the interorbital region is usually not reduced to the extreme narrowness of the interorbital septum of birds and many reptiles. Comparison with skulls of presumably ancestral theromorph reptiles justifies regarding the mammalian skull as of the **synapsid** type, but much disguised. The four types of skull are defined on the basis of the number and positions of "windows" (**fenestrae**) in the **temporal arcade** (p. 501). In extreme contrast to the anapsid skull in which the whole temporal space is covered laterally by a bony temporal arcade having no "windows" at all (Fig. 394), the temporal arcade in the modern mammal (Figs. 436B, 465) is nearly all "window" with little of its frame left except the "sill," which appears as a relatively slender bony arch projecting outward at the level of the upper jaw, the anterior end of the arch springing from the maxillary bone and its posterior end consisting of

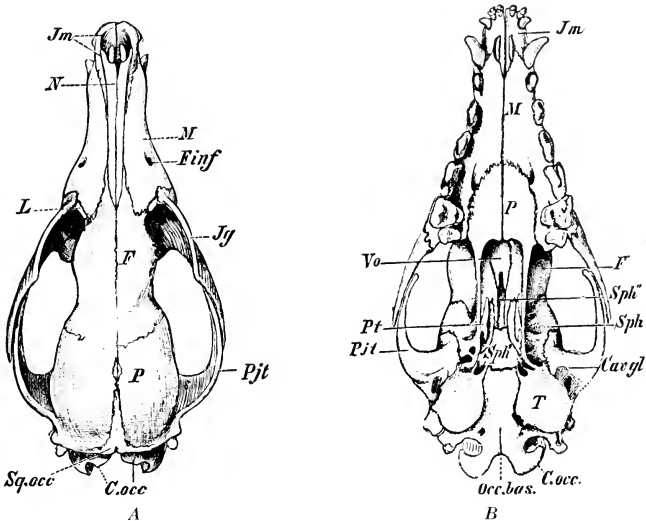


FIG. 465. Dog skull. (A) Dorsal view. (B) Ventral view. (*Cav.gl*) Fossa for articulation of lower jaw; (*C.occ.*) occipital condyle; (*F*) frontal; (*Finf*) infraorbital foramen; (*Jg*) jugal (malar); (*Jm*) premaxillary; (*L*) lacrimal; (*M*) maxillary; (*N*) nasal; (*Occ.bas.*) basioccipital; (*P*, in A) parietal; (*P*, in B) palatine; (*Pjt*) zygomatic process of temporal; (*Pt*) pterygoid; (*Sph*) alisphenoid; (*Sph'*) basisphenoid; (*Sph''*) presphenoid; (*Sq.occ*) squamosal; (*T*) tympanic bulla of temporal; (*Vo*) vomer. (Courtesy, Wiedersheim: "Grundriss der vergleichenden Anatomie der Wirbeltiere," Jena, Gustav Fischer.)

a strong process of the squamosal. The middle span of the arch is the **jugal**, in mammals known as the "**malar**." This remnant of a temporal arcade is called the **zygomatic arch**. In the anapsid skull the great muscles which elevate the lower jaw occupy the space between the side of the cranium and the temporal arcade. In the mammal the **masseter muscle** extends from the zygomatic arch to the lower jaw (Figs. 454, *bottom*; 460). The large space between the arch and the cranial wall is occupied by the **temporalis**, a bulky muscle which arises from an extensive area on the temporal region of the cranium (Fig. 460) and inserts on a prominent dorsal **coronoid process** (Fig. 436B) of the lower jaw. When the mouth is closed, the coronoid process, surrounded on all sides by the muscles which attach to it, extends up into the temporal space. Therefore the outer surface of the masseter (check-muscle) and the considerable area of the temporalis extending above it are covered externally only by the skin and some thin sheets of

subcutaneous muscle, whereas in the anapsid skull the muscles which elevate the lower jaw are inside the bony temporal arcade.

In the several orders of mammals there is much variation in the relation of the **orbital cavity** to the **temporal space**. There may be no complete bony wall between these (as in most insectivores, rodents, carnivores (Figs. 436*B*, 465*A*), and some hoofed mammals), or they may be more or less completely separated by a bony wall formed by the joining of a downward-projecting process of the frontal bone and an upward-projecting process from the zygomatic arch (as in the horse, cattle, sheep, monkeys, apes, and man: Fig. 468).

In possession of a **secondary** ("false") **palate**, because of which the nasal passages are prolonged posteriorly (Fig. 435), the mammals differ from birds, and from all modern reptiles except the crocodylians, whose secondary palate makes it possible for air to pass directly from the nasal cavities into the trachea without entering the mouth which may, at the time, be filled with water.

One of the most distinctive features of the mammalian skull is the **joint between upper and lower jaw**. Whereas in all other bony vertebrates the joint is between two cartilage bones, **quadrate** above and **articular** below, in mammals it is formed by dermal bones—the **squamosal** above and, below, a bone which is regarded as a much-enlarged **dentary**. This dentary constitutes all of one half, or ramus, of the lower jaw, but, in the reptilian lower jaw, each ramus includes several separate dermal bones (see Table 1, p. 122). In contrast to lizards, snakes, and birds, whose upper jawbones are to greater or less extent movably articulated, all of the bones of the mammalian upper jaw are immovably joined to one another.

The absence of a small perforation in the roof of the skull between the parietal bones (**parietal foramen**: p. 119) is significant in that it means that the mammal does not possess the "third eye" (pineal or parietal eye), a problematic organ characteristic of many reptiles, both past and present (*Sphenodon* and lizards).

**Mammalian Profiles.** The main cranial cavity lodges the brain. Among the several orders of mammals, there are great differences in the size, relative to size of body, and form of the brain. These differences are necessarily reflected in the proportions of the skull and, again, in the external form of the head. Also, the region in front of the brain-case is subject to great variation. In some mammals the nasal region is greatly elongated. In others it is relatively short. Comparing such "lower" mammals as anteaters, rats, and mice with carnivores and monkeys (Fig. 466), there is to be seen in the latter a marked shortening of the jaws and nasal region. This difference is a reduction with reference to length of body and quite irrespective of the




FIG. 166. Mammalian profiles. (*Top*) Lion (carnivore) and rat (rodent). (*Bottom*) *Solenodon* (insectivore) and chimpanzee (primate). (*Top*, courtesy, American Museum of Natural History, New York. *Bottom*, courtesy, Museum of Comparative Zoology, Harvard University.)

proportions of the brain-case. It follows, then, that the shape of a skull, and therefore that of the animal's head, depends largely on two factors: the degree of development of the brain, and the length of the nasal region. Usually long "snouts" go with small brains, but there are exceptions.

In a small-brained mammal, the skull is usually long, narrow, shallow, and flat or only slightly convex on top. The distance between ear and eye is usually less than the distance from eye to tip of snout. With increase in size of brain, the rear part of the skull expands both laterally and upward. If the increase is considerable, the rear part of

the skull becomes strongly convex on top and there may be a more or less abrupt increase in convexity near the junction of the nasal region and brain-case (Fig. 436B). It is the forebrain which undergoes greatest enlargement. Its expansion takes place laterally, upward, and backward, so that it may come to overlie more posterior parts of the brain, and, with extreme expansion, it (so to speak) presses strongly forward, pushing the already bulging roof of the skull ahead of it so that the region of the skull occupied by the frontal bones comes to lie to a greater or less extent *above* the more posterior part of the nasal region instead of *behind* it (Fig. 467). In connection with this change, the eyes are shifted from their primitive lateral position and come to be directed more nearly forward. Thus the mammal acquires a **fore-head**—the region of the forward-bulging frontal bones, and a **face**.

In general, the animal whose main concern is to escape enemies profits by having the eyes directed laterally so that it may have nearly

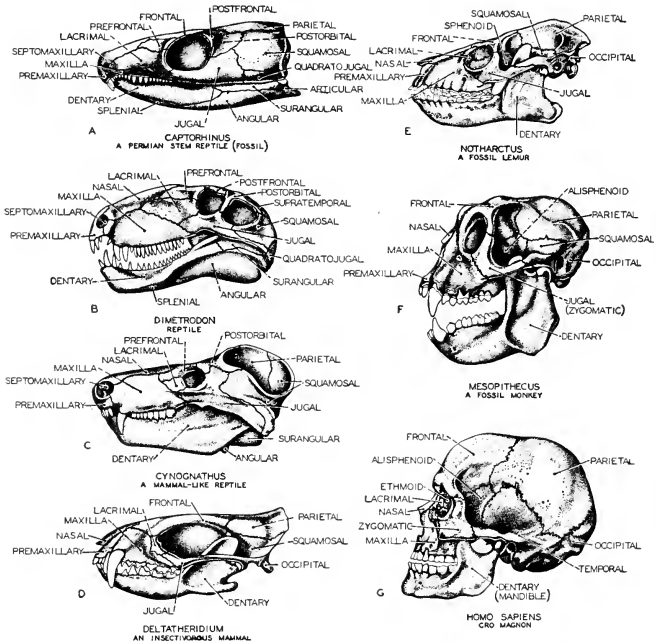


FIG. 467. A series of fossil skulls (A-G) which probably represent fairly well the phylogeny of the human skull. (After Romer: "Man and the Vertebrates," University of Chicago Press.)

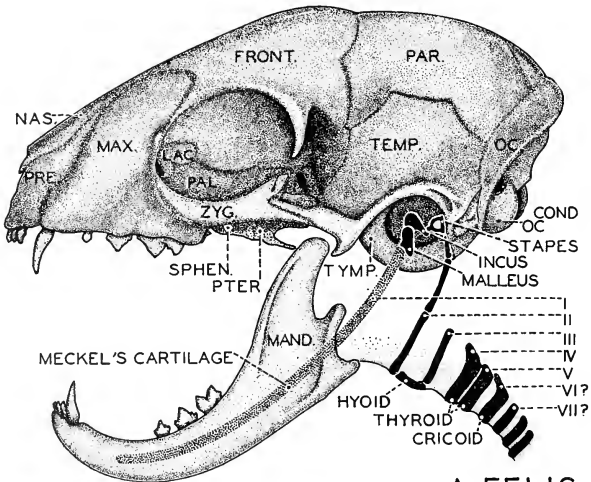


the whole environment in view at the same time. The rabbit is such an animal. But to the carnivore, intent upon catching a fleeing object of prey, it is an advantage to look forward with both eyes because such **binocular vision** gives a better sense of distance and relative positions of objects. Accordingly, the more primitive, smaller, and weaker animals usually have laterally directed eyes, while the forward-looking mammals are of the stronger and more aggressive types.

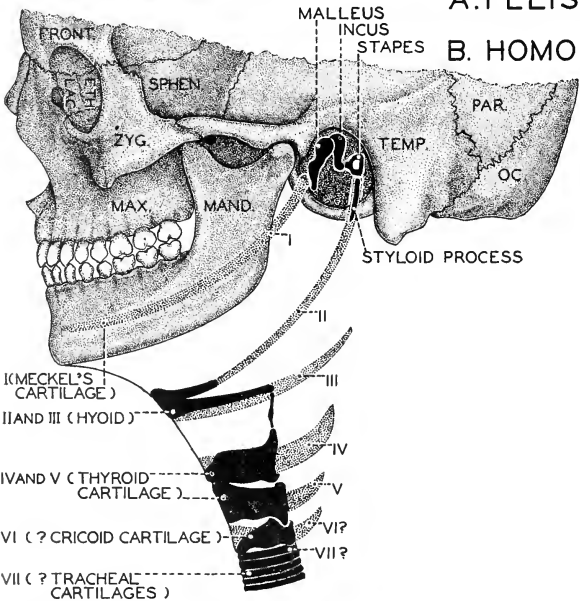
The heads of **ungulates** (Fig. 572) give evidence of some improvement in cranial capacity, but the nasal region is still long. The eyes are placed laterally but the region of the orbit projects more or less so that vision may be more nearly forward. In most **carnivores** the improvement is marked (Fig. 468A). The nasal region (with some exceptions) is short. The head is strongly convex on top. The distance between ear and eye may be greater than that from eye to tip of snout. The eyes are on the front surface of the head so that vision may be directed forward. The cat has a good face and a real forehead, even if somewhat of the "retreating" type. These features characteristic of the larger-brained mammals approach their extreme development in monkeys and apes and reach it in man.

**Sinuses.** The presence of cavities in bones is common. It is, however, a peculiarity of the mammalian skull that certain of its bones, especially in the facial region, contain particularly large air-filled cavities. Each maxillary bone usually contains a large sinus (the **antrum**) and there are commonly **frontal** (in man, just above the eyes) and **sphenoidal** sinuses (Fig. 507). The existence of these cavities may have some relation to the mechanical principle that a hollow structure of appropriate form possesses greater rigidity than a structure containing the same amount of material and of similar form, but solid. These sinuses open into the nasal cavities. Any advantage which they have for man would seem to be outweighed by their propensity for becoming infected and making trouble.

**Visceral Arches.** Such parts of the embryonic visceral skeleton as lie posterior to the first or **mandibular arch** are represented in the adult mammal in various ways. The midventral part of the **hyoid arch** ossifies to form a **hyoid bone** which lies transversely at the base of the tongue and immediately in front of the larynx (Fig. 468). It serves for attachment of muscles which extend down the neck to the thoracic region (**sternohyoid** and others) and as origin for an important muscle, the **hyoglossus**, which passes forward into the tongue, acting to pull the tongue downward and backward (Fig. 459). The hyoid bone supports the larynx, being connected with it by a membranous ligament. Also, some small muscles belonging to the laryngeal mechanism are attached to it. The lateral parts of the hyoid arch are



A. FELIS.



B. HOMO.

FIG. 168. (A) Visceral skeleton of the cat. (B) Visceral skeleton of man. The homologies of the sixth and seventh visceral arches are uncertain. (Courtesy, Neal and Rand: "Chordate Anatomy," Philadelphia, The Blakiston Company.)

highly variable. They may ossify to form, on each side, a chain of small elongated bones (four in the cat), the lower end of the chain being attached to one end of the median hyoid (**basihyal**, "**body**," or **copula**) and the upper end attached to the otic region of the skull (Fig. 468A). These chains thus support the ventral hyoid bone and the larynx. In man a dorsal region of the embryonic arch ossified to produce, on each side, a long spike of bone whose upper end becomes immovably fused to the temporal bone to form its characteristic **styloid process** (Fig. 468B). The region of the arch between the styloid process and the ventral hyoid bone is transformed into a **stylohyoid ligament**. These ligaments serve to swing the ventral hyoid and laryngeal structures from the base of the skull. The **third visceral arch**, corresponding to the first branchial of fishes, is commonly represented by a pair of small ossifications, each of which may articulate with an end of the median hyoid and extend backward to assist in supporting the larynx, or may become immovably fused to the hyoid body (as in man: Fig. 468B), forming the **posterior cornu (horn)**. The pair of shorter **anterior cornua** of the human hyoid are products of the hyoid arch and serve for attachment of the stylohyoid ligaments. Remnants of embryonic visceral arches posterior to the third appear in a highly modified way in the cartilaginous skeleton of the larynx (p. 612).



# Mammalia: Visceral Systems—

## Respiratory, Circulatory, Alimentary, Urinogenital

17

---

An automobile, a motor ship, and an airplane are very different in form, structure, and general appearance, yet their engines may be very similar. Their ability to operate under the diverse conditions attending motion on land, on water, and in air depends upon differences in the structure of the "bodies" of the several mechanisms and not on the use of totally different types of engine. An animal may run, leap, swim, fly, dig burrows, or climb trees. Each type of activity requires appropriate adaptation of the muscles and skeleton. The requirements are so different that the several bodies may appear to us in the forms of mammals so unlike as a tiger, a mole, a bat, and a whale. But corresponding visceral organs of very different mammals may possess only relatively minor differences. Digestion is the same sort of process whether the animal runs or swims. It makes no difference to a kidney whether the wastes to be eliminated result from muscular activities of flying or of burrowing.

**Somatic** (referring to the body-wall) anatomic differences between two animals are especially significant because they are *directly* correlated with the specific functional adaptation of either animal to its particular mode of living. Therefore **somatic differences** are to a large extent *qualitative*. Running, swimming, and burrowing are not just more or less of the same sort of thing. They are of different sorts, each having its peculiar pattern of muscular activity and a corresponding anatomic pattern. **Visceral** differences are to a large extent merely *quantitative*. The organs of nutrition, respiration, and excretion merely have more or less of their work to do depending on the amount of energy expended by the somatic mechanisms. However, new visceral

activities may arise—e.g., as when the respiratory stream of air is utilized for production of vocal sound.

There are two visceral organs which stand in especially close relation to the activities of the body-wall. These are the **lungs** and the **heart**. The physiologic demands upon these organs are immediate and constant. If either stops working, the animal almost instantly ceases to run or swim. The services of other visceral organs are equally necessary, but not so directly. The animal may run for miles while the stomach and intestine contain nothing to digest. A warm-blooded and very active animal must have a heart and lungs of high efficiency.

In view of the facts just stated, it may be expected that, in the following account of the mammalian visceral systems, the respiratory and circulatory organs will require much more extended attention than the organs of digestion and excretion. And the peculiarities of mammalian reproduction give special importance to a comparative account of the genital organs.

## I. Respiratory Organs

### PHARYNX

In all vertebrates the respiratory organs are closely associated with the pharyngeal region of the digestive tube. In most fishes the nasal cavities have no internal openings. Therefore breathing must be through the mouth (or partly through spiracles in the few fishes that have them). In all lung-breathing vertebrates the nasal cavities open internally into the mouth or pharynx. On occasion, or in an emergency, a mammal can breathe through the mouth. However, this close association of functions so unlike as eating and breathing gives rise to some complications. For the poikilothermous vertebrate these are apparently not serious. A "cold-blooded" animal can suspend breathing for a relatively long time without suffering inconvenience. Further, these animals ordinarily "bolt" the food without chewing, so that eating occasions only brief interruptions of breathing. The mouth-cavity and throat are wide and the thing to be swallowed is usually a large object. The glottis is a small, narrow slit. Although it is on the floor of the pharynx, there is little danger that food may enter it. In mammals the difficulties are greater. The homothermous animal must breathe regularly. (Whales possess exceptional arrangements for long submergence.) The greater need of oxygen requires a wide trachea and an open glottis. The **nasal passages are dorsal** to the oral cavity. The glottis being ventral, the **trachea is ventral** to the esophagus. Therefore the pharyngeal region becomes the intersection of two important traffic lanes (Fig. 469), the respiratory and the alimentary.

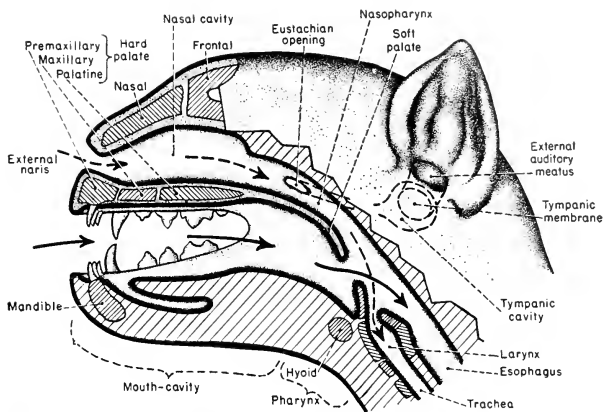


FIG. 469. Alimentary and respiratory passages of a mammal. (Compare with Fig. 135.)

As human mammals well know, it is a place where distressing accidents may occur. The fact that most mammals break up the food more or less, or even chew it finely (as in the cud-chewing herbivores), increases the danger of food entering the trachea.

**Crocodylians**, in adaptation to aquatic living, have acquired a secondary palate whereby the nasal passages are prolonged backward to the close vicinity of the glottis. From the dorsal surface of the posterior region of the tongue, a transverse fold of the skinlike outer layer of the tongue extends upward to meet a similar fold which descends from the under surface of the bony palate. These folds constitute a valve which can be opened to allow food to pass back into the esophagus, but may be closed to prevent water from passing into the nasal cavities and trachea. The nostrils are on the dorsal surface of the snout. Therefore an alligator can submerge, leaving only the nostrils exposed to the air, and can meanwhile breathe freely while the mouth is filled with water and perhaps busy with struggling prey. In general, the anatomy and history of crocodylians indicate that they are much more closely allied to birds than to mammals. The existence of very similar palatal and pharyngeal arrangements in crocodylians and mammals is therefore probably to be regarded as a striking case of **convergence** in evolution.

In mammals the bony **secondary palate** comes somewhat short of reaching the glottis. Its deficiency is compensated for by addition of a "**soft palate**" which arises from the posterior edge of the bony palate and extends back to the region of the glottis. This soft palate

consists of a fold of the skinlike investing layer of the "hard" palate. It prolongs the nasal passages backward, but as a single or undivided passage, separating the original pharynx into an upper **nasopharynx** and a lower buccal division (Fig. 469).

### TRACHEA

The anterior region of the **trachea** is enlarged to form the **larynx**, containing the vocal apparatus (Figs. 470, 471). The walls of the larynx are supported by cartilages. The most anterior and largest of them is the **thyroid**, which encloses the larynx ventrally and laterally but not dorsally. Attached to its midventral anterior edge and freely projecting forward is a flap of tissue consisting internally of elastic fibrocartilage and covered externally by a continuation of the mucous membrane which invests all neighboring surfaces. This flap, the **epiglottis**, is usually rounded or oval in outline, its form being such that,

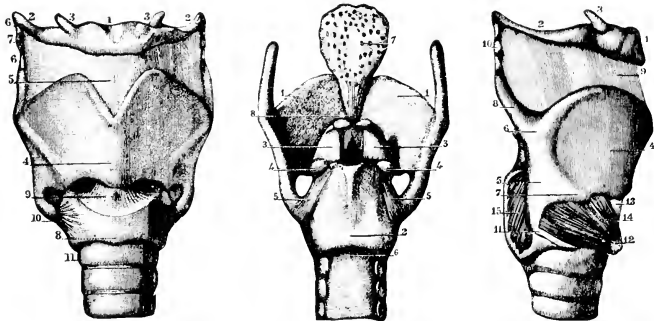


FIG. 470. (*Left*) Front view of the human laryngeal cartilages and ligaments. (Sappey.) (1) Hyoid bone; (2) its large cornua; (3) its small cornua; (4) thyroid cartilage; (5) thyrohyoid membrane; (6) lateral thyrohyoid ligament, containing the cartilago triticea (7); (8) cricoid cartilage; (9) cricothyroid membrane; (10) lateral ceratocricoid ligaments; (11) uppermost ring of trachea.

(*Center*) Back view of the laryngeal cartilages and ligaments. (Sappey.) (1) Thyroid cartilage; (2) cricoid cartilage; (3) arytenoid cartilages; (4) their muscular processes; (5) ligament connecting lower cornu of thyroid with back of cricoid cartilage; (6) upper ring of trachea; (7) epiglottis; (8) ligament connecting it to the angle of the thyroid cartilage.

(*Right*) Muscles of the larynx, as seen from the right side. (Sappey.) (1) Hyoid bone; (2, 3) its cornua; (4) right lamina of thyroid cartilage; (5) posterior part of same, separated by oblique line from anterior part; (6, 7) superior and inferior tubercles, at ends of oblique line; (8) upper cornu of thyroid; (9) thyrohyoid ligament; (10) cartilago triticea; (11) lower cornu of thyroid, articulating with cricoid; (12) anterior part of cricoid; (13) cricothyroid membrane; (14) cricothyroid muscle; (15) posterior cricoarytenoid muscle, partly hidden by thyroid cartilage. (Courtesy, Symington: "Quain's Anatomy," London, Longmans, Green & Co., Ltd.)



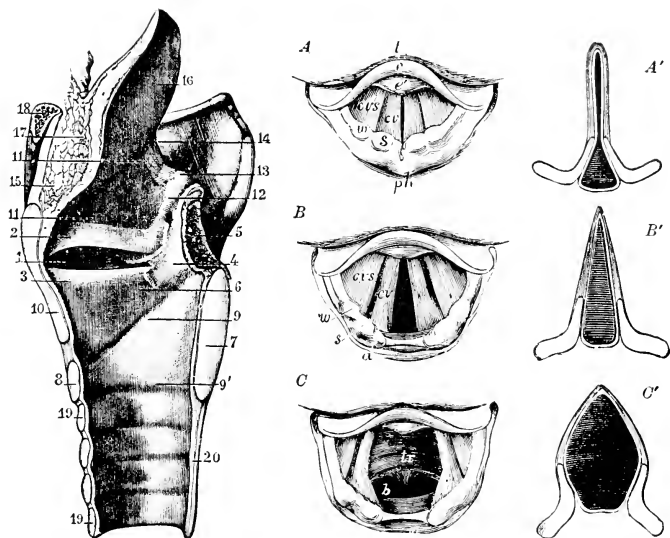


FIG. 471. (Left) Sagittal section of the larynx and the upper part of the trachea, with a view of the interior of their right halves. (Sappey.) (1) Ventricle; (2) plica ventricularis; (3) plica vocalis ("vocal cord"); (4) arytenoid cartilage covered with mucous membrane; (5) arytenoid muscle cut across; (6) slope of cricothyroid membrane leading up to ligamentum vocale; (7, 8) sections of cricoid; (9) its upper border; (9') its lower border; (10) section of thyroid; (11) upper part of larynx; (12, 13) glandular prominence in aryepiglottic fold; (14, 16) epiglottis; (15) fat between it and thyrohyoid membrane; (17) section of epiglottis; (18) section of hyoid bone; (19, 20) trachea.

(Right) Three laryngoscopic views of the superior aperture of the larynx and surrounding parts in different states of the glottis during life. (Czermak.) (A) The glottis during the emission of a high note in singing. (B) In easy or quiet inhalation of air. (C) In the state of widest possible dilatation, as in inhaling a very deep breath. The diagrams (A', B', C') have been added to Czermak's figures to show, in horizontal sections of the glottis, the position of the vocal ligaments and arytenoid cartilages in the three several states represented in the other figures. (l) Base of tongue; (e) upper free part of epiglottis; (e') tubercle or cushion of epiglottis; (ph) part of anterior wall of pharynx behind the larynx; in margin of aryepiglottic fold, (w, s) swellings of the membrane caused by the cuneiform cartilage; and the corniculum; (a) tip of arytenoid cartilages; (cv) plicae vocales; (cvs) plicae ventriculares; between them the ventricle of the larynx; in (C) (tr) is placed on the anterior wall of the receding trachea, and (b) indicates the commencement of the two bronchi beyond the bifurcation, which may be brought into view in this state of extreme dilatation. (Courtesy, Symington: "Quain's Anatomy," London, Longmans, Green & Co., Ltd.)

if the flap is bent backward over the anterior end of the larynx, the laryngeal cavity is quite effectually covered. Immediately posterior to the thyroid cartilage is the **cricoid**, which is a broad band of cartilage completely encircling the larynx. To the dorsal anterior edge of the cricoid are attached a pair of very small cartilages, the **arytenoids**. The laryngeal cartilages are tied together by ligaments which admit of slight movements of one cartilage in relation to another.

On the inside surface of each lateral wall of the thyroid cartilage is an inwardly projecting fold of the mucous layer which lines the larynx. The fold extends dorsoventrally, its dorsal end attached to the arytenoid of that side and the ventral end meeting the ventral end of the other fold at the midventral line of the inner surface of the thyroid (Fig. 471,3). These are the **vocal folds**, commonly called "**vocal cords**," but inaccurately so, for they are not literally "cords." The thyroid being incomplete dorsally, its lateral and ventral walls extend considerably anterior to the vocal folds. The glottis, in strict sense, is the slitlike opening between the vocal folds and not the much wider anterior aperture of the larynx as a whole. There is usually a second pair of folds situated anterior to the vocal folds and resembling them, but the space between their opposite free edges is much wider than the glottis. They are commonly called "**false vocal cords**" but, better, **ventricular folds**, the little pocket between each one and the adjacent vocal fold being known as the **ventricle** (Fig. 471, 1 and 2).

A complex set of small muscles effects slight movements of one part of the larynx in relation to another. There is a pair of external and ventral **cricothyroid** muscles whose contraction pulls the thyroid backward and downward in relation to the cricoid, thus increasing the tension on the vocal folds. To each arytenoid is attached a dorsal **cricoarytenoid** muscle whose contraction moves the arytenoid in such a way that the slit between the vocal folds is widened, and a **thyroarytenoid** situated on the inner surface of the larynx and acting to narrow the slit or close the glottis. Several other muscles are involved in the control of the vocal folds.

**Sound** is produced by vibration of the vocal folds, caused by more or less forcible passage of air, usually outward, through the glottis. By action of appropriate muscles, the degree of tension in the vocal folds may be varied, the length and thickness of the folds may be slightly changed, and the width and form of the glottic slit may be greatly changed. The pitch and quality of the sound depend primarily on these factors. The quality, however, is largely dependent on the resonant effects of vibration of air contained in all the air-filled spaces connected with the larynx, especially important being the pharynx and the oral and nasal cavities. The "false vocal cords" probably are not

directly concerned in production of sound, although it has been alleged that they are responsible for the cat's purring (Fig. 471, diagrams *A-C, A'-C'*).

At the moment when food is passing across the pharynx, breathing is stopped. The glottis is closed, the epiglottis is bent back over the laryngeal aperture, and the soft palate is moved upward against the roof of the nasopharynx, thus blocking the nasal passages. Any defect in the coördination of these several events may cause choking.

In **whales** and their allies, as in crocodilians, aquatic living increases difficulties in the pharyngeal region, which accordingly exhibits various modifications serving to emphasize the separation between the respiratory and the alimentary tracts. In sperm-whales the laryngeal wall and, especially, the epiglottis are greatly elongated so that the larynx projects forward into the nasopharynx, fitting it tightly and thus providing direct tubular connection between nasal and tracheal passages. Under similar necessity but quite different circumstances, the elongated larynx and epiglottis of the newborn kangaroo and other marsupials are inserted into the rear of the nasopharynx. This is an adaptation to the fact that, at time of birth, the marsupial is not yet sufficiently developed to be able to suck milk. For some time after birth, the young animal (actually a fetus) is continuously attached to a nipple of a mammary organ, and milk is injected into the young by contraction of a muscle (the **cremaster**) at the base of the nipple. Arriving in the pharynx, the stream of milk divides and passes around the tubular larynx and on into the esophagus, without interfering with the breathing.

Compared to the larynx of a mammal, the reptilian larynx (Fig. 60) is poorly developed, a fact consistent with the very inferior vocal abilities of reptiles. Cartilages apparently corresponding to the cricoid and arytenoids of mammals may be recognized. In the alligator certain folds on the inner surface of the laryngeal wall are probably concerned with the animal's roar, but the folds evidently do not correspond to mammalian vocal folds. As a vocal organ, the larynx of frogs and toads is much better developed than that of reptiles. In the laryngeal region of birds, cricoid and arytenoid cartilages are present but the region is only slightly differentiated, the vocal function having been shifted to the syrinx at the posterior end of the trachea.

The walls of the trachea are supported by regularly spaced transverse bands of cartilage which are usually incomplete rings, the deficiency being on the dorsal side where the trachea is in close proximity to the esophagus (Fig. 468). The dorsal gap in each skeletal ring makes the trachea more easily compressible and so facilitates passage of a bolus of food along the adjacent esophagus. Just anterior to the lungs,

the trachea divides into **right** and **left bronchi**. In some whales and some ungulates the trachea divides into three **bronchi** before entering the lungs.

### LUNGS

Within the lungs each **bronchus** divides repeatedly into tubes of successively smaller diameter, becoming reduced ultimately to the **bronchioles** (Fig. 472), each of which divides into several short **alveolar ducts** which differ from ordinary bronchioles in that the walls of the former are beset with numerous small outwardly bulging pockets, the **alveoli**. Each alveolar duct expands distally (the expanded region being sometimes distinguished as the **atrium**) and gives rise to one or more rounded saccules (or **infundibula**) whose walls contain close-set hemispherical alveoli like those of the alveolar duct. The essential wall of an alveolus consists of an inner layer which is an extremely thin epithelium. This is the primary endodermal pulmonary tissue. Externally, this epithelium is closely invested by a dense network of blood-capillaries. The capillary wall consists merely of an endothelium which is just about the thinnest possible layer of cells. Thus blood and air are brought so close together that the respiratory interchange of oxygen and carbon dioxide readily takes place by diffusion through the two apposed and exceedingly thin membranes. The alveoli provide the chief respiratory surfaces, but the characteristic thin respiratory epithelium and the accompanying capillary net may extend throughout the walls of the alveolar saccules and ducts and even into some bronchioles. But the larger bronchial passages within the lungs are lined by a relatively thick cuboidal and nonrespiratory epithelium. The walls of these larger passages are stiffened by incomplete cartilaginous rings similar to those of the trachea. The narrower bronchi have small irregularly placed plates of cartilage in their walls. Usually no cartilages occur in the walls of bronchioles, but in sea cows (*Sirenia*) and the whalelike mammals, even the bronchioles are supported by cartilages which are probably important in serving to prevent collapse of the small tubes under the tremendous pressure to which the animal is subjected when deeply submerged.

The many-branched bronchial system within a mammalian lung is often called the "**bronchial tree**." The term "**lobule**" is applied to the cluster of bronchioles, together with the terminal respiratory structures into which they lead, arising from one of the smallest bronchi (Fig. 472). The lobules and their constituent parts are all bound together and supported by fibrous connective tissue. In this tissue is a considerable proportion of elastic fibers. In the walls of the respiratory spaces the elastic fibers are especially abundant and are closely associated with a delicate network of smooth muscle-fibers.

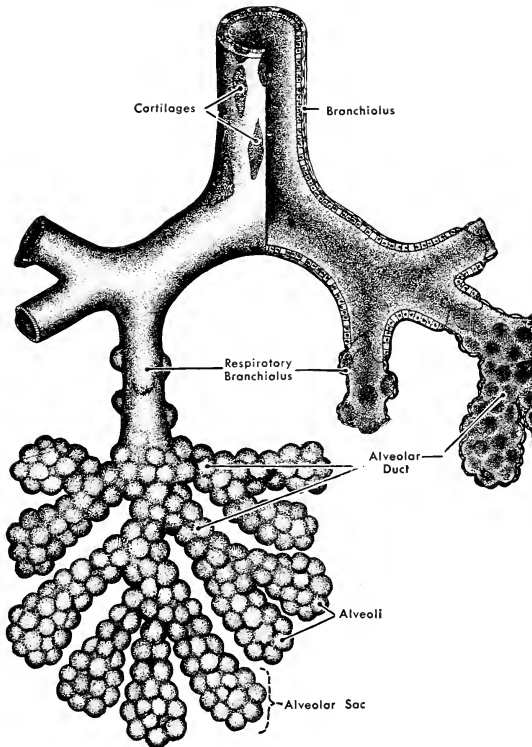


FIG. 472. Diagram of a lung lobule, showing the subdivision of a bronchiole into alveolar ducts, sacs, and alveoli. Respiratory epithelium may extend into the bronchioles. (After Bremer. Courtesy, Neal and Rand: "Chordate Anatomy," Philadelphia, The Blakiston Company.)

When the lungs are filled, the air-spaces are distended and the elastic fibers are stretched. Emptying the air-spaces during expiration depends largely on contraction of the elastic tissue, assisted more or less by muscular contraction.

The terminal respiratory structures are of minute dimensions. In man the nonrespiratory bronchioles have diameters of 1.0 mm. to 0.5 mm. The respiratory bronchioles are 0.5 mm. or less in diameter. A human alveolus is about 0.1 mm. in diameter at the end of expiration and may swell to a diameter of 0.3 mm. during inspiration. Attempts have been made to estimate the number of alveoli. The number varies

with the size of the animal and the corresponding size of the lungs; also, the size of the alveolus varies in different animals. The total respiratory area of the lungs has been estimated. According to F. E. Schulze (1906), the cat's lungs contain about 400,000,000 alveoli and the total respiratory surface is about 20 square meters. In the human lungs there are about 150,000,000 alveoli, but a single human alveolus has about four times as much surface as an alveolus of the cat. Therefore the total respiratory area in man is about 30 square meters. These estimates cannot be accurate, but they have at least comparative significance because the same method was applied to several animals.

**Lungs of Cetaceans.** The almost incredible ability of whales to endure long submergence presents problems. Accurate observations are difficult to obtain, but what seem to be conservative statements credit the blue whale and the cachelot (a sperm whale) with submergences lasting an hour or longer. A man cannot easily "hold his breath" for one minute. The following factors are probably involved in the whale's performance. In contrast to the fact that human lungs are rarely filled to capacity and never completely emptied, it is probable that, when the whale submerges, the lungs are filled to the limit. In view of the fact that elastic tissue is very much more strongly developed in whales' lungs than in lungs of land mammals, it may be inferred that there is comparatively little residual air in the whale's lungs after expiration. It has been reported, too, that the capillary net related to the air-spaces in the whale's lung is much denser than that in the lung of a land mammal, so that relatively more blood is exposed to the air, and that the red corpuscles of whale's blood are richer in the oxygen-carrier, hemoglobin. F. E. Schulze, cited above, estimated that a porpoise whose weight was about that of an average man had 437,000,000 respiratory alveoli, with a total surface of 43 square meters, in contrast to man's 150,000,000 alveoli and 30 square meters of surface.

When a whale returns to the surface after long submergence, it thoroughly cleans out the lungs by a succession of vigorous exhalations and inspirations—the characteristic "spouting." The nostrils are situated dorsally and far back from the anterior end of the head. The dorsal "blow hole" of the sperm whale is the common single nostril through which the two nasal cavities open externally.

#### COMPARISON OF LUNGS OF AMNIOTES

The lungs of reptiles, birds, and mammals are similar to the extent that they all possess an internal structure which serves to provide more or less expansion of respiratory surface, and in that this expansion results from elaboration of the posterior end of the bifurcated (forming

the two bronchi) endodermal pulmonary outgrowth from the ventral wall of the embryonic pharynx. But the expansion is effected in three quite different ways. The fully developed **reptilian lung**, as viewed in ordinary dissection, appears as a single large sac, usually of simple external form, more or less subdivided internally by incomplete partitions, which seem to arise as inward folds from the walls of the sac (Fig. 473D). In some cases the folds, projecting only slightly, intersect one another to produce shallow pockets so that the inner surface of the sac resembles a piece of honeycomb whose compartments have been laid open by cutting across the walls. Lungs of this simple structure, resembling lungs of frogs and toads, occur in *Sphenodon* and many lizards. More commonly the interior is divided into spaces of varying size and somewhat irregular arrangement, each opening freely into others. The extent to which this subdividing is carried and the arrangement of the spaces varies greatly in the several groups of reptiles. It is most elaborate in Crocodylia and Chelonia. The internal surfaces of the spaces are not smooth but are sacculated—i.e., beset with shallow pockets or alveoli resembling those which give the honeycomb appearance to the inner surface of the simpler lungs of anurans and some lizards. The region of the bronchus external to the lung is, like

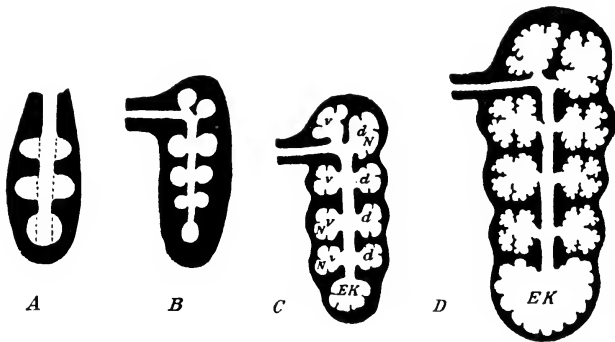


FIG. 473. Diagrams illustrating the budding of the bronchus in the developing lung of a turtle, *Emys*. (A) Buds from the intrapulmonary bronchus extend into the lung-wall. (B) The bronchus has given off several buds (primary pulmonary vesicles) extending into the thick wall of the lung. (C) The vesicles enlarge, the lung-wall becoming relatively thinner, and form chambers, of which four dorsal (*d*) and four ventral (*v*) are visible, each of which has developed secondary buds (*N*); the posterior end of the bronchus has enlarged to form a terminal chamber (*EK*). (D) Lung of adult. The several chambers have become enlarged and are separated from one another merely by thin septums, consisting of the reduced lung-walls; the secondary vesicles have given rise to buds of a third order, which form the lung-crypts (alveoli). (After Moser. From Wiedersheim. "Comparative Anatomy of Vertebrates." By permission of The Macmillan Company, publishers.)

the trachea, supported by rings of cartilage. Inside the more elaborately subdivided lung are wide and irregularly branching passages which are, in effect, continuations of the main bronchus but not so definitely tubular. In the complex lungs of *Chelonia* and *Crocodylia*, a wide central "bronchus" extends through nearly the entire length of the lung (Fig. 473*D*), opening laterally into several large spaces which, in turn, open into smaller spaces. Small irregular cartilages may occur in the walls of these main internal bronchial passages.

A study of its embryonic development shows that the adult reptilian lung is not to be interpreted as a sac subdivided by inwardly projected folds of its walls. It results, rather, from outgrowth of a cluster of pouches from the distal region of the growing bronchus—as if a cluster of soap bubbles were blown out from a pipe having several holes near its end. These pouches push out into a dense mass of mesenchyme which is the source of the connective tissue, smooth muscle-fibers, and blood-vessels of the lungs. The "partitions" of the adult lung, which look as if they had been formed by ingrowth of folds from the outer wall, result from the crowding together of walls of adjacent pulmonary "bubbles." The partition consists of pulmonary epithelium on each surface and a more or less thick layer of the mesodermal connective tissue between them. The outer wall of the lung as a whole is a mesodermal investment whose outermost layer is the pulmonary peritoneum (**pleura**). The internal complication of the lung results not from ingrowth of partitions, but from outgrowth of spaces.

Comparing amniote lungs, the differences seem more striking than the similarities. Even among **reptiles** the differences seem extreme, but they are differences in degree rather than in kind of complication. If several simple lungs such as occur in *Sphenodon* and some lizards were assembled around a common bronchial passage, all opening into it, the result would be such a lung as occurs in crocodylians and some turtles. Turning to **mammals**, it may be suggested that, if a single lobule of a mammalian lung (Fig. 472) were greatly enlarged, the result would be a system of spaces resembling those of the entire lung of a crocodylian, the bronchiole of the lobule corresponding to the central bronchial passage of the reptilian lung. **Birds** have gone beyond any such comparison, having completely abandoned pouches and saccules in their entirely **tubular lungs**.

As for **ventilation**, the reptilian lung of the simpler type is just one big "dead end." Those of more complex type are no better for having several or many "dead ends." The mammalian lung is a complex of millions of microscopic "dead ends." The bird lung, by virtue of its appended air-sacs, has no "dead ends."

Lungs intermediate in type between those of reptiles and those of



birds and mammals are not known. It is quite probable that they existed in *Archaeopteryx* and somewhere along the line of theromorph reptiles and the earliest mammals.

In some lizards, and especially well developed in the chameleon, the posterior end of the lung is prolonged into several elongated pouches whose very thin and simple walls are nonrespiratory. These **air-sacs** extend back into the posterior abdominal region. Their extreme inflation produces a marked swelling of the body—possibly useful in enabling the animal to intimidate its enemies. These reptilian air-sacs are of interest in connection with the existence of air-sacs in birds.

## II. Circulatory Organs

The statement that the adult mammalian skull is simpler than that of a reptile and much simpler than that of a teleost fish finds its parallel with reference to the circulatory system. In the early mammalian embryo the heart and main blood-vessels are laid down along the lines which they follow in fishes. In the later course of development there is much modification, the general tendency being to concentrate the blood channels into fewer and centralized vessels, as, e.g., by reduction of the several aortic arches of the embryo to such an extent that only a lateral half of one arch remains in its original relations, and by replacement of the pair of postcardinal veins by a single median postcava as the main venous channel of the trunk. The relative simplicity of the adult system is therefore secondary, as is true of the adult skull. Viewed in its entirety, the mammalian circulatory system is more complex than that of a fish because the adult pattern is achieved only by an elaborate metamorphosis of the originally complex system of the early embryo.

### HEART AND AORTIC ARCHES

In the early mammalian embryo the heart is a simple tube having a posterior auricular (or atrial) enlargement and an anterior ventricular enlargement whose outlet is a single undivided arterial trunk which leads forward into the several aortic arches (Fig. 474). Later the heart and its outlet become completely divided longitudinally so that the aerated blood from the lungs is entirely separated from the blood which is returned to the heart from the general systemic circulation. The systemic venous blood is received by the right auricle (atrium) and passes thence to the right ventricle, which pumps it to the lungs (Fig. 475). Returning from the lungs, the blood enters the left auricle (atrium) and passes thence to the left ventricle, which pumps it into the general arterial channels.

At the base of the aorta and of the pulmonary artery are **semilunar**

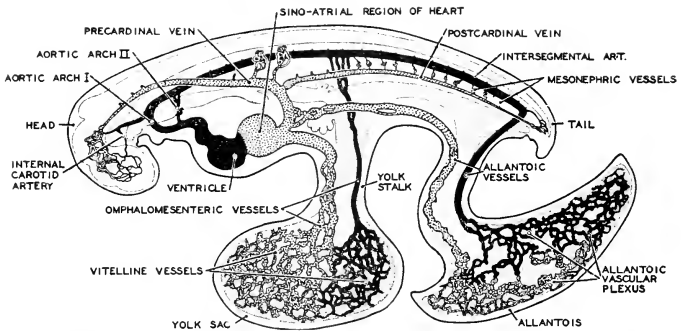


FIG. 471. The circulatory system of a young swine embryo. The arteries are shown in black; veins are stippled. All blood-vessels at this stage are paired, but those of the left side only are shown in the figure. (Modified from Patten: "Embryology of the Pig," Philadelphia, The Blakiston Company.)

**valves**, each being a projecting crescentic thin fold of the wall of the vessel that forms a small pocket so placed that backward pressure of blood distends it (Fig. 475). Ordinarily there are three such valves arranged in a set encircling the lumen of each arterial trunk. When distended, the three meet and completely occlude the lumen. Between each auricle and its ventricle are the relatively large **atrioventricular valves**. Each consists of two or three extensive folds of the lining of the heart (**endocardium**), so placed that under ventricular pressure they swell outward into the passage and close it. To the free edges of the folds are attached delicate tendons (**chordae tendineae**) which are connected to short **papillary muscles** projecting from the wall of the ventricle (Fig. 475). The chordae and their muscles prevent the membranous folds from being forced entirely through the passage. Usually the right valve consists of three flaps (**tricuspid valve**), while in the left are only two (**bicuspid** or **mitral valve**).

The **venous sinus**, a receiving chamber characteristic of the hearts of fishes, amphibians, and reptiles (more or less reduced in some reptiles), does not appear in the adult mammalian heart. But in the embryo it is present, formed by confluence of the veins which deliver blood into the auricle. Later it becomes unrecognizably merged into the wall of the right auricle. In this matter of the venous sinus, the hearts of birds and mammals are alike. In fact, so far as the adult hearts are concerned, there appear to be no important differences between mammalian and avian hearts. But in the relations of the main arteries which serve as outlets from the ventricles and in the embryonic history of the ventricles and their connections, there are radical differences.

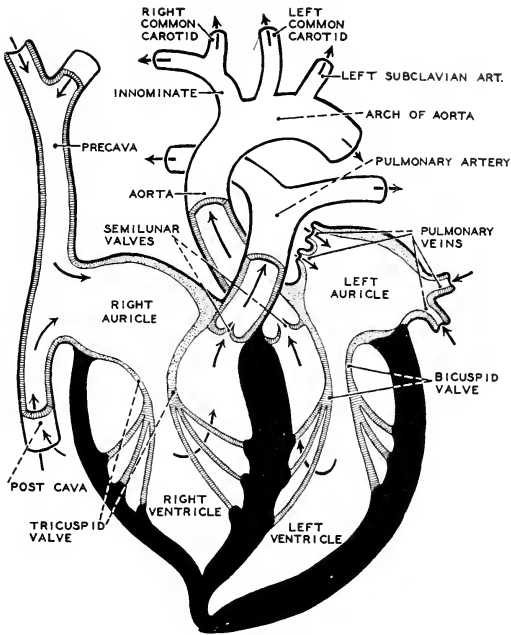


FIG. 175. Diagram (ventral view) of the chambers of the mammalian heart and their associated vessels and valves. The walls of the ventricles are shown in black; those of the auricles are stippled. The direction of flow of blood is indicated by arrows. (After Jammes, Courtesy, Neal and Rand: "Chordate Anatomy," Philadelphia, The Blakiston Company.)

In **adult modern reptiles** the ventral heart is connected with the dorsal aorta by two arteries which bend dorsalward, one on the right and one on the left, to join in the dorsal aorta (Fig. 176). This pair of vessels develops in the region of the **fourth visceral arch** of the embryo and therefore corresponds to the fourth of the several aortic arches of a fish. The relation of the two aortic trunks to the ventricles is extraordinary. Just anterior to their connection with the heart, the two vessels cross one another so that the one which passes upward on the right side connects with the left ventricle, and the vessel on the left comes from the right ventricle along with the main pulmonary trunk. This left vessel therefore carries "impure" blood. The ventricle in most reptiles has only an **incomplete partition** between right and left chambers. Accordingly, some mingling of aerated and nonaerated blood occurs in the ventricles. Even so, the right aortic trunk carries

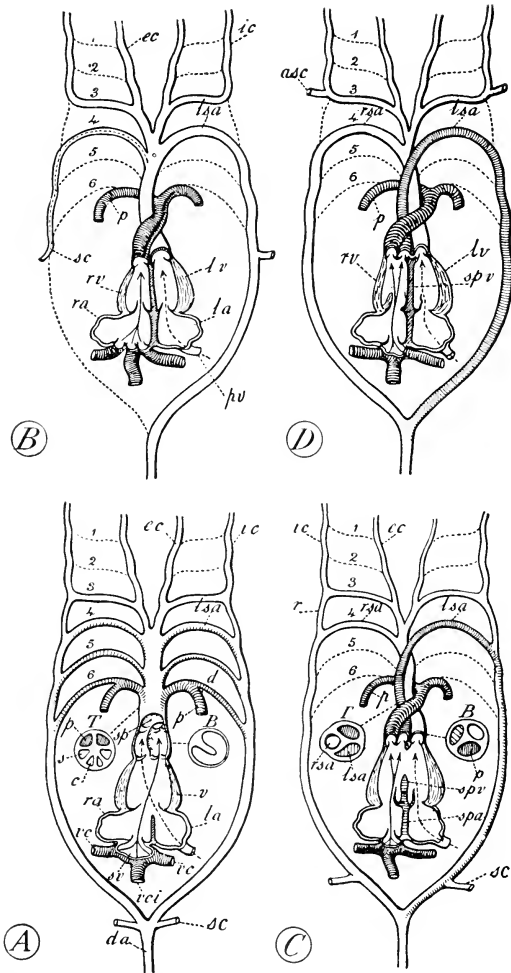


FIG. 476. Diagrams of heart and aortic arches in (A) an amphibian, (B) a mammal, (C) reptiles—Chelonia, Lacertilia, Ophidia, Rhynchocephalia, and (D) a crocodile. Ventral view of heart represented as untwisted so as to bring chambers into a single plane, with venous sinus behind and ventricle in front. (B) Transverse section of region of bulbus cordis; (r) transverse section of region of truncus arteriosus. [Author's note: The correctness of Goodrich's representation

blood of much better quality than that in the left. In view of this fact, it is significant that the arteries to the head (**carotids**) come off from the right aortic trunk. Also, the arteries (**subclavians**) to the forelegs receive blood from the right aorta. In lizards right and left subclavians come off together from the dorsal region of the right aorta. In crocodilians and chelonians the subclavians arise in conjunction with the carotids from a common trunk (**innominate**), which comes off from the right aorta ventrally and close to the heart. In crocodilians, whose ventricular septum is complete, the right aortic trunk carries quite pure aerated blood. But in all modern reptiles (including crocodilians) the left aortic trunk, usually of less diameter than the right, carries blood from the right side of the ventricle into the dorsal aorta and thus more or less vitiates the blood delivered by the aorta to the trunk and tail.

The embryonic development of a **bird's heart** is substantially like that of the reptiles. At an early stage, the fourth aortic arch is complete on both right and left sides, as it is permanently in reptiles, but, before the differentiation of the trunks at the apex of the ventricular region has been completed, the **left aortic trunk suffers complete degeneration**. (It has been reported that in rare cases the complete reptilian arrangement is temporarily present in the bird embryo.) Meanwhile, the subclavian and carotid connections are established, as in chelonians and crocodilians, with the **right aortic trunk**, which has become walled off so as to serve as the only outlet from the **left ventricle**. The left aortic arch having been obliterated, the **pulmonary trunk**, derived from the embryonic arch corresponding to the sixth of a fish, remains as the only outlet from the **right ventricle**.

In the **mammalian embryo** six aortic arches may be present, although not all at the same time (Figs. 474, 477). The more anterior arches begin to degenerate before the more posterior are fully developed. The fifth arch is rudimentary or, in some cases, not to be found at all. As in reptiles and birds, the permanent connection between the

FIG. 476.—(Continued)

of the subclavian arteries (*sc*) in (C) is questionable.] (*asc*) Anterior subclavian; (*d*) ductus Botalli; (*da*) dorsal aorta; (*ec*) external carotid; (*ic*) internal carotid; (*la*) left auricle; (*lsa*) left systemic arch; (*lv*) left ventricle; (*p*) pulmonary artery; (*pv*) pulmonary vein; (*r*) portion of lateral aorta remaining open only in *Sphenodon* and some *Lacertilia* as ductus arteriosus; (*ra*) right auricle; (*rsa*) right systemic arch; (*rv*) right ventricle; (*sc*) subclavian; (*sp*) septum; (*spa*) interauricular septum; (*spv*) interventricular septum; (*sv*) sinus venosus; (*v*) ventricle; (*vc*) vena cava superior; (*vci*) vena cava inferior. Arrows from sinus venosus indicate main stream of venous blood; arrows with dotted line from left auricles indicate stream of arterial blood. (1-6) Original series of six embryonic aortic arches. (From Goodrich: "Studies on the Structure and Development of Vertebrates." By permission of The Macmillan Company, publishers.)

heart and the dorsal aorta is by way of the **fourth aortic arch**. A remnant of the third arch persists, forming the posterior region of the carotid arteries. The dorsal region of the **sixth arch** degenerates, leaving the ventral parts of the two vessels to become the **pulmonary arteries**.

In development of the mammalian heart, the primarily undivided arterial trunk at the apex of the primarily undivided ventricle becomes divided by a longitudinal septum so placed as to separate its lumen into a **ventral space** into which open the right and left vessels of the **fourth aortic arch**, and a **dorsal space** into which open the two members of the **sixth aortic arch**. This septum then grows backward, but twisting spirally to such a degree that the spaces on either side of its more posterior region are right and left instead of dorsal and ventral as they are anteriorly. The now median (sagittal) posterior edge of this septum finally joins the anterior edge of the septum between right and left ventricles, with the result that the anterior ventral space (**fourth arch**) continues back as the posterior **left space**, while the anterior dorsal space (**sixth arch**) continues back as the posterior **right space**. Completion of the process of splitting the ventricle and its aortic outlet leaves both right and left members of the **fourth aortic arch** opening by a common trunk from the **left ventricle**, while ventral remnants of the **sixth arch**, having made connections with the lungs, join in a common trunk which is the only outlet of the **right ventricle**. Each **subclavian artery** develops as a branch of the aortic trunk of its own side. In the later embryo, that part of the right arch intervening between the dorsal aorta and the right subclavian completely disappears. A certain extent of the basal region of the adult "subclavian" is therefore a persisting ventral remnant of the embryonic right aortic trunk (Figs. 176, 177). Incidentally, it appears that the mammalian subclavians, arising dorsally as branches from the right and left trunks of the fourth arch, are not to be regarded as homologous with subclavians which arise ventrally as branches of the carotids, as happens in chelonians, crocodilians, and birds.

**Comparison of reptiles, birds, and mammals** reveals two radically different patterns in the arrangement of the main arteries leading out from the heart and in the relations of these vessels to the ventricular cavities. In adult animals of all three Classes there is a large degree of asymmetry in the plan of these arteries (Figs. 73, 176). In birds the pattern of the asymmetry is identical with that of modern reptiles, with the important difference that the left aortic arch is only temporarily present in birds. This, however, does not alter the pattern. It is merely omission of one element of the pattern. In reptiles right

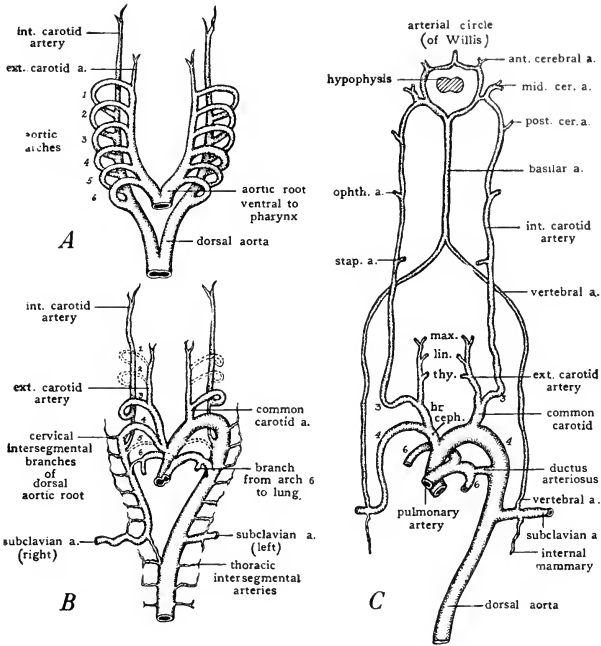


FIG. 177. Diagrams illustrating the changes which occur in the aortic arches of mammalian embryos. (A) Ground plan of complete set of aortic arches. (B) Early stage in modification of arches. (C) Derivatives of aortic arches. (br. ceph.) Brachiocephalic artery; (cer. a.) cerebral artery; (lin.) lingual artery; (max.) maxillary artery; (ophth. a.) ophthalmic artery; (stap. a.) stapedia artery; (thy.) thyroid artery. (Adapted from several sources. Courtesy, Patten: "Embryology of the Pig," Philadelphia, The Blakiston Company.)

and left aortic trunks cross one another, each opening into the ventricle of the opposite side. This extraordinary arrangement is virtually repeated in birds in that the persisting right aorta emerges from the left ventricle. In mammals only two arterial trunks, one from each ventricle, emerge from the heart, in contrast to the three in reptiles. Whereas in reptiles the right and left trunks of the fourth arch connect, respectively, with the left and right ventricles, in mammals both the right and left members of the fourth arch connect with the left ventricle. There is at no time a crossing of the two trunks.

Omission of the left aortic trunk in birds is physiologically intelligible. To the cold-blooded reptile, the left trunk, pouring blood from

the right auricle into the dorsal aorta, is not seriously detrimental, but it would be intolerable in a bird whose high temperature and high output of muscular energy require a blood having maximum content of oxygen.

**Abnormalities** of the blood-vessels are frequent, affecting even the main trunks. Among the many and varied abnormalities which have been found in man are numerous cases in which the right aortic trunk has been retained instead of the left, but still opening into the left ventricle. In these cases the basal region of the left subclavian is presumably a persisting remnant of the left aortic trunk. In rare human cases both right and left aortic trunks persist, both opening into the left ventricle.

In their embryonic history and their relations in the adult condition, the heart, and the arteries derived from the aortic arches in mammals, differ in such manner and to such a degree from those of birds as to put a great phylogenetic gap between the two Classes. It is true that, in minor details of their arrangement, blood-vessels are notably erratic. Normally a cat has a single artery passing from the dorsal aorta into each kidney, but among the many cats dissected in laboratories are frequently found individuals having two or three arteries passing to one kidney, and the number may not be the same on the two sides of the body. But the differences in the relations of the ventricles to the main arterial trunks leading out from them are of radical nature and involve the basic symmetry and relations of a large group of most important vessels. While abnormalities more or less commonly occur, each Class of Amniota has its characteristic pattern to which the very great majority of its members strictly adhere. The avian pattern is essentially like that in all modern reptiles and, in its details, most closely similar to that of Crocodylia. The mammalian pattern is radically different from that of any known modern reptile. Concerning the blood-vessels of extinct reptiles we are completely ignorant and doubtless must always remain so.

The available facts point to the conclusion that, early in the history of Reptilia, a cleavage in the group occurred. Along one line, or several related lines, was developed the vascular pattern which we now find in all modern reptiles and, with mere omission of the left aortic trunk, also in birds. Along another line developed the pattern found in modern mammals. There is convincing evidence that such a cleavage did occur. Those early reptiles of the theromorph type, with their synapsid skull, secondary bony palate, modified jaw-joint and heterodont teeth, had already diverged far from the main reptilian stock which went on to give rise to the dominant reptiles of the Mesozoic and the several



orders which still survive. It is highly probable that this divergence toward the mammalian type involved not only features of skeleton and teeth but also the organs of respiration and circulation. Along the line initiated by the theromorph reptiles must have appeared **minutely alveolar lungs** and a **vocal laryngeal organ** of the mammalian type, and an arterial pattern whose key feature is persistence of the **left aortic trunk** as sole outlet from the left ventricle and the only connection between heart and dorsal aorta. Along other lines, the lungs acquired the coarsely saccular structure seen in modern reptiles. One of these lines, its early history quite unknown to us, must have witnessed the transformation of saccular into tubular lungs, the development of the ultrapulmonary avian air-sacs, and the shifting of the function of vocalization to a syrinx at the posterior end of the trachea. Meanwhile, the arterial pattern became that which is characterized by the crossing of the right and left trunks of the fourth aortic arch and the concentration of functional importance on the right trunk, whose connection is with the left ventricle. The term "**Sauropsida**" was proposed by T. H. Huxley to include all reptiles and birds. It has more recently been suggested that it would be better to restrict the term to include birds, all modern reptiles, and extinct reptiles exclusive of those which were in the main line of mammalian descent. Then the mammals, together with their reptilian progenitors beginning with the theromorphs, could be designated as the "**Theropsida**" (meaning "mammal-like"; not to be confused with "**Therapsida**," a group of theromorph reptiles).

The persistence of the right instead of the left trunk of the embryonic fourth arch in a mammal results in a condition which looks quite avian. But it cannot be imagined that there is any genetic or causal relation of any sort between the abnormality and the condition in birds. Certainly there have been no birds in the mammalian "family tree." The presence of both right and left vessels of the fourth arch in an adult mammal is deceptively reptilian, but the fact that both the right and the left vessel come off by a common trunk from the left ventricle absolves the animal of any suspicion of being a reptilian "throwback." The fact that in all Classes of vertebrates the early embryo possesses a simple and longitudinally undivided heart and ventral aorta and a set of aortic arches makes possible such abnormalities as these. Their occurrence must be due to some derangement of the developmental mechanism, the nature and cause of it unknown. Any resulting resemblance to the vascular pattern of some other Class is probably merely incidental and may not safely be interpreted as a case of reversion so long as the abnormality involves only a single element of the complex pattern.

## VEINS

In the arrangement of the veins, the one major difference between mammals and reptiles has to do with the renal-portal system. In Anamnia the blood from the caudal and pelvic regions is collected into a pair of renal-portal veins, each of which passes into the corresponding mesonephric kidney and distributes the blood throughout the renal capillary system (Fig. 76). Emerging from the capillaries, it passes into efferent veins which return it to the heart by way of the postcardinal (most fishes) or the postcava (Dipnoi and Amphibia).

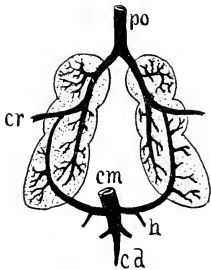


FIG. 178. Renal circulation of bird. (*cd*) Caudal vein; (*em*) coceygoesenteric vein; (*cr*) crural vein; (*h*) hypogastric vein; (*po*) postcava. (After Gegenbaur. Courtesy, Kingsley: "Comparative Anatomy of Vertebrates," Philadelphia, The Blakiston Company.)

The blood-supply to the mesonephros is chiefly venous, the renal arteries being relatively small. In embryos of all Amniota the posterior region of each postcardinal vein is in close relation to the mesonephros, and the two veins early establish a typical renal-portal arrangement in which blood from the posterior part of the embryo passes through a plexus of fine vessels in each mesonephros. When, in later course of development, the mesonephros is replaced by the metanephros as a definitive kidney, the renal-portal arrangement may extend backward into the territory of the metanephros, but with more or less modification and reduction. In adult reptiles there is a renal-portal system, but more or less of the blood which it carries into the kidney passes directly through by way of large veins which do not break up into capillaries. The arterial supply to the metanephros is correspondingly increased. In birds there is merely the outer

semblance of a renal-portal system (Fig. 178). A large vein commonly called "renal-portal" enters the posterior end of each metanephric kidney, carrying blood from the posterior region of the animal, but the vein passes forward through the kidney without dividing into capillaries and joins the iliac vein, which empties into the postcava. The so-called "renal-portal" may give off a few very small branches into the posterior lobe of the kidney, but it is certain that most, if not quite all, of its blood passes into the postcava without having entered renal capillaries. The blood-supply to the kidney is therefore mainly or entirely arterial. In mammals development of the metanephros is accompanied by complete obliteration of the renal-portal system. In the adult the veins from the caudal and pelvic regions do not enter the kid-

ney at all, but connect directly into the hind end of the postcava (Fig. 71E). Only arterial blood enters the kidneys.

In some mammals, but not characteristic of the Class as a whole, there is a striking modification of the embryonic venous system. In all vertebrates the embryo develops a right and a left **precava vein (duct of Cuvier)**, each formed by union of the **postcardinal**, **precardinal (jugular)**, and **subclavian** of its side of the body, and both opening into the right auricle. In later embryonic stages of many mammals a large vein develops, extending transversely and just anterior to the heart, connecting the left precava, or the posterior end of the left precardinal (jugular), with the right precava. The result is that some blood from the left side flows across into the right precava (Fig. 479, *left*). In some mammals (sloths, anteaters and other "edentates"; whales; sea cows; carnivores; monkeys, apes, man), after the establishment of this connection, that part of the left precava intervening between the transverse vein and the heart eventually undergoes complete atrophy so that all the blood carried by its former tributaries flows across into the right precava (Figs. 71E, 479, *right*). In the Australian duckbill and spiny anteater (both egg-laying mammals), in marsupials, and, with some exceptions, in insectivores, rodents, bats, and ungulates, both precaval veins persist although in some cases the cross connection between them is established.

The absence of the left precava in the adult mammal results in an asymmetry of the main venous trunks equaling that of the aortic trunks. A certain balance, or convenient spacing of the large vessels

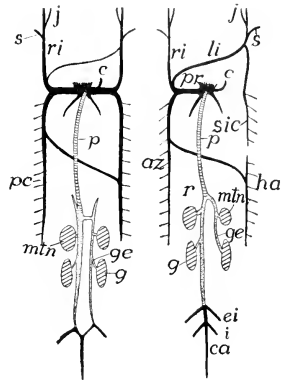


FIG. 179. Late embryonic stages in the development of the veins of a mammal. Ventral views. (*Left*) Right and left postcardinals and precardinals (*ri*) symmetrically developed and with a cross connection established between corresponding right and left veins. (*Right*) Later stage. Reduction of left postcardinal; obliteration of left Cuvierian duct leaving left jugular and subclavian connected only with the right Cuvierian duct (precava). (*az*) Azygos major; (*c*) coronary vein; (*ca*) caudal vein; (*ei*) external iliac; (*g*) gonads; (*ge*) genital (spermatic, ovarian) vein; (*ha*) hemiazygos; (*i*) ischiadic; (*j*) jugular; (*li*) left innominate; (*mtn*) metaephroi; (*p*) postcava; (*pc*) postcardinal; (*pr*) precava; (*r*) renal; (*ri*) right innominate; (*s*) subclavian; (*sic*) superior intercostal. Postcaval elements are crosslined; subcardinal, dotted; other veins black. (Courtesy, Kingsley: "Comparative Anatomy of Vertebrates," Philadelphia, The Blakiston Company.)

close to the heart, is achieved by retention of the *right* precava along with the *left* aortic trunk. The loss of the left precava is an extreme case of the simplification of the vascular system by concentration and reduction of the main channels.

#### LYMPHATICS

The mammalian lymphatic system is characterized by absence of "lymph-hearts," presence of numerous valves in the larger trunks, and the development of many large and definitely localized lymph-glands (Fig. 66).

In all vertebrates the walls of the larger lymph-vessels contain a thin layer of muscle. In anamniotes and reptiles certain localized regions of the larger lymphatics possess a thicker muscular layer rendering the region more strongly contractile—a "lymph-heart." In or near these "hearts" are valves similar to those found in veins. Contraction of the lymph-hearts drives lymph toward the veins into which the lymphatics open, the valves being so set as to prevent flow in the reverse direction. Such lymph-hearts are especially well developed and numerous in urodele amphibians, fewer in frogs and toads, in reptiles reduced to a single pair in the dorsal pelvic region, and in the bird embryo to a single pelvic pair which do not persist in the adult. In mammals lymph-hearts ordinarily do not occur, although on some of the lymphatics of bats have been found some enlarged thick-walled regions resembling lymph-hearts.

The flow of the fluid in mammalian lymphatics is due to several factors aside from contraction of the vessels themselves. Throughout the body the volume of lymph is continually being increased by the passage of blood-plasma through the very thin walls of the capillaries into the minute intercellular spaces. Some initial pressure is therefore maintained at all points of origin of the lymph. Blood-pressure is at a minimum in the larger veins, and it is into these veins that the main lymph-channels eventually open. Accordingly, the movement of lymph is from a region of higher to one of lower pressure. An additional and important factor in mammals is indicated by the usual absence of lymph-hearts and the presence of valves set at short intervals along the larger trunks (Fig. 480). When a bulky muscle such as those of the body-wall and appendages contracts, pressure must be exerted on vessels which are adjacent to it. Internal pressure in the lymphatics is low. When external pressure is increased, a thin-walled lymphatic is flattened and the lymph escapes from the compressed region in the only direction permitted by the valves—that is, toward the veins. Upon release from external pressure, the compressed region of the lymphatic refills from the reverse direction.

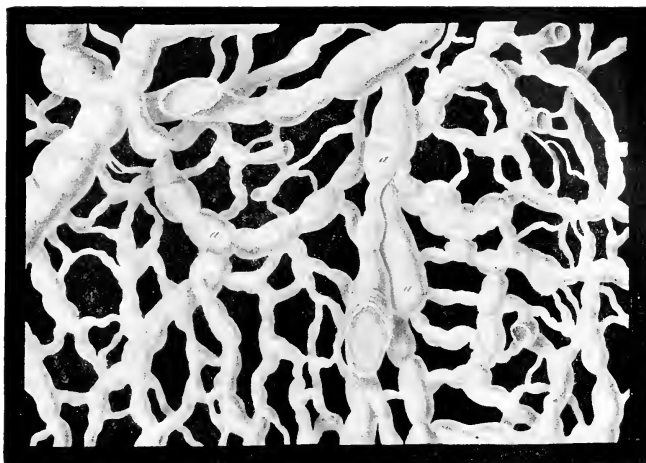


FIG. 480. The lymphatics of the human scrotum, showing the transition from capillaries to vessels with valves (*a, a, a*). (After Teichmann. Courtesy, Jackson: "Morris' Human Anatomy," Philadelphia, The Blakiston Company.)

Veins also contain valves permitting flow only toward the heart. They are especially numerous in veins of the body-wall and appendages, less so in the visceral veins, and entirely lacking in veins of the brain and spinal cord which are not subject to external muscular pressure. Acceleration of flow of lymph into the veins and flow of venous blood toward the heart is a vitally important by-product of vigorous muscular exercise. In birds the lymph-vessels contain valves, but they are less numerous than in mammals. In the absence of lymph-hearts, it is probable that the flow of lymph in birds, as in mammals, is partly dependent on compression of the vessels by adjacent muscles.

**Lymphoid tissue**, whose main function is production of **lymphocytes** (p. 329), exists in all vertebrates, occurring in small masses widely distributed over the body. In Amniota it also becomes locally aggregated to form definite organs or "lymph-glands" (cytogenic, not secretory glands; see p. 310). Doubtfully present in reptiles, a few lymph-glands occur in birds, but in mammals they are numerous, usually definitely localized, and some attain considerable size—e.g., the originally misnamed "**pancreas Aselli**" in the mesentery of the cat. The larger lymph-glands occur in the cervical, axillary, and inguinal regions, where they are either subcutaneous or lie between muscles. There are numerous lymph-glands also on the walls of the thoracic and abdominal viscera and in the mesenteries. The glands

are interpolated along the course of larger lymph-vessels whose fluid circulates through the spaces of the spongy lymphoid tissue (Fig. 481). The glands not only are seats of formation of lymphocytes but also serve a highly important protective function in that phagocytic cells in the endothelial walls of the lymph-spaces may remove bacteria or other foreign bodies or harmful substances from the lymph-stream.

**Mammalian blood** has one feature which is characteristic of the Class. The fully mature **erythrocytes contain no nuclei**. The nucleus of the young red blood-cell eventually degenerates and is completely obliterated.

### III. Alimentary System

In the alimentary system the features which are most characteristic of Mammalia are found in the mouth.

#### TEETH

The **heterodont teeth** are, in most orders, highly specialized in adaptation to the nature of the food and the manner in which the teeth are used. The toothed cetaceans (sperm whales and some others, porpoises, dolphins) are exceptional in being homodont, all their teeth having the same simple and usually conical form. In their form, cetacean teeth resemble teeth of the type commonly found in fishes, but they

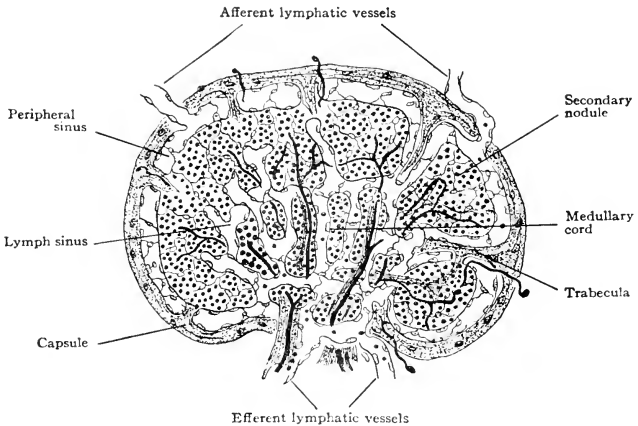


FIG. 481. Diagram representing two stages in the development of a lymph-gland. The left half of the diagram is an earlier stage than the right half. (Modified from Bremer: "Text-Book of Histology," Philadelphia, The Blakiston Company.)

are situated only on the jaws, whereas in fishes there may be numerous teeth on the roof of the mouth and even on the hyoid and branchial arches.

The **number of teeth** varies within broad limits. The following statements concerning number refer to functional teeth in the adult. Quite **toothless** are the Australian duckbill (*Ornithorhynchus*) and spiny anteater (*Echidna*); South American anteaters (Myrmecophagidae) and the Asiatic and African pangolins (Manidae); whalebone whales (*Mysticeti*) and the female narwhal (*Monodon*). The **extremes in number** of teeth occur in the one Order, Cetacea. The male narwhal (*Monodon*) has normally only one functional tooth which is exaggerated into a slender, straight tusk protruding directly forward from the left side of the upper jaw (Fig. 482). The corresponding right tooth is rudimentary. In females both are rudimentary. Spiral grooves on the surface of the tusk indicate a twist acquired during its growth. Its length is one-third to one-half that of the body, or as much as 9 or 10 feet in full-grown narwhals. Certain beaked whales, *Mesoplodon* and *Ziphius*, and the "bottlenose" whale, *Hyperoödon*, have only one pair of functional teeth in the lower jaw and none in the upper. In various other cetaceans the number ranges upwards—several or many pairs, and situated on both upper and lower jaws, but only on the lower jaw of sperm whales—to a maximum of 200 or more in some dolphins. In **heterodont placental mammals** a typical permanent dentition includes 44 or 48 teeth, but in many mammals the number is less than that and in some it is greater.

**Replacement** of a first or "milk" dentition by a second or permanent dentition (the **diphyodont** condition) may fairly be said to be characteristic of mammals, in contrast to the indefinitely repeated replacement (**polyphyodont** condition) of other vertebrates. The second dentition endures throughout the animal's life or, in event of loss of any of its members, they are not replaced. There are, however, some mammals which have only one obvious dentition, and these have been described as **monophyodont** (marsupials, some insectivores, cetaceans, sea cows). But the embryos of "monophyodont" mammals



FIG. 482. Narwhal skull. Bone has been removed to expose the root of the tusk and the rudimentary tusk of the other side. (Courtesy, Flower and Lydekker: "Introduction to the Study of Mammals." London, A. & C. Black, Ltd.)

commonly possess tooth-germs arranged in two rows, one in front of the other. Those of one row develop into functional teeth. The others disappear or may persist as useless rudiments buried within the jaws (see p. 54).

The various adaptive modifications of the teeth are mentioned in the descriptions of the Orders of mammals.

#### SALIVARY GLANDS

A dry oral cavity would require a lining of cuticula or horn to protect the living tissue of the oral surface. The most advantageous situation for sense-organs of taste is within the mouth. The most effective means of producing a sensation of taste is a solution of food substance acting to stimulate sensory cells so situated as to be easily accessible to the solution. The foregoing statements imply reasons why the oral cavity must be kept wet. Passage of food through the mouth will be facilitated if the surfaces are not only wet but also slippery.

In all vertebrates the lining of the mouth is glandular. In **aquatic animals** there is no difficulty about keeping the mouth wet, but glands are important in supplying a lubricating mucus. The oral mucous glands of anamniotes are mainly of the primitive unicellular type and are widely distributed on the oral surfaces. In **terrestrial vertebrates** the increased importance of oral glands is attested by development of the more efficient multicellular glands. In terrestrial amniotes small multicellular glands are more or less abundantly distributed over the oral surfaces. Some of them are **serous**, producing a watery secretion, others are **mucous**. Added to these small and diffusely distributed glands are larger and definitely localized glandular complexes which, according to their location, are designated as **labial**, **buccal**, **lingual**, **orbital** (on the floor of the orbit), or **molar**. Such local glands appear in terrestrial amphibians (e.g., the **intermaxillary gland**) and to a greater extent in reptiles and birds, but it is in mammals that they are most conspicuously developed and acquire highest functional importance by adding to their primitive functions the secretion of substances which begin the digestion of food.

Three pairs of large oral glands are especially characteristic of mammals—the **parotid**, **submaxillary**, and **sublingual** (Fig. 483). There are various other localized glands, but they are smaller and less constant in their occurrence. The **parotid** is the largest, situated superficially at the rear of the cheek and base of the external ear. Its duct (**Steno's duct**) opens on the inside of the cheek. The disease known as "mumps" is an infection of this gland. The **submaxillaries** (more logically called **submandibular**) lie beneath the floor of the mouth at the rear of the lower jaw. The two ducts (**Wharton's ducts**)



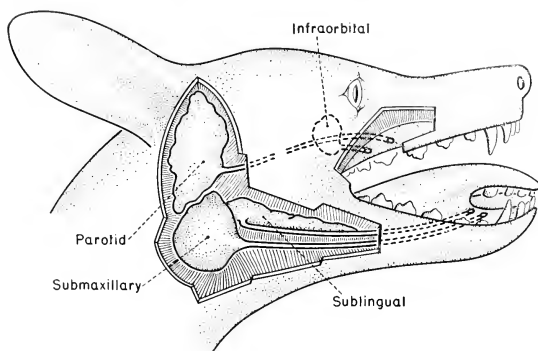


FIG. 433. Salivary glands of dog. The posterior region of each upper jaw, and the intervening region of the roof of the mouth have been cut away so as to expose the inside surface of the left cheek and bring into view the oral opening of the left parotid duct and, just behind it, that of the left intraorbital duct. The ducts of the submaxillary and sublingual glands open close together at the front of the base of the tongue. (Modified from Owen: "Comparative Anatomy and Physiology of Vertebrates," London, Longmans, Green & Co., Ltd.)

open on the floor of the mouth in front of the attachment of the tongue. A smaller gland, the **sublingual**, lies immediately anterior to each submaxillary, usually opening by several small ducts laterally to the tongue. These three pairs of glands collectively produce **mucin** and a watery or **serous** secretion, and two digestive enzymes—**ptyalin** and **maltase**. In man the parotid is entirely serous, producing no mucin, but the submaxillary and sublingual are "mixed" glands, producing both mucin and a serous secretion containing the enzymes (Fig. 434). An individual cell of the gland, however, is either serous or mucous, never both. The combined secretions of the glands constitute **saliva**.

The **digestion of starch** is initiated by the saliva. In the presence of **ptyalin**, the large and highly complex molecule of starch is disrupted and transformed into sugar molecules of the more complex sort (**maltose**). By action of the **maltase** (secreted also by the pancreas and anterior intestine), these are broken down to form the simpler sugar molecules (dextrose) which are capable of being absorbed and used for nutrition. It is obvious that salivary digestion is most important in animals whose food is well masticated and mixed with saliva in the mouth. After the food is swallowed, the digestive action of the saliva may continue until the normal alkalinity of the saliva is neutralized by the acidity of the gastric secretions.

In the wholly aquatic mammals salivary glands are very much reduced or entirely lacking.

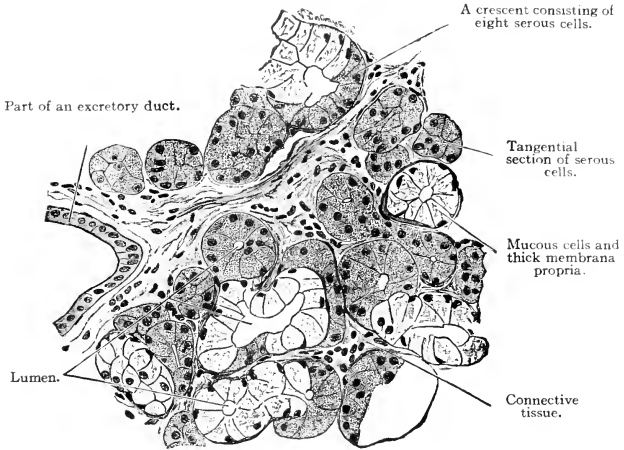


FIG. 184. Section of a human sublingual gland. ( $\times 252$ .) (Courtesy, Bremer: "Text-Book of Histology," Philadelphia, The Blakiston Company.)

### PHARYNX AND ESOPHAGUS

The peculiarities of the mammalian **pharynx** have been described in connection with the account of the respiratory passages (p. 610). The **esophagus** varies in length according to that of the neck. It is relatively narrow in mammals, consistent with the fact that they, in contrast to most other vertebrates, ordinarily swallow food in small portions. The cat ingests a mouse in numerous morsels, but so small a snake as a copperhead swallows a mouse, or even a rat, entire, and a python may swallow a whole pig. Such habits require a wide, or at least a highly distensible, gullet.

### STOMACH

The **stomach** exhibits many varieties of form. In most mammals it is a simple, more or less elongated, saclike enlargement of the digestive tube, the **cardiac region** of it (next to the esophagus) being of greater diameter than the **pyloric region**. The long axis of the stomach commonly extends more or less nearly transversely to the long axis of the body, the cardiac end being at the left. In many mammals the wall of the stomach acquires constrictions which divide the organ into two, three, or even four successive communicating compartments. This complication of the stomach is most marked in cetaceans and the cud-chewing (ruminant) ungulates. In the porpoise and most whales the stomach is divided into three or four major chambers, and

in some whales there are more. In the ox and sheep there are four chambers, specialized in relation to the habit of rumination (Fig. 370).

### INTESTINE

The digestive tube posterior to the stomach is divided into a longer anterior ("small") intestine and a shorter posterior ("large") intestine. In each of these, differentiated regions may be recognized. Depending

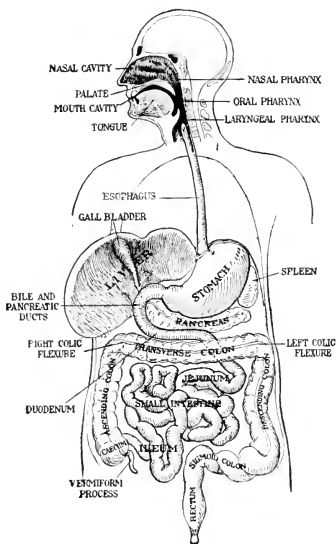


FIG. 185. Diagram of the human alimentary canal. Ventral view. (Courtesy, Jackson: "Morris' Human Anatomy," Philadelphia, The Blakiston Company.)

on differences in its glandular and absorbing structures, three regions of the anterior intestine may be distinguished—a **duodenum** adjoining the pylorus, a middle **jejunum**, and a posterior **ileum**. In the comparatively short "large" intestine, an anterior region, the **colon**, is marked by greater diameter and by walls which are sacculated—i.e., having many close-set, outward-bulging, shallow pockets arranged in longitudinal rows (Fig. 185). The shorter terminal **rectum** is narrower and not sacculated.

The passage of intestinal contents from the anterior into the posterior intestine is usually controlled by an **ileocolic valve** consisting

of a circular constricting muscle (sphincter) situated in an inward-projecting circular fold of the wall of the tube.

One of the several ways whereby the secreting and absorbing surface of the intestine is increased is the formation of pouches or **ceca** protruding outward from the main tube. In Amniota the colon commonly produces one or more ceca which, with rare exceptions, arise just behind the ileocolic passage. A single short colic cecum

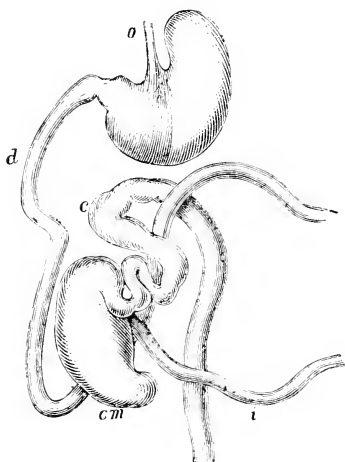


FIG. 136. Alimentary canal of rat (*Mus decumanus*), the greater part of the small intestine being omitted. (c) Colon; (cm) cecum; (d) duodenum; (i) ileum; (o) esophagus. (Courtesy, Flower and Lydekker: "Introduction to the Study of Mammals," London, A. & C. Black, Ltd.)

appears in most reptiles, but there is none in crocodilians. Birds usually have two ceca at the anterior end of the short posterior intestine, and these may attain great length (p. 530). In mammals there is usually but one cecum (Figs. 135, 136). It is situated in close relation to the ileocolic valve, which, in fact, may become an **ileocecal valve**. But in rare cases (e.g., the six-banded armadillo) there are two ceca, while a cecum is entirely lacking in the pangolin (*Manis*), the South American giant anteater (*Myrmecophaga jubata*), sloths, some cetaceans, some carnivores, and most bats. The Asiatic coney, *Hyrax*, has a moderately large cecum in the usual position and a pair of capacious ceca at a more

posterior position on the colon. In some cases (e.g., giant anteater and some whales) there is no definite ileocolic valve.

In degree of development the cecum exhibits a wide range of diversity, even among mammals of the same Order or Family. In general, it is more capacious and more highly differentiated in herbivores than in carnivores. In the horse it is about  $2\frac{1}{2}$  feet long and 8 inches in diameter. In the rabbit it is 15 to 18 inches long and an inch or more in diameter, except in the distal fourth or third of its length. This region is much narrower and its thickened wall contains much lymphoid tissue. The narrow region is known as the **vermiform appendix**. In the wider part of the rabbit's cecum an inward-projecting fold of its lining winds spirally from end to end of the lumen, greatly increasing the functional surface of the cecum. It strikingly resembles the **spiral valve** of the elasmobranch intestine. In the cat the cecum is little more than a half-inch long, and there is no appendix unless the somewhat pointed and thicker-walled distal tip of the cecum can be regarded as a vestige of an appendix. In man the cecum is very short but it bears an appendix which is usually 3 or 4 inches long (Fig. 485). The human appendix is highly variable and sometimes has no lumen. Its wall contains much lymphoid tissue, but physiologically the organ seems to be more of a liability than an asset.

#### IV Urinogenital System

##### EXCRETORY ORGANS

The mammalian **kidneys** are **metanephric**, each developing at the anterior end of a duct, the **ureter**, which grows forward from the mesonephric (Wolffian) duct, arising near the junction of the latter with the embryonic cloaca. In the adult the kidneys are on the dorsal body-wall and near the middle of the length of the abdominal cavity, but often not exactly opposite one another. In the several groups of mammals there is considerable variation as to the external form and general anatomy of the kidneys.

In **development of the metanephros**, branches bud out from the anterior tip of the embryonic ureter (Fig. 487). Each branch becomes the outlet of an elaborate system of numerous renal tubules, whose excretory parts are derived from the kidney-forming (nephrogenic) tissue of the adjacent mesoderm of the body-wall (p. 82), the whole complex constituting what is called a **renal lobule**. The number of lobules varies greatly, ranging from only a few in some mammals up to scores or hundreds in others. In general, they are more numerous in the larger mammals, whose kidneys are correspondingly larger. In the adult the lobules may remain distinct from one another so that the

kidney is externally more or less deeply subdivided and therefore is described as "**lobulated.**" The kidneys are more or less conspicuously lobulated in some ungulates—e.g., ox, rhinoceros, elephant—and in some carnivores—e.g., bear, otter (Fig. 183), seals, walrus. The number of lobules in the kidney of a walrus is estimated at between 300 and 400. Lobulation reaches its extreme in cetaceans, "each kidney appearing to be an aggregation of a multitude of small kidneys closely packed and contained within a single envelope" (A. B. Howell: "Aquatic

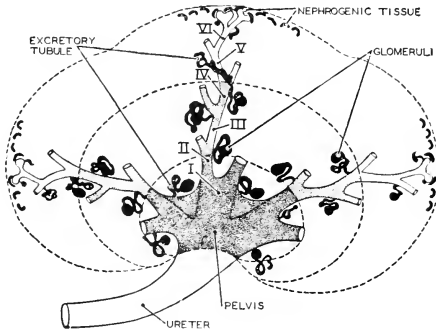


FIG. 187. A diagram illustrating the repeated branching of the collecting tubules in a nine-week (30 mm.) human embryo. Roman numerals indicate successive branchings. The diagram shows also the origin of excretory tubules from the nephrogenic tissue. (Redrawn from Braus, after Kampmeier. Courtesy, Neal and Rand: "Chordate Anatomy," Philadelphia, The Blakiston Company.)

Mammals"). The number of lobules in a kidney of the porpoise is estimated at above 400 (R. Owen).

In some cases, and especially in the smaller kidneys, the embryonic lobules may become closely compacted so that externally the adult kidney shows little or no sign of lobules. Internally, however, they may be recognizable. The human kidney is an example of this concealed lobulation, the number of internal lobules, corresponding to the "pyramids" (Fig. 85), ranging from 3 to 20. In many mammals, especially the smaller (e.g., the cat), the kidney is simple, consisting of a single lobe—therefore not "lobulated."

The smaller kidneys, not lobulated or with concealed lobulation, usually have the form of an indented ellipsoid—i.e., bean-shaped (and a certain variety of bean is called "kidney-bean"). The common term "kidney-shaped" refers to this characteristic form, but some mam-

malian kidneys are not "kidney-shaped." The ureter, the renal blood-vessels, and the nerves (of the autonomic system) join the kidney at the indentation or **hilum**, which is always on the medial side of the organ.

All mammals have a **urinary bladder**. It develops as a midventral outgrowth from the endodermal wall of the cloaca and in close relation to the **allantois**, whose proximal region may to some extent become incorporated into the wall of the bladder. The ureters at first open into the cloaca. Later, as the bladder becomes expanded and the cloaca is

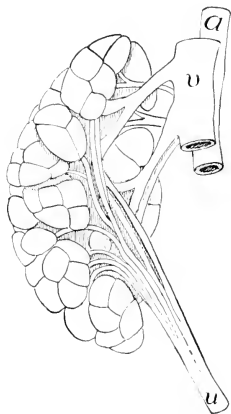


FIG. 488. Lobulated kidney (metanephros) of otter, *Lutra canadensis* (Princeton, 2234). (a) Aorta; (u) ureter; (v) postcava. (Courtesy, Kingsley: "Comparative Anatomy of Vertebrates," Philadelphia, The Blakiston Company.)

reduced, the posterior connections of the ureters are shifted to the dorsal surface of the bladder. Exceptional in this respect are the Australian duckbill and spiny anteater which, in the adult stage, retain the embryonic cloaca and the cloacal termination of the ureters.

#### OVARIES AND MÜLLERIAN DUCTS

The **ovaries** in the mammalian embryo are at first anterior to the metanephric kidneys but, in consequence of later unequal longitudinal growth of the body-wall and the supporting membranes and ligaments of the viscera, the adult position of the ovaries comes to be usually more or less posterior to the kidneys. The right and left ovaries, not always symmetrically placed, are of approximately the same size except in monotremes, whose left ovary is much larger than the right.

In placental reproduction, characteristic of most mammals, the developing embryo obtains its necessary food by way of the placenta. The egg contains a minimum of stored food and accordingly is of microscopic size. In contrast to anamniotes, in which an ovary may

produce scores, hundreds, or millions of relatively large eggs at a time, the mammalian ovary produces very few mature eggs. The number of young in a mammalian litter is under 25 and usually under 10. (There is record of an African hedgehog, *Centeles*, bearing a litter of 22.) In reptiles and birds the number of eggs produced is comparatively small but the eggs are of enormous size. Consistent with these several facts, the mammalian ovary is much smaller, relative to the size of the animal, than the ovaries of other vertebrates.

**Comparing ovaries of mammals of different size**, the organ is larger in the larger animal. In a given species there is much variation in size of the organ, depending on age, size, and physiologic condition of the animal. In **form**, it varies from nearly spherical to a more or less elongated and flattened ovoid. The roughly approximate average longest diameter and the average weight of an ovary in several species of mammal are as follows. (There is no constant ratio between the diameters and the corresponding weights because of difference in form of the organ in the several species.)

	<i>Long Diameter</i>	<i>Weight</i>
Mouse.....	4 mm.	0.02 Gm.
Cat.....	10 mm.	0.20 Gm.
Man.....	37 mm.	6.00 Gm.
Horse.....	75 mm.	75.00 Gm.
Whale (humpback, <i>Megaptera</i> —50 ft. long).....	125 mm.	500.00 Gm.

It is, perhaps, to be expected that the larger mammal should have a larger ovary but, taking into account certain other facts, a problem presents itself. A mouse produces usually about six young in a litter. (Exceptionally, as many as 14 have been reported.) The gestation period is 21 days. Under ordinary circumstances, a mouse may produce 60 or more young in a year. The very large mammals bear usually only one young at a time (twin whales have been reported) and have a prolonged period of gestation—in the elephant, about 18 months; in some whales, about 2 years. Further, among placental mammals there is no important difference in the size of eggs. Rats and mice produce eggs of nearly the same size (diameter 0.070–0.075 mm.); eggs of dog, horse, gorilla, and man range in diameter from 0.130 to 0.145 mm. The diameter of the mature egg of the humpback whale is given as from 0.100 to 0.130 mm., which makes it smaller than that of a cat, dog, or rabbit. (Because of difficulties of measurement, there is much dis-



agreement in statements of diameters of mammalian eggs as reported by various observers.) Taking it all together, then, it appears that the net reproductive output, measured in terms of number of offspring, is greatest for the smallest mammalian ovaries and least for such gigantic ovaries as those of large ungulates and whales.

In most organs there is some functional necessity which requires that the size of the organ shall maintain a certain proportion to that of the animal. The volume of blood varies with the animal's size; therefore the heart and blood-vessels must be of greater capacity in the larger animal. The output of excretory and secretory organs must be proportioned to the size of the animal. In the case of an ovary, the primary and essential function is the formation of eggs. If the pair of tiny ovaries of a mouse can produce eggs in sufficient number to ensure 60 or more progeny in a year, why should a whale have about 2 pounds of ovarian substance whose *effective* contribution to the survival of the species is only a single microscopic ovum in about two years?—"effective" in view of the fact that there is much of what appears to be ineffective activity. In all mammals, so far as is known, a large proportion of ovarian follicles (Fig. 196) suffer degeneration (**atresia**) before they are fully developed, so that many potential ova never arrive at the possibility of fertilization.

In the large mammal the multicellular internal structures of the ovary are on approximately the same scale of magnitude as the whole organ. An ovarian follicle in the horse may be a centimeter in diameter, i.e., as large as the entire ovary of a cat. In a whale the larger follicles range from 3.5 to 5.0 cm. in diameter. But the constituent cells of the follicles and of other tissues in the ovary are of the small size characteristic of mammalian cells in general. *The size of the egg-cell of placental mammals is consistent with that of tissue-cells, but not with the size of the organ or the animal.*

The minute particle of matter which is potentially a mouse differs visibly in no conspicuous way from the scarcely larger particle which is potentially a 50-foot whale. If it were the business of an ovary somehow to transmit and compress into the egg something representing the whole complex of structural characteristics of the animal to which the ovary belongs (after the manner of Charles Darwin's "pangene" theory of inheritance), it could be imagined that a massive and herculean ovary would be required to pack a whale into an egg no larger than a pin-point. But, in a strict sense, *the ovary does not produce eggs*. It merely provides a suitable supporting and nutritive substratum for the development of ova whose specific internal structure and potentialities have been acquired directly from a preceding egg. A secondary function of ovarian tissue, especially the **follicular tissue**, is **produc-**

**tion of endocrine substances** (hormones) which play an important part in the regulation of activities of the reproductive organs and mammary glands. It is possible that it is this secretory function of the ovary which makes it necessary for the large mammal to have a correspondingly large ovary. In the present incomplete state of our knowledge of the matter, there is room for the speculation that, in both the evolutionary and the ontogenetic development of animals, there is some factor whose operation tends to maintain a specific scale of proportions of parts, irrespective of functional necessity—some-what as in large modern buildings there may be massive columns which play no important part in supporting the reinforced concrete structure which appears to rest upon them.

Two mammals, *Ornithorhynchus* and *Echidna*, are oviparous. Their eggs are relatively enormous, the longer diameter, including the shell, being 15 to 17 mm. The diameter of the actual ovum—i.e., the egg exclusive of its envelopes—is about 2.5 mm. in the duckbill and 3.0 mm. in the anteater. The duckbill usually produces two eggs at a time, the anteater only one. Apparently most, if not all, of the eggs come from the larger left ovary. In many marsupials the eggs are much larger than in placental mammals.

In all mammals the embryonic **Müllerian ducts** open anteriorly into the coelom near the ovaries and posteriorly into the cloaca. In the later course of development each duct usually differentiates into three regions: an anterior narrow **Fallopian** (or “uterine”) **tube** which serves to transmit the egg back into a more or less enlarged **uterus**, in which the egg undergoes development for a period varying in different mammals, and a posterior **vaginal** region (the right and left usually joined), which serves to admit the male copulatory organ.

The anterior end of each oviduct expands into a thin-walled funnel whose mouth (**ostium abdominale**) usually has a fringed (**fimbriated**) edge (Fig. 489). This funnel more or less completely enwraps the ovary so that an ovum discharged by bursting of a follicle at the surface of the ovary is caught within it. In many mammals the edge of the ostium fuses more or less completely with a peritoneal fold which surrounds the ovary so that escape of an egg into the coelom is hardly possible. Otherwise, such escape sometimes happens and the misplaced egg may become attached to the coelomic wall and begin to develop there. Human cases of such **extra-uterine pregnancy** sometimes occur.

In **placental mammals** the funnel is lined by ciliated epithelium. By beating of the cilia the minute egg is transported into the narrow

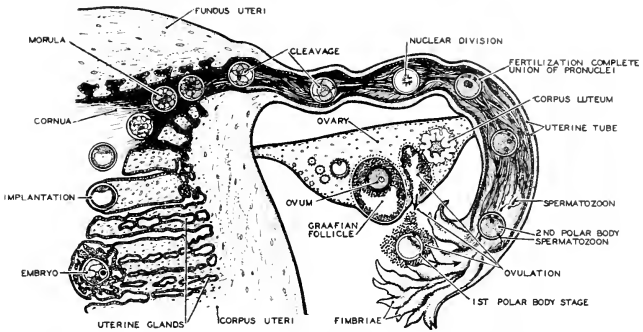


FIG. 189. Diagram illustrating the passage of the fertilized egg from the ovary to the uterus. The human ovum is a week in the tube and three days in the uterus before implantation takes place. (After Dickinson: "Sex Anatomy," Baltimore, Williams & Wilkins Co.)

adjacent Fallopian tube which, also by ciliary action, transmits the egg back into the uterine region of the oviduct. The egg, fertilized in the course of its passage along the Fallopian tube, becomes attached to the wall of the uterus where, as it develops, it establishes a placenta and the embryo enters upon a long period of gestation, at the end of which an advanced stage of development and considerable size have been attained. The uterine region is accordingly greatly enlarged and its walls develop strong layers of "smooth" muscle which serve to expel the young at birth. Posterior to their uterine regions, the right and left oviducts of placental mammals always coalesce, the cavities joining to form a single median chamber, the **vagina**.

In most placental mammals the fusion of the posterior ends of the two oviducts extends forward to involve also a greater or less extent of their uterine regions, so that several types of uterus may be recognized (Fig. 490). A **uterus duplex** results when the right and left uterine regions remain apart, having separate openings into a common median vagina (in some insectivores, most rodents, and conies, *Hyrax*). In a two-horned uterus (**uterus bicornis**) the anterior regions of the two uterine chambers remain apart, but their posterior regions join to form a median space which has a single opening into the vagina (in cetaceans and sea cows; in some members of each of the following groups— insectivores, rodents, bats, carnivores, ungulates; and in lemurs). In a **uterus bipartitus** the adjacent walls of the two uteri join to form a more or less extensive median partition between the two cavities which have a common opening into the vagina (in some bats; some

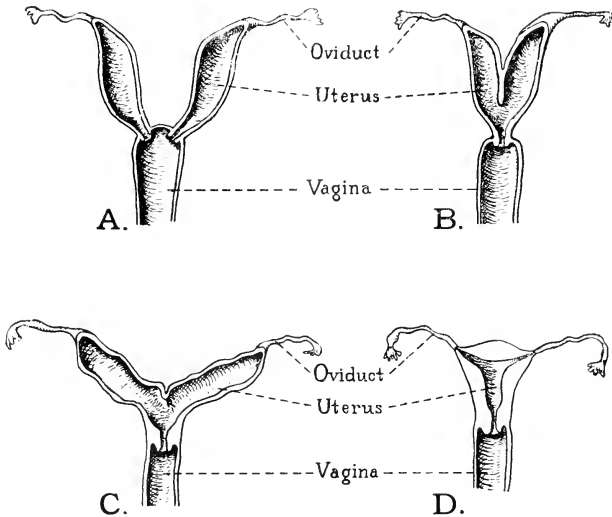


FIG. 190. Four types of uteri. (A) Duplex: in rodents. (B) Bipartite: in certain carnivores. (C) Bicornate: in most insectivores and prosimians. (D) Simplex: characteristic of primates. (After Wiedersheim. Courtesy, Patten: "Embryology of the Pig," Philadelphia, The Blakiston Company.)

carnivores; ruminant ungulates, pigs, horses). Complete union of right and left uterine chambers to form a single wide and undivided uterine space produces the **uterus simplex** (in monkeys, apes, and man).

In **marsupials** the egg is fertilized and transported through a Fallopian tube into a uterine region of the oviduct, but no placenta or, at most, a very transitory and weakly developed placenta is formed. The period of gestation is short and the fetus is born while still quite small. The uterus is therefore much less strongly developed than in placental mammals. As to the vaginal regions of the oviducts, there are various conditions. Each duct differentiates a vaginal region. In the opossum (*Didelphys*; Fig. 491), the two vaginas remain quite separate, although their anterior regions bend sharply toward the median plane and lie close together, while posteriorly they open independently into the urinogenital sinus. In other cases (e.g., kangaroo, phalanger, wombat; Fig. 491) the anterior regions of the right and left vaginal tubes become joined to form a median chamber into which the two uteri open, and from this median chamber a pouch (**vaginal cecum**) projects backward between the separate posterior right and left vaginal tubes. A median longitudinal septum more or less completely

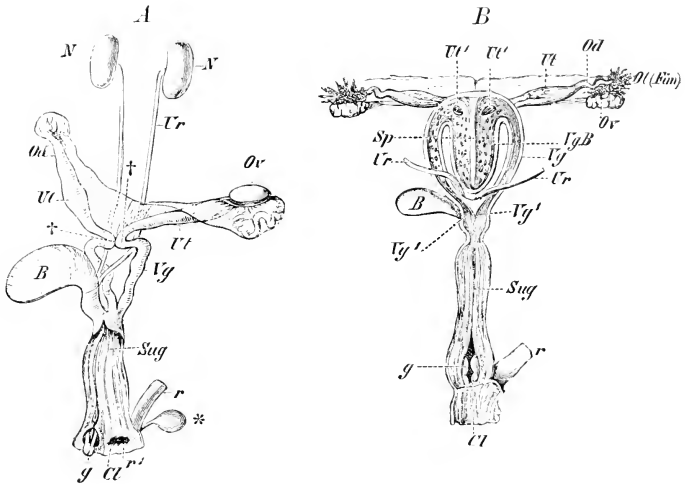


FIG. 191. Urinogenital organs of marsupials. (A) A young opossum (*Didelphys dorsigera*). (B) *Phalangista vulpina*. (b) Urinary bladder; (Cl) cloaca; (g) clitoris; (N) kidney; (Od) Fallopian tube; (Ol (*Fim*)) fimbriated abdominal opening of oviduct; (Ov) ovary; (r) rectum; ( $r^1$ ) anus; (Sp) septum; (Sug) urinogenital sinus; (Ur) ureter; (Ut) uterus; (Ut<sup>1</sup>) openings of uteri into vaginal cecum; (Vg) vagina; (Vg<sup>1</sup>) vaginal opening into urinogenital sinus; (VgB) vaginal cecum; (†) junction of uterus and vagina; (\*) rectal gland. (Courtesy, Wiedersheim: "Grundriss der vergleichenden Anatomie der Wirbeltiere." Jena, Gustav Fischer.)

divides the vaginal chamber and its cecum. In some kangaroos the vaginal cecum grows backward and acquires a median opening into the urinogenital sinus, the extraordinary result being three vaginal passages extending between the urinogenital sinus and the two uteri.

The deficiencies of the internal uterine arrangements in marsupials are compensated for by provision for continuation of maternal care and feeding after birth of the young. The minute and helpless newborn fetus is transferred to an external posteroventral pouch, the **marsupium**, formed by a fold of abdominal skin (Fig. 539). The pouch is supported by a pair of elongated **epipubic** or **marsupial bones** which project forward from the anterior bones, pubes, of the pelvic girdle. The epipubes, like the pubes, are cartilage-bones. The mammary glands are on the abdominal wall within the pouch.

The marsupium is present only in the female. In most cases it opens forward. In the bandicoots (*Perameles* and *Chaeropus*) and the marsupial mole (*Noloryctes*) it opens backward. The reversal in the direction of the opening is a very fortunate adaptation to the burrowing habit

of these animals. A few Australian mammals, definitely "marsupial" in other respects, lack the marsupium (e.g., the "marsupial" anteater, *Myrmecobius*), and in some species of the American opossum the pouch is poorly developed or lacking.

In the **oviparous mammals**, **Ornithorhynchus** and **Echidna**, the right oviduct is shorter than the left and the anterior mouths of the Fallopian tubes are not fimbriated. The large eggs, discharged from the ovary, are fertilized before they arrive in a slightly differentiated uterine region of the duct (always the left?) where they linger while the shell is deposited by the uterine wall. In *Echidna* the shell has a horny texture, but in the duckbill it is hardened by deposition of calcium. In these two animals no vaginal region is differentiated. The uterine chambers of the right and left oviducts open directly and independently into a cavity into which open also the urinary bladder ventrally and the pair of ureters dorsolaterally. It is, accordingly, a **urinogenital sinus**, and is the more anterior region of the embryonic **cloaca**. The sinus continues backward into the definitive cloaca, which is also entered by the more dorsal rectum. These animals, therefore, have only a single median posterior external opening, the cloacal aperture.

In *Echidna* a temporary **marsupial fold** of skin exists during the period of incubating the egg and early development after hatching. In **Ornithorhynchus** no pouch is formed at any time. The epipubic bones, however, are present in both of these animals.

#### TESTIS AND WOLFFIAN DUCTS

The **testis**, like the ovary, develops in close relation to the mesonephros but, unlike the ovary, it acquires functional relation with the mesonephros in that the sperm-producing tubules of the testis become connected with tubules of the more anterior part of the mesonephros (Fig. 78), thus providing the testis with an outlet into the mesonephric (Wolffian) duct, which thus becomes the **spermatic duct** (**vas deferens** or **ductus deferens**). At a later stage of the embryo, the metanephros replaces the mesonephros as functional kidney, but those tubules of the mesonephros which have become functionally necessary to the testis persist as the **vasa efferentia** connecting the tubules of the testis with the spermatic duct. The vasa efferentia, together with the much-elongated and closely coiled anterior portion of the mesonephric duct, constitutes the **epididymis** which, in the adult, forms a flattened mass closely joined to the outer surface of the testis. Emerging from the epididymis, the vas deferens continues backward to the terminal urinogenital passage, the **urethra** (Fig. 492). Just before entering the urethra, each vas deferens widens and its

walls become strongly muscular. This region of the tube is known as the **ductus ejaculatorius**.

In **size**, the testis, like the ovary, varies with the size of the animal. Ovoid in form, the cat's testis is about 1.5 cm. in long diameter and 1.0 cm. in short diameter. The human testis, exclusive of the epididymis, is 4 or 5 cm. long and 2.5 to 3 cm. in short diameter. That of a horse is about 11 by 6 cm. Often the testis of one side of the body is noticeably larger than that of the other side. The horse's left is often the larger.

In all cases the testis produces vast numbers of spermatozoa. It is probable that the number produced in the larger animal is not proportional to the greater size of the organ.

The **position of the testes** in adult mammals is variable. In *Ornithorhynchus* and *Echidna* they remain at the region of their embryonic origin—therefore near the kidneys. But in most other adult mammals they become shifted to more posterior positions. In some insectivores and in elephants they undergo little, if any, displacement. In many insectivores, in cetaceans and sea cows, in armadillos, sloths, American anteaters, and conies (*Hyrax*), the testes remain permanently in the abdominal cavity but are finally lodged in the extreme posterior (pelvic) region of it. In most other adult mammals, the testes lie temporarily or permanently in a sac, the **scrotum**, which protrudes externally from the posterior ventral abdominal wall.

The **scrotum** is an integumentary pouch occupied by a pair of coelomic pockets. The cavity within each pocket (**bursa inguinalis**) communicates, primarily if not permanently, with the abdominal coelom (Figs. 492, 493). The several layers of abdominal muscles continue into the wall of the bursa, being represented by layers of fascia if not by actual muscular tissue. The bursa is lined throughout by a continuation of the abdominal peritoneum forming the **tunica vaginalis**. It has been pointed out (p. 23) that the visceral organs do not, in strict sense, lie *in* the abdominal cavity. Each organ is separated from the coelom by a layer of peritoneum. The same relations obtain in the scrotal sac. The testis lies, not actually in the lumen of the bursa, but on the dorsal wall of it (Fig. 493) and separated from the lumen by the tunica vaginalis, which is reflected over the ventral surface of the testis. Thus the tunica vaginalis, like the abdominal peritoneum, has its parietal and its visceral part.

The connection of the testis with the vas deferens, blood-vessels, and nerves are all established before the organ is moved into the scrotum. In its "descent" into the scrotum, the testis carries these structures with it. Where they pass through the abdominal wall, they become wrapped together by connective tissue, the whole complex

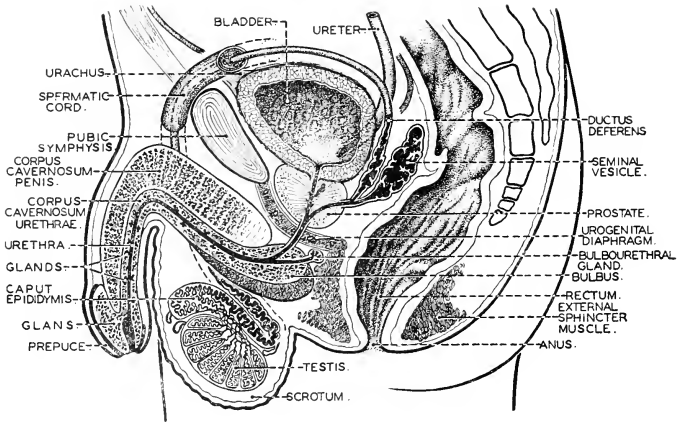


FIG. 492. The human male urinogenital system. (After Sobotta. Courtesy, Neal and Rand: "Chordate Anatomy," Philadelphia, The Blakiston Company.)

forming the so-called "**spermatic cord**" (Fig. 492), whose essential constituents are the **vas deferens**, the **spermatic artery and vein** and the small arteries and veins associated with the vas deferens, **lymphatics**, and **nerves**. The spermatic cord, of course, does not enter the cavity of the bursa but, like the testis, lies external to the tunica vaginalis—i.e., between the tunica and the adjacent fascia and muscle of the wall of the bursa.

In many mammals (marsupials, and commonly among insectivores, rodents, and bats), the canal connecting each scrotal bursa with the abdominal coelom remains permanently open. At the end of a breeding season, the testes may be withdrawn into the abdominal cavity. At the advent of another breeding season, they "descend" into the scrotum. This withdrawal of the testis is effected by contraction of a muscle, the **cremaster**, which is a continuation of the abdominal **transverse** muscle (the **internal oblique** muscle sometimes involved with it) along the wall of the communicating canal and into the wall of the bursa inguinalis. In other mammals, including man, the communicating canals normally close completely either before birth (in man) or during infancy, the tunica vaginalis becoming entirely detached from the abdominal peritoneum, and the testes are thereafter permanently lodged in the scrotum. Incomplete closure of a canal is a common abnormality in man. A loop of intestine may sag into the open canal, producing an **inguinal hernia**. Sometimes (in man) one or both testes fail to descend into the scrotum before the canal closes—the condition



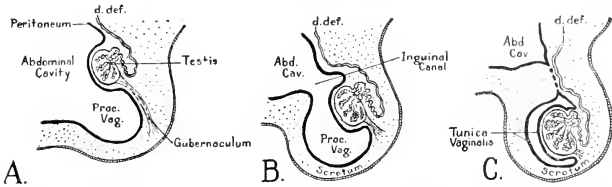


FIG. 493. Diagrams illustrating the descent of the testis as seen in parasagittal section. (d. def.) Ductus deferens; (Proc. Vag.) processus vaginalis (the diverticulum of the peritoneum pushed into the scrotal sac). (Courtesy, Patten: "Embryology of the Pig," Philadelphia, The Blakiston Company.)

known as **cryptorchism**—and so must remain permanently in the abdominal cavity.

In some mammals (e.g., tapir, rhinoceros, civet, otter) each testis lies in a bursa which extends more or less deeply into the inguinal or perineal (Fig. 494E) region, but the two sacs do not meet in a common scrotum and they cause little or no external protrusion of the body-wall.

In **marsupials** the scrotum, lacking in some of them, is **anterior** to the penis. In **placental mammals** the positions are reversed—the scrotum is **posterior**.

"**Inguinal canal**" is a name which may be applied logically and conveniently to the communicating passage between the abdominal cavity and the bursa inguinalis, and is often so used, but confusion results from the fact that the same name is applied, especially in human anatomy, to the passage occupied by the spermatic cord in its course through the abdominal wall *after the former passage has become closed*. The former (Fig. 493C) connects two regions of the coelom and is internal to the peritoneum. The vas deferens and other structures which constitute the spermatic cord lie in the dorsal wall of the bursa inguinalis and primarily external to the tunica vaginalis (peritoneum). In strict sense, the two passages are not the same, although intimately related.

The mechanics of the "**descensus testicularum**" is a problem not yet fully solved. Apparently several factors are involved. The initial factor in the backward shifting of the gonads, both ovary and testis, seems to be a polarized growth. Persistent growth at the hind end of the gonad is accompanied by atrophy, at a compensating rate, of the anterior end of the organ. This process may even be regarded as a unique method of locomotion in that it moves the organ from one place to another. Other factors are external to the gonad. The change of position is doubtless due in part to unequal longitudinal growth of the body-wall and the membranes and ligaments connecting gonad

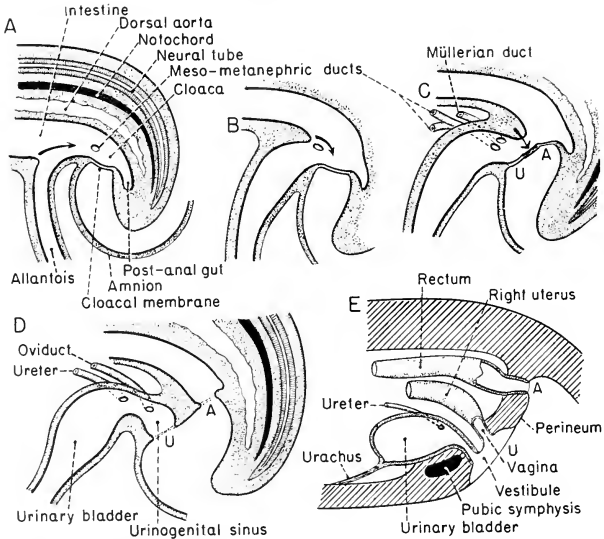


FIG. 194. Diagrams illustrating the dividing of the mammalian embryonic cloaca into a rectal and a urinogenital part. The diagrams represent sagittal sections of the caudal region of the embryo. The superficial ectoderm and the endoderm are shown in heavy lines; mesoderm is stippled. The amnion is removed except a remnant attached to the embryo ventrally.

(A) is a stage such as occurs in a pig embryo about 6 mm. long. This stage shows the primary cloaca, and the cloacal membrane consisting of apposed ectoderm and endoderm. The cloacal aperture of the right mesonephric (Wolffian) duct is shown. As the metanephros develops from the hind end of the mesonephric duct, this aperture is for a time common to the mesonephros and the developing metanephros.

In (B) the proximal region of the allantoic outgrowth has become enlarged, predicting the differentiation of a urinogenital sinus and urinary bladder. In (C) the right Müllerian duct (oviduct) appears in close relation to the cloacal end of the meso-metanephric duct.

The arrows in (A), (B), and (C) refer to the region where the intestinal wall bends ventrad to continue as the allantoic wall. As the cloacal space expands (by growth of its walls), the bend ("uro-rectal fold") extends caudad (suggested by the arrows) as seen in sagittal section. This intruding "fold," however, is not confined to the mid-anterior region of the cloacal wall but continues back on each side so that the cloacal space is constricted laterally as well as from in front. In (C) the anterior edge of the "fold" has nearly reached the cloacal membrane. A little later (D) the constriction is completed and the cloacal membrane has become divided into a dorsal anal membrane (A) and a ventral urinogenital membrane (U), each destined to become perforated to form, respectively, anus and urinogenital aperture.

In (D) a constriction intervenes between urinogenital sinus and urinary bladder. The mesonephric and metanephric ducts, by growth at their region of junction, become separated. The metanephric duct (ureter) shifts forward onto the dorsal

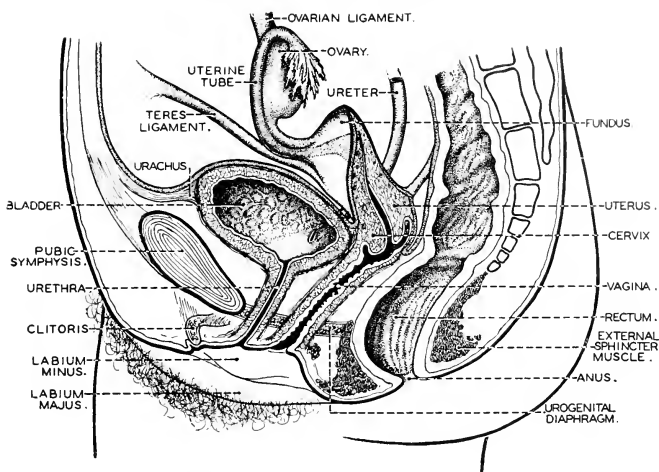


FIG. 195. The human female urinogenital system. (After Sobotta. Courtesy, Neal and Rand: "Chordate Anatomy," Philadelphia, The Blakiston Company.)

and body-wall. In the case of the testis, a specialized agent plays an important part in the later phase of the "descent." At an early period in the development of the testis a peritoneal fold becomes transformed into a ligament stretching from the hind end of the testis to that particular spot in the posterior abdominal wall where the scrotum is destined to develop. After the scrotum has been formed, this ligament, the **gubernaculum**, is found to be attached to the posterior wall of the scrotum (Fig. 193) and external to the tunica vaginalis. By some obscure process this **gubernacular ligament** (not muscular) shortens and in so doing pulls the testis into the scrotum, thus completing the "descensus."

The advantage which accrues to a mammal in possessing a scrotum is far from obvious. A testis which normally resides in a scrotum ceases to produce spermatozoa if it remains in the abdominal cavity. Crypt-

FIG. 194.—(Continued.)

surface of the expanding bladder. The mesonephric ducts in the male, serving as the spermatic ducts, retain their openings into the urinogenital sinus which becomes extremely contracted and elongated to form the urethral canal of the penis (see Fig. 192), while the Müllerian ducts degenerate. In a female, shown in (D) and (E), the mesonephric ducts degenerate and, as the ureters are carried forward onto the bladder, the oviducts retain their connection with the urinogenital sinus which appears as the vestibule of the adult. (E) shows a common adult condition—the posterior regions of the two oviducts joined to form a median vagina into which open right and left uteri (see also Fig. 195).

orchid testes are sterile. By experimental operation, testes of guinea pigs and rats have been confined to the abdominal cavity. They become sterile. The sterility is attributed to the fact that the abdominal temperature is higher than scrotal temperature. In general, however, it is clear that testes do not require lower temperatures than ovaries. In the many mammals whose testes are permanently abdominal and in birds whose abdominal temperatures are higher than that of any mammal, the testes operate quite successfully. The scrotum is a problematic structure.

#### CLOACAL REGION

In all amniote embryos the posterior region of the endodermal tube expands to become a **cloaca**. The **intestine** opens into the cloaca dorsally. The **Wolffian** and **Müllerian ducts** open into it ventrally, and the ventral wall gives rise to the embryonic **allantois**. Later, the base of the allantoic stalk is more or less involved in the development of the permanent **urinary bladder** from the floor of the cloaca. Before the embryonic cloaca has acquired an external aperture, its posterior endodermal wall grows backward until it comes to lie against the ectoderm, thus producing a two-layered membrane consisting of the joined endoderm and ectoderm. During the earlier period of development, this **cloacal membrane** separates the cloacal cavity from external space (Fig. 494A).

In **monotremes** the embryonic cloacal membrane is eventually perforated and the cloaca acquires a single wide external aperture. Otherwise it persists in the adult without important modification. The anus opens into it dorsally and its ventral region is urinogenital (Fig. 496). These egg-laying mammals therefore have a cloaca essentially like that of reptiles (Fig. 497) and birds. The name "monotreme" refers to the fact that the animal has only one posterior external aperture.

In all modern **mammals other than monotremes**, the embryonic cloaca, at a stage while the cloacal membrane is still intact, becomes divided into a dorsal and a ventral chamber by a horizontal partition which develops as a backward-growing fold of the anterior cloacal wall (Fig. 491). This partition eventually extends backward to the cloacal membrane, to which it becomes joined. It therefore effects complete separation of the dorsal and ventral cloacal regions, each of which later acquires its independent posterior opening to the exterior. In nearly all placental mammals this horizontal partition later undergoes great expansion dorsoventrally, so that the two cloacal regions are carried apart and the adult **dorsal anus** is far removed from the **ventral urinogenital aperture**. The superficial region

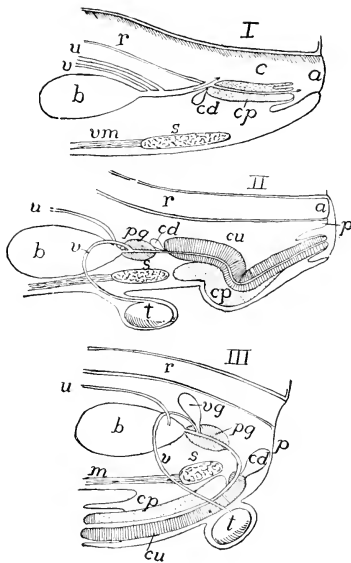


FIG. 496. Diagrams of cloaca and male urinogenitalia in (I) monotremes, (II) marsupials, and (III) placentals. (*a*, in I) Cloacal aperture; (*a*, in II) anus; (*b*) bladder; (*c*) cloaca; (*cd*) Cowper's gland; (*cp*) corpus cavernosum penis; (*cu*) corpus cavernosum urethrae; (*p*) perineum; (*pg*) prostate gland; (*r*) rectum; (*s*) symphysis pubis; (*t*) testis; (*u*) ureter; (*v*) vas deferens; (*vg*) vesicular gland; (*vm, m*) ventral muscles. (After Weber, Courtesy, Kingsley, "Comparative Anatomy of Vertebrates," Philadelphia, The Blakiston Company.)

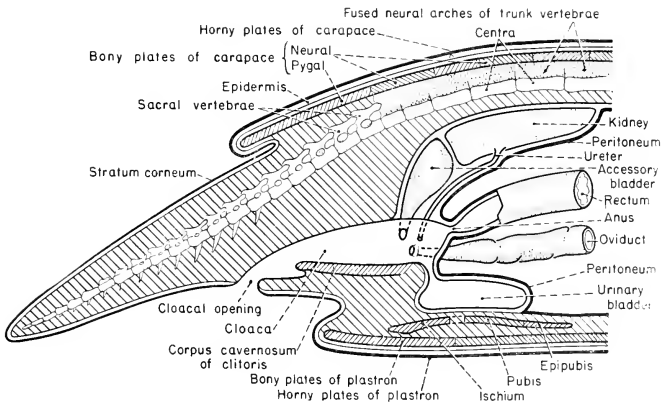


FIG. 497. Reptilian cloaca. Sagittal section of cloacal region of a female turtle.

intervening between them is known as the **perineum** (Fig. 494E). In the adult, therefore, the dorsal part of the cloaca is represented in the rectum, while the ventral part, from whose anterior region the urinary bladder has grown out, is otherwise represented by the urinogenital passages posterior to the bladder.

In **marsupials** the partition between the dorsal rectal and ventral urinogenital divisions of the cloaca is less strongly developed than in placental mammals. It attains much less dorsoventral thickness (Fig. 496). Consequently the perineal region is less extensive and the anus and urinogenital passage open fairly close together at the bottom of a shallow superficial remnant of the cloaca, the surface of it covered by proctodeal ectoderm (see p. 274). The pocket is surrounded by a circular muscle (sphincter) which serves to contract its rim. A similar shallow **ectodermal cloaca** occurs in a few placental mammals—some insectivores and some rodents.

The **ureter**, in both sexes of all Amniota, develops as an outgrowth from the hind end of the Wolffian duct (Fig. 82). As the cloacal wall expands, the posterior ends of the Wolffian duct and of the ureter derived from it are carried apart so that they come to open separately into the cloaca. They remain thus in adult **monotremes**, the ureters opening not directly into the bladder but into the cloaca close to the mouth of the bladder (Fig. 496). In the male monotreme, therefore, two pairs of ducts open into the ventral region of the cloaca: the ureters and the vasa deferentia (Wolffian ducts). The female cloaca likewise receives two pairs of urinogenital ducts: the ureters and the oviducts (their uterine regions), the Wolffian ducts having degenerated except in so far as they may be represented in the hind ends of the ureters.

In **all mammals other than monotremes**, the relations of the ventral cloacal structures become modified by differential growth in such a way that the hind ends of the ureters are shifted to the dorsal surface of the bladder, while the proximal "neck" of the bladder (Fig. 496) becomes more or less narrowed and elongated. In the male (Fig. 492) the neck of the bladder joins the vasa deferentia and from their point of junction a **common urinogenital passage**, the **urethra**, extends to the tip of the **penis**. In the female (Fig. 495) the neck of the bladder and the vagina (the joined oviducts) open into a urinogenital sinus, the **vestibule**, which therefore corresponds to the male urethra. All of the passages common to the urinary and genital systems are of cloacal origin.

#### COPULATORY ORGANS

The strategic position for copulatory organs is close to the posterior ends of the genital ducts. Consistent with this fact, the copulatory

organs of all Amniota develop as modifications of the wall of the cloaca. In **Chelonia** and **Crocodylia**, the midventral region of the cloacal wall contains a longitudinal thickening consisting of spongy and highly vascular connective tissue, more or less definitely divided into right and left parts, the **corpora cavernosa**, underlaid by a more compact **corpus fibrosum**. Extending along the internal ventral surface of the cloaca and between the two cavernous bodies is a median **seminal groove**. Posteriorly, these structures continue into a tongue-shaped flap (**glans penis**) which projects freely above the cloacal floor, pointing backward. The corpora cavernosa, when distended by blood, arch over the groove and convert it into a tubular passage, the whole structure meanwhile becoming so greatly distended that it protrudes through the external cloacal aperture. The spermatic fluid, discharged from the more anterior region of the cloaca, is conducted outward through the temporarily tubular seminal passage.

In mammals the **copulatory organs** are more highly differentiated than in other amniotes, and most so in placental mammals. At an early stage in a placental embryo, but after the primary cloaca has been horizontally divided into a rectal and a urinogenital part (Fig. 494), the latter part enters upon a somewhat complex set of developmental changes. At a median spot situated in its posteroventral wall and at the ventral edge of the **cloacal membrane** (the wall consisting of ectoderm externally, the cloacal endoderm internally, and mesenchyme between), rapid growth sets in, especially in the mesenchyme, producing at first a mere roundish, knoblike, solid body which projects externally—the **genital prominence** or **tubercle** (Fig. 498A). This prominence then elongates more or less rapidly—more so in the male, less in the female—to become a projecting cylindrical structure, the **phallus**, bearing an enlarged solid distal end (Fig. 498B). Meanwhile, the urinogenital cloacal cavity perforates the cloacal membrane and acquires a slitlike external aperture at the base of the phallic outgrowth. This aperture becomes continuous with a deep median groove formed along the dorsal surface of the phallus—the **urinogenital** or **urethral groove**. The longitudinal lips of this groove become much thickened, appearing then (viewed externally) as the so-called “**internal genital folds**” (Fig. 498B, C). At either side, right and left, of the phallus develops a broad swollen region variously known as a **genital ridge** or **swelling**, **scrotal fold**, or **external genital fold** (Fig. 498C, s).

These several structures attain maximum development in the male. Continued elongation of the embryonic phallus forms the **shaft** of the **penis** while the distal tubercle of the embryo becomes the enlarged terminal **glans penis** (Fig. 492). The urethral groove eventually

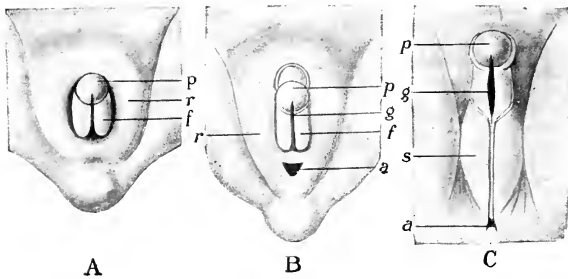


FIG. 198. Development of the male external genitalia of man. (A) Indifferent stage from which either sex may develop. (B) Early stage. (C) Later stage. (*a*) Anus; (*f*) genital folds; (*g*) urethral groove; (*p*) genital tubercle; (*r*) genital ridge (outer genital folds); (*s*) scrotum. (After Hertwig. Courtesy, Kingsley; "Comparative Anatomy of Vertebrates," Philadelphia, The Blakiston Company.)

extends to the distal tip of the genital tubercle. Meanwhile, growth of the internal genital folds causes them to arch over the cloacal slit and urethral groove, enclosing them to become the **urethral canal**, which finally retains communication with the exterior only by a small orifice, the **meatus urinarius**, on the distal surface of the glans. The mesenchyme within the internal genital folds of the phallus differentiates into a **corpus cavernosum penis** (more or less definitely divided into right and left corpora) ventral to the urethra, and another spongy body, the **corpus cavernosum urethrae** or **corpus spongiosum**, a median body dorsal to the corpus cavernosum penis and completely surrounding the urethra (Figs. 492, 499). Distally, the dorsal corpus is continuous with the glans and its proximal end forms a bulblike enlargement, the **bulbus urethrae**. At the base of the adult penis the two halves of the corpus cavernosum penis diverge, forming the **crura**, each arm (**crus**) of which extends forward and usually becomes attached to the posterior border of the adjacent ischium, thus giving the organ a skeletal anchorage. In many mammals a longitudinal rod of bone is formed in the connective tissue between the paired corpora cavernosa. This **os penis** is commonly found among rodents, bats, carnivores, and whales, and in some monkeys and apes. The skin at the distal end of the penis forms a cylindrical fold, the **foreskin** or **prepuce**, surrounding the glans.

The **external genital folds** (Fig. 198B, C) initiate the development of the **scrotum**, but the greater part of it results from an outward protrusion of a median area of perineum just dorsal (i.e., toward the anus) to the developing penis.

The embryonic parts which produce the male external genitalia are



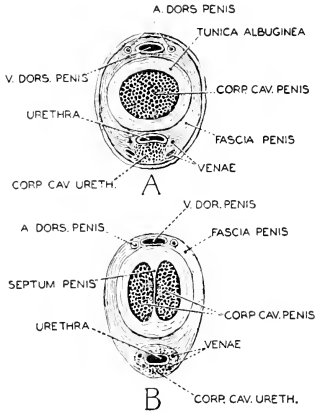


FIG. 199. Cross sections of the penis of the rhesus monkey. (A) 1 cm. behind the glans. (B) 3 cm. behind the glans. (A. DORS. PENIS) Dorsal arteries of penis; (V. DORS. PENIS) dorsal vein of penis. (Courtesy, Hartman and Straus: "Anatomy of the Rhesus Monkey," Baltimore, Williams & Wilkins Co.)

present also in the **female**, but undergo much less differentiation. There is comparatively little elongation of the phallic outgrowth. The urinogenital cloacal space does not become enclosed to form a tubular urethra, but persists as a dorsoventrally elongated but transversely narrow median passage, the **vestibule** (Figs. 194, 195). The **internal genital folds**, in their more distal region, produce very rudimentary corpora cavernosa which bear distally a rudimentary glans corresponding in origin to the glans penis. In the adult these structures constitute the **clitoris**, which lies in the ventral wall of the vestibule, slightly projecting. Rarely, a small **os clitoridis**, corresponding to the os penis, is present. The remainder of the internal genital folds become, in the human female, a pair of thin, wide folds, the **labia minora**, which bound the vestibule laterally (Fig. 195). The **external genital folds** become a pair of prominent and relatively thick folds, the **labia majora**, which are laterally adjacent to the labia minora and more or less completely enclose them and the vestibular aperture. In mammals other than man, there is usually only a single pair of labia at the vestibular aperture.

In some cases among insectivores, rodents, and lemurs, the urethral groove in the region of the clitoris becomes enclosed to form a narrow canal separated from the main urinogenital space. This canal becomes joined to the neck of the bladder. Thus an independent urinary outlet for the bladder is provided via the clitoris, leaving the major cloacal space as a genital passage only.

The approximate correspondence of parts of the human male and female external genitalia, based on embryonic origin, is summarized in the following table.

<i>Embryo</i>	<i>Adult Male</i>	<i>Adult Female</i>
Genital tubercle	Glans penis and Corpus spongiosum	Glans clitoridis
Internal genital folds	Corpora cavernosa penis	Corpora cavernosa clitoridis and Labia minora
Urinogenital space and urethral groove	Penile urethra	Vestibule
External genital folds	Scrotum (in part)	Labia majora

The development of the human external genitalia begins early in the second month of fetal life and is well advanced late in the fourth month. Or, in terms of fetal size, their development is seen in a series of fetuses ranging from 10 to 150 mm. in all-over length.

The **copulatory structures of monotremes** are more reptilian than mammalian. When not erected, the penis is entirely withdrawn into the cloaca (Fig. 496). The urethral (seminal) groove, extending between corpora cavernosa, is closed over dorsally except at its anterior end, where it remains open into the cloaca, but no definite corpus cavernosum urethrae is formed. During erection, however, the anterior aperture is closed so that, temporarily, there is a continuous and exclusive seminal passage from the vasa deferentia to the exterior. The monotreme "urethra," therefore, is not physiologically equivalent to the urethra of a placental mammal. A median furrow divides the glans into right and left parts, each beset with numerous small spines. The urethra divides distally into two branches, one passing to each half of the glans, where it subdivides into several fine ducts, each opening at the apex of a spine.

The **marsupial penis** is essentially like that of a placental mammal but, when not erected, is withdrawn into the shallow ectodermal cloaca with its distal end directed backward (Fig. 496). The crura of the corpora cavernosa penis are not attached to the pelvic skeleton. In many cases—e.g., the opossum (*Didelphys*) and bandicoot (*Perameles*)—the glans is two-forked in adaptation to the female's paired vaginas. The urethra may branch correspondingly, or from its median aperture a superficial groove may extend to the tip of each fork of the glans. *In a species in which the male glans is two-forked, the clitoris likewise has a bifid glans.* The scrotum, not present in all marsupials, is anterior to the penis, a position probably made necessary by the fact that the perineal space is of small extent and depressed below the surrounding surface of the body.

In **placental mammals**, the more extensive perineal area makes possible the more advantageously placed postpenial scrotum, and the

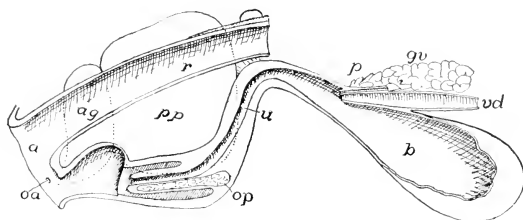


FIG. 500. Diagram of male genitalia of beaver, *Castor canadensis*. Penis retracted into the floor of the shallow cloaca. (a) Anus; (ag) anal gland; (b) urinary bladder; (gr) gland of vas deferens; (oa) opening of anal gland; (op) os penis; (p) prostate; (pp) preputial gland; (r) rectum; (u) urethra; (vd) vas deferens. (After Weber. Courtesy, Kingsley: "Comparative Anatomy of Vertebrates," Philadelphia, The Blakiston Company.)

penis is directed downward or more or less forward (Fig. 496). In those insectivores and rodents which have more or less of an ectodermal cloaca as in marsupials, the retracted penis is drawn into the cloaca, pointing backward. The right and left scrotal sacs lie laterally in the perineal region but are so shallow as to cause little external protrusion.

#### ACCESSORY GENITAL AND ANAL GLANDS

At certain regions in the more posterior part of the male urino-genital tract, the walls of the passages are glandular or may give rise to appended glandular organs. Their common function seems to be secretion of a mucous fluid which serves as a carrier for the spermatozoa and provides a medium favorable for their survival and activity. In some cases (rodents) the secretion coagulates in the vagina, thus favoring fertilization by preventing escape of the spermatic fluid.

These glands are distinguished mainly by their position in relation to the passages (Fig. 492). In the more posterior region of each vas deferens, but anterior to its ejaculatory region, the wall may be thick and glandular or, more commonly, it gives rise to a pair of large and more or less complexly subdivided glands, often called "**seminal vesicles**," but better known as **vesicular glands** because they are essentially secretory rather than for mere storage of sperm. Especially important glands occur along the neck of the bladder and the urethra. The **prostate** is usually a massive gland divided into a varying number of lobes, situated just posterior to the junction of the vasa deferentia with the neck of the bladder. At the base of the prostate, or embedded in the gland, is commonly found a small and usually bilobed vesicle protruding from the wall of the urethra. This **prostatic vesicle** or **utricle** is a remnant of the embryonic Müllerian ducts. It is usually known as the "**uterus masculinus**," but, being derived from the

extreme posterior ends of the Müllerian ducts, it would more logically be called "vagina masculina." The **bulbourethral** or "**Cowper's glands**" arise from the urethra at the region of the **bulbus urethrae**. In the female are **vestibular glands** (or **glands of Bartholin**) opening laterally into the vestibule. In position and relation to the urogenital passages, they correspond to the male bulbourethrales.

All three sets of glands—**vesicular, prostate, bulbourethral**—are present in the majority of mammals, but there is much diversity as to their relative degrees of development. When the glands of one set are weakly developed or absent, the others are correspondingly accentuated. The **monotremes** are described as having neither vesicular nor prostate glands, but very large bulbourethrales. **Marsupials** have no vesicular and no obvious prostate glands, but the "prostatic tract" of the urethra has a thickened and highly glandular wall and there are commonly three pairs of bulbourethral glands. Vesicular glands are especially strongly developed in such small and prolific animals as **insectivores** and **rodents** (Fig. 500), but are lacking in

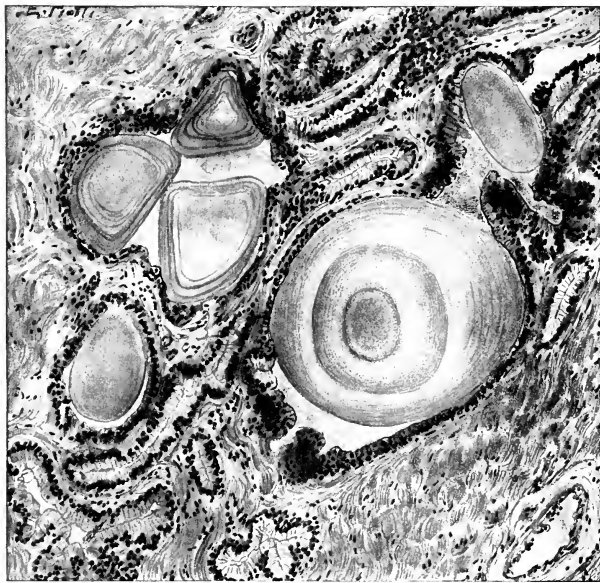


FIG. 501. Section of the human prostate showing concretions. Zenker fixation; hematoxylin and eosin. (Courtesy, Bremer-Weatherford: "Text-Book of Histology," Philadelphia, The Blakiston Company.)

rabbits. The substance which causes coagulation of the seminal fluid in the vagina of rodents is produced in the prostate. Vesicular glands are lacking in **carnivores**. In dogs the bulbourethral glands also are absent, but they are present in the cat. **Sloths** have neither vesicular nor prostate; the **armadillo** has no vesicular and a somewhat doubtful prostate; both of these "edentates" have bulbourethral glands. Vesicular glands are present in **sirenians** but not in **cetaceans**—one of many differences indicating that these two types of aquatic mammal are not closely related. In **man** there are small vesicular and bulbourethral glands and a massive prostate (Fig. 492) which completely surrounds the urethra. Characteristic roundish lamellated concretions of colloid substance are formed in the alveoli of the gland (Fig. 501). In later life the glandular tissue tends to increase and the concretions increase in size and number, with some deposition of calcareous material. The resulting enlargement of the prostate causes it to exert pressure on the urinary passage, tending to occlude it.

Arising from the inner layer of the fold of skin forming the preputial sac are **preputial glands**, whose secretion resembles that of the sebaceous glands which ordinarily occur at the roots of hairs, but it may be odorous. In some mammals, especially rodents (e.g., the beaver: Fig. 500), these glands attain great size. The **musk-glands** of the male musk deer of Asia are highly specialized preputial glands. The dried secretion is the "musk" of commerce, used in making some perfumes.

The skin surrounding the anus and in the groin and sometimes in more anterior parts of the body produces, in many mammals, glands which secrete odorous substances. These **scent-glands** are usually present in both sexes, but may be better developed in one sex, usually the male, than in the other. Such are the **inguinal glands** of some antelopes and the **ano-preputial** "castor bags" of beavers (Fig. 500). "Castoreum," derived from the beaver's secretion, is used as a medicament and source of perfume. Of similar nature are the **anal scent-glands** of many rodents and carnivores (e.g., the civet cats—Viverridae—of Asia and Africa: "civet" is another source of dainty perfume!). It is likely that in most cases (e.g., dogs) the odorous secretions of these glands have sexual significance.



It has been said of mammals that they have a "better brain" than that of other vertebrates and that, to a greater extent, they "live by their wits." Unquestionably, the behavior of mammals, compared to that of reptiles and birds, gives much more evidence of something approaching or even quite attaining intelligence. Therefore it would be reasonable to expect that the mammalian nervous system would be conspicuously different from that of other vertebrates. But **anatomically** it is not. So far as gross structure is concerned, the mammalian nervous organs, compared to those of reptiles, show no differences commensurate with those exhibited by the skin, heart, aortic arches, lungs, and reproductive organs of the two Classes. This fact is a consequence of the peculiar nature of nervous functions. Unlike most other functions, that of a nervous organ is largely independent of the *form* of that organ, this being especially true of the central organs, brain and spinal cord.

In a large manufacturing establishment the offices are connected with the shops by numerous telephone lines centering in an elaborate switchboard. The operation of the switchboard does not depend upon its being square, oblong, or circular. In times of peace the factory may produce automobiles and refrigerators. During war it may be "converted" to production of tanks, airplanes, and munitions. This change in function compels radical changes in the mechanical equipment of the shops, but it may require little or no alteration of the telephone system. At one time the office personnel may be of low efficiency, with the result that the output of the factory is deficient in quantity and quality. Under highly efficient management, great improvement may be made in the operation and products. But the telephones which formerly transmitted careless and stupid orders will transmit just as effectively orders given by highly intelligent and trained experts in the office. Increase in business, however, may require adding new telephones and enlarging the switchboard.

The brain is analogous to the offices of a factory. To say that cells of the brain correspond to the human occupants (each having a brain within himself!) of the offices would precipitate some perplexing questions which, for present purposes, need not be discussed. The cerebral "office" is connected with all parts of the body by nerves. Sense-organs, some at the surface of the body, others internal, report respectively the external and internal conditions to the "office," which thereupon sends out appropriate orders to the working parts of the body. But the nervous mechanism directly involved in the running of a greyhound differs in no conspicuous way from that which effects the awkward and laborious crawling of a sloth. The significant anatomic differences are in the structure of the appendages (part of the "factory"), not in the nervous structures ("office" and "telephones") concerned in the locomotion, and the facility with which the function is performed depends largely upon the efficiency of the cerebral "office." However, increase in size of a motor structure and in its complexity of differentiation necessitates increase in the number of related nerves, and this may be reflected by increase in the gross bulk of nervous tissue in certain transmitting regions and correlating centers of the spinal cord and brain. Comparing brains of mammal and reptile, there are differences in the relative bulk of the various regions, but there are no differences in the basic plan of the organ. These differences in mere volume of corresponding parts of the central nervous organs of different animals are indicative of the degree of differentiation of the motor organs concerned and the degree of complexity of their activities, but give no clue to the nature and pattern of those activities.

#### SENSE-ORGANS

##### SENSE-ORGANS OF SKIN

**Cutaneous (integumentary) sense-organs** in mammals are more numerous and structurally more diversified than in other vertebrates. The hard external horny layer and thick scales make reptilian skin an unfavorable site for delicate sensory structures, although they do occur beneath thinner regions of the horn or at perforations in the scales. The thick fur of mammals must greatly reduce the direct impact of external objects and agencies on the surface of the skin but, indirectly, the hair may, to an important degree, contribute to the sensitiveness of the skin. The epidermal wall of the follicle which lodges the root of a hair (Fig. 443) is richly beset with free nerve-endings. The surface of the hair is usually minutely scaly or even spiny—a texture which increases the susceptibility of the hair to mechanical disturbance by contact with an external object. Slight



pressures, tensions, or bending strains incurred by the shaft of the hair are transmitted to its root and there stimulate the follicular nerve-endings. (For a demonstration, touch very gently the tip of a single hair on the ear of a sleeping cat.) The **vibrissae**, long stiff hairs projecting laterally from each side of the upper lip ("whiskers" of dog and cat), are an important sensory apparatus. It is to be emphasized that the hair itself serves only for mechanical, not nervous, transmission. The nervous receptors are at the root.

Aside from the nerve-endings at the roots of hairs, mammalian skin is abundantly supplied with receptors which are stimulated by one or another of the various external agencies which give rise to sensations of touch (more accurately, pressure), heat (temperatures above that of the body), cold (temperatures below that of the body), and pain. Free nerve-termination is found in the skin of all parts of the body, especially in the epidermis. There are also highly specialized receptors in which the nerve-endings are in close relation to a cell or a group of cells, or to a connective-tissue investment of some sort (p.

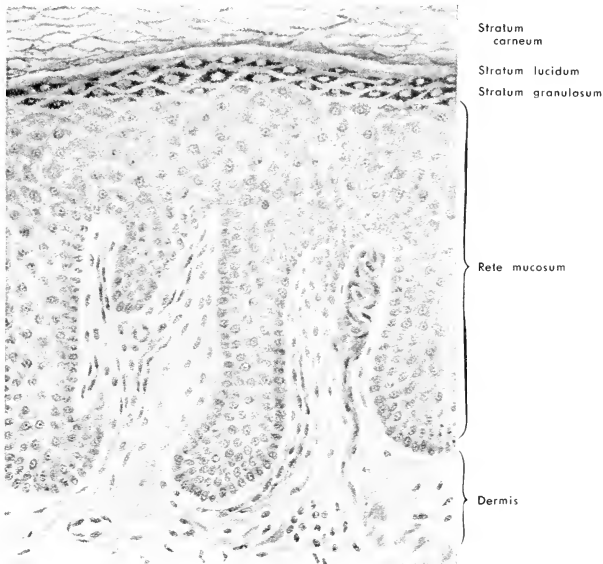


FIG. 502. Section perpendicular to the surface of the skin of the palmar side of a finger, showing two papillae, one of which (at right) contains a tactile corpuscle. (Schäfer.) (Magnified about 200 diameters.) (Courtesy, Schäfer: "Quain's Anatomy," London, Longmans, Green & Co., Ltd.)

193). The sensory "corpuscles" known as "Krause's," "Meissner's," and "Pacini's" are especially characteristic of mammals (Figs. 164-166). They are commonly called "tactile corpuscles," although it is likely that some of them are stimulated by agencies other than pressure. They are widely distributed in the mammalian skin, but are few or absent in regions covered by dense fur, and especially numerous on such hairless areas as the ventral surfaces of the paws, the lips and snout, the nipples of the mammary organs, and the external genitalia. They occur in the epidermis, but much more abundantly in the dermis. In such acutely sensitive regions as the tips of human digits, they are found each within a cylindric protrusion of the dermis into the epidermis—a **dermal papilla** (Fig. 502). They are thus brought into closer relation to the external surface of the skin. Dermal papillae, many of them sensory, occur in rows conforming to the cutaneous ridges which constitute the human "fingerprint" patterns.

There is considerable experimental evidence that a particular sensory structure of the skin is capable of giving rise to sensations of only one kind—i.e., pressure ("touch"), heat, cold, or pain. Sensations of pressure and of heat, referred to the same square centimeter of skin, result from stimulation of two totally distinct sets of receptors.

The highly developed sensitiveness of mammalian skin is one of the most important differences between the sensory equipments of reptiles and mammals, and of great significance in that it gives the mammal a far more intimate acquaintance with its immediate environment. Integumentary organs of chemical sense, however, are totally lacking, as in reptiles and birds, and there are not even embryonic vestiges of the lateral-line organs of Anamnia.

#### ORGANS OF TASTE

The **organs of taste**, or "taste-buds," are much alike in all vertebrates (see p. 196). In fishes organs of this sort exist not only in the mouth but also more or less extensively over the external surface of the body. They are evidently organs of chemical sense, and fishes may be said to possess a cutaneous sense of taste. In amphibians the taste-buds rarely occur externally, and never so in adult frogs and toads. In mammals, as in reptiles and birds, they are never external.

The **taste-buds of mammals** occur in the lining of the mouth and pharynx, but are less widely distributed than in Anamnia, tending to be restricted to the more posterior surfaces. They are found on the tongue, the soft palate, and in relatively small numbers on the larynx and epiglottis. The dorsal surface of the tongue is thickly beset with papillae of a variety of forms—slender, more or less branched **filiform**; mushroom-shaped **fungiform**; and, at the posterior region of the

tongue, the more specialized **foliate** and **vallate** papillae (Fig. 503). The foliate papillae, usually only a single pair of them, consist of a series of parallel thin folds of the epithelium. A vallate papilla (Fig. 501) resembles a fungiform papilla which, instead of protruding above the surface of the tongue, is depressed into the substance of the tongue

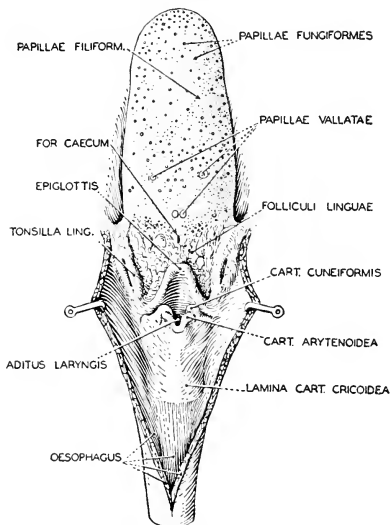


FIG. 503. Dorsal surface of the tongue and the larynx of the rhesus monkey. (Courtesy, Hartman and Straus: "Anatomy of the Rhesus Monkey," Baltimore, Williams & Wilkins Co.)

and surrounded by a narrow deep groove or "valley." Taste-buds are especially numerous on the lateral surfaces of the foliate and vallate papillae. In the case of the latter, the "valley" serves to retain samples of the fluids present in the buccal cavity, thereby prolonging the stimulation of the taste-buds.

The great majority of the taste-buds are connected with branches of the facial nerve (VII). Buds in the more posterior region are innervated by branches from the glossopharyngeal (IX) and vagus (X).

#### OLFACTORY ORGAN

A pair of sense-organs which correspond to the nasal olfactory organs of Amniota in position and mode of embryonic origin are well developed in fishes. Their sensory cells are stimulated by substances

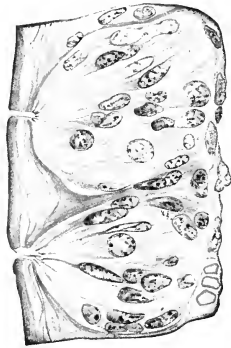
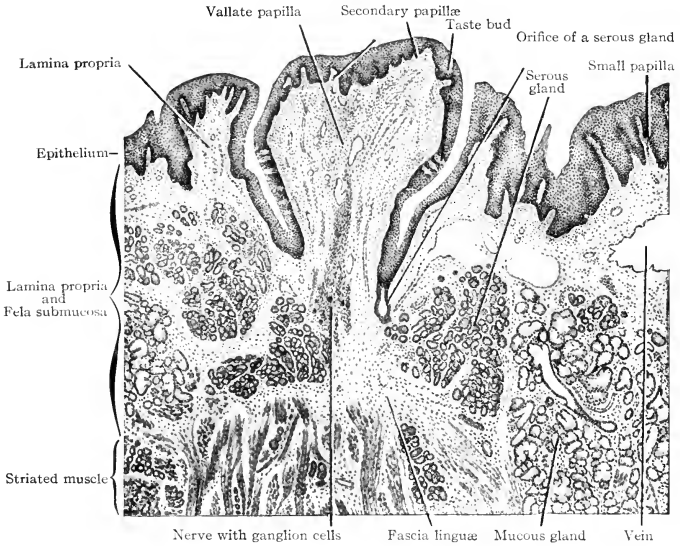


FIG. 501. (Top) Axial section of a human vallate papilla. ( $\times 25$ .)

(Left) Taste-buds in the wall of a foliate papilla of a rabbit. Surface of tongue at left. (Courtesy, Bremer: "Text-Book of Histology," Philadelphia, The Blakiston Company.)

dissolved (or suspended?) in the external water which, in one way or another, is introduced into the sensory sacs. Physiologically, there would seem to be little difference between these organs and the cutaneous "taste"-organs of fishes, since both are stimulated chemically by substances in the external water. In lung-breathers the olfactory cavities serve as respiratory passages, and the olfactory sensory cells are stimulated by air-borne substances emanating from more or less distant external sources.

It is important to any animal that it be aware of external conditions to as great a radius of distance as possible. Sight and hearing have limitations. An object may look as if it were good to eat, but not taste good. Chemical information concerning external objects is of great advantage, whether it makes the animal aware of the proximity of food or of enemies. That the sensations produced by the so-called "olfactory organs" are highly important to fishes is guaranteed by the fact that the correlating centers of the brain are dominated by the olfactory mechanism. But organs which serve to test the chemical nature of the external medium are even more important to the land animal. Most fishes live in a far-reaching expanse of transparent water affording unobstructed vision in all directions. Their highly developed eyes serve them well. Most land animals inhabit environments which offer a variety of opaque impediments to distant vision—rugged contour of ground, rocks, trees, underbrush. Food or enemies may be close at hand but unseen. To detect their presence by chemical means—i.e., to smell them—is vitally important.

The keenness of the sense of smell depends, in part, on the area of the surface over which the sensory cells are distributed, assuming that the number of sensory cells per unit of area is constant. In reptiles the internal surface of each nasal cavity is increased by an extensive thin plate of bone, the **concha**, which projects from the lateral wall into the cavity. To most mammals, far exceeding reptiles in speed, agility, diversity of activities, and propensity for roaming far afield, smell must be vastly more important than to the relatively sluggish and less migratory reptiles. It is therefore to be expected that the mammalian olfactory organs should be developed to a much higher point of efficiency than those of a reptile. This is accomplished by increase of olfactory surface.

The nasal cavities are relatively much larger in mammals than in reptiles, but the main factor in the increase of surface is the addition of numerous **conchae** and the utmost expansion and elaboration of each of them. As in reptiles, the conchae or **turbinals** (as they are more commonly called in mammals) develop as ingrowing longitudinal folds of the external or lateral wall of each nasal cavity. Into each fold

extends a thin cartilaginous plate derived from the cartilaginous capsule (Fig. 115) which, at an early embryonic stage, encloses the nasal cavity. Eventually these turbinal plates ossify (not always completely) and become more or less intimately joined to adjacent bones which meanwhile have developed around the nasal cavity. The uppermost, the **nasoturbinal**, joins the nasal bone which roofs the cavity. The lowermost, the **maxilloturbinal**, becomes attached to the maxillary bone which abuts upon the ventrolateral region of the nasal wall. Between nasoturbinal and maxilloturbinal, but more or less posterior to them, are developed a varying number of **ethmoturbinals**. They are continuous with the ethmoid bones which form the lateral walls

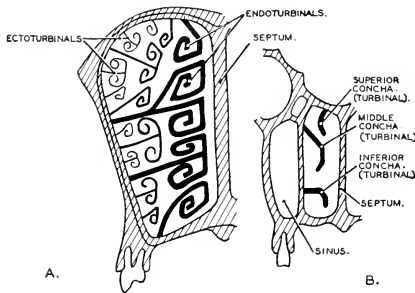


FIG. 505. Diagrams of cross sections of the nasal passage in (A) ruminant and (B) man, showing the contrast in the number of turbinal bones. (Courtesy, Neal and Rand: "Chordate Anatomy," Philadelphia, The Blakiston Company.)

of the nasal cavities. The single turbinal (concha) of reptiles (Fig. 367) is a maxilloturbinal.

In the adult these primary turbinals usually extend nearly across the cavity (Fig. 505). They are approximately parallel to each other and to the floor of the cavity. Each turbinal is more or less elaborately curled spirally (as a sheet of paper might be rolled), but always with some space between adjacent turns of the spiral. These rolled turbinals are often called "**nasal scrolls.**" In some cases a turbinal arising from the nasal wall as a single plate divides distally into two, which diverge and curl in opposite directions (Fig. 505). In the most elaborate systems, the spaces between adjacent major or primary turbinals are occupied by lesser **secondary turbinals** and there may be even smaller **tertiary scrolls** between the secondaries (Fig. 505). Because their scrolls occupy the more nearly median or deeper part of the cavity, the primary turbinals are called **endoturbinals**. The lesser

turbinals, secondary and tertiary, are restricted to the more lateral or outer region and are accordingly called **ectoturbinals**.

The turbinal surfaces are all covered by a thin periosteum (or perichondrium over unossified parts) overlaid by a continuation of the epithelium which lines the walls of the nasal cavity.

In contrast to the 1 concha of reptiles, most mammals have from 4 to 6 primary turbinals in each nasal cavity and there may be as many as 10 or 11 (e.g., in the African anteater, *Orycteropus*). Even among individuals of the same species the number may vary. The nasoturbinal is usually less extensive than the others, or may be rudimentary.

In mammals having the more numerous turbinals, there are no large open spaces in the nasal cavity. It is a labyrinth of narrow passages. The relation of these passages to the nostrils is such that the respiratory current of air passes mainly through the ventral region of the nasal cavity. In this region olfactory cells are few or usually entirely lacking. Accordingly, a **ventral respiratory part** and a **dorsal olfactory part** are distinguished, but with no sharp demarcation between them. There are, in mammals, no olfactory cells on the maxilloturbinals, but they are more or less abundantly present on the other turbinals, as well as on the main wall of the nasal cavity, especially the median nasal septum.

It is important to distinguish between the **olfactory epithelium** which contains olfactory sensory cells, each of which produces a nerve-fiber passing, via the olfactory nerve, into the olfactory lobe of the brain, and the **nonolfactory nasal epithelium**. Nerve-terminations whose stimulation produces sensations of pressure (touch), heat, cold, or pain are present in both the olfactory and nonolfactory regions. The receptors for these senses are related to branches of the trigeminal nerve (V).

The entire nasal surface is more or less richly glandular. The **glands** range from unicellular to complex multicellular, and the secretions are both **serous** and **mucous**.

**Keeness of sense of smell** is correlated with the area of olfactory surface but not with that of the nasal surface, for much of the latter is not olfactory and a region which is olfactory in one animal may not be so in another. Most important for the olfactory sense are the ethmoturbinals, but their surfaces may not be completely olfactory. The **human olfactory organ** (Fig. 506) is an extreme case of reduction of olfactory surface. In the human embryo as many as seven turbinals in each nasal cavity have been recognized—a maxilloturbinal which persists in the adult, a vestigial and temporary nasoturbinal, and five ethmoturbinals, of which usually only the lower two persist. The adult

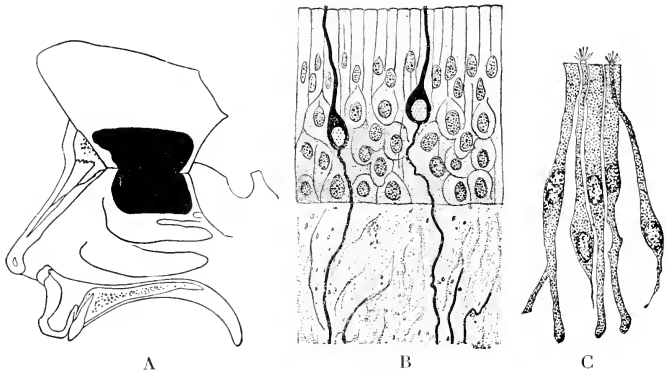


FIG. 506. The olfactory organ of man. (A) Right nasal cavity, with the nasal septum turned up along its superior border. The olfactory area is indicated in black. (After Read.) (B) Section of the olfactory mucous membrane prepared by the silver technic. The olfactory cells and fibers are in black. ( $\times 550$ .) (C) Isolated elements of the olfactory epithelium. The olfactory cells bear fine "hairs" resembling cilia. ( $\times 735$ .) (After Brunn.) (Courtesy, Jackson: "Morris' Human Anatomy," Philadelphia, The Blakiston Company.)

turbinals are relatively narrow and convex upward, but are not rolled into actual "scrolls." Of the three adult turbinals, usually only the upper of the two ethmoturbinals is olfactory and only a part of its surface is occupied by olfactory cells. Also, the adjacent upper region of the nasal septum is olfactory. The total olfactory area for the two human nasal cavities has been estimated at from 5 to 12 square centimeters, which is a small part of the nasal surface. The higher estimates are probably more nearly correct.

The human olfactory surfaces are so restricted to the posterodorsal region of the nasal cavity that they are out of the main part of the respiratory current. During ordinary easy breathing, the presence of an odorous substance in the air may not be noticed, but a forcible snuffing, drawing more air up into the olfactory region, may reveal it. Dogs and other mammals may be observed now and then snuffing in air.

The turbinals are important quite aside from their olfactory function. They are an "air-conditioning" apparatus. Their investing membranes are highly vascular. Hence the surfaces are warm. Glands keep them covered by a layer of moisture. On its way through the nasal labyrinth, the inhaled air (if cool) is warmed and moistened, thus becoming adapted to reception by the lungs. Also, the mucus-covered surfaces serve to screen out solid impurities from the air. Every person



who lives in the dusty and sooty air of a city has daily demonstration of this.

Each of the large **paranasal sinuses** of the forepart of the head—the **maxillary sinus (antrum of Highmore)**, the **frontal sinus**, and the **sphenoid sinus**—opens into the adjacent region of the nasal cavity (Fig. 507). In addition to these are several or many irregular sinuses (the “**ethmoid cells**” of man) in the lateral ethmoid bones. All of these sinuses are lined by a continuation of the nasal mucous

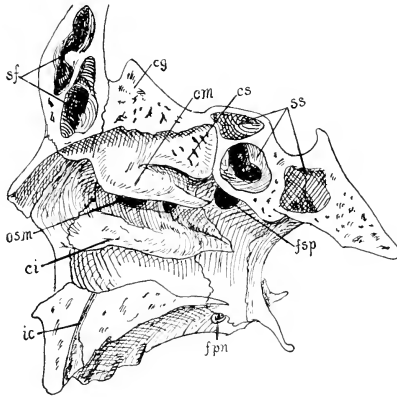


FIG. 507. Lateral wall of nasal cavity of man. (*cg*) Crista galli; (*ci*, *cm*, *cs*) inferior, middle, and superior conchae; (*fpm*) foramen palatinum majus; (*fsp*) sphenopalatine foramen; (*ic*) incisive canal; (*osm*) opening of maxillary sinus; (*sf*) frontal sinus; (*ss*) sphenoid sinus. (After Corning. Courtesy, Kingsley: "Comparative Anatomy of Vertebrates," Philadelphia, The Blakiston Company.)

epithelium, although, at least in man, it is thinner and less glandular in the sinuses than elsewhere. In those mammals whose sense of smell is especially keen, olfactory cells may be found to a limited extent in the frontal or the sphenoid sinus. In dogs olfactory cells have been found in the epithelium of the region of the frontal sinus adjacent to its opening into the nasal cavity.

The **nasal labyrinth** is most highly elaborated in rodents, ungulates, carnivores, and "edentates." It is well developed in lemurs but more or less reduced in other primates. In aquatic mammals the olfactory apparatus is reduced to an extent depending upon the degree

to which the animal is aquatic. All aquatic mammals are wholly air-breathing. The wholly aquatic mammal has little need of smelling air-borne substances and is incapable of smelling anything in the water because, for obvious reasons, it may not inhale water. The olfactory structures are fairly well developed in seals, probably less so in sea cows, and reach the limit of reduction in cetaceans. Mere vestiges of olfactory nerves are found in whalebone whales, and in some toothed cetaceans the olfactory nerves are completely lacking and the olfactory lobes of the brain are reduced. Of the two existing monotremes, the anteater, *Echidna*, has a well-developed olfactory organ with six or seven turbinals, but in the semiaquatic duckbill there are no ectoturbinals and the organ is not well developed.

The **vomeronasal (Jacobson's) organ** (see p. 475) is especially prominent in monotremes and usually well developed in such "lower" mammals as marsupials, insectivores, rodents, and "edentates." In most other mammals it is usually present as an apparently functional organ, but it is reduced or lacking in some bats and in cetaceans, while in the higher primates, apes and man, it is represented in the adult only by an apparently functionless vestige. The organ consists of a pair of small elongated sacs, more or less encased by cartilage, lying close together at either side of the anterior region of the base of the nasal septum. They are buried in the connective tissue beneath the nasal epithelium. In most cases each sac communicates with the oral cavity by a slender **nasopalatine duct** which opens on the roof of the mouth through the **incisive foramen** at the anterior region of the bony palate. Exceptionally, according to some accounts, each sac opens, not into the mouth, but into the adjacent nasal cavity (some rodents—rat, mouse, guinea pig).

Since the vomeronasal sacs develop as hollow outgrowths from the nasal cavities, they are lined by an epithelium which is of the same general nature as the nasal epithelium. It contains numerous olfactory cells whose nerve-fibers pass into the olfactory nerve. As in reptiles, the wall of the sac is innervated by fibers from the trigeminal nerve (V).

The nature of the **function** of the vomeronasal organ is even more problematic in mammals than in reptiles. The nasopalatine duct of the mammals is so narrow as to seem poorly adapted for passage of gases from the mouth to the organ. The probability that the organ serves for smelling substances contained in the mouth is weakened if, in some mammals, the organ has no direct connection with the oral cavity. Further, at least some mammals quite effectively smell food which is in the mouth without the aid of a vomeronasal organ.

The mouth and nasal cavities have a wide avenue of communication via the posterior region of the pharynx (Figs. 171, 469). Gas from the mouth and pharynx may pass up and around the rear edge of the soft palate into the nasopharynx. While food is in the mouth, and especially while it is being chewed, vapors from the food may be drawn into the current of exhaled air and thus carried forward through the nasal passages, enough of it penetrating into the olfactory region to cause olfactory stimulation. In man, at least, taste is probably limited to the sensations which we describe as sweet, sour, salty, and bitter. Those qualities which we describe as the "flavors" of food—the characteristic taste of a peach as distinguished from that of a pear, irrespective of the fact that both are sweet—are sensed only through the nasal olfactory epithelium. The sugar in the drink is tasted, the coffee is smelled. Knowing that the food is in the mouth, we thoughtlessly assign the location of the receptors to the region of taste. The human "palate" gets credit for a vast amount of work which is really done by the nose. The flavors of food are strongly sensed only during exhalation; during inhalation it has little or no flavor. When the nostrils are held tightly shut, apple and onion taste much alike, or not at all. The anatomic relations of the alimentary and nasal passages of land mammals are so similar to those of man as to make it highly probable that, for most mammals, "taste" is largely a matter of smelling—and it is even more probable that they give little thought to the location of the receptors.

#### *Nose, Snout, Trunk*

With increase in importance of the mammalian nasal apparatus, the nasal region of the head builds up dorsally and protrudes forward beyond the upper jaw and lip, thus producing a characteristic mammalian feature. Moderately developed, it is the **snout** of most mammals. It attains the extreme of exaggeration in the elephant's **trunk** and appears in varying degree of refinement in the human **nose**. The snout is especially prominent in hogs and becomes elongated into a veritable **proboscis** in the tiny elephant-shrew (an insectivore: Fig. 508), in the ungulate tapir (Fig. 565), the male elephant-seal (a carnivore), and in the proboscis-monkey of Borneo. The powerfully muscular trunk of the elephant is an extraordinary organ in that it combines the functions of prehension and breathing. The external nares are at its tip. The olfactory regions of the nasal passages are well back in the head, posterior to the base of the trunk. These various forms of the snout receive more or less skeletal support at their basal regions by elongation of the nasal bones and by cartilages developed anterior to the nasal bones.



FIG. 508. Elephant-shrew, an insectivore. (Courtesy, American Museum of Natural History, New York.)

In many ungulates and carnivores the external surface of the snout plays an important sensory role in conjunction with the internal organs of smell. The skin of the anterior region of the snout is scantily covered by hair and richly supplied with glands which keep its surface moist, thus making it highly sensitive to currents of air. By this means the animal is able to sense the direction of the wind and is thereby made aware of the location of the object which is being smelled. A deer hunter knows that he must not let the animal "get wind" of him.

#### EYE

The eye is one of the least changeable of vertebrate organs. In fishes it reaches so high a degree of efficiency that it is not susceptible of great changes of structure, except degenerative, in other vertebrates.

The **mammalian eyeball** and its associated structures are lodged in an **orbit** whose closely fitting bony wall nearly or quite surrounds the eye, giving it a degree of external protection which obviates the necessity of developing skeletal structures in its sclerotic layer.

The **size** of the eyeball necessarily varies with that of the animal, but not proportionately. Relative to size of body, eyes of large mammals are smaller than those of small mammals. In general, larger eyes give keener vision, but size is not the only factor involved and the smaller eyes of small animals are not necessarily of low efficiency. Animals of nocturnal habits generally have especially large eyes with disproportionately large pupils.

In fishes the external face of the eyeball is usually nearly flat and

the eyeball is more nearly hemispherical than spherical. An externally bulging eye would be inconsistent with the "streamlining" desirable in swiftly moving fishes. The mammalian eyeball is usually nearly spherical and its cornea strongly convex. But in wholly aquatic mammals, such as whales, the corneal surface is flattened. The lens in fishes is approximately spherical, but in land mammals considerable refraction occurs at the convex corneal surface and the curvature of the lens is accordingly reduced so that the lens becomes a more or less flattened biconvex body (Fig. 509).

The **sclerotic layer** of the eyeball (Fig. 509) consists of dense connective tissue but, except in monotremes whose eyes are in several particulars more reptilian than mammalian, it does not produce cartilage or bony plates such as occur in eyes of reptiles and birds (Figs. 369, 415). The method of accommodation in birds and most reptiles demands rigidity in the wall of the eyeball. This need is met by a ring of small sclerotic bones surrounding the lens. The mechanism of accommodation in mammals puts less strain upon the sclerotic layer.

The **pecten** (see p. 533), highly elaborated in birds and represented by the simpler **conus papillaris** of some reptiles, does not occur in mammals, except that possible embryonic vestiges of it have been observed.

In many mammals a reflecting layer, the **tapetum lucidum**, occurs at the surface of the choroid layer adjacent to the retina. It is especially well developed in most ungulates and in carnivores, and particularly in those of nocturnal habits. By reflecting into the retina light which has already penetrated it, the stimulation of the retinal sensory elements is intensified. It is this tapetum which causes eyes

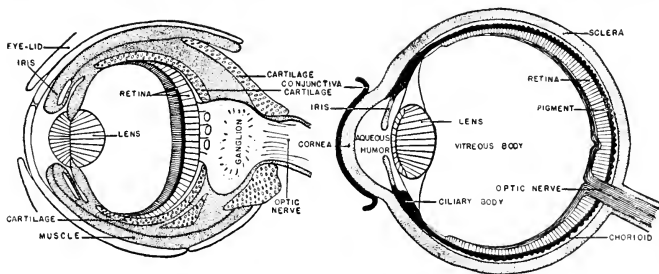


FIG. 509. Diagram of median section of the eye of a vertebrate (*right*) and a cuttlefish (*left*). While the two types of eye resemble one another in many fundamental characters, the retina of the vertebrate eye is inverted, while that of the cuttlefish is not. The similarities are presumably an instance of convergent evolution. (Courtesy, Neal and Rand; "Comparative Anatomy," Philadelphia, The Blakiston Company.)

(e.g., the cat's) to "shine in the dark." In ungulates the reflecting elements of the tapetum are microscopically delicate fibers arranged compactly in concentric order—the **tapetum fibrosum**. The carnivore tapetum consists of several layers of flattened cells, each cell nearly filled with minute rods which appear to be crystalline, although the nature of their substance is not known. This **tapetum cellulosum** is highly developed in those nocturnal primates, the lemurs. Either type of tapetum occurs in various mammals other than ungulates and carnivores, but less commonly.

The **pupil** is usually approximately circular but may be elliptic with its long axis either **horizontal** or **vertical**. When, in strong light, the elliptic pupil narrows, it approaches the form of a slit. For protection of the eye against entrance of strong sunlight, an elliptic pupil, capable of narrowing to a slit, is more effective than a circular pupil whose sphincter muscle is incapable of reducing the pupillary diameter to zero. **Horizontally elongated pupils** occur, for the most part, in herbivores, especially grazing animals, and in other animals whose mode of life makes it important for them to have a wide horizontal range of vision—marsupial kangaroos and wallabies, many ungulates, whales. The domestic cat, with a keen eye for birds, has frequent occasion to look aloft; a good up-and-down sweep of vision is useful. **Vertically elongated pupils** occur in the Australian "marsupial cats" (dasyures), in common cats and many of the smaller carnivores, in seals, and also in lemurs.

Whether or not an animal possesses the ability to discriminate colors—i.e., has "**color vision**"—is always difficult to prove. So far as present evidence goes, it would appear that, regarding the mammalian Class as a whole, color vision is developed to no higher level than in reptiles. It is only among primates that any wide range of color vision is certainly known to exist. Among reptiles, both the lizards and chelonians have some degree of color vision. Mammals seem to stand far below birds in this respect, for there is very satisfactory evidence that birds have good color vision. But it is possible that color vision may exist in many wild mammals whose eyes have not as yet been studied.

In capacity for **accommodation** of the eye to seeing objects at varying distances, most mammals seem to be, at best, not superior to reptiles and decidedly inferior to birds. So far as is known, highly efficient accommodation exists only in primates. The eye of the domestic cat accommodates fairly well, and it is probable that some degree of accommodation occurs in other carnivores, especially the larger and the aquatic, and possibly in some ungulates. There is evidence that

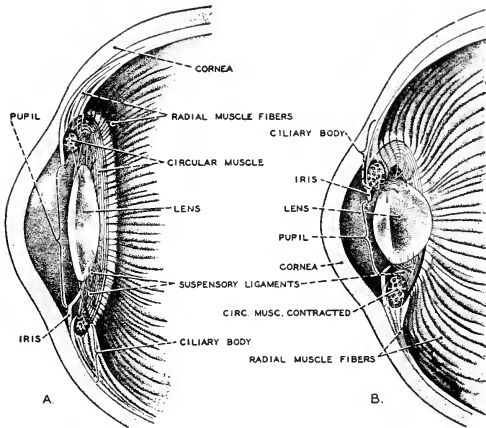


FIG. 510. Diagrams illustrating the accommodation of the eye by means of the change in shape of the lens. The elastic lens is flattened by tension of the suspensory ligaments. When the circular muscle of the iris contracts, tension is relaxed and the lens assumes a more nearly spherical shape as a result of its elasticity. (A) The lens adapted for distant vision. (B) The accommodation of the lens for near vision. The diagrams exaggerate the increase in convexity. (After Kahn: "Der Mensch," Zurich, Albert Müller.)

whales, especially toothed whales, and squirrels have considerable accommodation. Probably many mammals sharpen the image on the retina by narrowing the pupil rather than by manipulation of the lens.

In mammals, as in reptiles, the "resting" eye (i.e., in the absence of any accommodating muscular tension) is focused for seeing relatively distant objects. For sharp seeing of near objects, the focal length of the optical system of the eye must be decreased. This is done by increasing the convexity of the lens. The mechanism whereby this increase is effected in mammals is unique. The lens is swung in place between the iris and the vitreous humor (Figs. 509, 510) by a system of delicate fibrils which radiate from the periphery of the lens to their attachment at that region of the eyeball where the choroid layer merges into the iris and the sclera into the cornea—i.e., the region of the **ciliary processes**, which are vascular thickenings of the choroid arranged in a series encircling the eyeball. These fibrils constitute the **zonula ciliaris** (**zonule of Zinn** or **suspensory ligament**). Externally adjacent to the ciliary processes are two systems of nonstriated muscle-fibers. Those of one system form a **circular ciliary muscle**, encircling the eyeball. Those of the other extend in the direction of **meridians** of the eyeball ("meridian" in relation to the optic axis as

determined by the optic nerve and the center of the pupil). The circular muscle is weakly developed or even lacking in many mammals.

The **lens** is elastic throughout, and its outermost layer, the **lens capsule**, is a thin but tough and highly elastic membrane which is in a state of perpetual tension, thus exerting pressure on the deeper substance of the lens. The fibrils of the zonula ciliaris are likewise under more or less tension which, exerted centrifugally at the periphery of the elastic lens, tends to flatten it.

Contraction of the ciliary muscles, both circular and meridional, serves to pull or stretch the adjacent region of the choroid layer toward the iris, thereby slightly decreasing the diameter of the circular ring of ciliary processes and, accordingly, decreasing the diameter of that circular zone of the choroid layer at which the fibers of the zonula ciliaris are attached (Fig. 510). The result is to diminish the tension in the fibers of the zonula and therefore to lessen their centrifugal pull on the lens capsule, which thereupon contracts and increases the convexity of the lens. Because of inequalities in the thickness of the lens capsule, the increase affects mainly the external surface of the lens. The human lens, in later life, suffers some loss of elasticity. The resulting inability to accommodate for near vision is corrected by use of eyeglasses having convex lenses.

This mammalian method of accommodation is in sharp contrast to that which obtains in most reptiles and in birds. In these sauropsids (except snakes and crocodylians) contraction of a strong circular muscle situated in that part of the wall of the eyeball adjacent to the lens (apparently corresponding to the mammalian circular ciliary muscle) impinges directly upon the periphery of the lens, thereby exerting upon it a centripetal force which causes it to bulge. Thus, in the sauropsids, direct external muscular pressure *compels* the lens to bulge. In mammals muscles act indirectly to decrease tension in the zonula, thus *permitting* the lens to bulge by virtue of its inherent elasticity.

The **extrinsic muscles of the mammalian eyeball** are essentially like those of other vertebrates, consisting of **four rectus muscles** converging from the eyeball to a posterior point of attachment on the wall of the orbit, and **two oblique muscles**, a dorsal and a ventral (Fig. 511). These extend from their points of insertion on the eyeball toward more anterior points on the wall of the orbit where, by analogy with the condition in other vertebrates, both might be expected to attach. The ventral muscle does attach there, but the long tendon of the dorsal one bends through a loop of tendon-like tissue which is fixed to the wall of the orbit at that point and then passes into the belly of the muscle, which continues backward to an attachment



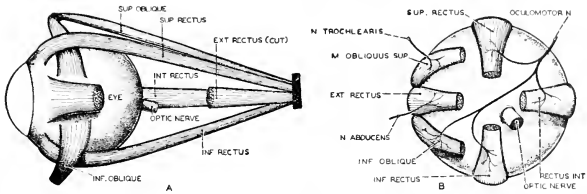


FIG. 511. Diagrams of the eye-muscles of man. (A) The left eyeball and associated muscles, viewed from the outer side. (B) The left eyeball with associated muscles and nerves, viewed from behind. (After Warren and Carmichael: "Elements of Human Psychology," Boston, Houghton Mifflin Co.)

(origin) in close relation to that of the rectus group. The loop (called "trochlea," meaning a wheel) is mechanically a pulley. Contraction of the muscle pulls the long tendon backward but the pull of the tendon on the eyeball is obliquely forward. This curious arrangement of the dorsal oblique muscle is definitely a mammalian characteristic.

The **retractor bulbi**, a muscle found in amphibians and well developed in reptiles, has origin on the wall of the orbit in close relation to the origin of the muscles of the rectus group, and inserts on the eyeball near the entrance of the optic nerve. It serves to draw the eyeball back more deeply into the orbit—a protective measure. It is commonly present in mammals, but often reduced or even quite absent, especially in the "higher" groups. It is well developed in ungulates, not found in whales, and occurs in man only as an occasional "abnormality."

Of the upper and lower **eyelids** (**palpebrae**), the upper is usually wider and does the major part in closing the eye. Their outer surfaces are usually covered by fine hair. The lid is commonly reinforced by a thin plate, the **tarsus**, consisting of connective tissue or cartilage. The edge of a lid is fringed by eyelashes, **cilia**, better developed on the upper lid. Elephants and whales lack cilia. In close relation to the roots of the cilia open the ducts of small **ciliary glands** which resemble sweat-glands. Opening along the edges of the lids are the ducts of large complex **tarsal (Meibomian) glands** which resemble sebaceous glands in structure and produce an oily secretion (Figs. 512, 513).

A **nictitating membrane** ("third eyelid") is usually present. It is a fold of the very thin layer of integument, the **conjunctiva**, which covers the inside surfaces of the upper and lower lids and continues over the cornea. The fold may be at the anterior angle between upper and lower lid, or it may be mainly within the lower lid. It is very thin, hairless, and transparent. In its degree of development it ranges from a maximum in the common cat, in which it may be drawn completely

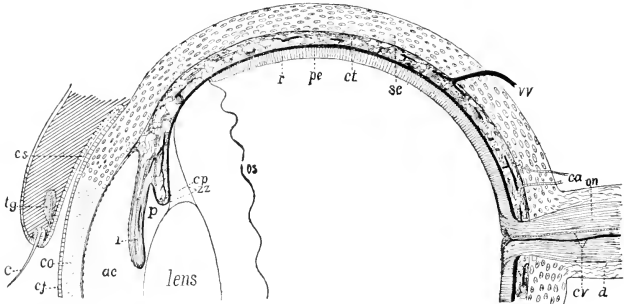


FIG. 512. Diagrammatic section of half a mammalian eye. (*ac*) Anterior chamber; (*c*) eyelash (cilium); (*ca*) ciliary arteries; (*cj*) conjunctiva; (*co*) cornea; (*cp*) ciliary process; (*cs*) conjunctival sac; (*ct*) choroid tunic; (*cr*) central retinal artery and vein; (*d*) dura of optic nerve; (*i*) iris; (*on*) optic nerve; (*os*) ora serrata; (*p*) posterior chamber; (*pe*) pigmented epithelium; (*r*) retina; (*sc*) sclera; (*tg*) tarsal gland; (*vv*) vorticosse vein; (*zz*) zomula zinii. (Courtesy, Kingsley: "Comparative Anatomy of Vertebrates," Philadelphia, The Blakiston Company.)

across the eye, to a minimum in man, where it appears as an apparently useless rudimentary fold, the **plica semilunaris**, at the anterior (nasal) angle of the lids. It is not found in whales.

The **lacrimal apparatus** (Fig. 513) is usually well developed, except in aquatic mammals. As in reptiles, there is a **Harderian gland** at the anterior (nasal side) region of the eyeball and in close relation to the nictitating membrane, and a posterior **lacrimal gland**. The lacrimal gland, however, becomes more important in mammals, and in higher primates the Harderian gland is rudimentary or lacking. Further, whereas in reptiles the several ducts of the lacrimal gland all open within the lower lid, in mammals they open at the region of the posterior angle between the lids, some below and some above, or (as in man) all on the upper lid. Beneath the anterior (nasal) angle of the lids, the very thin space (**conjunctival sac**) between either lid and the eyeball communicates with a small sac, the **lacrimal sinus**, leading into a **nasolacrimal duct** whose other end opens into the anterior region of the lower respiratory part of the adjacent nasal cavity.

The secretion of the lacrimal gland is a watery fluid containing (in man) small quantities of various salts such as occur in blood (mostly sodium chloride), and very small amounts of protein substances and sugar. Also, a mildly antiseptic agent is present. A little mucus in the fluid probably comes from small conjunctival glands. The secretion of the Harderian gland ordinarily resembles that of the lacrimal, but in some cases the secretion may be more or less mucous or, in some aquatic mammals, oily.

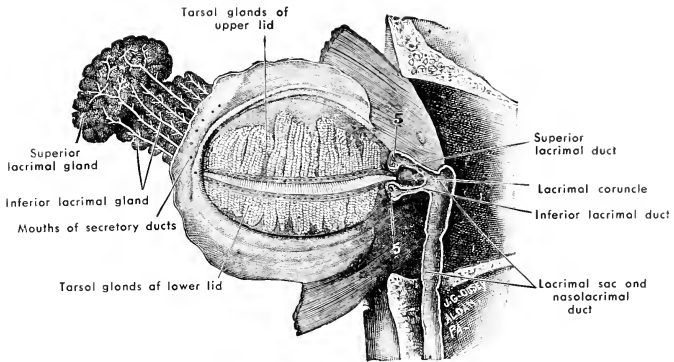


FIG. 513. Dissection of the human left eyelids and lacrimal apparatus, viewed from behind. (Natural size.) (After Fox. Courtesy, Jackson: "Morris' Human Anatomy," Philadelphia, The Blakiston Company.)

The watery "tear" fluid, usually produced mostly by the larger lacrimal gland, bathes the external surface of the eyeball, filling the conjunctival sac and prevented from flowing unduly beyond the confines of that space by the rim of oily substance deposited by the Meibomian glands along the edges of the lids. Any excess of the fluid drains away via the lacrimal sac and nasolacrimal duct into the nasal cavity. Movements of the lids ("blinking" in man) promotes flow of the fluid across the eyeball. Strong emotions, a vagrant puff of tobacco smoke, or proximity of raw onion may so augment the activity of the human lacrimal gland as to overtax the nasolacrimal drainage system, with the result that the fluid bursts through the Meibomian dam and floods the cheeks, and meanwhile the nasal cavity also is flooded.

The glandular apparatus of the lids prevents drying of the delicate and more or less exposed conjunctival layer and provides lubrication which facilitates movements of the lids. The flow of fluid across the eyeball keeps its surface clean. The lacrimal secretion is probably the chief source of nutriment for the corneal conjunctiva, which is remote from the blood-vessels. The antiseptic tendency of the fluid is protective.

There seems to be no good reason why a submarine mammal should produce salty tears. In fact, in all **aquatic mammals**, the eyelids and their glands exhibit a great variety of modifications—in the case of the glands, mostly by reduction. In general, the extent of reduction depends on the degree to which the animal is aquatic. In seals Meibomian glands are lacking, the Harderian is larger than the lacrimal gland and secretes an oily substance, and there is no nasolacrimal duct.

In sea cows and whales the lacrimal gland is much reduced or absent (but a rudiment of it may occur in the embryo), and the large Harde-rian gland is said to produce an oil in whales and a thick mucus-like substance in sea cows. That the secreted substances applied to the external surface of the eyeball in aquatic animals should be oily instead of watery is intelligible. Whales lack Meibomian glands, but are said to have small oil-glands in the conjunctiva of the lids, and they have no nasolacrimal duct.

In moles (insectivores) and some burrowing rodents the eyes are more or less degenerate. In the marsupial, molelike, burrowing *Noloryctes* there are only quite functionless vestiges of eyes.

#### EAR

The immediate connotation of the word "ear" is sound and hearing. But the vertebrate ear is physiologically two organs, one serving for equilibration, the other for hearing. The specialized structures concerned with these two very unlike functions tend to become separately localized in the ear. The at first simple otic sac which invaginates from the superficial ectoderm of the side of the embryo's head (see p. 207) differentiates into a dorsal and a ventral enlargement. The former, the **utricle**, produces the **semicircular canals** (Figs. 180, 182), three in all vertebrates except cyclostomes; and from the ventral **sacculus** grows out a more or less elongated tubular structure, the **lagena**. The semicircular canals are equilibratory. The lagena, becoming the longer and spirally curving **cochlea** of Amniota, is concerned exclusively with hearing. In vertebrates other than mammals, the utricle and sacculus communicate freely through the intervening narrower region of the original otic sac. In mammals the passage between them becomes very narrow, or, as in man (Fig. 514), they are commonly described as connecting only indirectly via the bifurcated proximal end of a tubular structure, the **endolymphatic duct**, whose distal end pierces the inner cranial wall and terminates in an enlarged **endolymphatic sac** which lies in the space between the cranial wall and the brain. The sac and duct probably allow for diffusion of substances between the endolymph and the lymphlike cerebrospinal fluid which bathes the outer surfaces of the brain and spinal cord. These mammalian endolymphatic ducts are not exact homologs of the similarly named ducts which, in sharks, open by a pair of pores on top of the head. The latter are the persisting and much-elongated distal parts of the original embryonic otic invaginations. In vertebrates other than elasmobranchs, the primary connection with the external surface is obliterated and a secondary endolymphatic duct develops by out-growth from the otic sac, but it may involve at least the stump of the primary invaginated duct.

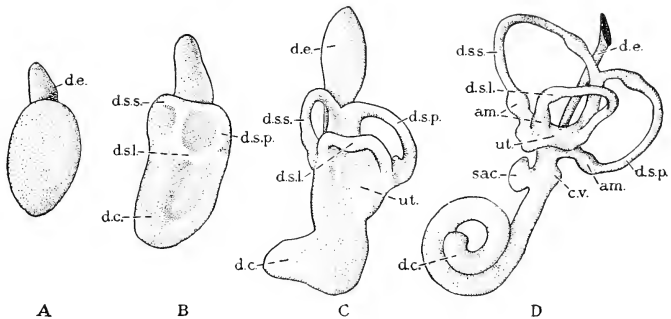


FIG. 511. Lateral surfaces of models of the membranous portion of the left internal ear from human embryos. (Different enlargements.) From embryos of (A) 6.9 mm., (B) 10.2 mm., (C) 13.5 mm., and (D) 22 mm. (am) Ampulla; (c.v.) cecum vestibulare of (d.c.) cochlear duct; (d.e.) endolymphatic duct; (d.s.l., d.s.p., d.s.s.) lateral, posterior, and superior semicircular canals; (sac) sacculus; (ut.) utriculus. (After His, Jr. Courtesy, Bremer: "Text-Book of Histology," Philadelphia, The Blakiston Company.)

The mammalian **utricle**, with its three semicircular canals, differs in no important way from that of other vertebrates. In the **saccular region** the conspicuous mammalian feature is the greatly elongated lagenar outgrowth (Fig. 180). It appears as a tube coiled into a close spiral. The form of the bony case enclosing it suggests a snail shell; hence the name, **cochlea**. The number of turns in the cochlea varies with the length of the tube, ranging from less than one full turn in monotremes to as many as five in a South American rodent, *Coelogenys*. Insectivores and cetaceans usually have about one and a half turns; ungulates and carnivores, three to four; man, between two and a half and three. The cochlea is a small structure compared to the size of the animal. The human cochlea measures some 25 to 30 mm. in its spirally coiled length. The junction of the cochlea with the sacculus is somewhat sharply constricted.

The **wall** of all parts of the definitive **otic sac**, except the relatively small regions occupied by sensory cells, is a very thin membrane consisting of the internal ectodermal epithelium, which is only one cell in thickness, and, externally, a delicate layer of connective tissue. The complete sac, with its appended canals and cochlea, is of such complexity of form as to merit the name **membranous labyrinth**.

The fully developed membranous **cochlear tube** is not circular in cross section but more nearly triangular (Figs. 515, 516). Its wall is very thin except on one of the three flattened sides, where it becomes much thickened and possesses an elaborate histologic differentiation which constitutes the essential nervous receptive mechanism of hearing

known as the **organ of Corti** (Fig. 517). This "organ" extends from base to apex of the spiral. Its histologic elements include certain curious rodlike cells (**pillar cells** or **rods of Corti**) arranged in parallel series on either side of a "tunnel," their expanded bases resting upon the basilar membrane (**membrana basilaris**) of the organ. At either side of the double row of pillar cells are the **sensory cells**, which are short and do not extend down to the membrana basilaris. Each sensory cell bears, on its free end, numerous fine stiff processes or "hairs" which look like cilia but probably are not motile. In addition to the pillar cells and "hair cells," the organ contains cells of several other types, probably serving merely as supporting elements. The basilar

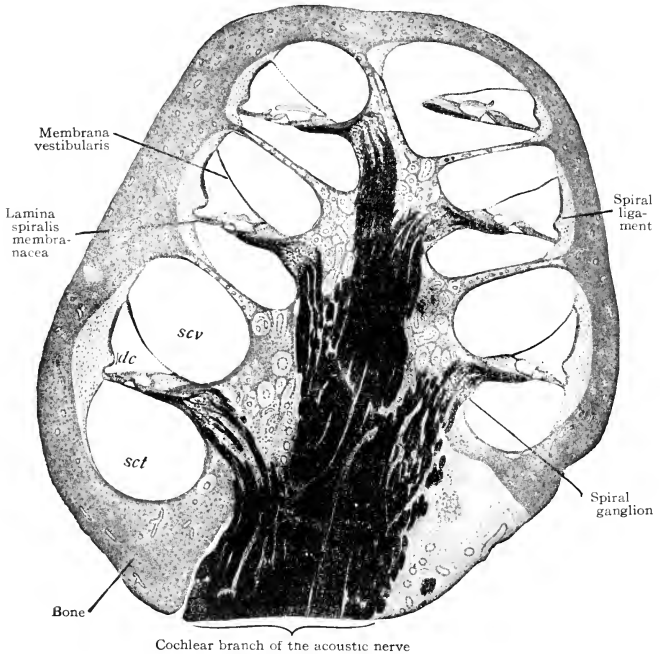


FIG. 515. Axial section of the cochlea of a cat. In the axis is the cochlear branch of the acoustic nerve blackened by osmic acid. Lateral branches of the nerve may be traced to the spiral ganglions where the nerve-fibers arise. At the apex of the cochlea is the helicotrema affording communication between the two perilymph spaces (scalae). (*dc*) Ductus cochlearis; (*sct*) scala tympani; (*scv*) scala vestibuli. ( $\times 25$ .) (After Sobotta. Courtesy, Bremer-Weatherford: "Text-Book of Histology," Philadelphia, The Blakiston Company.)

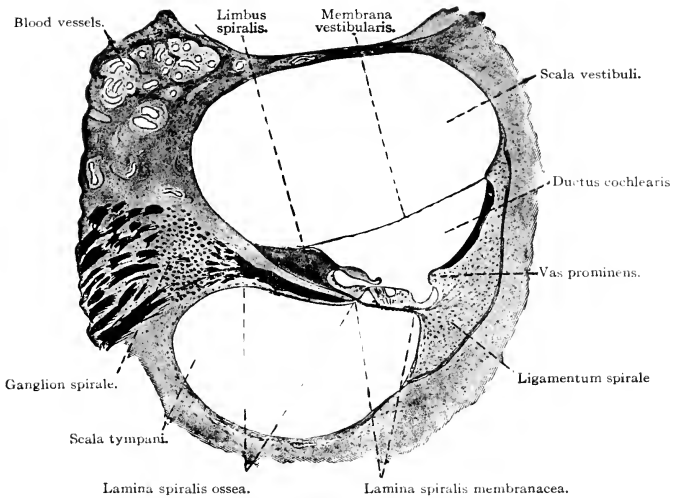


FIG. 516. Section of the cochlear tube. The organ of Corti rests upon the lamina spiralis. ( $\times 50$ .) (Courtesy, Bremer: "Text-Book of Histology," Philadelphia, The Blakiston Company.)

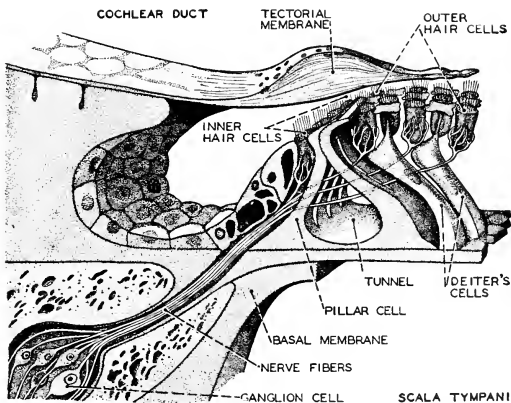


FIG. 517. Stereogram of a portion of the organ of Corti of man. (After Kahn: "Der Mensch," Zürich, Albert Müller.)

membrane contains a system of close-set, straight, parallel fibers which extend transversely to the longitudinal axis of the tube. One theory of hearing assumes that these **basilar fibers** vibrate "in sympathy" with external sound-vibrations and thus stimulate the adjacent "hair cells." Suspended like a canopy in the endolymph, and with its under surface in close proximity to the "hairs" of the sensory cells, is a membranous structure (**membrana tectoria**). This membrane is noncellular and of doubtful histologic nature. All of these various sorts of structures are arranged, in the same relation to one another, in a continuous spiral series extending from base to apex of the cochlea, but with the one very significant difference that the width of the organ of Corti and the length of the basilar fibers progressively **increase from base to apex**. This fact, in itself, justifies the belief that it is the organ of Corti which enables the animal to discriminate sounds of varying pitch.

In the **endolymph** of each cavity, utriculus and sacculus, is a soft conglomerate mass of a gelatinous substance containing numerous minute crystals of calcium carbonate (**otoconia**). Substance of similar nature occurs in close relation to the crista of each ampulla. These **bodies** apparently serve to intensify the impact of vibrations or movements of the endolymph on the "hairs" of the sensory cells.

The **eighth cranial** ("acoustic") **nerve** distributes to six localities in the mammalian otic sac. In the wall of each of its main divisions, the utriculus and sacculus, is a thickened spot (**macula**) occupied by sensory "hair cells" (Fig. 182). A branch of the nerve passes to the **macula acustica utriculi** and another to the **macula acustica sacculi**. In the wall of the ampulla of each semicircular canal is an elongated sensory ridge (**crista**). A small nerve goes to each of these three **cristae acusticae**. A major division of the nerve passes up the axis of the cochlea, giving off a continuous spiral whorl of small branches which pass to the organ of Corti and terminate in close relation to its sensory cells (Fig. 517).

The early embryonic otic sac is enclosed in a cartilaginous **otic capsule**. This later ossifies to produce the several otic bones which eventually fuse to form the mammalian **petrosal bone**. In most mammals fusion of the petrosal with the neighboring **squamosal** and **tympanic bones** results in the complex **temporal bone**. Ossification immediately adjacent to the otic sac produces a relatively thin layer of extremely compact and hard bone which closely follows the contour of all parts of the sac, but at a little distance so that nearly everywhere space intervenes between the sac and the bone. Thus the complex form of the otic sac is repeated by its bony case which, accordingly and in distinction from the membranous labyrinth, is called the "**bony**



**labyrinth.**" The space between the two is filled by the **perilymph**, similar in nature to the **endolymph**. The outer surface of the bony otic shell is continuous with the adjacent spongy or cancellous part of the petrosal bone. The cancellous bone, however, because of its loose texture, is easily dissected away so that it is not difficult to make an instructive separate preparation of the bony labyrinth.

The **bony cochlear tube** is of much greater diameter than that of the membranous cochlea within it and is divided into an upper and a lower passage by a spiral partition, partly bony and partly of connective tissue, the **lamina spiralis** (Figs. 515, 516). On this lamina rests that part of the membranous cochlear wall which contains the organ of Corti. The outer (in relation to the vertical axis of the spiral) wall of the membranous cochlea is closely attached to the adjacent wall of the bony tube, and the third side of the triangular (in cross section) membranous tube is unsupported by solid tissue and is therefore bounded by endolymph below and perilymph above. The upper spiral passage within the bony cochlea is called the **scala vestibuli**; the lower is the **scala tympani**. The lamina spiralis does not quite reach the apex of the cochlea, so that there the two scalae are in communication.

The bony cochlea of the human ear has a diameter of about 9 mm. at its base and an axial height of 5 mm. Its spiral length is about 30 mm.

The mammalian **tympanic apparatus** ("middle ear") possesses the same general structure as that of reptiles. The **tympanic membrane** ("eardrum") is at the bottom of an **external auditory passage** (**meatus**), as it is in some reptiles and in birds, but deeper. The meatus is lined by infolded skin which produces hairs (at least in the outer region of the meatus) and **ceruminous** (**wax**) **glands** which are modified sebaceous glands. The connection with the pharynx is by way of an elongated and narrow **Eustachian tube** (Fig. 518), which, in consequence of the development of a secondary palate, opens not into the alimentary pharyngeal passage but into the posterior region of the nasopharynx above the "soft palate." A thin bony wall separates the tympanic cavity from the perilymph space of the internal ear (Fig. 518).

The mechanism for transmitting vibrations from the tympanic membrane to the sensory **internal ear**—the function performed by the simple rodlike columella of amphibians and sauropsids—consists of a chain of three small bones articulated together (Figs. 468, 518, 519). Their names—**malleus**, **incus**, **stapes**, meaning respectively "hammer," "anvil," "stirrup"—were suggested by their several forms, especially as they appear in the human ear. The handle of the

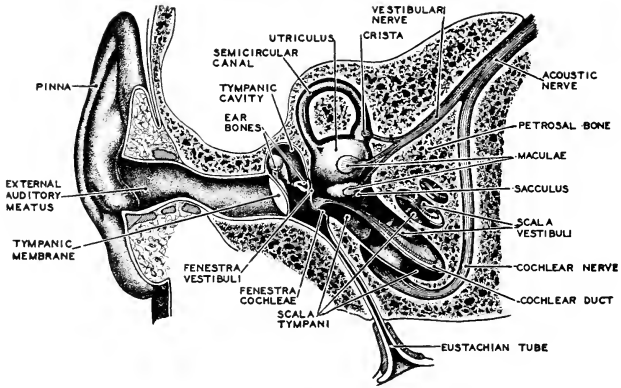


FIG. 518. The human ear: highly diagrammatic. In life the apex of the cochlea lies toward the Eustachian tube. In the figure it is rotated 180 degrees. (After Howell and Czermak. Courtesy, Neal and Rand: "Chordate Anatomy," Philadelphia, The Blakiston Company.)

"hammer" is attached to the tympanic membrane and its head rests upon a compactly formed solid little bone, the "anvil." The usual stirrup-like form of the third bone results from the fact that, at an early stage in its development, it is pierced by a small artery, a branch

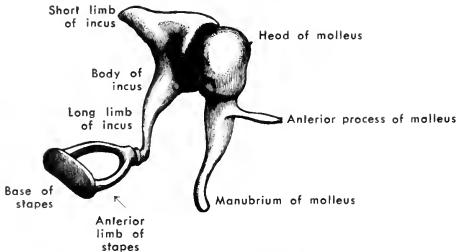


FIG. 519. The auditory ossicles of the human left middle ear, viewed from the anteromedial aspect. ( $\times 4$ ). (After Henle. Courtesy, Jackson: "Morris' Human Anatomy," Philadelphia, The Blakiston Company.)

of the internal carotid. In adults of some insectivores and rodents this **stapedial artery** persists, passing through the hole in the stapes. In most mammals the artery is only temporarily present, but meanwhile the stapes becomes ossified and disappearance of the artery leaves the empty hole through the bone. In monotremes, some marsupials, and pangolins (*Manis*), the stapes is solid and elongated, resembling the

reptilian columella with which it is probably, at least in part, homologous. The embryonic origin of the **malleus** and **incus** indicates that they correspond, respectively, to the reptilian **articular** and **quadrate**, which do not otherwise appear in the mammalian jaw. The joint between malleus and incus would therefore correspond to the joint between the reptilian lower and upper jaws (Fig. 520).

The **malleus**, attached to the tympanic membrane, articulates by its "head" with the **incus**, which, in turn, articulates with the **stapes** (Figs. 518, 519). That part of the stapes opposite the incus is an oval flat plate which fits fairly closely into an aperture (**fenestra vestibuli**, or **fenestra ovalis**) in the bony wall between the tympanic

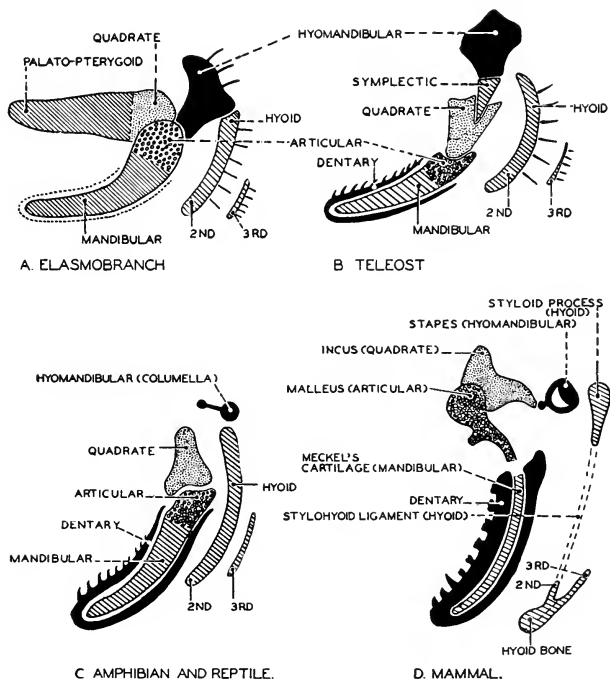


FIG. 520. Diagrams of the first and second visceral arches in (A) elasmobranch, (B) teleost, (C) amphibian and reptile, and (D) mammal, illustrating the transformation of the hinge of the jaw of lower vertebrates into the malleus and incus of the mammal. The third ear-bone, the stapes, comes from the hyomandibular. (After Gegenbaur and Stempell. Courtesy, Neal and Rand: "Chordate Anatomy," Philadelphia, The Blakiston Company.)

cavity and the perilymph space. The periphery of this stapedial plate is attached to the wall of the fenestra by a ring of tough fibrous tissue which effectually closes the aperture but is sufficiently elastic to permit of slight in-and-out movement of the stapedial plate. Near the fenestra vestibuli is another aperture in the bone, the **fenestra cochleae** (or **rotunda**). This fenestra is completely closed by a tough and elastic membrane. It is to be noted that the **fenestra cochleae** abuts upon the **scala tympani** of the bony cochlea, while the **fenestra vestibuli** is at the base of the upper cochlear passage, the **scala vestibuli**. The relations of these several spaces may be appreciated if it be imagined that a person small enough to do so should make an exploratory tour of the cochlea (Fig. 518). Starting at the "oval window," he could ascend the scala vestibuli (scala meaning a "staircase," but the lamina spiralis is, in fact, a spiral ramp rather than a flight of steps) and, arriving at the apex of the cochlea, could climb around the free edge of the lamina spiralis and descend the cochlea via the scala tympani, finishing his trip at the "round window" (fenestra cochleae). This relation of the passages is of physiologic significance.

Certain very small muscles extend between the deeper part of the wall of the tympanic cavity and the ear-bones. The **tensor tympani** inserts on the malleus; the **stapedius** inserts on that end of the stapes which articulates with the incus. Contraction of the tensor tympani pulls the tympanic membrane inward and thus increases the tension in it. Contraction of the stapedius tends to draw the stapes away from the fenestra vestibuli and so increases tension in the membrane which joins the stapedial plate to the rim of the fenestra.

An externally conspicuous and distinctively mammalian addition to the auditory apparatus is the **external ear** (**pinna** or **auricula**), whose more or less funnel-like form enables it to collect and reflect aerial vibrations into the external auditory meatus at its base. It is supported by cartilage and equipped with muscles which, in most mammals, make possible its rotation into positions favorable for reception of vibrations. In relative size, form, and degree of mobility, the pinna is highly variable, ranging from the disproportionately large pinna of the elephant to complete absence of pinnae in monotremes, sea cows, cetaceans, some seals, and some burrowing animals (e.g., the Australian marsupial blind mole, *Notoryctes*). Projecting pinnae are obviously incompatible with swimming and burrowing.

In relation to the tympanic cavity and external ear, the **tympanic bone** is a characteristic mammalian feature. This dermal bone surrounds, partly or completely, the tympanic membrane and constitutes the greater part of the bony wall of the tympanic cavity, the wall being

completed by the deeper petrosal bone. The tympanic bone commonly forms a conspicuous semiglobular swelling, the **bullae tympani** (Fig. 465, *T*), protruding externally at the base of the otic region of the skull. It provides a firm support for the tympanic membrane. In some cases it produces a thin-walled tubular shell enclosing the external auditory meatus and giving support to the base of the pinna. In the rabbit, for example, both this tubular part and the bullae are conspicuous. In monotremes, marsupials, and some placental mammals, the tympanic appears as a distinct bone in the adult skull, but in most mammals it fuses into the temporal complex.

The mammalian tympanic bone has been regarded as the homolog of the reptilian quadratojugal, which does not otherwise appear in mammals, but in the embryo the tympanic is in such relation to the malleus (reptilian articular) as would rather identify the tympanic as equivalent to the reptilian dermal **angular**.

#### *Hearing and Equilibration*

The sequence of events resulting in stimulation of the sensory cells of the organ of Corti is as follows: Vibrations of the external air, more or less concentrated into the meatus by the pinna, impinge upon the tympanic membrane. The texture and state of tension of this membrane are such that it has little or no tendency to vibrate at any fixed rate determined within itself, but freely vibrates in unison with the external medium. The tympanic cavity is filled with air and communicates with the external air via the Eustachian tube and nasal passage. This arrangement equalizes atmospheric pressure on the opposite sides of the tympanic membrane, thus allowing it perfect freedom of vibration. As a result of the malady known as a "common cold," the Eustachian tube may become obstructed, a condition which more or less impairs hearing.

The vibrations of the tympanic membrane are transmitted by the chain of auditory ossicles to the wall between the tympanic cavity and perilymph space of the internal ear, causing the stapediale plate to vibrate in and out in unison with vibrations of the tympanic membrane. This it is able to do because of its elastic attachment to the rim of the fenestra vestibuli (ovalis). The part played by the two muscles, tensor tympani and stapedius, is not certainly known. It is possible that, by controlling the degree of tension in the tympanic membrane and in the membranous attachment of the stapes, they may adjust the transmitting mechanism so as to produce an optimum response to the particular vibrations which are coming in, thus acting as a mechanism for auditory "accommodation." These muscles are striated but, at least in man, are usually involuntary. The rare individual in whom

they are under voluntary control may be able to render himself temporarily deaf by contracting (one or both of?) the muscles.

From the fenestra vestibuli the vibrations are passed on to the perilymph. The relation of the fenestra to the cochlear passages (Fig. 518) is such that the vibrations most readily progress up the spiral scala vestibuli and, at the apex of the cochlea, pass into the scala tympani and continue downward along it to arrive finally at the fenestra cochleae (rotunda), to whose membrane the vibrations are imparted. The perilymph being an incompressible fluid, the membrane of the fenestra cochleae must move outward synchronously with each inward movement of the stapedial plate.

As the vibrations pass through the perilymph of the scala vestibuli, they are freely transmitted to the endolymph of the membranous cochlea, the two fluids being separated only by a membrane of extreme thinness (Fig. 516). The vibrations of the cochlear endolymph are somehow caused to stimulate the "hair cells" of the organ of Corti. Just how is more a matter of conjecture than of precise knowledge. Whether the agencies immediately concerned are the **pillar cells** (least likely), or the transverse **fibers** of the **basilar membrane**, or vibrations of the **membrana tectoria** in close relation to the "hairs" projecting from the sensory cells into the endolymph, is a matter for further investigation. But the progressive change in the dimensions of the histologic elements of the organ of Corti along its spiral length makes it seem certain that the organ is locally adapted for response to vibrations of a particular frequency ranging from lowest frequency at the apex to highest at the base of the cochlea. A musical chord made by striking three piano keys would presumably affect three quite separate regions of the organ. It is a mechanism which serves for discriminative hearing.

The **sensory range** of the cochlea is not the same in all mammals. Dogs respond to vibrations whose frequency is above the range of the human ear—i.e., "**supersonic**" for man. The larynx of the bat can produce supersonic vibrations, but the bats hear them. While flying in darkness, bats emit these high-pitched sounds (i.e., "sounds" to them) which enable them to avoid collision with one another. Reflection of the vibrations by surfaces of external objects (echoes) enables the bats to avoid hitting the objects. The pinnae of bats are relatively large.

The sensory structures of the semicircular canals serve for **equilibration**, not for hearing. The planes of the three canals are at angles of approximately 90 degrees to one another. The vertical canals are at angles of about 45 degrees to the sagittal plane of the animal. Any

movement of the head must cause some flow of endolymph in the canals and their ampullae. The amounts of flow in the several cavities will be unequal, the degree of inequality depending upon the spatial relation of the plane of each canal to the direction in which the head moves. The result is a differential stimulation of the three cristae acusticae. There is doubt as to the exact nature of the functions of the sensory maculas of the mammalian utriculus and sacculus. It seems most likely that they have to do with equilibration, probably registering the *static* position of the animal, whereas the ampullar cristae register *changes of position*. There is evidence that fishes—at least some of them—hear, probably by means of the maculas of the utriculus and sacculus (possibly the sacculus only), because the lagena is very slightly developed. It is possible that the macula of the mammalian sacculus may serve for reception of vibrations which are of lower frequency than those which stimulate the cochlear organ.

Whether the average mammalian eye is superior to that of reptiles may be open to question. The olfactory organ of mammals, judged by its more elaborate structure, must be considerably more efficient than that of reptiles. The mammalian ear as an auditory organ is unquestionably far superior to the reptilian ear. The high degree of elaboration of the mammalian cochlear structures, even as compared to the best reptilian cochlea (that of crocodilians), cannot be without physiologic meaning. Some reptiles may have a very keen sense of hearing but they lack the mechanism requisite for any wide range of auditory discrimination.

The auditory capacities of vertebrates are, in general, correlated with their vocalizing abilities. This seems to imply that the thing of primary importance is that an animal should be able to hear another of its own kind. Consistent with the greater elaboration of the mammalian cochlea, the vocal performances of cats, coyotes, and donkeys and the chatter of primates far excel anything in the vocal repertory of reptiles. The roar of a big alligator is terrific but it is totally lacking in the tonal quality and emotional expressiveness which mark the voices of dogs and cats. The alligator is perhaps not especially interested in hearing anything but another alligator. It must be admitted that the correlation between vocalization and hearing is not to be observed in all members of a vertebrate Class. There are many mammals which seem to have very good ears but only feeble vocal ability.

The **human mammal** far excels all others in capacity for producing sounds. Structurally, his cochlea seems to be not markedly better than that of many other mammals, but he at least makes much more use of it. This is to be credited to his brain rather than to his ear.

The most striking biologic peculiarity of the human primate is his propensity for modifying his environment—achieving ends by use of means external to his body. Perhaps no aspect of his life better illustrates this than his production of sound and his responses to sonic stimuli. Equipped with an excellent cochlea attached to a restless, curious, and inventive brain (these are obviously not anatomically descriptive terms; they refer to the behavior which is somehow correlated with the brain), he is discontented with the vocal production of his own larynx and not satisfied by the multiplicity and diversity of sounds proffered him by “Nature,” both animate and inanimate. Accordingly, he has devised a great variety of sound-producing mechanisms. He provides himself with an accessory and extraneous larynx by inserting into his mouth a suitably contrived tube of wood or metal. By forcibly ejecting his breath into it, sound is produced by vibration of the air in the external tube instead of that in his own respiratory tube. He builds a mighty “organ,” a compound larynx comprising hundreds of laryngeal pipes, their activating breath supplied by an electric pump, and all operated by his hands and feet. He makes great tympani (kettledrums) whose vibrations impinge upon his own tympanic membrane. He creates hybrid mammalian voices by the unique device of drawing hairs from horses’ tails across cords of catgut. By use of external mechanisms, he is able to amplify greatly the volume of his own voice and of other sounds, to extend the distance—even to thousands of miles—over which his voice and other sounds may be heard, and to cause precise repetition of sonic vibrations days or years after they were produced and in complete absence of their original sources.

Not content with hearing one voice at a time, he listens to a chorus of hundreds of voices singing, not in unison, but in four or five parts whose sounds differ in pitch, sequence, and duration. He assembles a hundred or more players on most diverse instruments. All playing at once, they produce a sonic ensemble which, in complexity at a given instant and in the intricate interweaving of the many different sequences of tones, must far surpass any vibratory atmospheric disturbance that ever before assailed a vertebrate ear. The resulting complexity of events in the organ of Corti is unthinkable. The incoming stimuli are transmitted, all in proper order, to the acoustic center in the medulla of the brain and thence relayed forward to various correlating centers and also to the cerebral cortex. Apparently it is from the cortex that they somehow (we know not how) emerge into the higher levels of consciousness. At a particular instant, the sensation is that of a relatively simple and pleasing (depending on the composer) harmony. The successive harmonies integrate into a musical idea or



theme. In these final conscious forms there is nothing of the bewildering complexity of the physical events intervening between orchestra and cochlea and no suggestion of the incredible task performed by the organ of Corti in sorting out the innumerable overlapping sets of vibrations and forwarding the resulting stimuli to the brain not only faithfully but instantly. Heard through such an ear as that of most reptiles, the symphony would probably be, at best, merely a big noise. If dogs, cats, and some human individuals do not enjoy it, the inability is probably more cerebral than auditory. To many a human primate it may be a great esthetic, emotional, and intellectual adventure.

By use of external means, man achieves not only new sounds for the ear, but new sights for the **eye**. To the lens of his eye he adds the lenses of his telescopes and microscopes, thereby vastly extending the range of his vision into the far distance of the sky and the near distance of minute things. His cities and objects of art and his written and printed language add bewildering complexity to the "natural" landscape which confronted his primitive eyes. By photography he sees things which no longer exist and observes events long past—and television has most recently been achieved.

The senses of **smell** and **taste** are less amenable to exploitation than those of sight and hearing. Nevertheless, man's chemical manipulation of his environment has produced many new things which may or must be smelled and, by addition of various artificial and synthetically produced ingredients, the taste of his natural foods is not always improved but is at least modified, for better or worse.

### BRAIN

The assertion that the mammalian brain is relatively large is commonly made—and with the implication that the fact is creditable to the mammal. The significance of size of organs varies according to the nature of their functions. A stomach is large in proportion to the quantity of food it must contain and the amount of digestive fluid it must secrete. A muscle is large in proportion to the power it must produce when it contracts. A heart is large according to the volume of blood it must contain and pump. The size of the constituent cells of an organ does not vary with the size of the organ or animal. Cells of corresponding tissues are of approximately the same size in small and large mammals. (In fact, among amphibians, the largest cells occur in some of the very small salamanders.) In the organs of the larger mammals, therefore, the number of cells is correspondingly larger. This is true for the brain, but here the fact has a peculiar significance.

A suspension-bridge cable is large in diameter because it must

sustain great weight. Accordingly, it consists of a large number of strands of wire. A telephone or telegraph cable contains many wires, each wire (or pair of wires) serving a particular instrument or group of instruments. The single and simple weight-supporting function of the bridge cable is the summation of the functions of its many constituent wires acting all at once and all in the same way. The electric cable, as a whole, may be said to perform the function of communication, but it does not act as a whole in the manner that the bridge cable does. "Communication" is not the mechanical resultant of the actions of its wires acting all at once and all in the same way. Its specific functioning is that of the individual wire. The many wires act independently. They do many different things and probably they never all act at once. Were they to do so, the summation of their actions would not be a useful function analogous to the supporting function of the bridge cable; it would be a chaos of jumbled messages.

A muscle, consisting of many parallel muscle-fibers (cells), resembles the bridge cable except in that the function of the cable is static and that of the muscle is dynamic. The essential function of the muscle is its contraction, which is the summation of the contractions of its constituent fibers. The brain resembles rather the electric cable. The function of the brain as a whole may be said to be the control of the activities of the animal, but this total function is not the mechanical resultant of the simultaneous action of all of its constituent parts as it is in the bridge cable and muscle. Its essential functioning is that of the individual nervous elements or groups of related elements acting, at a given moment, independently of other elements or groups, the several elements or groups having each its own specific function and never all acting at once. (Were they all to act at once, the result might be cataclysmic for the animal!)

In muscles, hearts, stomachs, and glands, the function as a whole is the important thing, and each of the organ's constituent cells is functionally, as well as structurally, a subordinate constituent of the whole. In a brain the function of a single cell (neuron) or group of coöperating neurons is the primary thing. There is, in strict sense, no nervous function of the brain as a whole. Its **size** is, therefore, incidental to the necessary number of its neurons, and the **form** of the whole brain is merely an incident of the necessary and specific arrangement of the constituent parts, having in itself no dynamic or physiologic significance—i.e., it would not matter functionally whether a certain lobe of the brain were spherical, ovoid, or cubical, so long as its constituent neurons were properly connected. In short, then, *the larger muscle contains more cells because its function requires that it be larger; the larger brain is larger because its functions require that it contain more cells.*



teristic of the brains of all other vertebrates are well differentiated. Each is the seat of important nervous mechanisms. The telencephalon is concerned mainly with the olfactory sense. The visual centers are in the mesencephalon. The integumentary senses, taste and other visceral senses, equilibrium, and (if present at all) hearing have their primary centers in the myelencephalon. In the metencephalon the cerebellum is an important coördinating mechanism. In the telencephalon the differentiation of nervous structures takes place mainly in the ventral and lateral walls, forming the **corpora striata**. In teleosts the dorsal wall (**pallium**; Fig. 324) is quite devoid of nervous elements, and in other fishes the pallium is only moderately thickened by the presence of nervous elements. In amphibians, reptiles, and mammals, the nervous mechanisms of the pallium progressively increase in number and importance until, in many mammals, the pallial tissue not only outweighs the corpora striata (the ventral masses of the hemispheres), but may even exceed all the rest of the brain. Functionally, the pallial mechanism dominates all the rest of the brain. It seems likely that in the most primitive fishes the pallium was entirely non-nervous, as it is in modern cyclostomes. The nervous pallium, therefore, and especially in its highly developed state in mammals, can be conceived as a "new" acquisition of the vertebrate brain. Meanwhile, the corpora striata and all regions posterior to them have undergone relatively little change. Collectively, they constitute the persisting original or "old" brain. Edinger proposed to call it the "**palaeencephalon**," while the elaborated pallium, together with some other "new" parts closely related to it, he called the "**neencephalon**."

In the reptilian pallium the bodies of the nerve-cells are fairly definitely segregated into a superficial layer of "gray substance," the **cerebral cortex**, the deeper "white substance" consisting mainly of nerve-fibers. This cortex is much more prominent in mammals, the "gray" layer being relatively thicker and more definitely delimited. In ungulates, carnivores, and primates the cortical tissue is especially voluminous and its manner of disposition in relation to the underlying "white substance" is peculiar. The cortical layer is of approximately uniform thickness throughout its extent but it, together with the adjacent "white" material, is as if it had been elaborately folded inward and outward, the adjacent projecting masses being separated by narrow, deep depressions (Figs. 521, 523). The projecting masses are called **convolutions** or **gyri**, and the intervening clefts are **sulci**. An especially deep sulcus is called a **fissure**. Certain major fissures, definitely located and of common occurrence, are regarded as dividing the cerebral hemispheres into "**lobes**." Most conspicuous is the

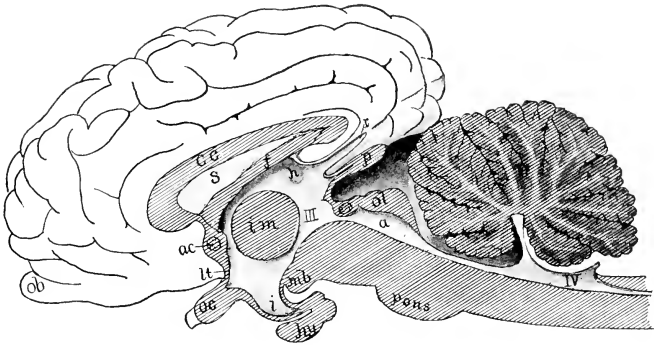


FIG. 522. Sagittal section of the brain of a calf. (*a*) Aqueduct; (*ac*) anterior commissure; (*cc*) corpus callosum; (*f*) fornix; (*h*) habenula; (*hy*) hypophysis; (*i*) infundibulum; (*im*) intermediate mass ("soft commissure"); (*lt*) lamina terminalis; (*mb*) mammillary body; (*ob*) olfactory bulb; (*oc*) optic chiasma; (*ol*) optic lobes; (*p*) pinealis; (*r*) recessus suprapinalis; (*s*) septum pellucidum; (III, IV) third and fourth ventricles. (After Bütschli. Courtesy, Kingsley: "Comparative Anatomy of Vertebrates," Philadelphia, The Blakiston Company.)

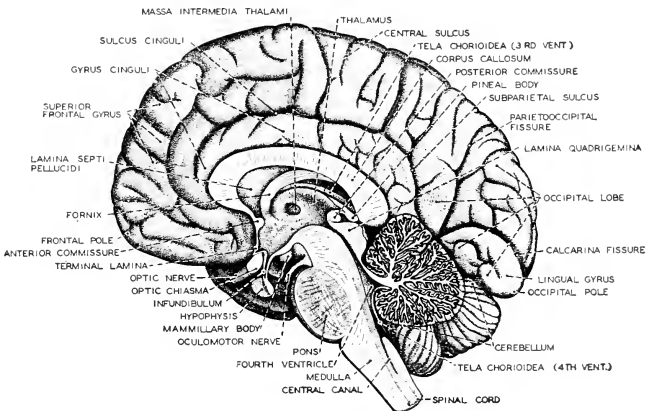


FIG. 523. The human brain in sagittal section. Since the plane of section passes between the two cerebral hemispheres, the figure shows the left (medial) surface of the right hemisphere. (After Sobotta. Courtesy, Neal and Rand: "Chordate Anatomy," Philadelphia, The Blakiston Company.)

fissure of Sylvius on the external side of the hemisphere, separating the **frontal lobe** from the **temporal lobe**, which is below and behind the fissure (Fig. 524). In the human brain **parietal** and **occipital lobes** also are recognized. These lobes are merely topographic, but are not functionally distinct.

The question arises as to why a given volume of cortical substance should be disposed in this elaborately folded manner rather than in the form of a thicker layer lying smoothly over a smooth surface of "white substance." It is as if the cortex had been unable to increase in thickness as it increased in volume and accordingly was compelled to develop wrinkles. Certain advantages of the convoluted arrangement can be recognized. The innermost investing membrane of the brain, the **pia mater**, thin but richly vascular, is folded deeply into all the fissures

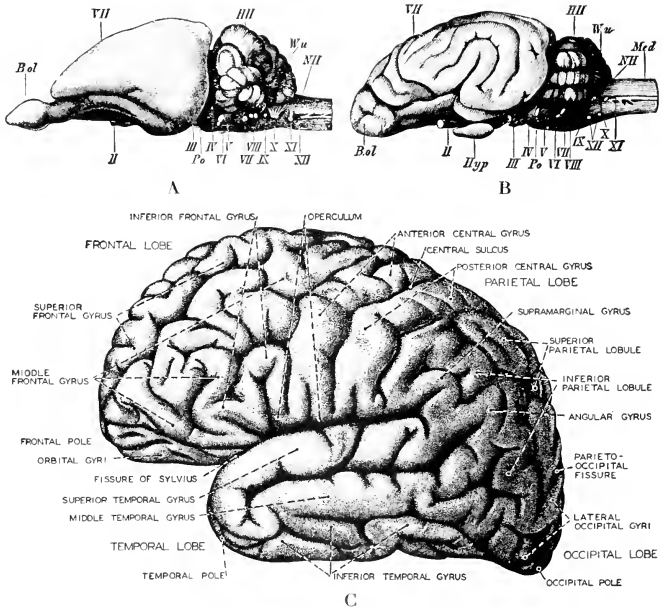


FIG. 524. Lateral views of brains of (A) rabbit, (B) dog, and (C) man. (*B.ol*) Olfactory lobe; (*III*) cerebellum; (*Hyp*) hypophysis; (*Med*) spinal cord; (*NII*) medulla oblongata; (*Po*) pons Varolii; (*VII*) cerebral hemispheres; (*Wu*) median vermis of cerebellum; (II–XII) cranial nerves. (A and B, courtesy, Wiedersheim: "Grundriss der vergleichenden Anatomie der Wirbeltiere," Jena, Gustav Fischer. C, after Sobotta. Courtesy, Neal and Rand: "Comparative Anatomy," Philadelphia, The Blakiston Company.)

and sulci, thereby greatly expanding the surface of contact between the cortex and pia. This makes it possible for the cortex to obtain a greater proportion of its necessary blood from an external source rather than from vessels inside the brain. It has been suggested that the presence of large pulsating arteries within the nervous tissue might interfere with nervous functions, although this is by no means certain. A second advantage derives from the fact that the folding increases the superficial extent of the region where the "gray" layer merges into the "white." Millions of nerve-cells in the cortex must be reached by nerve-fibers which course through the "white" substance in the form of great, but not sharply delimited, bundles or "tracts," each comprising vast numbers of fibers. Many of these tracts connect with centers in the more posterior parts of the brain (Fig. 525). Many others pass, by way of the "white" substance, from one region of the cortex to another (Fig. 526). The convoluted arrangement of the cortex increases the space available for the inconceivably great number of connections between the cortical cells and the nerve-fibers of the subcortical mass. It seems probable, further, that for spatial localization of nervous functions in the cortex a thinner layer having greater superficial extent is more favorable than a thicker layer of less extent. That such localization exists has been proved (Fig. 527). The sorting out of fiber-tracts so that certain tracts go to a particular group of cortical cells is more readily done if the cortical centers are spaced apart laterally in a thin layer instead of being superimposed one above another in a thick layer.

In monotremes and marsupials and in insectivores, bats, and rodents, convolutions of the cortex are, at most, few and not prominently developed, and in many cases the external surfaces of the hemispheres are quite smooth (Figs. 521*B*, 521*A*).

Next to the cerebral cortex itself, and important in relation to the function of the cortex, the most conspicuous "new" feature of the mammalian brain is a great system of nerve-fibers making transverse connection between right and left cerebral hemispheres. The central nervous organs, like most other vertebrate organs, are bilaterally symmetric. For perfect action and control of the motor mechanism of the body, right and left coordination is just as important as longitudinal. Correlation of right and left nervous centers in the brain is effected by transverse systems of fibers—**commissures**. For correlation of centers in the tremendously enlarged hemispheres of mammals, a "new" commissure, vastly larger than any of the several commissures of the palaeöencephalon, appears. It extends transversely between the hemispheres, but its position is extraordinary. The two hemi-

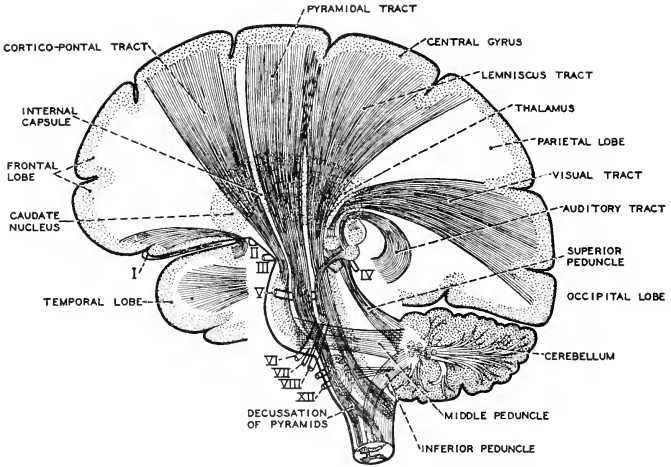


FIG. 525. Diagram showing the relations of the "projection" fiber-tracts of the human brain. The cranial nerves are numbered by the Roman numerals. (After Howell. Courtesy, Neal and Rand: "Comparative Anatomy," Philadelphia, The Blakiston Company.)

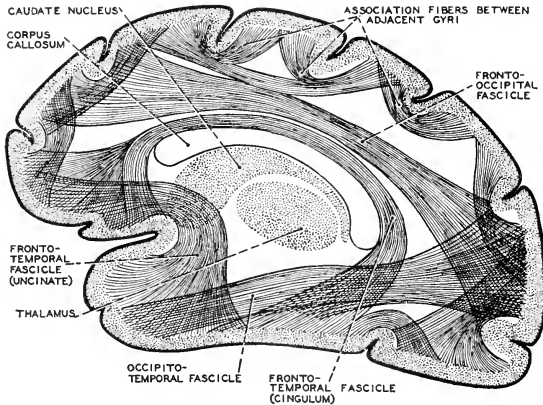


FIG. 526. Diagram of the "association" fiber-tracts of the cerebral hemisphere as seen in lateral aspect. These tracts all bring parts of the cerebral cortex into relation with one another. The integration of the activities of the various parts of the brain is, it may be assumed, effected in this way. (After Howell and Starr. Courtesy, Neal and Rand: "Comparative Anatomy," Philadelphia, The Blakiston Company.)



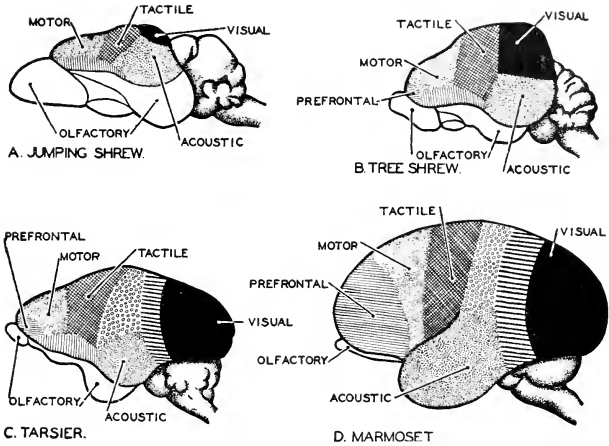


FIG. 527. Diagrams of the brains of insectivores and of lower primates, viewed from the left side. The figures show the increasing dominance of the centers of vision over those of smell. (A) Brain of jumping shrew. (B) Brain of tree shrew. (C) Brain of the primate *Tarsius*. (D) Brain of the marmoset. (After Smith. Courtesy, Neal and Rand: "Chordate Anatomy," Philadelphia, The Blakiston Company.)

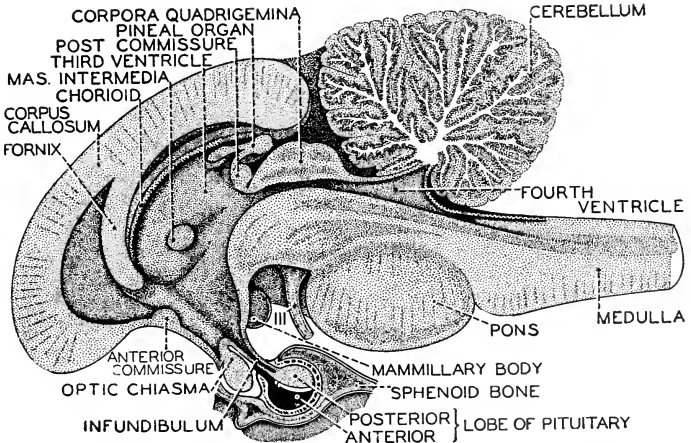


FIG. 528. Sagittal section of the human brain-stem. (After Sobotta. Courtesy, Neal and Rand: "Chordate Anatomy," Philadelphia, The Blakiston Company.)

spheres bulge forward far beyond the anterior end (**lamina terminalis**) of the median neural tube from which they have grown out (Fig. 522). The "new" commissure, the **corpus callosum**, extends across the very narrow median external space between the two hemispheres. It is so shaped (as best seen in sagittal section: Figs. 522, 528) that a small part of this space is completely enclosed between the corpus and the adjacent external surfaces of the brain. The earlier anatomists recognized four cavities or "ventricles" in the human brain and counted this thin little space beneath the corpus callosum as the "fifth ventricle." But it differs from the other "ventricles" in that they are regions of the lumen of the primary neural tube, while the "fifth ventricle" is a secondarily enclosed bit of space external to the tube.

Brains of monotremes and marsupials lack the corpus callosum.

The mammalian **olfactory lobes**, anteroventral outgrowths of the telencephalon, are well developed in proportion to the extent of the nasal olfactory surfaces. At their most, however, they appear insignificant in contrast to the otherwise enormously enlarged telencephalon (Figs. 521B, 522, 524A). Whereas in Anamnia the olfactory mechanism constitutes most of the corpora striata, in reptiles and mammals progressively more of its territory is occupied by association-tracts and centers related to the various centers in the rear parts of the brain. The primary olfactory mechanism may not decrease in absolute value, but it loses its primary sensory independence as it comes to be more closely tied in with all the other sensory mechanisms.

The lateral walls, **thalami** (Fig. 529), of the **diencephalon** are occupied by nervous centers whose relations in Anamnia seem to be mainly olfactory (possibly, to a small extent, visual in amphibians), but in Amniota, and becoming most prominent in mammals, important visual centers develop in the thalami, and the various thalamic centers have extensive connections both backward and forward. A considerable proportion of the fibers of the mammalian optic nerves, instead of going into the visual centers of the mesencephalon, pass to centers in the posterodorsal regions of the thalami, and these thalamic centers are connected with the cerebral cortex.

The thin non-nervous roof of the diencephalon produces a median dorsal outgrowth, the **pineal body**, whose position corresponds to that of the pineal eye or pineal organ of Anamnia and reptiles (Fig. 142), but its structure has nothing suggestive of an eye and its tissue is apparently glandular, but of unknown function (Figs. 522, 528).

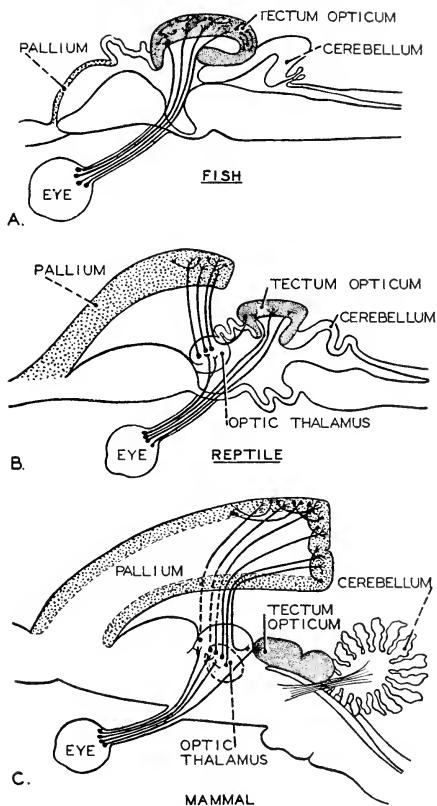


FIG. 529. Diagram illustrating the connections of optic nerve-fibers in (A) a fish, (B) a reptile, and (C) a mammal. The definitive centers of vision lie in the occipital lobes of the cerebral hemispheres. Some primitive centers in the optic lobes persist in mammals as reflex centers. (After Monakow. Courtesy, Neal and Rand: "Comparative Anatomy," Philadelphia, The Blakiston Company.)

The roof of the **mesencephalon** becomes thickened to form lobes which are more or less important as the seat of primary visual centers (Figs. 522, 528). In vertebrates other than mammals, a single pair of optic lobes (**corpora bigemina**) are the chief seat of the primary visual centers. In mammals two pairs of lobes (**corpora quadrigemina**) appear in the roof of the mesencephalon. Those of the anterior pair are visual centers, but those of the posterior and smaller

pair are mainly auditory. (In some reptiles and in birds there is a pair of very small lobes just behind the corpora bigemina.)

It is to be noted that, whereas the external connection of the optic nerves with the brain is at the base of the diencephalon, the internal connections of the fibers of the optic nerves are largely, or in fishes perhaps entirely, in the roof of the mesencephalon. The position of the external connection of the nerves with the brain is an incident of the fact that the retina develops as an outgrowth from the base of the first (anterior) primary brain vesicle (see p. 200).

In the **metencephalon** the **cerebellum** exhibits conspicuous mammalian peculiarities (Figs. 521, 524). Relatively large, it is divided into a **median lobe** and a pair of **lateral lobes** or **cerebellar hemispheres**. Lateral and ventral to each hemisphere is a very small lobe, the **flocculus**. The flocculi correspond to the similarly named bodies found in birds and some reptiles. The surfaces of the cerebellar lobes

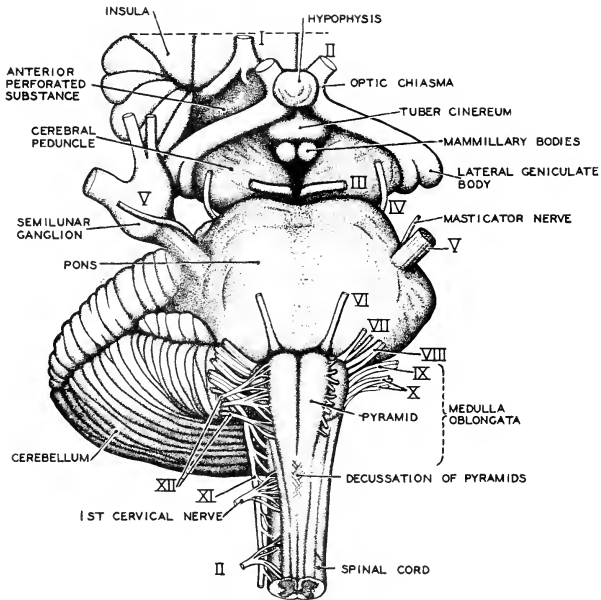


FIG. 530. Human brain-stem in ventral aspect, showing nerve connections. (After Morris and Thomson. Courtesy, Neal and Rand: "Chordate Anatomy," Philadelphia, The Blakiston Company.)

are more or less elaborately folded in a manner resembling that of the convolutions of the cerebral cortex. The middle lobe is called the **vermis** because its conspicuous transverse convolutions cause it to resemble a short, thick, segmented worm. The vermis is always well developed, but the lateral lobes vary in size according to the degree of development of the cerebral cortex.

The cerebellum resembles the cerebral hemispheres not only in the convoluted outer surface, but also in having a well-defined outer layer of "gray substance," the **cerebellar cortex**. The demarcation between this cortex and the underlying "white substance" is less regular than in the cerebral hemispheres. On the surface of a sagittal section of the vermis (Figs. 522, 528), the "white substance" is seen to be disposed in the form of a treelike mass whose branches extend up into the "gray"—hence the old name, **arbor vitae**, given to this arrangement of the materials.

The conspicuous feature of the ventral wall of the mammalian metencephalon is a great transverse band of substance including some "gray" masses ("nuclei"—clusters of nerve-cells) and great tracts of fibers. This transverse bridge, the **pons Varolii** (Figs. 522, 524B, 528, 530), connects the right and left cerebellar lobes. It makes a sharp ventral demarcation between the metencephalon and medulla.

The **myelencephalon** of mammals, compared to that of other vertebrates, shows a minimum of change. More so than any other of the five regions of the mammalian brain, it is truly **palaeöencephalic**.

#### CRANIAL NERVES

The cranial nerves of mammals consist of the 12 pairs characteristic of all Amniota (Figs. 521, 524, 530, 531). In their points of origin from the brain and in their general plan of distribution, they differ in no important way from the cranial nerves of reptiles. Certain peculiarities of the three nerves of "special sense," I, II, and VIII, should be mentioned.

The **olfactory (I)** fibers coming from the olfactory epithelium of each nasal cavity, instead of being bound up together in one compact nerve, are disposed in the form of numerous small nerves. Each olfactory lobe of the brain is close to the corresponding nasal cavity, being separated from it only by the thickness of the mesethmoid bone. The region of the bone adjacent to the two olfactory lobes is perforated by numerous minute holes, through each of which passes one of the small divisions of the nerve. The perforated part of the bone is called the "**cribriform** (sievelike) **plate**."

The **optic nerves (II)**, emerging from the eyeball, converge to a crossing or **chiasma** on the base of the diencephalon (Figs. 522, 528,

530). In vertebrates other than mammals, all the fibers of each nerve cross those of the other—"complete **decussation**"—so that each eye is connected only to the visual centers which are on the side of the brain opposite to it. In mammals there are varying degrees of incomplete decussation. In *Ornithorhynchus* the crossing is said to be complete. There is apparently a correlation between direction of vision and degree of incompleteness of decussation. In mammals with laterally directed eyes (e.g., rodents), the crossing is nearly or quite complete. In carnivores and primates, whose eyes are directed more or less nearly forward, a third (in cat) to a half (in man) of the fibers continue back to visual centers on the same side as the eye from which they came. It

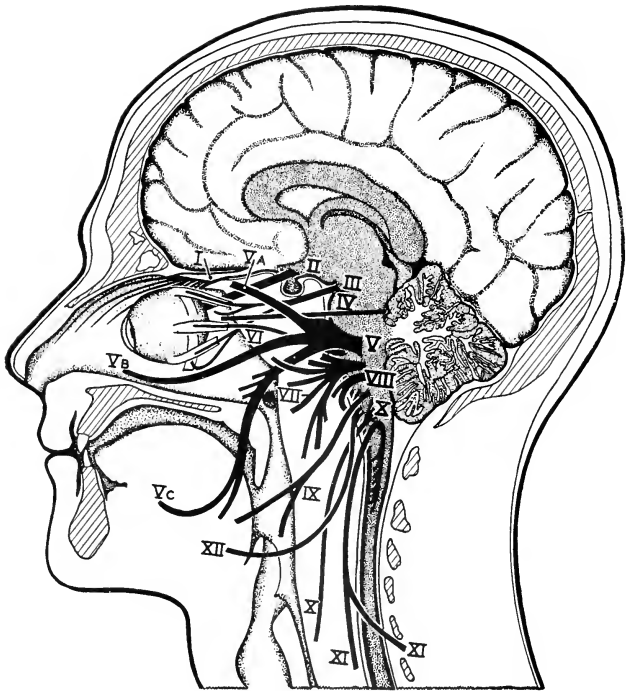


FIG. 531. The 12 cranial nerves shown as if projected upon a median section of the head. (I) Olfactory lobe; (II) optic; (III) oculomotor; (IV) trochlearis; (V) trigeminus; (VI) abducens; (VII) facialis; (VIII) acusticus; (IX) glossopharyngus; (X) vagus; (XI) accessorius; (XII) hypoglossus. (Courtesy, Neal and Rand: "Chordate Anatomy," Philadelphia, The Blakiston Company.)

seems evident, therefore, that incomplete decussation is related to binocular vision. It provides that the visual centers on each side of the brain shall receive impressions from both eyes. Precisely how it works to give the animal a unified picture of the outside world is the subject of many theories and is one of the many unsolved problems presented by vertebrate eyes.

The **eighth cranial nerve** (inaccurately named "auditory" or "acoustic") clearly demonstrates, by its central connections, that the ear is physiologically two organs. The nerve consists of two quite distinct trunks. The **vestibular trunk** passes to the sensory cristae of the semicircular canals and to the maculas of the utricle and saccule. The **cochlear trunk** goes to the organ of Corti. The two trunks pass together into the medulla, where each becomes related to primary reflex centers. The vestibular centers are connected with coördinating centers in the cerebellum but apparently have, at most, only slight connection forward into the cerebral cortex. The cochlear trunk is connected not only with various reflex mechanisms in the medulla and cerebellum and with others in the posterior pair of lobes of the mesencephalic corpora quadrigemina, but also has important connections forward with the higher coördinating centers of the thalami and, finally, with centers in the temporal region of the cerebral cortex.

#### MECHANISM OF BEHAVIOR

The foregoing account of the mammalian brain sketches only in barest outline the overwhelming intricacies of its structure. Even so, the meager outline may suffice for a little appreciation of its general mode of operation. The brain has been likened (p. 667) to the office of a manufacturing establishment. The office must receive information both from the outside and from the inside of the factory. From outside must come information (exteroceptive) concerning needed raw materials and orders for products. From inside must come reports (interoceptive) on the progress of the work and various other matters. Also, the office must be kept informed about the condition and working efficiency of its machinery (proprioceptive information). Information of the various sorts comes at first to the hands of secretaries and subordinate employees, each of whom transmits it to one of higher authority who, after some analysis and coördinating of information received, forwards the results to still higher officials. In a secluded private office may be found the person or persons who plan, make major decisions, and give orders as to what is to be done and when and how it shall be done. These orders are transmitted to a group of executive officers who see that the specified work is properly carried out in the factory. But the executives have no authority to initiate anything unusual or new

in the conduct of the business. However, in a large number of minor and routine matters, subordinate employees are authorized to act directly without referring the matter to a superior.

The brain, like the office of the factory, must receive "information," not necessarily conscious, as to conditions and events both outside (exteroceptive) and inside (intero- and proprioceptive) the animal. On the basis of the information received, "orders" must go forth to bring about appropriate action of the body. If the action is to be of highest advantage to the animal, there must be some agency competent to act in such a way that we must describe the action as showing discrimination, judgment, or choice of one—the most advantageous—among several possible reactions. However, as in the factory, it will tend toward efficiency and economy of effort if routine activities and subordinate details of motor operations are carried on automatically.

Incoming information arrives at various levels of the brain. To its rear entrance the spinal cord brings up from the body vast tracts of afferent nerves transmitting reports from the skin (exteroceptive), from internal surfaces such as that of the digestive epithelium (interoceptive), and from within the tissues of working parts such as muscles and joints (proprioceptive). The group of cranial nerves V, VII, IX, and X, entering at lateral portals of the medulla, contain afferent fibers of various sorts coming in from the head (both its skin and its internal surfaces) and (X) from the digestive and respiratory tracts within the trunk. Information concerning taste enters here (VII, IX, X). Also at the medulla arrive reports from the ear, exteroceptive via the cochlear trunk and proprioceptive via the vestibular trunk of the "auditory" nerve (VIII). Visual reports are received at the midbrain and, to greater or less extent, by the thalami. Consistent with the extreme anterior location of the olfactory receptors, the olfactory messages come in at the anterior extremity of the brain—in fact, the brain pushes forward more or less elongated olfactory lobes to receive them.

Each incoming tract of afferent fibers of a specific sort is received at an appropriate **primary sensory center** where the entering fibers come into relation with other neurons. These centers correspond, in a way, to the subordinate secretaries or receiving clerks at the factory. At the opposite or highest level of the controlling agencies of the brain are the nervous centers in the cerebral cortex. Between the primary centers and the ultimate cortical centers is an intricate maze of fiber-tracts and centers which collectively serve to establish the greatest possible number and variety of nervous pathways between the sensory receptors and the effectors (muscles and glands) of the body. The



primary olfactory centers in front are connected with more posterior sensory centers. The primary sensory centers of the rear parts of the brain are connected with one another by **association-tracts**. Numerous **correlation-centers** establish a great variety of relations between primary centers. Out of this maze of centers and tracts in the palaeencephalic part of the brain emerge great **projection-tracts** (Fig. 525) which pass up into the cerebral cortex. Centers in the thalami have been described as being especially important "way stations" on the road to the cortex. Within the cortex a complex system of association-tracts (Fig. 526) connects one region of the cortex with another. Finally, from the cortex come out tracts of **efferent** nerve-fibers transmitting impulses which are relayed eventually to the motor and glandular effectors.

It is in relation to these efferent tracts which pass downward and backward from the cerebral cortex that the cerebellum plays its important role. The connections of the cerebellum with the lower parts of the brain are very similar to those of the cerebral cortex. Tracts of fibers from all the sensory centers pass up into the cerebellar cortex, and descending efferent tracts connect with the numerous motor centers of the lower part of the brain. Also, and highly important, there are extensive connections between cerebral and cerebellar cortices.

The supreme governing body seated within the brain is the **cerebral cortex**. The cerebellar cortex is the executive department. The cerebral cortex "decides" what is to be done and when and how. The decision is based not merely on the information received at the moment but also on past experience. Sensory impressions are somehow—no one knows how—retained by cortical cells. The cortex becomes a library stored with records of the history of the animal's life. If the animal is one that can read a printed language, its cortical content becomes expanded to include the experiences of other lives and knowledge of things and events indefinitely remote in space and time. Action resulting from a stimulus may not be immediate. Time may be taken to "think it over," and in the course of the thinking the stored experience and knowledge are, or should be, taken into account. If the decision reached calls for muscular activity, the cerebral cortex (so far as we are aware) concerns itself with the action only in a large and general way, not with the details of the action of individual muscles. All of that is left to the "executive department." As the general orders go down the descending tracts from the cerebral cortex, "information" as to what is to be done is sent also to the cerebellum. The specified acts may involve the harmonious coöperation of scores of small muscles. All of this detailed work of coördination is automatically

attended to by the cerebellum. An important function of the cerebellum is to maintain a state of persistent but very slight contraction of the muscles—**muscle tonus**. This is apparently done by means of a continuous but very weak efferent nervous discharge. In the absence of the normal tonus, muscles become flabby and weak. Everything that the cerebellum does is of the nature of a reflex act in that it is "involuntary" on the part of the animal. The cerebellar activities do not, at least ordinarily, rise into consciousness. The cerebellum cannot modify behavior. It cannot do anything new or unusual. It is mechanically inexorable.

Just as in the factory office minor routine matters are handled by subordinate employees, so in the brain the lower centers execute responses of many sorts independently of the cerebral cortex. Even in a primary sensory center, an incoming stimulus may be transmitted more or less directly to efferent neurons which at once activate an effector. The animal may be conscious of it but the reflex act is involuntary. If a human finger receives an unexpected pin-prick, the hand is automatically jerked away from the pin. However, if the owner of the hand *expects* the prick and is sufficiently "strong-minded," he may hold out the hand and receive the prick without flinching. The rhythmic muscular contractions concerned in breathing take place automatically under control of reflex mechanisms in the medulla, but if a person chooses to do so he may, for a limited time, suspend breathing. The "choosing" brings the cerebral cortex into action. The cortex may delay or inhibit reflexes. The muscular activities involved in the more elaborate reflexes are coördinated by the cerebellar cortex.

A good illustration of the difference between cerebral and cerebellar control is afforded by the structures related to the duplex "auditory" nerve (VIII). As the orchestra plays, the discriminating organ of Corti, via the cochlear nerve, informs the hearer as to whether the music is the national anthem or a Strauss waltz. According to which it is, the hearer may either rise to his feet and stand still or he may begin to dance. In either case, the act as a whole, determined within the cerebral cortex, is voluntary and conscious. Meanwhile, the sensory cristae and maculas of the vestibular part of the ear (utricle and saccule) send, via the vestibular trunk, impulses which are relayed up into the cerebellum, but not to the cerebral cortex. On receipt of these proprioceptive stimuli, the cerebellum attends to all of the details of the muscular adjustments concerned in the changing of posture and maintaining of balance. But it is the cerebral cortex which decides what the changes of posture shall be, and the cerebellum must be "informed" of the decision in order that it may undertake coördination of the appropriate sets of muscles. The cerebellar cortex therefore

works under the combined "direction" of the cerebral cortex and the vestibular apparatus of the ear. But it does not initiate anything. However it may be determined, its action is involuntary and does not rise into consciousness.

The brain and spinal cord are directly connected with only somatic effectors, therefore controlling the striated muscles of the body-wall and appendages but not directly controlling the smooth muscles of the viscera, blood-vessels, and integumentary organs. These are under immediate control of the autonomic nervous system, whose working is involuntary.

The distinction between "old" and "new" brain must not be rigidly conceived. The cerebral cortex is not to be thought of as something "new" and important which has merely been added to an otherwise unaltered "old" brain. By itself the cortex can do nothing. It acquires importance only to the extent that it has nervous connections with other parts of the brain. It works through, or by means of, the reflex mechanisms. The establishing of these connections has necessitated development of numerous associating and correlating centers and tracts in various parts of the brain. However, these changes, numerous and important as they are, do not in themselves materially affect the external form and general anatomy of the "old" brain, nor do they result in any profound change in the nature of its functions so long as the functions are allowed to proceed without intervention of the cerebral cortex. "Allowed" is the significant word. An animal with an all-reflex brain is a mere robot. With a cerebral cortex superimposed on such a brain, the animal becomes a mechanism operated by a driver who knows where he is going and whose choice of a road is determined not merely by stimuli of the moment but by stored impressions of what is past and remote. But it must not be assumed that the fish with a non-nervous pallium is a robot. Even an earthworm can learn a little something by experience—at least, it can modify its reactions after repeated experiences—and unquestionably the most stupid fish possesses a little capacity for modifying its behavior. It must be conceded that the "old" brain of a teleost, with its non-nervous pallium, admits of a little flexibility in behavior. Therefore the cerebral cortex adds nothing of a new kind. What is "new" is that the primitive nervously inert (presumably) pallium was taken over as a site for the slow evolution of a complex structure through which an originally feeble or latent capacity of the brain has been elaborated and exalted into a dominant agency. Acquisition of nervous function makes it a "new" pallium.

The **cerebellar cortex** is "new" in so far as it has been developed

in conjunction with the cerebral cortex, and perhaps the same should be said of some higher centers in the thalami. Therefore the *neöencephalon* may be conceived as consisting of not only the cortex-bearing pallium but also the cerebellar and thalamic structures which are most directly concerned with it. Even the ventral **pons**, which consists mainly of fiber-tracts extending between cerebral and cerebellar cortices, can be regarded as "new." In fact, between "old" and "new" brains no sharp demarcation can be recognized, either structurally or functionally.

The **lower parts of the brain**—i.e., the regions exclusive of pallium and cerebellum—appear as a more or less modified forward continuation of the spinal cord, and consisting, within themselves, mainly of reflex mechanisms, they resemble the cord functionally. They are often referred to as constituting collectively the "**brain-stem**" (Fig. 528), while the nervous structures of the pallium and the cerebellum, superimposed upon the brain-stem, constitute a "**super-brain**." The brain has a certain transverse segmentation of its own, and the cranial nerves, exclusive of I and II, have such similarities to the segmentally arranged spinal nerves as to make it possible to interpret them as "modified spinal nerves." Therefore the brain-stem is sometimes called the "**segmental brain**" and the pallial structures and cerebellum are then "**suprasegmental**" structures.

Reptiles, in relation to birds and mammals, stand—or once stood—at the parting of the ways in more respects than one. Birds adopted aerial life; mammals remained primarily and mostly terrestrial. Their common reptilian ancestors must have made at least a good beginning at elaborating a pallial cortex. Birds did not, to any important extent if at all, go on with it. Instead, they developed the mechanism of the **palaeöencephalon** with the **corpora striata** as the especially important seat of complex nervous centers of the "old" type. Elaborate as this mechanism came to be, it acquired nothing of the flexibility which characterizes the action of a pallial cortex. The cerebellum is highly developed, as it must be to coördinate the highly complex muscular activities of the bird, but the cerebellum, both in bird and mammal, is as rigidly automatic as any simple reflex center. Therefore birds have only a relatively low degree of modifiability of behavior. Their lives, dominated by instinct, resemble those of fishes and insects. Reverting to the factory-and-office analogy, in the case of birds it is an old and established business which has settled down into deeply worn ruts and is carried on automatically by subordinates supervised by habit-bound executives, with little constructive and progressive direction by any higher officials and with small capacity for meeting emer-

gencies. Mammals took the other road and elaborated the "super-brain" to a degree which has given them the advantage over all other animals.

Statements to the effect that large brains, or brains containing large quantities of "gray matter," or brains having a "richly convoluted" cortex are indicative of a high degree of intelligence may carry unwarranted implications. Protoplasm can secrete substance and it can throw off energy in doing mechanical work or as heat, electricity, or light. Intelligence is not a substance, nor is it a physical force or form of energy. The relation of intelligence to protoplasm is the centuries-old and unsolved problem of the "relation of mind to matter." It is certain, however, that the existence of intelligence is not dependent on mere size of a mass of cells or mere quantity of any particular kind of nervous material. As a matter of fact, so far as quantity of substance is concerned, "white" is just as important as "gray" nervous substance because every "white" fiber is the product of a "gray" cell with which it is permanently connected. Nor can intelligence result from mere increase in number of neurons. No reason appears why 1000 cells should be more intelligent than 10 cells. They might all be somehow connected together but, even so, and supposing that they are connected in some systematic way, there still appears to be no reason why the group should be any more intelligent than a group of electric batteries and wires connected in some systematic way. Emphasis has been laid on the extraordinary complexity of the relations of neurons in the brain. There may, however, be great complexity with little intelligence. Birds have relatively large brains, and the much-enlarged corpora striata are occupied by nervous mechanisms of the extreme complexity necessary for execution of the bird's highly elaborate instinctive behavior. In this case a high degree of complexity is accompanied by very inferior intelligence. It is conceivable that a brain of this instinctive type might be relatively larger than that of an animal whose behavior, although of a simpler sort, shows some degree of intelligence. Granting the extreme of complexity, it does not appear how intelligence must result from mere complexity. On the other hand, it does appear that complexity of nervous mechanism is essential if intelligence is to control the complex activities of the animal. *Complexity cannot create intelligence, but the operation of intelligence requires complexity.*

Among mammals in all of which the neëncephalon is more or less dominant, in contrast to birds in which the palaeëncephalon dominates, relative size of brain, bulk of "gray matter," convolutions, number of neurons and complexity of their relations, and—especially

important—the capacity for retaining nervous impressions, are all more or less directly related to degree of intelligence, but they are merely the necessary accompaniments of intelligence, not (either singly or collectively) the source of it. Intelligence and the neñcephalic mechanism adequate for its operation always go together, but how they have come to be thus associated is beyond present knowledge.

**Consciousness** is something broader than intelligence. A person of low intelligence may be keenly aware of his inferiority, and we are all conscious of many of our unintelligent reflex and instinctive acts. We are confident that our fellow human beings are conscious because they act as if they were and they say they are. Other animals may act as if they were but they cannot tell us about it. We cannot absolutely prove that they are conscious. Granting that birds are dominated by the “old” brain, we nevertheless feel quite sure that they are aware of what they do instinctively. In fact, even a teleost fish, totally devoid of pallial nervous structures, acts as if it were conscious. While there are strong reasons for regarding the cerebral cortex as the seat of intelligence, it seems “as good as certain” that vertebrates without the cortex are conscious, even if only feebly intelligent.

The “seat” of consciousness is highly problematic. We feel that it is in the head. We are conscious of our feet but it seems to be via the head that we are aware of them. In man and other mammals the cerebral cortex (as shown by clinical and other evidence) is somehow especially concerned with consciousness, as would be expected if the cortex is the seat of intelligence. There is evidence, however, that sensations of pain and pleasure may emerge into consciousness via the thalami. All things considered, it is likely that consciousness is not necessarily associated with or limited to any sharply defined region of the brain. Our consciousness of ourselves seems somehow to include the whole body at once. Instead of thinking of consciousness as produced in or emanating from a limited part of the brain, it seems easier to think of it as associated with the entire brain, or possibly coextensive with the whole nervous system, even to the tips of the twigs of all its peripheral nerves, for the whole is a physiologically continuous system of protoplasmic nervous elements. The word “protoplasmic” in the foregoing sentence suggests further possibilities. Specialized cells merely emphasize one or another of the several potencies which inhere in all protoplasm. If consciousness is associated with nerve-cells, then it may be, in lower degree or in some indefinable vague or dim way, associated with *all* cells and therefore coexistent with all the living substance of the body. If this should be the truth, then we can imagine that the whole conscious field of the animal is somehow “polarized” or brought to a “focus” at the region where the nervous tissue is most

highly specialized, which might be in the corpus striatum of birds or the pallial cortex of mammals. All of this is purely speculative, but study of the vertebrate brain cannot fail to give rise to questions of this sort for which, at present, nothing better than speculative answers can be offered. The attempt of the conscious mind to understand itself resembles the effort of the rotating kitten to make its head go faster than the tip of its short tail. In both cases there is much whirling in circles. But either is a healthful exercise and affords some satisfaction so long as the pursuer of the truth or the tail is not distressed by the futility of his effort. In many of life's enterprises, there is more joy in pursuit than in possession.





---

In an earlier chapter it was pointed out (p. 381) that some characteristics of animals undergo adaptive evolutionary change much more readily than do others. For recognition of the more remote genetic relationships, chief reliance must be placed on "conservative" characteristics. Methods of reproduction are conservative. Most terrestrial amphibians, even to their disadvantage, retain the reproductive method of their aquatic ancestors. Aquatic reptiles are anatomically well adapted to aquatic living, but their eggs require a land-and-air environment. Judging modern mammals on the basis of reproduction, the Class at once cleaves sharply into three divisions, usually ranked as subclasses. The general comparative anatomy of mammals justifies, so far as could be expected, this tripartite division on the basis of reproduction.

In the great majority of mammals, **PLACENTALIA**, the minute eggs undergo prolonged intrauterine development, the physiologic necessities of embryo and fetus being provided by the placenta. In a much smaller division of mammals, **MARSUPIALIA**, the eggs, usually somewhat larger than those of placental mammals, develop for a relatively short time in the uterus and ordinarily without formation of a placenta (in a few cases a very weak placenta occurs: see p. 294), and, after birth, the fetus is retained for a long period in an abdominal integumentary pouch, the marsupium, within which are the mammary glands. Two existing genera of mammals are not included in either of these divisions. These are **Ornithorhynchus** and **Echidna** (**MONOTREMATA**), whose reproduction is essentially reptilian. Large eggs, containing much yolk and enclosed in shells, are "laid" and incubated externally. After hatching, the young obtain milk produced by mammary glands of primitive structure and devoid of nipples. This feeding after birth is the only mammalian feature of reproduction in these animals.

## SUBCLASS I. MONOTREMATA

The monotremes resemble reptiles in many anatomic features—the persistent cloaca; the completely separate oviducts with no differentiated vaginal regions, opening independently into the cloaca; ureters opening into the cloaca instead of directly into the bladder; the incompletely closed urethral groove of the cloacal penis; the pectoral girdle with a strongly developed coracoid bone; a distinct episternum (or interclavicle, a dermal bone) projecting forward from the sternum; the pair of epipubic (“marsupial”) bones; the columella-like form of the stapes; the brain without a corpus callosum. Also, they are imperfectly homothermous, the temperature of the body being lower than in other mammals and varying somewhat with the external temperature.

The question has been raised as to whether *Archaeopteryx* was a feathered reptile or a reptilian bird. A similar question may be raised about monotremes—are they reptiles with hair and mammary glands, or are they very reptilian mammals? In the case of *Archaeopteryx*, it was considered that feathers make it a bird, and so, in the case of monotremes, more weight must be given to the possession of new and definitely mammalian features than to mere retention of reptilian features.

**Ornithorhynchus** (Fig. 532), about as large as a common cat, has a stout body, a rather short and dorsoventrally flattened tail, and a small head with small laterally directed eyes and no auditory pinnae. (This absence of pinnae is not necessarily a primitive reptilian feature.




FIG. 532. *Ornithorhynchus*. (Courtesy, Vogt and Specht: "Die Säugetiere in Wort und Bild," Munich, F. Bruckmann-Verlag.)

Pinnæ may have degenerated in connection with acquisition of burrowing and aquatic habits.) The jaws, especially the upper, are prolonged forward to form a broad dorsoventrally flattened beak covered with smooth hairless skin—hence the animal's common name, "duck-bill." The legs are very short and each has five digits. A strong claw on each digit and webs of skin between digits doubly adapt them for burrowing and swimming. The brown fur is short and thick. Situated ventrally about midway of the length of the body is a pair of hairless and slightly depressed spots of skin. On the surface of each spot open the several ducts of a cluster of tubular mammary glands. The young animal merely licks off the milk as it exudes from the pores.

The duckbill is semiaquatic. It burrows into the bank of a stream or pond. The entrance to the burrow is under water, but the inner end, several yards distant, is high and dry. It feeds on small aquatic animals. In the absence of calcareous teeth (temporarily present in the embryo), horny plates covering both the upper and the lower jaw serve for crushing hard-shelled prey.

**Echidna**, of about the same size as the duckbill, differs from it in many respects (Fig. 533). The tail is a mere vestige. The "beak" is narrow and sharp-pointed. Teeth are totally lacking. The digits, five on each foot, are not webbed and the claws are very strongly developed. Dorsally and laterally, the animal bristles with long stiff spines (modified hairs) resembling those of a porcupine. Between the spines are ordinary coarse hairs, and ventrally there is merely coarse hair. As in



FIG. 533. *Echidna*. (Courtesy, Vogt and Specht: "Die Säugetiere in Wort und Bild," Munich, F. Bruckmann-Verlag.)

the duckbill, there are no auditory pinnae or, at most (in one species), only very poorly developed pinnae. The mammary organs resemble those of the duckbill except in that each mammary area is depressed to form a shallow pocket at whose bottom open the milk-ducts. A few long hairs project from the pocket, possibly serving to guide the exuding milk into the mouth of the young animal, whose beak is inserted into the pocket. During the period of rearing young, a fold of abdominal skin in the vicinity of the mammary pockets forms a temporary marsupium in which the egg is incubated and the young retained for a time after hatching. The brain is better developed than that of the duckbill. It is relatively larger and its cerebral cortex is well convoluted, in contrast to the quite smooth cortex of the duckbill.

*Echidna* avoids water and eats ants, having the long sticky tongue characteristic of anteaters. The strong claws are used for digging into anthills and excavating deep burrows.

#### SUBCLASS II. MARSUPIALIA

The marsupials are intermediate between monotremes and placentals in some respects—size of egg and duration of the period of intrauterine development; retention of merely the shallow ectodermal region of the embryonic cloaca; a vaginal region differentiated in each oviduct but the two vaginas not fused into a single median vagina; presence (in at least some marsupials) of an extensive cartilaginous coracoid in the embryo, although only its proximal end persists and ossifies to form the ventral coracoid process of the scapula. In some features they resemble monotremes—presence of epipubic bones; absence of corpus callosum. In many features they are like placentals—ureters opening directly into the bladder; complete enclosing of the cloacal urethral groove to form the urethral canal of the penis; absence of episternum (interclavicle); mammary glands with well-developed nipples. Their most unique characteristic is the **marsupium**. Whether the temporary egg-pouch of *Echidna* is homologous with this marsupium is doubtful, and in placentals there are, at most, only some possible embryonic vestiges of the marsupium. However, just as there are some "vertebrates" without a vertebral column, so there are a few marsupials with no marsupium.

#### SUBCLASS III. PLACENTALIA

The highly developed **placenta** is the preëminent anatomic characteristic of placental mammals. Otherwise, they are characterized by complete **absence of the marsupium** (except for possible embryonic vestiges) and of the epipubic bones; by **reduction of the coracoid**

to a small rudiment, which may be separate from the scapula but more commonly is fused to it; and by presence of the **corpus callosum** as an important adjunct of the highly developed cerebral cortex.

These three main divisions of Mammalia have been much over-named. One set of names refers to presence or absence of the cloaca. An animal with a cloaca has only one posterior external aperture—hence the name **Monotremata** (Greek *trema*, a hole). In the absence of a cloaca, there are two external apertures, anal and urinogenital. To marsupials and placentals collectively has been applied the name **Ditremata**, but inaccurately because it ignores the existence of the shallow ectodermal cloaca. Another set of names refers to the condition of the oviducts. The differentiation and relations of these ducts in monotremes are essentially the same as in reptiles and birds. This fact, along with the curiously birdlike beak of monotremes and the webbed feet of the duckbill, occasioned the name **Ornithodelphia** (Greek *delphus*, uterus), formerly applied to the monotremes. In marsupials the two oviducts remain completely double; hence the group is called **Didelphia**. In placental mammals there is more or less extensive longitudinal union of the two ducts to form median chambers, culminating in the uterus simplex (Fig. 490). Placentals are therefore **Monodelphia**. Still another set of names is one referring to the evolutionary sequence of the groups. The names are compounded from the following Greek words: *therion*, beast; *protos*, first; *meta*, after or between; *eu*, good. The monotremes are **Prototheria**, the marsupials are **Metatheria**, and placentals—the really “good beasts”—are **Eutheria**. In some schemes the term **Theria** appears as a sort of “super-subclass” comprising Metatheria and Eutheria. (In one scheme, Eutheria appears as a subclass comprising two “Divisions,” Didelphia and Monodelphia.)

The unfortunate avian implication of “Ornithodelphia” compels discard of the “-delphia” series of names. The terms “Marsupialia” and “Placentalia” merit preference because they refer to the especially distinctive anatomic characteristic of their respective groups. The usual synonymy of the several names is summarized below.

MONOTREMATA.....	PROTOTHERIA.....	ORNITHODELPHIA
DITREMATA.....	THERIA	
MARSUPIALIA.....	METATHERIA.....	DIDELPHIA
PLACENTALIA.....	EUTHERIA.....	MONODELPHIA

Following is an outline of the main divisions of a classification of modern mammals. The many classifications which have been made

differ greatly even in the arrangement of the three main divisions of the Class. For example, "Monotremata" has been counted as an Order under Subclass Prototheria, and "Marsupialia" as an Order under Subclass Metatheria. Or "Ditremata" may be listed as a Subclass under which Marsupialia and Placentalia appear as "Grades." The subdivisions of Marsupialia and Placentalia are, on the whole, fairly well stabilized. There is, however, some difference of opinion as to the treatment of certain groups, especially the large and highly diversified group of ungulates and the motley collection of animals formerly herded together under "Edentata." The orders of one classification may appear as suborders in another.

The type of differentiation of the **teeth** and the specialization of the **locomotor appendages** are especially important as distinctive characteristics, reflecting, as they must, the animal's diet, habitat, and general mode of living. The number of teeth of each kind in the heterodont dentition of a mammal is conveniently indicated by a "dental formula," which is written in the form of a series of fractions, each numerator being the number of teeth of a particular kind in the upper jaw, and the denominator the number of corresponding teeth in the lower jaw. The formula represents only one side of the jaws. The kinds of teeth may be indicated by "i" (incisors), "c" (canines), "p" (premolars), and "m" (molars). Premolars are teeth of the molar type and are preceded by temporary "milk-molars"; molars are posterior to the premolars and have no predecessors in the first dentition. All teeth of the molar type (premolars and molars) are designated as "cheek-teeth." The total number of teeth in the dentition is double the sum of all the numbers in the formula. E.g., the formula for the permanent dentition of the cat is

$$2 \left( i \frac{3}{3}, c \frac{1}{1}, p \frac{3}{2}, m \frac{1}{1} \right) = 30$$

Some of the more typical or better-known members of each group are mentioned. *The statements about geographic distribution refer to existing mammals only.* The term "world-wide" is conveniently used to indicate extensive distribution in both Eastern and Western Hemispheres, but with such limitations as may be imposed by climatic or other conditions. The statement that occurrence of Carnivora is "world-wide" does not mean that lions are found at the North Pole. Not all species of a group are to be found in every region of the territory specified as its area of distribution. The territory includes all regions in which the group is represented, even if by only a single species.



FIG. 534. Virginia opossum, *Didelphis virginiana* Kerr. (Courtesy, American Museum of Natural History, New York.)




FIG. 535. Australian "cat" or dasyure, *Dasyurus maculatus*. (Courtesy, American Museum of Natural History, New York.)




FIG. 536. Tasmanian wolf, *Thylacinus*. (Courtesy, American Museum of Natural History, New York.)




FIG. 537. Bandicoot, *Perameles*. (Courtesy, American Museum of Natural History, New York.)






FIG. 538. *Caenolestes*, a Bolivian marsupial. (Courtesy, American Museum of Natural History, New York.)

## Class Mammalia

### SUBCLASS I. MONOTREMATA

Only two existing FAMILIES:

ORNITHORHYNCHIDAE, containing the one Genus, **Ornithorhynchus**, the duckbill.

ECHIDNIDAE, including two or three species of **Echidna**, the spiny anteater. Some classifications recognize two **Genera: Echidna** (or **Tachyglossus**) and **Proechidna** (or **Zaglossus**).

Monotremes occur only in Australia, Tasmania, and New Guinea.

### SUBCLASS II. MARSUPIALIA

**Order 1: POLYPROTODONTIA.** Dentition of carnivorous type—many small incisors (four or five pairs in upper jaw, fewer in lower) of nearly equal size; large canines; sharp-pointed molars.

**Examples:** **Opossum** (**Didelphis**) whose dental formula is  $i \frac{5}{1}, c \frac{1}{1}, p \frac{3}{3}, m \frac{4}{1}$ ; **dasyure**, the "Australian cat" (**Dasyurus**); the "Tasmanian wolf" (**Thylacinus**); the burrowing **bandicoot** (**Perameles**); and "marsupial mole" (**Notoryctes**): (Figs. 534–537, 592).

**Order 2: CAENOLESTOIDEA.** Dentition numerically resembles that of polyprotodonts, but, in type of differentiation, more like that of diprotodonts. Small, rodent-like **Caenolestes** (Fig. 538).



FIG. 539. Wallaby, one of the kangaroo family (Macropodidae). (Courtesy, American Museum of Natural History, New York.)




FIG. 540. Wombat, *Phascolomys*. (Courtesy, Flower and Lydekker: "Introduction to the Study of Mammals," London, A. & C. Black, Ltd.)

**Order 3: DIPROTODONTIA.** Dentition of herbivorous type—usually two and never more than three pairs of chisel-like incisors in upper jaw and one pair in lower, the middle pairs being very strongly developed; canines small or lacking; molars of crushing type, sometimes ridged.

**Examples:** Kangaroos and the smaller kangaroo-like wallabies (FAMILY MACROPODIDAE); dental formula for kangaroo (**Macropus**),  $i \frac{3}{1}, c \frac{1}{0}, p \frac{2}{2}, m \frac{4}{1}$ ; the wombat (**Phascalomys**); phalangers and the bearlike koala (PHALANGERIDAE) mainly arboreal: (Figs. 539-542).

**Distribution.** Marsupials are found in Australia, Tasmania, New Guinea, and some other islands of that region, but not in New Zealand, and nowhere else except that the opossums (DIDELPHIDAE) occur in South America and southeastern North America, and the small, obscure, rodent-like **Caenolestes** is found in South America.



FIG. 541 (Left). Phalanger or Australian opossum. (Courtesy, American Museum of Natural History, New York.)

FIG. 542 (Right). Koala, *Phascolaretos cinereus*. (Courtesy, American Museum of Natural History, New York.)

## SUBCLASS III. PLACENTALIA

**Order 4: INSECTIVORA.** Small, including the smallest of mammals. Notably lacking in highly specialized characteristics except in some arboreal or burrowing species. Dentition complete, but teeth of the several types not strongly differentiated from one another; mainly insect-feeding. Usually five digits on each foot; digits bear claws; locomotion plantigrade. Uterus bicornis. Cerebral cortex smooth.

**Examples:** Shrew (*Sorex*); tree shrew (*Tupaia*); mole (*Talpa*); hedgehog (*Erinaceus*), with a protective coat of sharp spines resembling those of the porcupine, a rodent: (Figs. 543-545).

**Distribution:** Both Eastern and Western Hemispheres, but not in South America and not in Australia, New Zealand, and adjacent islands. The hedgehogs occur only in the Eastern Hemisphere.

**Order 5: DERMOPTERA.** Arboreal mammals having, on each side of the body, a broad fold of skin extending from the neck to the forelimb, from fore- to hindlimb, and behind hindlimb to tail (Fig. 546). The feet, with digits webbed, project freely beyond the edge of the fold. By spreading the "flying" membranes, the animal is enabled to make long sailing leaps. The brain is of primitive type. In general anatomy these animals resemble insectivores and also the more primitive primates (lemurs).

This Order contains only the "flying lemur," or colugo, *Galeopithecus*, of the East Indies.

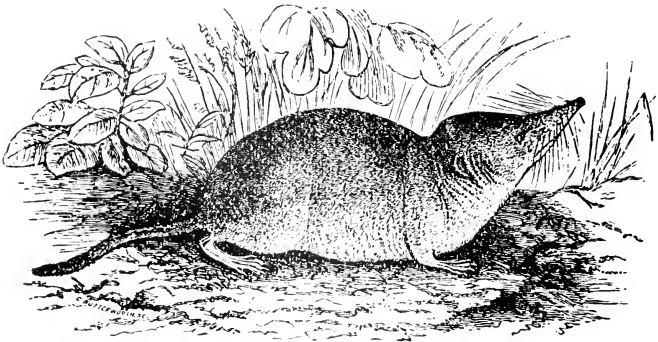


FIG. 543. Common shrew, *Sorex vulgaris*. (Courtesy, Flower and Lydekker: "Introduction to the Study of Mammals," London, A. & C. Black, Ltd.)




FIG. 544. The golden mole, *Chrysochloris obusirostris*. (Courtesy, Flower and Lydeker: "Introduction to the Study of Mammals," London, A. & C. Black, Ltd.)



FIG. 545. European hedgehog, *Erinaceus*. (Courtesy, American Museum of Natural History, New York.)

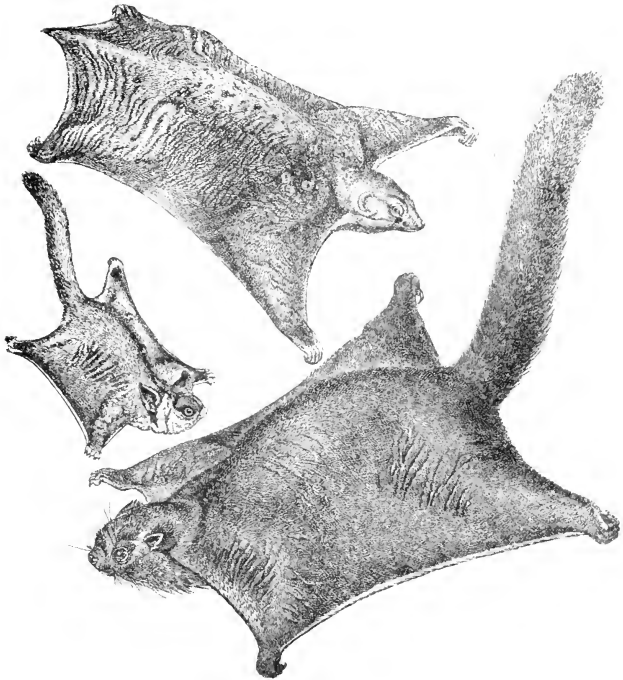


FIG. 516. (Top) "Flying lemur" (Dermoptera: *Galeopithecus*). (Center and bottom) Flying squirrels (rodents). (Courtesy, American Museum of Natural History, New York.)




FIG. 517. Bat, *Synotis*. (Courtesy, Vogt and Specht: "Die Säugetiere in Wort und Bild," Munich, F. Bruckmann-Verlag.)

**Order 6: CHIROPTERA.** Flying mammals. The **wing** (Fig. 517) is a web of skin supported largely by the forelimb, extending back along the side of the body to the hindlimb, and continued behind the hindlimbs as the **interfemoral membrane**, which may or may not include the tail. All parts of the skeleton of the forelimb are much elongated except the hallux, which is not involved in the wing. The four digits posterior to the hallux support a large area of the wing. The hallux always bears a sharp claw. The pes projects freely beyond the edge of the wing and each of its five digits bears a sharp claw. Tail may be long, short, or lacking. Low **keel on sternum** (see p. 518). Dentition complete and not highly specialized. Cerebral cortex not convoluted.

Two Suborders are recognized:

**Suborder MEGACHIROPTERA.** Large frugivorous bats. Claw on second digit of manus, as well as on the hallux; tail, if present, not enclosed in interfemoral membrane.

These are the "**fruit bats**" or "**flying foxes**" (**Pteropus**) of the warmer parts of the Eastern Hemisphere.

**Suborder MICROCHIROPTERA.** Small bats, chiefly insectivorous, but the South American **vampire** bites mammals and sucks their blood. No claw on second digit of manus. Tail, if present, enclosed in interfemoral membrane.

Numerous species of bats. Distribution world-wide.

**Order 7: RODENTIA.** Mostly small, chiefly herbivorous. Teeth specialized for gnawing hard substances: incisors, one pair in upper jaw, one pair in lower, long and chisel-like, their enamel usually thick only on the front surface of the crown, thin or lacking elsewhere, thus ensuring maintenance of a sharp cutting edge; no canines; wide gap (**diastema**) between incisors and cheek-teeth, the latter being flat-topped and adapted for crushing and grinding.

The articulating surface (**glenoid**) on which the lower jaw works is usually elongated anteroposteriorly, allowing the lower jaw to be moved backward and forward. When in its posterior position, the upper and lower cheek-teeth meet, but the incisors do not, the lower passing up behind the upper (Fig. 518). When the incisors are to be used for gnawing, the lower jaw must be moved forward so that the edges of upper and lower incisors meet exactly—meanwhile upper and lower cheek-teeth do not meet. The animal cannot gnaw and chew at the same time. There is more or less transverse motion of the lower jaw when the cheek-teeth are being used for grinding.

Locomotion is usually plantigrade. In the manus the pollex may be reduced or absent, and in the pes there may be even more reduction in

number of digits. The digits bear claws, in some cases so blunt as to resemble small hoofs.

**Examples:** Mouse, rat (*Mus*); squirrel (*Sciurus*—dental formula,  $i \frac{1}{1}$ ,  $c \frac{0}{0}$ ,  $p \frac{2}{1}$ ,  $m \frac{3}{3}$ ), gopher, woodchuck, beaver (*Castor*), guinea pig (*Cavia*), chinchilla, porcupine whose spines resemble those of the hedgehog (an insectivore). The largest living rodent is the South American **capybara**, semiaquatic, about 4 feet long, resembling a gigantic guinea pig: (Figs. 546, 549, 550).

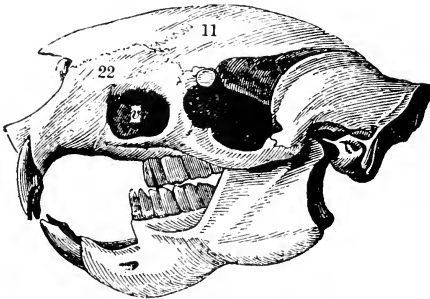


FIG. 548. Skull of the porcupine. (v) Antorbital vacuity; (11) frontal; (22) premaxillary. Notice the relatively great size of the premaxillaries, which carry the incisor teeth. (Courtesy, Owen: "Comparative Anatomy and Physiology of Vertebrates," London, Longmans, Green & Co., Ltd.)

The Order Rodentia includes more living species than any other mammalian order, some estimates of the number approaching 3000. Mostly terrestrial, some are burrowing, some arboreal, a few are aquatic or semiaquatic, and "flying squirrels" sail by spreading out a pair of broad folds of skin extending between fore- and hindlegs.

**Distribution:** World-wide; especially numerous in South America, relatively few in Australia and Madagascar. Rabbits are now abundant in Australia but are not native there, having been introduced by man.

**Order 8: LAGOMORPHA.** Two pairs of upper incisors, those of the more lateral pair being very small; one pair of lower incisors. Tail vestigial. Dental formula for rabbit,  $i \frac{2}{1}$ ,  $c \frac{0}{0}$ ,  $p \frac{3}{2}$ ,  $m \frac{3}{3}$ . This Order includes only the **rabbit**, **hare**, and **pika** (Fig. 551).

Older classifications usually include the lagomorphs as a **Suborder**





FIG. 549. African porcupine, *Hystrix cristata*. (Courtesy, American Museum of Natural History, New York.)




FIG. 550. Capybara, *Hydrochoerus capybara*. (Courtesy, Vogt and Specht: "Die Säugetiere in Wort und Bild," Munich, F. Bruckmann-Verlag.)




FIG. 551. Pika or cony, *Ocholona saxatilis*. (Courtesy, American Museum of Natural History, New York.)

DUPLICIDENTATA under **RODENTIA**. A **Suborder SIMPLICIDENTATA** then includes all other rodents.

**Distribution:** Eastern and Western Hemispheres, mainly northern; not native to Australia and Madagascar.

Under the old name "**Edentata**," meaning "toothless," were formerly included a small number of mammals whose claim to inclusion in the so-called "Order" rested more on some superficial resemblances than on positive evidence of close genetic relationship—and these "edentates" were not all toothless. The following three Orders contain these animals, most of them in Xenarthra.

**Order 9: XENARTHRA.** The Order takes its name from a peculiarity of the articulation between successive vertebrae in the posterior thoracic and lumbar region. The usual articulating processes, a pair of **postzygapophyses** on one vertebra articulating with a pair of **prezygapophyses** on the vertebra next behind it, are present but are supplemented by pairs of accessory articulating processes—a condition not known to occur in any other mammals, but found in some reptiles.

Other characteristics of the Order are as follows: Sacral region elongated and strengthened by articulation of ischia with several of the more anterior caudal vertebrae. Dentition never complete: no incisors, and no canines unless in some cases they are represented by the most anterior cheek-teeth; small "peglike" cheek-teeth varying from 4 to 10, but in some species 20 or 25, in each half-jaw; adult teeth lack enamel; rapid wear compensated by persistent growth of dentine

(see p. 46). Teeth entirely lacking in adults of some members of Order. Claws usually very long, curved, and strongly developed. Brain of primitive type.

The Order includes the **tree sloths**, South American **anteaters**, and the **armadillos**.

Modern **sloths** are arboreal, but their arboreal habits are unique. Most arboreal mammals are especially nimble—e.g., squirrels and monkeys. The sloths (Fig. 552), ranging in size from that of a small cat up to four or five times the bulk of a cat, are short in the body and long in the legs. Hooking the strongly curved claws of its long digits over the branch, the animal suspends itself beneath it and, in this upside-down attitude, clambers about slowly and clumsily amid the foliage which is its food. On the ground it is capable of only an awkward crawling gait. The hair is long, coarse, and gray, but becomes more or less infested by an alga which gives it a greenish tint which may have some protective significance. The teeth consist of four or five cheek-teeth (the most anterior possibly canine) in each half-jaw. The **three-toed sloth** (*Bradypus*) has nine cervical vertebrae; the **two-toed sloth** (*Choloepus*) has only six cervicals.

The **anteaters** (or **antbears**; Fig. 553) are hairy, some of them quite long-haired, especially as to the tail. They have the usual adaptations for their peculiar diet—long narrow snout, long sticky tongue, and forefeet equipped for digging out ants or, more commonly, termites. The adults are literally "edentate." Best known are the "**great anteater**" (*Myrmecophaga*), whose length from tip of snout to tip of tail may be 7 feet, and the "**lesser anteater**" (*Tamandua*). Some of the smaller anteaters are arboreal and the long tail is prehensile.

The **armadillo** (*Dasypus* and other genera; Fig. 554) simulates a reptile in its armor of heavy dermal bony plates overlaid by horny scales, but stiff coarse hairs projecting between scales betray the mammal. The plates in the region of the trunk are usually small and squarish and arranged in transverse bands whose number varies among the several species. Large plates may occur dorsally in the regions of the shoulder and sacrum. Check-teeth are numerous—usually 8 to 10 in each half-jaw, but in the **giant armadillo** (*Priodontes*) the number may reach 25, thus greatly exceeding the usual number in placental mammals.

Armadillos range in size from that of a rat to a length, including tail, of 4 or 5 feet. They are burrowing and nocturnal in habit, chiefly insectivorous or sometimes carnivorous, and not averse to eating long-dead carcasses.

In at least some armadillos there is an extraordinary feature of reproduction. The animal usually bears four young at a time, which

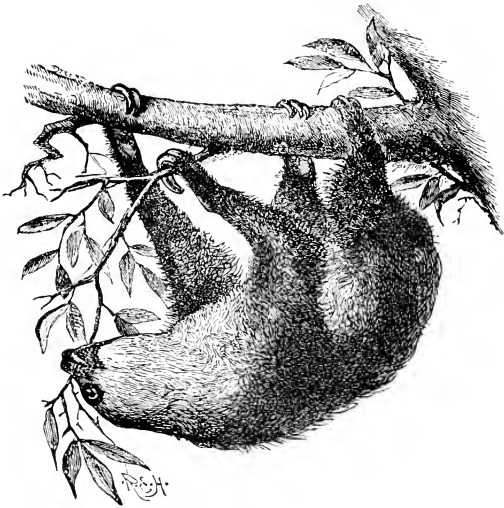

FIG. 552. Two-toed sloth, *Choloepus hoffmanni*. (Two toes in manus, three in pes.) (Courtesy, Flower and Lydekker: "Introduction to the Study of Mammals." London, A. & C. Black, Ltd.)



FIG. 553. Lesser anteater, *Tamandua tetradactyla*. (Courtesy, American Museum of Natural History, New York.)




FIG. 554. Armadillo. (Courtesy, Museum of Comparative Zoology, Harvard University.)

are all of the same sex and are otherwise "identical" quadruplets, all four being derived from a single fertilized egg which, at an early stage of development, forms four embryos instead of the usual one.

Modern xenarthrans are confined to South and Central America, except that one species of armadillo, the "**nine-banded armadillo**" (*Dasyus novemcinctus*), ranges north into southern Texas.

**Order 10: PHOLIDOTA.** This Order (name from the Greek *pholis*, scale) contains only the **scaly anteaters** or **pangolins** (FAMILY MANIDAE) of Asia and Africa (Fig. 555). Externally they resemble armadillos. The animal has a complete armor of large, overlapping, horny scales, but, in contrast to the armadillo, there are no underlying bony plates. Between scales are coarse stiff hairs (reduced or absent in some large or old animals). The hindfeet are plantigrade, but the digits of the manus are so strongly curved downward and backward that, in walking, it is their dorsal surfaces that bear upon the ground. The adults are toothless. Snout, jaws, and tongue are elongated, as is usual in anteaters.

Most pangolins are ground-dwellers, but some of the smaller ones are arboreal, the long slim tail being prehensile. The "**giant pangolin**" attains a length, including tail, of 5 or 6 feet. The chief food of pangolins is termites. They are commonly included in a single Genus, **Manis**, but some classifications recognize several Genera.

**Order 11: TUBULIDENTATA.** The one Genus constituting this Order is **Orycteropus**, the South African **aardvark** (Dutch, meaning "earth pig") or **Cape anteater** (Fig. 556). The animal is about as large as a hog. Its external appearance gives a general impression of inefficiency—ungainly body, stout legs, thick tail, small head with long, mulish ears. The moderately long, narrow snout, small mouth, and long tongue indicate the diet, chiefly termites. The animal is sparsely covered with short, coarse hair. The digits, four on the manus




FIG. 555. The African white-bellied pangolin, *Manis tricuspis*. (Courtesy, Flower and Lydekker: "Introduction to the Study of Mammals," London, A. & C. Black, Ltd.)



FIG. 556. Aardvark or earth hog, *Oryzomys*. (Courtesy, American Museum of Natural History, New York.)

and five on the pes, bear heavy blunt claws, but the plantigrade feet are not highly specialized for digging. It is described, however, as burrowing and nocturnal in habit.

The name of the Order refers to a peculiarity of the teeth. The dentition consists of four or five cylindrical cheek-teeth in each half-jaw. They lack enamel. The dentine of the crown of the tooth consists of numerous tubular columns extending parallel to the axis of the tooth and each traversed by a canal which connects with a common pulp-cavity in the base of the tooth.

**Order 12: CARNIVORA.** Aside from the teeth, most of these mammals are devoid of peculiarly specialized anatomic features. They are mainly, but not exclusively, flesh eaters. Dentition complete and strongly heterodont (Figs. 436, 465); incisors small, sharp-edged; canines long, conical, sharp-pointed, in some cases exaggerated into tusks (e.g., walrus and extinct "saber-tooth" tiger); cheek-teeth shaped for cutting, each bearing several cusps with sharp edges and points. Dental formula for dog,  $i \frac{3}{3}, c \frac{1}{1}, p \frac{4}{4}, m \frac{2}{3}$ . Digits usually five, never fewer than four, bearing sharp claws which may be retractile (as in the cat). Stomach simple. Brain well developed; the cerebral hemispheres strongly convoluted.

The great majority of carnivores are terrestrial, but a few have become highly adapted to aquatic life. Hence the two Suborders:

**Suborder FISSIPEDIA (CARNIVORA VERA).** Terrestrial or, in a few cases (e.g., otters), semiaquatic. Seven FAMILIES are recognized:

CANIDAE: **Dog (Canis), wolf, fox.**

PROCYONIDAE: **Raccoon (Procyon),** South American **kinkajou,** Asiatic **panda** (Fig. 557).

URSIDAE: **Bears (Ursus).**

MUSTELIDAE: **Weasel, ermine, ferret, marten, mink** (all in Genus **Mustela**); **skunk (Mephitis); otter (Lutra)**: (Figs. 558, 603).

VIVERRIDAE: **Civet (Viverra); mongoose (Herpestes); genet (Genetta**: Fig. 559). In Eastern Hemisphere only.

HYAENIDAE: **Hyenas** of Asia and Africa.

FELIDAE: **Cat, lynx, jaguar, lion, tiger, leopard, panther** (all in Genus **Felis**): (Fig. 560).

**Suborder PINNIPEDIA.** Aquatic. Body streamlined, approaching fishlike form; short tail, no tail-fin. Pectoral and pelvic limbs well developed, but short and externally finlike ("flippers"), the five digits being webbed together. Three FAMILIES are recognized:

OTARIIDAE: **"Eared seals,"** having small pinnae; pelvic flippers can assist in clumsy locomotion on land. **Sea lion, fur seal** (Fig. 561).



FIG. 557. (Left) South American kinkajou. (Right) Asiatic panda. Procyonidae; related to the raccoon, *Procyon*. (Courtesy, Museum of Comparative Zoology, Harvard University.)



FIG. 558. Mink, *Putorius vison*. (Courtesy, Ontario Department of Lands and Forests.)






FIG. 559 (Left). Common genet, *Genetta vulgaris*. (Courtesy, Flower and Lydekker: "Introduction to the Study of Mammals," London, A. & C. Black, Ltd.)

FIG. 560 (Right). A carnivore mouth—tiger. (Courtesy, Museum of Comparative Zoology, Harvard University.)



FIG. 561. Sea lions: family Otariidae. (Courtesy, American Museum of Natural History, New York.)

PHOCIDAE: "Earless seals" no pinnae; pelvic flippers, directed backward, serve in place of a caudal fin and cannot be rotated forward useless on land. Common "harbor seals."

ODOBENIDAE: No pinnae; upper canines become enormous tusks projecting downward. Walrus (Fig. 562).

**Distribution of Carnivora:** World-wide except in Australia, New Zealand, Polynesia, and islands adjacent to them. The "native dog" or "dingo" of Australia is a true carnivore (not marsupial), but its presence there as the only member of Carnivora in that part of the world is probably due to its importation by early man (Fig. 563).

The hoofed mammals, "ungulates," have commonly been regarded as constituting an Order, Ungulata, including several sub-orders. Such scanty knowledge as is available concerning the origin of ungulates indicates that probably they have not had common origin in some primitive hoofed ancestors. It is more likely that the common



FIG. 562. Walrus, *Odobenus*. (Courtesy, American Museum of Natural History, New York.)




FIG. 563. Australian dog, *Canis dingo*. (Courtesy, Museum of Comparative Zoology, Harvard University.)

ungulate features of several sharply demarked groups of modern mammals are an instance of convergent specialization along lines of independent origin.

The following four Orders (13–16) include “ungulate” mammals. The hoof is a massive horny structure developed, in place of a claw, on the distal phalanx of a digit, providing a broad flat surface of contact with the ground. The most significant difference between **Perissodactyla** and **Artiodactyla** is the structure of the feet. The members of both Orders are **unguligrade** (see p. 583), and more or less reduction in number of digits occurs, but the plan of symmetry involved in the reduction is radically different in the two Orders (Fig. 564). The commonly used terms “odd-toed” and “even-toed” must not be taken literally. The “odd-toed” tapir has four digits on the manus, and at least the primitive artiodactyls, “even-toed,” had all five digits. The **perissodactyl** plan of symmetry, **mesaxonic**, *tends toward* an odd-toed foot, and the **artiodactyl** plan, **paraxonic**, *tends toward* an even-toed foot.

**Order 13: PERISSODACTYLA.** “Odd-toed” or **mesaxonic**. The axis of symmetry of the foot is the third digit (Fig. 564). The second and fourth digits are equally and symmetrically developed, and the first and fifth, if present, are likewise equally developed. The third digit is strongest and, in cases of extreme reduction, is the only functional digit. During locomotion only the tips of the functional digits touch the ground (Fig. 450).

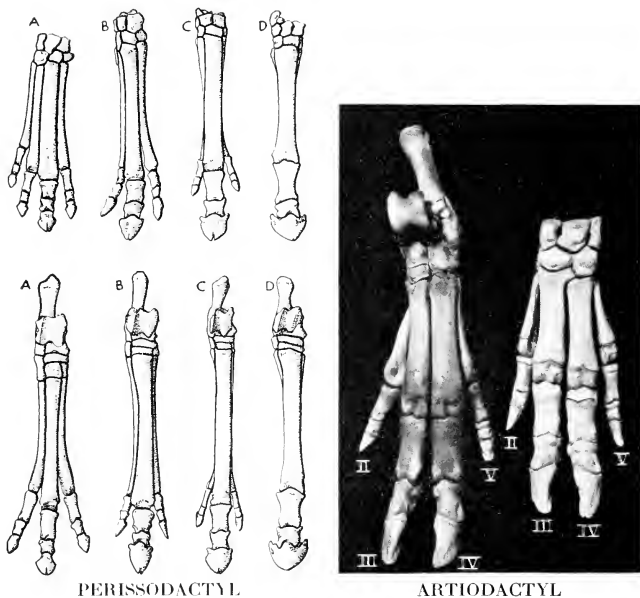


FIG. 561. (Left) Feet of horses. Manus at top, pes at bottom. (A) *Eohippus*, a primitive Lower Eocene perissodactyl with four toes in front, three behind. (B) *Miohippus*, an Oligocene three-toed horse. (C) *Merychippus*, a late Miocene horse with reduced lateral toes. (D) *Equus*. (A, after Cope; B and C, after Osborn. Courtesy, Romer: "Vertebrate Paleontology," University of Chicago Press.)

(Right) Feet of pig. Manus at right, pes at left.

The dentition is of the herbivorous type: incisors adapted for cutting, canines small, cheek-teeth flat-topped and ridged for crushing and grinding; formula for horse,  $i \frac{3}{3}$ ,  $c \frac{1}{1}$ ,  $p \frac{4}{4}$ ,  $m \frac{3}{3}$ . The stomach is simple and there is no gallbladder.

There are three FAMILIES of modern perissodactyls.

**EQUIDAE:** Only the third digit (in modern Equidae) functionally developed; vestiges of the second and fourth form the pair of "splint bones" attached laterally to the elongated third metacarpal or metatarsal (Fig. 561). **Horse, ass, zebra (Equus).**

**TAPIRIDAE:** Four digits on manus (pollex lacking), three on pes. Snout elongated into a short proboscis. **Tapir** of the Malayan region and South and Central America (Fig. 565).




FIG. 565. Tapir, *Tapirus*. (Courtesy, Museum of Comparative Zoology, Harvard University.)




FIG. 566. Rhinoceros (*Rhinoceros*) and chevrotain (*Tragulus*). (Courtesy, Museum of Comparative Zoology, Harvard University.)

**RHINOCEROTIDAE:** Three digits on manus, three on pes. One or two median "horns" on forepart of head (Fig. 566). Unlike horns of other ungulates, the **rhinoceros** horn is composed of longitudinal fibers of horny substance and has no bony core, being probably a mass of fused hairs. The rhinoceroses occur in Asia and Africa.

**Distribution of Perissodactyla.** Modern Equidae are native to the Eastern Hemisphere only, but fossil remains of members of all three modern Families of Perissodactyla are found in the Western




FIG. 567. Peccary, *Dicotyles*. (Courtesy, Flower and Lydekker: "Introduction to the Study of Mammals," London, A. & C. Black, Ltd.)

Hemisphere, including a complete series of progressively equine mammals which were quite clearly ancestral to the modern horse.

**Order 14: ARTIODACTYLA.** "Even-toed" or **paraxonic**. The axis of symmetry of the foot lies between the third and fourth digits (Fig. 564), which are equally and symmetrically developed and functionally most important. The other digits are reduced or absent. If present, the second and fifth are symmetrically developed. The first occurred in some extinct artiodactyls.

The dentition is of the herbivorous type—cutting incisors; canines usually small, sometimes lacking; cheek-teeth usually grinders.

Two Suborders are distinguished:

**Suborder SUINA (BUNODONTIA).** Four digits on each foot, the second and fifth being fairly well-developed. Canine teeth become




FIG. 568. A highly specialized nonruminant mouth—hippopotamus. (Courtesy, Museum of Comparative Zoology, Harvard University.)

long curved tusks, especially prominent in male; molars with rounded cusps (**bnodont** type); formula for pig,  $i \frac{3}{3}$ ,  $c \frac{1}{1}$ ,  $p \frac{1}{1}$ ,  $m \frac{3}{3}$ . Stomach simple. Two FAMILIES:

SUIDAE: **Pig (Sus)**, **peccary** (Fig. 567).

HIPPOPOTAMIDAE: **Hippopotamus** (Fig. 568).

**Suborder RUMINANTIA (SELENODONTIA)**. Usually only two functional digits (third and fourth), their two metacarpals or metatarsals fused into a single long "**cannon bone**," the second and fifth much reduced or lacking. Upper incisors small or usually lacking; canines small or lacking; molars with crescentic ridges (**selenodont** type); usual formula,  $i \frac{0}{3}$ ,  $c \frac{0}{1}$ ,  $p \frac{3}{3}$ ,  $m \frac{3}{3}$  (Fig. 569). Stomach complex—i.e., divided into several compartments, usually four (Fig. 570). Feeding and chewing are separated. Food, swallowed unchewed, passes into the more anterior one or two compartments for temporary storage. After feeding is finished, masses of the food are regurgitated into the mouth and thoroughly chewed at leisure ("chewing the cud," or rumination). It is then swallowed in a finely divided and semifluid state and, by action of a valvular arrangement, is caused to pass directly into the posterior division of the stomach, where it is digested.

The several FAMILIES fall into three groups, as follows:

**TYLOPODA:**

**CAMELIDAE:** Teeth exceptional in that a pair of upper incisors and all four canines are present. No horns or antlers. **Camels**—the **drome-**

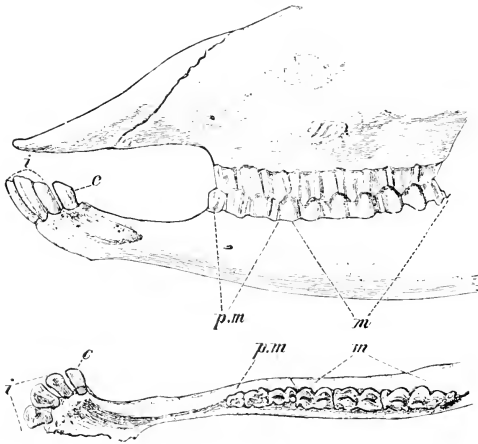


FIG. 569. Teeth of sheep (*Ovis aries*). (c) Canines; (i) incisors; (m) molars; (pm) premolars. (From Wiedersheim: "Comparative Anatomy of Vertebrates." By permission of The Macmillan Company, publishers.)

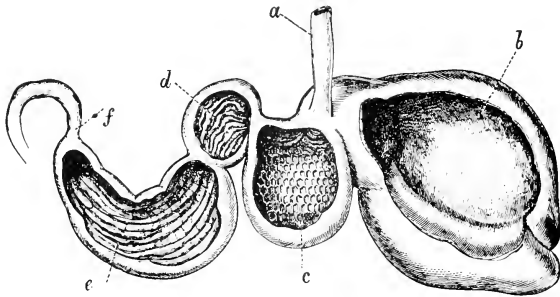


FIG. 570. Stomach of ruminant opened to show internal structure. (a) Esophagus; (b) rumen or paunch; (c) reticulum or honeycomb bag; (d) psalterium or manyplies; (e) abomasum or reed; (f) duodenum. (Courtesy, Flower and Lydekker: "Introduction to the Study of Mammals," London, A. & C. Black, Ltd.)



**dary** with one hump, and the two-humped **bactrian**—of Asia and Africa; **llamas** of South America (Fig. 571).

**TRAGULINA:**

**TRAGULIDAE:** The “**mouse deer**” or **chevrotain** (*Tragulus*) of Asia and Africa; smallest of ungulates, standing about 12 inches high. Deerlike in appearance, but without antlers (Fig. 566).

**PECORA:**

**CERVIDAE:** The **deer** tribe. Head usually bears a pair of antlers developed as solid bony outgrowths (covered temporarily by skin) from the frontal bones and more or less elaborately branched; shed and regenerated annually. Antlers usually present in male only, but in a few cases (e.g., **reindeer**) in both sexes; entirely absent in **musk deer**. **Deers** (*Cervus*: Fig. 572), **elk**, **moose**, **reindeer**.

**GIRAFFIDAE:** Extremely long legs and neck, adapted to feeding on foliage of trees. The “horns” are a pair of short frontal bony knobs, permanently covered by hairy skin. **Giraffe** (Fig. 194) and **okapi**, African only. The okapi (Fig. 573), in size and in the conspicuous stripes on the legs, resembles a zebra, but it is artiodactyl and otherwise giraffe-like, but with relatively shorter legs and neck. It was unknown (i.e., to white men) until 1900, when it was discovered in the Belgian Congo.

**ANTILOCAPRIDAE:** The **prongbuck** or “**American antelope**” (*Antilocapra*). The single-pronged frontal horns have a permanent bony core but its horny covering is shed annually.

**BOVIDAE:** “Hollow-horned,” but the “hollow” of the horny structure is filled by a permanent bony core produced by the frontal bone, and the horn is never shed. Horns usually present in both sexes. An Asiatic antelope has two pairs of horns, both borne by the frontal bones. **Cattle** (*Bos*), **bison**, **sheep** (*Ovis*), **goat** (*Capra*), **antelopes** (Fig. 574), **gnu**, **chamois**, **gazelle**.

**Distribution of Artiodactyla.** The Artiodactyla, taking the Order as a whole, are extensively represented in both Eastern and Western Hemispheres, but totally absent from the regions of Australia, New Zealand, and Polynesia except as introduced by man. Wild pigs occur only in the Eastern Hemisphere, peccaries only in the Western Hemisphere. The hippopotamus is African only. Cervidae are numerous in both hemispheres, mostly in their more northern parts. Antelopes (of Bovidae) are in the Eastern Hemisphere only; the prongbuck (“American antelope”) is found only in western North America.

**Order 15: PROBOSCIDEA.** **Elephants**, largest existing land mammals. In contrast to perissodactyl and artiodactyl ungulates, in which there is a strong tendency to concentrate the function of the foot



FIG. 571. Llamas, *Auchenia*. (Courtesy, Museum of Comparative Zoology, Harvard University.)



FIG. 572. Head of deer, *Cervus schomburgki*, showing antlers. (Courtesy, Flower and Lydekker, "Introduction to the Study of Mammals," London, A. & C. Black, Ltd.)

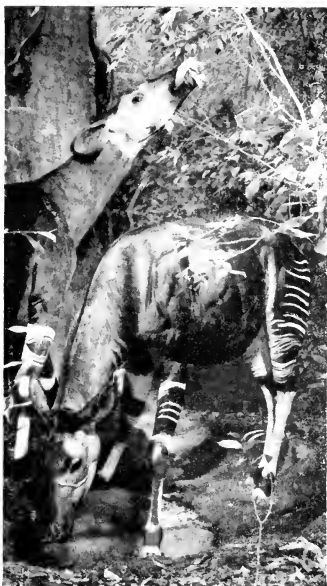

FIG. 573 (Left). Okapi group, Africa. (Courtesy, American Museum of Natural History, New York.)

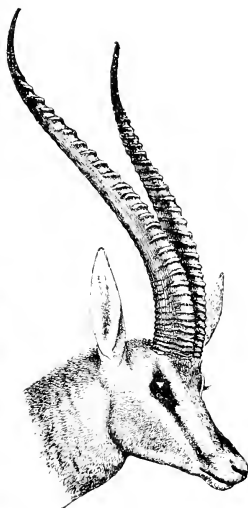


FIG. 574 (Right). Head of antelope, *Gazella granti*, showing horns. (Courtesy, Flower and Lydekker: "Introduction to the Study of Mammals," London, A. & C. Black, Ltd.)

into one or two strong digits, the elephant retains all five on each foot and all are functional. The five, however, are not externally free. Spread far apart, they are enclosed in a common covering of skin, and the wide interstices between them are filled with dense connective tissue which continues into a thick pad of similar tissue built out behind the row of digits. Each digit of the manus bears a large broad hoof; in the pes at least three or four digits have hoofs. By this highly specialized structure of the foot, the tremendous weight which it must sustain is distributed over a maximum area of ground. The horse walks on the tips of four toes, one on each foot. The elephant walks on 20 toes, but each set of five is so constructed that it is functionally a single enormous hoof-like member. Each leg is a massive straight column. The backward bend at the elbow and the forward bend at the knee, characteristic of other mammals, are necessarily eliminated, being incompatible with efficient support of the animal's weight.

The **dentition** is exceptional. One pair of upper incisors become the tusks, more strongly developed in the male than in the female. The fully developed tusk consists of a somewhat modified dentine ("ivory") covered by a very thin layer of cement but lacking enamel except at the tip of a young tusk. A pair of temporary and relatively small "milk-tusks" precede the permanent tusks. In some extinct elephant-like mammals, a pair of lower incisors became a second pair of tusks, projecting downward. There are no canines. In the course of its lifetime, the animal acquires a total of 24 cheek teeth—on each side, 6 above and 6 below. Of the six produced in each half-jaw, never more than two, and at times only one, are in functional position at the same time (Fig. 575). Of the two present at a particular time, the anterior one is fully developed and its crown is completely exposed for use. The posterior one is incompletely developed and only the anterior part of its crown is exposed. Eventually the older anterior tooth is shed and then the next one, becoming fully developed, moves forward into its place. Meanwhile a partially developed tooth which had been buried in the jaw behind the functional two moves forward to become the posterior functional tooth. This replacement is repeated until the sixth

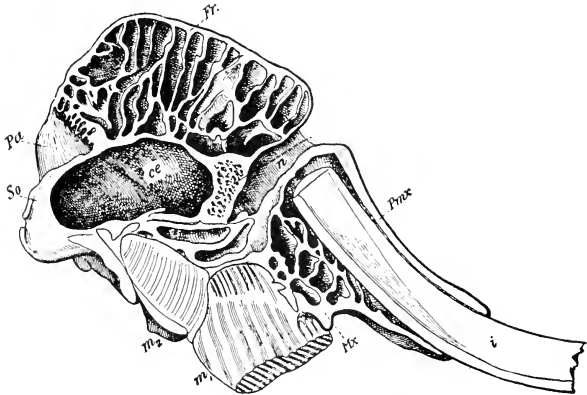


FIG. 575. Parasagittal section of elephant skull in a plane cutting through the root of one tusk. (*cc*) Cranial cavity; (*Fr*) frontal; (*i*) incisor tusk; (*m<sub>1</sub>*, *m<sub>2</sub>*) first and second molar teeth; (*Mr*) maxillary; (*n*) nasal cavity; (*Pa*) parietal; (*Pmr*) premaxillary; (*So*) supraoccipital.

The cranial cavity, containing the brain, occupies a small proportion of the volume of the skull. The size of the skull is greatly augmented by elaborate systems of air-filled sinuses, especially in its dorsal region and around the bases of the tusks. The arrangement of the bony walls of the sinuses is such as to provide maximum resistance to external impacts. The sinuses are in communication with the nasal cavities. (Courtesy, Zittel: "Handbuch der Palaeontologie," Munich, R. Oldenbourg.)

and last tooth comes into place. The first cheek-tooth is fully developed in an elephant about 3 months old and the fifth tooth comes into use 20 or more years later. These "grinders" attain a size consistent with other exaggerated features of the animal. In an old elephant the anteroposterior dimension of the crown of a tooth ranges from 9 to 15 inches and the width is about  $3\frac{1}{2}$  inches. The teeth are transversely ridged (**lophodont**).

Elongation of the snout to become the **proboscis** or "trunk" is the elephant's most distinctive feature. The external nares are at the tip of it. Powerfully muscular and equipped with a delicate finger-like process at its tip, the trunk can be used with equal facility for picking up a peanut or a railway tie (for elephants have been trained to assist in heavy construction).

The auditory **pinnae** are of impressive size, but the tail is negligible. The animal is strictly herbivorous and the stomach is simple—there is no rumination. The skin is much thickened and only very sparsely covered with hair. The brain is well developed, the cerebral hemispheres being strongly convoluted. The high degree of intelligence commonly credited to the animal is probably overrated.

The elephant is the most highly specialized of modern land mammals. Compared to the external configuration of a "normal" mammal, beautifully exemplified in a cat, tiger, or lion, most of the external features of the elephant are grossly exaggerated, but it is done so consistently that the whole seems well proportioned. Even the small tail seems more fitting than a large one would be. The tremendous bulk is not unwieldy; the gait is ponderous but not clumsy. Although the form of the giraffe is functionally intelligible, the ideal mammalian lines seem to have suffered much distortion. There is something ridiculous about the giraffe, but the elephant's form expresses efficiency and commands respect.

There are only two existing species of proboscideans, the Indian elephant (**Elephas indicus**) and the African (**E. africanus**). The African is somewhat larger and its pinnae are relatively much larger. The extinct elephant-like **mammoths** and **mastodons** existed in both Eastern and Western Hemispheres. A long-haired ("woolly") mammoth inhabited the cold northern regions of both hemispheres.

**Order 16: HYRACOIDEA.** To this Order are assigned certain small obscure mammals whose affinities are problematic. About the size of a rabbit, with legs of medium length, very short tail, small pinnae, and prominent incisor teeth, the animal might be taken for a rodent. The dentition as a whole, however, resembles that of an ungulate rather than that of a rodent. The manus has four functional digits.

the pes three. All of the digits except the first of the three on the pes terminate in broad, blunt, horny structures resembling nails or tiny hoofs rather than claws. The exceptional toe bears a long curved claw. Although the feet are plantigrade, their blunt horny structures appear ungulate in nature. The animals are herbivorous and the stomach is divided into two compartments. The gallbladder is lacking.

Two Genera of these animals are usually recognized, **Hyrax** (**Procavia**; Fig. 576) and **Dendrohyrax**. The name "cony" is commonly




FIG. 576. *Hyrax capensis*. (Courtesy, Flower and Lydekker: "Introduction to the Study of Mammals," London, A. & C. Black, Ltd.)

applied to them, but unfortunately the European rabbit also is often called by that name. They are found only in western Asia and northern Africa. *Hyrax* is terrestrial in habit but *Dendrohyrax* is said to live in hollows of trees.

**Order 17: SIRENIA.** Aquatic, but less highly adapted to aquatic life than whales—body relatively short and thick; head more distinct from body than in whales; no median fin; horizontal caudal fin. Pectoral limb externally finlike as in whales; pelvic limb represented only by small vestiges embedded in body-wall.

**Dentition** heterodont; incisors lacking or, at most, one pair of tusklke uppers; no canines; cheek-teeth resemble those of proboscideans, especially in manner of replacement—i.e., by loss of most anterior tooth and development of a new tooth at hind end of row. The total number produced in one half-jaw may exceed 20, but not more than 6 are in use at one time.

Skin very thick and nearly devoid of hair; only one pair of mammary organs, situated in extreme anterior (pectoral) region. Stomach complex, resembling that of artiodactyls. Brain relatively small and only slightly convoluted.

Sirenians are the **sea cows** inhabiting the warmer coastal regions of the Atlantic, Pacific, and Indian Oceans and adjoining bodies of fresh water. They feed on aquatic vegetation. Length up to 8 or 10 feet. There are only two living Genera:

**Manatee** (*Trichechus* or *Manatus*; Fig. 577): No incisors; only six cervical vertebrae. Atlantic coastal regions of America and Africa.

**Dugong** (*Halicore*): One pair of tusklike upper incisors; seven cervical vertebrae, the usual number in mammals. Southwest Pacific (Australia), Red Sea, Indian Ocean (east coast of Africa).

A third recent Genus, **Rhytina** (Steller's sea cow), said to be toothless when adult, inhabited the northern Pacific up to the eighteenth century, since when no observations of its occurrence have been reported.

**Order 18: CETACEA.** Aquatic; many of them of gigantic size (85 feet or more in length) and including the largest known mammals. External form fishlike; no externally evident neck region; seven cervical vertebrae much shortened and more or less fused together (Fig. 578). Caudal fin ("tail-flukes") horizontal instead of vertical as in fishes; a single median dorsal fin usually present, but devoid of internal skeleton. Pectoral limb short, broad, externally finlike, but internally having the skeletal parts of a typical pentadactyl limb; the four or five



FIG. 577. Manatee, *Manatus*. (Courtesy, American Museum of Natural History, New York.)

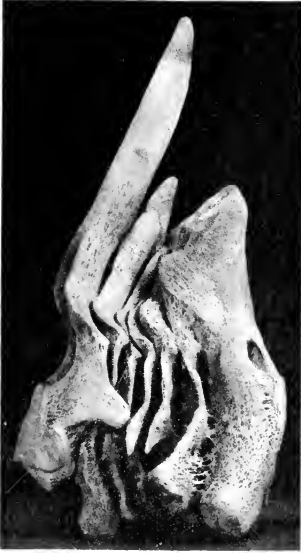

FIG. 578. The seven cervical vertebrae (left lateral view) of whale, *Mesoplodon densirostris*. (Courtesy, American Museum of Natural History, New York.)

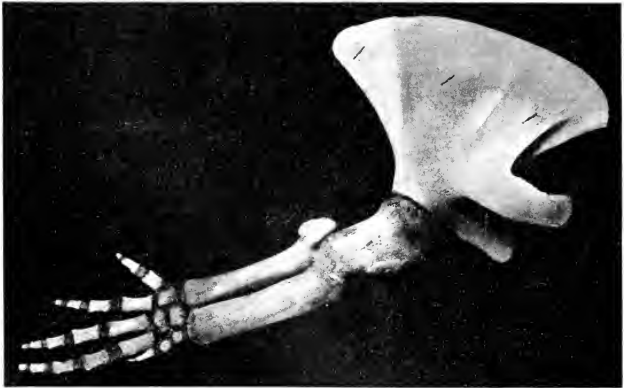


FIG. 579. Forelimb of beaked whale. (Courtesy, American Museum of Natural History, New York.)



digits completely enclosed within a common covering of skin (Fig. 579). Pelvic limbs represented only by small vestiges of the pelvic girdle (possibly also of the femurs) embedded in the body-wall.

Skin very thick and nearly or quite hairless in adult; thick subcutaneous layer of fat ("blubber"), important as insulation against loss of heat. One pair of mammary organs in extreme posterior (inguinal) region. External nares on dorsal surface of head. Complex stomach—divided into several compartments. Brain relatively large and cerebral hemispheres highly convoluted.

There are two Suborders:

**Suborder ODONTOCETI. Toothed whales;** carnivorous. Homodont teeth usually numerous and of simple conical form (Fig. 580); exceptionally, teeth reduced to a few pairs or even only one pair. Skull asymmetric—bones of right anterior region larger than corresponding bones of left side; reason unknown. External nares join in a single external opening. **Sperm whale (Physeter; Fig. 581); beaked whale; bottlenose; narwhal (Monodon); porpoises and dolphins (DELPHINIDAE).**

**Suborder MYSTACOCETI. Whalebone whales** (but "whalebone" is not bone). Adults toothless; horny plates (**baleen**), fringed along their lower edges, depend, like curtains, from the upper jaw, constituting a sieve through which water expelled from the oral cavity is strained, the animal's food being whatever small organisms (mostly fishes) are thus obtained (Figs. 582-584). Skull symmetric. External nares open separately. Greenland or Arctic **right whale** (or "**bow-head**"; **Balaena**), important as a source of commercial whalebone; **humpback whale (Megaptera);** **rorqual or finback (Balaenoptera)**, including some of the largest of whales.

Cetaceans range all the oceans from the equator to the arctic and antarctic regions. Some of the smaller members of the Order inhabit fresh water—large rivers of Asia and South America.

**Order 19: PRIMATES.** For purposes of a precise definition, the primates are perplexingly lacking in distinctive anatomic features. The limbs are devoid of any extreme specialization such as marks those of cetaceans, bats, and the several orders of ungulates. All of the primitive five digits are retained. Erect posture and bipedal locomotion characterize only a few primates; most of them "go on all fours," and all are plantigrade. The dentition is complete and heterodont, but no one kind of tooth is highly specialized. The dentition is perhaps even less specialized than that of Insectivora. The stomach is usually simple. The uterus may be either bicornis or simplex. Most definitions include

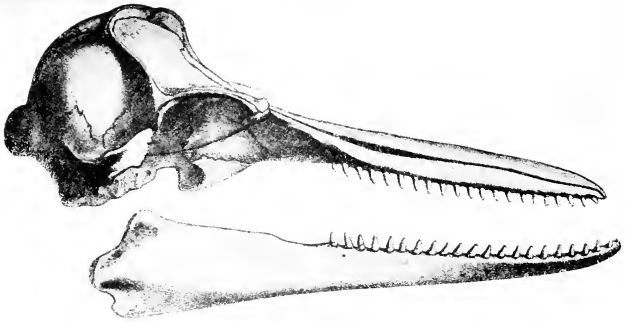


FIG. 580. Skull of toothed whale, *Sleno rostratus*. (Courtesy, American Museum of Natural History, New York.)




FIG. 581. Sperm whale, *Physeter macrocephalus*. (Courtesy, Flower and Lydekker: "Introduction to the Study of Mammals," London, A. & C. Black, Ltd.)

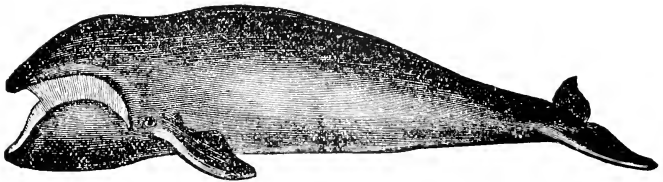


FIG. 582. Southern right whale, *Balaena australis*. (Courtesy, Flower and Lydekker: "Introduction to the Study of Mammals," London, A. & C. Black, Ltd.)

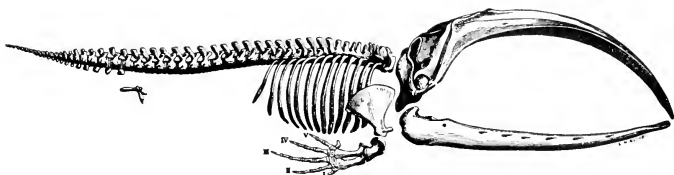


FIG. 583. Skeleton of baleen whale. (Courtesy, Owen: "Comparative Anatomy and Physiology of Vertebrates," London, Longmans, Green & Co., Ltd.)

the statement that the orbit is usually completely separated from the temporal fossa by a bony wall. In fact, it may almost be said of primates, as of insectivores, that their most characteristic feature is the absence of distinctively specialized structures. The search for them brings to light only such apparently trivial things as the flat nails on the digits, instead of claws or hoofs—and, in fact, some animals classed as primates have claws on some of the digits. Another small anatomic peculiarity makes possible the rotation of the first digit so that it becomes opposed to the other four, a position favorable for prehension and especially for grasping branches of trees, for most primates are arboreal. Either the pollex or the hallux or both may be opposable, but in some of the more primitive primates there is little or no power of opposition. The human primate, although not arboreal, finds the opposable thumb exceedingly useful. The feature of most outstanding significance is one that involves no new type of specialization but merely carries to a higher level something which is already well advanced in other mammals, especially ungulates and carnivores—namely, the development of the cerebral cortex. But, here again, many



FIG. 584. Jaws of baleen whale. (Courtesy, American Museum of Natural History, New York.)

animals classed as primates have brains quite inferior to those of members of some other orders and not notably better than those of insectivores. Among the lemurs, included as primates, are some animals which could just as well be classed with insectivores were it not that the lemurs have flat, horny, nail-like structures on some digits, are of larger average size, and present a vaguely monkey-like appearance.

Three Suborders may be recognized:

**Suborder LEMUROIDEA.** Small, although some are as large as a cat or larger; mostly arboreal and nocturnal; in general appearance slightly resembling monkeys (Fig. 585). Eyes directed laterally; brain relatively small and convolutions scantily developed. Digits bear various combinations of claws and flat nails or intermediate structures, but the second digit of the pes always bears a claw and the hallux always a nail. Tail long but not prehensile. Uterus bicornis. One pair of pectoral mammary organs; in some species, also an inguinal pair.

These are the **lemurs** found in southern Asia, the East Indies and Philippines, Africa, and especially numerous in Madagascar.




FIG. 585 (Left). Bush baby, a lemur, *Galago*. (Courtesy, American Museum of Natural History, New York.)

FIG. 586 (Right). *Tarsius*. (Courtesy, Vogt and Specht: "Die Säugetiere in Wort und Bild," Munich, F. Bruckmann-Verlag.)



FIG. 587. Golden marmoset, *Midas chrysoleucas*. (Courtesy, Flower and Lydekker: "Introduction to the Study of Mammals," London, A. & C. Black, Ltd.)




FIG. 588. Platyrrhine monkeys, *Cebus capucinus*. (Courtesy, Vogt and Specht: "Die Säugetiere in Wort und Bild," Munich, F. Bruckmann-Verlag.)

**Suborder TARSIOIDEA.** Size about that of a small squirrel; arboreal and nocturnal; resemble lemurs. Long hindlegs; very long tail with a brush of long hair at its end. Eyes disproportionately large, round, and directed forward; brain better developed than in lemurs.

The group includes only one living genus, **Tarsius**, living in the East Indies and Philippines (Fig. 586).

The Lemuroidea and Tarsioidea are sometimes combined in a Suborder called **Prosimii**.

**Suborder ANTHROPOIDEA.** Mostly larger than lemurs. Eyes directed forward; brain relatively large and with a much convoluted cerebral cortex. Usually flat nails on all digits; the pollex and, in many cases, the hallux may be opposed to the other digits. Uterus simplex; one pair of pectoral mammary organs.

Two distinct divisions are recognized:

**PLATYRHINA.** Nasal septum broad and nostrils directed more or less laterally. Flat nails on all digits except in marmosets (Hapalidae), which have claws on all digits except the hallux. Tail long and commonly prehensile. (Figs. 587, 588).

The two FAMILIES, HAPALIDAE (**marmosets**) and CEBIDAE (**monkeys**), occur only in Central and South America.




FIG. 589. Baboon. (Courtesy, Museum of Comparative Zoology, Harvard University.)

**CATARRHINA.** Nasal septum narrow; nostrils open more nearly forward and downward. Nails on all digits. Tail long, short, or lacking, but never prehensile.

Three FAMILIES are distinguished:

**CERCOPITHECIDAE:** **Macaque, baboon** (Fig. 589), **langur, proboscis monkey**, and many other monkeys. Asia and Africa.

**SIMIIDAE:** **Gibbon**, the smallest of them, only in the Malay region; **orangutan**, Borneo and Sumatra; **gorilla** and **chimpanzee**, Africa only: (Figs. 590, 591).

**HOMINIDAE:** **Man**; origin in Eastern Hemisphere. Present knowledge concerning the origin of the human race is derived chiefly from fragmentary remains found in widely separated regions of the Old World. Based on this scanty material, the following early human or prehuman types have been recognized:

**Australopithecus africanus**, the "Taungs skull" from South Africa; intermediate between skull of ape and human skull.

**Pithecantropus erectus**, the "Java man," but somewhat apelike.

**Eoanthropus**, the "Piltdown man" from Sussex, England.

**Sinanthropus**, the "Peking man" from China.

**Homo rhodesiensis**, from Rhodesia, South Africa.

**Homo heidelbergensis**, the "Heidelberg man" from Germany: lower jaw only.

**Homo neanderthalensis**, the "Neanderthal man" from Germany and various parts of Europe.

**Homo sapiens**, the "Cro-Magnon man" of southern France, and the several races of **modern man**.

#### RELATIONSHIPS OF GROUPS OF MAMMALS

Knowledge of early mammals is too scanty to warrant positive statements about the relationships of the three Subclasses of existing mammals. The reptilian characteristics of **monotremes** and the fact that modern marsupials are in many respects intermediate between monotremes and placentals does not necessarily mean that the three groups stand in direct linear evolutionary relationship. The ancestors of modern monotremes must have been mammals having numerous strongly marked reptilian characteristics, including oviparous reproduction. *Ornithorhynchus* and *Echidna* are highly specialized in some respects—the former in connection with semiaquatic habits and the latter as an anteater. These two animals must be a remnant of a mammalian line of very ancient origin, along which, in the main, primitive reptilian characteristics have been retained, even down to the present.




FIG. 590. The "great apes." (*Left*) Gorilla. (*Top*) Orangutan. (*Center*) Gibbon. (*Right*) Young chimpanzee. (Courtesy, Museum of Comparative Zoology, Harvard University.)



but with acquisition of some secondary specialization. This line must have diverged from the same primitive stock which, along other diverging lines, gave rise to marsupials and placentals. The beginnings of mammals were probably in the Triassic. In the latter part of the Jurassic lived mammals of about the size of the smaller rodents, lacking any highly specialized features and, so far as can be judged from structure of teeth and skull, probably chiefly insectivorous. These **Pantotheria** (or **Trituberculata**), or unknown animals allied to



FIG. 591. Young chimpanzees fraternizing with the author. (Photo by R. M. Yerkes.)

them, may have been the point of departure for the diverging marsupial and placental lines. The monotremes and the pantotheres (and their possible allies) must have had common ancestry in much more ancient times.

**Marsupials** and **placentals** both existed in the Cretaceous Period, but which came first is quite uncertain. However, at the close of the period, marsupials seem to have been somewhat more numerous than placentals. Possible vestiges of marsupial structures in embryos of some modern placentals suggest that placentals had marsupial ancestors. On the other hand, presence of a weakly developed placenta in a few modern marsupials may be taken to mean that marsupials had placental ancestors. Admitting the doubt as to the beginnings of the

two lines, it may be said that along one line anything of placental nature which may have been initially present was all but suppressed and marsupial reproduction became the dominant feature of the group. Along the other line, any marsupial propensities which may have been present at the start were suppressed and placental reproduction became perfected. It is quite possible that the two lines had entirely separate origins and that such similarities as exist between the reproductive mechanisms of the members of the two lines are instances of parallel but independent evolution.

At the end of the Cretaceous, the marsupials were widely distributed in both hemispheres. Apparently, however, they were unable to hold their own against the more aggressive placentals and suffered almost complete extinction, surviving only in the Australian region, where a few rodents and bats are the only native terrestrial placental mammals, and in South America and southeastern North America, where a few small marsupials (opossums and *Caenolestes*) survive, apparently by retreating from competition.

It is a most noteworthy fact that the marsupials eventually differentiated into various types of mammal, each type having distinctive characteristics wherein it closely resembles an analogous placental group. Many of the smaller marsupials externally resemble placental insectivores or rodents. In many cases the resemblance to rodents is increased by the prominence of the incisor teeth. The South American *Caenolestes* is called the "marsupial shrew." The blind burrowing *Notoryctes* (Fig. 592) is the "marsupial mole," having all of the specialized features of a placental mole. The banded anteater (*Myrmecobius*), about as large as a cat, has the long snout and long, sticky tongue which always go with anteating. There is a long-eared "rabbit bandicoot," and the "flying" phalangers (Fig. 593), of which there are several species ranging in size from that of a mouse to that of a cat, have "flying" (i.e., sailing) membranes similar to those of "flying" squirrels and the colugo (Order *Dermoptera*). The wombat (*Phascolomys*), 2½ to 3 feet long including a 2-inch tail, looks like an overgrown rodent. The arboreal koala (Fig. 542) is the "marsupial bear." Among the polyprotodonts are many marsupial carnivores resembling placental carnivores in appearance, teeth, and habits. The dasyures (Fig. 535) are more or less catlike. The Tasmanian wolf (Fig. 536) has a doglike head on a more catlike body. The Tasmanian "devil" (*Sarcophilus*), short in the legs and resembling a badger, is said to emit a frightful growl and has a reputation for great ferocity. The larger kangaroos (*Macropus*) correspond to the ungulates in being large and herbivorous, but there the similarity ends—the methods and mechanisms of locomotion in cow and kangaroo are about as unlike as possible.

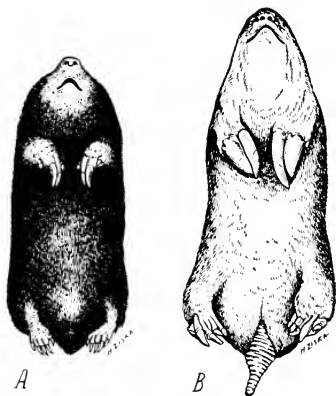


FIG. 592. (A) Mole, *Chrysochloris*, placental insectivore. (B) Marsupial mole, *Notoryctes*. (Courtesy, American Museum of Natural History, New York.)




FIG. 593. "Flying" mammals. (Top) Colugo, *Galeopithecus*. (Left) Flying phalanger, a marsupial. (Right) Flying squirrel, a rodent. (Courtesy, American Museum of Natural History, New York.)

These correspondences between marsupials and placentals are many and striking. The correctness of their interpretation as results of parallel (or convergent?) evolution (see p. 366) can hardly be questioned. It seems clear that, in animals of the same general kind (such as, e.g., members of a vertebrate Class), similarity of environment, diet, method of locomotion, and general mode of life will inevitably be associated with similar anatomic adaptations, quite regardless of close genetic relationship. This comparison of existing marsupials and placentals emphasizes the danger of error in judging relationships on the basis of similarity of adult structures, without adequate knowledge of their embryonic and phylogenetic history.

During the Eocene Epoch, the reptilian menace having become much reduced, placental mammals increased and entered upon a period of adaptive radiation (see p. 366). The Jurassic pantotheres did not last long, but they, or as yet unknown mammals of similar primitive nature (for the fossil material is exceedingly scanty), apparently left descendants which, in size and general anatomy, were essentially like modern Insectivora. The existence of Insectivora can be traced from the Eocene down to the present. Early in the Eocene appeared other mammals, still small and, in general, unspecialized, but showing in teeth and some skeletal characteristics evidences of a tendency toward carnivorous habits and structure—the beginning of a group called “**Creodonta**.” It was in this period, when most of the then existing mammals were in that anatomically generalized and plastic state which seems to be necessary for acquisition of adaptive structural modifications related to changes in habitat, diet, and mode of living, that placentals began to undergo the elaborate diversification which produced the numerous Orders (Fig. 594).

Evidence from fossils strongly indicates that most of the now existing Orders had their beginnings in either the ancient **Insectivora** or the contemporary incipient carnivores, the **Creodonta**. The main line of the Insectivora has persisted to the present with only minor modifications. The **Chiroptera** and **Dermoptera** are essentially insectivores in general anatomy, but specialized for aerial locomotion—actual flight in bats and sailing in the colugo. The **Rodentia** also would seem to be closely allied to the Insectivora, but there is some reason to believe that rodents go back to something even earlier than Insectivora, perhaps having had independent origin from pantotheres.

The members of the several “edentate” Orders, rather more strongly than other placentals, show reptilian features which mark them as of ancient origin. The **Xenarthra** and possibly also the **Pholidota** may be assigned to very early origin from the Insectivora or from some even more primitive placentals. Some of the ancient

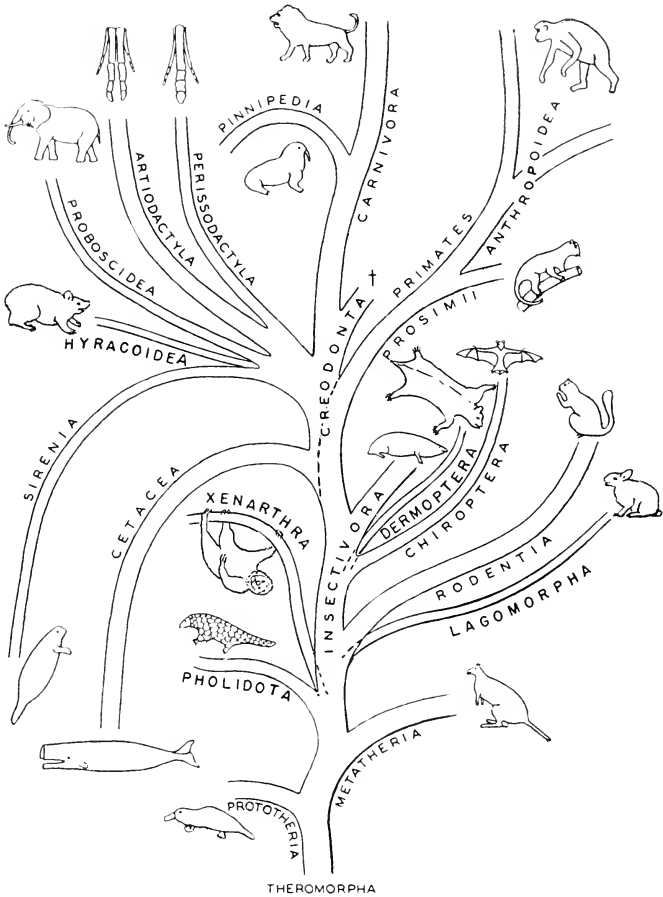


FIG. 591. A genealogic "tree" of the mammals. The general relationships of the branches are reasonably well supported by known facts, but the exact points and times of origin of many of the Orders are in more or less doubt. The origin of the Tubulidentata, not shown in the "tree," is most uncertain. The Creodonta (†) are extinct. Branches curving downward indicate groups which have reverted to aquatic life.

edentates were of enormous size. The armored **glyptodons**, resembling armadillos, attained a length of nearly 10 feet, and **ground sloths** ranged in size from that of a large dog to that of an elephant (Fig. 595). These xenarthran edentates were confined to the Western Hemisphere and were especially numerous in South America. The African aardvark (**Tubulidentata**), however, seems to have no special affinity to anything else. Its origin is quite problematic.

Typical **ungulates** are heavy-bodied terrestrial herbivores with hoofs, digital structures well adapted for swift locomotion of large animals over hard, open ground. It is by no means certain whether **Perissodactyla** and **Artiodactyla** diverged from one another before or after claws were replaced by hoofs. Ancient ungulates were very numerous and of most diverse types. One of the oldest known and most primitive groups was the **Condylarthra** (Fig. 596), existing in the

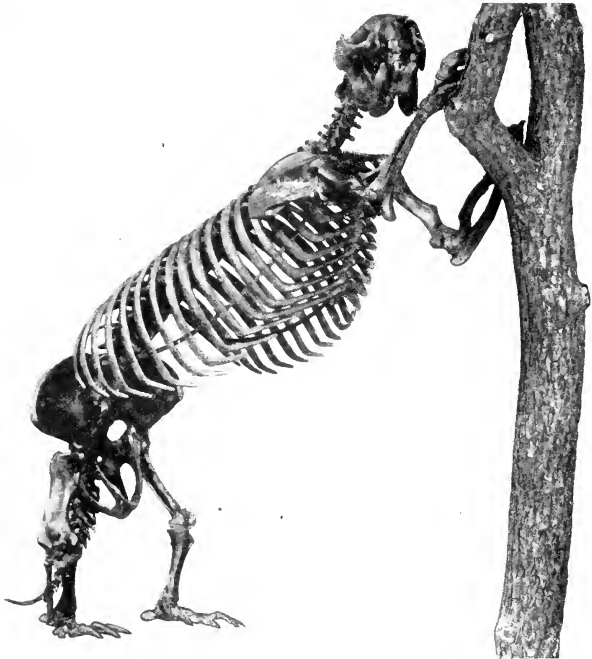


FIG. 595. Ground sloth (*Megalocnus*). (Courtesy, American Museum of Natural History, New York.)

Paleocene and Eocene but extinct before the end of the Eocene. The condylarthrans had five digits on each foot and the third digit was strongest, suggesting a tendency toward the mesaxonic type of foot. Some of these condylarthrans had claws; some had hoofs. The teeth were definitely of ungulate pattern. The origin of the group is quite obscure, but it seems likely that the **Perissodaetyla** may have been derived from **Condylarthra**. The history of horses (**Equidae**) is well known back to the early Eocene (possibly 50,000,000 years ago), beginning with **Eohippus** (Fig. 597), a little "odd-toed" North American ungulate, horselike in many ways, but only about 20 inches long and having four well-developed digits on the manus and three on the pes. Along the later line of "horses," there was progressive increase in size of the animal and decrease in number of digits in the mesaxonic foot to the present one-toed limit (Fig. 598).

The **Artiodactyla** were already well developed in the early Eocene. The teeth of the oldest known artiodactyls were not definitely of the herbivorous type, even resembling somewhat those of creodonts. It is possible that the group may have arisen in close relation to the early creodont line rather than from the **Condylarthra**—therefore quite independently of **Perissodaetyla**.

The **Proboscidea**, in retaining all five digits, show their independence of both perissodactyl and artiodactyl lines of descent. A line of more or less elephant-like mammals has been traced back into the late Eocene, where it becomes lost in the general obscurity of ungulate origins. The **Hyracoida** must have emerged from that same obscurity and, in retaining most of their digits and in some skeletal features, they show a possible remote affinity to elephants. But the conies remained relatively primitive while the elephants became the most highly

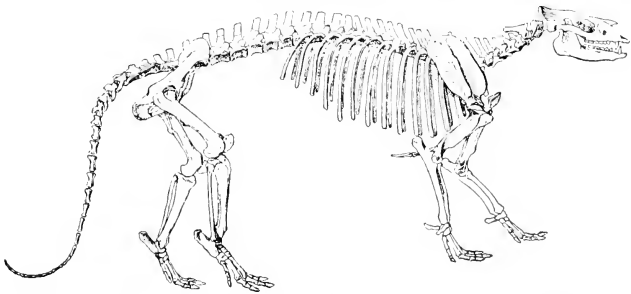


FIG. 596. *Phenacodus*, a primitive ungulate (**Condylarthra**), about 5½ feet long. (After Osborn. Courtesy, Romer: "Vertebrate Paleontology," University of Chicago Press.)

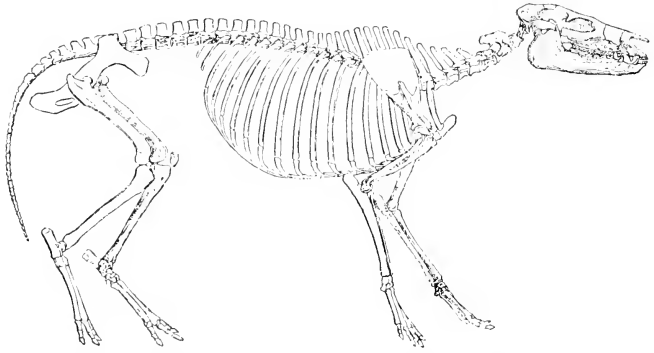


FIG. 597. *Eohippus*, the "dawn horse" of the Lower Eocene, probably close to the stem of the perissodactyls; length about 18 inches. (After Cope and Woodward. Courtesy, Romer: "Vertebrate Paleontology," University of Chicago Press.)

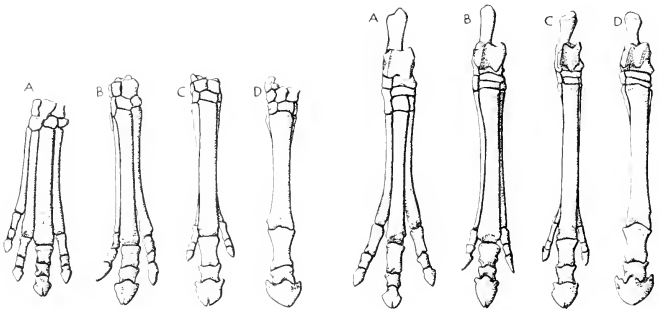


FIG. 598. Feet of horses. (Left) Manus. (Right) Pes. (A) *Eohippus*, a primitive Lower Eocene perissodactyl with four toes in front and three behind. (B) *Miohippus*, an Oligocene three-toed horse. (C) *Merychippus*, a late Miocene form with reduced lateral toes. (D) *Equus*. (A, after Cope; B, C, after Osborn. Courtesy, Romer: "Vertebrate Paleontology," University of Chicago Press.)



specialized of land mammals. African fossils indicate the existence of ancient hyracoids much larger and more numerous than modern conies. **Sirenia** show definite ungulate characteristics. Such teeth as they have resemble those of elephants, especially in the tendency to develop incisor tusks. Fossils prove the existence of sirenians in northern Africa in the Eocene. These ancient sea cows had a more nearly complete dentition and had small, but probably functional, hindlimbs.

Some classifications create a group, "**Subungulata**," to contain **Proboscidea** and **Hyracoidea**. The rabbit-like conies and elephants seem to be about as unlike as possible, but they possess at least a common negative characteristic in that neither of them shows any evidence of close relationship to either perissodactyl or artiodactyl ungulates, and the African fossils give some positive basis for putting the two groups together. The **Sirenia** also are sometimes included in Subungulata. Sea cows probably have the same relation to terrestrial ungulates that the seals and walrus have to terrestrial carnivores, but the sea cows have gone so much farther in their aquatic adaptations than have the pinnipeds that they seem to merit the status of a separate Order—they have ceased to be literally "ungulate."

The direct descent of **Carnivora** from the primitive **Creodonta** is reasonably certain. Except in the teeth, modern Carnivora are not very highly specialized, certainly far less so than most ungulates. Some classifications include Creodonta as a suborder under Carnivora. The **Cetacea**, existing and ancient, show no strong affinities to mammals of any other order. The earliest whales known existed in the middle Eocene in the northern African region. They were even then definitely whales, but the skull lacked the extreme specialization of the modern cetacean skull, resembling that of a creodont, and the teeth were of creodont type in both their number and their form. The cetaceans, still carnivorous in habit, possibly had origin from some early creodonts which had already become carnivorous.

**Cetaceans**, **sirenians**, and **pinnipeds** represent three independent parallel (?) lines of aquatic adaptation. Along the cetacean line, the adaptations to the mechanical needs of highly efficient aquatic locomotion have been carried to their physiologic limit, at the expense of complete loss of ability to go ashore, but giving these most highly specialized of all mammals a capacity for speed, deep diving, and long submergence which makes them masters of the "high seas" and cosmopolitan rovers over all the great oceans. The sirenians are relatively clumsy swimmers and their herbivorous diet limits them to habitation of coastal waters. The pinnipeds have departed least from their ancestral terrestrial anatomy. They are fairly good swimmers but are able to go ashore. (Fig. 599.)

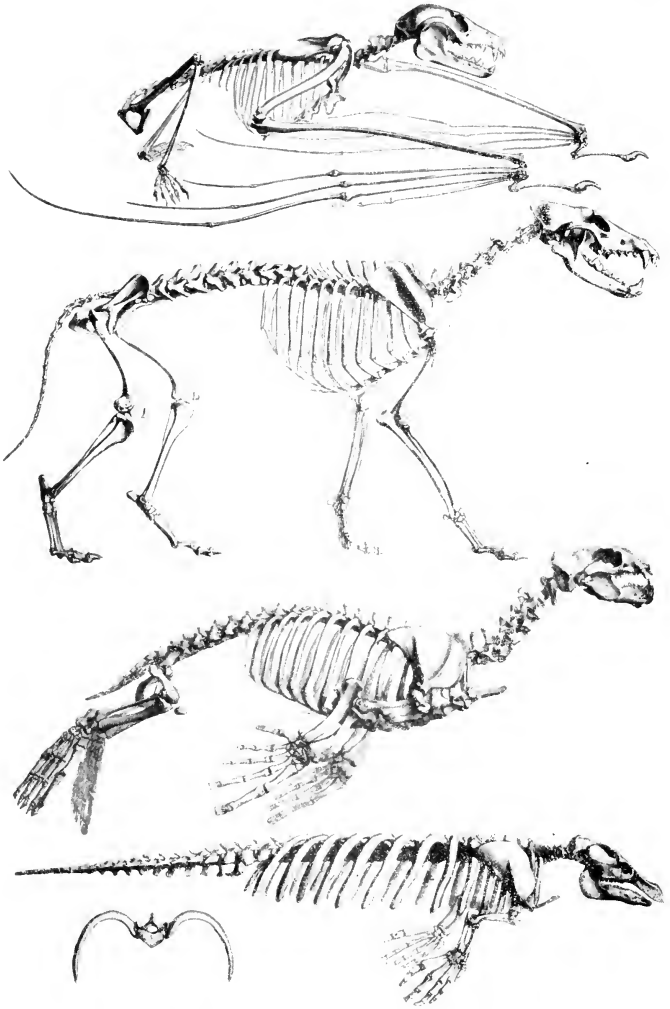


FIG. 599. (See legend and continuation of figure on facing page.)

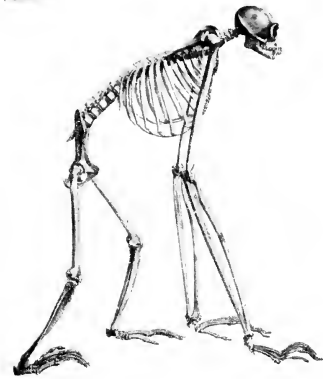

FIG. 599. Functional adaptations in the mammalian skeleton. (*Opposite page, top*) Flying fox, one of the Chiroptera. (*Second from top*) Terrestrial carnivore: wolf. (*Second from bottom*) Semiaquatic pinniped carnivore: seal. (*Bottom*) Aquatic: manatee, a sirenian. (*Left*) Arboreal: gibbon, a primate. (Courtesy, De Blainville: "Ostéographie Comparée du Squelette," Paris, Arthus Bertrand.)



FIG. 600. (*Left*) Bush baby, a lemur, *Galago*. (*Center*) Pentailed tree shrew. (*Right*) Opossum, a marsupial. (*Left and Right*, courtesy, American Museum of Natural History, New York; *center*, courtesy, Flower and Lydekker: "Introduction to the Study of Mammals," London, A. & C. Black, Ltd.)

The **Primates** are very definitely allied to the Insectivora by the lemurs. Fossils regarded as lemur-like are found in the early Eocene. It is true both of ancient and of existing mammals that there is no sharp anatomic demarcation between those of the insectivore type and the lemuroid primates. The most significant difference is a tendency toward relatively greater size of the lemur's brain and the shortening of the jaws and nasal region. The similarity, and also these differences, are especially well shown by comparison of a lemur with an arboreal insectivore such as a tree shrew (Fig. 600). In fact, the tree shrew might reasonably be regarded as a primate somewhat more primitive than a lemur.

## Epilogue: What Comes of Studying Vertebrates

Animals must eat, breathe, and move. The nature of the organs which perform these functions is most directly and necessarily related to the animal's environment. This is especially true of the *moving* and *breathing*. In relation to these two functions, the animal's environment may be, respectively, water-water, land-air, water-air, or air-air. Gill-breathing fishes possess a simple locomotor mechanism adapted to propelling a finely streamlined body through water. Lung-breathing reptiles and mammals possess a more or less elaborately specialized tetrapod mechanism adapted to locomotion over a solid substratum. Flight imposes excessive demands on the bird's breathing mechanism and requires a peculiar and very highly specialized locomotor apparatus.

The relations of vertebrates to environmental water, land, and air are almost as diverse as could be imagined. Yet all vertebrates, whether minnow, python, horse, or hummingbird, possess the same basic structure. But it is so modified and elaborated as to fit the most diverse requirements. Inspection of the whole assemblage of vertebrates reveals the fact that the modifications and elaborations of a particular organ or system are not desultory or unrelated to those of other organs in their occurrence. No fish possesses hair or feathers; no mammal has a three-chambered heart. On the contrary, it is possible to recognize groups of animals which may be so arranged in series that the structural differences of a particular organ are continuously progressive throughout the series. If this be done for each of all systems of organs, it will be found that, at least in general, the groups fall into the same sequence in all of the several series. Following are some examples of this sequence.

The **skin** of fishes secretes a thin superficial cuticula similar to that of invertebrate skin. Calcareous scales, usually bony, and mucous glands, usually of the simple unicellular type, are the characteristic products of their skin. In amphibians cuticula is present only in the

larva and in adults of some permanently aquatic species. Otherwise it is replaced by a stratum corneum. Mucous glands are of the complex multicellular sort; bony scales are rare in modern amphibians. In reptiles the stratum corneum is strongly developed and elaborated into horny scales. The general integument is devoid of glands; bony scales are lacking in most modern reptiles. Birds elaborate the stratum corneum into feathers, lack integumentary glands (except the uropygial oil-gland), and are totally devoid of bony scales. Mammals derive their hair from the stratum cutaneum, lack integumentary mucous glands but possess sweat-glands and oil-glands, and only rarely have bony scales. An epidermal cuticula does not occur among amniote vertebrates. In this series, beginning with fishes and culminating in birds and mammals, the differences exhibited by the skin are, in general, correlated with the nature of the environments of the several groups.

The **notochord** is functional in Cyclostomata. Among Pisces it persists in a somewhat reduced way in adults of Chondrostei and Dipnoi. Adults of other fishes retain only vestiges of it. In Amphibia the notochord is usually functional during the larval stage but merely vestigial in adults. Of Reptilia, the adult *Sphenodon* retains definite remnants of the embryonic notochord. In other reptiles and in all members of Aves and Mammalia, the notochord is restricted to the embryonic stages.

The embryonic **skeleton** (aside from the notochord) in all vertebrates is cartilaginous. The degree to which it becomes ossified varies. In Cyclostomata, Elasmobranchii, and Holocephali, the adult skeleton (except the notochord) is entirely cartilaginous. In fishes of the "ganoid" groups, there is more or less ossification, and in Teleostei, the "bony fishes," ossification reaches its limit for fishes. In modern Amphibia, especially in the Urodela, the adult skeletons retain more or less of the embryonic cartilage. In Reptilia ossification of the skeleton is nearly complete (the sternum usually does not ossify), and in Aves and Mammalia ossification reaches its extreme.

The segmented **muscles** of the body exhibit varying degrees of differentiation. Local elaboration of groups of muscles occurs in relation to (1) the mechanism of breathing; (2) the separation of an anterior thoracic from a posterior abdominal region of the trunk; and (3) the locomotor appendages. This differentiation is at its minimum in fishes. Corresponding to the capacity of the lungs and to the locomotor efficiency of the legs, there is some differentiation of appropriate muscles in amphibians, a decidedly more elaborate differentiation in reptiles, and in birds and mammals the extreme of complexity is attained (Fig. 91).

The **respiratory organs** of fishes are gills, with lungs in Dipnoi playing an accessory role. Amphibian larvae are gill-breathing, but most adult amphibians are lung-breathing, the skin in many cases being a more or less important accessory. All Amniota are lung-breathers. The pharyngeal chambers are at the maximum in number and functional importance in fishes, and at the minimum in birds and mammals.

The **heart** is two-chambered in lungless fishes; three-chambered in Dipnoi and Amphibia; three-chambered, but with a partial division of the ventricle, in Reptilia excepting the crocodylians. In Crocodylia, Aves, and Mammalia, the heart is four-chambered. A review of the aortic arches (Fig. 73) and the arrangement of the main venous channels (pp. 69–78) reveals in each of these two systems a graded series beginning with fishes and passing through amphibians and reptiles to a duplex culmination in birds and mammals.

The pronephros is the functional **kidney** of a few fishes. In most fishes and in amphibians the mesonephros is the adult kidney (see p. 79). In Amniota the adult kidney is the metanephros.

In most fishes **reproduction** is effected with a minimum of accessory provision for protection or other needs of the embryo. A relatively small egg, fertilized after it is discharged into the water, is freely exposed to the hazards of the environment. High mortality is compensated for by production of vast numbers of eggs. Reproduction in most amphibians is essentially similar to that in most fishes, but with the long larval stage interpolated into the course of development. The relatively large eggs of reptiles, deposited on land, are enclosed by a protective membrane and a shell. The early embryo produces the protective amnion and the respiratory allantois. Reproduction in birds is essentially of the reptilian type, but with eggs of maximum relative size. In monotreme mammals reproduction is definitely reptilian. In utmost contrast to this, most mammals produce eggs of the minimum size in vertebrates, and development is placental.

In this series of vertebrate reproductive methods there are two breaks. A very abrupt one occurs between amphibians and reptiles. The amnion and allantois correspond to nothing in the embryo of an amphibian or fish. A second break occurs, not between two classes, but within the Class Mammalia. There is nothing in a monotreme corresponding to a placenta. A simpler **ichthyopsidan type** of reproduction is sharply contrasted with a more elaborate **sauropsidan type**. Monotreme mammals are sauropsidan in their reproduction, and the conditions in modern marsupials do not bridge the gap between monotreme and placental reproduction.

Classed with reference to the structure of the **brain**, the serial

order of existing vertebrates is most definite. A palaeoencephalon extends throughout the series, with only relatively minor modifications. The elaboration of a neoencephalon or "superbrain" is at its minimum in fishes, particularly in the Teleostei. Elasmobranch fishes, amphibians, and reptiles show, in the order mentioned, progressive increase in the importance of the neoencephalic structures, especially the pallial cortex. The brain in birds is essentially reptilian in structure, the chief difference being greater complexity of the palaeoencephalic structures concerned with the very highly developed instinctive behavior of the bird. In the mammalian brain the neoencephalic parts are at the maximum for the vertebrate series.

Not only these several major features which have just been briefly reviewed but also innumerable details of vertebrate structure (especially the skull and other skeletal parts) show differences in degree and nature of their elaboration which, if made the basis of an arrangement of existing vertebrates, cause them to fall into line in the order, fishes—amphibians—reptiles, and at "reptiles" the series bifurcates into two lines, one mammalian, the other avian.

**Comparative Embryology** corroborates the serial order of the vertebrates as determined by **Comparative Anatomy**, and adds some highly relevant facts. The earlier developmental stages of all vertebrates exhibit an essential similarity in structure and in the manner in which the embryonic parts develop. Certain of the early embryonic organs—e.g., the notochord, pharyngeal pouches, and aortic arches—attain complete and permanently functional development only in fishlike vertebrates. In later stages of embryos of other vertebrates, these structures may be obliterated or may persist as abortive "vestiges," or may undergo a more or less profound metamorphosis, as when the pharyngeal pouches of the most anterior pair become converted into cavities of the middle ear. Also, in later embryonic stages appear structures, not recognizably present in earlier stages, which become distinguishing anatomic features of the adults. It may fairly be said, therefore, that all vertebrates begin to develop as if they were destined to become fishes. Upon this common early-embryonic basis is superimposed the development of the distinctive features of the adult. In the course of this later phase of development, the basic structures of the early embryo may attain full elaboration, or they may suffer reduction, suppression, or metamorphosis, and to them may be added various "new" structures—e.g., lungs, metanephros, feathers, hair. If modern vertebrates be arranged in a series determined by the degree to which the basic embryonic structure persists in the adults and by the number and nature of the structures secondarily



superimposed upon them, the groups fall into line in the same order as in the anatomic series.

**Paleontology** arranges the vertebrates in a chronologic series depending on the distribution of vertebrate fossils in geologic strata. Fishes appear in the early Paleozoic (see Table 3, p. 411). In the mid-Paleozoic Devonian, an "Age of Fishes," are found the first evidences of amphibians. Reptiles appear in the later Paleozoic. Mammal-like reptiles toward the close of the Paleozoic are succeeded by definitely mammalian types in the middle Mesozoic (Jurassic). *Archaeopteryx*, the earliest known bird, was Jurassic.

**Anatomy, Embryology, and Paleontology**, each using only its own data, arrange the major groups of vertebrates in the same serial




FIG. 601. Phylogeny of the vertebrates. The varying width of the black bands representing the several groups suggests the relative abundance of the members of the groups. (Courtesy, Romer: "Vertebrate Paleontology," University of Chicago Press.)

order. Comparative Anatomy, using only its own data, asserts the basic structural similarity of all vertebrates, but it cannot confidently assert more than that. Its data suffice merely to suggest a *theory* of the genetic continuity of animals, or "evolution." But, left to itself, Anatomy must have continued to use such terms as "basic structure," "plan," or "pattern," variously (but by what means?) adapted. These terms belong to the language of transcendentalism. Comparative Embryology discovers a common early-embryonic basis for all vertebrates. But, in the later embryonic stages, there is an extraordinary degree of indirectness in the manner of development of many of the organs. Primary embryonic structures may be torn down and rebuilt, as when cartilaginous skeletal parts are replaced by bone. A notochord is replaced by cartilaginous vertebrae, which are later replaced by bone. Pronephros and mesonephros may be more or less completely obliterated and replaced by a metanephros. A simple median postcaudal vein emerges from a prolonged and intricate process of rebuilding and transforming the primary venous drainage system of the embryonic trunk. In many instances it seems as if the embryo takes a long, devious, and unnecessarily laborious way of arriving at a simple definitive result. Especially significant is the fishlike structure and mode of life of the amphibian larva, and the transitory presence of reptilian characteristics during the embryonic development of mammals and birds—especially conspicuous in the development of the skull and other skeletal parts.

These striking peculiarities in the embryonic development of vertebrates seem to offer only one reasonable interpretation—the genetic continuity of a vertebrate series ranging from fishes through amphibians and then reptiles to a duplex climax in mammals and birds. If any doubt as to the correctness of this interpretation could remain, it should be dispelled by the chronology of the vertebrate series as revealed by Paleontology and by the fact that Paleontology provides many transitional types or "connecting links" which do much to fill the gaps between the groups of existing vertebrates. The basic structure of the ancestral fishlike vertebrate persists in the early embryo throughout the series. In the course of the embryonic development of later members of the series appear transitory characteristics inherited from successive ancestors—as, e.g., in the development of the aortic vessels of a bird, several aortic arches arranged as in fishes are reduced to a temporary arrangement similar to that of reptiles (see p. 625), to be followed by further reduction leaving only the right member of the fourth arch in the adult bird. According to Ernst Haeckel (see p. 349), "ontogeny repeats phylogeny"—and it surely does, at least in development of the basic vertebrate structures.

## FROM PRIMITIVE CHORDATE TO MAN

If the history of a half-billion or more years be condensed into a few sentences, the story of the vertebrates might go somewhat as follows: In early Paleozoic time there must have existed some very small, free-swimming, aquatic animals whose form probably resembled that of quite young amphibian tadpoles. Devoid of paired appendages, they swam by undulatory motions of the body and such tail as they may have had. Dorsal to the digestive tube was a median supporting rod, a notochord. They breathed by gills situated in paired pharyngeal clefts. The central nervous organ was a dorsal hollow cord slightly enlarged at its cephalic end.

The origin of such purely hypothetic **primitive chordates** is problematic. Whether derived from nemerteans (Hubrecht, 1883), or from annelid worms (Dohrn and Semper, 1875; Delsman, 1913), or from arthropods (Gaskell, 1908; W. Patten, 1912) is a question about which much has been said and written and nothing proved. Bateson (1886) regarded *Balanoglossus* as a very direct and little-altered descendant of the primitive chordates. According to Kowalewsky (1868) and W. K. Brooks (1893), the tunicate larva and the free-swimming tunicate *Appendicularia* are close to the primitive chordates. It is generally agreed that the modern protochordates, with some doubt in the case of the Hemichorda, are in one way or another closely related to the primitive chordates. *Amphioxus* is probably a direct but rather specialized descendant of early chordates. In its possession of some definitely fishlike characteristics, it is probably an example of parallelism in evolution. The Cyclostomata, commonly classified as vertebrates, show, especially in the larval stage, strong points of resemblance to *Amphioxus* (Figs. 315, 316) and in some respects are more fishlike than *Amphioxus*.

The typical fishes, **Pisces**, must have diverged at an early time from those chordate lines which lead down to modern protochordates and to cyclostomes. The earliest known definitely piscine chordates were sharklike. It is a widely, but not unanimously, accepted view that elasmobranch fishes were the ancestors of all modern fishes and of all other vertebrates. Descendants of early sharks became diversified along several lines, producing the crossopterygians and fishes of the several "ganoid" types, the lungfishes (Dipnoi), and, along a line achieving the maximum of piscine specialization, the now dominant Teleostei.

At this point we encounter what is perhaps the most serious break in the history of the vertebrates—the origin of **amphibians**. Whether they are derived from Dipnoi or from early crossopterygians, pre-

sumably also lung-breathing, is a matter of opinion. That Dipnoi and Amphibia had common origin from crossopterygians is perhaps the safest view. Having started with a hypothetic primitive chordate, we must again draw on imagination to get a finned fish out onto land as a tetrapod amphibian. No "connecting links" are known, but the fin-skeleton of some ancient crossopterygians may, without too great a strain on imagination, be converted into the skeleton of a leg (Fig. 123). Allowing a million years, or more if necessary, and admitting that we know not how the changes could have taken place (nor do we fully know the mechanism of any other evolutionary change), we can only imagine that some shallow-water fishes gradually shifted their habitat from water (presumably fresh water) to land, their fins meanwhile becoming legs.

Amphibians, restricted to life near water, never as such achieved wide distribution and dominance, but from them descended animals which, by appropriate changes in skin, respiratory organs, and method of reproduction, were able to free themselves from the ancient bonds of water and became wholly terrestrial **reptiles**. Among late Paleozoic tetrapod vertebrates were some (e.g., *Seymouria*) which, as judged by fossil skeletons, might have been reptile-like amphibians or amphibian-like reptiles. Once having attained a foothold on land and freedom to migrate inland, the tetrapod vertebrates found themselves on the threshold of an era of such expansion, diversification, and increase in size and power as gave them mastery of the habitable land surfaces of the Mesozoic world. The diversification even went so far that some reptiles reverted to aquatic living (but remained air-breathing), and others acquired power of flight. It was an Age of Reptiles.

Among early reptiles were some whose skeleton and teeth exhibit mammalian characteristics. Evidence of transition from reptiles to **mammals** is quite as satisfactory as that for origin of reptiles from amphibians. The early mammal-like (theromorph) reptiles lasted for a relatively short time, but it was long enough for them to give rise to a line of descendants which were unmistakably mammalian. Down through one or two hundred million years of the reptilian world trickled a thin stream of small (compared to reptilian contemporaries) and obscure mammals. It is possible that their smallness and obscurity favored their survival. When, in the later Mesozoic, climatic changes or other circumstances brought on hard times for the reptiles, the mammals, by dint of their warm blood, fur, and potentially superior neuromuscular equipment, began to come into their own and eventually acquired the dominant position which they have retained down to the present.

Meanwhile, **birds** appeared. As a "connecting link" between

reptiles and the more recent birds, no one animal could better satisfy requirements than the feathered flying reptile—or, because of feathers, call it a bird—*Archaeopteryx*. Because of their aerial habits, birds did not come into serious competition with mammals. The two groups have come down through tens of millions of years as flourishing contemporaries. Some mammals prey on birds and some large birds prey on small mammals, but this reciprocal eating is no more than a mutually advantageous relationship between the two groups.

From the early (Tertiary) Cenozoic time down to the present has been traced a line of mammals primitively of small size and quite indifferent anatomic characteristics, the Insectivora. At a remotely ancient time in the history of this line, it evidently gave rise to a branch along which adaptation for arboreal life was acquired. In most respects the animals retained the insectivore characteristics, but the forelegs became elongated and the digits were adapted for grasping, making possible a novel method of locomotion—swinging by the forelegs (“arms”) from branch to branch of trees. In some of the more recent animals along this **primate** line, a considerable increase in the size of the body occurred, while the brain attained a size greater than can

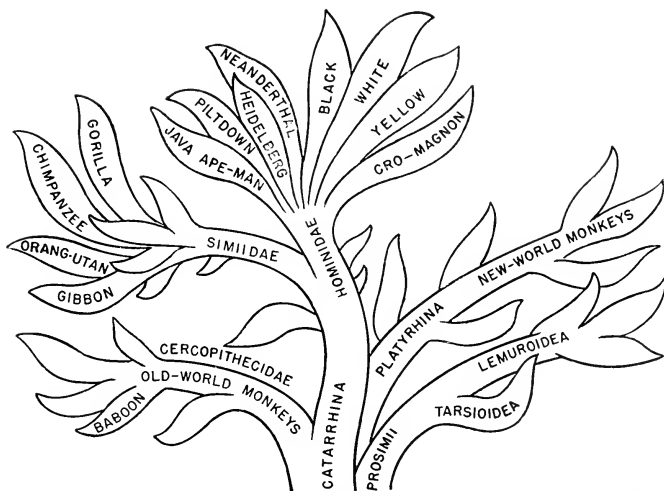


FIG. 602. Relationships of the primates. Copied, with minor modifications, from a “tree” which forms the background of a portrait of Robert M. Yerkes, founder of The Yerkes Laboratories of Primate Biology, Inc. The “tree” of the portrait is the painter’s artistic elaboration of a figure published by William Patten in 1930.

be accounted for by mere increase in size of the body. It was probably in the Glacial Period (one or two hundred thousand years ago) that some of these larger primates forsook the trees and came down to earth. But they retained their long arms and gradually adopted bipedal locomotion on the hindlegs with the body in a more or less nearly upright position. With the prehensile digits they grasped clubs or stones and, in the course of time, crude weapons and tools. Such, according to the fully consistent evidence from anatomy, embryology, and paleontology, was the origin of the human primate which, in an incredibly short (in the geologic scale) time, has become the world's dominant animal.

#### LINES OF SPECIALIZATION

Certain aspects of this history of vertebrates require special emphasis. Throughout the history (true not only of vertebrates but of all animals) may be seen numerous instances of lines of descent *diverging* from some common ancestral type. "Divergence" expresses the fact that along each of the several lines of descent the adaptive modifications or "specializations" of the ancestral structure are of a sort peculiar to that one line. Each of several such diverging lines may be called a "line of specialization." Degree of specialization is measured by the extent to which an organ or animal has progressed along its own peculiar line of specialization, whether the line be long or short. The mammalian ear is very highly specialized compared to a shark's ear. The mammary organs of a placental mammal are highly specialized compared to those of monotremes. Among Carnivora, seals have gone much farther than others along the line of specialization for aquatic life. Specialization, broadly defined, may consist either in elaboration and complication of a structure, or in reduction of it. The primitive pentadactyl mammalian foot is more highly specialized in the one-toed foot of a horse than in the three-toed foot of a tapir. In most snakes specialization by reduction of the paired appendages has gone to its limit, complete obliteration.

"Primitive" and "specialized" are relative terms. An animal which is a primitive member of its own group may, in some particulars, be specialized in relation to members of the group from which it was derived. *Archaeopteryx* was a primitive bird, but it had made considerable progress along the avian line of specialization as contrasted to its reptilian progenitors.

An especially significant fact which emerges from the history of vertebrates is that new lines of specialization arise, not from some highly specialized division of an established group, but always from some relatively unspecialized members of it. Amphibians arose, cer-

tainly not from teleost fishes, but probably from less specialized crossopterygians (or possibly Dipnoi?). Early reptiles were long of body and tail and short-legged, resembling urodele amphibians, not frogs and toads. The theromorph reptiles, transitional to mammals, existed before reptiles had become differentiated into their several specialized orders.

It seems evident that specialization is acquired at the expense of that plasticity which enables animals to become adapted to new situations and new modes of living. There is perhaps some remote analogy to old age in the individual animal. An old saying asserts that "it is hard to teach an old dog new tricks." Old persons do not readily change their habits or adopt new ideas. They become "set." It has been suggested that a highly specialized group of animals has arrived at a stage of "**phylogenetic old age**." Such an "old" group may go on indefinitely so long as external circumstances do not alter, but climatic or other environmental changes would cause the extinction of a group so "set" that it could not readapt itself to the new conditions. It seems likely that teleost fishes, anuran amphibians, snakes, birds, and cetaceans have nearly or quite reached the limits of their several lines of specialization. It is difficult to imagine any anatomic improvements which would better adapt a brook trout, tarpon, or whale to its aquatic life, or which would increase the efficiency of the wings of an eagle or sea gull.

Long survival of a group is not necessarily dependent on high specialization. Many small, feeble, and relatively unspecialized vertebrates survive by avoiding competition. The little amphibian newts and numerous mammals such as small rodents and insectivores survive by keeping out of the way of potential enemies, just as the very early mammals probably did. In short, animals may succeed and survive for a time by becoming large, strong, aggressive, and dominant, or they may survive by retreat. Some animals are specialized for retreat. In burrowing animals the locomotor appendages may be highly specialized for digging. The auditory pinnae of burrowing mammals are more or less reduced.

Numerous instances of **convergent evolution** may be found along two or more lines which are genetically very far apart. In some viviparous sharks the wall of the oviduct produces either vascular folds or processes (villi) which become closely related to the highly vascular abdominal wall (wall of yolk-sac) of the embryo. By this means, the nutritive and respiratory needs of the embryo are in part provided for by diffusion of substances from the maternal blood to that of the embryo. This arrangement is essentially like that of the mammalian placenta. Some viviparous lizards (Genus *Seps*) are similarly "pla-

cental." There cannot be any genetic connection between the "placenta" of a shark and that of a lizard or mammal, nor between the "placenta" of a lizard and that of a mammal. Extreme elongation of body, along with reduction of the locomotor appendages, is a line of specialization which has been followed by several groups quite independently of one another. Among teleost fishes it has produced the common eels and the large conger eel. *Amphiuma* and *Siren* (Fig. 349) are amphibian "eels." Snakes are the reptilian equivalent of eels. It is possible that the resemblances between legless lizards (amphisbaenians) and snakes are a case of parallel, instead of convergent, evolution (see p. 366). Such long-bodied, short-legged mammals as the mink and ermine (Figs. 558, 603) are somewhat snakelike in external form. The absence of locomotor appendages in the cyclostome eels is probably not the result of reduction. The cyclostome line probably diverged from the primitive chordate stock before paired locomotor fins had been acquired.

What it is that "directs" a group of animals along a definite "line of specialization" is not known. Darwin's "natural selection" seems to be not fully adequate to account for it, although selection may be an important factor. One theory asserts the action of an internal "drive," of an unknown sort, which holds evolutionary change to a certain direction, *as if* toward a preordained goal—the theory of **orthogenesis**, strongly advocated by the late H. F. Osborn, but not originated by him.

There is some ground for the idea that specialization may go beyond its optimum point, resulting in a condition of "**overspecialization**" which handicaps the animal. This is true of increase in size. Up to a certain point, large size combined with corresponding muscular power



FIG. 603. The ermine or stoat, *Putorius erminea*. (Courtesy, Ontario Department of Lands and Forests.)



may be favorable, but beyond an optimum limit the large animal becomes clumsy, unwieldy, and at a disadvantage in competition with smaller and more agile animals. In all the vertebrate Classes except the Cyclostomata, there have been groups whose members distinguished themselves from others of the Class by attainment of relatively great size. Some ancient amphibians were very much larger than the largest existing amphibian, the 5-foot Japanese salamander. Such gigantic animals as some of the dinosaurs and the South American ground sloths became extinct long ages ago. In more recent times, contemporary with early man, the super-elephantine mammoth and mastodon and the largest known birds, the moa of New Zealand and the elephant-bird (*Aepyornis*) of Madagascar, came to their end. Exceptional are the whales. So far as is known, cetaceans now living include the largest animals that ever existed. Whales are a very ancient race. Their persistent endurance long after the giants of all other vertebrate Classes have passed out is doubtless due to their aquatic mode of life. Ocean-going whales can operate successfully at a vastly larger size than would be practicable for a land animal. For analogous mechanical reasons, it is not practicable to build an automobile as large as the motor ship *Queen Mary*.

#### SPECIALIZATION AMONG MULTIPLE ORGANS

Evolution within a certain group of animals is necessarily the summation of consistently correlated adaptive changes in the constituent organs of the individuals in the group. Some organs of an animal exist in multiple; e.g., vertebrae, teeth, aortic arches, integumentary glands, glandular derivatives of the pharynx, etc. In the evolution of such multiple organs, some noteworthy peculiarities are to be seen.

In a *group of animals*, adaptive diversification is accompanied by *increase in number of individual animals* and in the *extent of their distribution*. In the evolution of a group or series of *multiple organs*, primitively all alike, more or less diversification occurs, but it is commonly associated with *decrease in number of organs* and *restriction in the area of their distribution*. The decrease in number of organs is correlated with increase in the size of the individual organ. For example, in the more primitive fishes teeth are numerous, small, all alike, and widely distributed over the oral surfaces. In most mammals they are relatively few and large, differentiated into incisors, canines, premolars, and molars, and restricted to the jaws. And again, in fishes numerous small mucous glands are distributed over all the oral surfaces. In mammals many small scattered oral glands persist, but the secretory functions of the oral surfaces are mainly assumed by a few pairs of

massive salivary glands which are definitely localized and physiologically diversified.

#### REPETITIVE RADIATION

One of the most characteristic properties of "Life" is its propensity for increase. Organisms grow—both in ontogeny and in phylogeny they increase in size and differentiation. They multiply in number, expand their habitats, push themselves along their ramifying lines of specialization into every spot which can, by any trick of adaptation, be made habitable. The vertebrates vividly illustrate this. Fishes, already widely dispersed in the world's waters, produced a line of descendants which went ashore and achieved an amphibious life. Some "amphibians" became wholly terrestrial. Reptiles and mammals began their careers as land animals, but in the course of time some members of each class reverted to amphibious or even wholly aquatic life, retaining lung-breathing and, in the case of reptiles, the necessity of breeding on land or else becoming viviparous. The ichthyosaurs may have been viviparous. Along other lines of specialization, reptiles went aloft and achieved flight as pterosaurs or as the much more highly specialized birds. Mammalian bats likewise invaded the air. Having acquired a highly efficient mechanism of flight, some birds came down to earth, suffering reduction of wings, and became ostriches, kiwis, dodos, and various other flightless birds. The extreme of reversion to ancestral habitat occurred when birds, descended from fishes via amphibians and terrestrial reptiles, resorted to aquatic life and, in such birds as penguins, became in some respects the avian equivalents of fishes.

Typically, fishes are aquatic, amphibians are amphibious, reptiles and mammals are terrestrial, and birds are aerial. But it is not straining the truth too much to say that each of the five groups has some representative on all three of earth's habitable levels, water, land, and air.

Flying fishes, using the greatly expanded pectoral fins as wings, are better fliers than some flying birds. Some fishes are capable of locomotion on land. Certain small fishes (e.g., the "mummichog," *Fundulus*), if left in a pool as the tide recedes, will travel, by flapping motions of the body, across the beach and back into the ocean. In southern Asia is a small fish (about 8 inches long), the climbing perch (*Anabas scandens*), which is able to make long sojourns out of water. Complicated expansions of certain of the visceral arches greatly increase the surface of the subopercular space. These expansions, covered by a highly vascular membrane, provide for aerial respiration while the fish is out of water. According to accounts which seem to be trust-




FIG. 604. Flying fish, *Erexocoetus volitans*. (Courtesy, Brehm: "Tierleben," Leipzig, Bibliographisches Institut.)

worthy, the fish will literally "drown" if compelled to remain in water. Coming out for an occasional airing is necessary for survival. The terrestrial locomotion of *Anabas* is unique. The chief locomotor organs are the gill-covers (opercula), whose edges are spiny. By moving an operculum alternately inward and outward, its spiny edge engaging the substratum, the fish is able to execute an obliquely sidewise hitching progress along the beach. Movements of fins and tail may assist. By the same method of progress, it even clambers to a height of 6 feet or more up the rough surface of the trunk of a palm tree. Pursuit of insects as food is the alleged incentive for these aerial excursions. Other notably amphibious fishes are the gobies of the coastal regions of southern Asia and of Africa, which stay out of water for hours during low tide. The "mud goby" (*Periophthalmus*), a fish about 6 inches long, has short stout pectoral fins by use of which it hops nimbly along the beach foraging for small crustaceans, mollusks, and insects. It is said to leap several inches into the air and, by means of the fins, grasp a mangrove root (exposed at low tide). Having thus gained "foothold" on a mangrove, it may clamber up to a height of 2 or 3 feet (Fig. 605).

Even the Amphibia can claim an aerial animal, a "flying frog." This tropical frog has long digits with webs of skin between them. It makes long sailing leaps, the digits being spread apart so that the webs facilitate gliding through the air. In the evolution of flight, such gliding was probably the initial stage. In reptilian pterosaurs and mammalian bats, webs of skin stretched between digits are an important part of the wing.

Finally, among Reptilia, chiefly terrestrial animals, are (or were) aquatic ichthyosaurs, plesiosaurs, crocodilians and sea turtles, and

flying pterosaurs. Among Mammalia, chiefly terrestrial, are cetaceans, sirenians, seals, and other aquatic animals, flying bats, and such gliders as the "flying" squirrel, "flying" phalanger, and colugo.




FIG. 605. Gobies, *Periophthalmus*. (Courtesy, Brehm: "Tierleben," Leipzig, Bibliographisches Institut.)

Among Aves are numerous flightless terrestrial birds and many aquatic birds, some of them incapable of flight.

As one vertebrate Class succeeds another, this radiating pattern of

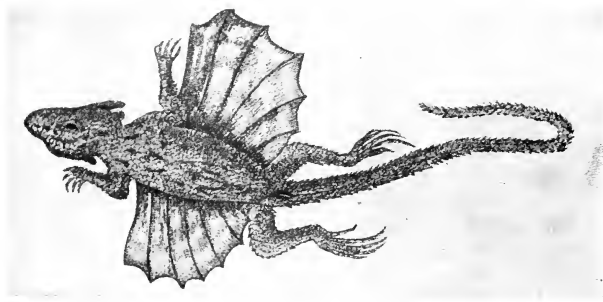


FIG. 606. Flying lizard, *Draco volans*, of the Indo-Malayan region. Like the "flying" squirrel, this lizard is merely a glider. The gliding planes are extensive lateral outfoldings of skin supported by elongated ribs. (After Nicholson. Courtesy, Galloway and Welch: "Text-Book of Zoology," Philadelphia, The Blakiston Company.)

lines of specialization repeats itself, not only along the three major lines of adaptation—aquatic, terrestrial, and aerial—but also along various minor lines such as lead, for example, to **fossorial** and **ar-boreal adaptations**. Many mammals, reptiles, and amphibians burrow. Some birds (motmots, todies; some owls, kingfishers, and swallows; and many petrels) inhabit burrows either dug by themselves or formerly the homes of other animals. Even some fishes (e.g., *Protopterus*, the African, and *Lepidosiren*, the South American, lungfish) during the dry season burrow into sand or mud at the bottom of the water. And many human primates spend most of their lives in cellars, mines, or tunnels. In the world's trees are most birds, but also monkeys, squirrels, sloths, anteaters, opossums, and other mammals, many lizards and snakes, some frogs and toads, and upon occasion may be found an Asiatic climbing perch 6 feet up the trunk of a palm, and gobies taking an airing among the mangroves while the tide is out.

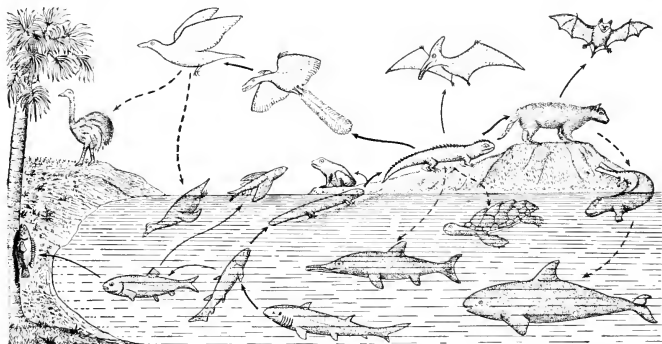


FIG. 607. Repetitive radiation. The heavy arrows indicate the main line of vertebrate evolution: from sharklike fishes (at middle bottom of figure) to bony fishes, then amphibians which emerged onto land and went on to terrestrial reptiles, thence along one line to terrestrial mammals and along another to flying reptiles with feathers—birds.

The light unbroken arrows indicate lines of specialization which are off the main line of evolution: e.g., from crossopterygians to teleost fishes, some of which make excursions ashore (climbing perch, *Anabas scandens*) and others essay flight; from terrestrial reptiles to flying reptiles without feathers (pterosaur); and from terrestrial mammals to flying mammals.

The broken arrows indicate reversion to ancestral habitat: aquatic ichthyosaurs and turtles from terrestrial reptiles; whales from terrestrial mammals (the "connecting link" in the figure is hypothetical); flying birds to terrestrial birds (ostrich) and amphibious birds (penguin).

The figure should have included flying frogs, and men in automobiles, submarines, and airplanes. Net result in our present world: all are everywhere, in water, on land, and in air.

The tendency of "all to be everywhere" is illustrated in Fig. 607.

#### "DEGENERATION"

Specialization by reduction or "degeneration" of structures seems to have occurred along many lines in the vertebrate series. The results of it greatly complicate the problem of discovering genetic relationships. In many instances, it is difficult to ascertain whether some weakly developed organ is at an early stage of progressive evolution or at a late stage of regression. This is especially true of the relation between cartilage and bone. It has long been a widely accepted idea that primitive elasmobranchs had an all-cartilaginous endoskeleton and that this primitive condition persists in modern shark-like fishes. It would then seem to be reasonable to regard the "ganoid" fishes, with their more or less incompletely ossified skeletons, as intermediate between elasmobranchs and the bony Teleostei. In modern urodele amphibians such as *Necturus*, there is much persistent embryonic cartilage in the adult skeleton. This invites interpretation as a primitive condition. The widely accepted, but perhaps overworked, idea that "ontogeny repeats phylogeny" interprets the cartilaginous skeleton of the vertebrate embryo as a heritage from shark ancestors. There is, however, much paleontologic evidence that the endoskeletons of early fishes and amphibians were ossified to a much greater extent than those of modern "ganoids" and amphibians, indicating, therefore, a reduction or "degeneration" in the degree of ossification. A question is raised, then, as to the phylogenetic status of modern elasmobranchs, "ganoids," and amphibians (especially the urodeles). To what extent do they retain the ancient primitive characteristics, and how far may they have undergone a regressive evolution which has resulted in anatomic characteristics deceptively primitive in appearance? The solution of these problems awaits more evidence from paleontology.

#### THE VERTEBRATE NAMED (BY HIMSELF) HOMO SAPIENS

All Orders of mammals except two are definable on the basis of highly specialized anatomic characteristics which are of predominant importance in the adaptation of the animal to its particular habitat and habits. One of the exceptional Orders is the Insectivora. They are commonly described as "generalized" or "primitive"—they are "just mammals." It is true that the mole is specialized for burrowing, but its digging claws and degenerate eyes are features of the mole as a fossorial animal and not of the Order as a whole. The hedgehog's sharp spines are specialized hairs, but among Insectivora they are confined to

hedgehogs. The other exceptional Order is Primates. The search for specialized features whereby the Order may be defined yields only such apparently trivial things as nails instead of claws or hoofs on the digits, and the opposable pollex and hallux—and they are not opposable in all primates. The primates have no anatomic characteristic which, in its high degree of specialization and in its prominence as a distinctive feature of the animal, is equivalent to the one-toed foot of a horse, the dentition of a rabbit or sheep, the wings of a bat, the trunk of an elephant, or the flippers and tail-flukes of a whale. This lack of conspicuously distinctive anatomic peculiarities characterizes not only the lemuroid primates but also the anthropoids, even the "great apes" and man.

Measured by the standards applied to members of other Orders of mammals, the anatomic differences between a man and a chimpanzee are trivial. They are less than the differences between the "great apes" and the South American monkeys. That there is something quite distinctive about the external aspect of the human body is not because it has some very prominent peculiarities. It is the collective result of many features, no one of which is of great anatomic magnitude. Form of trunk, shape of head, absence of external tail, proportions of arms and legs, upright posture associated with bipedal locomotion, restricted distribution of hair, facial features, form of auditory pinnae—in none of these particulars is there any extreme specialization peculiar to the human body. But, from the perhaps prejudiced human point of view, there seems to be a certain consistency and harmony among these numerous particulars, and the whole assemblage of them imparts to the body an appearance so characteristic that even a person without biologic training readily distinguishes between a man and a chimpanzee, although he may not be able to distinguish between a salamander and a lizard—members of different Classes of vertebrates.

#### MAN'S RELATIONS TO HIS ENVIRONMENT

Man is now the world's dominant animal. In this fact we are confronted by an anomaly. Throughout the history of vertebrates prior to the Age of Man, dominant positions have been attained only by the more highly specialized animals of a given period. Of existing mammals, the unspecialized insectivores survive by retreat. But the human primate, conspicuously lacking in highly specialized anatomic characteristics, is dominant. How has this dominance been achieved?

The **brain** of the more primitive or lemuroid primate differs in no important way from those of insectivores, rodents, and marsupials. The anthropoid brain closely resembles that of carnivores and ungulates. Its relative size, however, is somewhat greater and there is a

notable increase in the complexity of the convolutions of the cerebral cortex. In terms of gross anatomy, these are not "conspicuous" differences. But the greater size implies a larger number of neurons and an increase in the complexity of their relations. In terms of function, these differences may be highly significant in relation to the animal's behavior, because it is the nervous mechanism of the cerebral cortex which is somehow peculiarly concerned with the animal's capacity for effecting reactions which imply something approaching or attaining intelligence.

The **opposable thumb** has been referred to as a minor structural characteristic, and so, in itself, it is. To the arboreal primate, however, it is one of great importance. But when an ape, standing on the ground, grasps a stick and uses it to poke, hit, or move an object, something unique in mammalian behavior appears. The animal is obviously aware that he is not in a tree and he makes no attempt to swing from the stick as if it were an attached branch of a tree. He uses it in a definitely purposeful way as a tool. It requires no strain on the imagination to think of primitive man using his opposable thumb, inherited from arboreal ancestors, in grasping sticks, clubs, and stones which served him as weapons and tools. Later he fashioned crude implements of stone, then of metal. In the course of many thousands of years, his weapons and tools became more and more elaborate. By use of simple tools he made more complex tools and machines. He devised machines to make tools and to make parts of other machines. Early he learned how to produce and use fire. He availed himself of the energy of moving water and of wind and of the energy released by combustion. Lightning led him to the utilization of electric energy, and most recently he has found a way of releasing incredible and appalling energies by disruption of atomic structure. He has devised machines to serve his every need and he has created for himself a great many new necessities. The present has come to be a "Machine Age."

Man was primitively a terrestrial animal, but he never acquired more than moderate facility in locomotion on land. He is a poor runner as compared to many quadruped mammals. But he has found ways of compensating for his locomotor mediocrity. He attained the speed of a horse by the simple expedient of sitting astride the horse's back. Then he devised wheeled vehicles drawn by horses. Later, replacing horsepower by engines developing the power of many horses, he rides in self-driven wheeled vehicles which far outspeed the cheetah. Man has no aquatic adaptations. Compared to a seal or dolphin, he is a slow and clumsy swimmer. But he puts himself into a somewhat fish-shaped boat and his pectoral limbs, extended by oars grasped by his prehensile hands, serve as locomotor fins. Or, always seeking ways of avoiding



work, he rigs sails and allows the wind to drive his boat. He builds boats much larger than whales and, as powerful machines have become available, he effects speedy movement by installing at the posterior end of the fish-shaped craft an engine-driven screw propellor analogous to, but not homologous with, the locomotor caudal fin of a fish. His submarines enable him to invade the deeper realm of fishes. As for aerial locomotion, man is not even a good jumper. But here again he brings to his aid machines, and his airplanes carry him at speeds which make the swiftest bird a mere flying tortoise, and he soars to stratospheric heights quite inaccessible to birds.

Mammals other than man are more or less restricted to certain habitats by climate. Man in his natural state could tolerate only a moderately warm and equable climate. Some primitive men found refuge from weather by living in caves. In the course of time he contrived artificial shelters increasing, through the ages, in their elaborateness and in capacity for giving him physical comfort. For endurance of cold, mammals need thick fur. Man extended his habitat into cold regions by the simple device of covering his own body with skin and fur removed from other mammals, and, by use of fire, warmed his shelters. Modern man, by manipulation of an elaborate variety of machine-made clothing and by mechanical "air-conditioning" of his intricately complex and highly mechanized artificial caves, is able to live in all zones and climates of the world.

Most mammals are restricted to a particular diet to which their teeth and digestive organs are adapted. Human alimentary organs are not specialized for a particular diet. Man is omnivorous and his food varies greatly according to the region, climate, and state of human culture in which he lives. Machines and chemical manipulation have come to play an important part in the production and preparation of his foods.

In the foregoing brief and incomplete sketch of man's relations to his environment may be found the solution of the anomaly of world dominance by an anatomically unspecialized animal. Survival and success of any group of animals require a state of fitness between animal and environment. "A square peg does not fit a round hole." A fit may be made either by rounding the peg or squaring the hole. An animal may acquire anatomic specialization adapting it to a particular environment and mode of living. There is no conceivable way whereby an environment could adapt itself to a particular animal. In any case, the animal could not survive while waiting for the environment to change. But the animal may act upon its environment so as to modify it favorably. The evolution of most mammalian Orders has followed




FIG. 608. (Left) Paleolithic drawing of elephant showing heart; from the cavern of Pindal, Asturias, northwestern Spain. (Right) Magdalenian drawings of bison with arrows embedded in the heart; from the cavern of Niaux on the Ariège, southern France. (After Cartailhac and Breuil. Courtesy, Singer: "The Evolution of Anatomy," New York, Alfred A. Knopf, Inc.)

definite lines of specialization, each resulting in a type of mammal anatomically and physiologically highly adapted to a particular environment and mode of living. The group attains a high degree of success, but within the limitations imposed by its specialization. Such relatively unspecialized animals as the insectivores live where they best can. Their continued survival is due partly to retreat from competition and partly to great fecundity.

Primates have hit upon an entirely unique line of specialization. Retaining, with only minor modifications, the primitive "generalized" structure of their insectivore ancestors, they act upon their environment in such a way that it not only more readily yields them the primary necessities of living, but so that, in ever increasing degree, they become able to extend their habitats and utilize energies external to their bodies in the performance of a great diversity of activities of a sort never before achieved by any animal.

#### THE PRIMATE LINE OF SPECIALIZATION

The primates have reversed the old order of evolution. From the most ancient invertebrates onward, it has always been a tedious process of structural change requiring thousands or millions of years for animals to emerge from aquatic to effective terrestrial living or to acquire capacity for flight. Modification of environment has been limited to



FIG. 609. Michelangelo's "Creation of Man." (Photo by Ewing Galloway, New York.)

such simple and instinctive activities as building nests and digging burrows. But when primates began to grasp sticks and stones and use them as tools, the start was made toward the automobile, motor ship, and airplane, and the telephone, radio, and television. This modification of environment is as truly an evolution as the transformation of fins to land legs or legs to wings, but with an important difference. As organs of locomotion, legs replace fins and are genetically derived from fins by a process of alteration. Automobiles to a large extent replace human legs as a means of locomotion, but they are not derived from legs. From the "horseless carriage" to the 1950 automobile, there has been a radical evolution, but there is no "genetic" or physical continuity of any sort between one automobile and another. Construction of an automobile involves use of machines and tools and manual labor, all in accord with a plan represented on a blueprint or a drawing originated by the man who designed the model. The design was the product of prolonged and concentrated "thinking" about possible improvements in the old model. The automobile is derived, not from legs and not from a preëxisting automobile, but from the human brain. More precisely, its substance is environmental, but its pattern somehow emerges from cerebral activity. Here another aspect of primate evolution confronts us.

Many tens of thousands of years ago, animals possessing skeletons essentially like those of modern man made outline drawings of the contemporary mammoth on the stone walls of European caves. It is, of course, purely an assumption that the drawings were made by the possessor of the manlike skeleton, not by the mammoth. Granting the reasonableness of this assumption, the drawings have great significance. The lines were cut into the stone. The prehensile hand used a

tool. The movements of the hand were determined by motor impulses originating in a central nervous system whose brain had received, via the optic nerves, sensory impulses derived from a retinal image of a mammoth. Presumably the drawing was made from a stored mental image. It is not likely that the mammoth stood by and posed for the picture. It is not reasonable to regard the act of drawing as instinctive or automatic. Many other mammals possessing a well-developed cerebral cortex have seen elephants but have never made pictures of them. That early human act was unique—something new in the history of the world's life. It had no reference to physical needs of the body. It reveals the emerging of faculties to which we give such names as "imagination," "purpose," "constructive initiative," "intelligence." In that simple act of the cave man, his tool-grasping hand guided by a central nervous mechanism capable of mediating these incipient faculties, may be discerned the basic factors in the further evolution of the human primate. Crude vocal sounds came to be employed as means of communication. Marks or lines made on smooth surfaces came to signify certain objects or sounds, and so began communication by writing. With the advent of machines, writing was replaced by printing, but both the machine and that which it prints owe their origin to the imaginative and creative faculties which find outlet via the human brain. Long ages after the cave man, the hand of Michelangelo, grasping a brush and guided by an imagination transcending known reality, depicted on the walls of the Sistine Chapel the creation of man. Another hand, its tool a pen, traced the lines of Shakespeare's plays; another set down the notes of Beethoven's symphonies.

The primate line of specialization involves primarily the hand and the brain. Creative and adaptive modification of the environment exempts the remainder of the body from any urgent need of changing (which must not be construed as implying that evolutionary change takes place in response to need). Locomotor mechanisms enable man to transport himself on all three of the earth's habitable levels—water, land, air—at a degree of speed and comfort which could not possibly be attained by any anatomic modification of his body. If improved sight is needed, it is provided by microscope and telescope. Range of hearing is extended by telephone and radio. The human voice is mechanically amplified. By use of numerous instruments, musical and otherwise, a variety of sounds other than vocal may be enjoyed or endured. It has accordingly been predicted that, in so far as bodily functions are replaced by external mechanical and chemical means (e.g., as when a meat grinder is used instead of teeth), the organs thus relieved of full function will ultimately suffer regressive evolution or "degeneration." This is an interesting possibility, but the prediction

rests upon an insecure biologic foundation. The role of "use and disuse" in evolution of organs is highly problematic.

The primary factor in the evolution of the human environment is somehow associated with the brain. To what extent, if any, structural changes have occurred in the brain since the earliest days of man it is impossible to say. Human evolution is essentially an evolution, not of organs, but of ideas which find their expression in adaptive modification of the physical environment, and in the structure and relations of social and political groups of human individuals.

#### VELOCITY OF HUMAN EVOLUTION

In contrast to the evolution of bodily structure, human evolution is progressing at tremendous velocity. Some reason for this may be discerned. Bodily changes acquired during the lifetime of an individual animal are, so far as is known, not inherited by the offspring. Results of training and learning by experience are not transmitted to offspring. A dog may be taught tricks but the puppies must likewise be taught. An innate capacity for learning tricks is inherited, but not the tricks. Protoplasm is chemically a highly unstable substance, but the structure of the organisms which are constituted of protoplasm possesses an extraordinary degree of stability. Structural adaptations which have somehow become fixed or determined in the germ-plasm are not easily and quickly changed. Mutations occur, but it is safe to say that no single mutation produced a first amphibian, or a feather in place of a reptilian scale. It is likely that climatic or other environmental changes caused the downfall of the mighty dinosaurs and other Mesozoic reptiles, unable to adapt themselves even though the changes must have taken place very slowly over a period of many tens of thousands of years. The processes of embryonic development are especially conservative. The fishlike characteristics of the early embryo have presumably persisted for hundreds of millions of years from the earliest days of vertebrates down to the mammals and birds of the present.

Whereas bodily characteristics acquired by an adult animal are not transmitted to offspring, environmental structures and conditions produced by a human individual or group are "inherited" by the succeeding generation. It is not necessary for the new generation to rediscover how to use fire and make electricity, or to reinvent motors and telephones. The child of the cave man perhaps played with a toy club. The modern child's toys are models of automobiles, airplanes, and telephones. During the educational years of childhood and youth, the new individual acquires (to the limit of his intellectual capacity) knowledge of all that mankind, from cave man to the present, has done to acquaint himself with his environment (science), to make it serve

his needs and desires (technology), and to impress upon it—in written or printed language, painting, or otherwise—a record of his ideas (philosophy, religion, literature, and all the arts). Thus the new individual may arrive at adulthood in full possession of all that human evolution has acquired. He then enters the creative part of his life equipped to make new discoveries and inventions or to impress upon the environment a record of some new idea.

An important peculiarity of human evolution is that anything created by one individual may be imitated, possessed, or used by his fellow individuals. A newly evolved bodily characteristic can be transmitted only to the offspring. But one man invents a telephone and within a few years it is possessed and used by millions of his contemporaries. Also, there is an acceleration in the rate of human progress. The more complex the man-made environment becomes, the more opportunities it provides for further modification, and, as population steadily increases, there is progressive increase in the number of minds working upon it and they work upon all parts of it at once.

It has been said that the "higher" vertebrate, in the course of its embryonic development, "climbs its own family tree" ("ontogeny repeats phylogeny"). So far as bodily structure is concerned, they may climb the same tree from its primitive chordate roots upward, generation after generation for thousands or millions of years, never getting any higher. But in the case of human evolution, whose visible and tangible products are environmental, the thing that is climbed is a ladder rather than a tree. Each human generation extends the ladder upward and adds a rung. Each new generation begins at the top rung, where the preceding generation left off, and adds a new rung. Thus a century or even a decade may witness substantial progress in human evolution although no important changes have occurred in the body during thousands of years. Thus human environmental evolution, compared to evolution of bodily structure, proceeds at high velocity, its environmental products are rapidly cumulative, and the process is self-accelerating.

#### EPOCHAL PERIODS IN VERTEBRATE EVOLUTION

In evolution of the vertebrates may be recognized certain critical events, each fraught with far-reaching possibilities. The first was when animals whose ancestors for millions of years had been fishes emerged from water and acquired an amphibious foothold upon land. The second was when reptiles replaced external water with a fluid-filled amniotic cavity in which its embryo might live, and replaced larval gills by the respiratory allantois, thus completing the emancipation of

vertebrates from the necessity of living at any time in or near bodies of water. The third was when feathers enabled reptile-like animals to achieve aerial locomotion. Each of these three great events, all depending on structural modification, required tens or hundreds of thousands of years for its consummation. Then, in comparatively recent geologic time, something unique happened. Some prehuman or apelike primate used an external object as a tool. Prior to that, action upon the environment had been by direct impact of tooth, claw, or nail. There may have been a long period of vague groping and occasional accomplishment of unforeseen results by random wielding of some object grasped by the hands. But eventually came a time when a primate purposefully, and with prevision of the result, interposed a stick or other implement between his hand and the object to be affected, and so the first step toward the "Machine Age" of man was taken. It may have happened in a second, but it is impossible to say what long ages may have been required for the building up of the mental faculties of which the act gives evidence, and for the development of the cerebral mechanism concerned in their mediation. However that may have been, that simple act announced that the vertebrates, having long since made conquest of water, land, and air, had arrived at the threshold of a new domain. Thenceforth evolution was to proceed in the realm of ideas.

Has primate intelligence increased since that day when a tool was first used? We regard the invention of the telephone and radio as great achievements. But it must be remembered that each of these marvelous modern inventions has developed slowly and step by step in an environment already rich in a stimulating variety of mechanisms of the same general sort. The first primate tool was a complete innovation. It is even possible that, in an environment quite devoid of tools, it may have required nearly as much imagination to conceive the idea of definitely fashioning an implement of wood or stone as it did to think up, one by one, the numerous gadgets which collectively constitute a telephone. However, in view of the fact that, from primitive insectivore up to higher primate, there has been a steady advance in the degree of development of the brain and a corresponding progress toward the achievement of intelligent behavior, it seems fair to assume that mental faculties have continued to improve since the days of the first toolmaker. But it is a slow process, presumably because increase of intelligence must be linked with structural changes in the brain. The content of the human mind, knowledge, has vastly increased, but there is no convincing evidence that intelligence has increased within the relatively short period of recorded human history. Aristotle's brain was certainly quite as good as any modern brain.

## WHAT? WHENCE? WHITHER?

Natural Science, of which Comparative Morphology is a field, comprises man's endeavors to know and understand his environment, even to the remotest stars, and himself—if it is possible for anything to "understand itself"? For long ages past, his curious mind has been perplexed by three questions: What am I? Whence came I? Where am I going? Comparative Morphology has given a partial answer to the first question. Man possesses the essential peculiarities of all animals from *Ameba* upward. His embryonic notochord, pharyngeal pouches, and hollow dorsal neural tube make him a chordate. Hair and mammary glands make him a mammal. Nails on the digits, an opposable thumb, and otherwise a conspicuous lack of highly specialized organs make him a primate. Numerous trivial anatomic characteristics distinguish him from apes. His preëminent peculiarity is his capacity for acting constructively upon his environment. This action depends upon his possession of a brain whose neurons are so linked together as to make possible reactions which manifest mental faculties such as we designate as "purpose," "imagination," "intelligence." At this point our knowledge stops. The relation of mental faculties or "mind" to nervous structures is a baffling problem. Such a simple statement as "I made up my mind to cut down the tree" seems to imply that a human individual is a trinity of entities. There is an "I" that "makes up" something which it calls its "mind," and the tree is cut down by the body. Comparative Morphology has learned much about the body. The psychologist describes states of mind and their relations to the sensory nervous impulses which precede them and the motor impulses consequent upon them. The philosopher contemplates the whole trinity in a brave effort to make it understand itself. He offers us numerous philosophies from which we may choose according to our individual tastes, but no one of them seems to give us anything more intelligible or satisfying than the elemental "I am that I am."

To the second question—"Whence came I?"—Comparative Morphology has given an answer whose correctness cannot reasonably be questioned. No man should feel it ignominious to have come from a long line of subhuman ancestors. Far from causing him to feel belittled, knowledge of it should give him higher esteem and more consideration for his fellow vertebrates. In some matters of behavior, he could profit from their example. If the hundreds of millions of years of vertebrate history could be contracted to the dimensions of a modern moving picture, its appearance on the screen would be a mighty spectacle, surpassing in its dramatic power and rich in inspiration to us who seem



to be destined to play the leading role in the next act of the drama. Where will that next act take us?

The old saying, "History repeats itself," is exemplified in the history of the vertebrates. In the early days of Amphibia, the group began to radiate along several and various lines of specialization, but retaining in all of them the essential characteristics of amphibians. Many of the resulting groups became extinct; a few have survived to the present. But along another line amphibian characteristics were replaced by those of reptiles. In the early days of Reptilia, diversification set in and produced a temporarily dominant reptilian fauna, of which only a feeble remnant survives. But along one line reptilian characteristics were replaced by those of mammals. In both instances, the origin of reptiles and that of mammals, the new type of animal was superior to the old in its ability to extend the range of its habitat and attain a variety of modes of effective living. Then, in the early days of Mammalia, specialization set in along the many lines leading to the numerous and highly diverse mammalian Orders, of which some became extinct and many survive to constitute an important part of the world's present vertebrate life. But, along one line, mammals of an ancient and primitive type persisted even down to the present without undergoing any conspicuous anatomic specialization except for such sporadic instances as the burrowing adaptations of moles or the spines of hedgehogs. Then, in comparatively recent times, certain descendants of these lowly insectivores acquired a new trick of adaptation—adaptation of the environment to meet the needs of a relatively unspecialized body. Along this novel line came the now dominant human primate.

There is no reason to think that evolution has stopped or that man is its finished and final product. His ever-increasing command of his environment is a biologic evolution as truly as any change of bodily structure. The type of evolution peculiar to man—i.e., evolution of ideas which become embodied in environmental mechanisms and structures or otherwise imprinted upon the environment—is obviously progressing at a rapid and accelerating rate. The present human population of the world exhibits the characteristics of a group at an early stage of evolution, a stage of progressive change and of diversification. Numerous races have already been differentiated, distinguished by differences in pigmentation of skin and by small anatomic differences. There is a very wide range in degree and types of human intelligence. Some existing individuals could hardly be expected to poke something with a stick unless shown how. At the upper extreme are brains which give us higher mathematics and a knowledge of the atom and the Milky Way. Much more significant than the physical differentiation of races is the diversification of ideas, because differences

of this latter sort lie within the line of specialization peculiar to the evolution of the group. Man is gregarious and social. He organizes himself into groups, small and large, social, economic, religious, political, national. His nations, to a large extent but not entirely, are racially distinct. Each group stands for a set of ideas. Among these ideologies there is all manner and degree of conflict, ranging from friendly debate to cataclysmic world wars. The human race is in a state of flux. It is a seething ferment of clashing ideals and objectives. All of this is in utter contrast to what we see in existing races of other mammals. They seem to have arrived at a state of biologic equilibrium. The carnivore must, of course, take his food, but as a rule mammals of a kind do not form groups to make war upon one another. So far as they may have anything approaching an idea, they are all in fairly good agreement about it and there is a high degree of uniformity in their well-ordered behavior. Mammalian groups other than primates are phylogenetically relatively old. The human race is new. It is now in a plastic and formative stage. It has not "found itself." It has already performed miracles in adaptation of the environment, but it is torn by internal disharmonies.

Vertebrate history is repeating itself again. The human race is in a phase of evolution analogous to that when, in the early days of amphibians, reptiles began to emerge; or to that early formative period of reptilian history whence the theromorphs opened the way out toward mammals; or, yet again, to that later period when, in a world of diversifying mammals, a little remnant of the primitive stock somehow held itself aloof from the general tendency toward anatomic specialization and, in the course of long ages, built up the nervous mechanism which eventually put tools into the hands of primates.

During this present century, the internal disharmonies of the human race have become especially devastating. Dire prophecies are rife. We are told that human civilization is to be destroyed, that man will annihilate himself from the face of the earth, and that the world of the future will be dominated by insects. If the future may be foreseen in the light of the past, it would seem that a past of a half-billion years, more or less, should afford some reasonable ground for prophecy, and especially so if any consistent trend in that long past can be seen.

There is certainly such a trend, and it is most clearly discernible in the history of the chordates. From primitive chordate to man, it is a story of continuous progress. It is difficult to imagine any sort of adaptation to environment which has not been successfully achieved by some vertebrate. Finally, as if possibilities of structural adaptation to environment had been exhausted, primate mammals have begun to adapt the environment. It is true that many great and once success-

ful groups of animals have become extinct, but they have always been succeeded by something possessing even greater possibilities. There has been no backsliding, so far as the main trend is concerned.

A point of special significance is this: the line of evolution destined to produce the successful and dominant animal of a future age is initiated during the early and formative period of the race which becomes the dominant animal of the age preceding that. The human race, precociously in a dominant position, is still in its formative stage. By analogy with what has successively happened in the cases of amphibians, reptiles, and mammals, (1) some groups of a diversified human race, unable to achieve enduring harmony with their human environment, may expect to become extinct; (2) other groups may arrive at a state of mutual tolerance and equilibrium and survive indefinitely; (3) during the formative stage of the race may be initiated a new line of evolution destined to produce something better than present man—a "superman."

The past affords no ground for the prediction that the human race will become a "dead end" of evolution. If man does not go on indefinitely, he will at least give rise to something better. There is no reason to expect anything radically new to emerge from any existing group of mammals other than primates. They are all phylogenetically "old." As for a "world of insects," it is inconceivable. Insects have had their chance. They are at or near the limit of their specialization. Their instinct cannot compete with intelligence. There are "social insects," but they can never attain a world organization—an insect "UN."

The human race in its present state has many characteristics which are not fit to survive. Average intelligence is low. The better minds acquire knowledge and devise mechanisms, but the race as a whole lacks the intelligence to use the knowledge and mechanisms to its highest advantage. For example, the radio could bring daily to every human individual the best that human minds have produced in literature, drama, and music, but the usual day's program falls deplorably short of realizing these possibilities. Tremendous stores of energy, both environmental and human, are squandered in periodic outbursts of destruction. Man has an unreasoning passion for size. He wants to produce the biggest thing of its sort ever made; he delights in vast cities, "skyscrapers," and jet propulsion at a thousand miles an hour. In this matter, he should give heed to the dinosaurs. Increase in size may be overdone. Man's cities, viewed in their entirety, are impressive in their size and splendor. But the great majority of the inhabitants never see the city. Like moles in burrows, they spend their dull lives deep in the interiors of massive buildings, performing daily the mechan-

ized toil of factory, store, and office. Densely populated cities are especially favorable for the development of malignant spots which disseminate vice and crime. In general, they are biologically unhealthy. It has already been suggested that man is becoming a slave to his own machines. In several particulars, he faces the dangers of overspecialization. His insatiable thirst for wealth, power, fame, and dominance over his fellows is at the bottom of some of the most serious troubles of his race. Nations, motivated by these passions, become like carnivorous dinosaurs, putting their dependence on brute strength and crushing and devouring weaker nations.

The history of vertebrates gives man ample reason for confidence that his race will, in one way or another, go progressively onward. Throughout the history, that which was fit has survived as long as environment permitted and, meanwhile, it has given rise to something possessing greater potentialities. Throughout the welter of a reptilian world, certain small obscure quadrupeds lived their unobtrusive lives and survived while their dominant but stupid contemporaries, assisted by a changing environment, fought and starved themselves out of existence. It is possible that the future of primates may contain a parallel episode. By virtue of sheer brute strength and great number of individuals, temporary dominance may be achieved by human groups most of whose individuals are intellectually inferior, intolerant, devoid of altruism, and belligerent. It seems likely that, in the course of time, such mutually antagonistic and unadaptable groups, assisted by the economic consequences of overpopulation, may fight, crowd, and starve themselves out of existence. But meanwhile, living unobtrusive lives or surviving temporarily by retreat, some human minorities constituted of individuals of superior intelligence and finer ideals, esteeming truth, good, and beauty above power, speed, size, and vitiating luxuries and pleasures, will carry forward the main line of evolution.

The relatively near future of this biologic prospect may seem discouraging, or even terrifying, if we have at heart the welfare of generations soon to follow us. There is, however, a possible alternative. Primates owe their present position in the world to the fact that they inaugurated an entirely unique line of specialization. They did it unintelligently—we know not how, but it proved to be a line along which the highest existing degree of animal intelligence has developed. Having departed from traditional lines of evolutionary specialization, it may be possible for the human primate, using the intelligence which he has acquired, to break the precedent established by earlier vertebrate races which were relatively low in mental capacity. At the present moment, the human race seems to stand at a critical juncture in its history. The crucial question is whether it will go on blindly

and unintelligently, "letting 'Nature' take its course," as did the Mesozoic reptiles, or whether it is now in command of sufficient intelligence to control, at least in some measure, its own destiny. Diseases of the human body are to a large extent self-corrective. The body reacts by producing resistant and combative agencies which overcome the disease. Surgical operation is sometimes necessary. Similarly, human society may find corrective measures for the maladies which beset it. In acute cases, surgery may be necessary—removal of hopelessly vicious individuals or groups.

Do the great masses of the world's present human population possess the intelligence to distinguish between false prophets and truly wise leaders, farsighted as to both the past and the future? Are we now wise enough and capable of sufficient coöperative effort to plan a program of salutary racial hygiene which may be hoped to save our race from the necessity of undergoing the major surgical operation of "survival of the fittest"? A hopeful step toward an affirmative answer to this question was taken on July 22, 1946, when representatives of 61 nations signed the constitution of a World Health Organization. The constitution asserts that "Health is a state of complete physical, mental, and social well-being and not merely the absence of disease or infirmity." The functions conceived for the Organization include the following far-reaching projects: "to foster the ability to live harmoniously in a changing total environment"; promotion of mental hygiene, especially as to factors "affecting the harmony of human relations"; and "education to prevent the insanity of another total war and to destroy the basic causes of war." It must be remembered that vertebrate history teaches that "survival of the fittest" does not mean permanent survival of the biggest and most powerful. They that survive and go progressively onward are the most adaptable—most adaptable either by virtue of retention of some degree of structural plasticity, or else by possession of a nervous mechanism giving the animal superior capacity for effective and advantageous behavior.

Beyond question, man has a long and hard way to go in working out the salvation of his race. We of the present age have found that a little intelligence is a dangerous possession. It has brought us much knowledge. But, as a race, we need vastly more wisdom if we are to use profitably the knowledge and power which a little intelligence has given us. Judging by the past, man's intelligence will increase, but only very slowly. Along with his intelligence, he possesses (in greater or less degree, according to the individual) those mental states or attitudes which we designate as "altruism," "tolerance," "mercy," "justice," "sense of right and wrong." These are mental attributes which are, at most, only very doubtfully recognizable in any animals other than

primates. But they are effective biologic factors in that they may determine the survival or nonsurvival of human individuals and groups. All that is best in man will somehow go on. From micro-organism to primitive chordate and thence to man, there has been a steadily progressive increase in range of adaptation to the world's various environments, and primates made a tremendous step onward when they shifted the main line of evolution from structural adaptation of the body to modification of the environment and use of environmental energies to augment and supplement those of the body.

As determining factors in what may lie before him, man's most precious assets consist in that most recent evolutionary acquisition of the vertebrates—namely, the complex of mental attributes which we designate collectively as "ethical." These will serve, even more potently than his intelligence, to carry him through the tempestuous formative stage of his existence and bring him out into a well-ordered world. Intelligent coöperation must replace selfish competition and stupid collective brute force. Tolerance and respect for individual and national liberty must replace unreasoning insistence that all individuals and all nations accept one ideology. A world rich in variety of human cultures is vastly more interesting than the flat monotony of a one-idea world.

Each cell of the human body and the body as a whole are vitally interdependent. If certain of its cells become functionally deranged, the whole body may suffer illness. Misbehavior of the whole—e.g., as by ingestion of poisonous food—is detrimental to its constituent cells. A similar vital reciprocal relation exists between the human individual and his race. The welfare of the race is merely the collective welfare of its individuals. Mass misbehavior, as in world wars, is fatal to vast numbers of individuals and detrimental to all. Any system, political or economic, which enslaves and mechanizes individuals in order that a group may acquire dominance of some sort is inherently a failure. "All for one and one for all" is a sound biologic principle. In it, self-interest and altruism strangely coincide. The individual may expect to possess the right to life, liberty, and the pursuit (at least) of happiness only when he fully concedes the same right to his fellows—and the right to exercise that right stops at any point of impingement upon the right of another individual. The immediate welfare of the human race and the continuation of the upward progress of vertebrate evolution are the responsibility of every human individual. The main line of evolution has already been shifted from bodily structure into the realm of *ideas*. It is now becoming apparent that the next step must take us and our primate successors upward to the yet higher level of *ideals*.

The present classification of man as a primate mammalian chordate is based entirely on his bodily structure. The ideal of modern classification is that it should express genetic relationship and that it should be so devised as to indicate the points where major and crucial evolutionary steps have been taken—i.e., the initiation of important new lines of specialization. The primates took such a step. Their shaping of the environment to their own uses is perhaps the most radical step in the whole course of evolution. While it is not necessarily linked with bodily change except as to the microscopic structure of the brain, it is truly a line of evolutionary specialization. Man has already gone far enough along this line that a wide gap exists between him and his nearest allied vertebrates. Considered along with his environmental auxiliaries and appurtenances which have come to be a characteristic and essential part of him, man differs from other mammals vastly more than they differ from reptiles.

The time will come, and perhaps now is, when men should be assigned to an additional Class of vertebrates. If it were to be done now, it might be designated (the present classification comprising six Classes) as CLASS VII, ANTHROPOIDEA, using the name now applied to a Suborder. The lemurs and tarsiers should be left under Mammalia and recognized as an Order closely allied to Insectivora. The Order might best be called by the old name **Prosimii**, to suggest that its members have some faintly simian characteristics. The Prosimii, slightly apelike mammals, would then occupy a position analogous to that of the Theromorpha, an ancient Order of slightly mammal-like reptiles.

The CLASS ANTHROPOIDEA would necessarily be divided into two SUBCLASSES:

SUBCLASS 1, comprising the **Platyrrhina** (South American monkeys) and two FAMILIES of the **Catarrhina** (**CERCOPITHECIDAE**, Old World monkeys: **SIMIIDAE**, "great apes"), could be called **PROTOANTHROPOIDEA**—a group analogous to SUBCLASS PROTOTHERIA of Mammalia.

SUBCLASS 2, containing the present FAMILY **HOMINIDAE**. In some far-distant future, when man's social wisdom shall have so far caught up with his inventive intelligence as to justify the name for him, this SUBCLASS might be designated as **SAPIENTIA**.





# Index of Scientists' Names

(Exclusive of names which appear in legends of illustrations.)

---

Folios set in **boldface** type refer to portraits.

- Agassiz, Louis, **350**, 351  
Aristotle, 333, **334**, 335, 340
- Balfour, F. M., 350  
Bayliss, 215  
Bergson, 352  
Bonnet, 339  
Brooks, W. K., 350  
Buffon, 339, 341
- Cannon, W. B., 218  
Cope, E. D., 351  
Cuvier, 339, 342, **343**
- Darwin, Charles, 345, 346, 362, 363  
Darwin, Erasmus, 339, 341, **342**  
DeVries, 352
- Edinger, Ludwig, 703  
Eustachius, 338
- Fabricius ab Aquapendente, 338  
Fallopian, 338
- Galen, 335, **336**  
Gegenbaur, 348, **349**, 362  
Goethe, 339, 343
- Haeckel, Ernst, 298, **349**, 362, 363  
Haller, 339  
Harvey, William, 338  
Hatschek, B., 363  
Hertwig, Oskar, 350  
His, Wilhelm, 350  
Huxley, Thomas Henry, **346**, 348
- Lamarck, 339, 341  
Leeuwenhoek, 338  
Leidy, Joseph, 351  
Linnaeus, 339, 340  
Lyell, Charles, 351
- Malpighi, 338  
Marsh, O. C., 351  
Meckel, J. F., 339, 345  
Minot, C. S., 350  
Montgomery, T. H., 363  
Müller, Fritz, 349  
Müller, Johannes, 345, **346**
- Oken, 339, 343, 344  
Osborn, Henry F., 351  
Owen, Richard, 343, **347**, 348, 360, 363,  
538
- Rathke, 345  
Ray, John, 340
- Saint-Hilaire, Geoffroy, 339, **342**, 360  
Starling, 215  
Swammerdam, 338  
Sylvius, Jacobus, 336
- Von Baer, Karl E., 339  
Von Zittel, Karl, 351
- Wallace, Alfred R., 345, 346  
Weismann, 351, 352, 365  
Whitman, C. O., 351  
Wilson, Edmund B., 351  
Wolff, C. F., 339



# Subject Index

---

Folios set in **boldface** type refer to illustrations.

## A

- Aardvark, 745, **746**  
Abdominal cavity, 21  
  veins, **74**  
  walls, 91, **92**, 587, **588**  
Abducent nerve, 100, **163**, **164**  
Abductors, 94, 96  
Absorption, 155, 156  
Acanthodii, 421  
Accessory nerve, 168, 183, 481, 482  
Accommodation, 201, 533, 682, **683**, 684  
Acetabulum, 129, 130, **131**  
Acetylcholine, 190, 191  
Acinus (alveolus), 31, **34**  
Acoustic nerve, 166, 692, 715  
Aerania, 407  
Aerodont, 47, **48**, 52  
Aeromegaly, 226  
Aeromion, **132**  
Actinopterygii, 420, 425  
Adaptation(s), 230, 246, 299, 463, 782, 785  
  aquatic, **369**, 781  
  arboreal, 801  
  of birds, 556-558  
  to climate, 568  
  for flight, 504, 505  
  fossorial, 801  
  of hindlegs, **372**  
  of mammals, 568, 569, **782**  
  to pressure, 569  
  of teeth, 53  
Adaptive radiation, 366, **367**, 368-370  
Addison's disease, 217  
Adductors, 96  
Adipose tissue, **327**, 328  
Adrenal action, emergency theory of, 218  
  cortex, 217  
  medulla, 217, 218, **219**  
Adrenalin (epinephrine), 190, 218, 219  
Adrenals (adrenal glands, suprarenal glands), 190, 217, **218**, **219**, 220  
  development of, 217  
Adrenals- (*Continued*)  
  functions of, 217-219  
  innervation of, 218  
Adventitia, **28**  
Aepyornis, 554  
Afferent (sensory), 141  
  fibers, **142**, 179, 182, 211  
  nerves, 159, **184**  
Afterbirth, 295  
Age of fishes, 789  
  of mammals, 567  
  of reptiles, 497  
Air-bladders (swim-bladders), 276, 425,  
  427, **428**, 433  
Air-capillaries, 519  
Air-sacs, 519, **520**, **521**, **522**, 523-525, 621  
Albatrosses, 545, 556  
Albumen, 233, 235, **236**, 238, 243, **251**, 293  
Alcedo ispida, **552**  
Alimentary canal, **14**, **27**, **639**, **640** (*see also* Alimentary tube, Digestive tube)  
  passages, **562**, **610**  
  system, 25-56, 634-642  
  tube, 143, 154, **275** (*see also* Digestive tube, Alimentary canal)  
Alimentation, 213  
Alisphenoids, 124  
Allantoic arteries, 293  
  blood-vessels, 293, 295  
  cavity, 295  
  stalk, **290**  
Allantois, **6**, 241, 242, 244, **290**, **292**, 295,  
  483  
Alligator(s), **72**, 101, **107**, **152**, 235, 240,  
  **475**, **480**, 490, **492**, **565**, 703  
Alternation of generations, 231  
Alveolar ducts, 616  
  glands, 310, 311  
Alveolus(i) of glands (acinus), 31, **34**  
  of lungs, **61**, 616 (*see also* Air-sacs)  
  of teeth (tooth socket), 35, **37**, **39**, 42  
Amblystoma, **208**, 445, 452, **454**

- Ambystoma maculatum, **454**  
     tigrinum, 240, 445  
 Ameba, 140  
 Ameloblast layer, 40, **42**  
 Amia, 132  
 Ammocetes, **405**, 414  
 Amnion, 241, 242, 244, 289, **290**, **291**, **292**,  
     293, 295, 408, 483  
 Amnion(ic) (amniotic) cavity, **290**  
     fluid, 295, 483  
 Amniota(es), **80**, 280, 408, 409  
     arteries of, 626-629  
     lungs of, 618-621  
 Amphibia(n), **22**, **44**, 220, 222, 283, **287**,  
     288, 409, 410, 442-461  
     circulatory system of, **64**, **71**, **72**, **74**, **77**  
     classification of, 451-459  
     development of, 248, 249, 253-257,  
         261, **262**, 266, 278, 279  
     early, 459-461  
     evolution of, 461, 791, 792  
     fishes compared with, 459-461  
     heart of, 622, **624**  
     larval stages of, 442, **443**, **444**, 445  
     morphology of, 442-461  
     muscles of, 91, **92**, 95, 96, **97**  
     nervous system of, 150, 151, 155, 159,  
         160, **164**, 165, 173, 191, 195, 207,  
         208, 210, 214  
     reproductive system of, **80**, 81, 88, 233,  
         234, 236, 238-241, 244, 246  
     respiratory system of, 59, **60**, **61**, 445,  
         447  
     skeleton of, 101, **105**, 115, **121**, 122, 128,  
         **132**, 134, 138  
     tailed, 452  
     teeth of, 52, 53, 55  
     urinogenital system of, **79**, **80**, 81, 85,  
         88  
 Amphicoelous centrum, 106  
 Amphioxus, 11, **18**, **80**, **90**, **152**, **194**, **228**,  
     234, 394, 401, **402**, **403**, **404**, **405**  
     development of, **247**, **248**, 250, **252**, 253,  
         255, 256, 258, **259**, 260, **261**, 262,  
         266, 267, **268**, **269**, **270**, 271  
 Amphiplatyan centrum, 106  
 Amphisbaenia, 486  
 Amphiuma, 452  
 Ampullae, 208, **211**  
 Anal glands, 663-667  
 Analogy and homology, 360-365  
 Anamnia (anamniota), 408, 409  
 Anapsid skull, 501, **502**  
 Anatomy, 302  
     comparative, 5, 789-791  
     aim of, 355-384  
     history of, 333-354  
     method of, 355-384  
     medieval, 335-338  
     prescientific, 333  
 Ancestor, common, 348, 366, 368  
 Angular, 126  
 Animal hemisphere, **250**, 252, 257  
     pole, 235, **247**, 248, **249**, **250**, **252**, **254**  
 Ankle, **131**, 132  
 Ankylosed teeth, 46, 47  
 Annelid, 142, 197  
 Anomalies, somatic and visceral, 213-215  
 Ano-preputial glands, 665  
 Anseriformes, 546, 556  
 Antbears, 743  
 Anteaters, 56, 743  
     Cape, 745  
     great, 743  
     lesser, 743, **744**  
     scaly, 745  
     spiny, 236, 238, 242, 276, 384  
 Antebrachium (forearm), 94, 95, 131  
 Antelope(s), **757**, **759**  
     American, 757  
 Anterior, 12, 13  
     crescent, **262**  
 Anthrozoidea, 770, 771  
 Antilocapra, 757  
 Antilocapridae, 757  
 Antlers, 573, **576**  
 Antrum, 605  
     of Highmore, 677  
 Anura(n), **70**, **150**, 239, 454-458  
 Anus, 25, **107**, 268, 270, 274  
 Aorta, **6**, **64**, 67, **71**, **107**, **277**, **279**  
     dorsal, **6**, 175, 217, **272**, **275**  
 Aortic arches, **6**, **64**, 67, 69, **73**, **107**, 621,  
     **624**, **627**  
     trunk, 625, 629  
 Apes, **229**, **233**  
     great, **772**  
 Apoda, 239, 458, 459  
 Appendage(s), 92  
     locomotor, 17, 154  
     of mammals, 581, **582**, 583  
     median, 134, 135  
     paired, 128-134, 172, 173, **383**, 447,  
         467, 468  
     pectoral, 17, **129**  
     pelvic, 17, 129, 130  
     pentadactyl, 407  
 Appendicular muscles, 92-97  
 Appendicularia, 401  
     furcata, **400**  
 Appendix, vermiform, 641  
 Apterida, 508  
 Apterygiformes, 544  
 Apteryx, 544  
     australis, **546**  
 Aquatic adaptation, **369**, 781  
     birds, 556  
     mammals, 678, 687, 800  
     vertebrates, 408, 636  
 Aqueduct of Sylvius, 151  
 Aqueous humor, **202**, 203  
 Arachnoid, 191, **192**  
     spaces, **192**  
 Arbor vitae, 713  
 Arboreal adaptations, 801  
 Arborization, terminal, 316  
 Arc, nervous, **142**  
     reflex, 141, 174  
 Arch(es), 124  
     aortic, **6**, **64**, 67, 69, **73**, **107**, 621, **624**, **627**

- Arch(es)—(Continued)
- branchial, 118, **120**, 122, 126, 166
  - frontal, 122, 124
  - hemal, 106, **107**, 114
  - hyoid, 118, 122, 126, 166, 605
  - mandibular, 118, 122, 125, 127, 605
  - neural, 106, **107**, 111, 112, **279**, 413, 414
  - occipital, 112, 122, 124
  - parietal, 122, 124
  - of skull, 377
  - thoracic, 586
  - visceral, 96, **107**, 115, 118, **119**, 122t, 136, 138, 605, 607, 623, **695**
  - zygomatic, 128, 601
- Archaeopteryx, **539**
- Archaeornithes, 543, 553
- Archenteric cavity, 274
- Archenteron, **252**, **254**, 255, **256**, **259**, **261**, **262**, **268**, 296
- Archetype, 340, **348**
- Arcuate, veins, **86**
- Ardea herodias, **549**
- Area opaca, **263**
- pellucida, **262**
- Areolar tissue, 321
- Arm, **94**
- Armadillo(s), 44, 100, 101, **598**, 743, **745**
- giant, 743
  - nine-banded, 745
- Arteries, 63
- allantoic, 293
  - arrangement of, 626–629
  - branchial, **64**, 67
  - carotid, 67, 68, 625
    - external, **71**
    - internal, **6**, **70**, **71**  - caudal, **64**, 68, **74**
  - celiac, 68
  - ciliary, **203**
  - hepatic, **32**, **64**
  - iliac, **64**, 68, **71**, 74
  - innominate, 625
  - interlobar, 86
  - mesenteric, **64**, 68, **71**
  - ovarian, 68
  - pulmonary, **64**, 68, 69, **71**
  - renal, 68, **71**, 78, **86**
  - retinal, **203**
  - spermatic, 68, 652
  - stapedial, 694
  - structure of, 65, 67
  - subclavian, 68, 625, 626
  - vertebral, 592
- Arthropoda, 421
- Arthropod, 101, 141
- Articular, 126, 128, 563, 695
- Artiodactyl symmetry, 751, **752**
- Artiodactyla, 751, 754–757, 778, 779
- Arytenoids, 614
- Ascending fibers, 154, 169, **170**
- Ascidia(n), 394, 397
- Ass, 752
- Association cells, **170**
- neurons, 141, **184**
  - tracts, 717
- Astroscope, 439, 440
- Ateliotic dwarf, 226
- Atlas, **4**, **109**, **110**, 111, 596
- Atresia, 645
- Atrial cavity, 396, 397, **400**, 402
- Atriopore, 402
- Atrioventricular valves, **65**, 622
- Atrium(a) (auricle), **64**, 65, 67, 68, 69, **71**, 616
- Auchenia, **758**
- Auditory cells, **196**
- meatus, 534
  - nerve (acoustic nerve), 166, 692, 715
  - passage, 693
- Auerbach, plexus of, **174**
- Augmentative homology, 362
- Auk(s), 546, 556
- great, 551, 556
- Auricle(s) (atrium), **64**, 65, 67, 68, 69, **71**, 616
- Auricula, 696
- Auricular muscles, **98**
- Australopithecus africanus, 771
- Autonomic cord, 176
- ganglions, 172, 173–179, **177**, 215, 217, 219
  - nerves, distribution of, 183–186
    - functional components of, 179–183, **180**  - neurons, 186, 187
  - system, 159, 173–191, **176**, **178**, **181**, 272
  - antagonistic actions of, 187–189
  - cervical division of, 187
  - cranial division of, 187
  - craniosacral (parasympathetic) division of, 187, 218
  - distribution of,
    - craniosacral, 189, 190
    - thoracolumbar, 189, 190, 218
  - effectors of, 188
  - functions of, 187–191
  - sacral division of, 187
  - stimulation by,
    - craniosacral, 188, 189
    - thoracolumbar, 188, 189
    - thoracolumbar (sympathetic) division of, 187, 218
- Aves, 503–558 (see Birds)
- Axial skeleton, 136–138, 271
- Axis, 596
- coelomic, 136, 137
  - dorsal-parietal, 138
  - mechanical, 12, 104, 112, 136
  - notochordal, 104–106, **137**, 138
  - physiologic, 136
  - skeletal, 136–138, **137**
  - sternal, **137**, 138
  - structural, 136
  - ventral, 138
  - vertebral, 133, 134, 138
  - visceral, 136, **137**, 138
- Axolotyl, 240, 445
- Axon, **140**, **141**, **142**, 316 (see also Neurite and Neuraxon)
- Azygos veins, **66**, **71**, 73

## B

- Baboon, **2**, **770**, 771  
 Backbone (*see* Vertebral column)  
 Bactrian, 757  
 Balaena, 765  
   *australis*, **766**  
 Balaenoptera, 765  
 Balanoglossus, 393, **394**, **395**, **396**  
 Baleen, 19, 765  
   whale, **767**  
 Bandicoot, 294, **732**, 733  
 Barbs, 505, **506**, 509  
 Barbules, 505-507, 509  
 Bartholin, glands of, 664  
 Basal plate, 47  
 Basement membrane, 305  
 Basibranchial, 120  
 Basihyal, 118, 607  
 Basilar membrane (*membrana basilaris*),  
   690, 698  
   fibers of, 692, 698  
 Basilaris papilla, 477  
 Basioccipital, 112, 124  
 Basiphenoid, 124, 127  
 Basophils, 329  
 Bat(s), 229, 370, **568**, 571, **738**, 739  
   fruit, 739  
 Batfish, **229**  
 Batrachoseps attenuatus, **454**  
 Bdellostoma, **413**, 414, 415  
 Beak, 518  
 Beaked whale, **764**, 765  
 Bears, 747  
 Beaver(s), **663**, 665, 740  
 Bee-eaters, 551  
 Biceps, **92**, 95  
 Bicuspid, 53  
   valve, 622  
 Bile, 34, 35  
   capillaries, 31  
   duct, **14**, 31, **32**, 276  
 Bill, 518  
 Binocular vision, 605  
 Binomial nomenclature, 340, 341  
 Biochemistry, 353  
 Biogenesis, law of, 349  
 Biometry, 352, 353  
 Biophysics, 353  
 Bipolar cells, 316, **318**  
 Birds (*Aves*), 13, 14, 16, **22**, 227, 289, 293,  
   409, 410, 503-558, **630**  
   adaptations of, 556-558  
   air-spaces in, 522, 523, 525  
   aquatic, 556  
   behavior of, 537  
   circulatory system of, 68, 69, **72**, 527, 528  
   classification of, 542-553  
   development of, 249-251, 256, 257, 262,  
     263, 273, 275  
   digestive organs of, 528-531  
   early, 538-542  
   endocrinal system of, 220, 223  
   evolution of, 541, 542, 793, 794  
   flightless, 553-555  
 Birds—(*Continued*)  
   flying, 542  
   frigate, 545  
   hand of, 511  
   heart of, 625  
   morphology of, 503-558  
   muscles of, 91, 98, 100, 518, 519  
   nervous system of, 149, 151, 160, 193,  
     208, 210, 532-537  
   relationships among, 553-558  
   reproductive system of, 88, 233-235,  
     238, 240-242, 244-246, 537, 538  
   reptiles compared with, 553  
   respiratory system of, 519-527, **522**  
   running, 542  
   skeleton of, 115, 122, 124, 128, 133, 511,  
     **512**, 513-518  
   specialization in, 503-505  
   tail of, 515  
   toothless, 52, 56  
   urinogenital organs of, 79, 88, **531**, 532  
 Birth, 295  
 Bison, 757  
 Bladder(s), air-(swim-), 276, 425, 427,  
   **428**, 433  
   gall, **14**, **32**  
   urinary, **80**, 185, 186, 276, 285, 293, 295,  
     474, 643  
 Blastocoel, 247, 249, **250**, **251**, **252**, **254**,  
   255, **256**  
 Blastoderm, **236**, **251**, 254, **256**, 257, **262**,  
   263, 289  
 Blastodermic vesicle, **264**, **265**  
 Blastopore, **252**, 253, **254**, 255, **256**, 257,  
   258, **262**, 266, 267, **268**, 273, 274,  
   296, **392**  
 Blastula, 227, **228**, 246-251, **250**, **252**, 253,  
   255, 256, 263, 296  
 Blind spot, 204  
 Blindworms, 459  
 Blood, 241-243, **328**, 329, 330, 466, 527,  
   623, 634  
   calcium salts in, 222  
   glands, 65  
   platelets, 329  
   pressure, 227  
 Blood-vessels, 14, 18, **30**, **34**, 79, **82**, 154,  
   155, 185, 241, 242, 269, 281, 286,  
   293 (*see also* Arteries, Veins,  
   Capillaries)  
   abnormalities of, 628  
   allantoic, 295  
   caudal, 114  
   in pulp-cavity, **37**, 38  
   vitelline, 295  
 Blue jays, 553  
 Body-cavity (*coelom*), 16, **17**, **21**, **22**, 87,  
   114, **269**, 270, **275**, **277**, 278, **279**,  
   **281**  
 Body-wall, 154, 155, 156, 157, **281**  
 Bone(s), **102**, 222, 226, 278, 284, 298, 299,  
   325, **326**, 327  
   acetabulum, 129, 130, **131**  
   alisphenoid, 124  
   angular, 126

## Bone(s)—(Continued)

- of antebrachium, 131
- articular, 126, 128, 563, 695
- basioccipital, 112, 124
- basisphenoid, 124, 127
- of brachium, 94, 131
- cancellous, 325
- cannon, 755
- carpus, **107, 131, 132, 133**
- cartilage-, 103, 120, 122, 124, 126, 285
- cell, 284, **285**
- chevron, 595
- circumorbital, 125
- clavicle, **99, 129, 130, 132, 134, 285, 511**
- cleithrum, 107, 129, 133
- compact, 325
- coracoid, 130, **131, 511**
- coronoid, 126
- cranial, 122
- dentary, **107, 126**
- dermal, 20, **103, 120, 122, 125, 126, 285**
- development of, 598, **599, 600**
- ectethmoid, 124
- endochondral, **102, 285**
- epicoracoid, **132**
- epiotic, 125
- epipubic, 587, 649
- episternum (interclavicle), 114, 138, 472
- epistropheus, **4, 109, 110, 111**
- ethmoid, 124, 475
- exoccipital, **107, 124, 162**
- femur, 95, **107, 131**
- fibula, **107, 131, 512**
- frontal, **107, 124**
- fusion of, 517
- humerus, 95, **107, 131, 132**
- hyoid, 122
- ilium, **14, 107, 130, 131, 133**
- incus, 122, 563, 693, 695
- intermuscular, 113
- interopercular, 122, 126
- investing, 120
- ischium, **107, 130, 131, 514**
- jugal, 126, 128, 601
- lacrimal, 126
- malar, 122, 126, 128, 601
- mandible, **37, 199**
- marsupial, 587, 649
- matrix, **285**
- maxilla, 126, 127, 199
- membrane-, 103, **107, 285**
- mesethmoid, 124
- metacarpal, **107, 131**
- metatarsal, **107, 131, 132, 512**
- nasal, 107, 125, **199**
- occipital, 122
- opercular, 126
- opisthotic, 125
- orbitosphenoid, 124
- palatine, 125, **199**
- parasphenoid, 125, 127, 137
- parietal, 22, 93, 96, 97, 269
- patella, **131, 133**
- periotic, 125
- petrosal, 692

## Bone(s)—(Continued)

- phalanges, **107, 131, 132**
  - pisiform, 133
  - postfrontal, 125
  - postorbital, 125
  - precoracoid, **107, 130, 131, 132**
  - prefrontal, 125
  - premaxilla, 126, 127
  - preopercular, 126
  - presphenoid, 124
  - prevomer, 125, 137
  - procoracoid, **107, 130, 131, 132**
  - prootic, 125
  - pterygoid, 126
  - pubis, **107, 130, 131, 514**
  - quadrate, 126, 127, 128, 478, 517, 563, 695
  - radius, 95, **107, 131, 133**
  - rib (*see* Ribs)
  - scapula, 95, **99, 107, 129, 130, 131, 132, 511, 583**
  - sclerotic, 117
  - secretion of, **38**
  - sesamoid, 133
  - sphenoid, 122
  - splénial, 126
  - splint, 752
  - squamosal, 125, 126, 128, 563, 602, 692
  - stapes, 122, 477, 563, 693, 695
  - sternum, **99, 107, 113, 114, 115, 132, 134, 138, 471**
  - subopercular, 122, 126
  - supra-angular (surangular), 126
  - supraoccipital, **107, 112, 124**
  - supraorbital, 125
  - suprascapular, 132
  - symphysis, 130, 514
  - symplectic, 127
  - tarsus, **107, 131, 132, 133, 685**
  - temporal, 122, 692
  - tibia, **107, 131, 512**
  - tympanic, 692, 696
  - ulna, 107, 131
  - vertebra (*see* Vertebra)
  - vomer, 125, 127, 137
- Bony fishes (*see* Fishes, bony and Teleostei)
- plates, 573
  - scales, 19, **20**
  - skull, 120–126
- Bos, 757
- Bottlenose whale, 765
- Boveri's theory of origin of eyes, **200**
- Bovidae, 757
- Bow-fin, 432
- Bowhead whale, 765
- Bowman's capsule, 84, **87, 280**
- Brachial enlargement, 152
- plexus, **172, 177**
- Brachium (upper arm), 94, 131
- Bradypus, 743
- Brain(s), 112, 142–152, **144, 146, 147, 148, 158, 177, 178, 191, 207, 270, 290, 419, 448, 450, 478–480, 534, 535, 536, 537, 703, 705, 706, 709**
- anthropoid, 803, 804

## Brain(s)—(Continued)

- comparison of with office, 667, 668, 715–718
- convolutions (gyri) of, 704
- fiber-tracts of, **708**
- form of, 702
- and intelligence, 721, 722
- lobes of, 145, 151, 704, (*see also* Lobes)
- of mammals, 701–713
- of man, **705, 706, 708**
- nerve centers in, 157, **158**
- “new,” 703, 704, 719
- “old,” 703, 704, 719
- progressive elaboration of, 787, 789
- segmental, 720
- size and function of, 701–703
- ventricles of (*see* Ventricles)

## Brain-case, 116

Brain-stem, **225, 709, 712, 720**Brain-vesicles (*see* Vesicles)

- Branchial arch, 118, **120, 122, 126, 166**
- arteries, **64, 67**
- chambers, 96

Branchiomer muscle, 96–100, **97, 120, 288**Breast muscles (*see* Muscles, Pectoralis)

## Breathing, 472, 495, 524

valve, **417**

## Bridges, protoplasmic, 305

## Bronchial tree, 616

## Bronchioles, 616, 617

Bronchodilator nerves, **178**Bronchus(i), 59, **60, 276, 519, 616, 619**

- recurrent, 522
- secondary, 519

Brood-pouch, 238, **239, 245**

## Buccal glands, 636

nerves, **160, 165**

## Buccopharyngeal respiration, 447

## Bufo americanus, 458

## marinus, 239

## Bufonidae, 458

## Bulbourethral glands, 664, 665

## Bulbus urethrae, 660

## Bulla tympani, 697

## Bullfrog, 458

## Bunodont, 755

## Bunodontia, 754, 755

## Burrowing animals, 459

## Bursa Fabricii, 530, 531

## inguinalis, 651

## Bushmen, 1, 2

## Bustards, 546

Buteo vulgaris, **549**Buzzard(s), 546, **549**

## C

## Caecilians, 459

## Cacops, 460

## Caduceibranchiata, 452

Caecum, **14** (*see also* Cecum)Caenolestes, **733, 774**

## Caenolestoidea, 733

Caiman latirostris, **491**

## Calamoichthys, 421, 429

Calamus (quill), 505, **506**

## Calcareous structures, 101, 308

## Calcified cartilage, 325

## Calcium, 222

Calf, **148, 705**Calyx, **86**

## Camelidae, 755, 757

## Camels, 755

Canal, alimentary (*see* Alimentary canal,

Alimentary tube, Digestive tube)

## inguinal, 653

lateral-line, **165, 167**neurenteric, 267, **268, 270, 274, 275**sacculo-utricular, **211**semicircular, 208, **209, 211, 688, 698, 699**

## urethral, 660

## vertebral, 106, 173

Canaliculi, 35, 37, **38, 325**Canalis centralis, **152**

## Canary, 528

## Cancellous bone, 325

## Canidae, 747

Canine(s), **43, 45, 563**muscles, **98**

## Canis, 747

dingo, **751**

## Cannon bone, 755

Capillary(ies), 63, **86**

## air-, 519

## bile-, 31

## structure of, 67

Capped petrel, **548**

## Capra, 757

## Caprimulgiformes, 553

## Capsule, 201

Bowman's, 84, **87, 280**of lymph gland, **66**

## olfactory, 116

otic, 116, 125, **144, 209, 692**Capybara, **741**

## Carapace, 494, 495

## Carbohydrates, 215, 221, 227

## Carboniferous Period, 497

Cardiac (heart) muscles, 213, 287, **315, 316**stomach, **29, 638**

## Cardinal veins, anterior, 73

common, **65**post-, **64, 71, 73, 74, 78**

## pre-(anterior), 73

sub-, 73, **74**supra-, **71, 73**Cariamas, **555**

## Carina, 518

## Carinatae, 542, 544–553

## Carnivora(es), 294, 571, 605, 747–751, 781

## vera, 747

## Carotid arteries, 67, 68, 625

external, **71**internal, **6, 70, 71**ganglion, **178**Carpals, **107, 132, 133**

## Carpometacarpus, 511

Carpus (wrist), **131**Cartilage, 11, **102, 120, 278, 284, 285, 298,****323, 324, 325**



- Cartilage—(*Continued*)  
 calcified, 325  
 cricoid, 614  
 elastic, 325  
 hyaline, 324  
 hyomandibular, 118, 127  
 interdorsal, 106  
 interventral, 106  
 laryngeal, **612**  
 mandibular (Meckel's), 118, 126  
 thyroid, 612
- Cartilage-bone, 103, 120, 122, 124, 126, 285
- Cassowary, 543
- Castor, 740
- Casuariformes, 543
- Casuarus, 543  
 bennetti, **544**
- Cat, **39**, 95, 134, **194**, **294**, **597**, **606**, **690**,  
 747  
 Australian, 294, **731**, 733
- Catarrhina, 771
- Catfishes, 433
- Cattle, 757
- Cauda equina, 173
- Caudal, 13
- arteries, **64**, 68, **74**  
 blood vessels, 114  
 muscle, 288  
 vein, **64**, **74**, 77  
 vertebrae, 106, 455, 597
- Caudata, 452-454 (*see also* Urodela)
- Cavia, 740
- Cavity(ies), 21  
 allantoic, 295  
 amnion, **290**  
 archenteric, 274  
 atrial, 396, 397, **400**, 402  
 body-(coelom), 16, **17**, **21**, **22**, 87, 114,  
**269**, 270, **275**, **277**, 278, **279**, **281**  
 coelomic, **287**  
 dental, **36**  
 digestive, 267, 274  
 nasal, **14**, 195, **197**, 198, **199**, **677**  
 oral (mouth), **14**, 25, **26**, 166, 195, 196,  
**199**  
 orbital, 602  
 pancreatic, 31  
 peribranchial, 402  
 pericardial, 21, **275**, **286**, 287  
 peritoneal, **287**  
 pleural, 21, 287  
 pleuroperitoneal, 21, **287**  
 pulp, 35, **37**  
 subgerminal, 250, **251**  
 thoracic, 22  
 tympanic, 477  
 of yolk-sac, **292**
- Cebidae, 770
- Cebus capucinus, **769**
- Cecum(a), 29, **31**, 530  
 hepatic, 403  
 vaginal, 648
- Celiac arteries, 68  
 ganglion, **178**, 179, 185
- Cell(s), 301  
 association, **170**  
 auditory, **196**  
 bipolar, 316, **318**  
 bone-, 284, **285**  
 central, **32**  
 chromaffin, 217  
 egg-, 645  
 epithelial, 222  
 fat-, **327**  
 follicular, **237**  
 ganglion, **152**, 169, **170**, **171**, 271  
 germ-, 233, 237, **282**  
 gustatory, **196**  
 hair, **196**  
 hepatic, 31  
 of Merkel, 193  
 mesenchyme, 285  
 migration of, 52  
 motor, **142**, **152**, 160, **171**  
 multipolar, **140**, 316, **317**  
 nerve-, **140**  
 nucleus of, **317**, **318**  
 olfactory, **196**, **197**, **198**  
 pillar, 690, 698  
 pyramidal, **140**, **317**  
 receptor, **196**  
 secretory, 179, 185  
 sense (sensory), 140, 142, 192, 193, 195,  
 196, **197**, 198, 199, 209, **210**, 214,  
**309**, 690  
 stellate, **204**  
 tactile, 193, **194**  
 unipolar, **140**, 316, **317**, **318**  
 visual, **196**  
 yolk, 253, 255, 256
- Cell-body(ies), **140**, 153
- Cement, 35, **36**, **37**, **38**, 44
- Cementoblasts, **37**
- Cenogenetic structures, 299
- Cenozoic, 560, 567, 793
- Central cells, **32**  
 nervous organs, 140, 141, 142-157, 258,  
 407
- Centrum(a), 106, **107**, 144, **199**, **279**  
 amphicoelous, 106  
 amphiplatyan, 106  
 opisthocoeleus, 106  
 procoelous, 106
- Cephalad, 13
- Cephalic, 13  
 flexure, **144**  
 ganglions, 179
- Cephalochorda(tes), **90**, 394, 401-403,  
**404**, 405, 407
- Cephalodiscus, 395
- Cephalohumeral muscle, **92**
- Ceratobranchial, 120
- Ceratodus, 437
- Ceratohyal, 118
- Cercopithecidae, 771
- Cerebellar cortex, 713, 719  
 hemispheres, 712
- Cerebellum, **144**, **146**, **148**, 151, **177**, 534-  
 536, 712, 717, 718, 720

- Cerebral cortex (cortex cerebri), 448, 479,  
704, 717-719  
hemispheres, 145, 479, **480**, 534, 708  
peduncles, 150
- Cerebrospinal fluid, 152
- Ceruminous glands, 577, 693
- Cervical curvature, **4**, **109**  
flexure, **144**  
ganglions, 176, **177**, **178**, 184, 185  
nerves, **177**, 184  
plexus, 172  
vertebrae, 514, **515**, 596, **764**
- Cervicothoracic plexus, 172
- Cervidae, **757**
- Cervus, **757**  
schomburgki, **758**
- Cestracion, **423**
- Cetacea (eans), 571, 763-765, 781  
lungs of, 618
- Chain ganglions, 176
- Chalaza, **236**
- Chamber(s), anterior, **202**, **203**  
of heart, 418, 437, **623**, 787  
posterior, **202**, **203**
- Chamois, **757**
- Charadriiformes, 546
- Cheiropterygium, 130
- Chelonia, 493-497, 500  
imbricata, 497
- Chevron bones, 595
- Chevrotain, **753**, **757**
- Chiasma, **148**, **713**  
optic, 162, **202**  
trochlear, 164
- Click, **88**, **226**, **228**, **251**, **262**, **263**, **282**, **291**
- Chimaera, 424
- Chimpanzee, 771, **772**, **773**  
man compared with, 803
- Chinchilla, 740
- Chiroptera, 739, 776
- Chitin, 101
- Choana, 198, 199
- Choanichthyes, 439
- Choloepus, 743  
hoffmanni, **744**
- Chondrichthyes, 420
- Chondrin, 116
- Chondrocranium, 116, 117, 137
- Chondrostei, 427, **430**
- Chorda dorsalis, 393 (*see also* Notochord)  
tympani, **160**, **161**, 166, **178**
- Chordae tendineae, 622
- Chordate(a), **18**, **80**, **194**, **228**, 245, 247,  
257, 266, **275**, 393  
classification of, 389-411  
evolutionary progress of, 791-794, 814, 815  
primitive, 791
- Chorio-allantoic membrane, 293, 294
- Chorion, 241, 242, 244, **290**, 291, **292**, 293-  
295
- Chorionic villi, **292**
- Choroid fissure, **273**  
layer, 201, **202**  
plexus, 147, **148**, 151
- Chromaffin cells, 217
- Chromatin, 233, 237, 247
- Chromatophores, 19, **20**, 321
- Chromosomes, 237
- Chrysochloris, **775**  
obtusirostris, **737**
- Chunia, **555**
- Chyle, 65
- Ciconiiformes, 545
- Cilia, 308
- Ciliary arteries, **203**  
body, 201, **202**  
ganglion, 163, 176, **178**, 179, 183  
glands, 685  
muscles, 155, 183, 534, 683, 684  
process(es) **203**, 683
- Ciliated epithelium, **306**, 308
- Cilium (eyelash), **203**, 685
- Ciona, 397
- Circular muscle, **28**, **30**
- Circulation, 67-69, 242  
renal, **630**
- Circulatory system, 63-78, 258, **622**  
diagrams of, **64**, **66**, **69**, **71**  
general relations, 63-67  
respiratory organs in relation to, 67-69
- Circumorbital, 125
- Cistudo, **493**
- Civet, 747
- Clark's column, **170**
- Classes, 390
- Clavicle(s), **99**, 129, 130, **132**, 134, 285, 511
- Claws, **19**, **576**  
horny, 573
- Cleavage, 246, 247, **248**, **250**, **251**, 256,  
257, 263, 295, 296  
planes, 247
- Clefts, pharyngeal, 59, 214, 274, 275, 407,  
418
- Cleidomastoid muscle, **92**, 168
- Cleithrum(a), **107**, 129, 133
- Climate, adaptation to, 568, 805
- Clitoris, 661
- Cloaca, **6**, 25, **80**, 81, 82, 87, 238, 276, 448,  
474, 530, **654**, **657**  
ectodermal, 658
- Cloacal membrane, 659
- Cobra, **489**
- Coccygeal nerves, **177**
- Cochlea, **208**, **209**, 210, 477, 534, 688, 689,  
**690**
- Cochlear nerve, 166  
trunk, 715  
tube, 689, **691**, 693
- Cockatoos, 551
- Cod, 378, **379**
- Codfish, 124, 234
- Coelenterates, 297
- Coelom (body-cavity), 16, **17**, **21**, **22**, 87,  
114, **269**, 270, **275**, **277**, 278, **279**,  
**281**, **290**  
extra-embryonic, **290**, **292**
- Coelomic axis, 136, 137  
cavities, **287**
- Cold (sensation), 193
- Cold-blooded animals, 410

- Colies, 553  
 Coliiformes, 553  
 Collagen, 320, 321  
 Collar (Balanoglossus), 394  
 Collateral(s), 316  
   ganglions, 179, 185  
 Colon, 639  
   ascending, **14**  
   descending, **14**  
   sigmoid, **14**  
   transverse, **14**  
 Color vision, 682  
 Colors, structural, 508  
 Colugo, 736, **775**  
 Columba livia, **513, 514**  
 Columbiformes, 551, 556  
 Columella, 477, 563  
 Column, Clarke's, **170**  
   cortical, **86**  
   dorsal, **152**, 153  
   lateral, **152**  
   ventral, **152**, 153  
   vertebral (*see* Vertebral column)  
 Columnar epithelium, 304, **305, 306**  
 Colymbiformes, 545  
 Commissure(s), 707  
   anterior, **148**  
   gray, 153  
   posterior, **148**  
   superior, **148**  
 Common ancestor, 348, 366, 368  
 Comparative anatomy, 5, 789-791  
   aim of, 355-384  
   history of, 333-354  
   method of, 355-384  
   embryology, 788-791  
   morphology, 353  
 Compound glands, 310, 311  
 Concha(e), **199**, 475, 532, 673-676  
 Concrescence theory, 53  
 Conduction (nervous), 140  
 Condylarthra, 778, 779  
 Condyle(s), occipital, 111, 561, 564, 596  
 Cones, 203, **204, 205**, 206  
 Conjunctiva, 195, 201, **202, 203**, 206,  
   685  
 Conjunctival sac, **203**, 686  
 Connecting links, 405, 406  
 Connections, principle of, 360, 374, **375**,  
   378  
 Connective tissue, 191, 193, 221, 224, 278,  
   284, **285**, 320-322  
   fibrous, 117  
   subcutaneous, **18**, 100, 581  
 Connector neurons, 182  
 Consciousness, 722, 723  
   seat of, 722, 723  
 Conservatism, 381-384  
   of blood-vascular system, 382  
   of digestive organs, 382  
   of kidneys, 382  
   of motor mechanism, 382  
   of nervous structures, 381, 382  
   of reproductive system, 382  
   of skin, 381, 382  
 Contraction, 311  
 Conus, **65**  
   papillaris, 681  
 Convergence, 366, 367, **368, 369**, 370  
 Convergent evolution, 245, 557, 795  
 Convolutions of brain, 704  
   of cortex, 721  
   advantages of, 707  
 Cony, **742**  
 Coots, 546  
 Coprodeum, 530  
 Copula, 607  
 Copulation, 238  
 Coraciiformes, 551  
 Coracoid, 130, **131**, 511  
   process, 583  
 Cord(s), autonomic, 176  
   medullary, of lymph gland, **66**  
   spermatie, 652  
   spinal (*see* Spinal cord)  
   umbilical, 294, 295  
   voeal, 614  
 Cordis nerves, **178**  
 Corium (dermis), **18, 19, 20, 39**, 193, 195,  
   278, 581  
 Cormorants, 545, 556  
 Cornea, 201, **202, 203**  
 Cornua, anterior, 607  
   posterior (horn), 607  
 Corona radiata, 236, **237**  
 Coronary veins, **71**  
 Coronoid, 126  
   process, 601  
 Corpora bigemina, 711  
   cavernosa, 659  
   quadrigenina, 711  
   striata, 704, 720  
 Corpus callosum, **148, 710**  
   cavernosum penis, 660  
   urethrae, 660  
   fibrosum, 659  
   spongiosum, 660  
   striatum, 145, **178**, 479, 536  
 Corpuscles of Golgi-Mazzoni, 193, **194**,  
   195  
   Grandry's, 193  
   of Krause, 193, **194**  
   Malpighian (renal), 84, **87**, 280  
   Meissner's, 193, **194**  
   of Pacini, 193, 195  
   red (erythrocytes), 63, 65, 329, 634  
   white (leukocytes), 63, 65, 329  
 Correlation centers, 536, 717  
   neurons, 141  
 Correspondence, of dogfish spiracle and  
   mammalian ear, 357-359  
   of horse and man, bones, **361**  
   of kidneys, 359  
   of lungs and gills, 359  
   of organs, 342  
   of parts, 356  
   genetic, 363  
   of respiratory and hearing organs, 358  
 Cortex, 479, 707  
   adrenal, 217

- Cortex—(*Continued*)  
 cerebellar, 713, 719  
 cerebral (cortex cerebri), 448, 479, 704,  
 717, 719  
 convoluted, 721  
 of kidney, 82, **86**
- Corti, organ of, **196**, 210, 477, 534, 690,  
**691**  
 rods of, 690
- Corticospinal tract, **170**
- Cortin, 217
- Cosmin, 425
- Costocoracoid ligament (*see* Ligaments)
- Cotyledonary placenta, 294
- Cotylosaurs, 501, 564
- Cowper's glands, 664, 665
- Crane(s), **229**, 546, **550**
- Cranial nerves, 99, 100, 159–169, **160**, 183,  
 451, 481, 482, 537, 713, **714**, 715  
 groups of, 168, 169
- Craniata, 407
- Craniosacral system, 187–190 (*see also*  
 Autonomic system)
- Cranium, 111–112, 115, 116, **119**, 120, 137,  
 138, 191, 285  
 bones of, 124, 125  
 relation to jaws, 127, 128
- Creation, special, 340
- Cremaster muscle, 615, 652
- Creodonta, 776, 781
- Cretaceous, 502, 540, 773
- Cribriform plate, 713
- Cricoarytenoid muscle, 614
- Cricoid, **60**, **61**, **99**,  
 of mammals, **612**, **613**, 614
- Cricothyroid muscles, 614
- Crista(ae), **209**, 210, **211**, 692  
 acusticae, 692
- Crocodyles, 47, **114**, 198, 208, 235, **466**,  
 490, **492**, 500
- Crocodylia(n), 490, **491**, 492, 610
- Cro-Magnon man, 771
- Crop, 528
- Crossopterygii, 420, 421, 425, **426**
- Crown, 35, **36**
- Crows, 553
- Crura cerebri, 150, 151
- Crus (crura), 131, 660
- Cryptobranchus, 234, 452  
 allegheniensis, **449**, 452
- Cryptorchism, 653
- Crypturiformes, 544
- Ctenoid scales, **20**
- Cuboidal epithelium, **221**, **304**
- Cuckoo(s), **508**, 551
- Cuculiformes, 551
- Curlews, 546
- Curvature(s), cervical, **4**, **109**  
 lumbar, **4**, **109**  
 sacral, **4**, **109**  
 of stomach, **29**  
 thoracic, **4**, **109**
- Cusps, 53
- Cutaneous sense-organs, 193, **194**, 195
- Cuticula, 306
- Cuvier, duct (sinus) of, 73, **74**, 631
- Cycloid scales, **20**
- Cyclostome(ata), 11, 28, 56, 59, **90**, 105,  
**147**, **150**, 165, 198, 208, 217, 222,  
 224, 233, 237, 275, 409, 410, **413**,  
 414–416
- Cynognathus, 564, **565**
- Cyprinidae, 433
- Cytogenic glands, 310
- Cytology, 302
- Cytoplasm, 233, 237

## D

- Dance, eagle, **1**, 2
- Dark Ages, 335
- Dasypus, 743  
 novemcinctus, 745
- Dasyure(us), 294, **731**, 733  
 maculatus, **731**
- Dawn horse, **780**
- Deciduate placenta, 294
- Deciduous teeth (*see* Milk teeth)
- Decussation, 162, 714
- Deer, **576**, **757**, **758**  
 musk, 757
- Degeneration, 802
- Degenerative metamorphosis, 406, 407
- Delamination, 261
- Delphinidae, 765
- Deltoid muscles, **92**
- Dendrites, **140**, **142**, 193, **212**, 316
- Dendrohyrax, 762
- Dental cavity, **36**  
 formula, 730  
 human, **45**  
 groove, **41**  
 ridge (lamina), **39**, **41**
- Dentary, **107**, 126
- Dentine, 35, **36**, **37**, **38**, **42**, 44, **56**
- Dentition, acrodont, 47, **48**, 52  
 bicuspid, 53  
 bunodont, 755  
 diphyodont, 54, 55, 635  
 exceptional, 55, 56  
 heterodont, 53, 55, 563, 564, 634  
 homodont, 53, 55, 56, 563  
 lophodont, 53  
 monophyodont, 54, 635  
 multitubercular, 53  
 pleurodont, 47, **48**, 52  
 polyphyodont, 54, 55, 635  
 secodont, 53  
 selenodont, 755  
 thecodont, 47, **48**, 52  
 triconodont, **45**  
 tritubercular, **45**
- Depressors, 94, 96
- Dermal bone, 20, **103**, 120, 122, 125, 126,  
**285**  
 denticles, 50  
 papilla, 670
- Dermatome, **275**, 278, **279**, 283
- Dermis (corium), **18**, **19**, **20**, **39**, 193, 195,  
 278, 581

- Dermoptera, 736, **737**, 774, 776  
 Descartes, 227  
 Descending fibers, 154, 169, **170**  
 Desmognathus, 452  
 Determinants, 365  
 Deuterostomians, **391**, 393  
 Deutoplasm, 233  
 Development, 236, 237, 239, 240, 243,  
 246-299  
 Devonian, 789  
 Diachole, 149 (*see also* Ventricle, third)  
 Diaphragm, **22**, 213  
 Diaphysis, 598  
 Diapsid skull, 501, **502**  
 Diastema, 739  
 Dicamptodon ensatus, **454**  
 Dicotyles, **754**  
 Didelphis virginiana, **731**, 733  
 Didus ineptus, **551**  
 Diencephalon, **6**, **144**, 145, 147, **148**, 149,  
 215, 227, 710  
 Diet, 569, 805 (*see also* Food)  
 Differentiation theory, 53  
 Diffuse placenta, 293  
 Diffusion, 155, 156  
 Digastric muscle, **92**  
 Digestion, 155, 174  
 of starch, 637  
 Digestive cavity, 267, 274  
 epithelium, 23, 27, 258, 274, **281**, 303  
 passage, **199**  
 tube, 13, 25-35, 96, 136, 155, 174, 213,  
 241, 270, **281**, 285, 288 (*see also*  
 Alimentary tube, Alimentary  
 canal)  
 Digitigrade condition, 583  
 Digits, 132  
 Dilator fibers, 286  
 Dingo, **565**, 750  
 Dinornis, **347**, 554  
 Dinosaurs, **499**, 500  
 Dioecious, 233  
 Diphyodont, 54, 55, 635  
 Diplospondyly, 111  
 Dipnoi, 198, **426**, 437-439  
 Diprotodontia, 735  
 Directions, 12, 13  
 Discoidal placenta, 294  
 Disks, intercalated, **315**, 316  
 intervertebral, 597  
 Ditremata, 729  
 Divergence, 794  
 Diverticulum, hepatic, **275**  
 Division of labor, 297  
 Dodo, **551**  
 Dog, **54**, 563, **601**, **637**, **703**, **706**, 747  
 Australian, **565**, **751**  
 Dogfish(es), **6**, 11, **93**, **146**, **233**, **289**, **308**,  
**356**, 376, 422  
 and mammal, spiracle and ear, 357-  
 359  
 Doliolum, **400**, 401  
 Dolphins, 56, 765  
 Domestic fowl, 234, 530  
 Dorsal, 13 (*see under noun entries*)  
 Dorsal-parietal axis, 138  
 Double-tubular structure, 23, 154, 155,  
 156, 158  
 Dove(s), **229**, 551  
 Down-feathers (plumules), 507, **510**  
 nestling, 507  
 powder, 507, 509  
 Draco volans, **800**  
 Dromatherium, **45**  
 Dromedary, 755, 757  
 Dromiceius, 543  
 Duckbill, 236, 238, 242, 276, **726**, 727,  
 733 (*see also* Ornithorhynchus)  
 Ducks, 546  
 Duct(s), 281  
 alveolar, 616  
 bile, **14**, 31, **32**, 276  
 of Cuvier, 73, **74**, 631  
 endolymphatic, 209, **211**, 688  
 genital, 238  
 hepatic, 31  
 hypophyseal, 224, **225**  
 lacrimal, 199  
 mesonephric (Wolffian), **80**, 81, 82, **83**,  
 87, 88, 280, 650-656  
 Müllerian, **80**, 87, 88, 283  
 nasolacrimal, 686  
 nasopalatine, 475, 678  
 pancreatic, **14**  
 primitive, 81, **83**, **275**, **277**  
 pronephric, 87, **279**, 280  
 of Santorini, **32**  
 sperm (*see* Vas deferens)  
 Steno's, 636  
 thoracic, **66**  
 urinary, 87  
 urinogenital, 79-83, 87, 88, 154, 276,  
 283, 285, 474  
 Wharton's, 636  
 Wirsung's, **32**  
 Wolffian (mesonephric), **80**, 81, 82, **83**,  
 87, 88, 280, 283, 650-656  
 Ductus deferens (*see* Vas deferens)  
 ejaculatorius, 651  
 Dugong, 294, 763  
 Duodenum, **14**, **29**, 215, 639  
 Duplicitentata, 742  
 Dura mater, 191, **192**  
 Dwarf, ateliotic, 226

- Earthworm, 82  
 Ecdysis, 307  
 Echidna, 236, **727**, 728, 733  
 Echidnidae, 733  
 Echinoderm(s), **228**  
 and hemichordates, 406  
 Ectethmoid, 124  
 Ectoderm, **6**, 116, 142, 143, **186**, 195, **202**,  
 207, 208, 214, 215, 217, 224, **252**,  
**254**, 255, **256**, 258, **259**, **261**, **262**,  
**263**, **265**, **266**, 267, **268**, **269**, 270,  
 271, **272**, **273**, 274, **275**, 278, **279**,  
 283, 296, 297  
 Ectoturbinals, 675  
 Edentata(es), 571, 742  
 Eddinger, Ludwig, 703  
 Eel, electric, **439**, 440  
 lamprey, 11, **90**, 149, 208, **413**, **414**,  
 415  
 round-mouthed (*see* Cyclostome)  
 Effectors, 158  
 Efferent (motor), 141  
 fibers, **142**, 179, 182, 717  
 nerves, 159, **184**  
 Egg(s), 87, 223, 227, **228**, 231, 233-235,  
**236**, 237-240, 244-246, **248**, **249**,  
**250**, **251**, 266, 288, 291, 482, 496,  
 644  
 air space of, **236**  
 membrane of, 260  
 nucleus of, **237**, **249**  
 passage of, **647**  
 pigment of, 249  
 Egg-case, **235**  
 Egg-cell, size of, 645  
 Eggshell, 293 (*see also* Shell)  
 Egrets, 545  
 Elau vital, 352  
 Elasmobranch(ii), **48**, **50**, 51, **57**, **69**,  
**72**, **80**, **90**, **119**, **143**, 283, 284,  
 289, **426** (*see also* Fishes, shark-  
 like)  
 classification of, 422-424  
 Elastic cartilage, 325  
 fibers, 321, **322**  
 Elastin, 321  
 Elbow, **131**  
 Electric eel, **439**, 440  
 lobes, 441  
 nerves, 441  
 organs, **439**, **440**, 441, 442  
 energy release from, 441  
 function of, 441  
 ray (Torpedo), **439**, **440**, 441  
 Electrophorus, **439**, 440  
 Electroplax, 440  
 Elephant(s), 44, **46**, **229**, 230, 757, 759,  
**760**, 761  
 dentition of, 760, 761  
 Elephant-bird, 554  
 Elephant-shrew, **680**  
 Elephas africanus, 761  
 indicus, 761  
 Elimination, 155 (*see also* Excretion)  
 Elk, 757  
 Embryo(s), **6**, **42**, 52, **58**, 59, **60**, 69, **75**, **76**,  
 81, **82**, **84**, **85**, **86**, 88, 89, **91**, **93**,  
**103**, **104**, **110**, **143**, **144**, **149**, **186**,  
 206, 207, 208, **220**, **226**, 227, 228,  
 238-244, **286**, 288, 289, **290**, 291,  
 292, 408, 482, **483**, **513**, **622**, 625,  
**642**  
 development of, 246-281, **254**, **259**, **261**,  
**262**, **263**, **268**, **272**, **273**, **275**, **279**  
 fish-like structures in, 788, 790  
 Embryology, 231, 338, 339, 350  
 comparative, 788-791  
 Embryonic shield, 264, **265**, **266**  
 Emergency theory of W. B. Cannon, 218  
 Emu, 543  
 Enamel, 35, **36**, **37**, **39**  
 organs, **39**, **41**, **42**, 47  
 Encephalon, 14 (*see also* Brain)  
 End-plate, **142**  
 Endocardium, 286, 622  
 Endochondral bone, **102**, 285  
 Endocrinal function, 215  
 organs, 215-227  
 Endocrine (ductless) glands, 139, 215-227,  
 276  
 substances, 646 (*see also* Hormones)  
 Endoderm, 214, 215, 216, 222, **252**, **254**,  
 255, **256**, 257, 258, **259**, 260, **261**,  
**262**, **263**, **265**, **266**, 267, **268**, **269**,  
**272**, 273, 274, **275**, 276, 283, 285,  
 292, 296, 297  
 Endolymph, 209, 210, 478, 692, 693  
 Endolymph(atic) duct, 209, **211**, 688  
 pores, 209  
 sac, 688  
 Endoneurium, **141**, 320  
 Endoskeleton, 101, 284  
 Endostyle, 399, 402  
 Endothelial lining, 286  
 Endothelium, 67, 286, 303  
 Endoturbinals, 674  
 Energy, muscular, 155  
 English sparrow, 528  
 Enteron, 268, 270, 274, 276, 288, **290**, **292**  
 Enteropneusta, 395  
 Environment, external, 156, 157  
 internal, 156, 157  
 of man, 803-806  
 modification of, 806-809  
 Eoanthropus, 771  
 Eocene, 776  
 Eohippus, 779, **780**  
 Eosinophils, 329  
 Epaxial muscle, 89, 91, **92**, **279**  
 Epiboly, 256  
 Epibranchial, 120  
 Epicardium, 23, 286, 287  
 Epiceratodus, 437, **438**  
 Epicoracoid, **132**  
 Epidermis, **18**, **19**, **20**, **39**, 193, **194**, 195,  
**196**, 258, 303, **307**  
 Epididymis, 79, **80**, 280, 283, 474, 650  
 Epiglottis, **199**  
 Epiphyal, 118  
 Epimere(s), **277**, 278, 287

- Epimeric zone, 278  
 Epinephrine (adrenalin), 190, 218, 219  
 Epineurium, **141**, 320  
 Epitotic, 125  
 Epiphysis(es), **132**, **144**, 149, 227, 598  
 Epipubic bones, 587, 649  
 Episternum, 114, 138, 472  
 Epistropheus, **4**, **109**, **110**, 111  
 Epithelial cells, 304-310  
   tissue, 303-310  
 Epithelium, 208, 276, 303-310  
   ciliated, **306**, 308  
   columnar, 304, **305**, **306**  
   cuboidal, **221**, **304**  
   digestive, 23, 27, 258, 274, **281**, 303  
   functions of, 306  
   glandular, 308  
   nasal, 195, 675  
   olfactory, 675  
   oral, **37**, **41**, 195, 196  
   pigmented, 201, **203**, **204**, 205, **273**  
   pulmonary, 59  
   sensory (nerve-), 308  
   simple, 304, **305**  
   squamous, **304**, **305**  
   stratified, **305**  
 Epitheloid tissues, 303  
 Equidae, 752, 754, 779  
 Equilibration, 166, 213, 697-701  
   organs of, 207-211  
 Equus, 752  
 Erinaceus, 736, **737**  
 Ermine, 747, **796**  
 Erythrocytes, 63, 65, 329, 634  
 Esophagus, **60**, 167, 183, **199**, 213, 638  
 Esox lucius, **135**  
 Estrone, 216  
 Ethical characteristics, 817, 818  
 Ethmoid, 124, 475  
 Ethmoturbinals, 674  
 Eudypetes antipodium, **547**  
 Eurycea lucifuga, **454**  
 Eustachian tube, **199**, 477, 693  
 Eutheria, 729  
 Evolution, 6, 231, 243-246, 266, 790, 807  
   of amphibians, 461, 791, 792  
   of birds, 541, 542, 793, 794  
   of chordates, 814, 815  
   convergent, 245, 557, 795  
   of fishes, 791  
   of mammals, 567, 568, 792  
   of man, 791-794, 812-815  
   of primates, 793, 794  
   of reptiles, 792  
   saltations, 342  
   theory of, 339-351  
   velocity of human, 309, 310  
   of vertebrates, 231, 243, 245, 810-812  
 Exciter neurons, 182, 219  
 Excretion, 155, 156, 280  
   organs of, 79-81, 155, 258  
 Excretory glands, 310  
   system, 79-88  
   and reproductive system, 79  
   tubules, 79, 82, **86**, **87**  
 Exoccipital, **107**, 124, 162  
 Exocoetus volitans, **799**  
 Exoskeleton, 101  
 Extensores digitorum muscles, **92**  
 Extensors, 93, 96  
 Exteroceptor, 140  
 Extrafetal membranes, 294  
 Extrauterine pregnancy, 646  
 Eye(s), 103, 112, 117, 125, 144, 147, **149**,  
   155, 200-207, **202**, **203**, **273**, 419,  
   451, 475, 476, **533**, 534, 535  
   forward-directed, 714  
   laterally directed, 714  
   of mammals, 680, **681**, 682, **683**, 684,  
   685, **686**, 687, 688  
   muscles, 99, 100, 155, 162, 163, 185, 287,  
   684, **685**  
     innervation of, 99, 100, 162, **163**, 185  
     paired, 200  
     pineal (median parietal), 207  
 Eyeball, 99, 162, 163, 164, 203, 287, 680,  
   684  
   meridional muscles of, 683  
   muscles of (see Eye muscles)  
 Eyelash, **203**  
 Eyelid(s), 100, 162, 206, 451, 476, 685, **687**
- F**
- Face, 604  
 Facial muscles, **98**, 100  
   nerves, 100, 164, 179, 198, 214  
 Falconiformes, 546  
 Falcons, 546  
 Fallopian tube, **80**, 646  
 Falx cerebri, **192**  
 Families, 390  
 Fascia, 95  
 Fasciuli, **153**  
 Fat(s), 19, 226, 284, **327**, 328  
 Fat-cells, **327**  
 Father, 237  
 Feather(s), 19, 286, 373, 382, 505-511  
   color of, 508  
   contour, **505**, 507, 509  
   development of, 509, **510**  
   down-, 507, 509, **510**  
   for flight, 509  
   tracts, **508**  
 Feet of horse and pig, **752**  
 Felidae, 747  
 Felis, **92**, **114**, 747  
 Female, 238  
   genitalia, 661  
   sex-glands, 216, 217  
   urinogenital system, **655**  
 Femur, 95, **107**, 131  
 Fenestra(e), 600  
   cochleae (rotunda), 696  
   ovalis, 478, 695  
   rotunda, 478  
   vestibuli, 695, 696  
 Ferret, 747  
 Fertilization, 236-238, 249, 260  
   external, 238  
   internal, 238

- Fetal membranes, 291-295  
 placenta, 295
- Fetus, **294**
- Fibers, afferent, **142**, 179, 182, 211  
 ascending, 154, 169, **170**  
 basilar, 692, 698  
 descending, 154, 169, **170**  
 dilator, 286  
 efferent, **142**, 179, 182  
 elastic, 321, **322**  
 meridional, **202**  
 motor, 160, **171**  
 muscle, **90**, **142**, **212**, 214, **314**, **315**  
   circular, 26, 201  
   longitudinal, 26  
   radial, 201  
   smooth, 154, 155, 185, 201  
   striated, 154, 156  
 nerve, **142**, 153, **180**, 272  
 afferent, **142**, 179, 182, 211  
 efferent, **142**, 179, 182, 717  
 olfactory, 713  
 parasympathetic, **178**  
 postganglionic, **171**, **178**  
 preganglionic, **171**, **178**, 184, 219  
 sensory, 140, 160, **171**, 184  
 somatic, 171, 182  
 sympathetic, **178**  
 visceral, 171  
 suspensory, **202**  
 of Tomes, 38, **39**  
 tracts, **153**, 708
- Fibrin, 328
- Fibrinogen, 328
- Fibrocartilage, 324  
 intervertebral, **109**
- Fibrocytes, 321
- Fibula, **107**, **131**, 512
- Filiform papillae, 670
- Filoplumes, 507
- Filum terminale, 173, 177, **178**, 595
- Fimbriated ostium abdominale, 646
- Fin-folds, **135**
- Fin-rays, 129
- Finback whale, 765
- Finches, 553
- Fingerprint patterns, 670
- Fins, **93**, 94, 198  
 caudal, 134  
 dorsal, **108**, 134  
 lateral, 93  
 median, 17, 134, **135**  
 migration of, 378, 379, 380  
 paired, 416  
 pectoral, 93, 94, 128, **130**, 133, **135**, 420  
 pelvic, 93, 128, 133, **135**, 438
- Fish(es), 13, 16, **22**, 220, 222, **229**, 283, **284**,  
**287**, **562**  
 amphibians compared with, 459-461  
 ancient, 421  
 bony, 113, **123**, 126, 127, 129, 133, 198,  
 216, 233, 234, 237 (*see also*  
 Teleostei)  
 carplike, 433  
 circulatory system of, **65**, **70**, **72**, **77**
- Fish(es)—(*Continued*)  
 classification of, 420-422  
 development of, 276, 278, 279  
 evolution of, 791  
 flying, 435, 798, **799**  
 ganoid, 113, 120, 276, 436, 437  
 heart of, 622  
 kidney of, 79, 85  
 lobe-fin, 420  
 morphology of, 416-442  
 muscles of, 89, 91, **93**, 94, 96, 97, 99, 100  
 nervous system of, 145, 151, 156, 159,  
 164, 165, 173, 191, 195, 196, **197**,  
 198, 207, 208, 210, 214  
 ray-fin, 420  
 reproductive system of, 233, 234, 238-  
 241, 244, 245  
 respiratory organs of, 59  
 scales of, 50, 51, **424**  
 sharklike, 28, 29, 47, 111, 113, 118, 127,  
 169, 207, 217, 224, 274 (*see also*  
 Elasmobranch)  
   classification of, 422-424  
 skeleton of, 101, **107**, 113-115, 122, 125,  
 126, 133, **136**  
 tails of, **423**  
 teeth of, 50-53, 55
- Fissipedia, 747
- Fissure, 704  
 choroid, **273**  
 of Sylvius, 706  
 ventral, **152**, 153
- Flamingos, 545
- Flatfishes, 14, 15
- Flatworm(s), 142
- Flavors, 679
- Flexors, 94, 96
- Flexure, cephalic, **144**  
 cervical, **144**  
 pontine, **144**
- Flight, adaptations for, 504, 505  
 coordination of, 535  
 feathers for, 509
- Flightless birds, 553-555  
 rails, 555
- Flipper, whale, 373
- Flocculus, 712
- Flounder, **16**
- Flycatchers, 553
- Flying birds, 542  
 fishes, 435, 798, **799**  
 foxes, 739  
 frog, 799  
 lemur, 736, **738**  
 lizard, **800**  
 mammals, 369, 370, **775**, 800  
 membrane, 369, 370  
 squirrel, **775**
- Focus, 206
- Fold(s), genital, 659-661  
 marsupial, 650  
 metapleural, 403  
 scrotal, 659  
 ventricular, 614  
 vocal, 614



- Foliate papillae, 671  
 Follicle(s) of feather, 506, **507** '
  - colloid-filled, **221**, 222, 224
  - ovarian, **232**
 Follicular cells, **237**
  - tissue, 645
 Fontanels, 116  
 Food, 288, 289, 528, 529, 595 (*see also* Diet)  
 Foot (pes), 94, 96, **131**, 132  
 Foramen(s), 116
  - incisive, 678
  - intervertebral, **109**
  - magnum, 116
  - of Monro, 150
  - parietal, 149, 602
  - transversarium, 592
  - triosseum, 519
  - vertebrarterial, 592
 Forearm, 94, 95, 131  
 Forebrain, **144**, **273**, **275**  
 Forehead, 100, 604  
 Forelegs, 134, **582**  
 Forelimb, **131**, **764**
  - modifications of, **570**
 Foreskin, 660  
 Form, external and internal, 373  
 Fossa, 130  
 Fossil birds, discovery of, 538-540  
 Fossorial adaptations, 801  
 Fovea centralis, **202**, 205, 206  
 Fowl(s), domestic, 234, 530
  - jungle, 546
 Fox(es), 747
  - flying, 739
 Frigate birds, 545  
 Frog(s), **27**, 56, **57**, **61**, 124, 173, 176, 230, **233**, 234, **236**, 239, 240, 245, **446**, 454, **455**, 456, **457**, 458
  - development of, **249**, **250**, **254**, 255, 276
  - flying, 799
  - Goliath, 458
  - green, 458
  - leopard, 458
  - metamorphosis of, 457
  - tree, 458
 Frontal(s), **107**, 124
  - arch, 122, 124
  - lobe, **177**, 706
  - muscles, **98**
  - planes, 12
  - sinuses, **199**, 605, 677
 Frugivorous mammals, 569  
 Fundus of stomach, **29**  
 Fungiform papillae, 670  
 Fur seals, 747  
 Furecula, 511
- G**
- Galago, **768**, **783**  
 Galeopithecus, 736, **738**, **775**  
 Gall-bladder, **14**, **32**  
 Galliformes, 546, 554  
 Gallus, 546  
 Gallus—(*Continued*)
  - domesticus, **516**
 Gangliated plexus, 174  
 Ganglion(s), 140, 143, 159, 174, 175
  - autonomic, 172, 173-179, **177**, 215, 217, 219
  - carotid, **178**
  - celiac, **178**, 179, 185
  - cells, 152, 169, **170**, **171**, 271
  - cephalic, 179
  - cervical, 176, **177**, **178**, 184, 185
  - chain, 176
  - ciliary, 163, 176, **178**, 179, 183
  - collateral, 179, 185
  - dorsal root, 179
  - Gasserian, **178**
  - geniculate, **160**, **161**, 166
  - jugular, **160**, **161**, 167
  - lateral, **161**, 167, 176, 179, 183, 184, 185
  - mesenteric, **178**, 179, 185
  - nodose, 167
  - otic, 176, **178**, 179, 183
  - petrosal, **160**, 166
  - semilunar (Gasserian), **160**, **161**, 164, **178**
  - sphenopalatine, 176, **178**, 179, 183
  - spinal, 169, **170**, 171, **177**, 271
  - spiral, 166
  - stellate, 176, **178**, 185
  - sublingual, 176, **178**, 179, 183
  - submaxillary, 176, 179, 183
  - sympathetic, **143**, **171**, **177**, 272
  - terminal, 179, 182, 183, 185
  - thoracic, 185
  - vestibular, 166
 Ganoid(ei), 113, 120, 276, 436, 437
  - scales, **20**, **424**
 Garpike, 432  
 Gases, respiratory interchange of, 58, 241, 293, 464, 465, 616  
 Gasserian (semi-lunar) ganglion, **160**, **161**, 164, **178**  
 Gastraea theory, 297, 392  
 Gastralia, 472  
 Gastric nerve, **161**  
 Gastrocnemius muscles, **92**  
 Gastrotheca, 245
  - marsupiata, **445**
 Gastrula, 227, **228**, 252-258, 296, 298
  - significance of, 297
 Gastrulation, **252**, 253, **254**, 255, **256**, 261, 263, 296  
 Gavia, **547**  
 Gavial, 491, **492**  
 Gazella granti, **759**  
 Gazelle, 757  
 Geese, 546  
 Genera, 390  
 Generations, alternation of, 231  
 Genes, 365  
 Genet, 747, **749**  
 Genetic continuity, 340, 346, 363-366  
 Genetics, 352, 353  
 Genetta, 747
  - vulgaris, **749**

- Geniculate ganglion, **160, 161**, 166  
 Genioglossus muscle, **99, 199**, 593  
 Geniohyoid muscle, **99**, 199, 593  
 Genital(s) (ia), 185, 186, **531, 660**  
   correspondence of parts, 661, 662  
   ducts, 238  
   female, 661  
   folds, external, 659, **660**, 661  
   internal, 659, **660**, 661  
   glands, 663-667  
   male, **663**  
   pores, 237  
   prominence, 659  
   ridge, **275, 279, 282**, 659  
 Geococcyx californianus, **508**  
 Geologic time, 411  
 Germ-cells, 233, 237  
   primordial, **282**  
 Germ-disk, 235, 249, **251**  
 Germ-layers, 251, **252**, 256-258, 261, **262**,  
   **263**, 264, 265, 288, 289, 291, 298  
   determination in, 298  
 Germ-plasm, continuity of, 352, **364**, 365  
 Germ-ring, 253, 261, 266, 273  
 Gestation, 243  
 Giant tortoises, 497  
 Gibbon, 771, **772**  
 Gill(s), 56, **57**, 58, 59, 245, 274, 275, 445  
   constrictors of, **93**  
   development of, 59  
   external, 442, **444**  
   internal, 442, **444**  
   and lungs, correspondence of, 359  
   permanent, 416  
   pouches, **60**  
   slits, **93**  
 Gill-breathers, 166, 167  
 Gill-clefts, **57**, 118, **160, 161**, 166, 268,  
   **269**, 270, 275  
 Gingiva, 37  
 Giraffe, 182, 230, 757  
 Giraffidae, 757  
 Girdles, 128, 129, 130, 133, 134  
   pectoral, 95, **99**, 128, **130, 131**, 133, 134,  
   495, 511, 583  
   pelvic, 95, 128, **131**, 132, 133, 138, 514  
   shoulder, 285  
 Gizzard, 230, 528, 529  
 Glacial Period, 793  
 Gland(s), 154, **270**, 285, 286, 310, 311  
   adrenal, 190, 217, **218, 219**, 220  
   alveolar (acinous), 310, **311**  
   anal, 663-667  
   ano-preputial, 665  
   of Bartholin, 664  
   buccal, 636  
   hulbourethral, 664, 665  
   ceruminous (wax), 577, 693  
   ciliary, 685  
   compound, 310, 311  
   Cowper's, 664, 665  
   cytogenic, 310  
   endocrine (ductless), 139, 215-227, 276  
   excretory, 310  
   genital, 663-667  
   Gland(s)—(Continued)  
   Harderian, 686  
   hrenal (blood-glands), 65  
   inguinal, 665  
   integumentary, **449**  
   labial, 636  
   lacrimal (tear), 183, 185, 206, 577, 686  
   lingual, 636  
   lymph (lymph-nodes), 63, **66, 634**  
   mammary, 226, 242, 243, 577, **578**  
   mucus, 636  
   multicellular, 310, **311**  
   musk-, 464, 665  
   of nasal cavity, 183  
   oil, 206, 511  
   olfactory, **197, 198**  
   orbital, 636  
   parathyroid, 215, **220**, 222, **223**, 276  
   parotid, 636  
   pharyngeal, 219, **220**  
   pineal, 149, 215  
   pituitary (see Pituitary gland)  
   poison, 55, 56, 155  
   preputial, 665  
   prostate, 185, 663, **664**, 665  
   rectal, 29  
   reproductive, 79-81, 87, 88  
   salivary, 176, 183, 185, 636, **637**, 638  
   scent-, 577, 665  
   sebaceous, 574  
   secretory, 310  
   serous, 199, 636  
   sex, 226  
     female, 216, 217  
     male, 216  
   in skin, 20  
   sublingual, 636, 637, **638**  
   submaxillary, 636  
   suprarenal (adrenal), 190, 217, **218, 219**,  
     220  
   sweat, 155, 184, 574  
   tarsal, **203**, 685  
   tear (lacrimal), 183, 185, 206, 577, 686  
   thymus, 215, **220**, 222, **223**, 276  
   thyroid, 215, **220, 221**, 222, 445  
   tubular, 310, **311**  
   uropygial, 511  
   vesicular, 663-665  
   vestibular, 664  
   wax (ceruminous), 577, 693  
 Glandular epithelium, 308  
 Glans penis, 659  
 Glenoid, 739  
   facet, 129, 130, **131**  
 Glomerulus(i), **80, 85, 86, 87, 277**, 280  
 Glossopharyngeal, 166, 179  
 Glottis, 59  
 Gluteal muscles, 95, **92**  
 Glycogen, 34, 216  
 Glyptemys, **251**  
 Glyptodonts, 778  
 Gnathostomata, 410  
 Gnu, 757  
 Goat, 757  
 Goatsuckers, 553

- Gobies, **800**  
 Goethe-Oken theory, **112, 344, 377**  
 Golgi-Mazzoni, corpuscles of, 193, **194**, 195  
 Goliath frog, 799  
 Gonad(s), 81, 88, 154, 231, **279, 281**, 282, 283, 403  
 Gopher, 740  
 Gorilla, **585, 771, 772**  
 Grandry's corpuscles, 193  
 Gray matter, **152, 153**, 169, 171, 179, 184, 185  
 Grebes, 545  
 Groove, peripharyngeal, 399, 402  
   primitive, **263, 266**  
   seminal, 659  
   urethral, 659  
   urinogenital, 659  
 Ground sloth, **778**  
 Grouse, 530, 546  
 Growth, 217, 226  
 Gruiformes, 546, 555  
 Grus, **550**  
 Gubernacular ligament, 655  
 Gubernaculum, 655  
 Guinea pig, 740  
 Gull(s), 529, 546, 556  
 Gustatory cells, **196**  
   organs (taste organs), 195-198, 670, 671  
 Gymnophiona, 239, 458, 459  
 Gymnotus, **439, 440**  
 Gyri, 704

## H

- Haddock, 378, **379**  
 Hagfish, 11, 208  
 Hair(s), 19, 155, 286, 373, 382, 573, **575**  
   cells, **196**  
   modification of, **370**  
   sensory, 209  
 Hair-feathers, 507  
 Hake, 378, **379, 432**  
 Halicore, 763  
 Hallux (great toe), **131, 132, 514**  
 Hand (manus), 94, 96, **131, 133**  
   of bird, 511  
 Hapalidae, 770  
 Harbor seals, 750  
 Harderian glands, 686  
 Hare, 740  
 Hatching, 260, 293, 295  
 Haversian systems, 325  
 Hawk(s), 529, 546  
 Hawksbill, 497  
 Head, 16, **17, 121, 199, 226**, 287, **291, 356**, **455, 492**  
   muscles of, **594**  
 Hearing, 166  
   of mammals, 697-701  
   of music, 700  
   organs of, 207-211  
   and respiratory organs, correspondence of, 358  
 Hearing—(*Continued*)  
   and vocalization, 699, 700  
 Heart, **6, 13, 63, 65, 73, 167, 174, 183, 185**, 213, **226, 242, 286, 448, 466, 527**, 528  
   of amphibians, 448, 622, **624**  
   of bird, 527, 625  
   chambers of, **623, 787**  
   development of, **72, 265**  
   embryonic, 621  
   of fishes, **418, 622**  
   of mammals, 621-629, **623, 624**  
   modifications of, 787  
   muscles (cardiac muscles), 213, **315, 316**  
   of reptiles, 465, **466, 622, 623, 624, 625**  
   three-chambered, 437, 787  
   two-chambered, 418, 787  
   ventral, 228  
   ventricles of, **64, 65, 67-69, 71, 625, 626**  
 Heartbeat, rate of, 528  
 Hedgehog, 736  
   European, **737**  
 Heidelberg man, 771  
 Hemal arch, 106, **107, 114**  
   glands (blood glands), 65  
   rib, **279**  
   spine, 106  
 Hemiazygos veins, **71**  
 Hemichorda(te), **394, 395, 396**  
   and echinoderms, 406  
 Hemipenes, 482  
 Hemisphere(s), animal, **250, 252, 257**  
   cerebellar, 712  
   cerebral, 145, 479, **480, 534, 708**  
   vegetal, 249, 250, **252, 253, 255, 257**  
 Hemoglobin, 329  
 Hen, 234, **236, 520, 531, 532**  
 Henle, loop of, **86**  
 Hepatic artery, **32, 64**  
   cecum, 403  
   cells, 31  
   diverticulum, **275**  
   ducts, 31  
   -portal system, 31, 74, 77  
   veins, **71**  
   tubule, 31  
   vein, **32, 64, 73, 74**  
 Heptanchus, **225**  
 Herbivorous mammals, 569  
 Hermaphrodite, 233  
 Hernia, inguinal, 652  
 Heron, 530, 545  
   great blue, **549**  
 Herpestes, 747  
 Hesperornis, **541, 543, 556, 557**  
 Heterocoelous, 515  
 Heterodont, 53, 55, 563, 564, 634  
 Highmore, antrum of, 677  
 Hilum, 643  
 Hindbrain, **144, 273, 275**  
 Hindlegs, 133, 138, 582  
   modifications of, **372**  
 Hip, **131**  
 Hippocampus, 435 (*see also* Sea horses)  
 Hippopotamidae, 755

- Hippopotamus, **755**  
 Histology, 301-330, 338, 339  
 Hoatzin, 410, 546  
 Holocephali, 424, **426**  
 Holonephros, 85  
 Holostei, 429, **430**, 432  
 Hominidae, 771  
 Homo heidelbergensis, 771  
   neanderthalensis, 771  
   rhodesiensis, 771  
   sapiens, 771, 802, 803 (*see also* Man)  
 Homodont, 53, 55, 56, 563  
 Homodynamy, 362  
 Homologous organs, 342, 370  
 Homologue, 362  
 Homology and analogy, 360-365  
   augmentative, 362  
   complete, 362  
   criteria of, 370-381  
     color, 371  
     embryonic origin, 378, 380, 381  
     form, 373  
     function, 381  
     number, 371, 372  
     position of organs, 374, 380  
     size, 371  
     structure, 373  
   defective, 362  
   definition of, 363  
   general, 362  
   incomplete, 362  
   special, 362  
 Homomorphic, 363  
 Homonymy, 362  
 Homothermous, 410  
 Homotypy, 362  
 Hoof(s), **19**, 573  
 Hoopoes, 551, **552**  
 Hopi Indians, **1**  
 Hormone(s), 139, 175, 215-219, 221, 222,  
   226, 243, 646 (*see also* Endocrine  
   substances)  
 Hornbills, 551  
 Horns, 573  
 Horny layer, 18, **19**, **307**, 463 (*see also*  
   Stratum corneum)  
   scales, 19, **20**, 573  
 Horse(s), 46, 100, 134, **752**  
   dawn, **780**  
   feet of, **780**  
   and man, correspondence of bones, **361**  
 Human (*see* Man)  
 Humerus, 95, **107**, **131**, **132**  
 Hummingbird(s), 234, 528, 551, 553  
 Humor, aqueous, **202**, 203  
   vitreous, 203  
 Humpback whale, 765  
 Hyaenidae, 747  
 Hyaline cartilage, 324  
 Hydatid, stalked, **80**  
 Hydra, 297, 311  
 Hydrochoerus capybara, **741**  
 Hyenas, 747  
 Hyla versicolor, 458  
 Hylidae, 458  
 Hynobius, 452  
 Hyoid, **99**, 122, 166  
   apparatus, 468, **469**  
   arch, 118, 122, 126, 166, 605  
   nerve, **160**, **161**  
   region, 167  
 Hyomandibular cartilage (pharyngohyal),  
   118, 127  
   nerve, **161**, 166  
 Hypaxial muscles, 89, 91, **92**, **279**  
 Hypobranchial, 120  
   muscles, **99**, **593**  
 Hypocentrum, 111  
 Hypogastric nerve, **178**, 185  
 Hypoglossal muscles, **93**, **99**, 593, 605  
   nerve, 168, 481, 482  
 Hypophyal, 118  
 Hypomere, **277**, 283, 286  
 Hypomeric zone, 278, 281  
 Hypophysial duct, 224, **225**  
 Hypophysis, **148**, 149, **178**, **220**, 224, 275  
 Hyracoidea, 761, 762, 779, 781  
 Hyrax, 762  
   capensis, **762**  
 Hystrix cristata, **741**
- I**
- Ibises, 545  
 Ichthyophis, 459  
 Ichthyopsida, 410, 413-461  
 Ichthyopsidan reproduction, 787  
 Ichthyopterygium, 128, **129**  
 Ichthyornis, **541**, 543  
 Ichthyosaur(s), **500**, **501**  
 Iguana tuberculata, **471**  
 Ileocolic valve, 639, 640  
 Ileum, 639  
 Iliac arteries, **64**, 68, **71**, 74  
   process, 129  
   veins, **64**, **71**, **74**  
 Ilium, **14**, **107**, 130, **131**, 133, 471, 514  
 Impregnation, 236, 238  
 Incisive foramen, 678  
 Incisors, **36**, **41**, **43**, **45**, 563  
 Ineus, 122, 563, 693-695  
 Infundibula (*of air-passages*), 616  
 Infundibulum (*of brain*), **144**, 149, 224,  
   225  
 Ingluvies, 528  
 Inguinal canal, 653  
   glands, 665  
   hernia, 652  
 Inheritance, 237, 352  
   of acquired characteristics, 311  
 Innervation, double, 189  
 Innominate arteries, 625  
 Inscriptioes tendineae, 589, 593  
 Insectivora(es), 571, **709**, 736, 776  
   relationships with primates, 784  
 Insectivorous mammals, 569  
 Insertion of muscles, 95, 100  
 Instinctive behavior, 481, 537, 558  
 Insulin, 215  
 Integrative systems, 139-230

Integument, 17-20 (*see also* Skin)  
 Integumental muscles, 100  
 Integumentary glands, **449, 574, 575**  
   sense-organs, 581  
 Intelligence, 481, 536, 537, 808, 815, 817  
   and brain complexity, 721, 722  
 Intercalary neuron, **142**  
 Intercalated disks, 315, 316  
 Inter-cellular spaces, 63, 301  
 Interclavicle, 114, 138, 472  
 Interclavicular ligament, **132**  
 Intercostal muscles, 214, 586  
 Interfemoral membrane, 739  
 Interlobar arteries, 86  
 Interocceptor, 140  
 Interoperculum, 122, 126  
 Interorbital septum, 517  
 Interrenal bodies, 217  
 Interspinales, 591, 592  
 Intertransversarii, 591, 592  
 Intervertebral disks, 597  
   foramen, **109**  
 Intestine, 25, 167, **269, 270**, 276, **279**, 529  
   large, 25, 185, 186, 529, 530  
   of mammals, 639-641  
   small, **14**, 25, **174**, 183, 529, 530  
 Invagination, **252**, 253-255, **256**, 257, 262  
 Invertebrate(s), 17, 82, 101, 142, 195, 198,  
   298, 312, 405  
 Investing bone (membrane-bone), 103,  
   **107**, 285  
 Involuntary muscles, 96, 156, 157, 213,  
   214, 215  
 Iris, 155, 183, 201, **202**  
 Irritability, 140, 192  
 Ischiopubis, 129  
 Ischium, **107**, 130, **131**, 514  
 Islands of Langerhans, 32, **34**, 215, **216**  
 Ivory, 46

## J

Jacobson, organ of, 475, 532, 678  
 Jaguar, 747  
 Java man, 771  
 Jaw(s), **42, 43**, 96, **99**, 118, 122, **123**, 126,  
   136, 137, 166, 285  
   joint of, 602  
   movement of, in birds, **517**  
   relation to cranium, 127, 128  
   skeleton, 421  
 Jejunum, **14, 30**, 639  
 Joint of jaws, 602  
 Jugal, 126, 128, 601  
 Jugular ganglions, **160, 161**, 167  
   veins, **66, 71, 73, 74**  
 Jungle fowls, 546  
 Jurassic, 540, 773

## K

Kangaroo(s), 230, 238, 243, 735  
 Keratin, 18, 306

Kidney(s), 14, 79-86, **71, 80, 86**, 154, 155,  
   183, 185, **218**, 238, 241, 473, 531,  
   641, 642, **643**  
   correspondence of, 359  
   cortex of, 82, **86**  
   development of, **279**, 280, **281**  
   lobulated, **642, 643**  
   modifications of, 787  
 Kingfisher(s), 551, 552  
 Kinkajou, 747, **748**  
 Kiwi, 544  
 Knee, **131**  
 Knee-cap (Patella), **131, 133**  
 Koala, **735**  
 Krause, corpuscles of, 193, **194**

## L

Labia majora, 661  
   minora, 661  
 Labial glands, 636  
 Labor, division of, 297  
 Labyrinth(s), bony, 692, 693  
   membranous, 208, 689  
   nasal, 677  
 Labyrinthodont(ia), **44**, 460  
 Lacerta, **476, 480**  
 Lacertilia, 484  
 Lacertina, 452  
 Lacrimal bone, 125  
   duct, 199  
   glands (tear glands), 183, 185, 206, 577,  
     686  
   nerve, **178**  
   sinus, 686  
 Lacteals, 65  
 Lacuna(s), 37, **265**, 284, 323, 325  
 Lagena, 208, **209**, 210, **211**, 477  
 Lagomorpha, 740-742  
 Lamellas, 284, 285, 325  
   branchial, 56, **57, 58**  
 Lamina (dental ridge), **39, 41**  
   labial, 39, 40  
   lingual, **39, 40**  
   spiralis, 693  
   terminalis, **148**, 150, 710  
 Lampreys (lamprey eels), 11, **90**, 149, 208,  
   **413, 414**, 415  
 Langerhans, islands of, 32, **34**, 215, **216**  
 Langur, 771  
 Larks, 553  
 Larva(ae), 236, 239, **240**, 244  
   of amphibians, 442, **443, 444**, 445  
   urochordate, **398**  
 Larvacea, 401  
 Laryngeal cartilages, **612**  
   ligaments, **612**  
 Laryngo-tracheal tube, **60**  
 Larynx, 59, **61, 98**, 167, **199**, 525, **612, 613**,  
   614, 615, **671**  
   differentiation in, 615  
 Latebra, **236**  
 Lateral ganglion, **161**, 167, 176, 179, 183,  
   184, 185  
   lobes, 151, 712

- Lateral—(*Continued*)  
vein, 73
- Lateral-line canal, **165**, 167  
organs, **164**, 165, 166, 195, 420, 442, 451
- Lateralis nerve, **161**, **165**
- Latimeria, 420, 425
- Latissimus dorsi (muscles), 95, 100, 583
- Law (*see also* Principle, Theory)  
of biogenesis, 349  
Mendel's, 352  
of recapitulation, 7, 298, 299, 349, 380
- Layer(s), choroid, 201, **202**  
germ-, 251, 252, 256–258, 261, 262, **263**,  
264, 265, 288, 289, 291, 298  
horny, 18, **19**, 307, 463 (*see also* Stratum  
corneum)  
mesodermal, 268, 269, 277, 292  
odontoblast, 38, 40, **42**, 47  
parietal, 283  
sclerotic (sclera), 117, 201, **202**, **203**,  
533, 681  
somatic (parietal), 269, 270, 278, **279**,  
281  
visceral (splanchnic), 269, 270, 278, 281,  
283
- Leg(s), 94, 511, 566, 569 (*see also* Forelegs,  
Hindlegs)
- Legless lizards, 486, **488**
- Leibnitz, 339
- Lemur(s), 294, **768**, **783**  
flying, 736, **738**
- Lemuroidea, 768
- Lens, 201, **202**, **273**, 476, 684  
capsule, 684
- Leopard, 747  
frog, 458
- Lepidosiren, 437
- Lepidosteus, 432
- Leukocyte(s), 63, 65, 329  
mononuclear, 329  
polymorphonuclear, 329
- Levator muscles, **92**, 96, 162, 163
- Life, definition of, 3
- Ligament(s), 127, 321  
cartilages in, **132**  
costocoracoid, **132**  
gubernacular, 655  
interclavicular, **132**  
laryngeal, **612**  
stylohyoid, **99**, 607  
styloid, 122  
suspensory, 22, **203**, 683
- Limb-bud, **93**
- Limbs, pectoral, 128, 133  
pelvic, 128
- Linea alba, 588
- Lingual glands, 636  
nerve, **178**
- Linnaean binomial, 390
- Lion, **43**, **584**, 747
- Lips, 100
- Liver, **6**, **14**, 29–35, **32**, 74, 183, 185, 216,  
**287**, 530  
development of, 29, 31, 258, 276, **281**  
functions of, 35
- Lizard(s), **61**, 128, **229**, 238, 244, 245  
484, **487**, **488**, 490  
flying, **800**  
legless, 486, **488**
- Llamas, **757**, **758**
- Lobe(s) of brain, 145, 151  
electric, 441  
frontal, **177**, 706  
lateral, 151, 712  
of lungs, 287  
median, 712  
occipital, **177**, 706  
olfactory, **144**, 145, 148, 198, 710  
optic, 150, 534, **535**, 536, 537  
parietal, 706  
of pituitary, 224, **225**, 226  
temporal, **177**, 706
- Lobe-fin fishes, 420
- Lobule, lung, 616, **617**
- Locomotion, 804, 805
- Locomotor appendages (*see* Appendages)
- Longissimus capitis muscles, 592  
cervicis muscle, 592  
dorsi muscle, 589, 592
- Longus capitis muscles, 592  
colli muscles, 592
- Loons, 545, **547**, 556
- Loop of Henle, **86**
- Lophodont, 53
- Lorenzini, organs (ampullae) of, 165
- Lumbar curvature, **4**, **109**  
muscles, **591**  
nerves, **177**  
plexus, 172, **177**  
vertebrae, **4**, **109**, 596
- Lumbosacral enlargement, 152  
plexus, 172
- Lung(s), 14, 56, 58–62, **71**, 167, 174, 183,  
185, 198, 214, 285, **287**, 445, **465**,  
**495**, **520**  
of amniotes, 618–621  
of birds, 519–525  
of cetaceans, 618  
development of, 59, **60**, 258, 276  
and gills, correspondence of, 359  
lobes of, 287  
lobule of, 616, **617**  
of mammals, 616–621  
of reptiles, **619**, 620  
structure of, 59  
tubular, 620
- Lung-sac, **60**, 437
- Lungfish(es), **19**, 55, 151, 198, **306**, 437  
Australian, 55
- Lutra, 747
- Lymph, 63, 330  
-heart, 632  
movement of, 632  
-nodes, (-glands), 63, **66**, **634**  
sinus, **66**
- Lymphatics, **30**, 63, 65, **67**, **68**, 632, **633**,  
634
- Lymphocyte, 329
- Lymphoid tissue, 633
- Lynx, 747

## M

Macaque, 771  
 Macaws, 551  
 Macropus, 774  
   major, 243  
 Macula(ae), **209**, 210, **211**, 692  
   acustica sacculi, 692  
   utriculi, 692  
   lutea, 205  
 Magnum foramen, 116  
 Malapterurus, 440-442  
 Malar, 122, 126, 128, 601  
 Male, 238, **239**  
   genitalia, **660**, **663**  
   sex-glands, 216  
   urinogenital system, **652**, **657**  
 Malleus, 122, 563, 693, 695  
 Malpighian (renal) corpuscle, 84, **87**, 280  
 Maltase, 637  
 Maltose, 637  
 Mammal(ia), 16, 21, **22**, 227, **284**, **287**,  
**292**, 293, 295, 409, 410, 559-784  
   adaptations of, **782**  
     to climate, 568  
     to pressure, 569  
   alimentary system of, **47**, 52, 53, 55,  
     56, 634-642  
   anal glands of, 663-667  
   aortic arches of, 621, **624**  
   appendages of, 581, **582**, 583  
   aquatic, 678, 687, 800  
   behavior mechanism of, 715-723  
   brains of, 701-713  
   carnivorous, 569 (*see also* Carnivora)  
   characteristics of, 561  
   circulatory organs of, **66**, 68, 69, **71**,  
     **72**, 621-634, **624**  
   classification of, 725-784  
   cloacal region of, 656, **657**, 658  
   copulatory organs of, 658, 659, **660**,  
     **661**, 662, **663**  
   cranial nerves of, 713-715  
   development of, 273, 275, 276  
   diet of, 569  
   differentiation of teeth, 730  
   and dogfish, spiracle and ear, 357-359  
   ear of, 688-701  
   early, 561-570  
   endocrinal organs of, 216, 217, 220, 221,  
     222  
   equilibration of, 697-701  
   esophagus of, 638  
   evolution of, 567, 568, 792  
   excretory organs of, 641-643  
   eye of, 680, **681**, 682, **683**, 684, 685, **686**,  
     687, 688  
   flying, 369, 370, **775**, 800  
   frugivorous, 569  
   genealogic tree of, **777**  
   general form of, 572  
   genital glands of, 663-667  
   hearing of, 697-701  
   heart of, 621-629, **623**, **624**  
   herbivorous, 569

## Mammal(ia)—(Continued)

  history of, 564  
   insectivorous, 569  
   intestine of, 639-641  
   lungs of, 616-621  
   lymphatics of, 632, **633**, 634  
   marsupial (*see* Marsupials)  
   morphology of, 559-784  
   motor mechanism of, 581-607  
   Müllerian ducts of, 643-650  
   muscles of, 91, **92**, **94**, 98, **99**, 100, 581  
     607, **587**  
   mytmecephalous, 569  
   neck of, 591-593  
   nervous system of, 145, 149, **150**, 151,  
     155, 160, 166, 167, **181**, 191, 193,  
     198, **203**, 208, 210, 213, 667-723  
   nomenclature of, 729  
   nose, snout, trunk of, 679, 680  
   olfactory organs of, 671-679  
   omnivorous, 569  
   origin of, 559-561  
   ovaries of, 643-650  
   oviparous, 650  
   pharynx of, 610-612, 638  
   placental, 243, 263-266, 646, 653, **657**,  
     662  
   profile of, 602, **603**, 604, 605  
   relationships among, 771-784  
   reproductive system of, 88, 233, 234,  
     236, 238, 242-246  
   respiratory organs of, 610-621  
   salivary glands of, 636, **637**, 638  
   sense organs of, 668-701, **669**  
   size of, **569**  
     and size of ovaries, 644-646  
   skeleton of, 106, 115, 117, 122, 125, 126,  
     128, 561, 581-607  
   skin of, 573-581  
   skull of, 600-607  
   stomach of, 638, 639  
   tail of, 594, 595  
   taste organs, 670, 671  
   teeth of, **47**, 52, 53, 55, 56, 634-636, 730  
   testis of, 650-656  
   trachea of, 612-616  
   trunk of, 583-591  
   types of, 570-572  
   urinogenital system of, 79, 80, **86**, 641  
     666  
   veins of, 630, **631**, 632  
   vertebral column of, 596-600  
   visceral systems of, 609-667  
   Wolffian ducts of, 650-656  
 Mammary glands, 226, 242, 243, 577, **578**  
   organs, 577-580  
   pocket, 578  
 Mammillary body, **144**  
 Mammoths, 761  
 Man (human) (Homo), 2, 3, **4**, 5, **6**, 13,  
**14**, **229**, 571, **574**, **577**, **579**, **580**,  
**591**, **606**, **612**, **638**, **639**, **642**, **691**  
   alimentary system of, **29**, **30**, **32**, **36**,  
     **38**, 39, 40, **42**, **43**, **45**  
   brain of, **705**, **706**, **708**

- Man—(Continued)  
 brain-stem of, **709, 712**  
 chimpanzee compared with, 803  
 circulatory system of, **66**  
 classification of, 771  
   proposed, 819  
 and climate, 805  
 competitors of, 815  
 Cro-Magnon, 771  
 and diet, 805  
 ear of, **357, 694**  
 endocrinal organs of, **219, 220, 221, 223, 225**  
 environment of, 803-806  
 ethical characteristics of, 817, 818  
 evolution of, 791-794, 812-815  
   in future, 816-818  
 genitalia, **660**  
 Heidelberg, 771  
 and horse, correspondence of bones, **361**  
 interdependence of, 818  
 Java, 771  
 locomotion of, 804, 805  
 muscles of, 94, 95, **98, 99, 100**  
 nasal cavity of, **677**  
 Neanderthal, 771  
 nervous organs of, **144, 145, 150, 151, 152, 166, 173, 177, 178, 184, 197, 199, 204**  
 olfactory organ of, 675, **676**  
 Peking, 771  
 Piltown, 771  
 place in nature, 812  
 prostate glands of, **664**  
 reproductive system of, **85, 237, 244**  
 skeleton of, **103, 106, 109, 114, 122, 130, 131, 132**  
 survival of, 815  
 teeth of, **36, 38, 39, 40, 42, 43, 45**  
 unfavorable characteristics of, 815, 816  
 urogenital system of, **84, 86, 652, 655**
- Manatee, **763**  
 Manatus, **763**  
 Mandible, **37, 199**  
 Mandibular arch, 118, 122, 125, 127, 605  
   cartilage, 118, 126  
   nerve, **160, 161, 164, 165, 166**
- Manis tricuspis, **746**  
 Manus (hand), 94, 96, 131, 133  
 Marmoset(s), 770  
   golden, **769**
- Marrow, 212, 325  
 Marsupial(s), 238, 239, 242, 243, 245, 294,  
   571, 648, 653, 658, 725, 728, 733  
   bones, 587, 649  
   fold, 650  
   mole, 733  
   penis of, 662  
   pouch, 238 (see also Marsupium)  
   relationships with placentals, 773-776  
   urogenital organs of, **649, 657**
- Marsupialia (marsupial mammals), (see Marsupial(s))  
 Marsupium, 242, 243, 245, 649  
 Marten, 747
- Masseter muscles, **92, 601**  
 Matrix, 285, 320, 323  
 Maturation, 237  
 Maxilla, 126, 127, 199  
 Maxillary nerve, **160, 161, 164**  
   sinus, 677  
 Maxilloturbinal, 674  
 Meatus, auditory, 534  
   urinarius, 660  
 Mechanical axis, 12, 104, 112, 136  
 Meckel's cartilage, 118, 126  
 Median lobe, 712  
 Mediastinal septum, 21, 22  
 Medulla, adrenal, 217, 218, **219**  
   of kidney, 82, **86**  
   oblongata, **148, 151, 158**  
 Medullary (myelin) sheath, **140, 141, 142, 183, 319**
- Megachiroptera, 739  
 Megalobatrachus, 452  
 Megalocnus, **778**  
 Megaptera, 765  
 Meibomian glands, 685  
 Meissner, corpuscles of, 193, **194**  
   plexus of (myenteric plexus), **174**  
 Melanophores, 321, 322
- Membrana basilaris (basilar membrane),  
   690, 698  
   tectoria, 692, 698
- Membrane(s), basement, 305  
   basilar (membrana basilaris), 690, 698  
   chorio-allantoic, 293, 294  
   cloacal, 659  
   embryonic, 291-295  
   extrafetal, 294  
   fetal, 291-295  
   flying, 369, 370  
   interfemoral, 739  
   nictitating, 451, 476, 685  
   oral, 274  
   semilunar, 527  
   shell-, 235, 236  
   tympanic, 477, 534, 693  
   tympaniform, 526  
   vitelline, 233, 234, 235, **236, 249, 256**
- Membrane-bone (investing bone), 103,  
   **107, 285**
- Membranous labyrinths, 208, 689  
 Mendel's Law, 352  
 Meninges, 191, **192**  
 Meninx primitiva, 191  
 Menstruation, 216  
 Mentalis muscles, **98**  
 Mephitis, 747  
 Meridional fibers, **202**  
 Merkel, cells of, 193  
 Mesaxonic, 751  
 Mesectoderm, 283  
 Mesencephalon, **6, 144, 145, 148, 711**  
 Mesenchyme, **103, 278, 279, 283, 284, 285, 286-288**  
   cells, 285  
 Mesenteric arteries, **64, 68, 71**  
   ganglion, **178, 179, 185**  
   veins, **64**



- Mesentery(ies), 22, **194**, 195, 278, **279**, 281, 282
- Mesethmoid, 124
- Mesobronchus, 519
- Mesocoelae, 145, 151
- Mesoderm, 81, 82, 89, 91, 92, 93, 96, 97, 154, 156, 173, 213, 215, 217, 258, **259**, 260, **261**, **262**, **263**, 265, **266**, 270, **272**, 273, **275**, **277**, 289, 296
- Mesodermal folds, 261
- layers, 268, 269, 277, 292
- pouches, **259**, 260, 267, **268**, 270
- somites, **261**, **270**, 283
- Mesomere(s), **277**, 278
- Mesomeric zone, 278
- Mesonephric (Wolffian) duct, **80**, 81, 82, **83**, 87, 88, 280
- tubules, 81, **82**, 85, 280, 283
- Mesonephros, 79-87, **80**, **83**, 279, 280, 282, 473, 474
- Mesopterygium, **129**
- Mesothelium, 303
- Mesovarium, 282
- Mesozoic, 497, 560, 567, 789
- Metabolism, 221, 226, 246, 247, 251
- basal, 221, 222
- Metacarpals, **107**, **131**
- Metamorphosis, 240, 244, 299, 445, 457, 458
- degenerative, 406, 407
- of frogs, 457
- of toads, **457**
- Metanephric tubule, 85
- Metanephros, **71**, 79, 86, **80**, 88, 280, 641
- Metapleural folds, 403
- Metapterygium, **129**
- Metatarsals, **107**, **131**, 132, 512
- Metatheria, 243, 729
- Metazoa, 390
- Metencephalon, **6**, **144**, 145, **148**, 151, 712
- Michelangelo, **807**
- Microchiroptera, 739
- Midas chrysoleucas, **769**
- Midbrain, **144**, 273, **275**
- Migration of cells, 52
- Milk, 242, 243
- teeth, **39**, 40, **42**, **43**, **49**, 54
- Milk-line(s), 578, 580
- Mink, 747, **748**
- Mitral valve, 622
- Moa, 554
- Molars, **38**, **43**, **45**, **563**
- Mole, 736, **775**
- golden, **737**
- marsupial, 733
- Molgula, 397
- Mollusk, 101
- Molting, 508
- Mongoose, 747
- Monkey(s), **66**, **98**, **770**
- platyrrhine, **769**
- proboscis, 771
- rhesus, **588**, **589**, **594**, **661**, **671**
- Monodelphia, 729
- Monodon, 765
- Monoecious, 233
- Mononuclear leucocyte, 329
- Monophyodont, 54, 635
- Monotrema, 729
- Monotreme(ata), 571, **657**, 658, 661, 726, 728, 733
- copulatory structures of, 662
- reptilian characteristics of, 771
- Mouro, foramen of, 150
- Moose, 757
- Mormyridae, 440
- Morphology, causal, 351-353
- comparative, 353
- experimental, 353
- Morula, 263, **264**
- Mosasaurs, 500
- Mother, 237, 239, 243
- Motmots, 551
- Motor, 141
- cells, **142**, **152**, 160, **171**
- fibers, 160, **171**
- nerve-endings, **314**, **315**
- nerves, 159, 160, 182
- plate, 316
- system, 89-138
- tracts, 154
- Mouse (mice), **232**, **233**, 740
- Mouse deer, 757
- Mouth, 25, 98, 196, 198, 214, 268, 270, 274
- cavity, **14**, 25, **26**, 166, 195, 196, **199**
- floor of, 166
- roof of, 122, 125, 127, 136, 137, 166, 176, 198
- Mucin, 637
- Mucosa, **28**, **198**
- Mucus, **197**, 199
- glands, 636
- Mudfish, 432
- Müllerian duct(s), **80**, 87, 88, 283, 643-650
- Multipolar cell, **140**, 316, **317**
- Multitubercular, 53
- Multituberculata, 567
- Murres, 546
- Mus, 740
- Muscle(s), 89-100, 258, 581-607
- abductor, 94, 96
- acromiodeltoid, **92**
- adductor, 96
- appendicular, 92-97
- auricular, **98**
- belly of, 95
- biceps, 95
- femoris, **92**
- of birds, 518, 519
- body-, 89-92, **281**
- branchiomeric, 96-100, **97**, 120, 166, 167, 213, 288
- canine, **98**
- cardiac (heart), 213, 287, **315**, 316
- caudal, 288
- cephalohumeral, **92**
- ciliary, 155, 183, 534, 683, 684
- circular, **28**, **30**, 683
- cleidomastoid, **92**, 168
- cremaster, 615, 652

Muscle(s)—(*Continued*)

- cricoarytenoid, 614
- cricothyroid, 614
- depressor, 94, 96
- differentiation of, 786
- digastricus, **92**
- dorsal, **589, 590**
- elevator, 93, 128
- energy of, 155
- epaxial, 89, 91, **92, 172, 279**
- extensor, 93, 96
- extensores digitorum, **92**
- extrinsic, 95
- eye, 99, 100, 155, 162, 163, 185, 287, 684, **685**
- facial, **98, 100, 166**
- fibers, **90, 182, 212, 214**
  - circular, 26, 201
  - longitudinal, 26
  - radial, 201
  - smooth, 154, 155, 185, 201
  - striated, 154, 156
- flexor, 94, 96
- as food, 595
- frontal, **98**
- gastrocnemius, **92**
- genioglossus, **99, 199, 593**
- geniohyoid, **99, 199, 593**
- gluteus, 95
  - maximus, **92**
- head, **594**
- heart (cardiac), 213, 287, **315, 316**
- hypaxial, 89, 91, **92, 172, 279**
- hypobranchial, **99, 593**
- hypoglossal, **93, 99, 593, 605**
- innervation of, 96, **171**
- insertion of, 95, 100
- integumental (subcutaneous), 100
- intercostal, 214, 586
- intrinsic, 95
- involuntary, 96, 156, 157, 213–215
- latissimus dorsi, 95, 100, 583
- levator, 96
  - claviculae, **92**
  - palpebrae superioris, 162, 163
- longissimus capitis, 592
  - cervicis, 592
  - dorsi, 589, 592
- longitudinal, **28, 30**
- longus capitis, 592
  - colli, 592
- lumbar, **591**
- masseter, **92, 601**
- mentalis, **98**
- mimetic, **98**
- mylohyoid, **199**
- nasal, **98**
- neck, 288, 594
- non-striated, 96, 154, 155, 156, 285, 288, 312, **313**
- oblique, 162, 164
  - inferior, **163**
  - internal, 588
  - superior, **163**
- occipital, **98**

Muscle(s)—(*Continued*)

- omohyoid, **99**
  - orbicularis oculi, **98**
    - oris, **98**
  - origin of, 95
  - panniculus carnosus, 100
  - papillary, 622
  - pectoralis, **92, 95, 100, 518, 519, 583, 588**
  - platysma, **98, 100**
  - pronator, 96
  - quadratus labii, **98**
  - rectus, 162, **163, 588**
    - anterior, 162, **163**
    - posterior, 162, **163**
  - retractor, 96
    - bulbi, 685
  - rhomboideus, 95
  - rotator, 96
  - sartorius, **92**
  - scalenus, 592
  - segmented, 154, **275**
  - semimembranosus, **92**
  - semitendinosus, **92**
  - serratus magnus, **92**
  - smooth, 179, 218, 285, 312 (*see also* Non-striated muscles)
  - somatic, 154, 155, 156, 157
  - sphincter colli, **92, 100**
    - pyloric, **29**
  - spinodeltoid, **92**
  - stapedius, 98, 696
  - sternohyoid, **99, 593, 605**
  - sternomastoid, **92, 168, 593, 594**
  - sternothyroid, **99, 593**
  - striated, 96, 100, 154, 156, 157, 182, 212, 213, 278, 287, 288, 312, **313**
  - subclavius, 519
  - subcutaneous, 100, 581
  - supinator, 96
  - temporalis, **92, 601**
  - tensor tympani, 98
    - vaginae femoris, **92**
  - thoracic, **591, 594**
  - thyroarytenoid, 614
  - thyrohyoid, **99, 593**
  - tonus, 718
  - transverse, 588, 652
  - trapezius, **92, 95, 99, 168, 583**
  - triangular, **98**
  - triceps, **92**
  - trunk, **90, 473, 587**
    - unsegmented, 154, 156
  - visceral, 89, 96, 97, 154, 156
  - voluntary, 156, 157, 213, 214, 215
  - zygomatic, **98**
- Muscle-spindles, **212**
- Muscular tissue, 311–316
- Muscularis mucosae, **28, 30**
- Musk-glands, 464, 665
- Mustela, 747
- Mustelidae, 747
- Mutation theory, 352, 365
- Myelencephalon, **6, 144, 145, 148, 151, 713**
- Myelin (medullary) sheath, **140, 141, 142, 183, 319**

- Myelon, 145 (*see also* Spinal cord)
- Myenteric plexus, **174**
- Mylohyoid muscle, **199**
- Myocardium, 286
- Myocoele, **269, 277, 278, 279**
- Myocomma, 89, 91, 269
- Myofibrils, 311, 312
- Myomeres, 89, **90, 91**
- Myoseptum(s), 89, 91, 269
- Myotomes, 81, **83, 89, 91, 96, 99, 110, 213, 269, 271, 275, 278, 279**
- Myrmecobius, 774
- Myrmecophaga, 743
- Myrmecophagous, 569
- Mystacoceti, 765
- Myxine, **225, 233, 275, 413, 414, 415**
- N**
- Nail(s), **19, 576**
- Nail-plate, **576**
- Naris, 198
- Narwhal, 13, **16, 765**
- Nasal(s) (bone), 107, 125, **199**
- cavity, **14, 195, 197, 198, 199, 677**
- glands of, 183
- chamber, 414
- epithelium, 195, 675
- labyrinth, 677
- muscles, **98**
- nerve, **178**
- organs, 112, 116, 476 (*see also* Olfactory organs)
- passages, 610, **674**
- region, 121, 124, **475**
- scrolls, 674
- Nasociliary nerve, **178**
- Nasolacrimal duct, 686
- Nasopalatine duct, 475, 678
- Nasoturbinal, 674
- Natural selection, 345, 366
- Neanderthal man, 771
- Neck, 16, **17, 168, 175**
- of mammals, 591-593
- muscles of, 288, **594**
- of tooth, 35, **36**
- Necturus, **61, 64, 84, 92, 114, 234, 240, 287, 288, 452, 461, 473**
- maculosus, **443**
- Neēncephalon, 704
- Neoceratodus, 55, 437
- Neognathae, 543, 544
- Neornithes, 543
- Neoteny, 445
- Nephrogenic tissue, 86
- Nephrostome(s), 82, 84, 85, **87, 277, 280**
- Nerve(s), **141, 143, 281**
- abducent, 100, **163, 164**
- accessory, 168, 183, 481, 482
- acoustic (auditory), 166, 692, 715
- afferent, 159, **184**
- autonomic, distribution of, 183-186
- functional components of, 179-183, **180**
- bronchodilator, **178**
- buccal, **160, 165**
- Nerve(s)— (*Continued*)
- centers in brain, 157, **158**
- cervical, **177, 184**
- chorda tympani, **160, 161, 166, 178**
- classes of, 157-159
- coccygeal, **177**
- cochlear, 166
- collector, **172**
- cordis (accelerator and inhibitor), **178**
- cranial, 99, 100, 159-169, **160, 183, 451, 481, 482, 537, 713, 714, 715**
- groups of, 168, 169
- efferent, 159, **184**
- electric, 441
- facial, 100, 164, 179, 198, 214
- fibers, **142, 153, 180, 272**
- afferent, **142, 179, 182, 211**
- efferent, **142, 179, 182, 717**
- parasympathetic, **178**
- postganglionic, **171, 178, 184**
- preganglionic, **171, 178, 184, 219**
- sensory, 140, 160, **171, 181**
- somatic, 171, 182
- sympathetic, **178**
- visceral, 171
- gastric, **161**
- glossopharyngeal, 166, 179
- hyoid, **160, 161**
- hyomandibular, **161, 166**
- hypogastric, **178, 185**
- hypoglossal, 168, 481, 482
- lacrimal, **178**
- lateralis, **161, 165**
- lingual, **178**
- lumbar, **177**
- mandibular, **160, 161, 164, 165, 166**
- maxillary, **160, 161, 164**
- mixed, 160
- motor, 159, 160, 182
- nasal, **178**
- nasociliary, **178**
- oculomotor, 100, 162, **163, 178, 179**
- olfactory, 143, 162, 198
- ophthalmic, **160, 161, 164**
- optic, 150, 162, **163, 201, 202, 203, 204, 273, 711, 713**
- palatine, **160, 161, 166**
- pelvic, **178, 185**
- petrosal, **178**
- phrenic, 213
- post-trematic, **160, 161, 166, 167, 169**
- pretrematic, **160, 161, 166, 167, 169**
- in pulp-cavity, **37, 38**
- sacral, **177**
- sensory, 159, 160, 182
- somatic, 160
- spinal, 169-173, **170, 177, 180, 184, 272**
- spino-occipital, 168
- splanchnic, **177, 178, 179, 185**
- structure of, **319**
- terminations, free, **193, 194, 195, 212, 308, 309**
- thoracic, **177**
- trigeminal, 42, **161, 164**
- trochlear, 100, **163, 164**

- Nerve(s)—(*Continued*)  
 trunks, sympathetic, **177**  
 vagus (pneumogastric), **28, 160, 167, 178**  
 vertebral, **178**  
 vidian, **178**  
 visceral, 160, 182
- Nerve-cells, **140**
- Nerve-ending, motor, **314, 315**
- Nervous arc, **142**  
 organs, 418, **419, 420, 448**  
 central, 140, 141, 142-157, 258, 407  
 system(s), 140-215  
 analogies concerning, 667, 668, 715-718  
 anatomical comparisons of, 667, 668, 720  
 tissue, 316-320
- Nervus erigens, **178**  
 terminalis, 162
- Nest(s), 238, 239, 241
- Nestling down-feathers, 507
- Neural arch, 106, **107, 111, 112, 279, 413, 414**  
 crest(s), **186, 271, 272, 273, 275**  
 groove, **272**  
 plate, **186, 254, 258, 262, 268, 271, 272, 494, 495**  
 tube, 143, 144, 152, 173, **186, 200, 217, 228, 258, 259, 267, 269, 270, 271, 272, 273, 275, 281**  
 central canal of, **272, 273**  
 pigment spot in, **270**
- Neuraxon, 316, 318 (*see also* Axon and Neurite)
- Neurenteric canal, 267, **268, 270, 274, 275**
- Neurilemma, **141, 142, 319**  
 nucleus of, **141**
- Neurite, **141, 193, 316** (*see also* Neuraxon, Axon)
- Neurofibrils (fibrillae), **142, 317, 318**
- Neuroglia, 320
- Neurohumors, 139, 142
- Neuromast, 164-167
- Neuron(s), 140, 153, **171, 182, 202, 316, 317**  
 association, 141, **184**  
 autonomic, 186-187  
 connector, 182  
 correlation, 141  
 exciter (postganglionic), 182, 219  
 intercalary, **142**  
 sympathetic, **174**
- Neuropore, 267, **268, 270**
- Neutrophils, 329
- Newts, 452, 454
- Nictitating membrane, 451, 476, 685
- Nighthawks, 551, 553
- Nightingales, 553
- Nipple, 577, 578, **579**
- Nissl's bodies, 318
- Node(s) of Ranvier, **140, 141, 319**
- Nodose ganglion, 167
- Nodule of lymph gland, **66**
- Nondeciduate placenta, 294
- Nonepithelial tissues, 311
- Non-striated muscles, 96, 154-156, 285, 288, 312, 313
- Nose, 100, 679, 680
- Nostril, 198
- Notochord, **6, 101, 104-106, 107, 137, 143, 144, 228, 259, 260, 261, 262, 267, 268, 269, 270, 271, 272, 273, 274, 275, 277, 281, 296, 298, 322, 323, 393, 442, 448, 468**  
 modifications of, 786
- Notochordal axis, 104-106
- Notoryctes, 733, 774, **775**
- Nucleus(i), **140, 141, 142, 153**  
 egg, **237, 249**  
 of Pander, **236**
- Nutrition, provisions for, 238, 242, 243, 245, 246
- O
- Oblique muscles,  
 abdominal wall, **90, 91, 587, 588**  
 eye, 162, **163, 164**  
 in mammals, 684, **685**
- Obsolete organs, 299
- Occipital arch, 112, 122, 124  
 bone, 122  
 condyles, 561, 564, 596  
 lobe, **177, 706**  
 muscles, **98**  
 vertebrae (*see* Vertebrae)
- Ocellus, 396
- Ochotona saxatilis, 742
- Oculomotor nerves, 100, 162, **163, 178, 179**
- Odobenus, 750
- Odontoblast(s), **37, 38, 39, 40, 42**  
 layer, 38, 40, **42, 47**
- Odontoceci, 765
- Odontognathae, 543
- Odontoid process, 111, 593
- Oestrelata haesitata, **548**
- Oil-birds, 553
- Oil-glands, 206, 511
- Okapi, 757, **759**
- Old age, phylogenetic, 795
- Olfactory bulb, **177**  
 capsule, 116  
 cells, **196, 197, 198**  
 epithelium, **197, 675**  
 fibers, 713  
 glands, **197, 198**  
 lobe, **144, 145, 148, 198, 710**  
 nerves, 143, 162, 198  
 organs, 103, 116, 195-199, 273, 419, 475, 532  
 of mammals, 671-679  
 of man, 675, **676**  
 region, **532**  
 sacs, 144
- Omentum, **279**
- Omnivorous mammals, 569
- Omohyoid muscle, **99**
- Omosternum, 132
- Ontogeny, 297, 298, 349
- Onychodactylus, 452

- Opercular, 126  
 Operculum, 122, 126, 442  
 Ophidia, 486 (*see also* Serpentes)  
 Ophthalmic nerve, **160, 161**, 164  
 Opisthocoealous, 456  
 Opisthocoealus centrum, 106  
 Opisthocomus, 410, 546  
 Opisthonephros, 85  
 Opisthotic, 125  
 Opposable thumb, 804  
 Opossum, **61**, 733, **783**  
   Australian, **735**  
   Virginia, **731**  
 Optic chiasma, 162, **202**  
   cup, 117, 200, **273**  
   lobes, 150, 534, **535**, 536, 537  
   nerve, 150, 162, **163**, 201, **202**, **203, 204**,  
     273, **711**, 713  
   stalk, 117, 149, **163**, 200, **202**, **273**  
   vesicles, **6**, 200  
 Ora serrata, **203**  
 Oral epithelium, **37, 41**, 195, 196  
   membrane, 274  
 Orangutan, 771, **772**  
 Orbicularis oculi muscles, **98**  
   oris muscles, **98**  
 Orbit, 117, 122, 125, 176, 680  
 Orbital cavity, 602  
   glands, 636  
 Orbitosphenoids, 124  
 Orders, 390  
 Organ(s) of Corti, **196**, 210, 477, 534, 690,  
   **691**  
   definition of, 301, 302  
   of Jacobson, 475, 532, 678  
   lateral-line, **164**, 165, 166  
   of Lorenzini, 165  
   obsolete, 299  
   position of, 374-380  
   visceral, 285  
 Organogenesis, 266-299  
   in relation to yolk, 288-291  
 Origin, muscle, 95  
   of species, 345  
 Orioles, 553  
 Ornithodelphia, 729  
 Ornithorhynchus, 236, **726**, 727, 733 (*see*  
   *also* Duckbill)  
 Orthogenesis, 796  
 Oryzeteropus, 745, **746**  
 Os clitoridis, 661  
 Ossa suprasternalia, **132**  
 Ossicles, Weberian, 433, **434**  
 Osteichthyes, 420  
 Osteoblast, **102, 103**, 284, **285**, 325  
 Osteoclasts, 327  
 Osteology, 343  
 Ostium, 87  
   tubae abdominale, **80**, 646  
 Ostracoderm(i), **415**, 416, 442  
 Ostrich(es), 234, 530, 538, 544, 545  
 Otariidae, 747, **749**  
 Otic capsule, 116, 125, **144**, 209, 692  
 ganglion, 176, **178**, 179, 183  
 sac, 144, 207-210, 689  
 Otoconia, 209, 210  
 Otoliths, 209, 210  
 Otter, 747  
 Ovarian arteries, 68  
   follicles, **232**  
 Ovary(ies), 79, 87, 88, 216, 231, 233, 236,  
   237, 242, 282  
   function of, 645  
   of mammals, 643-650  
 Overspecialization, 796  
 Oviduct(s), **80**, 87, 88, 237-239, 241, 283  
 Oviparity, 238, 241, 244, 245  
 Oviparous mammals, 650  
 Ovis, 757  
   aries, **756**  
 Ovum(a), 231, **232**, 233-238, 291  
 Owl(s), 529, **535**, 551, 553  
 Ox, **47**
- P
- Pacini, corpuscles of, 193, 195  
 Paedogenesis, 445  
 Pain, 193, 195  
 Paired appendages, 128-134, 172, 173,  
   **383**, 447, 467, 468  
   fins, 416  
 Palaeoencephalic, 713  
 Palaeoencephalon, 704, 720  
 Palaeognathae, 543, 544  
 Palate, **14, 199**  
   secondary, 561, 564, 602, 611  
   soft, 611  
 Palatine bone, 125, **199**  
   nerve, **160, 161**, 166  
 Palato-pterygo-quadrate, 118, 125, 127, **446**  
 Paleolithic drawing, **806**  
 Paleontology, 342, 789, 790  
 Paleozoic, 789  
 Palingenetic structures, 299  
 Pallium, 145, **148**, 419, 448, 479, **480**, 481,  
   536, 704  
 Palm, 133  
   skin of, **577**  
 Palpebrae, 685 (*see also* Eyelids)  
 Pancreas, **14**, 29-35, **34**, 183, 185, 215,  
   **216**, 530  
   Aselli, 633  
   development of, 31, **32**, 258, 276  
   function, 35  
 Pancreatic cavities, 31  
   duct, **14**  
   islands (islands of Langerhans), 32, **34**,  
   215, **216**  
 Panda, 747, **748**  
 Pander, nucleus of, **236**  
 Pangolin(s), 101, 745, **746**  
 Panniculus carnosus muscles, 100  
 Panther, 747  
 Pantotheria, 773  
 Papilla(e), **39**, 40, **41**, 42, 210, **669**, 670  
   acustica lagenae, 477  
   basilaris, 477  
   dermal, 670  
   filiform, 670  
   foliate, 671

- Papilla(e)—(*Continued*)  
 fungiform, 670  
 vallate, 671, **672**
- Papillary muscles, 622
- Parabronchi, 519
- Paradidymis, **80**
- Parakeets, 551
- Parallelism, 366–370, **367**
- Paranasal sinuses, 677
- Paraphysis, 147
- Parapsid skull, 501, **502**
- Parasphenoid, 125, 127, 137
- Parasympathetic fibers, **178**  
 system (*see* Autonomic system, cranio-sacral)
- Parathyroid, 215, **220**, 222, **223**, 276
- Paraxonic, 751, 754
- Parietal, 22, 93, 96, 97, 269 (*see also* Somatic)  
 arch, 122, 124  
 bone, **107**, 124  
 foramen, 149, 602  
 layer, 283  
 lobe, 706  
 organ, 149, **150**, 227
- Parietes, 20
- Paroöphron, **80**
- Parotid glands, 636
- Parovarium, **80**
- Parrot(s), 56, **233**, 530, 551  
 ground, 555
- Pars intermedia, 224  
 tuberalis, 224, **225**
- Passeriformes, 553
- Patella (knee-cap), **131**, 133
- Patterns, vascular, 626–629
- Peafowls, 546
- Peccary, **754**, 755
- Pecora, 757
- Pecten, 533, 681
- Pectoral appendage, 17, **129**  
 fins, 93, 94, 128, **130**, 133, **135**, 420  
 girdles, 95, **99**, 128, **130**, **131**, 133, 134, 495, 511, 583  
 limbs, 128–134
- Pectoralis muscles, **92**, 95, 100, 518, 519, 583, **588**
- Peking man, 771
- Pelecyaniformes, 545
- Pelecanus erythrorhynchos, **548**
- Pelicans, 545
- Pelvic appendages, 17, 129, 130  
 fins, 93, 128, 133, **135**, 438  
 girdles, 95, 128, **131**, 132, 133, 138, 514  
 limbs, 128–134  
 nerve, **178**, 185
- Pelvis of kidney, **86**
- Penguin(s), 538, 544, **547**, 556
- Penis, 482, **661**  
 of marsupials, 662  
 shaft of, 659
- Pentadactyl appendages, 407
- Peraucles, 294, **732**, 733
- Perch, **431**  
 climbing, 435
- Perennibranchiata, 452
- Peribranchial cavity, 402
- Pericardial cavity, 21, **275**, **286**, 287
- Pericardium, 22, 286
- Perichondral bone, 285
- Perichondrium, 191, 284, 324
- Periderm, 509
- Perilymph, 209, 478, 693
- Perinysium, 316
- Perineum, **654**, 658
- Perineurium, 320
- Periophthalmus, **800**
- Periosteum, **37**, 191, 192, 195, 325
- Periotic, 125
- Peripharyngeal bands, 402  
 groove, 399, 402
- Perissodactyl, 751, **752**
- Perissodactyla, 751–754, 778, 779
- Peristalsis, 174
- Peritoneal cavity, **287**
- Peritoneum, **21**, 22, 23, 82, **91**, 93, 96, 195, 270, 278, **279**, **281**, 282, 287
- Permanent teeth, **39**, 40, **42**, **43**, **49**, 54
- Permian, 566
- Pes (foot), 94, 96, **131**, 132
- Pessulus, 527
- Petrels, 545, 556
- Petromyzon, **18**, **90**, **152**, 222, **225**, **413**, **414**, 415
- Petrosal bone, 692  
 ganglion, **160**, 166  
 nerves, **178**
- Phalanger(s), **735**  
 flying, **775**
- Phalanges, **107**, **131**, 132
- Phallus, 659
- Pharyngeal clefts, 59, 214, 274, 275, 407, 418  
 glands, 219, **220**  
 pouches, **6**, **220**, 222, **223**, 275, 276, 299
- Pharyngobranchial, 118
- Pharyngohyal (hyomandibula), 118, 127
- Pharynx, **14**, 25, **26**, 51, **58**, 59, **60**, 96, 98, 166, 167, 196, 198, **199**, 213, 214, 215, 219, **220**, 274, 276  
 of mammals, 610–612, 638
- Phascolarctos cinereus, **735**
- Phascalomys, **734**, 735, 774
- Pheasants, 546
- Phenacodus, **779**
- Phocidae, 750
- Pholidota, 745, 776
- Phrenic nerves, 213
- Phyllopteryx, **229**, 435
- Phylogenetic old age, 795  
 relationships, 298  
 tree, **391**
- Phylogeny, 297, 298, 349, **789**
- Phylum, 390
- Physeter, 765  
 macrocephalus, **766**
- Physiologic axis, 136
- Physiology, 338
- Physoclisti, 433, 434
- Physostomi, 433, 434

- Pia mater, 191, **192**, 706  
 Piciformes, 553  
 Pig, **33**, **41**, 46, **75**, **76**, **186**, **286**, **752**, 755  
 Pigeon(s), **256**, **521**, 530, **535**, 551  
 Pigeon milk, 243, 528  
 Pigmented epithelium, 201, **203**, **204**, 205, 273  
 Pika, 740, **742**  
 Pillar cells, 690, 698  
 Piltdown man, 771  
 Pineal body, **148**, 227, 710  
   eyes, 207  
   gland, 149, 215  
   organ, 149, **150**, **225**  
 Pimna(ae), 696, 761  
 Pinnipedia, 747-750  
 Pipa americana, 239  
 Pipe-fish, 55, 238  
 Pisces, 409, 410, 416-442 (*see also* Fishes)  
 Pisiform, 133  
 Pithecanthropus erectus, 771  
 Pituitary body, 149  
   gland, 224, **225**, 226, 227  
     anterior lobe of, 224, **225**, 226  
     functions of, 226, 227  
     intermediate lobe of, 224, **225**  
     posterior lobe of, 224, **225**, 226  
 Placenta, 243, 244, 245, **290**, **292**, 293, **294**, 295  
   cotyledonary, 294  
   diffuse, 293  
   discoidal, 294  
   fetal, 295  
   nondeciduate, 294  
   zonary, 294  
 Placental reproduction, 643  
 Placentalia (placental mammals), (*see* Placentals)  
 Placentals, 243, 263-266, 646, 653, **657**, 662, 725, 728, 729, 736-771  
   relationships with marsupials, 773-776  
   villi, **294**  
 Placodermi, 421  
 Placodes, 143, 207  
 Placoid scales, **50**, **51**, **424**  
 Planes, 12  
 Plantar surface, 133  
 Plantigrade condition, 583  
 Plasma, 63, 328  
 Plasmodesm, 305  
 Plate(s), motor, 316  
   neural, **186**, **254**, 258, **262**, **268**, 271, **272**, 494, 495  
   sclerotic, 476, 533  
 Platybasic skull, 517  
 Platyrrhina, 770  
 Platyrrhine monkeys, **769**  
 Platysma muscles, **98**, 100  
 Plesiosaurs, **500**  
 Plethodon, 452  
   cinereus, **449**  
 Plethodontidae, 452  
 Pleura, 22, 620  
 Pleural cavities, 21, 287  
 Pleurocentrum, 111  
 Pleurodont, 47, **48**, 52  
 Pleuroperitoneal cavity, 21, **287**  
 Plexus, **172**, 173, 175  
   of Auerbach, **174**  
   brachial, **172**, **177**  
   cervical, 172  
   cervicothoracic, 172  
   choroid, 147, **148**, 151  
   gangliated, 174  
   lumbar, 172, **177**  
   lumbosacral, 172  
   myenteric, **174**  
   sacral, 172  
 Plica semilunaris, 686  
 Plicae, 28, **30**  
 Plovers, 546  
 Plumes, 507  
 Plumules (down-feathers), 507, **510**  
 Pluteus, **223**  
 Pneumaticity of skeleton, 522, 523  
 Pneumogastric (vagus) nerve, **28**, **160**, 167, **178**  
 Poikilothermous, 410  
 Poison canal, **56**  
   glands, 55, 56, 155  
 Poison-fangs, **55**, **56**  
 Polar body, **247**, **252**  
 Pole, animal, 235, **247**, 248, **249**, **250**, **252**, **254**  
   vegetal, **247**, 248, **249**, **250**, **252**, **254**  
 Pollack, lateral-line organs, **165**  
 Pollex (thumb), **131**, 132, 133  
 Pollock, pelvic fins, 378  
 Polymastism, 580  
 Polymorphonuclear leukocyte, 329  
 Polyphyodont, 54, 55, 635  
 Polyprotodontia, 733  
 Polypterini, **426**, 428, **430**  
 Polypterus, 276, 421, **426**, 429, **430**  
 Polythelism, 580  
 Pons Varolii, **148**, 151, 713  
 Pontine flexure, **144**  
 Porcupine, **740**  
   African, **741**  
 Pores, genital, 237  
 Porpoises, 765  
 Postbranchial bodies, **223**, 224  
 Postcardinal veins, **64**, 71, 73, **74**, 78  
 Postcaval vein, **32**, **64**, 71, 73, **74**, 78  
 Post-Darwinian period, 346-353  
 Posterior, 12, 13  
 Postfrontal, 125  
 Postganglionic fibers, **171**, **178**, 184  
   neurons, 182, 219  
 Postorbital, 125  
 Post-trematic nerve, **160**, **161**, 166, 167, 169  
 Postzygapophys(es), 108, 742  
 Pouch(es), marsupial, 238 (*see also* Marsupium)  
   mesodermal, **259**, 260, 267, **268**, 270  
   pharyngeal, **6**, **220**, 222, **223**, 275, 276, 299  
 Precardinal veins, 73  
 Precaval veins, **64**, **71**, 73, 631

- Precoracoid, **107**, 130, **131**, **132**  
 Prefrontal, 125  
 Preganglionic fibers, **171**, **178**, 184, 219  
   neurons, 182  
 Pregnancy, extrauterine, 646  
 Prehensile tail, 595  
 Premaxilla, 126, 127  
 Premolars, **43**, **45**, 563  
 Preopercular, 126  
 Prepuce, 660  
 Preputial glands, 665  
 Presphenoid, 124  
 Pressure (sense), 193  
   adaptations to, 569  
 Pretrematic nerve, **160**, **161**, 166, 167, 169  
 Prevomers, 125, 137  
 Prezygapophys(es), 108, 742  
 Primates, 294, 571, **709**, 765, 767-771  
   evolution of, 793, 794  
   generalized structure of, 803, 806  
   relationships of, 784, **793**  
   specialization of, 806-809  
 Primitive (renal), duct, **81**, **83**, **275**, **277**  
   groove, **263**, **266**  
   streak, **263**, **265**, **266**, 273  
 Principle (*see also* Theory, Law)  
   of connections, 360, 374, **375**, 378  
 Priodontes, 743  
 Prisms, enamel, 36, **38**, 40  
 Proboscidea, 757, 759-761, 779, 781  
 Proboscis, 394, 679, 761  
   monkey, 771  
 Procavia, 762  
 Procellariiformes, 545, 556  
 Process(es), ciliary, **203**, 683  
   coracoid, 583  
   coronoid, 601  
   iliac, 129  
   odontoid, 111, 593  
   pterygoid, 122  
   scapular, 129  
   spinous, **109**  
   styloid, 122, 607  
   transverse, 108  
   uncinate, 518  
   vermiform, **14**  
   zygomatic, **601**  
 Procoelous centrum, 106  
 Procoracoid (*see* Precoracoid)  
 Proctodeum, 274, **275**, 530  
 Procyon, 747, **748**  
 Procyonidae, 747, **748**  
 Proechidna, 733  
 Progesterone, 216, 217  
 Projection-tracts, 717  
 Pronators, 96  
 Pronephric duct, 87, **279**, 280  
   tubules, **81**, **277**, 280  
 Pronephros, **60**, 79, **80**, **81**, **83**, **84**, 87, 279,  
   473  
 Prongbuck, 757  
 Prootic, 125  
 Proprioceptors, 140, 211-213  
 Propterygium, 129  
 Prosencephalon (*see* Telencephalon)  
 Prostate gland, 185, 663, **664**, 665  
 Prostatic vesicle, 663  
 Protection, provisions for, 238, 239, 246  
 Proterostomians, **391**  
 Proteus, 452  
 Protochordata, 389-411  
 Protonephridia, **80**  
 Protoplasm, 248, 249, 257, 289, 299, 301,  
   320  
 Protoplasmic bridges, 305  
 Protopterus, **19**, 437  
 Protostomians (proterostomians), **391**, 392  
 Prototheria, 729  
 Protozoa, 390  
 Protractors, 96  
 Proventriculus, 528  
 Proximal, 13  
 Psittaciformes, 551  
 Pteranodon, **568**  
 Pterodactyls, 490, 500  
 Pteropus, 739  
 Pterosaur(s), 490, 497, **498**, 500, 553, **568**  
 Pterygoid(s), 126  
   process, 122  
 Pterygiae, 508  
 Pterylosis, 508  
 Ptyalin, 637  
 Puberty, 216  
 Pubis, **107**, 130, **131**, 514  
 Puffins, 546  
 Pulmonary arteries, 68, **64**, 69, **71**  
   epithelium, 59  
   trunk, 625  
   veins, **64**, **69**, **71**  
 Pulp, **37**, **39**, **42**, **56**  
 Pulp-cavity, 35, **37**  
   nerves in, **37**, 38  
 Pupil, 201, 682  
 Putorius erminea, **796**  
   vison, **748**  
 Pygostyle, 516  
 Pyloric stomach, **29**, 638  
 Pylorus, 25  
 Pyramidal cell, **140**, **317**  
   tract, **171**  
 Pyramids, 151  
   of kidney, **86**  
 Python, **489**
- Q**
- Quadrangle, 126, 127, 128, 478, 517, 563, 695  
 Quadratojugal, 126  
 Quadratus labii muscles, **98**  
 Quails, 546  
 Quill (calamus), 505, **506**
- R**
- Rabbit, **198**, **264**, **265**, **266**, **703**, **706**, 740  
 Raccoon, 747  
 Rachis, 505, 509  
 Radialia, 129  
 Radiation, adaptive, 366, **367**, 368-370  
   repetitive, 798-800, **801**, 802  
 Radius, 95, **107**, **131**, 133



- Rails, 546, 555  
flightless, 555
- Ramus(i) communicans (communicantes),  
171, 172, **177**, 179, 183, 184, 185  
dorsal, **171**, 172  
of jaw, 126  
maxillaris, **178**  
post-trematic, **160**, **161**  
pretrematic, **160**, **161**  
ventral, **171**, 172
- Rana, **18**, **114**, **152**, **225**, **480**  
catesbiana, 458  
clamitans, 458  
esculenta, **450**  
pipiens, 458
- Range, sensory, 698
- Ranidae, 458
- Ranodon, 452
- Ranvier, node(s) of, **140**, **141**, 319
- Rat, **640**, 740
- Rathke's pouch, 224
- Ratitae, 542, 543, 544
- Rattlesnake, **55**
- Ray(s), 422  
electric (Torpedo), **439**, **440**, 441
- Ray-fin fishes, 420
- Recapitulation, Law of, 7, 298, 299, 349, 380
- Receptaculum chyli, **66**
- Receptor cells, **196**
- Receptors, 158, 193, 195, **196**, 199, 203,  
210, 214, 273
- Recessus opticus, **148**
- Rectal gland, 29
- Rectrix (rectrices), 511
- Rectum, **14**, 25, **80**, 185, 276, 530, 639
- Rectus muscles, 162, **163**, 588
- Reflex, 141  
arc, 141
- Regulation of temperature, **184**  
in birds, 525  
in mammals, 575
- Reindeer, 757
- Remex (remiges), 511
- Renal arteries, 68, **71**, 78, **86**  
circulation, **630**  
corpuscle, 84, **87**, 280  
lobule, 641  
tubules, **80**, 81, 87, 278, 279, 402  
veins, **71**, **74**, 78, **86**
- Renal-portal system, 77, 78, 630  
veins, 78
- Repetitive radiation, 798-800, **801**, 802
- Replacing bone (*see* Cartilage-bone)
- Reproduction, 231-299, 482  
ichthyopsidan type of, 787  
placental, 643  
sauropsidan type of, 787  
variations in methods of, 787
- Reproductive glands, 79-81, 87, 88  
organs, 13, 79-88, 226, 258, 531  
system, 79-88, 231-281
- Reptile(ia), 14, **22**, 289, 293, 409, 410,  
465-502, 563, **587**  
Age of, 497  
alimentary system of, **26**, 52, 53, 55  
Reptile(ia)—(*Continued*)  
behavior of, 479, 481  
birds compared with, 553  
circulatory system of, 68, 69, **71**, **72**,  
465, 466  
classification of, 483-497  
contour of body, 467  
decline of, 559, 560  
development of, 249-251, 256, 257, 262,  
263, 266, 273, 275  
early, 497  
endocrinal organs of, 220, 222, 225  
evolution of, 792  
heart of, 622, 623, **624**, 625  
as land animals, 559  
lungs of, **619**, 620  
mammal-like, 564, 567  
morphology of, 463-502  
muscles of, 91, **92**, 98, 100, 472, 473  
nervous organs of, **150**, 160, 208, 210,  
474-482  
reproductive system of, 88, 234, 235,  
238, 240-242, 244, 245, 482, 483  
respiration of, 464, 465  
skeleton of, 101, 115, 122, 123, 128, 133,  
467-469, **470**, 471, 472  
teeth of, 52, 53, 55  
transitional, 566  
urinogenital organs of, 79, 88, 473, 474  
viviparous, 295
- Respiration, 213, 214, 240, 243, 246, 274  
buccopharyngeal, 447  
gaseous exchange in, 58, 241, 293, 464,  
465, 616  
organs of, 56-61
- Respiratory area, 618  
organs, and hearing organs, 358  
modifications of, 787  
passages, **199**, **562**, **610**  
surfaces, 296
- Reticular tissue, 321
- Retina, 149, 200, **202**, **203**, **204**, **273**  
inverted, 206, 207  
layers of, 203, **204**, **205**
- Retinal artery, **203**  
veins, **203**
- Retractor(s), 96  
bulbi muscle, 685
- Rhabdopleura, 395
- Rhamphostoma, 470
- Rhea, 544
- Rheiformes, 544
- Rhesus monkey, **588**, **589**, **594**, **661**, **671**
- Rhinobatus lentiginosus, **427**
- Rhinoceros, **753**
- Rhinocerotidae, 754
- Rhomboideus muscles, 95
- Rhynchocephalia, 484, 500
- Rhynchotus rufescens, **547**
- Rhytina, 763
- Rib(s), **107**, 113-115, **132**, 133, 137, 138,  
471, 495, 518, 584, 586, 592  
dorsal, **113**, **279**  
hemal, **279**  
sternal, 584

- Rib(s)—(*Continued*)  
 ventral, **113**, 114  
 vertebral, 584
- Right whale, 765, **766**
- Robins, 533
- Rodent(ia), 46, **47**, 571, 739, 740, 776
- Rods (of retina), 203, **204**, **205**, 206  
 of Corti, 690
- Rollers, 551
- Root (of tooth), 35, **36**  
 canal, **37**  
 dorsal spinal, 169, **170**, **171**, 172, 272  
 ganglion, dorsal, 179  
 of hair, 155  
 ventral spinal, 169, **170**, **171**, 172, 272
- Rorqual whale, 765
- Rotators, 96
- Rubrospinal tract, **170**
- Rufous tinamou, **547**
- Rugae, 28, **29**
- Ruminant(ia), 755, **756**, 757
- Running birds, 542
- S**
- Sac(s), air-, 519, **520**, **521**, **522**, 523-525, 621  
 conjunctival, **203**, 686  
 endolymphatic, 688  
 lung-, **60**, 437  
 olfactory, 144  
 otic, 144, 207-210, 689  
 yolk-, 241, 242, **289**, 293-295
- Sacculo-utricular canal, **211**
- Sacculus, 208, **209**, **211**, 477  
 region of, 689
- Sacral curvature, **4**, **109**  
 nerves, **177**  
 plexus, 172  
 vertebrae, **4**, **109**, 133, 138, 447, 468,  
 515, 596
- Sacrum, 596, **597**, **598**
- Sagittal plane, 12
- Salamander(s), **33**, 56, **60**, **114**, 134, 156,  
**172**, **193**, 234, **236**, 240, 245, 452,  
**453**, 454  
 lungless, 447
- Salientia, 454-458
- Saliva, 637
- Salivary glands, 176, 183, 185, 636, **637**,  
 638
- Salmo fario, **20**
- Salmon, 240, 244
- Saltation evolution, 342
- Sandpipers, 546, **550**
- Santorini, duct of, **32**
- Sarcolemma, 314
- Sarcophilus, 774
- Sarcoplasm, 312
- Sartorius muscles, **92**
- Sauria, 484
- Sauripterus, **120**
- Sauropsida, 256, **237**, 410, 463-558, 629
- Sauropsidan reproduction, 787
- Scala tympani, 693  
 vestibuli, 693, 696
- Scalenus muscles, 592
- Scales, **308**, 373, 382, **464**  
 bony, 19, **20**  
 ctenoid, **20**  
 cycloid, **20**  
 fish, 50, 51, **424**  
 ganoid, **20**, **424**  
 horny, 19, **20**, 573  
 placoid, **50**, **51**, **424**
- Scapula (shoulder-blade), 95, **99**, **107**, 129,  
 130, **131**, **132**, 511, 583
- Scapular process, 129
- Scent-glands, 577, 665  
 anal, 665
- Schwann's sheath, **140**, 319 (*see also*  
 Neurilemma)
- Science, 5, 384
- Sciurus, 740
- Sclera (sclerotic layer), 117, 201, **202**, **203**,  
 533, 681
- Sclerotic plates, **476**, 533
- Sclerotome, **110**, **275**, 278, 283
- Serotal fold, 659
- Serotum, **68**, **633**, 651, **652**, 653, 655, 660
- Scup, 55
- Sea cows, 367, 368, 763  
 horse(s), 55, 238, **239**, 245, 435  
 lion(s), 367, 368, 747, **749**  
 squirts, 394, 396  
 urchin, **228**
- Seal(s), 367, 368  
 eared, 747  
 earless, 750  
 fur, 747  
 harbor, 750
- Sebaceous glands, 574
- Secodont, 53
- Secretin, 215
- Secretion(s), 155, 156, 174, 215-219, 221,  
 222, 226, 227
- Secretory cells, 179, 185  
 glands, 310
- Segmentation, 260, 262, 271, 277, 278
- Selection, natural, 345, 366
- Selenodont(ia), 755-757
- Semicircular canals, 208, **209**, **211**, 688  
 functioning of, 698, 699
- Semilunar (Gasserian) ganglion, **160**, **161**,  
 164, **178**  
 membrane, 527  
 valves, **65**, 621
- Seminembranosus muscles, **92**
- Seminal groove, 659  
 vesicles, 663
- Seminiferous tubules, 283
- Semitendinosus muscles, **92**
- Sense bud, **194**  
 (sensory) cells, 140, 142, 192, 193, 195,  
**196**, **197**, 198, 199, 209, **210**, 214,  
**309**, 690
- Sense-organs, 119-213, 419, 420, 451, 474-  
 478, 532-534, 581, 668-701
- Senses, chemical information from, 673
- Sensory, 141  
 bristle, **196**, **197**

- Sensory—(Continued)  
 center, primary, 535, 716  
 epithelium, 308  
 fibers, 140, 160, **171**, 184  
 nerves, 159, 160  
 range of ear, 698  
 tracts, 153, **170**
- Seps, 244
- Septum, dorsal spinal cord, **152**  
 interorbital, 517  
 mediastinal, 21, 22  
 transversum, 21
- Serosa, 241
- Serous glands, 199, 636
- Serpentes (Ophidia), 486, 488, 489, 490, 500
- Serratus magnus (muscle), **92**
- Serum, 329
- Sesamoid bones, 133
- Sex(es), 231, 233  
 differentiation of, 88
- Sex-glands, relation to pituitary, 226  
 female, 216, 217  
 male, 216
- Sexual development, 226
- Seymouria, **565**
- Shaft (rachis), 505, 509
- Shank, 94, 131
- Shark-like fishes (see Fishes, shark-like)
- Sharks, 11, **26**, 46, **49**, 51, 53, **58**, **64**, 87, **99**, **115**, **120**, 128, **129**, 165, 234, 235, 238, 239, 244, 380, 422
- Sheath, of muscle-spindle, **212**  
 myelin (medullary), **140**, **141**, **142**, 183, 319  
 non-medullated nerve-fiber, 183  
 Schwann's, **140**, 319 (see also Neurilemma)
- Sheep, **756**, 757
- Sheepshead, 55
- Shell, 233-235, **236**, 238, 240, 241, 245, 293; of Chelonia, 494, 495  
 membrane, 235, 236
- Shoulder, **131**  
 girdle (see Pectoral girdle)
- Shoulder-blade (see Scapula)
- Shrew, **736**  
 tree, 736, **783**
- Siluridae, 433
- Simiidae, 771
- Similarities, anatomic, 2
- Simplicidentata, 742
- Sinanthropus, 771
- Sinus venosus, 63, **64**, **65**, 73
- Sinus(es), 605  
 of Cuvier, 73, **74**  
 frontal, **199**, 605, 677  
 lacrimal, 686  
 lymph, **66**  
 maxillary, 605, 677  
 paranasal, 677  
 sphenoid(al), 605, 677  
 urinogenital, 650  
 venous, 63, **64**, **73**, 622
- Siphonops, **458**
- Siren, 452
- Sirenia(n), 571, 762, 763, 781
- Size and survival, 797
- Skate(s), **30**, **119**, 133, 234, 238, 239, 244, **417**, 422
- Skeletal tissues, 322-327
- Skeleton, 101-138, **107**, **383**, **431**, **446**, **470**, **512**, **584**, **585**  
 adaptations in, **782**  
 of amphibians, **446-449**  
 appendicular, 128-135, 136, 138  
 axial, 136-138, 271  
 of birds, 115, 122, 128, 133, 511, **512**, 513-518  
 degree of ossification of, 786  
 of fishes, 101, 113-115, 122, 125, 126, 133, **136**, **414**, **423**, **431**  
 jaws, of Placodermi, 421  
 lateral parietal, 137, 138  
 of mammals, 106, 115, 117, 122, 125, 126, 128, 561, 581-607  
 of man, **103**, 106, **109**, **114**, 122, 130, 131, 132  
 of the notochordal axis, **137**, 138  
 pneumaticity of, 522, 523  
 of reptiles, 14, **22**, 289, 293, 409, 410, 467-472, 563  
 of the sternal axis, **137**, 138  
 visceral, 118, 125, 126, 136, 138, 418, **606**
- Skin (integument), 17-20, **142**, 154, 164, 165, 166, **171**, 172, 193, **194**, 195, 198, 214, 258, 270, **306**, 416, 445, 447, 448, 463  
 blood-vessels in, 18  
 glands in, 20  
 of invertebrates, 17, 18  
 of mammals, 573-581  
 modifications of, 785, 786  
 of palm, **577**  
 of vertebrates, **18**
- Skull, **112**, **115**, **116**, **117**, 118, **119**, 120, **121**, 122, **123**, 124-128, 138, **432**, **449**, 468, **469**, **490**, 500, 501, **516**, 517, 563, **601**, **604**, **740**, **760**  
 anapsid, 501, **502**  
 arches of, 377  
 bony, 120-126  
 diapsid, 501, **502**  
 of mammals, 600-607  
 parapsid, 501, **502**  
 platybasid, 517  
 position of parts, **376**, **377**, 378, 379  
 shape of, 603, 604  
 synapsid, 501, **502**, 600  
 Taungs, 771  
 tropibasid, 517, 600
- Skunk, 747
- Sloth, 44  
 ground, **778**  
 three-toed, 743  
 tree, 743  
 two-toed, 743, **744**
- Smell, 195, 679  
 keenness of, 673, 675  
 organs of, 116, 195-199, 273

- Smooth muscle, 179, 218, 285, 312 (*see also* Non-striated muscle)
- Snake(s), **55**, 56, 115, 124, 128, **229**, 238, 478, 484, 486, 488, **489**, 490
- Snipe, 546
- Snout, 679, 680
- Soft palate, 611
- Sole, **574**
- Sole-horn, **576**
- Solitaire, 551
- Somatic, 22, 154-157, 175, 182, 213-215, **275**, 609, 610  
     differences, 609, 610  
     layers, 269, 270, 278, **279**, 281  
     muscles, 154, 155, 156, 157  
     nerve-fibers, 171, 182  
     nerves, 160
- Somatopleure, 270, 277, **279**, 289, **290**, **292**, 294
- Somites, 89, **261**, **268**, 270, 277, 278, **279**, 288  
     mesodermal, **261**, **270**, 283 (*see also* Myotomes)
- Sorex vulgaris, **736**
- Sound, production of, 614, 615, 700
- Space(s), intercellular, 63  
     temporal, 602
- Spalacotherium, **45**
- Sparrow(s), 553  
     English, 528
- Specialization, 297  
     of birds, 503-505  
     degree of, 794  
     lines of, 794-797  
     among multiple organs, 797, 798  
     over-, 795  
     of primates, 806-809
- Species, 390  
     origin of, 345
- Specificity, histological, 330
- Sperm, 79, 231, 238  
     whale, 765, **766**
- Spermatic arteries, 68, 652  
     cord, 652  
     duct (*see* Vas deferens)  
     vein, 652
- Spermatids, **232**
- Spermatocytes, **232**
- Spermatogonia, **232**
- Spermatophore, 238
- Spermatozoon(oa), 231, **232**, 233, 236-238
- Sphenisciformes, 544
- Sphenodon, **61**, **92**, **116**, **465**, **470**, **473**, 484, **485**  
     punctatum, 484
- Sphenoid bone, 122, **199**
- Sphenoid(al) sinuses, 605, 677
- Sphenopalatine ganglion, **178**, 179, 183
- Sphincter(s), 25, 26  
     coli, **92**, 100  
     pyloric, **29**
- Spinal accessory nerve, 168, 183  
     cord, **6**, 106, **107**, **142**, **143**, **144**, 145, 151, 152-154, **152**, **153**, 158, **171**, 173, **177**, **178**, 179, 191, **277**, 279
- Spinal ganglions, 169, **170**, 171, **177**, 271  
     nerves, 169-173, **170**, **177**, **180**, 184, 272
- Spine(s), integumentary, 369, **370**  
     hemal, 106  
     neural, **107**  
     of tooth, 47, 51
- Spinocerebellar tract, **170**
- Spino-occipital nerves, 168
- Spinous process, **109**
- Spiny anteater, 236, 238, 242, 276, 384
- Spiracle(s), 118, **160**, **161**, 275
- Spiral ganglion, 166  
     valves, **28**, **30**, 641
- Splanchnic, 22, 269 (*see also* Visceral)  
     layer, 269, 270, 278, 281  
     nerves, **177**, **178**, 179, 185
- Splanchnocoel, **277**
- Splanchnopleure, 270, 277, **279**, 289, **290**, **292**, 294
- Spleen, **14**, 65, 183, 185
- Splenic, 126
- Splint bones, 752
- Squalus, **6**, **18**, **48**, **58**, **64**, **93**, **108**, **114**, **143**, **146**, **152**, **163**, **233**, **423**  
     acanthias, 376
- Squamata, 484, 490
- Squamosal, 125, 126, 128, 563, 602, 692
- Squamous epithelium, **304**, **305**
- Squirrel, 740  
     flying, **775**
- Stalk, optic, 117, 149, **163**, 200, **202**, **273**  
     umbilical, 293  
     yolk, **6**, **290**
- Stapedial artery, 694
- Stapedius muscles, 98, 696
- Stapes, 122, 477, 563, 693, 695
- Starch, digestion of, 637
- Stargazer, 440
- Starlings, 553
- Static organ, 396
- Stegocephalia, 448, 460, 468
- Stegosaurus, **499**
- Stegoselachii, 421
- Stellate cells, **204**  
     ganglions, 176, **178**, 185
- Steno rostratus, **766**
- Steno's duct, 636
- Sternal axis, **137**, 138
- Sternebrae, 586
- Sternohyoid muscle, **99**, 593, 605
- Sternomastoid muscles, **92**, 168, 593
- Sternothyroid muscles, 593
- Sternum, **99**, **107**, 113, **114**, 115, **132**, 134, **471**, 518, 586
- Stigmas, 396, 399
- Stoat, **796**
- Stomach, **6**, **14**, 25, **26**, **29**, **107**, 167, 183, 188, 185, **529**, **756**  
     cardiac, **29**, 638  
     curvatures of, **29**  
     folds of, **29**  
     fundus of, **29**  
     of mammals, 638, 639  
     pyloric, **29**, 628

- Stomodeum, **6**, 274, **275**  
 Storks, 545  
 Stratified epithelium, **305**  
 Stratum corneum, **18**, **19**, **20**, 56, **307**, 463  
   germinativum, 39  
 Streak, primitive, **263**, **265**, **266**, 273  
 Striated muscles, 96, 100, 154, 156, 157,  
   182, 212, 213, 278, 287, 288, 312,  
   **313**  
 Strigiformes, 553  
 Stringops, 555  
 Structural axis, 136  
 Struthio, 544  
   camelus, **445**  
 Struthiomimus, **467**  
 Struthioniformes, 544  
 Sturgeon, 55, 120, **121**  
 Stylohyoid ligament, **99**, 122, 607  
 Styloid process, 122, 607  
 Subcardinal veins, 73, **74**  
 Subclavian arteries, 68, **70-72**, 625, 626  
   vein, **64**, **66**, **71**, 73  
 Subclavius muscle, 519  
 Subcutaneous connective tissue, **18**, 100  
   muscles, 100, 581  
 Subdural spaces, **192**  
 Subgerminal cavity, 250, **251**  
 Subintestinal vein, **269**  
 Sublingual ganglion, 176, **178**, 179, 183  
   glands, 636, 637, **638**  
 Submaxillary ganglion, 176, 179, 183  
   glands, 636, **637**  
 Submucosa, 27, **28**  
 Subopercular, 122, 126  
 Suborder, 390  
 Subphylum, 390  
 Subungulata, 781  
 Suidae, 755  
 Suina, 754, 755  
 Suleus(i), 704  
 Supernumerary teats, **580**  
 Supersonic vibrations, 698  
 Supinators, 96  
 Supra-angular, 126  
 Supracardinal veins, **71**, 73  
 Supraoccipital, **107**, 112, 124  
 Supraorbitals, 125  
 Suprapericardial bodies, **223**, 224  
 Suprarenals (*see* Adrenals)  
 Suprascapula, **132**  
 Suprasegmental structures, 720  
 Surangular, 126  
 Surface, importance of, 302  
   digestive, increase of, 26-29  
   pulmonary, increase of, 59  
 Survival of fittest, 817  
   of man, 815  
 Sus, 755  
 Suspensor of jaws, 127  
 Suspensory fibers of lens, **202**  
 Suspensory ligament, of lens, 202, **203**,  
   **683**  
   of liver, 22  
 Swallowing, 213, 615  
 Swallows, 553  
 Swans, 546  
 Sweat glands, 155, 184, 574  
 Swifts, 551, 553  
 Swim-bladders (air-bladders), 276, 425,  
   427, **428**, 433  
 Swimming, adaptation for, **369**  
 Swine, **622**  
 Swordfish, 55  
 Sylvius, aqueduct of, 151  
   fissure of, 706  
 Symmetry, 12-16  
   bilateral, 12  
   departures from bilateral, 13-16  
   functional modification of, 14  
   of median organs, 13  
   of paired organs, 13  
 Sympathetic ganglions, **143**, **171**, **177**, 272  
   nerve fibers, **178**  
   neurons, **174**  
   system, 159, 175, 218 (*see also* Auto-  
     nomic system, thoracolumbar)  
 Sympathin, 190, 191, 218  
 Symphysis, 130, 514  
 Symplectic, 127  
 Synapse, 142, 182  
 Synapsid skull, 501, **502**, 600  
 Synsacrum, 515  
 Synotus, 738  
 Syrinx, 525, **526**, 527
- T**
- Tachyglossus, 733  
 Tactile cells, 193, **194**  
 Tadpoles, **57**, 105, 134, 239, 442, **444**  
 Tail(s), 16, **17**, 133, **135**, 173, 175, 287, 288,  
   442  
   bird's, 515  
   fish, 134-**136**, **423**  
   of mammals, 594, 595  
   prehensile, 595  
 Tail-fin, in amphibians, 448  
 Talpa, 736  
 Tamandua, 743  
   tetradactyla, **744**  
 Tapetum celluloseum, 682  
   fibrosum, 682  
   lucidum, 681  
 Tapir, 752, **753**  
 Tapiridae, 752  
 Tapirus, **753**  
 Tarsal(s), **107**, 133  
   glands, **203**, 685  
 Tarsiodea, 770  
 Tarsius, **768**, 770  
 Tarso-metatarsus, 512, **513**  
 Tarsus, **131**, 132, 685  
 Taste, 195, 214, 419, 679  
   bud(s), **196**, **197**, 198, 214, **309**, 670, **672**  
   organs of, 195-198, 670, 671  
 Taungs skull, 771  
 Tautog, 55  
 Tear(s), 687  
   glands (lacrimal glands), 183, 185, 206,  
   577, 686

- Teat(s), 577  
 supernumerary, **580**
- Tectospinal tract, **170**
- Tectum, **148**
- Teeth, 35-56, 137, 222, **756**  
 adaptations of, 53  
 of amphibians, 52, 53, 55  
 ankylosed, 46, 47  
 cheek-, 46  
 comparative morphology of, 44-56  
 crown of, **35, 36**  
 dead, 38  
 decay of, 36, 38  
 deciduous (milk), **39, 40, 42, 43, 49, 54**  
 determination of shape, 44  
 development of, 39-44, **49**  
 diagram of structure, **37**  
 differentiation of, 52, 53  
 distribution of, 52  
 eruption of, 42, 44  
 of fishes, 50-53, 55  
 horny, 56  
 of mammals, 634-636  
 of man, **36, 38, 39, 40, 42, 43, 45**  
 milk (deciduous), **39, 40, 42, 43, 49, 54**  
 neck of, **35, 36**  
 number of, 52, 635  
 permanent, **39, 40, 42, 43, 49, 54**  
 replacement of, 50, 53-55, 635  
 of reptiles, 52, 53, 55  
 root of, **35, 36**  
 sensitivity of, 38  
 size of, 52  
 sockets of (alveoli), **35, 37, 39, 42**  
 structure of, 35-39
- Tegmentum, **148**
- Tela chorioidea, **146, 147, 151**
- Telencephalon, **6, 144, 145, 147, 148, 198,**  
 479, 703, 704
- Teleost(ei), 29, **57, 72, 90, 233, 426, 432-**  
 434, **435, 436** (*see also* Fishes,  
 bony)
- Teleostomi, 421
- Telodendron, **140**
- Temperature and body size, 560  
 regulation, **184**
- Temporal arcade, 600  
 bone, 122, 692  
 lobe, **177, 706**  
 space, 602
- Temporalis muscles, **92, 601**
- Tendon(s), 95, 195, 212, 321
- Tendon-spindles, 212
- Tensor tympani muscles, 98, 696  
 vaginae femoris muscles, **92**
- Tentorium cerebelli, 192
- Terminal ganglions, 179, 182, 183, 185
- Terns, 546, 556
- Terrapin, **496**
- Terrestrial vertebrates, oral glands of, 636
- Tertiary, 793
- Testis(es), 79, **80, 88, 231, 232, 233, 237,**  
 282, 650-656  
 descent of, **653**  
 position of, 651
- Tetany, 222
- Tetrapod(a), 94, 95, 120, 129, 130, **131,**  
 133, 410
- Thalamus(i), 145, **146, 202, 536, 710**
- Thalassochelys, 493
- Thecodont, 47, **48, 52**
- Theory (*see also* Law, Principle)  
 of archetypes, 340  
 concrescence (teeth), 53  
 differentiation (teeth), 53  
 of evolution (*see* Evolution)  
 Gastraea, 297, 392  
 genetic continuity, 340  
 Goethe-Oken, **112, 344, 377**  
 mutation, 352, 365  
 of natural selection, 345, 366  
 transcendentalism, 340  
 unity of plan, 340, 343
- Therapsida, 501, 564, 629
- Theria, 729
- Thermo-regulators, 155
- Theromorpha, 501, 564, 566
- Theropsida, 629
- Thigh, 94 (*see also* Femur)
- Thinking, 479, 481 (*see also* Intelligence)
- Thoracic, 584  
 arch, **586**  
 cavity, 22  
 curvature, **4, 109**  
 duct, **66**  
 ganglions, 185  
 museles, **591, 594**  
 nerves, **177**  
 vertebrae, **4, 109, 596**
- Thoracolumbar system, 187-190 (*see also*  
 Autonomic system)
- Throat, 99
- Thrush(es), 526, 553
- Thumb, opposable, 804
- Thylacinus, **732, 733**
- Thymus, 215, **220, 222, 223, 276**
- Thyroarytenoid muscle, 614
- Thyrohyoid muscle, **99**
- Thyroid cartilage, **61, 612**  
 gland, 215, **220, 221, 222, 445**
- Thyroxin, 221, 222
- Tibia, **107, 131, 512**
- Tibio-tarsus, 512
- Tiger, 747, **749**
- Tinamiformes, 544
- Tinamou, 542, 544, 554
- Tinamus, 544
- Tissue(s), 301, 302  
 adipose, **327, 328**  
 areolar, 321  
 connective, 191, 193, 221, 224, 278, 284,  
**285, 320-322**  
 fibrous, 117  
 subcutaneous, **18, 100, 581**  
 epithelial, 303-310  
 epithelioid, 303  
 follicular, 645  
 lymphoid, 633  
 for mechanical support, 320-327  
 muscular, 311-316

- Tissue(s)—(*Continued*)  
 nephrogenic, **86**  
 nervous, 316-320  
 nonepithelial, 311  
 reticular, 321  
 skeletal, 322-327
- Toad(s), 56, **57**, **229**, 239, 240, 454-456, **457**, 458  
 metamorphosis of, 457  
 tree, 458
- Toe, great (hallux), **131**, 132, 514
- Tomes, fiber of, **38**, **39**
- Tongue, **14**, **99**, 166, 198, 468, **671**
- Toothed whales, 765, **766**
- Tornaria, **396**
- Torpedo (electric ray), **439**, **440**, 441
- Tortoises, 56, 493, **496**, 497  
 giant, 497
- Totanus, **550**
- Toucans, 551, 553
- Touch, 193
- Trabecula, **66**
- Trachea (windpipe), 59, **60**, 167, 198, 276, 519, 610, **613**
- Tracts, association-, 717  
 corticospinal, **170**  
 feather, **508**  
 fiber, **153**, **708**  
 motor, 154  
 projection-, 717  
 pyramidal, **171**  
 rubrospinal, **170**  
 sensory, 153  
 spinocerebellar, **170**  
 tectospinal, **170**  
 vestibulospinal, **170**
- Tragulina, 757
- Tragulus, **753**, 757
- Transcendentalism, 340, 348
- Transverse muscles, 588, 652  
 planes, 12  
 process, 108
- Transversospinales, 591, 592
- Trapezius muscles, **92**, 95, 99, 168, 583
- Tree frogs, 458  
 shrew, 736, **783**  
 sloths, 743  
 toads, 458
- Triangular muscles, **98**
- Triassic, 564, 566, 567, 789
- Triceps muscles, **92**, **94**
- Triceratops, **499**
- Trichechus, 763
- Triconodont, **45**
- Tricuspid valve, 622
- Trigeminal nerves, 42, **161**, 164
- Trionyx, **469**
- Tritubercular, **45**
- Trituberculata, 773
- Triturus, 452
- Trochlea, 685
- Trochlear chiasma, 164  
 nerves, 100, **163**, 164
- Trogoniformes, 553
- Trogons, 551, 553
- Trophoblast, **264**, **265**
- Tropibasic skull, 517, 600
- Trout, **419**
- Truncus arteriosus, **65**
- Trunk, 16, **17**  
 aortic, 625, 629  
 cochlear, of eighth cranial nerve, 715  
 double-tubular structure of, 23, 154, 155  
 of elephant, 679, 761  
 of mammals, muscles and skeleton, 583-591  
 muscles, **90**, **473**, **587**  
 pulmonary, 625  
 vestibular, of eighth cranial nerve, 715
- Tube(s), alimentary (*see* Alimentary tube)  
 of body (double-tubular structure) 23, 154, 155, 156, 158  
 cochlear, 689, **691**, 693  
 digestive (*see* Digestive tube)  
 Eustachian, **199**, 477, 693  
 neural (*see* Neural tube)  
 uterine, 646
- Tubercles, 53
- Tubular glands, 310, **311**  
 lungs, 620
- Tubule(s), collecting, **80**, 82, **86**  
 convoluted, **86**  
 excretory, 79, 82, **86**, **87**  
 hepatic, 31  
 longitudinal, of testis, **80**  
 mesonephric, 81, **82**, 85, 280, 283  
 metanephric, 85  
 pronephric, 81, **277**, 280  
 renal, **80**, 81, 87, 278, 279  
 seminiferous, 283
- Tubulidentata, 745-747, 778
- Tunica vaginalis, 651
- Tunicates, 231, 396
- Tunicin, 397
- Tupaia, 736
- Turbinals, 673-676
- Turdus, 526
- Turkey(s), **529**, 546
- Turtles, 55, **60**, 101, **132**, 240, **251**, **469**, **493**, **494**, **495**, **496**, 497, 563, **619**, **657**  
 sea, **493**, 496
- Tusks, 13, 44, 46, (of walrus), **750**
- Tylopoda, 755, 757
- Tympanic bone(s), 692, 696  
 cavity, 477, 693-696  
 membrane, 477, 534, 693
- Tympaniform membranes, 526
- Tyrannosaurus, **499**

## U

- Udder, 578
- Ulna, **107**, **131**
- Ultimobranchial bodies, **223**, 224
- Umbilical cord, 294, 295  
 stalk, 293
- Umbilicus, 293
- Uncinate process, 518
- Ungulates, 293, 294, 571, 605, 750-761  
 778

- Ungulates—(*Continued*)  
 even-toed, 751, 754–757  
 odd-toed, 751–754
- Unguligrade, 583, 751
- Unipolar cell, **140**, 316, **317**, **318**
- Unity of plan, 340, 343
- Upper arm (brachium), 94, 131
- Upupa epops, **552**
- Urea, 34
- Ureter, **80**, 81, 82, **85**, **86**, 280, 531, 658
- Urethra, **80**, 81, 82, **85**, **86**, 186, 280, 531, 658
- Urethral canal, 660  
 groove, 659
- Urinary bladder, **80**, 185, 186, 276, 285, 293, 295, 474, 643, **654**  
 duct, 87
- Urinogenital ducts, 79–83, 87, 88, 154, 276, 283, 285, 474  
 groove, 659  
 sinus, 650, **654**  
 system, female, **655**  
 male, **652**, **657**
- Urochorda, 231, 394, 396, **397**, **398**, **399**, **400**, 401, **404**
- Urodele(a), **70**, **77**, **90**, **97**, 238–240, 452–454, 461
- Urodeum, 530
- Uropygial gland, 511
- Uropygium, 511
- Urostyle, 455
- Ursidae, 747
- Ursus, 747
- Uterine tube, 646  
 wall(s), 293–295
- Uterus, **80**, 185, 186, 227  
 bicornis, 647, **648**  
 bipartitus, 647, **648**  
 duplex, 647, **648**  
 masculinus, 663  
 simplex, **648**
- Utriculus, 208, **209**, **211**, 663, 688, 689
- V
- Vagina, 647, 648  
 masculina, 664
- Vaginal cecum, 648
- Vagus (pneumogastric) nerve, **28**, **160**, 167, **178**
- Vallate papillae, 671, **672**
- Valve(s), atrio-ventricular, **65**, 622  
 bicuspid, 622  
 breathing in fishes, **417**  
 ileocolic, 639, 640  
 mitral, 622  
 semi-lunar, **65**, 621  
 sino-atrial, **65**  
 spiral, in intestine, 28, **30**, 641  
 tricuspid, 622  
 in veins, **65**, **67**
- Vampire, 739
- Vane, 506
- Vas aberrans, **80**
- Vas deferens (ductus deferens) (sperm duct), 79, **80**, 283, 474, 650, 652
- Vasa efferentia, **80**, 650
- Vascular patterns, 626–629
- Vasodentine, 46
- Vegetal hemisphere, 249, 250, **252**, **253**, 255, 257  
 pole, **247**, 248, **249**, **250**, **252**, **254**
- Vein(s), 63, 69–78  
 abdominal, **74**  
 allantoic, 293  
 arcuate, **86**  
 azygos, **66**, **71**, **73**  
 cardinal, anterior, 73  
     common, **65**  
     post-, **64**, 71, 73, **74**, 75  
     pre-, 73  
     sub-, 73, **74**  
     supra-, **71**, 73  
 caudal, **64**, **74**, 77  
 coronary, **71**  
 development of, **74**, **75**  
 hemiazygos, **71**  
 hepatic, **32**, **64**, **71**, 73, 74  
 hepatic-portal, **71**  
 iliac, **64**, **71**, **74**  
 jugular, **66**, **71**, 73, **74**  
 lateral, 73  
 of mammals, 630, **631**, 632  
 mesenteric, **64**  
 postcardinal, **64**, 71, 73, **74**, 78  
 postcava, **32**, **64**, **71**, 73, **74**, 78  
 precardinal, 73  
 precava, **64**, **71**, 73, 631  
 pulmonary, **64**, **69**, **71**  
 renal, **71**, **74**, 78, **86**  
 renal-portal, 78  
 spermatie, 652  
 structure of, 65, 67  
 subcardinal, 73, **74**  
 subclavian, **64**, **66**, **71**, **73**  
 subintestinal, **269**  
 supracardinal, **71**, 73  
 valves of, 65, **67**  
 vorticose, **203**
- Vena cava, anterior (precava), 73  
 posterior (postcava), 73
- Venous sinus, 63, **64**, 73, 622
- Ventilation of lungs, 524, 620
- Ventral, 13 (*see under noun entries*)
- Ventricle(s) of brain, 145, 146  
 fourth, **147**, **148**, 151  
 of heart, **64**, **65**, 67–69, 71, 625, 626  
 lateral, 150  
 third, **148**, 149
- Ventricular folds (“false vocal cords”), 614
- Vermiform appendix, 641  
 process, **14**
- Vermis, 151
- Vertebra(e), 106, 144, 191  
 archetype, **348**  
 caudal, 106, 455, 597  
 cervical, **4**, **109**, 514, **515**, 596, **764**  
 coccygeal, **4**, **109**



## Vertebra(e)—(Continued)

- intersegmental, 111
- lumbar, **4**, **109**, 596
- occipital, 124
- sacral, **4**, **109**, 133, 138, 447, 468, 515, 596
- spinous processes of, **4**, **109**
- thoracic, **4**, **109**, 596

## Vertebral artery, 592

- axis, 133, 134, 138
- canal, 106, 173
- column, 3, **4**, 91, 95, 106–111, **109**, 112, 113, 115, 133, 134, 138, 144, 169, 173, 175, **281**, **455**, 468, **470**, 514, 515

of mammals, 596–600

- processes, 108, **109**
- rib, **586**

## Vertebral foramen, 592

Vertebrate(a), 393, 394, **404**, 405, 407–410

- aquatic, **369**, 408, 636
- classification of, 409
- conclusions from study of, 785–819
- definition of, 11, 12
- differences among, 407–409
- embryonic development of, 790
- evolution of, 243, 771–784, 791–811
- general features of, 11–23
- invertebrates contrasted with, 17, 82, 101, 142, 195, 198
- lower and higher, 503
- organogenesis in, 271–281
- pattern of, 227, **228**, **229**, 230
- phylogeny of, **789**
- reasons for studying, 1–7
- sections of, **17**, **21**
- specialization of, 503–505
- terrestrial, 636

Vesalius, **337**Vesicle(s) blastodermic, **264**, **265**

- brain, **144**, 207
- optic, **6**, 200
- seminal, 663

## Vesicular glands, 663–665

## Vessels (see also Arteries, Veins, Capillaries, Blood-vessels)

- lymphatic, 30, 63, 65, 67, **68**

## Vestibular ganglions, 166

- glands, 664
- trunk, 166, 715

Vestibule, **199**, 658, 661Vestibulospinal tract, **170**

## Vestiges, 380

## Vexillum, 506

## Vibrissae, 669

Vidian nerve, **178**Villi of intestine, 28, **30**

- chorionic, 242, **292**, 293, 294
- placental, **294**

Viscera, **494**

- visceral, 22, 89, 96, 97, 98, 99, 154–157, 174, 175, 182, 183, 213–215, 218, 274, **275**, 285, 609, 610
- arches, 96, **107**, 115, 118, **119**, 122, 136, 138, 605, 607, 623, **695**
- axis, 136, **137**, 138

## Visceral—(Continued)

- differences, 609, 610
- layer, 269, 270, 278, 281, 283
- muscles, 89, 96, 97, 154, 156
- nerve fibers, 171
- nerves, 160, 182
- skeleton, 118, 125, 126, 138, 418, **606**

## Vision, binocular, 605

- color, 682

## Visual aids, 701

- cells, **196**

Vitelline membrane, 233, 234, 235, **236**, **249**, **256**

- vessels, 241, 295

Vitreous body, **202**

- humor, 203

## Viverra, 747

## Viverridae, 747

## Viviparity, 238, 239, 241, 242, 244, 245

## Viviparous reptiles, 295

## Vocal cords, 614

- folds, 614
- organs, 525–527

## Voluntary muscles, 156, 157, 213, 214, 215

## Vomer(s), 122, 125, 127, 137

## Vomeronasal organ, 475, 678

Vorticose vein, **203**

## Vultures, 546

## W

Wallaby (ies), **734**, 735Walrus, 230, **750**

## Warblers, 553

## Warm-blooded animals, 410

## Warmth, 193

## Water, in relation to pituitary, 226

## Wax glands, 577, 693

## Weasel, 747

Weberian ossicles, 433, **434**Whale(s), 56, 124, 133, 134, 234, 244, 294, 367, 368, 615, **764**

- balen, **767**

- beaked, **764**, 765

- bottlenose, 765

- bowhead, 765

- finback, 765

- flipper, homologies of, 373

- humpback, 765

- right, 765, **766**

- rorqual, 765

- sperm, 765, **766**

- toothed, 765, **766**

## Whalebone, 765

## Wharton's duct, 636

## Whippoorwills, 551, 553

White matter, of nervous organs, **152**, 153, 184

## Windpipe (see Trachea)

Wirsung's duct, **32**

## Wishbone, 511

## Wolf, 747

- Tasmanian, **732**, 733

Wolffian duct (mesonephric duct), **80**, 81, 82, **83**, 87, 88, 280, 283, 650–656

Wombat, **734**, 735  
 Woodchuck, 740  
 Woodpeckers, 530, 551, 553  
 Wrens, 553  
 Wrist (carpus), **131**

## X

Xenarthra, 742-745, 776

## Y

Yolk, 233-235, **236**, **237**, 240-243, 245,  
 248, **249**, **251**, **254**, **256**, 257, **263**,  
 266, 288, **290**  
   plug, **254**, 255  
 Yolk-cells, 253, 255, 256

Yolk-mass, 249, 256, 257  
 Yolk-sac, 241, 242, **289**, 293-295  
   cavity of, **292**  
 Yolk-stalk, **6**, **290**

## Z

Zaglossus, 733  
 Zebra, 752  
 Zinn, zonule of, **203**, 683  
 Zona fasciculata, **219**  
   pellucida, 236, **237**  
 Zonary placenta, 294  
 Zonula ciliaris (zonule of Zinn), **203**, 683  
 Zygopophysis, 108  
 Zygomatic arch, 128, 601  
   muscles, **98**









