

UC-NRLF



B 4 100 362

# QUIZ-COMPENDS

## ANATOMY

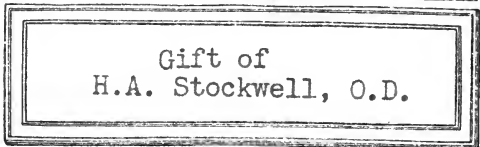


DR. POTTER.

# MORRIS' ANATOMY.

SECOND EDITION.

791 Illustrations, of which 214 are Colored.

H



OPTOMETRIST  
BERKELEY, CALIF.  
THUMB INDEX IN EACH COPY.

b  
t  
h  
n  
e  
t  
l  
c  
s  
e  
l  
e  
s  
t  
l

eatise by Vari-  
Surgical and  
Vestigial and  
MORRIS, M.A. and  
Middlesex Hos-  
ondon; Mem-  
ourt of Exam-  
cond Edition.  
d throughout.  
hich are Orig-  
Royal Octavo.  
her, net, \$7.00

and publishers  
The text has  
ten; the editor  
monious whole;  
ed in the first  
in colors, while  
ved in several

and excellence  
e. The text is  
**text-book on**  
ars.

surgical and topo-  
n is presented with  
y of the book with  
ay safely be recom-

atomy in the English  
l accurate.

For the student, the surgeon, or for the general practitioner who desires to review his anatomy, Morris' is decidedly the book to buy."

A Descriptive Circular of Morris' "Anatomy," with Sample Pages and Colored Illustrations, will be sent free to any address.

H. A. STOCKWELL  
OPTOMETRIST  
BERKELEY, CALIF.

COMPEND OF ANATOMY

---

POTTER

*From The Southern Clinic.*

"We know of no series of books issued by any house that so fully meets our approval as these ?Quiz-Compendis?. They are well arranged, full, and concise, and are really the best line of text-books that could be found for either student or practitioner."

## BLAKISTON'S ?QUIZ=COMPENDS?

The Best Series of Manuals for the Use of Students.

Price of each, Cloth, \$0.80 net. Interleaved, for taking Notes, \$1.00 net.

☞ These Compendis are based on the most popular text-books and the lectures of prominent professors, and are kept constantly revised, so that they may thoroughly represent the present state of the subjects upon which they treat.

☞ The authors have had large experience as Quiz-Masters and attaches of colleges, and are well acquainted with the wants of students.

☞ They are arranged in the most approved form, thorough and concise, containing over 600 fine illustrations, inserted wherever they could be used to advantage.

☞ Can be used by students of *any* college.

☞ They contain information nowhere else collected in such a condensed, practical shape.

*Illustrated Circular Free.*

- No. 1. POTTER'S ANATOMY. Sixth Revised and Enlarged Edition. Including Visceral Anatomy. Can be used with either Morris' or Gray's Anatomy. 117 Illustrations and 16 Lithographic Plates of Nerves and Arteries, with Explanatory Tables, etc.
- No. 2. HUGHES. PRACTICE OF MEDICINE. Part I. Sixth Edition, Revised, Enlarged, and Improved.
- No. 3. HUGHES. PRACTICE OF MEDICINE. Part II. Sixth Edition, Revised, Enlarged, and Improved. These two books furnish a complete set of notes on the Practice of Medicine, including Nervous and Mental Diseases.
- No. 4. BRUBAKER. PHYSIOLOGY. Tenth Edition, with new Illustrations and a Table of Physiological Constants. Enlarged and Revised.
- No. 5. LANDIS. OBSTETRICS. Sixth Edition. Revised and Edited by Wm. H. WELLS, M.D., Instructor Jefferson Medical College, Philadelphia. 47 Illustrations.
- No. 6. POTTER. MATERIA MEDICA, THERAPEUTICS, AND PRESCRIPTION WRITING. Sixth Revised Edition.
- No. 7. WELLS. GYNÆCOLOGY. Second Edition. With many Illustrations.
- No. 8. GOULD and PYLE. DISEASES OF THE EYE AND REFRACTION. Including Treatment and Operations and a Section on Local Therapeutics. With Formulæ and 109 Illustrations, several of which are in Colors. Second Edition.
- No. 9. HORWITZ'S SURGERY, Minor Surgery, and Bandaging. Fifth Edition, Enlarged and Improved. With 98 Formulæ and 167 Illustrations.
- No. 10. LEFFMANN. CHEMISTRY. Inorganic and Organic. Fourth Edition. Including Urinalysis, Animal Chemistry, Chemistry of Milk, Blood, Tissues, the Secretions, etc.
- No. 11. STEWART. PHARMACY. Fifth Edition. Based upon Prof. Remington's Text-Book of Pharmacy.
- No. 12. BALLOU. VETERINARY ANATOMY AND PHYSIOLOGY. With 29 graphic Illustrations.
- No. 13. WARREN. DENTAL PATHOLOGY AND DENTAL MEDICINE. Third Edition, Illustrated. Containing all the most noteworthy points of interest to the Dental Student, and a Section on Emergencies.
- No. 14. HATFIELD. DISEASES OF CHILDREN. Colored Plate. Third Edition, Revised and Enlarged.
- No. 15. THAYER. GENERAL PATHOLOGY. With many Illustrations.
- No. 16. SCHAMBERG. DISEASES OF THE SKIN. Second Edition. Illus.
- No. 17. CUSHING. HISTOLOGY. With many Illustrations.
- No. 18. THAYER. SPECIAL PATHOLOGY. With many Illustrations.

Price, each, \$0.80 net. Interleaved, for taking Notes, \$1.00 net.

P. BLAKISTON'S SON & CO., PUBLISHERS,  
PHILADELPHIA.

A COMPEND  
OF  
HUMAN ANATOMY

INCLUDING THE  
ANATOMY OF THE VISCERA

BY

<sup>209</sup>  
SAMUEL O. L. POTTER, M.A., M.D., M.R.C.P. (Lond.)

PROFESSOR OF THE PRINCIPLES AND PRACTICE OF MEDICINE AND CLINICAL MEDICINE IN  
THE COLLEGE OF PHYSICIANS AND SURGEONS OF SAN FRANCISCO; MEDICAL SUPERIN-  
TENDENT OF ST. MARK'S HOSPITAL; AUTHOR OF "HANDBOOK OF MATERIA MEDICA,  
PHARMACY, AND THERAPEUTICS," "QUIZ-COMPEND OF MATERIA MEDICA,"  
"AN INDEX OF COMPARATIVE THERAPEUTICS," AND "SPEECH AND  
ITS DEFECTS"; BRIGADE SURGEON U. S. VOL.

SIXTH EDITION, REVISED AND ENLARGED

WITH 117 WOOD ENGRAVINGS; ALSO AN APPENDIX CONTAINING  
NUMEROUS TABLES AND SIXTEEN LITHOGRAPHIC PLATES  
OF THE NERVES AND ARTERIES

PHILADELPHIA  
P. BLAKISTON'S SON & CO.  
No. 1012 WALNUT STREET

1902

TO THE MEMORY  
OF  
AN AMERICAN SURGEON AND ANATOMIST,  
WHOSE FAME IS ACKNOWLEDGED THROUGHOUT  
THE WHOLE CIVILIZED WORLD,  
JOSEPH PANCOAST,  
FORMERLY PROFESSOR OF ANATOMY IN JEFFERSON MEDICAL COLLEGE:  
AND TO  
WILLIAM H. PANCOAST,  
LATE PROFESSOR OF ANATOMY IN JEFFERSON MEDICAL COLLEGE,  
THE TALENTED AND COURTEOUS  
REPRESENTATIVE OF A GREAT NAME,  
WHOSE ENTHUSIASTIC TEACHINGS, NO LESS THAN HIS GENIAL SALUTATIONS,  
ARE TREASURED IN LOVING REMEMBRANCE BY EVERY STUDENT  
WHO HAS HEARD HIM,  
THIS COMPEND OF HUMAN ANATOMY  
IS  
AFFECTIONATELY DEDICATED,  
BY ONE OF HIS  
"STAR ANATOMICAL MEN."

QM 28  
P 86  
1902

## PREFACE.

---

THIS book contains the complete text of my two Compendis of Anatomy, namely—the “Human Anatomy,” and the “Visceral Anatomy,” heretofore published as separate volumes in this series of students’ manuals. The marked favor with which these Compendis were first received, some three and a half years ago, has since been continuously extended to them by teachers and students, both in America and in England. This has been manifested by the sale of a new and large edition every year, and has been extremely gratifying to the author. Upon the exhaustion of the third edition, the publishers resolved to acknowledge the universal appreciation shown these books, by incorporating the two in one volume; making this, the first of the now well-known “Quiz-Compendis,” a complete quiz-book on Human Anatomy. In carrying out this generous resolution, the original matter has not been curtailed anywhere; but, on the contrary, much new matter has been introduced wherever greater detail seemed to be desirable, and the number of the illustrations has been increased by eighteen new cuts.

Originally designed for the use of the medical student, in preparing for the exercises of the quiz-room and for his final examination, the text is confined to the essentials of each structure treated of, which are arranged in such a manner as to facilitate their rapid acquirement. All superfluities of description have been studiously avoided, and only such matter inserted as should be thoroughly known in order to pass a rigid examination on any organ or structure of the human body. The descriptions will be found to closely follow Gray, though Quain and other recognized authorities have been freely consulted during the preparation of the text. For many of the special arrangements

the author is indebted to the lectures of Professor W. H. Pancoast, late of Jefferson Medical College, and to the quizzes of Dr. Henry Morris, formerly assistant to the Chair of Anatomy in the same school.

While striving to carry out the object of this series in furnishing the medical student with a condensed Manual of Anatomy, the author has endeavored, from a strong appreciation of the importance of the subject, to make this volume deserving of first rank among its kind; and believing that a judicious condensation, which does not slight the essential features of the subjects treated, cannot fail to be of benefit in any department of science, he again commits his Compend to the teachers and students of Anatomy, in the hope that it may continue to be found worthy of a place alongside the more exhaustive and exhausting textbooks.

January, 1887.

---

## PREFACE TO THE FIFTH EDITION.

Another edition of this Compend having been exhausted, the publishers have requested me to improve the book in any way which will keep it in the front rank among works of its class. I have therefore added an Appendix of forty-three pages, containing an original and complete set of Tables and Plates of the Arteries, the Cranial and Spinal Nerves and Plexuses, and the Sympathetic Nervous System. These have been prepared especially for this book, and will, I think, prove of very great value to the student in college, and the physician in practice, who desires a comprehensive view of these complicated parts of the human organism.

SAM'L O. L. POTTER.

COOPER MEDICAL COLLEGE,  
*San Francisco*, July, 1890.



# TABLE OF CONTENTS.

## ANATOMY.

	PAGE
OSTEOLOGY.....	9
BONES OF THE HEAD.....	12
THE ORBITS.....	29
THE FOSSÆ.....	31
THE SUTURES AND FONTANELLES.....	33
THE WORMIAN BONES.....	33
THE HYOID BONE.....	33
TABLE OF THE FORAMINA AT THE BASE OF THE SKULL.....	34
BONES OF THE TRUNK.....	36
THE VERTEBRAL COLUMN.....	36
THE THORAX.....	38
THE STERNUM.....	38
THE RIBS.....	38
THE PELVIS.....	40
BONES OF THE UPPER EXTREMITY.....	43
THE SHOULDER.....	43
THE ARM.....	45
THE FOREARM.....	47
THE HAND.....	48
BONES OF THE LOWER EXTREMITY.....	50
THE THIGH.....	50
THE LEG.....	51
THE FOOT.....	53
ARTICULATIONS.....	55
MUSCLES AND FASCIÆ OF—	
THE HEAD.....	68
THE EAR.....	71
THE NECK.....	71
THE LARYNX AND EPIGLOTTIS.....	75
THE BACK.....	76
THE ABDOMEN.....	80
THE THORAX.....	82
THE PERINEUM.....	83

	PAGE
THE SHOULDER AND ARM .....	85
THE FOREARM .....	87
THE HAND .....	90
THE HIP AND THIGH.....	91
THE LEG.....	95
THE FOOT.....	97
THE HEART .....	99
ARTERIES.....	102
THE CIRCLE OF WILLIS.....	106
ARTERIAL ANASTOMOSES .....	114
VEINS.....	115
ABSORBENTS.....	119
NERVOUS SYSTEM.....	120
THE BRAIN.....	120
THE SPINAL CORD.....	129
THE CRANIAL NERVES .....	129
THE SPINAL NERVES.....	133
THE SYMPATHETIC NERVE.....	136

## VISCERAL ANATOMY.

DIGESTIVE ORGANS.....	141
ALIMENTARY CANAL.....	141
TEETH.....	141
STRUCTURE .....	142
DEVELOPMENT.....	143
MOUTH.....	144
PALATE .....	144
TONSILS.....	144
SALIVARY GLANDS.....	145
TONGUE.....	145
PHARYNX.....	146
ŒSOPHAGUS .....	147
STOMACH.....	148
SMALL INTESTINE.....	150
DUODENUM.....	150
JEJUNUM .....	150
ILEUM.....	150
LARGE INTESTINE.....	151
CÆCUM.....	151
APPENDIX VERMIFORMIS.....	151
COLON.....	152

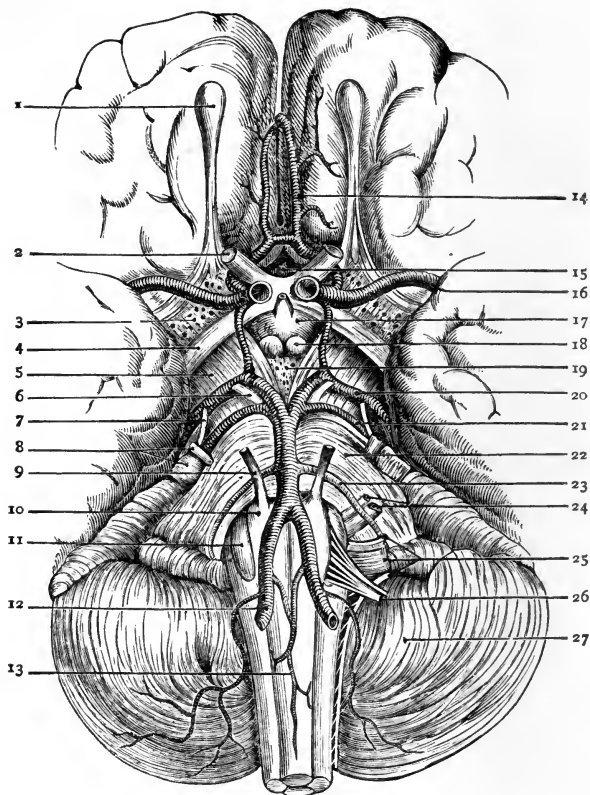
	PAGE
RECTUM.....	152
LIVER .....	153
LIGAMENTS.....	154
FISSURES.....	154
LOBES.....	154
VESSELS.....	155
CAPSULE OF GLISSON .....	156
GALL-BLADDER.....	156
PANCREAS.....	157
DUCTLESS GLANDS.....	158
SPLEEN.....	158
THYROID GLAND.....	159
THYMUS GLAND.....	160
SUPRA-RENAL CAPSULES.....	160
ABDOMINAL CAVITY.....	161
BOUNDARIES.....	161
OPENINGS .....	162
REGIONS.....	162
PERITONEUM.....	163
FORAMEN OF WINSLOW.....	163
OMENTA.....	164
MESENTERIES.....	164
ORGANS OF VOICE AND RESPIRATION.....	165
LARYNX .....	165
TRACHEA AND BRONCHI.....	170
LUNGS.....	171
PLEURÆ.....	174
MEDIASTINUM.....	174
URINARY ORGANS.....	175
KIDNEYS.....	175
URETERS.....	177
BLADDER.....	178
MALE URETHRA.....	179
FEMALE URETHRA .....	181
MALE GENERATIVE ORGANS.....	181
PROSTATE GLAND.....	181
COWPER'S GLANDS.....	181
PENIS.....	182
TESTES AND APPENDAGES.....	183
DESCENT OF THE TESTES.....	186

	PAGE
<b>FEMALE ORGANS OF GENERATION</b> .....	187
VULVA.....	187
VAGINA.....	188
UTERUS AND APPENDAGES.....	188
FALLOPIAN TUBES.....	190
OVARIES.....	190
PAROVARIUM.....	192
MAMMÆ.....	192
<b>ORGANS OF SENSE</b> .....	193
SKIN AND ITS APPENDAGES.....	193
TONGUE.....	195
NOSE.....	195
SCHNEIDERIAN MEMBRANE.....	195
EYE.....	197
SCLEROTIC AND CORNEA.....	198
UVEAL TRACT.....	200
RETINA.....	202
HUMORS.....	204
VESSELS AND NERVES OF THE EYE.....	207
APPENDAGES OF THE EYE.....	209
EAR.....	212
EXTERNAL EAR.....	213
MEMBRANA TYMPANI.....	214
TYMPANUM.....	216
EUSTACHIAN TUBE.....	219
INTERNAL EAR.....	219
<b>HERNIA</b> .....	226
INGUINAL HERNIA.....	226
COVERINGS.....	227
FEMORAL HERNIA.....	228
COVERINGS.....	229
<b>PERINEUM</b> .....	230
MALE PERINEUM.....	230
LITHOTOMY.....	231
FEMALE PERINEUM.....	232
<b>APPENDIX</b> .....	235
THE ARTERIAL SYSTEM, TABLES AND PLATES.....	236
THE NERVOUS SYSTEM, TABLES AND PLATES.....	251
<b>INDEX</b> .....	277

# LIST OF ILLUSTRATIONS.

FIG.		PAGE		FIG.		PAGE
	Base of the Brain.....	xii		59.	The Femoral Artery.....	112
1.	The Temporal Bone, external view,	15		60.	The Venæ Cavæ and Azygos	117
2.	The Temporal Bone, internal view,	16			Veins.....	130
3.	The Sphenoid Bone, upper surface,	18		61.	The Optic Nerves and Tract, etc.	130
4.	The Sphenoid Bone, lower surface..	19		62.	The Fifth Cranial Nerve.....	130
5.	The Ethmoid Bone.....	21		63.	The Sacral Plexus, and its	135
6.	The Superior Maxillary Bone.....	22			branches.....	138
7.	The Malar Bone.....	24		64.	The Three Petrosal Nerves.....	142
8.	The Palate Bone.....	25		65.	A Tooth.....	144
9.	The Inferior Turbinated Bone.....	26		66.	The Salivary Glands.....	145
10.	The Vomer.....	27		67.	The Tongue and Fauces.....	147
11.	The Inferior Maxillary Bone.....	29		68.	The Muscles of the Pharynx.....	148
12.	The Cavity of the Orbit.....	31		69.	The Stomach .....	149
13.	The Nasal Fossæ.....	34		70.	Arteries of the Stomach, Pancreas,	150
14.	The Base of the Skull.....	36			etc.....	152
15.	A Vertebra.....	38		71.	The Duodenum.....	153
16.	The Sternum.....	39		72.	The Colon and Rectum.....	155
17.	Ribs.....	40		73.	The Liver.....	156
18.	The First Rib.....	41		74.	Structure of the Liver (vessels).....	157
19.	The Pelvis.....	42		75.	Structure of the Liver (cells).....	158
20.	The Sacrum.....	46		76.	The Pancreas.....	162
21.	The Coccyx.....	47		77.	The Spleen.....	164
22.	The Innominate Bone.....	48		78.	Regions of the Abdomen.....	166
23.	The Humerus.....	50		79.	The Peritoneum.....	166
24.	The Radius and Ulna.....	52		80.	The Thyroid Cartilage.....	169
25.	The Bones of the Carpus.....	53		81.	The Cricoid Cartilage.....	172
26.	The Femur.....	56		82.	The Arytenoid Cartilages.....	173
27.	The Tibia and Fibula.....	57		83.	Muscles of the Larynx.....	175
28.	Bones of the Tarsus and Foot.....	58		84.	The Lungs, Heart, etc.....	176
29.	The Occipito-atloid Articulation, etc.	59		85.	Lobules and Alveoli of the Lung...	178
30.	The Temporo-maxillary Articulation,	60		86.	The Kidney.....	180
	tion.....	61		87.	A Malpighian Tuft.....	182
31.	The Costo-vertebral Articulations...	64		88.	The Bladder.....	185
32.	The Sacro-ischiatic Articulation, etc.	64		89.	The Male Urethra, etc.....	187
33.	The Shoulder-joint, etc.....	66		90.	Section of the Penis.....	188
34.	The Elbow-joint.....	69		91.	Section of the Testicle and Scrotum.....	189
35.	The Knee-joint, posteriorly.....	72		92.	Ducts of the Testicle and Epididymis.....	192
36.	The Knee-joint, anteriorly.....	77		93.	The Vulva.....	192
37.	Muscles of the Face and Forehead..	79		94.	The Uterus and its Appendages.....	193
38.	Muscles of the Neck.....	81		95.	The Mammæ.....	196
39.	Muscles of the Back.....	83		96.	The Skin and its Appendages.....	198
40.	Muscles of the Back, deep layers...	84		97.	The Nose.....	201
41.	Muscles of the Chest and Abdomen,	86		98.	The Eye.....	203
42.	The Diaphragm.....	88		99.	The Iris.....	205
43.	Muscles of the Perineum.....	89		100.	The Retina.....	206
44.	Muscles of the Arm.....	92		101.	The Crystalline Lens.....	209
45.	Muscles of the Fore-arm and Hand	93		102.	The Muscles of the Eyeball.....	210
	(1).....	94		103.	Appendages of the Eye.....	212
46.	Muscles of the Fore-arm and Hand	96		104.	Structure of the Eyelids.....	215
	(2).....	97		105.	The Lachrymal Gland.....	217
47.	Muscles of the Thigh, anteriorly....	98		106.	The Membrana Tympani.....	220
48.	Muscles of the Thigh, posteriorly....	101		107.	The Tympanum.....	221
49.	Muscles of the Hip-joint.....	103		108.	The Internal Ear.....	222
50.	Muscles of the Leg, anteriorly.....	104		109.	The Cochlea.....	223
51.	Muscles of the Leg, posteriorly.....	104		110.	The Membranous Labyrinth.....	224
52.	Muscles of the Foot.....	104		111.	The Membranous Cochlea.....	224
53.	The Heart.....	104		112.	Rods of Corti.....	224
54.	The Aorta.....	104		113.	Auditory Cells.....	224
55.	Arteries of the Face and Head.....	104		114.	Poupart's Ligament.....	227
56.	The Right Internal Maxillary Artery.....	104		115.	Femoral Hernia.....	228
57.	The Sub-clavian Artery.....	106		116.	The Male Perineum.....	232
58.	The Abdominal Aorta.....	109				

Sixteen Lithographic Plates, in Appendix.



### THE BASE OF THE BRAIN.

1. Olfactory Bulb. 2. Second, or Optic Nerves. 3. Anterior Perforated Space. 4. Optic Tract. 5. Crus Cerebri. 6. 3d Nerve. 7. 4th Nerve. 8. 5th Nerve. 9. 6th Nerve. 10. Pyramid. 11. Olivary Body. 12. Vertebral Artery. 13. Anterior Spinal Artery. 14. Anterior Cerebral Artery. 15. Lamina Cinerea. 16. Middle Cerebral Artery. 17. Tuber Cinereum. 18. Corpora Albicantia. 19. Middle Perforated Space. 20. Posterior Cerebral Artery. 21. Superior Cerebral Artery. 22. Pons Varolii. 23. Inferior Cerebellar Artery. 24. 7th and 8th Nerves. 25. 9th, 10th and 11th Nerves. 26. 12th Nerve. 27. Cerebellum.

## A

# COMPEND OF ANATOMY.

---

**Define the term Anatomy.** Derived from the Greek *ana ana*, through, and *τέμνειν temnein*, to cut, it strictly means *dissection*, but is technically applied to that science which treats of the structure of organized bodies.

**What are the divisions of Descriptive Human Anatomy?** They are,—*Osteology*, the anatomy of the bones; *Syndesmology*, of the joints; *Myology*, of the muscles; *Angiology*, of the vessels; *Neurology*, of the nerves; *Splanchnology*, of the internal viscera; *Adenology*, of the glands; *Dermatology*, of the skin; *Genesisiology*, of the generative organs.

**State the number of Bones in the Adult Human Skeleton.** It is variously stated by different anatomists. Excluding the teeth, the Wormian and sesamoid bones, and the ossicles of the middle ear, the whole number would be 200; excluding also the 2 patellæ, and the hyoid bone, would leave in the skeleton proper 197 bones.

**Describe the Long Bones.** They number 90, act as supports, or levers, and are known by having a medullary canal in the centre of each, a shaft (*diaphysis*), and two extremities. They are developed by osseous deposit in cartilage.

**Describe the Short Bones.** Numbering 30, they are found where strength is required, but limited motion. They also are developed by osseous deposit in cartilage.

**Describe the Flat Bones.** They number 38, protect the viscera by forming walls around them, and afford extensive attachment for muscles. They are developed by osseous deposit in membranes, and consists of 2 dense layers, separated by a cellular or cancellated osseous tissue, the *diploë*.

**What are the Irregular Bones?** They are 39 in number, and include the vertebræ, sacrum, coccyx, the temporal, ethmoid, and sphenoid bones, and the bones of the face, except the *nasal*, *lachrymal*, and *vomer*.

**Name the Bones of the Head.** They number 22, and comprise the—  
*Cranial Bones* (8)—the frontal, 2 parietal, occipital, 2 temporal, the sphenoid and the ethmoid bones.

*Facial Bones* (14)—2 superior maxillary, 2 malar, 2 nasal, 2 lachrymal, 2 palate, 2 inferior turbinated, vomer and inferior maxillary.

**Name the Bones of the Trunk.** They number 53, as follows, viz.—

*Vertebræ* (24)—7 cervical, 12 dorsal, and 5 lumbar vertebræ.

*Thorax* (25)—7 pairs of true ribs, 3 pairs of false ribs, 2 pairs of floating ribs, (articulating with the bodies of the dorsal vertebræ,) and the sternum.

*Pelvis* (4)—the sacrum, the coccyx, and 2 ossa innominata; each os innominatum consisting of 3,—the ilium, ischium, and pubes.

**Name the Bones of each Upper Extremity.** They number 32, as follows:—

*Shoulder* (2)—the clavicle and scapula.

*Arm* (1)—the humerus.

*Forearm* (2)—the radius and ulna.

*Hand* (27)—8 carpal bones,—the scaphoid, semilunar, cuneiform, pisiform, trapezium, trapezoid, os magnum, and unciform,—5 metacarpal, and 14 phalanges.

**Name the Bones of each Lower Extremity.** They number 29, viz.—

*Thigh* (1)—the femur.

*Leg* (2)—the tibia and fibula.

*Foot* (26)—7 tarsal bones,—the astragalus, os calcis, scaphoid, cuboid, external middle and internal cuneiform,—5 metatarsal, 14 phalanges.

**Name the Unclassified Bones.** They are the—

*Patellæ* (2), which are sesamoid bones, each developed in the tendon of the quadriceps extensor femoris muscle.

*Hyoid Bone* (1)—the tongue-bone, not articulated to the skeleton.

*Malleus, Incus, Staples* (3 pairs)—the bones of the middle ear.

*Sesamoid Bones*, of variable number, situated in the tendons of the gastrocnemius and peroneus longus muscles, and in the flexor tendons of the great toe and the thumb.

*Wormian Bones* (ossa triquetra), sometimes found in the cranial sutures, are not constant in number or size.

**Name the principal Eminences on Bones.** *Heads*, are convex and smooth, for articulation in movable joints. *Condyles*, are irregularly-shaped heads. *Trochanters*, when for turning the bone. *Tuberosities*, are broad, uneven prominences. *Tubercles*, are small tuberosities. *Spines*, or *Spinous processes*, when sharp and slender. *Apophysis*, is a process which has never



been separate from the bone. *Epiphysis*, is a process developed as a separate piece and afterwards united to the bone by ossification of the intermediate tissue.

**What other names are given to Bony Prominences?** There are several adjectives applied to them from their fancied resemblances, such as—*Azygos*, without a fellow; *Clinoid*, like a bed; *Coracoid*, like a crow's beak; *Coronoid*, hooked like a crow's beak; *Hamular*, hook-like; *Malleolar*, like a mallet; *Mastoid*, like a nipple; *Odontoid*, tooth-like; *Pterygoid*, wing-like; *Rostrum*, a beak; *Spinous*, thorn-like; *Styloid*, pen-like; *Squamous*, scaly; *Vaginal*, ensheathing, etc.

**Name the Cavities of Bones.** Articular cavities are called *Cotyloid*, cup-like; *Glenoid*, shallow; *Trochlear*, pulley-like; *Facet*, if smooth; *Alveolar*, or *Alveoli*, when socket-like. Non-articular cavities are named fossæ, sinuses, aqueducts, foramina, canals, fissures, notches, cells, grooves, depressions, etc.

**What is the Composition of Bone?** *Organic* or animal matter, about  $\frac{1}{3}$ , consisting of gelatin, vessels and fat. *Inorganic*, or mineral, about  $\frac{2}{3}$ , consisting of phosphate and carbonate of calcium ( $62\frac{1}{2}$  per cent.), with fluoride of calcium, phosphates of magnesium, sodium, and chloride of sodium ( $4\frac{1}{2}$  per cent.). *Heat* will remove the organic matter and leave the inorganic; dilute *Nitric* or *Hydrochloric acid* will remove the inorganic, and leave the organic. In old age the inorganic constituents predominate, and the bones are brittle; in youth the organic predominate, and epiphyseal dislocation is more common than fracture, especially in the long bones of the extremities.

**Describe the Structure of Bone.** Bone is composed of an outer compact layer, and an inner cellular or spongy structure. It is surrounded, except at the articular cartilages, by a vascular fibrous membrane, the *Periosteum*, which receives the insertions of all tendons, ligaments, etc.; and the central cavity of long bones is lined by a similar structure, the *Endosteum*. A transverse section of bone, examined microscopically, shows—

*Haversian Canals*, diameter  $\frac{1}{500}$  inch, for the passage of vessels.

*Canaliculi*, diameter  $\frac{1}{1000}$  inch, radiating from the canals, and connecting them with the lacunæ.

*Lacunæ*, arranged circularly around the canals, and contain the bone-cells, appearing as irregular dark spaces.

*Haversian Spaces*, connect the canals with the medullary spaces, and divide one Haversian system from another. An *Haversian System* comprises an Haversian canal with its lamellæ, lacunæ, and canaliculi.

*Concentric Lamellæ* of bone tissue, around the canals.

*Circumferential Lamellæ*, are bone layers binding the canals together.

*Interstitial Lamellæ*, woven in between the concentric lamellæ.

**What is the Marrow of Bone?** In young bones a tenacious, transparent fluid, free from fat. In adult bones of a yellow color, consisting of fat in varying proportion and extractive matters. It is found in the medullary canal, the cancellous texture, and the large Haversian spaces.

**What Vessels are found in Bones?** Arteries, veins, and some say lymphatics. *The Arteries* are,—the nutrient, entering at the nutrient foramen; the articular, nourishing the cancellous structure; and the periosteal, which supply the periosteum and the compact structure. *The Veins* emerge from the ends, the shaft, and from the nutrient foramen.

**Describe the process of Ossification.** The site of bone is first occupied by a mucoid substance, which becomes temporary cartilage (*blastema*) in the second month of foetal life. The young bone-cells (*osteo-blasts*) are then deposited in the cartilage at certain points, and their deposition and subsequent pressure cause the absorption of the cartilage. In most of the bones of the head and face, ossification is intra-membranous instead of intra-cartilaginous. *The first bones* in which ossification appears are the clavicle and inferior maxillary (5th to 7th foetal week); the *last* is the pisiform bone (12th year). *Epiphyses* ossify after birth and begin uniting to the bone from the age of puberty, and in the inverse order to that in which their ossification began, except the lower end of the fibula, which ossifies and is joined to the shaft earlier than its upper end.

## THE BONES OF THE HEAD.

### THE FRONTAL BONE.

**Describe the points on its vertical portion.** They are as follows:—  
Externally,—

*Frontal Eminences*, one on each side of the median line.

*Depression*, marking the site of the frontal suture before obliteration.

*Superciliary Ridges*, behind which are the frontal sinuses.

*Supraorbital Notches or Foramina*, in the supraorbital arches, at about their inner third, for the supraorbital vessels and nerves.

*Nasal Eminence*, at lower end of the frontal depression.

*External Angular Processes*, articulate with the malar bones and form the anterior part of the temporal ridges.

*Internal Angular Processes*, articulate with the lachrymal bones.

*Nasal Spine and Notch*, between the internal angular processes.

Internally,—

*Groove*, for superior longitudinal sinus and the falx cerebri.

*Frontal Crest*, for attachment of the falx cerebri.

*Foramen Cæcum*, for a small vein to the longitudinal sinus.

*Depressions and Elevations*, for convolutions of the brain.

Between the two tables of the vertical portion in the adult are the—

*Frontal Sinuses*, two spaces at the anterior inferior part of the bone, which are lined with mucous membrane, and open into the middle meatus of the nose by means of an *Infundibulum* for each.

**Describe its horizontal portion, or orbital plates.** They each present the following points, viz.—

*Fossa*, for the lachrymal gland, near the external angular process.

*Depression*, at the nasal margin for the pulley of the superior oblique muscle.

*Ethmoidal Notch*, having the following foramina on its margin.

*Anterior Ethmoidal Foramen*, for anterior ethmoidal vessels and the nasal branch of the ophthalmic nerve.

*Posterior Ethmoidal Foramen*, for posterior ethmoidal vessels.

*Grooves*, on the cranial surface, for branches of the anterior and middle meningeal arteries.

**Describe its articulations, development, and muscles.** The frontal articulates with 12 bones,—the sphenoid, ethmoid, 2 parietal, 2 nasal, 2 superior maxillary, 2 lachrymal, and 2 malar. It is developed by 2 centres in membrane, 1 for each lateral half. The muscles attached to it are 3 pairs,—the temporal, corrugator supercillii, and orbicularis palpebrarum.

## THE PARIETAL BONES.

**Describe their general characteristics.** They are 2 quadrilaterally-shaped bones situated at the superior and lateral regions of the cranium. The superior border of each joins the other by the *Sagittal Suture*; the anterior border joins the frontal bone by part of the *Coronal Suture*; the posterior border articulates with the occipital, forming the *Lambdoidal Suture*; the inferior border with the sphenoid and temporal bones. Forming the lateral walls of the skull they are named parietal, from *paries*, a wall.

**Describe the points on each Parietal bone.** Externally the bone is convex and presents for examination,—

*Temporal Ridge*, continuous with the same on the frontal bone.

*Parietal Eminence*, the point where ossification commenced.

*Parietal Foramen*, close to the upper border, transmits a vein to the superior longitudinal sinus. Is not constant.

Internally, the bone is concave, and marked by—

*Depressions* for the Pacchionian bodies, and for the cerebral convolutions.

*Furrows*, for branches of the middle meningeal artery.

*Groove*, for the lateral sinus, at the posterior inferior angle.

*Half-groove*, along the upper border, for the superior longitudinal sinus of the dura mater.

Describe their articulations, development, and muscles. Each parietal bone *articulates* with 5 bones,—the frontal, occipital, sphenoid, temporal, and opposite parietal. It is *developed* from 1 centre in membrane. The *only muscle* attached to it is the temporal.

### THE OCCIPITAL BONE.

Describe its general features and surfaces. It is trapezoidal in form, curved upon itself, and placed at the posterior and inferior region of the cranium. Externally its surface is convex and presents for examination the following, viz.—

*External Occipital Protuberance, and Crest*, for the attachment of the ligamentum nuchæ.

*Superior and Inferior Curved Lines*, extending outwards on each side of the external occipital crest.

*Foramen Magnum*, transmitting the medulla oblongata and its membranes, the vertebral arteries, and the spinal accessory nerves.

*Condyles*, 2 in number, for articulation with the atlas vertebra.

*Tubercles*, 1 on each condyle, for the check ligaments.

*Anterior Condylloid Foramina*, 2, for the hypoglossal nerves.

*Posterior Condylloid Foramina*, 2, (often absent) for veins.

*Jugular Processes*, 2, each helping to form the foramen lacerum posterius basis cranii.

Internally, the surface is concave, showing—

*Fossæ*, 4, for the cerebellar and posterior cerebral lobes.

*Internal Occipital Protuberance*, where 6 cranial sinuses meet to form the torcular (wine-press) Herophili.

*Crucial Ridge*, the vertical portion for the falx cerebri and falx cerebelli; the transverse portion for the tentorium cerebelli, having also a groove for the lateral sinus.

*Groove*, for the lateral sinus, and the inferior petrosal sinus, along the postero-lateral border.

*Internal Openings* of the foramina described above.

Describe the Basilar Process of the Occipital. It lies in front of the foramen magnum, articulates with the body of the sphenoid bone, smooth and grooved internally for the medulla oblongata and pons varolii, which lie upon it; rough inferiorly for the attachment of muscles, and presenting the—

*Pharyngeal Spine*, for the attachment of the superior constrictor muscle of the pharynx and its tendinous raphé.

Describe its articulations and development. The occipital *articulates* with 6 bones,—the 2 parietal, 2 temporal, sphenoid, and atlas. It is *developed* by 4 centres, 1 each for the posterior part, the basilar process,

and the 2 condyles; its ossification being completed about the 6th year of age.

**What muscles are attached to the Occipital Bone?** There are 12 muscles attached on each side to the following portions, viz.—

*Superior Curved Line* 3—the occipito-frontalis, trapezius, and sterno-cleido-mastoid.

*Space between the curved lines* 2—the complexus and splenius.

*Space below the inferior curved line* 3—the obliquus capitis superior, rectus capitis posticus major and minor.

*Basilar Process* 3—the superior constrictor of the pharynx, rectus capitis anticus major and minor.

*Jugular Process* 1—the rectus capitis lateralis.

### THE TEMPORAL BONES.

**Describe their situation and divisions.** They are situated at the inferior lateral portions of the skull, and contain the organs of hearing. Each bone is divided into 3 parts, the *Squamous*<sup>a</sup> (scale-like), *Mastoid*<sup>b</sup> (nipple-like), and *Petrous*<sup>c</sup> (hard); and it is named from being the site of the first gray hairs (*tempus*, time).

**Describe the Squamous Portion.** It is a semicircular plate, smooth externally, and grooved internally for the middle meningeal artery, with depressions for the cerebral convolutions. Externally are seen the—

*Zygomatic Process*,<sup>d</sup> or zygoma, arising by 3 roots, and extending forwards to articulate with the malar bone.

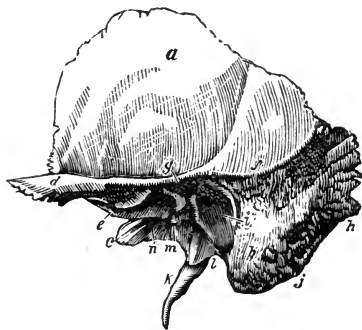
*Zygomatic Tubercle*,<sup>e</sup> at the base of the process, for the external lateral ligament of the lower jaw.

*Eminentia Articularis*, formed by the anterior root of the zygoma.

*Glenoid Fossa*,<sup>g</sup> between the anterior and middle roots of the zygoma; its anterior part receives the condyle of the lower jaw, and is covered with cartilage; its posterior part lodges the parotid gland.

*Glasserian Fissure*, divides the glenoid fossa; it transmits the laxator tympani muscle, the tympanic artery, and the processus gracilis of the malleus.

FIG. 1.



*Opening of the Canal of Hugier*, lies in the angle between the squamous and petrous portions of the bone; and transmits the chorda tympani nerve.  
*Temporal Ridge*,<sup>f</sup> in part.

**Describe the Mastoid Portion.** It projects like a nipple from the inferior portion of the bone posteriorly. Internally it is grooved for the lateral sinus;<sup>g</sup> externally are seen the—

*Mastoid Foramen*,<sup>h</sup> the largest of several foramina, for a vein.

*Mastoid Process*, at the tip, for the sterno-cleido-mastoid, splenius, and trachelo-mastoid muscles.

*Digastric Fossa*,<sup>j</sup> for the posterior belly of the digastric muscle.

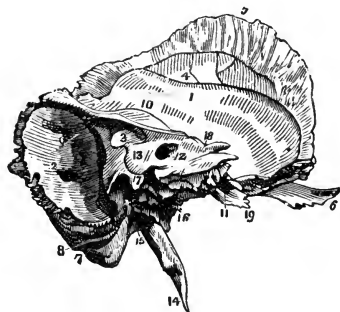
*Occipital Groove*,<sup>8</sup> for the occipital artery.

*Mastoid Cells*, in the interior of the mastoid process, open on the posterior wall of the middle ear, and are lined with mucous membrane.

**Describe the Petrous Portion.** It is very hard, pyramidal in form, contains the internal and middle ear, projects inwards and forwards, and presents a base, an apex, three surfaces, and three borders.

On the Base are seen, the—

FIG. 2.



*Meatus Auditorius Externus*,<sup>i</sup> the external opening of the ear.

*Auditory Process*, a bony ring for the external cartilage of the ear.

Apex lies internally, at the base of the skull, forming the outer boundary of the foramen lacerum medium, and contains the internal carotid canal.

Anterior Surface, presents from within, outwards—

*Opening of the Carotid Canal*,<sup>11</sup> for the internal carotid artery and plexus.

*Depression*, for the Gasserian ganglion of the 5th pair of cranial nerves.

*Hiatus Fallopii*, for great petrosal nerve and an artery.

*Foramen*, for small petrosal nerve.

*Eminence*, over the superior semicircular canal of the ear.

*Depression*, over the tympanum.

Posterior Surface, presents—

*Meatus Auditorius Internus*,<sup>12</sup> transmits the 7th and 8th pairs of cranial nerves and the auditory artery, and lodges a process of dura mater.

*Opening of the Aqueductus Vestibuli*,<sup>13</sup> transmits to the vestibule a small artery and vein, and lodges a process of dura mater.

Inferior surface, presents from within outwards—

*Rough Quadrilateral Surface*,<sup>19</sup> for the origin of the tensor tympani and levator palati muscles.

*Opening of the Carotid Canal*, transmitting the internal carotid artery, and the carotid plexus of the sympathetic nerve.

*Aqueductus Cochleæ*, transmitting a vein from the cochlea.

*Jugular Fossa*, a depression for the sinus of the internal jugular vein, forming with the occipital bone the foramen lacerum posterius, which transmits that vein and the 8th pair of cranial nerves, etc. (See page 35.)

*Foramen for Jacobson's Nerve* (tympenic branch of the glosso-pharyngeal), in the ridge between the jugular fossa and the carotid canal.

*Foramen for Arnold's Nerve* (auricular branch of the pneumogastric), in the outer wall of the jugular fossa.

*Jugular Surface*, for articulation with the jugular process of the occipital bone.

*Vaginal Process*,<sup>1</sup> ensheathing the root of the styloid process.

*Styloid Process*,<sup>14</sup> a long projection for the stylo-pharyngeus, stylo-hyoid, and stylo-glossus muscles (3); and the stylo-hyoid and stylo-maxillary ligaments (2), which are attached thereto.

*Stylo-mastoid Foramen*,<sup>15</sup> between the styloid and mastoid processes, for the exit of the facial nerve, and the entrance of the stylo-mastoid artery.

*Auricular Fissure*, for the exit of Arnold's nerve.

In the angle between the petrous and squamous portions, are seen the—

*Septum Tubæ*, a lamina separating the following canals. Its inner end projects into the tympanum, and is called the *Processus cochleariformis*.

*Opening of the canal for the tensor tympani muscle.*

*Osseous Opening of the Eustachian tube* inferiorly.

The Anterior Border articulates partly with the spinous process of the sphenoid bone.

The Posterior Border assists in forming the jugular foramen, and is grooved for the inferior petrosal sinus.

The Superior Border separates the anterior fossa of the skull from the middle fossa; to it is attached the tentorium cerebelli, and it is grooved for the superior petrosal sinus.<sup>10</sup>

**Describe its articulations and development.** The temporal articulates with 5 bones,—the occipital, parietal, sphenoid, malar, and inferior maxillary. It is developed by 4 centres, one each for the squamous portion, styloid process, and auditory process, and one for the petrous and mastoid portions. Its ossification is completed about the 2d or 3d year.

**What muscles are attached to it?** There are 14 muscles attached to the following-named portions. To the—

*Squamous Portion 2*,—the temporal and masseter.

*Mastoid Portion* 6,—the occipito-frontalis, sterno-cleido-mastoid, splenius capitis, trachelo-mastoid, digastric, and retrahens aurem.

*Petrous Portion* 3,—the tensor tympani, levator palati, and stapedius.

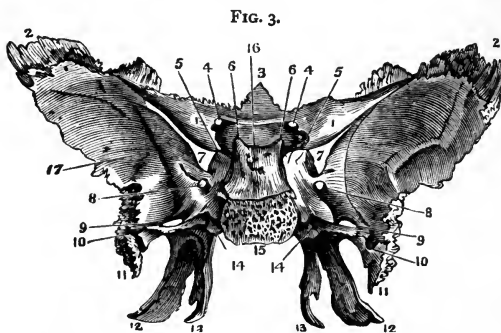
*Styloid Process* 3,—the stylo-glossus, stylo-hyoid, and stylo-pharyngeus.

### THE SPHENOID BONE.

**Describe its Position and Form.** Wedged in between the bones of the skull anteriorly, it resembles a bat with out-stretched wings. It is named from the Greek word σφήν *sphane*, a wedge, enters into the formation of 5 cavities, 4 fossæ, 3 fissures, and has—

A Body.	2 Pterygoid Processes.	12 Foramina.
2 Greater Wings. <sup>2</sup>	2 Styloid Processes.	12 pairs of Muscles.
2 Lesser Wings. <sup>1</sup>	6 Clinoid Processes.	12 Articulations.
10 Points of Ossification.	3 Lesser Processes.	

**Describe the Body of the Sphenoid Bone.** Placed in the median line, cuboid in shape, it presents on its **UPPER SURFACE** from before backwards, the following points, viz.—



*Ethmoidal Spine*,<sup>8</sup> articulating with the ethmoid bone.

*A Smooth Surface*, grooved for the olfactory nerves.

*Optic Groove*, supporting the commissure of the optic nerves.

*Olivary Process*, an olive-shaped eminence behind the optic groove.

*Middle Clinoid Processes*, bounding the sella Turcica in front.

*Sella Turcica*<sup>16</sup> (Turkish saddle), lodges the pituitary body and the circular sinus of the brain.

*Dorsum Sellæ* (back of the saddle), grooved for the 6th nerves.

*Posterior Clinoid Processes*,<sup>6</sup> for attachment of the tentorium cerebelli.

*Grooves*, laterally, for the cavernous sinus and internal carotid artery.

THE POSTERIOR SURFACE is rough and quadrilateral:<sup>15</sup> it articulates with the basilar process of the occipital bone, ossification being completed from the 18th to the 20th year.



THE ANTERIOR SURFACE is nearly vertical, and presents the—

*Lamella*, in the median line, articulating with the perpendicular plate of the ethmoid bone, and forming part of the nasal septum.

*Opening of the Sphenoidal Sinuses*,<sup>e</sup> or cavities in the body of the bone which exist in adults, not in children.

*Sphenoidal Turbinate Bones* (pyramids of Wistar), which partially close the sinuses, and articulate with the ethmoid and palate bones.

THE INFERIOR SURFACE helps to form the nasal fossæ, and presents the—

*Rostrum*,<sup>d</sup> which articulates with a groove on the vomer.

*Vaginal Processes*, 1 on each side of the rostrum.

*Pterygo-palatine Grooves*, which, with the sphenoidal processes of the palate bones, form the pterygo-palatine canals, for the transmission of the pterygo-palatine arteries and nerves.

**Describe the Greater Wings of the Sphenoid.** Each wing, on its SUPERIOR SURFACE, presents the following points, viz.—

*Foramen Rotundum*,<sup>8</sup> for the superior maxillary division of the 5th.

*Foramen Ovale*,<sup>9</sup> for the inferior maxillary division of the 5th nerve, the small petrosal nerve, and the small meningeal artery.

*Foramen Vesalii*, transmitting a small vein.

*Foramen Spinosum*,<sup>10</sup> transmitting the middle meningeal artery.

THE ANTERIOR SURFACE assists in forming the external wall of the orbit, the speno-maxillary and sphenoidal fissures. It articulates with the frontal and malar bones, and presents a—

*Notch*, transmitting a branch of the ophthalmic artery.

*Spine*, for part of the lower head of the external rectus muscle.

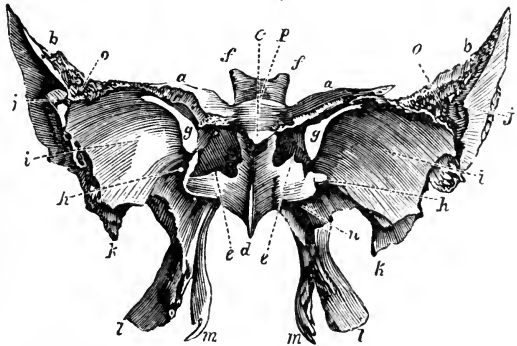
*External Orbital Foramina*, transmitting arterial branches.

THE EXTERNAL SURFACE presents the following points,—

*Pterygoid Ridge*, dividing the temporal fossa from the zygomatic.

*Spine of the Sphenoid*,<sup>11</sup> to which are attached the internal lateral ligament of the lower jaw, and the laxator tympani muscle.

FIG. 4.



THE CIRCUMFERENCE is partly serrated for articulation with the temporal and frontal bones, and partly smooth for the anterior margin of the foramen lacerum medium and the inferior margin of the sphenoidal fissure, which margins it assists in forming.

**Describe the Lesser Wings<sup>1</sup> of the Sphenoid.** Called also the Processes of Ingrassias,<sup>a</sup> they terminate internally in the *Anterior Clinoid Processes*;<sup>b</sup> their anterior borders articulate with the orbital plate of the frontal bone, the posterior are free, dividing the anterior cerebral fossa from the middle. Connected intimately with each of these wings are the—

*Optic Foramen*,<sup>4</sup> formed by the separation of its roots, and transmitting the optic nerve and the ophthalmic artery.

*Sphenoidal Fissure*,<sup>7</sup> or foramen lacerum anterius,<sup>g</sup> is bounded above by the lesser wing, below by the greater wing, and transmits the 3d, 4th, ophthalmic division of the 5th, and the 6th nerves, the ophthalmic vein, branches of the lachrymal and middle meningeal arteries, some filaments of the sympathetic nerve, and a process of the dura mater.

**Describe the Pterygoid Processes of the Sphenoid.** The wing-like processes descend, 1 on each side of the body, and divide each into 2 thin, bony plates,<sup>lm</sup> connected together anteriorly, and presenting—

*Pterygoid Fossa*, between the plates posteriorly, the origin of the external pterygoid muscle.

*Scaphoid Fossa*, at the base of the internal plate, serves as the origin of the tensor palati muscle.

*Hamular Process*, a hook-like projection at the apex of the internal plate, around which plays the tendon of the tensor palati muscle.

*Vidian Canal*,<sup>14</sup> at the root of the process, for the Vidian nerve and vessels.

*Triangular Notch*, at the end of the process, articulates with the pterygoid process of the palate bone.

**With what bones does the Sphenoid articulate?** With 12, the other 7 bones of the cranium and 5 of the face,—the vomer, 2 malar, and 2 palate.

**How is the Sphenoid developed?** By 10 centres, as follows.—2 for the greater wings, 2 for the lesser wings and anterior part of the body, 2 for the posterior part of the body, 2 for the pterygoid processes, and 2 for the sphenoidal turbinated processes. Ossification begins in the 2d fetal month, and is completed about the 11th year, by the union of the turbinated processes with the body.

**What muscles are attached to the Sphenoid bone?** There are 12 pairs, as follows, viz.—

*Orbital muscles*, 6—all except the inferior oblique of the eye.

*Muscles of Mastication*, 3—the temporal, external and internal pterygoids. Superior constrictor, tensor palati, and laxator tympani, 3.

### THE ETHMOID BONE.

**Describe its General Characteristics.** It is a spongy, light bone, depending from the ethmoidal notch of the frontal, and from between its orbital plates. It consists of a body and 2 lateral masses, and is named from the Greek word ἄθμος, *aythmos*, a sieve.

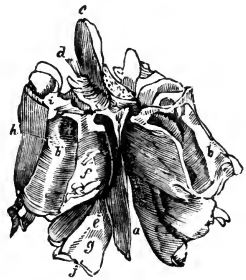
**What are the Points on its Body?** The body<sup>b</sup> consists of a horizontal or cribriform plate, and a perpendicular plate, and presents the—

*Crista Galli*,<sup>c</sup> or cock's comb, projecting upwards, for the attachment of the anterior end of the falx cerebri.

*Cribriform Plate*,<sup>d</sup> on each side of the crista galli. It is concave for the olfactory bulbs,<sup>i</sup> and perforated for the transmission of the olfactory nerves, the nasal branch of the ophthalmic nerve, and numerous small vessels.

*Perpendicular Plate*,<sup>a</sup> assists to form the nasal septum, is usually inclined to one side, grooved for filaments of the olfactory nerves, and has attached to it the cartilage of the nose.

FIG. 5.



**Describe the Lateral Masses.** They consist of a number of cellular cavities, and each one presents the following points, viz.—

*Ethmoid Cells*, the anterior opening by the infundibulum into the middle meatus of the nose, the posterior into the superior meatus.

*Os Planum*,<sup>h</sup> or orbital plate, helps to form the inner wall of the orbit, and is notched superiorly to form with the frontal bone the two ethmoidal foramina.

*Unciform Process*, descends to articulate with the inferior turbinate, and forms part of the inner wall of the antrum.

*Superior Turbinate Process*,<sup>f</sup> curves downwards and outwards.

*Middle Turbinate Process*,<sup>g</sup> is larger and more curved than the superior.

These processes bound the superior meatus of the nose, and are often called the superior and middle turbinated bones.

**Describe its articulations, development, and muscles.** The ethmoid articulates with 15 bones, viz.—all those of the face except the malar, and the frontal and sphenoid of the cranium. It is developed by 3 centres, 1 for each lateral mass, and 1 for the body, ossification being completed about the 6th year. There are no muscles attached to it.

## THE NASAL BONES.

**Describe them.** They are 2 small bones forming the bridge of the nose by articulation with each other in the median line. They are convex externally, concave internally, and grooved for the external branch of the nasal nerve and for small arteries. They each *articulate* with 4 bones,—the frontal, ethmoid, superior maxillary, and the opposite nasal; are each *developed* by one centre of ossification, and have *no muscles* attached to them.

## THE SUPERIOR MAXILLARY BONES.

**Describe them.** They are 2 hollow bones, together forming the upper jaw. Each bone consists of 4 processes, and a body which possesses a large cavity, the antrum of Highmore.

**Describe the Antrum of Highmore.** It is a pyramidal cavity in the body of the bone, and opens into the middle meatus of the nose by an aperture which is very small in the recent subject, admitting only a small probe. Its walls are very thin, and are covered internally by a mucous membrane. It presents the—  
*Aperture*, partly closed by the articulation of the unciform process of the ethmoid with the ethmoidal process of the inferior turbinated; and that of the maxillary process of the palate with a fissure in the superior maxillary; also by the maxillary process of the inferior turbinated which hooks over the lower edge of the orifice.

*Posterior Dental Canals*, on the posterior wall of the cavity.

*Processes* in its floor, formed by the alveoli of the 1st and 2d molar teeth, the roots of which occasionally perforate it.

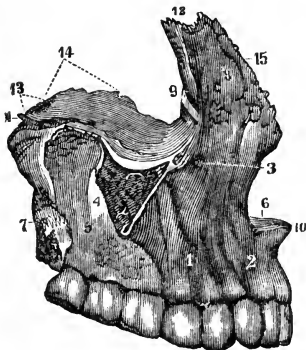
**What other points are presented by the body?** The body has 4 surfaces, the facial externally, the zygomatic posteriorly, the orbital superiorly, and an internal surface forming part of the outer wall of the nose and the cavity of the mouth. It presents the—

*Incisive Fossa*,<sup>2</sup> on the facial surface, above the incisor sockets, for the origin of the depressor alæ nasi muscle.

*Canine Fossa*,<sup>1</sup> more externally, for the levator anguli oris.

*Infraorbital Foramen*,<sup>3</sup> above the canine fossa, transmitting the infraorbital vessels and nerve, from the *infraorbital canal* in the orbital surface of the bone.

FIG. 6.



*Maxillary Tuberosity*, articulates with the tuberosity of the palate bone.

*Turbinated Crests*, inferior and superior, on the inner surface, bounding horizontal grooves which correspond to the meati of the nose.

*Vertical Grooves*, on the inner surface, one assisting to form the nasal duct, the other to form the posterior palatine canal.

*Rough Surface*, for articulation with the palate bone.

*Orbital Surface*, articulating with the lachrymal, ethmoid, and palate bones inferiorly, partly bounding the sphenomaxillary fissure exteriorly, and forming the lower margin of the orbit anteriorly.

*Infraorbital Groove*, along the orbital surface, ending in the infraorbital canal and foramen. (See *ante*.)

*Depression*, for the origin of the inferior oblique muscle of the eye.

**Describe its Processes.** They number 4, as follows.—

**MALAR PROCESS**,<sup>4</sup> is triangular, looks outwards from the body, and is rough for articulation with the malar bone.

**NASAL PROCESS**,<sup>8</sup> is thin anteriorly and serrated superiorly for articulation with the nasal bone; posteriorly it is smooth and articulates with the lachrymal. It presents the—

*Turbinated Crests*, superior and inferior, the former articulating with the middle turbinated process of the ethmoid bone.

*Outer Surface*, gives origin to the orbicularis palpebrarum and levator labii superioris alæque nasi muscles, and the tendo oculi.

*Groove* on the posterior border, helping to form the nasal duct.

**ALVEOLAR PROCESS**, forms the curved line of the teeth, and presents—

*Alveoli*, or sockets, for 8 teeth in the adult, 5 in the child.

**PALATE PROCESS**, forms part of the floor of the nasal cavity, and the roof of the mouth. It articulates with the vomer, the palate bone, and with its fellow process, and presents the—

*Incisive Foramen*, or foramen of Stenson, leading into the anterior palatine canal, for the anterior palatine vessels.

*Foramina of Scarpa*, 2, transmitting the naso-palatine nerves.

*Groove* on the under surface, for the protection of the vessels and nerves.

*Orifice* of the posterior palatine canal, at the posterior end.

*Nasal Crest*, at the articulation of the two processes with the vomer.

*Anterior Nasal Spine*, the anterior extremity of the nasal crest.

**Describe its articulations and development.** The superior maxillary articulates with 9 bones,—the frontal,<sup>12</sup> ethmoid,<sup>14</sup> vomer,<sup>13</sup> nasal,<sup>15</sup> lachrymal, malar, palate, inferior turbinated, and opposite superior maxillary.<sup>10</sup> It is developed probably by 4 centres,—1 for the facial and nasal parts, another for the orbital and malar, a 3d for the incisive, and a 4th for the palate portion.

What muscles are attached to it? There are 11, viz.—the orbicularis palpebrarum, and levator anguli oris *alæque nasi*, 2, to the *nasal process*;—the levator labii superioris, levator anguli oris, compressor naris, depressor *alæ nasi*, orbicularis oris, and inferior oblique of the eye, 6, to the *body*;—the buccinator, 1, to the *alveolar process*;—the masseter, 1, to the *malar process*;—and the external pterygoid, 1, to the *tuberosity*.

### THE LACHRYMAL BONES.

**Describe them.** They are 2 small quadrilateral-shaped bones, situated in the anterior part of the inner wall of the orbit. Each presents a—

*Groove*, on the external surface, forming part of the nasal duct.

*Ridge*, also externally, for attachment of the tensor tarsi muscle.

*Furrow*, internally, corresponding to the ridge on the external surface.

*Hamular Process*, projecting downwards to articulate with the lachrymal process of the inferior turbinated bone.

*Internal Surface*, closes the anterior ethmoidal cells.

**Describe its articulations, development, and muscles.** The lachrymal articulates with 4 bones,—the frontal, ethmoid, superior maxillary, and inferior turbinated. It is *developed* from 1 centre, and has but 1 muscle attached to it, the tensor tarsi, or Horner's muscle.

### THE MALAR BONES.

**Describe them.** The cheek bones are situated at the outer and upper part of the face, aiding to form the cavities of the orbits and the temporal and zygomatic fossæ. Each presents an—

*External Surface*, convex, for attachment of the zygomatic muscles.

*Foramen*, externally, for the malar branch of the temporo-malar nerve.

*Foramen*,<sup>c</sup> internally, for the temporal branch of the same nerve.

*Frontal Process*,<sup>a</sup> articulates with the external angular process of the frontal.

*Orbital Process*,<sup>b</sup> projecting backwards, forming part of the floor and outer wall of the orbit, as well as part of the temporal fossa, and bounds the spheno-maxillary fissure anteriorly.

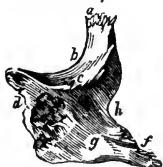FIG. 7. *Zygomatic Process*,<sup>f</sup> projecting backwards to articulate with the zygomatic process of the temporal bone by a serrated edge.

*Upper Border*,<sup>b</sup> forms the outer and inferior margin of the orbit.

*Lower Border*, thick and rough, for the origin of the masseter muscle.

*Anterior Border*,<sup>d</sup> articulates with the superior maxillary bone.

*Posterior Border*, terminates the temporal fossa below.



**Name its articulations, centres, and muscles.** The malar articulates with 4 bones,—the frontal, sphenoid, temporal, and superior maxillary. It is developed by one centre of ossification, and has 5 muscles attached to it,—the levator labii superioris, zygomaticus major and minor, masseter and temporal.

### THE PALATE BONES.

**Describe them.** They are 2 irregularly-shaped bones, situated posteriorly in the nares. Each bone assists in forming the floor and outer wall of the nose, the roof of the mouth, the floor of the orbit, the inner wall of the antrum, the zygomatic, speno-maxillary, and pterygoid fossæ, and presents the following points.—

**HORIZONTAL PLATE,** *a* completes the nasal floor and hard palate; has a—

*Ridge*, on the inferior surface, for the tensor palati aponeurosis.

*Groove*, assisting to form the posterior palatine canal.

*Foramina*, transmitting the anterior and posterior palatine nerves.

*Anterior Border*, is serrated, and joins the superior maxillary bones.

*Posterior Border*, is free and concave, for the attachment of the soft palate.

*Inner Border,* *d* is thick, and articulates with its fellow, forming a groove for the reception of the vomer.

Its posterior extremity is the—

*Posterior Nasal Spine*, for the origin of the azygos uvulæ muscle.

**VERTICAL PLATE,** *b* a broad and thick lamella, presents the following:—

*Superior Turbinate Crest*, on the inner surface. Below it is the—

*Inferior Turbinate Crest,* *g* dividing the middle meatus of the nose from the inferior, and articulating with the inferior turbinated bone.

*Posterior Border*, articulates with the pterygoid process of the sphenoid.

*Groove*, on the external surface, helping to form the posterior palatine canal.

*Two Smooth Surfaces*, externally, one forming the inner wall of the zygomatic fossa; the other, part of the inner wall of the antrum.

*Two Rough Surfaces*, also externally, one for articulation with the superior maxillary; the other with the pterygoid process of the sphenoid.

*Deep Notch*, which by articulation with the sphenoid bone, forms the *spheno-palatine foramen,* *h* for the spheno-palatine nerves.

**PTERYGOID PROCESS,** *c* is wedged into the notch between the plates of the pterygoid process of the sphenoid, with which it articulates laterally. In it are the—

*Palatine Foramina*, for the external and posterior palatine nerves.

*Posterior Surface*, aids in forming the pterygoid fossa.

FIG. 8.



**ORBITAL PROCESS,**<sup>i</sup> triangular in shape, large and hollow. It has—

*Three Articular Surfaces*, for the sup. maxillary, sphenoid, and ethmoid.

*Two Free Surfaces*, the orbital forming part of the floor of the orbit, the external aiding to form the zygomatic fossa.

*Rounded Border*, forms a part of the speno-maxillary fissure.

**SPHENOIDAL PROCESS,**<sup>j</sup> projects backwards, articulates superiorly with the body of the sphenoid, and externally with the pterygoid process of the sphenoid. On its upper surface is a—

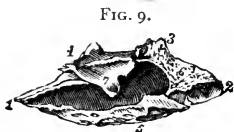*Groove*, which assists in forming the pterygo-palatine canal.

*Inner Surface*, forms part of the outer wall of the nasal fossa.

Describe its articulations, development, and muscles. The palate articulates with 6 bones,—the sphenoid, ethmoid, vomer, superior maxillary, inferior turbinated, and its fellow palate bone. It is developed by one centre at the junction of the two plates. There are 5 muscles attached to it,—the azygos uvulæ, internal and external pterygoids, superior constrictor, and tensor palati.

### THE INFERIOR TURBINATED BONES.

Describe them. They are 2 thin curved osseous plates situated in the nasal fossæ, their convex surfaces presenting inwardly. Each bone is attached above to the inferior turbinated crests of the superior maxillary and palate bones, and presents the following, viz.—



*Lachrymal Process,*<sup>3</sup> aiding to form the nasal duct, by articulation with the lachrymal and superior maxillary bones.

*Ethmoidal Process,*<sup>1</sup> articulating with the unci-form process of the ethmoid, thus helping to partially close the aperture of the antrum.

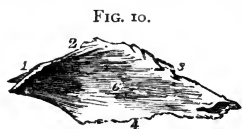*Maxillary Process,*<sup>4</sup> also helps to partially close the aperture of the antrum, by hooking<sup>7</sup> over the lower edge of that orifice.

*Free Border,*<sup>5</sup> below, coming to about  $\frac{1}{2}$  inch above the floor of the nose.

Name its articulations, centres, and muscles. The inferior turbinated articulates with 4 bones, the ethmoid, lachrymal, palate, and superior maxillary. It is developed by one centre, and has no muscles attached to it.

### THE VOMER.

Describe it. The vomer (plough-share) forms the postero-inferior part of the nasal septum, but is usually bent to one side. Its—



*Superior Border,*<sup>1 2</sup> has a groove and two alæ or wings, for articulation with the rostrum and vaginal processes of the sphenoid bone.



*Anterior Border*,<sup>3</sup> is grooved for the ethmoidal plate and the nasal cartilage.

*Inferior Border*,<sup>4</sup> the longest, articulates with the nasal crest of the superior maxillary and palate bones.

*Posterior Border*, is free and presents towards the pharynx.

*Naso-palatine Grooves*, laterally, for the naso-palatine nerves.

*Furrows*, on the lateral surfaces,<sup>6</sup> for vessels and nerve-filaments.

**Name its articulations, centres, and muscles.** The vomer *articulates* with 6 bones,—the sphenoid, ethmoid, 2 superior maxillary, and 2 palate bones. It is *developed* by one centre, which appears about the 6th foetal week in cartilage between two laminae which coalesce after puberty. It has *no muscles* attached to it.

### THE INFERIOR MAXILLARY BONE.

**Describe its general characteristics.** The inferior maxillary bone forms the lower jaw, receives the inferior teeth, and is the second bone of the body in which ossification appears, the clavicle being the first. It consists of a body and two rami.

**Describe the Body of the bone.** It is shaped somewhat like a horse-shoe, and presents for examination the following: viz.—

*Alveolar Portion*, above the oblique line, containing on its upper border *alveoli* for 16 teeth in the adult, for 10 in the child.

*Symphysis*, a vertical ridge on the median line, marking the junction of the two symmetrical portions of which the bone originally consisted.

*Mental Process*, a prominent triangular eminence, forming the chin.

Externally on each side from the symphysis backwards, are the—

*Incisive Fossa*, above the chin, for the origin of the levator menti.

*Mental Foramen*, below the 2d bicuspid alveolus, transmitting the mental artery and nerve.

*External Oblique Line*, for the origins of the depressor labii inferioris and depressor anguli oris muscles from its anterior half.

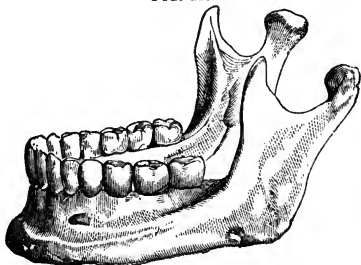
*Groove*, near the angle, for the facial artery.

Internally, on each side from the median depression backwards, are the—

*Genial Tubercles*, the superior for the genio-hyo-glossus muscle; the inferior for the genio-hyoid.

*Mylo-hyoid Ridge*, obliquely backwards, for the mylo-hyoid muscle.

FIG. 11.



*Sublingual Fossa*, near the genial tubercles, for the sublingual gland.

*Fossa*, below the sublingual, for the anterior belly of the digastric muscle.

*Submaxillary Fossa*, below the ridge, for the submaxillary gland.

**Describe the Rami of the Inferior Maxillary.** The rami, or ascending portions of the bone, are 2 in number, and each present the—

*Coronoid Process*, anteriorly, for the insertion of the temporal muscle.

*Condylloid Process*, posteriorly. Its condyle articulates with the glenoid fossa of the temporal bone, its *neck* receives the insertion of the external pterygoid muscle, its *tubercle* has attached to it the external lateral ligament of the lower jaw.

*Sigmoid Notch*, a deep depression separating the above-named processes from each other, and crossed by the masseteric vessels and nerve.

*Groove*, on the coronoid process internally, and prolonged downwards upon the body, for the attachment of the buccinator muscle.

*Ridges*, on the external surface, for the insertion of the masseter.

*Spine*, a projection on the internal surface, for the attachment of the internal lateral ligament of the jaw.

*Inferior Dental Canal*, opening behind the spine, lies within the ramus and body of the bone for the inferior dental vessels and nerve. It communicates with each alveolus and with the mental foramen.

*Mylo-hyoid Groove*, below the spine, for the mylo-hyoid vessels and nerve.

*Rough Surface*, behind the groove, for the internal pterygoid muscle.

*Angle of the Jaw*, at the junction of the posterior body of the ramus with the inferior border of the body, for the insertion of the masseter and internal pterygoid muscles, and the stylo-maxillary ligament.

**Describe the Articulations and Development of the Inferior Maxillary bone.** It articulates with one pair of bones,—the temporal. It is the earliest formed bone in the body except the clavicle, and is probably *developed* by 2 centres, one for each lateral half, the two halves coalescing at the symphysis about the 1st year of age. In *adult life* the ramus arises almost vertically from the body, and the dental canal lies about the middle of the body. In *old age* the ramus extends obliquely backwards, the angle becoming very obtuse; and the alveolar portion being absorbed, the dental canal is near the superior border.

**What Muscles are attached to the Inferior Maxillary?** They number 15 pairs,—the masseter, internal and external pterygoids and temporal, 4, to the *ramus*;—the genio-hyo-glossus, genio-hyoid, mylo-nyoid, digastric, and superior constrictor, 5, to the internal surface of the *body*;—the depressor labii inferioris, depressor anguli oris, levator menti, orbicularis oris, platysma myoides, and buccinator, 6, to the external surface of the *body*.

## THE ORBITS.

**Describe the Orbital Cavities.** The orbits are 2 conoidal cavities, situated between the forehead and the face, their bases outwards, their apices pointing backwards, the lines of axial prolongation meeting at the sella turcica of the sphenoid bone. They contain the organs of vision with their appendages, and are each formed by 7 bones,—the frontal,<sup>1</sup> ethmoid,<sup>2</sup> sphenoid,<sup>3</sup> 4 5 lachrymal,<sup>6</sup> superior maxillary,<sup>7</sup> palate,<sup>8</sup> and malar,<sup>9</sup> of which the first three are common to both orbits. Each orbit communicates with 1 cavity and 4 fossæ, as follows, viz.—

*Cavity* of the cranium, by the optic foramen<sup>11</sup> and sphenoidal fissure.<sup>10</sup>

*Fossæ* (4)—the nasal, temporal, zygomatic, and sphe-no-maxillary,—by the nasal duct<sup>12</sup> and the sphe-no-maxillary fissure.<sup>13</sup>

**What Foramina communicate with each orbit?** Nine,—the optic foramen,<sup>11</sup> sphenoidal fissure,<sup>10</sup> anterior<sup>21</sup> and posterior<sup>22</sup> ethmoidal foramina, supraorbital,<sup>14</sup> infraorbital,<sup>15</sup> and malar foramina,<sup>16</sup> the nasal duct,<sup>12</sup> and the sphe-no-maxillary fissure.<sup>13</sup>

**Describe the Roof of the Orbit.** Formed by the orbital plate of the frontal bone anteriorly,<sup>1</sup> and the lesser wing of the sphenoid<sup>4</sup> posteriorly, it is concave, and presents the—

*Lachrymal Fossa*,<sup>17</sup> at its outer angle, for the lachrymal gland.

*Depression*,<sup>18</sup> at the inner angle, for the pulley of the superior oblique.

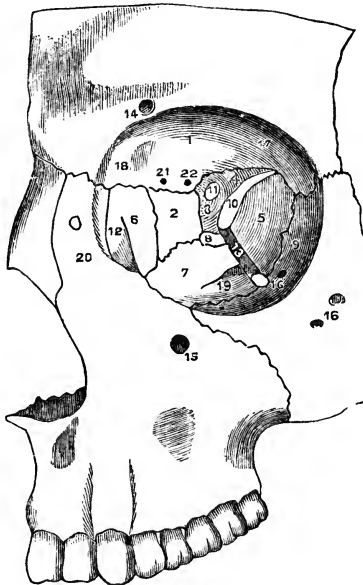**Describe the Floor of the Orbit.** Formed by the orbital surface of the superior maxillary bone,<sup>7</sup> and the orbital process of the malar<sup>9</sup> and palate bones,<sup>8</sup> it is nearly flat and presents the—

*Palato-maxillary Suture* posteriorly.

*Infraorbital Canal*, and a *Depression* for the superior oblique muscle of the eye, anteriorly.

*Infraorbital Groove*,<sup>19</sup> posteriorly.

FIG. 12.



**Describe the Inner Wall of the Orbit.** Formed by the nasal process of the superior maxillary bone,<sup>20</sup> the lachrymal,<sup>6</sup> the os planum of the ethmoid,<sup>2</sup> and the body of the sphenoid,<sup>3</sup> it presents—

- A Groove*, for the lachrymal sac, and the *Lachrymal Crest*, anteriorly.  
*2 Sutures*,—the ethmo-lachrymal, and the ethmo-sphenoidal.

**Describe the Outer Wall of the Orbit.** Formed by the orbital process of the malar bone,<sup>9</sup> and the greater wing of the sphenoid,<sup>5</sup> it presents the *Orifices*<sup>16</sup> of the malar canals, and the *Spheno-malar Suture*.

**Describe the Angles of the Orbit.** They present the following points.

**IN THE SUPERIOR EXTERNAL ANGLE.**

*Sphenoidal Fissure*,<sup>10</sup> or foramen lacerum anterius, transmits the 3d, 4th, ophthalmic division of the 5th, and the 6th nerves, the ophthalmic vein, branches of the lachrymal and middle meningeal arteries, filaments of the sympathetic nerve, and a process of the dura mater.

*Articulations*,—the fronto-malar, and fronto-sphenoidal.

**IN THE SUPERIOR INTERNAL ANGLE.**

*Suture*,—the lachrymo-ethmo-frontal, in which are the following foramina.  
*Anterior Ethmoidal Foramen*,<sup>21</sup> transmitting the anterior ethmoidal artery and the nasal nerve.

*Posterior Ethmoidal Foramen*,<sup>22</sup> transmitting the posterior ethmoidal artery and vein.

**IN THE INFERIOR EXTERNAL ANGLE.**

*Spheno-maxillary Fissure*<sup>13</sup> (described under the Zygomatic Fossa).

**IN THE INFERIOR INTERNAL ANGLE.**

*A Suture*, the ethmo-maxillo-palato-lachrymal.

**What other points are connected with the Orbit?** Two, the supra-orbital notch, and the optic foramen, as follows, viz.—

*Supraorbital Notch or Foramen*,<sup>14</sup> at the junction of the inner and middle thirds of the upper circumference, transmitting the supraorbital artery, veins, and nerve. A line prolonged from this notch through the interval between the bicuspid teeth of either jaw, will cross both the infraorbital and mental foramina, and the canine fossa of the superior maxillary bone.

*Optic Foramen*,<sup>11</sup> at the apex, is formed by the 2 roots of the lesser wing of the sphenoid, and transmits the optic nerve and the ophthalmic artery. From around its margin arises a tendinous ring, the common origin of the 4 recti muscles of the eye.

**What Muscles arise within the Orbit?** The 4 recti and 2 oblique of the eye, the levator palpebræ, and the tensor tarsi (8 in all).

## THE FOSSÆ.

**Describe the Nasal Fossæ.** Together they form the cavity of the nose, being separated from each other by the *Septum Nasi*.<sup>11</sup> They open in front by the anterior nares, behind by the posterior nares; and extend from the palate processes of the superior maxillary and palate bones,<sup>17</sup> upwards to the base of the cranium. They are formed by 14 bones,—the ethmoid, sphenoid, frontal, vomer, 2 nasal, 2 superior maxillary, 2 lachrymal, 2 palate, and 2 inferior turbinated.

**Describe the Septum Nasi.**<sup>11</sup> It forms the inner wall of each nasal fossa, and is formed chiefly by the perpendicular plate of the ethmoid bone, the vomer, and the triangular cartilage of the septum; to a less extent by 5 other bones,—the rostrum of the sphenoid, the nasal spine of the frontal, and the crests of the nasal, palate, and superior maxillary bones.

**Describe the points presented by each Nasal Fossa.** They are—

## ON THE ROOF.

*Openings*, posteriorly, into the sphenoidal sinuses.

*Olfactory Foramina*, and the *Nasal Slit*, in the cribriform plate of the ethmoid bone.

## ON THE FLOOR.

*Orifice*, of the anterior palatine canal.

*Suture*, between the bones forming the hard palate.

*Nasal Spines*, anterior and posterior, and the *Ridge* connecting them.

## ON THE OUTER WALL, from above downwards.

*Superior Turbinated* process of the ethmoid.

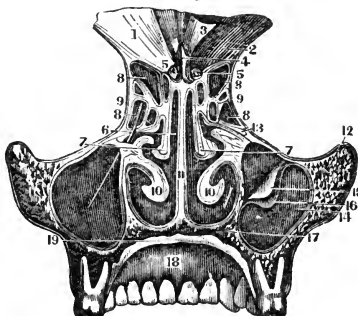
*Superior Meatus* of the nose, into which open 3 orifices,—those of the posterior ethmoidal and the sphenoidal sinuses, and the speno-palatine foramen.

*Middle Turbinated*<sup>7</sup> process of the ethmoid.

*Middle Meatus* of the nose, into which open 2 orifices,—those of the antrum<sup>14</sup> and infundibulum,—the latter draining the anterior ethmoidal cells,<sup>8</sup> and the frontal sinus.

*Inferior Turbinated Bone*,<sup>10</sup> below which is the—

FIG. 13.



*Inferior Meatus* of the nose, the largest; into it open 2 orifices,—those of the lachrymal, and anterior palatine canals. To these may be added the anterior and posterior nares.

**Describe the Temporal Fossa.** Situated on each side of the cranium, it is shallow above and behind, but deep in front and below; and is formed by parts of 5 bones,—the frontal, sphenoid, temporal, parietal, and malar. It is bounded above and behind by the temporal ridge, in front by the malar frontal and sphenoid bones, and below by the zygoma and the pterygoid ridge on the greater wing of the sphenoid. It is traversed by 6 sutures,—the speno-malar, speno-frontal, speno-parietal, speno-temporal, fronto-parietal, and temporo-parietal. It opens below into the zygomatic fossa; and lodges the temporal muscle, and the deep temporal vessels.

**Describe the Zygomatic Fossa.** Extending downwards from the temporal fossa, it is thus bounded,—

*In front*, by the tuberosity of the superior maxillary bone.

*Externally*, by the zygoma, and the ramus of the inf. maxillary.

*Internally*, by the external plate of the pterygoid process.

*Above*, by the temporal fossa, the squamous portion of the temporal bone, and the greater wing of the sphenoid.

*Below*, by the alveolar border of the inferior maxillary bone.

**What Fissures open into the Zygomatic Fossa.** Two, the—

*Spheno-maxillary Fissure*, between the greater wing of the sphenoid externally, and the superior maxillary and palate bones internally. It connects the orbit with the zygomatic, temporal, and speno-maxillary fossæ; and transmits the infraorbital artery, the superior maxillary nerve and its orbital branches, and the ascending branches of Meckel's ganglion.

*Pterygo-maxillary Fissure*, between the tuberosity of the superior maxillary bone and the pterygoid process of the sphenoid. It transmits branches of the internal maxillary artery, and connects the zygomatic fossa with the speno-maxillary.

**Describe the Spheno-Maxillary Fossa.** It is a triangular cavity between the pterygoid process of the sphenoid bone and the tuberosity of the superior maxillary, and is situated at the junction of the speno-maxillary, pterygo-maxillary, and sphenoidal fissures. Into it open—

3 *Fossæ*,—the orbital, zygomatic, and nasal.

2 *Cavities*,—the cranial, and buccal.

5 *Foramina*,—the Vidian and pterygo-palatine canals, and the foramen rotundum, posteriorly; the speno-palatine foramen on the inner wall; and the posterior palatine canal inferiorly,—occasionally also the accessory palatine canals.

## THE SUTURES AND FONTANELLES.

**Name the Sutures of the skull.** There are 17.

*At the Vertex* of the skull are 5, the—

Sagittal, or interparietal.

2 Coronal, or fronto-parietal. 2 Lambdoid, or occipito-parietal.

*At the Sides* of the skull are 4, the—

2 Spheno-parietal. 2 Temporo-parietal.

*At the Base* of the skull are 5, the—

2 Temporo-occipital. Basilar, in the central line of the base.

2 Temporo-sphenoidal.

*In the Mesial line*, besides the sagittal and basilar, are 3, the—

Spheno-ethmoidal. Spheno-frontal. Ethmo-frontal.

**Describe the Facial Sutures.** The most important are the following, but the sutures of the face are very numerous.

*Zygomatic Suture*, at the temporo-malar articulation.

*Transverse Suture*, extending from one external angular process of the frontal bone across to the other, and connecting that bone with the malar, sphenoid, ethmoid, lachrymal, superior maxillary, and nasal bones.

*Symphysis of the Chin*, the site of a foetal suture.

**How are the Sutures formed?** By dentations of the external tables interdigitating with each other, the adjacent edges of the internal tables lying in unjoined proximity. The sutures are not formed until a long time after the formation of the skull, probably to permit of the marginal growth of the bones.

**What are the Fontanelles?** They are 6 membranous intervals in the infant's skull, corresponding in situation with the angles of the two parietal bones. They are as follows, viz.—

*Anterior*, at the junction of the sagittal and coronal intervals.

*Posterior*, at the junction of the sagittal and lambdoid intervals.

*Lateral Fontanelles*, 4, two at the anterior inferior angles, and two at the posterior inferior angles of the parietal bones.

**Describe the Wormian Bones.** They are supernumerary small pieces of bone, irregularly shaped, and developed by special centres in unclosed portions of the cranial sutures and fontanelles, being more frequent in the lambdoid suture. They are also called "*ossa triquetra*" from their triangular form.

**Describe the Hyoid Bone.** It is shaped like a horse-shoe, has no articulation with the skeleton, but supports the tongue. It consists of a *Body*, two greater, and two lesser *Cornua* or horns. On the body is a *Crucial Ridge*, with a *Tubercle* at the centre. It is *developed* by 5 centres,—one for the body and one for each horn. Attached to it are 10 muscles, 3 ligaments, and 1 membrane, as follows, viz.—

*To the Body*,—the genio-, mylo-, stylo-, sterno-, thyro-, omo-hyoid, the genio-hyo-glossus, and the hyo-glossus muscles; also the pulley of the digastric, the hyo-epiglottic ligament, and the thyro-hyoid membrane.

*To the Greater Cornu*,—the hyo-glossus, middle constrictor muscles, and part of the thyro-hyoid;—also the thyro-hyoid ligament.

*To the Lesser Cornu*,—the stylo-hyoid ligament.

## TABLE OF THE FORAMINA AT THE BASE OF THE SKULL,

*with the various structures transmitted by each.*

**Anterior Fossa** contains 1 single foramen and 5 in pairs, viz.—

*Foramen Cæcum*,—lodges a fold of dura mater, and transmits a vein to the longitudinal sinus from the nose, sometimes one from the frontal sinus.

*Ethmoidal Fissure*,—the nasal nerve, and the anterior ethmoidal artery.

*Olfactory*,—olfactory nerves, and nasal branches of the ethmoidal arteries.

*Anterior Ethmoidal*,—anterior ethmoidal artery and the nasal nerve.

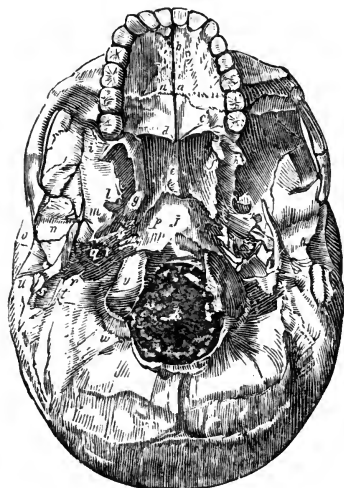
*Posterior Ethmoidal*,—posterior ethmoidal artery and vein.

*Optic Foramen*,—optic nerve and ophthalmic artery.

**Middle Fossæ** contain 8 pairs, viz.—

*Foramen Lacerum Anterius*, or *Sphenoidal Fissure*,<sup>p</sup>—the 3d, 4th, ophthalmic division of the 5th, and the 6th cranial nerves, and filaments of the sympathetic; ophthalmic vein, a branch of the lachrymal artery, orbital branches of the middle meningeal artery, and a process of dura mater.

FIG. 14.



*Foramen Rotundum*,—superior maxillary division of the 5th cranial nerve.

*Foramen Vesalii*,—a small vein. This foramen is often absent.

*Foramen Ovale*,<sup>l</sup>—inferior maxillary division of the 5th nerve, lesser petrosal nerve, and the small meningeal branch of the internal maxillary artery.

*Foramen Spinosum*,<sup>m</sup>—middle meningeal artery, meningeal veins, and sympathetic filaments from the cavernous plexus.



*Foramen Lacerum Medium*,<sup>g</sup>—internal carotid artery, carotid plexus, large petrosal nerve, and a branch from the ascending pharyngeal artery.

*Small Foramen*,—lesser petrosal nerve.

*Hiatus Fallopii*,—large petrosal nerve, branch of middle meningeal artery.

**Posterior Fossa** contains 6 pairs and 1 single, viz.—

*Meatus Auditorius Internus*,—facial and auditory nerves, auditory artery.

*Aqueductus Vestibuli*,—small artery and vein, process of dura mater.

*Foramen Lacerum Posterius*,<sup>r</sup>—glosso-pharyngeal, pneumo-gastric, and spinal accessory nerves, internal jugular vein, meningeal branches of the ascending pharyngeal and occipital arteries.

*Mastoid Foramen* (often absent),—small vein, occasionally the mastoid artery.

*Anterior Condylloid Foramen*,—hypoglossal nerve, meningeal branch from the ascending pharyngeal artery.

*Posterior Condylloid Foramen*<sup>w</sup> (often absent), posterior condylloid vein.

*Foramen Magnum*,<sup>k</sup>—medulla oblongata and its membranes, the vertebral arteries, and the spinal accessory nerves.

**Externally**, at the base of the skull are 10 pairs, viz.—

*Opening of the Eustachian Tube*,—air to the middle ear.

*Opening of Tensor Tympani Canal*,—the tensor tympani muscle.

*Orifice of the Vidian Canal*,—the Vidian nerve, and vessels.

*Glasserian Fissure*,<sup>n</sup>—laxator tympani muscle, tympanic artery, processus gracilis of the malleus.

*Orifice of the Canal of Hugier*,—chorda tympani nerve.

*Foramen for Jacobson's Nerve*,—tympanic branch of glosso-pharyngeal.

*Foramen for Arnold's Nerve*,—auricular branch of pneumogastric.

*Opening of the Aqueductus Cochleæ*,—vein to the cochlea.

*Stylo-mastoid Foramen*,<sup>t</sup>—facial nerve, stylo-mastoid artery.

*Auricular Fissure*,—exit of Arnold's nerve.

**Face** presents 3 pairs, viz.—

*Supraorbital Foramen or Notch*,—supraorbital artery, vein, and nerve.

*Infraorbital Foramen*,—infraorbital artery and nerve.

*Mental Foramen*,—mental artery and nerve.

**Palate** presents, on each side at least 6 pairs, viz.—

*Incisive Foramina*<sup>b</sup> (one or two),—nerves and vessels to the incisor teeth.

*Anterior Palatine*,—anterior palatine vessels, naso-palatine nerves.

*Posterior Palatine*,—posterior palatine vessels, anterior palatine nerve.

*Accessory Palatine Foramina* (one or two),—posterior palatine nerves.

*Pterygo-palatine Foramen*,—pterygo-palatine vessels.

## THE BONES OF THE TRUNK.

### THE VERTEBRAL COLUMN.

**What Characteristics are Common to the Vertebrae?** Each vertebra consists of a body and an arch, the latter being formed by 2 pedicles and 2 laminae, which support 7 processes.

*Body*<sup>6</sup> is thick and spongy, convex in front<sup>7</sup> from side to side, concave vertically, and on the upper and lower surfaces, which are surrounded by a bony rim. Anteriorly are small foramina for nutrient vessels, posteriorly a large foramen for the exit of the venæ basis vertebrarum.

*Pedicles*, project backwards from the body, inclining outwards. They are notched above and below, thus forming, with the adjacent notches, the *Intervertebral Foramina* for the entrance of vessels and the exit of the spinal nerves.

*Laminae*,<sup>2</sup> are 2 broad plates, meeting in the spinous process behind, and rough on their upper and lower borders for the attachment of the ligamentum subflava.

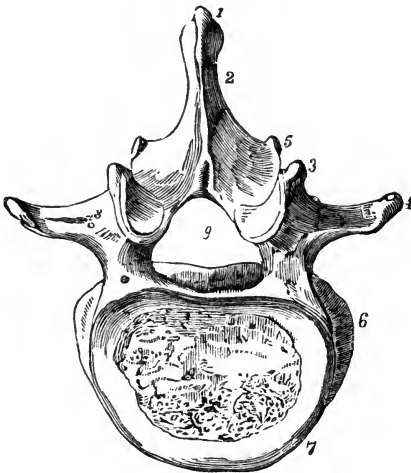
*Transverse Processes*,<sup>4</sup> one on each side, projecting outwards.

*Articular Processes*, two on each side, superior<sup>3</sup> and inferior,<sup>5</sup> project from the junction of the laminae and pedicles, and articulating above and below with the articular processes of the adjacent vertebrae. Their superior facets look upwards in the cervical region, outwards in the dorsal, and inwards in the lumbar.

*Spinous Process*,<sup>1</sup> projects backwards from the junction of the laminae with each other, sometimes very obliquely.

*Spinal Foramen*,<sup>9</sup> is the space enclosed by the body, pedicles, and laminae; and which, when the vertebrae are articulated, forms part of the spinal canal.

FIG. 15.



**How are the Vertebrae distinguished?** As cervical (7), dorsal (12), and lumbar (5). Each of these divisions has several peculiar features, but their especial characteristics are as follows.

*The Cervical Vertebrae* are pierced at the bases of their transverse processes by the *vertebral foramina*, which transmit the vertebral artery, vein, and plexus.

*The Dorsal Vertebrae* have facets and demifacets on their bodies, for articulation with the heads of the ribs.

*The Lumbar Vertebrae* are marked by the absence of the foramina and facets which distinguish the other two classes.

**What are the Peculiar Vertebrae?** They are 9 in number,—the atlas or 1st cervical, the axis or 2d cervical, the vertebra prominens or 7th cervical, the 1st, 9th, 10th, 11th, and 12th dorsal, and the 5th lumbar.

*The Atlas* is a bony ring supporting the head. A bony arch takes the place of a body, and its spinous process is a mere tubercle. Its *Lateral Masses* form its chief bulk, supporting large *Articular Processes* which all look inwards, the superior articulating with the condyles of the occipital bone.

*The Axis* is marked by its *Odontoid Process* projecting upwards from the body into the anterior part of the spinal foramen of the atlas, where it articulates with the anterior arch, and receives the occipito-axis and the check ligaments.

*The Vertebra Prominens* has a long and prominent spinous process which ends in a tubercle for the ligamentum nuchæ.

*The Dorsal Vertebrae.* The 1st has one facet and a demifacet. The 9th has a demifacet only. The 10th has but one facet on the body and one on the transverse process. The 11th and 12th have each but one facet on the body, and none on the transverse processes. The 12th resembles a lumbar vertebra in size and shape.

*The 5th Lumbar* is much deeper in front than behind; its spinous process is small, but its transverse processes are large and thick, and point slightly upwards.

**What important Relations have Certain Vertebrae?**

*The 3d Cervical* corresponds to—the bifurcation of the common carotid artery, and the superior cervical ganglion.

*The 5th Cervical*, to—the junctions of the larynx with the trachea, and the pharynx with the œsophagus, and the middle cervical ganglion of the sympathetic.

*The 2d Lumbar*, to—the junction of the duodenum with the jejunum, the commencement of the thoracic duct and the portal vein, the origin of the superior mesenteric artery, the lower margin of the pancreas, the opening of the ductus communis cholédochus, the lower end of the spinal cord, and the crura of the diaphragm.

[The false vertebrae are described as bones of the pelvis.]

## THE THORAX.

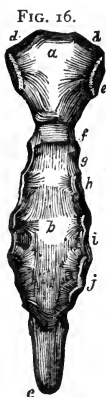**What is the Thorax?** An osseo-cartilaginous cage formed by the bodies of the dorsal vertebræ posteriorly, the ribs and costal cartilages laterally, and the sternum in front. Its shape is conical, the axis inclined forwards, the base below and closed by the diaphragm.

**What Structures pass through its Apex?** The trachea, œsophagus, large vessels of the neck, pneumogastric, phrenic and sympathetic nerves, thoracic duct, and in inspiration the apex of the lung.

**What Structures are contained in its Cavity?** The trachea, bronchi and lungs, the heart and great vessels, internal mammary arteries, azygos and bronchial veins, pneumogastric, phrenic, and splanchnic nerves, œsophagus, thoracic duct, lymphatic vessels, and glands.

## THE STERNUM.

**Describe it.** The sternum, or breast-bone, consists of 3 parts,—the manubrium,<sup>a</sup> or handle; the gladiolus,<sup>b</sup> or sword; and the ensiform or xiphoid appendix.<sup>c</sup> It presents the—



*Interclavicular Notch*, on its superior border.

*Manubrium*,<sup>a</sup> articulates with the clavicle,<sup>d</sup> 1st costal cartilage,<sup>e</sup> and a part of the 2d.<sup>f</sup>

*Gladiolus*, articulates with the costal cartilages from the 3d to the 6th inclusive, and partly with the 2d and 7th.

*Ensiform Appendix* (the tip), articulates with the cartilage of the false ribs, and in part with the 7th costal cartilage.<sup>j</sup>

**Describe its development and muscles.** The sternum is *developed* by 6 centres, 1 each for the manubrium and ensiform appendix, and 4 for the gladiolus. The *muscles* attached to it are 9 pairs and one single muscle,—the sterno-cleido-mastoid, sterno-hyoid, and sterno-thyroid, 3, to its upper part;—the rectus abdominis, external and internal oblique, transversalis, and the diaphragm, 5, to its lower part;—the pectoralis major, 1, anteriorly;—and the triangularis sterni, 1, posteriorly.

## THE RIBS.

**Describe them.** There are 12 ribs on each side, of which 7 are “true ribs,” being each connected to the sternum by a separate cartilage;—and 5 are “false ribs.” Three of the latter are connected by their cartilages to the cartilage of the 7th rib, while two are called “floating ribs,” having each one extremity free.

**What are the Characteristics Common to most of the Ribs?** They each consist of a head, neck, and shaft, and present the following points, viz.—

*Head,* *a* is divided by a ridge into 2 facets, which articulate with the facets on the bodies of the dorsal vertebræ; the ridge giving attachment to the interarticular ligament.

*Neck,* about an inch long, having attached to its upper border the anterior costo-transverse ligament, to its posterior surface the middle costo-transverse ligament; its anterior surface is smooth.

*Tuberosity,* *b*

at the junction of the neck with the shaft, has a facet for articulation with the transverse process of the next lower

vertebra, and a rough surface for the posterior costo-transverse ligament.

*Shaft,* twisted on itself, is concave internally, convex externally, its upper border round and smooth, its lower border grooved *d* for the intercostal vessels and nerves. At its external extremity *c* is an oval depression for the insertion of the costal cartilage.

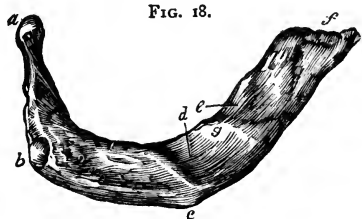
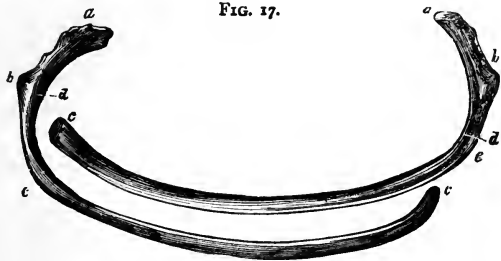
*Angle,* *e* just in front of the tuberosity, is marked by a rough line, to which are attached the muscles of the deep layer of the back.

**How are they developed?** Each rib has 3 centres, one each for the head, shaft, and tuberosity. The last 2 ribs, having no tuberosity, are developed each by 2 centres.

**Describe the Peculiar Ribs.** They are the 1st, 2d, 10th, 11th, and 12th. They respectively present the following peculiarities, viz.—

*1st Rib,* is broad, short, not twisted, has no angle, only one facet on the head; *a* but on its upper surface are seen *two grooves* for the subclavian artery *d* and vein, *e* and between them a *tubercle g* for the scalenus anticus muscle.

*2d Rib,* is not twisted, its tuberosity and angle are very close together, and its upper surface presents rough surfaces for the serratus magnus and scalenus posticus muscles.



*10th Rib*, has but one facet on its head.

*11th Rib*, has no neck, no tuberosity, and but one facet on its head.

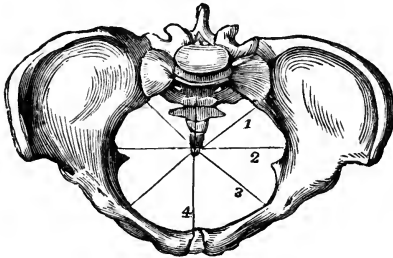
*12th Rib*, has neither neck, angle, tuberosity nor groove, and but one facet

## THE PELVIS.

**Describe the Pelvis.** It is formed by the sacrum, coccyx, and two ossa innominata, and is divided into,—the *false pelvis*, comprising the upper and expanded portion,—and the *true pelvis*, below the ilio-pectineal line. The false pelvis corresponds to the iliac fossæ, and is marked by its walls being deficient anteriorly between the iliac borders, and posteriorly between the sacrum and the posterior iliac spines. The true pelvis has a—

*Brim*, or inlet, bounded in front by the crest and spine of the pubes, behind by the promontory of the sacrum, laterally by the ilio-pectineal line. Its axis corresponds to a line from the umbilicus to the middle of the coccyx. Its average diameters in the female are,—4 inches antero-posteriorly,<sup>1</sup> over 5 inches transversely,<sup>2</sup> under 5 inches obliquely.<sup>3</sup> In the male each of these measurements is about  $\frac{1}{2}$  an inch less.

FIG. 19.



*Cavity*, is a short curved canal, connecting the brim with the outlet. In front its depth is about  $1\frac{3}{4}$  inch, posteriorly 4 to  $4\frac{1}{2}$  inches in the female,  $4\frac{1}{2}$  to  $5\frac{1}{2}$  inches in the male. Its diameter is about  $4\frac{3}{4}$  inches in the female,  $4\frac{1}{2}$  inches in the male, all around.

*Outlet*, is bounded by the pubic arch above, the tip of the coccyx behind, and the tuberosities of the ischii laterally. Its axis, if prolonged, would touch the promontory of the sacrum. Its diameters in the female are each about  $4\frac{1}{4}$  inches, in the male about  $3\frac{1}{2}$  inches.

**State the chief differences between the male and female pelvises.** The *male pelvis* is marked by strength of the bones, prominence of the muscular impressions, a deep and narrow cavity, and large obturator foramina. The *female pelvis* has lighter bones, broader iliac fossæ, the spines being further apart, greater diameters at every point, the sacrum less curved, and the pubic arch wider.

**Describe the Sacrum.** The "sacred bone" is triangular, curved, with its convexity backwards, and is situated base upwards between the ossa innominata, forming with the coccyx the posterior wall of the pelvis. The bone is formed by the coalescence of 5 vertebræ, and presents the following points, viz—

4 *Ridges*,<sup>4</sup> transversely across both surfaces, mark the union of its original segments.

8 *Anterior Sacral Foramina*, for the anterior sacral nerves.

8 *Grooves*,<sup>5</sup> shallow and broad, for the aforesaid nerves.

*Promontory*, at its junction with the last lumbar vertebræ.

8 *Posterior Sacral Foramina*, for the posterior sacral nerves.

*Tubercles*, representing the spinous processes of the segments.

*Groove*, posteriorly, on each side of the spinous tubercles.

2 *Cornua*, at the posterior inferior portion of the bone.

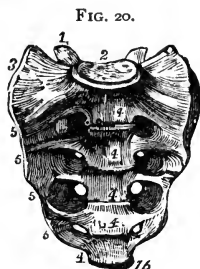
*Auricular Surface*,<sup>3</sup> on each side, articulates with the ilium.

*Notch*, laterally and inferiorly, for the 5th sacral nerve.

*Base*,<sup>2</sup> has all the characteristics of the lumbar vertebræ, with the last of which it articulates.

*Apex*,<sup>16</sup> has an oval surface for articulation with the coccyx.

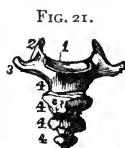*Sacral Canal*, the continuation of the spinal, is incomplete posteriorly at its lower end. It transmits the *Cauda Equina*; into it open the sacral foramina laterally.



**Describe the Coccyx.** It consists of 4 or 5 rudimentary vertebræ coalesced into a triangular bone, the base<sup>1</sup> of which articulates with the apex of the sacrum. Its posterior surface is rough for muscles and ligaments, its anterior surface is smooth and marked by ridges at the junction of its constituent vertebræ. It presents the following points.—

2 *Cornua*,<sup>2</sup> superiorly, articulating with the sacral cornua to form foramina for the 5th sacral nerves.

*Apex*, is sometimes bifid and turned to one side.



**Describe the Ossa Innominata.** The unnamed bones are placed one on each side of the osseous pelvis, and are each formed by the union, about puberty, of 3 bones,—the ilium, ischium, and pubes. The innominate bone as a whole presents the following points, viz.—

*Acetabulum*, or cotyloid cavity, receives the head of the femur. It is situated at the junction of the 3 bones, the ilium and ischium each forming about two-fifths, and the pubes one-fifth of it. A depression in its centre lodges a mass of fat containing vessels for the nourishment of the synovial

membrane. The *Cotyloid Notch* is a deficiency in its lower anterior margin, transmitting nutrient vessels to the joint; to the edges of the notch is attached the *ligamentum teres*, and it is bridged over by the *transverse ligament*, a continuation of the *cotyloid ligament* which surmounts the brim of the *acetabulum*.

*Obturator, or Thyroid Foramen*,<sup>8</sup> on the anterior surface between the pubes and ischium, large and oval in the male, small and triangular in the female; is closed by the *obturator membrane*, except above where the *obturator nerves and vessels* pass through it.

**Describe the Ilium.** It is the superior part of the innominate bone, and presents the following points, viz.—

*Crest*,<sup>1</sup> along its upper border, having an outer and inner lip for muscular attachment, and ending in the *superior spines*.

*Anterior Superior Spine*,<sup>2</sup> to which is attached the *sartorius* and *tensor vaginæ femoris* muscles, and *Poupart's ligament*.

*Anterior Inferior Spine*,<sup>4</sup> for the straight tendon of the *rectus femoris*.

*Notch*, between the above-named spines, transmitting the *external cutaneous nerve*, and lodging some fibres of the *sartorius*.

*Posterior Superior Spine*,<sup>19</sup> for the attachment of the *erector spinæ* muscle, and the *oblique part* of the *sacro-sciatic ligament*.

*Posterior Inferior Spine*,<sup>17</sup> for the *great sacro-sciatic ligament*.

*Great Sacro-sciatic Notch*,<sup>16</sup> below the last-named spine, transmits the *great sciatic*, *superior gluteal*, and *pubic nerves*, the *pyriformis* muscle, and the *sciatic*, *pubic*, and *gluteal vessels*, and a nerve supplying the *obturator externus* muscle.

*Curved Lines*,<sup>21</sup> superior middle and inferior, on the outer surface of the bone, from the spaces between which arise the *glutei* muscles.

*Groove*, above the *acetabulum*, for the *reflected tendon* of the *rectus femoris* muscle.

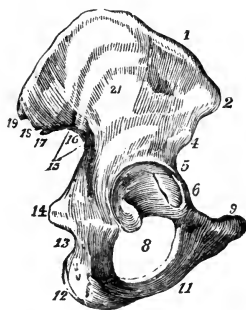
*Linea Ilio-pectinea*, in part; on the inner surface, above which is a smooth surface, the *Venter of the Ilium*.

*Auricular Surface*,<sup>18</sup> rough, articulates with the *sacrum*.

**Describe the Ischium.** It is the lowermost portion of the innominate bone, and presents the following points, viz.—

*Body*, forms two-fifths of the *acetabulum*, and the *external margin* of the

FIG. 22.





obturator foramen; on it is a broad groove for the tendon of the obturator externus muscle. Its posterior margin assists in forming the great sacro-sciatic notch.

*Spine*,<sup>14</sup> for the gemellus superior, coccygeus, and levator ani muscles, and the lesser sacro-sciatic ligament.

*Lesser Sacro-sciatic Notch*,<sup>13</sup> below the spine, transmits the obturator muscle, its nerve, and the pudic vessels and nerve as they re-enter the pelvis, having crossed the spine of the ischium. The sacro-sciatic notches are converted into foramina by the sacro-sciatic ligaments; the greater notch by the lesser ligament, the lesser notch by the greater ligament.

*Tuberosity*,<sup>12</sup> the lowest and most prominent part, gives attachment to the greater sacro-sciatic ligament, and to several muscles. On it one rests when sitting.

*Ascending Ramus*, bounds the obturator foramen inferiorly, articulates with the descending ramus of the pubes, and gives attachment to the obturator membrane and several muscles.

**Describe the Pubes.** The pubic or pectineal bone forms the anterior portion of the innominate. It presents the following, viz.—

*Body*, lies between the rami, with its fellow forms the *Symphysis*, giving origin to several muscles and ligaments.

*Crest*,<sup>9</sup> is the upper part of the body, terminates externally in the *Spine*, and internally in the *Angle*.

*Spine*, affords attachment to one end of Poupart's ligament.

*Linea Ilio-pectinea*, in part; gives attachment to the conjoined tendon, Gimbernat's ligament, and the triangular ligament.

*Horizontal Ramus*, forms part of the brim of the pelvis, of the margin of the obturator foramen, and of the acetabulum. On its under surface is a groove for the obturator vessels and nerve.

*Pectineal Eminence*,<sup>5</sup> gives attachment to the psoas parvus muscle.

*Descending Ramus*,<sup>11</sup> flat and thin, joins the ascending ramus of the ischium, and bounds the obturator foramen internally.

**What Muscles are attached to the Os Innomiatum?** 36, comprising those of the abdomen, thigh, perineum, floor of the pelvis, and rotators of the hip-joint.

## BONES OF THE UPPER EXTREMITY.

### THE SHOULDER.

**What Bones form the Shoulder?** The clavicle and scapula connecting the arm with the trunk, and in this respect homologous to the innominate bone in the lower part of the body.

**Describe the Clavicle.** The collar- or key-bone, is a short bone by structure, having no medullary canal; and is curved like the letter *f*, its inner two-thirds being cylindrical, and convex anteriorly; its outer third flattened, and concave anteriorly. It is placed horizontally between the sternum and the scapula, and is the most elastic bone in the body. It presents, from within outwards, the following points, viz.—

*Facets*, for articulation with the sternum and the cartilage of the 1st rib, at its sternal end.

*Impression* for the rhomboid, or costo-clavicular ligament.

*Groove*, on the lower surface, for the subclavius muscle.

*Tubercle*, for the conoid part of the costo-clavicular ligament.

*Oblique Line*, for the trapezoid part of the same ligament.

*Facet*, on the acromial end, for articulation with the scapula.

*Nutrient Foramen*, in the subclavian groove.

**Describe the Scapula.** The shoulder-blade is a large, flat, and triangular bone, situated on the posterior and lateral portion of the thorax, from the 2d rib to the 7th, inclusive.

**THE VENTER**, or anterior surface, presents from within outwards,—

*Ridges*, giving attachment to the subscapularis muscle.

*Marginal Surface*, along the inner border, for the attachment of the serratus magnus muscle.

*Subscapular Fossa, and Angle*, for the subscapularis muscle.

**THE DORSUM**, or posterior surface, presents the following, viz.—

*Spine*, a bony ridge, which affords attachment to the trapezius and deltoid muscles, and ends in the acromion process.

*Supraspinous Fossa*, above the spine, for the supraspinatus muscle.

*Infraspinous Fossa*, below the spine, larger than the supraspinous, convex at its centre, lodges the infraspinatus muscle, and the nutrient foramen.

*Marginal Surface*, along the external border, to which are attached the teres minor muscle above, the teres major below, and sometimes a few fibres of the latissimus dorsi at the lower angle.

*Groove* crossing the margin, for the dorsalis scapulæ vessels.

*Smooth Surface*, behind the root of the spine, over which the trapezius muscle glides.

**THE ACROMION PROCESS**, or “summit of the shoulder,” extends from the spine, and projects over the glenoid cavity, articulating with the clavicle by an oval facet. It affords attachment to the deltoid and trapezius muscles, and by its apex to the coraco-acromial ligament.

**THE CORACOID PROCESS**, or “crow’s beak,” projects from the upper border and neck of the bone over the inner and upper part of the glenoid cavity.

Into it is inserted 1 muscle, the pectoralis minor; the coraco-brachialis, and the short head of the biceps arise from it by a common tendon; and 3 ligaments are attached to it,—the conoid, trapezoid, and coraco-acromial.

THE SUPERIOR BORDER presents the—

*Suprascapular Notch*, converted into a foramen for the suprascapular nerve by the transverse ligament, over which passes the suprascapular artery. The omo-hyoid muscle is attached to the border just internal to the notch.

THE AXILLARY BORDER is the thickest, and presents a—

*Rough Surface*, for the long head of the triceps muscle, just below the glenoid cavity.

*Groove*, the origin of a part of the subscapularis muscle.

THE VERTEBRAL BORDER is the longest, and presents an—

*Anterior Lip*, for the attachment of the serratus magnus.

*Posterior Lip*, for the supra- and infra-spinatus muscles.

*Interspace*, between the lips, for the levator anguli scapulæ, the rhomboideus minor, and the fibrous arch of the rhomboideus major muscles.

OTHER POINTS of interest on the bone are the—

*Superior Angle*, affords attachment to part of the serratus magnus, levator anguli scapulæ, and supra-spinatus muscles.

*Inferior Angle*, affords attachment to part of the serratus magnus and teres major muscles, and occasionally to a few fibres of the latissimus dorsi.

*Glenoid Cavity*, at the external angle or head of the bone, a shallow cavity for the reception of the head of the humerus. It is deepened by the glenoid ligament which is attached around its margin; and at its upper part gives origin to the long head of the biceps flexor cubiti muscle.

*Neck*, is the contracted part of the bone behind the glenoid cavity; from it arises the anterior root of the coracoid process.

## THE ARM.

**Describe the Humerus.** It is the only bone in the arm, and articulates with the scapula above, and with the ulna and radius below. It presents the following points, viz.—

*Head*,<sup>b</sup> is nearly hemispherical, and smooth for articulation with a glenoid cavity of the scapula.

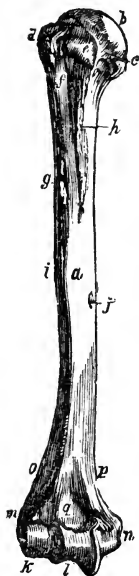*Anatomical Neck*,<sup>c</sup> is a constriction in the bone, just below the head, for the attachment of the capsular ligament.

*Greater Tuberosity*,<sup>d</sup> has 3 small facets for the insertions of the supra-spinatus, infraspinatus, and teres minor muscles.

*Lesser Tuberosity, e* on the inner side of the bone, gives insertion to the subscapularis muscle.

*Bicipital Groove, f* lies vertically between the tuberosities for the upper third of the bone, and lodges the tendon of the long head of the biceps flexor cubiti. Into its inner or posterior lip *h* are inserted the teres major and latissimus dorsi muscles, while its outer or anterior lip *g* receives the insertion of the tendon of the pectoralis major, which covers the groove.

FIG. 23.



*Surgical Neck, i* is situated immediately below the tuberosities, and is a slight constriction in the upper part of the shaft.

*Shaft, a* is cylindrical above, prismatic and flattened below.

*Rough Surface, i* for the insertion of the deltoid muscle, about the middle of the external surface of the shaft.

*Musculo-spiral Groove, g*, lodging the musculo-spiral nerve, and the superior profunda artery, is situated on the posterior surface of the shaft, separating the origins of the outer and inner heads of the triceps muscle.

*Orifice, j* of the nutrient canal, about the middle of the shaft.

*Condyloid Ridges, p*, internal and external, arising from the respective condyles, extending upwards along the shaft.

*External Condyle, m* gives attachment to the external lateral ligament and the extensor and supinator group of muscles.

*Internal Condyle, n* lower and more prominent than the other, gives attachment to the internal lateral ligament and the flexor and pronator group of muscles of the fore-arm.

*Radial Head, k* forms the external part of the inferior articular surface; for articulation with the radius.

*Trochlear Surface, l* articulates with the greater sigmoid cavity of the ulna; is a deep depression between two borders, and extends from the anterior to the posterior surface of the bone.

*Coronoid Fossa, q* in front of the trochlea, receives the coronoid process of the ulna when the fore-arm is flexed.

*Olecranon Fossa, r*, behind the trochlea, receives the tip of the olecranon process, when the fore-arm is extended.

## THE FORE-ARM.

**Describe the Ulna.** The elbow-bone is the internal bone of the fore-arm. It is larger and longer than the radius, forming the greater portion of the articulation with the humerus. It does not enter into the formation of the wrist-joint, being excluded therefrom by an interarticular fibro-cartilage. It presents the following, viz.—

*Olecranon Process,*<sup>d</sup> at the upper extremity, forming the elbow. It is curved forwards, its apex being received into the olecranon fossa of the humerus when the fore arm is extended. Its posterior surface gives insertion to the tendon of the triceps. In its function and structure it resembles the patella.

*Coronoid Process,*<sup>e</sup> below the olecranon, projects forwards, its apex being received into the coronoid fossa of the humerus when the fore-arm is flexed. Its upper surface is concave for articulation with the humerus, its lower surface rough for the insertion of the brachialis anticus muscle. Its inner surface has a margin for the internal lateral ligament, a tubercle for the flexor sublimis digitorum, and a ridge for the pronator radii teres.

*Greater Sigmoid Cavity,*<sup>b</sup> lies between the processes, and is divided by a vertical ridge into two unequal parts. It articulates with the trochlear surface of the humerus.

*Lesser Sigmoid Cavity*<sup>c</sup> lies external to the coronoid process; is oval and concave, articulating with the head of the radius, and giving attachment to the orbicular ligament.

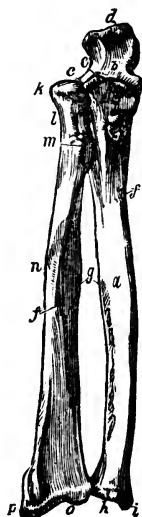*Shaft,*<sup>a</sup> large and prismatic above, smaller and rounded below, has the *Nutrient Foramen*<sup>f</sup> on its anterior surface, and a prominent margin<sup>g</sup> externally, to which is attached the interosseous membrane. The shaft gives attachment to 9 of the 12 muscles of the fore-arm.

*Head,*<sup>h</sup> at the carpal end, articulates with the lesser sigmoid cavity of the radius, and the fibro-cartilage of the wrist-joint.

*Styloid Process,*<sup>i</sup> projecting from the head internally and posteriorly, its apex gives attachment to the internal lateral ligament, and a depression at its root to the fibro-cartilage of the joint.

*Groove,* for the tendon of the extensor carpi ulnaris muscle.

FIG. 24.



**Describe the Radius.** The radius lies externally to the ulna when the fore-arm is in supination; it is prismatic in form with the base below where it articulates with the carpus. The bone is curved outwards and is shorter than the ulna, by the length of the olecranon. It presents the following points from above downwards, viz.—

*Head,*<sup>k</sup> cylindrical and cup-shaped, articulating with the radial head of the humerus, and the lesser sigmoid cavity of the ulna, and playing within the orbicular ligament.

*Neck,*<sup>l</sup> the constricted part below the head.

*Tuberosity,*<sup>m</sup> rough behind for the insertion of the biceps, and smooth in front where it is covered by a bursa.

*Shaft,*<sup>j</sup> prismoid in form, presents a sharp border internally for the attachment of the interosseous membrane; the *Nutrient Foramen* is on its anterior surface. It gives attachment to 8 of the 12 muscles of the fore-arm.

*Sigmoid Cavity,* at the internal side of the carpal end, is shallow, and articulates with the head of the ulna.

*Articular Surface,*<sup>o</sup> is divided by a ridge into 2 facets for articulation with the semilunar and scaphoid bones of the carpus.

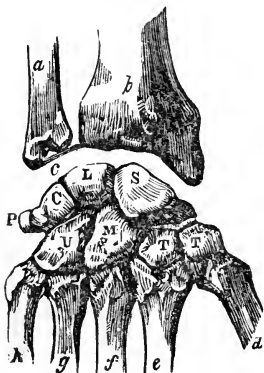
*Styloid Process,*<sup>p</sup> externally, gives attachment by its apex to the external lateral ligament, and by its base to the supinator longus muscle.

*Grooves,* on the posterior and external surfaces of the lower extremity, for the tendons of the 8 extensor muscles of the thumb, and those of the radial side of the wrist, and fingers.

## THE HAND.

**How are the Bones of the Hand divided?** Into the carpus (8), the metacarpus (5), and the phalanges (14). Total, 27 bones.

FIG. 25.



**Name the Bones of the Carpus.** They are placed in 2 rows, one row in front of the other, with 4 bones in each row, as follows,—the left hand being in supination, naming from without inwards, viz.—

*1st, or Proximal Row,*—Scaphoid,<sup>S</sup> Semi-lunar,<sup>L</sup> Cuneiform,<sup>C</sup> Pisiform.<sup>P</sup>

*2d, or Distal Row,*—Trapezium,<sup>T</sup> Trapezoid,<sup>T</sup> Os-magnum,<sup>M</sup> Unciform.<sup>U</sup>

**State the number of Articulations in the Carpus.** 34, as follows,—the number after each bone representing the number of its articulations, viz.—

Scaphoid, 5.    Semilunar, 5.    Cuneiform, 3.    Pisiform, 1.  
 Trapezium, 4.    Trapezoid, 4.    Os-magnum, 7.    Unciform, 5.

**What peculiarities have the Carpal bones?** The first three enter into the formation of the wrist-joint; the pisiform does not, but is wholly without it, and may be considered a mere appendage of the carpus. When the hand is in pronation—

*The Scaphoid*, or boat-shaped bone, has a tuberosity on its outer side, its largest auricular facet is uppermost, and a transverse groove crosses its posterior surface.

*The Semilunar Bone* has a crescentic facet externally, and a convex facet superiorly.

*The Cuneiform Bone* is wedge-shaped, its convex surface above, and has an isolated facet for the pisiform articulation.

*The Pisiform Bone* is the smallest, and has but one facet, which lies posteriorly when the bone is in position.

*The Trapezium* has a deep groove for the tendon of the flexor carpi radialis, and a saddle-shaped facet, inferiorly.

*The Trapezoid* is small and quadrilateral, bent on itself, with a saddle-shaped facet looking downwards.

*The Os-magnum* has a head looking upwards, a neck, and a body; is the largest bone of the carpus, and has a tubercle on the inner side of the base.

*The Unciform Bone* is triangular, with a concavity which lies to the outer side; and the unciform process, long and curved, projecting from its palmar surface.

**Describe the Metacarpus.** The 5 metacarpal bones are placed between the carpus and the phalanges, are long bones, and each has a head, shaft, and base. Their heads articulate with the respective phalanges.

*1st Metacarpal Bone,<sup>d</sup>* articulates with the trapezium, is shorter than the others by one-third, and its base has but 1 articular facet. This bone is classed among the phalanges by Professor W. H. Pancoast.

*2d Metacarpal Bone,<sup>e</sup>* articulates with 3 bones of the carpus,—the trapezium, trapezoid, and os-magnum; its base is large, and has 4 articular facets.

*3d Metacarpal Bone,<sup>f</sup>* articulates with 1 bone of the carpus,—the os-magnum; its base has a projecting process on the radial side, and 2 small facets on the opposite side.

*4th Metacarpal Bone,<sup>g</sup>* articulates with 2 bones of the carpus and with the adjacent metacarpal bones; its base is small, and has 2 circular facets, 1 on each side.

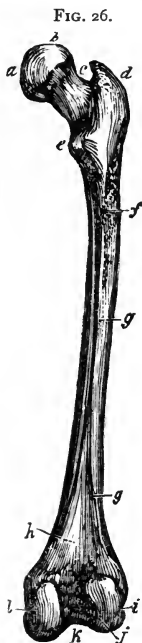
*5th Metacarpal Bone,<sup>h</sup>* articulates with 1 carpal bone,—the unciform; its base has 1 lateral articular facet.

**Describe the Phalanges.** The finger-bones are 14 in number (15 according to Pancoast), 3 to each finger, and 2 to the thumb. They are long bones, and each has a base, a shaft, and a digital extremity. The *Bases* of the first row articulate with the heads of the metacarpal bones. The *Digital Extremities* of the first and second rows have each 2 small lateral condyles, while in the terminal row they are rough, for the attachment of the sensitive pulp of the fingers.

## BONES OF THE LOWER EXTREMITY.

### THE THIGH.

**Describe the Femur.** The thigh-bone is nearly cylindrical, and is the longest, largest, and strongest bone in the body. In the vertical position of the skeleton it forms one side of a triangle, of which the base is the breadth of the pelvis, and the apex at the knee-joints. The base of this triangle is longest in the female, and consequently that sex is usually knock-kneed.



*Head, b* articulates with the acetabulum, forms about two-fifths of a sphere, and has an oval depression *a* below its centre for the attachment of the ligamentum teres.

*Neck, c* connects the head with the shaft, is pyramidal and flattened; its obliquity varies with age, being less before puberty, about 120 to 125 degrees in the adult, and nearly horizontal to the shaft in old or debilitated subjects.

*Great Trochanter, d* a broad, rough, quadrilateral process directed outwards and backwards from the summit of the shaft to within three-fourths of an inch of the level of the head. On its outer surface the tendon of the gluteus maximus plays over a bursa. It gives insertion to the obturator internus, two gemelli, pyramiformis, and gluteus minimus and medius muscles.

*Digital Fossa, h* on the inner surface of the great trochanter, gives insertion to the obturator externus muscle.

*Lesser Trochanter, e* at the inferior root of the neck posteriorly, is small and conical, and affords insertion to the tendon of the psoas magnus muscle, the tendon of the iliacus being inserted immediately below it.

*Inter-trochanteric Lines*, anterior and posterior, the latter the most prominent; to the anterior is attached the capsular ligament of the hip-joint.

*Linea Quadrati*, extends from the middle of the posterior inter-trochanteric line about 2 inches down the shaft, and gives attachment to the quadratus femoris muscle.



*Shaft*, is slightly curved forwards, broad and cylindrical at each end, and narrow and triangular in the centre. Its nutrient foramen perforates its posterior surface below the centre. From its anterior surface arise the crureus and sub-crureus muscles.

*Linea Aspera*,<sup>g</sup> a crest lying along the central third of the shaft posteriorly; bifurcating above towards each trochanter, also below towards the 2 condyles. To its outer lip is attached the vastus externus, to its inner lip, the vastus internus; and between them, the pectineus, adductor brevis, and gluteus maximus above the short head of the biceps below, and the adductors longus and magnus along the greater portion of the space.

*Groove*, crossing the internal condyloid ridge, and lodging the femoral artery.

*Popliteal Space*,<sup>h</sup> triangular and smooth, lying between the condyloid ridges, for the popliteal artery.

*External Condyle*,<sup>i</sup> broader and shorter than the internal, so as to form a horizontal articulation, the bone being inclined towards the median line. It gives attachment to the external lateral ligament, and the popliteus and gastrocnemius muscles.

*Internal Condyle*,<sup>l</sup> the longest by half an inch; it gives attachment to the internal lateral ligament and the gastrocnemius muscle.

*Inter-condyloid Notch*,<sup>k</sup> lodges the crucial ligaments. In front the condyles are continuous with each other, forming a concave depression or trochlea for the patella.

*Outer Tuberosity*, on the external condyle, for the attachment of the external lateral ligament.

*Groove*, below the outer tuberosity, for the tendon of the popliteus muscle, terminating in a depression whence the muscle takes its origin.

*Inner Tuberosity*, on the internal condyle, for the attachment of the internal lateral ligament.

*Tubercle*, above the inner tuberosity, for the insertion of the tendon of the adductor magnus muscle.

*Depression*, behind the tubercle, for the tendon of the inner head of the gastrocnemius.

## THE LEG.

**Describe the Tibia.** The shin-bone ranks next to the femur in respect to size and length. Its form is prismoidal, the upper extremity being much larger than the lower.

*Head*, expands into 2 lateral tuberosities,<sup>bc</sup> which articulate with the condyles of the femur.

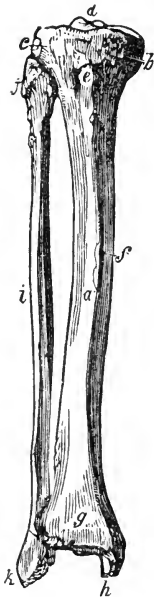
*Spine*,<sup>d</sup> projects vertically between the 2 articular surfaces, is bifid, affording attachment to the semilunar fibro-cartilages, and by depressions in front and behind its base to the crucial ligaments of the joint.

*Tubercle, e* anteriorly on the head, between the tuberosities, for the insertion of the ligamentum patellæ.

*Popliteal Notch*, posteriorly between the tuberosities, affords attachment to the posterior crucial ligament.

*Groove*, on the inner tuberosity posteriorly, for the insertion of the tendon of the semi-membranosus muscle.

FIG. 27.



*Facet*, on the outer tuberosity posteriorly and looking downwards, for articulation with the head of the fibula.

*Popliteal Line*, obliquely across the upper part of the shaft posteriorly, affords attachment to the fascia of the popliteus, and parts of the soleus, flexor longus digitorum, and tibialis posticus muscles.

*Nutrient Canal*, the largest in the skeleton, opens just below the popliteal line, its orifice looking upwards.

*Shaft, a* has 3 sharp ridges,—1 in front, the *Crest* or *Shin, f* and 1 on either side, to the external of which is attached the interosseous membrane.

*Lower Extremity, g* is smaller than the upper, grooved posteriorly for the tendon of the flexor longus pollicis; externally has a rough triangular depression for articulation with the fibula, and for the attachment of the inferior interosseous ligament. Its inferior surface is concave and smooth for articulation with the upper surface of the astragalus.

*Internal Malleolus, h* projects downwards from the internal side of the lower extremity. It articulates with the astragalus, is grooved posteriorly for the tendons of the tibialis posticus and flexor longus digitorum muscles, and affords attachment to the internal lateral ligament.

**Describe the Fibula.** It is a long slender bone, placed nearly parallel with the tibia on the outer side of the leg. It is also called the peroneous, or peroneal bone.

*Head, j* articulates with the external tuberosity of the tibia by a flat facet.

Externally it has a prominence for the attachment of the long external lateral ligament of the knee-joint.

*Styloid Process*, projects upwards from the head posteriorly, and gives insertion to the tendon of the biceps muscle, and the short external lateral ligament of the knee-joint.

*Shaft i* is triangular and twisted on itself, having 3 marked ridges, the

innermost of which is sharp for the attachment of the interosseus membrane. The shaft arches backwards, and gives attachment to 8 of the 12 muscles of the leg.

*Nutrient Canal*, opens about the centre of the shaft posteriorly, its orifice looking downwards.

*External Malleolus*,<sup>k</sup> is the lower extremity of the bone. It is larger and longer than the internal, articulates with the astragalus by a triangular facet, and is grooved posteriorly for the tendons of the peroneus longus and brevis muscles. Its edge affords attachment to the external lateral ligament of the ankle-joint.

## THE FOOT.

**How are the bones of the Foot divided?** Into the tarsus (7), metatarsus (5), and phalanges (14). Total, 26 bones.

**Name the bones of the Tarsus.** They are placed in 2 rows side by side, 2 bones in the external row, 5 in the internal, as follows. viz.—

*Internally*,— Astragalus.<sup>a</sup> Scaphoid.<sup>d</sup> 3 Cuneiform.<sup>e, f, g</sup>

*Externally*,— Os calcis.<sup>c</sup> Cuboid.<sup>h</sup>

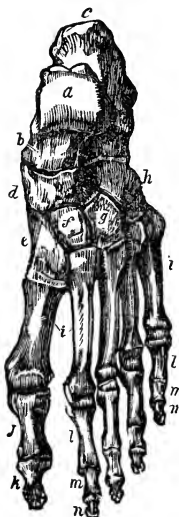**How many Articulations are in the Tarsus?** 28, each bone articulating with 4 others, except the os calcis, which articulates with 2, and the external cuneiform with 6 bones.

**What Peculiarities have the Tarsal Bones?** They may be divided transversely at the astragaloscaphoid-calcaneo-cuboid articulation, the site of Chopart's operation.

*The Astragalus*,<sup>a</sup> has a rounded head, a convex surface on which is a broad articular facet, and on its inferior surface a deep groove between 2 articular facets.

*The Os Calcis*,<sup>c</sup> is a large bone, having on its upper surface a deep groove for the interosseous ligament, between 2 articular surfaces; anteriorly a large irregular portion, the head; and posteriorly an elongated portion forming *the Heel*. On its internal surface is a projection, the *Sustentaculum Tali*, which supports the internal articulating surface; below which process the bone is deeply grooved for the plantar vessels and nerves and the flexor tendons. To the os calcis are attached 8 muscles and the plantar fascia.

FIG. 28.



*The Scaphoid Bone,<sup>d</sup>* is boat-shaped, has 3 facets anteriorly for the cuneiform bones, a concave surface posteriorly for the astragalus, and a facet externally for the cuboid bone. A tubercle is situated on the lower surface internally, for the insertion of the tibialis posticus muscle.

*The Cuboid Bone,<sup>h</sup>* has 3 articular surfaces, and a groove inferiorly for the tendon of the peroneus longus.

*The Internal Cuneiform Bone,<sup>e</sup>* the largest of the 3, has a tubercle on its plantar surface for the insertion of parts of the tendons of the tibialis anticus and tibialis posticus muscles.

*The Middle Cuneiform Bone,<sup>f</sup>* is small and wedge-shaped with the narrow end downwards. Its anterior surface is considerably behind the line of the tarso-metatarsal articulation, thus forming a recess into which the base of the second metatarsal bone fits.

*The External Cuneiform Bone,<sup>g</sup>* is also wedge-shaped, but longer than the middle one; and affords origin to 1 muscle, the flexor brevis pollicis.

**Describe the Metatarsus.** The metatarsal bones <sup>i</sup> are 5 in number, are long bones, having each a shaft and 2 extremities. Their bases articulate with the tarsal bones and with each other; their heads with the first row of phalanges.

*1st Metatarsal,* is large but shorter than the others, and forms the inner border of the foot, articulating with the internal cuneiform.

*2d Metatarsal,* is the longest; its base has 3 facets for articulation with the 3 cuneiform bones in the recess formed by the shortness of the middle cuneiform.

*3d Metatarsal,* has 2 facets on the inner side of its base, besides the facets for the internal cuneiform and the 4th metatarsal bone.

*4th Metatarsal,* articulates with the cuboid bone, and also with the internal cuneiform.

*5th Metatarsal,* articulates obliquely with the cuboid bone, and has a tubercular projection on the outer surface of its base, which forms the guide to Hey's operation.

**Describe the Phalanges of the Foot.** They number 14 as in the hand, the great toe having 2, the other toes 3 each. They are long bones, each having a base, a shaft, and an anterior extremity. They are convex above, concave below, and articulate by the bases of the first row with the bones of the metatarsus. The anterior extremities of the distal phalanges <sup>k, n</sup> are expanded into surfaces for the support of the nails and pulp of the toes.

## THE ARTICULATIONS.

**Into what Classes are the Articulations divided?** Into 3,—1. *Synarthro'sis*, immovable; 2. *Amphiarthro'sis*, *Synchondrosis*, or *Symphysis*, having limited motion; 3. *Diarthro'sis*, having free motion.

**How are the Synarthroses subdivided?** Into 3 divisions,—*Sutura*, by indentations; *Schindy'lesis*, by a plate of bone into a cleft in another; and *Gompho'sis*, by a conical process into a socket. The *Sutura* are again subdivided into—*S. Dentata*, having tooth-like processes; *S. Serrata*, with serrated edges; *S. Limbosa*, having beveled margins and dentated processes; *S. Squamosa*, with thin beveled margins overlapping each other; *S. Harmonia*, contiguous rough surfaces opposed to each other. The first 3 are also named *Sutura Vera* (true sutures) having indented borders; the last 2 *Sutura Notha* (false sutures) being formed by rough surfaces.

**How are the Diarthroses divided?** Into 4 divisions,—*Arthrodia*, gliding joint; *Enarthrosis*, ball-and-socket joint; *Ginglymus*, hinge-joint; and *Diarthrosis Rotatorius*, a ring surrounding a pivot.

**Give an Example of each of the above-named articulations.**

*Synarthro'sis*,—bones of cranium and face, except the lower jaw.

*Sutura Dentata*,—the inter-parietal suture.

*Sutura Serrata*,—the inter-frontal suture.

*Sutura Limbosa*,—the fronto-parietal suture.

*Sutura Squamosa*,—the tempora-parietal suture.

*Sutura Harmonia*,—the intermaxillary symphysis.

*Schindy'lesis*,—rostrum of sphenoid with the vomer.

*Gompho'sis*,—the teeth in their alveoli.

*Amphiarthro'sis*,—the bodies of the vertebræ, the sacro-iliac, and pubic symphyses.

*Diarthro'ses*,—

*Arthrodia*,—sterno-clavicular articulation.

*Enarthrosis*,—hip-joint, shoulder-joint.

*Ginglymus*,—elbow-joint, ankle-joint, knee-joint.

*Diarthrosis Rotatorius*,—the superior radio-ulnar, and atlo-axoid articulations.

**Name the Varieties of motion in joints?** There are 7 varieties, viz.—flexion, extension, adduction, abduction, rotation, circumduction, and gliding movement.

**What Structures enter into the formation of joints?** There are 5, viz.—the articular lamella of bone, ligaments, cartilage, fibro-cartilage, and synovial membrane.

*Articular Lamella* of bone differs from ordinary bone tissue in being more dense, containing no Haversian canals nor canaliculi, and having larger lacunæ.

*Ligaments* are bands of white fibrous tissue, except the *ligamentum subflava* and the *ligamentum nuchæ*, which are both composed purely of yellow elastic tissue.

*Cartilage* is temporary or permanent. The first forms the original framework of the skeleton, and becomes ossified. Permanent cartilage is not prone to ossification, and is divided into 3 varieties,—*Articular*, covering the ends of bones in joints; *Costal*, forming part of the skeleton; *Reticular*, arranged in lamellæ or plates to maintain the shape of certain parts.

*Fibro-cartilage* is *Interarticular* (menisci), separating the bones of a joint; *Connecting*, binding bones together; *Circumferential*, deepening cavities; *Stratiform*, lining grooves.

*Synovial Membranes* secrete the synovia, a viscid, glairy fluid, and resemble the serous membranes in structure. They are *Articular*, lubricating joints; *Bursal*, forming closed sacs (bursæ); *Vagina*,<sup>2</sup> ensheathing tendons.

**Describe the Vertebral Articulations.** They are formed by the adjacent surfaces of the bodies of the vertebræ, and their articular processes, and are connected by the following ligaments, etc.—(See FIG. 31.)

*Intervertebral Fibro-cartilages*, between the bodies of all true vertebræ, except the axis and atlas.

*Anterior Common Ligament*,<sup>1</sup> along fronts of the bodies.

*Posterior Common Ligament*, along backs of the bodies.

*Ligamenta Subflava*, connect the laminæ of adjacent vertebræ.

*Capsular*,<sup>4</sup> surround the articular processes, and are lined by synovial membrane.

*Supra-spinous and Inter-spinous*, connect the spinous processes.

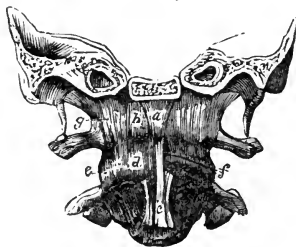*Inter-transverse*,<sup>3</sup> connect the transverse processes.

**Describe the Occipito-atloid Articulation.** It is a double arthrodia formed by the condyles of the occipital bone with the superior articular surfaces of the atlas, and has 7 ligaments, viz.—

1 *Anterior Occipito-atloid*,<sup>a</sup> from the anterior margin of the foramen magnum to the anterior arch of the atlas.

2 *Posterior Occipito-atloid*, from the posterior margin of the foramen magnum to the posterior arch of the atlas. It is perforated by the vertebral arteries and suboccipital nerves.

FIG. 29.



*a Lateral*, from the jugular processes of the occipital bone to the bases of the transverse processes of the atlas.

*2 Capsular, d* around the articular surfaces, lined by synovial membrane.

**Describe the Occipito-axoid Articulation.** Formed by the occipital bone and the odontoid process of the axis, which do not articulate with each other strictly, but are connected by 4 ligaments.

*Occipito-axoid<sup>1</sup> (Apparatus Ligamentosus Colli)*, a continuation of the posterior common spinal ligament to the basilar process of the occipital bone.

*2 Lateral Occipito-odontoid<sup>5</sup> (Check Ligaments)*, from the head of the odontoid process to the sides of the occipital condyles.

*Vertical Occipito-odontoid (Ligamentum Suspensorium)*, from the anterior margin of the foramen magnum to the odontoid apex.

**Describe the Atlo-axoid Articulation.** It is a double arthrodia between the articular processes, a double diarthrosis rotatorius between the atlas and the odontoid process, and has 6 ligaments, and 4 synovial membranes.

*2 Anterior and 1 Posterior Atlo-axoid*, continuations of the anterior and posterior common spinal ligaments.

*2 Capsular*, surrounding the articular surfaces, each lined by a synovial membrane.

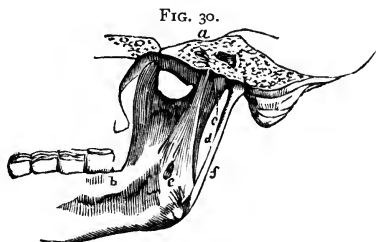
*Transverse, or Cruciform Ligament*, divides the spinal foramen of the atlas into two portions, stretching across between the tubercles on the inner sides of the articular processes. It holds the odontoid process in place, having a synovial membrane interposed. Another synovial membrane is situated between the process and the anterior arch. The transverse ligament sends two vertical slips, one upwards, the other downwards, from which it is named the *Cruciform Ligament*.

**Describe the Temporo-maxillary Articulation.** A double arthrodia between the condyle of the lower jaw and the anterior part of the glenoid cavity of the temporal bone. It has 2 synovial membranes with an inter-articular fibrocartilage between them, and 4 ligaments, viz.—

*External Lateral*, from the tubercle of the zygoma to the outer side of the neck of the condyle of the lower jaw.

*Internal Lateral, d* from the spine of the sphenoid to the margin of the inferior dental foramen.

*Stylo-maxillary, f* from the styloid process of the temporal bone to the angle of the inferior maxillary.



*Capsular,* from the edge of the glenoid cavity and the eminentia articularis to the neck of the inferior maxillary condyle.

*Nerves* are derived from the auriculo-temporal and masseteric branches of the inferior maxillary.

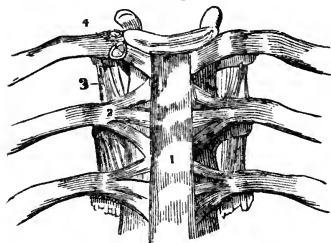
**Describe the Costo-vertebral Articulations.** They are each a double arthrodia between the head of the rib and the bodies of 2 adjacent vertebræ, except in the 1st, 10th, 11th, and 12th ribs, which are each a single arthrodia, as they articulate with but 1 vertebra each. Their ligaments are 3, viz.—

*Anterior Costo-vertebral,<sup>2</sup> or Stellate Ligament,* consists of 3 bundles, which fasten the anterior part of the head of the rib to the intervertebral disk and the 2 adjacent bodies.

*Inter-articular Costo-vertebral,* in the interior of the joint, from the crest on the head of the rib to the intervertebral disk; on each side there is a separate synovial membrane.

*Capsular,* surrounding the articular surfaces.

FIG. 31.



**Describe the Costo-transverse Articulations.** They are 10 arthrodiar articulations between the tubercles of the first 10 ribs and the transverse processes of the vertebræ next below. Their ligaments are 3, viz.—*Anterior, Middle, and Posterior Costo-transverse.*

**Describe the Costo-sternal Articulations.** One a synarthrodial, 6 are arthrodiar articulations, between the costal cartilages and the margin of the sternum. The first has no synovial membrane, the second only has an inter-articular fibro-cartilage. Each has 3 ligaments,—the *Anterior and Posterior Costo-sternal,* and a *Capsular.* The *Costo-xiphoid Ligament* connects the xiphoid appendix to the cartilage of the 6th or 7th rib.

**How are the Costal Cartilages connected with the ribs and with each other?** With the ribs by a depression on the end of each rib, strengthened by the blending together of the periosteum and the perichondrium. The cartilages of the lower ribs, sometimes from the 5th to the 10th inclusive, articulate with each other by their borders and for each a capsular and an intercostal ligament, with 3 synovial membranes for the 3 articulations between the 6th and the 9th cartilages.

**What are the Ligaments of the Sternum?** An anterior sternal and a posterior sternal ligament, with a layer of cartilage between the manubrium and the gladiolus.



**Describe the Sacro-vertebral Articulation.** It is similar to the other vertebral articulations, but has 2 additional ligaments on each side, viz.—

*Lumbo-sacral*, from the transverse processes of the 5th lumbar vertebra to the base of the sacrum laterally and anteriorly.

*Lumbo-iliac*, from the apices of the transverse processes of the 5th lumbar vertebra to the crest of the ilium.

**Describe the Sacro-coccygeal Articulation.** It is an amphiarthrodial joint, and has 3 ligaments, viz.—

*Anterior Sacro-coccygeal.*

*Posterior Sacro-coccygeal.*

*Interarticular Fibro-cartilage*, in the joint.

**Describe the Sacro-iliac Articulation.** It is an amphiarthrodial joint, formed by the auricular surfaces of the sacrum and ilium. Its ligaments on each side are as follows, viz.—

*Anterior Sacro-iliac.*

*Posterior Sacro-iliac.*<sup>8</sup>

*Oblique Sacro-iliac.*

**Describe the Sacro-ischiatic Articulation.** Its ligaments convert the sacro-sciatic notches into foramina, the greater notch by the lesser ligament, the lesser notch by the greater ligament. These foramina are described under the ilium and ischium bones.

*Great Sacro-sciatic Ligament*,<sup>13 14</sup> from the posterior inferior spine of the ilium and the posterior surfaces and margins of the sacrum and coccyx, to the inner margin of the tuberosity and the ascending ramus of the ischium.

*Lesser Sacro-sciatic Ligament*,<sup>15 16</sup> from the margins of the sacrum and coccyx, into the spine of the ischium.

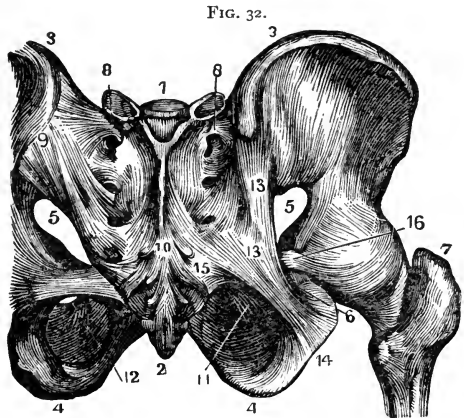
**Describe the Pubic Articulation.** It is an amphiarthrodial joint, formed by the 2 pubic bones. It has an interarticular fibro-cartilage and 4 ligaments, viz.—

*Anterior Pubic.*

*Posterior Pubic.*

*Supra-pubic.*

*Sub-pubic*, forming a fibrous arch between the rami.



**Describe the Sterno-clavicular Articulation.** It is an arthrodial joint, formed by the sternal end of the clavicle with the sternum and the cartilage of the 1st rib. It has an interarticular fibro-cartilage, 2 synovial membranes, and 4 ligaments, viz.—

*Anterior Sterno-clavicular.*

*Interclavicular.*

*Posterior Sterno-clavicular.*

*Costo-clavicular or Rhomboid.*

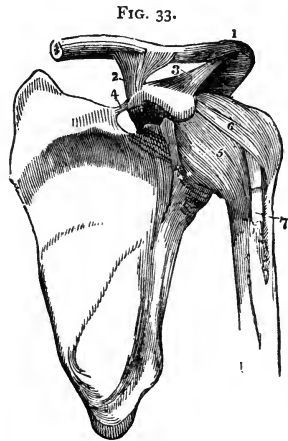
**Describe the Scapulo-clavicular Articulation.** It is an arthrodial joint, formed by the outer extremity of the clavicle and the acromion process of the scapula. It frequently has an interarticular fibro-cartilage and 2 synovial membranes; usually but 1 synovial membrane is present, and 3 ligaments, viz.—

*Superior Acromio clavicular.*<sup>1</sup> *Coraco-clavicular*<sup>2</sup> } Trapezoid, externally.  
*Inferior Acromio-clavicular.* divided into— { Conoid, internally.

**What are the proper Ligaments of the Scapula?** They are 2, the coraco-acromial, and the transverse, as follows.—

*Coraco-acromial*,<sup>3</sup> completes the vault partially formed by the 2 processes over the head of the humerus.

*Transverse*,<sup>4</sup> from the base of the coracoid process to the margin of the suprascapular notch, converting it into a foramen, for the supra-scapular nerve.



**Describe the Shoulder-joint.** It is an enarthrodial joint, formed by the head of the humerus and the glenoid cavity of the scapula. It has a *Synovial Membrane* which is reflected upon the tendons of the biceps, subscapularis, and infraspinatus muscles, and communicates with bursæ beneath the 2 latter tendons. Its *Arteries* are derived from the anterior and posterior circumflex and the suprascapular; its *Nerves* from the circumflex and the supra-scapular. It has 3 ligaments, viz.—

*Capsular*,<sup>5</sup> from the margin of the glenoid cavity to the anatomical neck of the humerus; has 3 openings for the reflexions of the synovial membrane over the tendons.

*Coraco-humeral*,<sup>6</sup> intimately united with the capsular, extends from the coracoid process to the greater tuberosity.

*Glenoid*, a fibro-cartilaginous ring, continuous above with the tendon of the

long head of the biceps,<sup>7</sup> and attached around the margin of the glenoid cavity in order to deepen the articular surface.

**Describe the Elbow-joint.** It is a ginglymus articulation, formed by the lower end of the humerus with the greater sigmoid cavity of the ulna and the head of the radius. Its *Synovial Membrane* is reflected over the ligaments, and dips down between the surfaces of the superior radio-ulnar articulation. Its *Arteries* are derived from the anastomotica magna, radial, ulnar, and interosseous recurrent, superior and inferior profunda arteries. Its *Nerves* are branches of the ulnar and the musculo-cutaneous. It has 4 ligaments,—

*Anterior*, from the inner condyle and anterior surface of the humerus to the orbicular ligament of the radius and the coronoid process of the ulna.

*Posterior*, from the posterior surface of the humerus to the olecranon process of the ulna.

*External Lateral*,<sup>4</sup> from the external condyle of the humerus to the orbicular ligament of the radius.

*Internal Lateral*, from the internal condyle of the humerus to the coronoid and olecranon processes of the ulna.

**Describe the Radio-ulnar Articulations.** They are 3 in number, as follows, viz.—

**SUPERIOR RADIO-ULNAR ARTICULATION** is a lateral ginglymoid joint, formed by the head of the radius and the lesser sigmoid cavity of the ulna. Its synovial membrane is a continuation of that in the elbow-joint. It has 1 ligament, the—

*Orbicular Ligament*,<sup>5</sup> forms four-fifths of a circle and surrounds the neck of the radius. It is attached to the margins of the lesser sigmoid cavity of the ulna, and to the external lateral ligament of the elbow-joint.

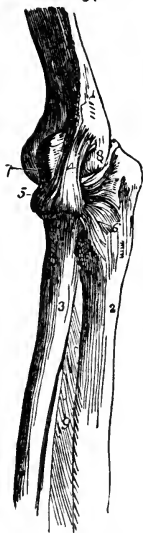**MIDDLE RADIO-ULNAR ARTICULATION** is formed by the shafts of the radius and ulna, which do not touch each other, but are connected by 2 ligaments, as follows, viz.—

*Oblique Ligament*, from the tubercle at the base of the coronoid process of the ulna to the shaft of the radius.

*Interosseous Membrane*,<sup>9</sup> obliquely downwards from the interosseous ridge on the radius to that on the ulna. Through the interval between its upper border and the oblique ligament, the posterior interosseous vessels pass.

**INFERIOR RADIO-ULNAR ARTICULATION** is a lateral ginglymoid joint, formed by the head of the ulna and the sigmoid cavity of the radius. Its *Synovia Membrane* (membrana sacciformis) is very loose, and sometimes communicates

FIG. 34



with that of the wrist-joint through an opening in the *triangular fibro-cartilage* which separates the head of the ulna from the wrist-joint, and acts as one of the ligaments of this articulation, which are 3, viz.—

*Anterior Radio-ulnar.*

*Posterior Radio-ulnar.*

*Triangular Interarticular Fibro-cartilage.*

**Describe the Wrist-joint.** It is chiefly an enarthrodial articulation, though incapable of rotation, and is formed by the lower end of the radius and the triangular fibro-cartilage, with the scaphoid, semilunar, and cuneiform bones of the carpus. Its *Arteries* are the anterior and posterior carpal from both the radial and ulnar, the anterior and posterior interosseous and ascending branches from the deep palmar arch. Its *Nerves* are derived from the ulnar; it is lined by a *synovial membrane*, and has 4 ligaments, viz.—

*External Lateral* (radio-carpal).

*Anterior.*

*Internal Lateral* (ulno-carpal).

*Posterior.*

**Describe the Carpal Articulations.** They are in 3 sets, (1) between the bones of the first row, (2) between the bones of the second row, (3) between the 2 rows of bones.

- (1) The scaphoid, semilunar, and cuneiform bones are connected together by 2 *Dorsal*, 2 *Palmar*, and 2 *Interosseous Ligaments*. The pisiform bone has a separate capsular ligament and synovial membrane and 2 *fasciculi* connecting it with the unciform and the 5th metacarpal.
- (2) The 4 bones of the second row are connected together by 3 *Dorsal*, 3 *Palmar*, and 3 *Interosseous Ligaments*.
- (3) The 2 rows of bones are united by a *Dorsal*, a *Palmar*, and 2 *Lateral Ligaments*, the last named being continuous with the lateral ligaments of the wrist-joint.

**Describe the Carpo-metacarpal Articulations.** That of the thumb with the trapezium is an enarthrodial joint, having a *Capsular Ligament* and a separate synovial membrane. The 4 inner metacarpal bones form 4 arthrodial joints with the adjacent carpal bones by 6 *Dorsal*, 8 *Palmar*, and 2 *Interosseous Ligaments*, irregularly disposed.

**Describe the Synovial Membranes of the Wrist.** They number 5, and are situated as follows, viz.—

*The First, or Membrana Sacciformis*, between the head of the ulna, the sigmoid cavity of the radius, and the triangular interarticular fibro-cartilage.

*The Second*, between the lower end of the radius, the triangular fibro-cartilage, and the scaphoid, semilunar, and cuneiform bones of the carpus.

*The Third*, between all the carpal bones except the pisiform, and between the bases of the inner 4 metacarpal bones; but it extends only halfway into the 2 intervals between the 3 proximal bones of the carpus.

*The Fourth*, between the trapezium and the metacarpal bone of the thumb.

*The Fifth*, between the cuneiform and pisiform bones.

**Describe the Metacarpo-metacarpal Articulations.** The 4 inner metacarpal bones are connected together at their bases by *Dorsal, Palmar, and Interosseous Ligaments*; and at their digital extremities by the *Transverse Ligament*.

**Describe the remaining Articulations of the Hand.** The metacarpophalangeal and the phalangeal articulations are all ginglymoid joints, and each has an *Anterior* and 2 *Lateral Ligaments*, the former being lined each with a synovial membrane. There are no posterior ligaments to these articulations, the extensor tendons of the hand supplying their places.

**Describe the Hip-joint.** It is a true enarthrodial articulation, formed by the head of the femur with the acetabulum of the os innominatum. Its *Synovial Membrane* is extensive, investing most of the head and neck of the femur, the capsular, cotyloid and teres ligaments, and the cavity of the acetabulum. Its *Arteries* are derived from the obturator, sciatic, internal circumflex, and gluteal. Its *Nerves* are branches from the sacral plexus, great sciatic, obturator, and accessory obturator. It has 5 ligaments, as follows, viz.—

*Capsular*, from the margin of the acetabulum and the transverse ligament, into the base of the neck of the femur above, the anterior inter-trochanteric line in front, and to the middle of the neck of the bone, behind.

*Ilio-femoral or Y-ligament*, from the anterior inferior spine of the ilium, into the anterior inter-trochanteric line by two fasciculi. It is a dissected portion of the capsular ligament which is very strong anteriorly.

*Ligamentum Teres*, from a depression on the head of the femur into the margins of the cotyloid notch of the acetabulum and into the transverse ligament, by two fasciculi.

*Cotyloid*, a fibro-cartilaginous band surrounding the margin of the acetabulum in order to deepen its cavity.

*Transverse*, that part of the cotyloid ligament which crosses over the cotyloid notch converting it into a foramen.

**Describe the Knee-joint.** It is a ginglymus articulation, formed by the condyles of the femur with the head of the tibia, and the patella in front. Its *Synovial Membrane* is the largest in the body, being reflected for 2 or 3 inches over the anterior surface of the femur, where it is supported by the subcrureus muscle, also over its condyles, the patella, semilunar cartilages, crucial ligaments, and head of the tibia; and is prolonged through an opening in the capsular ligament beneath the tendon of the popliteus. Its *Arteries* are derived from the anastomotica magna, the 5 articular branches of the popliteal, and the recurrent branch of the anterior tibial. Its *Nerves* are branches of the

obturator, anterior crural, external and internal popliteal. It has 14 ligaments, of which 6 are external and 8 internal, as follows:—

*Anterior, or Ligamentum Patellæ*, is a continuation of the tendon of the rectus femoris muscle, extending from the apex of the patella to the lower part of the tubercle of the tibia.

*Posterior, or Ligamentum Winslowii*,<sup>1</sup> from the inner tuberosity of the tibia to the external condyle of the femur, being partly derived from the tendon of the semimembranosus muscle.<sup>2</sup>

*Internal Lateral*,<sup>5</sup> from the internal condyle of the femur to the internal surface of the tibia and semilunar cartilage.

*External Lateral*,<sup>6</sup> from the external condyle of the femur to the head of the fibula. These ligaments are a *Long* anteriorly and a *Short* posteriorly, separated by the tendon of the biceps.

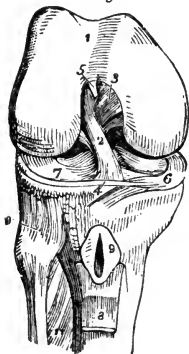
*Capsular*, is only present where intervals are left by the preceding ligaments. It is thin but very strong.

The Internal ligaments are as follows:—

*Anterior Crucial*,<sup>2</sup> from the depression in front of the spine of the tibia to the inner side of the *outer condyle* of the femur.

*Posterior Crucial*,<sup>3</sup> from the same depression, to the outer side of the *inner condyle*. [To remember the positions and insertions of these crucial ligaments, let the student cross his index fingers over each knee in succession; when over the right knee placing the right finger in front, when over the left knee the left finger in front. The positions of the fingers will then in each case correspond with those of the respective crucial ligaments.]

FIG. 36.



*Semilunar Fibro-cartilages*,<sup>6</sup> external and internal, are situated between the articular surfaces, and attached to the depressions in front and behind the spine of the tibia.

*Transverse*,<sup>4</sup> is a connecting slip between the semilunar fibro-cartilages anteriorly.

*Coronary*,<sup>7</sup> are short bands connecting the outer margins of the fibro-cartilages to the tibia and the adjacent ligaments.

*Ligamentum Mucosum*, is a triangular fold of the synovial membrane which at the lower border of the patella is given off to the intercondyloid notch of the femur.

*Ligamenta Alaria*, are fringes on the sides of the ligamentum mucosum, and are attached to the sides of the patella.

*Bursæ* in the vicinity of this joint are 5, viz.—1 under the ligamentum patellæ,<sup>9</sup> 1 between the patella and the skin; 1 between the internal lateral ligament and the tendons crossing it; sometimes 1 replacing the synovial pouch on the anterior surface of the femur; and occasionally 1 in the popliteal space replacing the synovial pouch usually situated therein.

**Describe the Tibio-fibular Articulations.** They are 3 in number, as follows, viz.—

**SUPERIOR TIBIO-FIBULAR ARTICULATION**, is an arthrodial joint, formed by the contiguous surfaces of the bones. It has a *Synovial Membrane* which is sometimes continuous with that of the knee-joint, and 2 ligaments, the—

*Anterior and Posterior Superior Tibio-fibular*,<sup>10</sup> which connect the head of the fibula with the outer tuberosity of the tibia.

**MIDDLE TIBIO-FIBULAR ARTICULATION.** The shafts of these bones do not touch each other, but are connected by the *Interosseous Membrane* extending between their contiguous borders, and perforated, above for the anterior tibial artery, below for the anterior peroneal vessels.

**INFERIOR TIBIO-FIBULAR ARTICULATION**, is an amphiarthrodial joint, formed by the contiguous rough surfaces on the bones. Its *Synovial Membrane* is derived from that of the ankle-joint, and it has 4 ligaments, viz.—

*Inferior Interosseous*, continuous with the interosseous membrane.

*Anterior and Posterior Inferior Tibio-fibular*, from the margins of the external malleolus to the front and back of the tibia.

*Transverse*, posteriorly between the 2 malleoli.

**Describe the Ankle-joint.** It is a ginglymoid articulation, formed by the lower ends of the tibia and fibula and their malleoli, with the astragalus. Its *Synovial Membrane* is prolonged upwards between the tibia and fibula for a short distance. Its *arteries* are derived from the malleolar branches of the anterior tibial and peroneal arteries; and its *Nerves* from the anterior tibial nerve. It has 3 ligaments, viz.—

*Anterior*, connecting the margins of the tibia and astragalus.

*Internal Lateral, or Deltoid Ligament*, from the internal malleolus to the 3 adjacent tarsal bones.

*External Lateral*, by anterior posterior and middle fasciculi, from the external malleolus to the astragalus and os calcis.

**Describe the Tarsal Articulations.** They are in 3 sets, (1) between the bones of the first row, (2) between the bones of the second row, (3) between the 2 rows of bones.

(1.) The astragalus and os calcis are united by 3 ligaments.

*External Calcaneo-astragaloid.*

*Interosseous.*

*Posterior Calcaneo-astragaloid.*

(2.) The scaphoid, cuboid, and three cuneiform bones are united by an irregular number of *Dorsal* and *Plantar* and 4 *Interosseus* ligaments, which latter are arranged transversely.

(3.) The 2 rows of bones are united by 7 ligaments viz.—

*Superior Astragalo-scaphoid.*                      *Inferior Calcaneo-scaphoid.*

*Superior Calcaneo-cuboid.*                      *Short Calcaneo-cuboid.*

*Superior Calcaneo-scaphoid.*                      *Long Calcaneo-cuboid.*

*Interosseous, or Internal Calcaneo-cuboid.*

**Describe the Tarso-metatarsal Articulations.** They are 5 arthrodial joints formed by the bases of the metatarsal bones with the adjacent bones of the tarsus, the 2d metatarsal bone articulating with all 3 cuneiform in the recess formed by the shortness of the second cuneiform. They are united by *Dorsal, Plantar, and 3 Interosseous Ligaments*. The 2d metatarsal bone has 3 dorsal ligaments, 1 from each cuneiform bone. The interosseous ligaments pass from the 2d and 3d metatarsal bones to the internal and external cuneiform.

**Describe the Synovial Membranes of the Tarsus and Metatarsus.** They are 6 in number, and are situated as follows, viz.—

*The First*, between the os calcis and the astragalus, behind the interosseous ligament.

*The Second*, between the same bones in front of the interosseous ligament, also between the astragalus and the scaphoid.

*The Third*, between the os calcis and the cuboid.

*The Fourth*, between the scaphoid and the 3 cuneiform bones, running backwards between the scaphoid and the cuboid, forwards between the cuneiform bones, between the external cuneiform and the cuboid, between the middle and external cuneiform and the bases of the 2d and 3d metatarsal, passing also between the bases of these bones and the 4th metatarsal.

*The Fifth*, between the cuboid and the 4th and 5th metatarsal bones, also running forwards between their bases.

*The Sixth*, between the internal cuneiform and the base of the 1st metatarsal bone.

**Describe the Metatarso-metatarsal Articulations.** The metatarsal bones are connected together, except the first, at their bases by *Dorsal, Plantar, and Interosseous Ligaments*; and all 5 are connected at their digital extremities by the *Transverse Metatarsal Ligament*.

**Describe the remaining Articulations of the Foot.** The metatarso-phalangeal and the phalangeal articulations are similar to those in the hand, each having an *Interior or Plantar, and 2 Lateral Ligaments*. The extensor tendons of the foot supply the places of posterior ligaments.



## THE MUSCLES AND FASCIÆ.

**What are the Muscles?** They are the active organs of locomotion, formed of bundles of reddish fibres endowed with the property of shortening themselves upon irritation, which is called *muscular contractility*, and chemically consisting of syntonin, or muscular fibrin.

**How are the Muscles divided?** Into 2 great classes, (1) *Voluntary, Striped, or Muscles of animal life*, comprise those which are under the control of the will. (2) *Involuntary, Unstriped, or Muscles of organic life*, are those which are not under the control of the will.

*Voluntary Muscular Fibre* consists of fasciculi about  $\frac{1}{400}$  inch in diameter, each surrounded by a tubular membranous sheath, the perimysium; and marked by fine striæ passing around them in curved parallel lines about  $\frac{1}{11000}$  inch apart. These fasciculi are formed of *fibrillæ*, each about  $\frac{1}{18000}$  inch thick, also striated, presenting the appearance of a row of minute particles, the "sarcois elements" of Bowman, and surrounded by cellular tissue, the sarcolemma.

*Involuntary Muscular Fibre* consists of flattened fusiform or spindle-shaped fibres, averaging about  $\frac{1}{4000}$  inch in breadth, consisting of elongated cells, and bound together in bundles by areolar tissue. These fibres are found in the alimentary canal, in the posterior wall of the trachea, in the bronchi, the ducts of certain glands, in the ureters, bladder, urethra, genitalia of both sexes, walls of all arteries and most veins and lymphatics, in the iris and ciliary muscle, and in the skin.

**What are Tendons and Aponeuroses?** *Tendons* are white, glistening cords or bands formed of white fibrous tissue almost entirely, have few vessels and no nerves, and serve to connect the muscles with the structures on which they act. *Aponeuroses* are fibrous membranes, of similar structure and appearance, and serve the same purpose.

**What are Fasciæ?** They are laminae of variable thickness which invest (*fascia*, a bandage) the softer structures. The superficial fascia is composed of fibro-areolar tissue, and is found beneath the skin almost over the whole body. The deep fascia is of aponeurotic structure, dense, inelastic, and fibrous, ensheathing the muscles and affording some of them attachment, also the vessels and nerves, and binding down the whole into a shapely mass.

**To what Structures are Muscles attached?** To the periosteum and perichondrium of bone and cartilage, to the subcutaneous areolar tissue, and to ligaments. In the latter case only are their tendons in direct contact with the tissue on which they are to act.

**How many Muscles are Doub'e-bellied?** Five,—the occipito-frontalis, biventer cervicis, digastric, omo-hyoid, and the diaphragm.

Describe each Muscle of the Body, giving its Origin, Insertion, Action, and Nervous supply.

### MUSCLES OF THE HEAD.

**Occipito-frontalis,** *from* the external two-thirds of the superior curved line of the occipital bone and the mastoid process of the temporal; also from the pyramidalis nasi, corrugator supercilii, and orbicularis palpebrarum fibres,—*into* an aponeurosis or “galea capitis,” which covers the vertex of the skull. *Action*, chiefly as a muscle of facial expression. *Nerves*, facial, supraorbital, small occipital.

**Attollens Aures,** *from* the occipito-frontalis aponeurosis,—*into* the pinna of the ear superiorly. *Action*, to raise the pinna. *Nerve*, small occipital branch of the cervical plexus.

**Attrahens Aures,** *from* the lateral cranial aponeurosis,—*into* the helix of the ear anteriorly. *Action*, to draw the pinna forwards. *Nerves*, facial, and auriculo-temporal branch of the inferior maxillary.

**Retrahens Aures,** *from* the mastoid process of the temporal bone,—*into* the concha. *Action*, to retract the pinna. *Nerve*, facial.

**Orbicularis Palpebrarum,** *from* the internal angular process of the frontal bone, the nasal process of the superior maxillary, and the borders of the tendo oculi,—*into* the skin of the eyelids, forehead, temple, and cheek, blending with the occipito-frontalis and the corrugator supercilii. *Action*, to close the eyelids. *Nerve*, facial.

**Corrugator Supercilii,** *from* the inner end of the superciliary ridge of the frontal bone,—*into* the orbicularis palpebrarum. *Action*, to draw eyebrow downwards and inwards. *Nerve*, facial.

**Tensor Tarsi** (Horner's muscle), *from* the crest of the lachrymal bone,—*into* the tarsal cartilages by two slips. *Action*, to compress the puncta lachrymalia against the globe of the eye, and to compress the lachrymal sac. *Nerve*, facial.

**Levator Palpebræ Superioris,** *from* the lesser wing of the sphenoid,—*into* the upper tarsal cartilage. *Action*, to lift the upper lid. *Nerve*, 3d cranial, or motor oculi.

**Rectus Superior,** *from* the upper margin of the optic foramen and the sheath of the optic nerve,—*into* the sclerotic coat. *Action*, to rotate the eyeball upwards. *Nerve*, 3d cranial.

**Rectus Inferior,** *from* the ligament of Zinn,—*into* the sclerotic coat. *Action*, rotates the eyeball downwards. *Nerve*, 3d cranial.

**Rectus Internus,** *from* the ligament of Zinn,—*into* the sclerotic coat. *Action*, rotates the eyeball inwards. *Nerve*, 3d cranial.

**Rectus Externus**, by 2 heads, the upper from the outer margin of the optic foramen, the lower from the ligament of Zinn and a bony process at lower margin of the sphenoidal fissure,—into the sclerotic coat. *Action*, to rotate the eyeball outwards. *Nerve*, 6th cranial, or abducens.

Between the 2 heads of the external rectus pass the 3d, nasal branch of the 5th, and the 6th cranial nerves, and the ophthalmic vein.

**Obliquus Superior**, from about a line above the inner margin of the optic foramen, its tendon passing through a "pulley" near the internal angular process of the frontal bone and thence beneath the rectus superior,—into the sclerotic coat at right angles to the insertion of the rectus superior. *Action*, to rotate the eyeball on its antero-posterior axis. *Nerve*, 4th cranial, or patheticus.

**Obliquus Inferior**, from the orbital plate of the superior maxillary,—into the sclerotic coat below the insertion of the external rectus and at right angles thereto. *Action*, to rotate the eye on its antero-posterior axis. *Nerve*, 3d cranial.

**Pyramidalis Nasi**,<sup>c</sup> from the occipito-frontalis,—into the compressor naris. *Action*, to depress the eyebrow. *Nerve*, facial.

**Levator Labii Superioris Alæque Nasi**,<sup>e</sup> from the nasal process of the superior maxillary bone,—into the cartilage of the ala of the nose and into the upper lip. *Action*, to elevate the upper lip, and dilate the nostril. *Nerve*, facial.

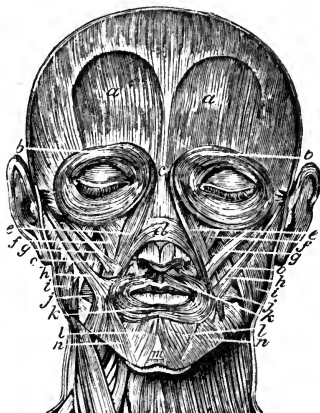
**Dilator Naris Anterior**, from the cartilage of the ala,—into the border of its integument. *Action*, to dilate the nostril. *Nerve*, facial.

**Dilator Naris Posterior**, from the nasal notch of the superior maxillary and the sesamoid cartilages,—into the integument at the margin of the nostril. *Action*, to dilate the nostril. *Nerve*, facial.

**Compressor Naris**,<sup>d</sup> from the superior maxillary above the incisive fossa,—into the fibro-cartilage of the nose, being continuous with its fellow and the pyramidalis nasi aponeurosis. *Action*, to dilate the nostril. *Nerve*, facial.

**Compressor Narium Minor**, from the alar cartilage,—into the skin at the end of the nose. *Action*, to dilate the nostril. *Nerve*, facial.

FIG. 37.



- Depressor Alæ Nasi**, *from* the incisive fossa of the superior maxillary,—*into* the septum and ala of the nose. *Action*, to contract the nostril. *Nerve*, facial.
- Levator Labii Superioris**, *f* *from* the lower margin of the orbit,—*into* the upper lip. *Action*, to elevate the lip. *Nerve*, facial.
- Levator Anguli Oris**, *o* *from* the canine fossa of the superior maxillary,—*into* the angle of the mouth. *Action*, as named. *Nerve*, facial.
- Zygomaticus Major**, *h* *from* the malar bone,—*into* the angle of the mouth. *Action*, to raise the lip outwards. *Nerve*, facial.
- Zygomaticus Minor**, *g* *from* the malar bone anteriorly,—*into* the angle of the mouth, blending with the levator labii superioris. *Action*, to raise the lip outwards. *Nerve*, facial.
- Levator Labii Inferioris**<sup>m</sup> (Levator Menti), *from* the incisive fossa of the inferior maxillary bone,—*into* the integument of the chin. *Action*, as named. *Nerve*, facial.
- Depressor Labii Inferioris**<sup>l</sup> (Quadratus Menti), *from* the external oblique line of the inferior maxillary bone,—*into* the lower lip. *Action*, as named. *Nerve*, facial.
- Depressor Anguli Oris**<sup>n</sup> (Triangularis Menti), *from* the external oblique line of the inferior maxillary,—*into* the angle of the mouth. *Action*, as named. *Nerve*, facial.
- Orbicularis Oris**, *k* *by* accessory fibres (accessorii orbicularis superioris and inferioris, and naso-labialis) *from* the nasal septum and the superior and inferior maxillary borders,—*into* the buccinator and other adjacent muscles, forming the sphincter of the mouth. *Action*, to close the mouth. *Nerve*, facial.
- Buccinator**, *j* *from* the posterior alveolar processes of both the maxillary bones and the pterygo-maxillary ligament,—*into* the orbicularis oris. *Action*, to compress the cheeks. *Nerves*, facial, and the buccal branch of the inferior maxillary.
- Risorius**, *from* the fascia over the masseter muscle,—*into* the angle of the mouth. *Action*, the laughing muscle. *Nerve*, facial.
- Masseter**, *i* *from* the anterior two-thirds and the inner surface of the zygoma and the malar process of the superior maxillary,—*into* the angle, ramus, and coronoid process of the lower jaw. *Action*, to raise the back part of the lower jaw; a muscle of mastication. *Nerve*, inferior maxillary.
- Temporal**, *from* the temporal fossa and temporal fascia,—*into* the coronoid process of the inferior maxillary. *Action*, to bring the incisor teeth together; the biting muscle. *Nerve*, inferior maxillary.

**Internal Pterygoid**, *from* the pterygoid fossa of the sphenoid bone, and the tuberosity of the palate,—*into* the angle and inner surface of the ramus of the jaw, as high as the dental foramen. *Action*, raises and draws forward the lower jaw; a triturating muscle of mastication. *Nerve*, inferior maxillary.

**External Pterygoid**, by 2 heads, *the upper*, from the pterygoid ridge on the greater wing of the sphenoid, *the lower* from the external pterygoid plate, and the tuberosities of the palate and superior maxillary bones,—*into* a depression in front of the condyle of the inferior maxillary, and the inter-articular fibro-cartilage. *Action*, to draw the jaw forwards; a triturating muscle of mastication. *Nerve*, inferior maxillary.

Between the two heads of the external pterygoid muscle passes the internal maxillary artery.

### MUSCLES OF THE EAR.

**Tensor Tympani**, *from* the under surface of the petrous portion of the temporal bone, the cartilaginous Eustachian tube, and its own osseous canal,—*into* the handle of the malleus. *Action*, to draw the membrana tympani tense. *Nerve*, branch from otic ganglion.

**Laxator Tympani Major**, *from* the spinous process of the sphenoid and the cartilaginous Eustachian tube,—through the Glasserian fissure to the neck of the malleus just above the processus gracilis. *Action*, to relax the membrana tympani. *Nerve*, tympanic branch of the facial.

**Laxator Tympani Minor**, *from* the back of the external meatus,—passes between the layers of the membrana tympani *into* the handle of the malleus and processus brevis. *Action*, to relax the membrana tympani. Considered a ligament by many anatomists (the lig. mallei posticum).

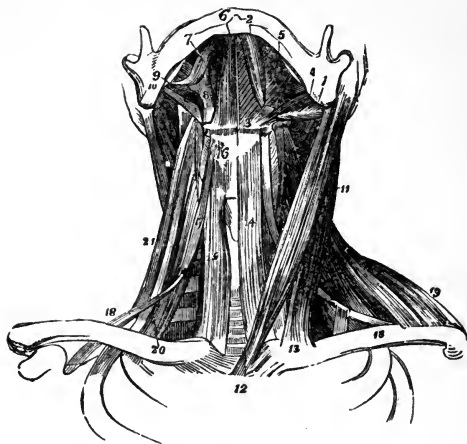
**Stapedius**, *from* the interior of the pyramid,—through the orifice at its apex *into* the neck of the stapes. *Action*, to depress the base of the stapes. *Nerve*, filament from the facial.

### MUSCLES OF THE NECK.

**Platysma Myoides**, *from* the clavicle, the acromion, and the fascia covering the pectoral, deltoid, and trapezius muscles,—*into* the lower jaw, the angle of the mouth, and the cellular tissue of the face. *Action*, to wrinkle the skin, and depress the mouth. *Nerves*, facial and superficial cervical.

**Sterno-cleido-mastoid**,<sup>11</sup> by two heads from the sternum<sup>12</sup> and the clavicle<sup>13</sup> at its inner third,—*into* the mastoid process of the temporal bone, and the superior curved line of the occipital. *Action*, to depress and rotate the head. *Nerves*, spinal accessory, and branches of the cervical plexus.

FIG. 38.



Between the sternal and clavicular origins is a fossa, the *fonticulus gutturis*, which rises and falls during labored breathing.

**Sterno-hyoid,**<sup>14</sup> from the posterior surface of the sternum and the sternal end of the clavicle,—into the body of the hyoid bone. *Action*, to depress the hyoid bone. *Nerve*, a branch from the communicating loop between the descendens and communicans noni.

**Sterno-thyroid,**<sup>15</sup> from the posterior surface of the sternum and the cartilage of the 1st rib,—into the oblique line on the ala of the thyroid cartilage. *Action*, to depress the larynx. *Nerve*, a branch from the communicating loop between the descendens and communicans noni.

**Thyro-hyoid,**<sup>16</sup> from the oblique line on the thyroid cartilage,—into the body and greater cornu of the hyoid bone. *Action*, to elevate the larynx. *Nerve*, hypoglossal.

**Omo-hyoid,**<sup>17</sup> <sup>18</sup> from the upper border of the scapula and the transverse ligament,—into the body of the hyoid bone. It has a tendon in its centre which is bound down to the cartilage of the 1st rib by a loop of the deep cervical fascia. *Action*, to depress the hyoid bone, and draw it backwards. *Nerve*, branch from the communicating loop between the descendens and communicans noni.

**Digastric**, by 2 bellies, the *posterior one*<sup>1</sup> from the digastric groove of the mastoid process of the temporal bone; the *anterior*<sup>2</sup> from a fossa on the inner surface of the inferior maxillary, near its symphysis,—into a central tendon<sup>3</sup> which perforates the stylo-hyoid muscle, and is bound down to the body of the hyoid bone by an aponeurotic loop. *Action*, to raise the hyoid bone and tongue. *Nerves*, facial, and mylo-hyoid branch of the inferior dental.

**Stylo-hyoid,**<sup>4</sup> from the styloid process of the temporal bone near its base,—into the body of the hyoid bone. *Action*, to elevate and retract the hyoid bone. *Nerve*, facial. This muscle is perforated by the digastric.

**Mylo-hyoid**,<sup>5</sup> *from* the mylo-hyoid ridge of the lower jaw,—*into* the body of the hyoid bone and a fibrous raphé in the median line running from the hyoid bone to the chin. *Action*, elevates the hyoid bone and draws it forwards, also forms the floor of the mouth. *Nerve*, mylo-hyoid branch of inferior dental.

**Genio-hyoid**,<sup>6</sup> *from* the inferior genial tubercle of the inferior maxillary,—*into* the body of the hyoid bone. *Action*, same as the mylo-hyoid. *Nerve*, hypoglossal.

**Genio-hyo-glossus**, *from* the superior genial tubercle of the inferior maxillary,—*into* the body of the hyoid bone, the side of the pharynx, and the whole length of the under surface of the tongue, forming a fan-like muscle. *Action*, to retract and protrude the tongue. *Nerve*, hypoglossal.

**Hyo-glossus**<sup>8</sup> (the basio-kerato-chondro-glossus), *from* the body of the hyoid bone, its lesser cornu, and the whole length of its greater cornu,—*into* the side of the tongue. *Action*, to draw down the side of the tongue. *Nerve*, hypoglossal.

**Stylo-glossus**,<sup>9</sup> *from* the styloid process and the stylo-maxillary ligament,—*into* the side of the tongue and the hyo-glossus muscle. *Action*, to elevate and retract the tongue. *Nerve*, hypoglossal.

**Lingualis**, lies between the hyo-glossus and the genio-hyo-glossus, *from* the base to the tip of the tongue, along its under surface; some of its fibres being attached to the hyoid bone. *Action*, to elevate the centre of the tongue. *Nerve*, chorda tympani.

**Inferior Constrictor**, *from* the sides of the cricoid and thyroid cartilages,—*into* the fibrous raphé of the pharynx. *Action*, to contract the pharyngeal calibre. *Nerves*, glosso-pharyngeal, pharyngeal plexus, and external laryngeal.

**Middle Constrictor**, *from* the cornua of the hyoid bone and the stylo-hyoid ligament,—*into* the pharyngeal raphé. *Action*, to constrict the pharynx. *Nerves*, glosso-pharyngeal, pharyngeal plexus.

**Superior Constrictor**, *from* the lower third of the margin of the internal pterygoid plate and its hamular process, the contiguous part of the palate bone, the tendon of the tensor palati, the pterygo-maxillary ligament, part of the alveolar process of the lower jaw and the side of the tongue,—*into* the pharyngeal raphé and the pharyngeal spine of the occipital bone. *Action*, to constrict the pharynx. *Nerves*, glosso-pharyngeal, pharyngeal plexus.

**Stylo-pharyngeus**,<sup>10</sup> *from* the inner side of the base of the styloid process,—*into* the constrictor and palato-pharyngeus muscles, and the thyroid car-

tilage. *Action*, to elevate the pharynx. *Nerves*, glosso-pharyngeal, pharyngeal plexus. The former nerve crosses this muscle in passing to the tongue.

**Levator Palati**, *from* the under surface of the apex of the petrous portion of the temporal bone and from the Eustachian tube,—*into* the posterior surface of the soft palate. *Action*, to elevate the soft palate. *Nerve*, facial, through the Vidian and petrosal.

**Tensor Palati**, *from* the scaphoid fossa of the sphenoid bone and the Eustachian tube,—reflected around the hamular process,—*into* the anterior surface of the soft palate, and the horizontal portion of the palate bone. *Action*, to tense the palate. *Nerve*, a branch from the otic ganglion.

**Azygos Uvulæ**, *from* the posterior nasal spine of the palate bone, and from the soft palate,—*into* the uvula. *Action*, possibly to raise the uvula. *Nerve*, facial, through the Vidian and petrosal. This muscle is wrongly named, as it is double.

**Palato-glossus** (anterior pillar of the fauces), *from* the anterior surface of the soft palate laterally,—*into* the side and dorsum of the tongue. *Action*, constrictor isthmi faucium. *Nerves*, palatine branches of Meckel's ganglion.

**Palato-pharyngeus** (posterior pillar of the fauces), *from* the soft palate,—*into* the side of the pharynx and the posterior border of the thyroid cartilage, having joined the stylo-pharyngeus. *Action*, to close the posterior nares. *Nerves*, palatine branches from Meckel's ganglion.

**Rectus Capitis Anti'cus Major**, *from* the anterior tubercles of the transverse processes of the 3d, 4th, 5th, and 6th cervical vertebræ by 4 slips,—*into* the basilar process of the occipital bone. *Action*, to flex the head. *Nerves*, sub-occipital and deep branches of cervical plexus. This muscle is a continuation of the scalenus anticus.

**Rectus Capitis Anti'cus Minor**, *from* the anterior surface of the lateral mass of the atlas, and the root of its transverse process,—*into* the basilar process of the occipital bone. *Action*, to flex the head. *Nerves*, sub-occipital and deep branches of the cervical plexus.

**Rectus Lateralis**, *from* the upper surface of the transverse process of the atlas,—*into* the jugular process of the occipital bone. *Action*, to draw the head laterally. *Nerve*, sub-occipital.

**Longus Colli**, 3 portions,—*the superior oblique*, from the anterior tubercles of the transverse processes of the 3d, 4th, and 5th cervical vertebræ, into a tubercle on the anterior arch of the atlas:—*inferior oblique*, from the bodies of the first 2 or 3 dorsal vertebræ, into the transverse processes of the 5th and 6th cervical:—*vertical portion* from the bodies of the lower 3 cervical and upper 3 dorsal vertebræ, to the bodies of the 2d, 3d, and 4th cervical.



*Action*, to flex the cervical vertebræ and slightly to rotate them. *Nerves*, branches from the lower cervical.

**Scalenus Anti'cus**,<sup>20</sup> *from* a tubercle on the upper surface of the 1st rib,—*into* the transverse processes of the cervical vertebræ, from the 3d to the 6th inclusive. *Action*, to flex the neck laterally, or to raise the 1st rib. *Nerves*, branches from the lower cervical. (See Fig. 38.)

**Scalenus Medius**,<sup>22</sup> *from* the upper surface of the 1st rib, behind the subclavian groove,—*into* the transverse processes of the lower 6 cervical vertebræ. *Action*, same as scalenus anticus. *Nerves*, branches from the lower cervical.

**Scalenus Posti'cus**,<sup>21</sup> *from* the outer surface of the 2d rib,—*into* the posterior tubercles on the transverse processes of the lower 2 or 3 cervical vertebræ. *Action*, to flex the neck laterally, or to elevate the 2d rib. *Nerves*, branches from lower cervical.

#### MUSCLES OF THE LARYNX AND EPIGLOTTIS.

**Crico-thyroid**, *from* the front and side of the cricoid cartilage,—*into* the lower and inner borders of the thyroid cartilage. *Action*, to elongate and make tense the vocal chords. *Nerve*, superior laryngeal.

**Crico-arytenoideus Posticus**, *from* the cricoid cartilage posteriorly,—*into* the outer angle of the base of the arytenoid cartilage. *Action*, to rotate the arytenoid cartilages outwards and open the glottis, while keeping the vocal chords tense. *Nerve*, recurrent laryngeal.

**Crico-arytenoideus Lateralis**, *from* the upper border of the cricoid cartilage laterally,—*into* the outer angle of the base of the arytenoid cartilage. *Action*, to rotate the arytenoid cartilages inwards and close the glottis. *Nerve*, recurrent laryngeal.

**Thyro-arytenoideus**, *from* the receding angle of the thyroid cartilage and the crico-thyroid membrane,—*into* the base and anterior surface of the arytenoid cartilage. *Action*, to shorten and relax the vocal chords by approximating the cartilages. *Nerve*, recurrent laryngeal.

**Arytenoideus**, *from* the posterior surface and outer border of one arytenoid cartilage,—*into* the corresponding parts of the opposite cartilage, filling up the posterior concave surface of these cartilages. *Action*, by approximating the arytenoids, to close the back part of the glottis. *Nerves*, superior and recurrent laryngeal.

**Thyro-epiglottideus**, *from* the inner surface of the thyroid cartilage,—*into* the margin of the epiglottis and the aryteno-epiglottidean fold. *Action*, a depressor of the epiglottis. *Nerve*, recurrent laryngeal.

**Aryteno-epiglottideus Superior**, *from* the apex of the arytenoid cartilage,—*into* the aryteno-epiglottidean folds. *Action*, to constrict the superior laryngeal aperture. *Nerve*, recurrent laryngeal.

**Aryteno-epiglottideus Inferior**, *from* the arytenoid cartilage anteriorly,—*into* the sacculus laryngis and the margin of the epiglottis. *Action*, to compress the sacculus laryngis. *Nerve*, recurrent laryngeal.

### MUSCLES OF THE BACK.

**First layer (2)**—*Trapezius. Latissimus Dorsi.*

**Second layer (3)**—*Levator Anguli Scapulæ. Rhomboideus Major and Minor.*

**Third layer (3)**—*Serratus Posticus Superior. Serratus Posticus Inferior. Splenius Capitis et Colli.*

**Fourth layer (11)**—in 4 sets, viz.—

LUMBAR (1)—*Erector Spinæ.*

EXTERNAL (3).	MIDDLE (3).	INTERNAL (4).
<i>Sacro lumbalis.</i>	<i>Longissimus Dorsi.</i>	<i>Spinalis Dorsi.</i>
<i>Musculus Accessorius ad Sacro-lumbalem.</i>	<i>Transversalis Colli.</i>	<i>Spinalis Colli.</i>
<i>Cervicalis Ascendens.</i>	<i>Trachelo-mastoid.</i>	<i>Biventer Cervicis.</i>
		<i>Complexus.</i>

**Fifth layer (12)**—6 having the word *spinal* in them, viz.—

<i>Semi-spinalis Dorsi.</i>	<i>Inter-transversales.</i>
<i>Semi-spinalis Colli.</i>	<i>Rectus Capitis Posticus Major.</i>
<i>Multifidus Spinæ.</i>	<i>Rectus Capitis Posticus Minor.</i>
<i>Rotatores Spinæ.</i>	<i>Obliquus Capitis Superior.</i>
<i>Supra-spinales.</i>	<i>Obliquus Capitis Inferior.</i>
<i>Inter-spinales.</i>	<i>Extensor Coccygis.</i>

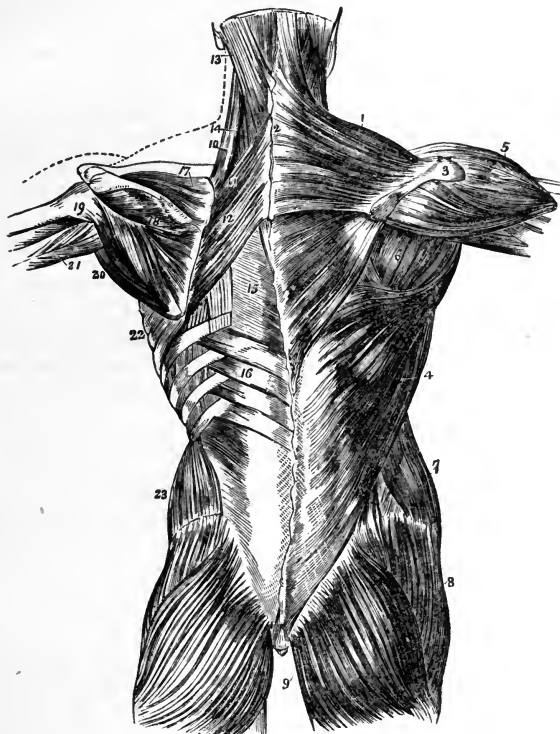
**Trapezius**,<sup>1</sup> *from* the inner third of the superior curved line of the occipital bone, the ligamentum nuchæ,<sup>2</sup> the spinous processes of the last cervical and all the dorsal vertebræ, and the supra-spinous ligament,—*into* the outer third of the posterior border of the clavicle, the superior margin of the acromion process, the whole length of the superior border of the spine of the scapula,<sup>3</sup> and a tubercle at its inner extremity. *Action*, to draw the head backwards. *Nerves*, spinal accessory, cervical plexus.

**LIGAMENTUM NUCHÆ**, *from* the external occipital protuberance,—*to* the spines of the cervical vertebræ, from the 2d to the 7th inclusive.

**Latissimus Dorsi**,<sup>4</sup> by an aponeurosis *from* the spines of the 6 lower dorsal and the lumbar and sacral vertebræ, the supra-spinous ligament, the crest of the ilium, and the 3 or 4 lower ribs,—*into* the bicipital groove of the humerus. *Action*, the *cursor ani* muscle, drawing the arm downwards and backwards; or raising the lower ribs and drawing the trunk forwards. *Nerves*, the subscapular.

**Levator Anguli Scapulæ**,<sup>10</sup> by 4 slips from the transverse processes of 3 or 4 upper cervical vertebræ,—into the posterior border of the scapula. *Action*, as named. *Nerves*, branches from the 5th cervical and the cervical plexus.

FIG. 39.



**Rhomboideus Minor**,<sup>11</sup> from the ligamentum nuchæ and spines of the 7th cervical and 1st dorsal vertebræ,—into the smooth surface at the root of the spine of the scapula. *Action*, to draw the scapula backwards and upwards. *Nerve*, 5th cervical.

**Rhomboideus Major**,<sup>12</sup> from the spines of the 4 or 5 upper dorsal vertebræ and the supra-spinous ligament,—into the scapula at the root of its spine and inferior angle, by a tendinous arch. *Action*, to draw the scapula upwards and backwards. *Nerve*, 5th cervical.

**Serratus Posticus Superior**, from the ligamentum nuchæ, and spines of the 7th cervical and 2 or 3 upper dorsal vertebræ,—into the upper borders of the 2d, 3d, 4th, and 5th ribs, by 4 digitations. *Action*, to raise ribs in inspiration. *Nerves*, external posterior branches of the cervical nerves.

**Serratus Posticus Inferior**,<sup>16</sup> from the spines of the last 2 dorsal and first 3 lumbar vertebræ,—into the lower borders of the 4 lower ribs, by 4 digitations. *Action*, to depress these ribs in expiration. *Nerves*, external branches of the dorsal nerves.

**Splenius Capitis**<sup>13</sup> et **Colli**,<sup>14</sup> from the lower half of the ligamentum nuchæ, the last cervical and 6 upper dorsal spines, and the supra-spinous ligament,—the *S. capitis* into the mastoid process and a rough surface below the superior curved line of the occipital bone,—the *S. colli* into the transverse processes of the 3 or 4 upper cervical vertebræ. *Action*, to draw the head backwards and the neck erect. *Nerves*, external posterior branches of the cervical nerves.

**Erector Spinæ**,<sup>1</sup> from the sacro-iliac groove, and by the lumbo-sacral tendon from the sacral, lumbar and 3 lower dorsal spines, the iliac crest, and the posterior eminences of the sacrum,—divides into the sacro-lumbalis<sup>2</sup> and longissimus dorsi<sup>3</sup> muscles. *Action*, to erect the spine and bend the trunk backwards. *Nerves*, external posterior branches of the lumbar nerves.

**Sacro-lumbalis**,<sup>2</sup> from the erector spinæ,—into the angles of the 6 lower ribs. *Action*, as the erector spinæ. *Nerves*, branches of the dorsal.

**Musculus Accessorius ad Sacro-lumbalem**,<sup>2</sup> from the angles of 6 lower ribs,—into the angles of 6 upper ribs. *Action*, as the erector spinæ. *Nerves*, branches of the dorsal.

**Cervicalis Ascendens**,<sup>5</sup> from the angles of 4 or 5 upper ribs,—into the transverse processes of the 4th, 5th, and 6th cervical vertebræ. *Action*, to keep the neck erect. *Nerves*, branches of the cervical.

**Longissimus Dorsi**,<sup>3</sup> from the erector spinæ,—into the transverse and articular processes of the lumbar vertebræ, into the tips of the transverse processes of all the dorsal vertebræ, and into from 7 to 11 ribs between their tubercles and angles. *Action*, as the erector spinæ. *Nerves*, branches of the lumbar and dorsal nerves.

**Transversalis Colli**,<sup>6</sup> from the transverse processes of the 3d, 4th, 5th, and 6th dorsal vertebræ,—into the transverse processes of the 5 lower cervical.<sup>9</sup> *Action*, to keep the neck erect. *Nerves*, cervical branches.

**Trachelo-mastoid**,<sup>7</sup> from the transverse processes of the 3d, 4th, 5th, and 6th dorsal vertebræ, and the articular processes of the 3 or 4 lower cervical,—into the posterior margin of the mastoid process. *Action*, to steady the head. *Nerves*, branches of the cervical.

**Spinalis Dorsi**, from the last 2 dorsal and first 2 lumbar spines,—into all the remaining dorsal spines. *Action*, to erect the spinal column. *Nerves*, branches of the dorsal.

**Spinalis Colli**, from the 5th and 6th cervical spines, sometimes from the 1st and 2d dorsal,—into the spine of the axis, or the 3d and 4th cervical spines. *Action*, to steady the neck. *Nerves*, branches of the cervical. [This muscle is frequently absent.]

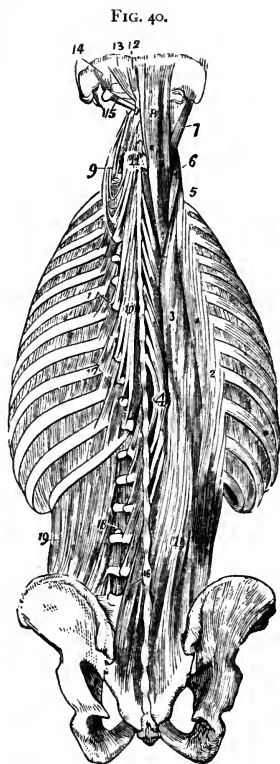
**Biventer Cervicis**, from the transverse processes of 2 to 4 upper dorsal vertebræ,—into the superior curved line of the occipital bone. [Is but a portion of the complexus muscle.]

**Complexus**,<sup>8</sup> by 7 tendons from the tips of the transverse processes of the 7th cervical and 3 upper dorsal vertebræ, and from the articular processes of the 4th, 5th, and 6th cervical,—into the inner depression between the curved lines of the occipital bone. *Action*, to retract and rotate the head. *Nerves*, suboccipital, great occipital, and branches of the cervical nerves.

**Semispinalis Dorsi**,<sup>10</sup> from the transverse processes of the dorsal vertebræ, from about the 5th to the 11th,—into the last 2 cervical and 4 upper dorsal spines. *Action*, to erect the spinal column. *Nerves*, branches of the dorsal nerves.

**Semispinalis Colli**,<sup>11</sup> from the transverse processes of the 4 upper dorsal vertebræ, and the articular processes of the 4 lower cervical,—into the 2d, 3d, 4th, and 5th cervical spines. *Action*, to erect the spinal column. *Nerves*, branches of the cervical.

**Multifidus Spinæ**,<sup>16</sup> from the back of the sacrum, posterior superior spine of the ilium, posterior sacro-iliac ligaments, articular processes of lumbar and cervical vertebræ, and the transverse processes of the dorsal,—into the laminae and spines of the next 4 vertebræ above. *Action*, to erect and rotate the spinal column. *Nerves*, posterior spinal branches.



**Rotatores Spinæ** (11), *from* the transverse processes of the dorsal vertebræ, from the 2d to the 12th inclusive,—each *into* the lamina of the next dorsal vertebræ above. *Action*, to rotate the spinal column. *Nerves*, branches of the dorsal.

**Supra-spinales**, lie on the spinous processes in the cervical region. *Nerves*, branches of the cervical.

**Inter-spinales**, placed in pairs between the spines of contiguous vertebræ, 6 pairs in the cervical region, 3 in the dorsal, 4, sometimes 6, in the lumbar. *Nerves*, posterior spinal branches.

**Inter-transversales**,<sup>18</sup> placed between the transverse processes of contiguous vertebræ, 7 in the cervical region, 12 in the dorsal, and 4 in the lumbar. *Nerves*, posterior spinal branches.

**Rectus Capitis Posticus Major**,<sup>13</sup> *from* the spine of the axis,—*into* the inferior curved line of the occipital bone and the surface below. *Action*, to rotate the head. *Nerves*, sub- and great occipital.

**Rectus Capitis Posticus Minor**,<sup>12</sup> *from* the tubercle on the posterior arch of the atlas,—*into* a rough surface between the foramen magnum and the inferior curved line of the occipital bone. *Action*, to draw the head backwards. *Nerves*, sub- and great occipital.

**Obliquus Capitis Inferior**,<sup>15</sup> *from* the spinous process of the axis,—almost horizontally to the transverse process of the atlas. *Action*, to rotate the atlas and cranium. *Nerves*, sub- and great occipital.

**Obliquus Capitis Superior**,<sup>14</sup> *from* the transverse process of the atlas;—upwards and inwards *into* the occipital bone between the curved lines. *Action*, draws the head backwards. *Nerves*, sub- and great occipital.

**Extensor Coccygis**, *from* the last bone of the sacrum or first of the coccyx,—*into* the lower part of the coccyx, posteriorly. *Action*, as named. *Nerves*, posterior sacral branches.

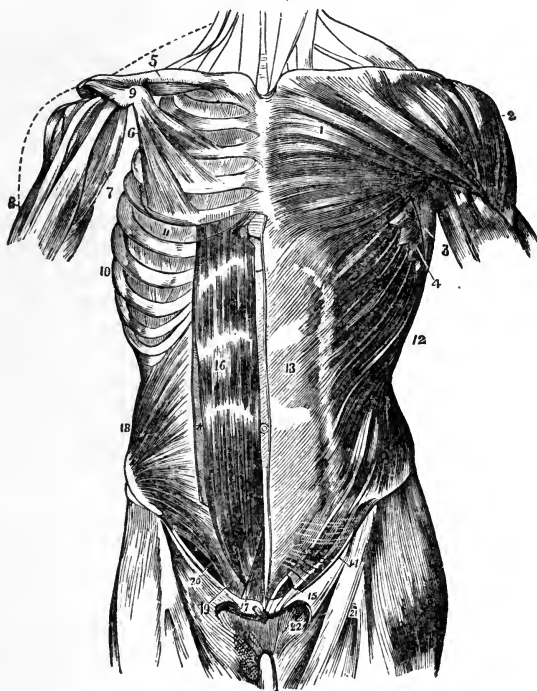
#### MUSCLES OF THE ABDOMEN.

**External Oblique**,<sup>12</sup> *from* 8 lower ribs by 8 fleshy digitations,—*into* the anterior half of the outer lip of the crest of the ilium, and by a broad aponeurosis,<sup>13</sup> *into* the ensiform cartilage, linea alba, symphysis, and spine of the pubes, and the pectineal line. Its aponeurosis is continuous with that of the pectoralis major above, and below it forms Poupart's<sup>14</sup> and Gimbernat's ligaments, and by the separation of its fibres, the external abdominal ring.<sup>15</sup> *Action*, to compress the viscera, and flex the thorax on the pelvis, and *vice versa*. *Nerves*, lower intercostal, ilio-hypogastric, and ilio-inguinal.

**Internal Oblique**,<sup>18</sup> *from* the lumbar fascia, the anterior two-thirds of the middle lip of the crest of the ilium, and the outer half of Poupart's liga-

ment,—into the cartilages of 4 lower ribs; by its aponeurosis into the linea alba; and leaving an arched border<sup>20</sup> over the spermatic cord, by the conjoined tendon<sup>19</sup> with the transversalis into the pubic crest and the pectineal line. Its aponeurosis splits at the rectus abdominis for its upper three-fourths, one layer passing in front, the other behind that muscle, to unite again at the linea alba; for its lower one-fourth it passes in front of the rectus. *Action and Nerves*, same as the external oblique.

FIG. 41.



**Transversalis**, from the outer one-third of Poupart's ligament, the anterior two-thirds of the inner lip of the crest of the ilium, the cartilages of 6 lower ribs, and an aponeurosis from the spines and transverse processes of the lumbar vertebræ,—by its aponeurosis into the linea alba, and by the conjoined tendon<sup>19</sup> with the internal oblique, into the pubic crest and the pectineal line. Its aponeurosis passes behind the rectus abdominis for its upper three-fourths, in front of that muscle for its lower one-fourth.

**LUMBAR FASCIA**, or vertebral aponeurosis of the transversalis, divides into 3 leaflets, the *anterior* and *middle* being attached to the apices of the transverse processes of the lumbar vertebræ, the *posterior* leaflet to the apices of their spines. The anterior and middle leaflets enclose the quadratus lumborum muscle, the middle and posterior enclose the erector spinæ.

**Rectus Abdominis**,<sup>16</sup> by 2 tendons from the pubic crest and the ligaments covering the symphysis,—*into* the cartilages of the 5th, 6th, and 7th ribs. It lies in a sheath formed by the aponeuroses of the internal oblique and transversalis muscles for its upper three-fourths, and is crossed by 2 to 5 tendinous lines, the *Lineæ Transversæ*. At its outer border is a similar line placed vertically, the *Linea Semilunaris*, formed by the aponeurosis of the internal oblique at its point of division. *Action*, to flex the thorax on the pelvis and *vice versâ*, also to compress the abdominal viscera. *Nerves*, same as the external oblique.

**Pyramidalis**,<sup>17</sup> lies in front of the rectus, but in the same sheath, arises *from* the front of the pubic bone and the anterior pubic ligament,—*into* the linea alba, half-way to the umbilicus. *Action*, a tensor of the linea alba. *Nerves*, same as the external oblique.

**Quadratus Lumborum**,<sup>19</sup> Fig. 40 *from* the ilio-lumbar ligament, adjacent 2 inches of the crest of the ilium, and transverse processes of the lower 3 lumbar vertebræ,—*into* one-half of the lower border of the last rib, and the transverse processes of the last 3 lumbar vertebræ. *Action*, to flex the thorax laterally on the pelvis and *vice versâ*. *Nerves*, anterior branches of the lumbar.

## MUSCLES OF THE THORAX.

**External Intercostals** (II), each *from* the outer lip of the groove in the inferior costal border,—*into* the upper border of the next rib below, directed obliquely downwards and forwards. *Action*, to raise and evert the ribs in inspiration. *Nerves*, intercostal.

**Internal Intercostals** (II), each *from* the inner lip of the groove in the inferior costal border,—*into* the upper border of the rib below, directed obliquely downwards and backwards. *Action*, at sides of thorax to depress the ribs in expiration; anteriorly they raise the costal cartilages. *Nerves*, intercostals.

**Infra-costales** (IO), obliquely *from* inner surface of 1 rib,—*into* the inner surface of the 1st, 2d, or 3d rib below. *Action*, muscles of inspiration. *Nerves*, intercostal.

**Triangularis Sterni**, *from* the inner surface of the ensiform cartilage, inner surfaces of costal cartilages of 3 or 4 lower true ribs, and lower sides of the



sternum,—into the lower border and inner surfaces of the 2d, 3d, 4th, and 5th costal cartilages. *Action*, to draw down the cartilages in expiration. *Nerves*, intercostal.

**Levatores Costarum**,<sup>17</sup> Fig. 40 (12), each from the transverse process of a dorsal vertebra,—into the upper surface of the next rib below, near its angle. *Action*, to raise the ribs. *Nerves*, intercostal.

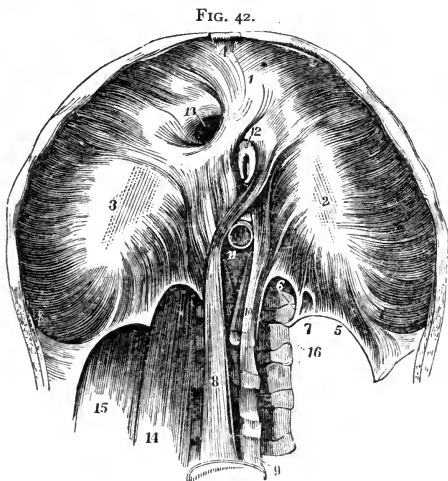
**Diaphragm**, from the ensiform cartilage,<sup>4</sup> inner surfaces of 6 or 7 lower ribs, ligamenta arcuata,<sup>5</sup> and by its crura<sup>8 10</sup> from the bodies of the lumbar vertebræ, from the 2d to the 4th on the right side, the 2d and 3d on the left,—into the central or cordiform tendon.<sup>2 3</sup> *Action*, the great muscle of respiration and expulsion. *Nerve*, the phrenic.

*Openings of the Diaphragm.*

*The Aortic*,<sup>11</sup> in the middle line posteriorly, and behind the diaphragm; transmits the aorta, vena azygos major, and thoracic duct, occasionally the left sympathetic nerve. *The Œsophageal*,<sup>12</sup> in the muscular structure, transmits the œsophagus and the pneumogastric nerves.

*The Opening for the Vena Cava*<sup>13</sup> is the highest, and has 4 tendinous margins. *The Right Crus*<sup>8</sup> transmits the sympathetic and greater and lesser splanchnic nerves of that side. *The Left Crus*,<sup>10</sup> the greater and lesser splanchnic nerves of the left side and the vena azygos minor.

*Descent of the Diaphragm.* Its central tendon does not descend during inspiration, being connected with the deep cervical fascia by the fibrous pericardium.

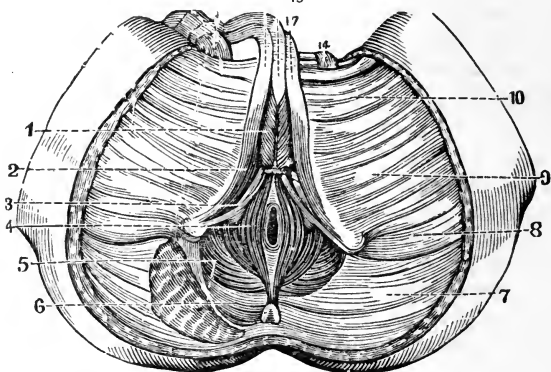


## MUSCLES OF THE PERINEUM.

**Sphincter Ani**,<sup>4</sup> from the tip of the coccyx and superficial fascia,—into the tendinous centre of the perineum. *Action*, to close the anus. *Nerve*, hemorrhoidal branch of the pudic.

**Internal Sphincter**, a muscular ring, half an inch broad, about an inch from the margin of the anus; is an aggregation of the involuntary circular fibres of the intestine.

FIG. 43.



**Sphincter Tertius of Hyrtl**, from the sacrum, encircling the rectum about 4 inches above the anal orifice. [Demonstrated by Hyrtl, Nelaton, and Velpeau, but denied by most anatomists.]

**Accelerator Urinæ**,<sup>1</sup> from the central tendon of the perineum and the median raphé in front,—fibres spread over the bulb, corpus spongiosum, corpus cavernosum,<sup>17</sup> and dorsal vessels. *Action*, to accelerate the flow of urine, and erect the penis. *Nerve*, perineal branch of pudic.

**Erector Penis**,<sup>2</sup> from the inner surface of the tuberosity of the ischium, the crus penis, and pubic ramus,—into the crus penis laterally and inferiorly. *Action*, to maintain erection. *Nerve*, perineal.

**Transversus Perinei**,<sup>3</sup> from the ascending ramus of the ischium,—into the central tendon of the perineum. *Action*, to draw tense the central tendon. *Nerve*, perineal.

**Levator Ani**,<sup>5</sup> from the body and ramus of the pubes posteriorly, pelvic fascia, and the spine of the ischium,—into the tendinous centre of the perineum, sides of the rectum (and vagina), apex of the coccyx, and a fibrous raphé extending from the coccyx to the anus. *Action*, to support the lower end of the rectum and vagina and the bladder, and assist in forming the floor of the pelvis. *Nerves*, inferior hemorrhoidal and 4th sacral.

**Compressor Urethrae**, from the upper part of the ramus of the pubes,—into its fellow of the opposite side after encircling the membranous portion of the urethra. *Action*, stop-cock muscle. *Nerve*, perineal.

**Coccygeus**,<sup>6</sup> *from* the spine of the ischium and the lesser sacro-sciatic ligament,—*into* the margin of the coccyx and the side of the last sacral segment. *Action*, to support the coccyx, and close the outlet of the pelvis posteriorly. *Nerve*, 5th sacral, anterior division.

**Sphincter Vaginæ** (in the female), *from* the central tendon of the perineum, —*into* the corpora cavernosa and body of the clitoris. Represents the accelerator urinæ of the male.

**Erector Clitoridis** (in the female), replaces the erector penis.

### MUSCLES OF THE SHOULDER AND ARM.

**Pectoralis Major**, *from* the sternal one-half of the clavicle, by an aponeurosis from the front of the sternum as low as the 6th or 7th rib, the cartilages of all the true ribs, and the aponeurosis of the external oblique,—the fibres converge, cross and are inserted by a flat tendon *into* the external bicipital ridge of the humerus, having crossed the bicipital groove. *Action*, to draw the arm forwards and downwards; also to elevate the ribs in forced inspiration. *Nerves*, anterior thoracic.

**Pectoralis Minor**, *from* the 3d, 4th, and 5th ribs, and the intercostal aponeurosis,—*into* the coracoid process of the scapula. *Action*, to depress the point of the shoulder, also to elevate the ribs in forced inspiration. *Nerves*, anterior thoracic.

**Subclavius**, *from* the cartilage of the 1st rib,—*into* the under surface of the clavicle, in a groove about its middle 3d. *Action*, to draw the clavicle downwards. *Nerve*, a branch from the 5th and 6th cervical.

**Serratus Magnus**, by 9 digitations *from* the 8 upper ribs (the 2d rib having 2) and from the intercostal aponeurosis,—*into* the whole length of the inner margin of the posterior border of the scapula. *Action*, to elevate the ribs in inspiration, also to raise the point of the shoulder. In lower animals the great sling-muscle, slinging the body between the upper extremities. *Nerve*, posterior thoracic.

**Deltoid**, *from* the outer one-third of the anterior and superior surfaces of the clavicle, the outer margin and upper surface of the acromion, and the whole lower border of the spine of the scapula,—*into* a prominence on the outer side of the shaft of the humerus, about its middle. *Action*, to raise the arm. *Nerve*, circumflex.

**Subscapularis**, *from* the inner two-thirds of the subscapular fossa,—*into* the lesser tuberosity of the humerus. *Action*, to rotate the head of the humerus inwards. *Nerves*, subscapular.

**Supra-spinatus**, *from* the inner two-thirds of the supra-spinous fossa,—*into* the upper facet of the greater tuberosity of the humerus. *Action*, to support the shoulder-joint, and to raise the arm. *Nerve*, supra-scapular.

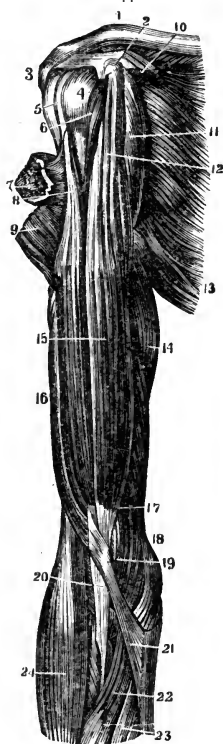**Infra-spinatus**, from the inner two-thirds of the infra-spinous fossa,—into the middle facet on the greater tuberosity of the humerus. *Action*, to rotate the humerus outwards. *Nerve*, supra-scapular.

**Teres Minor**, from the upper two-thirds of the dorsal surface of the axillary border of the scapula,—into the lowest facet on the greater tuberosity of the humerus, and the bone below. *Action*, to rotate the humerus outwards. *Nerve*, circumflex.

**Teres Major**, from the dorsal aspect of the inferior angle of the scapula,—into the internal bicipital ridge of the humerus. *Action*, to assist the latissimus dorsi. *Nerve*, subscapular.

**Coraco-brachialis**,<sup>11</sup> from the apex of the coracoid process<sup>2</sup> of the scapula,—into a ridge on the inner side of the shaft of the humerus, about its middle. *Action*, elevates the humerus forwards and inwards. *Nerve*, musculo-cutaneous, which perforates this muscle.

FIG. 44.



**Biceps**<sup>15</sup> (Biceps Flexor Cubiti). *Long head*<sup>8</sup> from the upper margin of the glenoid cavity, *short head*<sup>12</sup> from the apex of the coracoid process,<sup>2</sup> in common with the coraco-brachialis,—into the back of the tuberosity of the radius, and the fascia of the forearm.<sup>20</sup> *Action*, to flex and supinate the forearm, and to make tense its fascia. *Nerve*, the musculo-cutaneous.

**Brachialis Anti'cus**,<sup>17</sup> from the lower half of the shaft of the humerus anteriorly and laterally, embracing the insertion of the deltoid,<sup>9</sup>—into the base of the coronoid process of the ulna.<sup>19</sup> *Action*, a flexor of the forearm. *Nerves*, musculo-cutaneous and musculo-spiral.

**Triceps**<sup>16</sup> (Triceps Extensor Cubiti), by three heads, *the outer and inner* from the posterior surface of the shaft of the humerus, the outer above, the inner below the musculo-spiral groove; the *middle or long head* from a depression below the glenoid cavity of the scapula,—into the upper end of the olecranon process of the ulna. *Action*, to extend the forearm. *Nerve*, musculo-spiral.

**Subanconeus**, from the humerus above the olecranon fossa,—into the posterior ligament of the elbow-joint. *Action*, probably a tensor of the ligament *Nerve*, musculo-spiral.

## MUSCLES OF THE FOREARM.

Muscles of the forearm (20), arranged in groups of five and threes. (Pancoast.)

ANTERIORLY, 5 flexors, 2 pronators, 1 tensor of palmar fascia:—

*Flexor Carpi Radialis.*

*Pronator Radii Teres.*

*Flexor Carpi Ulnaris.*

*Pronator Quadratus.*

*Flexor Longus Pollicis.*

*Palmaris Longus.*

*Flexor Sublimis Digitorum Perforatus Manis.*

*Flexor Profundus Digitorum Perforans Manis.*

POSTERIORLY (12), in 4 sets of threes:—

*Supinator Longus.*

*Extensor Indicis.*

*Extensor Carpi Radialis Longior.*

*Extensor Communis Digitorum.*

*Extensor Carpi Radialis Brevior.*

*Extensor Minimi Digiti.*

*Extensor Ossis Metacarpi Pollicis.*

*Extensor Carpi Ulnaris.*

*Extensor Primi Internodii Pollicis.*

*Anconeus.*

*Extensor Secundi Internodii Pollicis.*

*Supinator Brevis.*

**Pronator Radii Teres**,<sup>4</sup> by 2 heads, one from above the internal condyle of the humerus, the common tendon, fascia, and the intermuscular septum; the other from the inner side of the coronoid process of the ulna,—into a rough ridge on the outer side of the shaft of the radius, about its middle. *Action*, to pronate the hand. *Nerve*, median, which passes between the 2 heads of the muscle.

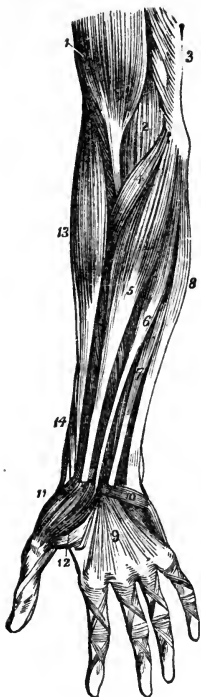
**Flexor Carpi Radialis**,<sup>5</sup> from the internal condyle by the common tendon, the fascia, and intermuscular septa,—into the base of the metacarpal bone of the index finger. *Action*, to flex the wrist. *Nerve*, median.

**Palmaris Longus**,<sup>6</sup> from the same origin as the flexor carpi radialis,—into the annular ligament and the palmar fascia.<sup>9</sup> *Action*, to make the palmar fascia tense. *Nerve*, median.

**Flexor Carpi Ulnaris**,<sup>8</sup> by 2 heads, one from the internal condyle by the common tendon, the other from the inner margin of the olecranon, the upper two-thirds of the posterior border of the ulna, and the intermuscular septum,—into the pisiform bone, the annular ligament, and the base of the 5th metacarpal bone. *Action*, to flex the wrist. *Nerve*, ulnar.

**Flexor Sublimis Digitorum (Perforatus)**,<sup>7</sup> by 3 heads, one from the inner condyle by the common tendon, the internal lateral ligament, and the intermuscular septum; the 2d from the inner side of the coronoid process; the 3d from the oblique line of the radius,—into the lateral margins of the second

FIG. 45



phalanges by 4 tendons which are split for the passage of the deep flexor tendons. *Action*, to flex the second phalanges. *Nerve*, median.

**Flexor Profundus Digitorum** (Perforans), *from* the upper two-thirds of the shaft of the ulna, a depression on the inner side of the coronoid process, and the interosseous membrane,—*into* the bases of the last phalanges, by 4 tendons which perforate the tendons of the superficial flexor. *Action*, to flex the phalanges. *Nerves*, ulnar, and anterior interosseous.

**Flexor Longus Pollicis**, *from* the upper two-thirds of the shaft of the radius, and the interosseous membrane,—*into* the base of the last phalanx of the thumb, which it flexes. *Nerve*, anterior interosseous.

**Pronator Quadratus**, *from* the oblique line on the lower one-fourth of the ulna, and the internal body of the ulna,—*into* the lower one-fourth of the external border of the shaft of the radius. *Action*, to pronate the hand. *Nerve*, anterior interosseous.

**Supinator Longus**,<sup>13</sup> *from* the upper two-thirds of the external condyloid ridge on the humerus, and the intermuscular septum,—*into* the base of the styloid process of the radius. *Action*, to supinate the hand. *Nerve*, musculo-spiral.

**Extensor Carpi Radialis Longior**,<sup>e</sup> *from* the lower one-third of the external condyloid ridge on the humerus, and the intermuscular septum,—*into* the base of the metacarpal bone of the index finger,<sup>g</sup> on its radial side. *Action*, to extend the wrist. *Nerve*, musculo-spiral.

**Extensor Carpi Radialis Brevior**,<sup>f</sup> *from* the external condyle by the common tendon, the external lateral ligament, and the intermuscular septa,—*into* the radial side of the base of the 3d metacarpal bone.<sup>g</sup> *Action*, to extend the wrist. *Nerve*, posterior interosseous.

**Extensor Communis Digitorum**,<sup>h</sup> *from* the external condyle by the common tendon, the deep fascia, and the intermuscular septa,—*into* the 2d and 3d phalanges of all the fingers, by 3 tendons, one of which divides into two. *Action*, to extend the fingers. *Nerve*, posterior interosseous.

**Extensor Minimi Digiti,**<sup>i</sup> from the common tendon and the intermuscular septa,—into the 2d and 3d phalanges of the little finger, with the tendon derived from the common extensor. *Action*, as named. *Nerve*, posterior interosseous.

**Extensor Carpi Ulnaris,**<sup>j</sup> from the common tendon, the middle one-third of the posterior border of the ulna, and the fascia of the forearm,—into the base of the 5th metacarpal bone. *Action*, to extend the wrist. *Nerve*, posterior interosseous.

**Anconeus,**<sup>k</sup> from the external condyle of the humerus, posteriorly,—into the side of the olecranon, and upper one-third of the posterior surface of the shaft of the ulna. *Action*, to extend the forearm. *Nerve*, the musculo-spiral.

**Supinator Brevis,** from the external condyle of the humerus, the external lateral and orbicular ligaments, and an oblique line on the ulna,—into the inner surface of the neck of the radius, the outer edge of its bicipital tuberosity, and the oblique line. *Action*, to supinate the hand. *Nerve*, posterior interosseous, which pierces it.

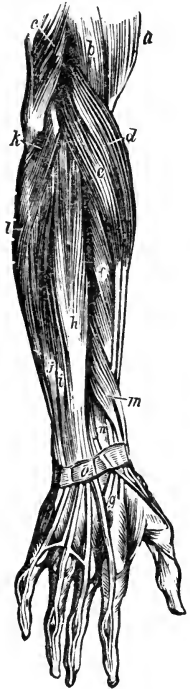**Extensor Ossis Metacarpi Pollicis,**<sup>l</sup> from the posterior surfaces of the shafts of the radius and ulna, and the interosseous ligament,—into the base of the metacarpal bone of the thumb. *Action*, to extend the thumb. *Nerve*, posterior interosseous.

**Extensor Primi Internodii Pollicis,**<sup>n</sup> from the posterior surface of the shaft of the radius and the interosseous membrane,—into the base of the 1st phalanx of the thumb. *Action*, to extend the thumb. *Nerve*, posterior interosseous.

**Extensor Secundi Internodii Pollicis,**<sup>m</sup> from the shaft of the ulna posteriorly and the interosseous membrane,—into the base of the last phalanx of the thumb. *Action*, to extend the thumb. *Nerve*, posterior interosseous.

**Extensor Indicis,** from the shaft of the ulna posteriorly and the interosseous membrane,—into the 2d and 3d phalanges of the index finger with the tendon of the common extensor. *Action*, to extend the index finger. *Nerve*, posterior interosseous.

FIG. 46.



## FASCIÆ OF THE HAND.

**ANTERIOR ANNULAR LIGAMENT**, *from* the pisiform and unciform bones,—*to* the tuberosity of the scaphoid and the ridge on the trapezium. It is pierced by the tendon of the flexor carpi radialis, and beneath it pass the tendons of the superficial and deep flexors and the flexor longus pollicis, also the median nerve. It is continuous with the palmar fascia and the fascia of the forearm.

**POSTERIOR ANNULAR LIGAMENT**, *from* the ulna, cuneiform, and pisiform bones and the palmar fascia,—*to* the margin of the radius and the ridges on its posterior surface. It has 6 canals for the passage of the extensor tendons, each lined by a synovial membrane. It is continuous with the fascia of the forearm.

**PALMAR FASCIA**, ensheathes the muscles of the hand, and divides into slips for the four fingers, each slip dividing and forming tendinous arches for the passage of the flexor tendons.

## MUSCLES OF THE HAND.

**Abductor Pollicis**,<sup>11</sup> *from* the ridge of the trapezium and annular ligament,—*into* the radial side of the base of the 1st phalanx of the thumb. *Action*, to draw the thumb from the median line. *Nerve*, median.

**Opponens Pollicis**, *from* the palmar surface of the trapezium and annular ligament,—*into* the radial side of the metacarpal bone of the thumb, for its whole length. *Action*, as a flexor ossis metacarpi pollicis. *Nerve*, median.

**Flexor Brevis Pollicis**,<sup>12</sup> *from* the trapezium, annular ligament, trapezoid, os-magnum, base of the 3d metacarpal, and the sheath of the tendon of the flexor carpi radialis,—*into* both sides of the base of the 1st phalanx of the thumb, by two tendons, each of which has a sesamoid bone in it. *Action*, to flex the thumb. *Nerves*, median and ulnar.

**Adductor Pollicis**, *from* the whole palmar surface of the 3d metacarpal bone,—*into* the ulnar side of the base of the 1st phalanx of the thumb, and the internal sesamoid bone. *Action*, to draw the thumb towards the median line. *Nerve*, ulnar.

*Thenar Eminence*, or ball of the thumb, is formed by the above-named 4 muscles. The following first 4 form the *Hypo-thenar Eminence*.

**Palmaris Brevis**,<sup>10</sup> *from* the annular ligament and palmar fascia,—*into* the skin on the inner border of the palm of the hand. *Action*, to corrugate the skin of the hand. *Nerve*, ulnar.

**Abductor Minimi Digiti**, *from* the pisiform bone and the tendon of the flexor carpi ulnaris,—*into* the ulnar side of the base of the 1st phalanx of the little finger. *Action*, as named. *Nerve*, ulnar.



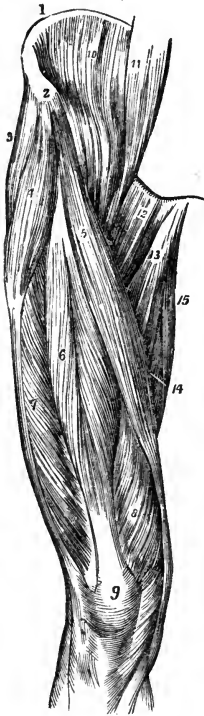
- Flexor Brevis Minimi Digiti**, *from* the tip of the unciform process and the annular ligament,—*into* the base of the 1st phalanx of the little finger, with the preceding muscle. *Action*, as named. *Nerve*, ulnar.
- Opponens Minimi Digiti**, *from* the unciform process and annular ligament,—*into* the whole ulnar margin of the 5th metacarpal bone. *Action*, a flexor of the 5th metacarpal bone. *Nerve*, ulnar.
- Lumbricales** (4), *from* the tendons of the deep flexor,—*into* the expanded tendons of the common extensor, on the dorsi of the phalanges. *Action*, probably to flex the 1st phalanges. *Nerves*, median and ulnar.
- Dorsal Interossei** (4), by 2 heads *from* the adjacent sides of the metacarpal bones,—*into* the bases of the 1st phalanges of the index, middle, and ring fingers, the middle finger having two. *Action*, abductors of the fingers from the median line. *Nerve*, ulnar.
- Palmar Interossei** (3), *from* the palmar surfaces of the 2d, 4th, and 5th metacarpal bones,—*into* the bases of the 1st phalanges of the same fingers. *Action*, adductors of the fingers. *Nerve*, ulnar.

#### MUSCLES OF THE HIP AND THIGH.

- Psoas Magnus**,<sup>11</sup> *from* the bodies, transverse processes, and intervertebral substances of the last dorsal and all the lumbar vertebræ,—*into* the lesser trochanter of the femur, by a common tendon with the iliacus. *Action*, to flex and rotate the femur outwards, also to flex the trunk and pelvis on the thigh. *Nerves*, anterior lumbar branches.
- Psoas Parvus**, *from* the bodies of the last dorsal and first lumbar vertebræ, and the intervertebral substance,—*into* the ilio-pectineal eminence, and the iliac fascia. *Action*, when present it is a tensor of the iliac fascia. *Nerves*, anterior lumbar branches.
- Iliacus**,<sup>10</sup> *from* the iliac fossa, inner margin of the iliac crest, ilio-lumbar ligament, base of the sacrum, anterior spinous processes of the ilium and the notch between them, and from the capsule of the hip-joint,—*into* the outer side of the tendon of the psoas magnus. *Action*, the same as the psoas magnus. *Nerve*, anterior crural.
- FASCIA LATA**, the deep fascia of the thigh, extends from Poupart's ligament to the prominent points around the knee-joint, and from the margin of the sacrum and coccyx around the limb to the pubic arch and pectineal line. It sends two strong intermuscular septa down to the linea aspera, and contains the *Saphenous Opening*, which is formed by the reflected margins of its pubic and iliac portions. *Poupart's Ligament* is made by the knife, and is only the line of junction between the aponeurosis of the external oblique

muscle and the fascia lata; extending from the anterior superior spine of the ilium to the spine of the pubic bone.

FIG. 47.



**Tensor Vaginæ Femoris,**<sup>4</sup> *from* the anterior part of the outer lip of the iliac crest, and the anterior superior spinous process,—*into* the fascia lata laterally, for one-fourth down the thigh. *Action*, a tensor of the fascia lata. *Nerve*, superior gluteal.

**Sartorius,**<sup>5</sup> *from* the anterior superior spine of the ilium<sup>2</sup> and half of the notch below it,—*into* the upper internal surface of the shaft of the tibia. *Action*, to flex and cross the legs. *Nerve*, anterior crural.

**Quadriceps Extensor**, includes the rectus, vastus internus and externus, and the crureus muscles. Its tendon contains the patella.

**Rectus Femoris,**<sup>6</sup> by two tendons, *the Straight* from the anterior inferior spine of the ilium, *the Reflected* from a groove above the brim of the acetabulum,—*into* the tuberosity of the tibia by the tendon<sup>9</sup> common to this and the next 3 muscles. *Action*, to extend the leg. *Nerve*, anterior crural.

**Vastus Externus,**<sup>7</sup> *from* the anterior border of the great trochanter and the whole length of the linea aspera,—*into* the tuberosity of the tibia, by the common tendon.

**Vastus Internus**<sup>8</sup> and **Crureus** are one muscle, arising *from* the inner lip of the linea aspera and nearly the whole of the shaft of the femur in front and laterally from the trochanters down to within the

lower one-fourth of the bone,—*into* the tuberosity of the tibia by the common extensor tendon. *Action*, to extend the leg. *Nerve*, anterior crural.

**Subcrureus**, *from* the lower part of the femur anteriorly,—*into* the synovial pouch behind the patella. *Action*, to draw up the synovial sac. *Nerve*, anterior crural.

**Gracilis,**<sup>15</sup> *from* the inner margin of the rami of the pubes and ischium,—*into* the inner surface of the shaft of the tibia below the tuberosity. *Action*, to flex and adduct the leg. *Nerve*, obturator.

**Pectineus,**<sup>12</sup> *from* the ilio-pectineal line, and the bone in front thereof, also from an expansion of Gimbernat's ligament,—*into* the rough line extending

from the trochanter minor to the linea aspera. *Action*, to flex the thigh and rotate it outwards. *Nerves*, obturator, accessory obturator, and anterior crural.

**Adductor Longus**,<sup>13</sup> *from* the front of the pubes,—*into* the middle third of the linea aspera. *Action*, to adduct the thigh and flex it. *Nerve*, obturator.

**Adductor Brevis**, *from* the descending ramus of the pubes,—*into* the upper part of the linea aspera. *Action*, to adduct and flex the thigh. *Nerve*, obturator.

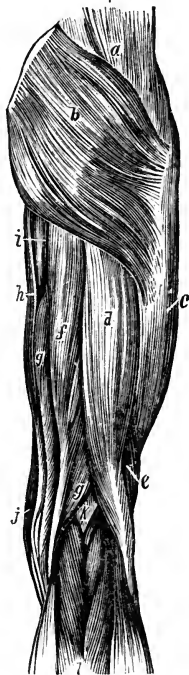**Adductor Magnus**,<sup>14</sup> *from* the rami of the pubes and ischium, and the outer margin and under surface of the tuberosity of the ischium,—*into* the rough line leading from the great trochanter to the linea aspera, the whole length of the linea aspera, and by a tendon into the tubercle above the inner condyle of the femur. *Action*, to adduct the thigh and rotate it outwards. *Nerves*, obturator and great sciatic. This muscle is pierced by 4 apertures for the 3 superior perforating and the profunda arteries, and about the lower one-third of its insertion an angular interval is left therein, the lower opening of Hunter's canal, for the passage of the femoral vessels into the popliteal space.

**Gluteus Maximus**,<sup>b</sup> *from* the superior curved line of the ilium, the crest behind it, the last piece of the sacrum, the side of the coccyx and the great and posterior sacro-sciatic ligaments,—*into* the fascia lata and the rough line leading from the great trochanter to the linea aspera. *Action*, to extend and abduct the thigh and rotate it outwards, also to maintain the trunk erect. *Nerves*, inferior gluteal and a branch from the sacral plexus.

**Gluteus Medius**,<sup>a</sup> *from* the ilium between the superior and middle curved lines, the crest between them and the fascia of the part,—*into* the oblique lines on the great trochanter. *Action*, its posterior fibres rotate the thigh outwards, its anterior fibres rotate inwards. It also abducts the thigh and draws it forwards, and assists to maintain the trunk erect. *Nerve*, superior gluteal.

**Gluteus Minimus**,<sup>8</sup> *from* the ilium between the middle and inferior curved lines, and the margin of the great sacro-sciatic notch,—*into* the anterior

FIG. 48.



border of the great trochanter. *Action*, to rotate the thigh inwards, also to abduct and draw it forwards, and to maintain the trunk erect. *Nerve*, superior gluteal.

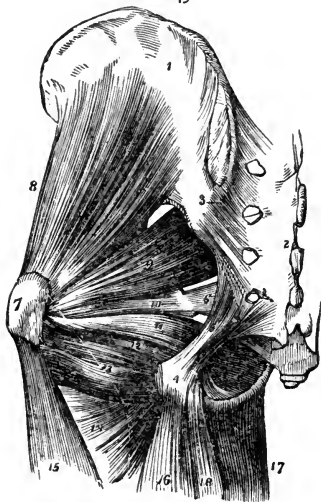
**Pyramidalis**,<sup>9</sup> by 3 digitations from the front of the sacrum, from the margin of the great sacro-sciatic foramen and the great sacro-sciatic ligament,—into the upper border of the great trochanter,<sup>7</sup> having passed through the great sacro-sciatic foramen. *Action*, an external rotator of the thigh. *Nerves*, branches from the sacral plexus.

**Obturator Internus**,<sup>11</sup> from the posterior bony margin of the obturator foramen and the inner surface of the obturator membrane,—into the great trochanter,<sup>7</sup> passing through the lesser sacro-sciatic notch. *Action*, an external rotator of the thigh. *Nerves*, branches from the sacral plexus.

**Gemellus Superior**,<sup>10</sup> from the outer surface of the spine of the ischium,—into the great trochanter, being blended with the tendon of the obturator internus. *Action*, an external rotator of the thigh. *Nerves*, branches from the sacral plexus.

**Gemellus Inferior**,<sup>12</sup> from the tuberosity of the ischium,—into the tendon of the obturator internus and the great trochanter. *Action*, an external rotator of the thigh. *Nerves*, branches from the sacral plexus.

FIG. 49.



**Obturator Externus**, from the anterior inner bony margin of the obturator foramen, and the inner two-thirds of the anterior surface of the obturator membrane,—into the digital fossa of the femur at the inner base of the great trochanter. *Action*, an external rotator of the thigh. *Nerve*, obturator.

**Quadratus Femoris**,<sup>13</sup> from the tuberosity of the ischium,—into the upper part of the linea quadrati on the trochanter major posteriorly. *Action*, an external rotator of the thigh. *Nerves*, branches from the sacral plexus.

**Biceps**,<sup>16</sup> by 2 heads, the *Long Head*<sup>d</sup> from the tuberosity of the ischium posteriorly, the *Short Head*,<sup>e</sup> from the outer lip of the linea aspera, and the intermuscular septum,—into the outer side

of the head of the fibula; its tendon embracing the external lateral ligament of the knee joint, and forming the *Outer Hamstring*, the tendons of the semi-

tendinosus, semi-membranosus, gracilis, and sartorius, forming the *Inner Hamstring*. *Action*, to flex the leg and rotate it outwards. *Nerve*, great sciatic.

**Semi-tendinosus**, *f* from the tuberosity of the ischium by a tendon<sup>4</sup> common to it and the long head of the biceps, and from the adjacent aponeurosis,—*into* the shaft of the tibia at its upper and inner surface, its tendon curving around the inner tuberosity. *Action*, to flex the leg upon the thigh. *Nerve*, great sciatic.

**Semi-membranosus**, *g* from the tuberosity of the ischium above the origin of the above-named muscles,—*into* the inner tuberosity of the tibia; its tendon dividing into 3 parts, one over the popliteus muscle, and another forming the posterior ligament of the knee-joint. *Action*, to flex the leg, and rotate it inwards. *Nerve*, great sciatic.

*External Rotators of the Hip-joint* are  $13\frac{1}{2}$ ,—the 3 adductors, pyriformis, <sup>a</sup> obturators, 2 gemelli, quadratus femoris, pectineus, psoas magnus, iliacus, sartorius, and posterior half of the gluteus medius.

*Internal Rotators of the Hip-joint* are  $2\frac{1}{2}$ ,—the tensor vaginæ femoris, gluteus minimus, and the anterior half of the gluteus medius.

## MUSCLES OF THE LEG.

Muscles of the leg arranged in groups of threes. (Pancoast.)

*Tibialis Anticus.*

*Extensor Proprius Pollicis.*

*Extensor Longus Digitorum.*

*Gastrocnemius.*

*Soleus.*

*Plantaris.*

*Tibialis Posticus.*

*Flexor Longus Pollicis.*

*Flexor Longus Digitorum.*

*Peroneus Longus.*

*Peroneus Brevis.*

*Peroneus Tertius.*

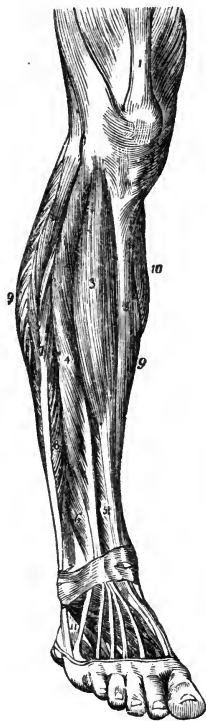
**Tibialis Anti'cus**<sup>3</sup> (Flexor Tarsi Tibialis), from the outer tuberosity and upper two-thirds of the shaft of the tibia externally, the interosseous membrane, deep fascia, and intermuscular septum,—through the inner canal in the anterior annular ligament *into* the inner and plantar surface of the internal cuneiform bone, and the base of the 1st metatarsal. *Action*, to flex the tarsus on the leg, and elevate the inner border of the foot. *Nerve*, anterior tibial.

**Extensor Proprius Pollicis**,<sup>5</sup> from the middle two-fourths of the fibula anteriorly and the interosseous membrane,—through the 2d canal in the anterior annular ligament,—*into* the base of the last phalanx of the great toe. *Action*, to extend that toe. *Nerve*, anterior tibial.

**Extensor Longus Digitorum**,<sup>4</sup> from the outer tuberosity of the tibia, the upper three-fourths of the shaft of the fibula anteriorly, interosseous membrane, deep fascia, and intermuscular septa,—*into* the 2d and 3d phalanges of the

4 lesser toes, by 4 tendons which pass over the dorsum of the foot, from the outer canal in the anterior annular ligament. *Action*, to extend the lesser toes. *Nerve*, anterior tibial.

FIG. 50.



**Peroneus Tertius**<sup>6</sup> (Flexor Tarsi Fibularis), *from* the outer lower one-fourth of the fibula, interosseous membrane, and intermuscular septum,—*into* the base of the 5th metatarsal bone. This muscle is a part of the last named, and passes through the same canal in the annular ligament. *Action*, to flex the tarsus. *Nerve*, anterior tibial.

**Gastrocnemius**, by 2 heads *from* the condyles of the femur, and the supra-condyloid ridges,—unites with the tendon of the soleus to form the *tendo Achillis*, into the posterior tuberosity of the os calcis. *Action*, to extend the foot. *Nerve*, internal popliteal.

**Soleus**, *from* the head and upper one-half of the shaft of the fibula posteriorly, the oblique line of the tibia, and the tendinous arch,—unites with the tendon of the gastrocnemius as the *tendo Achillis* (see above). *Action*, to extend the foot. *Nerve*, internal popliteal.

**Plantaris**, *from* the outer bifurcation of the linea aspera, and posterior ligament of the knee-joint, by a very long, delicate tendon,—*into* the posterior surface of the os calcis. *Action*, to extend the foot. *Nerve*, internal popliteal.

**Popliteus**,<sup>6</sup> *from* a depression on the external condyle of the femur, and the posterior ligament of the knee-joint,—*into* the inner two-thirds of the triangular surface on the shaft of the tibia posteriorly and above the oblique line. *Action*, to flex the leg. *Nerve*, internal popliteal.

**Flexor Longus Pollicis**,<sup>9</sup> *from* the lower two-thirds of the shaft of the fibula internally, the interosseous membrane, fascia, and intermuscular septum,—through grooves in the tibia, astragalus, and os calcis,—*into* the base of the last phalanx of the great toe. *Action*, to flex the great toe. *Nerve*, posterior tibial.

**Flexor Longus Digitorum**,<sup>7</sup> *from* the shaft of the tibia posteriorly and below the oblique line, and the intermuscular septum,—passes behind the inner malleolus in a groove<sup>13</sup> with the tibialis posticus,—*into* the bases of

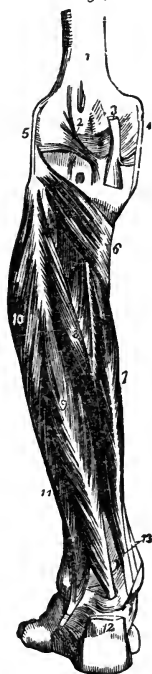the last phalanges of the lesser toes by 4 tendons which perforate the tendons of the flexor brevis digitorum. *Action*, to flex the phalanges and extend the foot. *Nerve*, posterior tibial.

**Tibialis Posticus**,<sup>8</sup> by two processes between which pass the anterior tibial vessels, *from* the upper one-half of shaft of the tibia posteriorly, the upper two-thirds of the shaft of the fibula internally, the interosseous membrane, deep fascia, and intermuscular septa,—passes behind the inner malleolus in a groove<sup>13</sup> with the long flexor, *into* the tuberosity of the scaphoid and internal cuneiform bones. *Action*, to extend the tarsus, and invert the foot. *Nerve*, posterior tibial.

**Peroneus Longus**,<sup>10</sup> *from* the head of the fibula and the upper two-thirds of its shaft externally, the deep fascia, and intermuscular septa,—passes behind the outer malleolus in a groove with the peroneus brevis, through a groove in the cuboid bone, to the outer side of the base of the 1st metatarsal bone. *Action*, to extend and evert the foot. *Nerve*, musculo-cutaneous.

**Peroneus Brevis**,<sup>11</sup> *from* the middle one-third of the shaft of the fibula externally, and the intermuscular septa,—passes behind the external malleolus in a groove with the long peroneal, *into* the dorsum of the base of the 5th metatarsal bone. *Action*, to extend the foot. *Nerve*, musculo-cutaneous branch of external popliteal.

FIG. 51.



## FASCIÆ OF THE FOOT.

**ANTERIOR ANNULAR LIGAMENT**, consists of vertical and horizontal portions, is attached to the lower ends of the fibula and tibia, the os calcis and the plantar fascia. It contains 5 sheaths lined by synovial membranes for the tendons of the extensor muscles, that of the extensor proprius pollicis passing beneath it, as also the anterior tibial vessels and nerve.

**INTERNAL ANNULAR LIGAMENT**, *from* the inner malleolus *to* the os calcis, converting 3 bony grooves into canals lined by synovial membranes for the flexor tendons and the posterior tibial vessels and nerve.

**EXTERNAL ANNULAR LIGAMENT**, *from* the outer malleolus *to* the os calcis, binding down the peronei tendons in one synovial sac.

**PLANTAR FASCIA**, the densest in the body, divided into a central and two lateral portions, and attached to the inner tuberosity of the os calcis, divides into 5 processes, 1 for each toe, and several intermuscular septa.

## MUSCLES OF THE FOOT.

**Extensor Brevis Digitorum**, the only muscle on the dorsum of the foot, arises from the os calcis externally, the astragalo-calcanean and the anterior annular ligaments,—by 4 tendons, 1 into the 1st phalanx of the great toe, and the others into the outer sides of the long extensor tendons of the 2d, 3d, and 4th toes. *Action*, to extend the toes. *Nerve*, anterior tibial.

Muscles on the sole of the foot (19), by layers:—

1st Layer.

*Flexor Brevis Digitorum.*

*Abductor Pollicis.*

*Abductor Minimi Digiti.*

2d Layer.

*Flexor Accessorius.*

*Lumbricales (4).*

3d Layer.

*Flexor Brevis Pollicis.*

*Flexor Brevis Minimi Digiti.*

*Adductor Pollicis.*

*Transversus Pedis.*

4th Layer.

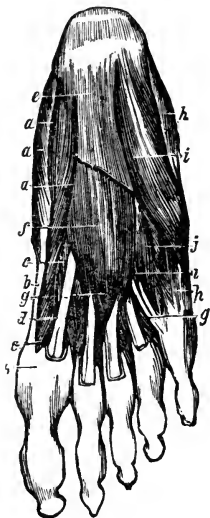
*Interossei (4 Dorsal, 3 Plantar).*

} Pancoast's Tri-  
angle, the low-  
est in the body.

**Abductor Pollicis**,<sup>a</sup> from the inner tuberosity of the os calcis, the internal annular ligament, plantar fascia, and intermuscular septum,—into the inner side of the base of the 1st phalanx of the great toe. *Action*, to abduct the great toe. *Nerve*, internal plantar.

**Flexor Brevis Digitorum**,<sup>f</sup> from the inner tuberosity of the os calcis, the plantar fascia and intermuscular septa,—into the sides of the 2d phalanges of the lesser toes by 4 tendons which are perforated for the long flexor tendons. *Action*, to flex the lesser toes. *Nerve*, internal plantar.

FIG. 52.



**Abductor Minimi Digiti**,<sup>h</sup> from the outer tuberosity and under surface of the os calcis, the plantar fascia and the intermuscular septum,—into the base of the 1st phalanx of the little toe with the tendon of its short flexor. *Action*, to abduct the little toe. *Nerve*, external plantar.

**Flexor Accessorius**, by 2 heads, from the os calcis and the calcaneo-scaploid and long plantar ligaments,—into the tendon of the flexor longus digitorum. *Action*, accessory flexor of the toes. *Nerve*, external plantar.

**Lumbricales**<sup>g</sup> (4), from the long flexor tendons—into the inner side of the second phalanges of the lesser toes. *Action*, accessory flexors. *Nerves*, internal plantar to the two internal, external plantar to the others.



**Flexor Brevis Pollicis,**<sup>c</sup> *from* the cuboid and external cuneiform bones, and the prolonged tendon of the tibialis posticus,—*into* both sides of the base of the 1st phalanx of the great toe, by 2 portions, of which one blends with the abductor pollicis, the other with the adductor pollicis. *Action*, to flex the great toe. *Nerve*, internal plantar.

**Adductor Pollicis,** *from* the tarsal ends of the three middle metatarsal bones, and the sheath of the tendon of the peroneus longus,—*into* the base of the 1st phalanx of the great toe, externally. *Action*, to adduct the great toe. *Nerve*, external plantar.

**Flexor Brevis Minimi Digiti,**<sup>i</sup> *from* the base of the 5th metatarsal bone and the sheath of the tendon of the peroneus longus,—*into* the base of the 1st phalanx of the little toe externally. *Action*, to flex the little toe. *Nerve*, external plantar.

**Transversus Pedis,** *from* the under surface of the head of the 5th metatarsal bone, and the transverse ligament of the metatarsus,—*into* the outer side of the 1st phalanx of the great toe, blending with the tendon of the adductor pollicis. *Action*, to adduct the great toe. *Nerve*, external plantar.

**Dorsal Interossei** (4), each by two heads *from* the adjacent sides of two metatarsal bones,—*into* the base of the 1st phalanx of the corresponding toe. *Action*, to abduct the toes. *Nerve*, external plantar.

**Plantar Interossei**<sup>j</sup> (3), *from* the shafts of the 3d, 4th, and 5th metatarsal bones,—*into* the bases of the 1st phalanges of the same toes. *Action*, to adduct the toes towards the median line. *Nerve*, external plantar.

## THE HEART.

**What is the Pericardium?** It is a conical membranous closed sac, containing the heart and the roots of the great vessels. It lies behind the sternum and between the pleuræ, its apex upwards, its base below and attached to the central tendon of the diaphragm. It is composed of an outer fibrous coat, and an inner serous one; the latter consisting of two portions, a parietal layer, lining the inner surface of the fibrous coat, and a visceral layer, which is reflected over the heart and vessels. The serous portion secretes a thin fluid, about 1 drachm in quantity normally, for the lubrication of its surfaces. The fibrous coat is prolonged on the outer surfaces of the great vessels, except the inferior vena cava, and becomes continuous with the deep layer of the cervical fascia.

**Describe the Endocardium.** It is a serous membrane which lines the inner surface of the heart, forming by its reduplications the cardiac, aortic, and pulmonary valves, and continuous with the lining membrane of the great vessels.

**Describe the Heart.** It is a hollow muscular organ, conoidal in shape, placed obliquely in the chest between the lungs, base upwards, apex towards the left and front, corresponding to the interspace between the 5th and 6th costal cartilages, one inch inside of and two inches below the left nipple. In the adult its size is about 5 inches by  $3\frac{1}{2}$  by  $2\frac{1}{2}$ , and from 8 to 12 oz. in weight.

**What are the Cavities of the Heart?** They are 4 in number, an auricle and a ventricle on each side of the heart, separated by a longitudinal muscular septum, and indicated on the external surface of the organ by grooves, named, from their contiguous cavities, as the *Auriculo-ventricular Groove* transversely, and the *Inter-Ventricular Groove* longitudinally.

**Describe the Right Auricle.** It is larger than the left, can hold about 2 fluidounces, its walls being about 1 line in thickness. It receives the venous blood by the superior and inferior venæ cavæ and the coronary sinus, and presents interiorly the following points for examination:—

*Appendix Auriculæ*, a conical pouch projecting from the auricle to the front and left, its margins being dentated.

*Openings* of the superior and inferior venæ cavæ and the coronary sinus, the latter having a valve in two segments.

*Foramina Thebesii*, several minute orifices, the mouths of veins from the substance of the heart.

*Tubercle of Lower*, a very small projection on the right wall, supposed to influence the direction of the blood-current.

*Eustachian Valve*, at the anterior margin of the inferior vena cava; large in the fœtus, to direct the blood to the foramen ovale.

*Fossa Ovalis*, a depression on the inner wall, and the situation of the foramen ovale in the fœtus.

*Annulus Ovalis*, the oval margin of the fossa ovalis.

*Musculi Pectinati*, muscular columns on the inner surface of the appendix and the inner wall of the auricle.

*Auriculo-ventricular Opening*, communicates with the right ventricle, is oval, about an inch broad, surrounded by a fibrous ring, and is guarded by the tricuspid valve.

**Describe the Right Ventricle.** Its form is conical, its cavity containing about 2 fluidounces, its apex above the apex of the heart, and it presents interiorly the following, viz.—

*Tricuspid Valve*, consists of 3 triangular segments connected by their bases with the auriculo-ventricular orifice, and by their sides with each other, the largest being on the left side.

*Chordæ Tendinæ*, delicate tendinous cords which connect the margins and lower surfaces of the tricuspid valve with the columnæ.

*Columnæ Carneæ*, muscular columns projecting from the surface of the ventricle, of which 3 or 4, called *Columnæ Papillares*, give attachment to the chordæ tendinæ.

*Semilunar Valves*, are 3 in number, and guard the orifice of the pulmonary artery, each about the middle of its free margin has a fibro-cartilaginous nodule, the *Corpus Arantii*, which more perfectly closes the orifice.

*Opening of the Pulmonary Artery*, at the superior and internal angle of the ventricle, the *Conus Arteriosus*. It is circular in form, surrounded by a fibrous ring, and is guarded by the semilunar valves.

*Sinuses of Valsalva*, are 3 pouches, one behind each valve, between it and the commencement of the pulmonary artery.

**Describe the Left Auricle.** Its walls are about  $1\frac{1}{2}$  lines in thickness, its capacity rather less than 2 fluidounces, has an appendix auriculæ, and receives the arterialized blood from the lungs. It presents the following internally:—

*Openings of the Pulmonary Veins*, are 4 in number, sometimes 3, as the two left veins frequently end in a common opening.

*Left Auriculo-ventricular Opening*, is smaller than the right one.

*Musculi Pectinati*, on the inner surface of the appendix.

*Depression*, corresponding to the fossa ovalis in the right auricle.

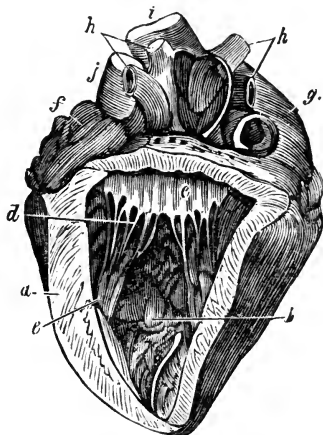
**Describe the Left Ventricle.**

It is longer, thicker, and more conical than the right, projecting towards the posterior aspect. Its walls are the thickest of those in the heart, being twice as thick as those of the right ventricle. Its interior presents the following:—

*Aortic Opening*, is small and circular, placed in front and to the right of the auriculo-ventricular, a segment of the mitral valve being between them. It is surrounded by a fibrous ring, and guarded by semilunar valves.

*Mitral Valve*, consists of two unequal-sized segments, and is attached to the fibrous ring which surrounds the auriculo-ventricular opening. Its margins are connected with the ventricular walls by *Chordæ Tendinæ* and *Musculi Papillares*.

FIG. 53.



*Semilunar Valves*, guard the aortic orifice, and are larger and stronger than those on the right side.

*Sinus Aortici*, or sinus of Valsalva, a pouch between each valve and the beginning of the aorta.

*Columnæ Carneæ*,<sup>e</sup> are smaller and more numerous than on the right side; the *Musculi Papillares* are but two in number.

**Describe the Structure of the Heart.** The muscular fibres take origin from the four fibrous rings at the auriculo-ventricular and aortic openings. The fibres of the auricles are arranged in two layers, a superficial and a deep one, the latter having looped fibres and annular fibres. In the ventricles the fibres are superficial and deep, the latter being arranged circularly, the former spirally, coiling inwards at the apex of the heart into a whorl-like form, the *vortex*.

### THE ARTERIES.

**What are the Arteries?** Cylindrical vessels which carry arterial blood to the body from the heart. Those going to the lungs with the returning veins, form the *Lesser or Pulmonic Circulation*. The aorta with its branches and the returning veins, constitute the *Greater or Systemic Circulation*. The arteries anastomose or communicate freely with each other everywhere throughout the body, permitting the establishment of collateral circulations.

**Describe the Structure of the Arteries.** They are dense, very elastic, preserving their cylindrical form, and are composed of 3 coats, *an Internal* or serous; *a Middle*, which is of muscular and elastic tissue; and *an External*, of connective tissue. They are generally included in a fibro-areolar investment, the *Sheath*, which also encloses the accompanying veins. The larger arteries are nourished by the *Vasa Vasorum*, blood-vessels which ramify in the external and middle coats; and are supplied with nerves, the *Vaso-motor*, derived from both the sympathetic and cerebro-spinal systems, and forming intricate plexuses on the larger trunks.

**What are the Capillaries?** Minute vessels forming a network throughout the tissues of the body between the terminating arteries and the commencing veins. Their average diameter is about the  $\frac{1}{3000}$  of an inch, and their walls consist of a transparent homogeneous membrane continuous with the innermost layer of the arterial and venous walls.

[In the following pages, main branches are in italics, sub-branches in Roman.]

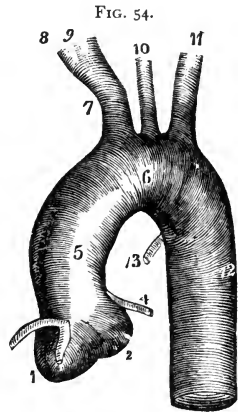
**Describe the Aorta.** It is the main trunk of the systemic arteries, commencing at the aortic opening of the left ventricle of the heart, arching backwards over the roof of the left lung into the thorax, where it descends on the left of the spinal column, and after passing through the aortic opening in the diaphragm, it terminates in the right and left common iliac arteries opposite

the 4th lumbar vertebra. It is divided into the arch, the thoracic aorta, and the abdominal aorta; and the arch is subdivided into the ascending,<sup>5</sup> transverse,<sup>6</sup> and descending<sup>12</sup> portions. The upper border of the arch is generally situated about an inch below the upper margin of the sternum. The branches of the aorta are,—

- |                              |                                  |  |                    |                      |                    |                              |                    |                   |                              |                      |                        |                         |                  |  |
|------------------------------|----------------------------------|--|--------------------|----------------------|--------------------|------------------------------|--------------------|-------------------|------------------------------|----------------------|------------------------|-------------------------|------------------|--|
| From the Arch,—              | 2 <i>Coronary</i> . <sup>4</sup> | <i>Left Common Carotid</i> . <sup>10</sup>   |                    |                      |                    |                              |                    |                   |                              |                      |                        |                         |                  |  |
|                              | <i>Innominate</i> . <sup>7</sup> | <i>Left Subclavian</i> . <sup>11</sup>   |                    |                      |                    |                              |                    |                   |                              |                      |                        |                         |                  |  |
| From the Thoracic,—          | <i>Pericardiac</i> .             | <i>Œsophageal</i> .  |                    |                      |                    |                              |                    |                   |                              |                      |                        |                         |                  |  |
|                              | <i>Bronchial</i> .               | 20 <i>Intercostals</i> .   |                    |                      |                    |                              |                    |                   |                              |                      |                        |                         |                  |  |
|                              |                                  | <i>Posterior Mediastinal</i> .   |                    |                      |                    |                              |                    |                   |                              |                      |                        |                         |                  |  |
| From the Abdominal,—         | 2 <i>Phrenic</i> .               |  |                    |                      |                    |                              |                    |                   |                              |                      |                        |                         |                  |  |
|                              | <i>Celiac Axis</i> .             | <table border="0"> <tr> <td>{ <i>Gastric</i>.</td> <td>2 <i>Spermatic</i>.</td> </tr> <tr> <td>{ <i>Hepatic</i>.</td> <td><i>Inferior Mesenteric</i>.</td> </tr> <tr> <td>{ <i>Splenic</i>.</td> <td>8 <i>Lumbar</i>.</td> </tr> <tr> <td><i>Superior Mesenteric</i>.</td> <td><i>Sacra Media</i>.</td> </tr> <tr> <td>2 <i>Supra-renal</i>.</td> <td>2 <i>Common Iliac</i>.</td> </tr> <tr> <td>2 <i>Renal</i>.</td> <td></td> </tr> </table> | { <i>Gastric</i> . | 2 <i>Spermatic</i> . | { <i>Hepatic</i> . | <i>Inferior Mesenteric</i> . | { <i>Splenic</i> . | 8 <i>Lumbar</i> . | <i>Superior Mesenteric</i> . | <i>Sacra Media</i> . | 2 <i>Supra-renal</i> . | 2 <i>Common Iliac</i> . | 2 <i>Renal</i> . |  |
| { <i>Gastric</i> .           | 2 <i>Spermatic</i> .             |  |                    |                      |                    |                              |                    |                   |                              |                      |                        |                         |                  |  |
| { <i>Hepatic</i> .           | <i>Inferior Mesenteric</i> .     |  |                    |                      |                    |                              |                    |                   |                              |                      |                        |                         |                  |  |
| { <i>Splenic</i> .           | 8 <i>Lumbar</i> .                |  |                    |                      |                    |                              |                    |                   |                              |                      |                        |                         |                  |  |
| <i>Superior Mesenteric</i> . | <i>Sacra Media</i> .             |  |                    |                      |                    |                              |                    |                   |                              |                      |                        |                         |                  |  |
| 2 <i>Supra-renal</i> .       | 2 <i>Common Iliac</i> .          |  |                    |                      |                    |                              |                    |                   |                              |                      |                        |                         |                  |  |
| 2 <i>Renal</i> .             |                                  |  |                    |                      |                    |                              |                    |                   |                              |                      |                        |                         |                  |  |

**Describe the Coronary Arteries.** They are 2 in number, a right and a left,<sup>4</sup> arise from the aorta behind the semilunar valves and run in the vertical grooves of the heart, the left artery in front, to supply the tissue of that organ.

**Describe the Innominate.**<sup>7</sup> It arises from the summit of the arch of the aorta, is 1½ inch long, and divides behind the right sterno-clavicular joint into the *Right Common Carotid*<sup>9</sup> and *Right Subclavian*,<sup>8</sup> these arteries on the left side of the body arising directly from the arch of the aorta.<sup>10 11</sup> It sometimes sends off a *Middle Thyroid* (artery of Neubauer) which may arise directly from the arch of the aorta. The innominate is sometimes absent, and not infrequently varies in length from an inch to two or more.



**Describe the Common Carotid.** Arising differently (see above), the two carotids are similarly described, except that the left is longer and deeper than the right one. Their course is indicated by a line drawn from a point midway between the angle of the lower jaw and the mastoid process to the sterno-clavicular articulation. At the lower part of the neck they are separated only by the width of the trachea, and they are each contained in a sheath of the deep cervical fascia with the internal jugular vein externally and the pneumogastric nerve between the artery and vein. On the front of the sheath lies the descendens noni nerve (descending branch of the 9th or hypoglossal). The artery lies beneath the inner border of the sterno-cleido-mastoid muscle, and is crossed about its middle by the omo-hyoid muscle and the middle thyroid vein.

It is also crossed *above* by the facial, lingual, and superior thyroid veins, *below* by the anterior jugular vein, and on the left side often by the internal jugular vein. It bifurcates, at the level of the upper border of the thyroid cartilage, into the *External and Internal Carotids*, of which the internal is the most remote from the median line.

Name the Branches and Sub-branches of the External Carotid Artery.<sup>2</sup> (Fig. 55.) It has 8 branches, as follows, viz.—

*Superior Thyroid*,<sup>4</sup> arising below the greater cornu of the hyoid bone.

Muscular.	Hyoid.	Superior Laryngeal.
Glandular.	Superficial Descending.	Crico-thyroid.

*Lingual*,<sup>5</sup> under the hyo-glossus muscle to the tongue.

Hyoid.	Dorsalis Linguae.	Sublingual.	Ranine.
--------	-------------------	-------------	---------

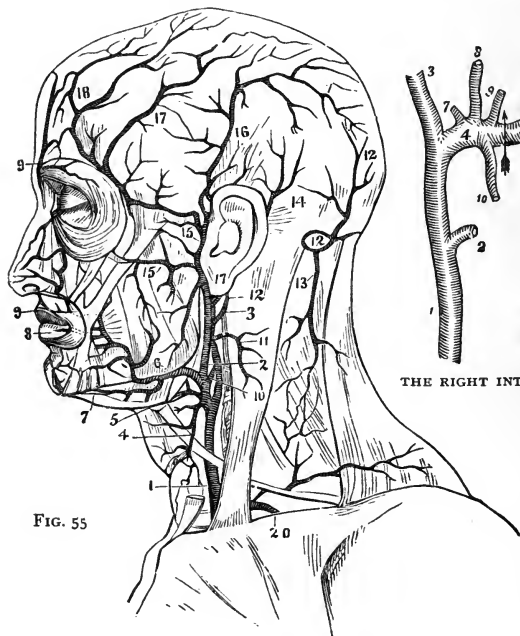


FIG. 55

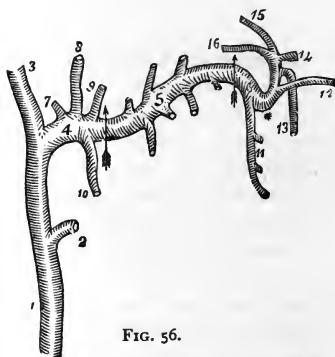


FIG. 56.

THE RIGHT INTERNAL MAXILLARY ARTERY

*Facial*,<sup>6</sup> crosses the lower jaw at the anterior angle of the masseter.

Inferior or Ascending Palatine.	Submental. <sup>7</sup>	2 Coronary. <sup>8,9</sup>
Tonsillar.	Muscular.	Lateralis Nasi.
Submaxillary.	Inferior Labial.	Angular.

*Occipital*,<sup>10</sup> lies in the occipital groove of the temporal bone.

Muscular.	Inferior Meningeal.	Cranial Branches, over
Auricular.	Arteria Princeps Cervicis. <sup>13</sup>	the occiput.

*Posterior Auricular*,<sup>14</sup> ascends under cover of the parotid gland.

Stylo-mastoid.	Auricular.	Muscular.	Glandular.
----------------	------------	-----------	------------

*Ascending Pharyngeal*, lies on the rectus capitis anticus major.

External Branches.	Pharyngeal and Meningeal Branches.
--------------------	------------------------------------

*Temporal*,<sup>15</sup> the smallest of the termini of the external carotid, begins in the parotid gland, crosses the zygomatic arch, and divides into anterior<sup>18</sup> and posterior temporal.<sup>16</sup>

Transverse Facial. <sup>15</sup>	Middle Temporal. <sup>17</sup>	Anterior Auricular.
----------------------------------	--------------------------------	---------------------

*Internal Maxillary*,<sup>4</sup> the other terminal branch of the external carotid,<sup>1</sup> is divided into three portions, Maxillary,<sup>4</sup> Pterygoid,<sup>5</sup> and Spheno-maxillary,<sup>6</sup> which respectively give off the following branches: (Fig. 56.)

Deep Auricular, to the tragus and canal.	Deep Temporal, ant. and posterior.	Alveolar. <sup>11</sup> Infra-orbital. <sup>12</sup>
Tympanic, <sup>7</sup> entering the Glaserian fissure.	Pterygoid Branches, to those muscles.	Descending Palatine. <sup>13</sup> Vidian. <sup>16</sup>
Middle Meningeal. <sup>8</sup>	Masseteric, to the	Pterygo-palatine. <sup>15</sup>
Small Meningeal. <sup>9</sup>	masseter muscle.	Spheno-palatine or Nasal. <sup>14</sup>
Inferior Dental, <sup>10</sup> divides into Incisor and Mental.	Buccal, to the bucci- nator muscle.	

**Describe the Internal Carotid Artery.** It ascends in front of the transverse processes of the three upper cervical vertebræ, and close to the tonsil, traverses the carotid canal in the temporal bone, and after piercing the dura mater by the anterior clinoid process, divides into its terminal branches. Its branches are the

*Tympanic*, enters the tympanum from the carotid canal, and anastomoses on the membrana tympani with the tympanic branch of the internal maxillary, the stylo-mastoid, and the Vidian arteries.

*Arteria Receptaculi*, numerous small vessels going to the walls of the sinuses, the Gasserian ganglion and the pituitary body; one of them, to the dura mater, is called the *Anterior Meningeal*.

*Ophthalmic*, arises from the cavernous portion, enters the orbit through the optic foramen, terminating at the inner angle of the eye into the frontal and nasal branches. It gives off,—

Lachrymal.	Short Ciliary.	Anterior Ethmoidal.
Arteria Centralis Retinæ.	Anterior Ciliary.	Palpebral.
Muscular Branches.	Supraorbital.	Nasal.
Long Ciliary.	Posterior Ethmoidal.	Frontal.

*Anterior Cerebral*, joined to its fellow by the anterior communicating branch, about 2 lines long.

*Middle Cerebral*, in the fissure of Sylvius; divides into 3 branches, anterior, median, and posterior.

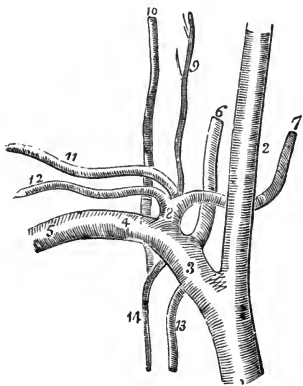
*Anterior Choroid*, to the choroid plexus, corpus fimbriatum, etc.

*Posterior Communicating*, anastomoses with the posterior cerebral, a branch of the basilar.

**What is the Circle of Willis?** An anastomosis at the base of the brain, between the branches of the internal carotid and vertebral arteries, to equalize the cerebral circulation. The 2 *Vertebral* arteries join to form the *Basilar*, which ends in 2 *Posterior Cerebral*. These are connected with the *Internal Carotid* by the 2 *Posterior Communicating*. The circle is completed by the connection of the 2 *Anterior Cerebral* branches of the internal carotid through the short *Anterior Communicating* artery.

**Describe the Subclavian.** It arises on the right side from the innominate, on the left side from the arch of the aorta, and is divided into 3 portions by the scalenus anticus, which crosses it just external to the origin of the thyroid axis, viz.—the parts internal, behind, and external to that muscle. At the outer border of the 1st rib, the subclavian becomes the axillary artery. Its upper border is a little above the clavicle, and it is separated from the subclavian vein by the scalenus anticus at its origin from the first rib. Its branches are all given off from its first portion, except the *Superior Intercostal*, which on the right side arises from the second portion.

FIG. 57.



*Vertebral*,<sup>6</sup> passing up the neck, through the foramina in the transverse processes of six cervical vertebræ, and enters the skull by the foramen magnum, where it joins its fellow to form the *Basilar Artery*. Its branches are—

Lateral Spinal Branches.

Anterior Spinal.

Muscular Branches.

Posterior Spinal.

Posterior Meningeal.

Inferior Cerebellar.

*The Basilar*, formed by the junction of the vertebrals, gives off on each side a transverse, anterior, and superior cerebellar, and ends in the two posterior cerebral. (See *Circle of Willis*, above.)



**THYROID AXIS,**<sup>8</sup> at once divides into the three following branches:—

*Inferior Thyroid,*<sup>7</sup> to the thyroid gland, giving off,—

Laryngeal Branch.	Œsophageal Branches.
Tracheal Branches.	Ascending Cervical. <sup>9</sup>

*Transversalis Colli,*<sup>11</sup> divides beneath the margin of the trapezius into—

Superficial Cervical.	Posterior Scapular.
-----------------------	---------------------

*Suprascapular,*<sup>12</sup> to the shoulder-joint and the dorsum of the scapula, anastomosing there with the posterior- and sub-scapular.

*Internal Mammary,*<sup>13</sup> arises opposite the thyroid axis, descends upon the costal cartilages, and ends at the 6th interval, in the musculo-phrenic and superior epigastric, the latter anastomosing with the deep epigastric branch of the external iliac. Its branches are the—

Comes Nervi Phrenici,	Pericardiac.	Perforating.
or Superior Phrenic.	Sternal.	Musculo-phrenic.
Mediastinal.	Anterior Intercostal.	Superior Epigastric.

*Superior Intercostal,*<sup>14</sup> gives off branches in the intercostal spaces to the posterior spinal muscles and to the spinal cord.

*Profunda Cervicis,*<sup>10</sup> supplies the muscles of the back of the neck, and anastomoses with the arteria princeps cervicis of the occipital.

**Describe the Axillary.**<sup>5</sup> It is the continuation of the subclavian, extending from the edge of the 1st rib to the lower margin of the armpit muscles, where it becomes the brachial. It has 7 branches, viz.—

*Superior Thoracic,* to the pectoral muscles and walls of the thorax.

*Acromial Thoracic,* branches are thoracic, acromial, descending.

*Thoracica Longa,* to the muscles of the chest and mammary gland.

*Thoracica Alaris,* a small branch to the axillary glands.

*Subscapular,* to the inferior dorsum of the scapula. Its branches anastomose with the supra- and posterior scapular, and are the—

Subscapular.	Dorsalis Scapulae.	Median Branch.
--------------	--------------------	----------------

*Posterior Circumflex,* to the deltoid muscle and the shoulder-joint.

*Anterior Circumflex,* to the joint and the head of the bone, anastomosing with the posterior circumflex and acromial thoracic.

**Describe the Brachial.** It is the continuation of the axillary from the lower margin of the teres major tendon to its bifurcation into the radial and ulnar, which is usually about one-half inch below the bend of the elbow. The median nerve crosses it from the outside to the inside at its centre. Its branches are the—

*Superior Profunda,* winds over the arm in the musculo-spiral groove, giving off the posterior articular to the elbow anastomosis.

*Nutrient Branch*, enters the nutrient canal.

*Inferior Profunda*, to the elbow-joint anastomosis.

*Anastomotica Magna*, anastomoses with the posterior articular, inferior profunda, anterior and posterior ulnar recurrent.

*Muscular Branches*, to the muscles in the course of the artery.

**Describe the Radial.** It extends from the bifurcation of the brachial to the deep palmar arch, and gives off the following branches respectively, in the forearm, the wrist, and the hand, viz.—

<i>Radial Recurrent.</i>	<i>Posterior Carpal.</i>	<i>Princeps Pollicis.</i>
<i>Muscular.</i>	<i>Metacarpal.</i>	<i>Radialis Indicis.</i>
<i>Superficialis Volæ.</i>	<i>Dorsalis Pollicis.</i>	<i>Perforantes.</i>
<i>Anterior Carpal.</i>	<i>Dorsalis Indicis.</i>	<i>Interosseæ.</i>

**Name the Branches of the Ulnar.** It extends from the division of the brachial to the superficial palmar arch. It has 8 branches, viz.—

<i>Anterior Ulnar Recurrent.</i>	<i>Muscular.</i>	<i>Deep or Communicating</i>
<i>Posterior Ulnar Recurrent.</i>	<i>Anterior Carpal.</i>	<i>Branch.</i>
<i>Interosseous</i> {	<i>Anterior.</i>	<i>Posterior Carpal. Digital.</i>
	<i>Posterior.</i>	

**Describe the Palmar Arches.** *The Superficial Palmar Arch* is that part of the ulna artery lying in the palm of the hand, and anastomosing with the superficialis volæ from the radial, and a branch from the radialis indicis, at the root of the thumb. It gives off 4 branches, the digital, to the sides of the fingers, except the inside of the index finger, which is supplied by the radialis indicis. *The Deep Palmar Arch* is formed by the palmar portion of the radial artery anastomosing with the deep or communicating branch of the ulna. It gives off the radialis indicis, palmar interosseæ, perforating and recurrent branches.

**Describe the Thoracic Aorta.** It begins on the left of the spine, at the lower border of the 3d dorsal vertebra, and ends at the aortic opening in the diaphragm directly in front of the last dorsal vertebra. Its branches are as follows :—

*Pericardiac Branches*, irregular in number and origin.

*Bronchial*, also vary in number and origin; generally one on the right side and two on the left. They nourish the lungs.

*Œsophageal*, 4 or 5, anastomose on the œsophagus with branches of the inferior thyroid, phrenic, and gastric.

*Posterior Mediastinal*, numerous small vessels.

*Intercostals*, usually 10 on each side, each dividing into an anterior and a posterior branch. The *anterior* divides again into two along the adjacent borders of the ribs, supplying the intercostal muscles and anastomosing with

branches of the internal mammary and axillary. The *posterior* divides into a spinal branch going to the vertebræ and the spinal cord, and a muscular to the muscles of the back.

**Describe the Abdominal Aorta.** It begins where the thoracic ends, and terminates at the 4th lumbar vertebra in the common iliacs. Its branches are as follows:—

**CÆLIAC AXIS,**<sup>2</sup> arises opposite the margin of the diaphragm, runs forwards for half an inch and divides into the Gastric, Hepatic, and Splenic arteries, occasionally giving off one of the phrenics.

*Gastric,*<sup>3</sup> supplies the stomach along its lesser curvature, anastomosing with the aortic, œsophageal, splenic, and hepatic branches.

*Hepatic,*<sup>4</sup> divides in the transverse fissure of the liver into the right and left branches, to the lobes of that organ; also the—

Pyloric.  
Cystic.

Gastro-duodenalis { Gastro-epiploica Dextra  
Pancreatico-duodenalis.

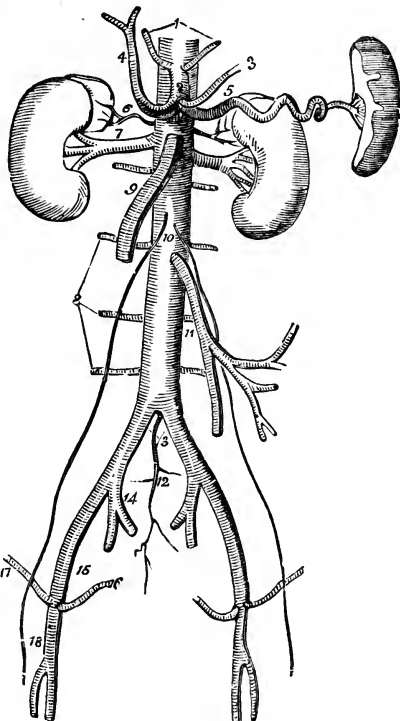
*Splenic,*<sup>5</sup> the largest branch of the cœliac axis, passes by a very tortuous course to the spleen, giving off the following:—

Pancreaticæ Parvæ.                      Gastric (vasa brevia).  
Pancreatica Magna.                      Gastro-epiploica Sinistra.

*Phrenic,*<sup>1</sup> one on each side, but usually only one arises from the aorta, the other springing from either the cœliac axis or the renal artery. They go to the under surface of the diaphragm.

*Superior Mesenteric,*<sup>9</sup> supplies the small intestine, cæcum, ascending and

FIG. 58.



transverse colon. Arising about one-fourth inch below the cœliac axis, it arches forwards, downwards, and to the left, giving off—

Inferior Pancreatico-duodenal. Ileo-colic.

Vasa Intestini Tenuis. Colica Dextra and Media.

*Inferior Mesenteric*,<sup>11</sup> supplies the descending colon, sigmoid flexure, and most of the rectum, giving off the following branches:—

Colica Sinistra. Sigmoid. Superior Hemorrhoidal.

*Supra-renal*,<sup>6</sup> arise one on each side, opposite the origin of the superior mesenteric, passing to the supra-renal capsules.

*Renal*,<sup>7</sup> one from each side, just below the preceding, pass to the kidney, at the hilum having the middle place between the ureter behind and the renal vein in front. U. A. V. (you 'ave!)

*Spermatic*,<sup>10</sup> one on each side, in the male through the inguinal canal to the testes; in the female to the ovaries, uterus, and the skin of the labia and groins.

*Lumbar*,<sup>8</sup> usually 4 on each side, analogous to the intercostals. They each divide into two branches, the—

Dorsal, giving off a spinal branch. Abdominal.

*Middle Sacral*,<sup>12</sup> arises just at the bifurcation of the aorta; it descends along the sacrum and coccyx, giving off numerous branches.

**Describe the Common Iliac Arteries.** They extend from the bifurcation of the aorta at the 4th lumbar vertebra to near the lumbo-sacral articulation, where they each divide into the external<sup>15</sup> and internal iliac.<sup>14</sup> They are about 2 inches in length, the right being a little longer than the left one, and each is crossed by the ureter, just before its bifurcation.

**Describe the Internal Iliac.**<sup>14</sup> It is about 1½ inches long, and extends from the lumbo-sacral articulation to the great sacro-sciatic notch, where it divides into an anterior and a posterior trunk. From the anterior trunk are given off from above downwards, the—

*Superior Vesical*, the remaining pervious part of the fœtal hypogastric artery.

It sends branches to the vas deferens and the ureter; and one, the *Middle Vesical*, to the base of the bladder.

*Obturator*, through the canal in the obturator foramen to the thigh, where it divides into an internal and external branch. Within the pelvis it gives off an iliac, vesical, and a pubic branch. In one out of 3½ cases this artery arises from the epigastric.

*Inferior Vesical*, to the bladder, prostate gland, and vesiculæ seminales. In the female this artery is called the *Vaginal*.

*Middle Hemorrhoidal*, to the rectum.

*Uterine*, in the female, anastomosing with the ovarian.

*Internal Pudic*, the smaller of the terminal branches of the anterior trunk, supplies the external generative organs. Its branches in the pelvis are numerous and small, in the perineum they are—

Inferior Hemorrhoidal.	Artery of the Bulb.
Superficial Perineal.	Artery of the Corpus Caverosum.
Transverse Perineal.	Dorsal Artery of the Penis.

*Sciatic*, the other terminal branch, supplies the muscles on the back of the pelvis. Its branches are as follows:—

Muscular Branches.	Coccygeal.	Muscular, external
Hemorrhoidal Branches.	Inferior Gluteal.	to the pelvis.
Vesical Branches.	Comes Nervi Ischiadici.	Articular Branches.

THE POSTERIOR TRUNK gives off the following:—

*Ilio-lumbar*, dividing into lumbar and iliac branches.

*Lateral Sacral*, superior and inferior on each side.

*Gluteal*, the continuation of the posterior trunk, divides into a superficial and a deep branch, to the glutei muscles, the skin over the sacrum, and the hip-joint. Before dividing it gives a nutrient branch to the ilium, and some muscular branches.

**Describe the External Iliac.** It extends to beneath the centre of Poupart's ligament, where it enters the thigh and becomes the *Femoral Artery*, lying between the femoral vein on the inside and the anterior crural nerve on the outside—V.A.N. Its branches are, small muscular and glandular, and—

*Epigastric*, which usually arises a few lines above Poupart's ligament, passes between the peritoneum and the transversalis fascia, to the sheath of the rectus which it perforates, and ascends behind that muscle, to anastomose by numerous branches with the terminal branches of the internal mammary and inferior intercostal. It gives off—

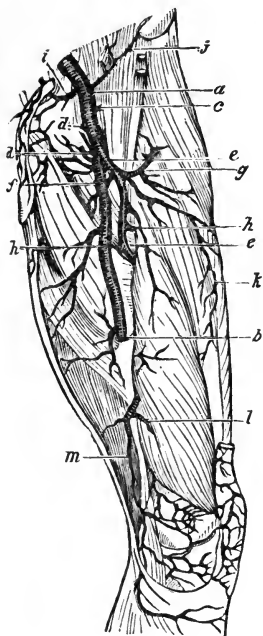
Cremasteric.	Pubic.	Muscular Branches.
--------------	--------	--------------------

*Circumflex Iliac*, arises opposite to the epigastric, passes along the crest of the ilium to anastomose with the ilio-lumbar, gluteal, lumbar, and epigastric arteries.

**Describe the Femoral Artery.** It extends from Poupart's ligament to the opening in the adductor magnus, where it becomes the popliteal artery. Its course corresponds to a line drawn from a point midway between the anterior superior spine of the ilium and the symphysis pubis, to the inner side of the inner condyle of the femur. It lies in a strong fibrous sheath with the femoral vein, but divided from the latter by a fibrous partition. It bisects Scarpa's triangle in the upper part of its course, where it is superficial, and rests on the inner margin of the psoas, which separates it from the capsule of the hip-joint. Its branches are as follows:—

*Superficial Epigastric, c* to the superficial fascia of the abdomen.

FIG. 59.



*Superficial Circumflex Iliac, j* to the skin over the iliac crest.

*Superficial External Pudic, d* to the integument of the lower abdomen, penis, and scrotum.

*Deep External Pudic, d* to the skin of the scrotum and perineum.

*Profunda Femoris, e* arises posteriorly about 1 or 2 inches below Poupart's ligament, and descends to the lower third of the back of the thigh, giving off the following branches:—

Ext. Circumflex. *g* Int. Circumflex. *f*  
3 Perforating. *h*

*Muscular Branches, k* to the sartorius and vastus internus.

*Anastomotica Magna*, arises from the femoral in Hunter's canal, and divides into a superficial and deep branch, the latter anastomosing around the knee-joint with the superior external and internal articular arteries, and the recurrent tibial.

**Describe the Popliteal Artery.** It extends from the opening in the adductor magnus to the lower border of the popliteus muscle, where, having passed behind the knee-joint, it divides into the anterior and posterior tibial arteries. Its branches are as follows:—

*Superior Muscular Branches.*

*Inferior Muscular, or Sural.*

*Cutaneous Branches.*

*Superior External Articular.*

*Superior Internal Articular. l*

*Azygos Articular.*

*Inferior External Articular.*

*Inferior Internal Articular.*

These are distributed around the knee-joint in a free anastomosis.

The azygos branch perforates the posterior ligament of the joint to reach the internal ligaments and the synovial membrane.

**Describe the Anterior Tibial Artery.** It extends from the bifurcation of the popliteal to the front of the ankle-joint, where it becomes the *Dorsalis Pedis*. It passes between the two heads of the tibialis posticus, over the upper edge of the interosseus membrane and along its anterior surface, resting on

the tibia for its lower one-third. It is accompanied by the anterior tibial nerve close to it externally, and is crossed below by the tendon of the extensor proprius pollicis. Its branches are—

*Recurrent Tibial. Muscular. External and Internal Malleolar.*

**Describe the Dorsalis Pedis Artery.** It is the continuation of the anterior tibial, extending from the front of the ankle-joint to the 1st interosseous space, where it terminates in the *Dorsalis Hallucis* and the *Communicating*. The anterior tibial nerve lies close to its outer side. Its branches are as follows :—

*Tarsæ*, passing outwards along the tarsus.

*Metatarsæ*, giving off 3 interosseæ, and they 7 digital.

*Dorsalis Hallucis*, to the great toe and the inner side of the second toe by its 3 digital branches.

*Communicating*, which dips down into the sole of the foot in the 1st interosseous space of the metatarsus, to inosculate with the external plantar; and gives off 2 digital branches. to the plantar surface of the great and second toes.

**Describe the Posterior Tibial Artery.** It is a large vessel, extending from the bifurcation of the popliteal along the back of the tibia to the fossa below the inner malleolus, where it divides into the *Internal* and *External Plantar*. The posterior tibial nerve crosses it a short way below its origin and then lies close to its outer side for the rest of its course. Its branches are as follows :—

*Peroneal*, along the fibular side, giving off the anterior peroneal, muscular branches, and the nutrient artery of the fibula.

*Nutrient of the Tibia*, the largest nutrient artery of bone.

*Muscular Branches*, to the posterior muscles of the leg.

*Communicating*, a branch to the peroneal artery.

*Internal Calcanean Branches*, to the heel and sole of the foot.

**Describe the Internal Plantar.** This artery is the smallest of the terminating branches of the posterior tibial, and passes along the inner side of the foot and great toe.

**Describe the External Plantar Artery.** It sweeps across the plantar aspect of the foot in a curve, the convexity of which is directed outwards and forwards; and at the interval between the bases of the 1st and 2d metatarsal bones it inosculates with the communicating branch from the dorsalis pedis, forming the *Plantar Arch*, or the *Stirrup Anastomosis*. It gives off numerous muscular branches, and the—

*Posterior Perforating*, 3 small branches passing through the 3 outer interosseous spaces.

*Digital*, 4 branches supplying the sides of the 3 outer toes and the outer side of the 2d toe; its inner side, together with the great toe, being supplied by the *Digital Branches* of the *Dorsalis Pedis Communicating*.

**Describe the Pulmonary Artery.** It alone of the arteries carries venous blood, which it conveys from the right side of the heart to the lungs. It is only about 2 inches long, and nearly all within the pericardium; arising from the right ventricle in front of the ascending aorta, passing upwards and backwards to the under surface of the arch of the aorta, where it bifurcates, and is connected to the aorta by a fibrous cord, the remains of the ductus arteriosus of the fœtus. Its terminal branches are the—

*Right and Left Pulmonary Arteries*, the latter being the shorter of the two; pass horizontally outwards to the roots of their respective lungs, where each divides into two branches, which again and again subdivide to ramify throughout the lung tissue and end in the capillaries of those organs.

### ARTERIAL ANASTOMOSES.

**Describe the Anastomosis around the Shoulder-joint.** It is formed by the following 8 arteries, viz.—

<i>Posterior Scapular</i> , br. of transv. colli.	<i>Suprascapular</i> , br. of thyroid axis.
<i>Subscapular</i> , br. of axillary.	<i>Ant. Circumflex</i> , br. of axillary.
<i>Dorsalis Scapulæ</i> , br. of subscapular.	<i>Post. Circumflex</i> , br. of axillary.
<i>Infraspinous</i> , br. of dorsalis scapulæ.	<i>Acromial</i> , br. of acromio-thoracic.

**What Arteries Anastomose around the Elbow-joint?** The—

<i>Superior Profunda</i> , br. of brachial.	<i>Radial Recurrent</i> , br. of radial.
<i>Inferior Profunda</i> , br. of brachial.	<i>Recurrent Interosseous</i> , br. of posterior interosseous.
<i>Anastomotica Magna</i> , br. of brachial.	<i>Anterior Ulnar Recurrent</i> , br. of ulnar.
<i>Posterior Articular</i> , br. of superior profunda.	<i>Posterior Ulnar Recurrent</i> , br. of ulnar.

**What Arteries Anastomose around the Hip-joint?** They are the *Gluteal*, *Ilio-lumbar*, and *Circumflex Iliac*, with the *External Circumflex*. *Obturator* and *Sciatic*, with the *Internal Circumflex*. *Comes Nervi Ischiadici*, with the *Perforating* branches of the *Profunda*.

**Name the Arteries Anastomosing around the Knee-joint.** The—

<i>Descending</i> , br. of ext. circumflex.	<i>Sup. Int. Articular</i> , br. of popliteal.
<i>Anastomotica Magna</i> , br. of femoral.	<i>Inf. Ext. Articular</i> , br. of popliteal.
<i>Inferior Perforating</i> , br. of profunda.	<i>Inf. Int. Articular</i> , br. of popliteal.
<i>Superior Ext. Articular</i> , br. of popliteal.	<i>Recurrent Tibial</i> , br. of anterior tibial.

**How is the Collateral Circulation established after Ligature of the Carotid or Subclavian?** By the following anastomoses, viz.—

*Superior Thyroid*, br. of external carotid, with the *Inferior Thyroid*, br. of the thyroid axis, from the subclavian.



*Arteria Princeps Cervicis*, br. of occipital, from the external carotid, with the *Vertebral*, br. of subclavian, and the *Profunda Cervicis*, br. of the superior intercostal, from the subclavian.

**What is the Longest Anastomosis in the Body?** That between the subclavian and the external iliac by the anastomosis of the *Superior Epigastric*, br. of the internal mammary, with the *Deep Epigastric*, br. of the external iliac.

[The circle of Willis has been described on page 106; the palmar and plantar arches on pages 108 and 113 respectively; and the anastomosis on the membrana tympani on page 105.]

## THE VEINS.

**What are the Veins?** Vessels carrying blood towards the heart. Their walls are composed of 3 coats, an internal, serous; a middle, muscular; and an external, fibrous. They all carry carbonized or venous blood, except the pulmonary veins, which bring oxygenated blood to the left side of the heart. The deep veins accompany the arteries, generally in the same sheath, and are given the same names. The secondary arteries, as the radial, ulnar, brachial, etc., have each two veins, called *Venæ Comites*. The superficial veins are usually unaccompanied by arteries, and lie, as a rule, between the layers of the superficial fascia, terminating in the deep veins. Many veins are so irregular in their origin that they cannot be accurately described; they all anastomose with each other much more freely than do the arteries.

**What are Sinuses?** They are venous channels, differing from veins in structure, but answering the same purpose. Those of the cranium are formed by the separation of the layers of the dura mater.

**How are the Veins divided?** Into the *Pulmonary*, *Systemic*, and *Portal Systems*; the latter being an appendage of the systemic, its capillaries ramifying in the liver.

**What Veins have no Valves?** The *venæ cavæ*, hepatic, portal, renal, uterine, ovarian, cerebral, spinal, pulmonary, umbilical, and the very small veins.

**Name the principal Veins of the Head and Neck.** They are the—

(1.) Exterior veins.	(2.) Veins of the diploë and cranium.	
<i>Facial.</i>	<i>Veins of the Diploë.</i>	<i>Transverse Sinus.</i>
<i>Temporal.</i>	<i>Cerebral and Cerebellar.</i>	<i>Cavernous Sinus.</i>
<i>Internal Maxillary.</i>	<i>Superior Longitudinal Sinus.</i>	<i>Occipital Sinus.</i>
<i>Temporo-maxillary.</i>	<i>Inferior Longitudinal Sinus.</i>	<i>Superior Petrosal Sinus.</i>
<i>Posterior Auricular.</i>	<i>Straight Sinus.</i>	<i>Inferior Petrosal Sinus.</i>
<i>Occipital.</i>	<i>Circular Sinus.</i>	<i>Lateral Sinus.</i>

(3.) Veins of the neck draining the above-named.

*External Jugular*,<sup>6</sup> terminating in the subclavian vein.<sup>4</sup>

*Posterior External Jugular*, opens into the external jugular.

*Anterior Jugular*,<sup>7</sup> enters the subclavian vein near the external jugular.

*Internal Jugular*,<sup>5</sup> formed by the junction of the two last-named sinuses at the jugular foramen, and uniting with the subclavian vein to form the innominate, at the root of the neck. In its course it receives the facial, lingual, pharyngeal, superior and middle thyroid veins, and the occipital.

*Vertebral*, descends the foramina in the transverse processes of the cervical vertebræ, and empties into the innominate vein.

**Name the Veins of the Upper Extremity.** They are in two sets, superficial and deep. The deep follow the arteries, generally as *venæ comites*, beginning in the hand as *Digital*, *Interosseous*, and *Palmar* veins, they unite in the *Deep Radial* and *Ulnar* which unite to form the *Venæ Comites* of the brachial artery at the bend of the elbow. The superficial veins lie in the superficial fascia; they are as follows:—

<i>Radial</i> .....	} <i>Median Cephalic.</i> <i>Cephalic.</i> }	} AXILLARY VEIN.
<i>Median</i> .....		
<i>Anterior and Posterior Ulnar</i> .....	} <i>Median Basilic.</i> <i>Basilic.</i> }	

**Name the principal Veins of the Thorax.** They are as follows, viz.—

<i>Internal Mammary.</i>	<i>Bronchial.</i>	<i>Right Azygos (major).</i>
<i>Inferior Thyroid.</i>	<i>Mediastinal.</i>	<i>Left Lower Azygos (minor).</i>
<i>Intercostal.</i>	<i>Pericardiac.</i>	<i>Left Upper Azygos (minimus).</i>

**What are the Azygos Veins?** They supply the place of the *venæ cavæ* in the region where these trunks are deficient, being connected with the heart. *The Right Azygos*<sup>17</sup> begins by a branch from the right lumbar veins usually, passes through the aortic opening in the diaphragm, and ends in the superior vena cava, having drained 9 or 10 right lower intercostals, the vena azygos minor, the right bronchial, œsophageal, mediastinal, and vertebral veins. *The Left Lower Azygos*<sup>18</sup> begins by a branch from the left lumbar or renal, passes the left crus of the diaphragm, crosses the vertebral column and ends in the right azygos, having drained 4 or 5 lower intercostals. *The Left Upper Azygos* drains 2 or 3 left intercostals and empties into either of the other two. It is often wanting, its place being filled by the left superior intercostal vein.<sup>21</sup>

**Name the Spinal Veins.** They may be arranged into 4 sets, as follows, viz.—

*Medulli-spinal*, the veins of the spinal cord, which lie in plexus form between the pia mater and arachnoid. They unite into 2 or 3 small trunks near the base of the skull, which terminate in the inferior cerebellar veins or in the petrosal sinuses.

*Venæ Basis Vertebrarum*, empty into the anterior longitudinal.

*Longitudinal*, in two plexuses, anterior and posterior, running the whole length of the spinal canal. The posterior join the dorsi-spinal veins, the anterior empty into the vertebral, intercostal, lumbar, and sacral veins in their various regions.

*Dorsi-spinal*, form a plexus around the spines, processes, and laminae of all the vertebrae. They empty into the vertebral, intercostal, lumbar, and sacral veins in their respective regions.

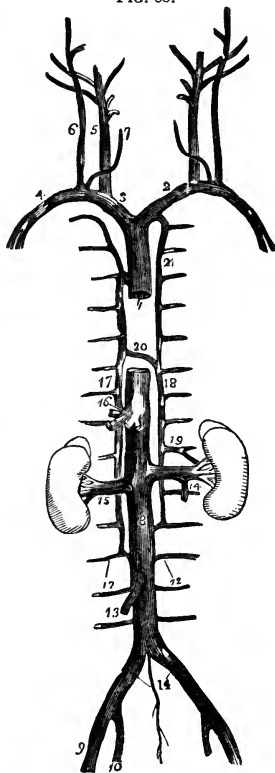
**Describe the Subclavian Vein.** It is the continuation of the axillary, extending from the outer margin of the 1st rib to the sternoclavicular articulation, where it unites with the internal jugular to form the innominate vein. At the angle of junction enters the thoracic duct on the left side of the body and the right lymphatic duct on the right side. In its course it receives the external and anterior jugular veins and a branch from the cephalic.

**Describe the Venæ Innominatæ.** The two innominate veins are each formed by the union of the subclavian and internal jugular, and unite below the 1st costal cartilage to form the superior vena cava. *The Right Innominate*<sup>3</sup> is about 1½ inch long, and receives, besides its constituent branches, the right internal mammary, right inferior thyroid, and right superior intercostal veins. *The Left Innominate*<sup>2</sup> is about 3 inches long, and in its course it receives the vertebral, inferior thyroid, internal mammary, and superior intercostal veins of the left side.

**Describe the Superior Vena Cava.**<sup>1</sup> It is a short trunk about 2½ or 3 inches in length, formed by the union of the venæ innominatæ, and receives all the blood from the upper half of the body, terminating in the right auricle of the heart. It is half covered by the pericardium, and receives the vena azygos major and small pericardiac and mediastinal veins.

**Name the Principal Veins of the Lower Extremity.** They are in two sets, superficial and deep. The deep are the *Venæ Comites* of the anterior and

FIG. 60.



posterior tibial and peroneal arteries, which collect the blood from the deep parts of the foot and leg, and unite in the—

*Popliteal*, which becomes the *Femoral*, and it the *External Iliac* in the same manner as the respectively-named arteries.

The superficial veins of the lower extremity are the—

*Internal or Long Saphenous*, on the inside of the leg and thigh, enters the femoral at the saphenous opening  $1\frac{1}{2}$  inch below Poupart's ligament. In its course it receives the following:—

Cutaneous Branches.	Superficial Circumflex Iliac.
Superficial Epigastric.	Pudic. Communicating Branches.

*External or Short Saphenous*, formed by branches from the dorsum and outer side of the foot, it ascends behind the outer malleolus, up the middle of the back of the leg, and empties into the popliteal vein.

**Describe the Internal Iliac Vein.**<sup>10</sup> It is formed by the venæ comites of the branches of the internal iliac artery, except the umbilical. It terminates with the external iliac, at the sacro-iliac articulation, to form the common iliac vein. It receives the following veins:—

<i>Gluteal.</i>	<i>Internal Pudic.</i>	<i>Hemorrhoidal and Vesico-</i>	<i>Uterine and Vagi-</i>
<i>Sciatic.</i>	<i>Obturator.</i>	<i>prostatic, in the male.</i>	<i>nal Plexuses, in the female.</i>

**Describe the Common Iliac Veins.**<sup>11</sup> They are each formed by the union of the two iliac veins as above described, and unite between the 4th and 5th lumbar vertebræ to form the inferior vena cava, the right common iliac being the shortest of the two. Each receives the *Ilio-lumbar*, sometimes the *Lateral Sacral*, and the left one in addition the *Middle Sacral Vein*, which sometimes ends in the vena cava.

**Describe the Inferior Vena Cava.**<sup>8</sup> It extends from the junction of the two common iliac veins, passing along the front of the spine, through the tendinous centre of the diaphragm, to its termination in the right auricle of the heart. It receives the following veins:—

<i>Lumbar.</i> <sup>12</sup>	<i>Renal.</i> <sup>15</sup>	<i>Phrenic.</i>
<i>Right Spermatic.</i> <sup>13</sup>	<i>Supra-renal.</i>	<i>Hepatic.</i> <sup>16</sup>

**Describe the Portal System.** The portal system is formed by the *Superior and Inferior Mesenteric, Splenic, and Gastric Veins*, which collect the blood from the digestive viscera, and by their union behind the head of the pancreas form the *Portal Vein*, which enters the transverse fissure of the liver, where it divides into 2 branches, and these again subdivide, ramifying throughout that organ, therein receiving blood also from the branches of the hepatic artery. Its contents enter the inferior vena cava by the hepatic vein. The portal vein is about 4 inches long, receives the *Gastric and Cystic Veins*, and is

formed by the union of the superior mesenteric and splenic veins, the inferior mesenteric joining the splenic, which also receives one of the gastric, the other emptying into the portal.

**Name the Cardiac Veins.** They return the blood from the tissue of the heart into the right auricle. They are the—

<i>Great Cardiac Vein.</i>	<i>Anterior Cardiac Veins.</i>
<i>Posterior Cardiac Vein.</i>	<i>Venæ Thebesii.</i>

*Coronary Sinus*, is a dilatation of the great cardiac vein, receiving the posterior cardiac and an oblique vein from the left auricle.

**Describe the Pulmonary Veins.** They alone of the veins carry arterial blood, beginning in the capillaries of the lungs, forming a single trunk for each lobule, which, uniting into a single trunk for each lobe, form two main trunks from each lung which open separately into the left auricle. Sometimes the 3 lobe-trunks of the right lung remain separate to their termination in the auricle, and not unfrequently a common opening serves for the 2 left pulmonary veins.

## THE ABSORBENTS.

**What are the Lymphatics?** They are very delicate, transparent vessels, formed of three coats like arteries and veins, found in nearly every part of the body, except the brain, spinal cord, eyeball, cartilage, tendons, membranes of the ovum, placenta, umbilical cord, nails, cuticle, hair, and bone. They are nourished by nutrient vessels, and have valves, but no nerves, so far as known. They convey *lymph* to the blood.

**What are the Lacteals?** They are the lymphatics of the small intestine, conveying the *chyle* therefrom into the blood.

**What are the Lymphatic Glands?** Small solid bodies placed in the course of the absorbent vessels, and found chiefly in the mesentery, along the great blood-vessels, in the mediastina, axilla, neck, front of the elbow, groin, and popliteal space. The lymphatics and lacteals before entering these glands break up into smaller branches, the *afferent vessels*, which form a plexus in the gland, and pass out as *efferent vessels* to unite again in one trunk. They also contain spheroidal bodies about  $\frac{1}{3000}$  inch in diameter. These glands are named after the regions in which they are situated, as the axillary, inguinal, mesenteric, etc.

**Describe the Thoracic Duct.** It is the main channel for the lymph and chyle from the whole body except the right arm and lung, right side of the head, heart, neck, and thorax, and the convex surface of the liver. It begins in the *Receptaculum Chyli*, in front of the 2d lumbar vertebra, passes through the aortic opening in the diaphragm, and at the upper border of the 7th cer-

vical vertebra it curves forwards, outwards, and downwards, terminating in the left subclavian vein at its junction with the internal jugular.

**Describe the Right Lymphatic Duct.** It is about an inch long, terminating in the right subclavian vein at its union with the internal jugular, and draining the lymphatics of those parts which are not connected with the thoracic duct.

### THE NERVOUS SYSTEM.

**How is the Nervous System divided?** Into the *Cerebro-spinal*, or nervous system of animal life; and the *Sympathetic*, or nervous system of organic life.

**What is the Structure of the Nervous tissue?** It is formed of two substances essentially different from each other, the *White* or fibrous, and the *Gray* or vesicular matter. Chemically these contain phosphorized fat, albumen, and water. A third form, the *Gelatinous*, is yet a subject of disagreement among authorities.

**Describe the White Nerve-matter.** It is composed of a number of tubes, each consisting of a central *Axis-cylinder*, surrounded by the *White Substance of Schwann*, and this again enclosed in the tubular membrane, or *Nerve-sheath*. The whole arrangement is precisely analogous to that of a submarine telegraphic cable. A bundle of such tubes is invested by a covering, the *Neurilemma*, or perineurium, and is called a *Nerve*, and is nourished by a minute capillary system of blood-vessels.

**How do Nerves terminate?** Sensory nerves end peripherally as plexuses in their end-organs in the tissues. Motor nerves end peripherally in muscles as plexuses, or plates. Their central termination is not yet understood.

**Of what does the Cerebro-spinal system consist?** Of the brain, the spinal cord, the ganglia, and the cranial and spinal nerves.

### THE BRAIN.

**What are the Membranes of the Brain?** The *dura mater*, the *arachnoid*, and the *pia mater*.

**Describe the Dura Mater.** It is a dense fibrous membrane lining the interior of the skull, and forming the internal periosteum of the cranial bones. It is continuous with the *dura mater* of the spinal cord, and is attached to many parts of the base of the skull. It presents the following for examination:—

*Falx Cerebri*, an arched process sent into the longitudinal fissure of the brain, contains in its upper and lower margins the superior and inferior longitudinal sinuses,

*Tentorium Cerebelli*, a lamina of dura mater supporting the posterior lobes of the brain, and covering the upper surface of the cerebellum. It incloses the lateral and superior petrosal sinuses.

*Falx Cerebelli*, projects between the lateral lobes of the cerebellum, from the tentorium to the foramen magnum.

*Pacchionian Bodies*, clusters of white granulations situated on the outer and inner surfaces of the dura mater, in the superior longitudinal sinus, and on the pia mater, found only after the 7th year, and of unknown function.

**Describe the Arachnoid.** It is the serous sac which forms the middle membrane, having a visceral and a parietal layer, the latter being reflected over the interior surface of the dura mater. *The Anterior Sub-arachnoid Space* is the interval between it and the pia mater of the brain at the base, where it is extended across between the two middle lobes. *The Posterior Sub-arachnoid Space* is a similar interval between the hemispheres of the brain and the medulla oblongata. These spaces communicate together across the crura cerebri; and also with the general ventricular cavity, by an opening in the lower boundary of the 4th ventricle; and contain the cerebro-spinal fluid which forms a water-bed for the nervous centres. The sac of the arachnoid also contains a serous fluid in small quantity.

**What is the Pia Mater?** It is the vascular membrane, being supplied by the branches of the internal carotid and vertebral arteries. It covers the surface of the brain, dipping down into all the sulci, and forms the velum interpositum and choroid plexus of the 4th ventricle; and contains lymphatics and nerves.

**How is the Brain divided?** Into the cerebrum, cerebellum, pons Varolii, and medulla oblongata. Its average weight in the male adult is 49½ oz., in the female 44 oz., of which the cerebrum is about seven-eighths. The extreme weights in 278 male cases were 65 oz. and 34 oz.,—in 191 female cases, 56 oz. and 31 oz.

**Describe the principal Lobes and Fissures of the Cerebrum.** Each lateral half of the cerebrum, or hemisphere, has the following 5 lobes and 8 fissures, besides many of less importance.

*Frontal Lobe*, bounded internally by the longitudinal fissure, below by the fissure of Sylvius, and posteriorly by the fissure of Rolando.

*Parietal Lobe*, extending down to the fissure of Sylvius, and antero-posteriorly from the fissure of Rolando to the parieto-occipital.

*Occipital Lobe*, behind the parieto-occipital fissure.

*Temporo-sphenoidal Lobe*, lying in the middle fossa of the skull, and bounded in front by the fissure of Sylvius.

*Central Lobe, or Island of Reil*, lies in the fissure of Sylvius, covered by the frontal and temporo-sphenoidal lobes.

*Longitudinal Fissure*, separating the two hemispheres.

*Fissure of Sylvius*, at the base of the brain, extending outwards on each side, and dividing into 2 branches, an ascending and a horizontal one. It lodges the middle cerebral artery.

*Fissure of Rolando*, on the superior surface, extending from the longitudinal fissure about its centre, downwards and forwards towards the fissure of Sylvius, separating the frontal and parietal lobes.

*Parieto-occipital Fissure*, extends from the longitudinal fissure outwards for about an inch between the parietal and occipital lobes. It is better marked in a longitudinal section of the brain.

*Calloso-marginal Fissure*, above the gyrus fornicatus on the inner surface of the hemisphere.

*Transverse Fissure*, between the middle lobe and the crus cerebri, at the base of the brain. It admits the pia mater to the lateral ventricle.

*Calcarine Fissure*, also seen on the inner surface, extending from the lower end of the parieto-occipital fissure outwards to the posterior border of the occipital lobe.

*First Temporo-sphenoidal Fissure*, below the fissure of Sylvius, on the lateral surface of the brain.

**Name the principal Convolution of the Cerebrum.** The superior and inner surfaces of each hemisphere are formed of convolutions (*gyri*) with intervening furrows (*sulci*) of various depths, both gyri and sulci being formed of gray matter thus arranged to enable it to present a great extent of surface. The convolutions are not uniform in all brains as to arrangement, nor are they symmetrical in the two hemispheres. The most constant are the following:—

*Gyrus Fornicatus*, the convolution over the corpus callosum, seen on the inner surface, arching from before backwards.

*Convolution of the Longitudinal Fissure*, along the edge of that fissure on the superior surface, curving over the front and back of each hemisphere, to the base of the brain.

*Ascending Frontal*, lies in front of the fissure of Rolando.

*Ascending Parietal*, lies behind the fissure of Rolando.

*Angular Gyrus, or Pli Courbe*, around the posterior end of the first temporo-sphenoidal fissure.

Many other convolutions are named by writers on the localization of cerebral functions, such as the temporo-sphenoidal, occipital, supra-marginal convolutions, etc. Their names will be found sufficiently explanatory of their several locations. The *Cuneus*, *Precuneus*, and *Paracentral Lobule* are names



given to the regions between the calcarine, parieto-occipital, and calloso-marginal fissures, the last-named locality lying in front of the last-named fissure.

**Name the Points in view on the Inferior Surface of the Brain.** From before backwards, excluding the cranial nerves, are the following:—

*Longitudinal Fissure*, its anterior portion.

*Corpus Callosum*, the great transverse commissure of the brain.

*Lamina Cinerea*, a thin, gray layer, beneath the optic tracts.

*Fissure of Sylvius*, between the anterior and temporo-sphenoidal lobes.

*Anterior Perforated Space*, for vessels to the corpora striata.

*Optic Commissure*, formed by the junction of the optic tracts.

*Tuber Cinereum*, a gray lamina behind the optic commissure, forming part of the floor of the 3d ventricle.

*Infundibulum*, a hollow process, connecting the pituitary cavity with the 3d ventricle in the foetus.

*Pituitary Body*, a vascular bi-lobed body, of glandular structure, projects from the infundibulum into the sella turcica of the sphenoid.

*Corpora Albicantia*, two round, white eminences, united together; they are the anterior crura of the fornix folded on themselves.

*Posterior Perforated Space (Pons Tarini)*, for vessels to the optic thalami.

*Crura Cerebri*, or cerebral peduncles, connect the cerebrum with the cerebellum, spinal cord, and medulla oblongata; containing the fibres passing to the basal ganglia. They, with the optic tracts, form the boundaries of the *Inter-peduncular Space*.

*Pons Varolii*, to be described separately. [See page 127.]

**What Ganglia are comprised in the Brain?** Besides the gray matter of the cerebral hemispheres, of the cerebellum, and of the medulla oblongata, there are the following at the base of the brain:—

Olfactory Bulbs.                      Optic Thalami.                      Tuber Annulare.

Corpora Striata.                      Tubercula Quadrigemina.

**Describe the Basal Ganglia.** They are as follows, viz.—

*Olfactory Bulbs* are the ganglia of the sense of smell, lie one on each side of the median line, upon the cribriform plate of the ethmoid, and are connected with the hemispheres by the *Olfactory Tracts*.

*Corpora Striata*, the motor ganglia, are situated in the floor of the lateral ventricles, and therefore within the hemispheres. Each corpus striatum has a—

Caudate Nucleus,—the intraventricular part.

Lenticular Nucleus,—the extraventricular part.

Internal Capsule,—divides these two parts.

*Optic Thalami*, the sensory ganglia, are in the floor of the lateral ventricles,

behind the corpora striata. Each thalamus opticus is divided into an anterior tubercle seen in the lateral ventricle, and a posterior tubercle beneath the fornix.

*Corpora Quadrigemina, or Optic Lobes* (2 nates and 2 testes), lie beneath the posterior lobes, near the union of the cerebrum and cerebellum. They form two single ganglia for vision. [Described under Meso-cephalon.]

*Tuber Annulare*, a ganglion in the substance of the pons Varolii, the seat of indistinct sensation probably.

**Name the Commissures of the Brain.** These connecting bands number 19 in all, of which 10 are longitudinal, and 9 transverse in direction, viz.—

*Longitudinal Commissures.*

Olfactory Tracts.  
 Tænia Semicircularis.  
 Crura Cerebri.  
 Processes e Cerebello ad Testes.  
 Peduncles of the Pineal Gland.  
 Fornix.  
 Infundibulum.  
 Lamina Cinerea.  
 Gyrus Fornicatus.  
 Fasciculus Unciformis.

*Transverse Commissures.*

Anterior Commissure of 3d ventricle.  
 Middle Commissure of 3d ventricle.  
 Posterior Commissure of 3d ventricle.  
 Corpus Callosum.  
 Optic Commissure.  
 Pons Varolii.  
 Fornix, is a transverse commissure as well as a longitudinal one.  
 Posterior Medullary Velum.  
 Valve of Vieussens.

**What are the Ventricles of the Brain?** They are 5 cavities, each of which is situated as follows:—

*Two Lateral Ventricles*, within the substance of the hemispheres.

*Third Ventricle*, between the optic thalami, on the base of the brain.

*Fourth Ventricle*, between the cerebellum and the medulla oblongata.

*Fifth Ventricle*, between the two lateral, in the septum lucidum.

*Ventricle of the Corpus Callosum*, so called, is merely the space between the upper surface of that commissure and the margins of the hemispheres above (*labia cerebri*).

The *Foramina of Monroe* connect the two lateral ventricles with the 3d; the *Iter e Tertio ad Quartam Ventriculum*, or aqueduct of Sylvius, connects the 3d with the 4th.

**Describe and bound the Lateral Ventricles.** They each have 3 *Cornua*, the anterior, middle, and posterior, and are bounded as follows:—

*Roof*,—the corpus callosum.

*Floor*,—the corpus striatum, tænia semicircularis or horny band of *Tarinus*, optic thalamus, choroid plexus, corpus fimbriatum, and the fornix.

*Internally*,—the septum lucidum.

*Externally, behind and in front*,—the brain substance.

**What are the parts above-named?** Some, as the corpus striatum, optic thalamus, etc., have been described already; the others are—

*Corpus Callosum*, the great transverse commissure, arching backwards to become continuous with the fornix, reflected below, forming the *Peduncles* at the entrance of the fissure of Sylvius; and marked above by a depression, the *Raphé*, and longitudinal elevations, the *Striæ Longitudinales* or *Nerves of Lancisi*.

*Tænia Semicircularis*, consists of commissural fibres between the corpus striatum and the optic thalamus.

*Choroid Plexus of Veins*, is the margin of a fold of pia mater which enters at the transverse fissure, passes up the descending cornu, passes through the foramen of Monroe, and as the *Velum Interpositum* spreads out over the roof of the 3d ventricle.

*Corpus Fimbriatum*, or *Tænia Hippocampi*, is a white band, the edge of the posterior pillar of the fornix.

*Fornix*, is a commissure situated beneath the corpus callosum, but continuous with it posteriorly, the *Septum Lucidum* separating them in front. It is of triangular form with the apex in front. Its *Anterior Crura* curve downwards to the base of the brain, are there reflected, forming the *Corpora Albicantia*, and end in the optic thalami. Its *Posterior Crura* pass down the descending horns of the lateral ventricles, as the *Hippocampi Majores*. The *Lyra* is a series of markings on its under surface.

*Septum Lucidum*, consists of 2 layers of white and gray matter, lined by epithelium; is placed vertically between the lateral ventricles, from the raphé of the corpus callosum above to the fornix below. The cavity in its centre is the 5th ventricle.

**Describe the Cornua of the Lateral Ventricles.** The *Anterior Cornu* curves over the anterior end of the corpus striatum into the anterior lobe. The *Posterior Cornu* curves downwards and inwards in the occipital lobe, and contains a smooth eminence, the *Hippocampus Minor*. The *Middle Cornu* descends into the middle lobe to the transverse fissure at the base of the brain, curving backwards, outwards, downwards, forwards, and inwards (B. O. D. F. I.). On its floor are the following:—

*Hippocampus Major*, the doubled-in surface of the gyrus fornicatus.

*Pes Hippocampi*, rounded eminences at the end of the hippocampus.

*Pes Accessorius*, or *Eminentia Collateralis*, between the hippocampi, at the junction of the middle and posterior cornua.

*Corpus Fimbriatum*, a continuation of the posterior pillar of the fornix.

*Choroid Plexus of Veins*, a process of pia mater, already described.

*Fascia Dentata*, the gray serrated edge of the middle lobe.

*Transverse Fissure*, at the extremity of the cornu, extending to the median

line, between the hippocampus major and the optic thalamus. It opens at the base of the brain between the middle lobe and the crus cerebri, and admits the pia mater to the middle cornu.

**Describe and bound the Third Ventricle.** It is a mere fissure, situated between the optic thalami in the median line. It communicates with the lateral ventricles above by the foramina of Monroe, and with the 4th ventricle behind by the *iter e tertio ad quartam ventriculum*. It is crossed by 3 bands, the anterior, middle, and posterior commissures, the middle one being of gray matter, the others of white. In the fœtus its cavity communicates with the 5th ventricle, and through the infundibulum with the cavity of the pituitary body. It is bounded as follows:—

*Roof*,—the velum interpositum, and above it the fornix.

*Floor*,—the parts comprised in the interpeduncular space at the base of the brain, viz.—the lamina cinerea, tuber cinereum, infundibulum, corpora albicantia, and posterior perforated space.

*Anteriorly*,—the anterior crura of the fornix, and the anterior commissure of the ventricle.

*Posteriorly*,—the posterior commissure, and the *iter e tertio*, etc.

*Laterally*,—the optic thalami and the peduncles of the pineal gland.

**Describe and bound the Fourth Ventricle.** The fourth, or ventricle of the cerebellum, lies between the medulla oblongata and the cerebellum. It is considered by some to be a dilatation of the central canal of the spinal cord, and is enclosed posteriorly by the pia mater; an opening in which admits the entrance and exit of the sub-arachnoid fluid from the sub-arachnoidean space of the brain and spinal cord, and a fold of the pia mater called the *Choroid Plexus*. It also communicates with the 3d ventricle by the *iter e tertio*, etc. Its boundaries are as follows:—

*Roof*,—the valve of Vieussens, and the cerebellum.

*Anteriorly*,—the medulla oblongata, and the pons Varolii.

*Posteriorly*,—the cerebellum.

*Laterally*,—the *processus e cerebello ad testes*, the posterior pyramids and the restiform bodies of the medulla oblongata.

*Floor*,—the posterior median fissure of the medulla, the orifice of the central canal of the cord, the locus ceruleus and tænia violacea (both of blue color), the fasculi teretes (2 spindle-shaped elevations) and eminences of origin of certain nerves.

**Describe the Fifth Ventricle.** It is situated between the two layers of the septum lucidum, and therefore between the lateral ventricles. Its roof is formed by the corpus callosum, and in the fœtus it communicates with the 3d ventricle by an opening between the pillars of the fornix. It usually contains fluid.

**What is the Meso-cephalon?** It comprises the parts which connect the cerebrum with the cerebellum and the medulla oblongata, and includes the following structures, viz :—

*Pons Varolii*, a great transverse commissure seen at the base of the brain in front of the medulla. Its fibres connect the hemispheres of the cerebellum with each other and the medulla.

*Crura Cerebri*, or *Peduncles of the Cerebrum*, extend from the pons to the corpora striata and optic thalami, and consist of the *Peduncular Fibres* which pass from the medulla to the ganglia named, and thence upwards to the gray matter of the hemispheres as the *Corona Radiata*. Each crus contains in its centre a mass of gray matter called the *locus niger*.

*Valve of Vieussens*, is a thin lamina forming the roof of the iter e tertio ad quartam ventriculorum, and stretched between the two processus e cerebello ad testes. Its *Frenulum* is a ridge descending on its upper part from the corpora quadrigemina.

*Corpora Quadrigemina*, or *Optic Lobes*, are 4 spherical eminences placed together above the valve of Vieussens, and behind the 3d ventricle beneath the posterior border of the corpus callosum. The anterior pair are called the *Nates*, the posterior, the *Testes*, and they are connected with the optic thalami and optic tracts by 4 bands, their *Brachia*; and with the cerebellum by a white cord on each side, the *Processus e Cerebello ad Testes*. They form two ganglia for the centre of vision.

*Pineal Gland*, is a small conical reddish body situated between the *nates*, on which it rests. Its 4 peduncles connect it with the anterior crura of the fornix, and the optic thalami. It is very vascular, and has a small cavity (said to communicate with the 3d ventricle) which contains a viscid fluid, and some concretions formed of the phosphates of lime, magnesia, and ammonia, etc., called the *Acervulus Cerebri*.

**Describe the Medulla Oblongata.** This ganglion is the upper enlarged part of the spinal cord, extending from the upper border of the atlas to the pons Varolii. Its posterior surface forms the floor of the 4th ventricle, its anterior surface rests on the basilar groove of the occipital bone. It is divided into two lateral halves by the *Anterior and Posterior Median Fissures*, and contains gray matter scattered throughout it, from which the cranial nerves from the 5th to the 12th inclusive arise entirely or in part. In it are supposed to lie the centres for the vaso-motor and the cardiac nerves, also centres of respiration, phonation, deglutition, mastication, and expression. On each side it presents the following,—

*Anterior Pyramid*, formed by the anterior and lateral columns of the spinal cord.

*Olivary Body*, behind the pyramid, from which it is separated by the groove of the hypoglossal nerve. It contains a capsule of gray matter in its centre, the *Corpus Dentatum*.

*Lateral Tract*, continuous with the lateral column of the spinal cord, lies behind the olivary body and in front of the restiform.

*Restiform Body*, the posterior lateral portion of the medulla, also called the *Fasciculus Cuneatus*.

*Posterior Pyramid, or Fasciculus Gracilis*, the most posterior portion, is formed by the posterior median column of the spinal cord. It diverges from its fellow at the apex of the 4th ventricle and forms the lateral boundary of the *Calamus Scriptorius*.

**What is the Cerebellum?** It is that portion of the brain situated in the inferior occipital fossæ, beneath the posterior lobes of the cerebrum. It is an oblong flattened ganglion, divided into two lateral hemispheres, and a central portion, the *Vermiform Process*.

**Name the Fissures of the Cerebellum.** They are 3 in number,—2 vertical and 1 horizontal, viz.—

*Incisura Cerebelli Anterior.*

*Great Horizontal Fissure*, from which secondary fissures originate.

*Incisura Cerebelli Posterior.*

**Name the Points on the surfaces of the Cerebellum.** They comprise 15 lobes, 2 commissures, and 3 projections, as follows:—

On the upper surface of each hemisphere,—

*Anterior or Square Lobe.*

*Posterior or Semilunar Lobe.*

On the under surface of each hemisphere, from before backwards,—

*Flocculus, Sub-peduncular Lobe, or Pneumogastric Lobule.*

*Amygdala Lobe, or Tonsil*, projects into the 4th ventricle.

*Digastric Lobe.*

*Slender Lobe.*

*Posterior Inferior Lobe.*

On the vermiform process are the—

*Lobulus Centralis.*

*Monticulus Cerebelli.*

*Commissura Simplex.*

} superiorly.

*Pyramid.*

*Uvula.*

*Commissura Brevis.*

} inferiorly.

*The Vallecula*, or valley of the cerebellum, is the central depression on its under surface between the two lateral hemispheres.

**Name the Peduncles of the Cerebellum,** They are 3 in number on each side, and from below upwards are as follows:—

*Processus e Cerebello ad Medullam*, to the medulla oblongata.

*Processus e Cerebello ad Pontem*, connect the hemispheres.

*Processus e Cerebello ad Testes*, to the cerebrum.

**Describe the Gray Matter of the Cerebellum.** It occupies the surface of

the mass in laminated shape, and is traversed by curved furrows, between the laminae. A vertical section gives an appearance called the *Arbor Vitæ*.

*Corpus Dentatum*, is a capsule of gray matter in the centre of the white and is open anteriorly. It is sometimes called the ganglion of the cerebellum.

### THE SPINAL CORD.

**Describe the Spinal Cord.** It is that part of the cerebro-spinal axis which is situated in the spinal canal. Its length is about 16 inches, terminating at the lower border of the 1st lumbar vertebra in the *Cauda Equina*. It is cylindrical in general form, with 2 enlargements, one in the cervical region, the other in the lumbar. It is composed of gray and white matter, the gray being inside (instead of outside, as in the cerebrum), and arranged so as to present a crescentic appearance in horizontal section, joined by a transverse commissure, and forming, by their extremities, the *Anterior and Posterior Horns*, from which regions respectively the anterior and posterior roots of the spinal nerves have their apparent origin.

*Membranes* of the cord are 3, as in the brain,—dura mater, arachnoid, and pia mater. The *Dura Mater* is not adherent to the spinal column, but is connected thereto by fibrous tissue. The *Arachnoid* is arranged as on the brain, its sub-arachnoid space being filled with its fluid, for the protection of the cord. The *Pia Mater* has a fibrous band on each side, the ligamentum denticulatum, connecting it to the dura mater by some 20 serrations.

*Fissures*, number 8,—the anterior and posterior median, the anterior and posterior lateral on each side, and the two posterior intermediary in the cervical region.

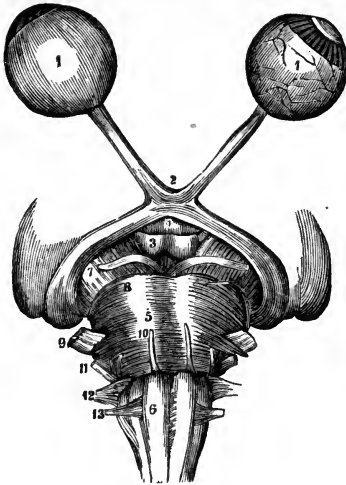
*Columns*, are 8 in number, 4 on each side of the cord,—an anterior, lateral, posterior, and posterior median. The *Anterior* is continuous with the anterior pyramid of the medulla; the *Lateral*, with the lateral column of the medulla; the *Posterior*, with the restiform body; the *Posterior-median*, with the posterior pyramid.

*Central Canal*, or *Ventricle of the Cord*, extends through its entire length in the fœtus and in some adults, but is usually closed except for one-half inch below its orifice in the floor of the 4th ventricle.

### THE CRANIAL NERVES.

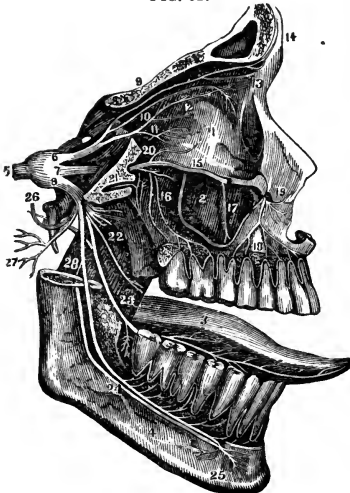
**Describe each Cranial Nerve**, stating its function, apparent and deep origin, foramen of exit, principal branches and distribution. There are 12 pairs of cranial nerves (9 according to Willis), of which those from the 6th to the 12th inclusive have their deep origin wholly or in part from the floor of the 4th ventricle. They are the—

FIG. 61.



—arises from the crus cerebri, *deeply* from the floor of the iter e tertio ad quartam ventriculum; *exit* through the sphenoidal fissure, *to* all the muscles of the orbit except the superior oblique and the external rectus, also to the iris.

FIG. 62.



**1st, Olfactory, nerve of smell,**—*arises* by 2 roots from the anterior cerebral lobe and 1 root from the middle lobe, *deeply* from the optic thalamus, island of Reil, corpus striatum, and anterior commissure; *exit* by 20 branches through the cribriform plate, *to* the Schneiderian membrane. Its bulb is a lobe of the cerebrum.

**2d, Optic, nerve of sight,**—*arises* from the optic commissure<sup>2</sup> and tracts, *deeply* from the optic thalamus, corpora geniculata, and corpora quadrigemina; *exit* through the optic foramen *to* the retina.

[This nerve and the Optic Tract are more fully described at the end of the volume, under the sub-title, **VESSELS AND NERVES OF THE EYE.**]

**3d, Motor Oculi,**<sup>7</sup> motor of the eye, —*arises* from the outer side of the crus, *deeply* from the valve of Vieussens; *exit* through the sphenoidal fissure, *to* the superior oblique muscle of the eye.

**4th, Patheticus,**<sup>8</sup> motor of the eye, —*arises* from the outer side of the crus, *deeply* from the valve of Vieussens; *exit* through the sphenoidal fissure, *to* the superior oblique muscle of the eye.

**5th, Trigeminus,**<sup>9</sup> nerve of sensation, motion, and taste,—*arises* by two roots,—from the side of the pons Varolii,<sup>5</sup> *deeply* from the pyramidal body (motor root), lateral tract of the medulla, the pons, and cerebellum (sensory root). *Exit* of ophthalmic division by the sphenoidal fissure; of superior maxillary by the foramen rotundum; of inferior max





**9th, Glosso-pharyngeal,**<sup>12</sup> nerve of sensation and taste,—*arises* from the medulla oblongata behind the olivary body, *deeply* from the floor of the 4th ventricle; *exit* by the jugular foramen, *to* the back of the tongue (taste), the middle ear, the tonsils, and pharynx. Branches are—

<i>Tympanic</i> (Jacobson's).	<i>Pharyngeal.</i>	<i>Tonsillar.</i>
<i>Carotid.</i>	<i>Muscular.</i>	<i>Lingual.</i>

**10th, Pneumogastric, or Par Vagus,**<sup>12</sup> the auriculo-laryngo-pharyngo-oesophago-tracheo-pulmono-cardio-gastro-hepatic nerve. A nerve of sensation and motion, probably receiving its motor influence from its *spinal* accessory. It *arises* from the medulla behind the olivary body and below the 9th nerve, *deeply* from the floor of the 4th ventricle; *exit* by the jugular foramen, *to* the parts indicated by the above euphonious appellation, supplying *sensation* to the external ear and larynx, *motion* to the other parts. Its branches are the—

<i>Auricular</i> (Arnold's).	<i>Recurrent Laryngeal.</i>	<i>Œsophageal.</i>
<i>Pharyngeal.</i>	<i>Cervical and Thoracic Cardiac.</i>	<i>Gastric.</i>
<i>Superior Laryngeal.</i>	<i>Ant. and Post. Pulmonary.</i>	<i>Hepatic.</i>

**11th, Spinal Accessory**<sup>12</sup> (to the pneumogastric),—motor nerve,—*arises* by a double origin (1) from the lateral tract of the medulla, *deeply* from near the floor of the 4th ventricle; (2) from the lateral tract of the cord by several filaments, as low as the 6th cervical nerve, *deeply* from the anterior gray horn of the cord. *Exit* by jugular foramen, its spinal portion having first entered by the foramen magnum, *to* the sterno-cleido-mastoid and trapezius muscles, *communicating* with the pharyngeal and laryngeal nerves by its accessory portion in the same sheath with the pneumogastric; also with the 2d, 3d, 4th, and 5th cervical nerves by its spinal portion. Its branches are indicated by the above-described distribution.

**12th, Hypo-glossal,**<sup>13</sup> (Nonus or 9th of Willis), motor of the tongue,—*arises* by 10 to 15 filaments from the groove between the pyramidal and olivary bodies of the medulla oblongata, *deeply* from the floor of the 4th ventricle; *exit* by the anterior condyloid foramen, *to* the thyro- and genio-hyoid, the stylo-hyo-, and genio-hyo-glossus muscles; and by the *descendens noni* branch to the sterno-hyoid, sterno-thyroid, and omo-hyoid muscles. It *communicates* with the pneumogastric, sympathetic, 1st and 2d cervical, and gustatory nerves. Its branches of distribution are the—

<i>Descendens Noni.</i>	<i>Muscular.</i>	<i>Thyro-hyoid.</i>
-------------------------	------------------	---------------------

**What Nerves enter the Cranium before passing out of it?** The spinal portion of the Spinal Accessory, and the Nasal branch of the Ophthalmic. The first enters by the foramen magnum, and then leaves by the jugular foramen. The second enters from the orbit by the anterior ethmoidal foramen, and leaves by the nasal slit at the side of the crista galli.

## THE SPINAL NERVES.

**Describe the Spinal Nerves.** There are 31 pairs of spinal nerves, of which the cervical number 8, the dorsal 12, the lumbar 5, the sacral 5, and the coccygeal 1. The 1st cervical escapes above the 1st vertebra, each of the others below the corresponding vertebra through the intervertebral foramina. Each nerve arises by 2 roots, an anterior motor root, and a posterior sensory one, the latter having a ganglion on it. These unite, and the nerve then divides into 2 branches, both having motor and sensory fibres. The posterior branches are small and generally unimportant; they supply the muscles and integument of the back. The anterior branches supply the neck, front, and sides of the trunk, and the extremities, uniting in various regions to form plexuses from which important nerve-trunks originate.

**How is the Cervical Plexus formed and distributed?** It is formed by the anterior branches of the first 4 cervical nerves, and rests on the levator anguli scapulæ and scalenus medius muscles. Its branches (10) comprise 4 superficial to the integument of the head and neck, and the following deep branches, viz.—

*Phrenic. Communicans Noni. 2 Muscular. 2 Communicating.*

**Describe the Phrenic Nerve.** It arises by 3 heads from the 3d, 4th, and 5th cervical, descends across the front of the scalenus anticus, crossing the subclavian and internal mammary arteries in the middle mediastinum, and is distributed to the inferior surface of the diaphragm. It is often called the Internal Respiratory Nerve of Bell. It sends filaments to the pericardium and pleura, and communicates with the plexuses of the sympathetic in the abdomen.

**Describe the formation and distribution of the Brachial Plexus.** It is formed by the union of the 4 lower cervical nerves and the 1st dorsal. The 5th, 6th, and 7th unite into one trunk externally to the scalenus medius, as also do the 8th cervical and 1st dorsal behind the same muscle. Below the line of the clavicle both these trunks bifurcate; the two adjacent branches unite behind the axillary artery making the *Posterior Cord*, and the remaining 2 form the *Outer* and *Inner Cords*, referred to the artery. Each of these cords bifurcates, but the 2 adjacent branches of the outer and inner cords unite over the artery, to form the *Median Nerve*, leaving 4 other branches, the *Ulnar, Musculo-cutaneous, Musculo-spinal, and Circumflex Nerves*, the last 2 being derived from the posterior cord.

THE BRANCHES of the brachial plexus are as follows, viz.—

Above the clavicle are given off 4, the—

*Communicating*, completing the phrenic nerve.

*Muscular*, to the longus colli, scaleni, rhomboidei, and subclavius muscles

*Posterior, or Long Thoracic*, external respiratory nerve of Bell, to the serratus magnus, arising from the 5th and 6th cervical.

*Suprascapular*, from the 1st trunk of the plexus, to the scapular muscles.

Below the clavicle are 12, the,—

2 *Anterior Thoracic*, from outer and inner cords to the pectoral muscles.

3 *Subscapular*, from the posterior cord, to the subscapularis, teres major, and latissimus dorsi muscles.

*Circumflex*, from the posterior cord, to the muscles and integument of the shoulder, and the shoulder-joint.

*Musculo-cutaneous*, from the outer cord, to the forearm externally, piercing the coraco-brachialis muscle.

*Internal Cutaneous*, from the inner cord, to the arm and forearm.

*Lesser Internal Cutaneous* (nerve of Wrisberg), from the inner cord to the inner side of the arm. Is sometimes wanting, sometimes connected with the intercosto-humeral.

*Median*, from outer and inner cords, passes between the two heads of the pronator radii teres, supplying the pronators, flexors, first 2 lumbricales, and the integument of the thumb, 2½ fingers, and the radial side of the palm. Its branches are all in the palm, the—

Muscular.            Anterior Interosseus.            Palmar Cutaneous.

*Ulnar*, from the inner cord, passes between the two heads of the flexor carpi ulnaris at the inner condyle of the humerus, supplying the elbow- and wrist-joints, several muscles, and the palmar and dorsal integument of the little finger and half of the ring finger. Branches are the—

2 Articular.            Cutaneous.            Superficial Palmar.

Muscular.            Dorsal.            Deep Palmar.

*Musculo-spiral*, from the posterior cord, accompanies the superior profunda artery and vein in the spiral groove of the humerus, and at the external condyle it divides into the radial and posterior interosseus nerves. Its branches are—

Muscular.            Cutaneous.            Radial.            Posterior Interosseous.

*The Radial* supplies the outer side and ball of the thumb, and the dorsal integument of 2½ fingers.

*The Posterior Interosseus* supplies all the muscles on the back of the forearm except 3, and also sends a filament to the wrist-joint.

**What is the Intercosto-humeral Nerve?** It is the lateral cutaneous branch of the 2d intercostal (anterior branch of the 2d dorsal); it pierces the external intercostal muscle and crosses the axilla, joining with a filament from the lesser internal cutaneous (nerve of Wrisberg), and supplying the skin of the upper half of the inside of the arm.

**Describe the Lumbar Plexus.** It is formed by communicating loops from the anterior branches of the first 4 lumbar nerves, in the following manner.

From the **FIRST** lumbar nerve are given off the—

*Ilio-hypogastric*, to the abdominal and gluteal regions.

*Ilio-inguinal*, to the inguinal region, and the scrotum.

*Communicating Loop*, to the second lumbar nerve.

From the **SECOND** lumbar nerve are given off the—

*External Cutaneous*, to the integument of the outside of the thigh.

*Genito-crural*, to the spermatic cord and front of the thigh.

*Communicating Branch*, to the third lumbar nerve.

From the **THIRD** and **FOURTH** lumbar nerves are given off the following by a branch of origin from each, viz.—

*Obturator*, through the obturator foramen to the external obturator and adductor muscles and the hip and knee-joints.

*Accessory Obturator* (often absent), to the pectineus and hip-joint.

*Communicating*, from the 3d lumbar to the 4th.

*Communicating*, from the 4th lumbar to the 5th.

*Anterior Crural*, which descends through the psoas muscle, and beneath Poupart's ligament to the thigh, where it divides into an anterior and posterior division. Its branches are,—

To the Iliacus muscle.            Long Saphenous.

To the Femoral artery.            Muscular.

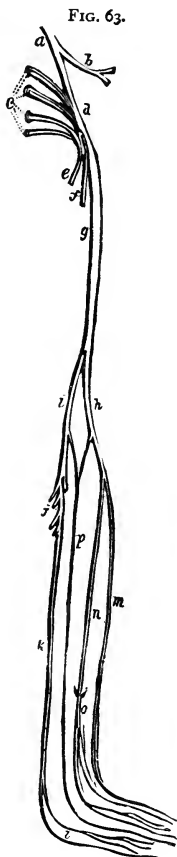
Middle and Internal Cutaneous.    Articular.

**Describe the Sacral Plexus.** It is formed by the union of the upper 4 sacral nerves with the 5th lumbar and a loop from the 4th, the two latter forming the *Lumbo-sacral Cord*. It lies upon the pyriformis muscle and gives off the following 5 branches, viz.—

*Superior Gluteal*, from the lumbo-sacral cord, supplies the glutei and tensor vaginae femoris.

*Muscular Branches*, to the pyriformis, obturator internus, gemelli, and quadratus femoris muscles.

*Pudic*, escapes by the great sacro-sciatic foramen, crosses the ischiatic



spine, and re-enters the pelvis by the lesser sacro-sciatic foramen, supplying the perineum, anus, and genitalia.

*Small Sciatic, f* to the gluteus maximus, and integument of the perineum, scrotum, and back of the thigh and leg.

*Great Sciatic, g* the largest nerve of the body, and the direct continuation of the sacral plexus, escapes by the great sacro-sciatic foramen, sends an *Articular Branch* to the hip-joint, *Muscular* branches to the adductor magnus, semimembranosus, semitendinosus, and biceps muscles, and terminates in the *External<sup>h</sup>* and *Internal<sup>i</sup> Popliteal* nerves, generally about the lower one-third of the thigh.

**Describe the External Popliteal Nerve.** It passes from the bifurcation of the great sciatic along the outer side of the popliteal space, gives off *Articular* and *Cutaneous* branches, and about an inch below the head of the fibula it divides into the—

*Anterior Tibial,<sup>m</sup>* supplying the extensors, and the integument of the adjacent sides of the great and 2d toes.

*Musculo-cutaneous,<sup>n</sup>* by 2 branches (internal and external) to the peroneal muscles, the integument of the ankles, and the dorsal integument and sides of all the toes, except the outer side of the little toe and the adjoining sides of the great and 2d toes.

**Describe the Internal Popliteal Nerve.** It is the largest of the two, and descends along the middle of the back of the leg, becoming the *Posterior Tibial<sup>k</sup>* at the lower border of the popliteus muscle, and dividing into the *External* and *Internal Plantar<sup>l</sup>* below the inner malleolus. Its branches are as follows:—

*Articular,* 3 in number, to the knee-joint.

*Muscular,* to the gastrocnemius, soleus, plantaris, and popliteus.

*External or Short Saphenous,<sup>p</sup>* formed by a filament from both popliteal nerves, supplies the integument of the little toe and outer side of the foot.

*Muscular,* to the tibialis posticus, flexor longus pollicis, and flexor longus digitorum.

*Plantar Cutaneous,* to the skin of the heel and inner sole of the foot.

*Internal Plantar,* to the inner plantar muscles, sole of the foot, and the plantar integument of the inner  $3\frac{1}{2}$  toes.

*External Plantar,* to the external plantar muscles, and the plantar integument of the outer  $1\frac{1}{2}$  toes.

## THE SYMPATHETIC NERVE.

**What is the Sympathetic Nerve?** It consists of a series of ganglia situated on each side of the vertebral column, connected together and to the cerebro-

spinal system by intervening cords, beginning in the *ganglion of Ribes* on the anterior communicating artery, and ending in the *ganglion impar*, in front of the coccyx.

**Name the Ganglia of the Sympathetic in the Cranium and its vicinity.** They are 9 in number, as follows:—

*Ganglion of Ribes*, on the anterior communicating artery.

*Ganglion of Laumonier*, on the internal carotid artery.

*Ciliary, or Ophthalmic Ganglion*, in the orbital cavity.

*Spheno-palatine (Meckel's) Ganglion*, in the spheno-maxillary fossa.

*Otic (Arnold's) Ganglion*, under the foramen ovale.

*Submaxillary Ganglion*, above the submaxillary gland.

*Ganglion of Cloquet*, in the incisive fossa, on the naso-palatine nerve.

*Ganglion of Bidder*, below the foramen spinosum, on the middle meningeal artery.

*Ganglion of Bochdalek*, on a branch between the spheno-palatine ganglion and the anterior dental nerve at their junction.

**Describe the Ganglia connected with the 5th Cranial Nerve.** There are 4 such, each having a motor, a sensory, and a sympathetic root, viz.—

*Ciliary, or Ophthalmic Ganglion*, is situated in the orbit, between the optic nerve and the external rectus muscle. Its sensory root is derived from the nasal branch of the ophthalmic, its motor root from the 3d nerve, its sympathetic root from the cavernous plexus. Its branches are the short ciliary nerves, and are distributed to the ciliary muscle and the iris.

*Spheno-palatine, or Meckel's Ganglion*, is a large ganglion situated in the spheno-maxillary fossa. Its sensory root is derived from the superior maxillary, its motor root from the facial by the Vidian and large petrosal, its sympathetic root from the carotid plexus, by the carotid branch of the Vidian. Its branches are the—

Ascending. Middle Palatine.

Anterior Palatine. Superior Nasal. Pharyngeal, or

Posterior Palatine. Naso-palatine. Pterygo-palatine.

*Otic Ganglion (Arnold's)*, is situated on the inferior maxillary nerve, immediately below the foramen ovale. Its sensory root is derived from the auriculo-temporal branch of the inferior maxillary; its motor root from the internal pterygoid branch of the same, also from the facial and glosso-pharyngeal by the small petrosal; its sympathetic root from the middle meningeal plexus. Its branches are distributed to the tensor palati and tensor tympani muscles.

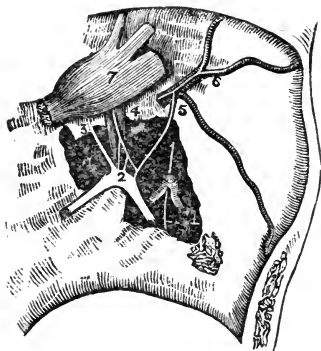
*Submaxillary Ganglion*, is situated above the submaxillary gland. Its sensory root is derived from the gustatory branch of the inferior maxillary,

its motor root from the facial by the chorda tympani, its sympathetic root from the facial plexus. Its branches are distributed to the submaxillary gland, its duct, and the mucous membrane of the mouth.

**What Nerves appear on removing the Gasserian Ganglion?** The three Petrosal branches of the 7th nerve (see page 131), lying on the petrous portion of the temporal bone, and communicating with the sympathetic system as follows, viz., the—

*Large Superficial Petrosal*,<sup>3</sup> (Great Petrosal),—a branch of the 7th nerve, from its geniculate ganglion,<sup>2</sup> (intumescentia gangliformis), which passes through the hiatus Fallopii, and thence through the foramen lacerum medium to the Vidian canal, where it joins the large deep petrosal from the carotid plexus, to form the Vidian nerve, as which it goes to Meckel's ganglion (page 137), forming its motor root.

FIG. 64.



*Small Superficial Petrosal*,<sup>4</sup> (Small Petrosal), immediately external to the preceding, going from the geniculate ganglion of the 7th to the otic ganglion, and lying directly over the tensor tympani muscle.

*External Superficial Petrosal*,<sup>5</sup> (External Petrosal),—going from the 7th to the sympathetic plexus on the middle meningeal artery.<sup>6</sup>

**Describe the Cervical Ganglia.** They are 3 in number on each side, of which the superior is the largest, communicate with each other, and are as follows, viz.—

*Superior Cervical Ganglion*, lies behind the carotid sheath opposite the 2d and 3d cervical vertebræ. Its branches are distributed to the carotid, cavernous, and pharyngeal plexuses, and one of its internal branches is the superior cardiac nerve going to the cardiac plexus.

*Middle Cervical Ganglion*, on the superior thyroid artery, opposite the 5th cervical vertebra, and gives off the middle cardiac nerve to the cardiac plexus, also communicating branches.

*Inferior Cervical Ganglion*, on the superior intercostal artery, between the neck of the 1st rib and the transverse process of the 7th cervical vertebra. It gives off several communicating branches and the inferior cardiac nerve to the cardiac plexus.



**What are the other Ganglia of the Sympathetic?** There are on each side of the vertebral column 11 or 12 dorsal ganglia, 4 or 5 lumbar, 5 sacral, besides the single coccygeal *Ganglion Impar* in which terminates the double chain. Connected with the viscera are many ganglia, from which branches ramify around the arteries in plexuses named from their locations.

**Describe the Splanchnic Nerves.** They are 3 in number on each side, and are derived from branches of the 6 lower thoracic ganglia, as follows, viz.—

*Great Splanchnic*, from branches of the 6th to the 10th, connecting with the upper six, passes through the posterior mediastinum, perforates the crus of the diaphragm, to the semilunar ganglion.

*Lesser Splanchnic*, from the 10th and 11th, passes through the diaphragm with the great splanchnic, to the cœliac plexus.

*Smaller or Renal Splanchnic*, from the last thoracic ganglion, also perforates the diaphragm, and ends in the renal and cœliac plexuses.

**Describe the Solar Plexus.** This plexus, called also the “abdominal brain,” is a network of nerves and ganglia, chiefly formed by the splanchnic nerves and the right pneumogastric. It lies behind the stomach, and in front of the aorta and the crura of the diaphragm, surrounding the cœliac axis and the root of the superior mesenteric artery. Its two largest ganglia are the *Semilunar Ganglia* situated in front of the crura of the diaphragm. From it are derived branches which form *Plexuses* over most of the abdominal arteries, as follows:—

<i>Phrenic.</i>	<i>Gastric.</i>	<i>Splenic.</i>	<i>Renal.</i>	<i>Superior Mesenteric.</i>
<i>Cœliac.</i>	<i>Hepatic.</i>	<i>Suprarenal.</i>	<i>Spermatic.</i>	<i>Inferior Mesenteric.</i>

**Describe the Carotid and Cavernous Plexuses.** They are two plexuses of the sympathetic, situated on the internal carotid artery, the Carotid lying on the outer side of the artery, as it lies by the side of the body of the sphenoid bone; and the Cavernous being on the inner side of the artery, below its last bend, in the upper portion of the cavernous sinus. The—

*Carotid Plexus*,—is connected by numerous filaments with the 6th nerve and the Gasserian ganglion, and furnishes the *Large Deep Petrosal* to unite with the large superficial petrosal of the facial, to form the Vidian nerve; also the *Small Deep Petrosal*, to join the tympanic plexus probably.

*Cavernous Plexus*,—communicates with the 3d and 4th nerves and the ophthalmic division of the 5th, and gives a branch to the Ciliary ganglion in the orbit.

**Mention some other Plexuses of the Sympathetic system.** They are very numerous; besides those already mentioned, the most important are the following:—

*Tympanic Plexus*,—described under Nerves of the Tympanum.

*Meningeal Plexus*, on the middle meningeal artery.

*Facial Plexus*, surrounding the facial artery.

*Cardiac Plexuses*, the deep in front of the bifurcation of the trachea, the superficial in front of the right pulmonary artery; the first named lies behind the arch of the aorta, the latter beneath it.

*Coronary Plexuses*, anterior and posterior, accompanying respectively the left and right coronary arteries.

*Aortic Plexus*, on the sides and front of the aorta between the superior and inferior mesenteric arteries.

*Hypogastric Plexus*, on and between the common iliac arteries; supplying the viscera of the pelvic cavity.

*Inferior Hypogastric or Pelvic Plexuses*, two in number, one on each side of the rectum and bladder. Their branches are the—

Inferior Hemorrhoidal Plexus.	Small Cavernous Nerve.
Vesical and Prostatic Plexuses.	Large Cavernous Nerve.
Vaginal Plexus.	Uterine Nerve.

**What is the Vidian Nerve?** It has generally been described as a branch of the sphenopalatine (Meckel's) ganglion (see p. 137), running backwards through the Vidian canal, and dividing into a *Petrosal Branch* to the Facial nerve, and a *Carotid Branch* to the carotid plexus of the Sympathetic. It is now, however, more correctly described as a short nerve of communication, between the Facial and the Sympathetic on the one hand, and the Sphenopalatine Ganglion on the other, supplying that ganglion with its motor and vaso-motor roots. It is formed by the junction of the—

*Large Superficial Petrosal*, Br. of the Facial (p. 138), with the—

*Large Deep Petrosal*, Br. of the Carotid Plexus (p. 140), which occurs in the cartilage filling in the foramen lacerum medium (p. 35). It then enters the Vidian Canal (p. 20), in the pterygoid process of the sphenoid bone, passing through which to finally join the posterior part of the sphenopalatine ganglion (p. 137). Some filaments, the—

*Upper Posterior Nasal Branches*,—are apparently given off from the Vidian in the canal, to the septum and roof of the nose; but they are really branches from the ganglion; bound up in the same sheath with the Vidian nerve.

# VISCERAL ANATOMY.

---

**What is a Viscus?** Viscus, *gen. visceris, pl. viscera*, is a term which is applied to any internal organ of the body. *The Viscera* are the organs contained in the three great cavities—cranium, thorax and abdomen—with their appendages. Of these the Heart and Brain have been described, with the circulatory and nervous systems respectively. [See pp. 99, 120; also the COMPEND OF PHYSIOLOGY in this series.]

## THE DIGESTIVE ORGANS.

**What is the Alimentary Canal?** A musculo-membranous tube, from 25 to 30 feet in length, extending from the mouth to the anus, lined throughout with mucous membrane, furnished with several accessory organs, and performing the functions of ingestion, digestion, and egestion.

**Name its Subdivisions.** They are the Mouth, Pharynx, Œsophagus, Stomach, Small Intestine (duodenum, jejunum and ileum) and Large Intestine (cæcum, colon and rectum). The first three lie above the diaphragm, the rest below it.

**Name the Accessory Organs of Digestion.** They are—the Teeth, Salivary glands (parotid, sub-maxillary, sub-lingual), Liver, Pancreas and Spleen.

## THE TEETH.

**What are the Teeth?** They are 32 organs of digestion (20 being temporary, or milk-teeth), situated one-half in each jaw, imbedded in the alveolar processes, and partly surrounded by the *Gums*, which are composed of fibrous tissue and covered with mucous membrane. In each half of each jaw there are—

*Temporary Teeth* (5)—2 Incisors, 1 Canine, 2 Milk-molars.

*Permanent Teeth* (8)—2 Incisors, 1 Canine, 2 Bicuspids, 3 Molars.

**What are their General Characteristics?** Each tooth presents a—  
*Crown, or Body*,—the part seen projecting above the gum.  
*Neck*,—the constricted portion between the crown and the fang.  
*Fang, or Root*,—imbedded in the alveolus; and surrounded by the periodontal membrane or periosteum lining the alveolus.

*Pulp-cavity*,—in the interior, opening at the apex of the fang for the entrance of vessels and nerves.

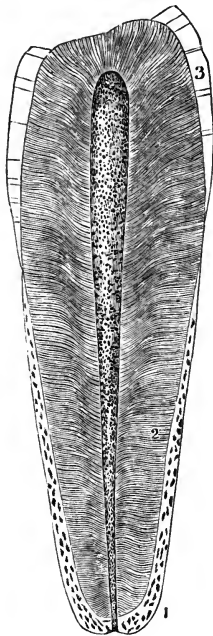
**State the Characteristics of each class of Teeth.**

*Incisors, or Cutters*.—Crown chisel-shaped, beveled posteriorly. Fang single, long, thickest antero-posteriorly.

*Canines, or Tearers*.—Crown thick and conical. Fang longest and thickest of all the teeth, forming a projection on the alveolar arch. The 2 upper canines are the “eye-teeth.”

*Bicuspid*s,—Crown has 2 cusps. Fang single but grooved deeply, showing a marked tendency to bifurcate.

FIG. 65.



*Molars, or Grinders*.—Crown large, low and cuboid in shape, has 4 cusps on upper molars, 5 on the lower ones. Fangs multiple, usually 3 on the first two upper molars, 2 on the first two lower ones; the third molar of either jaw, having but one fang, is called the “wisdom tooth,” and is the smallest of the three.

*The 2d or 3d Temporary Molar* is larger than the first.

**Describe the Structure of a Tooth.** Each consists of—

*Dentine or Ivory*,<sup>2</sup>—composed of tubules surrounded by the inter-tubular tissue or Matrix, and opening into the pulp cavity. It resembles compact bone in appearance and in composition, consisting of 28 parts Animal matter and 72 Earthy matter. The *Tubules* are delicate wavy canals, diameter about  $\frac{1}{4500}$  of an inch, which branch outwardly and anastomose with each other, forming concentric shadings or *Schreyer's Lines*.

*Enamel*,<sup>3</sup>—covers the crown; consists of very dense tissue, which contains but  $3\frac{1}{2}$  per cent. of animal matter. It is covered by a very delicate epithelial cuticle, *Nasmyth's Membrane*, which when intact withstands the action of acids.

*Crusta Petrosa or Cement*,<sup>1</sup>—the enamel of the fang; is a layer of true bony tissue, containing lacunæ, canaliculi, and Haversian canals.

*Pulp*,—fills the pulp-cavity and is prolonged into the dental tubules; is soft, vascular, and sensitive; and consists of connective and fibrous tissue,

nucleated cells, blood-vessels and nerves. The cells are caudate and anastomose with each other, those situated superficially being termed *Odontoblasts*.

**What Arteries and Nerves supply the Teeth?** *The Arteries* are derived from the inferior dental, and from the alveolar and infraorbital branches of the internal maxillary. *The Nerves* are derived from the inferior dental branch of the inferior maxillary division of the 5th, and also from the anterior and posterior dental branches of the superior maxillary division of the same nerve.

**When do the Temporary Teeth appear?** Their eruption begins about the 7th month after birth, with the central incisors, and ends with the appearance of the second molars, about the age of two years. The lower teeth slightly antedate the upper. Their formula is as follows:—

	Mo.	Mo.	Ca.	In.	In.	In.	In.	Ca.	Mo.	Mo.	
{	Upper...	$\frac{1}{1}$	$\frac{1}{1}$	$\frac{1}{1}$	$\frac{1}{1}$	$\frac{1}{1}$	$\frac{1}{1}$	$\frac{1}{1}$	$\frac{1}{1}$	$\frac{1}{1}$	= 10
	Lower...	$\frac{1}{1}$	$\frac{1}{1}$	$\frac{1}{1}$	$\frac{1}{1}$	$\frac{1}{1}$	$\frac{1}{1}$	$\frac{1}{1}$	$\frac{1}{1}$	$\frac{1}{1}$	= 10
	24	12	18	9	7	7	9	18	12	24	months.

**When do the Permanent Teeth appear?** The first molars appear about the end of the 6th year, followed by the incisors about the 7th or 8th year, the bicuspidis from the 9th to the 10th year, the canines about the 11th or 12th year, the second molars from the 12th to the 13th year, and the third molars from the 17th to the 25th year. Those of the lower jaw are slightly in advance of the corresponding upper ones. Their formula is as follows:—

	Wis.	Mo.	Mo.	Bi.	Bi.	Ca.	In.	In.	In.	In.	Ca.	Bi.	Bi.	Mo.	Mo.	Wis.	
{	Upper.	$\frac{1}{1}$	$\frac{1}{1}$	$\frac{1}{1}$	$\frac{1}{1}$	$\frac{1}{1}$	$\frac{1}{1}$	$\frac{1}{1}$	$\frac{1}{1}$	$\frac{1}{1}$	$\frac{1}{1}$	$\frac{1}{1}$	$\frac{1}{1}$	$\frac{1}{1}$	$\frac{1}{1}$	$\frac{1}{1}$	= 16
	Lower.	$\frac{1}{1}$	$\frac{1}{1}$	$\frac{1}{1}$	$\frac{1}{1}$	$\frac{1}{1}$	$\frac{1}{1}$	$\frac{1}{1}$	$\frac{1}{1}$	$\frac{1}{1}$	$\frac{1}{1}$	$\frac{1}{1}$	$\frac{1}{1}$	$\frac{1}{1}$	$\frac{1}{1}$	$\frac{1}{1}$	= 16
	18	12	6	10	9	11	8	7	7	8	11	9	10	6	12	18	years.

**What is the greatest Number of Teeth at one time in the jaws, and when?** Forty-eight, namely, all the temporary and permanent teeth except the third molars,—occurring between the 5th and 7th years of age.

**Describe the Development of the Teeth.** They arise from the mucous membrane covering the maxillary arches, in which, about the 6th foetal week, appears a depression, the *Primitive Dental Groove*, from the floor of which arise papillæ of mucous membrane to form the pulp of the milk-teeth.

In the *Follicular Stage*, membranous septa form across the groove, and its margins become thick and prominent.

*The Saccular Stage* extends from the 13th week to the 16th, and is marked first by the projection of the papillæ from the follicles, next by the growth of the follicular margins, the formation of processes or *Opercula* thereon, which meet and close in the papillæ; and finally by the closing in of the dental

groove by the union of its margins. A *Cavity of Reserve* for each tooth is then formed by the closure of the secondary dental groove, from the floor of which another papilla arises to form the germ of the permanent tooth.

The dental pulps now take the forms of teeth, a thin lamina of dentine appears and increases from without inward, the enamel organ and membrane are formed, and when calcification has advanced sufficiently, the pressure of the teeth causes the absorption of the gum above them, the septa ossify and the eruption of the teeth occurs. *The Cement* is formed from the periodontal membrane, at a later period of life.

### THE MOUTH.

**Describe the Mouth.** It is an oval cavity formed by the lips, cheeks, jaws, palate and tongue, forming the superior portion of the alimentary canal, and opening posteriorly into the pharynx by the fauces. It presents the teeth (already described), the tongue (to be described), and also the—

*Hard Palate*, formed by the palate processes of the superior maxillary and palate bones, and covered with mucous membrane; forms the roof of the mouth.

*Soft Palate*, formed by 5 muscles on each side, viz., the levator palati, tensor palati, palato-glossus, palato-pharyngeus, and the azygos uvulæ;—the latter forming with its fellow the *Uvula*, a descending muscular projection.

*Anterior Pillars of the Fauces*,—arch downwards and forwards to the base of the tongue, and contain the palato-glossi muscles.

*Posterior Pillars of the Fauces*,—arch downwards and backwards to the sides of the pharynx, and contain the palato-pharyngei muscles.

*Isthmus Faucium*,—the space bounded by the pillars, the free border of the palate, and the base of the tongue.

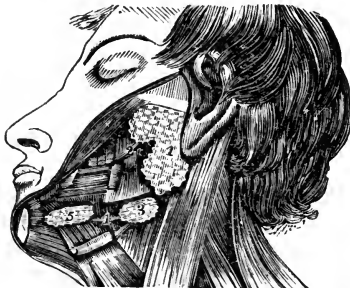*Tonsils*,—are small, elongated, glandular bodies, situate done on each side of the fauces, between the anterior and posterior pillars. Each has 12 or 15

openings on its surface leading to follicular depressions within the gland, and lies close to the internal carotid artery.

*Openings of Steno's Ducts*,—from the parotid glands, are situated internally one on each cheek, opposite the 2d upper molar tooth.

*Openings of Wharton's Ducts*,—from the sub-maxillary glands, one at each side of the frenum of the tongue.

FIG. 66.



*Openings of the Ducts of Rivinus*,—8 to 18 on each side from the sublingual glands, near the frenum of the tongue. The longest is the *Duct of Bartholine*, which opens into the duct of Wharton.

**Where are the Salivary Glands?** The *Parotid Gland*<sup>1</sup> lies below and in front of the external ear,—the *Sub-maxillary*<sup>3</sup> and *Sub-lingual*<sup>5</sup> Glands lie in the corresponding fossæ on the inner surface of the inferior maxillary bone. [See Fig. 66.]

**Describe the Tongue.** The tongue consists of extrinsic and intrinsic muscles, a hyo-glossal membrane and a mucous membrane, a median fibrous septum, vessels and nerves. Its *Base* is attached to the hyoid bone, the epiglottis, the soft palate and the pharynx. Its *Under Surface* is attached to the hyoid bone and the inferior maxillary. Its mucous membrane is reflected over the floor of the mouth to the inner surface of the gums, forming in front a fold, the *Frenum Linguae*.

The Tongue presents—

*Filiform Papillæ*, along its sides, closely packed in rows.

*Fungiform Papillæ*,<sup>2</sup> scattered over the anterior two-thirds of its dorsum.

*Circumvallate Papillæ*,<sup>1</sup> 7 to 12 in number, in two rows, forming a V at the base of the tongue, meeting at the *Foramen Cæcum*, which contains the central papilla.

*Follicular Glands*, posteriorly to the circumvallate papillæ.

*Racemose Glands*, over the dorsum, sides, and under surface. Beneath the tip they form two small oblong masses.

*Extrinsic Muscles*, are the stylo-, hyo-, genio-hyo-, and palato-glossus muscles. [See pp. 73, 74.]

*Intrinsic Muscles*, are the several fibres of the lingualis muscle,—superior, inferior, transverse and perpendicular.

**Name the Arteries of the Tongue.** They are the—

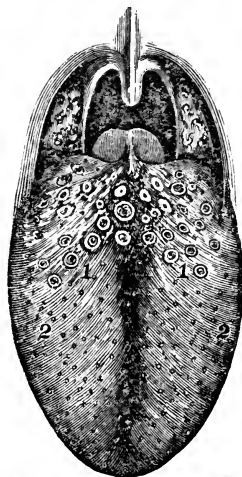
*Lingual*, branch of the external carotid,—with its branches, the—

Dorsalis linguæ. Sub-lingual. Ranine.

*Sub-mental*, branch of the facial,—anastomoses with the sub-lingual.

*Ascending Pharyngeal*, branch of the external carotid,—sends some small branches to the pharynx and tongue.

FIG. 67.



**What Nerves are distributed to the Tongue ? The—**

*Gustatory Branch of the 5th*,—to the mucous membrane of the sides and anterior two-thirds of the tongue, endowing it with general sensibility.

*Chorda Tympani Branch of the 7th*,—joins the gustatory, and is distributed to the same region, being the nerve of taste for the anterior two-thirds of the tongue.

*Lingual Branches of the 9th or Glosso-pharyngeal*,—to the mucous membrane of the base and sides of the tongue, being the nerve of taste for its posterior third.

*Hypoglossal, or 12th*,—to the intrinsic and extrinsic muscles of the tongue, being its nerve of motion.

*Superior Laryngeal Branch of the 10th or Pneumogastric*,—sends a few fibres to the base of the tongue from its internal branch.

**What special Anatomical Features are presented by the Mouth ?**

They are as follows, viz.—the—

*Hamular Process of the Sphenoid Bone*,—may be felt behind the last upper molar tooth ; also the *Internal Pterygoid Plate*, and part of the *Pterygoid Fossa*.

*Coronoid Process*,—of the lower jaw, its anterior border.

*Posterior Palatine Artery*,—at inner side of the last upper molar tooth, and in front of the hamular process.

*Gustatory Nerve*,—very near the last lower molar tooth.

*Pterygo-maxillary Ligament*,—felt as a fold posteriorly to the last lower molar tooth.

**THE PHARYNX.**

**Describe the Pharynx.** It is a conical, musculo-membranous bag, about  $4\frac{1}{2}$  inches long, hung base up from the basilar process of the occipital bone, and extending to the lower border of the cricoid cartilage posteriorly, or the 5th cervical vertebra, where it becomes continuous with the œsophagus.<sup>5</sup> It forms the part of the alimentary canal which lies behind the mouth, being incomplete in front.

**What are its Relations ?** It is connected with—

*Posteriorly*,—the longus colli and recti capitis antici muscles, and by loose areolar tissue to the first 5 cervical vertebræ.

*Laterally*,—the styloid processes and their muscles, the pterygoid muscles, the internal carotid arteries, the internal jugular vein, the 8th, 9th, and the sympathetic nerves.

*Near its Apex*,—the lobes of the thyroid gland, the common carotid and lingual arteries, the sterno-hyoid muscle, and the lingual nerves.



**What are its Anterior Attachments?**

The internal pterygoid plate, pterygo maxillary ligament, lower jaw, base of the tongue, cornua of the hyoid bone, stylo-hyoid ligament, thyroid and cricoid cartilages of the larynx.

**Name the Openings into the Pharynx.**

They are 7, viz.—

- |                     |        |            |
|---------------------|--------|------------|
| 2 Posterior Nares,  | Mouth. | Larynx.    |
| 2 Eustachian Tubes. |        | Œsophagus. |

**Describe its Structure.** The pharynx is composed of 3 coats,—a mucous, a muscular and a fibrous, the latter lying between the other two, and sometimes called the *Pharyngeal Aponeurosis*. The mucous coat is covered with ciliated columnar epithelium above the level of the floor of the nares—below that level by squamous epithelium; and contains simple follicular glands, also compound follicular and racemose glands, the latter being most numerous in the upper part, between the two Eustachian tubes.

**Name its Muscles, Arteries and Nerves.**

Its—

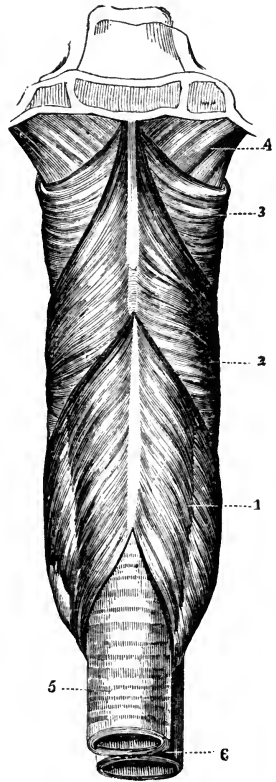
*Muscles*, 5,—are the Superior, Middle and Inferior Constrictors, Stylo-pharyngeus, and Palato-Pharyngeus. [See pages 73, 74.]

*Arteries* number 4, as follows,—

- |                            |                                       |               |
|----------------------------|---------------------------------------|---------------|
| Superior Thyroid Branches. | } Branches of                         | Ext. Carotid. |
| Ascending Pharyngeal.      |                                       |               |
| Pterygo-palatine.          | } Branches of the Internal Maxillary. |               |
| Descending Palatine.       |                                       |               |

*Nerves*,—Branches of the Pharyngeal Plexus, which is formed by the pharyngeal branches of the pneumogastric, glosso-pharyngeal, superior laryngeal, and superior cervical ganglion of the sympathetic.

FIG. 68.



**THE ŒSOPHAGUS.**

**Describe the Œsophagus.** It is a musculo-membranous tube, about 9 inches long, extending from the 5th cervical vertebra and the lower border of the cricoid cartilage of the larynx, through the œsophageal opening in the

diaphragm to the cardiac orifice of the stomach, opposite the 9th dorsal vertebra, where it terminates. It lies in the neck, between the trachea and the vertebral column, resting in part on the longus colli muscle; then inclining to the left side it reaches the posterior mediastinum behind the left bronchus.

**Describe its Structure.** The Œsophagus has three coats, a—*Mucous*,—in thick longitudinal folds, containing compound racemose glands, and covered with a thick layer of squamous epithelium.

*Cellular*,—forms a loose connection between the other two coats, and contains the œsophageal vessels.

*Muscular*,—having longitudinal fibres externally, circular fibres internally, which are continuous with the fibres of the stomach below, and with those of the inferior constrictor muscle above.

**Name its Vessels and Nerves.** The Œsophageal—*Arteries*, are chiefly branches from the thoracic aorta.

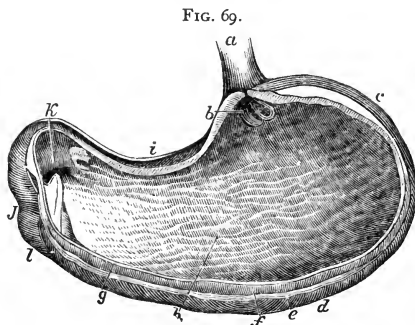
*Veins*, empty into the vena azygos minor.

*Nerves*, are branches of the pneumogastric and the cervical sympathetic, forming the Œsophageal Plexus.

## THE STOMACH.

**Describe the Stomach.** It is the principal organ of digestion, pyriform in shape, of musculo-membranous structure, about 12 inches long by 4 inches in average diameter, held in position by the lesser omentum, and situated diagonally across the upper abdomen, in the epigastric and right and left hypochondriac regions, above the transverse colon, below the liver and diaphragm. It presents for examination a—

*Fundus or Splenic End*, *c*—connected to the spleen by the gastro-splenic omentum. (See under PERITONEUM.)



*Pylorus or Lesser End*,—lies in contact with the anterior wall of the abdomen, the under surface of the liver, and the neck of the gall-bladder, its position being near the end of the cartilage of the 8th rib.

*Greater Curvature*, *d*—is convex, and is connected to the colon by the gastro-colic omentum. (See under PERITONEUM.)

*Lesser Curvature, i*—is concave, and connected to the liver by the gastro-hepatic omentum, and to the diaphragm by the gastro-phrenic ligament.

*Œsophageal Orifice, b*—is situated between the fundus and the lesser curvature. It is funnel-shaped, and the highest part of the organ.

*Pyloric Orifice, k*—opens into the duodenum, *l* and is guarded by the circular muscular fibres of the pylorus, which are aggregated into a circular ring, projecting into the cavity, and with its covering fold of mucous membrane, forming the Pyloric Valve.

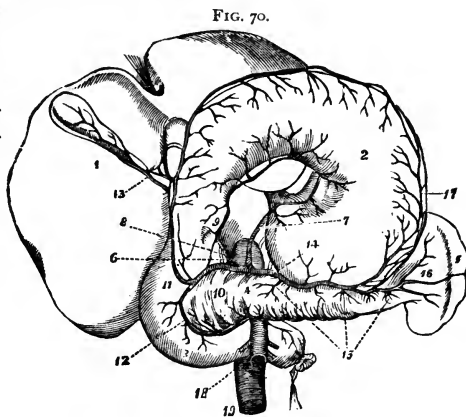
**Describe its Structure.** The Stomach has 3 coats, a—

*Mucous Coat, g*—lined with columnar non-ciliated epithelium, covered with polygonal *Alveoli*,  $\frac{1}{150}$  of an inch in diameter, containing the orifices of the *Gastric Follicles*. When the stomach is contracted the mucous membrane lies in longitudinal folds or *Rugæ, h* one of which aids in forming the valve at the pyloric orifice.

*Cellular or Sub-mucous Coat,*—contains the gastric vessels.

*Muscular coat, f*—consists of longitudinal, circular, and oblique fibres. *The Longitudinal* are continuous with those of the œsophagus and small intestine, and are the most superficial. *The Circular* lie deeper, and over the whole organ; they form a sphincter valve around the pyloric orifice. (See above.) *The Oblique Fibres* lie deepest, forming two sets around the œsophageal opening, in continuation of the circular fibres of the œsophagus.

THE SEROUS INVESTMENT of the stomach is derived from the peritoneum, and covers the whole external surface, excepting the points where the gastro-splenic, greater and lesser omenta are attached. It is usually, but incorrectly, described as a fourth coat of the stomach.



**Describe the Gastric Glands.** They are of 3 kinds, the—  
*Peptic Follicles,*—situated all over the stomach, but most numerous towards the splenic end,—are tubules lined with columnar epithelium in their upper one-fourth, and filled with nucleated cells in their deepest parts.

*Simple Solitary Glands* are found scattered along the lesser curvature, and near the pyloric end.

**Name the Vessels and Nerves of the Stomach.** Its Arteries are the *Gastric*<sup>7</sup>, arising from the Coeliac Axis.

*Pyloric*<sup>9</sup>,  
*Right Gastro-epiploic*<sup>11</sup>, } Branches of the Hepatic Artery.<sup>8</sup>

*Left Gastro-epiploic*<sup>17</sup>,  
*Vasa Brevia*<sup>16</sup>, } Branches of the Splenic Artery.<sup>14</sup>

*Veins*, terminate in the splenic and portal veins.

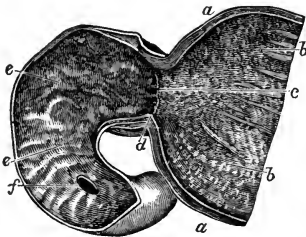
*Nerves*, are terminal branches of the right and left pneumogastriacs, and branches of the semilunar ganglia of the sympathetic, forming the *Gastric Plexus*.

### THE SMALL INTESTINE.

**Describe the Small Intestine.** It is a convoluted, tubular, digestive organ, about 20 feet in length, held to the spinal column by the mesenteric portion of the peritoneum, and divided into 3 parts, the—

*Duodenum*,—about 12 fingers (10 inches) long, *ascends* for 2½ inches to the under surface of the liver and the neck of the gall-bladder,—*descends* for 3½ inches in front of the right kidney,—and passes transversely for 4 inches to the left, across the spinal column, to the left side of the second lumbar vertebra, where the superior mesenteric artery crosses its junction with the jejunum. The duodenum has no mesentery, is partially covered with peritoneum, and surrounds the

FIG. 71.



head of the pancreas. Into its descending portion open the ductus communis cholédochus *f* and the pancreatic duct.

*Jejunum*,—about two-fifths of the rest of the small intestine, its coils lying around the umbilical region. It is named from the fact that it is usually found empty (*jejunos*) after death.

*Ileum*,—comprises the remainder of the small intestine; is named from its twisted course, lying below the umbilicus, and terminating in the right iliac fossa, at the ileo-cæcal valve, or valve of Bauhin.

**What Coats has the Small Intestine?** Three, a mucous, a sub-mucous or cellular, and a muscular coat. Its peritoneal investment is sometimes described as a fourth coat, but incorrectly. The—

*Mucous Membrane*,—is covered with columnar non-ciliated epithelium, and thrown into crescentic transverse folds, the *Valvula Conniventes*, or valves of Kirkring. It also presents numerous vascular projections or *Villi*, each formed of basement membrane, epithelium, a lacteal vessel, a capillary plexus, granular corpuscles, and longitudinal muscular fibres, and numbering about four millions in the whole length of the intestine.

*Cellular Coat*,—contains the vessels of the intestine, and connects the other two coats together.

*Muscular Coat*,—consists of external longitudinal and internal circular fibres, the former being thinly distributed along the bowel, the latter forming a thick layer, but not making complete rings.

**Describe the Glands of the Small Intestine.** The mucous membrane of the small intestine contains—

*Crypts of Lieberkühn, or Simple Follicles*,—are minute tubular depressions, found all over the intestine and also in the stomach.

*Brunner's Glands*,—are small conglomerate glands, found only in the duodenum and the first part of the jejunum, being most numerous near the pylorus. In structure they resemble the pancreas.

*Solitary Glands*,—are lymphoid organs, situated throughout the intestine, though most numerous at the lower portion of the ileum. They are agminated into some 20 or 30 oval patches, named—

*Peyer's Patches*,—on the surface opposite to the mesenteric attachments, some of which are as much as 4 inches in length. They are most numerous and largest in the ileum, and are most developed during digestion.

## THE LARGE INTESTINE.

**Describe the Large Intestine.** It is about five feet long, of large calibre, sacculated, consists of the same coats as the small intestine, the mucous being smooth, and without villi, the muscular having its longitudinal fibres collected into 3 narrow bands, producing a pouching of the tube. It presents the following PARTS and *points*, viz.—

*CÆCUM, or Caput Cæcum Coli*,<sup>c</sup>—a dilated blind pouch behind the entrance of the small intestine.<sup>a</sup> It is the beginning of the large intestine, lies in the right iliac fossa, and is two-thirds covered by peritoneum.

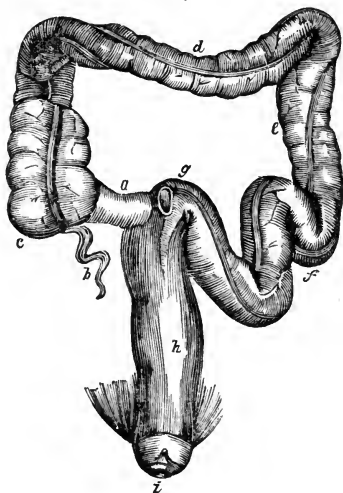
*Appendix Vermiformis*,<sup>b</sup>—a blind prolongation about 3 to 6 inches long, narrow and worm-like, directed backwards and upwards from the lower part of the cæcum, being retained by a fold of the peritoneum.

*Ileo-cæcal Valve, or Valve of Bauhin*,—guards the entrance of the small intestine, being formed by two crescentic folds of the mucous and cellular coats and circular muscular fibres, each covered with villi on the side toward the ileum, but smooth on the cæcal side.

**ASCENDING COLON**,—extends upwards to the under surface of the liver, where it forms the *Hepatic Flexure of the Colon*.

**TRANSVERSE COLON**, *d*—crosses the abdominal cavity just below the liver, gall-

FIG. 72.



bladder, stomach and spleen, to the left hypochondrium, where it terminates in the *Splenic Flexure of the Colon*.

**DESCENDING COLON**, *e*—passes downwards in front of the left kidney to the left iliac fossa, where it forms the—

*Sigmoid Flexure of the Colon*, *f*—curved like an *f*, first upwards, then downwards; extending from the crest of the left ileum to the left sacro-iliac synchondrosis.

**RECTUM**, *h*—from the last-named point to the anus; is 6 to 8 inches long, not sacculated, and, though not straight, is straighter than the rest of the gut. It curves laterally to the middle of the sacrum, and backwards about an inch above its termination at the *Anus*, *i* where it is

distended into a pouch. This lower inch has no peritoneal investment.

*Appendices Epiploicae*,—are small pouches of peritoneum containing fat, and found along the colon and part of the rectum. They are due to the incompleteness of the investment of the gut by peritoneum.

*Sphincters of the Rectum* are 3,—the sphincter ani, internal sphincter and sphincter tertius of Hyrtl. (See *ante*, pp. 83, 84.)

*Folds of Houston*,—three semilunar transverse folds, one in the upper part of the rectum on the right side, another about the middle on the left side, and the third in front, opposite the base of the bladder.

**What Glands are found in the Large Intestine?** The *Follicles of Lieberkühn* are more numerous here than elsewhere, also a few *Solitary Glands* and *Peyer's Patches* in its upper portion. The glands of Brunner are absent, the villi and *valvulae conniventes* are almost wanting.

**State the Principal Relations of each of the three parts of the Rectum.** They are as follows, viz.—

*Upper Part* (4 inches),—lies on the left pyriformis muscle and the left

sacral plexus; and to its left lie the left ureter and branches of the left internal iliac artery.

*Middle Part* (3 inches), in the male subject lies just behind the trigonum vesicæ and the vesiculæ seminales, and close below the under surface of the prostate gland. In the female it is adherent to the central portion of the posterior wall of the vagina.

*Lower Part* (1 inch),—is surrounded by the 3 sphincters and the levator ani muscle, and is separated by the perineum from the membranous portion and bulb of the urethra in the male, from the vagina in the female.

## THE LIVER.

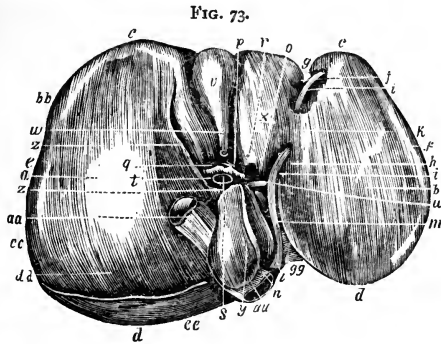
**Describe the Liver.** It is the largest gland in the body, weighing from 3 to 4 pounds, measuring transversely about 12 inches, antero-posteriorly 6 inches, in greatest thickness 3 inches. It is situated in the right hypochondriac, epigastric and part of the left hypochondriac regions; has 5 fissures, 5 lobes, 5 ligaments, and 5 sets of vessels, and is invested by peritoneum, except for a small space at the attachment of the coronary ligament. It is also surrounded by a fibrous coat which is continuous at the transverse fissure with the capsule of Glisson. Its—

*Upper Surface*,—is convex, in relation with the under surface of the diaphragm and 6 or 7 lower ribs, and is divided into two lobes by the suspensory or broad ligament.

*Under Surface* (Fig. 73), is concave, covers the stomach, duodenum, hepatic flexure of colon, right kidney and supra-renal capsule, and is divided into 5 lobes by 5 fissures.

*Anterior Border, c*—sharp and notched opposite the fundus of the gall-bladder and the round and falciform ligaments. It corresponds to the lower border of the ribs and costal cartilages, descending a little lower during deep inspiration and in the upright posture.

*Posterior Border, d*—rounded, and deeply grooved (sometimes channeled) for the inferior vena cava. *aa*



**Describe the 5 Ligaments of the Liver.** Four are folds of peritoneum; one, the round ligament, is the obliterated umbilical vein and ductus venosus of the fœtus. The—

*Suspensory or Falciform Ligament, j*—called also the Broad and the Longitudinal Ligament,—is a sickle-shaped double fold reflected over the round ligament, and is attached to the sheath of the right rectus muscle as low as the umbilicus, and to the diaphragm.

*Coronary Ligament, f*—is a double fold, containing firm areolar tissue in its interspace, and extending from the posterior border of the liver to the diaphragm.

*Lateral Ligaments, 2,*—are the triangular extremities of the coronary ligament.

*Round Ligament, i*—ascends in the free margin of the suspensory ligament from the umbilicus to the longitudinal fissure, in which it is continued to the vena cava.

**Describe the 5 Hepatic Fissures.** They are all situated on its under surface, and separate the 5 lobes, one from another. They are the—

*Longitudinal Fissure, h*—its anterior two-thirds, in front of the transverse fissure, is called the *Umbilical Fissure*, from containing the umbilical vein; its posterior one-third is the *Fissure of the Ductus Venosus*, lodging the slender cord which represents that fœtal vessel.

*Transverse Fissure, o*—about 2 inches long, running from the longitudinal towards the right; and transmit the portal vein, hepatic artery, bile-duct, lymphatics and nerves, surrounded by the *Capsule of Glisson*.

*Fissure of the Gall bladder, v*—on the right of the longitudinal fissure, and nearly parallel with it, extending from the anterior border, backwards to near the right end of the transverse fissure.

*Fissure for the Vena Cava,*—extends inwards from the posterior border, where it joins the fissure for the ductus venosus; and gives exit to the hepatic veins which here join the vena cava. This fissure is occasionally a complete foramen.

**Describe the 5 Hepatic Lobes.** Three are mere lobules, formed from the right lobe by the smaller fissures. The—

*Right Lobe, a*—is much the largest, and presents the three small fissures and two depressions, one anteriorly for the colon, the other posteriorly for the kidney.

*Left Lobe, b*—is divided from the right by the longitudinal fissure, and rests upon the stomach.

*Lobulus Quadratus, x*—in front of the transverse fissure, and between the umbilical fissure and that for the gall bladder.



*Lobulus Spigelii*,<sup>γ</sup>—behind the transverse fissure, and between the fissure for the ductus venosus and that for the vena cava.

*Lobulus Caudatus*,<sup>z</sup>—a connecting ridge from the lobulus Spigelii to the right lobe; it separates the transverse fissure from the fissure for the vena cava, and forms the roof of the foramen of Winslow.

**Describe the 5 Hepatic Vessels.** They are the — portal vein,<sup>s</sup> hepatic artery,<sup>g</sup> hepatic duct,<sup>h</sup> and lymphatics, situated in the transverse fissure, and surrounded by the capsule of Glisson,—also the hepatic veins in the fissure for the vena cava. The—

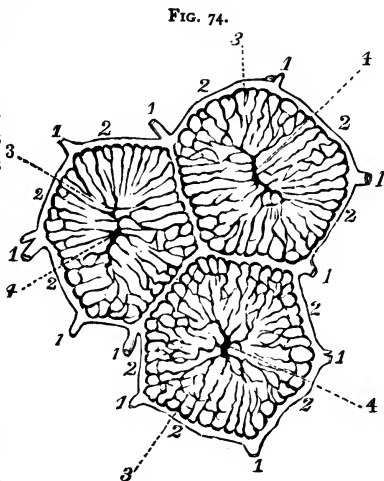
*Portal Vein*,<sup>s</sup>—formed by the superior and inferior mesenteric, splenic and gastric veins (all the main veins of the abdomen except the renal), is about 4 inches long. It enters the transverse fissure of the liver, where it divides into two branches, and these again divide and subdivide to ramify throughout the gland. Its branches are the—

Right Portal.	Inter-lobular Veins. <sup>1</sup>	} Lobular Plexus. (Fig. 74.)
Left Portal.	Lobular Veins. <sup>3</sup>	
Vaginal Branches.	Intra-lobular Veins. <sup>4</sup>	

*Hepatic Veins*,—are the continuations of the intra-lobular, beginning as the *Sub-lobular Veins* beneath each lobule, and entering the inferior vena cava in the fissure for that vessel.

*Hepatic Artery*,<sup>g</sup>—the nutrient vessel of the liver; arises from the cœliac axis, enters the transverse fissure, and divides into branches which supply the cellular tissue, the walls of the vessels, and the investing membranes of the liver, also forming a plexus in each lobule which anastomoses with the terminal branches of the portal vein.

*Hepatic Duct*,—about 1½ inch long; is formed in the transverse fissure by the union of



the two main biliary ducts, from the right and left lobes. It joins the cystic duct from the gall-bladder to form the Ductus Communis Cholédocus. (See next page.)

*Lymphatics*,—accompany the blood vessels in two sets, a superficial set and a deep one.

**What Nerves supply the Liver?** Branches of the Hepatic Plexus, which is formed by branches derived from the left pneumogastric, right phrenic and solar plexus.

**Describe the Structure of the Liver.** The substance of the liver is

composed of numerous *Lobules*,<sup>1</sup> of polygonal shape, and about  $\frac{1}{20}$  of an inch in diameter, clustered around the sublobular branches of the hepatic veins, and connected together by connective tissue,<sup>3</sup> blood vessels, ducts,<sup>2</sup> and lymphatics. Each lobule consists of—

*Hepatic Cells*,—each about the  $\frac{1}{1500}$  of an inch in diameter, having a nucleus and

nucleolus, yellow coloring matter, glycogen granules, and oil globules.

*Lobular Veins*,<sup>3</sup>—forming a plexus in the lobule.

*Intra-lobular Vein*,<sup>4</sup>—in the centre of each lobule. } (See Figs. 74, 75.)

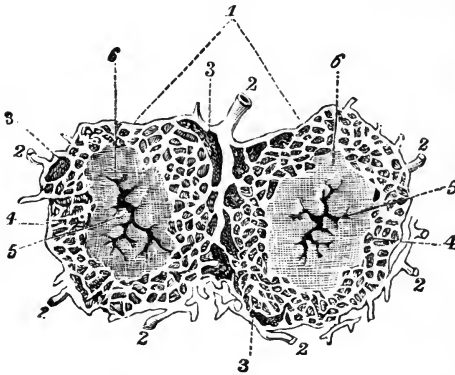
*Plexuses*,—of lymphatics, nerves, and bile-ducts.

**What is the Capsule of Glisson?** The areolar tissue which surrounds the hepatic vessels in the transverse fissure, and accompanies them in their course throughout the substance of the liver. It is continuous with the fibrous covering of the organ.

**How may the Portal Veins be distinguished from the Hepatic, on section of the Liver?** The portal veins remain closed, being surrounded by the capsule of Glisson. The hepatic veins gape open, being adherent to the liver substance.

**Describe the Gall-bladder.** It is a pear-shaped bag, 3 to 4 inches long, an inch in greatest diameter, holding from 8 to 12 fluid drachms, invested by peritoneum on its under surface and fundus, formed of a fibromuscular coat and lined by a mucous one, lying in a fissure on the under surface of the liver, close to its anterior border, and directed obliquely downwards, forwards, and to the right. Its—

FIG. 75.



**Fundus**,—touches the abdominal wall immediately below the 9th costal cartilage, and is completely invested by peritoneum.

**Neck**,—coils twice upon itself, and empties into the *Cystic Duct*, which is about an inch long, and joins with the *Hepatic Duct* to form the *Ductus Communis Cholédochus*.

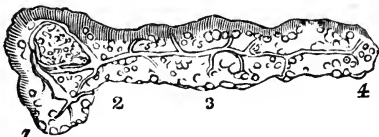
**What is the Ductus Communis Cholédochus?** A fibro-muscular tube, covered by peritoneum and lined with mucous membrane, about 3 inches in length, formed by the junction of the Cystic and Hepatic ducts, and emptying its contents (bile) into the descending part of the duodenum at a point about 3 inches from the pyloric orifice of the stomach, generally in common with the duct of the pancreas. The three ducts above-named are often called the *Biliary Ducts*.

## THE PANCREAS.

**Describe the Pancreas.** The Pancreas is a racemose gland, about 7 inches long, of a grayish-white color, situated behind the stomach and in front of the first lumbar vertebra. Its structure resembles that of the salivary glands, being composed of reddish-yellow lobules, united by cellular tissue, vessels and ducts, and ending in closed pouches surrounded by a capillary plexus. The—

*Pancreatic Duct, or Duct of Wirsung*,<sup>5</sup>—extends the whole length of the gland, and opens into the duodenum about 3 inches below the pylorus, by an orifice common to it and the ductus communis cholédochus.

FIG. 76.



*Head, or Right Extremity*,<sup>1</sup>

is surrounded by the curve of the duodenum, the ductus communis cholédochus and the pancreatico-duodenal arteries.

*Tail, or Left Extremity*,<sup>4</sup>—lies above the left kidney and in contact with the lower end of the spleen.

*Body*<sup>3</sup>—is in relation *anteriorly* with the ascending layer of the transverse meso-colon, the posterior wall of the stomach and the transverse colon; *posteriorly* with the aorta, portal vein, inferior vena cava, splenic vein, origin of the superior mesenteric artery, crura of the diaphragm, left kidney and supra-renal capsule, and the left quadratus lumborum muscle.

*Arteries*, are the—

Pancreatica Magna, and Pancreaticæ Parvæ, from the splenic.

Pancreatico-duodenalis,—branch of the hepatic artery.

Inferior Pancreatico-duodenalis,—branch of the sup. mesenteric.

*Veins*,—open into the splenic and mesenteric veins.

*Nerves*,—from the solar plexus, forming a Splenic Plexus.

**What is the Lesser Pancreas?** A lobe of the head of the pancreas; sometimes detached therefrom, in which case it opens by a duct into the duodenum about an inch above the orifice of the pancreatic duct.

## THE DUCTLESS GLANDS.

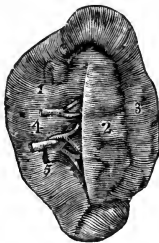
**Name the so-called Ductless Glands.** They are the Spleen, Supra-renal Capsules, Thyroid and Thymus Glands. The first two are in the abdominal cavity, the thyroid gland is in the front of the trachea, and the thymus gland is in the anterior mediastinum of the thorax. These organs have no excretory ducts, and their functions are unknown.

### THE SPLEEN.

**Describe the Spleen.** The spleen is a soft, spongy and very vascular organ, about 5 by 3 by 2 inches, from 6 to 10 ounces in weight, and situated deeply in the left hypochondrium, embracing the cardiac end of the stomach, to which it is connected by the gastro-splenic omentum. Its—

*Outer Surface*,—is convex, corresponds to the 9th, 10th and 11th ribs, and is in relation with the inferior surface of the diaphragm.

FIG. 77.



*Inner Surface*,—is concave, and embraces the cardiac or splenic end of the stomach.

*Borders*,—the anterior is thin and often notched; the posterior is thick and lies on the left kidney.

*Suspensory Ligament*,—attaches the upper extremity to the diaphragm, and is a fold of peritoneum.

*Hilum*,—a vertical fissure about the middle of the concave surface. It is pierced by the vessels, lymphatics and nerves.

*Peritoneal, or Serous Coat*,—covers the whole organ, except at the attachments of the suspensory ligaments and the gastro-splenic omentum.

*Fibro-elastic Coat, or Tunica Propria*,—is reflected at the hilum upon the vessels, and gives off numerous bands (*trabeculae*), which bound the lacunar spaces (*areolae*) of the organ.

*Malpighian Corpuscles*,—are lymphoid sphenoidal expansions of the outer coat of the small arteries, and average in diameter about the  $\frac{1}{8}$  of an inch. They are attached to the arterioles of the organ in groups of 6 or 8, and are usually pierced by an artery. Their reticulum is slender and open, densely filled with lymphoid corpuscles, and well supplied with capillaries. They have no capsule.

*Splenic Substance or Pulp*,—a soft, pulpy, brown-red mass, surrounding the Malpighian corpuscles, and contained in the areolæ. It consists of a delicate net-work of connective-tissue corpuscles, containing pigment-granules (disintegrated blood-corpuscles), granular albuminous matter, nucleated and non-nucleated cells, and free nuclei, also red blood-corpuscles in every stage of metamorphosis. These are denominated the colored and colorless elements.

*Splenic Artery*,—is large and tortuous, and divides at the hilum into 5 or 6 branches, each supplying a segment of the organ, and terminating either directly in the venous radicles, or in the lacunar spaces.

*Splenic Vein*,—arises by radicles partly from the capillaries, partly from the lacunar spaces, and empties into the portal vein.

*Nerves*,—are derived from the semi-lunar ganglion of the solar plexus and the right pneumogastric, forming the *Splenic Plexus*.

### THE THYROID GLAND.

**Describe the Thyroid Gland.** It is a bi-lobed organ, about 3 inches in length, situated on the sides of the upper 2 or 3 rings of the trachea, and consisting of minute closed vesicles containing a yellow-colored fluid, surrounded by a dense plexus of capillaries, and connected together by areolar tissue. Its—

*Isthmus*,—connects the lower third of each lobe together, passing in front of the trachea. It is occasionally absent.

*Pyramid*,—is a third lobe, which sometimes arises from the left lobe, or from the left upper border of the isthmus.

*Levator Glandulæ Thyroideæ*,—are muscular bands occasionally found extending from the body of the hyoid bone to the isthmus of the gland or its pyramid.

**Name the Arteries of the Thyroid Gland.** They are very large, anastomose freely, and are the—

*Superior Thyroid*,—branch of the external carotid, arising therefrom below the greater cornu of the hyoid bone, and giving off the following branches, viz.—

Muscular.	Hyoid.	Superior Laryngeal.
Glandular.	Superficial Descending.	Crico-thyroid.

*Middle Thyroid, Artery of Neubauer, or Arteria Thyroidea Ima*,—is occasionally found arising from the innominate artery or directly from the arch of the aorta, passing upwards along the front of the trachea.

*Inferior Thyroid*, branch of the thyroid axis, gives off—

Laryngeal Branch.	Œsophageal Branches.
Tracheal Branches.	Ascending Cervical.

**Enumerate the Veins and Nerves of the Thyroid Gland.** The *Veins* form a plexus in front of the gland and the trachea, giving rise to the—

*Superior Thyroid Vein.*  
*Middle Thyroid Vein.* } open into the Internal Jugular Vein.

*Inferior Thyroid Vein,* opens into the Innominate Vein.

*Nerves*—are branches of the pneumogastric, and of the middle and inferior ganglia of the sympathetic.

### THE THYMUS GLAND.

**What is the Thymus Gland?** It is a temporary organ, attaining its full size about the age of 2 years, then being about 2 inches long, 1½ inch broad, 3 lines thick, and weighing about half an ounce. It subsequently atrophies, and has almost disappeared at puberty. It is situated in the anterior mediastinum and the neck, behind the sternum and the sterno-hyoid and sterno-thyroid muscles, extending from the level of the 4th costal cartilage to the lower border of the thyroid gland. In the mediastinum it rests upon the pericardium, and is separated by the thoracic fascia from the arch of the aorta and the great vessels.

**Describe its Structure.** The Thymus gland consists of two lateral lobes (sometimes a third), together forming a pyramidal mass. It is surrounded by a fibrous capsule and is divided by *Trabeculae* into primary and secondary lobules, which consist of meshes of delicate retiform tissue closely packed with lymph-corpuscles, and pervaded with capillaries. The so-called *Central Cavity* and *Primitive Linear Tube*, are deceptive appearances of the multiplying cells in the interior of the gland.

**Name its Vessels and Nerves.** The Thymus—

*Arteries*,—are derived from the internal mammary, superior and inferior thyroid, subclavian and carotid. They ramify on the surface of each lobule, having smaller twigs converging toward the centre.

*Veins*,—open into the left innominate and the thyroid.

*Lymphatics*,—consist of intralobular and interlobular plexuses, and open into the anterior mediastinal glands.

*Nerves*,—are very minute and derived from the pneumogastric and the sympathetic.

### THE SUPRA-RENAL CAPSULES.

**What are the Supra-Renal Capsules?** They are two small, crescentic-shaped bodies, situated one on each kidney. Each presents a small fissure or *Hilum* anteriorly, from which its vein emerges, and consists of a—

*Fibrous Capsule*,—which is very thin, closely adherent, and sends numerous septa inwards.

*Cortical Substance*,—composed of columnar and rounded cells, held together in layers by a fibrous stroma.

*Medullary Substance*,—is darker than the cortical portion, and pulpy. Consists of cells in groups, supported by a delicate stroma, and believed by some anatomists to be prolonged into nerve fibres.

**What are their Relations?** Their bases rest on the upper front parts of the kidneys, their posterior surfaces on the crura of the diaphragm, about the level of the 10th dorsal vertebra. The—

*Anterior Surface*,—of the right capsule is covered by the liver; that of the left one by the spleen and pancreas.

*Superior Surface*,—of each is in relation internally with the great splanchnic nerve and semilunar ganglion.

**Name their Vessels and Nerves.** The *Lymphatics* of these bodies open into the lumbar glands, but are very imperfectly known. Their—

*Arteries*,—are the *Supra-renal Branches* of the aorta, renal, and inferior phrenic arteries, forming a dense capillary plexus in the cortical portion of the organ.

*Veins*,—of each open into a single trunk, the *Supra-renal Vein*, which on the right side of the body empties into the inferior vena cava, on the left side into the left renal vein.

*Nerves*,—are chiefly derived from the solar and renal plexuses, with some filaments from the phrenic and pneumogastric nerves, forming a complicated network in the medullary substance of the organ, and having numerous small ganglia developed upon them.

## THE ABDOMINAL CAVITY.

**What is the Abdomen?** An oval cavity, situated between the thorax above and the pelvis below, invested by peritoneum internally, and containing the—

<i>Stomach.</i>	<i>Pancreas.</i>	<i>Abdominal Aorta.</i>
<i>Intestines.</i>	<i>Kidneys and Ureters.</i>	<i>Inferior Vena Cava.</i>
<i>Liver.</i>	<i>Supra-renal Capsules.</i>	<i>Receptaculum Chyli.</i>
<i>Gall-bladder.</i>	<i>Bladder (when distended.)</i>	<i>Thoracic Duct.</i>
<i>Spleen.</i>	<i>Uterus (during pregnancy.)</i>	<i>Solar Plexus, etc.</i>

**Name the Boundaries of the Abdomen.** *Above*, it is bounded by the diaphragm;—*below*, by the brim of the pelvis;—*posteriorly*, by the vertebral column, and the fasciæ covering the psoæ and quadrati lumborum muscles;—*anteriorly and laterally*, by the transversalis fascia, the lower ribs, and the venter of the ilium.

**What Openings are found in its Walls?** They are the—

*Opening for the Vena Cava*,—in the diaphragm.

*Aortic Opening*,—behind the diaphragm, for the aorta, vena azygos minor, the thoracic duct, and occasionally the left sympathetic nerve.

*Œsophageal Opening*,—in the diaphragm, for the œsophagus, and the pneumogastric nerves.

*Umbilical Opening*,—in the anterior wall, transmitting the umbilical vessels in the fœtus, but obliterated after birth, leaving a puckered depression, the *Umbilicus*.

*Internal Abdominal Ring*,—on each side, half an inch above Poupart's ligament, for the passage of the spermatic cord in the male, and the round ligament of the uterus in the female.

*Femoral or Crural Ring*,—on each side, just below Poupart's ligament; for the passage of the femoral vessels. This opening is closed by the Septum Crurale. (See Femoral Hernia.)

**Name the Regions of the Abdomen.** The Abdomen is divided into 9 regions, by two horizontal lines,—one between the cartilages of the 9th ribs, another between the crests of the ilia,—and 2 vertical lines from the cartilages of the 8th ribs to the centre of Poupart's ligament. The 9 regions thus formed are named the—

*Right Hypochondriac.*

*Epigastric.*

*Left Hypochondriac.*

*Right Lumbar.*

*Umbilical.*

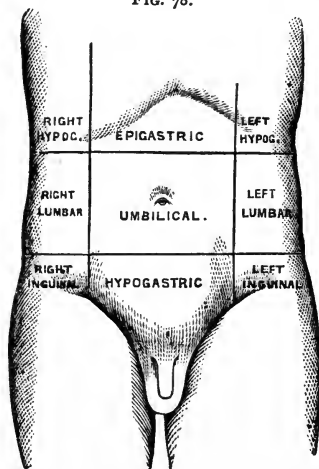
*Left Lumbar.*

*Right Inguinal.*

*Hypogastric.*

*Left Inguinal.*

FIG. 78.



**What Parts are contained in each Region?**

*Right Hypochondriac Region*,—contains the right lobe of the liver, gall-bladder, duodenum, hepatic flexure of the colon, upper part of the right kidney, and the right supra-renal capsule.

*Epigastric Region*,—contains the right two-thirds of the stomach, left lobe and lobus Spigelii of the liver, hepatic vessels, coeliac axis, solar plexus, pancreas, and parts of the aorta, inferior vena cava, vena azygos, and thoracic duct.

*Left Hypochondriac Region*,—contains the splenic end of the stomach, spleen, tail of the pancreas, splenic flexure of the colon, upper half of the left kidney and its supra-renal capsule.



*Right Lumbar Region*,—contains the ascending colon, lower half of the right kidney, and part of the small intestine.

*Umbilical*,—contains the transverse colon, transverse duodenum, part of the great omentum and mesentery, and part of the small intestine.

*Left Lumbar Region*,—contains the descending colon, lower half of the left kidney, and part of the small intestine.

*Right Inguinal Region*,—contains the right ureter, cæcum, appendix vermiformis, and the spermatic vessels of that side.

*Hypogastric Region*,—contains part of the small intestine, the bladder in children and when distended in adults, and the uterus during pregnancy.

*Left Inguinal Region*,—contains the left ureter and spermatic vessels, and the sigmoid flexure of the colon.

## THE PERITONEUM.

**What is the Peritoneum?** A serous membrane, forming a closed sac, its *parietal layer* lining the walls of the abdomen and pelvis, its *visceral layer* being reflected more or less completely over all the abdominal and pelvic viscera. Its free surface is covered with squamous epithelium, and is smooth, moist, and shining. Its attached surface is connected to the viscera and the parietes of the abdomen by the sub-peritoneal areolar tissue.

**Is the Peritoneum always a closed sac?** No! In the female it is continuous with the mucous lining of the Fallopian tubes, which at their free extremities open into its cavity.

**Name the Divisions of the Peritonæum.** The—

*Greater Sac*,—extends over the anterior two-thirds of the liver, behind and above the stomach, below, behind, and in front of the great omentum, and below the meso-colon.

*Lesser Sac, or Cavity of the Great Omentum*,—extends behind and below the liver and stomach, above the meso-colon, and within the great omentum.

**What is the Foramen of Winslow?** A constriction of the peritoneal cavity connecting the two sacs, situated behind the right free border of the gastro-hepatic or lesser omentum, and formed by the gastric and hepatic arteries as they curve around to the celiac axis. Its boundaries are as follows, viz.—

*Anteriorly*,—the lesser omentum, containing the duodenum, hepatic artery, portal vein, and the ductus communis cholédochus.

*Posteriorly*,—the inferior vena cava, and the right crus of the diaphragm.

*Superiorly*,—the lobus Spigelii of the liver.

*Inferiorly*,—the hepatic artery, curving forwards from the celiac axis

**What passes through the Foramen of Winslow?** Nothing.

What are the Omenta or Epiploa? They are folds of peritoneum connecting the stomach with other organs, and are 3 in number, namely, the—

*Gastro-colic or Great Omentum*,<sup>14</sup>—consists of four layers of peritoneum, the most anterior and posterior of which belong to the greater sac, the two internal to the lesser sac. The two anterior layers descend from the stomach and the spleen, over the small intestines, and then ascend as the posterior layers, to enclose the transverse colon.

*Gastro-hepatic or Lesser Omentum*,—consists of two layers of peritoneum, the upper belonging to the greater sac, the lower to the lesser sac. It extends from the transverse fissure of the liver to the lesser curvature of the stomach, and contains in its right free margin the—

Hepatic Artery.

Portal Vein.

Lymphatics.

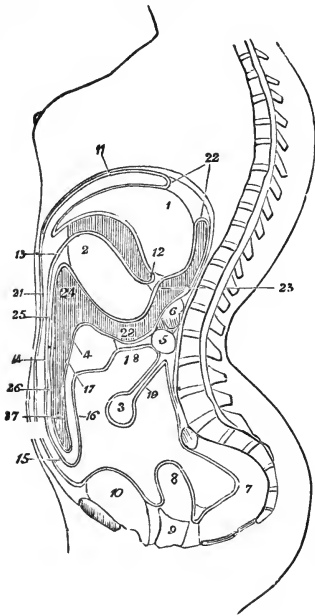
Ductus Communis Cholédochus.

First part of the Duodenum.

Hepatic Plexus of Nerves.

*Gastro-splenic Omentum*,—connects the stomach with the spleen, and is continuous by its lower border with the great omentum. It contains the Splenic Vessels and the Vasa Brevia.

FIG. 79.



What are the Mesos or Mesenteries? Folds of peritoneum connecting the various parts of the intestinal canal (except the duodenum) to the abdominal walls. Each one contains the vessels of the part which it supports. They are the—

*Mesentery proper*.<sup>19</sup> *Meso-cæcum*. *Meso-colon*.<sup>28</sup> *Meso-rectum*.

What Ligaments are formed by the Peritoneum? They are 17 folds of peritoneum which support certain organs, viz.—

1 *Gastro-phrenic*,—from the stomach to the diaphragm.

4 *Hepatic*—the longitudinal, coronary, and 2 lateral ligaments of the liver.

5 *Vesical*,—the false ligaments of the bladder.

6 *Uterine*,—2 vesico-uterine, 2 recto-uterine, and 2 lateral or broad ligaments of the uterus.

1 *Splenic*,—the suspensory ligament of the spleen.

**Name the Viscera covered by Peritoneum.** They are the—

<i>Liver</i> <sup>1</sup> (almost wholly).	<i>Transverse Colon</i> . <sup>4</sup>
<i>Stomach</i> <sup>2</sup> (almost wholly).	<i>Sigmoid Flexure</i> .
<i>Spleen</i> .	<i>Rectum</i> (upper $\frac{1}{3}$ ).
<i>Duodenum</i> <sup>5</sup> (first part).	<i>Ovaries</i> .
<i>Small Intestine</i> . <sup>3</sup>	<i>Uterus</i> . <sup>8</sup>

**Name the Viscera partially invested by Peritoneum.** The—

<i>Duodenum</i> <sup>5</sup> (descending and transverse portions).	<i>Descending Colon</i> .
<i>Cæcum</i> .	<i>Rectum</i> <sup>7</sup> (middle third).
<i>Ascending Colon</i> .	<i>Vagina</i> <sup>9</sup> (upper part).
	<i>Bladder</i> <sup>10</sup> (posterior wall).

**What Viscera have no Peritoneal Investment?** The—

<i>Rectum</i> <sup>7</sup> (lower third).	<i>Pancreas</i> . <sup>6</sup>
<i>Bladder</i> <sup>10</sup> (neck, base and anterior surface).	<i>Kidneys</i> .
	<i>Supra-renal Capsules</i> .
	<i>Vagina</i> <sup>9</sup> (lower part).

**What are the Appendices Epiploicæ?** Pouches of peritoneum situated along the colon and upper third of the rectum, and filled with fat. They are chiefly found along the transverse colon.

**A Demonstration of the Peritoneum** is best made with a large bag of mosquito-netting, sewn up along all four sides, and having a central slit to represent the incision usually made in the laparotomy operation. Sponges of various sizes will represent the various organs, and may be pushed into folds of the bag and tied in by string, wholly covered or partially covered, as the case may be, for each. Professor Pancoast used this method of demonstration in his lectures, making the subject perfectly clear to many who never understood it before.

## ORGANS OF VOICE AND RESPIRATION.

### THE LARYNX.

**What is the Larynx?** A musculo-membranous-cartilaginous box placed between the trachea and the base of the tongue, and constituting the essential organ of voice.

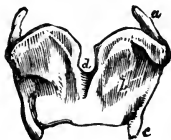**Name its Cartilages.** They are nine in number, 3 single and 3 in pairs, viz.—

<i>Thyroid Cartilage.</i>	<i>2 Arytenoid Cartilages.</i>
<i>Cricoid Cartilage.</i>	<i>2 Cuneiform Cartilages.</i>
<i>Epiglottis.</i>	<i>2 Cornicula Laryngis.</i>

**Describe the Thyroid Cartilage.** The Thyroid or shield-like cartilage consists of two *Alæ* or wings,<sup>b</sup> united in front at an acute angle, the highest portion of its front being called the *Pomum Adami*, Adam's apple. Its—

*Inner Surface*,—gives attachment to the true and false vocal cords, the epiglottis, thyro-arytenoid and thyro-epiglottidean muscles, and the thyro-epiglottic ligament.

FIG. 80.



*Outer Surface*,—affords attachment to the sternothyroid, thyro-hyoid and inferior constrictor muscles; the first two being attached along its oblique ridge.

*Upper Border*,—is curved irregularly, and gives attachment to the thyro-hyoid membrane.

*Lower Border*,—gives attachment to the crico-thyroid membrane in the median line and on each side to the crico-thyroid muscle.

*Posterior Border* of each wing ends above and below in *Cornua* (horns), and gives attachment to the stylo- and palato-pharyngeus muscles.

*Superior Cornu* of each side affords attachment to the thyro-hyoid ligament.

*Inferior Cornu* of each side articulates with the cricoid cartilage by a small oval facet. (See *a* and *c*, Fig. 80.)

**Describe the Cricoid Cartilage.** The Cricoid, or ring-like cartilage, is placed below the thyroid, with its narrow part to the front. It has on each side 2 *Articular Facets*, one on the

FIG. 81.



upper margin posteriorly for the arytenoid cartilage, and one near the lower margin for the inferior cornu of the thyroid cartilage. Its—

*Outer Borders*,—give attachment to the crico-arytenoideus posticus muscle, and the longitudinal fibres of the œsophagus.

*Upper Border*,—affords attachment to the crico-thyroid membrane and the crico-arytenoidei laterales muscles.

*Lower Border*,—is connected to the upper ring of the trachea by fibrous membrane.

**Describe the Arytenoid Cartilages.** The Arytenoid, or pitcher-like cartilages, are 2 in number, pyramidal-shaped, and situated on the upper margin of the cricoid cartilage posteriorly, closing in the back of the larynx. Each cartilage has 3 surfaces, 2 angles, a base and an apex. The—

FIG. 82.



*Anterior Surface*,—gives attachment to the false vocal chord, and the thyro-arytenoideus muscle.

*Anterior Angle*,—gives attachment to the true vocal chord and the thyro-arytenoideus muscle.

*Posterior Surface*,—has attached to it the arytenoideus.

*Posterior Angle*,—gives attachment to the crico-arytenoideus lateralis and posticus muscles.

*Internal Surfaces* of each look towards each other.

*Base*,—has a facet for articulation with the cricoid.

*Apex*,—articulates with the corniculum laryngis.

**What are the Cornicula Laryngis?** They are 2 small cartilaginous nodules attached to the apices of the arytenoid cartilages, and are also called the *Cartilages of Santorini*. To them are attached the aryteno-epiglottidean folds.

**What are the Cuneiform Cartilages?** The Cuneiform, or *Cartilages of Wisberg*, are 2 rods of yellow elastic cartilage contained in the free borders of the aryteno-epiglottidean folds.

**Describe the Epiglottis.** The Epiglottis is a cartilaginous lid for the larynx. It is leaf-shaped, situated behind the base of the tongue, and attached by its *apex* to the posterior surface of the thyroid cartilage, just below the median notch. Its—

*Base*,—is free, and curves over the base of the tongue.

*Apex*,—is connected to the receding angle of the thyroid cartilage by the thyro-epiglottidean ligament.

*Anterior Surface*,—is attached to the hyoid bone by the hyo-epiglottic ligament, and to the tongue by 3 glosso-epiglottidean folds.

*Posterior Surface*,—covers the superior aperture of the larynx when food passes through the pharynx.

*Lateral Margins*,—are connected to the arytenoid cartilages by the aryteno-epiglottidean folds.

**Name the Ligaments of the Larynx.** They are 19 in number,—3 extrinsic ligaments, connecting the larynx to the hyoid bone; and 16 intrinsic, binding its several cartilages together, viz.—

*Extrinsic Ligaments* (3), are the—

Thyro-hyoid Membrane, bounded laterally by—

2 Lateral Thyro-hyoid Ligaments, each contain a nodule of cartilage, the *Cartilago Triticea*.

*Intrinsic Ligaments* (16) are the—

Crico-thyroid Membrane.

2 Crico-thyroid Capsular Ligaments.

2 Crico-arytenoid Ligaments.

2 Crico-arytenoid Capsular Ligaments.

2 Superior Thyro-arytenoid (situated in the false vocal chords).

2 Inferior Thyro-arytenoid (situated in the true vocal chords).

Hyo-epiglottic Ligament.

Thyro-epiglottic Ligament.

3 Glosso-epiglottic Folds.

**Describe the Vocal Chords.** They are in two sets, the—

*Superior or False Vocal Chords*,—containing the superior thyro-arytenoid ligaments,—extend from the angle of the thyroid cartilage around to the anterior surfaces of the arytenoids, and consist of two folds of mucous membrane, each having a free crescentic margin.

*Inferior or True Vocal Chords*,—containing the inferior thyro-arytenoid ligaments,—extend from the angle of the thyroid cartilage around to the anterior angles of the bases of the arytenoids, and consist of two thin layers of mucous membrane covering the ligaments named, each having the thyro-arytenoideus muscle external and parallel to it.

**What is the Glottis?** The Glottis or *Rima Glottidis* is a narrow chink or interval between the inferior vocal chords, formed by the projection into the cavity of the larynx of these chords and the thyro-arytenoidei muscles. Its greatest length is less than an inch, its greatest breadth about half an inch. Its form is a narrow fissure of varying size.

**What is the Ventricle of the Larynx?** An oval depression on each side of the larynx, between the true and false vocal chords, leading up to the sacculus laryngis by a narrow opening.

**What is the Sacculus Laryngis?** A blind pouch situated in each laryngeal wall at the level of the false vocal chord. It is of conical shape, and contains 60 or 70 small mucous glands which secrete a fluid for the lubrication of the true vocal chord. The sacculus is covered in by the aryteno-epiglottideus inferior muscle internally, and by the thyro-epiglottideus externally, both muscles compressing it to discharge its contents. The Sacculus Laryngis is also called the *Sinus of Morgagni*, and the lower part of the ventricle is sometimes named the *Sac of Hilton*.

**What class of Epithelium lines the Larynx?** Its mucous membrane is covered with *Ciliated Epithelium* below the level of the superior vocal chords, extending in front as high as the centre of the epiglottis. Over the rest of the larynx is *Squamous Epithelium*.

**Describe the Laryngeal Muscles.** They are 4 in number on each side and one in the median line, viz.—

*Crico-thyroid* (2),—from the front and side of the cricoid cartilage,<sup>b</sup>—into the lower and inner border of the thyroid.<sup>c</sup> *Action*, to tilt the thyroid cartilage forwards, thus elongating and making tense the vocal chords. *Nerve*, superior laryngeal.

*Crico-arytenoideus Posticus* (2),—from the cricoid cartilage posteriorly,—into the posterior angle of the base of the arytenoid cartilage. *Action*, to rotate the arytenoids outwards and open the glottis, while keeping the vocal chords tense. *Nerve*, recurrent laryngeal.

*Crico-arytenoideus Lateralis d* (2),—from the upper lateral border of the cricoid cartilage, —into the posterior angle of the base of the arytenoid. *Action*, to rotate the arytenoids inwards and close the glottis. *Nerve*, recurrent laryngeal.

*Thyro-arytenoideus e* (2),—from the angle of the thyroid cartilage and the posterior surface of the crico-thyroid membrane,—into the base and anterior surface of the arytenoid. *Action*, to shorten and relax the vocal chords by approximating the cartilages, and to compress the sacculus laryngis. *Nerve*, recurrent laryngeal.

*Arytenoideus* (1),—from the posterior surface and outer border of one arytenoid cartilage,—into the corresponding parts of the opposite cartilage; having oblique and transverse fibres, and filling up the posterior concave surfaces of the arytenoid cartilages. *Action*, by approximating the arytenoids, to close the back part of the glottis. *Nerves*, superior and recurrent laryngeal.

A small fasciculus, called the *Kerato-cricoideus*, is sometimes found below the arytenoideus, extending from the cricoid cartilage to the inferior cornu of the thyroid. It occurs once in 5 cases, usually on one side only, but occasionally on both, and acts to fix the lower horn of the thyroid cartilage backwards and downwards.

Another small muscle is found frequently, though rarely described in the books, the *Triticeo-glossus*. It arises from the cartilaginous nodule in the lateral thyro-hyoid ligament, and passes forwards and upwards to enter the tongue along with the kerato-glossus muscle.

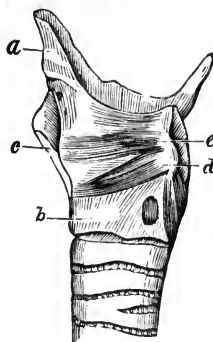
**Describe the Muscles of the Epiglottis.** They are 3 double muscles, as follows, viz.—

*Thyro-epiglottideus* (2),—from the inner surface of the thyroid cartilage,—into the margin of the epiglottis, and the aryteno-epiglottidean fold. *Action*, to depress the epiglottis, and compress the sacculus laryngis. *Nerve*, recurrent laryngeal.

*Aryteno-epiglottideus Superior* (2),—from the apex of the arytenoid cartilage,—into the aryteno-epiglottidean fold. *Action*, to constrict the superior aperture of the larynx. *Nerve*, recurrent laryngeal.

*Aryteno-epiglottideus Inferior* (2),—from the arytenoid cartilage just above the attachment of the superior vocal chord,—into the sacculus laryngis

FIG. 83.



and the margin of the epiglottis. *Action*, to compress the sacculus laryngis. *Nerve*, recurrent laryngeal.

**Name the Arteries and Veins of the Larynx. The—**

*Arteries*,—are the Laryngeal Branches of the superior and inferior thyroid; and the Crico-thyroid Branches of the superior thyroid, which anastomose on the crico thyroid membrane with their fellows of the opposite side.

*Veins*,—empty into the superior, middle and inferior thyroid veins.

**Describe the Laryngeal Nerves.** They are the Superior and Recurrent Laryngeal Branches of the pneumogastric, joined by filaments from the spinal accessory and the sympathetic. The—

*Superior Laryngeal*,—is the nerve of sensation. It enters the larynx by a hole in the thyro-hyoid membrane, and supplies the mucous membrane, and the crico-thyroid and arytenoideus muscles. It has the following branches, namely—

External Laryngeal.

Internal Laryngeal.

*Recurrent Laryngeal*,—is the motor nerve. It winds from before backwards, around the subclavian artery on the right side, around the arch of the aorta on the left side, and is distributed to all the laryngeal muscles except the crico-thyroid,—giving off, in its course, cardiac, œsophageal, tracheal and pharyngeal filaments, and finally anastomosing with the superior laryngeal nerve.

## THE TRACHEA AND BRONCHI.

**What is the Trachea?** A membrano-cartilaginous, cylindrical tube, about  $4\frac{1}{2}$  inches long, and  $\frac{3}{4}$  to 1 inch in diameter, beginning at the lower border of the larynx,<sup>2</sup> opposite the 5th cervical vertebra, and ending opposite the 3d dorsal, by its bifurcation into the two bronchi. It is composed of a fibro elastic membrane containing 16 to 20 imperfect cartilaginous rings, connected by muscular fibres. It is lined with mucous membrane covered with ciliated columnar epithelium, and furnished with glands. Its anterior surface is convex, its posterior surface flat.

**State its Chief Relations in the Neck and Thorax.**

*Anteriorly*,—it is covered from above downwards by the—

Isthmus of the Thyroid Gland.

Thymus Gland.

Inferior Thyroid Veins.

Arch of the Aorta.

Sterno-hyoid Muscle.

Innominate Artery.

Sterno-thyroid Muscle.

Left Carotid Artery.

Manubrium of the Sternum.

Deep Cardiac Plexus.

*Posteriorly*,—it is in relation with the—

Œsophagus.

Right Recurrent Laryngeal Nerve.



*Laterally*,—with the—

Common Carotid Arteries.

Thyroid Gland.

Inferior Thyroid Arteries.

Recurrent Laryngeal Nerves.

Pleuræ.

Pneumogastric Nerves.

**Describe the Bronchi.** They are two tubes similar in formation to the trachea, extending from its bifurcation into the lungs, where they divide and subdivide into bronchial tubes, losing their rings at the 2d or 3d subdivision, whence plates of cartilage extend in their walls to their minuter ramifications. The—

*Right Bronchus*,—is the widest, and the most horizontal, about 1 inch long, has 6 to 8 rings, and divides into 2 main divisions (though its lung has 3 lobes).

*Left Bronchus*,—is the narrowest and most oblique, nearly 2 inches long, has 9 to 12 rings, and divides into 3 main divisions (though its lung has 2 lobes).

**What are the Relations of the Bronchi?** Beginning opposite the 3d dorsal vertebra, the right bronchus enters the lung opposite the 4th dorsal vertebra, the left bronchus opposite the 5th. *The Right Bronchus* lies behind the vena cava superior and the right auricle of the heart, having the right pulmonary artery at first below, then anterior to it, and the vena azygos major arching over it from behind forwards. *The Left Bronchus* passes beneath the arch of the aorta and in front of its descending portion, also in front of the œsophagus and the thoracic duct, having the left pulmonary artery above and in front of it.

**Name the Vessels and Nerves of the Trachea and Bronchi.**

*Arteries*,—Tracheal Branches of the inferior thyroid (br. of thyroid axis), and the Bronchial (brs. of thoracic aorta).

*Veins*,—open into the thyroid plexus and the bronchial veins.

*Lymphatics*,—terminate in the mediastinal glands.

*Nerves*,—are derived from the pneumogastric and its recurrent laryngeal branch, also from the sympathetic.

## THE LUNGS.

**Describe the Lungs.** The lungs are the two essential organs of respiration, contained in the cavity of the thorax, covered by the pleuræ, and characterized by lightness (sp. gr. 0.345 to 0.746), sponginess, elasticity, and crepitation when pressed. They weigh together about 42 ounces, the right lung being the heaviest by about 2 ounces. At birth their color is a pinkish-white, mottled as age advances by slate colored patches, from the deposit of carbonaceous granules in the areolar tissue of the organ. *The Right Lung* is the largest and has 3 lobes; the *Left Lung* has 2 lobes. Each lung presents for examination an—

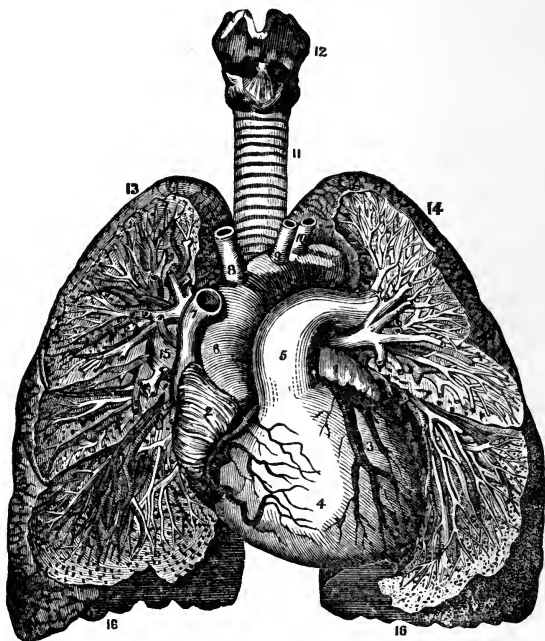
*Apex,*<sup>13</sup>—projecting into the neck about an inch above the 1st rib, where it is in relation with the subclavian artery and the scaleni muscles.

*Base,*<sup>16</sup>—is broad, concave, and directed obliquely downwards and backwards, resting on the upper convex surface of the diaphragm.

*External Surface,*—is convex, smooth, marked by the fissures, and corresponds in form to that of the thorax.

*Inner Surface,*—is concave, the left lung excavated for the heart, the surface forming part of the walls of the middle mediastinum.

FIG. 84.



*Root,*—is where the bronchi, vessels, and nerves enter the lung, bound together by areolar tissue. In front of the root is the phrenic nerve, behind it the pneumogastric nerve. Its chief structures are arranged in the following manner:—

From before, backwards.  $\left. \begin{array}{l} \text{Pulmonary veins.} \\ \text{Pulmonary artery.}^5 \\ \text{Bronchus, etc.} \end{array} \right\} \text{V. A. B.}$


From above, downwards, on right side of body.	<table> <tr> <td>Bronchus, etc.</td> <td rowspan="3">} B. A. V.</td> </tr> <tr> <td>Pulmonary artery.</td> </tr> <tr> <td>Pulmonary veins.</td> </tr> </table>	Bronchus, etc.	} B. A. V.	Pulmonary artery.	Pulmonary veins.
Bronchus, etc.	} B. A. V.				
Pulmonary artery.					
Pulmonary veins.					
From above, downwards, on left side of body.	<table> <tr> <td>Pulmonary artery.</td> <td rowspan="3">} A. B. V.</td> </tr> <tr> <td>Bronchus, etc.</td> </tr> <tr> <td>Pulmonary veins.</td> </tr> </table>	Pulmonary artery.	} A. B. V.	Bronchus, etc.	Pulmonary veins.
Pulmonary artery.	} A. B. V.				
Bronchus, etc.					
Pulmonary veins.					

**Describe the Structure of the Lung.** The lung has a serous coat (the pleura); a sub-serous, elastic areolar tissue, investing the entire organ, and extending inwards between the lobules; and the parenchyma, or true lung-tissue, composed of—

FIG. 85.

*Lobules*,—each consisting of several air-cells or compartments, arranged around the termination of a bronchiole, and surrounded by 6 plexuses of pulmonary and bronchial arteries and veins, lymphatics and nerves. Each lobule is a miniature lung, pyramidal in form, with base outwards, and about  $\frac{1}{2}$  inch in diameter.

*Alveoli, or Air-cells*,—are separated from each other by thin septa, are lined with pavement epithelium on a basement membrane, and vary in diameter from  $\frac{1}{200}$  to  $\frac{1}{70}$  inch. [See Fig. 85.]



**Name the Vessels and Nerves of the Lungs.** The lungs are nourished by the bronchial arteries, and supplied with blood for oxygenation by the pulmonary arteries.

*Bronchial Arteries*,—are derived from the thoracic aorta.

*Pulmonary Arteries*,—are derived from the right heart.

*Bronchial Veins*,—open on the right side into the vena azygos, on the left side into the superior intercostal vein.

*Pulmonary Veins*,—open by 4 large orifices into the left auricle of the heart, carrying oxygenated blood from the lungs to the heart.

*Lymphatics*,—terminate in the bronchial glands.

*Nerves*,—are branches from the pneumogastric and the sympathetic, forming the Anterior and Posterior Pulmonary Plexuses, from which filaments are distributed to each lobule.

## THE PLEURÆ.

**What are the Pleuræ?** Two delicate serous sacs, one surrounding each lung and reflected over the pericardium, the diaphragm, and the inner surface of the thorax.

**Where do the Pleuræ meet?** For a short space behind the middle of the sternum, at the approximation of the anterior borders of the lungs.

**What Names are given to the parts of the Pleuræ?** The—  
*Pleura Pulmonalis, or Visceral Layer*,—covers the lung, and invests that organ as far as its root.

*Pleura Costalis, or Parietal Layer*,—lines the inner surface of the parietes of the chest.

*Cavity of the Pleura*,—is the space between the two layers.

**What is the Ligamentum Latum Pulmonis?** The Broad Ligament of the Lung is a triangular fold or reflection of pleura, which descends from the root of the lung posteriorly to the upper surface of the diaphragm.

**State the Differences between the Pleuræ.** The right sac is shorter, wider, and reaches higher into the neck than the left.

**Enumerate the Parts in Relation with the Left Pleura.** Its—  
*Visceral Layer*,—is in contact with the left lung.

*Parietal Layer*,—is in relation with the vertebral column, the ribs, intercostal muscles and vessels, the sternum, the left sympathetic nerve, the diaphragm, the arched portion of the subclavian artery, and the origin of the left carotid, the left pneumogastric, phrenic and cardiac nerves, the trachea, œsophagus, aorta and the pericardium.

**What is the Mediastinum?** It is the space between the two pleuræ in the median line of the thorax, extending from the sternum to the vertebral column, and containing all the thoracic viscera except the lungs.

**Enumerate the Contents of each of its Divisions.** The—  
*Anterior Mediastinum*, contains the—

Origins of the Sterno-hyoid and Sterno-thyroid Muscles.	
Triangularis Sterni Muscle.	Thymus Gland.
Left Internal Mammary Vessels.	Lymphatics.

*Middle Mediastinum*, contains the—

Heart and Pericardium.	Bifurcation of the Trachea.
Ascending Aorta.	Pulmonary Arteries and Veins.
Superior Vena Cava.	Phrenic Nerves.

*Posterior Mediastinum*, contains the—

Descending Aorta.	Pneumogastric Nerves.
Azygos Veins.	Splanchnic Nerves.
Superior Intercostal Veins.	Thoracic Duct.
Œsophagus.	Lymphatic Glands.

## THE URINARY ORGANS.

## THE KIDNEYS.

**Where are the Kidneys situated?** Posteriorly in the abdomen, one on each side of the spinal column, behind the peritoneum, and extending from the level of the 11th rib to near the crest of the ileum. The right kidney is lower than the left.

**State their Dimensions.** Each one is about 4 inches by 2 by 1, and weighs from 4 to 6 oz.

**Enumerate their Relations.** The—

*Anterior Surface of the Right Kidney*,—is in relation with the right lobe of the liver, descending duodenum, and the ascending colon.

*Anterior Surface of the Left Kidney*,—with the tail of the pancreas, descending colon, and part of the spleen.

*Posterior Surface*,—with the crus of the diaphragm, 11th and 12th ribs, psoas magnus, quadratus lumborum, and the aponeurosis of the transversalis muscle.

*Superior Extremity*,—is capped by the supra-renal capsule.

**Describe the Hilum of the Kidney.** The *Hilum* is a fissure on the inner or concave border, leading into the *Sinus* or cavity of the gland. It contains the—

*Renal Vein*,—in front.

*Renal Artery*,—next in order.

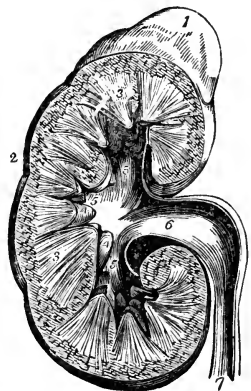
*Ureter*, or Excretory Duct,—behind and below.

**Describe the Kidney-structure.** A vertical section presents the—  
*Pelvis or Sinus*,<sup>6</sup>—the cavity, forming the beginning of the ureter<sup>7</sup> or excretory duct of the gland. Its divisions are the 3 *Infundibula*<sup>5</sup>, and these are again divided into *Calices*<sup>4</sup> or pouches, into which open the orifices of the pyramids, 1000 orifices situated on each *Papilla*.

*Medullary Substance*,<sup>3</sup>—consists chiefly of the tubes of Bellini and Henle, arranged in *Pyramids of Malpighi*, whose apices project into the calices of the pelvis.

*Cortical Substance*,<sup>2</sup>—forms the surface of the gland, and consists of uriniferous tubules (straight and convoluted), Malpighian bodies, blood-vessels, nerves, lymphatics, connective tissue, and a granular matrix. It is of a red color, and is prolonged down to the pelvis between the pyramids, these prolongations being named the *Columns of Bertin*.

FIG. 86.



**Describe the Tubuli Uriniferi.** The uriniferous tubes begin at the Malpighian corpuscles in the Capsules of Müller, and end at the orifices on the surfaces of the papillæ. Their various portions are the—

*Convolutud Tubes of Ferrein*,—in the cortical substance.

*Looped Tubes of Henle*,—descending from the former and ascending into the next mentioned.

*Straight Tubes of Bellini*,—in the medullary substance, arranged in pyramids, the *Pyramids of Malpighi*.

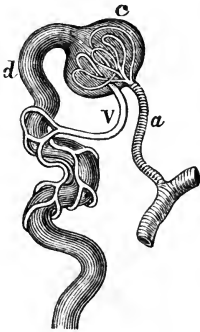
**What are the Pyramids of Ferrein?** They are pyramidal arrangements of the tubes of Ferrein at the bases of the pyramids of Malpighi.

**What are the Malpighian Bodies?** They are small red bodies found in the cortical substance, each formed by the dilated extremity of a tube of Ferrein, about the  $\frac{1}{20}$  inch in diameter, and consisting of the—

*Malpighian Tuft*,—a tuft of capillary vessels, the termination of some branches of the renal artery *a* and vein *v*.

*Capsule of Müller*, *c*—the dilated extremity of a tube of Ferrein, *d* investing the Malpighian tuft probably by two layers, similar to the pleural investment of the lungs.

FIG. 87.



**How is the Kidney invested?** By a dense fibrous Capsule, which is continued inwards at the hilum, to line the sides of the sinus and form sheaths around the vessels. The kidney is also surrounded by a large quantity of fat.

**Enumerate the various Divisions of the Renal Vessels.** They are all derived from the Renal Artery and the Renal Vein, but in their course have received different names, as follows, viz.—

*Renal Artery*,—branch of the abdominal aorta. Divides into the—  
*Primary Branches*, 4 or 5,—arising just external to the hilum, again subdivide and enter in the columns of Bertin as the *Arteriæ Propriæ Renales*, which form—

*Arterial Arches*,—over the bases of the pyramids, and divide into ascending and descending branches.

*Interlobular Arteries*, or *Ascending Branches*,—supply the cortical substance, and end in the Stars of Verheyen. (See next page.)

*Arteriolæ Rectæ*, or *Descending Branches*,—supply the medullary pyramids, ending in venous plexuses therein.

*Afferent Vessels*,—to the Malpighian bodies, from the ascending branches.

*Malpighian Tufts*,—are capillary plexuses within the Malpighian bodies.

From them arise the—

*Efferent Vessels*,—whether arterial or venous, is undecided. They form

*Venous Plexuses*,—on the convoluted uriniferous tubes.

*Stars of Verheyen*,—are venous plexuses of stellate form, situated on the surface of the kidney, beneath its capsule, joining to form the—

*Interlobular Veins*,—from the cortical portion; which with the

*Venæ Rectæ*,—from the medullary pyramids, making

*Venous Arches*,—over the bases of the pyramids, finally meet in the—

*Venæ Propriæ Renales*,—and they end in the

*Renal Vein*,—which empties into the inferior vena cava.

**Whence are the Nerves of the Kidney derived?** From the Renal Plexus, which is formed by filaments from the solar plexus and the lesser splanchnic nerve.

### THE URETERS.

**What is the Ureter?** The excretory duct of the kidney, forming, by its upper expanded portion, the cavity of that gland. It is a musculo-membranous tube, 16 to 18 inches long, as large as a small goose-quill; and ends at the base of the bladder, into which it opens obliquely by a constricted orifice, about 2 inches from the orifice of its fellow. The ureter commences in the—

*Calices*,—7 to 13 small tubes, embracing the papillæ of the kidney, and joining to form the—

*Infundibula*,—3 or 4 in number, which unite in the—

*Pelvis*,—a funnel-shaped dilatation of the upper portion of the ureter.

**Describe its Course.** It descends obliquely inwards along the posterior wall of the abdomen, enters the posterior false ligament of the bladder in the male, and that of the uterus in the female, through which it passes forwards and inwards to the posterior angle of the trigone vesicæ, lying between the muscular and mucous coats of the bladder, for about three-fourths of an inch.

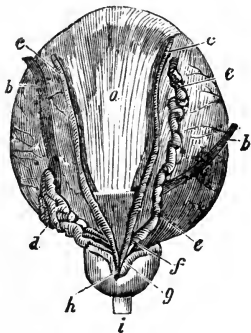
**What are its Relations?** It lies upon the psoas muscle, behind the peritoneum and below the spermatic vessels, over the common iliac or the external iliac artery, behind the ileum on the right side, behind the sigmoid flexure on the left. The right ureter lies close to the outer side of the inferior vena cava.

**Describe its Structure.** The ureter has 3 coats—a fibrous, a muscular, and a mucous; the epithelium of the mucous coat is different from that of the urethra, the bladder, or the uriniferous tubes, being spheroidal in shape.

## THE BLADDER.

**What is the Bladder?** It is the urinary reservoir, a musculo-membranous sac, situated in the anterior portion of the pelvis, behind the pubes. When moderately distended it measures about 5 by 3 inches, and holds about a pint. Its—

FIG. 88.



*Summit*,—is connected to the umbilicus by the *Urachus* and the obliterated Hypogastric Arteries of the fœtus, forming three fibrous cords, the Superior Ligament of the bladder.

*Body*,—is in relation in front with the triangular ligament, the symphysis pubis, and the internal obturator muscles,—behind it is covered by peritoneum, and is in relation with the rectum in the male, with the uterus and upper part of the vagina in the female. Each side is crossed obliquely by the obliterated hypogastric artery and the vas deferens, the first passing from below forwards, the latter from below backwards.

*Fundus or Base*,—rests on the second portion of the rectum in the male, on the lower part of the cervix uteri and adherent to the anterior wall of the vagina in the female. It is partly covered by peritoneum.

*Cervix or Neck*,—is constricted and continuous with the urethra.<sup>i</sup> It is surrounded in the male by the prostate gland,<sup>h</sup> and is directed downwards and forwards.

**Name the Ligaments of the Bladder.** They number 10, of which 5 are true ligaments, and 5 are false, the latter being folds of peritoneum. They are named as follows,—

*True Ligaments.*

2 Anterior (pubo-prostatic).

2 Lateral.

Superior (the Urachus, etc.).

*False Ligaments.*

2 Posterior.

2 Lateral.

Superior.

**What is the Urachus?** It is the obliterated remains of a canal, which in the embryo connects the bladder with the allantois. It is situated between the two obliterated hypogastric arteries, and with them forms the superior ligament of the bladder, connecting the summit of that organ with the umbilicus.

**What is the Trigonum Vesicæ?** (7, Fig. 89.) The Vesical Trigone is a triangular space, of pale color, at the base of the bladder interiorly, characterized by its smooth surface and the intimate adhesion between its mucous and muscular coats. Its boundaries are—



*In Front*,—the urethral opening.

*Posteriorly*,—a line connecting the orifices<sup>3</sup> of the ureters.

*Laterally*,—two ridges of mucous membrane, which extend from the urethral orifice back to the orifices of the ureters.

**What is the Uvula Vesicæ?** (4, Fig. 89.) A small elevation of mucous membrane projecting from the floor of the bladder into the urethral orifice. It is said to be lifted by the anterior fibres of the levator ani muscle.

**Describe the Structure of the Bladder.** It has a partial peritoneal investment, and its walls are composed of 3 coats,—a muscular, a cellular, and a mucous. The—

*Muscular Coat*,—consists of 5 sets of fibres, as follows,—

External and Internal Longitudinal fibres.

Intermediate Circular fibres, forming a *Sphincter Vesicæ* at the neck of the bladder.

Transverse fibres, connecting the orifices of the ureters.

Muscles of the Ureters, connecting their orifices with the middle lobe of the prostate gland.

*Cellular Coat*,—connects the other two coats together, and is closely attached to the mucous coat.

*Mucous Coat*,—is covered with epithelium intermediate in form between the columnar and the squamous; is loosely connected to the muscular coat, except at the trigone vesicale and the uvula vesicæ, where it is closely adherent.

**What Nerves supply the Bladder?** Branches from the hypogastric plexus supply its upper part,—from the sacral plexus its base and neck.

#### THE MALE URETHRA.

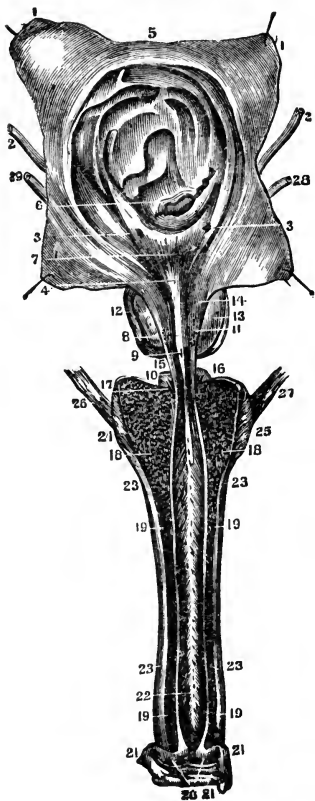
**What is the Urethra?** It is the urinary canal from the neck of the bladder to the meatus urinarius; in the male it is chiefly within the penis, and from 8 to 9 inches in length.

**Enumerate its Divisions.** The male urethra is divided into 3 parts,—the prostatic, membranous and spongy.

**Describe the Prostatic portion of the Urethra.**<sup>14</sup> It is that part of the canal which pierces the prostate gland,<sup>12</sup> is about  $1\frac{1}{4}$  inch in length, of spindle-shape, and is the widest and most dilatable part of the urethra. Its floor presents the—

*Veru Montanum, or Caput Gallinaginis*,<sup>8</sup>—an elevation of the mucous membrane and its adjacent tissue,  $\frac{3}{4}$  inch long, and supposed to contain muscular and erectile tissue.

FIG. 89.



*Prostatic Sinus*,<sup>11</sup>—one on each side of the veru montanum, containing the orifices of the prostatic ducts.

*Sinus Pocularis, or Uterus Masculinus*,<sup>9</sup>—a small cul-de-sac situated at the front part of the veru montanum. It extends for  $\frac{1}{4}$  inch upwards and backwards into the prostate gland, beneath its middle lobe.

*Orifices of the Seminal Ducts*,—open on the margins of the sinus pocularis.

Describe the **Membranous portion of the Urethra**.<sup>15</sup> It is  $\frac{3}{4}$  inch long above, and  $\frac{1}{2}$  inch along its floor, being that part of the canal lying between the layers of the triangular ligament of the perineum. Its walls are very thin, and almost destitute of erectile tissue. It is surrounded by the compressor urethrae muscle, and except the orifice, is the narrowest part of the urethral canal. On its sides are the—

*Ducts of Cowper's Glands*,<sup>16</sup>—on their way to open into the bulb of the urethra. (See p. 182.)

Describe the **Spongy portion of the Urethra**. It is about 6 inches long, and has two dilatations, one at each end, named respectively the Bulb and the Fossa Navicularis. The—

*Bulb of the Urethra*,<sup>18</sup>—is the upper end of the spongy portion, projects backwards for  $\frac{1}{4}$  inch, and contains the orifices of Cowper's glands.

*Fossa Navicularis*,—is the lower dilatation of the urethra, and is situated within the glans penis.

*Lacuna Magna*,—the largest of several orifices of mucous follicles, situated on the roof of the fossa navicularis.

*Glands of Littre*,—are numerous mucous glands and follicles, opening into the urethral canal, their orifices being directed forwards.

**Describe the Structure of the Urethra.** It has 3 coats, a mucous, a muscular, and an erectile. The—

*Mucous Coat*,—is continuous with that of the whole urinary tract and the ducts of the glands opening therein. Its epithelium is columnar, except in the fossa navicularis, where it is squamous.

*Muscular Coat*,—consists of a layer of longitudinal fibres of the unstriped variety. [For the voluntary muscles of the urethra, see the Compressor Urethræ and Accelerator Urinæ, page 84.]

*Erectile Coat*,—is the corpus spongiosum of the penis, and a thin layer continued therefrom around the membranous and prostatic portions.

#### THE FEMALE URETHRA.

**Enumerate the Characteristics of the Female Urethra.** It is about  $1\frac{1}{2}$  inch long, imbedded in the anterior wall of the vagina, perforating the triangular ligament, and surrounded by the fibres of a compressor urethræ muscle. Its diameter is about  $\frac{1}{4}$  inch, but it is capable of considerable dilatation, being surrounded by softer structures than those around the male urethra.

### THE MALE GENERATIVE ORGANS.

#### THE URETHRAL GLANDS.

**Where is the Prostate Gland?** It encircles the neck of the male bladder, its apex touching the deep perineal fascia, its under surface resting on the rectum. It is perforated by the urethra and the common seminal ducts, and its ducts open into the prostatic portion of the urethra.

**State its Dimensions and Characteristics.** It measures about  $1\frac{1}{2}$  inch by 1 inch by  $\frac{3}{4}$  inch, weighs about  $\frac{3}{4}$  oz., resembles a horse-chestnut in size and shape, and consists of three lobes, two being lateral and of equal size, the third or middle lobe being a small prominence situated in the notch between the lateral lobes.

**Describe its Structure.** The prostate gland is composed of glandular substance and muscular tissue, inclosed in a fibrous capsule.

**How is it Held in Position?** By the pubo-prostatic ligaments of the bladder, the posterior layer of the deep perineal fascia, and by the anterior portion of the levator-ani muscle.

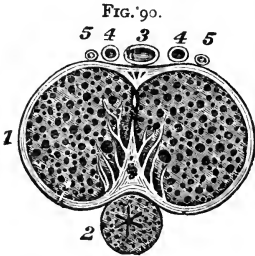
**Where are Cowper's Glands?** They are situated between the two layers of the deep perineal fascia, one on each side of the membranous portion of the urethra, close behind the bulb, and inclosed by the transverse fibres of the compressor urethræ muscle.

**Where do their Ducts open?** On the floor of the bulbous part of the spongy portion of the urethra, after traversing the wall of the urethra for about one inch, between its mucous and muscular coats.

## THE PENIS.

**Of what is the Penis composed?** Of a mass of erectile tissue arranged in three compartments of cylindrical shape, each surrounded by a fibrous sheath which is prolonged inwards, forming numerous bands (trabeculæ), which divide the compartment into a number of spaces. The compartments are named the Corpora Caverosa<sup>1</sup> and the Corpus Spongiosum,<sup>2</sup> the latter lying between and beneath the former, like the ramrod of a double-barreled gun.

**Describe the Corpora Caverosa.** (<sup>19</sup>, Fig. 89.) They lie side by side, forming the upper and lateral parts of the penis, are joined together along their anterior three-fourths, their posterior one-fourth forming the *Crura*, which arise from the tuberosities of the ischia and their descending rami, and meet beneath the symphysis pubis, forming two grooves, one above for the dorsal vessels<sup>3</sup>,<sup>4</sup> and nerves,<sup>5</sup> the inferior one for the corpus spongiosum.<sup>2</sup>



*Bulb of the Corpus Caverosum*,—is a slight enlargement on each crus, near its junction with its fellow.

*Suspensory Ligament*,—a fibrous membrane which connects the root of the organ to the symphysis pubis.

*Septum Pectiniforme*,—is a portion of the fibrous septum between the corpora cavernosa. This septum extends but two-thirds along the penis, and is wanting for its anterior third.

**Describe the Corpus Spongiosum.** It is an erectile tube lying in the inferior groove between the two corpora cavernosa, having within it the urethra, and being expanded at both ends to form the glans penis and the bulb. It is composed of trabecular (band-like) structure, derived from a fibrous sheath, and containing erectile tissue. The—

*Bulb of the Corpus Spongiosum*,—receives the urethra and is surrounded by the accelerator urinæ muscle.

*Glans Penis*,—is the external expansion of the corpus spongiosum, and covers by its base the ends of the two corpora cavernosa. Its base presents a rounded border, called the *Corona Glandis*, behind which is a deep sulcus, the *Cervix*.

*Meatus Urinarius*,—the external orifice of the urethra, is situated at the summit of the glans penis.

*Prepuce*,—a prolongation of the integument of the penis, covering or partly covering the glans penis.

*Frenum Preputii*,—a fold of mucous membrane lying along the raphé of the glans penis, and connecting the prepuce thereto.

*Glands of Tyson*,—small lenticular sebaceous glands opening on the corona and cervix of the glans, and secreting an odorous sebaceous matter, which is easily decomposed.

**Of what does Erectile Tissue consist?** Of an intricate venous plexus, supplied by afferent arteries and emptied by efferent veins. Such are the essential features of the erectile tissue of the penis, which is lodged in the interspaces between the trabeculæ of the fibrous structure.

**What are the Helicine Arteries?** They are peculiar vine-like arterial branches, which project in a convoluted manner into the venous plexuses in the posterior portion of the penis.

**Enumerate the Vessels and Nerves of the Penis.** Its—

*Arteries*,—are derived from the internal pudic, and are the—

Artery of the Bulb,—to the corpus spongiosum.

Artery of the Corpus Cavernosum,—to that structure.

Dorsal Artery of the Penis,—to the glans, prepuce and skin.

*Veins*,—empty into the Dorsal Vein of the Penis, the prostatic plexus and the pudic vein. The venous plexuses of the erectile tissue are very intricate, and remarkably developed.

*Lymphatics*,—the superficial terminate in the inguinal glands; the deep set joins the deep lymphatics of the pelvis.

*Nerves*,—are derived from the internal pudic nerve, and the hypogastric plexus of the sympathetic.

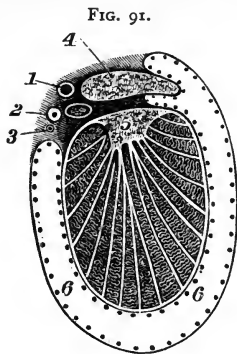
## THE TESTES AND THEIR APPENDAGES.

**What are the Testes?** The Testes or Testicles are the glandular organs which secrete the seminal fluid,—two oval bodies suspended obliquely in the scrotum by the spermatic cords, each measuring about an inch in diameter, and weighing  $\frac{3}{4}$  oz. to an ounce.

**What is the Scrotum?** A cutaneous pouch, consisting of 2 layers—the integument and the *Dartos*,—the latter being a contractile vascular tunic, continuous with the superficial fascia of the thighs and perineum, and forming a septum in the scrotum between the two cavities for the testes.

**Describe the Essential Coats of the Testis.** They are 3 in number, as follows, viz. : the—

*Tunica Vaginalis*, the Serous Covering,—having a visceral layer (*tunica vaginalis propria*) and a parietal layer (*tunica vaginalis reflexa*). It was originally derived from the peritoneum, and the upper part being obliterated, it remained a closed sac. (See <sup>6</sup> Fig. 91.)



*Tunica Albuginea*, the Fibrous Covering,—formed of white fibrous tissue, and forming an incomplete vertical septum within the gland, the *Corpus Highmorianum* or *Mediastinum Testis*,<sup>5</sup> from which fibrous bands (*trabeculae*) cross the gland, dividing its interior into spaces for the lobules of the organ.

*Tunica Vasculosa*, the Pia Mater Testis,—is the vascular tunic, lying beneath the tunica albuginea, and giving off numerous processes between the lobules.

**Name the Coverings of the Testicle.** From without inwards they are 6 in number, as follows, the—

- (1) *Skin*,—of the scrotum, closely adherent to the dartos.
- (2) *Dartos*,—or superficial fascia.
- (3) *External Spermatic Fascia*, *Intercolumnar Fascia*,—derived from the margins of the external abdominal ring.
- (4) *Cremasteric Fascia*,—derived from the lower border of the internal oblique muscle. [Called also the Cremaster Muscle.]
- (5) *Internal Spermatic Fascia*, or *Fascia Propria*,—the infundibuliform process of the transversalis fascia.
- (6) *Tunica Vaginalis*,<sup>6</sup>—originally a process of peritoneum. [Shown by dots in Fig. 91.]

**Describe the Structure of the Testicle.** The glandular structure is composed of small, convoluted tubes, the *Tubuli Seminiferi*,<sup>3</sup> (Fig. 92), which are collected into *Lobules*, about 300 in number, from which straight ducts, the *Vasa Recta*,<sup>4</sup> enter the mediastinum and form an ascending plexus of anastomosing tubes, the *Rete Testis*,<sup>5</sup> which gives off some 12 to 20 ducts, the *Vasa Efferentia*;<sup>6</sup> these perforate the tunica albuginea of the testis, and form a number of conical masses, the *Coni Vasculosi*,<sup>7</sup> which together constitute the *Globus Major*<sup>7</sup> of the Epididymis.<sup>8</sup>

**What is the Epididymis?**<sup>8</sup> It is an appendix to the testicle, lying along its posterior border, and consists of a single duct about 20 feet in length when unraveled, but which is wound upon itself so as to occupy a very small space. The—

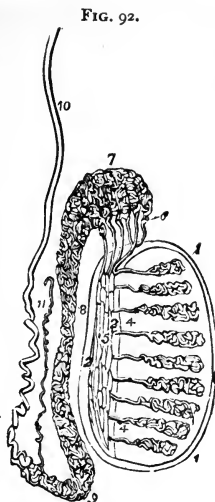
*Globus Major*,<sup>7</sup>—is formed by the coni vasculosi, or efferent ducts of the testis, which therein open into the single duct which forms the epididymis.

*Body*,<sup>8</sup>—is formed by the convolutions of the tube, held together by fine connective tissue, and is the central portion.

*Globus Minor*,<sup>9</sup>—the lower expanded portion, similarly formed, and connected to the testis by fibrous tissue.

*Vasculum Aberrans*,<sup>11</sup>—a narrow tube, sometimes found opening into the canal of the epididymis near its lower end, and ending in a blind extremity.

*Hydatids of Morgagni*,—small pedunculated bodies, found attached to the epididymis or to the upper end of the testicle. One of them is believed to be the remains of the duct of Müller. (See COMPEND OF PHYSIOLOGY, page 131.)



**Describe the Vas Deferens.**<sup>10</sup> It is the continuation of the epididymis, and is the excretory duct of the testicle. Beginning at the globus minor it ascends along the back of the spermatic cord to the external abdominal ring, where it enters the inguinal canal, and penetrates the abdominal cavity through the internal abdominal ring. Descending into the pelvis it passes between the bladder and the rectum, along the inner side of the vesicula seminalis, and at the base of the prostate gland it joins with the duct of the vesicula seminalis to form the ejaculatory duct. The vas deferens is about 2 feet long, and has a canal of only half a line in diameter. Its walls are very dense, making it feel like a piece of wire or whip-cord when grasped between the fingers. (<sup>2</sup> Fig. 91.)

**Name the Arteries of the Testicle.** The *Spermatic Artery*<sup>1</sup> supplies the gland itself; but the coverings of the testicle are supplied by the—

*Superficial External Pudic*, } —branches of the Femoral.  
*Deep External Pudic*, }

*Superficial Perineal*,—br. of the Internal Pudic, from the Int. Iliac.

*Cremasteric*,—branch of the Epigastric, from the External Iliac.

**Name the Nerves of the Testicle.** They are the—

*Ilio-inguinal*, } —branches of the Lumbar Plexus.  
*Ilio-hypogastric*, }

*Superficial Perineal*,—branch of the Internal Pudic nerve.

*Inferior Pudendal*,—branch of the Small Sciatic nerve.

*Genital*,—branch of the Genito-crural nerve.

**Describe the Spermatic Cord.** It extends from the internal abdominal ring to the globus minor of the epididymis, and is about 4 inches long. It consists of the following-named 10 structures, bound together by areolar tissue and invested by its coverings. These structures are the—

*Vas Deferens.* <sup>2</sup> Fig. 91.

*Spermatic Artery.*<sup>1</sup>

*Cremasteric Artery.*

*Artery of the Vas Deferens.*<sup>3</sup>

*Spermatic Veins.*

*Spermatic Plexus of Nerves.*

*Branch of the Ilio-inguinal Nerve.*

*Branch of the Genito-crural Nerve.*

*Vasculum Aberrans.*

*Lymphatics.*

**What is the Pampiniform Plexus?** A venous plexus formed by the spermatic veins and branches from the epididymis. It forms the chief mass of the spermatic cord, and unites into a single trunk, which on the right side empties into the inferior vena cava, on the left side into the left renal vein.

**Describe the Vesiculæ Seminales.** They are two sacculated, membranous pouches, serving as reservoirs for the semen, and are filled by the backing up of that fluid from the vasa deferentia. They are about 2½ inches in length, and are situated between the base of the bladder and the rectum. Their—

*Ejaculatory Ducts*,—one on each side, are formed by the junction of the vasa deferentia with the ducts of the vesiculæ seminales. They are about ¾ inch in length, and terminate in the prostatic portion of the urethra, by orifices on the sides of the veru montanum.

**Describe the Descent of the Testes.** In early foetal life the testes are situated in the abdominal cavity, just below and in front of the kidneys, and are each connected to the dartos of the scrotum and the tissues about the inguinal canal by the 3 processes of a cord named the *Gubernaculum Testis*, which is supposed to gradually shorten itself and draw the testis down. At the beginning of the 5th month the descent begins; during the 7th month the testicle enters the inguinal canal, and ordinarily arrives in the scrotum by the end of the 8th month. A process of peritoneum is supposed to be carried down in front of the testis; which process, by obliteration of the canal, becomes a separate structure, the *Tunica Vaginalis*. The structures of the inguinal canal are also supposed to be brought down with the testicle, and to constitute some of its coverings.



## FEMALE ORGANS OF GENERATION.

## THE VULVA.

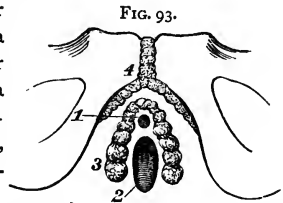
**Enumerate the Organs comprised in the Vulva.** They are the Mons Veneris, the Labia Majora, Labia Minora, Clitoris, Meatus Urinarius, and the Orifice of the Vagina.

**Describe the Labia Majora.** They are two prominent folds formed of skin, mucous membrane, areolar and dartoid tissues;—are joined together at the mons veneris, forming the *Anterior Commissure*, and also in front of the perineum, where they form the *Posterior Commissure*.

**What are the Labia Minora?** The Labia Minora or Nymphæ are two folds of mucous membrane, lost posteriorly in the labia majora, but anteriorly they embrace the clitoris, forming the *Prepuce* of that organ.

**Describe the other Parts comprised in the Vulva.** The—  
*Mons Veneris*,—is the eminence in front of the pubes. It is formed of adipose tissue, and at puberty becomes covered with hair.

*Clitoris*,<sup>4</sup>—is situated beneath the anterior commissure, its *Glans* only appearing as a small rounded tubercle between the anterior extremities of the labia minora. It is a diminutive penis in all but the urethra, having a body, two crura, a glans, prepuce, suspensory ligament and muscles, the *erectores clitoridis*.



*Bulbi Vestibuli*,<sup>3</sup>—are two oblong masses extending from the clitoris along the sides of the vestibule, and consisting of a venous plexus surrounded by a fibrous membrane.

*Pars Intermedia*,—is a small venous plexus situated between the glans clitoridis and the bulbi vestibuli.

*Vestibule*,—is a triangular depression in front of the vaginal orifice, bounded laterally by the labia minora.

*Meatus Urinarius*,<sup>1</sup>—situated in the vestibule, about an inch below the clitoris, and close to the vaginal orifice.

*Orifice of the Vagina*,<sup>2</sup>—is surrounded by the sphincter vaginæ muscle, and in the virgin is sometimes partly closed by the hymen.

*Hymen*,—a fold of mucous membrane situated across the lower part of the vaginal orifice, of various shapes, but usually semilunar, the concavity upwards. It is frequently absent in virgins, and after sexual intercourse its rupture and cicatrization give rise to small eminences along the margin of the vaginal orifice, named the *Caruncula Myrtiliformes*.

*Fourchette*,—a small transverse fold just behind the posterior margin of the vaginal orifice.

*Fossa Navicularis*,—the space between the fourchette and the posterior commissure of the vulva.

*Glands of Bartholine*,—one on each side of the vaginal orifice, their ducts opening on the inner sides of the labia minora. They are the analogues of Cowper's glands in the male.

## THE VAGINA.

**Describe the Vagina.** It is a curved canal extending from the vulva to the uterus, placed between the bladder and the rectum. Its length is about 4 inches along its anterior wall, an inch longer posteriorly, and its walls are usually in contact with each other. It is very dilatable, especially at its upper part.

**Describe its Structure.** The vaginal wall consists of a muscular coat externally, a layer of erectile tissue, and a mucous lining covered with squamous epithelium, and furnished with mucous glands and follicles. The—

*Columns of the Vagina*,—are two longitudinal raphés situated along its mucous surface, connected by numerous transverse ridges, or *Rugæ*.

**What are the Relations of the Vagina?** They are—

*Anteriorly*,—the urethra and the base of the bladder.

*Posteriorly*,—the anterior wall of the rectum, and the recto-uterine fold of peritoneum which forms *Douglas' cul-de-sac* behind its upper fourth.

*Laterally*,—are attached the broad ligaments of the uterus, the levatores ani muscles, and the recto-vesical fascia.

*Superiorly*,—it is attached to the cervix uteri above the os, and higher on the posterior wall than anteriorly.

## THE UTERUS AND ITS APPENDAGES.

**Where is the Uterus situated?** In the pelvic cavity, between the bladder and the rectum, and above the vagina.

**Describe the Uterus.** It is a hollow, pear-shaped, muscular organ, measuring about 3 inches long, 2 inches broad, and 1 inch thick, flattened from before backwards, placed base upwards, and forming an angle with the vagina, which partially receives its cervix. The—

*Fundus, A*,—is broad, convex, having walls  $\frac{5}{8}$  inch thick, and is covered by peritoneum.

*Body*,—is about  $1\frac{3}{8}$  inch long, walls  $\frac{1}{2}$  inch thick, flat anteriorly, convex posteriorly, concave laterally, and joined to the bladder by its lower ante-

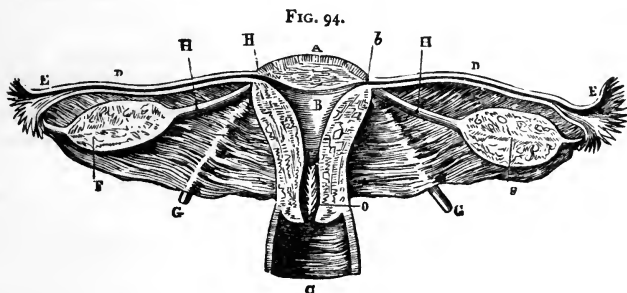
rior fourth. It is invested by peritoneum posteriorly, and in front for its upper three-fourths.

*Cervix, or Neck,*—is the lower constricted portion, about  $1\frac{3}{8}$  inch long, walls  $\frac{1}{4}$  inch in thickness, and is embraced for  $\frac{1}{2}$  to  $\frac{3}{4}$  inch by the upper extremity of the vagina.

*Cavity of the Body,* *B*—is small and triangular, flattened from before backwards, about  $1\frac{1}{8}$  inch in length, and has two lateral *Cornua* above, and a constricted orifice—the *Os Internum Uteri*—at its lower angle, opening into the cavity of the cervix.

*Cavity of the Cervix,*—is spindle-shaped, about  $1\frac{3}{8}$  inch long, and presents on its inner surface transverse folds of mucous membrane proceeding from a longitudinal fold, giving an appearance named the *Arbor Vitæ*.

*Os Uteri or Os Tinæ,*—is a transverse orifice at the lower end of the cervical cavity, opening into the vagina, and having an anterior and a posterior lip.



**Enumerate the Ligaments of the Uterus.** The proper ligaments of the uterus are 6 in number,—2 Anterior, or *Utero-vesico-pubic*, 2 Posterior, or *Utero-recto-sacral*, and 2 Lateral, or *Broad Ligaments*, all composed of peritoneum. The—

*Broad Ligaments,*—pass from the sides of the uterus to the lateral walls of the pelvis, and form a septum across the pelvic cavity. They contain, between the two folds of peritoneum of which they are composed, the Fallopian tubes, the Ovaries, and the so-called Round Ligaments.

**What are the Round Ligaments of the Uterus?** They are two cords, composed of areolar and fibrous tissue, muscular fibres, vessels and nerves, extending one on each side, from the lateral aspects of the fundus uteri, through the inguinal canals, to the labia majora, where they are lost. Each ligament lies, for a part of its course, between the two layers of the broad ligament, and is covered by a process of peritoneum. (*G* Fig. 94.)

*Canal of Nuck*,—is the extension of the above-named process of peritoneum into the inguinal canal. It exists in the fœtus, and is usually obliterated in the adult.

**Describe the Uterine Structure.** The uterine wall has 3 coats—peritoneal, muscular and mucous. Its—

*Peritoneal or Serous Coat*,—invests the body of the organ, excepting on its lower anterior fourth.

*Muscular Coat*,—constitutes the chief bulk of the uterus. It consists of bundles of unstriped muscular fibres, disposed in 3 layers interlaced together; circular fibres predominating in the cervix, longitudinal fibres in the body of the organ.

*Mucous Coat*,—is very thick,  $\frac{1}{2}$  to  $\frac{1}{8}$  inch, and closely adherent to the muscular tissue, having no basement layer of connective tissue. It is covered with ciliated columnar epithelium, and studded with mucous follicles and glands, which are most numerous in the cervix. The latter, when distended by their own secretions, form sacs, which Naboth mistook for human ova, and hence were named the *Ovules of Naboth*.

**Enumerate the Uterine Vessels and Nerves.** Its—

*Arteries*,—are the Uterine, from the anterior trunk of the external iliac, anastomosing with twigs from the Ovarian—(spermatic branch of the abdominal aorta).

*Veins*,—accompany the arteries, and in the impregnated state become sinuses. They end in the uterine plexuses.

*Lymphatics*,—those of the cervix end in the sacral and internal iliac glands, those of the fundus in the lumbar glands.

*Nerves*,—are derived from the inferior hypogastric and ovarian plexuses, and from the 3d and 4th sacral nerves.

**Describe the Fallopian Tubes or Oviducts.** They are two tubes, each about 5 inches in length, and  $\frac{1}{16}$  inch in calibre, situated in the free margin of the broad ligament, and extending from the superior angles of the uterus <sup>b</sup> outwards, to terminate in free, trumpet-shaped ends, the *Fimbriated Extremities*,<sup>E</sup> surrounded by fringe-like processes, the *Fimbriae*, of which one or more are attached to the ovary of that side. Their structure is similar to that of the uterus, their mucous lining being continuous with the uterine mucous membrane and with the peritoneum. They open by one end into the uterus at its cornua, by the other end into the peritoneal cavity.

**What are the Ovaries?** Two oval bodies,<sup>F</sup> of whitish color, situated in the broad ligament, behind and below the Fallopian tubes, one on each side of the uterus, to which they are attached by the *Ligaments of the Ovaries*.<sup>H</sup>

They each measure about  $1\frac{1}{2}$  inch by  $\frac{3}{4}$  by  $\frac{1}{3}$ , and are invested by peritoneum, except posteriorly.

**Describe the Structure of the Ovaries.** They are composed of a vascular stroma containing the *Graafian Vesicles* or *Ovisacs*, in various stages of development, and are surrounded by a dense fibrous coat, the *Tunica Albuginea*.

**Describe the Graafian Vesicles.** They are the ovisacs containing the human ova, are very numerous (about 70,000 in each ovary), vary in diameter from  $\frac{1}{80}$  to  $\frac{1}{60}$  inch, but after puberty a few are found of from  $\frac{1}{20}$  to  $\frac{1}{8}$  inch or more. Each vesicle presents an—

*External Coat*,—of fibro-vascular structure.

*Ovi-capsule*,—or internal coat.

*Membrana Granulosa*,—a layer of nucleated cells, which at one point are heaped up around the ovum in a mature vesicle, forming the *Discus Pro-ligerus*.

*Fluid*,—of transparent, albuminous character, containing the ovum in immature vesicles.

**What is the Ovum?** It is a spherical mass of protoplasm, about  $\frac{1}{120}$  inch in diameter when fully developed. It presents a—

*Vitelline Membrane*,—also called the *Zona Pellucida*,—a colorless envelope, in which is contained the—

*Vitellus* or *Yolk*,—composed of granules in a fluid substance, one of which is called the—

*Germinal Vesicle*,—which contains a smaller body named the *Germinal Spot*, measuring about the  $\frac{1}{3000}$  of an inch in diameter.

**What is the Corpus Luteum?** It is a puckered yellow spot in the substance of the ovary, produced as a result of the rupture of a Graafian vesicle and the discharge of an ovum, probably by the fatty degeneration of the extravasated blood. The—

*True Corpus Luteum*,—is that of pregnancy, and may increase in size, not disappearing until full term.

*False Corpus Luteum*,—occurs when impregnation has not taken place, and is absorbed in about three months.

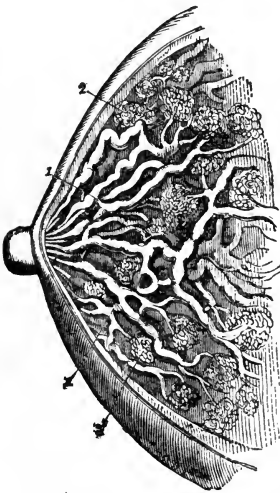
**What is the Pampiniform Plexus?** A venous plexus near the ovary, formed by the veins of that organ.

**Enumerate the Arteries and Nerves of the Ovaries.** Their—  
*Arteries*,—are the Ovarian (or Spermatic), from the aorta, which also supply the Fallopian tubes, anastomosing with the uterine arteries.  
*Nerves*,—are derived from the Spermatic plexus.

**What is the Parovarium?** The Parovarium, or *Organ of Rosenmüller*, is a group of tubules, situated in the broad ligament, between the ovary and the Fallopian tube, and converging to a large duct, the *Duct of Gärtner*, which ramifies in the broad ligament, and descends along the side of the uterus. It is thought to be a remnant of the Wolffian Body of foetal life. (See "Reproduction," in COMPEND OF PHYSIOLOGY.)

### THE MAMMÆ.

**Describe the Mammæ.** The breasts are two hemispherical eminences, situated one on each latero-anterior aspect of the chest, extending from the sternum to the axilla, and from the 3d rib to the 7th. Each breast contains the *Mammary Gland* and is surmounted by the *Nipple*, around the base of which is a zone of colored cutaneous tissue, the *Areola*, pink in virgins, darker in women who have borne children. In the male the mammæ are rudimentary organs, but capable of development under special circumstances.



**Describe the Structure of the Mammary Gland.** It is a compound conglomerate gland, composed of 15 or 20 lobes and their ducts,<sup>1</sup> with a packing of areolar and adipose tissue, and enveloped by a fibrous capsule which forms septa between the lobes. Each lobe is made up of lobules,<sup>2</sup> and these again are formed by the aggregation of the *Acini* or terminal vesicles, in which the milk is secreted. The—

*Tubuli Lactiferi* or *Tubuli Galactophori*,<sup>1</sup>—are the excretory ducts of the lobes, one for each. They are formed by the junction of the ducts from each lobule, and converge towards the areola, beneath which they form *Ampulle* or dilatations, and thence, piercing the nipple, open on its summit by separate orifices.

**What is the Circulus Venosus?** An anastomotic venous circle around the base of the nipple, from which larger veins run outwards and terminate in the axillary and internal mammary veins.

**Name the Arteries of the Mammæ.** They are derived from the Thoracic Branches of the axillary, the Intercostals, and the Internal Mammary arteries.

THE ORGANS OF SENSE.

THE SKIN AND ITS APPENDAGES.

Name the Divisions of the Skin. It is divided into the—

<i>Epidermis, or Cuticle,</i>	{	<i>Superficial</i> Epithelial layers. <i>Rete Mucosum</i> , the pigmentary layers.
<i>Derma, or Cutis Vera,</i> the True Skin.	{	<i>Papillary Layer,</i> <sup>c</sup> next below the rete, from which it is separated by a homogeneous basement membrane. <i>Corium,</i> <sup>d</sup> the deepest portion.

What Structures lie in and beneath the Skin? The *Sensitive Papillæ*, containing the *Tactile Corpuscles* in very sensitive parts,—in the papillary layer of the Derma.

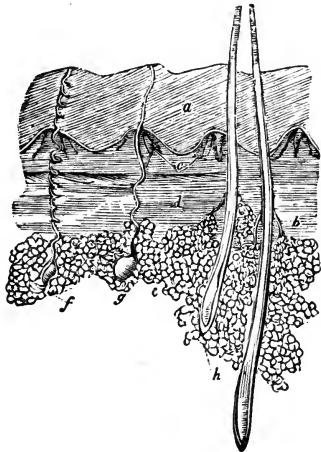
<i>Sweat-glands,</i> <sup>f, g.</sup>	<i>Hair-roots,</i> <sup>h</sup>	}	In the Sub-cutaneous Cellular Tissue.
<i>Sebaceous Glands,</i> <sup>i</sup>	<i>Fat Cells,</i> <sup>e</sup>		

<i>Ducts of the Sweat-glands.</i> <i>Hair-follicles,</i> —into which most of the sebaceous ducts open. <i>Ducts of the Sebaceous Glands,</i> —occasionally.	}	Perforate both the Derma and the Epidermis.
---	---	---

Describe the Structure of the Epidermis. It is an unorganized epithelial structure, having no vessels or nerves. The cells of which it is composed are agglutinated together in a laminated arrangement, are flat and dry on the surface, round and softer in the central portion, columnar and softest in the deepest layers. The lowest and softest layers are named the—

*Rete Mucosum*,—which is closely moulded upon the papillary layer of the derma, and contains pigment cells, to which the color of the skin is due.

FIG. 96.



Describe the Structure of the Derma. The true skin is a highly organized, tough yet elastic tissue, and serves to protect the parts beneath, to perform the functions of excretion and absorption, and as the chief seat of the sense of touch. It consists of fibro-areolar tissue, vessels and nerves. The—

*Papillary Layer*,—situated next to the rete mucosum, is covered with minute conical elevations (papillæ),  $\frac{1}{100}$  inch high  $\frac{1}{250}$  inch in diameter at their base, very numerous and arranged in parallel curved lines wherever sensibility is greatest. Each papilla contains a capillary loop or plexus, the termination of one or more sensory nerves,—and in highly sensitive parts, an oval-shaped body, the *Tactile Corpuscle*.

*Corium*,—the lower layer of the derma, is composed chiefly of interlacing bundles of white fibrous tissue, in which are mingled some yellow elastic fibres, also plain muscular fibres wherever hairs are found,—and lymphatic vessels, blood-vessels and nerves, in plexiform arrangement.

**Describe the Nails.** They are flat, horny structures, a modification of the epidermis, molded upon the derma at the dorsal surface of the terminal phalanges of both fingers and toes. Each nail is convex on its outward surface, and is imbedded by its *Root* into a fold of the skin. Its—

*Matrix*,—is that portion of the derma directly beneath the nail. It is covered with highly vascular papillæ. The—

*Lunula*,—is a white crescentic portion of the nail nearest to its root, produced by the diminution in number and size of the papillæ beneath.

**What are the Hairs?** They are also a modified form of the epidermis, found over nearly the whole surface of the body, much varied in size and color. Each hair consists of a *Root* and a *Shaft*. The—

*Root*,—is lodged in an involution of the epidermis called the *Hair-follicle*, which sometimes extends into the subcutaneous cellular tissue. The root rests on a vascular papilla at the bottom or *Bulb* of the follicle, which supplies it with the material for its growth.

*Shaft*,—is the projecting portion of the hair. It consists of a medulla in the centre, next a fibrous portion, externally a cortex of thin, flat scales. The finest hairs have no medulla.

*Point*,—consists of the fibrous portion and the cortex, the medulla being wanting.

**Where are the Sebaceous Glands most abundant?** In the scalp, the face, around the anus, and the apertures of the nose, mouth and external ear. The largest are the—

*Meibomian Glands*,—situated in the eyelids (see Fig. 104).

**Describe the Sebaceous Glands.** They are small, glandular bodies situated in the corium or in the subcutaneous cellular tissue over most of the body, but not in that of the palmar surface of the hands nor on the plantar surface of the feet. Each gland consists of a single sacculated duct, usually opening into a hair follicle, but sometimes ending on the surface of the integument.



**Describe the Sweat-glands.** Each gland consists of a single convoluted tube, situated usually in the subcutaneous cellular tissue, and opening on the surface of the integument by a spiral duct which pierces the derma and the epidermis. It is formed of two coats, an external fibro-cellular, which is continuous with the corium, and an epithelial lining, continuous with the epidermis.

**State the probable number of Sweat-glands and their Evaporating area.** They are estimated as varying, in different parts of the integument, from 417 to 2800 to the square inch, giving for the whole body a total of nearly two millions and a half, representing an evaporating surface of about 8 square inches.

### ORGANS OF TASTE.

**What are the special Organs of Taste?** The *Taste-buds*, small, flask-shaped bodies, each about  $\frac{1}{800}$  inch long, situated in the fungiform and circumvallate papillæ of the tongue. The seat of the sense of taste lies, however, in the mucous membrane covering the dorsum of the tongue, the upper portion of the pharynx, the soft palate and the fauces.

**Name the special Nerves of Taste in the Tongue.** The—

*Chorda Tympani Branch of the Facial*,—for its anterior two-thirds; perceiving saline, acid and styptic qualities (Flint).

*Lingual Branch of the Glosso-pharyngeal*,—for its posterior third; appreciating alkaline, metallic, sweet and bitter tastes (Flint).

**What is Sapolini's view of the Chorda Tympani Nerve?** From repeated dissections, Dr. Sapolini, of Milan, believes the chorda tympani to be a separate cranial nerve, having its proximal end in the so-called intermediary nerve of Wrisberg, originating in the floor of the 4th ventricle, and terminating in a dense plexus with the lingual branch of the 5th nerve, in the muscles of the tongue. He further concludes that the chorda tympani is the nerve governing the movements of the tongue in speech, and that the nerves of taste are the Lingual Branches of the 5th and 9th nerves.

### THE NOSE.

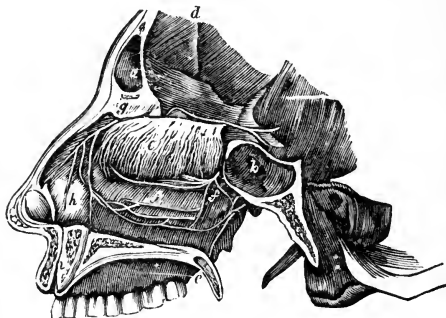
[For an osteological description of the Nasal Fossæ and Septum, see page 31.]

**Where is the Organ of Smell situated?** In the mucous lining of the upper portion of the nasal fossæ, which is the seat of distribution of the terminal filaments<sup>e</sup> of the *Olfactory Nerve*,<sup>d</sup> the special nerve of the sense of smell.

**What is the Schneiderian Membrane?** The Schneiderian or Pituitary Membrane is the mucous membrane of the nasal fossæ. It is continuous with

the mucous lining of the pharynx, Eustachian tube, tympanum and mastoid cells; also with that of the frontal,<sup>a</sup> ethmoidal and sphenoidal sinuses,<sup>b</sup> the antrum, nasal duct, and the conjunctiva. It is covered with columnar epithelium, ciliated throughout most of its extent, provided with mucous glands, and in

FIG. 97.



its deeper layer with the—  
*Olfactory Cells of Schultze*,  
— spindle-shaped, epithelial structures grouped around and between the columnar epithelial cells, and joined together by their anastomosing processes, to form an intricate plexus on which the terminal fibres of the olfactory nerve are supposed to be distributed.

**Name the Arteries of the Nose.** They are the—

*Lateralis Nasi*,—branch of the facial, to the alæ of the nose.

*Nasal of the Septum*,—from the superior coronary artery, to the septum.

*Nasal*,—branches of the ophthalmic and infra-orbital, to the dorsum and sides of the nose.

**Name the Arteries of the Nasal Fossæ.** They are the—

*Anterior and Posterior Ethmoidal*,—from the ophthalmic.

*Spheno-palatine*,—branch of the internal maxillary.

*Alveolar*,—branch of the internal maxillary, to the antrum.

**What Nerves supply the Nose?** Branches from the facial, infra-orbital and infra-trochlear, and a filament from the nasal branch of the ophthalmic nerve.

**What Nerves supply the Nasal Fossæ?** They are the—

*Olfactory or 1st Cranial*,<sup>e</sup>—over the upper third of the septum nasi, and over the superior and middle turbinated bones.

*Nasal Branch of the Ophthalmic*,<sup>g</sup>—to the septum and outer walls.

*Anterior Dental Branch of the Superior Maxillary*,<sup>j</sup>—to the inferior meatus of the nose and the inferior turbinated bone.

*Spheno-palatine Ganglion*,—sends branches to the septum and the superior turbinated bone,—the *Superior Nasal Br.* to the same parts,—the *Naso-palatine* to the middle of the septum,—and the *Anterior Palatine* to the middle and lower turbinated bones.

## THE EYE.

[For an osteological description of the Orbit, see page 29.]

**What is the Visual Apparatus?** It comprises the eyeballs and their appendages, which collect the luminous impressions,—and the optic nerves, which convey these impressions to the brain.

**Describe the Eyeball.** It is a spherical organ, situated in the anterior part of the orbital cavity, on a cushion of connective tissue and fat, where it is retained by its muscles, the optic nerve, the conjunctiva, etc., and protected in front by the eyelids and eyebrows. Projecting from its anterior surface is the segment of a smaller, transparent sphere, the Cornea. The eyeball has the following—

*Diameters*,—Antero-posterior, about .95 inch,—Transverse, .92 inch,—Vertical, .90 inch,—in the adult.

*Anterior Pole*,—is the geometric centre of the cornea.

*Posterior Pole*,—is the geometric centre of the fundus.

*Optic Axis*,—is an imaginary straight line connecting the poles.

*Visual Axis*,—an imaginary straight line from the yellow spot to the object, through the nodal point. It cuts the cornea above the optic axis, at an angle therewith of  $3^{\circ}$  to  $7^{\circ}$ , the *Visual Angle*.

*Nodal Point*,—the centre of curvature of the refracting surfaces.

*Equatorial Plane*,—an imaginary plane through the centre of the eyeball, perpendicular to the axis, dividing the ball or globe into the anterior and posterior hemispheres. The *Equator* is the line where this plane cuts the surface of the globe.

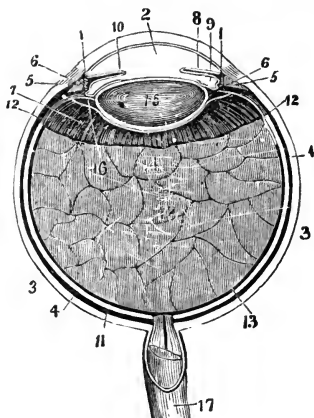
*Meridional Planes*,—are imaginary planes coinciding with the axis of the eyeball. *Meridians* are the lines where these planes intersect the surface of the globe.

**Describe the Tunica Vaginalis Oculi.** It is a fibrous capsule, surrounding the eyeball and the intra-orbital portion of the optic nerve; arising from the optic foramen and being lost anteriorly on the sclerotic. It consists of two layers (parietal and visceral) enclosing a lymph-space which communicates with the lymph-space between the sclerotic and choroid coats. The tendons of the ocular muscles pierce it. The—

*Capsule of Bonnet*,—is the portion of tunica vaginalis posterior to the point where the tendons pass through it. This part is loosely attached to the eyeball, which rotates in it.

*Capsule of Tenon*,—is the portion of the tunica vaginalis anterior to the passage of the tendons. [The whole capsule or Tunica Vaginalis is by many anatomists named the Capsule of Tenon.]

FIG. 98.



*Vitreous*,<sup>18</sup>—in the posterior chamber of the eyeball.

### Name the Tunics of the Eyeball.

They number 3, and are named as follows: the—

*Sclerotic*<sup>3</sup> and *Cornea*,<sup>1</sup>—the external and protective tunic.

*Uveal Tract*,—or vascular tunic, comprising the *Choroid*,<sup>4</sup> *Ciliary body* and the *Iris*,<sup>5</sup> within which is the—

*Retina*,<sup>11</sup>—the innermost, nervous tunic.

### Name the Humors of the Eyeball.

They also number 3, as follows:—

*Aqueous*,<sup>2</sup>—in the anterior<sup>2</sup> and middle<sup>9</sup> chambers.

*Crystalline*,—forming the crystalline lens.<sup>15</sup>

### THE SCLEROTIC AND CORNEA.

**Describe the Sclerotic.** The Sclerotic or hard coat is the posterior five-sixths of the external tunic of the eyeball, the anterior one-sixth being the Cornea. Externally it is of a white color, covered anteriorly by the conjunctival mucous membrane, posteriorly being continuous with the sheath of the optic nerve. Internally its color is brown, and its surface marked by grooves for the ciliary nerves. The optic nerve pierces it posteriorly, also the long and short ciliary arteries, posterior ciliary veins and short ciliary nerves. In the equatorial region it is pierced obliquely by the *venæ vorticosæ*, and around the corneal border by the anterior ciliary arteries and veins. It is composed of connective tissue with elastic fibres, intermixed with pigment cells, and cells resembling the corneal corpuscles. It presents for consideration the following points, viz.:—

*Thickness*,— $\frac{1}{25}$  inch posteriorly,  $\frac{1}{80}$  inch anteriorly.

*Lamina Fusca*,—a layer of very fine connective tissue, connecting the sclerotic with the outer surface of the choroid.

*Lamina Cribosa*,—the posterior perforated portion of the sclerotic, which at this point is a thin, cribriform lamina. Its largest opening transmits the *arteria centralis retinæ*, and is named the *Porus Opticus*, or Optic Canal.

*Sub-conjunctival Tissue*,—connects the conjunctiva with the outer surface of the sclerotic.

*Sulcus*,—a slight circular depression around the junction of the sclerotic with the cornea.

*Arteries*,—from the Ciliary, are few and in a coarse net-work, uniting at wide intervals, but forming, however, the—

*Posterior Vascular Zone*, or *Zone of Zinn*,—an arterial zone around the optic nerve entrance, formed by twigs of the short ciliary going to the optic nerve to anastomose with branches of the central artery of the retina, forming the only connection between the ciliary and retinal systems.

*Anterior Vascular Zone*,—around the cornea, formed by sub-conjunctival branches of anterior ciliary vessels.

*Nerves*,—none have been yet found in the sclerotic.

**What is the Cornea?** The Cornea, or horny body, is the anterior transparent projecting portion of the external tunic of the eyeball, forming about one-sixth thereof. It is set into the sclerotic as a watch-crystal into its case, is of ellipsoidal base, the transverse diameter being the longest, and slightly more convex vertically than horizontally. Its—

*Thickness*,—is  $\frac{1}{8}$  inch at centre,  $\frac{1}{2}$  inch at periphery.

*Index of Refraction*,—1.342.

*Vessels*,—none, except the peripheral zone,  $\frac{1}{5}$  inch wide, formed of capillary loops from Episcleral branches of the anterior ciliary, which terminate at its circumference; so that it is practically a non-vascular structure.

*Nerves*,—are numerous; 20 or 30 twigs from the Ciliary nerves form an intricate plexus throughout its laminated substance.

**Describe the Structure of the Cornea.** It consists of five layers,—centrally the true corneal tissue, having in front an anterior elastic lamina and the conjunctival epithelium; behind, a posterior elastic lamina and the epithelial lining of the aqueous chamber. The—

*Layer of Conjunctival Epithelium*  $\frac{1}{800}$  inch thick, consists of two or three layers of transparent nucleated cells.

*Anterior Elastic Lamina*, also named the *Anterior Limiting Layer*, the Membrane of Bowman or Membrane of Reichert,—is  $\frac{1}{5000}$  to  $\frac{1}{2000}$  inch thick, a firm, elastic and transparent homogeneous membrane, consisting of closely-interwoven fibrils, similar to those in the corneal tissue proper.

*True Corneal Tissue*,— $\frac{1}{5}$  inch thick, a transparent, fibrous structure, formed of five connective-tissue fibrillæ, united in bundles, and these in laminae, between which is a semi-fluid cement, filled with *Corneal Corpuscles* and wandering cells.

*Posterior Elastic Lamina*, Membrane of Descemet, or Demours,—is, like the anterior elastic lamina, a structureless basement membrane, of extreme thinness, resisting the action of water, alcohol or acids; very brittle, ex-

ceedingly elastic, and curls up inwardly upon itself, when detached from the true cornea. At the corneal margin it breaks up into fibres, which are continuous with the ligamentum pectinatum of the iris.

*Posterior Epithelial Layer*,—a single layer of flattened, polygonal, transparent, nucleated cells, forming the endothelium of the membrane of Descemet or Demours, and the epithelial lining of the aqueous chamber.

#### THE UVEAL TRACT.

**Describe the Choroid.** It is the posterior portion of the middle tunic of the eyeball,  $\frac{1}{300}$  to  $\frac{1}{150}$  inch thick, and extends from the optic nerve entrance to the ora serrata, a little in front of the equator. It is highly vascular, of dark-brown color, connected to the sclerotic by the *Lamina Fusca*, terminates anteriorly in the *Ciliary Processes*, and is composed of four layers, as follows:—

*Tunica Vasculosa*,—externally, consists of the venæ vorticosæ and the larger arterial branches.

*Membrana Ruyschiana, or Chorio-capillaris*, the middle layer—consists of a fine capillary plexus, formed by the short ciliary vessels.

*Limiting Membrane*,—a structureless hyaline membrane, covering the inner surface of the capillary layer.

*Pigmentary Layer*, internally,—a single layer of hexagonal nucleated cells, loaded with pigment of a brown-black color, which is absent in albinos, and of slight amount in blondes. [Considered by many anatomists the 10th layer of the retina.]

*Arteries of the Choroid*,—are the short posterior ciliary, and recurrent branches from the long posterior and anterior ciliary. (See p. 105.)

*Veins*,<sup>2</sup>—unite into 4 or 6 Venæ Vorticosæ,<sup>4</sup> which pass out through the sclerotic near its equator.

*Nerves*,<sup>3</sup>—derived from 3d, 5th, and sympathetic, through the long and short ciliary nerves. (See p. 137.)

**What are the Ciliary Processes?** They are 70 or 80 folds, formed by the anterior prolongation of the middle and internal layers of the choroid on the inner surface of the ciliary muscle, being received into corresponding folds on the suspensory ligament of the lens. They are about  $\frac{1}{10}$  inch in length, and form a curtain-like expansion behind the iris.

**Describe the Ciliary Body.**<sup>5</sup> It is the portion of the uveal tract between the choroid and the iris,<sup>6</sup> and consists of ciliary muscle covered by choroidal stroma and the ciliary processes. The—

*Ciliary Muscle or Muscle of Bowman*,—is a ring of involuntary muscular fibres, supplied by the 3d nerve; is thickest anteriorly, thin posteriorly. Its fibres arise from the corneo-sclerotic junction, and pass backwards to

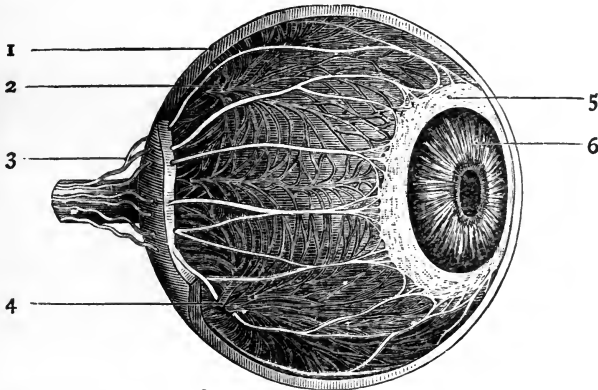
be attached to the choroid in front of the retina. Consists of meridional fibres drawing the choroid forwards, and circular fibres which relax the zonula and permit the lens to become more convex, from its own elasticity.

*Annular Muscle of Müller*,—consists of separate circular bundles at the anterior internal angle of the ciliary body.

*Circulus Arteriosus Major and Minor*,—are arterial circles on the ciliary muscle, formed by branches of the long posterior ciliary and anterior ciliary arteries.

**What is the Iris<sup>6</sup>?** It is a perforated curtain, suspended in the aqueous humor behind the cornea and in front of the lens, and is the anterior portion of the middle tunic of the eyeball, being continuous with the ciliary muscle and the choroid coat. It is about  $\frac{1}{8}$  inch wide,  $\frac{1}{100}$  inch thick, and is com-

FIG. 99.



posed of radiating and circular muscular fibres, a fibrous stroma and pigment cells, covered by a layer of irregular cells continuous with those of the membrane of Descemet. The—

*Pupil*,—is the central opening in the iris, situated a little to the nasal side of the centre, diameter  $\frac{1}{2}$  to  $\frac{1}{4}$  inch.

*Ligamentum Pectinatum Iridis*, or Dollinger's band,—is the suspensory ligament of the iris, connecting its ciliary margin with the corneo-sclerotic junction. It is formed of strong fibrous prolongations from the membrane of Descemet and the posterior surface of the cornea.

*Fontana's Spaces*,—are spaces between the prolongations which form the ligamentum pectinatum. In some animals, as the ox, they form regular canals.

*Uvea, or Tapetum*,—a layer of purple pigment-cells on the posterior surface of the iris, continuous with the pigment layer of the ciliary processes.

*Sphincter Pupillæ*,—a layer of circular muscular fibres around the pupillary margin, supplied by the 3d nerve.

*Dilator Pupillæ*,—radiating muscular fibres from the pupillary margin toward the ciliary border, supplied by fibres of the sympathetic, from the ciliary ganglion. [See p. 137.]

*Membrana Pupillaris*,—a vascular membrane which covers the pupil in the foetus, disappearing about the eighth month,—occasionally permanent. It is nourished by the *Hyaloid Artery*, through the *Canal of Stilling* (described under the VITREOUS HUMOR).

*Arteries*,—are derived from the long and anterior Ciliary, forming the *Circulus Major Iridis* at the ciliary border, and the *Circulus Arteriosus Iridis Minor* near the pupillary margin.

*Veins*,—empty into those of the ciliary processes and the anterior ciliary veins

*Sinus Circularis Iridis, Canal of Schlemm, or Canal of Fontana*,—is a minute canal at the internal corneo-sclerotic junction, extending around the circumference of the attached border of the iris. It is lined by endothelium and encloses a venous plexus, receiving veins from the sclerotic and the ciliary plexus. It communicates with the chamber of the aqueous humor and with the anterior ciliary veins.

*Nerves of the Iris*,—are derived from the 3d, 5th and the sympathetic, through the long and short ciliary nerves. The 3d supplies the circular fibres, the sympathetic the radiating ones, the 5th being nerves of common sensation.

#### THE RETINA.

**What is the Retina?** It is the innermost or nervous tunic of the eye,—a delicate, grayish, transparent membrane, about  $\frac{1}{75}$  of an inch thick at the fundus,  $\frac{1}{100}$  inch at the anterior margin. It is formed by a membranous expansion of the optic nerve elements, and extends from the termination of that nerve nearly as far forwards as the ciliary processes, terminating in a jagged margin, the *Ora Serrata*, though its fibrous stroma is continued as the *Pars Ciliaris Retinæ* over the ciliary body. The Retina presents for examination the following points, viz., the—

*Macula Lutea, or Yellow Spot*,—situated on the retina, exactly in the visual axis; is an elevated oval spot where vision is very acute, the retina being very thin and full of nerve elements closely packed together at the expense of its connective tissue. No rods, no nerve-fibre layer here, but the cones and ganglion-cells are very numerous.

*Fovea Centralis*,—a depression at the centre of the macula lutea,  $\frac{1}{25}$  to  $\frac{1}{60}$  inch in diameter, in which the sense of vision is most acute.



*Optic Disc or Papilla*,—the point where the optic nerve enters, the central artery of the retina piercing its centre. It lies about  $\frac{1}{10}$  inch internal to and  $\frac{1}{10}$  inch below the posterior pole of the eye, and is often called the *Blind Spot*, being the only part of the fundus oculi from which the power of vision is absent.

*Pars Ciliaris Retinæ*,—the part of the retinal stroma which is prolonged over the ciliary body. It is destitute of nerve-elements.

*Arteries of the Retina*,—arise from the Arteria Centralis Retinæ (br. of the ophthalmic), just behind the optic disc; run chiefly upwards and downwards, accompanied by veins, to terminate in capillary network. No vessels exist in the fovea centralis, and only the finest capillaries in the macula lutea.

**Describe the Structure of the Retina.** It is composed of nervous elements, blood-vessels, and modified connective tissue resembling the neuroglia of the brain, arranged in 9 or 10 layers, from within outwards, as follows, viz.—

*Membrana Limitans Interna*,—a perfectly transparent membrane, made up of the retinal connective tissue, and lining the inner surface of the retina (shown in the cut by the lowest line).

*Optic Nerve Fibres*,<sup>1</sup>—composed of the terminal fibres of the optic nerve radiating from the papilla in all directions. They consist of the axis-cylinder only.

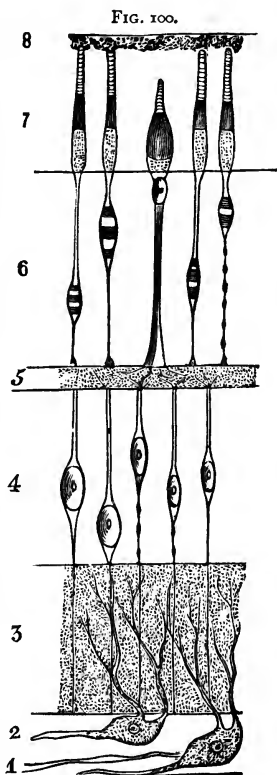
*Ganglionic Layer*,<sup>2</sup>—a very thin layer of large ganglion cells, having large nuclei and nucleoli, with branching processes to the optic nerve fibres of next layer.

*Internal Molecular Layer*,<sup>3</sup>—fine granules intersected by finest nerve fibres and connective tissue elements.

*Internal Granular Layer*,<sup>4</sup>—small, round cells with large nuclei, their processes uniting with the ganglion cells.

*External Molecular Layer*,<sup>5</sup>—a very thin layer of fine granules and nerve-fibrillæ.

*External Granular Layer*,<sup>6</sup>—consists of ellipsoid cells, forming a nucleated enlargement of Jacob's membrane.



*External Limiting Membrane*,—a membranous expansion of radial connective tissue, perforated by foramina (shown in the cut by a line between <sup>6</sup> and <sup>7</sup>).

*Rods and Cones, or Jacob's Membrane*,<sup>7</sup>—the perceptive layer of the retina, composed of rods and cones closely packed together, like palisades, the termini, probably, of the optic nerve fibres.

[A tenth layer is described by some anatomists, the pigmentary layer of the choroid.<sup>8</sup> See *ante*, p. 200.]

### Name the Essential Elements of the Retinal Structure.

PRINCIPAL ELEMENTS, are three, as follows, viz.—

*Nerve fibres*,—which in the molecular layers break up into very delicate plexuses. In their course are found—

*Nerve-cells*,—ordinary bipolar or multipolar, and modified ones, the so-called granular layers of the retina.

*Terminal Organs*,—the rods and cones of Jacob.

SUBORDINATE ELEMENTS, are two, the—

*Modified Connective Tissue*,—of spongy nature.

*Vessels*,—blood-vessels and lymphatics.

### THE HUMORS.

**What is the Aqueous Humor?** It is a clear, alkaline, serous fluid, composed of water 96.7, albumen 0.1, chloride of sodium and extractive matters 3.2, weighing 4 to 5 grains, and filling the anterior and posterior aqueous chambers, which communicate with each other when the pupil is dilated sufficiently to remove the pupillary margin of the iris from the surface of the lens. The—

*Anterior Chamber of the Aqueous Humor*,—has the cornea in front and the iris behind.

*Posterior Chamber of the Aqueous Humor*,—has the iris in front, the lens, zonula and ciliary body behind. [The existence of any such space is denied by many authorities.]

**Describe the Crystalline Lens.** It is a bi-convex, elastic, transparent body, enclosed in a capsule, held in place by a suspensory ligament, and situated between the posterior aqueous chamber and the chamber of the vitreous humor, immediately behind the pupil. Its posterior surface is the most convex, and rests in the *Hyaloid Fossa* of the vitreous. Its—

*Dimensions and Weight*,—diameter, about  $\frac{3}{8}$  inch,—axis about  $\frac{1}{4}$  inch,—weight, 4 to  $4\frac{1}{2}$  grains,—index of refraction, 1.44.

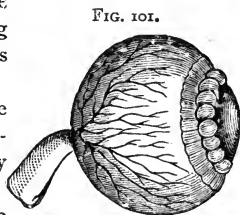
*Composition*,—water 60, soluble albuminous matter 35, insoluble albuminous matter 2.5, fat and cholesterine 2 per cent.

**Capsule**,—is transparent, elastic,  $\frac{1}{2000}$  inch thick anteriorly,  $\frac{1}{8000}$  inch posteriorly; has a layer of flat cells between its anterior portion and the lens, which, after death, break down into a fluid, the *Liquor Morgagni*.

**Zonula of Zinn, or Suspensory Ligament**,—connects the capsule with the ciliary body. It is formed by a splitting of the hyaloid membrane into two layers, one going in front of the lens, the other behind. It is shown exaggerated in the cut.

**Canal of Petit**,—is a triangular space around the circumference of the lens, formed by the separation of the two portions of the suspensory ligament (shown inflated in the cut).

**Processus Zonulæ**,—are small radiating folds on the anterior surface of the suspensory ligament, which are received between the ciliary processes.



**Describe the Structure of the Crystalline Lens.** It consists of flattened hexagonal fibres, united laterally into lamellæ, by serrated edges, and curving around the borders of the organ. Its centre or *Nucleus* is unstratified, and denser than the surrounding portion or *Cortex*. It is unorganized, having no vessels or nerves, but receives its nutriment by imbibition from the uveal tract, and possibly from the other humors of the eye.

**What is the Vitreous Humor?** The Vitreous Humor or Hyaloid Body is an apparently structureless substance, of gelatinous consistence, consisting of water with a little albumen and salts, and containing cells, nuclei, and connective-tissue filaments. It has no vessels or nerves, and is situated in the posterior chamber of the eye, behind the lens, which it supports, as also the retina. The—

**Canal of Stilling, Canal of Cloquet, or Hyaloid Canal**,—traverses the vitreous humor antero-posteriorly, being the channel for the transmission in the foetus of the *Hyaloid Artery* to the *membrana pupillaris*. [See *ante*, p. 202.]

**Hyaloid Fossa**,—a depression on the anterior surface of the vitreous, receiving the posterior convexity of the lens.

**What is the Hyaloid Membrane?** It is a delicate capsule investing the vitreous, and supposed to send delicate septa into the substance of that humor. It divides anteriorly into two layers, which enclose the Canal of Petit and the Lens, forming the suspensory ligament of the latter, or *Zonula of Zinn*. [See above.]

The foregoing is the view of most anatomists, but some assert that this membrane is identical with the internal limiting membrane of the retina, extending only to the *ora serrata*. [Henle, Iwanoff, etc.]

Others admit a hyaloid membrane surrounding the vitreous, but deny that it splits to enclose the lens, and assign but one layer to the suspensory ligament, namely, that in front of the Canal of Petit. [Gray, etc.]

**Describe the Muscles of the Eyeball.** They number 6, of which 4 are Recti and 2 Oblique, as follows:—

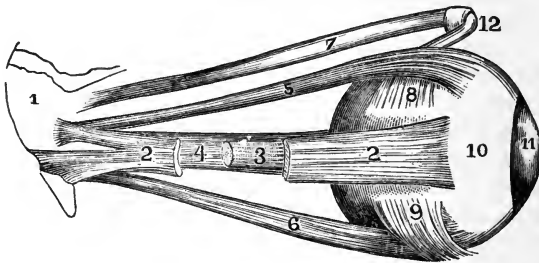
*Rectus Superior*,<sup>5</sup>—from the upper margin of the optic foramen and the sheath of the optic nerve,—into the sclerotic coat. *Action*, to rotate the eyeball upwards. *Nerve*, 3d cranial.

*Rectus Inferior*,<sup>6</sup>—from the ligament of Zinn,—into the sclerotic coat. *Action*, rotates the eyeball downwards. *Nerve*, 3d cranial.

*Rectus Internus*,<sup>4</sup>—from the ligament of Zinn,—into the sclerotic coat. *Action*, rotates the eyeball inwards. *Nerve*, 3d cranial.

*Rectus Externus*,<sup>2</sup>—by two heads, the upper from the outer margin of the optic foramen, the lower from the ligament of Zinn and a bony process

FIG. 102.



at lower margin of the sphenoidal fissure,—into the sclerotic coat.<sup>10</sup> *Action*, to rotate the eyeball outwards. *Nerve*, 6th cranial, or abducens. Between the two heads of the external rectus pass the 3d, nasal branch of the 5th, and the 6th cranial nerves, and the ophthalmic vein.

*Obliquus Superior*,<sup>7</sup>—from about a line above the inner margin of the optic foramen, its tendon passing through a “pulley”<sup>12</sup> near the internal angular process of the frontal bone and thence beneath the rectus superior,—into the sclerotic coat, at right angles<sup>8</sup> to the insertion of the rectus superior. *Action*, to rotate the eyeball on its antero-posterior axis. *Nerve*, 4th cranial, or patheticus.

*Obliquus Inferior*,<sup>9</sup>—from the orbital plate of the superior maxillary,—into the sclerotic coat below the insertion of the external rectus and at right angles thereto. *Action*, to rotate the eye on its antero-posterior axis. *Nerve*, 3d cranial.

## VESSELS AND NERVES OF THE EYE.

**What Nerves supply the Muscles of the Eye?** The—

*3d Cranial, or Motor Oculi*,—supplies the superior, inferior and internal recti, and the inferior oblique muscles.

*4th Cranial, or Trochlear*,—supplies the superior oblique muscle.

*6th Cranial, or Abducens*,—supplies the external rectus.

**Describe the Arteries of the Eye.** The Eye is supplied by the *Ophthalmic* and *Anterior Cerebral* branches of the internal carotid artery, and the *Infra-orbital* branch of the internal maxillary (from the external carotid). The—

**OPHTHALMIC**,—arises from the cavernous portion of the Internal Carotid, and enters the optic foramen, giving off the following-named branches:—

*Lachrymal*,—to the lachrymal gland, the upper eyelid, and the conjunctiva, anastomosing with the palpebral arteries.

*Supra-orbital*,—supplies the superior rectus and levator palpebræ muscles, the forehead and pericranial tissues.

*Anterior and Posterior Ethmoidal*,—to the dura mater, the nose, the anterior ethmoidal cells, and the frontal sinus.

*Palpebral*,—superior and inferior,—to the eyelids.

*Frontal*,—to the tissues of the forehead.

*Nasal*,—to the lachrymal sac, and the nose.

*Short Ciliary, 12 or 15*,—pierce the sclerotic at the lamina cribosa, supplying the choroid and the ciliary processes.

*Long Ciliary, 2*,—pierce the sclerotic, and pass forwards between it and the choroid, to supply the iris, forming two arterial circles thereon, the *Circulus Major Iridis* at the ciliary border, and the *Circulus Arteriosus Iridis Minor* near the pupillary margin.

*Anterior Ciliary*,—arise from the muscular branches, pierce the sclerotic, and join the great arterial circle of the iris.

*Arteria Centralis Retinæ*,—pierces the optic nerve obliquely, and is distributed to the retina.

*Muscular Branches, 2*,—superior and inferior, supply the muscles of the eyeball.

**ANTERIOR CEREBRAL**, branch of the Internal Carotid,—sends nutrient capillaries to the optic nerve.

**INFRA-ORBITAL**, branch of the Internal Maxillary artery,—sends branches to the inferior rectus and inferior oblique muscles, and to the lachrymal gland.

**Name the Principal Lymph-spaces of the Eyeball.** The—

*Canal of Schlemm*,—around the circumference of the iris.

*Peri-choroidal Space*,—between the choroid and the sclerotic.

*Space of Tenon*,—between the globe and its capsule.

*Vaginal Spaces*,—between the sheaths of the optic nerve.

**What Veins has the Eye?** It has two main trunks, the *Superior* and *Inferior Ophthalmic Veins*, which empty into the cavernous sinus, after collecting the blood from the smaller venous channels through the *Venæ Vorticosæ* of the choroid. The veins of the eye anastomose freely with the facial veins, thus permitting the escape of venous blood in either direction.

**Describe the Nerves of the Eye.** They are the—  
*Nerve of Special Sense*,—the Optic, or 2d cranial nerve.

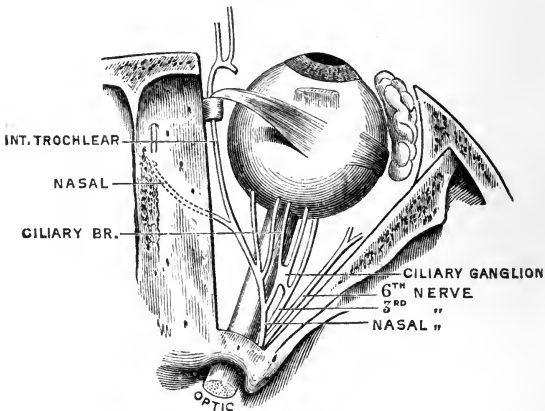
*Motor Nerves*,—the 3d, 4th, 6th, filaments of the 5th, and some fibres from the sympathetic.

*Sensory Nerve*,—the Ophthalmic Division of the 5th, giving off the—

*Lachrymal*,—to the lachrymal gland, the conjunctiva, and the integument of the upper eyelid.

<i>Frontal</i> ,	{	Supra-trochlear.		{	Ganglionic.
		Supra-orbital.			Long Ciliary.
					Infra-trochlear.

FIG. 103.



*Sympathetic Branches*,—arise from the medulla, cilio-spinal region, cavernous and carotid plexuses, and join the 3d, 4th, 5th, and 6th nerves, sending filaments to the dilator fibres of the iris, to the muscles of the orbit and lids, to the ciliary ganglion, and to the walls of the arteries.

*Short Ciliary*,—some 20 in number, arise from the *Ciliary Ganglion* [See *ante*, page 137], pierce the sclerotic and go to the ciliary muscle, choroid, iris, cornea, and to the sheath of the optic nerve.

*Ascending*,—from Meckel's ganglion [See *ante*, page 137], enter the orbit by the sphenomaxillary fissure, going to the optic nerve, the 6th nerve, and the ciliary ganglion.

**Describe the formation and course of the Optic Tract.** The fibres which form the optic tract have their deep origin in the optic thalamus, corpora geniculata, and the anterior corpora quadrigemina. The tract winds around the crus cerebri as a flattened band, receiving from the crus a few fibres of attachment, and also fibres from the lamina cinerea and the tuber cinereum. In front of the latter body the two tracts join to form the *Optic Commissure* or *Chiasm*. [See <sup>2</sup> on Fig. 61, page 130.]

**What is the arrangement of the Fibres in the Optic Commissure?** As generally described, the fibres undergo a partial decussation, as follows, viz., the—

*Decussating Fibres*,—are the most numerous. They lie in the centre of the commissure, and pass across to the opposite side, connecting the retina of each eye with the opposite cerebral hemisphere.

*Longitudinal Fibres*,—are the external fibres in the optic tracts, passing into the optic nerve of the same side, connecting each retina with the cerebral hemisphere of its own side.

*Inter-cerebral Fibres*,—situated posteriorly in the commissure, passing from one optic tract to the other.

*Inter-retinal Fibres*,—lie anteriorly in the commissure, passing from one optic nerve to the other, and connecting the retina of one eye with that of the other.

**Describe the Optic Nerve.** The Optic Nerve proper is the 2d cranial nerve, arises from the optic commissure, passes into the orbit by the optic foramen in company with the ophthalmic artery, is pierced by the central artery of the retina, and enters the eyeball posteriorly  $\frac{1}{10}$  inch inwardly from its axis, piercing the sclerotic and choroid coats, and finally expanding in the retina. It is surrounded by a tubular process of dura mater, which as the nerve enters the orbit, subdivides to form both the sheath of the nerve and the periosteum of the orbit.

#### APPENDAGES OF THE EYE.

**What are the Tutamina Oculi?** They are the appendages of the eye, including the—

*Eyebrows*, or Supercilia.

*Eyelids*, or Palpebræ.

*Conjunctiva*, or lining membrane.

*Lachrymal Gland*, and *Ducts*.

*Lachrymal Sac*.

*Nasal Duct*.

**What are the Eyebrows?** They are arched elevations of the integument over the supra-orbital arches, are covered with a row of short hairs, and are drawn downwards and inwards by the *Corrugator Supercilii* muscle. [See page 68.]

**Describe the Eyelids.** The Palpebræ, or Eyelids, are two thin, movable folds, placed in front of the eye, for its protection. The upper lid is the most movable one, having its own levator muscle, the Levator palpebræ superioris. [See page 68.] The—

*Palpebral Fissure*,—is the space between their free margins, its outer and inner angles being termed respectively the *External Canthus* and *Internal Canthus*.

*Lacus Lachrymalis*,—is a small triangular space at the internal canthus, between the lids and the globe.

*Lachrymal Papilla*,—on the edge of each lid, about  $\frac{1}{4}$  inch from the internal canthus.

*Punctum Lachrymale*,—a minute orifice on each papilla, and the beginning of the lachrymal canal.

**Describe the Structure of the Eyelids.** They are composed externally of skin, internally of mucous membrane (the palpebral conjunctiva), and between these lie areolar tissue, the orbicularis muscle, tarsal cartilage, fibrous membrane, Meibomian glands, vessels and nerves. The—

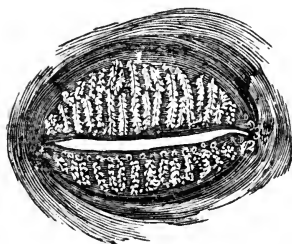
*Orbicularis Palpebrarum Muscle*,—is very thin and pale. [See p. 68.]

*Tensor Tarsi*, or *Horner's Muscle*, [See p. 68]—is a portion of the orbicularis, compressing the punctum and the sac.

*Tarsal Cartilages*,—are plates of fibro-cartilage, forming the framework of the lids. The upper one is crescentic in shape, the lower one elliptical and smaller.

*Tarsal Ligaments*,—are fasciæ connecting the tarsal cartilages to the circumference of the orbit. Externally they connect with the malar bone, and are there called the *External Canthal Ligaments*.

FIG. 104.



*Tendo Oculi*,—connects the inner end of each tarsal cartilage to the nasal process of the superior maxillary bone.

*Meibomian Glands*,<sup>1</sup>—are sebaceous glands imbedded in the tarsal cartilages, 30 to 40 in the upper lid, 20 to 30 in the lower one. They open along the inner edge of the free border of each lid, and furnish a sebaceous secretion, to prevent adhesion of the lids to each other.



*Eyelashes, or Cilia*,—are a double or triple row of short hairs, situated on the free margins of the lids; their follicles lying in the connective tissue beneath the tarsal cartilages.

*Arteries*,—are the *Palpebral* branches of the ophthalmic artery, forming the *Superior and Inferior Tarsal Arches*, and anastomosing with the angular, anterior temporal, lachrymal and transverse facial.

*Nerves*,—the 3d, facial and sympathetic to the muscles; the 5th to the skin and conjunctiva.

**What is the Conjunctiva?** It is the mucous membrane which lines the eyelids, and is reflected over the front of the sclerotic and cornea. It is continuous with the mucous lining of the Meibomian glands, canaliculi, lachrymal sac, nasal duct, lachrymal duct and gland. The—

*Palpebral Conjunctiva*,—consists of connective tissue covered by epithelium, is traversed by furrows, and has papillæ and follicular glands.

*Ocular Conjunctiva*,—is very thin and transparent, loosely attached on the sclerotic, firmly adherent over the cornea, where it has no vessels in its structure. It has very few papillæ, and no glands.

*Retro-tarsal or Palpebral Folds*,—superior and inferior,—are where the conjunctiva is reflected over the globe. They contain prominent papillæ, and conglomerate glands, called the accessory lachrymal glands.

*Plica Semilunaris, or Semi-lunar Folds*,—a crescentic fold of conjunctiva at the inner canthus, considered to be the rudiment of the *Membrana Nictitans* or 3d eyelid (of birds).

**What is the Caruncula Lachrymalis?** It is a small, red, conical body, situated in the lacus lachrymalis, at the inner canthus of the eye; consisting of hair follicles and sebaceous glands, and covered by conjunctiva. It is connected by tendinous fibres to the capsule of Tenon and to the rectus internus muscle.

**Name the parts constituting the Lachrymal Apparatus.** They are the lachrymal gland and its ducts, the accessory conjunctival glands, the canaliculi, lachrymal sac, and nasal duct.

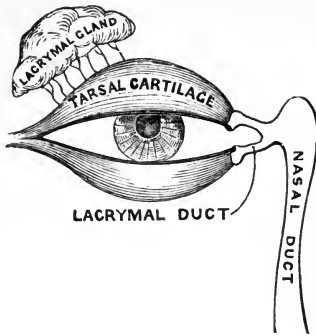
**Describe the Lachrymal Gland.** It is an oval gland situated in a fossa of the orbital portion of the frontal bone, at the outer angle of the orbit, its inferior surface resting on the eyeball, its lower margin or lobe being covered by conjunctiva. The—

*Tarso-orbital Fascia*,—connects the lachrymal gland to the bony roof of the orbit.

*Ducts*,—6 to 12 in number; open on the upper and outer portion of the palpebral conjunctiva.

*Secretion*—(tears),—lubricates the anterior surface of the eyeball. Excess

FIG. 105.



evaporates, or collects in lacus and passes through puncta into canaliculi, and so to lachrymal sac, and thence, by the nasal duct, into the inferior meatus of the nose.

**What are the Canaliculi?** They are two minute canals,  $\frac{1}{25}$  inch in diameter and  $\frac{1}{3}$  inch long, which extend from the punctum in each lid to the lachrymal sac. They are lined with mucous membrane, and enveloped by fibres of the tensor tarsi muscle.

**Describe the Lachrymal Sac.** It is the superior dilated extremity of the nasal

duct, and is situated in the groove formed by the lachrymal bone and the nasal process of the superior maxillary. Its form is oval, flattened antero-posteriorly; its dimensions about  $\frac{2}{5}$  inch long and  $\frac{1}{8}$  inch wide. Its fundus is crossed by the tarsal ligament, and by the tensor tarsi muscle. Its junction with the nasal duct may be interrupted by folds of the lining mucous membrane.

**What is the Nasal Duct?** A membranous canal extending from the lachrymal sac to the inferior meatus of the nose. It is about  $\frac{3}{4}$  inch long,  $\frac{1}{8}$  inch in diameter, is contained in the osseous lachrymal canal, curving downwards, backwards and outwards, and its calibre is narrowest about its middle. Its mucous lining is thick, and continuous with the Schneiderian membrane of the nasal cavity. Surrounding it is a vascular network of connective tissue, and outside this, a tendinous sheath. At its lower end a fold of mucous membrane forms an imperfect valve.

## THE EAR.

**What Bone contains the Auditory Apparatus?** The petrous and mastoid portions of the Temporal bone. [Described on page 16.]

**Name the Divisions of the Auditory Apparatus.** The organ of hearing consists of the following parts, viz.—

- |                                 |   |                                 |
|---------------------------------|---|---------------------------------|
| 1. External Ear.....            | } | <i>Auricle, or Pinna.</i>       |
|                                 |   | <i>External Auditory Canal.</i> |
| 2. Middle Ear, or Tympanum..... | } | <i>Membrana Tympani.</i>        |
|                                 |   | <i>Cavity of the Tympanum.</i>  |
|                                 |   | <i>Mastoid Cells.</i>           |
|                                 |   | <i>Eustachian Tube.</i>         |

3. *Internal Ear, or Labyrinth*..... {  
*Vestibule.*  
*Semicircular Canals.*  
*Cochlea.*  
*Auditory Nerve.*

## THE EXTERNAL EAR.

**Describe the Auricle.** The Auricle or Pinna is the external irregularly shaped appendage, fastened to the malar and temporal bones by elastic fibres. It consists of a broad plate of yellow cartilage, deficient in places where its parts are joined together by ligamentous tissue, and is covered by perichondrium and integument, the latter containing sebaceous and sweat glands, and provided with short, downy hairs. The Auricle presents several elevations and depressions, named as follows:—

*Concha*,—the central cavity leading into the canal.

*Tragus*,—a conical eminence in front of the concha, usually covered with hairs along its inferior border.

*Anti-tragus*,—a similar projection facing the tragus, from which it is separated by a deep fissure, the *Incisura Intertragica*.

*Helix*,—the outer curved edge of the pinna, beneath which is a deep groove, the *Fossa Navicularis*.

*Anti-helix*,—a curved ridge along the posterior boundary of the concha, bifurcating above to enclose a triangular depression, named the *Fossa Triangularis*.

*Lobe or Lobule*,—the soft, pendulous portion, composed of integumentary, adipose and connective tissues.

**Name the Muscles of the Auricle.** The—

EXTRINSIC MUSCLES are the—

*Attolens Aurem, Attrahens Aurem, Retrahens Aurem.*

[These muscles are described on page 68.]

INTRINSIC MUSCLES are but slightly developed. They are the—

*Tragicus*,—lies vertically on the outer surface of the tragus.

*Anti-tragicus*,—on the posterior wall of the auditory canal.

*Helicis Major*,—vertically on the anterior border of the helix.

*Helicis Minor*,—on lateral surface of the root of the helix.

*Transversus Auriculæ*,—on the posterior surface of the auricle, radiating outwards from the convexity of the concha.

*Obliquus Auriculæ*,—also on the posterior surface, radiating upwards from the convexity of the concha.

*Dilator of Concha*,—on the tragus.

**Name the Arteries and Nerves of the Auricle. The—**

**ARTERIES,**—are derived from the External Carotid. The—

*Posterior Auricular,*—a main branch of the external carotid.

*Anterior Auricular,* branch of the Temporal br. of the ext. carotid.

*Auricular,*—branch of the Occipital branch of the ext. carotid.

**NERVES,**—are the—

*Auriculus Magnus,*—from the cervical plexus. [See p. 133.]

*Posterior Auricular,*—from the facial nerve.

*Auricular,*—branch of the pneumogastric (also called Arnold's nerve).

*Auriculo-temporal,*—branch of the inferior maxillary div. of the 5th.

**Describe the External Auditory Canal.** It is an osseo-cartilaginous tube, about  $1\frac{1}{4}$  inch long, extending from the concha to the membrana tympani, and curved irregularly in its course. The cartilaginous, or external portion, is about  $\frac{1}{2}$  inch long, and deficient posteriorly and above, where it is filled by strong fibrous tissue. The canal is lined with integument, having numerous hair follicles, sebaceous and ceruminous glands.

*Sulcus Tympanicus,*—a groove at the bottom of the canal for the insertion of the membrana tympani. It is interrupted above by the—

*Segment of Rivinus,*—at the upper part of the sulcus tympanicus, each end having an osseous spine, the *Spina Tympanica Major* and *Minor*.

**What are the Relations of the External Auditory Canal?** *In front,* the articulation of the lower jaw; *below and in front,* the parotid gland; *behind,* the mastoid cells and the transverse sinus; *above,* the mastoid cells and the dura mater of the brain.

**Name its Vessels and Nerves. Its—**

*Arteries,*—are branches of the Posterior and Deep Auricular.

*Nerves,*—are chiefly derived from the Temporo-auricular Branch of the inferior maxillary division of the 5th nerve.

**THE MEMBRANA TYMPANI.**

**What is the Membrana Tympani?** The Membrana Tympani, or Drumhead, is an oval, inelastic, semi-transparent membrane, about  $\frac{1}{25}$  inch in thickness, situated obliquely at the bottom of the external auditory canal, which it separates from the cavity of the tympanum. Seen through the canal, it is of a delicate blue-gray color, arched inwards, and presenting for consideration the following points, viz. :—A

*Tubercle,*—white in color at the upper border, made by the short process of the malleus.

*Stripe,*—also white, running downwards from the tubercle, and formed by the handle of the malleus.

*Light-spot*,—a triangular reflection, its apex at the tip of the malleus-handle, its base extending to the periphery of the membrane. It is due to the concavity of the drumhead.

*Umbo*,—or shadow, is the darker central portion.

*Shrapnell's Membrane*,—is the upper posterior part of the drumhead, where it is somewhat flaccid.

*Rivian Foramen*,—a minute opening supposed to exist in the portion called Shrapnell's membrane.

FIG. 106.



In what direction is the *Membrana Tympani* placed? Obliquely inwards and forwards, almost forming a continuation of the posterior wall of the external auditory canal.

Describe the Structure of the *Membrana Tympani*. It is composed of 3 layers, as follows:—

*External, or Dermoid Layer*,—continuous with the integument lining the external auditory canal.

*Middle Layer, or Lamina Propria*,—formed of outer radiating fibres, and inner circular ones. Between these two sets of fibres are situated the short process and handle of the malleus.

*Internal or Mucous Layer*,—is continuous with the mucous lining of the tympanum.

*Tendinous Ring* (*At*, Fig. 106),—surrounds the margin of the membrane, being received into the sulcus tympanicus. Its anterior and posterior ends are shown by *v* and *h* in Fig. 106.

What Structures are presented by its Internal Surface? A fibrous fold descends from the upper portion of the marginal ring, for a short distance along the malleus-handle, forming the—

*Anterior and Posterior Pouches*,—one on each side of the malleus-handle, opening downwards.

*Tendinous Bands*,—4 or 5,—converge from the posterior margin to the middle of the malleus-handle.

What Arteries Supply the *Membrana Tympani*? The—

*Deep Auricular*, branch of the internal maxillary,—supplies the external layer, and forms with the Tympanic Branches a capillary plexus in the middle layer. (von Trölsch, Roosa, etc.)

*Tympanic*, branches of the internal maxillary and internal carotid arteries,—supply the internal layer, and anastomose on the membrana tympani with the—

*Vidian and Stylo-mastoid*,—branches respectively of the internal maxillary and posterior auricular branches of the external carotid.

**What Nerves supply the Membrana Tympani?** The external layer contains filaments from the *Superficial Temporal* branch of the 5th; the inner layer is supplied by the *Tympanic Plexus*. (See Nerves of Tympanum.)

#### THE TYMPANUM.

**Describe the Tympanum.** The Tympanum, Drum, or Middle Ear, is an irregularly-shaped cavity lying between the membrana tympani and the internal ear, and communicating with the pharyngeal cavity by the Eustachian tube. It contains the ossicles of the tympanum, part of the chorda tympani nerve, and air. Its average diameters are about  $\frac{1}{2}$  inch antero-posteriorly,  $\frac{3}{8}$  to  $\frac{5}{8}$  inch vertically, and  $\frac{1}{2}$  to  $\frac{3}{8}$  inch transversely.

**Name the Points on each wall of the Tympanum.** Its—

**ROOF**,—is very thin, and corresponds to a depression on the anterior surface of the petrous portion of the temporal bone.

**FLOOR**,—is a thin plate, separating it from the jugular fossa and vein. Has—  
*Opening for Jacobson's Nerve*,—in the floor.

**OUTER WALL**,—is formed by the membrana tympani and presents the—  
*Iter Chordæ Posterioris*,—opens close to posterior edge of drumhead, for the entrance of the chorda tympani nerve.

*Iter Chordæ Anterioris, or Canal of Hugier*,—opening just in front of the drumhead, for the exit of the chorda tympani nerve. (See p. 16.)

*Glaserian Fissure*,—opens above and in front of the drumhead, receiving the long process of the malleus, the anterior ligament of the malleus, and the tympanic artery. (See *ante*, p. 15.)

**INNER WALL**,—is the outer wall of the labyrinth;—presents the—  
*Fenestra Ovalis*,—an oval opening, leading into the vestibule, and closed by a membrane, to which is attached the base of the stapes.

*Fenestra Rotunda*,—a smaller opening, below the fenestra ovalis, leading into the scala tympani of the cochlea, and closed by the *Membrana Tympani Secundaria*.

*Promontory*,—an elevation corresponding to the first turn of the cochlea, situated between the fenestræ and in front of them.

*Ridge of the Aqueductus Fallopii*,—above the fenestra ovalis, behind which it curves downwards along the posterior wall.

*Pyramid*,—a conical eminence containing a canal which communicates with the aqueductus Fallopii and encloses the stapedius muscle.

**ANTERIOR WALL**,—presents the—  
*Opening of Canal for the Tensor Tympani Muscle*,—above, situated on a small projection, the *Anterior Pyramid*.

*Opening of the Eustachian Tube*,—next below. These two canals being separated by a bony lamina, the *Septum Tubæ*.

*Processus Cochleariformis*,—the small end of the septum tubæ, projecting into the tympanum. (See p. 17.)

POSTERIOR WALL, separates it from the mastoid cells, and presents the—

*Openings of the Mastoid Cells.* *Ridge of the Aqueductus Fallopii*, curving downwards and nearly vertically. (See above.)

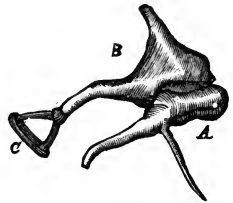
**Describe the Ossicles of the Tympanum.** They are three small bones, which form a chain across the tympanic cavity, connecting the membrana tympani with the fenestra ovalis, and named the—

*Malleus, or Hammer, A*—consists of a head, neck, short process, long process, or *Processus Gracilis*, and handle, or *Manubrium*. The short process and handle are fastened to the middle layer of the drumhead. The long process is received into the Glaserian fissure, and the head articulates with the head of the Incus.

*Incus, or Anvil, B*—has a head, also a long and a short process. The head articulates with the head of the malleus, the short process with the posterior wall of the tympanum, the long process with the head of the stapes, by the *Os Orbiculare*, its convex extremity.

*Stapes, or Stirrup, C*—presents a head, neck, base and crura. Its head articulates with the incus, its base rests on the membrane closing the fenestra ovalis, its neck receives the tendon of the stapedius muscle.

FIG. 107.



**Name the Ligaments of the Ossicles.** They are the—

*Ligamentum Mallei Anterioris*,—from the spina tympanica major to the neck and long process of the malleus.

*Lig. Mallei Externum*,—from the border of the Rivinian segment (p. 214), to the neck of the malleus. Its posterior fibres are the—

*Lig. Mallei Posticum*,—(*Laxator tympani minor* muscle of Sömmerring)—is simply the posterior group of fibres of the preceding ligament.

*Lig. Mallei Superius*,—(*Suspensory lig. of the malleus*) from the roof of the tympanum to the head of the malleus.

*Lig. Incudis Superius*,—from the roof of the tympanum to the head of the incus (Arnold).

*Lig. Incudis Posticum*,—from the posterior wall of the tympanum to the short process of the incus.

*Lig. Obturatorium Stapedium*,—a thin membrane which closes the opening between the crura of the stapes.

*Annular Ligament*,—connecting the base of the stapes to the margin of the fenestra ovalis.

*Capsular Ligaments*,—around the articulations between the ossicles themselves, which articulations are lined by synovial membranes, with articular cartilages between the contiguous surfaces.

**Name the Muscles of the Tympanum.** Three are usually described, —the *Tensor Tympani*, *Laxator Tympani*, and the *Stapedius*. A fourth, the *Laxator Tympani Minor*, is now generally omitted, being considered the posterior ligament of the malleus by most writers. Many otologists omit the *Laxator Tympani* from the list also. [These muscles are described on page 71.]

**What Arteries supply the Tympanum?** The—

*Tympanic*,—branch of the internal maxillary, entering the Glaserian fissure, anastomosing on the membrana tympani, in a vascular circle, with the Stylo-mastoid and Vidian arteries, and the Tympanic br. of the internal carotid.

*Stylo-mastoid*,—br. of the posterior auricular br. of the external carotid, entering at the stylo-mastoid foramen.

*Petrosal*,—br. of middle meningeal artery, entering by the hiatus Fallopii.

*Tympanic*,—br. from the internal carotid artery. (See p. 105.)

*Vidian*,—br. of the internal maxillary br. of the external carotid.

*Branches*,—from the ascending pharyngeal br. of the external carotid.

**Name the Nerves of the Tympanum.** The—

*Tympanic Br. of the Glosso-pharyngeal* (Jacobson's Nerve),—enters the tympanum through its floor, and supplies the two fenestræ and the mucous lining of the cavity, helping to form the *Tympanic Plexus* (see below).

*Tympanic Branch of the Facial Nerve*,—to the stapedius and laxator tympani muscles.

*Branch from the Otic Ganglion*,—to the tensor tympani muscle. [This ganglion is described on page 137.]

*Chorda Tympani Br. of the Facial*,—enters the tympanum by the iter chordæ posterius, crosses the cavity between the handle of the malleus and the long process of the incus, and makes its exit by the iter chordæ anterius, after passing close along the upper part of the membrana tympani.

**How is the Tympanic Plexus Formed?** By the—

*Tympanic Br. of the Glosso-Pharyngeal*,—or Jacobson's nerve.

*Branch of the Superficial Petrosal*, from the Facial,—entering from above.

*Branches from the Carotid Plexus* of the Sympathetic,—through the wall of the carotid canal.

The plexus lies in grooves on the inner wall around the promontory, and supplies the mucous membrane of the tympanum.



## THE EUSTACHIAN TUBE.

**What is the Eustachian Tube?** It is an osseo-cartilaginous canal, about  $1\frac{1}{2}$  inches long,  $\frac{1}{8}$  inch in diameter at tympanic end,  $\frac{1}{3}$  inch at pharyngeal, which leads downwards and forwards from the tympanic cavity into the pharynx. Of its length two-thirds is cartilaginous, one-third osseous. Above its bony portion is the canal for the tensor tympani muscle, from which it is divided by an osseous lamina, the *Septum Tubæ*. Its—

*Cartilaginous Portion*,—consists of two plates of cartilage, their non-approximated edges being connected by a membrane.

*Pharyngeal Orifice*,—is trumpet-shaped, and situated in the posterior nasal space, just above the nasal floor.

*Mucous Membrane*,—covered with the ciliated epithelium, and continuous with that of the pharynx and the tympanum.

**Describe the Muscles of the Eustachian Tube.** They are the—

*Spheno-salpingo-staphylinus*,—the abductor or dilator of the tube—is described as arising from the sphenoid bone and the cartilage of the tube, and being inserted into the convex border of the outer cartilage for its whole length.  
*Nerve*,—internal pterygoid.

*Levator Veli Palati*,—arises from the temporal bone and the cartilage of the tube,—into the osseous tube, the cartilage, and the mucous membrane.  
*Action*, to enlarge the transverse diameter of the tube. *Nerve*, pneumogastric.

*Salpingo-pharyngeus*,—a thin layer disposed along the median cartilaginous plate and the mucous membrane. *Action*, to fix the median cartilage. Called a fascia by some anatomists.

**What Arteries supply the Eustachian Tube?** The—

*Ascending Pharyngeal*,—branch of the external carotid.

*Middle Meningeal*,—branch of the internal maxillary br. of the ext. carotid.

*Branch*,—from the internal carotid artery.

**Name its Nerves.** Besides those which supply the muscles of the tube (see above), it has branches from the—

*Superior Pharyngeal.*

*Glosso-pharyngeal.*

## THE INTERNAL EAR.

**Name the Parts comprised in the Internal Ear.**

*Osseous Labyrinth*, consists of the

{ *Vestibule.*  
*Semicircular Canals.*  
*Cochlea.*

*Membranous Labyrinth*, comprises the

{	<i>Utricle.</i>
	<i>Membranous Semicircular Canals.</i>
	<i>Sacculæ.</i>
	<i>Membranous Cochlea.</i>

*Auditory Nerve*,—the 8th cranial nerve, or the *Portio Mollis* of the 7th.

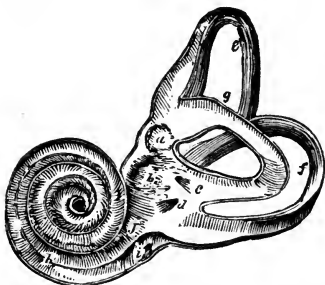*Organ of Corti*,—the terminal auditory apparatus.

*Internal Auditory Canal*,—by which the auditory nerve enters.

Describe the general arrangement of the **Internal Ear**. It lies internal to the tympanum, within the petrous portion of the temporal bone, and consists of a series of osseous chambers, the *Osseous Labyrinth*, containing a fluid, the *Perilymph*, or *Liquor Cotunnii*, in which lies a membranous reproduction of the chambers, the *Membranous Labyrinth*, which also contains a fluid, the *Endolymph*, or *Liquor Scarpæ*. Upon the membranous labyrinth are distributed the terminal filaments of the auditory nerve, which being suspended between two fluids, are not only protected from injury, but enabled to perceive the most delicate vibrations which may be communicated to the fluids surrounding them.

Describe the **Vestibule**. It is the common cavity of communication between the osseous parts of the internal ear, and measures in vertical diameter about  $\frac{1}{5}$  inch, laterally about  $\frac{1}{10}$  inch. It communicates in front with the scala vestibuli of the cochlea; and behind (by five openings) with the semicircular canals. It presents the following points, viz.:—the—

FIG. 108.



*Fenestra Ovalis*,—on its outer wall, closed by the base of the stapes and its annular ligament.

*Fovea Hemispherica*, *b*—a small circular depression on the inner wall, for the sacculæ.

*Macula Cricosa*,—are groups of very minute orifices on the inner wall, admitting the nerve filaments.

*Crista*, or *Pyramidal Eminence*,—a vertical ridge on the inner wall, bounding the fovea posteriorly.

*Aqueductus Vestibuli*, *d*—opens behind the crista, ending on the posterior surface of the petrous portion of the temporal bone. It contains a small blind canal opening by two arms, one into the utricle, the other into the sacculæ; also a small vein.

*Fovea Semi-elliptica*, *a*—a small oval depression on the roof, above and be-

hind the fovea hemispherica. It lodges the utricle, and presents a *Macula Cribosa* for the entrance of branches of the vestibular nerve.

**What are the Semicircular Canals?** They are three C-shaped bony tubes, each about  $\frac{1}{10}$  inch in diameter, situated above and behind the vestibule, into which they open by 5 apertures. Each canal lies at a right angle with the other two. The—

*Superior and Posterior Canals*,—are each nearly an inch long, vertically placed, joined together posteriorly where they open into the vestibule by a common orifice.<sup>c</sup>

*External Canal*, *g*—is  $\frac{1}{3}$  inch long, horizontally placed, and directed outwards and backwards.

*Ampulla*,—is a flask-shaped dilatation of each canal at one extremity, having a diameter of about  $\frac{1}{10}$  inch.

**Describe the Cochlea.** The Cochlea is a bony tube, about  $1\frac{1}{2}$  inch long, tapering from  $\frac{1}{10}$  to  $\frac{1}{20}$  inch in diameter, coiled around a central conical axis for  $2\frac{1}{2}$  turns, and resembling a snail shell in appearance. It measures about  $\frac{1}{4}$  inch in length and the same in breadth at the base. It is situated in front of the vestibule, its apex pointing forwards and outwards, and is separated from the carotid canal in front by a thin wall. Its—

*Modiolus*, *a*—is the central axis, conical in shape, channeled by small canals for the passage of arteries and nerves, and by a central one, the *Canalis Centralis Modioli*. Its apex is within the last coil of the cochlea, and is expanded into a funnel-shaped lamella, the *Infundibulum*.

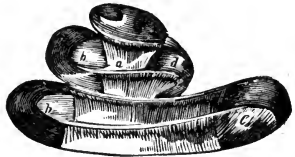

FIG. 109.

*Lamina Spiralis*, *b*—is a thin, osseous plate, projecting from the modiolus half way across the spiral canal, and winding around the modiolus terminates near the apex in a hook-like or *Hamular Process*. Its deficiency in the last half turn of the cochlea forms the *Helicotrema*, a space in which the *scalæ vestibuli* and *tympani* unite. (See below.) It consists of two laminae, <sup>1</sup>, <sup>2</sup>, between which pass the filaments of the cochlear nerve.<sup>10</sup> From its free edge the structures composing the membranous cochlea pass to their attachment on the opposite wall of the cavity. (See Fig. 111.)

*Spiral Canal*,—is the space between the modiolus and the outer wall of the cochlea. It makes  $2\frac{1}{2}$  turns,—from left to right in the right ear, from right to left in the left ear; and terminates in the *Cupola*, a cul-de-sac at the apex of the cochlea. It is divided, by the osseous lamina spiralis and

the membranous cochlea, into 2 Scalæ,—the *Scala Vestibuli*<sup>6</sup> and the *Scala Tympani*.<sup>7</sup> [Fig. III.]

[A third scala is described by many authorities, the *Scala Media*,<sup>8</sup> including the space occupied by the membranous cochlea. See Fig. III.]

**Describe the Scala Vestibuli.** It is the portion of the spiral canal lying above the lamina spiralis and the membranous cochlea; communicates with the vestibule below, and with the scala tympani above at the Helicotrema. It is filled with perilymph.

**What is the Scala Tympani?** It is the portion of the spiral canal lying below the lamina spiralis and the membranous cochlea, communicates with the aqueductus cochleæ (see below), and with the scala vestibuli at the *Helicotrema*. It terminates inferiorly at the fenestra rotunda, and is filled with perilymph.

**What is meant by the Helicotrema?** It is a space at the apex of the cochlea, formed by the deficiency of the lamina spiralis in the last half turn of the same. In this space the two scalæ are believed to open, thereby communicating with each other.

**What is the Aqueductus Cochleæ?** A small canal which begins by a small orifice in the lower wall of the scala tympani, and runs in the inner wall of the jugular fossa, ending at the edge between the inferior and inner surfaces of the petrous portion of the temporal bone. It transmits a vein from the cochlea to the jugular vein.

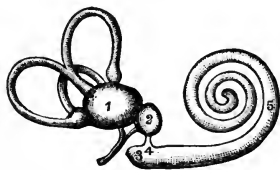
**What Parts are comprised in the Membranous Labyrinth?** It consists of two membranous sacs, the *Utricule*<sup>1</sup> and *Sacculæ*,<sup>2</sup> which lie in

the vestibule, together with the *Membranous Semicircular Canals*,<sup>6</sup> and the *Membranous Cochlea*.<sup>3, 5</sup> The utricule and sacculæ communicate with each other indirectly by a small canal contained in the aqueductus vestibuli. The sacculæ communicates with the membranous cochlea by the *Canalis Reuniens*,<sup>4</sup> and the membranous semicircular canals open into the utricule; so that the

membranous labyrinth presents an uninterrupted channel for the endolymph which it contains.

**What is the Utricule?** It is a flattened, elliptical membranous sac, fastened to the inner wall of the vestibule in the fovea semi-elliptica. It is filled with endolymph, nearly surrounded by perilymph, and communicates with the sacculæ through the small tube in the aqueductus vestibuli. The membranous

FIG. 110.



semicircular canals open into it by 5 orifices. The wall of the utricle has attached to it the—

*Otoliths, or Ear-stones*,—a powder, consisting of crystals of carbonate of calcium,  $\frac{1}{3000}$  to  $\frac{1}{2000}$  inch in diameter, held together by a mucoid substance.

*Macula Acoustica*,—See below, under *Sacculæ*.

**Describe the Membranous Semicircular Canals.** They are 3 canals, having the same shape as the osseous ones in which they are contained, being fastened thereto by their convex curves, and elsewhere surrounded by perilymph, except at the ampullæ, where they fill the osseous canals. They open into the utricle by 5 orifices.

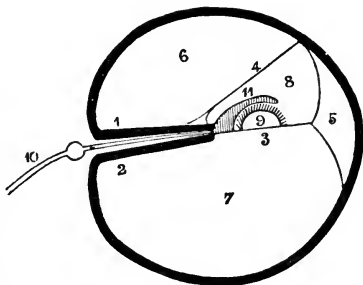
**What is the Sacculæ?** It is a flask-shaped, membranous sac, about  $\frac{1}{15}$  inch in diameter, attached at one point to the utricle, and also to the fovea hemispherica of the vestibule, being elsewhere surrounded by perilymph, and containing endolymph. It communicates with the utricle through the small canal in the aqueductus vestibuli, and also with the membranous cochlea by its neck, the—

*Canalis Reuniens*,—about  $\frac{1}{3}$  inch long and  $\frac{1}{12}$  inch in diameter, is V-shaped, its arms opening respectively into the sacculæ and the vestibular end of the membranous cochlea.

*Macula Acoustica*,—is a dense, circular point,  $\frac{1}{12}$  inch in diameter, on the wall of both the utricle and the sacculæ, formed by a thickening of the connective tissue where the fibres of the vestibular nerve enter it.

**Describe the Membranous Cochlea.** This portion of the membranous labyrinth, also called the *Ductus Cochlearis*, commences in the lower end of the osseous cochlea and send at its summit in a closed extremity. It is attached on one side to the lamina spiralis, on the other side to the outer wall of the osseous cochlea. It is formed by the *Membrana Basilaris*<sup>3</sup> below, the *Membrane of Reissner*<sup>4</sup> on one side, and the periosteum of the cochlear wall on the outer side, its cross section being of a triangular form. It is filled with endolymph, and contains the *Organ of Corti*<sup>9</sup> covered by the *Membrana Tectoria*.<sup>11</sup> The—

FIG. III.



*Limbus Laminae Spiralis*,—is the soft structure on the edge of the lamina spiralis, and lies in the membranous cochlea. It has two lips,—an upper.

or *Labium Vestibulare*, a lower, or *Labium Tympanicum*, with a furrow between them, called the *Sulcus Spiralis Internus*.

*Membrane of Reissner*,<sup>4</sup>—extends from the edge of the lamina spiralis to the outer cochlear wall, forming the vestibular wall of the membranous cochlea. Its outer insertion is the *Angulus Vestibularis*.

*Membrana Basilaris*,<sup>3</sup>—is the tympanic wall of the membranous cochlea, extending from the labium tympanicum of the lamina spiralis to the outer cochlear wall, where its insertion is called the *Ligamentum Spirale*,<sup>5</sup> or *Muscle of Todd and Bowman*. On it rests the *Organ of Corti*,<sup>9</sup>—covered by the —

*Membrana Tectoria*,<sup>11</sup>—extends parallel to the membrana basilaris from the labium vestibulare to the outer cochlear wall, where, according to some authorities, it is inserted, according to others it is free and rests directly on the organ of Corti, perhaps to act as a damper to its vibrations.

**Describe the Organ of Corti.** It is a peculiar arrangement of cartilaginous rods and epithelial hair cells, which is supposed to constitute the essential organ of hearing.<sup>9</sup> It lies on the membrana basilaris<sup>3</sup> and is covered by the membrana tectoria.<sup>11</sup> The—

*Rods of Corti*,—are arranged in two rows, resting, by their pedestals, on the membrana basilaris, and uniting with each other by their heads, so as to form an arched tunnel all along the membrane. Number of rods in inner row about 6,000, in outer row 4,500. Average diameter of the rods, from  $\frac{1}{25000}$  to  $\frac{1}{35000}$  inch.

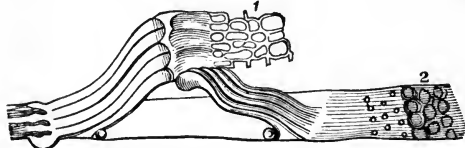
*Head-plates*,—are attached to the heads of the inner rods, for the reception of the rods of the opposite row.

*Lamina Reticularis*,<sup>1</sup>—a perforated delicate membrane which extends from

FIG. 112.

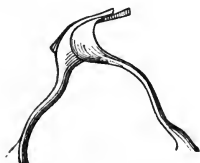

FIG. 113.



the articulations of the rods outwards to the external wall of the cochlea.

*Auditory Cells*,<sup>2</sup>—are epithelial structures covering the inner

surfaces of the walls and the floor of the membranous cochlea. Those which cover the inner rods by a single row number about 3,300, are nucleated, covered with tufts of cilia, and called the *Inner Hair-cells*. On the outer rods are 3 or 4 rows of similar cells, numbering about 18,000, and named the *Outer Hair-cells*.

*Rings and Phalanges*,<sup>1</sup>—are very minute structures which connect the ciliæ of the hair-cells together, and form the Lamina Reticularis. (See page 224.)

**Describe the Origin, Course and Distribution of the Auditory Nerve.** The 8th Cranial Nerve, or Portio Mollis of the 7th pair, arises by two roots from the medulla oblongata, one from the floor of the 4th ventricle, the other from a nucleus in the processus e cerebello ad medullam. It winds around the restiform body, from which it receives fibres, and emerges at the lower border of the pons, in company with the facial nerve. The two nerves pass into the internal auditory canal, at the bottom of which the auditory nerve divides into two branches, the vestibular and cochlear nerves. The—

*Vestibular Nerve*,—has a ganglionic swelling on it in the internal auditory canal, and then divides into 3 branches, which pass through the maculæ cribosæ, and are distributed to the utricle, saccule, and the ampullæ of the semicircular canals, respectively.

*Cochlear Nerve*,—gives off a small branch to the wall between the utricle and saccule, and then divides into numerous filaments which pass through the small canals into the modiolus, to form a plexus between the two plates of the lamina spiralis, from which filaments pass through the lower edge of the lamina to terminate in the spindle-shaped cells of the organ of Corti. (See page 224.)

*Intumescencia Ganglioniformis Scarpa*,—is the ganglionic swelling on the vestibular nerve in the internal auditory canal.

*Ganglion Spirale*,—is a ganglion found on each filament of the cochlear nerve, just as it enters between the plates of the lamina spiralis.

**What Arteries supply the Labyrinth?** The—

*Internal Auditory Artery*, br. of the basilar (from the vertebral),—accompanies the auditory nerve into the internal auditory canal, where it divides into vestibular and cochlear branches.

*Stylo-mastoid Artery*, br. of the posterior auricular (from the external carotid),—sends some small branches to the internal ear.

**Describe the Internal Auditory Canal.** It begins by a large orifice on the posterior surface of the petrous portion of the temporal bone, and runs outwards for  $\frac{1}{3}$  inch, to end in a blind fossa, the floor of which is marked by 4 depressions, which are perforated by fine foramina, for the passage of the filaments of the auditory nerve to the labyrinth. One of these depressions is the—

*Tractus Spiralis Forminosus*,—a spiral shaped depression containing a number of the above foramina, situated opposi the base of the cochlea.

*Macula Cribosa*,—are the other 3 depressions.

## HERNIA.

**What is a Hernia?** A protrusion of any viscus from its natural cavity. The term, when unqualified as to the viscus, is understood to mean a protrusion of the intestines or mesentery, or both, from the abdominal cavity.

**Name the Herniæ of most importance anatomically.**

*Oblique Inguinal Hernia*,—in which the protrusion follows the spermatic cord through the inguinal canal; passing to the outer side of the epigastric artery, and through both the internal and external abdominal rings.

*Direct Inguinal Hernia*,—occurs at Hesselbach's triangle, escaping to the inner side of the epigastric artery, and through the external abdominal ring only.

*Femoral Hernia*,—in which the protrusion descends through the femoral or crural canal.

## INGUINAL HERNIA.

**Where is the Inguinal Canal?** It is a passage in the abdominal wall, parallel to Poupart's ligament, and just above it. It commences at the internal abdominal ring<sup>5</sup> and ends at the external abdominal ring,<sup>1</sup> being about  $1\frac{1}{2}$  inch in length. It serves for the passage of the spermatic cord in the male, and the round<sup>4</sup> ligament of the uterus in the female; and is directed downwards and inwards. The—

*Internal Abdominal Ring*,<sup>5</sup>—is an oval opening in the transversalis fascia, formed by the prolongation of this fascia around the cord, as the infundibuliform fascia. It lies  $\frac{1}{2}$  inch above Poupart's ligament and midway between the anterior superior spine of the ilium and the spine of the pubes. It is bounded above and externally by the arched fibres of the transversalis muscle; below and internally by the epigastric vessels.

*External Abdominal Ring*,<sup>1</sup>—is a triangular opening in the aponeurosis of the external oblique muscle, situated just above and external to the crest of the pubes. It is about 1 inch long, and  $\frac{1}{2}$  inch wide, and is bounded laterally by its own margins, called the *Internal*<sup>4</sup> and *External*<sup>3</sup> Pillars of the ring. From these margins is given off the *Inter-columnar Fascia*, around the cord and testis.

**What are the Boundaries of the Inguinal Canal?**

*Anteriorly*,—the Skin, Superficial fascia, External oblique muscle, and the Internal oblique for its outer one-third.

*Posteriorly*,—the Conjoined tendon, Transversalis fascia, Triangular ligament, Sub-peritoneal tissue, and Peritoneum.

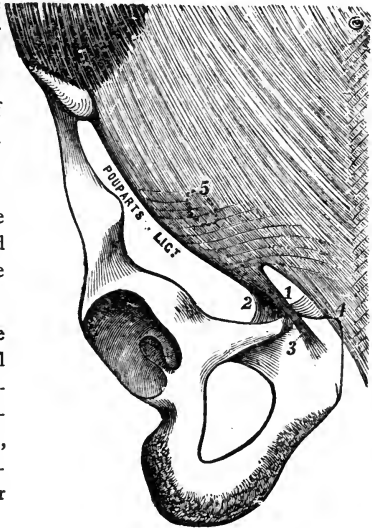
*Above*,—the arched fibres of the Internal oblique and Transversalis muscles.

*Below*,—Poupart's ligament, and the Transversalis fascia.



**What is Poupart's Ligament?** The Crural Arch or Poupart's Ligament is that portion of the aponeurosis of the external oblique muscle which extends from the anterior superior spine of the ilium to the spine of the pubes. Its lower portion<sup>3</sup> forms the external pillar of the external abdominal ring,<sup>1</sup> and its reflection along the pectineal line is called *Gimbernat's Ligament*.<sup>2</sup> Other fibres, reflected behind the internal pillar of the ring,<sup>4</sup> upward to the linea alba, are termed the *Triangular Ligament*.

FIG. 114.



**What is the Relation of the Epigastric Artery to the Internal Abdominal Ring?** The Epigastric artery lies between the transversalis fascia and the peritoneum, passing obliquely upwards and inwards along the lower and inner margins of the internal ring.<sup>5</sup>

**What is the Cremasteric Fascia?** It consists of a series of muscular loops, united by areolar tissue, and forming a thin covering over the spermatic cord. The muscular fibres (Cremaster muscle) are supposed to have been originally part of the Internal oblique muscle, but carried down by the testicle in its descent to the scrotum. It does not exist in the female.

**Name the Coverings of Inguinal Hernia.** In the oblique form of Inguinal Hernia the coverings are—

1. *Skin*.
2. *Superficial Fascia*,—2 layers.
3. *Intercolumnar Fascia*,—from the external abdominal ring.
4. *Cremasteric Fascia*,—from the inguinal canal.
5. *Infundibuliform Process* of the transversalis fascia,—from the internal abdominal ring.
6. *Peritoneum*,—the proper hernial sac.

In the direct form of Inguinal Hernia, the coverings are precisely the same, except that the *Conjoined Tendon* is substituted for the Cremasteric fascia, and the *Transversalis Fascia* for its Infundibuliform process.

A 7th covering is sometimes enumerated, viz. : the *Sub-serous Areolar Tissue*,

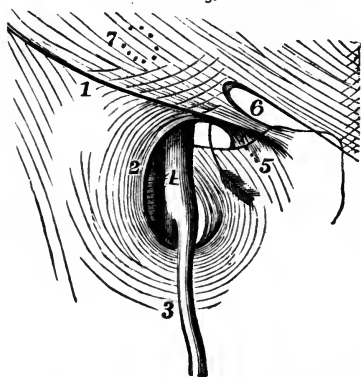
which would come before the peritoneum in the above list. It is not sufficiently dense to make an appreciable covering.

### FEMORAL HERNIA.

**Where and What is the Femoral Canal?** The Femoral or Crural Canal lies beneath Poupart's ligament,<sup>1</sup> close to the inner side of the femoral vein<sup>4</sup>; and extends from the *Femoral Ring* to the *Saphenous Opening* in the fascia lata of the thigh. It is a narrow interval between the femoral vein and the inner wall of the *Crural Sheath* or sheath of the vessels. The canal is  $\frac{1}{4}$  to  $\frac{1}{2}$  inch in length; is closed above by the *Septum Crurale*, below by the *Cribriform Fascia*; and contains only some loose areolar tissue and a few lymphatic vessels. The—

*Femoral or Crural Ring*,—is an oval-shaped opening, about  $\frac{1}{2}$  inch in

FIG. 115.



diameter (larger in the female), situated below the internal abdominal ring<sup>7</sup> and Poupart's ligament,<sup>1</sup> and between the inner side of the femoral vein and the margin of Gimbernat's ligament.<sup>5</sup> It is closed by the *Septum Crurale* and a small lymphatic gland. The arrow in the figure goes into the femoral ring.

*Saphenous Opening*,<sup>2</sup>—is an oval-shaped structure,  $1\frac{1}{2}$  inch long,  $\frac{1}{2}$  inch wide, situated below the inner third of Poupart's ligament, and formed by a reflection inwards of

the fascia lata around the end of the internal saphenous vein.<sup>3</sup> The outer margin curves over to the spine of the pubes, and is named the *Falciform Process*, or *Ligament of Burns*, its pubic end being often called the *Ligament of Hey*. The inner margin curves upwards behind the saphenous vein and under the outer margin, and is blended with the pubic portion of the fascia lata over the pectineus muscle. The opening is covered by the *Cribriform Fascia*.

#### What are the Boundaries of the Femoral Canal?

*Anteriorly*,—Poupart's ligament, Transversalis fascia, and the Falciform Process of the fascia lata.

*Posteriorly*,—Iliac fascia, and Pubic portion of the fascia lata.

*Externally*,—the Septum covering the femoral vein.

*Externally*,—Transversalis fascia, Iliac fascia, Gimbernat's ligament, and the deep Crural arch.

**Name the Structures in relation with the Femoral Ring.** The—

*Spermatic Cord*,—in the male, lies directly above its anterior margin, replaced by the round ligament in the female.

*Femoral Vein*,<sup>4</sup>—lies next on its outer side.

*Epigastric Artery*,—crosses its upper and outer angle.

*Obturator Artery*,—when arising from a common trunk with the epigastric, as it does once in  $3\frac{1}{2}$  subjects, may lie close along its internal and superior margins.

**What is the Septum Crurale?** A layer of condensed cellular tissue, supporting a lymphatic gland, and perforated for the passage of lymphatic vessels. It lies across the femoral ring, and forms one of the coverings to any hernia escaping thereby. It is sometimes named the *Fascia of Cloquet*, or *Fascia of Cooper*.

**Describe the Crural Sheath.** It is the sheath which invests the femoral vessels below Poupart's ligament, and is formed by a prolongation of the transversalis fascia anteriorly, and the iliac fascia posteriorly. It is divided by two septa into 3 compartments, the exterior of which contains the *Femoral Artery*, the middle one the *Femoral Vein*, while the one most internal is the *Femoral Canal*. The sheath is perforated anteriorly by the genito-crural nerve, internally by the internal saphenous vein, and forms one of the coverings of a femoral hernia.

**What is the Deep Crural Arch?** It is the lower thickened border of the transversalis fascia, which arches across the front of the crural sheath, and is intimately connected therewith. It seems to be attached externally to the centre of Poupart's ligament; internally it is inserted into the pectineal line behind the conjoined tendon.

**Name the Coverings of Femoral Hernia.** From without inwards its coverings are the—

1. *Skin*.
2. *Superficial Fascia*,—2 layers.
3. *Cribriform Fascia*,—from the saphenous opening.
4. *Crural Sheath*,—from the transversalis fascia.
5. *Septum Crurale*,—from the femoral ring.
6. *Peritoneum*,—the proper hernial sac.

## THE PERINEUM.

**What is the Perineum?** It is a triangular space containing the structures which close the pelvic outlet anterior to a line drawn between the tuberosities of the ischia. Posteriorly to this line the corresponding space is named the *Ischio-rectal Fossa*. The Perineum is bounded laterally by the rami of the pubes and ischia, anteriorly by the symphysis pubis, and posteriorly by the line above mentioned, which averages about  $2\frac{3}{4}$  inches in length.

[For the Muscles of the Perineum, see *ante*, p. 83.]

### THE MALE PERINEUM.

**What Fasciæ are met with in the Perineum?** The—

*Superficial Layer of the Superficial Fascia*,—is thick, loaded with fat, and continuous with the subcutaneous fascia of the thighs.

*Deep Layer of the Superficial Fascia*,—is thin but strong, continuous in front with the dartos of the scrotum, (?), attached on each side to the rami of the pubes and ischium; posteriorly it joins the deep perineal fascia under the transversus perinei muscle. It sends inwards a vertical septum which is incomplete in front. [This fascia is called by Professor Pancoast the “anterior leaflet of the triangular ligament.”]

*Anterior Layer of the Deep Perineal Fascia*,—is triangular in shape, and extends from the pubic arch and the sub-pubic ligament, laterally to the rami of the pubes and ischia, and posteriorly to the central tendinous portion of the perineum, where it becomes blended with the deep layer of the superficial fascia. It embraces the anterior part of the membranous portion of the urethra. [Called by Professor Pancoast, the “middle leaflet of the triangular ligament.”]

*Posterior Layer of the Deep Perineal Fascia*,—has the same attachments as the anterior layer above described, but in its course it embraces the posterior part of the membranous portion of the urethra, and is in connection with the apex of the prostate gland. [Called by Prof. Pancoast, the “posterior leaflet of the triangular ligament.”]

*Obturator Fascia*,—is the part of the pelvic fascia which covers the obturator internus muscle, and is continued on to the levator ani muscle as the *Ischio-rectal* or *Anal fascia*.

*Recto-vesical Fascia*,—is the portion of the pelvic fascia which invests the internal surface of the levator ani muscle, and the prostate gland, bladder, rectum, and vesiculæ seminales.

**What is Buck's Fascia?** It is a continuation of the Deep Layer of the Superficial Fascia of the Perineum, extending forwards upon the penis, and investing that organ completely as far as the glans. It is continuous above

with the suspensory ligament of the penis, and is held by some anatomists to prove that the deep layer aforesaid is not continuous in front with the dartos of the scrotum. This fascia was named from Dr. Buck, an American surgeon, who, in 1846, first insisted on the importance of this structure. It modifies the direction of urinary infiltration of the perineum, until perforated.

**What is the Triangular Ligament of the Urethra?** According to some authorities it is the anterior layer of the deep perineal fascia; according to others it includes the posterior layer also. Prof. Pancoast includes in the term "*Triangular Ligament*" all three layers which are united at the central tendinous portion of the perineum, including, therefore, the deep layer of the superficial perineal fascia.

**Name the Structures which lie between the Layers of the Deep Perineal Fascia.** In this space, which by some writers is termed the Cavity of the Triangular Ligament, are the—

*Membranous Portion of the Urethra.*

*Compressor Urethræ Muscle.*      *Artery of the Bulb.*

*Pudic Vessels and Nerve.*      *Nerve of the Bulb.*

*Cowper's Glands and Ducts.*      *Plexus of Veins.*

**What Structures lie behind the Posterior Layer of the Deep Perineal Fascia?** They are the—

*Bladder.*

*Rectum.*

*Prostate Gland.*

*Levator Anti Muscle.*

*Ischio-rectal, or Anal Fascia.*

**Enumerate the Structures situated between the Anterior Layer of the Deep Perineal Fascia and the Deep Layer of the Superficial Perineal Fascia.** They are as follows, the—

*Crura of the Penis.*

*Erector Penis Muscle.<sup>2</sup>*

*Corpus Spongiosum.*

*Transversus Perinei Muscle.<sup>3</sup>*

*Bulb of the Urethra.*

*Transversus Perinei Artery.*

*Accelerator Urinæ Muscle.<sup>1</sup>*

*Superficial Perineal Vessels.*

**Enumerate the Structures which are divided in the Lateral Operation of Lithotomy.** If the knife is inserted  $1\frac{1}{4}$  inch above the verge of the anus, and carried to a point  $\frac{3}{4}$  inch below that orifice, and about half-way outwards to the tuber ischii (*Gross*), it will divide the

*Skin and Superficial Fascia (1st Layer).*

*Inferior Hemorrhoidal Vessels and Nerves.*

*Deep Layer of the Superficial Fascia.*

*Superficial Perineal Vessels and Nerves.*

*Accelerator Urinæ Muscle<sup>1</sup> (posterior fibres).*

*Transversus Perinei Muscle<sup>3</sup> and Artery.*

*Anterior Layer of the Deep Perineal Fascia.*

*Compressor Urethrae Muscle* (a few fibres).

*Levator Ani Muscle* <sup>5</sup> (anterior fibres).

*Membranous and Prostatic Portions of the Urethra.*

*Posterior Layer of the Deep Perineal Fascia.*

*Prostate Gland* (in part only).

*Neck of the Bladder.*

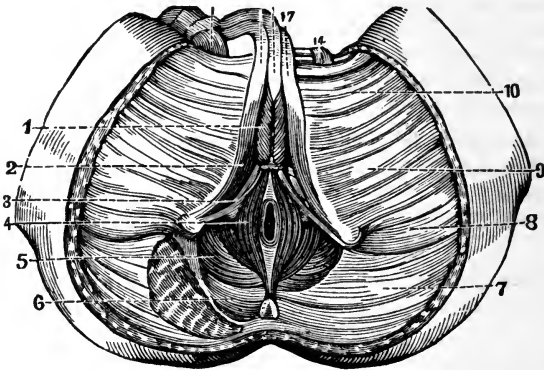
**What Parts are to be avoided in the Lateral Operation of Lithotomy?** They are the—

*Bulb and its Artery*,—in front.

*Rectum*,—inwardly and posteriorly.

*Pudic Artery*,—outwardly.

FIG. 116.



*Prostate Gland and Veins*,—by not carrying the deep incision too far backwards, the entire division of the left lobe of this gland will be avoided.

### THE FEMALE PERINEUM.

**What especial Function does the Female Perineum Perform?** That of supporting the posterior wall of the vagina, and thereby aiding materially in the support of the whole vagina, uterus and bladder. The—

*Perineal Body*,—is the pyramidal-shaped prolongation of the female perineum upwards between the vagina and rectum.

**Enumerate the chief points of Difference between the Female Perineum and that of the Male.** The—

*Orifice of the Vulva*, including the vaginal orifice,—perforates the female

perineum, its posterior commissure approaching the anal margin within about an inch.

*Superficial Fascia*,—is incomplete, by reason of its perforation by the orifice of the vulva, but consists of two layers, as in the male.

*Deep Perineal Fascia*,—being also perforated by the vagina, is less apparent than in the male, though presenting two layers, with the urethra perforating them, as in the other sex.

*Muscles*,—the Sphincter Vaginæ takes the place, in the female, of the Accelerator Urinæ of the male.

*Prostate Gland* is wanting,—but its place is occupied by a number of minute glands disposed around the neck of the bladder.

... ..

... ..

... ..

... ..

... ..

... ..

... ..

... ..

... ..

... ..

... ..

... ..



# APPENDIX TO POTTER'S ANATOMY.

---

## TABLES AND PLATES OF THE ARTERIAL AND NERVOUS SYSTEMS.

---

### ABBREVIATIONS.

Anas. . . . .	Anastomoses.	Inf. . . . .	Inferior.
Ant. . . . .	Anterior.	Int. . . . .	Internal.
Art. or A. . . . .	Artery.	L. . . . .	Left.
Asc. . . . .	Ascending.	M. . . . .	Middle.
Br. . . . .	Branch.	N. . . . .	Nerve.
Cerv. . . . .	Cervical.	Pl. . . . .	Plexus.
Com. . . . .	Common.	Post. . . . .	Posterior.
Commun. . . . .	Communicating.	R. . . . .	Right.
Desc. . . . .	Descending.	Sup. . . . .	Superior.
Ext. . . . .	External.	Superf. . . . .	Superficial.
	Trans. . . . .		Transverse.

---

NOTE—The arteries in the following plates should be colored red, by painting them over with ordinary crimson ink, or water-color paint, using a fine camel's-hair brush for the purpose.

## THE ARTERIAL SYSTEM.

1. Pulmonary Artery. (Plate I.) { R. PULMONARY ART. (Plate 3)  
L. PULMONARY ART. (Plate 3) } Numerous branches throughout the pulmonary tissue, carrying Venous blood.

2. Arch of Aorta. (Plate I.) { R. CORONARY } to the muscular tissue of the heart.  
L. CORONARY }  
INNOMINATE { R. COMMON CAROTID { *Ext. Carotid* (3).  
*Int. Carotid* (4).  
R. SUBCLAVIAN becomes *Axillary* (9) { *Vertebral* (5).  
*Thyroid Axis* (6).  
*Int. Mammary* (7).  
*Sup. Intercostal* (8).  
L. COMMON CAROTID, . . Same as R. Common Carotid.  
L. SUBCLAVIAN, . . Same as R., continuing as *Axillary* (9).

3. External Carotid. (Plate I.) { SUPERIOR THYROID. { *Hyoid*, along lower border of os hyoides.  
*Superf. Descending*, crosses Com. Carotid.  
*Sup. Laryngeal*, to larynx and epiglottis.  
*Inf. Laryngeal*, crosses Crico-thyroid membr.  
LINGUAL. . { *Hyoid*, along upper border of bone.  
*Dorsalis Linguae*, to tongue, tonsil, palate, etc.  
*Sublingual*, to gland, mouth, gums.  
*Ranine*, under surface of tongue, to tip.  
FACIAL. . . { *Inf. (Asc.) Palatine*, { *Br.* to soft palate.  
*Br.* to tonsil.  
*Tonsillar*, to tonsil and root of tongue.  
*Submaxillary*, to gland, skin, muscles.  
*Submental* { *Superf. Br.* anas. inf. labial.  
*Deep Br.* to the lip.  
*Muscular*, to pterygoid, masseter, buccinator.  
*Inf. Labial*, anas. with br. of 7th and 5th N.  
*Inf. Coronary*, anas. with br. of inf. dental art.  
*Sup. Coronary*, { *Art. of Septum Nasi*.  
*Br.* to ala of nose.  
*Lateralis Nasi*, to ala and dorsum of nose.  
*Angular*, termination of facial trunk.  
OCCIPITAL. { *Muscular*, to digastric, stylo-hyoid, sterno-mastoid, etc.  
*Auricular*, to back part of concha.  
*Inf. Meningeal*, to dura mater in post. fossa.  
*Princeps Cervicis* { *Superf. Br.* anas. superf. cervical.  
*Deep Br.* anas. vertebral, and deep cerv. br. of sup. intercostal.







## THE ARTERIAL SYSTEM.—Continued.

<b>3.</b> <b>External</b> <b>Carotid.</b> <i>(Continued.)</i>	}	Post. Auricular.	{	<i>Branches</i> (small), to muscles and glands.		
		Ascending Pharyngeal.		{	<i>Stylo-mastoid</i> { <i>anas.</i> with Tympanic of Int. Maxil. forming vascular circle around tympanum.	
					<i>Auricular</i> , to cartilage of ear.	
		TEMPORAL. . . .	{	<i>Transverse Facial</i> , lies on the masseter.		
				<i>Anterior Auricular Branches</i> , to pinna, etc.		
				<i>Middle Temporal</i> , supplies that muscle. <i>Anterior Temporal</i> . Its brs. directed backward. <i>Posterior Temporal</i> , along side of head.		
		INTERNAL MAXILLARY Divisions :	}	<ol style="list-style-type: none"> <li>1. <i>Maxillary</i>.</li> <li>2. <i>Pterygoid</i>.</li> <li>3. <i>Spheno-maxillary</i>.</li> </ol>	{	<i>Tympanic</i> { to memb. tympani, <i>anas.</i> with Stylo-mastoid and Vidian arteries.
						<i>Mid. Meningeal</i> , to dura and cranial bones.
						<i>Small Meningeal</i> , to dura and Gasserian gang.
						<i>Inferior Dental</i> {
<i>Incisor</i> , } Terminal Brs. <i>Mental</i> , }						
1	{					<i>Deep Temporal</i> (2), under temporal muscle.
						<i>Pterygoid Brs.</i> , to pterygoid muscles.
						<i>Masseteric</i> , to deep surface of masseter. <i>Buccal</i> , a small br. to buccinator.
2	{					<i>Alveolar</i> { <i>Supr. Dental</i> , to molars, bicuspid.
						<i>Branches</i> , to antrum, gums, etc.
		<i>Infraorbital</i> , has several brs. in canal.				
		<i>Post. (Desc.) Palatine</i> , to palate, glands, etc.				
		<i>Vidian</i> , to Eustachian tube and pharynx.				
		<i>Pterygo-palatine</i> , to Eustach. tube and pharynx.				
3	{	<i>Spheno-Palatine</i> { <i>Artery of Septum</i> , to septum.				
		<i>or Nasal.</i> } <i>External Branches</i> (3), to the nares, antrum, ethmoid and sphenoid cells.				

## THE ARTERIAL SYSTEM.—Continued.

4. Internal Carotid. (Plate 1.)	} <i>Tympanic</i> , to tympanum by foramen in carotid canal. <i>Arteria Receptaculi</i> (several), in cavernous sinus. <i>Ant. Meningeal</i> , to dura, anas. mid. meningeal.	} OPTHALMIC. Groups, 1. <i>Orbital</i> . 2. <i>Ocular</i> . (Plate 4.) Fig. 2.	} 1	} <i>Lachrymal</i> , to that gland, lid, etc. <i>Supraorbital</i> , the largest sub-branch. <i>Post. Ethmoidal</i> { <i>Meningeal</i> , to dura. { <i>Nasal Brs.</i> , to nose.	} <i>Ant. Ethmoidal</i> , has same branches. <i>Sup. Palpebral</i> , arch on margin of lid. <i>Inf. Palpebral</i> , margin of lower lid. <i>Frontal</i> , to muscles, skin } Terminal { <i>Dorsalis Nasi</i> , } Brauches.
} <i>Anterior Cerebral</i> { <i>Ant. Communicating</i> , 2 lines long.	} <i>MIDDLE CEREBRAL</i> { <i>Anterior</i> , to anterior lobe of brain. { <i>Posterior</i> , to middle lobe of brain. { <i>Median</i> , to the island of Reil.	} <i>Posterior Communicating</i> , { anas. with Post. Cerebral of Basilar, to { form the circle of Willis.	} <i>Anterior Choroid</i> , to the choroid plexus, etc.		

## THE CIRCLE OF WILLIS.

BASILAR	} <i>Post. Cerebral</i> } <i>Post. Commun.</i> { <b>MIDDLE CEREBRAL</b> } <i>Ant. Cerebral</i> }	} <i>Post. Cerebral</i> } <i>Post. Commun.</i> { <b>MIDDLE CEREBRAL</b> } <i>Ant. Cerebral</i> }	} <i>Ant. Commun.</i>

## THE ARTERIAL SYSTEM.—Continued.

5. VERTEBRAL. (Plate 1.)
- Lateral Spinal* { *Br.* to spinal cord and membranes.  
                  *Br.* to bodies of Vertebrae posteriorly.
  - Muscular Branches*, to deep cervical muscles.
  - Post. Meningeal*, ramify between dura mater and skull.
  - Anterior Spinal*, { joins its fellow to form Ant. Median Artery of the  
                          spinal cord.
  - Posterior Spinal*, to spinal cord and membranes, laterally.
  - Inferior Cerebellar* { *Internal* } to cerebellum, and choroid plexus  
                          { *External* } of the 4th Ventricle.
- BASILAR.
- { *Transverse Brs.* { *Auditory*, to that canal.  
                          *Ant. (Inferior) Cerebellar*.
  - { *Superior Cerebellar*, to pia mater, pineal gland, etc.
  - { POSTERIOR CEREBRAL { *Post. Choroid*, to choroid plexus.  
                                  *Branches*, to posterior lobes of  
                                  cerebrum, anas. with Ant. and  
                                  Mid. Cerebral Arteries.
- 
6. THYROID AXIS. (Plate 1.)
- { *Inferior Thyroid*. . . { *Laryngeal*, to posterior muscles of larynx.  
                                  *Tracheal Brs.* to trachea, anas. Bronchial.  
                                  *Cesophageal Brs.* to œsophagus.  
                                  *Ascending Cervical*, to muscles, spinal cord.
  - { *Transversalis Colli*. . . { *Superficial Cervical*, beneath Trapezius.  
                                  *Posterior Scapular*, along post. border.
  - { *Supra-scapular*. . . { *Supra-acromial*, anas. Acromial Thoracic.  
                                  *Communicating*, across neck of scapula.
- 
7. INTERNAL MAMMARY. (Plate 1.)
- { *Comes Nervi Phrenici (Superior Phrenic)*, to Diaphragm.
  - { *Mediastinal Brs.* to connec. tissue, ant. mediastinum.
  - { *Pericardiac Brs.* to upper part of pericardium.
  - { *Sternal Brs.* to sternum and Triangularis sterni.
  - { *Anterior Intercostals*, to 5 or 6 upper intercostal spaces.
  - { *Perforating*, to Pectoralis major, mammary gland, etc.
  - { *Musculo-phrenic* { *Ant. Intercostals*, to lower spaces.  
                          *Brs.* to lower pericardium, Diaphragm, etc.
  - { *Superior Epigastric* { anas. Epigastric of Ext. Iliac.  
                                  supplies Rectus abdominis, etc.
- 
8. SUPERIOR INTERCOSTAL. (Plate 1.)
- { *Profunda Cervicis*, ascends along back of neck, to axis; anas. with  
                          Art. princeps cervicis of Occipital.
  - { *Brs.* to 1st and 2d intercostal spaces, giving br. to post. spinal mus-  
                          cles. and one to spinal cord, and anas. with Aortic Intercostals.



## THE ARTERIAL SYSTEM.—Continued.

9. Axillary.  
(Plate 2.)
- 1 from 1st part.  
2 " 2d "  
3 " 3d "
1. *Superior Thoracic*, to Pectoral muscles and wall.  
*Acromial Thoracic* { *Thoracic Brs.* to Pectorals.  
*Acromial Brs.* to Deltoid.  
*Descending*, to both these muscles.
  2. { *Thoracica Longa*, to Serratus, Pectorals and gland.  
*Thoracica Alaris*, to glands of axilla.
  3. SUBSCAPULAR. { *Dorsalis Scapulae*, { Subscapular.  
{ Infra-spinous.  
{ Median.  
*Main trunk* to inf. angle of the scapula.
  3. *Anterior Circumflex*, { around neck of humerus, to Deltoid.  
{ Br. to shoulder-joint.
  - Posterior Circumflex* { around neck of humerus, to Deltoid  
{ muscle and shoulder-joint.
- Becomes BRACHIAL (10), at lower margin of tendon of the *Teres major* muscle.

10. Brachial.  
(Plate 2.)
- SUPERIOR PROFUNDA, { *Post. Articular*, to elbow, and inner side  
of arm.  
*Main trunk*, in spiral groove of the  
humerus, to Deltoid, Triceps, etc.
  - Nutrient*, to nutritious canal of humerus.
  - Inferior Profunda*, to inner condyle and olecranon.
  - ANASTOMOTICA MAGNA, transversely inwards on *Brachialis anticus* muscle, anas. with several arteries.
  - Muscular*, 3 or 4, to muscles in course of artery.
  - Bifurcates into RADIAL (11) and ULNAR (12), about ½ inch below the bend of the elbow.

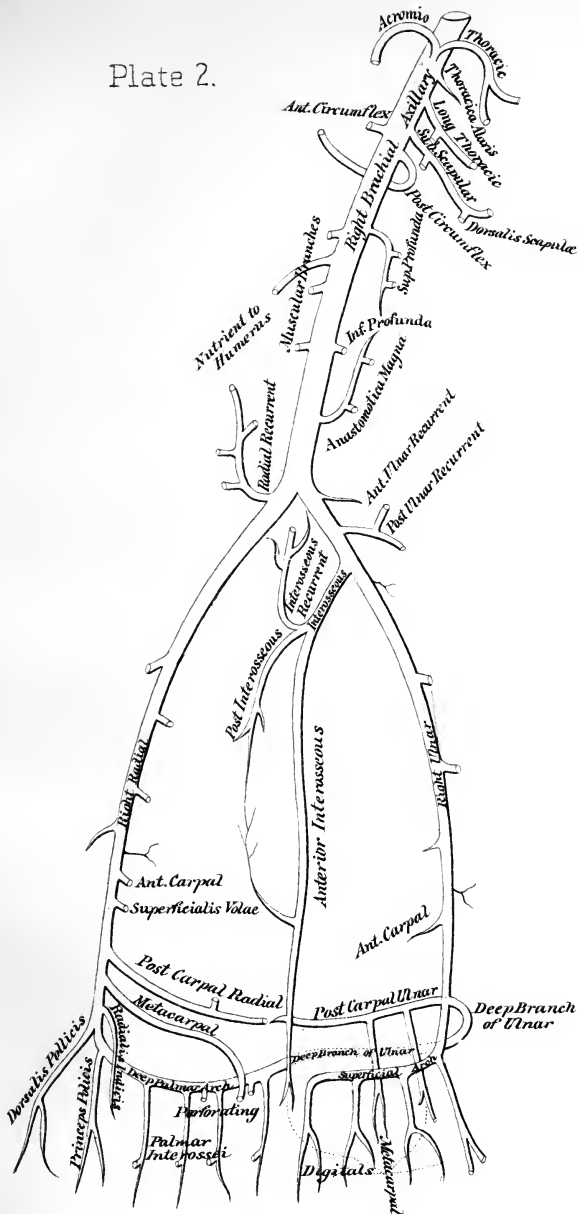
11. Radial.  
(Plate 2.)
1. In forearm.  
2. In wrist.  
3. In hand.
  1. *Radial Recurrent*, anas. branches of Sup. profunda.  
*Muscular Brs.* to muscles on radial side of arm.  
*Superficialis Volæ*, { to muscles of thumb, anas. with Ulnar  
{ Art. completing Superf. Palmar Arch.  
*Ant. Carpal*, to wrist-joints, anas. Ant. Carpal of Ulnar.
  2. *Post. Carpal* { to wrist-joints, anas. Post. Carpal of Ulnar.  
{ *Dorsal Interosseous*, for 3d and 4th spaces.  
*Metacarpal*, is the First Dorsal Interosseous Branch.  
*Dorsales Pollicis* (2), laterally on dorsum of thumb.  
*Dorsalis Indicis*, on radial side of index dorsum.
  3. *Princeps Pollicis*, { 2 Brs. forming arch on last phalanx.  
*Radialis Indicis*, along radial side of index finger.  
*Perforantes* (3) between heads of last Dorsal Interossei.  
*Palmar Interosseæ* { (3 or 4) along Interossei muscles, given  
{ off by Deep Palmar Arch.
- Forms DEEP PALMAR ARCH in the hand, by inosculating with the Communicating from the Ulnar, at the base of the metacarpal bone of the little finger.

## THE ARTERIAL SYSTEM.—Continued.

12. **Ulnar.**  
(Plate 2).
1. In forearm.  
2. In wrist.  
3. In hand.
1. **INTEROSSEOUS** { *Anterior Ulnar Recurrent*, ascends in front of inner condyle.  
*Posterior Ulnar Recurrent*, ascends behind inner condyle.
- { **ANTERIOR INTEROSSEOUS** { pierces Interosseous membrane, descending to back of wrist.  
    { *Muscular Branches.*  
    { *Nutrient*, of both bones.  
    { *Br.* on Pronator quadratus.  
    { *Median*, along median n.  
    { *Posterior Interosseous* { to back of wrist.  
    { *Post. Interosseous Recurrent*, to ext. condyle of humerus.
- { *Muscular*, to muscles on ulnar side of arm.
2. { *Anterior Carpal*, to joints, anas. Carpal of Radial.  
    { *Posterior Carpal*, { to joints of wrist, anas. Carpal of Radial.  
    { *Br.* forming *Post. Carpal Arch*.
3. { *Deep (Communicating)* { anas. with termination of Radial Artery, forming the *Deep Palmar Arch*.  
    { *Digital* (4), { from convexity of Superf. Palmar Arch, to ulnar side of little finger, and adjoining sides of ring, middle, and index fingers (rest supplied by radial).
- FORMS SUPERFICIAL PALMAR ARCH in palm of hand, by inosculating with Superficialis Volæ of Radial Artery.

13. **Thoracic Aorta.**  
(Plate 3.)
- { *Bronchial Arteries* (3) nutrient vessels of the lungs.  
    { *Œsophageal*, (4 or 5) anas. brs. Inf. Thyroid, Phrenic, Gastric.  
    { *Pericardiac*, Brs. distributed to the pericardium.
- { **INTERCOSTAL** (20) { **ANTERIOR (Proper)** { *Br.* along lower border of rib.  
    { { *Br.* along upper border of rib.  
    { **POSTERIOR (Dorsal)** { *Spinal*, to vertebræ, cord, etc.  
    { { *Muscular*, to tissues of back.
- { *Posterior Mediastinal*, (several) to glands, etc., in mediastinum.

Plate 2.





MEMORANDUM FOR THE RECORD

Subject: [Illegible]

Reference is made to [Illegible]

[Illegible]

[Illegible]

[Illegible]

[Illegible]

[Illegible]

[Illegible]

[Illegible]

[Illegible]

[Illegible]

[Illegible]

[Illegible]

[Illegible]

[Illegible]

[Illegible]

[Illegible]

[Illegible]

[Illegible]

[Illegible]

[Illegible]

[Illegible]

[Illegible]

[Illegible]

[Illegible]

[Illegible]

[Illegible]

[Illegible]

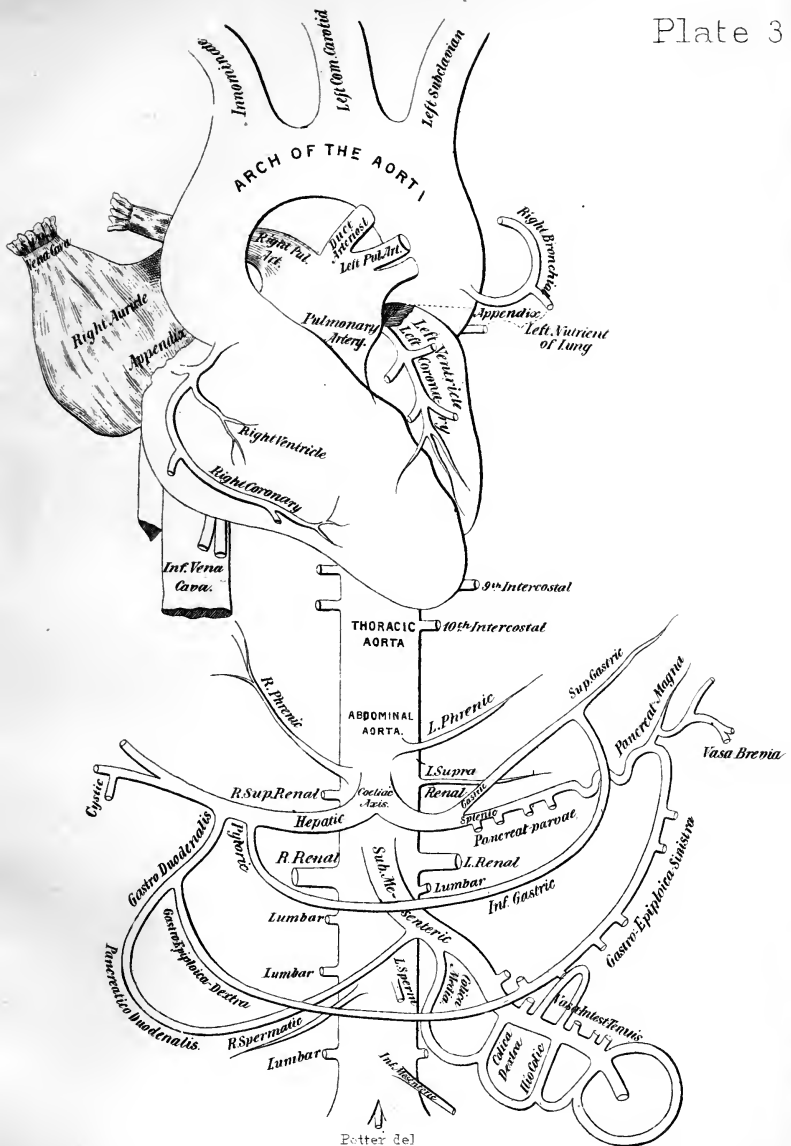
[Illegible]

[Illegible]

[Illegible]

## THE ARTERIAL SYSTEM.—Continued.

	<i>Phrenic</i>	{	<i>Internal</i> , to front of thorax and Diaphragm.	
		{	<i>External</i> , to side of thorax.	
	CELIAC AXIS.	{	GASTRIC, {	
				to cardiac orifice of stomach, cardiac end, then along lesser curvature to pylorus, where it anas. with Pyloric Br. of Hepatic Art.
		{	HEPATIC	<i>Pyloric</i> , to pylorus, anas. Gastric Art.
				<i>Gastro-duodenalis</i> , {
			{	<i>Gastro-epiploica Dextra</i> , along greater curvature.
			{	<i>Pancreatico-duodenalis</i> , to those organs.
			<i>Cystic</i> , br. R. Hepatic, to gall-bladder.	
	SPLENIC	{	<i>Pancreaticæ Parvæ</i> } to the pancreas.	
			<i>Pancreatica Magna</i> }	
		{	<i>Gastric (Vasa Brevia)</i> , 5 to 7, to the greater curvature of stomach.	
			<i>Gastro-epiploica Sinistra</i> , along the greater curvature, from left to right.	
			<i>Terminal Brs</i> enter hilum of Spleen.	
14. Abdominal Aorta. (Plate 3.)	SUPERIOR MESENTERIC	{	<i>Inferior Pancreatico-duodenal</i> , to those organs.	
			<i>Vasa Intestini Tenuis</i> (12 to 15) form arches in mesentery, in several series, from terminal arches branches ramify on intestines.	
			<i>Ileo-colic</i> {	
			{	
			<i>Inferior</i> , anas. <i>Vasa intes. ten.</i>	
			<i>Superior</i> , anas. <i>Colica dextra.</i>	
			<i>Colica Dextra</i> {	
			{	
			<i>Desc. Br.</i> } Arches branching to ascending colon.	
			<i>Asc. Br.</i> }	
			<i>Colica Media</i> {	
			{	
			<i>Right</i> } Arches, branching to trans-	
			<i>Left</i> } verse colon.	
			SUPRA-RENAL, to supra-renal capsule.	
			RENAL. {	
			{	
			<i>Brs.</i> to substance of kidney.	
			<i>Small Brs.</i> to capsule, ureter, etc.	
			SPERMATIC (or OVARIAN) to testes or ovaries.	
	INFERIOR MESENTERIC	{	<i>Colica Sinistra</i> {	
			{	
			<i>Asc.</i> } Arches branching to de-	
			<i>Desc.</i> } scending colon.	
			<i>Sigmoid</i> , across Psoas to that flexure of colon.	
			<i>Sup. Hemorrhoidal</i> , {	
			{	
			<i>Br.</i> to right } side of rectum.	
			<i>Br.</i> to left }	
	Lumbar (4)	{	to muscles, etc., of back.	
			{	<i>Dorsal</i> }
				<i>Spinal</i> , to canal {
			<i>Br.</i> } Arches.	
			<i>Br.</i> }	
			<i>Abdominal</i> , between abdominal muscles.	
			<i>Middle Sacral</i> , to coccyx, anas. Lateral Sacral.	
			Bifurcates . . {	
			{	
			RIGHT COM. ILIAC, <i>R. Int. and Ext. Iliac</i> (15, 16).	
			LEFT COM. ILIAC, <i>L. Int. and Ext. Iliac</i> (15, 16).	
			Bifurcation occurs at 4th Lumbar Vertebra, opposite Umbilicus.	



Potter del







## THE ARTERIAL SYSTEM.—Continued.

15.	Internal Iliac. ANTERIOR TRUNK. (Plate 4.)	OBTURATOR.	<i>Superior Vesical</i> { <i>Art. of Vas Deferens</i> , to that organ. <i>Middle Vesical</i> , to base of bladder. <i>Inferior Vesical</i> , to base of bladder, prostate gland, etc. <i>Middle Hemorrhoidal</i> , to rectum, anas. other hem. arteries. <i>Uterine</i> , to neck of uterus { <i>Brs. to bladder.</i> <i>Brs. to ureter.</i> } In the female. <i>Vaginal</i> , analogous to Inf. Vesical in male.
			INTERNAL PUDIC.
		SCIATIC.	<i>Inf. (Ext.) Hemorrhoidal</i> , 2 or 3 to anus. <i>Superf. Perineal</i> , to scrotum, etc. <i>Transverse Perineal</i> , to muscle of same name. <i>Artery of the Bulb</i> , large but very short. <i>Art. of Corpus Cavernosum</i> , to that body. <i>Dorsal Artery of the Penis</i> , thereto.  <i>Muscular Brs.</i> within the pelvis. <i>Hemorrhoidal Brs.</i> to the rectum. <i>Vesical Brs.</i> to base and neck of bladder. <i>Coccygeal</i> , to back of coccyx. <i>Inf. Gluteal</i> (3 or 4) to Gluteus maximus. <i>Comes Nervi Ischiadici</i> , along sciatic nerve. <i>Muscular Brs.</i> to back of hip. <i>Articular Brs.</i> to capsule of joint.

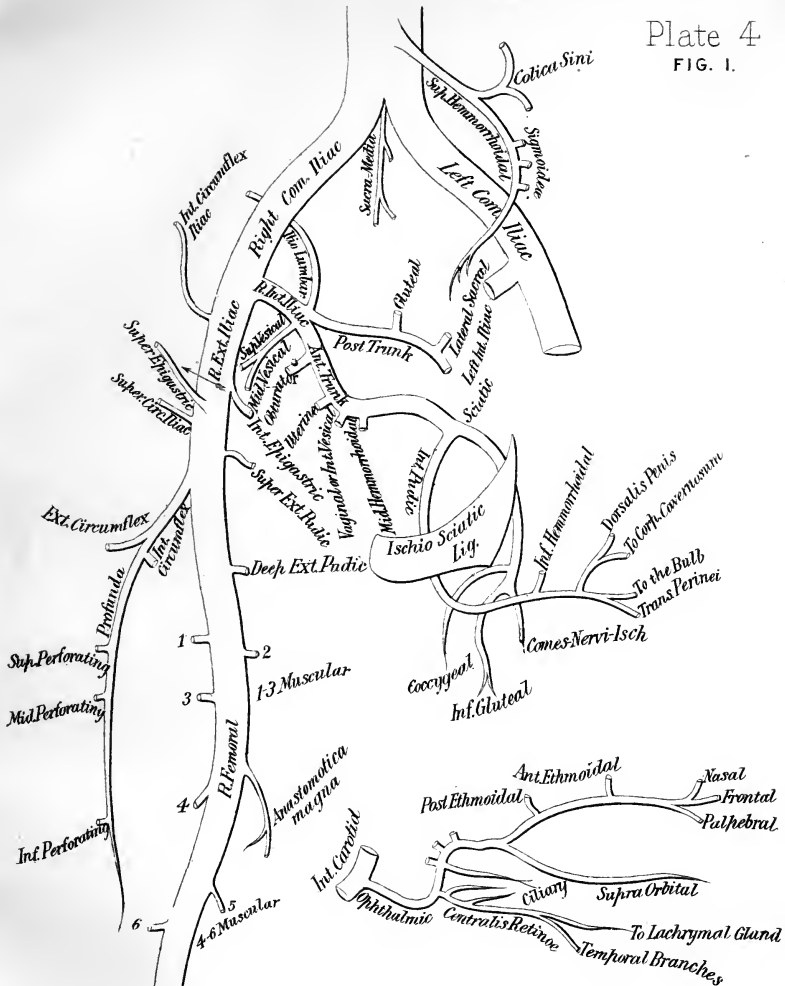


FIG. 2.

BRANCHES OF OPHTHALMIC ARTERY.



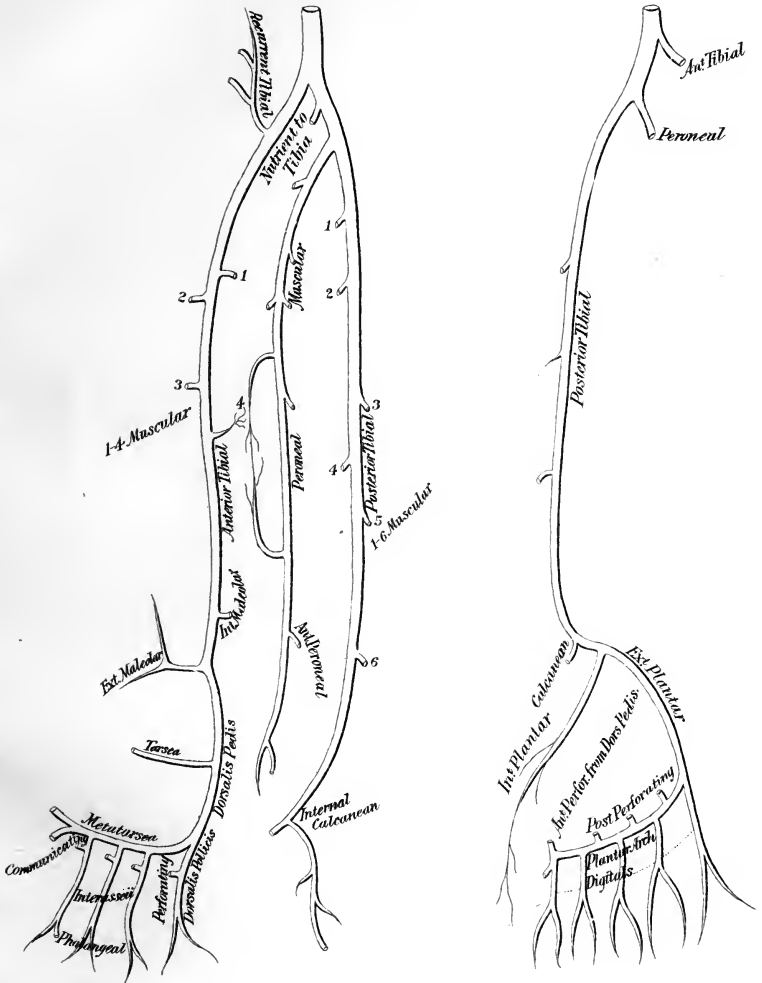


## THE ARTERIAL SYSTEM.—Continued.

15.  
Internal Iliac.  
POSTERIOR  
TRUNK.
- GLUTEAL {
    - Muscular Brs.* within the pelvis.
    - Nutrient*, of the Ilium.
    - Superficial*, to Gluteus maximus, etc.
    - Deep* {
      - Superior*, to ant. sup. spine of Ilium.
      - Inferior*, to glutei and hip-joint.
  - ILIO-LUMBAR . {
    - Iliac*, to Iliacus internus and Ilium.
    - Lumbar* . {
      - to Psoas and Quad. lumborum.
      - Spinal Br.* to cord and membranes.
- Superior Lateral Sacral*, to dorsum of sacrum.  
*Inferior Lateral Sacral*, to front of sacrum, and coccyx, anas with Sacra media, etc.
- 

16.  
External Iliac.  
(Plate 4.)
- Muscular Brs.* several, to Psoas and glands.
  - EPIGASTRIC {
    - Cremasteric*, to cremaster muscle.
    - Pubic*, to inner side of femoral ring.
    - Muscular*, to abdominal muscles and skin.
  - CIRCUMFLEX ILIAC. {
    - betw. Transversalis and Int. oblique.
    - Br.* anas. with Lumbar and Epigastric.
- Becomes FEMORAL (17) at Poupart's Ligament.
- 

17.  
Femoral.  
(Plate 4.)
- Superficial Epigastric*, in superf. fascia, to umbilicus.
  - Superf. Circumflex Iliac*, outwards to iliac crest.
  - Superf. Ext. Pudic*, inwards to skin of penis, scrotum, etc.
  - Deep Ext. Pudic*, inwards to skin of perineum, etc.
  - PROFUNDA FEMORIS. {
    - Ext. Circumflex* {
      - Asc. Brs.* outer side of hip.
      - Transverse*, to back of hip.
      - Descending*, as far as knee.
    - Int. Circumflex* {
      - Ascending*, to Adductors, etc.
      - Descending*, to Adductors, etc.
      - Articular*, to head of femur.
    - Perforating* {
      - Superior*, pierces Adductor magnus.
      - Middle* {
        - Nutrient of Femur.*
      - Inferior*, pierces Adductor magnus.
  - Muscular* (2 to 7), along course of the artery.
  - ANASTOMOTICA MAGNA, {
    - Superficial Br.* to integument.
    - Deep Br.* to inner side of Knee and joint.
- Becomes POPLITEAL (18), at opening in Adductor magnus.









## THE ARTERIAL SYSTEM.—Continued.

18. Popliteal. (Plate 4.)
- Muscular* { *Superior Brs.* to Vastus ext. and flexor muscles.  
*Inferior or Sural* (2), to Gastrocnemius and Plantaris.  
*Cutaneous Brs.* to integument of calf.  
*Superior Internal Articular*, to Vastus int. and joint.  
*Superior External Articular*, to Vastus ext. and joint.  
*Azygos Articular*, to synovial membrane of joint.  
*Inferior Internal Articular*, to head of tibia and joint.  
*Inferior External Articular*, to front of knee-joint.
- Bifurcates into { ANTERIOR TIBIAL (19) } at lower border  
{ POSTERIOR TIBIAL (20) } Popliteus muscle.
- 
19. Anterior Tibial, (Plate 5.)
- Recurrent Tibial*, on front and sides of knee-joint.  
*Muscular Brs.* numerous to muscles of leg.  
*Internal Malleolar*, beneath tendon of Tibialis anticus.  
*External Malleolar*, to outer ankle.
- DORSALIS PEDIS { *Tarsæa*, to tarsal joints and Ext. brev. digit.  
*Metatarsæa* { 3 *Interosseæ*, { Dorsal Br.  
{ Dorsal Br.  
*Dorsalis Hallucis* { Br. to inner of great toe.  
{ Br. to great and 2d toes.  
*Communicating*, { anas. Ext. Plantar (Arch).  
{ 2 Digital Brs.
- Ends in the PLANTAR ARCH.
- 
20. Posterior Tibial. (Plate 5.)
- PERONEAL { *Anterior Peroneal*, pierces interosseous membrane.  
*Nutrient of Fibula*, to that bone.  
*Muscular Brs.* in its course.
- Muscular*, to Soleus, etc., on back of leg.  
*Nutrient of Tibia*, the largest nutrient artery of bone.  
*Communicating Br.* to the Peroneal, near its end.  
*Internal Calcanean Brs.* to the heel, and sole of foot.  
*Internal Plantar*, along inner side of foot.
- EXTERNAL PLANTAR, { *Brs.* to muscles, fascia and skin.  
*Posterior Perforating* (3) Branches.  
{ 4 *Digital*, { *Ant. Perforating* Branches.  
Ends as the PLANTAR ARCH, anas.  
with Commun. Br. of Dorsalis Pedis.

**TABLES AND PLATES**

**OF THE**

**NERVOUS SYSTEM.**

---

**NOTE.**—These Tables are of original arrangement, and are designed to show the origin, formation and distribution of each nerve. They are generally self-explanatory. That for the 2d Cranial (Optic Nerve) is too long for the width of the page, and breaks at the Optic Commissure, which is repeated again where the table continues below.

**SAM'L Q. L. POTTER,**

## THE CRANIAL NERVES.

**1st NERVE,—Olfactory.** *Function*,—smell. *Exit*,— $\left\{ \begin{array}{l} \text{Ethmoidal foramina, 20,} \\ \text{in cribriform plate of Eth-} \\ \text{moid bone.} \end{array} \right.$

*Ext. Root*, Temp.-sphen. lobe, } **1st N.** { *Ext. Filaments*, to outer wall of nasal cavity.  
*Mid. Root*, Olfac. tubercle, } **and Bulb** { *Mid. Filaments*, to root of cavity.  
*Int. Root*, Gyrus fornicat. } { *Int. Filaments*, to Septum nasi.

**2d NERVE,—Optic.** *Function*,—sight. *Exit*,—Optic foramen.

Optic thalamus	} Fibres	{	<i>Longitudinal</i> <i>Decussating</i> <i>Inter-cerebral</i>	} Left Optic Tract	} OPTIC COMMISSURE OR CHIASM.
Corp. geniculata					
Corp. quad. ant.					
Corp. quad. ant.	} Fibres	{	<i>Inter-cerebral</i> <i>Decussating</i> <i>Longitudinal</i>	} Right Optic Tract	
Corp. geniculata					
Optic thalamus					

OPTIC COMMISSURE OR CHIASM.	} <b>2d</b>	} <b>Optic N.</b>	{	<i>Longitudinal</i> , to temporal $\frac{1}{2}$ of retina	} L. Eye.
				<i>Decussating</i> , fr. opp. tract to nasal $\frac{1}{2}$ of ret.	
				<i>Inter-retinal</i> , fr. opp. retina to retina	
				<i>Inter-retinal</i> , fr. opp. retina to retina	
}	}	}	{	<i>Inter-retinal</i> , fr. opp. retina to retina	} R. Eye.
				<i>Decussating</i> , fr. opp. tract to nasal $\frac{1}{2}$ of ret.	
				<i>Longitudinal</i> , to temporal $\frac{1}{2}$ of retina.	

**3d NERVE,—Motor Oculi.** *Function*,—motion. *Exit*,—Sphenoidal fissure.

Corp. quadrig.	} <b>3d N.</b>	{	<i>Sup. Branch</i> , to Lev. palp. sup., Rectus superior. <i>Inf. Branch</i> { to Rectus int., Rect. inf., Inf. oblique. motor root to Ciliary Ganglion.
Valve of Vieus.			
Aqued. of Syl.			
Crus cerebri.			

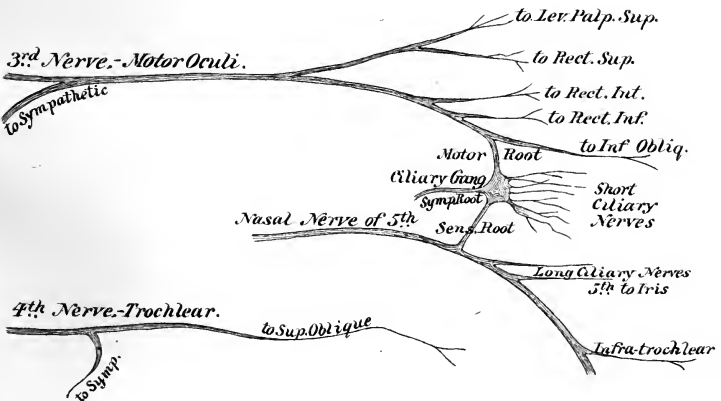
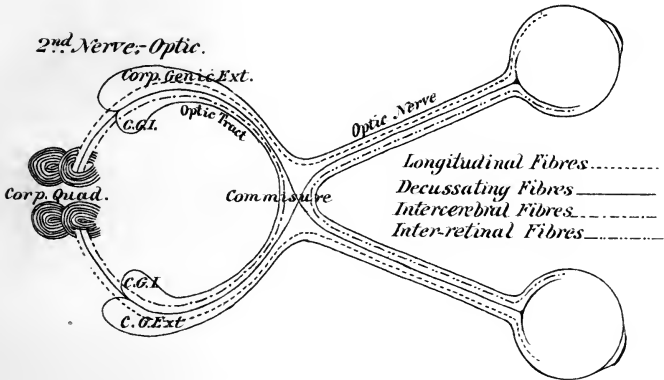
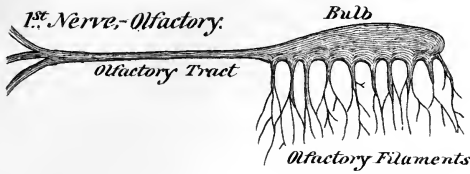
*Supplies all the Ocular muscles, including iris, except Sup. oblique and Ext. Rectus.*

**4th NERVE,—Trochlear.** *Function*,—motion. *Exit*,—Sphenoidal fissure.

Aq. of Sylvius,	} <b>4th N.</b>	{	to Sup. Oblique on upper (orbital) surface. <i>Branch</i> to Cavernous Plexus of Sympathetic.
Valve of Vieus.			
Crus cerebri.			

*Is the smallest cranial nerve, with the longest nerve-course in the cranial cavity.*

# THE CRANIAL NERVES.





STATE OF NEW YORK

IN SENATE

JANUARY 18, 1891

REPORT

OF THE

COMMISSIONERS OF THE LAND OFFICE

FOR THE YEAR

ENDING

DECEMBER 31, 1890

ALBANY:

ANDREW W. HENNINGER, STATE

PRINTING OFFICE.

1891.

1891.

1891.

1891.

1891.

1891.

1891.

1891.

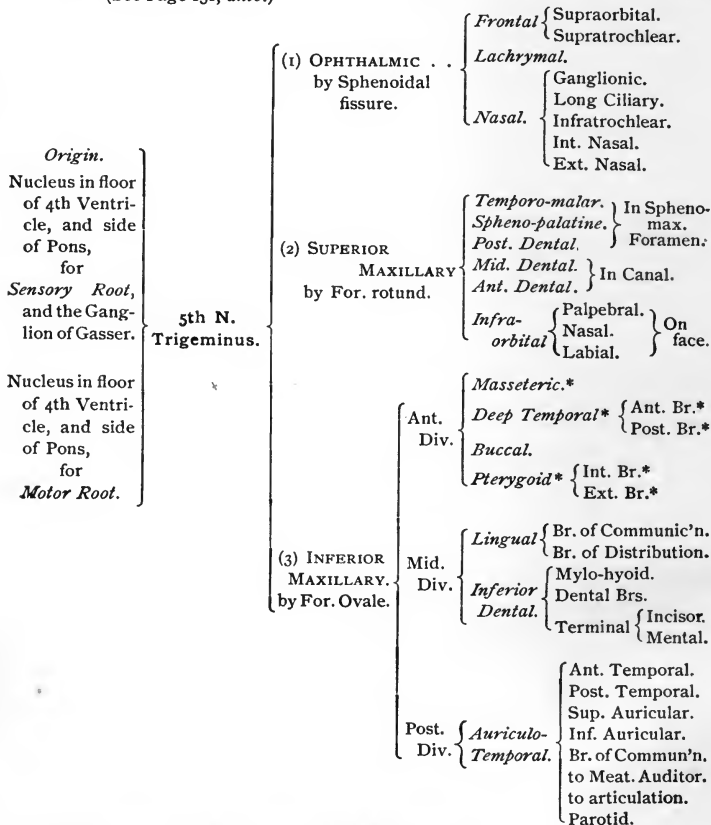
1891.

1891.

## THE NERVOUS SYSTEM.—Continued.

5th NERVE,—Trigeminus.

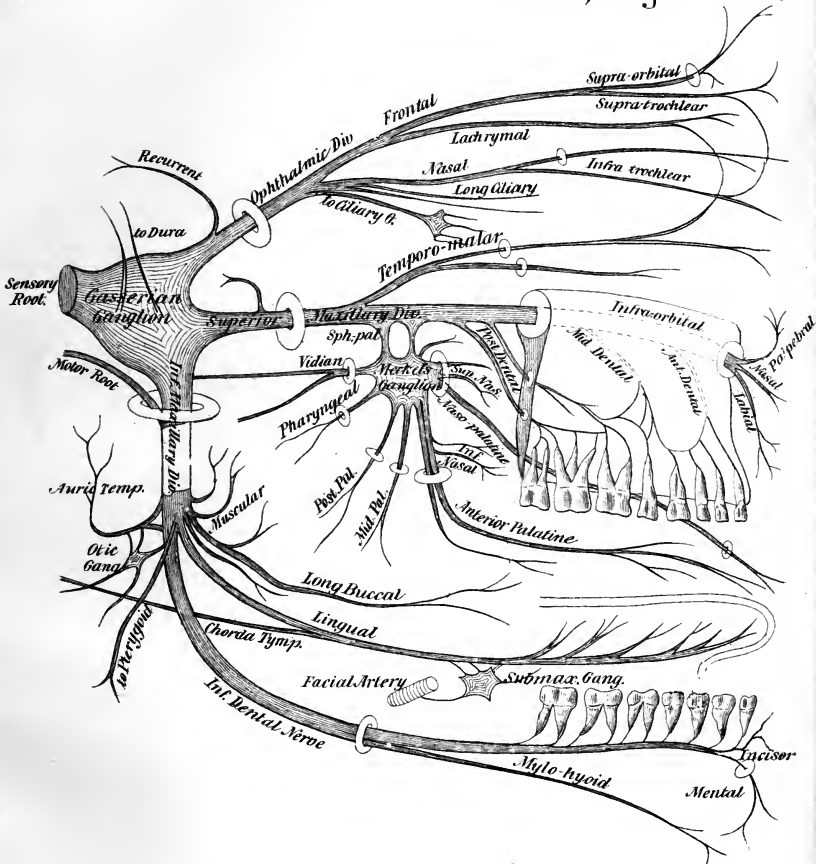
Functions, Sensation, Motion, Special sense.


(See Page 131, *ante*.)\* *Motor Branches, going to the muscles of mastication.*



# THE CRANIAL NERVES.

## 5<sup>th</sup> Nerve,-Trigeminus.





MEMORANDUM

TO THE BOARD OF TRUSTEES

FROM THE

COMMISSIONER OF THE UNIVERSITY OF CHICAGO

RE: THE PROPOSED CHANGES IN THE

UNIVERSITY OF CHICAGO

AND THE UNIVERSITY OF CHICAGO

AND THE UNIVERSITY OF CHICAGO

AND THE UNIVERSITY OF CHICAGO

AND THE UNIVERSITY OF CHICAGO

Very respectfully,

W. H. H. H.

Commissioner

THE UNIVERSITY OF CHICAGO

CHICAGO, ILLINOIS

1910

## THE NERVOUS SYSTEM.—Continued.

7th NERVE,—Facial, or Portio Dura.

Function,—Motion.

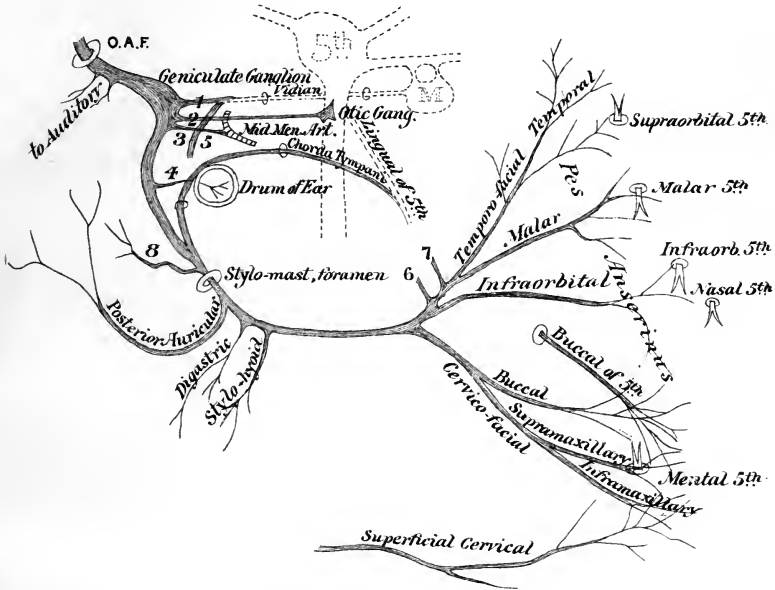
(See *ante*, p. 131.)

<i>Origin.</i> Nucleus in floor of the 4th Ventricle and groove between Olivary and restiform bodies of medulla oblongata.	} 7th N. Facial	} Branches of Communication.	In auditory canal. <i>Br.</i> to Auditory N.
			In Aqueduct of Fallopius . . . <ul style="list-style-type: none"> <li>{ <i>Large Petrosal</i>, to Meckel's Ganglion.</li> <li>{ <i>Small Petrosal</i>, to Otic ganglion.</li> <li>{ <i>Ext. Petrosal</i>, to meningeal plexus.</li> <li>{ <i>Tympanic Br.</i> to ear.</li> </ul>
			At exit from the Stylo - mastoid Foramen <ul style="list-style-type: none"> <li>{ <i>Br.</i> to Great Auricular (Cerv. Plex.)</li> <li>{ <i>Br.</i> to Auriculo-Temporal (5th).</li> <li>{ <i>Br.</i> to Pneumogastric.</li> <li>{ <i>Br.</i> to Glosso-pharyngeal.</li> <li>{ <i>Br.</i> to Carotid Plexus (Symp.).</li> </ul>
			On the face . . . <i>Brs.</i> to 5th Nerve.
		} Branches of Distribution.	In Aqueduct of Fallopius . . . <ul style="list-style-type: none"> <li>{ <i>Tympanic Nerve.</i></li> <li>{ <i>Chorda Tympani Nerve.</i></li> </ul>
			Near Stylo-mastoid Foramen. <ul style="list-style-type: none"> <li>{ <i>Post. Auricular</i> { Auricular.</li> <li>                          { Occipital.</li> <li>{ <i>Br.</i> to Digastric.</li> <li>{ <i>Br.</i> to Stylo-hyoid.</li> <li>{ <i>Lingual.</i></li> </ul>
			On the face * . . <ul style="list-style-type: none"> <li>{ <i>Temporo-facial</i> { <i>Temporal.</i></li> <li>                          { <i>Malar.</i></li> <li>                          { <i>Infra-orbital.</i></li> <li>{ <i>Cervico-facial</i> { <i>Buccal.</i></li> <li>                          { <i>Supra-maxillary.</i></li> <li>                          { <i>Infra-maxillary.</i></li> </ul>

\* Forming the *Pes Anserinus*, or Goose-foot, as these branches are named.

# THE CRANIAL NERVES.

## 7<sup>th</sup> Nerve - Facial, or Portia Dura.



### REFERENCES.

1. GREAT PETROSAL, TO FORM VIDIAN WITH N<sup>o</sup> 5.
2. SMALL PETROSAL, TO OTIC GANGLION.
3. EXTERNAL PETROSAL, TO PLEXUS ON MID. MENINGEAL ARTERY.
4. TYMPANIC BR. TO STAPEDIUS, ETC.
5. BR. FROM CAROTID PLEXUS, MAKING VIDIAN, WITH N<sup>o</sup> 1
6. 7. BRs. TO AURICULO-TEMPORAL OF 5<sup>th</sup>
8. BR TO AURICULAR OF VAGUS.
- M. THE GANGLION OF MECKEL.
- O.A.F. ORIFICE OF AQUEDUCTUS FALLOPII.





## THE NERVOUS SYSTEM.—Continued.

The Eighth Pair (Willis) includes the 9th GLOSSO-PHARYNGEAL, 10th PNEUMOGASTRIC, and 11th SPINAL ACCESSORY,—all of which *Exit* by the *Jugular Foramen*, or *Foramen Lacerum Posterius*.

9th NERVE,—Glossopharyngeal. *Functions*,—Motion, Sensation, Special Sense.  
(See *ante*, page 132.)

<p><i>Origin.</i> A Gray nucleus in floor of 4th Vent. and medulla oblong. behind the olivary body.</p>	}	<p>9th Nerve Glosso- pharyngeal.</p>	<p><i>Tympanic.</i> (Jacobson's N.)</p> <p><i>Carotid Branches.</i> <i>Pharyngeal Brs.</i>—to Pharyngeal Plexus. <i>Muscular Brs.</i>—to muscles of pharynx. <i>Tonsillar Brs.</i>—to Tonsillar Plexus. <i>Lingual Brs.</i>—to post. <math>\frac{1}{3}</math> of tongue, giving taste thereto.</p>	<p>Communicating Brs. to</p> <p>Distributing Brs. to</p>	<p>Large Petrosal. Small Petrosal. Carotid Plexus.</p> <p>Fenestra ovalis. Fenestra rotunda. Eustachian tube.</p>
---	---	--	--	--	---

10th NERVE,—Pneumogastric, or Vagus.

*Functions*, { Sensation,  
Motion.

(See *ante*, page 132.)

<p><i>Origin.</i> A nucleus in the floor of 4th Ventricle below that of 9th nerve and groove between olivary and restiform bodies of medulla.</p>	}	<p>10th Nerve Vagus.</p>	<p><i>Auricular</i> (Arnold's Nerve). <i>Pharyngeal.</i> <i>Sup. Laryngeal</i> { Ext. Br. Int. Br. <i>Recurrent or Inf. Laryngeal</i> <i>Cervical Cardiac.</i> <i>Thoracic Cardiac.</i> <i>Ant. Pulmonary.</i> <i>Post. Pulmonary.</i> <i>Gastric. Intestinal.</i> <i>Hepatic. Renal. Splenic.</i></p>	<p>Probably comes from the Spinal Accessory, and supplies all the laryngeal muscles except crico-thyroid.</p> <p>Terminal Brs.</p>
---	---	------------------------------	--	--

Gives sensation to external ear and larynx, motion to other parts, also vaso-motorial, inhibitory, trophic and secretory influences. A nerve of deglutition, phonation, respiration, circulation, and digestion. The Auriculo-Laryngo-Pharyngo-Œsophago-Tracheo-Pulmono-Cardio-Gastro-Hepatic-Intestinal-Renal-Splenic Nerve.

11th NERVE,—Spinal Accessory.

*Function*,—Motion.

(See *ante*, page 132.)

<p><i>Origin.</i> The floor of 4th Ventricle, and gray horn in cord, down to 6th Cervical N.</p>	}	<p>11th Nerve</p>	<p><i>Branch</i> to Vagus, ganglion of root. <i>Internal</i>, anastomosing with Vagus, is probably the Recurrent Laryngeal Br. of the latter nerve. <i>External</i>, or <i>Muscular</i>, to</p>	<p>{ Sterno-mastoid. Trapezius.</p>
--	---	-------------------	---	---

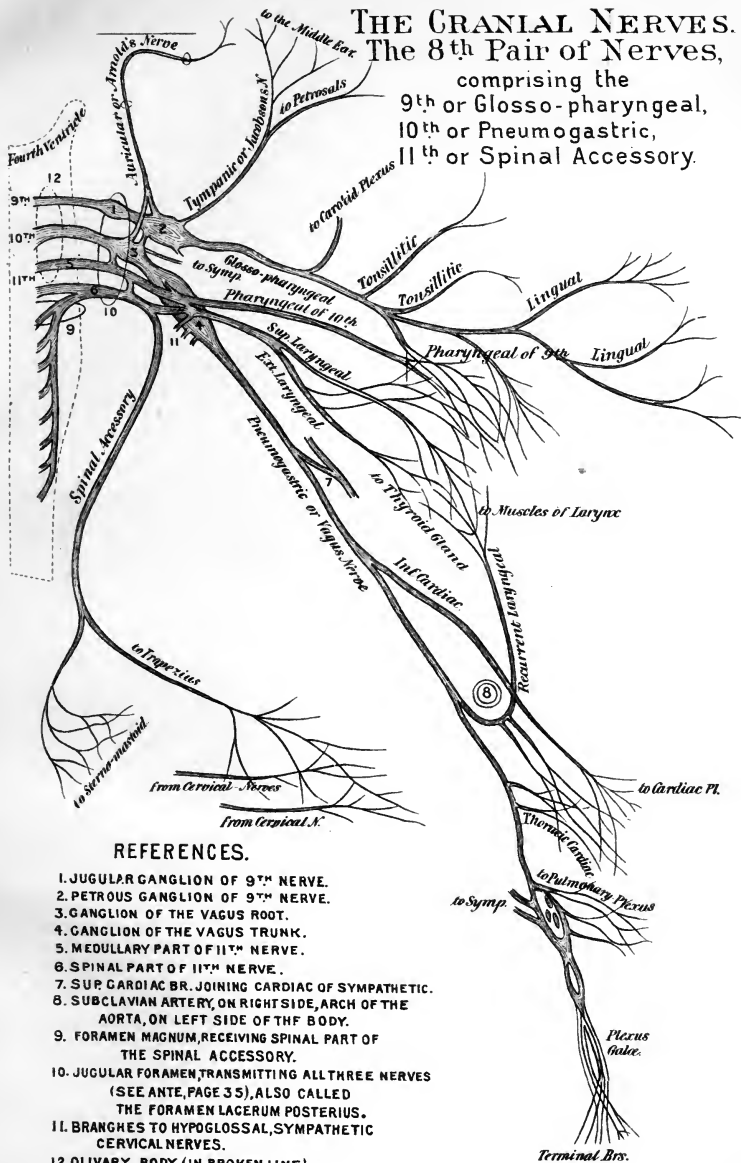
A motor nerve to the muscles named, also probably to the laryngeal also.



# THE CRANIAL NERVES.

## The 8<sup>th</sup> Pair of Nerves,

comprising the  
 9<sup>th</sup> or Glosso-pharyngeal,  
 10<sup>th</sup> or Pneumogastric,  
 11<sup>th</sup> or Spinal Accessory.



### REFERENCES.

1. JUGULAR GANGLION OF 9<sup>TH</sup> NERVE.
2. PETROUS GANGLION OF 9<sup>TH</sup> NERVE.
3. GANGLION OF THE VAGUS ROOT.
4. GANGLION OF THE VAGUS TRUNK.
5. MEDULLARY PART OF 11<sup>TH</sup> NERVE.
6. SPINAL PART OF 11<sup>TH</sup> NERVE.
7. SUP. CARDIAC BR. JOINING CARDIAC OF SYMPATHETIC.
8. SUBCLAVIAN ARTERY, ON RIGHT SIDE, ARCH OF THE AORTA, ON LEFT SIDE OF THE BODY.
9. FORAMEN MAGNUM, RECEIVING SPINAL PART OF THE SPINAL ACCESSORY.
10. JUGULAR FORAMEN, TRANSMITTING ALL THREE NERVES (SEE ANTE, PAGE 35), ALSO CALLED THE FORAMEN LACERUM POSTERIUS.
11. BRANCHES TO HYPOGLOSSAL, SYMPATHETIC CERVICAL NERVES.
12. OLIVARY BODY. (IN BROKEN LINE).



[illegible]

[illegible text]

## THE NERVOUS SYSTEM.—Continued.

6th NERVE,—Abducens (See *ante*, page 131).*Function*, { Motion to Ext.  
Rectus of Eye.*Origin*.—Same as 7th,  
a gray nucleus in floor  
of 4th Ventricle,  
and  
lower border of Pons. }

6th Nerve, Abducens. }

*Exit* by sphenoidal fissure be-  
tween the two heads of the  
Ext. Rectus muscle of the  
eye.*No branches.*

8th NERVE,—Auditory, OR PORTIO MOLLIS OF THE 7TH PAIR.

*Function*,—Special Sense.*Origin*.—Striæ in floor  
and anterior wall of  
the 4th Ventricle,  
and  
winds around the  
restiform body. }8th Nerve,  
Auditory. }*Vestibular*, to { 2 Semi-circ. canals.  
Utricle.  
Saccule.*Cochlear*, to { Post. S.-C. canal.  
Saccule—Utricle Wall.  
Cochlea, and Organ of Corti.A nerve of special sense (hearing), fully described on page 225, *ante*. Its *Exit* is by the Internal Auditory Meatus, through the Internal Auditory Canal, to the internal ear. It is the only cranial nerve which does not leave the cranial wall.

12th NERVE,—Hypoglossal (NONUS OR 9TH OF WILLIS).

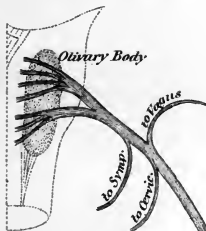
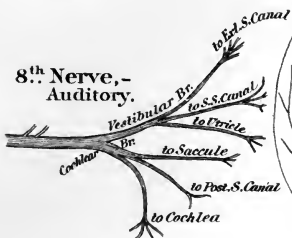*Function*,—Motor of tongue, etc.*Origin*.—Nucleus in  
floor of 4th Ventricle,  
and  
groove between the  
pyramidal and  
olivary bodies of  
the medulla. }12th Nerve,  
Hypoglossal }*Communicating Brs.* to { Gustatory of 5th.  
Sympathetic.  
1, 2, Cervical.  
Vagus.*Descendens Noni*, { Br. to Sterno-hyoid.  
Br. to Sterno-thyroid.  
Br. to Omo-hyoid.  
Joins Communicans  
Noni Nerve.*Thyro-hoid*, to that muscle.*Lingual*, to { Stylo-glossus.  
Hyo-glossus.  
Genio-hyoid.  
Genio-hyo-glossus.*Exit*, by Ant. Condylod foramen.

# THE CRANIAL NERVES.

6<sup>th</sup> Nerve, - Abducens.

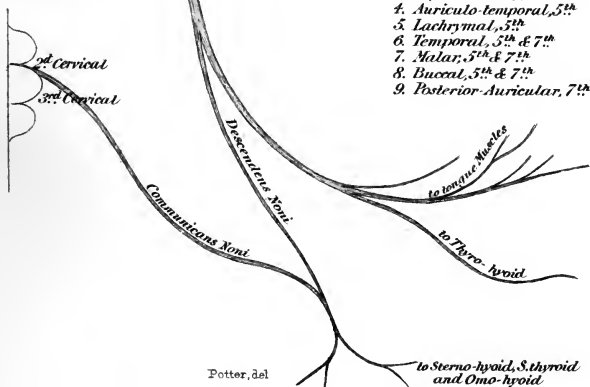


8<sup>th</sup> Nerve, - Auditory.

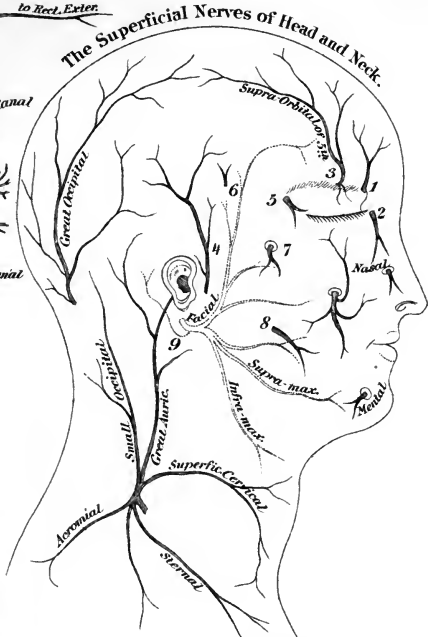

12<sup>th</sup> Nerve, - Hypoglossal.

(Nonus or 9<sup>th</sup> of Willis.)



## The Superficial Nerves of Head and Neck.



1. Supra-trochlear, 5<sup>th</sup>
2. Infra-trochlear, 5<sup>th</sup>
3. Supra-orbital, 5<sup>th</sup>
4. Auriculo-temporal, 5<sup>th</sup>
5. Lachrymal, 5<sup>th</sup>
6. Temporal, 5<sup>th</sup> & 7<sup>th</sup>
7. Malar, 5<sup>th</sup> & 7<sup>th</sup>
8. Buccal, 5<sup>th</sup> & 7<sup>th</sup>
9. Posterior-Auricular, 7<sup>th</sup>





## THE SPINAL NERVES, 31 PAIRS.

8 CERVICAL, 12 DORSAL, 5 LUMBAR, 5 SACRAL, 1 COCCYGEAL.

*N. B.*—Read from the **Black Type** outwards to left and right.

to muscles and { *Ext. Br.* }  
 skin of back. { *Int. Br.* } POST. DIV. { **Each Spinal Nerve** } ANT. DIVISION, to  
 divides into } Plexuses, etc.

Post. Div. of 2d N. }  
 Post. M. of head, etc. } POST. DIV. { **1st Cervical Nerve.** } ANT. DIV. { *Commun'g Brs. to* }  
 Complexus Muscle. } { *Sub-occipital* } { 2 Cerv. N. }  
 Skin of occiput. } { } { Vagus N. }  
 { } { } { Hypogl. N. }  
 { } { } { Sup. Cerv. Gang. }

*Brs. (3) to Recti cap. Muscles.*  
*Br. to Occip-atloid artic'n.*

Splenius }  
 Cerv. ascendens } { *Ext. Branch* }  
 Transv.-colli } supplying } POST. DIV. { **2d Cervical Nerve.** } ANT. DIV. { *Fil. to Sterno-mastoid M.*  
 Trach-mastoid } { } { } { *Asc. Br. to 1st Cerv. N.*  
 Complexus } { } { } { *Desc. Br. to 3d Cerv. N.*  
 to 1st Cerv. N. } { *Int. Br. or* } { } { *Fil. to Commun. Noni N.*  
 Skin of occiput. } { *Great Occip.* } { } { *Occipitalis Minor Nerve.*  
 Auricular. } { } { } { }

Splenius }  
 Cerv. ascend. } { *Ext. Br.* }  
 Trans. colli } supplies } POST. DIV. { **3d Cervical Nerve.** } ANT. DIV. { *Ascen. Br.* }  
 Trach-mast. } { } { } { *Suparf. Cervical.*  
 Integument of } { *Int. Br.* } { } { *Br. to 2d Cerv. N.*  
 occiput. } to supply } { } { *Br. to Spinal-ac.*  
 } { } { } { *Descen. Br.* }  
 { } { } { } { *Fil. to 4th Nerve.*  
 { } { } { } { *Fil. to Lev. ang. scap.*  
 { } { } { } { *Supra-clavicular.*  
 { } { } { } { *Fil. to Com. Noni N.*  
 { } { } { } { *Fil. to Phrenic N.*

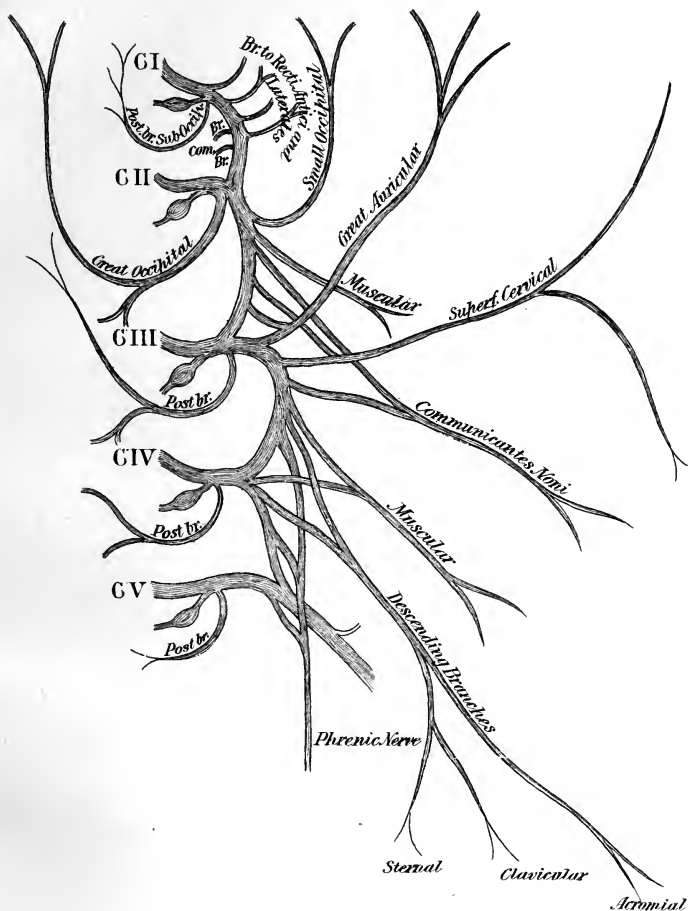
Muscles of the Back. } POST. DIV. { **4th Cervical Nerve.** } ANT. DIV. { *Fil. to 3d Cerv. N.*  
 { } { } { } { *Fil. to 5th Cerv. N.*  
 { } { } { } { *Fil. to Phrenic N.*  
 { } { } { } { *Fil. to Scalenus medius.*  
 { } { } { } { *Fil. to Supra-clav. N.*

*Anterior Branches* }  
 of }  
 1st Cerv. N. } **Cervical Plexus.** { *Superficial Br.* } { *Ascending Set (5) to head and shoulder.*  
 2d Cerv. N. } { } { *Descending Set (3) Sternal, Clavic. Acrom.*  
 3d Cerv. N. } { } { } { }  
 4th Cerv. N. } { } { } { }  
 { } { } { *Internal Set* } { *Communicating to* } { *Vagus.*  
 { } { } { } { } { *Hypogl.*  
 { } { } { } { } { *Symp.*  
 { } { } { } { } { }  
 { } { } { } { } { *Muscular.*  
 { } { } { } { } { *COMMUNIC. NONI NERVE.*  
 { } { } { } { } { *PHRENIC NERVE.*  
 { } { } { } { } { *External Set* } { *Muscular (4).*  
 { } { } { } { } { *Comm'g to Spinal-ac. N.*



THE SPINAL NERVES.

Cervical Plexus.



THIS PLEXUS { LIES UPON THE { SCALENUS MEDIUS AND } MUSCLES.  
 { LEVATOR ANGULI SCAPULAE }  
 THE CERVICAL { IS COVERED BY THE STERNO-CLEIDO-MASTOID MUSCLE.



THE HISTORY OF THE

1787

of the

of the

of the

of the

of the

of the

of the

of the

of the

of the

of the

of the

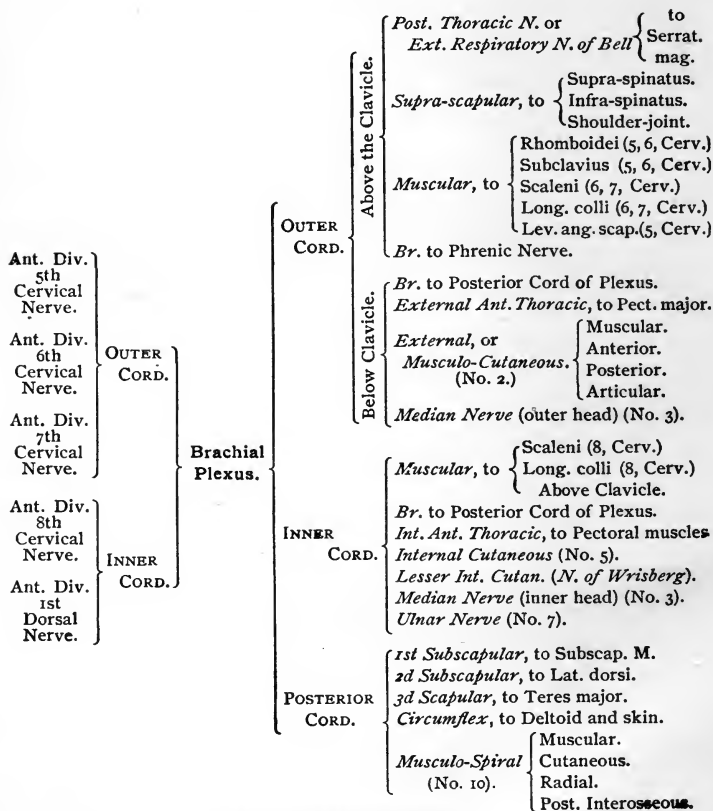
of the

of the

of the

## THE NERVOUS SYSTEM.—Continued.

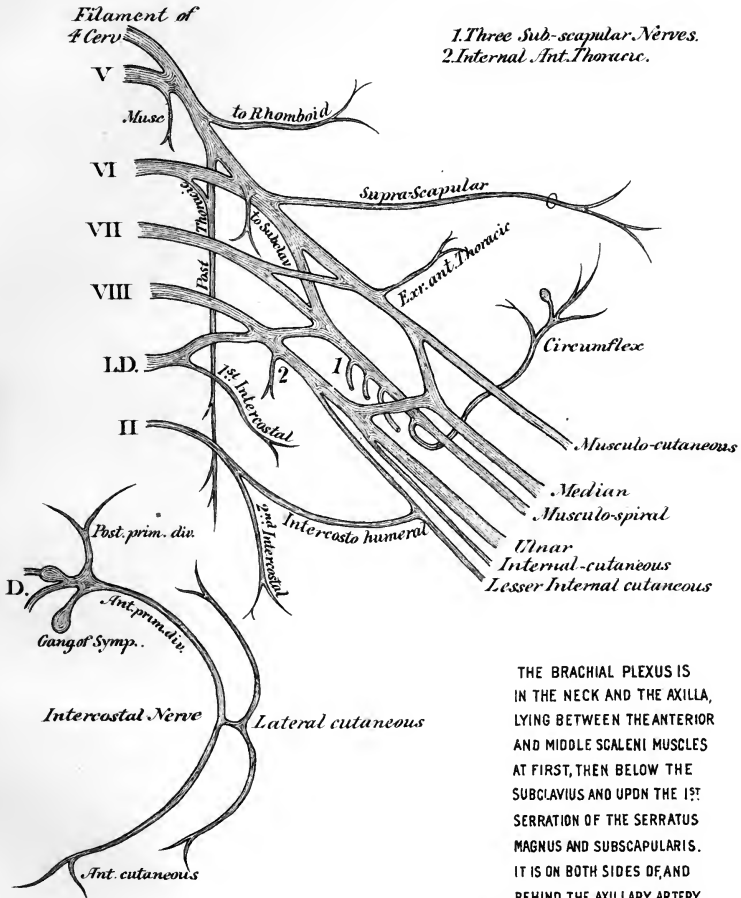
## THE BRACHIAL PLEXUS.



Note.—Nos. 1, 2, 3, etc., refer to the next two Tables.

# THE SPINAL NERVES

## Brachial Plexus



THE BRACHIAL PLEXUS IS IN THE NECK AND THE AXILLA, LYING BETWEEN THE ANTERIOR AND MIDDLE SCALENI MUSCLES AT FIRST, THEN BELOW THE SUBCLAVIUS AND UPON THE 1ST SERRATION OF THE SERRATUS MAGNUS AND SUBSCAPULARIS. IT IS ON BOTH SIDES OF, AND BEHIND THE AXILLARY ARTERY IN ITS 2ND PORTION, EXTERNAL THERETO IN ITS 1ST PORTION.





## THE NERVOUS SYSTEM.—Continued.

## NERVES OF THE UPPER EXTREMITY.

## TERMINAL BRANCHES OF THE BRACHIAL PLEXUS.

Outer Cord of the Brachial Plexus.	}	(1) EXTERNAL ANTERIOR THORACIC, to Pectoralis major.					
		(2) EXTERNAL OF MUSCULO-CUTANEOUS.	}	<i>Muscular, to . .</i>	}	Coraco-brachialis.	
						Biceps.	
						Brachialis anticus.	
				<i>Anterior Br.</i>		Skin of forearm (front).	
						Skin of ball of thumb.	
						Joins Radial Nerve.	
				<i>Posterior Br.</i>		Skin of forearm (back).	
						Joins Radial Nerve.	
						Joins Ext Cutan. Br. of Musculo-spiral N.	
		<i>Articular Br.</i>		to Elbow-joint.			
	}	(3) MEDIAN.	}	In Forearm.	}	<i>Muscular, to . .</i>	Pronator radii teres.
							Flex. carpi rad.
							Palm. longus.
							Flex. subl. digit.
						<i>Anterior Interosseous.</i>	to Flex. long. poll.
							to Flex. prof. digit. (Ext. ½.)
							to Pronat. quadrat.
						<i>Palmar Cutaneous.</i>	Skin of palm.
							Skin of ball of thumb.
							}
	to Opponens poll.						
	to Flex. brev. poll.						
	<i>Digital, to thumb.</i>						
	<i>Digital, to 1st finger.</i>						
<i>Internal Br. . .</i>	<i>Digital, to contiguous sides of index, middle and ring fingers.</i>						
	Filaments to two outer Lumbricales.						







ANNALS OF THE ENTOMOLOGICAL SOCIETY OF AMERICA

Volume 54, Number 1, February 1963

Published by the Entomological Society of America

521 North Dearborn Street, Chicago 10, Illinois

Subscription price, \$12.00 per volume in advance

Single copies, 50¢ each (plus postage)

Second-class postage paid at Chicago, Illinois

Postmaster: Send address changes to Entomological Society of America, 521 North Dearborn Street, Chicago 10, Illinois

Entered as Second-Class Matter, June 26, 1925

Post Office at Chicago, Illinois, Post Office No. 334

Acceptance for mailing at special rate of postage provided for in Section 1103, Act of October 3, 1917, authorized on July 27, 1957

Copyright © 1963 by Entomological Society of America

Printed in the United States of America

Printed by R. W. Taylor, Chicago, Illinois

Printed on acid-free paper

Library of Congress Catalog Card No. 62-10000

Library of Congress Catalog Card No. 62-10000

Library of Congress Catalog Card No. 62-10000

Library of Congress Catalog Card No. 62-10000

Library of Congress Catalog Card No. 62-10000

Library of Congress Catalog Card No. 62-10000

Library of Congress Catalog Card No. 62-10000

Library of Congress Catalog Card No. 62-10000

Library of Congress Catalog Card No. 62-10000

Library of Congress Catalog Card No. 62-10000

Library of Congress Catalog Card No. 62-10000

Library of Congress Catalog Card No. 62-10000

Library of Congress Catalog Card No. 62-10000

Library of Congress Catalog Card No. 62-10000

Library of Congress Catalog Card No. 62-10000

Library of Congress Catalog Card No. 62-10000

Library of Congress Catalog Card No. 62-10000

Library of Congress Catalog Card No. 62-10000

Library of Congress Catalog Card No. 62-10000

Library of Congress Catalog Card No. 62-10000

Library of Congress Catalog Card No. 62-10000

Library of Congress Catalog Card No. 62-10000

Library of Congress Catalog Card No. 62-10000

Library of Congress Catalog Card No. 62-10000

Library of Congress Catalog Card No. 62-10000

Library of Congress Catalog Card No. 62-10000

Library of Congress Catalog Card No. 62-10000

Library of Congress Catalog Card No. 62-10000

Library of Congress Catalog Card No. 62-10000

Library of Congress Catalog Card No. 62-10000

Library of Congress Catalog Card No. 62-10000

Library of Congress Catalog Card No. 62-10000

Library of Congress Catalog Card No. 62-10000

Library of Congress Catalog Card No. 62-10000

Library of Congress Catalog Card No. 62-10000

Library of Congress Catalog Card No. 62-10000

Library of Congress Catalog Card No. 62-10000

## THE NERVOUS SYSTEM.—Continued.

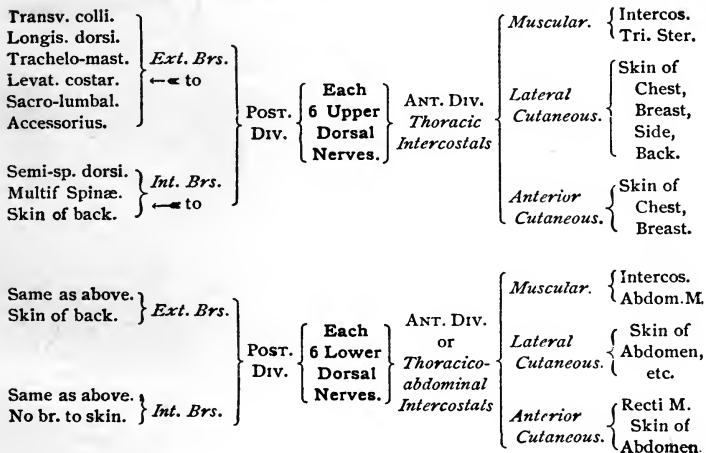
- Inner Cord of the Brachial Plexus.
- (4) INTERNAL ANTERIOR THORACIC, to both Pectoral muscles.
  - (5) INTERNAL CUTANEOUS { *Anterior Br.* to skin of forearm, inner side.  
*Posterior Br.* to skin of forearm, inner side.
  - (6) LESSER INTERNAL CUTANEOUS. { Is often wanting, Intercosto-humeral taking its place, to post. surface of lower  $\frac{1}{2}$  of skin of arm.  
*(N. of Wrisberg.)*
  - (7) ULNAR {
    - In Forearm. {
      - Articular*, . . . to Elbow-joint.
      - Muscular*, . . . to { Flex. carp. ulnaris.  
Flex. prof. dig. (inner  $\frac{1}{2}$ .)
      - Palmar Cutaneous*. Skin of front wrist, and palm of hand.
      - Dorsal Cutaneous*. Skin of back wrist, and  $1\frac{1}{2}$  fingers.
    - In Hand. {
      - Superficial Brs.* to { Palmaris brevis.  
Skin of  $1\frac{1}{2}$  fingers.
      - Deep Brs.* . . . to { Muscles of little finger  
Interossei.  
2 inner Lumbricales.  
Adduc. pollicis.  
Flex. brev. poll. (inner head).

- Posterior Cord of the Brachial Plexus.
- (8) SUBSCAPULAR (3). { *1st Upper*, to Subscapular muscle,  
*2d Long*, to Latiss. dorsi.  
*3d Lower*, to Teres major.
  - (9) CIRCUMFLEX . . {
    - Superior Br.* . . to { Deltoid.  
Skin of shoulder.
    - Inferior Br.* . . to { Teres minor.  
Deltoid (post).  
Skin of shoulder.
  - (10) MUSCULO-SPIRAL. {
    - Muscular*, . . to { Triceps, Anconeus.  
Brach. anticus  
Supin. long.  
Ext. carpi rad. long.
    - Cutaneous*, to skin of arm.
    - RADIAL. { *External Br.* to skin of thumb.  
*Internal Br.* { to skin of  $3\frac{1}{2}$  fingers on  
radial side of dorsum.
    - POSTERIOR INTEROSSEOUS { to all muscles on back of forearm,  
except Anconeus, Sup. long. and  
Ext. carpi radialis long.  
Filaments to wrist-joints.

**THE NERVOUS SYSTEM.—Continued.**

**THE DORSAL NERVES.**

*N. B.—Read from the Black Types outwards to left and right.*



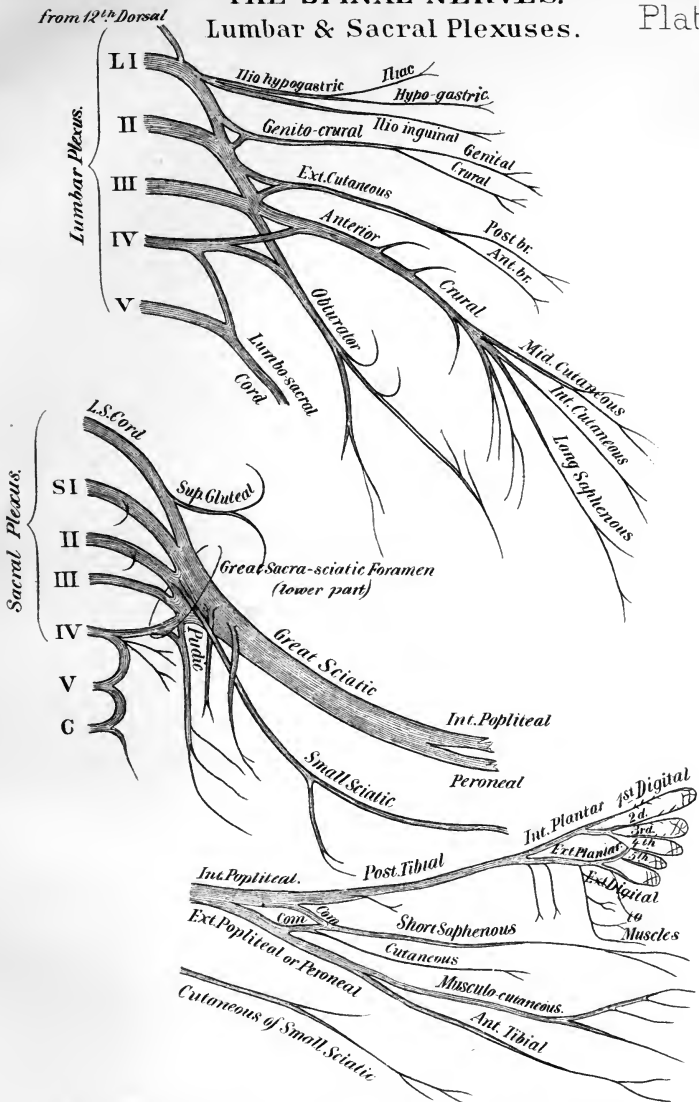
THE LUMBAR AND SACRAL NERVES.

(DISTRIBUTION SHOWN ON NEXT TABLE.)

<p><i>An External Branch,</i> sending filaments to the Erector spinæ and Intertransversales muscles, and the skin of the gluteal region, posteriorly.</p>	<p>The Posterior Division of each of these Nerves has</p>	1st Lumbar.	<p>Ant. Div. { Nos. 1, 2, 3, Comm. Br. to 2d Lum.</p>	<p>Lumbar Plexus. { (1) <i>Ilio-hypogastric</i> (2) <i>Ilio-inguinal</i> (3) <i>Genito-crural</i> (4) <i>Ext. Cutaneous</i> (5) <i>Ant. Crural</i> (6) <i>Obturator</i> (7) <i>Accessory Obturator</i> (when present.)</p>
		2d Lumbar.	<p>Ant. Div. { Nos. 3, 4, 5, Comm. Br. to 3d Lum.</p>	
		3d Lumbar.	<p>Ant. Div. { Part of 5, 6, 7, Comm. Br. to 4th Lum.</p>	
		4th Lumbar.	<p>Ant. Div. { Part of 5, 6, 7, Lumbo-Sacral Cord to 5th Lum.</p>	
<p><i>An External Branch,</i> forming loop on sacrum and great Sac-Sciat. lig. to supply skin over glutei.</p>	<p>The Posterior Division of each of these Nerves has</p>	5th Lumbar.	<p>Ant. Div. { Joins the Lumbo-Sacral Cord</p>	<p>Sacral Plexus. { (1) <i>Super. Gluteal</i> (2) <i>Muscular Brs.</i> (3) <i>Small Sciatic</i> (4) <i>Great Sciatic</i> (5) <i>Puñic</i> (6) <i>Articular</i></p>
		1st Sacral.	<p>Ant. Div. { Joins the Lumbo-Sacral Cord and 2d Sacral.</p>	
		2d Sacral.	<p>Ant. Div. { Joins with 1st Sacral.</p>	
		3d Sacral.	<p>Ant. Div. { Joins with 2d Sacral and part of the 4th.</p>	
		4th Sacral.	<p>Ant. Div. { Br. to Plexus, Visc. Brs. Mus. Brs. Fil. to 5th.</p>	
<p><i>An Internal Branch,</i> to Multifidus Spinæ and back part of coccyx. (the two lower nerves.)</p>	<p>The Posterior Division of each of these Nerves has</p>	5th Sacral.	<p>Ant. Div. { Br. to skin of coccyx. Br. to Coccygeus M. Br. to Cocc. Nerve.</p>	
		Coccygeal.	<p>Ant. Div. { A delicate filament, going to skin, over coccyx.</p>	
<p>Are below the Multifid. Spinæ, join together in loops over back of sacrum, sending filaments to skin.</p>	<p>Post. Div. {</p>	<p>5th Sacral.</p>	<p>Ant. Div. {</p>	<p>Br. to skin of coccyx. Br. to Coccygeus M. Br. to Cocc. Nerve.</p>
	<p>Post. Div. {</p>	<p>Coccygeal.</p>	<p>Ant. Div. {</p>	<p>A delicate filament, going to skin, over coccyx.</p>

# THE SPINAL NERVES.

## Lumbar & Sacral Plexuses.



THE LUMBAR PLEXUS LIES IN THE SUBSTANCE OF THE PSOAS MUSCLE, LIES UPON THE PYRIFORMIS MUSCLE IN THE PELVIS, AND IS COVERED BY THE PELVIC FASCIA, AND THE SCIATIC AND PUDIC ARTERIES

THE SACRAL PLEXUS LIES UPON THE PYRIFORMIS MUSCLE IN THE PELVIS, AND IS COVERED BY THE PELVIC FASCIA, AND THE SCIATIC AND PUDIC ARTERIES





Memorandum

Subject: [Illegible]

Date: [Illegible]

To: [Illegible]

From: [Illegible]

Reference: [Illegible]

[Illegible text block]

[Illegible text block]

[Illegible text block]

[Illegible text block]

[Illegible text block]

[Illegible text block]

[Illegible text block]

[Illegible text block]

## THE NERVOUS SYSTEM.—Continued.

DISTRIBUTION OF THE BRANCHES  
FROM THE 7 GREAT TRUNKS OF THE LUMBAR PLEXUS.


(A CONTINUATION OF THE TABLE ON PAGE 288.)

- |  |                          |   |  |   |   |
|--|--------------------------|---|--|---|---|
| (1).   | ILIO-HYPOGASTRIC . . .   | {   | <i>Iliac</i> , to skin of gluteal region.                              |   |   |
|  |                          | {   | <i>Hypogastric</i> , to skin of that region.                           |   |   |
| (2).   | ILIO-INGUINAL, . . . . . | {   | to Internal Oblique Muscle.  |   |   |
|  |                          | {   | to skin of upper and inner thigh, scrotum, penis.                      |   |   |
| (3).   | GENITO-CRURAL . . . . .  | {   | <i>Genital</i> , to Cremaster, scrotum, round ligament.                |   |   |
|  |                          | {   | <i>Crural</i> , to skin of upper and front thigh.                      |   |   |
| (4).   | EXTERNAL CUTANEOUS       | {   | <i>Ant. Br.</i> to skin of ant. and outer thigh, above knee.           |   |   |
|  |                          | {   | <i>Post. Br.</i> to skin of post. and outer thigh, above knee.         |   |   |
| (5).   | ANTERIOR<br>CRURAL.      | {   | Ant.<br>Div.   | {   | <i>Mid. Cutaneous.</i> { to Sartorius, and skin of ant. thigh<br>above knee.  |
|  |                          |   |  |   | <i>Int. Cutaneous.</i> { <i>Ext. Br.</i> to skin, lateral of knee.<br><i>Post. Br.</i> to skin of inner thigh<br>and leg. |
|  |                          |   |  |   | <i>Long Saphenous.</i> { to Skin of knee and of front and<br>inner leg and foot.  |
|  |                          | {   | Post.<br>Div.  | <i>Muscular Brs.</i> to muscles on front of thigh, all but 2. |   |
| <i>Articular Brs.</i> (2) to capsules of knee- and hip-joints. |                          |   |  |   |   |
| (6).   | OBTURATOR. . .           | {   | Ant.<br>Br.  | <i>Articular Brs.</i> to hip-joint.                           |   |
|  |                          |   |  | <i>Muscular Brs.</i> to Adductors, Gracilis and Pectineus.    |   |
|  |                          |   |  | <i>Anastomotic Brs.</i> with Int. Cutan. and Int. Saphenous.  |   |
| {  | Post.<br>Br.             | <i>Articular Brs.</i> to knee-joint.                        |  |   |   |
|  |                          | <i>Muscular Brs.</i> to Adduc. mag. and Obturator externus. |  |   |   |
| (7).   | ACCESSORY OBTURATOR.     | {   | <i>Muscular Br.</i> to Pectineus.                                      |   |   |
|  |                          | {   | <i>Articular Br.</i> to hip-joint.                                     |   |   |
|  |                          | {   | <i>Cutaneous Br.</i> to skin of thigh and leg. } Occasionally present. |   |   |

The Lumbar Plexus lies in the substance of the Psoas muscle, in front of the transverse processes of the lumbar vertebræ.

THE SPINAL NERVES.

Distribution of Branches of the Lumbar & Sacral Plexuses.







## THE NERVOUS SYSTEM.—Continued.

DISTRIBUTION OF THE BRANCHES  
OF THE SACRAL PLEXUS.

[CONTINUATION OF TABLE ON PAGE 288.]

- (1). SUPERIOR GLUTEAL,  $\left\{ \begin{array}{l} \text{Sup. Br. to the Gluteus medius and minimus.} \\ \text{Inf. Br. } \left\{ \begin{array}{l} \text{to the Gluteus medius and minimus.} \\ \text{to the Tensor vaginæ femoris.} \end{array} \right. \end{array} \right.$
- (2). MUSCULAR BRANCHES, to  $\left\{ \begin{array}{l} \text{Pyriformis, Obturator internus, the two Gemelli, and} \\ \text{the Quadratus femoris muscles.} \end{array} \right.$
- (3). ARTICULAR BRANCHES, to the hip-joint.
- (4). SMALL SCIATIC.  $\left\{ \begin{array}{l} \text{Inf. Gluteal, } \left\{ \begin{array}{l} \text{Gluteus maximus muscle.} \\ \text{Skin of side of penis, or vulva.} \end{array} \right. \\ \text{Inf. Pudendal, } \left\{ \begin{array}{l} \text{Skin of upper and inner thigh, and of scrotum} \\ \text{or labium.} \end{array} \right. \\ \text{Cutaneous, . } \left\{ \begin{array}{l} \text{Ascending, to Skin over Glutei.} \\ \text{Descending, to Skin of post. thigh.} \end{array} \right. \end{array} \right.$
- (5). GREAT SCIATIC.  $\left\{ \begin{array}{l} \text{Articular, . . . to the hip-joint.} \\ \text{Muscular, to } \left\{ \begin{array}{l} \text{Adductus magnus, Biceps.} \\ \text{Semi-membranosus, Semi-tendinosus.} \end{array} \right. \\ \text{EXTERNAL POPLITEAL OR PERONEAL. } \left\{ \begin{array}{l} \text{Terminal Branches.} \\ \text{INTERNAL POPLITEAL NERVE. } \left\{ \begin{array}{l} \text{(See next page.)} \end{array} \right. \end{array} \right. \end{array} \right.$
- (6). PUDIC. . . . .  $\left\{ \begin{array}{l} \text{Perineal, } \left\{ \begin{array}{l} \text{Superficial Perineal, } \left\{ \begin{array}{l} \text{to Skin of anus, scrotum,} \\ \text{penis and labia, and the} \\ \text{Sphincter ani muscle.} \end{array} \right. \\ \text{Muscular, to perineal muscles.} \end{array} \right. \\ \text{Inferior Hemorrhoidal, } \left\{ \begin{array}{l} \text{to Sphincter ani muscle.} \\ \text{to Skin of anal region.} \end{array} \right. \\ \text{Dorsal of Penis, } \left\{ \begin{array}{l} \text{Skin of dorsum of penis.} \\ \text{Br. to Corpora cavernosa.} \end{array} \right. \end{array} \right.$

The Sacral Plexus lies in the pelvis upon the Pyriformis muscle, and is covered by the Pelvic fascia, and the Sciatic and Pudic Arteries.

**THE NERVOUS SYSTEM.—Continued.**

**DISTRIBUTION OF THE NERVES  
OF THE LEG AND FOOT.**

[TERMINAL BRANCHES OF THE GREAT SCIATIC.]

EXTERNAL POPLITEAL OF PERONEAL NERVE.	}	(1). <i>Articular</i> (3), distributed to the knee-joint.	
		(2). <i>Cutaneous</i> (2 or 3), to skin of leg, exteriorly and posteriorly.	
		(3). ANTERIOR TIBIAL.	<i>Muscular</i> , to { front muscles of leg. Peroneus tertius.
			<i>External Br.</i> { Extensor brevis digitorum. Tarsal articulations.
		<i>Internal Br.</i> { Skin of contiguous sides of great and 2d toes.	
(4). MUSCULO- CUTANEOUS.	}	<i>Muscular</i> , . . { Peroneus longus and brevis.	
		<i>External Br.</i> { Skin, outer side of foot and ankle. Skin, contig. sides, 3d, 4th, 5th toes.	
		<i>Internal Br.</i> { Skin, inner side of foot and ankle. Skin, contig. sides, 2d and 3d toes, and inner side of great toe.	

INTERNAL POPLITEAL NERVE.	}	(1). <i>Articular</i> (3), to knee-joint.	
		(2). <i>Muscular</i> , to Gastrocnemius, Plantaris, Soleus, and Popliteus.	
		(3). EXT. SAPHENOUS,	formed by a filament from each of the Popliteal nerves, to skin of outer side of the foot and little toe.
			<i>Muscular</i> , to { Flexor longus pollicis, Flexor longus digitorum. Tibialis posticus.
POSTERIOR TIBIAL.	}	<i>Plantar Cutaneous</i> , to skin of heel and sole.	
		<i>Internal Plantar.</i>	<i>Digital</i> , to skin, 3½ inner toes.
			<i>Muscular</i> , to flexors, etc.
			<i>Articular</i> , to tarsus. <i>Cutaneous</i> , to sole of foot.
<i>External Plantar.</i>	}	<i>Muscular</i> , to Flexor accessorius. to 1½ outer toes.	
		<i>Superficial</i> , { Flexor brevis min. dig 4th Interosseous.	
		<i>Deep Br.</i> { 3d and 4th Lumbricales. Rest of Interossei.	

## THE NERVOUS SYSTEM.—Continued.

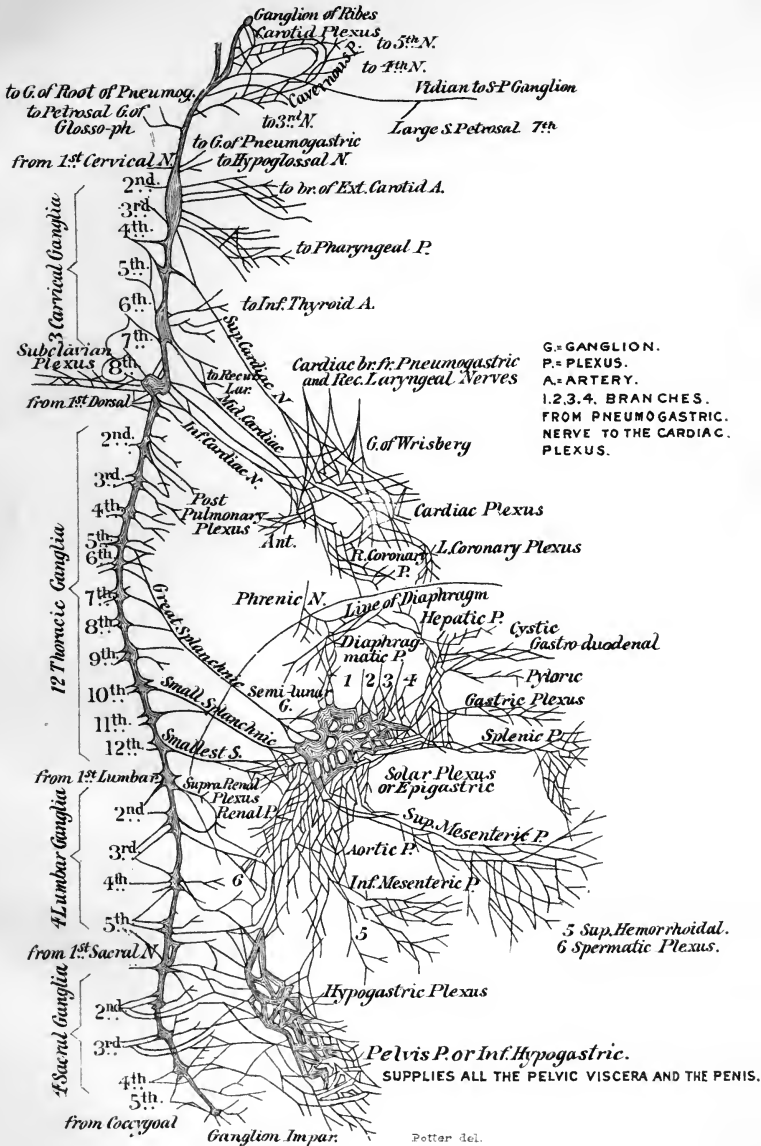
## THE SYMPATHETIC SYSTEM.

		Ganglion of Ribs		<ul style="list-style-type: none"> <li>on the Anterior Communicating Artery.</li> <li>In it begins the double chain of gangliated cords enumerated below.</li> </ul>
<ul style="list-style-type: none"> <li><i>External Branches</i></li> <li>to join the</li> <li>1st, 2d,</li> <li>3d, 4th</li> <li>Cervical</li> <li>Nerves.</li> </ul>	<ul style="list-style-type: none"> <li>Superior</li> <li>Cervical</li> <li>Ganglion</li> </ul>	<ul style="list-style-type: none"> <li><i>Sup. Brs.</i></li> </ul>	<ul style="list-style-type: none"> <li>Some to Pneumogastric, Glossopharyngeal, and Hypoglossal Nerves.</li> </ul>	
			<ul style="list-style-type: none"> <li><i>Ascend. Br.</i></li> </ul>	<ul style="list-style-type: none"> <li><i>Ext. Br.</i> forms CAROTID PLEXUS.</li> <li><i>Int. Br.</i> forms CAVERNOUS PLEX. along Int. Carotid Artery.</li> </ul>
		<ul style="list-style-type: none"> <li><i>Anterior Branches</i>, to Plexus on Ext. Carotid Artery.</li> </ul>	<ul style="list-style-type: none"> <li><i>Int. Brs.</i></li> </ul>	<ul style="list-style-type: none"> <li><i>Pharyngeal</i>, to PHARYNGEAL PLEXUS.</li> <li><i>Superior Cardiac Nerve</i>, to CARDIAC PLEXUS; goes to Deep Pl. on right side, to Superficial Pl. on left side of body.</li> </ul>
				<ul style="list-style-type: none"> <li><i>Middle Cervical Ganglion</i></li> </ul>
		<ul style="list-style-type: none"> <li><i>Inferior Cervical Ganglion</i></li> </ul>	<ul style="list-style-type: none"> <li><i>Int. Brs.</i></li> </ul>	<ul style="list-style-type: none"> <li><i>Filaments</i> along Vertebral Art. to cranium.</li> <li><i>Inf. Cardiac Nerve</i>, to DEEP CARDIAC PLEXUS.</li> </ul>
		<ul style="list-style-type: none"> <li>12</li> <li>Thoracic Ganglia.</li> </ul>	<ul style="list-style-type: none"> <li><i>Int. Brs.</i></li> </ul>	<ul style="list-style-type: none"> <li>Upper 5 or 6 to Aorta and Vertebral column.</li> <li>2d, 3d and 4th to Post. Pulmonary Plexus.</li> <li>Lower 6 from the 3 Splanchnic Nerves, thus—</li> <li>6-10, <i>Great Splanchnic</i>, to Semi-lunar Gang.</li> <li>10, 11, <i>Small Splanchnic</i>, to Celiac Plexus.</li> <li>12, <i>Smallest Splanchnic</i>, to Renal Plexus.</li> </ul>
		<ul style="list-style-type: none"> <li>4</li> <li>Lumbar Ganglia.</li> </ul>	<ul style="list-style-type: none"> <li><i>Int. Brs.</i></li> </ul>	<ul style="list-style-type: none"> <li>Some to Aortic Plexus.</li> <li>Some to Hypogastric Plexus.</li> </ul>
		<ul style="list-style-type: none"> <li>4</li> <li>Sacral Ganglia.</li> </ul>	<ul style="list-style-type: none"> <li><i>Int. Brs.</i></li> </ul>	<ul style="list-style-type: none"> <li>to Pelvic Plexus.</li> <li>to Plexus on Middle Sacral Artery.</li> </ul>
		<ul style="list-style-type: none"> <li>Coccygeal G., or Ganglion Impar.</li> </ul>	<ul style="list-style-type: none"> <li>In which ends the double chain of gangliated cords enumerated above, and called THE SYMPATHETIC NERVOUS SYSTEM.</li> </ul>	

[FOR THE VARIOUS CONNECTED GANGLIA, ETC., SEE *ante*, PAGES 137 TO 140.]



# THE SYMPATHETIC SYSTEM OF NERVES.





# INDEX.

NOTE.—Titles which contain the name of a person are entered twice, one entry being under the person's name, the other under that of the structure.

	PAGE		PAGE
<b>A</b> BDOMEN.....	161	Arteries, Pharyngeal.....	145
Abdominal Cavity.....	161	Sub-lingual.....	145
Regions.....	162	Arteries of the—	
Absorbents.....	119	ankle-joint.....	65
Acervulus cerebri.....	127	auditory canal.....	214
Acetabulum.....	41	auricle.....	214
Adenology.....	9	bone.....	12
Alveoli.....	11, 23	choroid.....	200
of the lungs.....	173	elbow-joint.....	61
Alveolus.....	141	Eustachian tube ..	219
Amphiarthrosis.....	55	eye.....	206
Ampulla of semi-circ. canals.....	221	eyelids.....	210
of the milk-ducts.....	192	hip-joint.....	63
Anastomoses.....	114	iris.....	202
Anastomosis, The Stirrup.....	113	kidney.....	176
Anatomy.....	9	knee-joint.....	63
Angiology.....	9	labyrinth.....	225
Angle of the jaw.....	28	larynx.....	170
Visual.....	197	lung.....	173
Angulus vestibularis.....	224	mammaræ.....	192
Annulus ovalis.....	100	membrana tympani.....	215
Anti-helix.....	213	nasal fossæ.....	196
Anti-tragus.....	213	nose.....	196
Antrum of Highmore.....	22	oesophagus.....	148
Anus.....	152	ovaries.....	191
Aorta.....	102	pancreas.....	157
Apparatus ligam. colli.....	57	penis.....	183
Appendices epiploicæ.....	152, 165	pharynx.....	147
Appendix auriculæ.....	100	retina.....	203
Ensiform.....	38	shoulder-joint.....	60
vermiformis.....	151	stomach.....	150
Aponeuroses.....	67	supra-renal capsules.....	161
Aponeurosis, Pharyngeal.....	147	testicle.....	185
Apophysis.....	10	thymus gland.....	160
Aqueduct of Sylvius.....	124	thyroid gland.....	159
Aqueductus cochleæ.....	17, 35, 222	tympanum.....	218
Fallopîi.....	216	uterus.....	190
vestibuli.....	16, 35, 220	wrist-joint.....	62
Arachnoid of brain.....	121	Arteriolæ rectæ.....	176
of spinal cord.....	129	Artery.....	102
Arbor vitæ.....	129	Anastomotica magna.....	108, 112
Arch, Crural.....	227, 229	Aorta.....	108, 109
Palmar.....	108	Art. receptaculi.....	105
Plantar.....	113	Auricular.....	105
Areola of mammæ.....	192	Axillary.....	107
Arm.....	45	Basilar.....	106
Arnold's ganglion.....	137	Brachial.....	107
nerve.....	35, 132	Carotid.....	103, 104, 105
Arteriæ propriæ renales.....	176	Cerebral, Anterior.....	105, 207
Arterial anastomoses.....	114	Middle.....	106
Arteries.....	102	Choroid, Anterior.....	106
Helicine.....	182	Circumflex, Anterior.....	107
Hepatic.....	155	Posterior.....	106
Lingual.....	145	Communicating, Anterior.....	106

	PAGE		PAGE
Artery, Communicating, Posterior.....	106	Artery, Vaginal.....	110
Coronary.....	103	Vertebral.....	106
Digital.....	114	Vesical.....	110
Dorsalis hallucis.....	113	Arthrodial joints.....	55
pedis.....	113	Articulation.....	55
Epigastric.....	111, 227	Atlo-axoid.....	57
Superficial.....	112	Carpal.....	62
Facial.....	104	Carpo-metacarpal.....	62
Femoral.....	111	Costo-sternal.....	58
Gastric.....	109	Costo-transverse.....	58
Gluteal.....	111	Costo-vertebral.....	58
Hemorrhoidal.....	110	Metacarpo-metacarpal.....	63
Hepatic.....	109	Metatarso-metatarsal.....	66
Iliac, Circumflex.....	111	Occipito-atloid.....	56
External.....	111	Occipito-axoid.....	57
Internal.....	110	Phalangeal of foot.....	66
Ilio-lumbar.....	111	of hand.....	63
Infra-orbital.....	207	Radio-ulnar.....	59, 61
Innominate.....	103	Sacro-coccygeal.....	59
Intercostales.....	107, 108	Sacro-iliac.....	59
Lingual.....	104	Sacro-ischiatic.....	59
Lumbar.....	110	Sacro-vertebral.....	59
Mammary.....	107	Scapulo-clavicular.....	60
Maxillary, Internal.....	105	Sterno-clavicular.....	60
Meningeal, Anterior.....	105	Tarsal.....	53, 65
Mesenteric, Inferior.....	110	Tarsometatarsal.....	66
Superior.....	109	Temporo-maxillary.....	57
of Neubauer.....	103, 159	Tibio-fibular.....	65
Obturator.....	110, 229	Vertebral.....	56
Occipital.....	105	Arytenoid cartilages.....	166
Ophthalmic.....	105, 206	Atlas.....	37
Palmar arches.....	108	Auricle.....	213
Peroneal.....	113	Axis.....	37
Pharyngeal, Ascending.....	105	Celiac.....	103, 109
Phrenic.....	109	Optic.....	197
Plantar.....	113	Thyroid.....	107
Popliteal.....	112	Visual.....	197
Profunda femoris.....	112	Azygos.....	11
inferior.....	108	uvulæ.....	74
superior.....	107		
Pudic.....	111	<b>B</b> AND, Dollinger's.....	201
External.....	112	Bartholine, Duct of.....	145
Pulmonary.....	114	Glands of.....	188
Radial.....	108	Bauhin, Valve of.....	150, 151
Renal.....	110	Bell, Nerve of.....	133
Sacral, Lateral.....	111	Bellini, Tubes of.....	176
Middle.....	110	Bertin, Columns of.....	175
Sciatic.....	111	Bladder.....	178
Spermatic.....	110	Blastema.....	12
Splenic.....	109, 159	Bodies, Malpighian.....	176
Subclavian.....	106	Pacchionian.....	121
Sub-scapular.....	107	Body, Ciliary.....	200
Supra-renal.....	110	Hyaloid.....	205
Supra-scapular.....	107	Olivary.....	128
Temporal.....	105	Perineal.....	232
Thoracic, Acromial.....	107	Pituitary.....	123
Superior.....	107	Restiform.....	128
Thoracica alaris.....	107	Bone.....	11
longa.....	107	Astragalus.....	53
Thyroid.....	104, 159	Clavicle.....	44
Inferior.....	107	Coccyx.....	41
Thyroidea ima.....	159	Cuboid.....	54
Tibial, Anterior.....	112	Cuneiform.....	49, 54
Transversalis colli.....	107	Etmoid.....	21
Tympanic.....	105, 218	Femur.....	50
Ulnar.....	108	Fibula.....	52
Uterine.....	110	Frontal.....	12

	PAGE		PAGE
Bone, Humerus.....	45	Bulb of corpus spongiosum.....	182
Hyoid.....	53	Bulbi vestibuli.....	187
Ilium.....	42	Bulbs, Olfactory.....	123
Incus.....	217	Burns, Ligament of.....	228
Innominate.....	41	Bursæ of knee-joint.....	65
Ischium.....	42	<b>CÆCUM</b> .....	151
Lachrymal.....	24	Calamus scriptorius.....	128
Malar.....	24	Calices of the kidney.....	175
Malleus.....	217	Canal, Alimentary.....	141
Maxillary, Inferior.....	27	Auditory, External.....	214
Superior.....	22	Internal.....	225
Nasal.....	22	Carotid.....	17
Occipital.....	14	Central of the Cord.....	129
Os calcis.....	53	Crural.....	228
Os magnum.....	49	Dental.....	22, 28
Palate.....	25	Femoral.....	228
Parietal.....	13	Hunter's.....	93
Pectineal.....	43	Hyaloid.....	205
Peroneal.....	52	Infraorbital.....	22, 29
Phalanges of foot.....	54	Inguinal.....	226
of hand.....	50	of the modiolus.....	221
Pisiform.....	49	Nutrient.....	52, 53
Pubic.....	43	Palatine.....	23
Sacral.....	40	Sacral.....	41
Scaphoid.....	49, 54	Spiral of the cochlea.....	221
Scapula.....	44	for tensor tympani.....	35
Semilunar.....	49	Vidian.....	20, 35
Sphenoid.....	18	Canal of—	
Stapes.....	217	Cloquet.....	205
Sternum.....	38	Fontana.....	202
Temporal.....	15	Hugier.....	16, 35, 215
Tibia.....	51	Nuck.....	190
Trapezium.....	49	Petit.....	204
Trapezoid.....	49	Schlemm.....	202
Turbinated.....	19	Stilling.....	205
Inferior.....	26, 31	Canaliculi.....	II. 212
Ulna.....	47	Canalis reuniens.....	223
Unciform.....	49	Canals, Semicircular.....	221
Vomer.....	26	Membranous.....	223
Bones of the—		Canthus.....	210
Body.....	9	Capillaries.....	102
Carpus.....	48	Capsule of Bonnet.....	197
Foot.....	53	of Glisson.....	156
Hand.....	48	of the lens.....	204
Head.....	12	of Müller.....	176
Leg.....	51	of Tenon.....	197
Lower extremity.....	50	Capsules, Supra-renal.....	160
Metacarpus.....	49	Caput cæcum coli.....	151
Metatarsus.....	54	gallinaginis.....	179
Tarsus.....	53	Carpus.....	49
Trunk.....	36	Cartilage.....	56
Upper extremity.....	43	Cartilages of the larynx.....	165
Bones, Unclassified.....	10	of Santorini.....	167
Wormian.....	10, 33	Tarsal.....	210
Bonnet, Capsule of.....	197	of Wrisberg.....	167
Bowman's membrane.....	199	Cartilago triticea.....	167
Muscle.....	200	Caruncula lachrymalis.....	211
Bowman and Todd's muscle.....	224	Carunculæ myrtiformes.....	187
Brain.....	120	Cauda equina.....	41, 129
Commissures of Brain.....	124	Cavity, Cotyloid.....	41
Divisions.....	121	Glenoid of scapula.....	45
Points on surface.....	123	of the omentum.....	163
Ventricles.....	124	Orbital.....	29
Weights of average.....	121	of reserve.....	144
Bronchi.....	170, 171	Sigmoid.....	47
Brunner's glands.....	151	of the radius.....	48
Bulb of corpus cavernosum.....	182		

	PAGE		PAGE
Cells, Auditory.....	224	Corpus Highmorianum.....	184
Ethmoid.....	21	luteum.....	191
Hepatic.....	156	spongiosum.....	182
Mastoid.....	16, 216	Corpuscles, Malpighian.....	158
Olfactory of Schultze.....	196	Tactile.....	194
Cement.....	144	Corti, Organ of.....	224
Cerebellum.....	128	Cortical substance.....	175
Cerebrospinal system.....	120	Cotunnus, Liquor of.....	219
Cerebrum.....	121	Cotyloid.....	11
its convolutions.....	122	Coverings of the testicle.....	184
its lobes, fissures, etc.....	121	of hernia.....	227, 229
Cervix of the penis.....	182	Cowper's glands.....	181
uteri.....	189	Crest of the ilium.....	42
Chopart's operation.....	53	lachrymal.....	30
Chordæ tendinæ.....	100	nasal.....	23
Choroid tunic.....	200	of the pubes.....	43
plexus.....	125	of the tibia.....	52
Cilia.....	210	turbanated.....	23, 25
Circle of Willis.....	106	Cricoid cartilage.....	166
Circulus arteriosus.....	201	Crista galli.....	21
iris minor.....	202	vestibuli.....	220
major iris.....	202	Crura cerebri.....	123, 127
venosus.....	192	of penis.....	182
Clavicle.....	44	Crusta petrosa.....	142
Clinoid.....	11	Crypts of Lieberkühn.....	151
Clitoris.....	187	Cuneiform cartilages.....	167
Cloquet, Canal of.....	205	Cuneus.....	122
Fascia of.....	228	Cupola of cochlea.....	221
Coccyx.....	41	Cuticle.....	193
Cochlea, Membranous.....	223		
Osseous.....	220	<b>DARTOS</b> .....	183
Cœliac Axis.....	103, 109	Dentine.....	142
Collar-bone.....	44	Derma.....	193
Colon.....	152	Dermatology.....	9
Flexures of.....	152	Descemet, Membrane of.....	199
Columnæ carnae.....	101	Diaphragm.....	83
papillares.....	101	Diarthrosis.....	55
Columns of Bertin.....	175	Digestion, Organs of.....	141
of spinal cord.....	129	Disc, Optic.....	202
Commissure, Optic.....	123, 208	Discus proligerus.....	191
Concha.....	213	Dollinger's band.....	201
Condyles.....	10	Dorsum of scapula.....	44
of femur.....	51	Douglas' cul-de-sac.....	188
of humerus.....	46	Duct of Bartholine.....	145
Coni vasculosi.....	184	Cystic.....	157
Conjunctiva.....	211	of Gærtner.....	192
Conus arteriosus.....	101	Hepatic.....	155, 157
Convulsions of cerebrum.....	122	Lymphatic.....	120
Cooper, Fascia of.....	229	of Müller.....	185
Coracoid.....	11	Nasal.....	212
Corium.....	194	Pancreatic.....	157
Cornea.....	199	of Rivinus.....	145
Cornicula laryngis.....	167	of Steno.....	144
Cornua of thyroid cartilage.....	166	Thoracic.....	119
uteri.....	189	of Wharton.....	144
of the ventricles.....	125	of Wirsung.....	157
Corona glandis.....	182	Ducts, Biliary.....	157
radiata.....	127	Ejaculatory.....	186
Coronoid.....	11	Seminal.....	180
Corpora albicantia.....	123, 125	Ductus cochlearis.....	223
cavernosa.....	182	communis choledochus.....	157
quadrigemina.....	124, 127	Duodenum.....	150
striata.....	123	Dura mater of cerebrum.....	120
Corpus Arantii.....	101	of spinal cord.....	129
callosum.....	123, 125		
dentatum.....	128, 129	<b>EAR</b> .....	212
fimbriatum.....	125	Internal.....	219

	PAGE
Earstones .....	223
Eminence, Hypothenar.....	90
Thenar.....	90
Eminentia collateralis.....	125
Enamel.....	142
Enarthrosis.....	55
Endocardium.....	99
Endolymph.....	220
Endosteum.....	11
Epidermis.....	193
Epididymis.....	184
Epigastric region.....	162
Epiglottis.....	167
Epiphysis.....	11
Epiploa.....	164
Equator of eye-ball.....	197
Eustachian tube.....	219
Eye.....	197
Its appendages.....	209
Eyeball.....	197
Eyebrows.....	209
Eyelashes.....	210
Eyelids.....	209
<b>FACET</b> .....	<b>11</b>
Fallopian tubes.....	190
Fallopian, Aqueduct of.....	216
Hiatus of.....	35
Falx cerebelli.....	121
cerebri.....	120
Fascia, Anal.....	230
Buck's.....	230
of Cloquet.....	229
of Cooper.....	229
Cremasteric.....	227
Cribriform.....	228
Dentata.....	125
Intercolumnar.....	226
Ischio-rectal.....	230
Lata.....	91
Lumbar.....	82
Obturator.....	230
Palmar.....	90
Perineal.....	230, 232
Plantar.....	97
Recto-vesical.....	230
Tarso-orbital.....	211
of Testis.....	184
Fasciæ.....	67
of the perineum.....	230
Fasciculus cuneatus.....	128
gracilis.....	128
Fauces.....	144
Femur.....	50
Fenestra ovalis.....	216, 220
rotunda.....	216
Ferrein, Pyramids of.....	176
Tubes of.....	176
Fibro-cartilage.....	56
Fibula.....	52
Fimbriæ.....	190
Fimbriated extremities.....	190
Fissure, Auricular.....	17, 35
Ethmoidal.....	34
Glaserian.....	15, 35, 216
Palpebral.....	209

	PAGE
Fissure Pterygo-maxillary.....	32
of Rolando.....	122
Spheno-maxillary.....	30, 32
Sphenoidal.....	20, 30, 34
of Sylvius.....	122
Transverse.....	125
Fissures of cerebellum.....	128
of cerebrum.....	122
of liver.....	154
of spinal cord.....	129
Folds, Retro-tarsal.....	211
Semi-lunar.....	211
Fontana, Canal of.....	202
Spaces of.....	201
Fontanelles.....	33
Foot.....	53
Foramen for Arnold's nerve.....	17, 35
Cæcum.....	12, 34
Condyloid.....	35
Ethmoidal.....	30, 34
Incisive.....	23, 35
Infra-orbital.....	22, 35
Inter-vertebral.....	36
for Jacobson's nerve.....	17, 35
Lacerum anterior.....	20, 30, 34
medium.....	35
posterior.....	35
Magnum.....	14, 35
Mastoid.....	16, 35
Mental.....	27, 35
of Munroe.....	124
Nutrient.....	47, 48
Obturator.....	42
Olfactory.....	34
Ovale.....	19, 34
Optic.....	20, 30, 34
Orbital.....	19
Palatine.....	25, 35
Petrosal.....	35
Pterygo-palatine.....	35
Rivinian.....	215
Rotundum.....	19, 34
Sacral.....	41
of Scarpa.....	23
Spheno-palatine.....	25
Spinal.....	36
Spinousum.....	19, 34
of Stenson.....	23
Stylo-mastoid.....	17, 35
Supra-orbital.....	30, 35
Supra-scapular.....	45
Thyroid.....	42
Vesalii.....	19, 34
of Winslow.....	163
Foramina at the base of the skull.....	34
Olfactory.....	31
Orbital.....	29
Spheno-maxillary.....	32
Thebesii.....	100
Fore-arm.....	47
Fornix.....	125
Fossa, Canine.....	22
Coronoid.....	46
Di-gastric.....	28
Digital.....	50
Glenoid.....	15
Hyaloid.....	204, 205

	PAGE		PAGE
Fossa, Incisive.....	22, 27	Glans clitoridis.....	187
Infra-spinous.....	44	penis.....	182
Ischio-rectal.....	230	Glenoid.....	11
Jugular.....	17	Glisson's capsule.....	156
Lachrymal.....	29	Globus major.....	184, 185
Navicularis of vulva.....	188	minor.....	185
of penis.....	180	Glottis.....	168
of auricle.....	213	Gomphosis.....	55
Olecranon.....	46	Graafian vesicle.....	191
Ovalis.....	100	Groove, Bicipital.....	46
Pterygoid.....	20	Infraorbital.....	23, 29
Scaphoid.....	20	Musculo-spiral.....	46
Spheno-maxillary.....	32	Mylo-hyoid.....	28
Sublingual.....	28	Naso-palatine.....	27
Sub-maxillary.....	28	Optic.....	18
Subscapular.....	44	Pterygo-palatine.....	19
Supraspinous.....	44	Gubernaculum testis.....	186
Temporal.....	32	Gums.....	141
Triangularis.....	213	Gyrus, Angular.....	122
Zygomatic.....	32	Fornicatus.....	122
Fossæ, Nasal.....	31	<b>H</b> AIRS.....	194
of the Skull.....	34, 35	Hamstrings.....	94
Fourchette.....	188	Hamular.....	11
Fovea centralis.....	202	Hand.....	48
hemispherica.....	220	Haversian canals.....	11
semi-elliptica.....	220	system.....	11
Frenulum.....	127	Head of the humerus.....	45
Frenum preputii.....	183	of the ulna.....	47
<b>G</b> AERTNER, Duct of.....	192	Heart.....	99, 100
Gall-bladder.....	156	Heel.....	53
Ganglia, Basal.....	123	Helicotrema.....	221
Cervical.....	138	Helix.....	213
of Fifth nerve.....	137	Henle, Tubes of.....	176
of the Sympathetic.....	137	Hernia.....	226
Ganglion, Arnold's.....	137	Femoral.....	228
Gasserian.....	131, 138	Inguinal.....	226
Impar.....	137, 139	Hey, Ligament of.....	228
Meckel's.....	137, 196	Operation of.....	54
of Ribes.....	137	Hiatus Fallopii.....	16, 35
Spheno-palatine.....	196	Hilton, Sac of.....	168
Spirale.....	225	Hilum of kidney.....	175
Gasser, Ganglion of.....	131, 138	Hippocampus Major.....	125
Genesiology.....	9	Minor.....	125
Gimbernat's ligament.....	227	Horner's muscle.....	68
Ginglymus.....	55	Houston, Folds of.....	152
Gladius.....	38	Hugier, Canal of.....	16, 35, 216
Gland, Lachrymal.....	211	Humerus.....	45
Mammary.....	192	Humor, Aqueous.....	204
Pineal.....	127	Vitreous.....	205
Prostate.....	181	Humors of the eyeball.....	198
Thymus.....	160	Hunter's Canal.....	93
Thyroid.....	159	Hydatids of Morgagni.....	185
Glands of Bartholine.....	188	Hymen.....	187
Brunner's.....	151	Hypochondrium.....	162
Cowper's.....	181	Hypogastrium.....	163
Ductless.....	158	<b>I</b> LEUM.....	150
Gastric.....	149	Ilium.....	42
Intestinal.....	152	Incisura intertragica.....	213
Lachrymal.....	211	Infundibula of kidney.....	175
Littré's.....	180	Infundibulum.....	13
Lymphatic.....	119	of brain.....	123
Meibomian.....	194, 210	of cochlea.....	221
Sebaceous.....	194	Inguinal regions.....	163
Solitary.....	151	Intestine, Large.....	151
Sweat.....	195	Small.....	150
of Tyson.....	183		



	PAGE		PAGE
Intumescencia gangliiformis Scarpæ.....	225	Ligament, Orbicular.....	61
of 7th nerve.....	138	Poupart's .....	91, 227
Iris.....	201	Rhomboid.....	63
Ischium.....	42	Round of the liver.....	154
Island of Reil.....	122	of the uterus.....	189
Iter chordæ anterioris.....	216	Sacro-sciatic.....	59
Iter chordæ posterioris.....	216	Stellate.....	58
Iter e tertio ad quartam ventriculū.....	124	Stylo-mastoid.....	57
Ivory.....	142	Suspensory of lens.....	204
<b>JACOB'S MEMBRANE</b> .....	203	of liver.....	154
Jacobson's nerve.....	35, 132, 216, 218	of penis.....	182
Jejunum.....	150	of spleen.....	158
Joint, Ankle.....	65	Transverse.....	57
Elbow.....	61	of hip-joint.....	63
Hip.....	63	Trapezoid.....	63
Rotators of the hip-joint.....	95	Triangular.....	227
Knee.....	63	of perineum.....	230
Shoulder.....	60	of Zinn.....	205
Wrist.....	62	Ligaments.....	56
Joints, Motion in.....	55	of the Bladder.....	178
Structures of.....	55	Broad.....	189
<b>KIDNEYS</b> .....	175	Canthal.....	210
Kirkring's valves.....	151	Check.....	57
<b>LABIA MAJORA</b> .....	187	of the Knee-joint.....	64
minora.....	187	of the Larynx.....	167
Labium tympanicum.....	224	of the Liver.....	154
vestibulare.....	224	of the Ossicles.....	217
Labyrinth.....	219, 220	of the Ovaries.....	190
Membranous.....	222	Peritoneal.....	164
Lacteals.....	119	of the Scapula.....	60
Lacuna magna.....	180	of the Sternum.....	58
Lacunæ.....	11	Tarsal.....	210
Lacus lachrymalis.....	209	of the Uterus.....	189
Lamina cinerea.....	123	Ligamentum latum pulmonis.....	174
cribrosa.....	198	mucosum.....	64
fusca.....	198	nuchæ.....	76
reticularis.....	224	pachellæ.....	64
spiralis.....	221	pectinatum iridis.....	201
Laminæ.....	36	spirale.....	224
Lancisi, Nerves of.....	125	suspensorium.....	57
Larynx.....	165	teres.....	63
Layer, Dermoid.....	215	Winslowii.....	64
Ganglionic.....	203	Limbus laminæ spiralis.....	223
Granular.....	203	Line, Inter-trochanteric.....	50
Molecular.....	203	Popliteal.....	52
Leg.....	51	Linea aspera.....	51
Lens, Crystalline.....	204	ilio-pectinea.....	42
Lieberkuhn, Crypts of.....	151	quadrati.....	50
Ligament, Annular.....	90	Liquor Cotunnii.....	220
Annular of foot.....	97	Morgagni.....	204
of Burns.....	228	Scarpæ.....	220
Canthal, External.....	210	Lithotomy, Structures affected.....	231
Conoid.....	60	Littre, Glands of.....	180
Coronary.....	64, 154	Liver.....	153
Costo-xiphoid.....	58	Structure of liver.....	156
Cotyloid.....	63	Lobe of the ear.....	213
Crucial of knee-joint.....	64	Lobes of the cerebellum.....	128
Cruciform.....	57	of the cerebrum.....	121
Deltoid.....	65	of the liver.....	154
Falciform.....	154	Optic.....	124, 127
Gimbernat's.....	227	Lobule, of the ear.....	213
Glenoid.....	60	Paracentral.....	122
of Hey.....	228	Lobules of the liver.....	156
Ilio-femoral or Y.....	63	of the lung.....	173
		Lobulus caudatus.....	155
		quadratus.....	154
		Spigelii.....	155

	PAGE		PAGE
Locus niger.....	127	Mesenteries.....	164
Lower, Tubercle of.....	100	Meso-cephalon.....	127
Lumbar regions.....	163	Mesos.....	164
Lung, Broad ligament of.....	174	Metacarpus.....	49
Lungs.....	171	Metatarsus.....	54
Lunula.....	194	Modiolus.....	221
Lymphatics.....	119	Mons veneris.....	187
Hepatic.....	156	Morgagni, Hydatids of.....	185
of Lung.....	173	Sinus of.....	168
of Penis.....	183	Mouth.....	144
of Supra-renal capsules.....	161	Müller, Capsule of.....	176
of Thyms gland.....	160	Duct of.....	185
of Trachea and Bronchi.....	171	Muscle of.....	201
of Uterus.....	190	Munroe, Foramen of.....	124
Lymph-spaces of eyeball.....	207	Muscle of Bowman.....	200
Lyra.....	125	Ciliary.....	200
		Cremaster.....	227
<b>MACULA ACOUSTICA</b> .....	223	Dilator papillæ.....	202
Macula lutea.....	202	Horner's.....	68
Maculæ cribrosæ.....	220	Kerato-cricoideus.....	169
Malleolar.....	11	Levator glandulæ thyroideæ.....	159
Malleolus.....	52, 53	of Müller.....	201
Malpighi, Bodies of.....	176	Sphincter papillæ.....	202
Pyramids of.....	176	of Todd and Bowman.....	224
Malpighian Corpuscles.....	158	Triticeo-glossus.....	169
Tuft.....	176	Muscles.....	67
Mammæ.....	192	of the abdomen.....	80-82
Manubrium.....	38	of the arm.....	85
of the malleus.....	217	of the auricle.....	213
Marrow of bone.....	12	of the back.....	76-80
Masses, Lateral of Ethmoid.....	21	Double-bellied.....	67
Mastoid.....	11	of the ear.....	71
Meatus auditorius externus.....	16	of the epiglottis.....	75, 169
internus.....	35	of the eustachian tube.....	219
nasi.....	31	of the eyeball.....	68, 205
urinarius.....	183, 187	of the face.....	69, 70
Meckel's ganglion.....	137	of the forearm.....	87
Mediastinum.....	174	of the foot.....	98
testis.....	184	of the hand.....	90
Medulla oblongata.....	127	of the head.....	68
Medullary substance.....	175	of the hip.....	91
Membrana basilaris.....	224	of the larynx.....	75, 168
granulosa.....	191	of the leg.....	95
pupillaris.....	202	of the neck.....	71-75
Ruyshiana.....	200	of the palate.....	74
sacciformis.....	61, 62	of the perineum.....	83, 231
tectoria.....	224	of the pharynx.....	73, 147
tympani.....	214	of the shoulder.....	85
secundaria.....	216	of the stomach.....	149
Membrane of Bowman.....	199	of the thigh.....	91
of Descemet.....	199	of the thorax.....	82
Hyaloid.....	205	of the tympanum.....	218
Interosseous.....	61, 65	Muscular fibre.....	67
Jacob's.....	203	Musculi pectinati.....	100
Limiting.....	203	Myology.....	9
Pituitary.....	195		
of Reichert.....	199	<b>NABOTH, Ovules of</b> .....	190
of Reissner.....	223	Nails.....	194
Schneiderian.....	195	Nates of cerebrum.....	127
Shrapnell's.....	215	Nasmyth's membrane.....	142
Vitelline.....	191	Neck of humerus.....	45, 46
Membranes of Brain.....	120	Neubauer, Artery of.....	103
of the Spinal Cord.....	129	Nerve.....	120
Synovial.....	56	Abducens.....	131
Tarsal synovial.....	66	Arnold's.....	17, 35, 132
Wrist synovial.....	62	Auditory.....	131, 225
Meridians of eyeball.....	197	Bell's respiratory.....	133

	PAGE		PAGE
Nerve, Chorda tympani.....	131, 195, 218	Nerves of pancreas.....	158
Circumflex.....	134	of penis.....	183
Cochlear.....	225	Petrosal.....	131, 138, 140
Crural anterior.....	135	of pharynx.....	147
Facial.....	131	Popliteal.....	136
Genito-crural.....	135	Sciatic.....	136
Glosso-pharyngeal.....	132	of shoulder-joint.....	60
Hypo-glossal.....	132	Spinal.....	133
Ilio-hypogastric.....	135	Splanchnic.....	139
Ilio-inguinal.....	135	of spleen.....	159
Intercosto-humeral.....	134	of stomach.....	150
Interosseous.....	134	of supra-renal capsules.....	161
Jacobson's.....	17, 35, 132, 215, 218	of taste.....	195
Laryngeal.....	170	of testicles.....	185
Maxillary, Inferior.....	131	of thymus gland.....	160
Superior.....	131	Thyroid.....	160
Median.....	133, 134	of tongue.....	146
Motor oculi.....	130	of trachea and bronchi.....	171
Musculo-spiral.....	134	of tympanum.....	218
Nonus or 9th pair.....	132	of uterus.....	190
Obturator.....	135	of wrist-joint.....	62
Olfactory.....	130	Nervous system.....	120
Ophthalmic div. of 5th.....	131	Neurilemma.....	120
Optic.....	130, 209	Neurology.....	9
Par vagum.....	132	Nipple.....	192
Patheticus.....	130	Nose.....	195
Phrenic.....	133	Notch, Cotyloid.....	42
Pneumogastric.....	132	Inter-clavicular.....	38
Portio dura.....	131	Inter-condyloid.....	51
Portio mollis.....	131	Popliteal.....	52
Pudic.....	135	Sacro-sciatic.....	42, 43
Radial.....	134	Sigmoid.....	28
Spinal accessory.....	132	Supra-orbital.....	30, 35
Sympathetic.....	136	Supra-scapular.....	45
Thoracic.....	134	Nuck, Canal of.....	190
Trigeminus.....	130	Nymphæ.....	187
of tongue movements.....	195	<b>O</b> DONTOBLASTS.....	12, 143
Tympanic.....	218	Odontoid.....	11
Ulnar.....	134	Oesophagus.....	147
Vestibular.....	225	Omentum.....	163, 164
Vidian.....	140	Opening, Saphenous.....	91, 229
of Wrisberg.....	134	Opercula.....	143
Nerve-fibres, Optic.....	203	Optic thalami.....	123
Nerves of ankle-joint.....	65	Ora serrata.....	202
of auditory canal.....	214	Orbit.....	29
of auricle.....	214	Organ of Corti.....	224
of bladder.....	179	of hearing.....	212
of choroid.....	200	of Rosenmüller.....	192
Cranial.....	129	of sight.....	197
of elbow-joint.....	61	of smell.....	195
of eustachian tube.....	219	Organs of generation.....	181, 187
of eye.....	207	of sense.....	193
of eyelids.....	210	of taste.....	195
of eye-muscles.....	206	Urinary.....	175
Hepatic.....	156	of voice and respiration.....	165
of hip-joint.....	63	Os orbiculare.....	217
of iris.....	202	planum.....	21
of kidney.....	177	tincæ.....	189
of knee-joint.....	63	uteri.....	189
of Lancisi.....	125	Ossa innominata.....	41
of larynx.....	170	triqueta.....	33
of lung.....	173	Osteology.....	9
of membrana tympani.....	216	Ossification.....	12
of nasal fossa.....	196	Ossicles of tympanum.....	217
of nose.....	196	Otoliths.....	223
of oesophagus.....	148	Ovaries.....	190
of ovaries.....	191		

	PAGE		PAGE
Oviducts.....	190	Pons Varolii.....	127
Ovisacs.....	191	Tarini.....	123
Ovules of Naboth.....	190	Portal system.....	118
Ovum.....	191	Porus opticus.....	198
<b>PACCHIONIAN BODIES</b> .....	13	Porus of membrana tympani.....	215
Palate.....	144	Poupart's ligament.....	227
Palpebræ.....	209	Precuneus.....	122
Pampiniform plexus.....	186	Prepuce.....	183
Pancoast, W. H.....	49, 50, 95, 230	of the clitoris.....	187
Pancoast's triangle.....	98	Process, Acromion.....	44
Pancreas.....	157	Alveolar.....	23
Lesser.....	158	Articular.....	36
Papilla, Lachrymal.....	209	Auditory.....	16
Optic.....	202	Basilar.....	14
Papillæ of skin.....	194	Clinoid.....	18
Parovarium.....	192	Condyloid.....	28
Pars ciliaris retinæ.....	203	Coracoid.....	44
intermedia.....	187	Coronoid.....	28, 47
Peduncles of cerebellum.....	128	Ethmoidal.....	26
Pelvis.....	40	Falciform.....	228
of the kidney.....	175	Hamular.....	20, 24
Penis.....	182	of cochlea.....	221
Pericardium.....	99	Lachrymal.....	26
Perilymph.....	220	Malar.....	23
Perineum.....	230	Mastoid.....	16
Female.....	232	Maxillary.....	26
Periosteum.....	11	Mental.....	27
Peritoneum.....	163, 165	Nasal.....	23
Peroneus.....	52	Odontoid.....	37
Pes accessorius.....	125	Olecranon.....	47
hippocampi.....	125	Olivary.....	18
Petit, Canal of.....	204	Orbital.....	24, 26
Peyer's patches.....	151	Palate.....	23
Phalanges.....	50	Pterygoid.....	20, 25
Pharynx.....	146	Sphenoidal.....	26
Pia mater of brain.....	121	Spinous.....	36
of spinal cord.....	129	Styloid.....	17, 47, 48, 52
of the testes.....	184	Transverse.....	36
Pinna.....	213	Turbinated.....	21, 31
Plane, Equatorial.....	197	Unciform.....	21
Meridional.....	197	Vaginal.....	17, 19
Plantar arch.....	113	Vermiform.....	128
Plate, Cribriform.....	21	Zygomatic.....	15, 24
Orbital.....	21	Processes, Ciliary.....	200
Perpendicular.....	21	Clinoid.....	20
Pleuræ.....	174	of Ingrassias.....	20
Plexus, Brachial.....	133	Processus cochleariformis.....	17, 217
Carotid.....	139	e cerebello ad medullam.....	128
Cavernous.....	139	ad pontem.....	128
Cervical.....	133	ad testes.....	127, 128
Choroid.....	125	gracilis.....	217
Gastric.....	150	zonulæ.....	205
Lumbar.....	135	Promontory of tympanum.....	216
Lobular.....	155	Prostate gland.....	181
Pampiniform.....	186, 191	Prostatic urethra.....	179
Sacral.....	135	sinus.....	180
Solar.....	139	Pterygoid.....	11
Splenic.....	159	Pubes.....	43
Tympenic.....	218	Punctum lachrymale.....	209
Plexuses of the sympathetic.....	140	Pupil.....	201
Pli courbe.....	122	Pylorus.....	148, 149
Plica semilunaris.....	211	Pyramid, Anterior.....	127
Point, Nodal.....	197	Posterior.....	128
Poles of the eyeball.....	197	of tympanum.....	216
Pomum Adami.....	166	Pyramids of Ferrein.....	176
		of Malpighi.....	176
		of Wistar.....	19

	PAGE		PAGE
<b>RADIUS</b> .....	48	Sigmoid flexure ..	152
Rami of Inferior Maxillary.....	28	Silvius, Aquedu of.....	124
Ramus of ischium.....	43	Fissure of.....	122
of the pubes.....	43	Sinus aortici.....	102
Receptaculum chyli.....	119	circularis iridis.....	202
Rectum.....	152	of the kidney.....	175
Regions of abdomen.....	162	of Morgagni.....	168
Reichert, Membrane of.....	199	pocularis.....	180
Reil, Island of.....	122	Sinuses.....	115
Reissner, Membrane of.....	223	Sphenoidal.....	19
Renal vessels.....	176	of Valsalva.....	101
Rete mucosum.....	193	Skin.....	193
testis.....	184	Slit, Nasal.....	31
Retina.....	202, 204	Smell, Organ of.....	195
Ribes, Ganglion of.....	137	Space, Inter-peduncular.....	123
Ribs.....	38	Anterior perforated.....	123
Ridge, Mylo-hyoid.....	27	Posterior perforated.....	123
Pterygoid.....	19	Spaces, Fontana's.....	201
Rima glottidis.....	168	Spermatie cord.....	186
Ring, Abdominal.....	162, 226	Sphincter vesicæ.....	179
Crural.....	229	Spinal cord.....	129
Femoral.....	228	Spine, Ethmoidal.....	18
Rings and phalanges.....	225	of the ischium.....	43
Rivinus, Duct of.....	145	Nasal.....	23, 25, 31
Segment of.....	214	of the pubes.....	43
Rods and cones.....	203	of the scapula.....	44
of Corti.....	224	of the sphenoid.....	19
Rolando, Fissure of.....	122	of the tibia.....	51
Rosenmüller, Organ of.....	192	Spines of the ilium.....	42
Rostrum.....	11	Spina tympanica.....	214
of the sphenoid.....	19	Spinous.....	11
<b>SAC OF HILTON</b> .....	168	Splanchnology.....	9
Lachrymal.....	212	Spleen.....	158
Saccule.....	223	Spot, Blind.....	202
Sacculus laryngis.....	168	Germinal.....	191
Sacs of the peritoneum.....	163	Light.....	215
Sacrum.....	40	Yellow.....	202
Santorini, Cartilages of.....	167	Squamous.....	11
Sapolini.....	195	Stars of Verheyen.....	177
Scala media.....	222	Steno's ducts.....	144
tympani.....	222	Stenson's foramen.....	23
vestibuli.....	222	Sternum.....	38
Scapula.....	44	Stilling, Canal of.....	205
Scarpa, Foramen of.....	23	Styloid.....	11
Intumentescia gang. of.....	225	Stomach.....	148
Liquor of.....	220	Substance of Schwann.....	120
Scheyer's lines.....	142	Sulci.....	122
Schindylesis.....	55	sulcus spiralis internus.....	224
Schlemm, Canal of.....	202	tympanicus.....	214
Schultze, Olfactory cells of.....	196	Surface, Auricular.....	41, 42
Schwann, Substance of.....	120	Trochlear.....	46
Sclerotic.....	198	Sustentaculum tali.....	53
Scrotum.....	183	Sutura.....	55
Segment of Rivinus.....	214	Suture, Coronal.....	13
Sella Turcica.....	18	Lachrymo-ethmo-frontal.....	30
Septum crurale.....	228	Lambdoidal.....	13
lucidum.....	125	Palato-maxillary.....	29
nasi.....	31	Sagittal.....	13
pectiniforme.....	182	Spheno-malar.....	50
tubæ.....	17, 216	Sutures, Facial.....	33
Sheath, Crural.....	228, 229	of the orbit.....	30
Shin.....	52	of the skull.....	33
Shoulder.....	43	Sympathetic system.....	120
Shoulder-blade.....	44	Symphysis.....	55
Shrapnell's membrane.....	215	of inferior maxillary.....	27
Sight, Organ of.....	197	Synarthrosis.....	55
		Synchondrosis.....	55

	PAGE		PAGE
Synovia.....	56	<b>U</b> LNNA.....	47
Synovial membranes.....	56	Umbilical region.....	163
Syndesmology.....	9	Umbilicus.....	162
<b>T</b> APETUM.....	201	Umbo.....	215
Tarsus.....	53	Urachus.....	178
Taste, Nerves of.....	195	Ureters.....	177
Taste-buds.....	195	Urethra.....	179
Tænia hippocampi.....	125	Bulb of.....	180
semicircularis.....	125	Uterus.....	188
Teeth.....	141, 143	masculinus.....	180
Tendo oculi.....	210	Utricle.....	222
Tendons.....	67	Uvea.....	201
Tenon, Capsule of.....	197	Uvula.....	144
Tentorium cerebelli.....	121	vesicæ.....	179
Testes.....	183	<b>V</b> AGINA.....	188
of the cerebrum.....	127	Vaginal.....	11
Descent of.....	186	Vallecula cerebelli.....	128
Thebesius, Foramina of.....	100	Valsalva, Sinuses of.....	101, 102
Thigh.....	50	Valve of Bauthin.....	150, 151
Thorax.....	38	Eustachian.....	100
Thyroid axis.....	107	Ileo-cæcal.....	150, 151
cartilage.....	166	Mitral.....	101
Todd and Bowman's muscle.....	224	Tricuspid.....	100
Tongue.....	145, 195	of Viussens.....	127
Tonsils.....	144	Valves of Kirkring.....	151
Torcular Herophili.....	14	Semilunar.....	101, 102
Trachea.....	170	Valvulæ conniventes.....	151
Tract, Lateral.....	128	Vas deferens.....	185
Optic.....	208	Vasa efferentia.....	184
Uveal.....	200	recta.....	184
Tracts, Olfactory.....	123	vasorum.....	102
Tractus spiralis forminosus.....	225	Vasculum aberrans.....	185
Tragus.....	213	Vein, Axillary.....	116
Triangle, Fancoast's.....	98	Basilic.....	116
Trigonum vesicæ.....	178	Cephalic.....	116
Trochanters.....	10	Femoral.....	118
of femur.....	50	Median.....	116
Trochlear.....	11	Popliteal.....	118
Tube, Eustachian.....	17, 35, 216, 219	Portal.....	118, 155
Tuber annulare.....	124	Radial.....	116
cinereum.....	123	Splenic.....	159
Tubercle.....	10	Sub-clavian.....	117
Genial.....	27	Supra-renal.....	161
of Lower.....	100	Ulnar.....	116
Tuberosties.....	10	Vena Cava.....	117, 118
of femur.....	51	Vertebral.....	116
of humerus.....	45	Veins.....	115, 202
of ischium.....	43	Azygos.....	116
Maxillary.....	23	of bone.....	12
Tubes of Bellini.....	176	Cardiac.....	119
of Ferrein.....	176	Choroid.....	200
of Henle.....	176	of the eye.....	207
Tubuli galactopheri.....	192	of head and neck.....	115
lactiferi.....	192	Hepatic.....	155
seminiferi.....	184	Iliac.....	118
uriniferi.....	176	Innominate.....	117
Tuft, Malpighian.....	176	Jugular.....	116
Tunica albuginea.....	184	of the kidney.....	177
vaginalis.....	184	of the larynx.....	170
oculi.....	197	Lobular.....	155
vasculosa.....	184, 200	of lower extremities.....	117
Tunics of eyeball.....	198	of the lung.....	173
Tutamina oculi.....	209	of œsophagus.....	148
Tympanum.....	216	of the pancreas.....	158
Tyson, Glands of.....	183	Pulmonary.....	119
		of the penis.....	183

	PAGE		PAGE
<b>Veins, Saphenous</b> .....	118	<b>Vieussens, Valve of</b> .....	127
Spinal.....	116	<b>Villi</b> .....	151
of the stomach.....	150	<b>Viscera</b> .....	141
of supra-renal capsules.....	161	covered by peritoneum.....	165
of the thorax.....	116	<b>Vitellus</b> .....	191
of thymus gland.....	160	<b>Vocal chords</b> .....	168
Thyroid.....	160	<b>Vomer</b> .....	26
of trachea and bronchi.....	171	<b>Vortex of the heart</b> .....	102
Uterine.....	190	<b>Vulva</b> .....	187
without valves.....	115	Orifice of.....	232
<b>Velum interpositum</b> .....	125	<b>W</b>	
<b>Venæ comites</b> .....	115	<b>WALLS OF THE TYMPANUM</b> ... 216	
propriæ renales.....	177	Wharton's ducts.....	144
rectæ.....	177	<b>Willis, Circle of</b> .....	106
vorticosaë.....	200	<b>Wings of the sphenoid</b> .....	19
<b>Venter of the ilium</b> .....	42	<b>Winslow, Foramen of</b> .....	163
of the scapula.....	44	Ligament of.....	64
<b>Ventricle of the cord</b> .....	129	<b>Wirsung, Duct of</b> .....	157
Fifth.....	126	<b>Wistar, Pyramids of</b> .....	19
Fourth.....	126	<b>Wormian bones</b> .....	10
of the larynx.....	168	<b>Wrisberg, Cartilages of</b> .....	167
Third.....	126	Nerve of.....	134
<b>Ventricles, Lateral</b> .....	124	<b>Y</b>	
<b>Verheyen, Stars of</b> .....	177	<b>YELK</b> .....	191
<b>Vertebra prominens</b> .....	37	<b>Z</b>	
<b>Vertebrae</b> .....	36	<b>ZINN, LIGAMENT OF</b> ..... 205	
<b>Veru montanum</b> .....	179	Zone of.....	199
<b>Vesalius, Foramen of</b> .....	35	Zonula of.....	204
<b>Vesical, Germinal</b> .....	191	<b>Zona pellucida</b> .....	191
Graafian.....	191	<b>Zone, Peripheral</b> .....	199
<b>Vesiculæ seminales</b> .....	186	of Zinn.....	199
<b>Vestibule</b> .....	187	Vascular.....	199
of the ear.....	220	<b>Zonula of Zinn</b> .....	204
<b>Vidian canal</b> .....	20	<b>Zygoma</b> .....	15
<b>nerve</b> .....	140		





A Classified Catalogue of  
Books on Medicine and the  
Collateral Sciences, Phar-  
macy, Dentistry, Chemistry,  
Hygiene, Microscopy, Etc.



P. Blakiston's Son & Company, Pub-  
lishers of Medical and Scientific Books,  
1012 Walnut Street, Philadelphia

No. 8. 1-18-02.

# SUBJECT INDEX.

Special Catalogues of Books on Pharmacy, Dentistry, Chemistry, Hygiene, and Nursing will be sent free upon application. All inquiries regarding prices, dates of edition, terms, etc., will receive prompt attention.

SUBJECT.	PAGE	SUBJECT.	PAGE
Alimentary Canal (see Surgery) .....	19	Mental Therapeutics.....	4
Anatomy.....	3	Microscopy .....	13
Anesthetics .....	14	Milk Analysis (see Chemistry) .....	4
Autopsies (see Pathology) .....	16	Miscellaneous .....	14
Bacteriology (see Pathology)..	16	Nervous Diseases .....	14
Bandaging (see Surgery).....	19	Nose.....	20
Blood, Examination of.....	16	Nursing .....	15
Brain .....	4	Obstetrics.....	16
Chemistry. Physics.....	4	Ophthalmology.....	9
Children, Diseases of.....	6	Organotherapy .....	14
Climatology. ....	14	Osteology (see Anatomy).....	3
Clinical Charts.....	20	Pathology .....	16
Compendis .....	22, 23	Pharmacy .....	16
Consumption (see Lungs).....	11	Physical Diagnosis .....	6
Cyclopedia of Medicine.....	8	Physical Training .....	12
Dentistry .....	7	Physiology .....	17
Diabetes (see Urin. Organs)..	21	Pneumotherapy.....	14
Diagnosis.....	6	Poisons (see Toxicology) .....	13
Diagrams (see Anatomy).....	3	Practice of Medicine.....	18
Dictionaries, Cyclopedias.....	8	Prescription Books.....	18
Diet and Food.....	14	Refraction (see Eye) .....	9
Dissectors .....	3	Rest .....	14
Ear .....	9	Sanitary Science .....	11
Electricity .....	9	Skin.....	19
Embryology.....	3	Spectacles (see Eye).....	9
Emergencies.....	19	Spine (see Nervous Diseases) .....	14
Eye .....	9	Stomach (see Miscellaneous).....	14
Fevers .....	9	Students' Compendis.....	22, 23
Food.....	14	Surgery and Surgical Dis-	
Gynecology .....	21	eases.....	19
Hay Fever.....	20	Technological Books.....	4
Heart .....	10	Temperature Charts.....	6
Histology.....	10	Therapeutics .....	12
Hydrotherapy.....	14	Throat .....	20
Hygiene.....	11	Toxicology.....	13
Hypnotism .....	14	Tumors (see Surgery).....	19
Insanity .....	4	U. S. Pharmacopœia .....	17
Intestines (see Miscellaneous) .....	14	Urinary Organs .....	20
Latin, Medical (see Miscella-		Urine .....	20
neous and Pharmacy).....	14, 16	Veneral Diseases.....	21
Life Insurance.....	14	Veterinary Medicine.....	21
Lungs .....	11	Visiting Lists, Physicians'.	
Massage.....	12	( <i>Send for Special Circular.</i> )	
Materia Medica.....	12	Water Analysis.....	11
Mechanotherapy.....	12	Women, Diseases of.....	21
Medical Jurisprudence.....	13		

Self-Examination for Medical Students. 3500 Questions on Medical Subjects, with References to Standard Works in which the correct replies will be found. Together with Questions from State Examining Boards. 3d Edition. Paper Cover, 10 cts.

**SPECIAL NOTE.**—The prices given in this catalogue are net, no discount can be allowed retail purchasers under any consideration. This rule has been established in order that everyone will be treated alike, a general reduction in former prices having been made to meet previous retail discounts. Upon receipt of the advertised price any book will be forwarded by mail or express, all charges prepaid.

## ANATOMY.

- MORRIS.** Text-Book of Anatomy. 2d Edition. Revised and Enlarged. 790 Illustrations, 214 of which are printed in colors. *Thumb Index in Each Copy.* Cloth, \$6.00; Leather, \$7.00  
 "The ever-growing popularity of the book with teachers and students is an index of its value."—*Medical Record, New York.*
- BROOMELL.** Anatomy and Histology of the Human Mouth and Teeth. 284 Illustrations. \$4.50
- CAMPBELL.** Dissection Outlines. Based on Morris' Anatomy. 2d Edition. .50
- DEAVER.** Surgical Anatomy. A Treatise on Anatomy in its Application to Medicine and Surgery. With 400 very Handsome full-page Illustrations Engraved from Original Drawings made by special Artists from dissections prepared for the purpose. Three Volumes. Cloth, \$21.00; Half Morocco or Sheep, \$24.00; Half Russia, \$27.00
- GORDINIER.** Anatomy of the Central Nervous System. With 271 Illustrations, many of which are original. Cloth, \$6.00
- HEATH.** Practical Anatomy. 8th Edition. 300 Illus. \$4.25
- HOLDEN.** Anatomy. A Manual of Dissections. Revised by A. HEWSON, M.D., Demonstrator of Anatomy, Jefferson Medical College, Philadelphia. 320 handsome Illustrations. 7th Edition. In two compact 12mo Volumes. 850 Pages. Large New Type. *Just Ready.*  
 Vol. I. Scalp—Face—Orbit—Neck—Throat—Thorax—Upper Extremity. \$1.50  
 Vol. II. Abdomen—Perineum—Lower Extremity—Brain—Eye—Ear—Mammary Gland—Scrotum—Testes. \$1.50
- HOLDEN.** Human Osteology. Comprising a Description of the Bones, with Colored Delineations of the Attachments of the Muscles. The General and Microscopical Structure of Bone and its Development. With Lithographic Plates and numerous Illus. 8th Ed. \$5.25
- HOLDEN.** Landmarks. Medical and Surgical. 4th Ed. .75
- HUGHES AND KEITH.** Dissections. With Colored and other Illustrations. In three Parts; I, Upper and Lower Extremity. *Ready.* \$3.00  
 II, Abdomen, Pelvis; III, Perineum, Thorax. *In Press.*
- MACALISTER.** Human Anatomy. Systematic and Topographical. 816 Illustrations. Cloth, \$5.00; Leather, \$6.00
- McMURRICH.** Embryology. Illustrated. *In Press.*
- MARSHALL.** Physiological Diagrams. Life Size. Colored. Eleven Life-Size Diagrams (each seven feet by three feet seven inches). Designed for Demonstration before the Class.  
 In Sheets, Unmounted, \$40.00; Backed with Muslin and Mounted on Rollers, \$60.00; Ditto, Spring Rollers, in Handsome Walnut Wall Map Case, \$100.00; Single Plates—Sheets, \$5.00; Mounted, \$7.50. Explanatory Key, .50. *Purchaser must pay freight charges.*
- POTTER.** Compend of Anatomy, Including Visceral Anatomy. 6th Ed. 16 Lith. Plates and 117 other Illus. .80; Interleaved, \$1.00
- WILSON.** Anatomy. 11th Edition. 429 Illus., 26 Plates. \$5.00
- WINDLE.** Surface Anatomy. Colored and other Illus. \$1.00

## BRAIN AND INSANITY (see also Nervous Diseases).

- BLACKBURN.** A Manual of Autopsies. Designed for the Use of Hospitals for the Insane and other Public Institutions. Ten full-page Plates and other Illustrations. \$1.25
- DERCUM.** Mental Therapeutics, Rest, etc. *Nearly Ready.*
- GORDINIER.** The Gross and Minute Anatomy of the Central Nervous System. With full-page and other Illustrations. \$6.00
- HORSLEY.** The Brain and Spinal Cord. The Structure and Functions of. Numerous Illustrations. \$2.50
- IRELAND.** The Mental Affections of Children. 2d Ed. \$4.00
- LEWIS (BEVAN).** Mental Diseases. A Text-Book Having Special Reference to the Pathological Aspects of Insanity. 26 Lithographic Plates and other Illustrations. 2d Ed. \$7.00
- MANN.** Manual of Psychological Medicine and Allied Nervous Diseases. \$3.00
- PERSHING.** Diagnosis of Nervous and Mental Disease. Illustrated. *Just Ready.* \$1.25
- REGIS.** Mental Medicine. Authorized Translation by H. M. BANNISTER, M.D. \$2.00
- SHUTTLEWORTH.** Mentally Deficient Children. \$1.50
- STEARNS.** Mental Diseases. With a Digest of Laws Relating to Care of Insane. Illustrated. Cloth, \$2.75; Sheep, \$3.25
- TUKE.** Dictionary of Psychological Medicine. Giving the Definition, Etymology, and Symptoms of the Terms used in Medical Psychology, with the Symptoms, Pathology, and Treatment of the Recognized Forms of Mental Disorders. Two volumes. \$10.00
- WOOD, H. C.** Brain and Overwork. .40

## CHEMISTRY AND TECHNOLOGY.

*Special Catalogue of Chemical Books sent free upon application.*

- ALLEN.** Commercial Organic Analysis. A Treatise on the Modes of Assaying the Various Organic Chemicals and Products Employed in the Arts, Manufactures, Medicine, etc., with concise methods for the Detection of Impurities, Adulterations, etc. 8vo.
- Vol. I. Alcohols, Neutral Alcoholic Derivatives, etc., Ethers, Vegetable Acids, Starch, Sugars, etc. 3d Edition. \$4.50
- Vol. II, Part I. Fixed Oils and Fats, Glycerol, Explosives, etc. 3d Edition. \$3.50
- Vol. II, Part II. Hydrocarbons, Mineral Oils, Lubricants, Benzenes, Naphthalenes and Derivatives, Creosote, Phenols, etc. 3d Ed. \$3.50
- Vol. II, Part III. Terpenes, Essential Oils, Resins, Camphors, etc. 3d Edition. *Preparing.*
- Vol. III, Part I. Tannins, Dyes and Coloring Matters. 3d Edition. Enlarged and Rewritten. Illustrated. \$4.50
- Vol. III, Part II. The Amines, Hydrazines and Derivatives, Pyridine Bases. The Antipyretics, etc. Vegetable Alkaloids, Tea, Coffee, Cocoa, etc. 8vo. 2d Edition. \$4.50
- Vol. III, Part III. Vegetable Alkaloids, Non-Basic Vegetable Bitter Principles. Animal Bases, Animal Acids, Cyanogen Compounds, etc. 2d Edition, 8vo. \$4.50
- Vol. IV. The Proteids and Albuminous Principles. 2d Ed. \$4.50

- BAILEY AND CADY.** Chemical Analysis. *Just Ready.* \$1.25
- BARTLEY.** Medical and Pharmaceutical Chemistry. A Text-Book for Medical, Dental, and Pharmaceutical Students. With Illustrations, Glossary, and Complete Index. 5th Edition. \$3.00
- BARTLEY.** Clinical Chemistry. The Examination of Feces, Saliva, Gastric Juice, Milk, and Urine. \$1.00
- BLOKAM.** Chemistry, Inorganic and Organic. With Experiments. 9th Ed., Revised. 281 Engravings. *Preparing.*
- CALDWELL.** Elements of Qualitative and Quantitative Chemical Analysis. 3d Edition, Revised. \$1.00
- CAMERON.** Oils and Varnishes. With Illustrations. \$2.25
- CAMERON.** Soap and Candles. 54 Illustrations. \$2.00
- CLOWES AND COLEMAN.** Quantitative Analysis. 5th Edition. 122 Illustrations. \$3.50
- COBLENTZ.** Volumetric Analysis. Illustrated. *Just Ready.* \$1.25
- CONGDON.** Laboratory Instructions in Chemistry. With Numerous Tables and 56 Illustrations. \$1.00
- GARDNER.** The Brewer, Distiller, and Wine Manufacturer. Illustrated. \$1.50
- GRAY.** Physics. Volume I. Dynamics and Properties of Matter. 350 Illustrations. *Just Ready.* \$4.50
- GROVES AND THORP.** Chemical Technology. The Application of Chemistry to the Arts and Manufactures.  
 Vol. I. Fuel and Its Applications. 607 Illustrations and 4 Plates. Cloth, \$5.00; 1/2 Mor., \$6.50  
 Vol. II. Lighting. Illustrated. Cloth, \$4.00; 1/2 Mor., \$5.50  
 Vol. III. Gas Lighting. Cloth, \$3.50; 1/2 Mor., \$4.50  
 Vol. IV. Electric Lighting. Photometry. *In Press.*
- HEUSLER.** The Terpenes. *In Press.*
- HOLLAND.** The Urine, the Gastric Contents, the Common Poisons, and the Milk. Memoranda, Chemical and Microscopical, for Laboratory Use. 6th Ed. Illustrated and interleaved, \$1.00
- LEFFMANN.** Compend of Medical Chemistry, Inorganic and Organic. 4th Edition, Revised. .80; Interleaved, \$1.00
- LEFFMANN.** Analysis of Milk and Milk Products. 2d Edition, Enlarged. Illustrated. \$1.25
- LEFFMANN.** Water Analysis. For Sanitary and Technic Purposes. Illustrated. 4th Edition. \$1.25
- LEFFMANN.** Structural Formulæ. Including 180 Structural and Stereo-Chemical Formulæ. 12mo. Interleaved. \$1.00
- LEFFMANN AND BEAM.** Select Methods in Food Analysis. Illustrated \$2 50
- MUTER.** Practical and Analytical Chemistry. 2d American from the Eighth English Edition. Revised to meet the requirements of American Students. 56 Illustrations. \$1.25
- OETTEL.** Exercises in Electro-Chemistry. Illustrated. .75
- OETTEL.** Electro-Chemical Experiments. Illustrated. .75
- RICHTER.** Inorganic Chemistry. 5th American from 10th German Edition. Authorized translation by EDGAR F. SMITH, M.A., PH.D. 89 Illustrations and a Colored Plate. \$1.75
- RICHTER.** Organic Chemistry. 3d American Edition. Trans. from the 8th German by EDGAR F. SMITH. Illustrated. 2 Volumes.  
 Vol. I. Aliphatic Series. 625 Pages. \$3.00  
 Vol. II. Carbocyclic Series. 671 Pages. \$3.00

- ROCKWOOD. Chemical Analysis for Students of Medicine, Dentistry, and Pharmacy. Illustrated. *Just Ready.* \$1.50
- SMITH. Electro-Chemical Analysis. 2d Ed. 28 Illus. \$1.25
- SMITH AND KELLER. Experiments. Arranged for Students in General Chemistry. 4th Edition. Illustrated .60
- SUTTON. Volumetric Analysis. A Systematic Handbook for the Quantitative Estimation of Chemical Substances by Measure, Applied to Liquids, Solids, and Gases. 8th Edition, Revised. 112 Illustrations. \$5.00
- SYMONDS. Manual of Chemistry. 2d Edition. \$2.00
- TRAUBE. Physico-Chemical Methods. Translated by Hardin. 97 Illustrations. \$1.50
- THRESH. Water and Water Supplies. 3d Edition. \$2.00
- ULZER AND FRAENKEL. Chemical Technical Analysis. Translated by Fleck. Illustrated. \$1.25
- WOODY. Essentials of Chemistry and Urinalysis. 4th Edition. Illustrated. \$1.50
- \*.\* *Special Catalogue of Books on Chemistry free upon application.*

## CHILDREN.

- CAUTLEY. Feeding of Infants and Young Children by Natural and Artificial Methods. \$2.00
- HALE. On the Management of Children. .50
- HATFIELD. Compend of Diseases of Children. With a Colored Plate. 2d Edition. .80; Interleaved, \$1.00
- IRELAND. The Mental Affections of Children. Idiocy, Imbecility, Insanity, etc. 2d Edition. \$4.00
- POWER. Surgical Diseases of Children and their Treatment by Modern Methods. Illustrated. \$2.50
- SHUTTLEWORTH. Mentally Deficient Children. New Edition. \$1.50
- STARR. The Digestive Organs in Childhood. The Diseases of the Digestive Organs in Infancy and Childhood. 3d Edition, Rewritten and Enlarged. Illustrated. *Just Ready.* \$3.00
- STARR. Hygiene of the Nursery. Including the General Regimen and Feeding of Infants and Children, and the Domestic Management of the Ordinary Emergencies of Early Life, Massage, etc. 6th Edition. 25 Illustrations. \$1.00
- SMITH. Wasting Diseases of Children. 6th Edition. \$2.00
- TAYLOR AND WELLS. The Diseases of Children. 2d Edition, Revised and Enlarged. Illustrated. 8vo. \$4.50

## DIAGNOSIS.

- BROWN. Medical Diagnosis. A Manual of Clinical Methods. 4th Edition. 112 Illustrations. Cloth, \$2.25
- DA COSTA. Clinical Examination of the Blood. Illustrated. *In Press.*
- EMERY. Bacteriological Diagnosis. *In Press.*
- MEMMINGER. Diagnosis by the Urine. 2d Ed. 24 Illus. \$1.00

- PERSHING.** *Diagnosis of Nervous and Mental Diseases.*  
Illustrated. *Just Ready.* \$1.25
- STELL.** *Physical Signs of Pulmonary Disease.* \$1.25
- TYSON.** *Hand-Book of Physical Diagnosis.* For Students and Physicians. By the Professor of Clinical Medicine in the University of Pennsylvania. Illus. 4th Ed., Improved and Enlarged. With Two Colored and 55 other Illustrations. *Just Ready.* \$1.50

## DENTISTRY.

*Special Catalogue of Dental Books sent free upon application.*

- BARRETT.** *Dental Surgery for General Practitioners and Students of Medicine and Dentistry.* Extraction of Teeth, etc. 3d Edition. Illustrated. \$1.00
- BROOMELL.** *Anatomy and Histology of the Human Mouth and Teeth.* 284 Handsome Illustrations. \$4.50
- FILLBROWN.** *A Text-Book of Operative Dentistry.* Written by invitation of the National Association of Dental Faculties. Illustrated. \$2.25
- GORGAS.** *Dental Medicine.* A Manual of Materia Medica and Therapeutics. 7th Edition. *Just Ready.* Cloth, \$4.00; Sheep, \$5.00
- GORGAS.** *Questions and Answers for the Dental Student.* Embracing all the subjects in the Curriculum of the Dental Student. Octavo. *Just Ready.* \$6.00
- HARRIS.** *Principles and Practice of Dentistry.* Including Anatomy, Physiology, Pathology, Therapeutics, Dental Surgery, and Mechanism. 13th Edition. Revised by F. J. S. GORGAS, M.D., D.D.S. 1250 Illustrations. Cloth, \$6.00; Leather, \$7.00
- HARRIS.** *Dictionary of Dentistry.* Including Definitions of Such Words and Phrases of the Collateral Sciences as Pertain to the Art and Practice of Dentistry. 6th Edition. Revised and Enlarged by FERDINAND F. S. GORGAS, M.D., D.D.S. Cloth, \$5.00; Leather, \$6.00
- HEATH.** *Injuries and Diseases of the Jaws.* 4th Edition. 187 Illustrations. \$4.50
- RICHARDSON.** *Mechanical Dentistry.* 7th Edition. Thoroughly Revised and Enlarged by DR. GEO. W. WARREN. 691 Illustrations. Cloth, \$5.00; Leather, \$6.00
- SMITH.** *Dental Metallurgy.* Illustrated. \$1.75
- TAFT.** *Index of Dental Periodical Literature.* \$2.00
- TOMES.** *Dental Anatomy.* Human and Comparative. 263 Illustrations. 5th Edition. \$4.00
- TOMES.** *Dental Surgery.* 4th Edition. 289 Illustrations. \$4.00
- WARREN.** *Compend of Dental Pathology and Dental Medicine.* With a Chapter on Emergencies. 3d Edition. Illustrated. .80; Interleaved, \$1.25
- WARREN.** *Dental Prosthesis and Metallurgy.* 129 Ills. \$1.25
- WHITE.** *The Mouth and Teeth.* Illustrated. .40

## DICTIONARIES AND CYCLOPEDIAS

- GOULD.** *The Illustrated Dictionary of Medicine, Biology and Allied Sciences.* Being an Exhaustive Lexicon of Medicine and those Sciences Collateral to it: Biology (Zoology and Botany), Chemistry, Dentistry, Pharmacology, Microscopy, etc., with many useful Tables and numerous fine Illustrations. 1633 pages. 5th Ed. Sheep or Half Dark Green Leather, \$10.00; Thumb Index, \$11.00  
Half Russia, Thumb Index, \$12.00
- GOULD.** *The Medical Student's Dictionary.* 11th Edition. Illustrated. Including all the Words and Phrases Generally Used in Medicine, with their Proper Pronunciation and Definition, Based on Recent Medical Literature. With Table of Eponymic Terms and Tests and Tables of the Bacilli, Micrococci, Mineral Springs, etc., of the Arteries, Muscles, Nerves, Ganglia, Plexuses, etc. 11th Edition. Enlarged and illustrated with a large number of Engravings. 840 pages. Half Green Morocco, \$2.50; Thumb Index, \$3.00
- GOULD.** *The Pocket Pronouncing Medical Lexicon.* 4th Edition. (30,000 Medical Words Pronounced and Defined.) Containing all the Words, their Definition and Pronunciation, that the Medical, Dental, or Pharmaceutical Student Generally Comes in Contact With; also Elaborate Tables of Eponymic Terms, Arteries, Muscles, Nerves, Bacilli, etc., etc., a Dose List in both English and Metric Systems, etc., Arranged in a Most Convenient Form for Reference and Memorizing. Fourth Edition, Revised and Enlarged. 838 pages. Full Limp Leather, Gilt Edges, \$1.00; Thumb Index, \$1.25  
130,000 Copies of Gould's Dictionaries Have Been Sold.
- GOULD AND PYLE.** *Cyclopedia of Practical Medicine and Surgery.* Seventy-two Special Contributors. Illustrated. One Volume. A Concise Reference Handbook, Alphabetically Arranged, of Medicine, Surgery, Obstetrics, Materia Medica, Therapeutics, and the Various Specialties, with Particular Reference to Diagnosis and Treatment. Compiled under the Editorial Supervision of GEORGE M. GOULD, M.D., Author of "An Illustrated Dictionary of Medicine": Editor "Philadelphia Medical Journal," etc.; and WALTER L. PYLE, M.D., Assistant Surgeon Wills Eye Hospital; formerly Editor "International Medical Magazine," etc., and Seventy-two Special Contributors. With many Illustrations. Large Square 8vo, to correspond with Gould's "Illustrated Dictionary." Full Sheep or Half Dark-Green Leather, \$10.00  
With Thumb Index, \$11.00; Half Russia, Thumb Index, \$12.00 net.
- GOULD AND PYLE.** *Pocket Cyclopedia of Medicine and Surgery.* Based upon above book and uniform in size with "Gould's Pocket Dictionary." Full Limp Leather, Gilt Edges, \$1.00, with Thumb Index, \$1.25
- HARRIS.** *Dictionary of Dentistry.* Including Definitions of Such Words and Phrases of the Collateral Sciences as Pertain to the Art and Practice of Dentistry. 6th Edition. Revised and Enlarged by FERDINAND J. S. GORGAS, M.D., D.D.S. Cloth, \$5.00; Leather, \$6.00
- LONGLEY.** *Pocket Medical Dictionary.* With an Appendix, containing Poisons and their Antidotes, Abbreviations used in Prescriptions, etc. Cloth, .75; Tucks and Pocket, \$1.00
- MAXWELL.** *Terminologia Medica Polyglotta.* By Dr. THEODORE MAXWELL, Assisted by Others. \$3.00  
The object of this work is to assist the medical men of any nationality in reading medical literature written in a language not their own. Each term is usually given in seven languages, viz.: English, French, German, Italian, Spanish, Russian, and Latin.
- TREVES AND LANG.** *German-English Medical Dictionary.* Half Russia, \$3.25



**EAR** (see also Throat and Nose).

- BURNETT.** Hearing and How to Keep It. Illustrated. .40  
**DALBY.** Diseases and Injuries of the Ear. 4th Edition. 38  
 Wood Engravings and 8 Colored Plates. \$2.50  
**HOVELL.** Diseases of the Ear and Naso-Pharynx. Includ-  
 ing Anatomy and Physiology of the Organ, together with the Treat-  
 ment of the Affections of the Nose and Pharynx which Conduce to  
 Aural Disease. 128 Illustrations. 2d Edition. *Just Ready.* \$5.50  
**PRITCHARD.** Diseases of the Ear. 3d Edition, Enlarged.  
 Many Illustrations and Formulæ. \$1.50

**ELECTRICITY.**

- BIGELOW.** Plain Talks on Medical Electricity and Bat-  
 teries. With a Therapeutic Index and a Glossary. 43 Illustra-  
 tions. 2d Edition. \$1.00  
**HEDLEY.** Therapeutic Electricity and Practical Muscle  
 Testing. 99 Illustrations. \$2.50  
**JACOBY.** Electrotherapy. 2 Vols. Illustrated. Including Special  
 Articles by Various Authors. (*Subscription.*) *Just Ready.* \$5.00  
**JONES.** Medical Electricity. 3d Edition. 117 Illus. \$3.00

**EYE.**

*A Special Circular of Books on the Eye sent free upon application.*

- DONDERS.** The Nature and Consequences of Anomalies of  
 Refraction. With Portrait and Illustrations. Half Morocco, \$1.25  
**FICK.** Diseases of the Eye and Ophthalmoscopy. Trans-  
 lated by A. B. HALE, M. D. 157 Illustrations, many of which are in  
 colors, and a glossary. Cloth, \$4.50; Sheep, \$5.50  
**GOULD AND PYLE.** Compend of Diseases of the Eye and  
 Refraction. Including Treatment and Operations, and a Section  
 on Local Therapeutics. With Formulæ, Useful Tables, a Glossary,  
 and 111 Illus., several of which are in colors. 2d Edition, Revised.  
 Cloth, .80; Interleaved, \$1.00  
**GREEFF.** The Microscopic Examination of the Eye. Illus-  
 trated. *Just Ready.* \$1.25  
**HARLAN.** Eyesight, and How to Care for It. Illus. .40  
**HARTRIDGE.** Refraction. 104 Illustrations and Test Types.  
 11th Edition, Enlarged. \$1.50  
**HARTRIDGE.** On the Ophthalmoscope. 4th Edition. With  
 4 Colored Plates and 68 Wood-cuts. \$1.50  
**HANSELL AND REBER.** Muscular Anomalies of the Eye.  
 Illustrated. \$1.50  
**HANSELL AND BELL.** Clinical Ophthalmology. Colored  
 Plate of Normal Fundus and 120 Illustrations. \$1.50  
**JENNINGS.** Manual of Ophthalmoscopy. 95 Illustrations and  
 1 Colored Plate. *Just Ready.* \$1.50

- MORTON.** *Refraction of the Eye. Its Diagnosis and the Correction of its Errors.* 6th Edition. \$1.00
- OHLEMANN.** *Ocular Therapeutics.* Authorized Translation, and Edited by DR. CHARLES A. OLIVER. \$1.75
- PARSONS.** *Elementary Ophthalmic Optics.* With Diagrammatic Illustrations. *Just Ready.* \$2.00
- PHILLIPS.** *Spectacles and Eyeglasses.* Their Prescription and Adjustment. 2d Edition. 49 Illustrations. \$1.00
- SWANZY.** *Diseases of the Eye and Their Treatment.* 7th Edition, Revised and Enlarged. 164 Illustrations, 1 Plain Plate, and a Zephyr Test Card. \$2.50

*From The Medical News.*

"Swanzy has succeeded in producing the most intellectually conceived and thoroughly executed résumé of the science within the limits he has assigned himself. As a 'students' handbook,' small in size and of moderate price, it can hardly be equaled."

- THORINGTON.** *Retinoscopy.* 4th Edition. Carefully Revised. Illustrated. \$1.00
- THORINGTON.** *Refraction and How to Refract.* 200 Illustrations, 13 of which are Colored. 2d Edition. \$1.50
- WALKER.** *Students' Aid in Ophthalmology.* Colored Plate and 40 other Illustrations and Glossary. \$1.50
- WRIGHT.** *Ophthalmology.* 2d Edition, Revised and Enlarged. 117 Illustrations and a Glossary. \$3.00

## FEVERS.

- GOODALL AND WASHBOURN.** *Fevers and Their Treatment.* Illustrated. \$3.00

## HEART.

- THORNE.** *The Schott Methods of the Treatment of Chronic Heart Disease.* Third Edition. Illustrated. \$1.75

## HISTOLOGY.

- CUSHING.** *Compend of Histology.* By H. H. CUSHING, M.D., Demonstrator of Histology, Jefferson Medical College, Philadelphia. Illustrated. *Nearly Ready.* .80; Interleaved, \$1.00
- STIRLING.** *Outlines of Practical Histology.* 368 Illustrations. 2d Edition, Revised and Enlarged. With new Illustrations. \$2.00
- STÖHR.** *Histology and Microscopical Anatomy.* Edited by A. SCHAPER, M.D., University of Breslau, formerly Demonstrator of Histology, Harvard Medical School. Fourth American from 9th German Edition, Revised and Enlarged. 379 Illus. *Just Ready.* \$3.00

## HYGIENE AND WATER ANALYSIS.

*Special Catalogue of Books on Hygiene sent free upon application.*

- CANFIELD.** Hygiene of the Sick-Room. A Book for Nurses and Others. Being a Brief Consideration of Asepsis, Antisepsis, Disinfection, Bacteriology, Immunity, Heating, Ventilation, etc. \$1.25
- CONN.** Agricultural Bacteriology. Illus. *Just Ready.* \$2.50
- COPLIN.** Practical Hygiene. A Complete American Text-Book. 138 Illustrations. New Edition. *Preparing.*
- HARTSHORNE.** Our Homes. Illustrated. .40
- KENWOOD.** Public Health Laboratory Work. 116 Illustrations and 3 Plates. \$2.00
- LEFFMANN.** Select Methods in Food Analysis. 53 Illustrations and 4 Plates. \$2.50
- LEFFMANN.** Examination of Water for Sanitary and Technical Purposes. 4th Edition. Illustrated. \$1.25
- LEFFMANN.** Analysis of Milk and Milk Products. Illustrated. Second Edition. \$1.25
- LINCOLN.** School and Industrial Hygiene. .40
- McFARLAND.** Prophylaxis and Personal Hygiene. *In Press.*
- NOTTER.** The Theory and Practice of Hygiene. 15 Plates and 138 other Illustrations. 8vo. 2d Edition. \$7.00
- PARKES.** Hygiene and Public Health. By Louis C. Parkes, M.D. 6th Edition. Enlarged. Illustrated. \$3.00
- PARKES.** Popular Hygiene. The Elements of Health. A Book for Lay Readers. Illustrated. \$1.25
- STARR.** The Hygiene of the Nursery. Including the General Regimen and Feeding of Infants and Children, and the Domestic Management of the Ordinary Emergencies of Early Life, Massage, etc. 6th Edition. 25 Illustrations. \$1.00
- STEVENSON AND MURPHY.** A Treatise on Hygiene. By Various Authors. In Three Octave Volumes. Illustrated.  
Vol. I, \$6.00; Vol. II, \$6.00; Vol. III, \$5.00
- \* \* Each Volume sold separately. Special Circular upon application.
- THRESH.** Water and Water Supplies. 3d Edition. \$2.00
- WILSON.** Hand-Book of Hygiene and Sanitary Science. With Illustrations. 8th Edition. \$3.00
- WEYL.** Sanitary Relations of the Coal-Tar Colors. Authorized Translation by HENRY LEFFMANN, M.D., PH.D. \$1.25

## LUNGS AND PLEURÆ.

- KNOPF.** Pulmonary Tuberculosis. Its Modern Prophylaxis and Treatment in Special Institutions and at Home. Illus. \$3.00
- STEELL.** Physical Signs of Pulmonary Disease. Illus. \$1.25

## MASSAGE—PHYSICAL EXERCISE.

- OSTROM.** *Massage and the Original Swedish Movements. Their Application to Various Diseases of the Body. A Manual for Students, Nurses, and Physicians. Fourth Edition, Enlarged.* 105 Illustrations, many of which are original. \$1.00
- MITCHELL AND GULICK.** *Mechanotherapy.* Illus. *In Press.*
- TREVES.** *Physical Education. Methods, etc.* .75
- WARD.** *Notes on Massage. Interleaved.* Paper cover, \$1.00

## MATERIA MEDICA AND THERAPEUTICS.

- BIDDLE.** *Materia Medica and Therapeutics. Including Dose List, Dietary for the Sick, Table of Parasites, and Memoranda of New Remedies. 13th Edition, Revised.* 64 Illustrations and a Clinical Index. Cloth, \$4.00; Sheep, \$5.00
- BRACKEN.** *Outlines of Materia Medica and Pharmacology.* \$2.75
- COBLENTZ.** *The Newer Remedies. Including their Synonyms, Sources, Methods of Preparation, Tests, Solubilities, Doses, etc. 3d Edition, Enlarged and Revised.* \$1.00
- COHEN.** *Physiologic Therapeutics. Mechanotherapy, Mental Therapeutics, Electrotherapy. Climatology, Hydrotherapy, Pneumatotherapy, Prophylaxis, Dietetics, etc. 11 Volumes, Octavo. Illustrated. (Subscription.)* Cloth, \$27.50; ½ mor., \$38.50  
*Special Descriptive Circular will be sent upon application.*
- DAVIS.** *Materia Medica and Prescription Writing.* \$1.50
- GORGAS.** *Dental Medicine. A Manual of Materia Medica and Therapeutics. 7th Edition, Revised. Just Ready.* \$4.00
- GROFF.** *Materia Medica for Nurses, with questions for Self-Examination and a complete Glossary.* \$1.25
- HELLER.** *Essentials of Materia Medica, Pharmacy, and Prescription Writing.* \$1.50
- MAYS.** *Theine in the Treatment of Neuralgia.* ½ bound, .50
- POTTER.** *Hand-Book of Materia Medica, Pharmacy, and Therapeutics, including the Action of Medicines, Special Therapeutics, Pharmacology, etc., including over 600 Prescriptions and Formulæ. 8th Edition, Revised and Enlarged. With Thumb Index in each copy.* Cloth, \$5.00; Sheep, \$6.00
- POTTER.** *Compend of Materia Medica, Therapeutics, and Prescription Writing, with Special Reference to the Physiologic Action of Drugs. 6th Edition.* .80; Interleaved, \$1.00
- MURRAY.** *Rough Notes on Remedies. 4th Edition.* \$1.25

**SAYRE.** *Organic Materia Medica and Pharmacognosy.* An Introduction to the Study of the Vegetable Kingdom and the Vegetable and Animal Drugs. Comprising the Botanical and Physical Characteristics, Source, Constituents, and Pharmacopoeial Preparations, Insects Injurious to Drugs, and Pharmacal Botany. With sections on Histology and Microtechnique, by W. C. STEVENS. 374 Illustrations, many of which are original. 2d Edition. Cloth, \$4.50

**FAVERA.** *Medicinal Plants of the Philippines.* *Just Ready.* \$2.00

**WHITE AND WILCOX.** *Materia Medica, Pharmacy, Pharmacology, and Therapeutics.* 5th American Edition, Revised by REYNOLD W. WILCOX, M.A., M.D., LL.D., Professor of Clinical Medicine and Therapeutics at the New York Post-Graduate Medical School. *Just Ready.* Cloth, \$3.00; Leather, \$3.50

"The care with which Dr. Wilcox has performed his work is conspicuous on every page, and it is evident that no recent drug possessing any merit has escaped his eye. We believe, on the whole, this is the best book on *Materia Medica* and *Therapeutics* to place in the hands of students, and the practitioner will find it a most satisfactory work for daily use."—*The Cleveland Medical Gazette.*

## MEDICAL JURISPRUDENCE AND TOXICOLOGY.

**REESE.** *Medical Jurisprudence and Toxicology.* A Text-Book for Medical and Legal Practitioners and Students. 5th Edition. Revised by HENRY LEFFMANN, M.D. Clo., \$3.00; Leather, \$3.50

"To the student of medical jurisprudence and toxicology it is invaluable, as it is concise, clear, and thorough in every respect."—*The American Journal of the Medical Sciences.*

**MANN.** *Forensic Medicine and Toxicology.* Illus. \$6.50

**TANNER.** *Memoranda of Poisons. Their Antidotes and Tests.* 8th Edition, by DR. HENRY LEFFMANN. .75

## MICROSCOPY.

**CARPENTER.** *The Microscope and Its Revelations.* 8th Edition, Revised and Enlarged. 817 Illustrations and 23 Plates. *Just Ready.* Cloth, \$8.00; Half Morocco, \$9.00

**LEE.** *The Microtometist's Vade Mecum.* A Hand-Book of Methods of Microscopical Anatomy. 887 Articles. 5th Edition, Enlarged. \$4.00

**REEVES.** *Medical Microscopy,* including Chapters on Bacteriology, Neoplasms, Urinary Examination, etc. Numerous Illustrations, some of which are printed in colors. \$2.50

**WETHERED.** *Medical Microscopy.* A Guide to the Use of the Microscope in Practical Medicine. 100 Illustrations. \$2.00

## MISCELLANEOUS.

- BERRY. Diseases of Thyroid Gland. Illustrated. \$4.00  
 BURNETT. Foods and Dietaries. A Manual of Clinical Dietetics. 2d Edition. \$1.50  
 BUXTON. Anesthetics. Illustrated. 3d Edition. \$1.50  
 COHEN. Organotherapy. *In Press.*  
 DAVIS. Dietotherapy. Food in Health and Disease. (*Subscription.*) *Just Ready.* \$2.50  
 GOULD. Borderland Studies. Miscellaneous Addresses and Essays. 12mo. \$2.00  
 GREENE. Medical Examination for Life Insurance. Illustrated. \$4.00  
 HAIG. Causation of Disease by Uric Acid. The Pathology of High Arterial Tension, Headache, Epilepsy, Gout, Rheumatism, Diabetes, Bright's Disease, etc. 5th Edition. \$3.00  
 HAIG. Diet and Food. Considered in Relation to Strength and Power of Endurance. 3d Edition. \$1.00  
 HEMMETER. Diseases of the Stomach. Their Special Pathology, Diagnosis, and Treatment. With Sections on Anatomy, Dietetics, Surgery, etc. 2d Edition, Revised and Enlarged. Illustrated. Cloth, \$6.00; Sheep, \$7.00  
 HEMMETER. Diseases of the Intestines. Illustrated. 2 Volumes. 8vo. *Just Ready.* Cloth, \$10.00; Sheep, \$12.00  
 HENRY. A Practical Treatise on Anemia. Half Cloth, .50  
 LEFFMANN. Food Analysis. Illustrated. \$2.50  
 NEW SYDENHAM SOCIETY'S PUBLICATIONS. Circulars upon application. Per Annum, \$8.00  
 OSGOOD. The Winter and Its Dangers. .40  
 OSLER AND McCRAE. Cancer of the Stomach. \$2.00  
 PACKARD. Sea Air and Sea Bathing. .40  
 RICHARDSON. Long Life and How to Reach It. .40  
 ST. CLAIR. Medical Latin. \$1.00  
 TISSIER. Pneumatotherapy. *In Press.*  
 TURNBULL. Artificial Anesthesia. 4th Edition. Illus. \$2.50  
 WEBER AND HINSDALE. Climatology. 2 Vols. Illustrated with Maps. *Just Ready. (Subscription.)* \$5.00  
 WILSON. The Summer and Its Diseases. .40  
 WINTERITZ. Hydrotherapy. Illustrated. *In Press.*

## NERVOUS DISEASES.

- DERCUM. Rest, Hypnotism, Mental Therapeutics. *In Press.*  
 GORDINIER. The Gross and Minute Anatomy of the Central Nervous System. With 271 original Colored and other Illustrations. Cloth, \$6.00; Sheep, \$7.00  
 GOWERS. Manual of Diseases of the Nervous System. A Complete Text-Book. Revised, Enlarged, and in many parts Rewritten. With many new Illustrations. Two volumes.  
 Vol. I. Diseases of the Nerves and Spinal Cord. 3d Edition, Enlarged. Cloth, \$4.00; Sheep, \$5.00  
 Vol. II. Diseases of the Brain and Cranial Nerves; General and Functional Disease. 2d Edition. Cloth, \$4.00; Sheep, \$5.00  
 GOWERS. Syphilis and the Nervous System. \$1.00

- GOWERS.** *Epilepsy and Other Chronic Convulsive Diseases.* 2d Edition. *Just Ready.* \$3.00
- HORSLEY.** *The Brain and Spinal Cord. The Structure and Functions of.* Numerous Illustrations. \$2.50
- ORMEROD.** *Diseases of the Nervous System.* 66 Wood Engravings. \$1.00
- PERSHING.** *Diagnosis of Nervous and Mental Diseases.* Illustrated. *Just Ready.* \$1.25
- PRESTON.** *Hysteria and Certain Allied Conditions. Their Nature and Treatment.* Illustrated. \$2.00
- WOOD.** *Brain Work and Overwork.* .40

## NURSING (see also Massage).

*Special Catalogue of Books for Nurses sent free upon application.*

- CANFIELD.** *Hygiene of the Sick-Room. A Book for Nurses and Others. Being a Brief Consideration of Asepsis, Antisepsis, Disinfection, Bacteriology, Immunity, Heating and Ventilation, and Kindred Subjects for the Use of Nurses and Other Intelligent Women.* \$1.25
- CUFF.** *Lectures to Nurses on Medicine.* Third Edition. \$1.25
- DOMVILLE.** *Manual for Nurses and Others Engaged in Attending the Sick.* 9th Edition. With Recipes for Sick-room Cookery, etc. *In Press.*
- FULLERTON.** *Obstetric Nursing.* 41 Ills. 5th Ed. \$1.00
- FULLERTON.** *Surgical Nursing.* 3d Ed. 69 Ills. \$1.00
- GROFF.** *Materia Medica for Nurses. With Questions for Self-Examination and a very complete Glossary.* \$1.25
- "It will undoubtedly prove a valuable aid to the nurse in securing a knowledge of drugs and their uses."—*The Medical Record, New York.*
- HADLEY.** *Medical and Surgical Nursing.* *Nearly Ready.*
- HUMPHREY.** *A Manual for Nurses. Including General Anatomy and Physiology, Management of the Sick Room, etc.* 23d Edition. 79 Illustrations. \$1.00
- "In the fullest sense, Dr. Humphrey's book is a distinct advance on all previous manuals. It is, in point of fact, a concise treatise on medicine and surgery for the beginner, incorporating with the text the management of childbed and the hygiene of the sick-room. Its value is greatly enhanced by copious wood-cuts and diagrams of the bones and internal organs."—*British Medical Journal, London.*
- STARR.** *The Hygiene of the Nursery. Including the General Regimen and Feeding of Infants and Children, and the Domestic Management of the Ordinary Emergencies of Early Life, Massage, etc.* 6th Edition. 25 Illustrations. \$1.00
- TEMPERATURE AND CLINICAL CHARTS.** See page 6.
- VOSWINKEL.** *Surgical Nursing.* Second Edition, Enlarged. 112 Illustrations. \$1.00

## OBSTETRICS.

- CAZEAUX AND TARNIER.** *Midwifery.* With Appendix by MUNDÉ. The Theory and Practice of Obstetrics, including the Diseases of Pregnancy and Parturition, Obstetrical Operations, etc. 8th Edition. Illustrated by Colored and other full-page Plates, and numerous Wood Engravings. Cloth, \$4.50; Full Leather, \$5.50
- EDGAR.** *Text-Book of Obstetrics.* Illustrated. *Preparing.*
- FULLERTON.** *Obstetric Nursing.* 5th Ed. Illustrated. \$1.00
- LANDIS.** *Compend of Obstetrics.* 7th Edition, Revised by WM. H. WELLS, Demonstrator of Clinical Obstetrics, Jefferson Medical College. 52 Illustrations. .80; Interleaved, \$1.00
- WINCKEL.** *Text-Book of Obstetrics, Including the Pathology and Therapeutics of the Puerperal State.* Authorized Translation by J. CLIFTON EDGAR, M.D. Illus. Cloth, \$5.00

## PATHOLOGY.

- BARLOW.** *General Pathology.* 795 pages. 8vo. \$5.00
- BLACK.** *Micro-Organisms. The Formation of Poisons.* .75
- BLACKBURN.** *Autopsies. A Manual of Autopsies Designed for the Use of Hospitals for the Insane and other Public Institutions.* Ten full-page Plates and other Illustrations. \$1.25
- CONN.** *Agricultural Bacteriology.* Illus. *Just Ready.* \$2.50
- COPLIN.** *Manual of Pathology. Including Bacteriology, Technic of Post-Mortems, Methods of Pathologic Research, etc.* 330 Illustrations, 7 Colored Plates. 3d Edition. \$3.50
- DA COSTA.** *Clinical Hematology.* Six Colored Plates and 48 Illustrations. *Just Ready.* \$5.00
- EMERY.** *Bacteriological Diagnosis.* *In Press.*
- HEWLETT.** *Manual of Bacteriology.* 75 Illustrations. Second Edition, Revised and Enlarged. *In Press.*
- ROBERTS.** *Gynecological Pathology.* Illus. *Just Ready* \$6.00
- THAYER.** *Compend of General Pathology.* Illustrated. *Nearly Ready.* .80; Interleaved, \$1.00
- THAYER.** *Compend of Special Pathology.* Illustrated. *Nearly Ready.* .80; Interleaved, \$1.00
- VIRCHOW.** *Post-Mortem Examinations.* 3d Edition. .75
- WHITACRE.** *Laboratory Text-Book of Pathology.* With 121 Illustrations. \$1.50
- WILLIAMS.** *Bacteriology. A Manual for Students.* 90 Illustrations. 2d Edition, Revised. \$1.50

## PHARMACY.

*Special Catalogue of Books on Pharmacy sent free upon application.*

- COBLENTZ.** *Manual of Pharmacy.* A Complete Text-Book by the Professor in the New York College of Pharmacy. 2d Edition, Revised and Enlarged. 437 Illus. Cloth, \$3.50; Sheep, \$4.50
- COBLENTZ.** *Volumetric Analysis.* Illustrated. *In Press.*
- BEASLEY.** *Book of 3100 Prescriptions.* Collected from the Practice of the Most Eminent Physicians and Surgeons—English, French, and American. A Compendious History of the *Materia Medica*, Lists of the Doses of all the Official and Established Preparations, an Index of Diseases and their Remedies. 7th Ed. \$2.00



- BEASLEY. Druggists' General Receipt Book.** Comprising a Copious Veterinary Formulary, Recipes in Patent and Proprietary Medicines, Druggists' Nostrums, etc.; Perfumery and Cosmetics, Beverages, Dietetic Articles and Condiments, Trade Chemicals, Scientific Processes, and many Useful Tables. 10th Ed. \$2.00
- BEASLEY. Pharmaceutical Formulary.** A Synopsis of the British, French, German, and United States Pharmacopœias. Comprising Standard and Approved Formulæ for the Preparations and Compounds Employed in Medicine. 12th Edition. \$2.00
- PROCTOR. Practical Pharmacy.** 3d Edition, with Illustrations and Elaborate Tables of Chemical Solubilities, etc. \$3.00
- ROBINSON. Latin Grammar of Pharmacy and Medicine.** 3d Edition. With elaborate Vocabularies. \$1.75
- SAYRE. Organic Materia Medica and Pharmacognosy.** An Introduction to the Study of the Vegetable Kingdom and the Vegetable and Animal Drugs. Comprising the Botanical and Physical Characteristics, Source, Constituents, and Pharmacopœial Preparations, Insects Injurious to Drugs, and Pharmacal Botany. With sections on Histology and Microtechnique, by W. C. STEVENS. 374 Illustrations. Second Edition. Cloth, \$4.50
- SCOVILLE. The Art of Compounding.** Second Edition, Revised and Enlarged. Cloth, \$2.50
- STEWART. Compend of Pharmacy.** Based upon "Remington's Text-Book of Pharmacy." 5th Edition, Revised in Accordance with the U. S. Pharmacopœia, 1890. Complete Tables of Metric and English Weights and Measures. .80; Interleaved, \$1.00
- TAVERA. Medicinal Plants of the Philippines.** *Just Ready.* \$2.00
- UNITED STATES PHARMACOPŒIA.** 7th Decennial Revision. Cloth, \$2.50 (postpaid, \$2.77); Sheep, \$3.00 (postpaid, \$3.27); Interleaved, \$4.00 (postpaid, \$4.50); Printed on one side of page only, unbound, \$3.50 (postpaid, \$3.90).  
 Select Tables from the U. S. P. Being Nine of the Most Important and Useful Tables, Printed on Separate Sheets. .25
- POTTER. Hand-Book of Materia Medica, Pharmacy, and Therapeutics.** 600 Prescriptions. 8th Ed. Clo., \$5.00; Sh., \$6.00

## PHYSIOLOGY.

- BIRCH. Practical Physiology.** An Elementary Class Book. 62 Illustrations. \$1.75
- BRUBAKER. Compend of Physiology.** 10th Edition, Revised and Enlarged. Illustrated. .80; Interleaved, \$1.00
- JONES. Outlines of Physiology.** 96 Illustrations. \$1.50
- KIRKES. Handbook of Physiology.** 17th Authorized Edition. Revised, Rearranged, and Enlarged. By PROF. W. D. HALLIBURTON, of Kings College, London. 681 Illustrations, some of which are in colors. Cloth, \$3.00; Leather, \$3.75

- LANDOIS.** A Text-Book of Human Physiology, Including Histology and Microscopical Anatomy, with Special Reference to the Requirements of Practical Medicine. 5th American, translated from the 9th German Edition, with Additions by Wm. STIRLING, M.D., D.Sc. 845 Illus., many of which are printed in colors. *In Press.*
- STARLING.** Elements of Human Physiology. 100 Ills. \$1.00
- STIRLING.** Outlines of Practical Physiology. Including Chemical and Experimental Physiology, with Special Reference to Practical Medicine. 3d Edition. 289 Illustrations. \$2.00
- TYSON.** Cell Doctrine. Its History and Present State. \$1.50

## PRACTICE.

- BEALE.** On Slight Ailments; their Nature and Treatment. 2d Edition, Enlarged and Illustrated. \$1.25
- FAGGE.** Practice of Medicine. 4th Edition, by P. H. PYE-SMITH, M.D. 2 Volumes. *In Press.*
- FOWLER.** Dictionary of Practical Medicine. By various writers. An Encyclopædia of Medicine. Clo., \$3.00; Half Mor. \$4.00
- GOULD AND PYLE.** Cyclopædia of Practical Medicine and Surgery. A Concise Reference Handbook, Alphabetically Arranged, with particular Reference to Diagnosis and Treatment. Edited by Drs. GOULD and PYLE, Assisted by 72 Special Contributors. Illustrated, one volume. Large Square Octavo, Uniform with "Gould's Illustrated Dictionary."  
Sheep or Half Morocco, \$10.00; with Thumb Index, \$11.00  
Half Russia, Thumb Index, \$12.00

*☞ Complete descriptive circular free upon application.*

- HUGHES.** Compend of the Practice of Medicine. 6th Edition, Revised and Enlarged.
- Part I. Continued, Eruptive, and Periodical Fevers, Diseases of the Stomach, Intestines, Peritoneum, Biliary Passages, Liver, Kidneys, etc., and General Diseases, etc.
- Part II. Diseases of the Respiratory System, Circulatory System, and Nervous System; Diseases of the Blood, etc.  
Price of each part, .80; Interleaved, \$1.00
- Physician's Edition.** In one volume, including the above two parts, a Section on Skin Diseases, and an Index. 6th Revised Edition. 625 pp. Full Morocco, Gilt Edge, \$2.25
- MURRAY.** Rough Notes on Remedies. 4th Ed. *Just Ready.* \$1.25
- TAYLOR.** Practice of Medicine. 6th Edition. *Just Ready.* \$4.00
- TYSON.** The Practice of Medicine. By JAMES TYSON, M.D., Professor of Medicine in the University of Pennsylvania. A Complete Systematic Text-book with Special Reference to Diagnosis and Treatment. 2d Edition, Enlarged and Revised. Colored Plates and 125 other Illustrations. 1222 Pages. Cloth, \$5.50; Leather, \$6.50

## PRESCRIPTION BOOKS.

- BEASLEY.** Book of 3100 Prescriptions. Collected from the Practice of the Most Eminent Physicians and Surgeons—English, French, and American. A Compendious History of the Materia Medica, Lists of the Doses of all Official and Established Preparations, and an Index of Diseases and their Remedies. 7th Ed. \$2.00

- BEASLEY. Druggists' General Receipt Book.** Comprising a Copious Veterinary Formulary, Recipes in Patent and Proprietary Medicines, Druggists' Nostrums, etc.; Perfumery and Cosmetics, Beverages, Dietetic Articles and Condiments, Trade Chemicals, Scientific Processes, and an Appendix of Useful Tables. 10th Edition, Revised. \$2.00
- BEASLEY. Pocket Formulary.** A Synopsis of the British, French, German, and United States Pharmacopœias and the chief unofficial Formularies. 12th Edition. \$2.00

## SKIN.

- BULKLEY. The Skin in Health and Disease.** Illustrated. .40
- CROCKER. Diseases of the Skin.** Their Description, Pathology, Diagnosis, and Treatment, with Special Reference to the Skin Eruptions of Children. 92 Illus. 3d Edition. *Preparing.*
- SCHAMBERG. Diseases of the Skin.** 2d Edition, Revised and Enlarged. 105 Illustrations. Being No. 16 of Quiz-Compend? Series. Cloth, .80; Interleaved, \$1.00
- VAN HARLINGEN. On Skin Diseases.** A Practical Manual of Diagnosis and Treatment, with special reference to Differential Diagnosis. 3d Edition, Revised and Enlarged. With Formulæ and 60 Illustrations, some of which are printed in colors. \$2.75

## SURGERY AND SURGICAL DISEASES (see also Urinary Organs).

- BERRY. Diseases of the Thyroid Gland and Their Surgical Treatment.** Illustrated. *Just Ready.* \$4.00
- BUTLIN. Operative Surgery of Malignant Disease.** 2d Edition. Illustrated. Octavo. \$4.50
- DEAVER. Surgical Anatomy.** A Treatise on Human Anatomy in its Application to Medicine and Surgery. With about 400 very Handsome full-page Illustrations Engraved from Original Drawings made by special Artists from Dissections prepared for the purpose. Three Volumes. Royal Square Octavo. Cloth, \$21.00; Half Morocco or Sheep, \$24.00; Half Russia, \$27.00  
*Complete descriptive circular and special terms upon application.*
- DEAVER. Appendicitis, Its Symptoms, Diagnosis, Pathology, Treatment, and Complications.** Elaborately Illustrated with Colored Plates and other Illustrations. 2d Edition. \$3.50
- DULLES. What to Do First in Accidents and Poisoning.** 5th Edition. New Illustrations. \$1.00
- FULLERTON. Surgical Nursing.** 3d Edition. 69 Illus. \$1.00
- HAMILTON. Lectures on Tumors.** 3d Edition. \$1.25
- HEATH. Minor Surgery and Bandaging.** 12th Edition, Revised and Enlarged. 195 Illus., Formulæ, Diet List, etc. *Just Ready.* \$1.50
- HEATH. Injuries and Diseases of the Jaws.** 4th Ed. \$4.50
- HORWITZ. Compend of Surgery and Bandaging,** including Minor Surgery, Amputations, Fractures, Dislocations, Surgical Diseases, and the Latest Antiseptic Rules, etc., with Differential Diagnosis and Treatment. 5th Edition, very much Enlarged and Rearranged. 167 Illustrations, 98 Formulæ. Clo., .80; Interleaved, \$1.00

- JACOBSON.** Operations of Surgery. Over 200 Illustrations.  
Cloth, \$3.00; Leather, \$4.00
- KEHR.** Gall-Stone Disease. Translated by WILLIAM WOTKYNs  
SEYMOUR, M.D. \$2.50
- LANE.** Surgery of the Head and Neck. 110 Illus. \$5.00
- MACREADY.** A Treatise on Ruptures. 24 Full-page Litho-  
graphed Plates and Numerous Wood Engravings. Cloth, \$6.00
- MAKINS.** Surgical Experiences in South Africa. 1899-1900.  
Illustrated. \$4.00
- MAYLARD.** Surgery of the Alimentary Canal. 97 Illustrations.  
2d Edition, Revised. \$3.00
- MOULLIN.** Text-Book of Surgery. With Special Reference to  
Treatment. 3d American Edition. Revised and edited by JOHN B.  
HAMILTON, M.D., LL.D., Professor of the Principles of Surgery and  
Clinical Surgery, Rush Medical College, Chicago. 623 Illustrations,  
many of which are printed in colors. Cloth, \$6.00; Leather, \$7.00
- SMITH.** Abdominal Surgery. Being a Systematic Description of  
all the Principal Operations. 224 Illus. 6th Ed. 2 Vols. Clo., \$10.00
- VOSWINKEL.** Surgical Nursing. Second Edition, Revised and  
Enlarged. 111 Illustrations. \$1.00
- WALSHAM.** Manual of Practical Surgery. 7th Ed.,  
revised and Enlarged. 483 Engravings. 950 pages. \$3.50

## TEMPERATURE CHARTS, ETC.

- GRIFFITH.** Graphic Clinical Chart for Recording Temper-  
ature, Respiration, Pulse, Day of Disease, Date, Age, Sex,  
Occupation, Name, etc. Printed in three colors. Sample copies  
free. Put up in loose packages of fifty, .50. Price to Hospitals, 500  
copies, \$4.00; 1000 copies, \$7.50. With name of Hospital printed  
on, 50 cts. extra.
- KEEN'S CLINICAL CHARTS.** Seven Outline Drawings of the  
Body, on which may be marked the Course of Disease, Fractures,  
Operations, etc. Each Drawing may be had separately, twenty-five  
to pad, 25 cents.
- SCHREINER.** Diet Lists. Arranged in the form of a chart.  
With Pamphlets of Specimen Diets. Pads of 50. .75

## THROAT AND NOSE (see also Ear).

- COHEN.** The Throat and Voice. Illustrated. .40
- HALL.** Diseases of the Nose and Throat. 2d Edition, Enlarged.  
Two Colored Plates and 80 Illustrations. \$2.75
- HOLLOPETER.** Hay Fever. Its Successful Treatment. \$1.00
- KNIGHT.** Diseases of the Throat. A Manual for Students.  
Illustrated. *Nearly Ready.*
- LAKE.** Laryngeal Phthisis, or Consumption of the Throat.  
Colored Illustrations. \$2.00
- MACKENZIE.** Pharmacopœia of the London Hospital for  
Dis. of the Throat. 5th Ed., Revised by Dr. F. G. HARVEY. \$1.00
- MCBRIDE.** Diseases of the Throat, Nose, and Ear. With col-  
ored Illustrations from original drawings. 3d Edition. \$7.00
- POTTER.** Speech and its Defects. Considered Physiologically,  
Pathologically, and Remedially. \$1.00
- SHEILD.** Nasal Obstructions. Illustrated. \$1.50

## URINE AND URINARY ORGANS.

- ACTON.** The Functions and Disorders of the Reproductive  
Organs in Childhood, Youth, Adult Age, and Advanced Life,  
Considered in their Physiological, Social, and Moral Relations.  
8th Edition. \$1.75

- BEALE.** One Hundred Urinary Deposits. On eight sheets, for the Hospital, Laboratory, or Surgery. Paper, \$2.00
- HOLLAND.** The Urine, the Gastric Contents, the Common Poisons, and the Milk. Memoranda, Chemical and Microscopical, for Laboratory Use. Illustrated and Interleaved. 6th Ed. \$1.00
- KLEEN.** Diabetes and Glycosuria. \$2.50
- MEMMINGER.** Diagnosis by the Urine. 2d Ed. 24 Illus. \$1.00
- MORRIS.** Renal Surgery, with Special Reference to Stone in the Kidney and Ureter and to the Surgical Treatment of Calculous Anuria. Illustrated. \$2.00.
- MOULLIN.** Enlargement of the Prostate. Its Treatment and Radical Cure. 2d Edition. Illustrated. \$1.75
- MOULLIN.** Inflammation of the Bladder and Urinary Fever. Octavo. \$1.50
- SCOTT.** The Urine. Its Clinical and Microscopical Examination. 41 Lithographic Plates and other Illustrations. Quarto. Cloth, \$5.00
- TYSON.** Guide to Examination of the Urine. For the Use of Physicians and Students. With Colored Plate and Numerous Illustrations engraved on wood. 9th Edition, Revised. \$1.25
- VAN NUYS.** Chemical Analysis of Urine. 39 Illus. \$1.00

## VENEREAL DISEASES.

- GOWERS.** Syphilis and the Nervous System. \$1.00
- STURGIS AND CABOT.** Student's Manual of Venereal Diseases. 7th Revised and Enlarged Ed. 12mo. \$1.25

## VETERINARY.

- BALLOU.** Veterinary Anatomy and Physiology. 29 Graphic Illustrations. .80; Interleaved, \$1.00

## WOMEN, DISEASES OF.

- BISHOP.** Uterine Fibromyomata. Their Pathology, Diagnosis, and Treatment. Illustrated. Cloth, \$3.50
- BYFORD (H. T.).** Manual of Gynecology. Second Edition, Revised and Enlarged by 100 pages. 341 Illustrations. \$3.00
- DÜHRSSEN.** A Manual of Gynecological Practice. 105 Illustrations. \$1.50
- FULLERTON.** Surgical Nursing. 3d Edition, Revised and Enlarged. 69 Illustrations. \$1.00
- LEWERS.** Diseases of Women. 146 Illus. 5th Ed. \$2.50
- MONTGOMERY.** Practical Gynecology. A Complete Systematic Text-Book. 527 Illustrations. Cloth, \$5.00; Leather, \$6.00
- ROBERTS.** Gynecological Pathology. With 127 Full-page Plates containing 151 Figures. *Just Ready.* \$6.00
- WELLS.** Compend of Gynecology. Illustrated. 2d Edition. .80; Interleaved, \$1.00

## COMPENDS.

### *From The Southern Clinic.*

"We know of no series of books issued by any house that so fully meets our approval as these ?Quiz-Compend??. They are well arranged, full, and concise, and are really the best line of text-books that could be found for either student or practitioner."

## BLAKISTON'S ?QUIZ-COMPENDS?

The Best Series of Manuals for the Use of Students.

Price of each, Cloth, .80. Interleaved, for taking Notes, \$1.00.

☞ These Compends are based on the most popular text-books and the lectures of prominent professors, and are kept constantly revised, so that they may thoroughly represent the present state of the subjects upon which they treat.

☞ The authors have had large experience as Quiz-Masters and attaches of colleges, and are well acquainted with the wants of students.

☞ They are arranged in the most approved form, thorough and concise, containing over 600 fine illustrations, inserted wherever they could be used to advantage.

☞ Can be used by students of *any* college.

☞ They contain information nowhere else collected in such a condensed, practical shape. Illustrated Circular free.

**No. 1. POTTER. HUMAN ANATOMY.** Sixth Revised and Enlarged Edition. Including Visceral Anatomy. Can be used with either Morris's or Gray's Anatomy. 117 Illustrations and 16 Lithographic Plates of Nerves and Arteries, with Explanatory Tables, etc. By SAMUEL O. L. POTTER, M.D., Professor of the Practice of Medicine, College of Physicians and Surgeons, San Francisco; Brigade Surgeon, U. S. Vol.

**No. 2. HUGHES. PRACTICE OF MEDICINE. Part I.** Sixth Edition, Enlarged and Improved. By DANIEL E. HUGHES, M.D., Physician-in-Chief, Philadelphia Hospital, late Demonstrator of Clinical Medicine, Jefferson Medical College, Phila.

**No. 3. HUGHES. PRACTICE OF MEDICINE. Part II.** Sixth Edition, Revised and Improved. Same author as No. 2.

**No. 4. BRUBAKER. PHYSIOLOGY.** Tenth Edition, with Illustrations and a table of Physiological Constants. Enlarged and Revised. By A. P. BRUBAKER, M.D., Professor of Physiology and General Pathology in the Pennsylvania College of Dental Surgery; Adjunct Professor of Physiology, Jefferson Medical College, Philadelphia, etc.

**No. 5. LANDIS. OBSTETRICS.** Seventh Edition. By HENRY G. LANDIS, M.D. Revised and Edited by WM. H. WELLS, M.D., Demonstrator of Clinical Obstetrics, Jefferson Medical College, Philadelphia. Enlarged. 52 Illustrations.

**No. 6. POTTER. MATERIA MEDICA, THERAPEUTICS, AND PRESCRIPTION WRITING.** Sixth Revised Edition (U. S. P. 1890). By SAMUEL O. L. POTTER, M.D., Professor of Practice, College of Physicians and Surgeons, San Francisco; Brigade Surgeon, U. S. Vol.

### ? QUIZ-COMPENDS ?—Continued.

- No. 7. WELLS. GYNECOLOGY.** Second Edition. By **WM. H. WELLS, M.D.**, Demonstrator of Clinical Obstetrics, Jefferson Medical College, Philadelphia. 140 Illustrations.
- No. 8. GOULD AND PYLE. DISEASES OF THE EYE AND REFRACTION.** Second Edition. Including Treatment and Surgery, and a Section on Local Therapeutics. By **GEORGE M. GOULD, M.D.**, and **W. L. PYLE, M.D.** With Formulæ, Glossary Tables, and 109 Illustrations, several of which are Colored.
- No. 9. HORWITZ. SURGERY, Minor Surgery, and Bandaging.** Fifth Edition, Enlarged and Improved. By **ORVILLE HORWITZ, B.S., M.D.**, Clinical Professor of Genito-Urinary Surgery and Venereal Diseases in Jefferson Medical College; Surgeon to Philadelphia Hospital, etc. With 98 Formulæ and 71 Illustrations.
- No. 10. LEFFMANN. MEDICAL CHEMISTRY.** Fourth Edition. Including Urinalysis, Animal Chemistry, Chemistry of Milk, Blood, Tissues, the Secretions, etc. By **HENRY LEFFMANN, M.D.**, Professor of Chemistry in the Woman's Medical College of Penna; Pathological Chemist, Jefferson Medical College Hospital.
- No. 11. STEWART. PHARMACY.** Fifth Edition. Based upon Prof. Remington's Text-Book of Pharmacy. By **F. E. STEWART, M.D., PH.G.**, late Quiz-Master in Pharmacy and Chemistry, Philadelphia College of Pharmacy; Lecturer at Jefferson Medical College. Carefully revised in accordance with the new U. S. P.
- No. 12. BALLOU. VETERINARY ANATOMY AND PHYSIOLOGY.** Illustrated. By **WM. R. BALLOU, M.D.**, Professor of Equine Anatomy at New York College of Veterinary Surgeons; Physician to Bellevue Dispensary, etc. 29 graphic Illustrations
- No. 13. WARREN. DENTAL PATHOLOGY AND DENTAL MEDICINE.** Third Edition, Illustrated. Containing a Section on Emergencies. By **GEO. W. WARREN, D.D.S.**, Chief of Clinical Staff, Pennsylvania College of Dental Surgery.
- No. 14. HATFIELD. DISEASES OF CHILDREN.** Second Edition. Colored Plate. By **MARCUS P. HATFIELD**, Professor of Diseases of Children, Chicago Medical College.
- No. 15. THAYER. GENERAL PATHOLOGY.** By **A. E. THAYER, M.D.**, Cornell University Medical College. Illustrated.
- No. 16. SCHAMBERG. DISEASES OF THE SKIN.** Second Edition. By **JAY F. SCHAMBERG, M.D.**, Professor of Diseases of the Skin, Philadelphia Polyclinic. Second Edition, Revised and Enlarged. 105 handsome Illustrations.
- No. 17. CUSHING. HISTOLOGY.** By **H. H. CUSHING, M.D.**, Demonstrator of Histology, Jefferson Medical College, Philadelphia. Illustrated.
- No. 18. THAYER. SPECIAL PATHOLOGY.** Illustrated. By same Author as No. 15.

Price, each, Cloth, .80. Interleaved, for taking Notes, \$1.00.

Careful attention has been given to the construction of each sentence, and while the books will be found to contain an immense amount of knowledge in small space, they will likewise be found easy reading; there is no stilted repetition of words; the style is clear, lucid, and distinct. The arrangement of subjects is systematic and thorough; there is a reason for every word. They contain over 600 illustrations.

THE STANDARD TEXT-BOOK

# MORRIS' ANATOMY

SECOND EDITION

Rewritten. Revised. Improved

WITH MANY NEW ILLUSTRATIONS

---

Has been recommended as a text-book at more than seventy of the most prominent medical schools in the United States and Canada, and is considered by all anatomists as a standard authority. It contains many features of special advantage to students. A complete Text-book. Edited by HENRY MORRIS, F.R.C.S., Surgeon to, and Lecturer on Anatomy at, Middlesex Hospital, assisted by J. BLAND SUTTON, F.R.C.S., J. H. DAVIES-COLLEY, F.R.C.S., WM. J. WALSHAM, F.R.C.S., H. ST. JOHN BROOKS, M.D., R. MARCUS GUNN, F.R.C.S., ARTHUR HENSMAN, F.R.C.S., FREDERICK TREVES, F.R.C.S., WILLIAM ANDERSON, F.R.C.S., PROF. W. H. A. JACOBSON, and ARTHUR ROBINSON, M.R.C.S.

**Octavo. With 790 Illustrations, of which a large number are printed in colors**

**CLOTH, \$6.00; LEATHER, \$7.00**

---

“The ever-growing popularity of the book with teachers and students is an index of its value, and it may safely be recommended to all interested.”—From *The Medical Record*, New York.

“Of all the text-books of moderate size on human anatomy in the English language, Morris is undoubtedly the most up-to-date and accurate.”—From *The Philadelphia Medical Journal*.

---

**THUMB INDEX IN EACH COPY**



## Eighth Revised Edition.

**POTTER'S MATERIA MEDICA, PHARMACY, AND THERAPEUTICS.** Eighth Edition, Enlarged and Revised. A Handbook, including the Physiological Action of Drugs, Special Therapeutics of Disease, Official and Practical Pharmacy, Prescription Writing, etc. By SAMUEL O. L. POTTER, M.A., M.D., formerly Professor of the Practice of Medicine, Cooper Medical College, San Francisco; late Major and Brigade Surgeon, U. S. Vol., etc. Octavo. 950 pages. Thumb Index.

Cloth, *net*, \$5.00; Leather, *net*, \$6.00

### A UNIQUE BOOK.

The present edition contains material gathered from the writer's experience in active professional practice in a tropical climate, among soldiers and civilians, men, women, and children, during a period of nearly two years' duration.

The text throughout the book has again been subjected to a thorough and critical revision, has been largely rewritten, and has been expanded by the introduction of much new matter. The latter has to some extent taken the place of material considered obsolete or comparatively unimportant, so that the increased size of the book over the previous edition is only twenty pages.

In the section on *Materia Medica* twelve articles have been rewritten and thirty-eight new articles have been inserted. The rewritten ones are those on *Argentum*, *Cinchona*, *Coca*, *Coffea*, *Digitalis*, *Dulcin*, *Ergot*, *Ferrum*, *Ipecacuanha*, *Myrrha*, *Saccharinum*, and *Veratrum Viride*. The new matter includes paragraphs on *Actol*, *Airol*, *Argentamin*, *Argentol*, *Argonin*, *Chinosol*, *Creosotal*, *Dionine*, *Eucaine*, *Eudoxin*, *Glycero-phosphates*, *Heroine*, *Holocaine*, *Iodothyrim*, *Itrol*, *Largin*, *Nosophen*, *Orphol*, *Orthoform*, *Passiflora*, *Pellotine*, *Peronine*, *Phloridzin*, *Piperidin*, *Protargol*, *Tuberculin-R*, *Urotropin*, and *Xeroform*.

In the section on *Therapeutics* new articles are inserted on *Local Anesthesia*, *Beriberi*, *Dhobie Itch*, *Tropical Fevers*, *Heat-stroke*, *Hemoglobinuric Fever*, *Lymphadenoma*, *Millaria*, *Bubonic Plague*, *Sprue*, *Tinea Imbricata*, *Tinea Versicolor*, and *Toxemia*. Twenty-eight articles in this portion of the book have been rewritten, including those on *Amenorrhœa*, *Asthma*, *Boils*, *Cholera*, *Diabetes*, *Dysentery*, *Dyspnea*, *Gonorrhœa*, *Insomnia*, *Leprosy*, *Lucocythemia*, *Lichen*, *Myxedema*, *Pemphigus*, *Phthisis*, *Remittent Fever*, *Typhoid Fever*, *Septicemia*, *Shock*, *Suppuration*, *Ulcers*, *Uremia*, *Variola*, and *Wounds*. The text of many other articles has been expanded by the incorporation of more than two hundred items from current medical literature and from the author's personal experience in practice.

### ARRANGEMENT OF CONTENTS.

INTRODUCTION.—Administration of Drugs, Classification, Dosage, etc.

PART I.—*Materia Medica* and *Therapeutics*, arranged alphabetically; under each drug is given its *Synonym*, *Description*, *Preparations*, *Analogous Compounds*, *Derivatives*, and *Doses*, official and unofficial; *Physiological Action*; *Antagonists*, *Antidotes*; *Therapeutics*.

PART II.—*Pharmacy* and *Prescription Writing*; *Constituents of Vegetable Drugs*; *Weights and Measures*; *Incompatibility*; *Extemporaneous Pharmacy*, etc. Written for the physician who prefers to, or must from necessity, dispense his own medicines.

PART III.—*Special Therapeutics*. Consists of 280 pages, in which diseases are taken up in alphabetical order and the treatment indicated in each concisely stated. This section contains a vast number of suggestions and over 650 *Prescriptions*, *Formulæ*, etc.

APPENDIX, containing many useful *Tables of Differential Diagnosis*, *Lists of Latin Phrases*, *Hyperdermic and Patent Medicine Formulæ*, etc.

INDEX, 38 pages, double column, very carefully prepared.

# **FOR MEDICAL STUDENTS.**

TAYLOR AND WELLS. DISEASES OF CHILDREN. Illustrated by Louis Marsson, T. ...

**THE LIBRARY**  
**UNIVERSITY OF CALIFORNIA, SAN FRANCISCO**  
**(415) 476-2335**

**THIS BOOK IS DUE ON THE LAST DATE STAMPED BELOW**

Books not returned on time are subject to fines according to the Library Lending Code. A renewal may be made on certain materials. For details consult Lending Code.

**28 DAY**

**JUL 22 1995**

**RETURNED**

**AUG 30 1995**

Series 4128

**P. BLAKISTON'S SON & CO., Publishers and Booksellers,**  
**1012 WALNUT STREET, PHILADELPHIA.**

# FOR MEDICAL STUDENTS.

**KIRKES' PHYSIOLOGY.** Seventeenth Edition. (*The Authorized Edition. 12mo. Dark Red Cloth.*) Revised and Enlarged. By W. D. HALLIBURTON, M.D., F.R.S., Professor of Physiology, King's College, London. 681 Illustrations, a number of which are printed in Colors. Cloth, net, \$3.00

**STÖHR. TEXT-BOOK OF HISTOLOGY, INCLUDING THE MICROSCOPICAL TECHNIC.** By DR. PHILIP STÖHR, Professor of Anatomy at University of Würzburg. Authorized Translation. Edited, with Additions, by DR. ALFRED SCHAPER, Professor of Anatomy, Uni-

ve	QM28	Potter, S.O. L.	85937	Medical
Sc	P86	A compend of human anatomy.		on, En-
la	1902	6th ed.		\$3.00
HAL				By F.
DR	STU			minster
H				1; and
H				ospital,
G				London
Pe				\$2.75
WILL				ERT U.
W				cal De-
pa				larged.
W				\$1.50
TYSC				Ninth
F				te
				-
				5
TYSC				1
				-

RE  
SV  
BY  
BA  
P.

85937

631644



3 1378 00631 6445

